

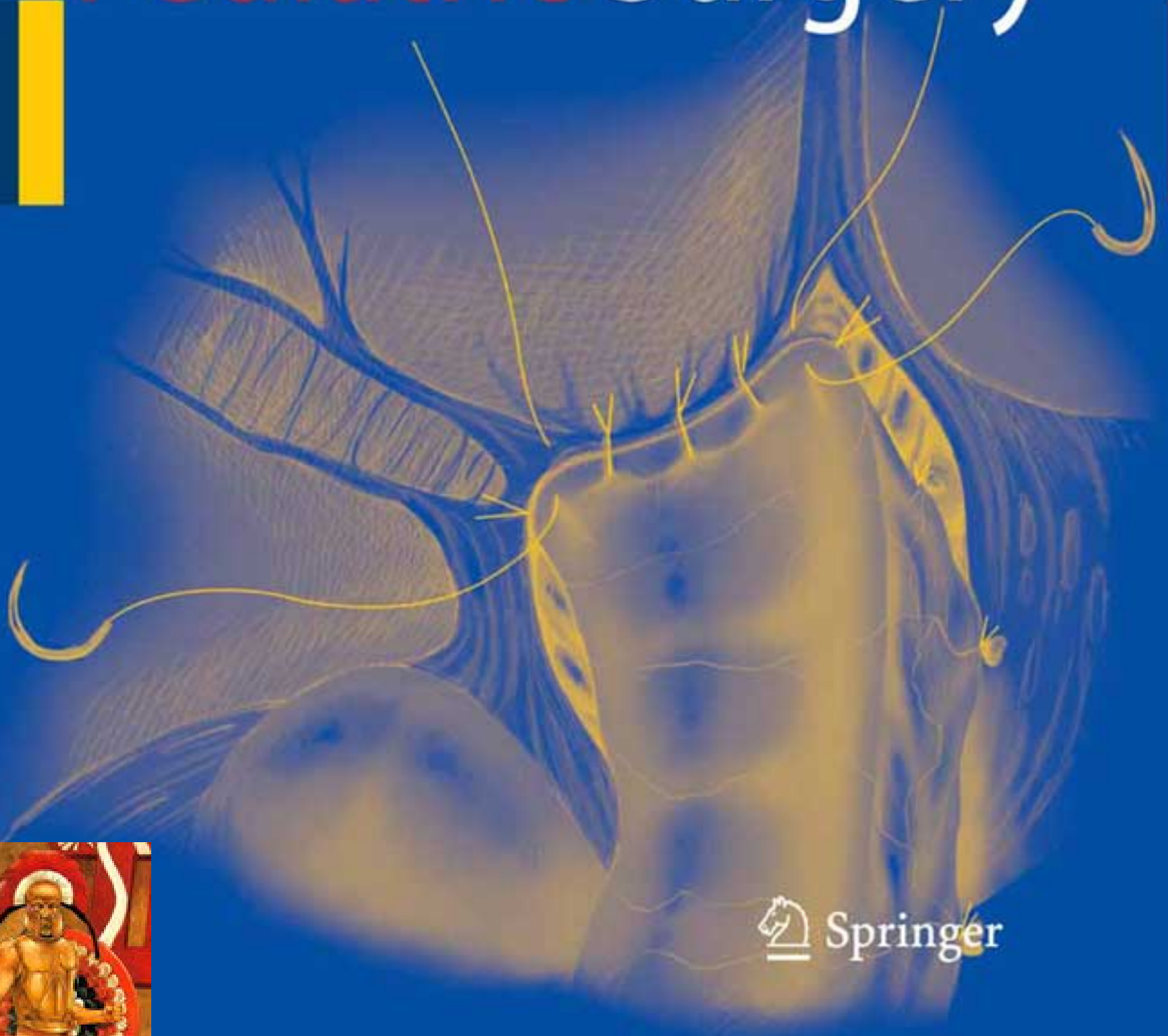


Springer Surgery Atlas Series

Series Editors: J. S. P. Lumley · J. R. Siewert

P. Puri
M. Höllwarth
Editors

Pediatric Surgery



Springer



SPRINGER SURGERY ATLAS SERIES

Series Editors: J. S. P. Lumley · J. R. Siewert



P. Puri · M. E. Höllwarth (Eds.)

Pediatric Surgery

With 589 Color Figures,
in 666 separate Illustrations

 Springer

Prem Puri MS, FRCS, FRCS (Ed), FACS
Newman Clinical Research Professor,
University College, Dublin
Consultant Paediatric Surgeon and
Director of Research Children's Research Centre
Our Lady's Hospital for Sick Children
Crumlin
Dublin 12, Ireland

Michael E. Höllwarth MD
Professor & Head
Department of Paediatric Surgery
Medical University of Graz
Auenbruggerplatz
8036 Graz
Austria

ISBN-10 3-540-40738-3
Springer-Verlag Berlin Heidelberg New York
ISBN-13 978-3-540-40738-6
Springer-Verlag Berlin Heidelberg New York

Library of Congress Control Number: 2004104708

This work is subject to copyright. All rights are reserved, whether the whole or part of the material is concerned, specifically the rights of translation, reprinting, reuse of illustrations, recitation, broadcasting, reproduction on microfilm or in any other way, and storage in data banks. Duplication of this publication or parts thereof is permitted only under the provisions of the German Copyright Law of September 9, 1965, in its current version, and permission for use must always be obtained from Springer. Violations are liable to prosecution under the German Copyright Law.

Springer is a part of Springer Science+Business Media
springeronline.com
© Springer-Verlag Berlin Heidelberg 2006
Printed in Germany

The use of general descriptive names, registered names, trademarks, etc. in this publication does not imply, even in the absence of a specific statement, that such names are exempt from the relevant protective laws and regulations and therefore free for general use.

Product liability: the publishers cannot guarantee the accuracy of any information about dosage and application contained in this book. In every individual case the user must check such information by consulting the relevant literature.

Editor: Gabriele Schröder, Heidelberg, Germany
Desk Editor: Stephanie Benko, Heidelberg, Germany
Wissenschaftliche Zeichnungen: Reinhold Henkel, Heidelberg
Production: ProEdit GmbH, 69126 Heidelberg, Germany
Cover: Frido-Steinen-Broo, EStudio, Calamar, Spain
Typesetting: K. Detzner, 67346 Speyer, Germany

Printed on acid-free paper 21/3151 ML 5 4 3 2 1 0



Preface

During the past two decades major advances in prenatal diagnosis, imaging, resuscitation, intensive care, minimally invasive surgery and operative techniques have radically altered the management of infants and children with surgical conditions. There are now several excellent paediatric surgery texts available which focus on the historical background, embryogenesis, pathophysiology, diagnosis and management of childhood surgical disorders. The main aim of this new textbook on paediatric surgery was to provide a comprehensive description of operative techniques for various conditions in children. The book contains contributions by outstanding and well-known paediatric surgeons and paediatric urologists from five continents. Each contributor was selected to provide an authoritative, comprehensive and complete account of their respective topic. The text is organised in a systematic manner, providing step-by-step, detailed practical advice on the operative approach in the management of congenital and ac-

quired conditions in infants and children. The book is intended for trainees in paediatric surgery, established paediatric surgeons, paediatric urologists and general surgeons with an interest in paediatric surgery. It is our sincere hope that the readers will find this volume a useful reference in the operative management of childhood surgical disorders.

We wish to thank all the contributors most sincerely for their outstanding work in producing this innovative textbook. We are indebted to Reinhold Henkel for his excellent artwork. We wish to express our gratitude to Karen Alfred, Louise McCrossan (Dublin) and Gudrun Raber (Graz) for their skilful secretarial help. Finally we wish to thank the editorial staff of Springer, particularly Gabriele Schroeder, who has been behind each step of this book, from its original concept to its delivery.

Prem Puri
Michael Höllwarth

Contents

PART I HEAD and NECK

- Chapter 1 Thyroglossal Duct Cyst** 3
Michael E. Höllwarth
- Chapter 2 Branchial Cysts and Sinus** 7
Michael E. Höllwarth
- Chapter 3 Cystic Hygroma** 13
Baird M. Smith, Craig T. Albanese
- Chapter 4 Tracheostomy** 19
Thom E. Lobe

PART II OESOPHAGUS

- Chapter 5 Oesophageal Atresia** 29
Michael E. Höllwarth, Paola Zaupa
- Chapter 6 Gastro-oesophageal Reflux and Hiatus Hernia** 49
Keith E. Georgeson
- Chapter 7 Achalasia** 61
Paul K. H. Tam
- Chapter 8 Colonic Replacement of the Oesophagus** 67
Alaa Hamza
- Chapter 9 Gastric Transposition for Oesophageal Replacement** 77
Lewis Spitz

PART III CHEST

- Chapter 10 Thoracoscopy** 89
Klaas Bax
- Chapter 11 Repair of Pectus Excavatum** 97
Robert C. Shamberger
- Chapter 12 Pulmonary Malformations** 107
Brian T. Sweeney, Keith T. Oldham
- Chapter 13 Congenital Diaphragmatic Hernia and Eventration** 115
Prem Puri

- Chapter 14 Extracorporeal Membrane Oxygenation** 125
Jason S. Frischer, Charles J. H. Stolar

PART IV ABDOMEN

- Chapter 15 Hernias – Inguinal, Umbilical, Epigastric, Femoral and Hydrocele** 139
Juan A. Tovar
- Chapter 16 Omphalocele** 153
Stig Somme, Jacob C. Langer
- Chapter 17 Gastroschisis** 161
Marshall Z. Schwartz
- Chapter 18 Hypertrophic Pyloric Stenosis** 171
Takao Fujimoto
- Chapter 19 Gastrostomy** 181
Michael W. L. Gauderer
- Chapter 20 Malrotation** 197
Agostino Pierro, Evelyn GP Ong
- Chapter 21 Duodenal Obstruction** 203
Yeziel Sweed
- Chapter 22 Jejunio-ileal Atresia** 213
Heinz Rode, Alastair J. W. Millar
- Chapter 23 Meconium Ileus** 229
Massimo Rivosecchi
- Chapter 24 Gastrointestinal Duplications** 239
Mark D. Stringer
- Chapter 25 Short Bowel Syndrome** 257
Michael E. Höllwarth
- Chapter 26 Hirschsprung's Disease** 275
Prem Puri
- Chapter 27 Anorectal Anomalies** 289
Alberto Peña, Marc A. Levitt
- Chapter 28 Intussusception** 313
Karl-Ludwig Waag
- Chapter 29 Appendectomy** 321
Vincenzo Jasonni

- Chapter 30 Omphalomesenteric Duct Remnants** 327
David Lloyd
- Chapter 31 Ulcerative Colitis** 333
Risto J. Rintala
- Chapter 32 Crohn's Disease** 347
Risto J. Rintala

PART V LIVER, PANCREAS AND SPLEEN

- Chapter 33 Biliary Atresia** 357
Ryoji Ohi, Masaki Nio
- Chapter 34 Choledochal Cyst** 371
Takeshi Miyano, Masahiko Urao,
Atsuyuki Yamataka
- Chapter 35 Cholecystectomy** 387
Thom E. Lobe
- Chapter 36 Surgery for Persistent Hyperinsulinaemic Hypoglycaemia of Infancy** 395
Lewis Spitz
- Chapter 37 Splenectomy** 403
Peter Borzi

PART VI SPINA BIFIDA AND HYDROCEPHALUS

- Chapter 38 Spina Bifida** 413
Martin T. Corbally
- Chapter 39 Hydrocephalus** 419
Kai Arnell, Leif Olsen,
Tomas Wester
- Chapter 40 Dermal Sinus** 427
Andrew B. Pinter

PART VII TUMOURS

- Chapter 41 Sacrococcygeal Teratoma** 435
Kevin C. Pringle
- Chapter 42 Neuroblastoma** 443
Edward Kiely
- Chapter 43 Wilms Tumour** 451
Robert Carachi

- Chapter 44 Liver Tumours** 459
Wendy T. Su, Michael P. La Quaglia
- Chapter 45 Testicular Tumours** 477
Jonathan Ross

PART VIII UROLOGY

- Chapter 46 Pyeloplasty** 485
Boris Chertin, Prem Puri
- Chapter 47 Endoscopic Treatment of Vesicoureteral Reflux** 493
Prem Puri
- Chapter 48 Vesicoureteral Reflux – Surgical Treatment** 499
Jack S. Elder
- Chapter 49 Ureteric Duplication** 515
Claude C. Schulman
- Chapter 50 Posterior Urethral Valves** 523
Chester J. Koh, David A. Diamond
- Chapter 51 Hypospadias** 529
Pierre Mouriquand,
Pierre-Yves Mure
- Chapter 52 Phimosis and Buried Penis** 543
Peter Cuckow
- Chapter 53 Orchidopexy** 555
John M. Hutson
- Chapter 54 Variocoele** 569
Michael E. Höllwarth
- Chapter 55 Genitoplasty for Congenital Adrenal Hyperplasia** 577
Amicur Farkas
- Chapter 56 Bladder Exstrophy and Epispadias** 589
Dominic Frimberger,
John P. Gearhart
- Chapter 57 Cloacal Exstrophy** 607
Duncan Wilcox, Manoj Shenoy
- Chapter 58 Augmentation Cystoplasty and Appendicovesicostomy (Mitrofanoff Principle)** 613
Boris Chertin
- Chapter 59 The ACE (Antegrade Continence Enema) Procedure** 623

List of Contributors

Craig T Albanese MD

Professor of Surgery
Chief, Division of Pediatric Surgery
Stanford University Medical Center
Palo Alto, California
USA

Kai Arnell MD

Department of Paediatric Surgery
University Children's Hospital
SE-751 85 Uppsala
Sweden

Klass MA Bax MD, PhD, FRCS (Ed)

Professor of Pediatric Surgery
Wilhelmina Children's Hospital
University Medical Center Utrecht
PO Box 85090, 3508 AB Utrecht
The Netherlands

Peter Borzi MB, BS, FRACS, FRCS

Paediatric Surgery & Paediatric Urology
Taylor Medical Centre
40 Annerley Road
Woolloongabba 4102
Australia

Robert Carachi MD, FRCS

Professor of Paediatric Surgery
Head of Department
Department of Surgical Paediatrics
Royal Hospital for Sick Children
Yorkhill, Glasgow G2 8SJ
UK

Boris Chertin MD

Consultant Pediatric Urologist
Department of Urology
Shaare Zedek Medical Center
Jerusalem, Israel, 91031

Martin T Corbally MCh, FRCSI, FRCS

Consultant Paediatric Surgeon
Our Lady's Hospital for Sick Children
Crumlin
Dublin 12
Ireland

Peter M Cuckow FRCS

Consultant Paediatric Urologist
Great Ormond Street Hospital for Sick Children
30 Guilford Street
London WC1N 1EH
UK

David A Diamond MD

Associate Professor of Surgery (Urology)
Children's Hospital Boston
and Harvard Medical School
300 Longwood Avenue, Hunnewell 3
Boston, MA 02115
USA

Jack S Elder MD

Director
Division of Pediatric Urology
Rainbow Babies & Children's Hospital
11100 Euclid Avenue
Cleveland, OH 44106
USA

Amicur Farkus MD

Professor and Head
Department of Urology
Shaare Zedek Medical Center
Jerusalem, Israel 91031

Dominic Frimberger MD

Johns Hopkins Hospital
Urology, Marburg 149
600N Wolfe St
Baltimore, MD 21287
USA

Takao Fujimoto MD, PhD

Director of Pediatric Surgery
Imperial Gift Foundation
The Aiiiku Maternal & Children's Medical Centre
5-6-8 Minami-Azabu, Minato-Ku
Tokyo 106-8580
Japan

Michael W L Gauderer MD, FACS, FAAP

Professor, Department of Pediatric Surgery
Children's Hospital
Memorial Medical Office Building, Suite 440
890 West Fans Road
Greenville, South Carolina 29605-4253
USA

John P Gearhart MD

Professor & Director
Division of Pediatric Urology
James Buchanan Brady Urological Institute
Johns Hopkins Hospital
Baltimore, Maryland
USA

Keith E Georgeson MD

Professor and Director
Division of Pediatric Surgery
Children's Hospital and Alabama
1600 Seventh Avenue South
Birmingham, Alabama 35233
USA

Alaa F Hamza MD, FRCS

Consultant Paediatric Surgeon
45 Ramsis Street
11341 Heliopolis
Cairo
Egypt

Michael E Höllwarth MD

Professor & Head
Department of Paediatric Surgery
Medical University of Graz
Auenbruggerplatz
A-8036 Graz
Austria

John M Hutson BS, MD(Monash), MD(Melb), FRACS

Professor & Director
General Surgery
Royal Children's Hospital
Parkville, Victoria 3052
Australia

Vincenzo Jasonni MD

Professor and Director
Universita degli Studi di Genova
Largo Gerolamo Gaslini 5
16147 Genova
Italy

Edward Kiely FRCSI, FRCS, FRCPCH

Consultant Paediatric Surgeon
234 Great Portland Street
London W1W 5QT
UK

Chester J Koh MD

Fellow in Pediatric Urology
Children's Hospital Boston
and Harvard Medical School
300 Longwood Avenue, Hunnewell 3
Boston, MA 02115
USA

Jacob C Langer MD

Professor, Chief of Paediatric General Surgery
Hospital for Sick Children
Rm 1526, 555 University Ave
Toronto, ON M5G 1X8
Canada

Michael P La Quaglia MD

Department of Surgery
Memorial Sloan-Kettering Cancer Center
1275 York Ave.
New York, NY 10021
USA

Marc A Levitt MD

Assistant Professor of Surgery and Pediatrics
Schneider Children's Hospital
North Shore-Long Island Jewish Health System
269-01 76th Avenue
New Hyde Park, NY 11040
USA

David A Lloyd Mchir, FRCS, FCS(SA)

Professor of Paediatric Surgery
15 Eshe Road North
Blundellsands
Liverpool L23 8UE
UK

Thom E Lobe MD

Chairman, Section of Pediatric Surgery
Blank Childrens Hospital
Des Moines
Iowa
USA

Padraig S J Malone MCh, FRCSI, FRCS

Consultant Paediatric Urologist
Department of Paediatric Urology
Southampton University Hospitals NHS Trust
Tremona Road
Southampton So16 6YD
Hampshire, UK

Alastair J W Millar FRCS(Eng) (Edin), FRACS, DCH

Consultant Paediatric Surgeon
Department of Paediatric Surgery
Birmingham Childrens Hospital
Birmingham
UK

Takeshi Miyano MD, PhD, FAAP(Hon), FACS, FAPSA (Hon)

Professor and Head
Department of Pediatric Surgery
Juntendo University School of Medicine
2-1-1 Hongo, Bunkyo-ku
Tokyo 113-8421
Japan

Pierre Mouriquand MD, FRCS(Eng), FEBU

Professor, Service d'Urologie Pédiatrique
Hopital Debrousse
29, rue Soeur Bouvier
69322 Lyon Cedex 05
France

Pierre-Yves Mure

Service d'Urologie Pédiatrique
Hopital Debrousse
29, rue Soeur Bouvier
69322 Lyon Cedex 05
France

Masaki Nio MD

Department of Pediatric Surgery
Tohoku University School of Medicine
Sendai, 980
Japan

Ryoji Ohi MD

Professor, Department of Pediatric Surgery
Tohoku University School of Medicine
Sendai, 980
Japan

Keith Oldham MD

Division of Pediatric Surgery
Medical College of Wisconsin
Children's Hospital Office Building
9000 West Wisconsin Av
Milwaukee, Wisconsin 53201
USA

Leif Olsen MD, PhD

Department of Paediatric Surgery
University Children's Hospital
SE-751 85 Uppsala
Sweden

Evelyn G P Ong MBBS, BSc, FRCS (Eng)

Clinical Research Fellow
Paediatric Surgery Unit
Institute of Child Health & Great Ormond Street
Hospital for Children
30 Guilford Street
London WC1N 1EH
UK

Alberto Pena MD

Cincinnati Children's Hospital Medical Center
Cincinnati
USA

Agostino Pierro MD, FRCS (Eng), FRCS (Ed), FAAP

Professor, Department of Paediatric Surgery
Institute of Child Health & Great Ormond Street
Hospital for Children
30 Guilford Street
London WC1N 1EH
UK

Andrew B Pinter

Professor of Paediatric Surgery
Department of Paediatrics/Surgical Unit
Jozsef A. u. 7., 7623
Pecs
Hungary

Kevin C Pringle MB, ChB, FRACS

O&G Health of Department
Capital Coast Health
Private Bag 8902
Riddiford Street
Wellington
South, New Zealand

Prem Puri MS, FRCS, FRCS (Ed), FACS

Consultant Paediatric Surgeon
 Professor & Director of Research
 Children's Research Centre
 Our Lady's Hospital for Sick Children
 Crumlin
 Dublin 12, Ireland

Risto J Rintala MD

Professor, Department of Paediatric Surgery
 Hospital for Children and Adolescents
 University of Helsinki
 PO Box 281
 Fin-00029 Hus
 Finland

Massimo Rivosecchi MD

Professor, Department of Pediatric Surgery
 Bambino Gesù Children's Hospital
 Palidoro
 Rome
 Italy

Heinz Rode Mmed(Chir), FC(SA), FRCSEd

Professor of Paediatric Surgery
 Red Cross Children's Hospital
 Rondebosch 7700
 South Africa

Jonathan Ross MD

Head, Section of Pediatric Urology
 Glickman Urological Institute
 Cleveland Clinic Children's Hospital
 9500 Euclid Avenue
 Cleveland, OH 44195
 USA

Claude C Schulman MD, PhD

Professor
 Hospital Erasme
 Route de Lennik 808
 1070 Bruxelles
 Belgium

Marshall Z Schwartz MD

St. Christopher's Hospital for Children
 Department of Surgery
 Erie Avenue at Front Street
 Philadelphia, PA 19134
 USA

Robert C Shamberger MD

Department of Surgery
 Children's Hospital Boston
 300 Longwood Avenue
 Boston, Massachusetts 02115
 USA

Manoj Shenoy FRCS

Consultant Paediatric Urologist
 City Hospital
 Nottingham
 UK

Baird M Smith MD

Assistant Professor of Surgery
 Division of Pediatric Surgery
 Stanford University
 Palo Alto, California
 USA

Stig Somme MD

Research Fellow
 Department of Surgery
 Hospital for Sick Children
 555 University Avenue
 Toronto, ON M5G 1X8
 Canada

Lewis Spitz MB, ChB, PhD, MD(Hon), FRCS(Edin), FRCS(Eng)

Nuffield Professor of Paediatric Surgery
 Institute of Child Health
 30 Guilford Street
 London WC1N 1EH
 UK

Charles J H Stolar MD

Children's Hospital of New York
 3959 Broadway, 202N
 New York, NY 10032
 USA

Mark D Stringer BSc, MS, FRCS FRCS(Paed), FRCP, FRCPC

Consultant Paediatric Surgeon
 Children's Liver & GI Unit
 Gledhow Wing
 St James's University Hospital
 Leeds LS9 7TF
 UK

Wendy T Su MD

Department of Surgery
Memorial Sloan-Kettering Cancer Center
1275 York Av.
New York, NY 10021
USA

Yeziel Sweed MD

Head, Paediatric Surgery
Western Galilee Hospital
Nahariya
Israel 21/22100

Brian T Sweeney MD

Pediatric Surgery Fellow
Division of Pediatric Surgery
Medical College of Wisconsin
9000 W. Wisconsin Ave.
Milwaukee, WI 53226
USA

Paul Tam MD FRCS

Professor, Division of Paediatric Surgery
University of Hong Kong
Medical Centre
Queen Mary's Hospital
Pokfulam Road
Hong Kong

Juan A Tovar MD

Professor, Department of Pediatric
Surgery Hospital Universitario "La Paz"
Paseo de la Castellana 261
28046 Madrid
Spain

Masahiko Urao MD, PhD

Department of Pediatric Surgery
Juntendo University, School of Medicine
2-1-1 Hongo, Gunkyo-ku
Tokyo 113-8421
Japan

Karl-Ludwig Waag MD

Professor, Department of Paediatric Surgery
Mannheim/Heidelberg
Im Neuenheimer Feld 110
D-69120 Heidelberg
Germany

Tomas Wester MD, PhD

Department of Paediatric Surgery
University Children's Hospital
SE-751 85 Uppsala
Sweden

Duncan Wilcox MD, FRCS (Paed)

Associate Professor
Department of Urology
University of Texas
South Western Medical Center
Dallas, Texas
USA

Atsuyuki Yamataka MD

Department of Pediatric Surgery
Juntendo University School of Medicine
2-1-1 Hongo, Bunkyo-ku
Tokyo 113-8421
Japan

Paola Zaupa MD

Department of Paediatric Surgery
Medical University Graz
Auenbruggerplatz 34
A-8036 Graz
Austria

Michael E. Höllwarth

INTRODUCTION

The median cervical cyst is a remnant of the thyroglossus duct, which runs from the pyramidal lobe of the thyroid gland to the foramen caecum in the dorsal part of the tongue. Embryologically, the thyroid diverticulum develops in a caudal direction from the foramen caecum after formation of the tongue. The thyroid gland descends to the neck in the same period of gestation as the hyoid bone develops from the second branchial arch. The thyroglossal duct may pass in front, behind or through the body of the hyoid bone in the middle of the neck, and islands of thyroid tissue may be found scattered along the tract. At no time during embryogenesis does the thyroglossal duct contact the body surface; the original cysts thus never open to the skin. A fistula can only develop secondarily, e.g., following spontaneous perforation or surgical incision of an infected cyst.

Thyroglossal cysts are the most common tumours of the anterior cervical region. They are usually located in the midline at the level of or somewhat below the hyoid bone. Due to the connection with the foramen caecum of the tongue, the lesion typically moves upwards with swallowing like the thyroid gland, and, different from the latter, also with tongue protrusion. In contrast, dermoid cysts or lymph nodes do not change their position with either act. Ultrasound examination may be helpful, in the first instance to ascertain the presence of a normally situated normally sized thyroid gland as well as to confirm the cystic nature of the mass under consideration. In cases of a suppurative infection, incision and drainage in combination with antibiotics is the appropriate treatment followed by excision once the acute inflammation has settled.

Figure 1.1

Following induction of general anaesthesia with endotracheal intubation, the neck is hyperextended by placing a sandbag or towel roll beneath the shoulders. A horizontal skin incision is made over the cyst. In case of a fistula, the cutaneous orifice is circumcised in a horizontally oriented elliptical fashion. Subcutaneous tissue, platysma and cervical fascia are divided exposing the capsule of the cyst. In cases with previous history of inflammation, these layers may be fibrosed and lack a clear demarcation against each other as well as against the cyst wall. The cyst is carefully separated from the surrounding tissue by blunt and sharp dissection.

Figure 1.2

The duct is attached to the cyst running in a cephalad direction between the sternohyoid muscles to the body of the hyoid bone. It is usually not possible to recognize whether the duct perforates the hyoid body or passes across its anterior or posterior surface. The central part of the hyoid bone is freed from the muscles attached to its upper and lower margin. The thyrohyoid membrane is carefully dissected off the posterior aspect with scissors.

Figure 1.3

The exposed hyoid bone is then stabilized with strong Kocher forceps on one side, clearly lateral to the median line, and the central segment is excised with strong Mayo scissors.

Figure 1.4

If the duct is extending beyond on the posterior aspect of the hyoid bone, it is followed cephalad and divided close to the base of the tongue with a 5/0 absorbable transfixation ligature. If the floor of the mouth is entered accidentally, the mucosa of the tongue is closed with interrupted plain absorbable sutures. Often, however, no duct structures are found behind the hyoid bone, in which case some of the midline connective tissue is excised in the cranial direction to make sure that no duct epithelium is left behind.

The lateral segments of the hyoid bone are left separated, but the anterior neck muscles are approximated in the midline with absorbable 4/0 sutures. Platysma and subcutaneous fat are closed with absorbable 5/0 sutures, and the skin is closed either with interrupted subcuticular absorbable 6/0 stitches or with a continuous subcuticular nonabsorbable 4/0 suture, which can be removed 3–4 days later. A drain is usually not necessary, except in cases requiring extensive dissection as may occur after a previously infected cyst or a recurrent cyst.

Figure 1.1

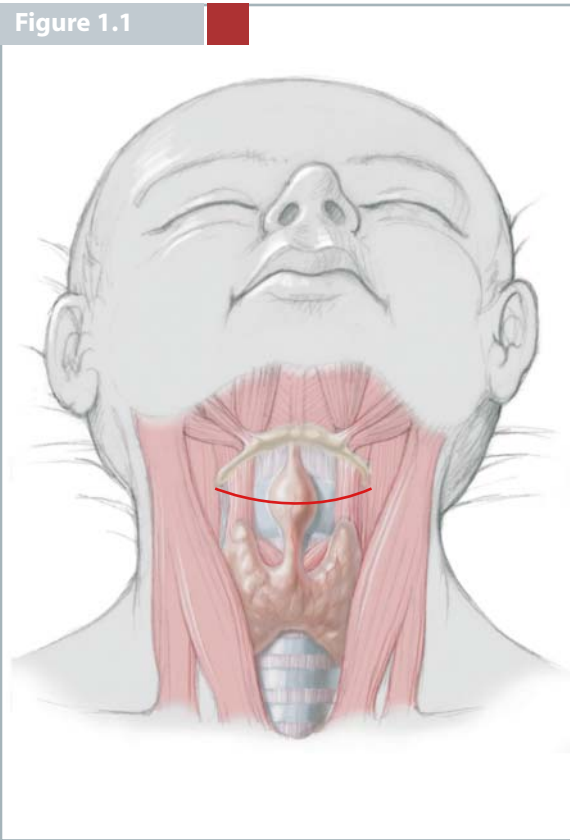


Figure 1.2

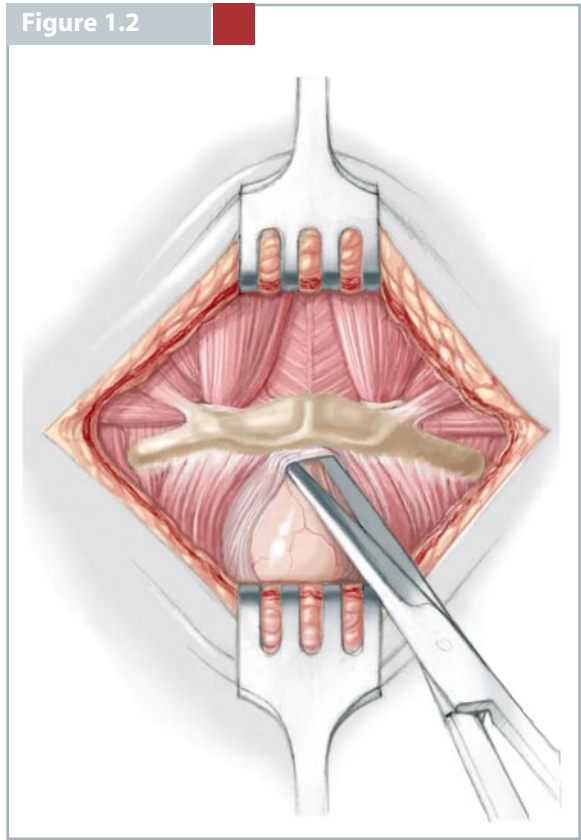


Figure 1.3

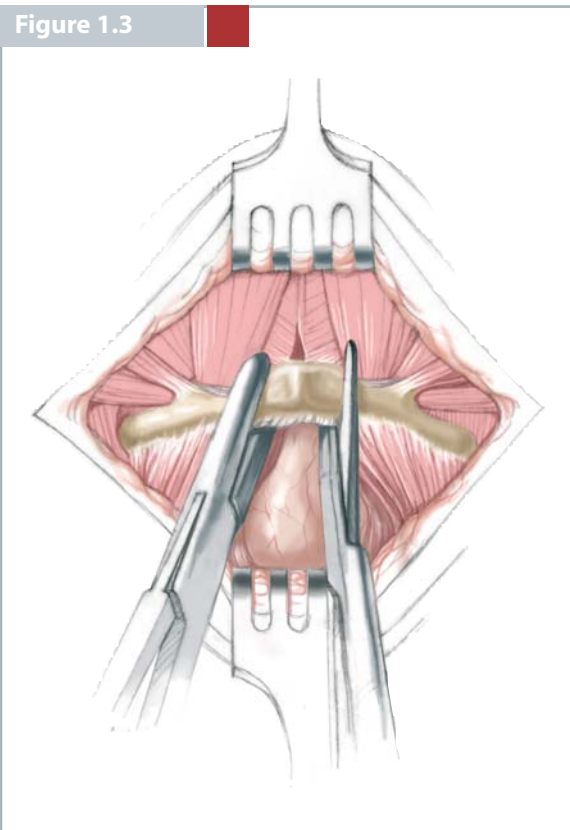
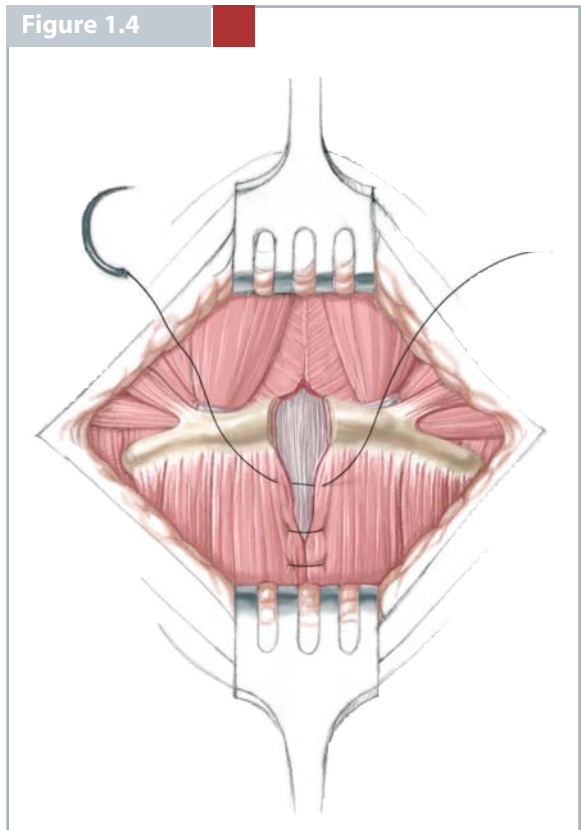


Figure 1.4



CONCLUSION

Complete excision of the thyroglossal cyst consists of removal of the cyst, the entire tract and the midportion of the hyoid bone through which the tract passes. If this principle is followed, recurrence is extremely unlikely. While the procedure is easily performed

in native tissue, dissection is much more difficult in a previously infected cyst. Therefore, postponement of the surgical procedure is not to be recommended once the diagnosis has been made.

SELECTED BIBLIOGRAPHY

- Horisawa M, Niiomi N, Ito T (1991) Anatomical reconstruction of the thyroglossal duct. *J Pediatr Surg* 26:766–769
- Smith CD (1998) Cysts and sinuses of the neck. In: O'Neill JA, Rowe MI, Grosfeld JL, Fonkalsrud EW, Coran AG (eds) *Pediatric surgery*. Mosby, St Louis, pp 757–772
- Telander RL, Deane S (1977) Thyroglossal and branchial cleft cysts and sinuses. *Surg Clin North Am* 57:779–791
- Waldhausen JHT, Tapper D (2000) Head and neck sinuses and masses. In: Ashcraft KW (ed) *Pediatric surgery*. WB Saunders, Philadelphia, pp 987–999

Michael E. Höllwarth

INTRODUCTION

During the fourth to eighth week of gestation, four pairs of branchial arches and their intervening clefts and pouches are formed. Congenital branchial cysts and sinus are remnants of these embryonic structures that have failed to regress completely. Treatment of branchial remnants requires knowledge of the related embryology. The first arch, cleft and pouch form the mandible, the maxillary process of the upper jaw, the external ear, parts of the Eustachian tube, and the tympanic cavity. Anomalies of the first branchial pouch are rare. Sinuses typically have their external orifice inferior to the ramus of the mandible. They may traverse the parotid gland, and run in close vicinity to the facial nerve in the external auditory canal. Cysts are located anterior or posterior to the ear or in the submandibular region. They have to be distinguished from the preauricular cysts and sinuses, which are ectodermal remnants from an aberrant development of the auditory tubercles, tend to be bilateral, and are localized anterior to the tragus of the ear. Sinuses are blind, ending in close vicinity of the external auditory meatus.

The most common branchial cysts and sinus derive from the second branchial pouch, which forms the tonsillar fossa and the palatine tonsils. The external orifice of the sinus can be located anywhere along the middle- to lower-third of the anterior border of the sternocleidomastoid muscle. The sinus penetrates the platysma and runs parallel to the common carotid artery, crosses through its bifurcation and most commonly exits internally in the posterior ton-

sillar fossa. A complete sinus may discharge clear saliva. A cyst, as a remnant of the second branchial pouch, presents as a soft mass deep to the upper-third of the sternocleidomastoid muscle. The depth distinguishes it from cystic hygromas, which are located in the subcutaneous plane.

The third arch forms the inferior parathyroid glands and the thymus, while the fourth arch migrates less far down and develops into the superior parathyroid glands. Sinuses of the third arch open externally in the same region as those of the second one, but run upwards behind the carotid artery to the piriform fossa. Cystic remnants may compress the trachea and cause stridor. Sinuses and cysts of the fourth branchial arch and cleft are extremely rare. Both, third and fourth arch remnants most commonly present as inflammatory lateral neck masses, more often on the left side. The cyst may evoke a false impression of acute thyroiditis. Computed tomography (CT) of the neck helps to identify the origin of such lesions. In an acute suppurative phase, external pressure onto the mass may result in laryngoscopically visible evacuation of pus into the piriform fossa.

Cystic remnants present commonly in adolescence and adulthood, whereas sinuses and fistulas are usually seen in infancy and early childhood. In principle, clinical manifestation – no matter at what age – should be taken as an indication for elective excision before complications – mainly of an inflammatory nature – supervene.

Figure 2.1

The patient is placed in a supine position. Following induction of general anaesthesia with endotracheal intubation, the head is turned to the side. A sandbag is placed underneath the shoulders to expose the af-

ected side. Instillation of Methylene blue into the orifice aids identification of the sinus during dissection. Some surgeons introduce a lacrymal duct probe into the orifice to guide dissection of the tract.

Figure 2.2

In case of branchial cyst the incision is made over the cyst along the Langer's lines. An elliptical incision is made around the sinus. A traction suture is applied

to it just underneath the skin for manipulation during further dissection.

Figure 2.1

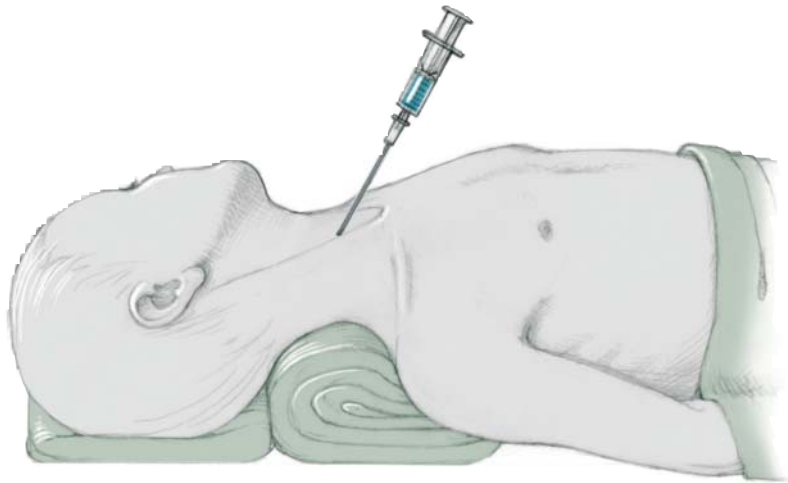


Figure 2.2

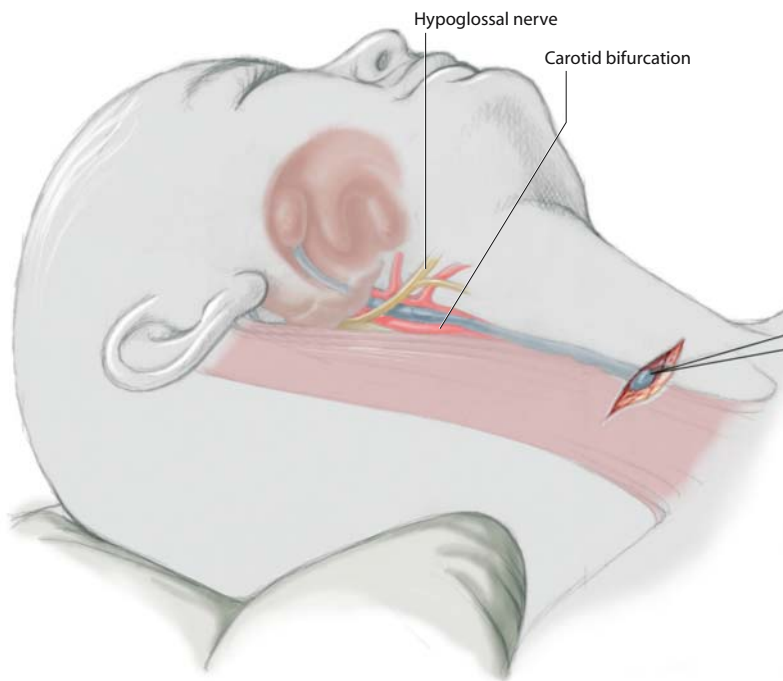


Figure 2.3

Subcutaneous tissue and platysma are divided until the sinus tract is reached, which is easily palpable when the traction suture is gently tensed. Mobilization of the sinus continues in cephalad direction as far as possible with gentle traction. The operation can usually be done through a single elliptical incision by keeping traction on the sinus tract and by the anaesthetist placing a gloved finger to push the tonsillar fossa downwards. Dissection then continues through the carotid bifurcation to the tonsillar fossa. Close contact with the sinus is obligatory to avoid any injury to the arteries or the hypoglossal nerve. Close to the tonsillar fossa, the sinus is ligated with a 5/0 absorbable transfixation suture and divided.

Figure 2.4

In adolescents a second transverse (stepladder) incision, made approximately 4–5 cm above the first, may be necessary to completely excise the sinus tract. Both incisions are closed with absorbable interrupted fine subcutaneous (5/0) and subcuticular (6/0) sutures.

Figure 2.5

For the first branchial pouch remnants, the opening of the fistula is circumcised with an elliptical skin incision. Careful dissection liberates the subcutaneous segment of the embryological remnant, which is now transfixed with a stay suture. This is used for traction on the duct, which facilitates its identification on subsequent dissection into the depth towards the auditory canal. Because of intimate contact with the parotid gland and potentially in the immediate vicinity

of the fascial nerve, dissection must stay close to the tract, and – exclusively bipolar – electrocoagulation must be used sparingly. A neurosurgical nerve stimulator may be employed to identify and preserve fine nerve fibres. The sinus is transected and ligated with an absorbable 5/0 stitch close to the auditory canal. The subcutaneous tissue is approximated using 5/0 absorbable sutures, followed by interrupted subcuticular absorbable 6/0 sutures.

Figure 2.3

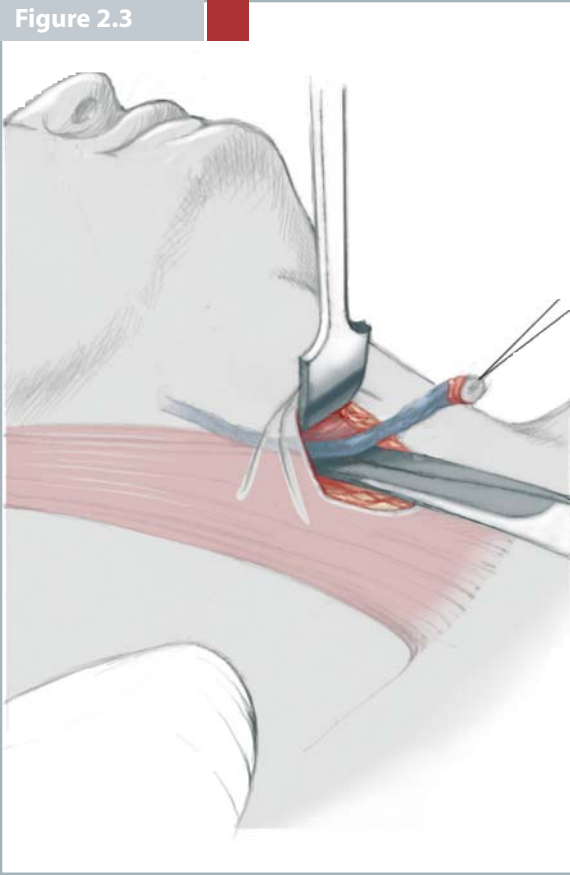


Figure 2.4

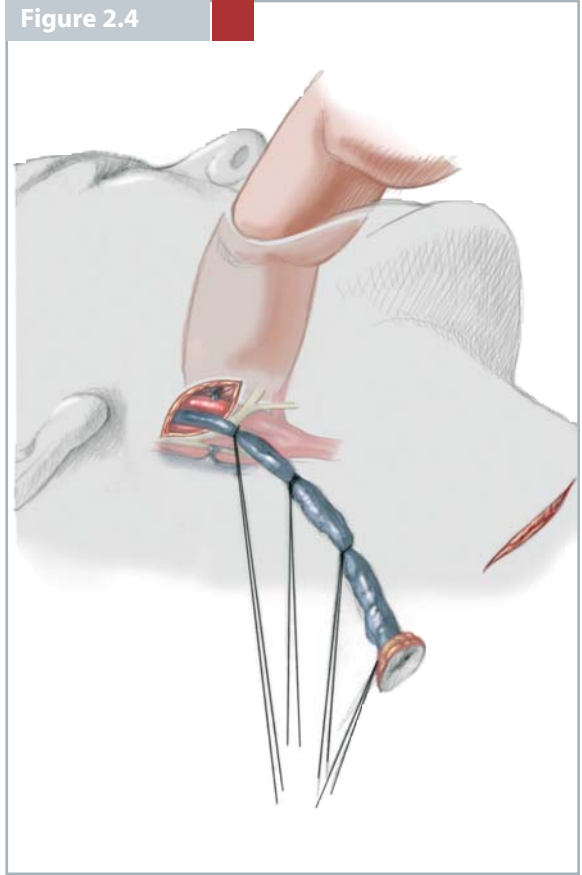
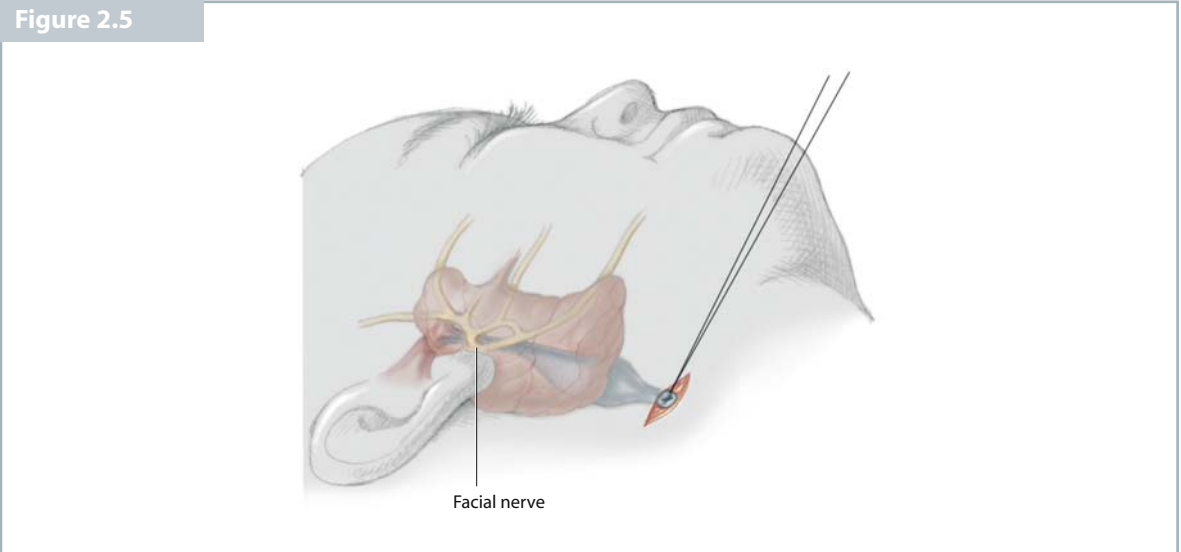


Figure 2.5



CONCLUSION

Recurrences are most likely due to proliferation of residual epithelium from cysts or sinuses. The surgical procedure should thus be performed electively soon after diagnosis. Infected cysts and sinuses are treated with antibiotics until the inflammatory signs subside, unless abscess formation mandates incision and drainage. Repeated infections render identifica-

tion of the tissue layers much more difficult. Surgery after infections of remnants of the first branchial pouch carries an increased risk of facial nerve injury. In order to avoid damage to vital vascular and nerve structures it is important to confine dissection close to the sinus tract.

SELECTED BIBLIOGRAPHY

- Deane SA, Telander RL (1978) Surgery for thyroglossal duct and branchial cleft anomalies. *Am J Surg* 136:348–353
- Smith CD (1998) Cysts and sinuses of the neck. In: O'Neill JA, Rowe MI, Grosfeld JL, Fonkalsrud EW, Coran AG (eds) *Pediatric surgery*. Mosby, St Louis, pp 757–772
- Waldhausen JH, Tapper D (2000) Head and neck sinuses and masses. In: Ashcraft (ed) *Pediatric surgery*. WB Saunders, Philadelphia, pp 787–799

INTRODUCTION

Lymphangiomas are benign masses with multinodular cysts of different sizes and contents. Microcysts are less than 1 cm in diameter; macrocysts are greater than 1 cm in diameter and tend to be less invasive, less numerous, and less difficult to remove. Both microcysts and macrocysts may contain blood and/or lymph, a consequence of similar lymphatic and vascular embryology. In general, microcysts are more likely to contain blood and macrocysts more likely to contain lymph. Macrocysts that contain lymph are also called cystic hygromas and they are subsumed in the general category of lymphatic malformations.

The risks of expectant management include infection, progressive growth and disfigurement, extension into previously uninvolved areas, dysphagia, airway compromise, and erosion into vascular structures. Asymptomatic cysts in the premature or small-for-dates child may await growth and development of the infant. For the majority of patients there is no need to defer excision.

The determination of a lymphangioma's size and character is based on location, clinical examination

and investigation. Some regions tend to have typical lesions: for example, reddish lesions in the base of the tongue are typically microcystic with a significant vascular component; soft boggy masses in the superficial neck or axilla – sometimes with a bluish hue – are often macrocysts with lymph. The best investigations to determine cyst contents is either a T2-weighted gadolinium-enhanced magnetic resonance imaging (MRI) or needle aspiration of the dominant cyst. Lymph is straw-coloured; thin bloody fluid may occur when a lymphatic cyst is enlarged by a ruptured blood vessel. Abundant dark or red blood indicates a significant vascular component. Viscid yellow-clear fluid from an intra-oral lesion may signal a ranula, deriving from salivary tissue. Depth of invasion and an estimate of the structures involved is best determined by MRI scanning. Rarely, a neck lesion may extend to the anterior mediastinum and compress the trachea. Spontaneous enlargement may occur following an upper respiratory tract infection; spontaneous regression is rare although sometimes follows local infection

Figure 3.1

General anaesthesia is used and blood made available if the lesion appears vascular on pre-operative screening. If lesions are close to important motor nerves, one may use a nerve stimulator and interdict use of musculoskeletal blocking agents.

Pre-operative planning will usually demonstrate a safe plane of attack and may set expectations with regard to a complete excision or a debulking operation. Loupe magnification is often helpful, as is a bipolar cautery when working close to nerves or vital structures. Microvascular lesions tend to infiltrate tissue planes, are more likely to bleed and have a high rate of recurrence. Macrocystic lesions tend to spread along fascial planes and around neurovascular structures. Intra-operative rupture decreases the likelihood of complete resection, which averages 50%. Any residual cystic tissue will increase the likelihood of recurrence. Because this is not a malignant lesion, it is seldom necessary to sacrifice essential local structures. It is commonly necessary to place a closed suction drain, particularly when the lesion is incompletely excised. For the most common (cervical) lesions, a transverse skin crease incision extending the length of the mass is placed in Langer's lines. A first-generation cephalosporin is used peri-operatively.

Figure 3.2

If the lymphangioma demonstrates dermal infiltration, an ellipse of skin is removed. Otherwise, generous sub-platysmal skin flaps are raised. The external jugular vein and ansa cervicalis are not considered essential and may be sacrificed.

Figure 3.3

Dissection of cervical lesions begins at the superior margin of the mass, near the ramus of the mandible. Upward reflection of the facial artery and vein allow the precise visualization necessary to preserve the marginal branch of the facial nerve. Bipolar cautery may be used and optical magnification is often helpful.

Figure 3.4

The dissection proceeds medially, lifting the cyst from the surrounding alveolar tissue.

It may be necessary to divide the middle thyroid vein and artery as the carotid sheath is approached. Deep dissection frequently involves the contents of the carotid sheath and sometimes the following nerves: vagus, spinal accessory, hypoglossal, sympathetic trunk, phrenic and the brachial plexus.

Figure 3.1

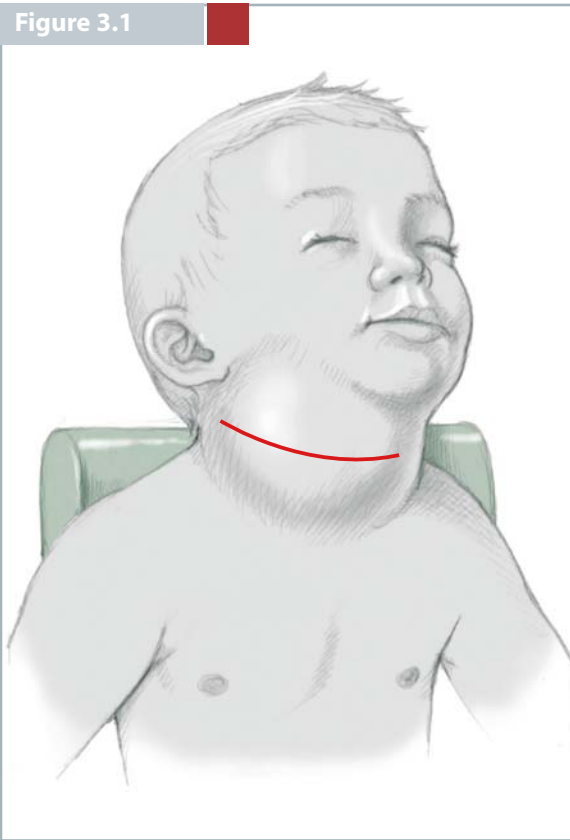


Figure 3.2

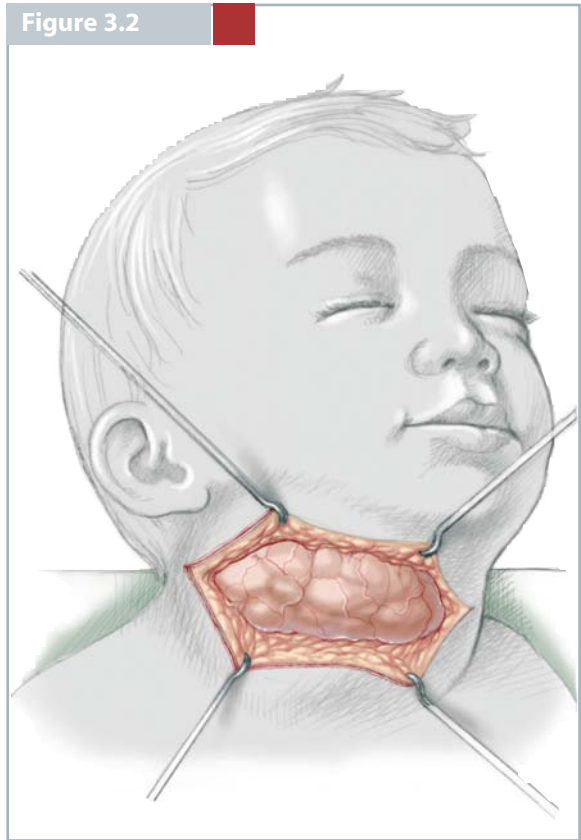


Figure 3.3

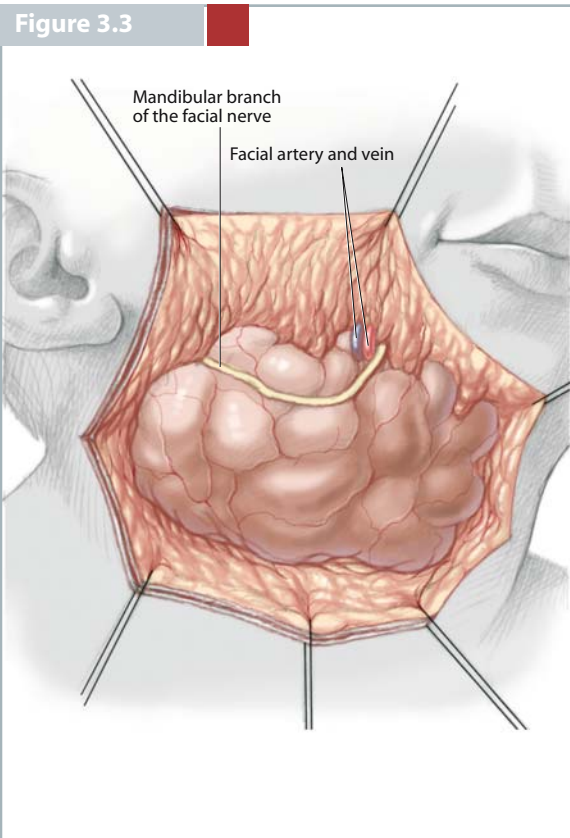


Figure 3.4

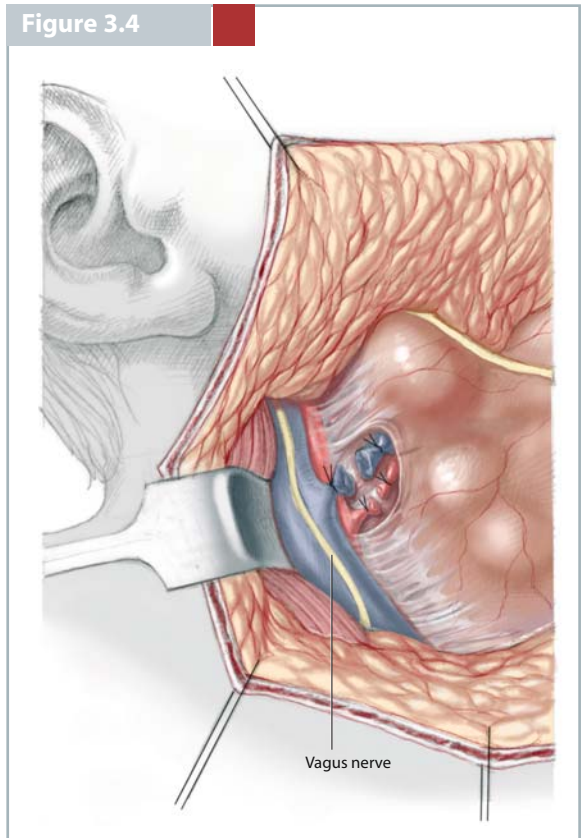


Figure 3.5

Care is taken to preserve the hypoglossal nerve as it passes through the bifurcation of the carotid artery. The mass must then be freed from the hyoid bone and submandibular gland. It is rarely necessary to remove the submandibular gland en bloc with the mass, sacrificing the facial artery. The mass may be adherent to the brachial plexus in the floor of the an-

terior triangle or the spinal accessory nerve as it courses through the posterior triangle. Extension of the lymphangioma under the clavicle may lead to axillary or mediastinal involvement (requiring sternotomy if the lesion proceeds deeply). Combined masses may be delivered either above or below the clavicle.

Figure 3.6

The platysma is re-approximated with fine absorbable sutures and the skin closed with subcuticular

sutures of similar material. Closed suction drainage is used for most lesions.

Figure 3.5

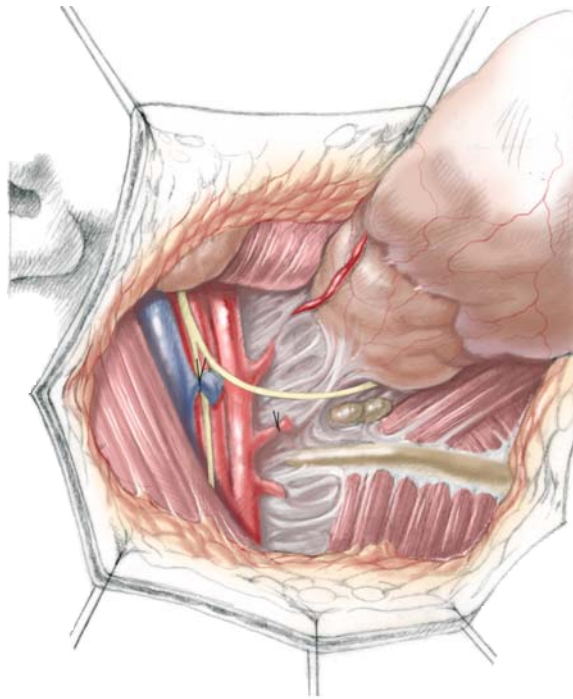
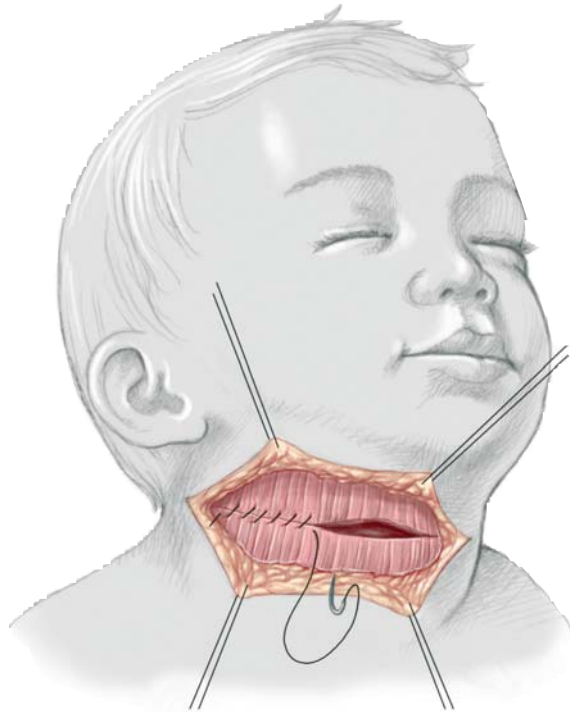


Figure 3.6



CONCLUSION

Feeding resumes when the infant is awake and alert. Extensive intra-oral dissection may temporarily impair swallowing and delay the onset of oral feeds. Drain removal may take days or weeks and is dictated by the daily drainage volume. Antibiotics are administered daily from 1 to 3 days.

In cases of partial resection, recurrence typically occurs within a year of surgery. Lymph leaks and nerve injuries are minimized by the use of bipolar diathermy. Rarely, lymph leaks may require re-exploration when drains are inadequate or removed early.

Excision is the current gold-standard therapy. There are several reports of successful use of sclerosing agents such as OK-432 or bleomycin in lymphangiomas. This appears to be effective mainly in macrocystic lesions.

An exciting advance in the management of fetuses with a high probability of upper-airway obstruction at birth due to a giant cervical lymphangioma, is the development of the ex utero intrapartum treatment (EXIT).

SELECTED BIBLIOGRAPHY

- Banieghbal B, Davies MR (2003) Guidelines for the successful treatment of lymphangioma with OK-432. *Eur J Paediatr Surg* 13: 103–107
- Bouchard S, Johnson MP, Flake AW, Howell LJ, Myers LB, Adzick NS, Crombleholme TM (2002) The EXIT procedure: experience and outcome in 31 cases. *J Pediatr Surg* 37: 418–426
- Charabi B, Bretlau P, Bille M, Holmelund M (2000) Cystic hygroma of the head and neck – long-term follow up of 44 cases. *Acta Otolaryngol Suppl* 543: 248–250
- Hirose S, Farmer DL, Lee H, Nobuhara KK, Harrison MR (2004) The ex utero intrapartum treatment procedure: Looking back at the EXIT. *J Pediatr Surg* 39: 375–380
- Schuster T, Grantzow R, Nicolai T (2003) Lymphangioma coli: a new classification contributing to prognosis. *Eur J Paediatr Surg* 13: 97–102

Thom E. Lobe

INTRODUCTION

The indications for tracheostomy in infants and children fall into five main categories: airway immaturity, obstructing congenital anomalies, acquired obstructions, tumours and trauma.

The immature airway manifests itself as laryngomalacia, tracheomalacia or a combination of the two conditions. These infants present with inspiratory stridor, and some degree of nasal flaring and chest retractions. Other related conditions are congenital vocal chord paralysis, which is usually due to a central nervous system deficit, phrenic nerve injury, which may be associated with a difficult delivery, and recurrent laryngeal nerve injury, which may occur after ligation of a patent ductus arteriosus.

Some patients with choanal atresia and Pierre Robin syndrome or other craniofacial abnormalities may be candidates for tracheostomy.

Patients with a congenitally stenotic airway or tracheal agenesis are special cases. In the case of agenesis, an emergency tracheostomy may be necessary where the trachea reestablishes distally.

There are several acquired conditions that require tracheostomy. Among them are infection, neuromuscular failure, chronic aspiration and subglottic stenosis. Chronic respiratory failure, sleep apnea or neuromotor problems resulting in poor airway maintenance also require tracheostomy. Long-term respiratory support after major surgery, repair of laryngo-tracheo-oesophageal cleft or major trauma may necessitate tracheostomy.

Occasionally the management of a tumour such as a cervical teratoma or sarcoma in infancy will mandate a tracheostomy. More likely, a hemangioma or lymphangioma will compromise the airway to the extent that a more stable airway is needed.

Tracheostomy in infants and children routinely is performed under general anaesthesia with the patient intubated unless the patient's condition is so unstable that the patient cannot tolerate the necessary drugs.

Figure 4.1

The patient is placed supine on the operating table toward the head of the table so that the surgeon can access the patient's neck easily, but not so far down on the table that the anaesthesiologist cannot reach the patient to manipulate the endotracheal tube when required. The anaesthesiologist or anaesthetist must be able to maintain control of the airway while the surgeon is exposing and manipulating the trachea. The neck should be extended sufficiently to allow complete access to the neck. Sometimes, on chubby infants, it is still difficult to see the entire neck, despite the best attempts. A roll should be placed under the infant's shoulders to facilitate proper positioning.

The endotracheal tube should be secured so that the anaesthesiologist can easily remove the tube at the appropriate time. This means that any tape should be loosened before hand. If there is a feeding tube in place, it should be removed so that it does not interfere with endotracheal tube manipulation. When the infant is properly positioned and monitored, the entire neck from the lower lip to below the nipples should be prepped with a suitable surgical prep and draped. The superior most surgical drape should allow easy access to the patient by the anaesthesiologist.

Figure 4.2

Incision is made in the lower neck crease, about the width of one finger above the jugular notch. A transverse incision is preferable. If the incision is too low you will end up in the mediastinum and the cannula

will end up too low in the trachea. We first score the skin with a scalpel, then use a needle-point electrocautery device to deepen the incision, taking care not to burn the skin.

Figure 4.1

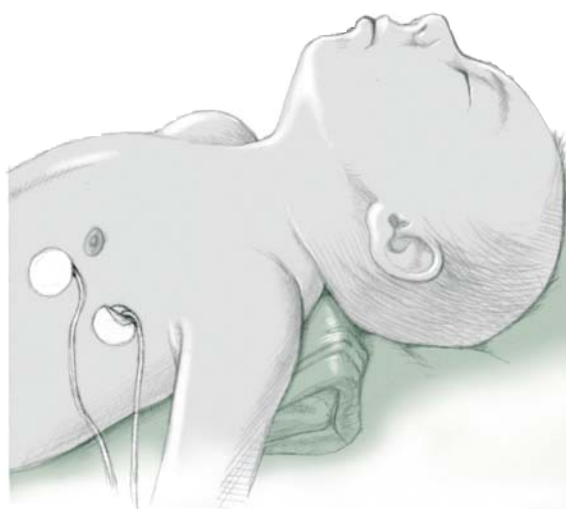

Figure 4.2

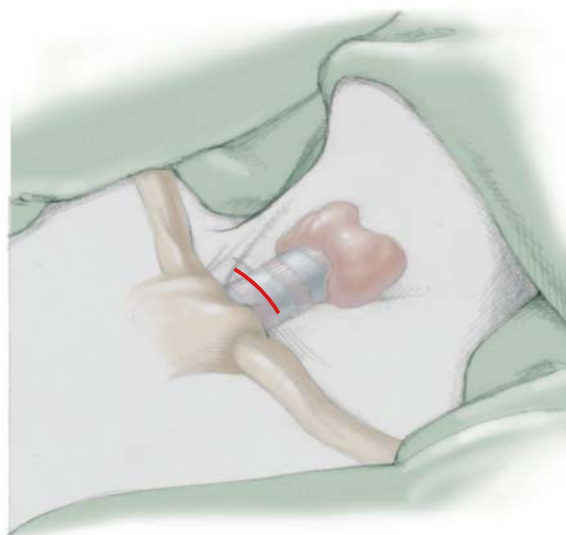

Figure 4.3

This incision is extended through the subcutaneous fascia and platysma muscle, which is quite thin in the small infant. It is helpful to insert two right-angled retractors in the corners of this incision to better expose the operative site.

Next, we use two atraumatic forceps to grasp the cervical fascia on either side of the midline and open it vertically in the midline. We extend this incision inferiorly to the jugular notch and superiorly to the thyroid gland.

The strap muscles, immediately beneath the anterior cervical fascia similarly are separated in the midline. Usually, there are few to no blood vessels in the dissection thus far. Occasionally, you will encoun-

ter a few small vessels that cross the midline. These should be cauterized and divided as they are encountered.

Once these muscles are separated, we place the two retractors deep to the muscle edges and gently retract laterally to better expose the trachea below. Sometimes it is necessary to free the muscle edges sufficiently to allow room for the blade of the retractor to gain a secure purchase.

The trachea should be visualized easily. If not, then palpation in the wound with manipulation of the endotracheal tube by the anaesthesiologist will help locate the trachea.

Figure 4.4

The proposed tracheostomy cannula should be selected, opened and its outer diameter visually checked against the exposed trachea to judge the correctness of its size. If it seems that the initial selection was incorrect, then a tracheostomy cannula of a more appropriate size should be selected.

The pre-tracheal fascia should be scored with the cautery to coagulate any tiny vessels on the surface of the trachea in the midline. Again, the blades of the retractors should be deep in the wound on either side of the trachea for optimal exposure.

A suture of 4/0 monofilament nonabsorbable suture or its equivalent is placed on either side of the

midline scored anterior trachea. Each suture incorporates one or two tracheal rings. These sutures are not tied onto the tracheal wall, but can be tied at their ends and should be left 6–8 cm in length. At the end of the case, these sutures will be taped securely to the anterior chest wall and will be used to locate the tracheal incision in the event of a post-operative emergency in which the newly placed tracheostomy cannula dislodges. These sutures also can be used to hold open the edges of the tracheal incision for ease of placement of the tracheostomy cannula at operation.

Figure 4.3

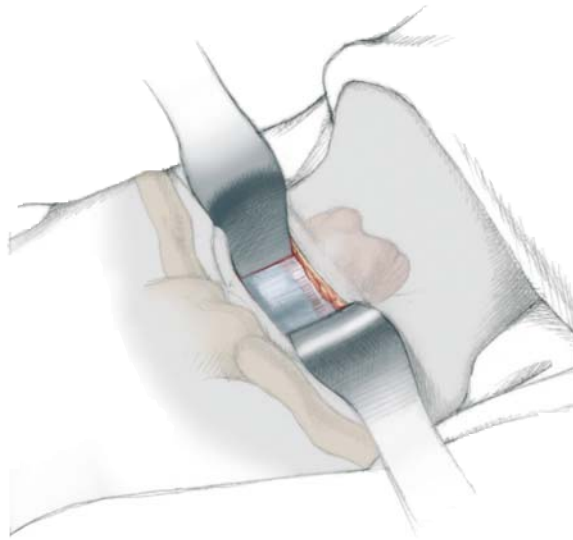


Figure 4.4

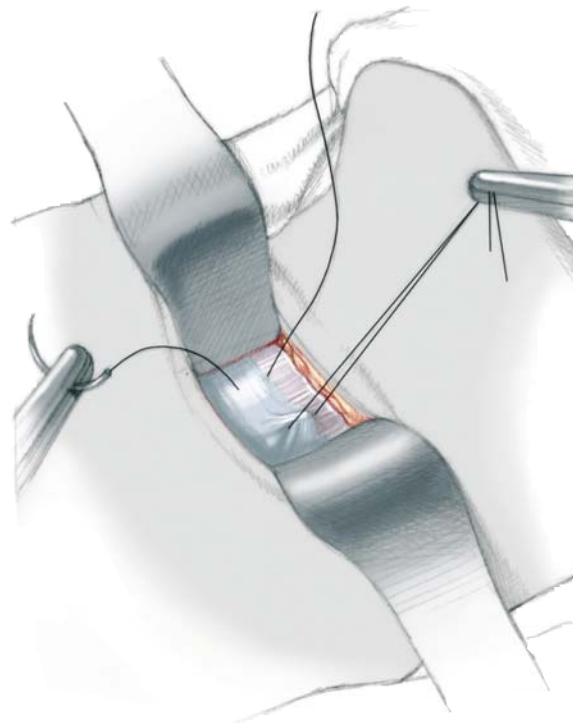


Figure 4.5

The surgeon should request that the endotracheal tube be loosened and prepared for removal. Using a number 11 blade, a vertical incision is made through the tracheal wall along the score mark. Two or three tracheal rings should be divided. Usually these are rings 2, 3 and 4. Rarely, it is necessary to divide the isthmus of the thyroid gland for proper tracheostomy positioning. A transverse tracheal incision or removal of a tracheal ring is likely to result in a tracheal deformity and thus should be avoided.

Suction should be available in case blood or secretions interfere with the surgeon's view of the tracheal lumen. The tip of the cannula to be inserted should be lubricated with a water-soluble surgical lubricant and positioned over the incision, poised for insertion when the endotracheal tube is withdrawn.

The surgeon then requests the anaesthesiologist to withdraw the endotracheal tube sufficiently to

clear the lumen so that the tracheostomy cannula can be inserted and directed caudally toward the carina.

One way to avoid misplacement is to insert a suction catheter through the lumen, beyond the tip of the cannula. The suction catheter then can be inserted into the tracheal lumen first and serve as a guide over which the cannula can be passed. This technique also is useful should the cannula become dislodged after the procedure.

If, for any reason, the tracheostomy cannula does not fit easily into the trachea, it should be removed and the endotracheal tube should be advanced beyond the tracheal incision so that ventilation will not be compromised. This might occur if the diameter of the tracheal lumen has been over estimated and the previously selected tracheostomy cannula is too large to fit into the trachea. In that case, a smaller cannula should be selected.

Figure 4.6

As soon as the cannula is in place, the obturator or suction catheter should be removed and the anaesthesiologist should disconnect the ventilator hose from the endotracheal tube and connect it to the tracheostomy cannula. Once that is done, the anaesthesiologist should administer several deep breaths to the patient to confirm that the cannula is in the proper place and that the infant can be ventilated satisfactorily. If it appears that, although the cannula width is appropriate, the cannula is too long and its tip rests on the carina, then several pieces of gauze can be used to build up the gap between the neck and the tracheostomy collar, thus backing the tip of the cannula away from the carina. Once adequate ventilation is confirmed, then the endotracheal tube can be removed completely.

Once the cannula is connected to the ventilator, the cervical wings of the body of the cannula need to be secured to the patient. We don't rely on a tie placed around the neck, but accomplish this with the aid of sutures.

For each wing, a suture of 3/0 silk or its equivalent is passed through the skin of the neck, then through

the upper edge of the wing of the cannula (midway between the midline and the end of the wing), through the lower edge of the wing, then again through the skin. When this suture is tied, the skin will be drawn over the wing and usually will cover it. After you have placed these sutures, both wings will be securely fixed to the skin of the neck.

The two ties that were placed in the anterior tracheal wall are now taped securely to the anterior chest wall in such a fashion that their ends are easily accessible in case they are needed in an emergency to reinsert the cannula.

Finally, the umbilical tape or tie that usually comes with the cannula is passed through the holes in the end of the wings and tied around the neck to further secure the cannula. This should be tied in back of the neck. A simple gauze dressing with some antibiotic ointment is placed underneath the wings of the cannula over the cervical incision to complete the procedure.

We send our infants to the intensive care unit after a fresh tracheostomy in case of emergency.

Figure 4.5

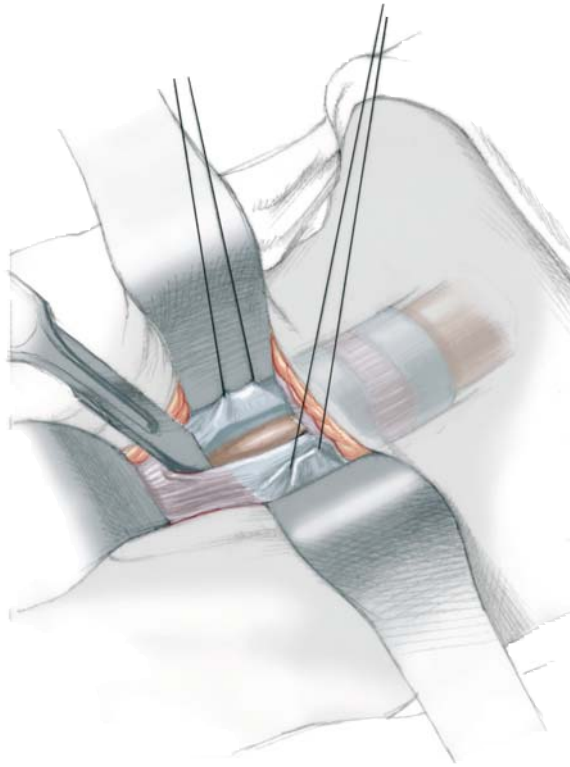
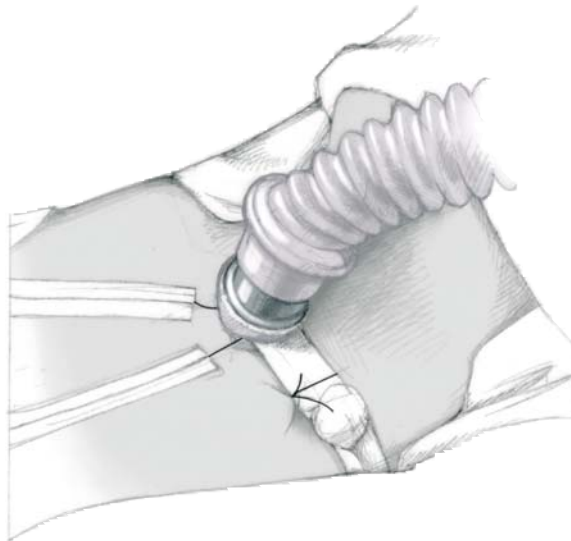


Figure 4.6



CONCLUSION

Tracheostomy is a simple technical procedure to perform, but it can be one of the more difficult procedures in paediatrics. The cannula should be selected carefully to make certain that it is not too long after the roll (used to extend the neck) is removed and the patient is repositioned. Occasionally, it is necessary to order a special tracheostomy cannula. Such is the case for a short, wide trachea.

The most common problems occur post-operatively when the cannula becomes occluded or, worse yet, dislodged. This is why we secure the sutures to the chest wall, to make certain that if the cannula becomes dislodged it will be as easy to re-insert it or a new cannula into the tracheal lumen.

We change the cannula 10 days after the surgery, before the patient is discharged from the hospital, to make certain that the cannula can be changed easily and to minimize the risk of cannula-related problems after discharge.

These patients need to be followed closely as they grow to assure the optimal cannula size and to determine whether the tracheostomy still is necessary.

Decannulation, when possible, is done in the hospital, usually after flexible or rigid bronchoscopy to assess the adequacy of the tracheal lumen and the presence of obstructing granulation tissue or malacia.

SELECTED BIBLIOGRAPHY

- Bach JR, Zhitnikov S (1998) The management of neuromuscular ventilatory failure. *Semin Pediatr Neurol* 5: 92-105
- Carr MM, Poje CP, Kingston L, Kielma D, Heard C (2001) Complications in pediatric tracheostomies. *Laryngoscope* 111: 1925-1928
- Estournet-Mathiaud B (2001) Tracheostomy in chronic lung disease: care and follow-up. *Pediatr Pulmonol* 23: 135-136
- Kenigsberg K (1994) Tracheostomy in infants. *Semin Thorac Cardiovasc Surg* 6: 196-199
- Kremer B, Botos-Kremer AI, Eckel HE, Schlondorff G (2002) Indications, complications, and surgical techniques for pediatric tracheostomies - an update. *J Pediatr Surg* 37: 1556-1562

Michael E. Höllwarth, Paola Zaupa

INTRODUCTION

Oesophageal atresia is defined as an interruption in the continuity of the oesophagus with or without fistula to the trachea. The anomaly results from an insult occurring within the fourth week of gestation, during which separation of trachea and oesophagus by folding of the primitive foregut normally takes place. Familial cases affecting siblings or offspring suggest genetic factors. Most cases, however, occur sporadically without evidence for either hereditary or specific environmental teratogenic causes. The incidence approximates to 1:4,500 live births with a slight male preponderance (59%). Associated malformations are obvious or easily detected in 40–60% of cases, and may be found in up to 80% by meticulous search for structural and numerical anomalies in the skeletal system. At least 18 different syndromes have been reported in association with oesophageal atresia. The best known is probably the VATER or VACTERL association of anomalies (Vertebral-Anal-Cardiac-Tracheal-Esophageal-Renal-Limb).

The earliest symptom of oesophageal atresia is a polyhydramnios in the second half of pregnancy. Polyhydramnios is an unspecific manifestation of swallowing disorders or of disturbance of fluid passage through the uppermost part of the intestinal tract of the fetus. Prenatal ultrasound may further reveal forward and backward shifting of fluid in the upper pouch, and in cases without a lower fistula, a paucity of fluid in the stomach and small intestine. Postnatal presentation is characterized by drooling of saliva and cyanotic attacks. If passage of 12 F feeding tube into the stomach is not possible, oesophageal atresia is almost certain. Immediate oro- or naso-oesophageal insertion of a Replogle tube as soon as the diagnosis is established is mandatory for continuous or intermittent aspiration of saliva in order to prevent aspiration. The baby should be nursed propped up in order to prevent aspiration of gastric contents into the tracheobronchial tree.

Prior to surgery, the type of atresia should be determined. Air below the diaphragm on a plain X-ray film including neck, chest and abdomen provides evidence of a commonly seen lower tracheo-oesophageal fistula. In most of these cases (type 3b/C or 3c/D), a primary anastomosis between the oesophageal segments is possible. In contrast, a gasless abdomen indicates that a pure oesophageal atresia without lower fistula is present, and a long distance between the segments is to be expected (type 1/–, 2/A or 3a/B). A Replogle tube maximally advanced into the upper pouch helps to estimate its approximate length.

Additional malformations are looked for. Every neonate is checked for visible anomalies such as anal atresia or limb malformations. The thoraco-abdominal radiography may reveal duodenal or lower intestinal atresia, a diaphragmatic hernia and/or skeletal anomalies. Ribs and vertebrae must be counted and carefully examined for deformations. Usage of contrast medium is rarely indicated. Cardiologic assessment, including echocardiography, forms part of routine pre-operative workup in order to recognize associated congenital cardiac abnormalities, which may influence anaesthetic management, and the presence of right-sided aortic arch, which is of importance for the surgeon. Abdominal ultrasound searching for urinary tract anomalies is performed routinely.

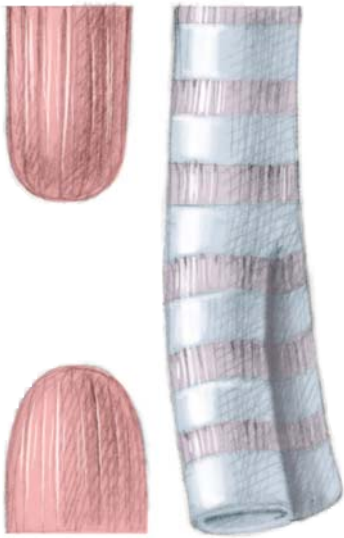
The baby is nursed in the intensive care unit (ICU). Immediate surgery is rarely required, so that all above-mentioned investigations can be performed step by step. Intubation and ventilation is only necessary in cases of respiratory distress, severe pneumonia or severe associated malformations demanding respirator therapy. The endotracheal tube should be positioned beyond a distal tracheo-oesophageal fistula to avoid insufflation of gas into the stomach inducing a risk of rupture, especially if a high gastrointestinal atresia is associated.

Figure 5.1 a–e

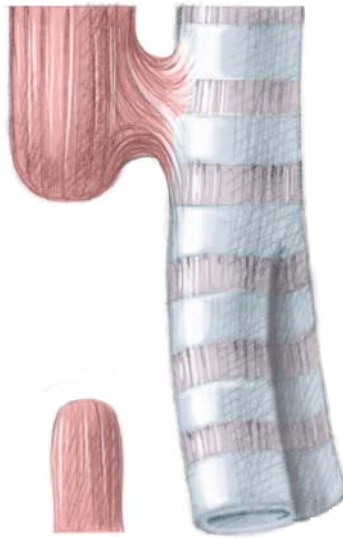
Classifications usually take their orientation on concurrence and type of tracheo-oesophageal fistula. The commonly used systems are those described by Vogt (numbers ± lower case letters) and Gross (capital letters). The most frequent type of oesophageal atresia (3b according to Vogt, C by Gross) affects over 85% of the patients and consists of a blind-ending upper pouch with a fistula between trachea and lower oesophagus. Vogt's extremely rare type 1, characterized by a more or less total lack of the oesophagus is not included in Gross' classification. Type 2/A (7%)

corresponds to pure atresia without a fistula. The distance between the two segments is usually too long – the same as in type 3a/B (2%) – with a fistula to the upper oesophageal pouch. The patients with type 3c/D oesophageal atresia (3%) have an upper and a lower pouch fistula. Some authors classify an isolated tracheo-oesophageal fistula without atresia – H-type fistula – as type 4/E (3%), although it belongs to a different spectrum because the oesophagus is patent. In Gross' classification, congenital oesophageal stenosis constitutes type F.

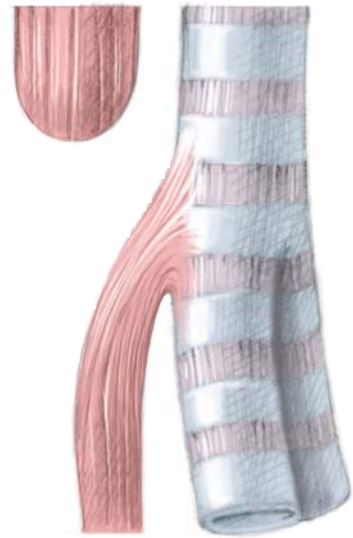
Figure 5.1a-e



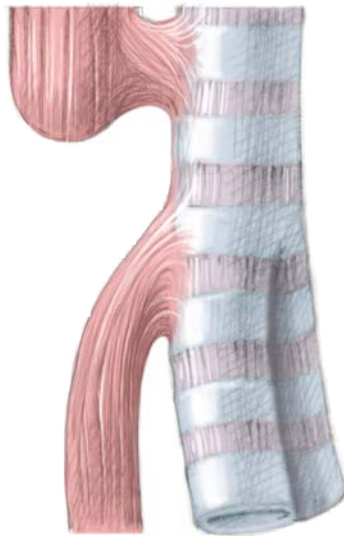
2/A



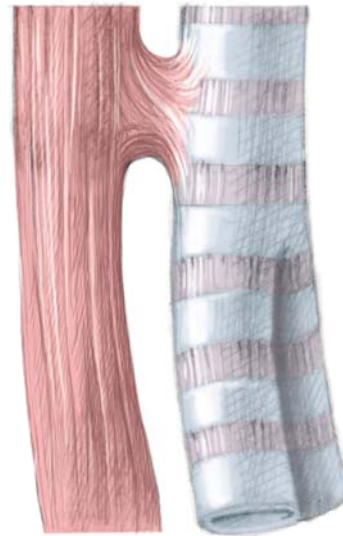
3a/B



3b/C



3c/D



4/E

Figure 5.2

Surgical repair is performed under general anaesthesia with endotracheal intubation. The endotracheal tube is advanced close to the tracheal bifurcation, and the infant is ventilated manually with rather low inspiration pressures and small tidal volumes. These measures serve to avoid overinflation of the stomach as well as to stabilize the trachea throughout the intervention. The Replogle tube is initially kept in place to easily identify the upper pouch intra-operatively. Broad-spectrum antibiotic prophylaxis is administered on induction. We routinely start with a tracheo-bronchoscopy using a rigid 3.5 mm endoscope. Trachea and main bronchi are briefly inspect-

ed, and the fistula to the oesophagus is localized, which is usually approximately 5–7 mm above the carina. Exceptionally, it may be found at the carina or even in the right main bronchus, indicating a short lower segment, and most likely with a long oesophageal gap. The next step is to look for an upper fistula. The dorsal – membranous – region of the tracheal wall is inspected carefully up to the cricoid cartilage. Small upper fistulas are easily missed. To avoid this pitfall, irregularities of the dorsal wall are gently probed with the tip of a 3F ureteric catheter passed through the bronchoscope. If a fistula is present, the ureteric catheter will glide into it.

Figure 5.3

The standard approach for repair of an oesophageal atresia is a right latero-dorsal thoracotomy. If a right aortic arch is diagnosed pre-operatively, a left-sided thoracotomy is recommended. However, if an unsuspected right descending aorta is encountered during surgery, the procedure can be continued in most cases, establishing the anastomosis on the right of the aortic arch.

The baby is positioned on the left side, stabilized with sandbags and fixed to the table with adhesive bands. The right arm is abducted without undue tension. Mild anteversion helps to reduce the risk of traction injury to the brachial plexus. The elbow is flexed to 90°, and the forearm is best tied to a transverse bar mounted over the head of the child with soft slings. Care must be taken that no part of the body is submitted to pressure during the procedure. Exposed sites must be well padded. Soft pillars may be placed between the knees and underneath the feet, or the limbs wrapped with cotton wool, which protects against heat loss at the same time. A folded

towel under the left side of the chest improves exposure and facilitates access in particular to the deeper structures.

A slightly curved skin incision is placed 1 cm below the tip of the scapula from the midaxillary line to the angle of the scapula. Some surgeons prefer a vertical skin incision in the midaxillary line for cosmetic reasons. A major advantage in neonates is the possibility of employing a muscle sparing technique – due to their soft and mobile tissue layers. Only small flaps of skin and subcutaneous tissue are raised around the incision. The latissimus dorsi muscle is mobilized by cutting through the anterior fascial attachment. It is then lifted off the thoracic wall and retracted posteriorly together with the thoracodorsal nerve, which runs on its deep surface following the posterior axillary line. When the latissimus muscle is retracted, the border of the serratus anterior muscle is mobilized along its origin from the tip of the scapula to the sixth rib and retracted up and forwards simultaneously with the scapula.

Figure 5.2

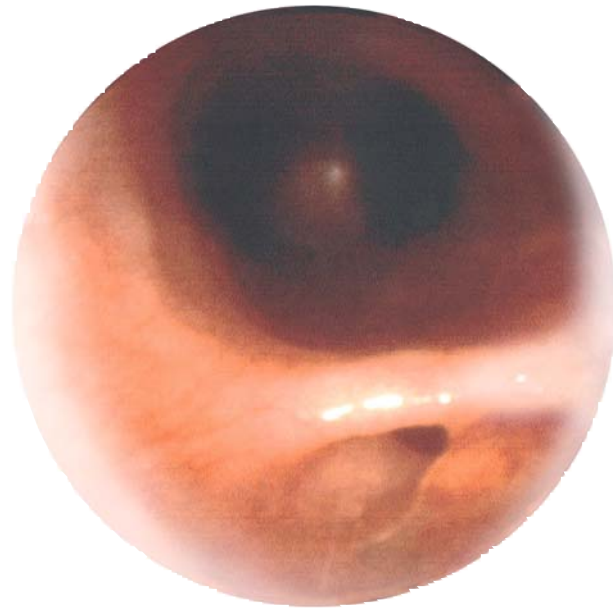

Figure 5.3

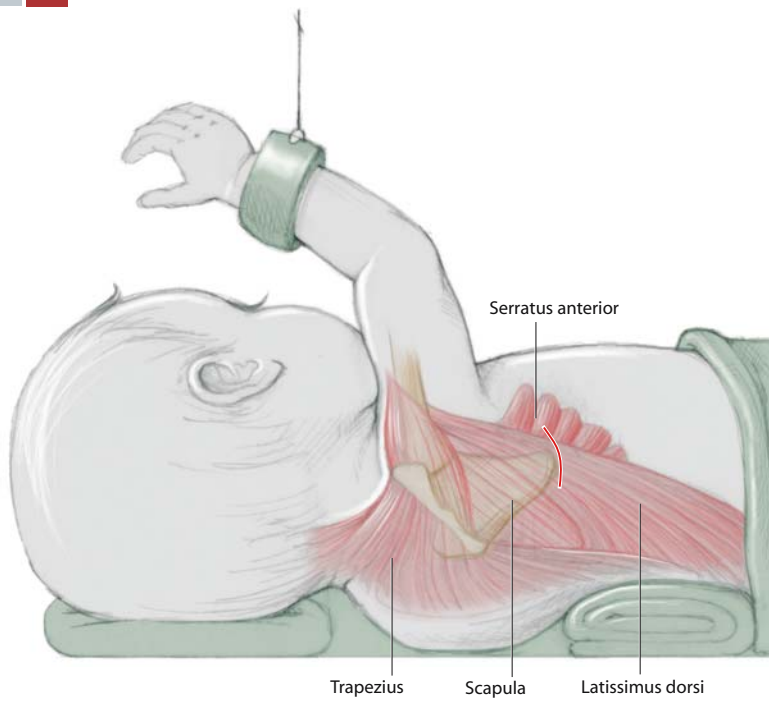


Figure 5.4–5.6

The intercostals muscles are divided along the upper border of the fifth rib. When the parietal pleura is exposed in one spot, a tiny moist cotton swab mounted on an artery forceps is used to sweep it off the thoracic wall for an extrapleural approach. As soon as possible, a rib spreader is inserted and opened stepwise with care. For continuation of the pleural stripping

towards the dorsal mediastinum, the use of two soft pledgets is recommended, one to hold the already reflected pleura under mild tension by pressing it towards the dorsal mediastinum, the other to proceed with the dissection. An inadvertent tear in the pleura can be closed with a fine (6/0) monofilament absorbable suture.

Figure 5.4

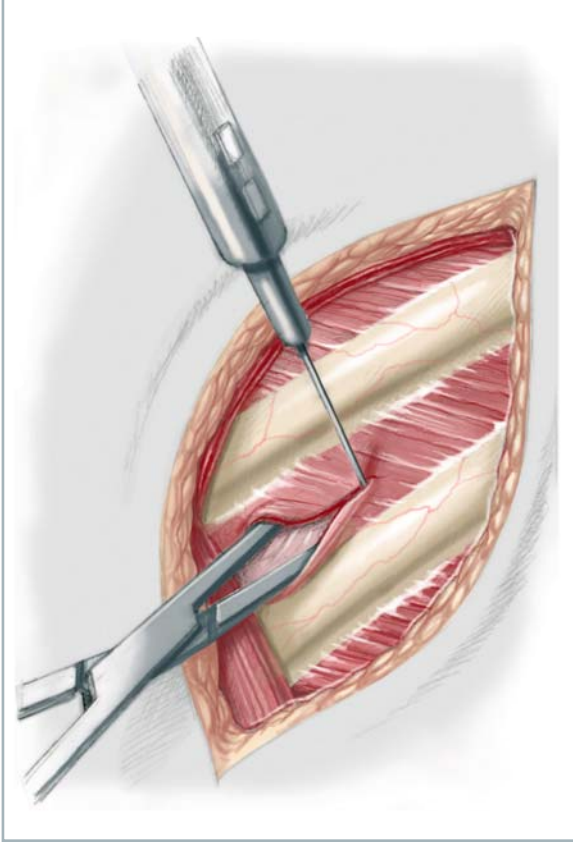


Figure 5.5

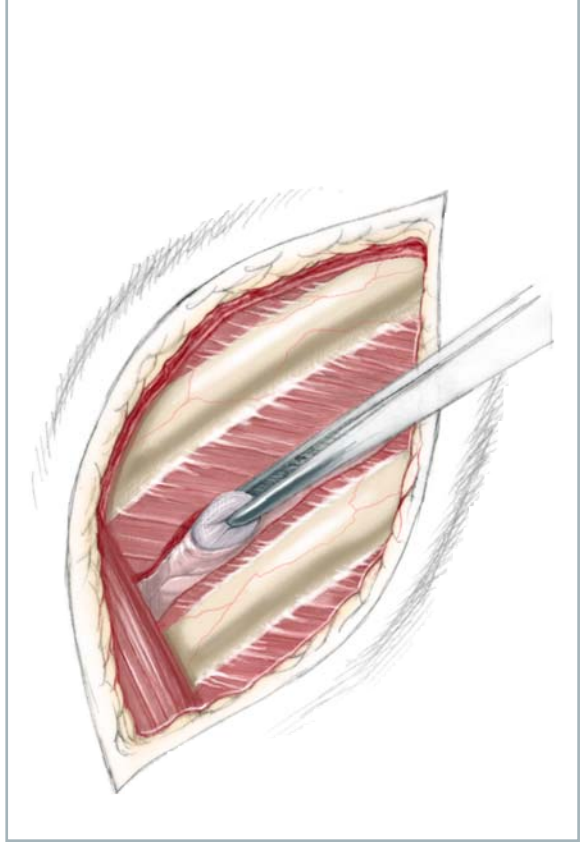


Figure 5.6

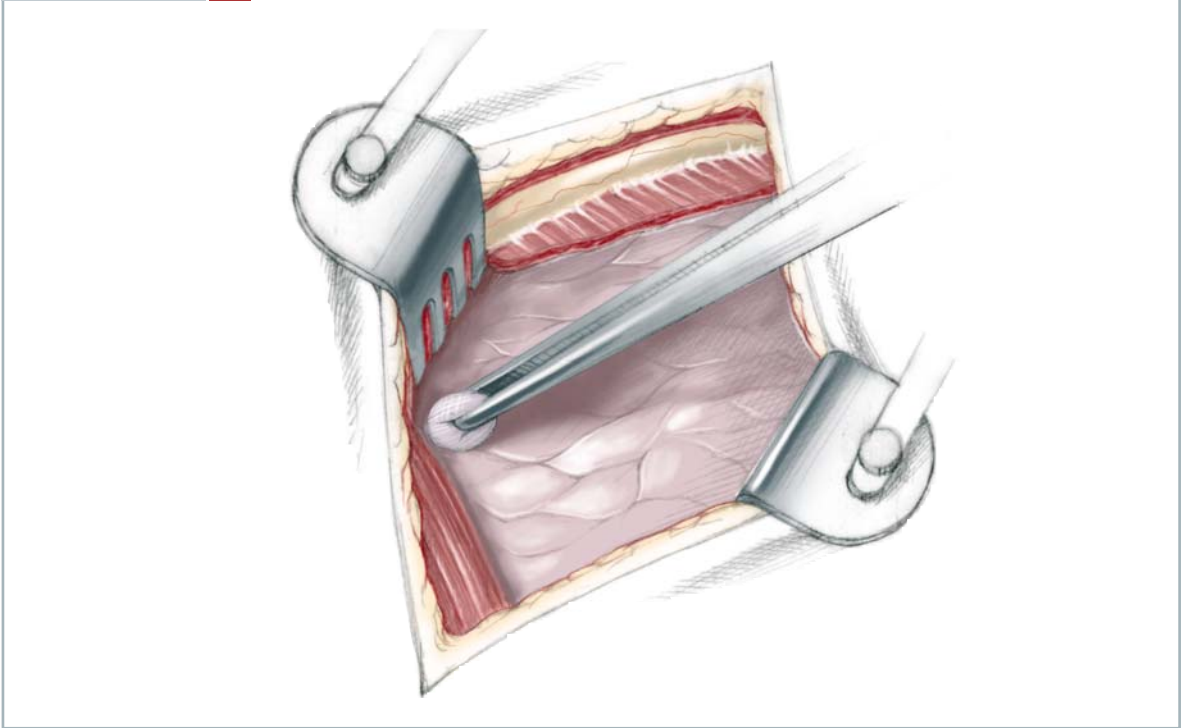


Figure 5.7

The azygos vein is mobilized with right-angled forceps and divided in between two ligatures (4/0 Vicryl). The right vagus nerve is identified, which runs along the lateral border to the upper pouch and accompanies the tracheo-oesophageal fistula towards the lower oesophagus. The lower oesophagus is usually rather thin and hypoplastic. Extreme care must

be taken to avoid any trauma to the delicate tissue. Handling and squeezing the oesophageal wall with forceps should be restricted to an absolute minimum. Preservation of all vagal fibres supplying the lower oesophagus is also aimed for. Denudation invariably entails a significant motility disorder and may cause severe gastro-oesophageal reflux.

Figure 5.8, 5.9

Right-angled forceps are passed behind the distal oesophagus and a vascular sling is placed around it in order to pull it away from the trachea. This facilitates identification of tracheo-oesophageal fistula, which is now freed from surrounding tissue.

Traction sutures are then placed at the tracheal and oesophageal ends of the fistula, and one additional stay suture nearby holds the lower oesophagus.

Figure 5.7

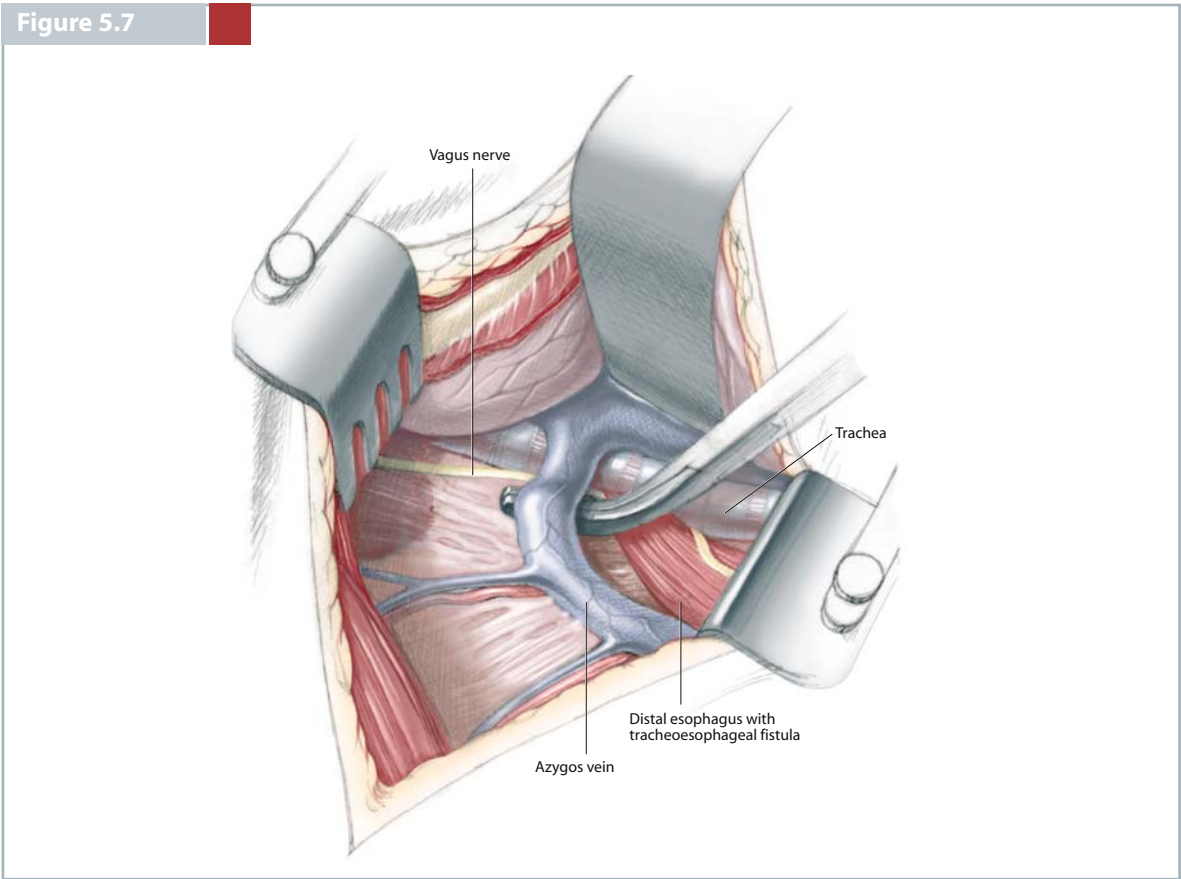


Figure 5.8

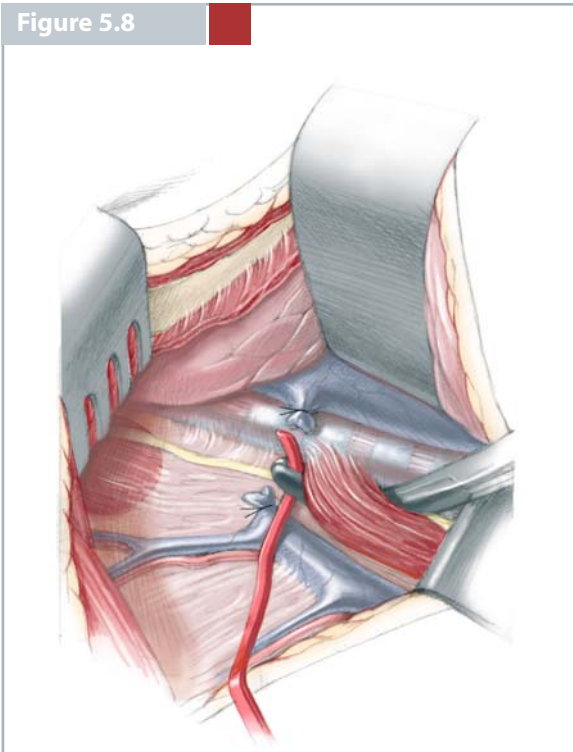


Figure 5.9

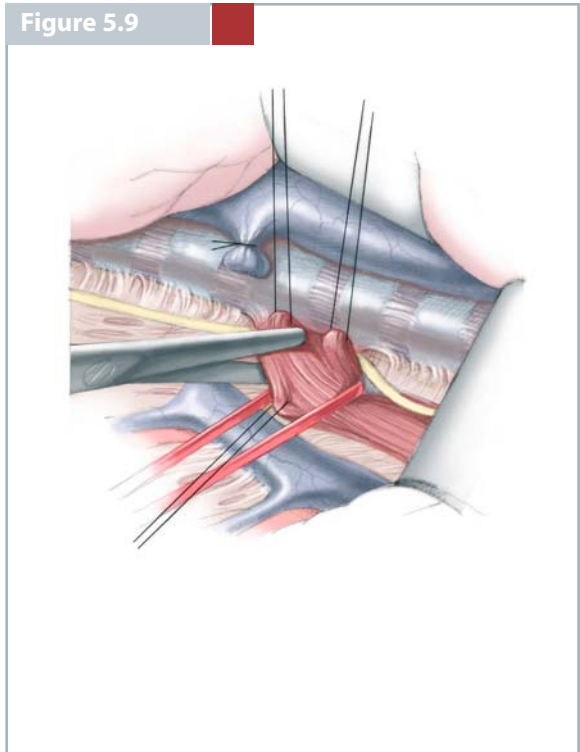


Figure 5.10

At this stage, the fistula is divided and closed with a continuous absorbable monofilament 6/0 suture. Some authors prefer interrupted stitches, others apply transfixation stitches. The level of division must be as close to the trachea as possible without risking a narrowing of the airway. Since most fistulas run obliquely upwards, a small residual pouch frequently

remains in the trachea. The fistula closure is tested for an air leak by watching out for air bubbles during forceful ventilation after filling warm saline solution into the chest. At this stage it is advisable to temporarily relieve the lung from the continuous retraction and achieve through careful ventilation cycles a full expansion of all collapsed areas.

Figure 5.11

The upper pouch is often retracted into the neck. Asking the anaesthetist to push on the Replegle tube serves to advance the upper pouch into the operative field. Traction sutures are placed on either side of the pouch to assist mobilization. Dissection of the oesophagus from the trachea is most challenging because they are adherent to each other by an intervening firm connective tissue layer. Sharp scissor dissection is required taking extreme care to avoid any accidental penetration into either organ. Anterior and lateral aspects of the upper pouch are easily freed using pledgets. If an upper fistula is encoun-

tered, it is transected close to the oesophagus and closed on both sides with interrupted monofilament absorbable 6/0 sutures. Contrary to the lower oesophagus, the upper pouch has an excellent blood supply and can be dissected up to the thoracic inlet if necessary. Thus, if a large gap exists, further dissection of the upper oesophagus is preferable to extensive mobilization of the lower segment which involves the risks of ischaemia and subsequent dysmotility. After the upper oesophageal pouch is mobilized, both segments are approximated to see whether an end-to-end anastomosis is possible.

Figure 5.12

Opening of the upper pouch for the anastomosis should be well centred at its lowermost point. This is best achieved by incising the pouch exactly over the tip of the fully advanced Replegle tube. An asymmetric opening results in an uncentred anastomosis, po-

tentially leading to lateral pre-anastomotic out-pouching. The upper pouch is opened by a horizontal incision, which results in a fish-mouth-shaped aperture, adapted to the diameter of the lower oesophagus.

Figure 5.10

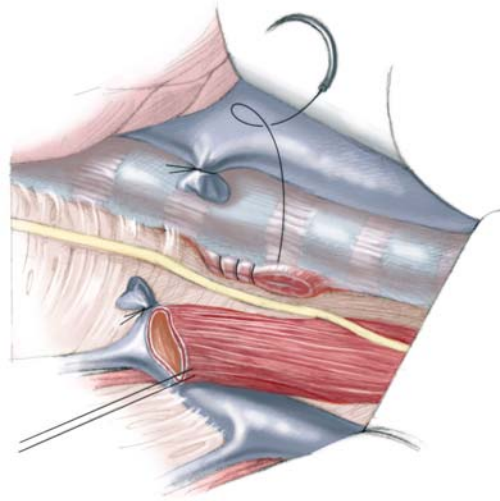


Figure 5.11

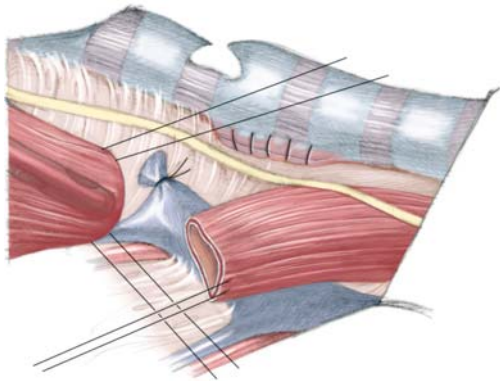


Figure 5.12

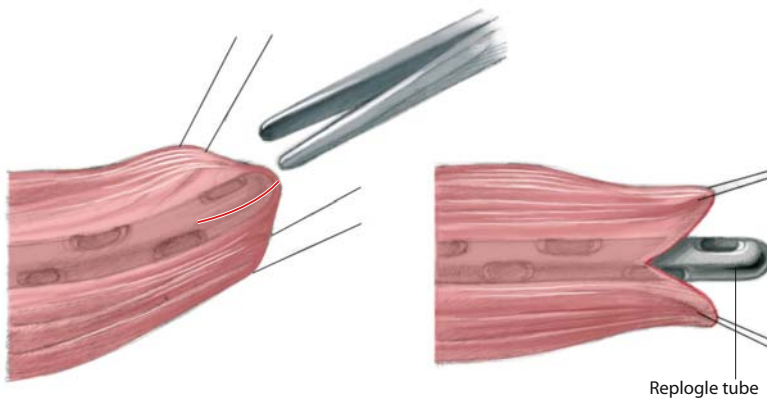


Figure 5.13, 5.14

The end-to-end anastomosis is fashioned with interrupted absorbable 6/0 sutures. The first two stitches are placed on either side. The posterior wall needs two or three additional sutures. Meticulous care must be given to take sufficiently large “bites” of muscular tissue together with the mucosal layer. The latter tends to retract upwards in the upper pouch as soon as it is opened. Once all posterior wall sutures are placed, the oesophageal segments are gently pulled together, and the sutures are tied on the mucosal surface. Thereafter, a 5F silastic feeding tube – the connection hub of which has been cut off – is sutured

with the cut end to the tip of the Replogle tube, which is then withdrawn by the anaesthetist until the feeding tube appears outside the mouth. The distal end of the feeding tube is passed into the stomach. The tube serves for postoperative gastrointestinal decompression and early feeding, and also functions as trans-anastomotic splint for drainage of saliva.

The anterior aspect of the anastomosis is completed in a similar way as described above with three or four stitches, this time tying the knots on the outside of the oesophageal wall.

Figure 5.15, 5.16

The goal of a tension-free end-to-end anastomosis can be achieved with this technique in most cases of oesophageal atresia with a distal fistula. If the tension appears to be too much despite mobilization of the upper pouch up to the thoracic inlet, further length may be gained with a circular myotomy in the upper pouch according to Livaditis. This is achieved by introduction of a 8F balloon catheter into the upper pouch transorally, which is transfixed at the lower end of the pouch with a 4/0 monofilament traction suture and the balloon is blown up until it fills the pouch. The muscle layer is then divided above the

balloon approximately 1 cm cranial to the future anastomotic line, either in a circular or in a spiral fashion. The mucosal layer of the upper pouch is rather thick so that mucosal tears can usually be avoided with careful dissection. The upper pouch can be lengthened by 5–10 mm by this method, which may suffice to create an anastomosis without undue tension. Development of a pseudodiverticulum (out-pouching of the mucosa through the established gap in the muscle layer) after circular myotomy has been described.

Figure 5.13

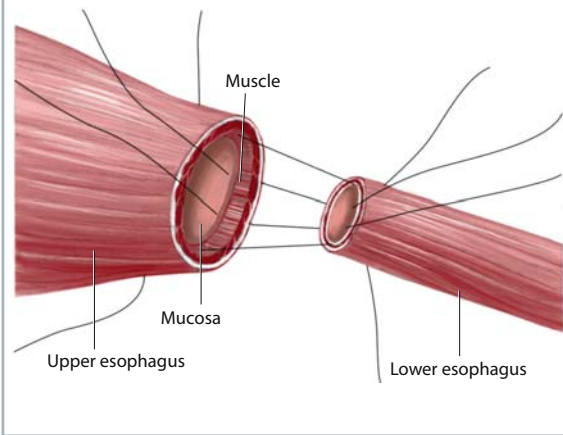


Figure 5.14

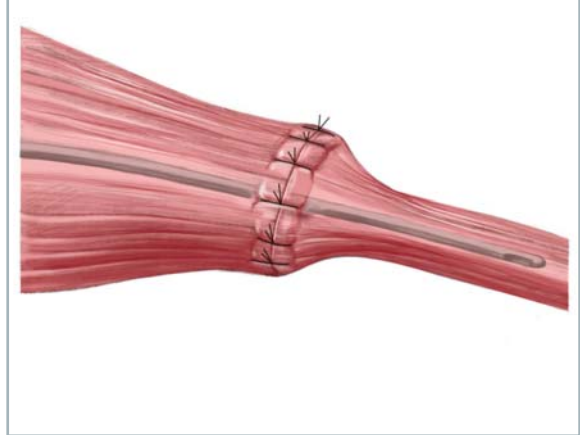


Figure 5.15

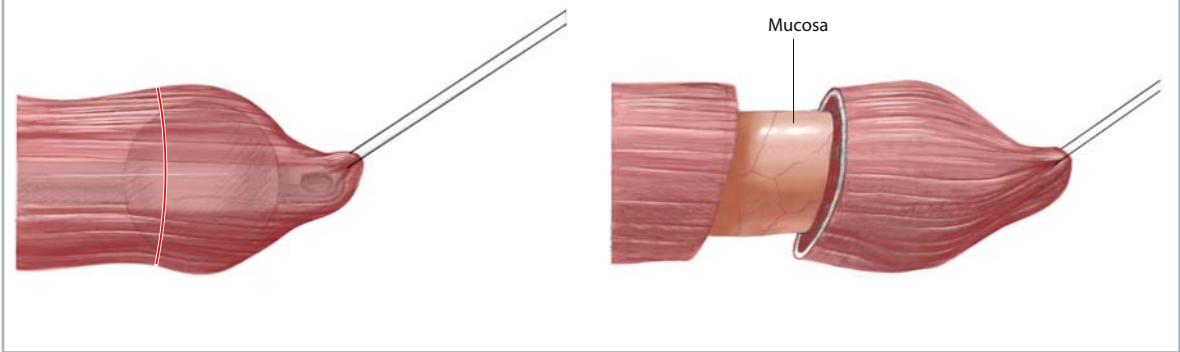


Figure 5.16

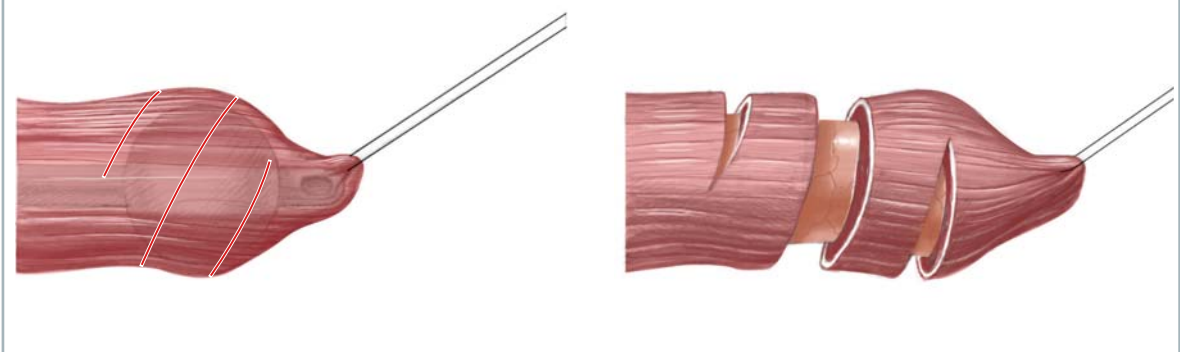


Figure 5.17, 5.18

Another way to reduce inappropriate tension on the anastomosis is to fashion a mucosal-muscular flap from a larger upper oesophagus. A right-angled incision is made in one half of the upper pouch. The flap thus created is turned by 90° so that the vertical cut surface faces downwards. It is then rolled into a tube. However, the gain in length results in a reduction in diameter.

If a satisfactory dorsal wall anastomosis can be established, but undue tension arises in the anterior half, a right-angled flap in the corresponding part of the upper pouch without tubularization may bridge the gap and result in a safe anastomosis.

The thoracic cavity is irrigated with normal saline. A soft drain is introduced via a separate intercostal stab incision and the tip placed near the anastomosis. Before closure, the lungs are fully expanded by

forced ventilation until all collapsed regions are well aerated again.

The ribs are approximated with two or three pericostal sutures. Latissimus dorsi and serratus anterior muscles are allowed to fall back into their original positions and are sutured to their fascial insertion sites with one or two 3/0 absorbable sutures each. The subcutaneous fat is readapted with 5/0 absorbable sutures including the corium. This technique approximates the skin perfectly in most cases so that separate skin sutures are not necessary. The incision is simply approximated with adhesive strips. In those cases in whom wound margin adaptation remains unsatisfactory, a continuous subcuticular monofilament 5/0 suture is applied, which is pulled after a few days.

Figure 5.17

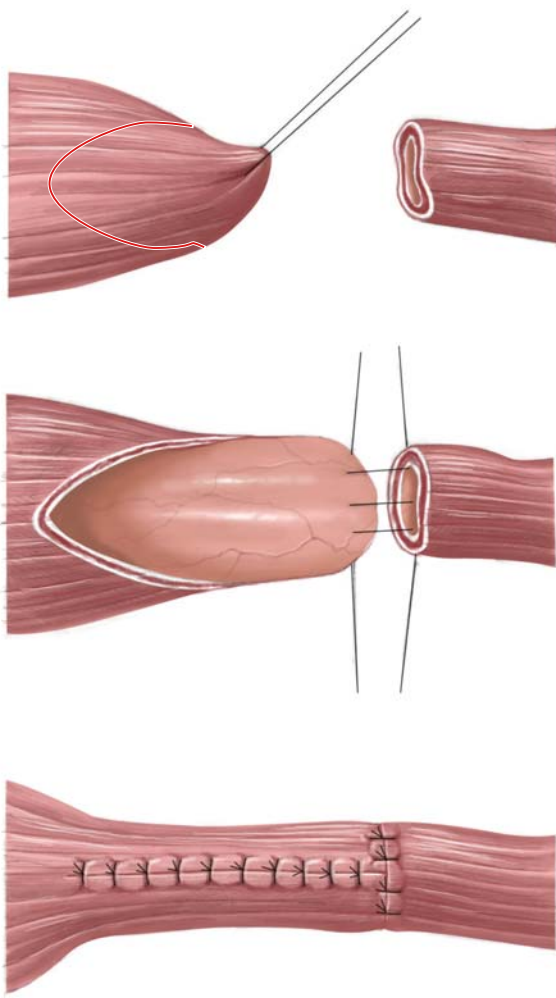


Figure 5.18

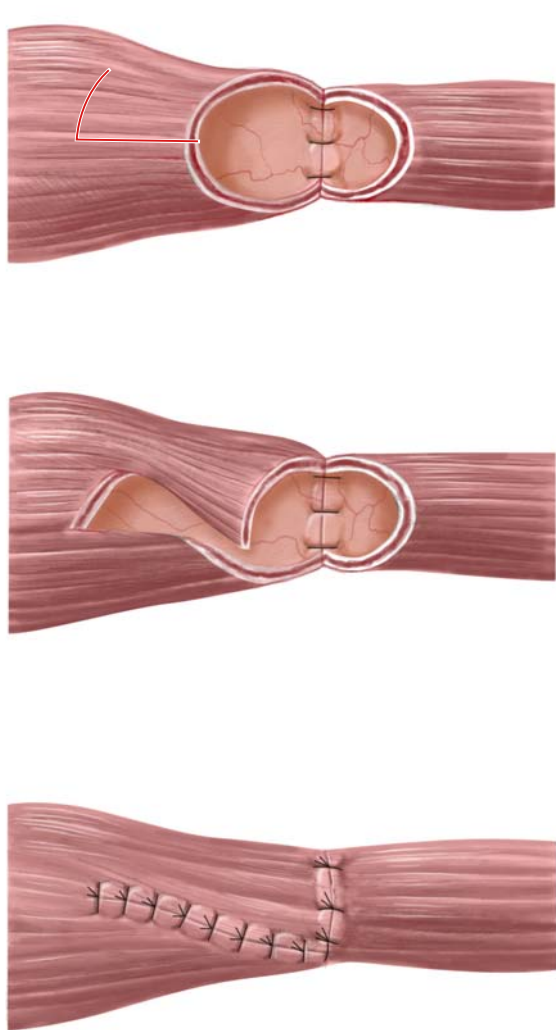


Figure 5.19

An airless abdomen on thoraco-abdominal X-ray leads to suspicions of oesophageal atresia without a lower fistula (10%). A primary end-to-end anastomosis is not possible in these cases due to the long distance between the oesophageal pouches.

Two basic surgical strategies are available in cases of long-gap oesophageal atresia: either preservation of the patient's own oesophagus or oesophageal replacement. Three opinions exist concerning preservation and delayed repair of the native oesophagus in the absence of a lower fistula. The first is to await spontaneous growth, which is more pronounced in the upper stump. As experience tells us, it takes 8–12 weeks on the average until a safe anastomosis is feasible. Second, one can attempt to promote elongation of the upper oesophageal segment by regular longitudinal stretching. Third, approximation may be further accelerated by additional bouginage of the lower pouch. The latter is our preferred method, permitting one to anastomose the two segments after 3–5 weeks.

A primary gastrostomy is essential for enteral feeding in all long-gap oesophageal atresia cases. It is

also used for estimation of the length of the gap as well as for the distal elongation manoeuvre.

A transverse incision is made in the left epigastric area at a level midway between umbilicus and costal angle. We favour a Stamm gastrostomy with two circular 3/0 absorbable purse-string sutures close to the gastric angle on the lesser curve. The stomach wall is incised in the centre of the purse-string sutures. If stretching of the lower pouch is not desired, a proper gastrostomy tube is introduced, the purse-string sutures are tied and fixed to the parietal peritoneum within the incision. If, however, a longitudinal bouginage from above and below is planned, a jejunostomy for feeding is fashioned in the first jejunal loop with a separate exit below the abdominal incision and with a single 3/0 purse-string suture that is anchored on the internal aspect of the abdominal wall. The feeding tube is advanced deep into the jejunum. Enteral feeding may be started after 24 h.

Figure 5.20

If mechanical elongation of the lower pouch is planned, the gap is assessed in the following way: a 8F–10F feeding tube is cut approximately 10–13 cm from its distal end, and a 70° curved metal sound is introduced into the feeding tube up to its tip. This assembly is passed into the lower oesophageal pouch via the stomach. At the same time, the anaesthetist introduces a radio-opaque device into the upper pouch. Both probes are pushed towards each other under fluoroscopic control, and the distance between the maximally approximated oesophageal stumps is gauged. Usually it corresponds to four or more vertebral bodies. The feeding tube with the metal probe is

kept in the stomach for the stretching procedures, and longitudinal stretching of both oesophageal stumps is performed twice daily for 3–5 min under mild sedation. Gentle pressure is used in the lower, more forceful pressure in the upper pouch. Leaving the manoeuvre in the same experienced hands throughout has saved us from ever causing a perforation. Progress of elongation is evaluated by weekly fluoroscopic calibration and radiographic documentation. Distinct overlapping of the segments, which is necessary for end-to-end anastomosis without tension, is achieved within 3–5 weeks.

Figure 5.19

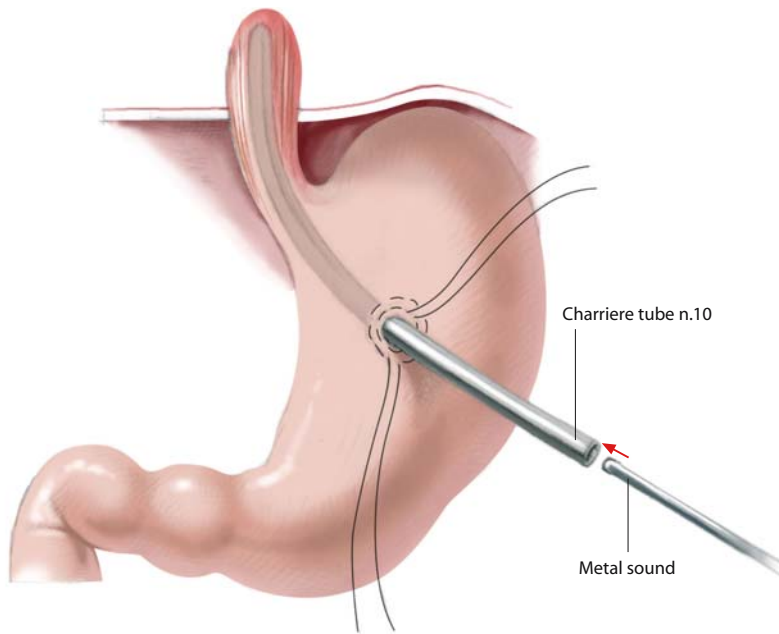


Figure 5.20

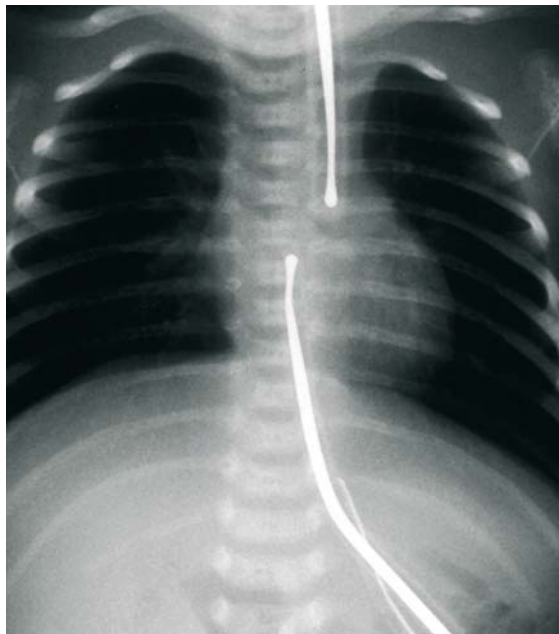


Figure 5.21

H-type fistulas without atresia account for about 3% of the tracheo-oesophageal anomalies. Presentation is usually more protracted and sometimes delayed beyond the first year of life. Typical symptoms are choking episodes during feeding together with cyanotic spells. Diagnosis is made either by contrast oesophagogram or tracheobronchoscopy. If an H-type fistula is confirmed, a 3F ureteric catheter is passed across the fistula during bronchoscopy. Most H-type fistulas can be approached from the neck because they are usually situated at or above the level of the second thoracic vertebra. For the cervical repair, the child is placed supine on the operating table. The head is turned to the left and a folded towel or a sandbag is placed underneath the shoulders to hyperextend the neck. This position maximally ex-

pands and exposes the right cervical area. The incision follows a suitable skin crease, approximately 1 cm above the medial third of the right clavicle. After dividing the platysma, the medial border of the sternomastoid muscle is retracted posteriorly.

The dissection proceeds medially to the carotid artery, and it may be necessary to divide the middle thyroid vein and the inferior thyroid artery to reach trachea and oesophagus which are situated medial and posterior to thyroid lobes and isthmus. Palpation of the tracheal cartilages and the feeding tube in the oesophagus facilitates anatomical orientation. The recurrent laryngeal nerve runs upwards in the groove between trachea and oesophagus close to the fistula. It must be clearly identified and protected from any injury.

Figure 5.22–5.24

The plane between oesophagus and trachea is carefully developed. The ureteric catheter in the fistula aids its identification. Right-angled forceps are used to dissect the fistula and a small vascular sling is passed around it. Two stay sutures are placed on the oesophageal side of the fistula, which is divided after withdrawal of the ureteric catheter. A transfixation

monofilament absorbable 6/0 suture is employed to close the tracheal side of the fistula and the oesophagus in interrupted technique. The wound is closed in layers with absorbable suture material finishing with interrupted subcuticular absorbable 6/0 sutures. At the end of the operation, the motility of the vocal cords should be reassessed.

Figure 5.21

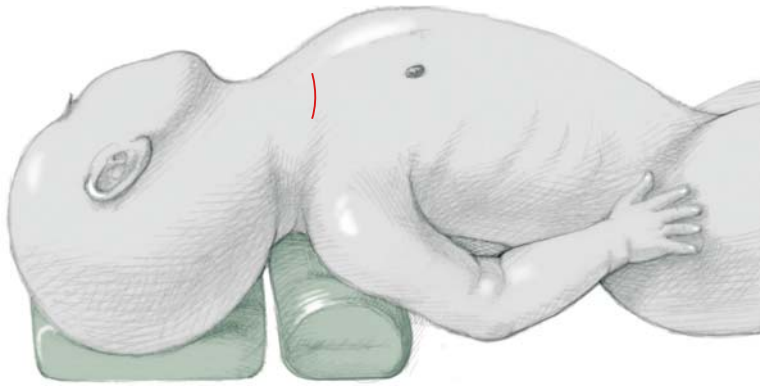


Figure 5.22

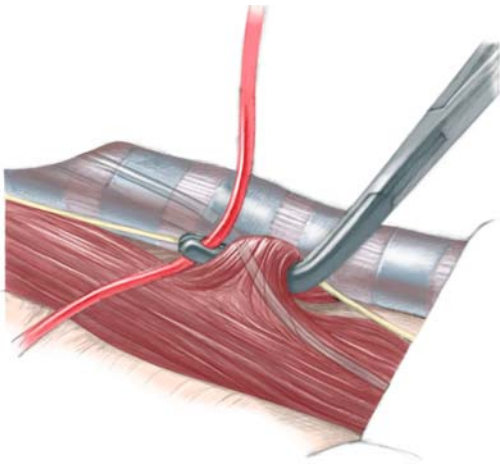


Figure 5.23


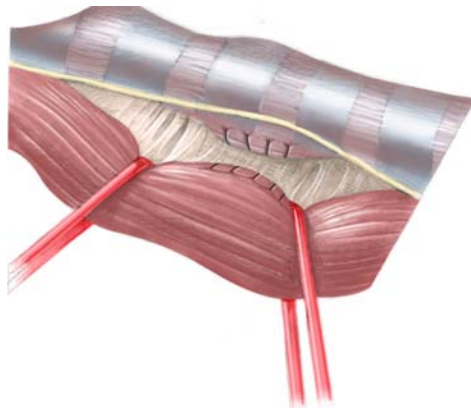


Figure 5.24



CONCLUSION

The first successful primary repair of an oesophageal atresia was achieved by Cameron Haight in 1941. Mortality remained, however, high in the following decades. The outcome was influenced by birth weight, severity of additional malformations, and development of aspiration pneumonia due to delayed diagnosis. Nowadays, the diagnosis is, in most cases, established immediately after birth, and pneumonia can be prevented by continuous suction of the upper pouch. Survival of premature infants has significantly improved with progress in neonatal intensive care. Thus, severe associated anomalies have become the main factor determining outcome. While basic surgical management has become uniform for the most common type of oesophageal atresia with a lower fistula, the best strategy for babies with long-gap oesophageal atresia has remained controversial. Some authors – including our team – prefer to restore the native oesophagus whenever possible, even at the price of severe gastro-oesophageal reflux, whereas others propagate more generous indications for oesophageal substitution, either with colon or stomach.

The overall prognosis of patients with oesophageal atresia is good, but recurrent dysphagia, secondary problems of gastro-oesophageal reflux, and an increased incidence of recurrent respiratory tract infection – possibly due to repeated minimal aspirations during sleep – are common sequel. The distal oesophagus frequently suffers from delayed clearance due to disturbed motility. The impairment of propulsive peristalsis may be part of the malformation pattern, but may be iatrogenically worsened by damage of vagal nerve fibres during dissection of the

distal oesophageal pouch. However, severe swallowing problems with dysphagia are rare, but impaction of foreign bodies, most often bread, meat or fruit pieces, may be partially attributable to the motility disorder.

An anastomotic stricture can be either the result of an anastomosis fashioned under high tension, impaired perfusion and/or an anastomotic leak, or it may be caused by continuous acid exposure due to gastro-oesophageal reflux. Clinically, delayed clearance of acid reflux is probably of greater importance due to the high incidence of gastro-oesophageal reflux disease that exceeds 40% in patients with oesophageal atresia.

Atypically shaped cartilaginous C-rings and a wide intercartilaginous membrane within the region of the former fistula may be underlying causes of another common complication: tracheomalacia with an incidence around 20%. The anterior-posterior diameter of the trachea is reduced and may collapse completely with strained inspiration and expiration. The anomaly rarely causes serious problems and usually resolves with age and growth. Sometimes, however, severe respiratory distress with near-miss events may occur. Continuous monitoring and urgent treatment are then indicated. Aortopexy under bronchoscopic control is currently the most commonly used surgical method. It resolves the problem in many cases, unless the weak tracheal segment is too long. Recently, tracheoscopic stabilization with a self-expanding or balloon-expandable stent has been advocated. The ideal stent has, however, yet to be found and long-term results are awaited.

SELECTED BIBLIOGRAPHY

- Deurloo JA, Ekkelkamp S, Schoorl M, Heij HA, Aronson DC (2002) Esophageal atresia: historical evolution of management and results in 371 patients. *Ann Thorac Surg* 73: 267–272
- Kluth D, Steding G, Seidl W (1987) The embryology of foregut malformations. *J Pediatr Surg* 18: 217–219
- Lemmer JH, Mark NG, Symreng T, Ross AF, Rossi NP (1990) Limited lateral thoracotomy. *Arch Surg* 125:873–877
- Little DC, Rescorla FJ, Grosfeld JL, West KW, Scherer LR, Engum SA (2003) Long-term analysis of children with esophageal atresia and tracheoesophageal fistula. *J Pediatr Surg* 38: 737–739
- Livaditis A, Rafberg L, Odensjö G (1972) Esophageal end-to-end anastomosis. Reduction of anastomotic tension by circular myotomy. *Scand J Thorac Cardiovasc Surg* 6: 206–211

Gastro-oesophageal Reflux and Hiatus Hernia

Keith E. Georgeson

INTRODUCTION

Most infants spit up milk after feedings, sometimes in a spectacular fashion. This post-prandial regurgitation is rarely associated with any serious consequences to the baby and is usually outgrown by 1 year of age.

Pathologic gastro-oesophageal reflux (GER) in infants is associated with potentially serious complications including failure to thrive, recurrent apnea and aspiration of gastric contents. Older children can also present with reactive airways disease, chronic sinusitis and peptic oesophagitis.

A careful history is invaluable in eliciting the symptoms of GER in children. Frequent regurgitation, asthma associated with recumbency and extreme irritability are all potential signals of GER. Further workup should include an upper gastrointestinal study to rule out other anatomic causes of regurgitation and to detect the presence of a hiatus hernia. A 24-h pH probe study is considered the gold standard for detecting pathological GER in children. A negative pH probe study does not rule out symptomatic GER due to the common occurrence of non-ac-

id reflux in paediatric patients. Upper gastrointestinal endoscopy is occasionally useful in defining the presence of oesophagitis secondary to GER. Gastric emptying studies are not usually useful in the work-up for GER in children.

Proton pump inhibitors and promotility agents are useful therapeutic modalities for most children with pathologic GER. Even those patients who do not fully respond to medical management should be treated for 8 weeks before surgical therapy is considered, unless the patient is experiencing life-threatening symptoms.

Antireflux surgery is indicated in patients with inadequate response to medical management or in children who cannot be weaned from medical management. Antireflux surgery is also appropriate in children with the complication of peptic oesophagitis presenting with a stricture or Barrett's oesophagus. Those infants with life-threatening events despite optimal medical management are also candidates for immediate surgery.

Figure 6.1

The intubated patient is positioned at the end of the operating table. The knees are flexed and the feet cushioned. The patient is taped to the table so he/she will not slide when placed in the reversed Trendelenburg's position. The operator stands at the end of the table, which is positioned low enough for easy manipulation of the laparoscopic instruments. A large Maloney bougie is passed through the mouth into the

stomach. The dilator should be large enough to fully distend the distal oesophagus for safer peri-oesophageal dissection. The patient's head should be positioned so that the anaesthetist has access to withdraw and advance the dilator as needed throughout the course of the operative procedure. The patient is prepped from nipples to groin.

Figure 6.2

Five trocars are inserted in the abdominal wall. Unlike adult patients, who have a precisely defined position for each trocar, children have more variation in body habitus and liver position so the placement of the trocars must be tailored to the individual patient. The initial trocar placement is through the centre of the umbilicus in the midline. Each trocar site should be infiltrated prior to the placement of the trocar with a local anaesthetic. The incision in the umbilicus should be the same size as the trocar. The umbilical scar does not stretch well. An extremely tight trocar will cause ischaemic injury to the skin of the umbilicus if the skin incision is not large enough to accommodate the trocar. The incision should be made through the central portion of the umbilicus. The peritoneal cavity is usually easily entered through the umbilicus because the layers of the abdomen are scarred together at this point. Once the peritoneal cavity is opened with a no. 11 blade, a curved mosquito clamp is introduced into the peritoneal cavity with the tip upward pointing away from the abdominal viscera. The clamp is pushed inward to dilate the umbilical opening allowing easier access to the peritoneal cavity. A radially expanding disposable 5-mm trocar with a fitted Veress needle is then passed into the peritoneal cavity while pulling upward on the umbilical skin. The trocar should be advanced at a 30° angle and its tip kept as close to the parietal peritoneum of the anterior abdominal wall as possible to avoid injury to intra-abdominal or retroperitoneal

structures. The Veress needle inside the expandable sheath is then removed and the trocar cannula inserted through the plastic sheath expanding the trocar and fixing it to the abdominal wall due to its snug fit. Suture fixation is sometimes necessary in smaller infants with a thin abdominal wall. A 30° 4-mm scope is advanced through the umbilical trocar after a pneumoperitoneum has been instilled. This scope is then used for surveillance during the placement of the other four trocars. The second trocar is placed in the right upper quadrant. This trocar should be positioned at the inferior margin of the liver border in the right anterior axillary line. The articulated retractor is passed toward the left upper quadrant and tightened to form its working position. It is then secured to the frame of the operating table by way of a retractor holder. The third, fourth and fifth trocars are then placed under laparoscopic surveillance. All but the umbilical trocars are reusable 3- or 4-mm trocars except in patients over 20 kg when a larger liver retractor is passed through a 5-mm trocar.

Trocar site 3 is used for the endoscope and is also the prospective gastrostomy site during gastrostomy button placement. Trocar sites 2 and 4 are the working ports for the operating surgeon. Trocar site 5 is the initial entry point and is also used for surveillance during placement of the other 4 ports. When the endoscope is moved to port 3 to perform the operation, port 5 is used for intraperitoneal access by the surgeon's assistant.

Figure 6.1

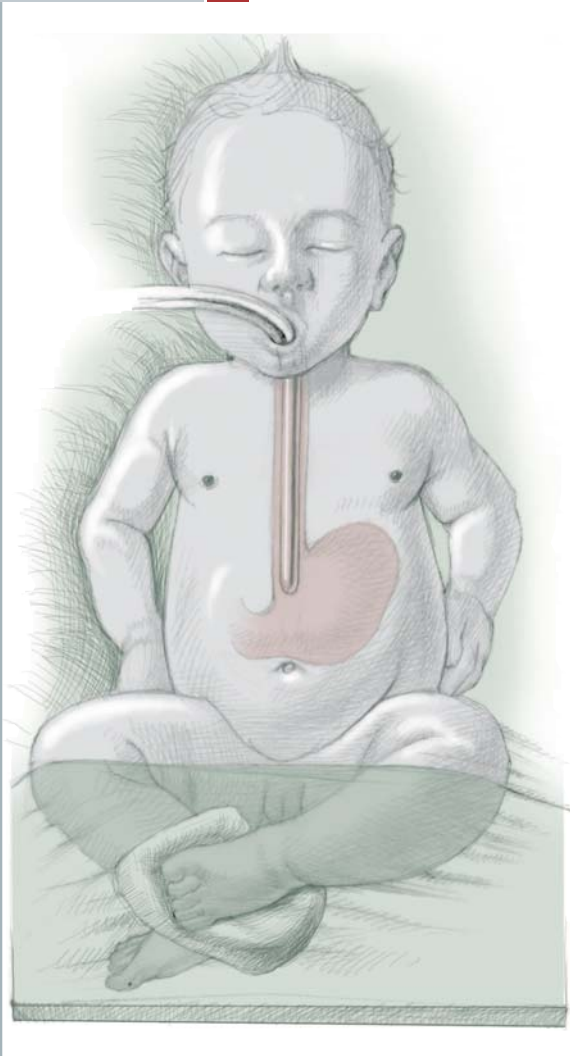


Figure 6.2

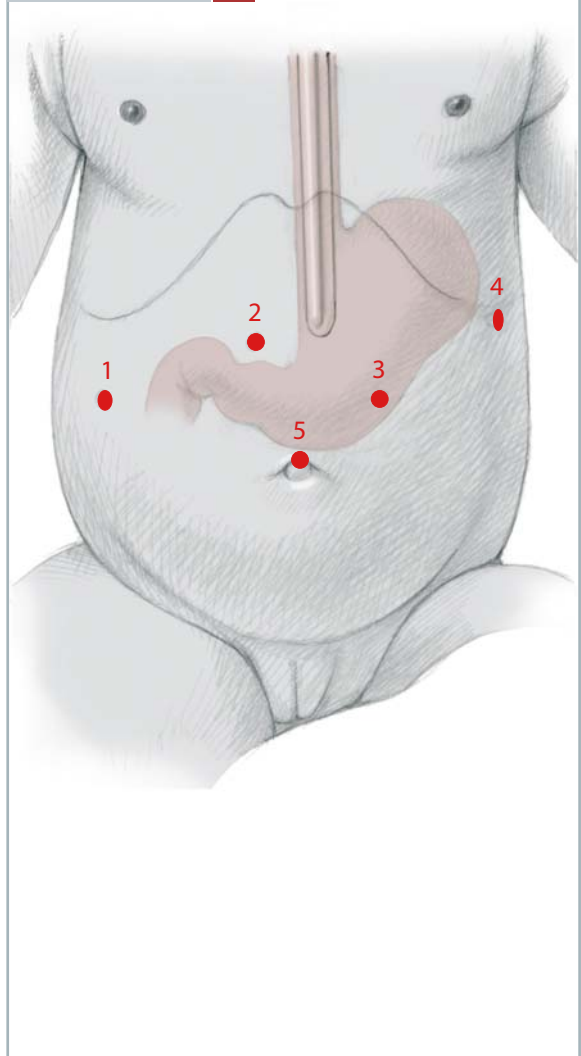


Figure 6.3

The intraperitoneal dissection is begun by opening the upper part of the hepatogastric ligament. The dissection is performed sharply. The hepatic branches of the vagus nerve are divided. The small vessels to the liver are also divided using electrocautery. Care is taken to avoid transecting the left hepatic artery, which can be found in this ligament in a very small number of patients. The dissection is carried up to the hiatus in an avascular plane. The phreno-oesophageal ligament is opened between the oesophagus and the right crus. The peri-oesophageal plane should be entered cleanly to avoid excessive bleeding

and to facilitate a faster operation. The dissection is continued in this plane bluntly and sharply over the top of the oesophagus and down the left side. The anterior vagus nerve is usually tightly adherent to the muscle of the oesophageal wall. However, occasionally the nerve falls away and is only loosely associated with the oesophageal wall. Linear structures along the anterior oesophageal wall should be carefully evaluated before dividing them. The cleavage between the oesophagus and left crus should be carried posteriorly until the fundus of the stomach is encountered.

Figure 6.4

The short gastric vessels are divided routinely. Dividing these vessels allows for much better visualization of the left crus and also contributes to a better geometry of the fundoplication wrap. In most patients, the vessels are divided with a hook electrocautery. In large or obese patients an ultrasonic scalpel is useful

in dividing the short gastric vessels. The gastrosplenic ligament is opened at the mid portion of the spleen. The dissection is carried cephalad from this point. Most patients have both an anterior and posterior leaflet of the gastrosplenic ligament. Vessels run in both leaflets.

Figure 6.3

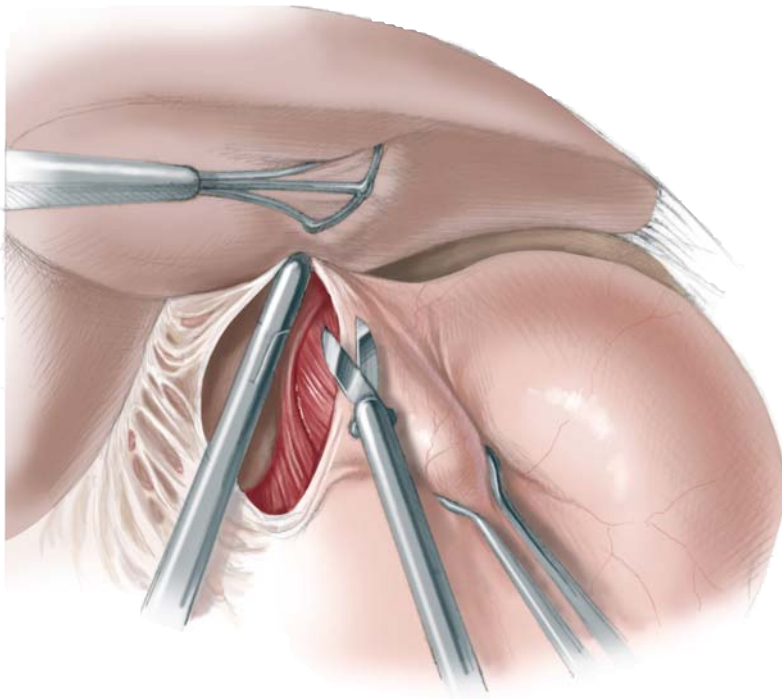


Figure 6.4

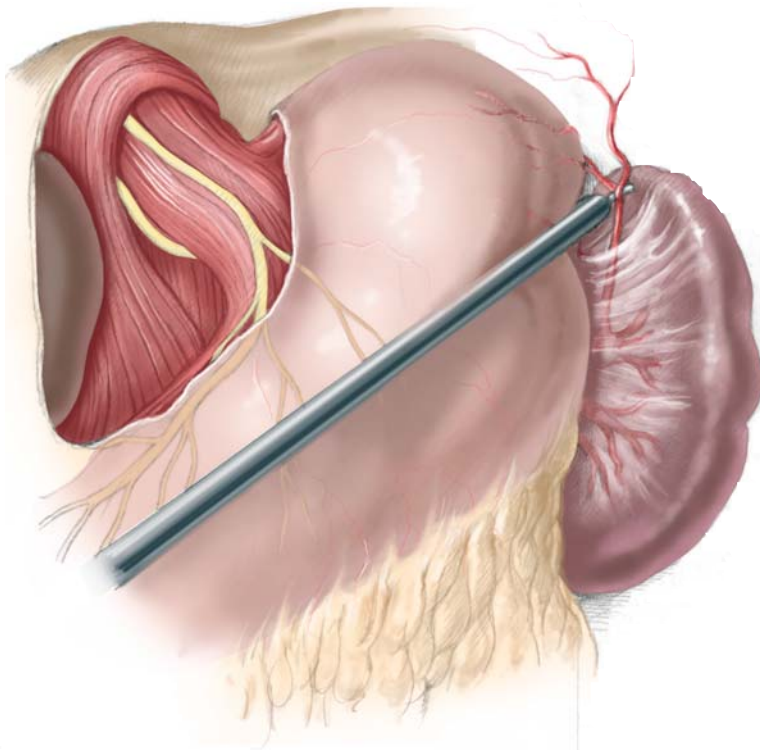


Figure 6.5

The left crus should be followed as it courses toward the right side behind the oesophagus. Dissection is performed from both sides. The fundus is pulled down using a grasper through the umbilical port site, which allows excellent visualization of the left crus. For visualization of the right crus, the grasper is pulled downward and toward the splenic flexure of the colon. By dissecting both sides alternately using the left crus as a guide, a window is safely formed behind the oesophagus. The tissues tethering the oesophagus to the crura are further divided circumferentially to lengthen the intra-abdominal portion of the oesophagus. The posterior vagus is vulnerable and should be identified and preserved. An instrument passed through the umbilical trocar is used to retract downward on the gastro-oesophageal junction while lengthening the intra-abdominal oesophagus. Circumferential dissection around the oesophagus is continued as far into the mediastinum as necessary to provide at least 2.5 cm of oesophagus in the abdomen with no downward tension on the oesophagus. If less than 2.5 cm of oesophagus remains in the abdomen after releasing the downward tension on the oesophagus, consideration should be given to lengthening the abdominal oesophagus by tubularizing the upper stomach. As much as possible, the fascia covering the crura should be left intact. Care should also be taken to avoid entry into the plural cavity on either side. If a hole is made in the pleura it should be enlarged to avoid the development of a tension pneumothorax caused by a one-way ball-valve effect. The pneumothorax can be evacuated by needle thoracentesis at the end of the operation.

Figure 6.6

The crura are closed in every case by approximating them behind the oesophagus with non-absorbable sutures. Generous bites of crus are taken on both the left and right sides and are tied snugly. The aorta is located behind the posterior aspect of the left crus and should not be incorporated in the suture closing the crura. The author prefers to close the crura with the dilator withdrawn into the oesophagus. Great care should be taken to avoid closing the hiatus too tightly. If a large dilator is left in the intra-abdominal oesophagus, suture placement is more difficult and the hiatus is often left larger than it should be. With large hiatal defects, the hiatus may require both posterior and anterior closure. Once the hiatus is closed around the oesophagus, at least 2 cm or more of oesophagus is fixed in the abdomen utilizing three or four collar sutures. These sutures are usually placed at the 11, 7 and 3 o'clock positions on the oesophagus incorporating a portion of the oesophageal wall and coapting it to the associated crus. For large hiatus hernias it may take four or more collar sutures to adequately close the oesophageal hiatus.

Figure 6.7

The mobilized fundus is pushed up beside the left side of the oesophagus. A grasper via the umbilical port is used to lift the oesophagus exposing the fundus behind the oesophagus. The fundus is grasped and pulled through the retro-oesophageal window.

The fundus is fluffed until a geometric symmetry is achieved. A "shoe shine" manoeuvre is used to confirm the fundal wrap and to avoid attaching the fundus to the mid portion of the stomach.

Figure 6.5

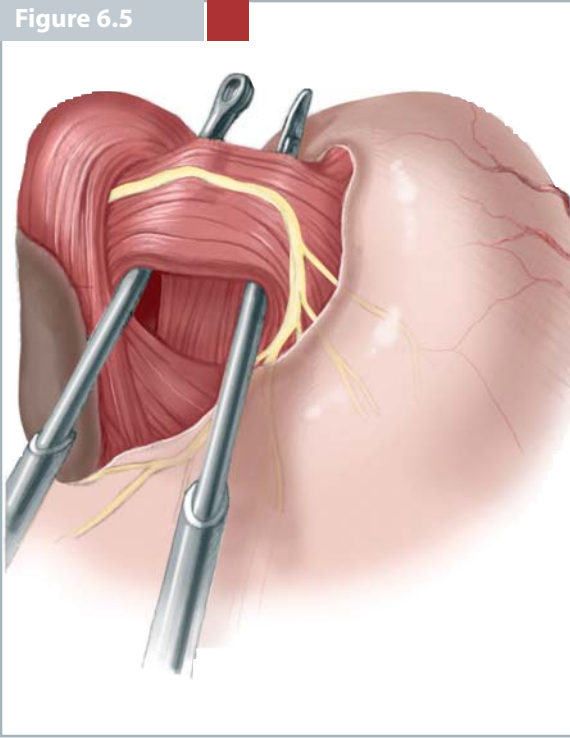


Figure 6.6

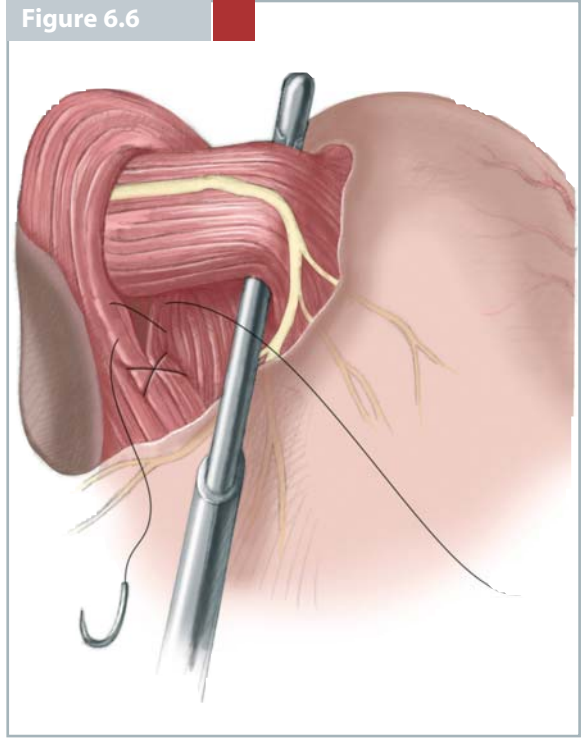


Figure 6.7

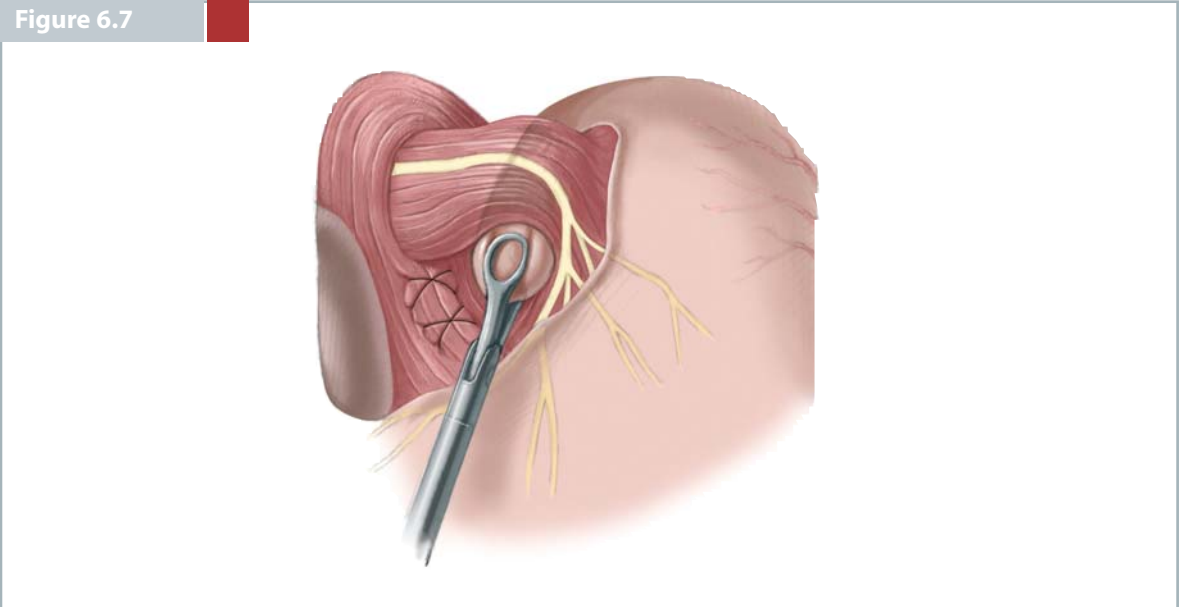


Figure 6.8

The dilator should be repositioned into the stomach at this time. The left side of the fundus is then basted to the right side of the fundus with a single stitch that does not incorporate oesophageal tissue. The wrap should be loose and should encircle the oesophagus. Two or three non-absorbable sutures are placed above and/or below the first stitch incorporating the

left and right sides of the fundal wrap and securing them to the oesophagus. The wrap should be no more than 1.5–2 cm in length and lie loosely around the oesophagus. A figure-of-eight suture is then placed near the bottom of the wrap as a second layer to secure the fundoplication and prevent wrap breakdown.

Figure 6.9

Gastrostomy placement is performed in conjunction with fundoplication only in those patients who have swallowing disorders or severe failure to thrive. It is not used as a routine procedure to decompress the stomach after a fundoplication. The laparoscope is moved back to the umbilical port. A locking grasper is passed through the medial left upper quadrant trocar site. This trocar is initially positioned with the intention of using this site as the gastrostomy site. The stomach is grasped near the greater curvature at the junction of the body and antrum. If a fundoplication

was not performed, the stomach should be grasped close to the lesser curvature. Using a large curved needle with a monofilament suture swaged to the needle, a U-suture is passed through the abdominal wall through the stomach taking a 1–0.5 cm bite of stomach and back through the abdominal wall. Passing the suture into the gastric lumen does not seem to lead to complications. A second U-suture is passed parallel to the first 1.5 cm lateral to the first suture. The grasper is then removed along with the trocar.

Figure 6.8

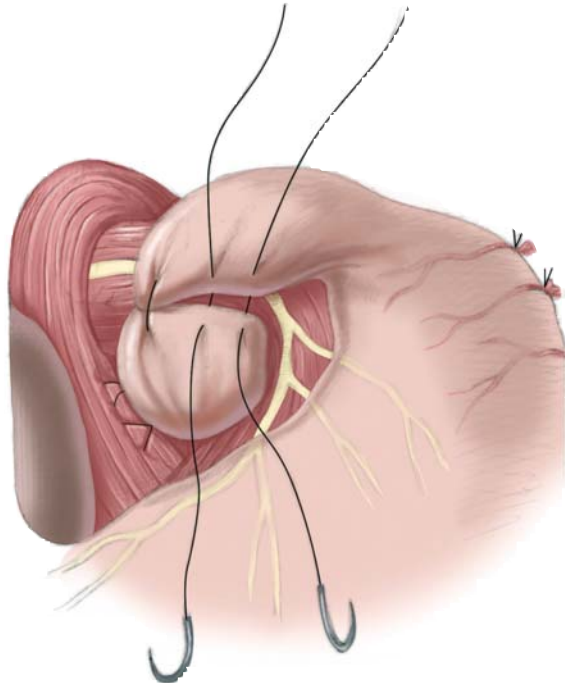


Figure 6.9

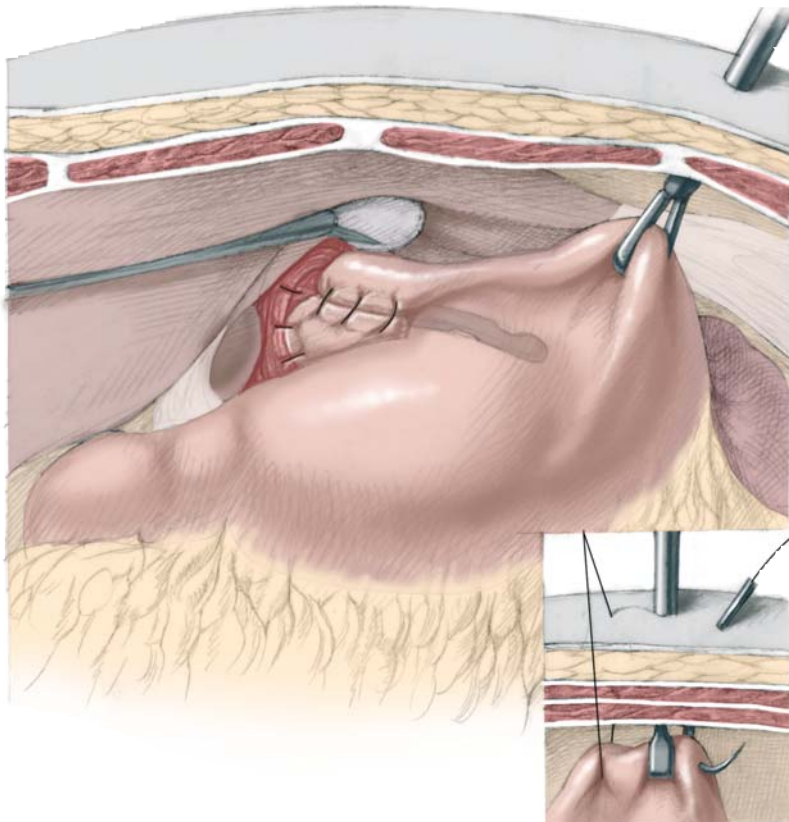


Figure 6.10

The anaesthetist passes a single lumen orogastric tube into the stomach and inflates the stomach with 60–120 cc air. A hollow needle is passed through the medial left upper quadrant trocar site into the inflated stomach. The passage of the needle into the lumen of the stomach should be visualized completely and should not occur on the blind side of the stomach. A J-wire is then passed through the needle into the

stomach and the needle removed over the J-wire. The tract is dilated with vascular dilators from a size 8-French up to a size 20-French. The 20-French dilator should be passed through the abdominal wall only and not into the stomach. The U-suture should be allowed to slacken during passage of the 20-French dilators to avoid passing of the dilator into the stomach.

Figure 6.11

The gastrostomy button is stiffened by passing the 8-French dilator through it. The dilator and balloon button are passed over the guide wire. Gentle twisting of the balloon button while holding countertraction on the U-suture allows the balloon button to slip into the stomach under laparoscopic surveillance. The balloon should be inflated under direct visualization. The U-sutures are slackened at this point to make certain that the stomach is independently held against the abdominal wall by the inflated balloon button. The U-sutures are then tied over the wings of the balloon button. The laparoscope is passed through the lateral left upper quadrant trocar site to look at the gastrostomy button from a different angle to assure that it is properly positioned and remains inflated.

The liver retractor is removed using laparoscopic surveillance. The umbilical trocar is the first trocar to be removed after the pneumoperitoneum is evacuated. The fascia of the umbilicus is closed using a groove director to protect the underlying bowel and omentum. A simple or figure-of-eight suture is used

to close the umbilical fascia. Once closure of the umbilical fascia has been achieved, the pneumoperitoneum is reinstated and the umbilical closure visualized from a lateral port site to confirm that the omentum has not been incorporated in the umbilical closure. The other trocars are then removed. The fascia in these other trocar sites does not usually require closure. The skin is closed with subcuticular sutures and skin strips. The umbilical skin should be closed carefully with rapidly absorbable braided suture. Careless closure of the umbilicus can result in granuloma formation post-operatively.

The patients are fed clear liquids on the day of surgery. Pureed foods are useful for 3–4 weeks to avoid the dysphagia associated with oedema of the fundoplication wrap. Discharge is 1–3 days after surgery. Post-operative pain is controlled with intravenous ketorolac, scheduled acetaminophen and ibuprofen. Narcotic agents are only used when necessary. The U-sutures in the gastrostomy are removed on the second post-operative day.

Figure 6.10

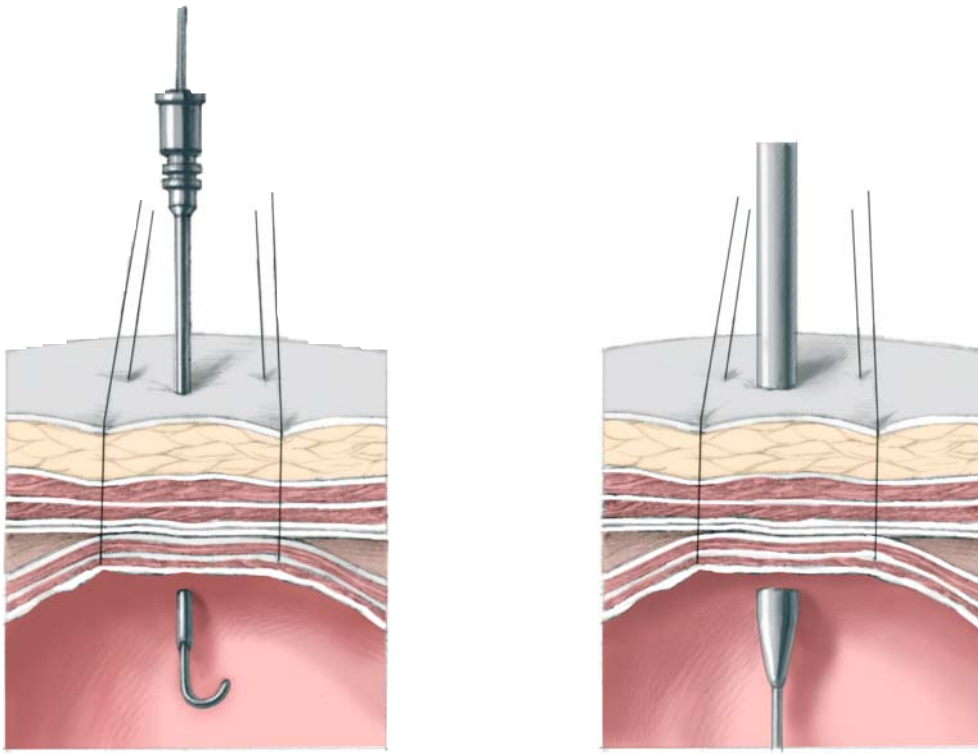
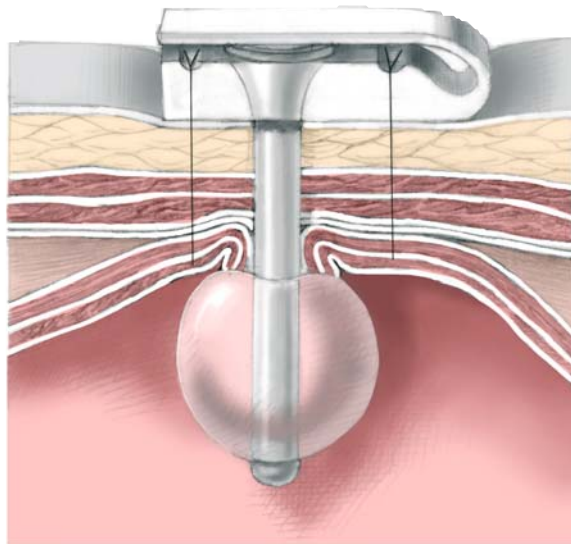


Figure 6.11



CONCLUSION

Reflux control is excellent after fundoplication. Poor results are obtained in children whose pre-operative symptoms were unrelated to GER. Dysphagia can be symptomatic in up to 40% of children if they are allowed solid foods during the first few weeks of surgery. Long-term dysphagia occurs in less than 2% of patients. Post-operative oesophageal dilatation should be avoided, as it is associated with breakdown of the fundoplication wrap and/or herniation of the stomach into the chest. Recurrent reflux at 2 years is less than 5% with little further recurrence after 2 years. Retching and choking are most commonly seen in neurologically impaired children. Those children with new onset retching after fundoplication are usually responding to overzealous feeding leading to hypersatiety. Retching immediately after bolus feeding is often due to gastric distension or dumping

and can be ameliorated by dividing the feeding bolus into two parts given 30 min apart or by continuous drip feeding. Retching after the third or fourth bolus feeding of the day is often due to a low satiety set point and can be temporarily improved by anabolic steroids, which increases the child's appetite. Gagging unrelated to feeding is often induced by a variety of stimuli and is very difficult to treat. This global type of retching often results in breakdown of the fundoplication because of the chronic and forceful nature of the gagging.

Fundoplication is a highly reliable therapy in children with persistent or life-threatening GER. Laparoscopic fundoplication is superior to open fundoplication and should be in the repertoire of all paediatric surgeons who operate on children with GER.

SELECTED BIBLIOGRAPHY

- Fonkalsrud EW, Ashcraft KW, Coran AG et al (1998) Surgical treatment of gastroesophageal reflux in children: a combined hospital study of 7,467 patients. *Pediatrics* 101: 419-422
- Georgeson KE (1998) Laparoscopic fundoplication and gastrostomy. *Semin Laparosc Surg* 5: 25-30
- Rothenberg SS (1998) Experience with 220 consecutive laparoscopic Nissen fundoplication in infants and children. *J Pediatr Surg* 33: 274-278
- Sampson LK, Georgeson KE, Winters DC (1996) Laparoscopic gastrostomy as an adjunctive procedure to laparoscopic fundoplication in children. *Surg Endosc* 10: 1106-1110
- Wulkan ML, Owings E, Georgeson KE (1998) Safety and efficacy of the 2 U-stitch gastrostomy tube. *Surg Endosc* 12: 643

Paul K. H. Tam

INTRODUCTION

Achalasia (a Greek term meaning “does not relax”) is a rare motility disorder characterized by an absence of normal oesophageal peristalsis, and an increased basal resting pressure and failure of complete relaxation of the lower oesophageal sphincter (LOS). Less than 5% of all cases present before the age of 15 years, giving an estimated incidence of 0.1 per 100,000 children. Males and females are equally affected.

The condition was first described in 1674 by Willis who successfully treated a patient by repeated oesophageal dilatation using a sponge-tipped whale bone rod. In the early 1900s, based on observations in 100 reported cases, von Mikulicz suggested cardiospasm as the aetiology. In 1914 Heller described cardiomyotomy, a procedure that carries his name and forms the basis of all surgical approaches to this problem up to this date. The original operation consisted of two myotomies anteriorly and posteriorly on the lower oesophagus performed through a laparotomy. A single anterior cardiomyotomy was subsequently found to be adequate for symptomatic relief. The operation has been performed through a thoracotomy, as well as thoracoscopically and laparoscopically with or without an additional antireflux procedure.

The pathogenesis of primary achalasia is not well understood. The most consistent histologic finding is a decrease or loss of myenteric ganglion cells, and this is more pronounced in advanced cases. The degenerative process especially involves neurones producing neuropeptides and nitric oxide, the latter being identified as inhibitory neurotransmitters. Loss of inhibitory innervation causes increased tonic contraction and interference with normal relaxation of LOS, as well as aperistalsis of oesophageal body. There are no specific histologic changes in the oesophageal muscles. The cause of the neuronal damage remains unknown. Various mechanisms, including autoimmune, infectious, genetic, toxic and primary, have been proposed. The finding of myenteric inflammation, which is predominantly lymphocytic, the presence of serum auto-antibodies to myenteric plexus, and the increased frequency of class II histocompatibility antigens in patients with achalasia

supports an autoimmune aetiology. Similarity between achalasia and Chagas’ disease caused by *Trypanosoma cruzi* suggests that a neurotropic infectious agent may be responsible. Rarely, familial cases and association with microcephaly and the congenital anomalies have been observed.

Patients usually present one or more of the following symptoms: vomiting/regurgitation of undigested food, progressive dysphagia, weight loss/failure to thrive, choking, retrosternal discomfort, and pulmonary problems such as recurrent coughing or chest infections. Vomiting and dysphagia are the commonest initial symptoms. Vomiting occurs more frequently in infants and young children whereas dysphagia is commoner in older children.

Chest X-ray may show an air-fluid level in the oesophagus; there may be a soft tissue shadow in the mediastinum on the left hemithorax corresponding to a dilated lower oesophagus, and sometimes pneumonic changes. The characteristic radiological features of achalasia in a contrast swallow are a proximal dilated oesophagus with a smooth tapering of the gastro-oesophageal junction (bird’s-beak sign or rat-tail deformity). There is an absence of coordinated peristaltic waves in the proximal oesophagus and a persistent failure of relaxation of the LOS on swallowing.

Endoscopy confirms a dilated oesophagus which funnels smoothly towards a narrowed LOS. Retained food or yeast oesophagitis may be noted in the oesophagus. Although the LOS is closed, it provides little resistance to the advancing endoscope.

Oesophageal manometry is the “gold standard” for the diagnosis of achalasia. Diagnostic features include a failure of relaxation of LOS on swallowing and absence of peristalsis in the body of the oesophagus. Features that are characteristic but not required for the diagnosis include elevated resting LOS pressure (>45 mmHg), and resting pressure in the oesophageal body exceeding that in the stomach.

Symptomatic relief can be achieved by lowering LOS pressure with nitrate or calcium channel blocker (nifedipine) medication or with intrasphincteric injection of botulinum toxin. The need for life-long

medication (with its associated side-effects) or repeated injections, respectively, limits the role of medical therapy to those children who are not suitable for treatment by dilatation or surgery.

Definitive treatment of achalasia consists of dilatation or oesophago-cardiomyotomy. Dilatation should be guided by endoscopy/fluoroscopy and can

be achieved using either rigid or balloon dilators, the latter being the preferred choice in children. Pneumatic dilatation can be used for primary treatment or as a secondary procedure when symptoms recur after surgery. Our experience suggests that dilatation is less effective than surgery for long-term symptomatic relief.

Figure 7.1

Heller's oesophago-cardiomyotomy remains the mainstay of treatment for achalasia and can be performed via the abdomen or thorax, either as an open procedure or by the minimally invasive approach, and with or without a concomitant fundoplication. Preoperatively, any yeast oesophagitis should have been eradicated with antifungal medication. The patient is kept on clear fluids a day prior to surgery to minimize the risk of aspiration of retained food on anaesthesia induction. Preoperative endoscopy ensures complete emptying of dilated oesophagus. A large feeding tube or a balloon catheter is introduced into the stomach.

Depending on the surgeon's preference, surgical access can be achieved via the abdomen or left thorax. The abdominal approach is more popular, and allows concomitant fundoplication to be performed more easily. With the patient supine, an upper midline is made for laparotomy. For laparoscopic access, the patient is placed in a lithotomy position with the surgeon at the end of the operating table; four to five ports are placed as shown. The telescope is placed in the supra-umbilical port (1).

To expose the oesophagus in the open procedure, the left lobe of the liver is retracted superiorly and medially; the left triangular ligament may be divided to enhance the exposure. For the laparoscopic approach, a cotton-tipped rod is inserted into the epigastric port (3) to retract the caudate lobe of the liver cephalad. Instrumentation is carried out via the remaining ports (2, 4, 5).

Figure 7.2

The phreno-oesophageal ligament is incised. The anterior vagus is seen on the anterior wall of the oesophagus and should be preserved. The hiatal window is identified adjacent to the caudate lobe and the tissues between the oesophagus and the crura are divided. The abdominal oesophagus is further freed by blunt dissection into the posterior mediastinum, taking care not to penetrate the pleura proximally. The posterior vagus is preserved. A cotton tape encircling the cardio-oesophageal junction is used to retract the abdominal oesophagus caudally. The site of myotomy is marked by electrocautery to the left of the anterior vagus.

Figure 7.1

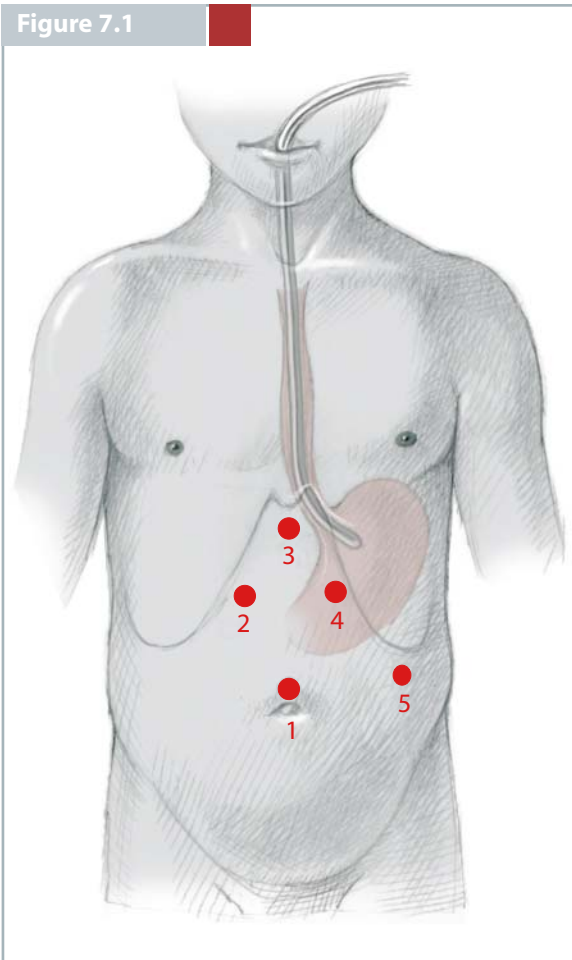


Figure 7.2

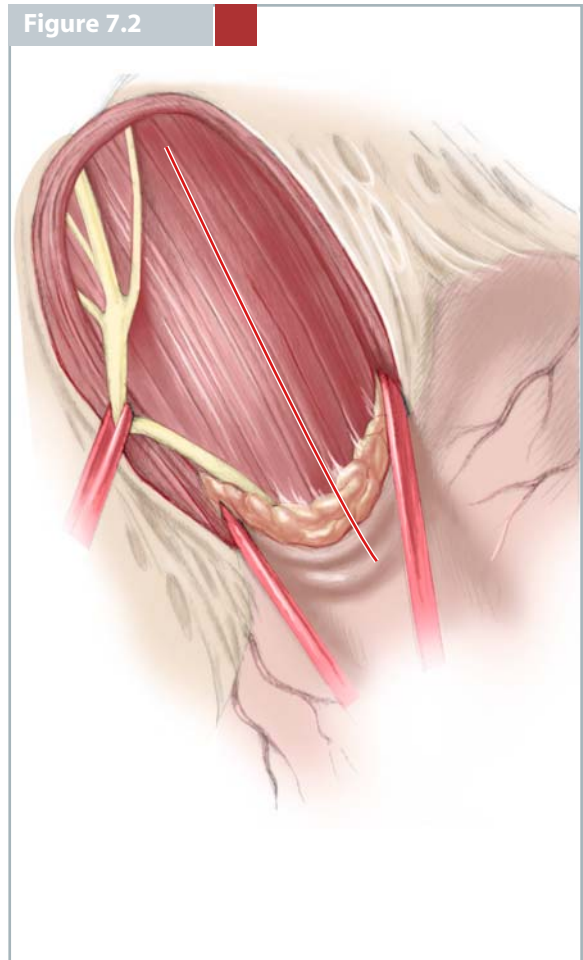


Figure 7.3

Myotomy extends for 4–6 cm above, and 0.5–1 cm below the cardio-oesophageal junction. A superficial incision is made with the diathermy tip. The thickened oesophageal muscle is then divided with scissors and separated by blunt dissection with grasping/preparation forceps until the submucosal plane is reached. Great care is taken to avoid mucosal perforation. Myotomy is continued proximally and distally with diathermy hook and blunt dissection until all constricting muscles have been separated and the mucosa is seen bulging outwards; the muscular edges should be undermined for 50% of the oesophageal circumference. The gastro-oesophageal junction is recognized by the “collar-like” configuration of the circular muscles. The gastric muscles are usually more adherent to the mucosa. Mucosal perforation is tested by insufflation of the oesophagus; if present, this should be repaired by fine suture. A widened hiatus should be narrowed by one or two non-absorbable deep sutures placed through the crura. The wound is closed in the usual manner.

Figure 7.4

To avoid the long-term complication of gastro-oesophageal reflux after myotomy, many surgeons recommend a concomitant fundoplication. Details of the procedure are separately described (see Chap. 6). The fundoplication should be loose to avoid dysphagia. A posterior 180° (Toupet) fundoplication can be performed over the distal 1–1.5 cm of the oesophagus. The fundus is sutured separately to the cut edge of the oesophageal muscle on either side using three non-absorbable interrupted sutures. This procedure holds the myotomy edges apart in addition to providing an antireflux mechanism.

Figure 7.5

Alternatively, an anterior 180° (Dor or Thal) fundoplication is performed. The anterior fundus is “draped” over the anterior oesophagus, covering the myotomy. This procedure may be more appropriate for patients with mega-oesophagus as the posterior fundoplication is more prone to result in outflow obstruction. It may also provide additional cover after repair of a mucosal perforation.

A nasogastric tube is left overnight. Fluid diet is commenced after a contrast study confirms the absence of a leak and when gastric stasis has resolved. Return to normal feeds is usually faster for laparoscopic procedures.

Figure 7.3

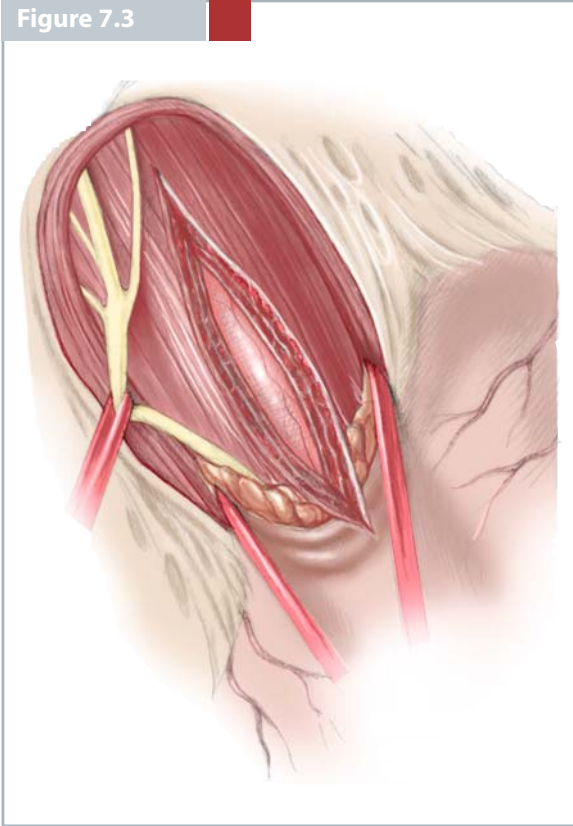


Figure 7.4

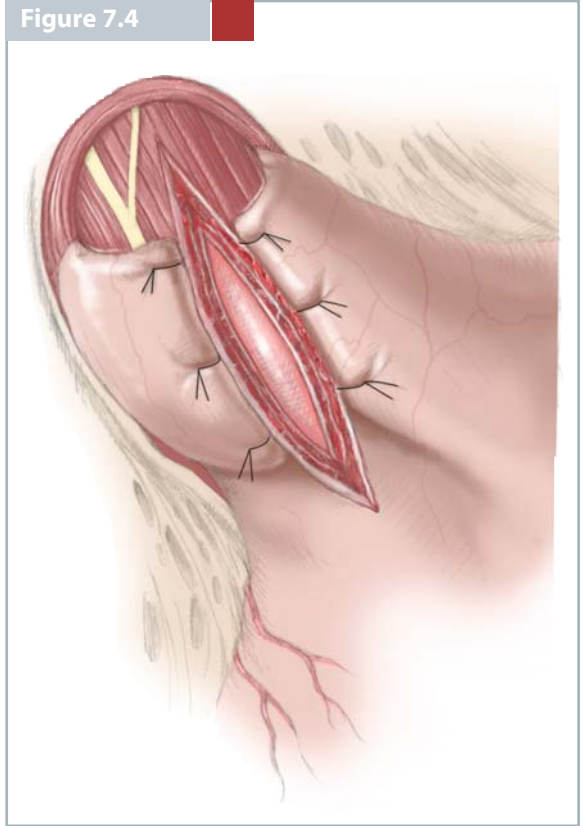
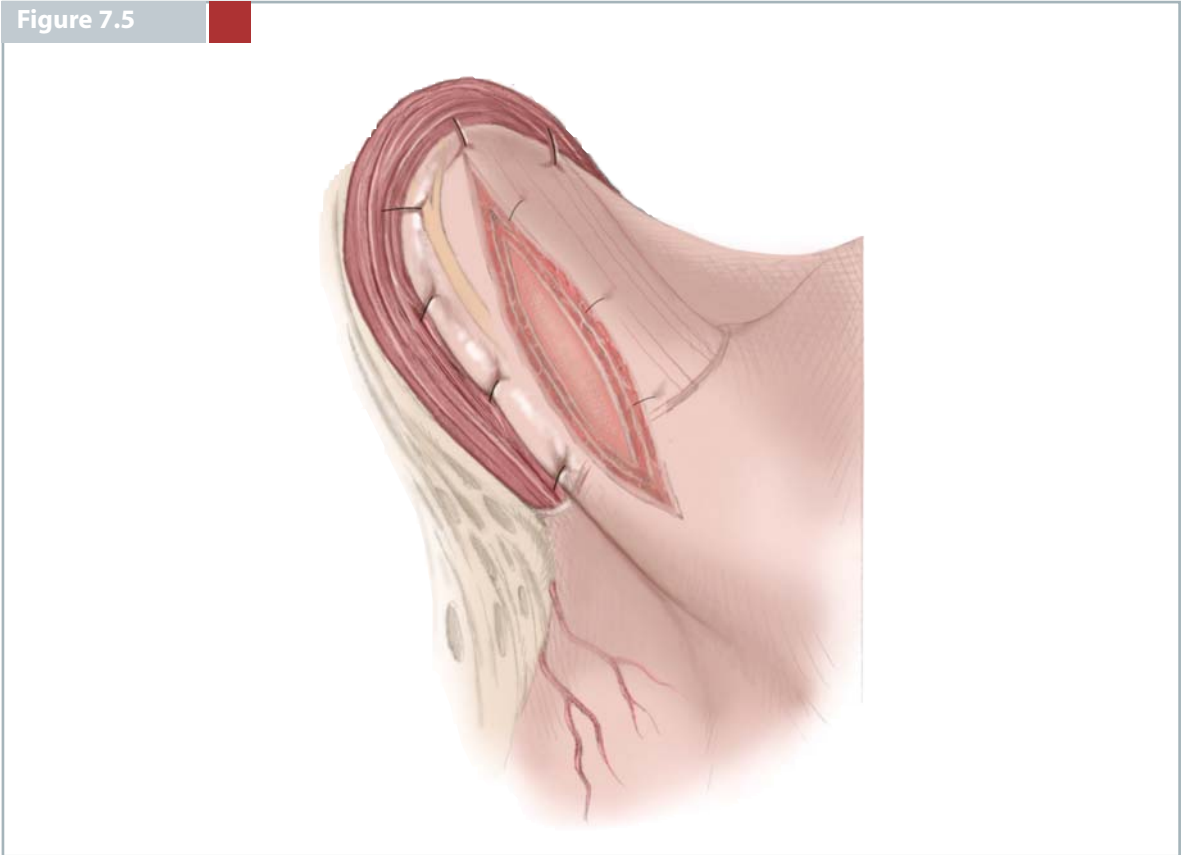


Figure 7.5



CONCLUSION

Oral medication with nifedipine or nitrates can result in a 50% decrease in LOS but is commonly associated with side-effects such as headache. Experience of intrasphincteric injection of botulinum toxin is limited in children. Recent studies suggest a mean duration of effect of 4 months; more than half of the patients are expected to require a repeat injection within 6 months.

Pneumatic dilatation has been reported to be effective in 50–90% of cases in selected small series. Most authors, including ourselves, have been unimpressed with its efficacy as primary treatment in children with achalasia. Multiple dilatations are often required. Complications include oesophageal perforation and symptomatic gastro-oesophageal reflux.

Heller's oesophago-cardiomyotomy is the method of choice for the treatment of achalasia in children. Long-term symptomatic relief is obtained in 86% of children after surgery. Most series report zero mortality. Complications include oesophageal perforation (10%), atelectasis and post-operative fever (42%), dysphagia (14%) and gastro-oesophageal reflux (20%). A poor result following oesophago-cardi-

omyotomy can be due to mega-oesophagus, incomplete myotomy or gastro-oesophageal reflux. Incomplete myotomy usually responds to secondary pneumatic dilatation. Gastro-oesophageal reflux is preventable by a concomitant fundoplication during myotomy; attempts to perform a fundoplication as a second operation after an initial myotomy without fundoplication is technically more difficult. Laparoscopic myotomy is gaining popularity. Transthoracic video-assisted Heller's myotomy has also been performed successfully. An additional fundoplication is easier to perform laparoscopically than thoracoscopically. Compared to open procedures, the minimally invasive approach results in superior cosmesis, less post-operative pain, earlier return to resumption of feeding (means: 2.7 days for laparoscopic procedure, 9.0 days for open) and shorter hospital stay. Conversion to open myotomy is necessitated in 10% of laparoscopic procedures, usually as a result of intra-operative oesophageal perforation. With increasing experience, even oesophageal perforations can be repaired laparoscopically.

SELECTED BIBLIOGRAPHY

- Babu R, Grier D, Cusick E et al (2001) Pneumatic dilatation for childhood achalasia. *Pediatr Surg Int* 17: 505–507
- Esposito C, Medoza-Sagaon M, Roblot-Maigret B et al (2000) Complications of laparoscopic treatment of esophageal achalasia in children. *J Pediatr Surg* 35: 680–683
- Hurwitz M, Bahar RJ, Ament ME et al (2000) Evaluation of the use of botulinum toxin in children with achalasia. *J Pediatr Gastroenterol Nutr* 30: 509–514
- Mehra M, Bahar RJ, Ament ME et al (2001) Laparoscopic and thoracoscopic esophagomyotomy for children with achalasia. *J Pediatr Gastroenterol Nutr* 33: 466–471
- Vane DW, Cosby K, West K et al (1988) Late results following esophagomyotomy in children with achalasia. *J Pediatr Surg* 23: 515–591

Colonic Replacement of the Oesophagus

Alaa Hamza

INTRODUCTION

To date, there is no better substitute for the native oesophagus because the ideal graft does not exist. Many studies have been done and different organs are used: the jejunum, the stomach as a tube or as the whole organ, and the colon. There is no agreement on a single organ or a single route. The colon is the most commonly used organ, and experienced centres consider it as a good substitute in most of the cases.

Indications include oesophageal atresia failed after repair or a wide gap. Full-thickness injury to a long segment of the oesophagus after caustic ingestion invariably results in an intractable stricture that fails to respond to repeated dilatation and requires substitution. Other indications include multiple extensive strictures, marked irregularity or pocketing of the oesophagus, and the need for frequent dilata-

tions. Extensive infection with candida, epidermolysis bullosa or, very rarely, massive varices due to portal hypertension and strictures after injection are rare causes for replacement.

Over the last 30 years more than 850 oesophageal replacements have been performed in the Pediatric Surgery Department of Ain-Shams University. The technique has evolved from gastric pull-up to colon replacement, initially subcutaneously, then retrosternally. In the last 13 years we started transhiatal oesophagectomy with posterior mediastinal colon replacement. The left colon based on the left colic artery as a graft in all cases of oesophageal replacement or bypass has been used since 1972. The graft is usually isoperistaltic.

Figure 8.1

All patients are given intestinal antiseptics 3 days before surgery (metronidazole and colimycin). Colonic washouts are done three times per day 48 h prior to surgery. Patients with a gastrostomy have saline infusions through the tube at 20 ml/kg body weight over 30 min. This is repeated three times every 2 h. Intravenous cephalosporin and metronidazole are given with premedication.

The patient is placed in the supine position with a small sandbag under the shoulder with the neck extended and turned to the right side. A tube is placed through the nose into the oesophagus to allow easy dissection. Skin preparation includes neck, chest and abdomen.

Left transverse supraclavicular incision is made, which can be extended upwards in a hockey stick manner over the anterior border of the sternomastoid. If oesophagostomy is present stay sutures are placed around the oesophagus and an elliptical incision around the oesophagostomy is made. Dissection of the oesophagus should not extend proximally more than 4–5 cm to avoid ischaemic injury to the wall.

Figure 8.2

After incising the skin, subcutaneous tissue and platysma the cervical fascia is opened along the anterior border of the sternomastoid. Dissection continues with the strap muscles either divided (easier for dissection) or retracted. Internal jugular vein and the common carotid artery all retract laterally. The oesophagus is identified and the dissection distal to the stricture is started to avoid proximal devascularization. Isolation of the oesophagus is done after visualising the recurrent laryngeal nerve and retracting it medially. If the oesophagus is severely adherent to the trachea, distal dissection and identification of the nerve at its entry to the neck is important to avoid nerve injury. Now the oesophagus is encircled with a tape and mobilized proximal to the strictured segment for only 2–3 cm to prevent devascularization injury of the blood supply. Distal dissection, around the oesophagus is usually done bluntly through the posterior mediastinum.

Figure 8.3

The abdomen is entered through a midline incision. Mobilization of the colon is done carefully and it should be freed from the ascending to the descending colon and exteriorized for examination of the vascular supply. The graft is chosen on the territory supplied by the upper left colic artery with the length equal to the distance from the antrum to the stricture

site (*insert*). Usually division of the middle colic vessels is needed and before that the blood supply is clamped by bulldog clips and the colon is left inside the abdomen to verify adequate circulation. If there are any vascular anomalies, the right or even the middle colic artery are utilized.

Figure 8.1

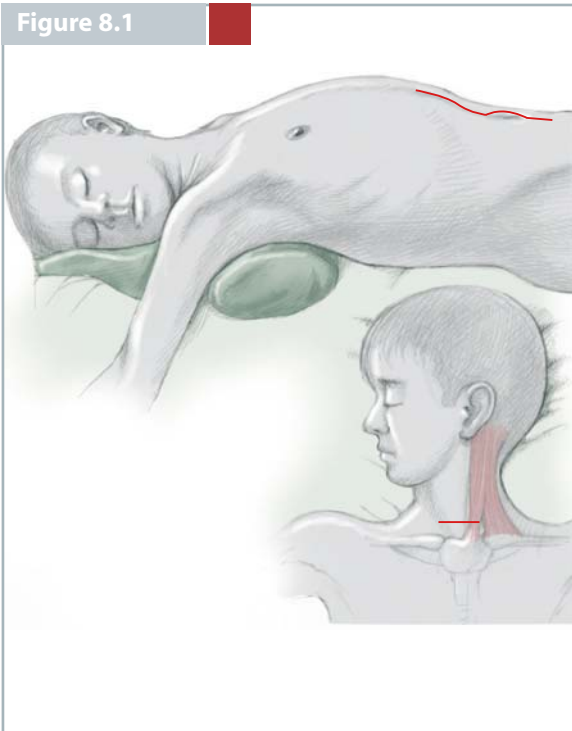


Figure 8.2

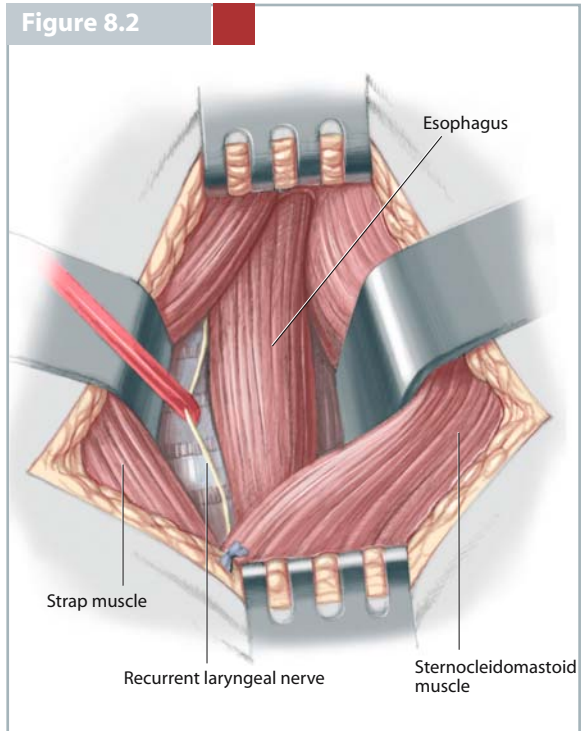


Figure 8.3

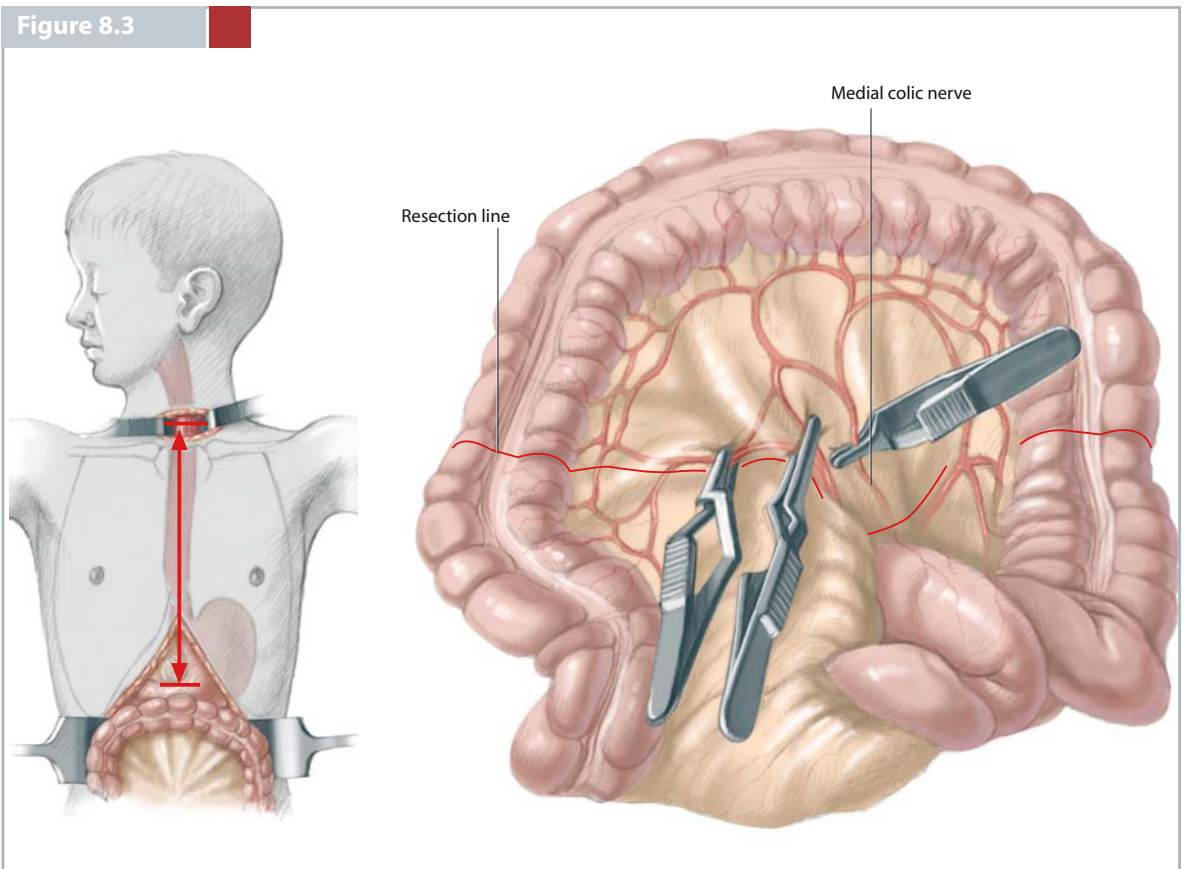


Figure 8.4

The dissection starts by incising the left triangular ligament of the liver followed by dissection of the oesophagus at the hiatus and incising the phreno-oesophageal ligament. The vagi are evident at this stage and both are divided. Sometimes the posterior vagus can be saved with meticulous intra-thoracic dissection. The oesophagus is encircled with a tape to facilitate mobilization. The hiatus is explored utilizing two malleable retractors. Under direct vision all oesophageal vessels are diathermized. Traction is obtained with the help of the tape and the dissection is

kept very close to the oesophageal wall to avoid injury to the surrounding structures

With blunt and sharp dissection the oesophagus is freed as high as possible. Care is taken to avoid entering the pleura or an intercostal tube drain has to be inserted. The blunt dissection is continued from above and below until the oesophagus is freed completely. It is essential to avoid aggressive dissection in the region of the aortic arch and to stay close to the oesophageal wall.

Figure 8.5, 8.6

The two tapes encircling the oesophagus are both moved up and down to be sure of having freed the oesophagus from all attachments. Oesophagectomy is then done by dividing the oesophagus at the cardia with occlusion of the gastric end with an intestinal clamp. The oesophagus is then passed upward by traction with a long silk suture to the gastric end of the oesophagus. The silk suture is left in place to be

used for the passage of the colon through the hiatus later on.

The colon is re-evaluated and the pulsation of the marginal artery is carefully examined. The exact measurement of the colon is examined after oesophageal resection; extra length leads to redundancy later on. The graft is washed with diluted povidone iodine solution and left open with no clamps.

Figure 8.4

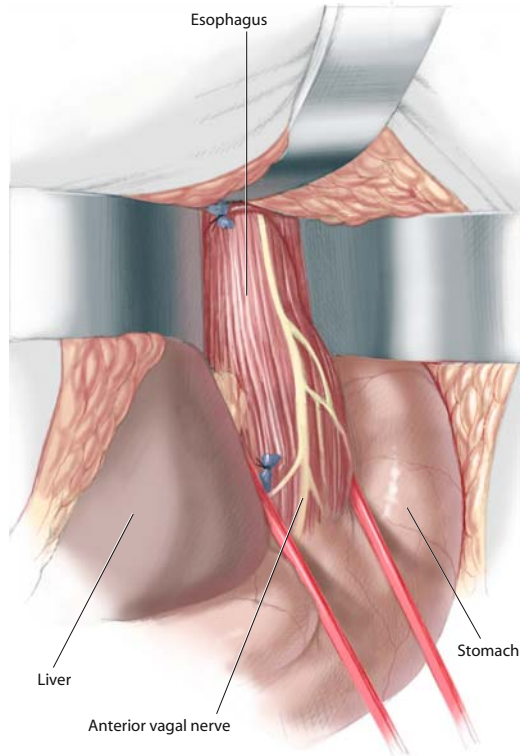


Figure 8.5

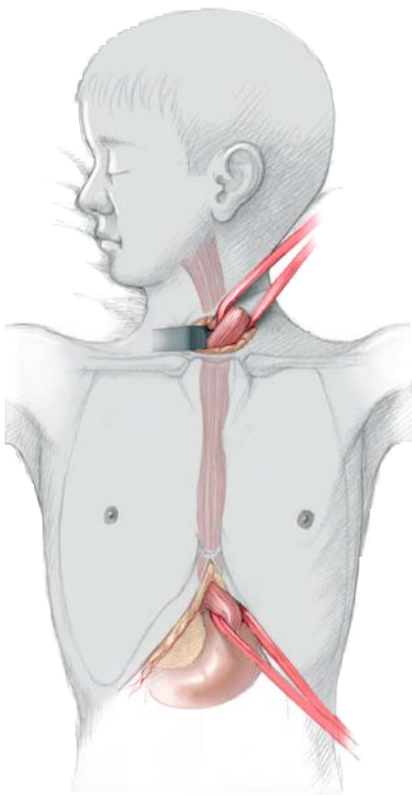


Figure 8.6

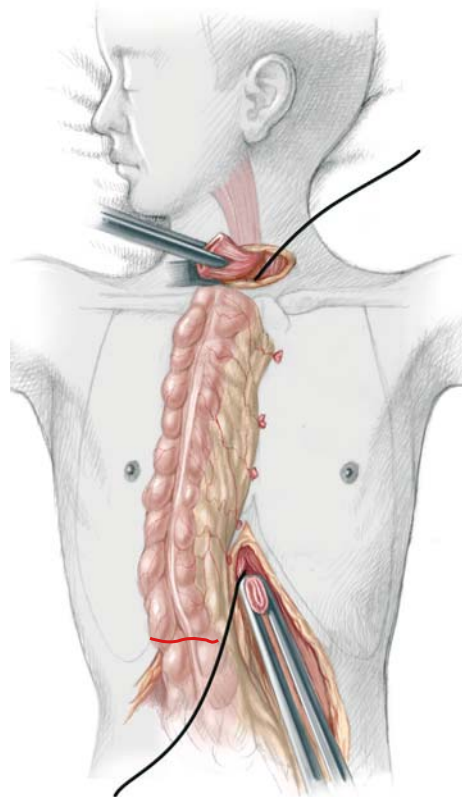


Figure 8.7

Then, the colon is resected and passed behind the stomach in an isoperistaltic manner taking care to avoid either stretch or torsion of the pedicle. To facilitate passage through the chest, the silk suture previously present is sutured to the proximal end of the colon and pulled through the cervical incision until the colon is in place in the posterior mediastinum. Care should be taken regarding the position of the pedicle and repositioning should be done immediately in case of torsion or traction of the vessels. Viability of the graft is confirmed by noting bleeding from its cervical end. Redundant parts are resected at

the cervical and gastric end, avoiding injury to the pedicle.

If the oesophagus has not been resected and a colon bypass procedure is planned, then a retrosternal tunnel is made by blunt dissection, dividing the endothoracic fascia very close to the sternum, at the upper end from the neck incision after division of the muscles at the supra sternal notch and at the lower end by incising the posterior aspect of the lower end of sternum. The tunnel is enlarged using fingers, taking care not to injure the pleura, and a long silk suture is passed through the tunnel.

Figure 8.8

The oesophageal end is examined to rule out any proximal strictures. According to the oesophageal size and disparity to the colonic end, the type of anastomosis is chosen. If both sizes are equal or without marked disparity, an end-to-end single layer anastomosis is made using 4/0 absorbable sutures. If the colonic end is slightly bigger, a posterior incision of the oesophagus to accommodate a larger size of colon can facilitate the anastomosis. A single layer, end-to-side, oesophago-colic anastomosis is made, with closure of the colonic stump if the oesophagus is much smaller in diameter than the colon. Fixation of the colon to the neck muscles is done to avoid traction.

Suturing the strap muscles is important to avoid blowing of the neck during swallowing. Closure of the wound is done in layers, leaving a drain in place.

In cases of caustic pharyngeal strictures the pharyngo-colic anastomosis is made as an end-to-side to the wall of the pharynx. First, the incision should extend to the angle of the mandible. Then, the dissection should reach the wall of the pharynx, opened on stay sutures, and healthy mucous membrane should be available for anastomosis. The colonic graft should be long enough to reach the pharynx. A wide single-layer end-to-side anastomosis is made with no tension. Sometimes a wide bore tube is left as a splint for 1 week and endoscopy is done before discharge to check the anastomosis.

Figure 8.7

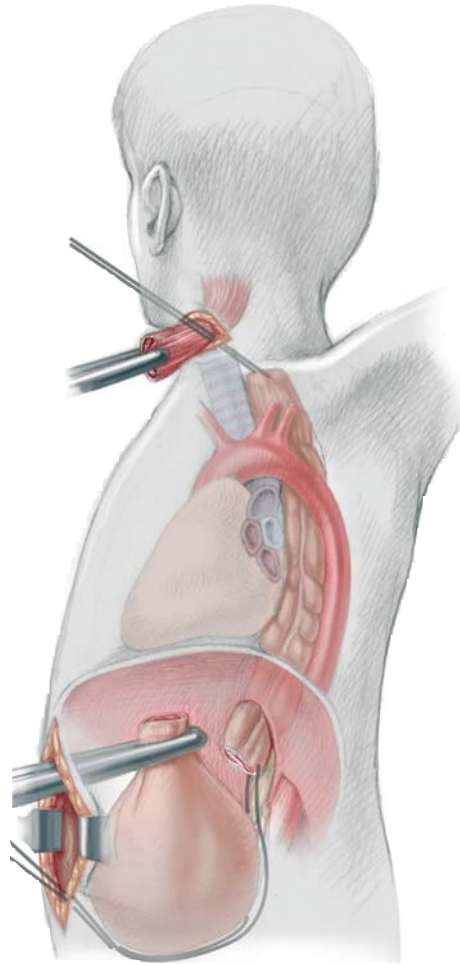


Figure 8.8

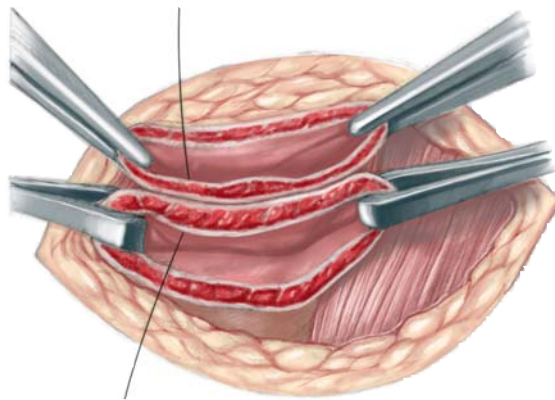


Figure 8.9

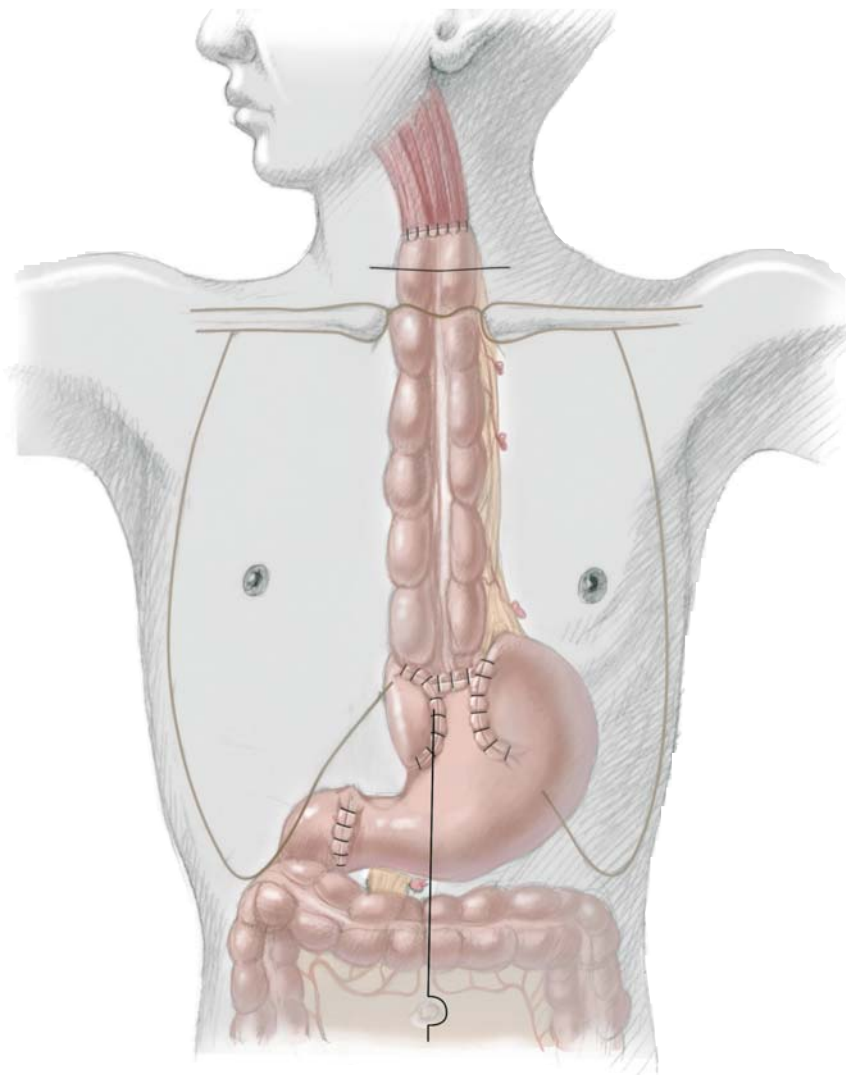
After passage of the colonic graft to the neck the gastro-colic anastomosis is performed in two layers. It is done at the cardia with a 270° anti-reflux wrap of the stomach to avoid injury to the pedicle. In cases of retrosternal colon the anastomosis is made to the anterior wall of the stomach near the antrum and the colon should be positioned correctly since it could be hinged by the liver edge. The colon should be fixed to the edges of the tunnel in cases of retrosternal colon and to the edge of the hiatus in cases of posterior mediastinal colonic replacement.

Pyloroplasty is done in all cases with posterior mediastinal replacement. It is performed as a Heinz-Mickulicz type with single-layer anastomosis. The colo-colic anastomosis is performed and care should

be taken to close the window after the colonic resection and this could be achieved by fixing the colon to the edge of duodenum. In patients with no gastrostomy, a Stamm-type gastrostomy is preformed. The abdomen is closed in layers with a mediastinal drain.

Patients usually stay in the Intensive Care Unit for 2–4 days. The drains are removed after 48 h, and the patients are fed by the gastrostomy for 7–10 days. A contrast study is performed and, if there is no leakage, feeding is started. The gastrostomy tube is clamped and removed 3 months after surgery unless there is dysphagia. In cases with proximal anastomotic strictures, if dilatation is unsuccessful, surgical revision of the colo-oesophageal anastomosis is undertaken.

Figure 8.9



CONCLUSION

We share the view of many authors, that an isoperistaltic left colon segment based on the left colic vessels is the best method of oesophageal replacement for benign caustic oesophageal strictures in children. A sufficient length is available to replace the whole oesophagus and even the lower pharynx if needed. The blood supply from the left colic vessels is robust and rarely prone to anatomic variation. The close relationship between the marginal vessels and the border of the viscus results in a straight conduit with little redundancy or tendency to kinking. The left colon seems to transmit solid food more easily than the

right colon and fewer problems are associated with its removal. The colon has proved to be relatively acid-resistant, and significant ulceration in the interposed segment is unusual.

In a survey of the last 475 cases, we had five deaths related to respiratory problems. No instance of graft necrosis occurred in this series; however, three patients developed late graft stenosis, two of which were at the distal part. Both patients required surgical revision, and the third patient developed an unusual proximal stenosis that was corrected by gastric pull-up.

SELECTED BIBLIOGRAPHY

- Bahnassy AF, Bassiouny IE (1993) Esophagocoloplasty for caustic strictures of the esophagus: changing concepts. *Pediatr Surg Int* 8: 103
- Bassiouny IE, Bahnassy AF (1992) Transhiatal esophagectomy and colonic interposition for caustic strictures. *J Pediatr Surg* 27: 1091–1096
- Freeman NV, Cass DT (1982) Colon interposition: a modification of the Waterstone technique using the normal esophageal route. *J Pediatr Surg* 17: 17–21
- Hamza AF, Abdelhay S, Sherif H et al (2003) Caustic esophageal strictures in children: 30 years experience. *J Pediatr Surg* 38: 828–833
- Spitz L (1988) Esophageal replacement in children. In: Coran A, Fonkalsrud E, O'Neil J, Grosfeld J (eds) *Pediatric surgery*, 6th edn, Mosby Year Book, St Louis

Gastric Transposition for Oesophageal Replacement

Lewis Spitz

INTRODUCTION

While every attempt should be made to retain the child's own oesophagus there are circumstances in which this aim cannot be achieved. These include:

- **Oesophageal atresia:** in particular very long gap pure atresia where delayed primary anastomosis has failed, and, in addition, complicated oesophageal atresia when the primary repair has disrupted and a cervical oesophagostomy established
- **Caustic oesophageal damage** that fails to respond to dilatation
- **Injuries to the oesophagus by prolonged foreign body impaction**
- **Tumours of the oesophagus**, e.g., diffuse leiomatosis, inflammatory pseudo-tumour
- **Motility disorders**

There are four recognized methods of oesophageal substitution, which include:

- Colon interposition
- Gastric tube oesophagoplasty
- Jejunal interposition
- Gastric transposition

Gastric transposition has been my procedure of choice for oesophageal replacement for over 20 years. It has the following advantages:

- The stomach has an excellent blood supply.
- Adequate length to reach the cervical region can usually be achieved.
- The procedure involves a single anastomosis.
- The leak and stricture rates are relatively low.
- The procedure itself is simple to perform.

It is recommended that bowel preparation is carried out to ensure an empty colon in the event that the stomach is unavailable for the transposition procedure. The surgeon should be capable of performing the various alternative methods of oesophageal replacement.

Figure 9.1

A midline upper abdominal incision is made. An elliptical incision around the cervical oesophagostomy or, alternatively, a right or left low transverse cervical incision is made to expose the cervical oesophagus. A lateral thoracotomy may be required if the surgeon

encounters any difficulty in mobilizing the thoracic oesophagus, which may have been damaged by caustic oesophagitis or repeated attempts at retaining the child's own oesophagus.

Figure 9.2

The stomach is exposed, the gastrostomy site is taken down and the defect in the stomach closed. The greater and lesser curvatures of the stomach are mobilized, preserving the integrity of the right gastroepiploic and right gastric arcades. The mobilization of

the stomach continues proximally by dividing the short gastric vessels between the fundus of the stomach and the spleen and by ligating and dividing the left gastric artery and vein.

Figure 9.1

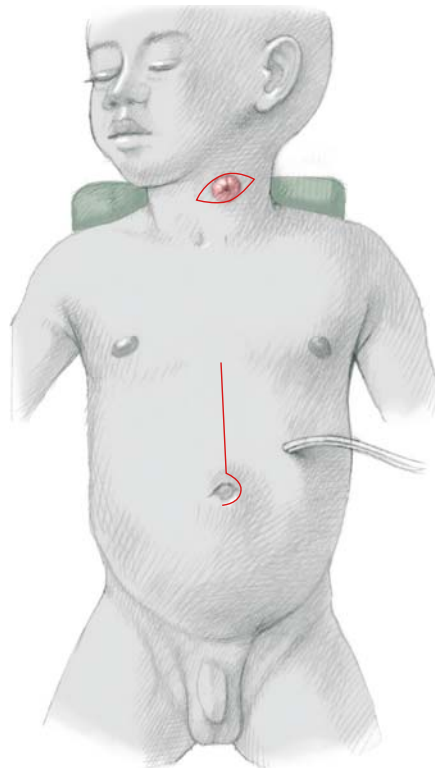


Figure 9.2

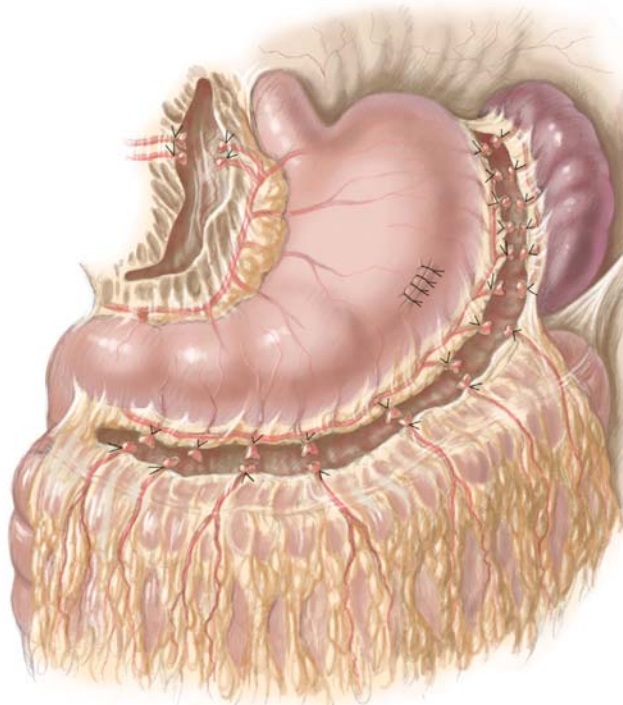


Figure 9.3

The stump of the distal oesophagus (in the case of long gap atresia) is mobilized from the posterior mediastinum by dividing the phreno-oesophageal membrane and dissecting out the oesophagus. The

anterior and posterior vagal nerves are divided. The oesophagus is divided at the oesophago-gastric junction and the defect in the stomach repaired.

Figure 9.4

A pyloroplasty is performed. The sutured gastrotomy site and the closed-off gastro-oesophageal junction are shown. The highest point on the stomach and the place for the oesophago-gastric anastomosis is the top of the fundus. Two sutures of different ma-

terials are placed in the fundus. The orientation of these sutures is used to ensure that rotation of the stomach does not occur while it is being pulled up into the neck.

Figure 9.3

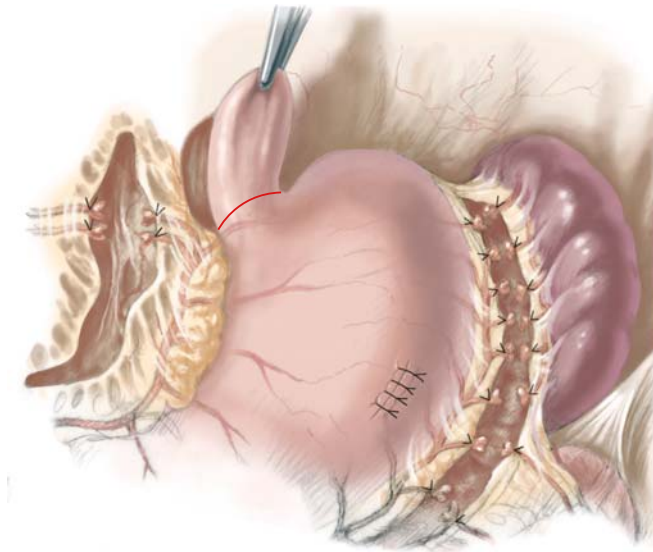


Figure 9.4

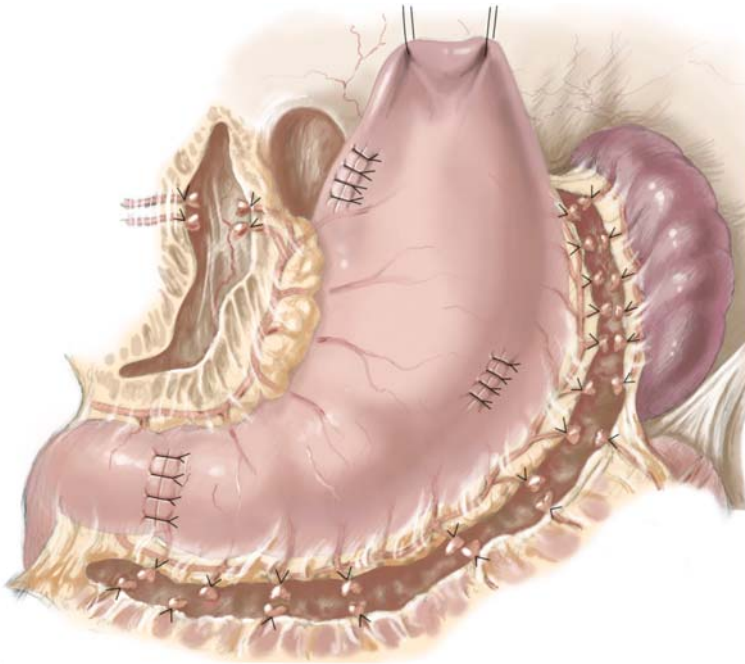


Figure 9.5

Via the cervical incision, full thickness of the oesophagus is mobilized. It is easy to enter into the submucosal plane during the dissection but this should be avoided as the vascularity of the oesophagus will be impaired. The recurrent laryngeal nerves must be preserved during the mobilization procedure.

Figure 9.6

The plane of dissection for the mediastinal tunnel is directly anterior to the prevertebral fascia. From above the dissection proceed immediately posterior to the trachea posteriorly and caudally into the posterior mediastinum. From below, through a widened hiatus, dissection is carried out under vision in the prevertebral space behind the heart. The tunnel is completed from above and from below by gentle digital dissection in the posterior mediastinum.

If any problems are encountered in creating the posterior mediastinum tunnel by blunt finger dissection, it is advisable to perform a lateral transpleural thoracotomy and complete the dissection under direct view. This approach is also essential to remove a scarred oesophagus or a tumour of the oesophagus.

Figure 9.5

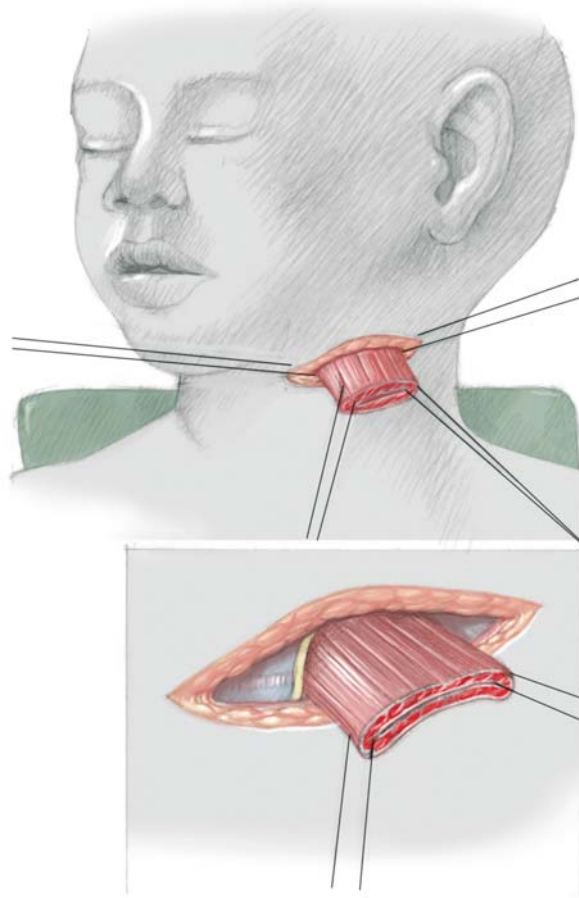


Figure 9.6

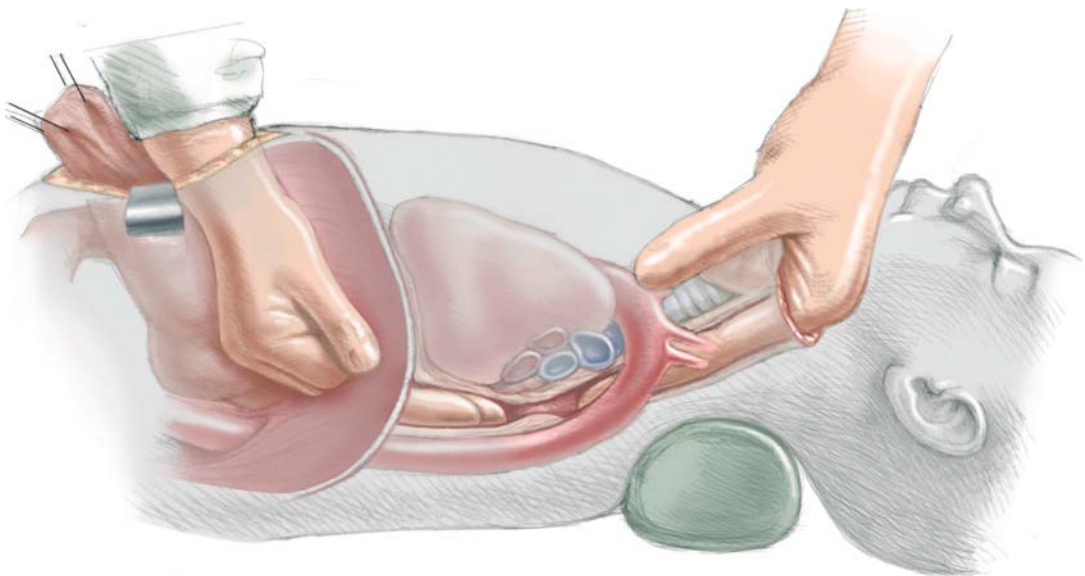


Figure 9.7

Using the “stay-sutures” as guides, the stomach is pulled up through the hiatus in the diaphragm, through the posterior mediastinal tunnel until the fundus appears at the cervical incision. The transpo-

sition should be smooth and under no tension, and the stay-sutures should be correctly orientated to avoid twisting of the stomach in the posterior mediastinum.

Figure 9.8

The anastomosis between the end of the cervical oesophagus and the top of the fundus of the stomach is fashioned using a single layer of 5/0 or 6/0 sutures, taking the full thickness of the walls of the oesophagus and the stomach. Before completing the anterior wall of the anastomosis a size 10F–12F nasogastric tube is passed with the tip in the intrathoracic stomach. The wounds are closed with a soft rubber drain

at the cervical incision. A feeding-tunnelled jejunostomy is highly recommended for infants with oesophageal atresia who have not previously been established on oral feeding. In addition to the usual post-operative management following any major procedure, it has been our practice to electively paralyse and mechanically ventilate our patients for a minimum of 48–72 h post-operatively.

Figure 9.7

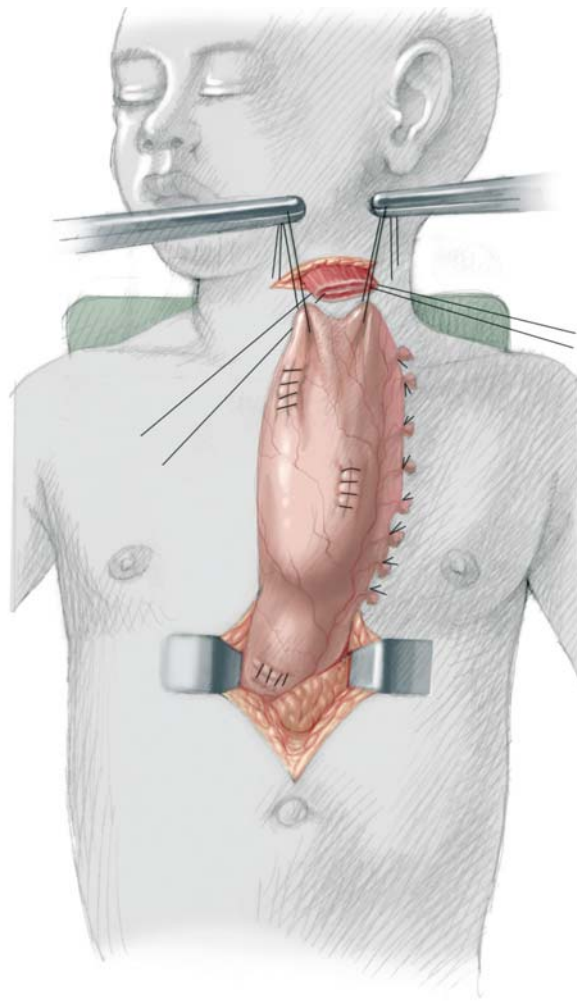
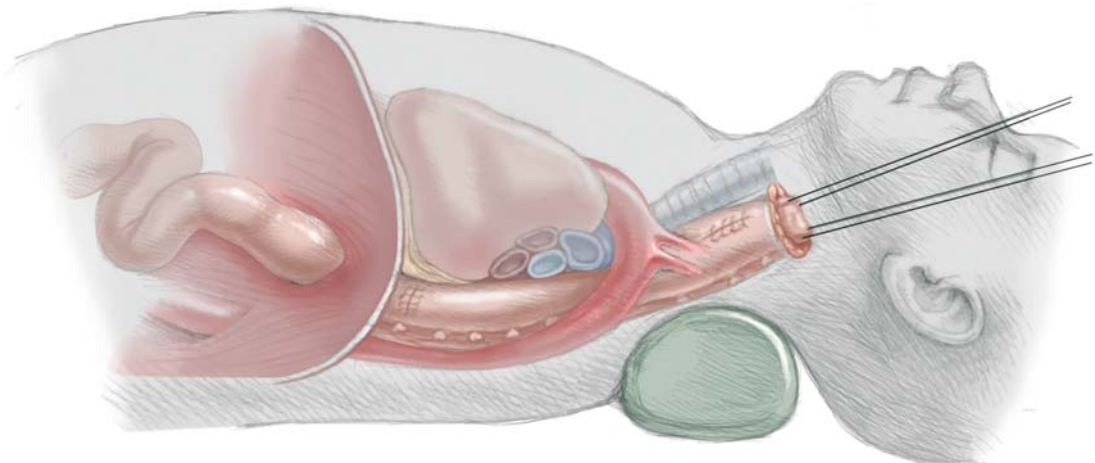


Figure 9.8



CONCLUSION

Mortality of this procedure is in the region of 5% while the morbidity is significant and includes:

- Anastomotic leak rate 12%
- Anastomotic stricture rate 19.6%
- Swallowing problems 30%
- Delayed gastric emptying 8.7%
- Complications with the jejunal feeding tube 4%
- Dumping syndrome 3%

Most of the children prefer to take small frequent meals, although in the older children a normal eating pattern is generally established. Many of the patients grow at a slower rate than normal and are in the lower half of the growth charts for both weight and height. This applies particularly to children who are born with oesophageal atresia.

SELECTED BIBLIOGRAPHY

- Ludman L, Spitz L (2003) Quality of life after gastric transposition for oesophageal atresia. *J Pediatr Surg* 38: 53–57
- Spitz L (1984) Gastric transposition via the mediastinal route for infants with long-gap esophageal atresia. *J Pediatr Surg* 19: 149–154
- Spitz L (1995) Gastric transposition of the esophagus. In: Spitz L, Coran AG (eds) *Pediatric surgery*, 5th edn. Chapman and Hall, London, pp 152–158

- Spitz L (1998) Esophageal replacement. In: O'Neill JA, Rowe MI, Grosfeld JL, Fonkalsrud EW, Coran AG (eds) *Pediatric Surgery*, 5th edn. Mosby Year Book, St Louis, pp 981–995
- Spitz L, Kiely EM, Pierro A (2004) Gastric transposition in children – a 21-year experience. *J Pediatr Surg* 39: 276–281

INTRODUCTION

Pediatric surgeons have been involved in thoracoscopy for a long time. Until the late 1980s most thoracoscopies were purely diagnostic. The explosion of endoscopic surgical techniques came shortly after the introduction of the chip camera and video technology into surgery. Since that time most of the operations that have been classically performed through a formal thoracotomy can now be performed in a video-assisted way using a number of small access holes. The term VATS is often used and stands for video-assisted thoracoscopic surgery. This technique provides excellent view of the internal thoracic anatomy. Additionally, it avoids trauma to the thoracic wall not only as a result of the transection of the various tissues but also because of the spreading of the ribs.

The following are indications for VATS:

- Diagnostic procedures
 - Interstitial lung disease
 - Metastatic lung disease
 - Mediastinal lesions
- Therapeutic procedures
 - Chest wall
 - Empyema
 - Pectus excavatum correction according to the Nuss method
 - Trachea and lungs
 - Tracheomalacia
 - Pneumothorax
 - Bronchogenic cysts
 - Sequestration
 - Lobectomy
 - Metastases
- Mediastinum
 - Thymus
 - Thymectomy
 - Heart and great vessels
 - Closure of the ductus arteriosus
 - Pericardial cysts
 - Vascular access
 - Esophagus
 - Atresia
 - Achalasia
 - Duplication
 - Esophagectomy for caustic burn
 - Sympathetic chain
 - Neurogenic tumours
 - Sympathectomy for hyperhydrosis
 - Thoracic duct
 - Ligation
- Spine
 - Anterior spinal fusion
- Diaphragm
 - Diaphragmatic hernia, eventration, relaxation
 - Diaphragmatic pacing

Thoracoscopy has also gained a definitive position in the treatment of childhood and adolescent cancer.

Figure 10.1

A good working space is of paramount importance for good quality VATS. In children the working space is very limited, a greater reason to make all available space available. The organ that limits the working space during VATS is most usually the lung. Techniques have been developed to keep the lung out of the way.

By allowing air to enter the pleural cavity, the lung will collapse. However, VATS is usually done under general anaesthesia and positive pressure ventilation. As a result, the lungs expand during each insufflation. One-lung ventilation by selective intubation of the main bronchus with a cuffed tube (Fig. 1) or by the use of a double lumen tube is a good alternative but only applicable in larger children, e.g., children over 10 years of age. In children below 10 years of age, one lung ventilation is theoretically possible by ventilating the child endotracheally while the ipsilateral main bronchus is blocked with a Fogarty catheter.

Such a technique, however, is not simple and demands a high level of expertise as well as time.

Instead of one-lung ventilation, the lung can be pushed out of the way by inflating the ipsilateral thorax with CO₂. Pressures of up to 5 mmHg at a flow of 2 l/min are well tolerated, even in the neonate. After a short while, the ipsilateral lung collapses, and once that stage is reached an even lower inflation pressure usually suffices. In order to maintain the CO₂ pneumothorax, valved cannulae have to be used. The respiratory pressure will be increased by the same amount as the CO₂ inflation pressure and hypercapnia will occur as a result of CO₂ absorption. Both can be managed by adjustment of the ventilator settings, e.g., by increased rate and minute volume. Close collaboration between surgeon and anaesthesiologist is mandatory. It is very important that the surgeon is patient enough to allow the body to seek a new equilibrium.

Figure 10.2

The surgeon, the operative target area and the screen should be inline. This means that the surgeon stands behind the back of the patient for anterior mediastinal surgery and in front of the patient for posterior

mediastinal surgery. The cameraman, when right-handed, usually stays to the left of the surgeon. The scrub nurse usually stands on the opposite side.

Figure 10.1

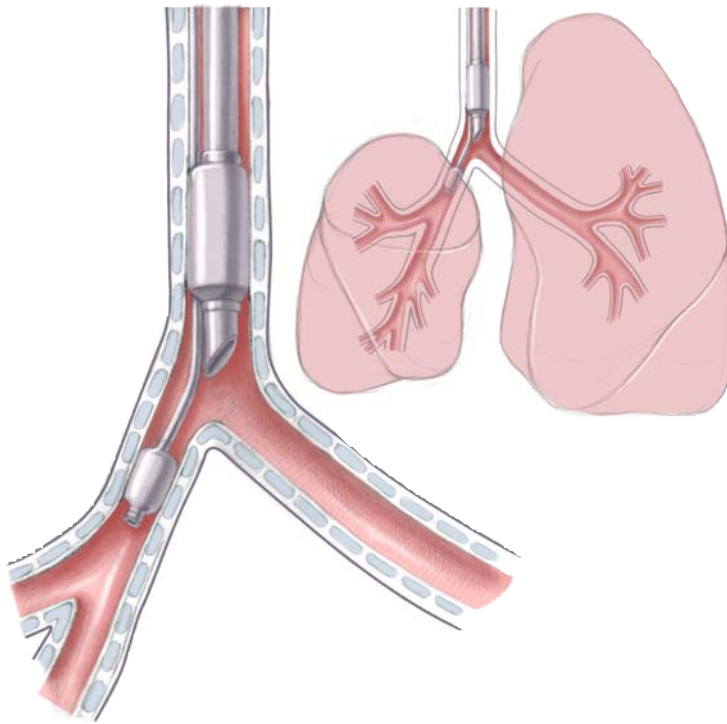


Figure 10.2

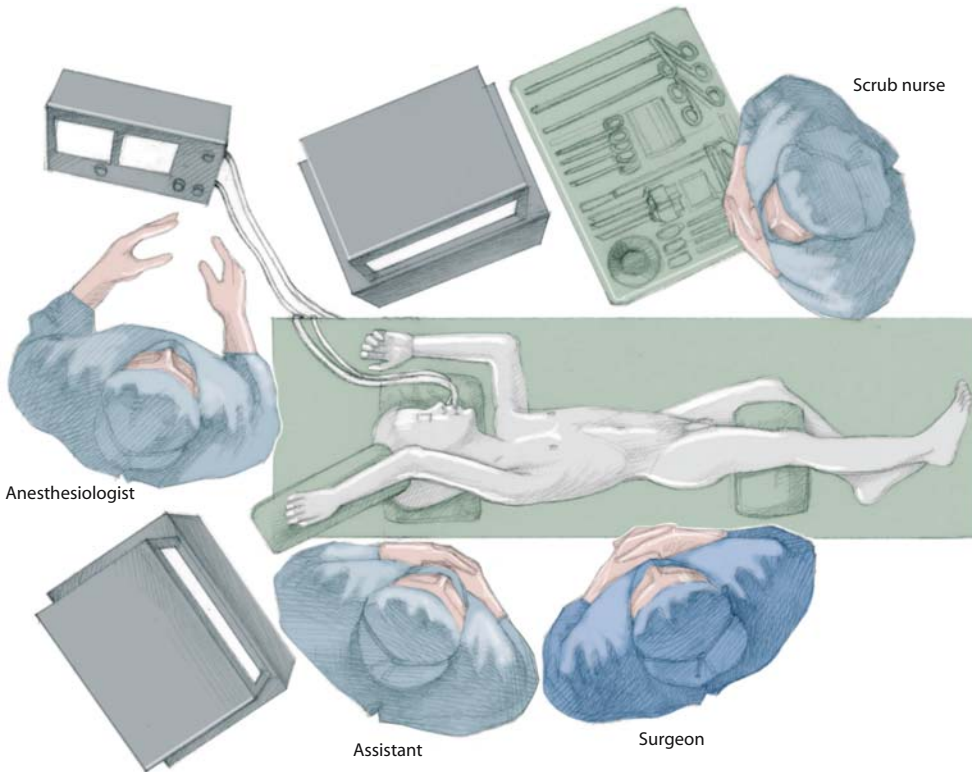


Figure 10.3, 10.4

Gravitational forces should also be used to get the lung out of the way. This means that the position of the child on the table has to be adjusted to take maximal advantage of these forces.

For anterior mediastinal surgery a three-quarters posterolateral decubitus position should be chosen; for posterior mediastinal surgery rather a three-quarters anterolateral decubitus position should be used. Moreover, for VATS in the upper part of the chest, the table should be put in a reversed Trendelenburg position, whereas for VATS in the lower part of the chest the table should be put in a Trendelenburg position. When all above measures are taken, usually no retractors are needed. If they are needed, they should be used with care as they can easily damage the organ that has to be retracted.

The cannulae can be inserted in a closed or open way. When the closed way is chosen, a radially expandable cannula is usually used. A Veress needle with radially expandable sheath is punctured through the intercostal space at the desired place. Air is allowed to enter the chest through the needle so that the pleurae detach. The Veress needle is then removed and the sheath left behind for dilatation with the cannula and blunt trocar.

In the open way, a small incision is made through the skin. Next, the wound is deepened just over the upper border of the rib until the pleural cavity is

opened and air is sucked into the chest. Next a cannula with blunt trocar is inserted. The hole in the thorax wall for the cannula should be as small as possible so that the tissues fit snugly around the cannula in order to avoid CO₂ leakage. All secondary cannulae are inserted in the same way but under concomitant telescopic control.

Especially in small children, who have a rather thin body wall, cannulae have a tendency to glide further into the body cavity, thereby further limiting the working space, or to glide out. Using radially expandable cannulae may lessen this. Cannulae with a screw on the outer side should not be used, as these will be pulled out resulting in a rather large hole. The best way to prevent this gliding in and out is to put a snugly fitting sleeve of silastic tubing around the cannula. The sleeve can then be sutured to the skin. Alternatively the stopcock of the cannula is sutured to the skin and circular tape is applied around the cannula and tied at the base.

The most ergonomic position of the cannulae is triangular or V-shaped. The tip of the V is directed towards the surgeon and the open side of the V towards the patient. The telescope cannula is inserted at the tip of the V while the cannulae for the working instruments are positioned at the top of the limbs of the V. Ideally the angle of the V should be around 60°.

Figure 10.3

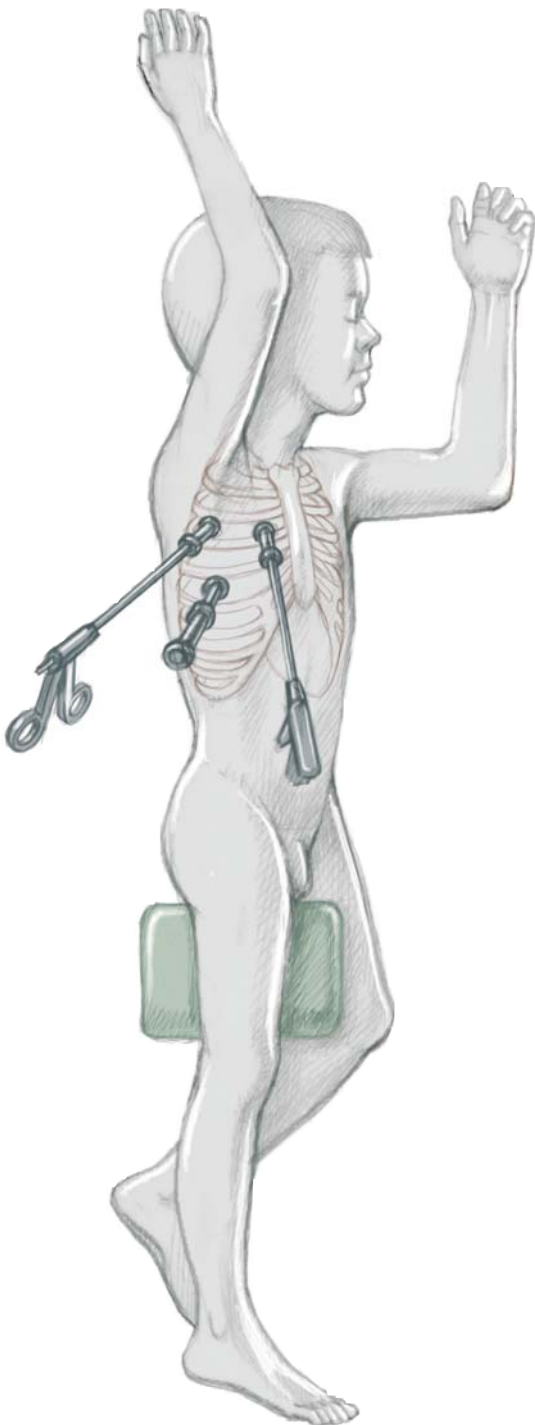


Figure 10.4

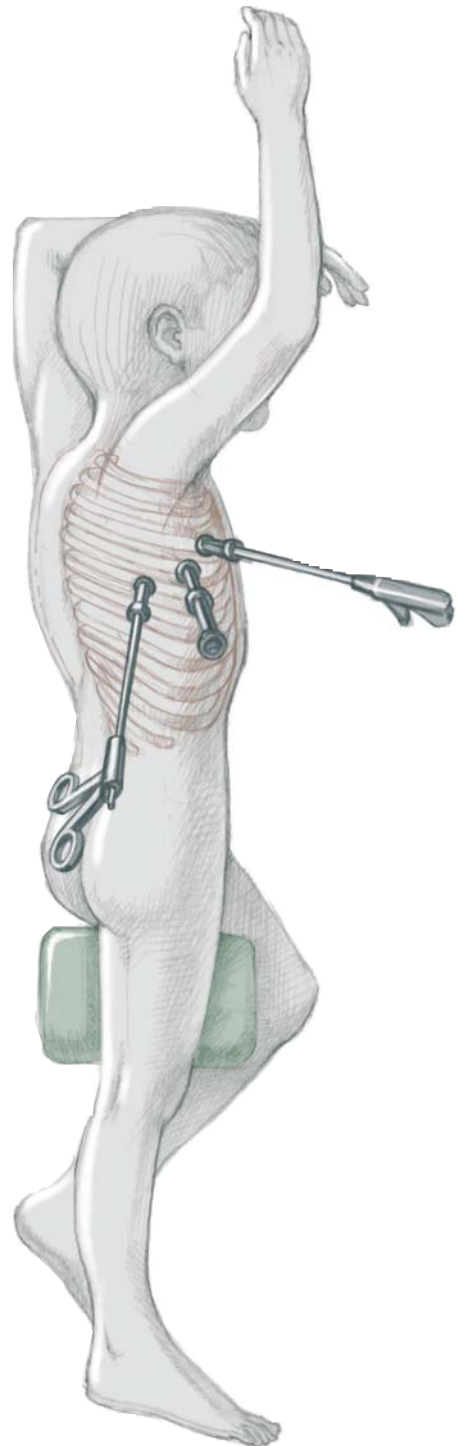

Figure 10.5

The smaller the diameter of the telescope, the less good the quality of the picture is and the less light that can be transmitted. Telescopes with a diameter of 5 mm are of sufficient quality to be used for all endoscopic operations in children. The optical axis can vary with the axis of the physical axis of the telescope from 0° to 75°. The most commonly used scopes have an angle of 30°. In contrast to 0° scopes, angled scopes allow one to look around structures, which has great advantages. Most telescopes have a length of 33 cm. For use in small children, the 24-cm length is advantageous.

For most endoscopic surgical operations in children, instruments with a diameter of 3.5 mm, to be used in conjunction with cannulae with a diameter of 3.8 mm, are appropriate. In neonates and infants, 20-cm long instruments instead of 30-cm long ones should be used. These 3.5 mm instruments can be used with monopolar high-frequency electrocautery (HFE), which suffices for most operations in smaller children.

Ligating loops can be used to seal leaking lung or to take a lung biopsy.

For the application of bipolar HFE or of ultrasonic energy, the minimal diameter of the instrument is 5 mm. This also applies for the endoscopic Ligasure instrument, which is a sophisticated bipolar HFE instrument allowing one to seal vessels with a diameter up to 7 mm in diameter. These 5-mm instruments are rather long to be used in small children.

Clipping devices also have a minimal diameter of 5 mm and are quite long.

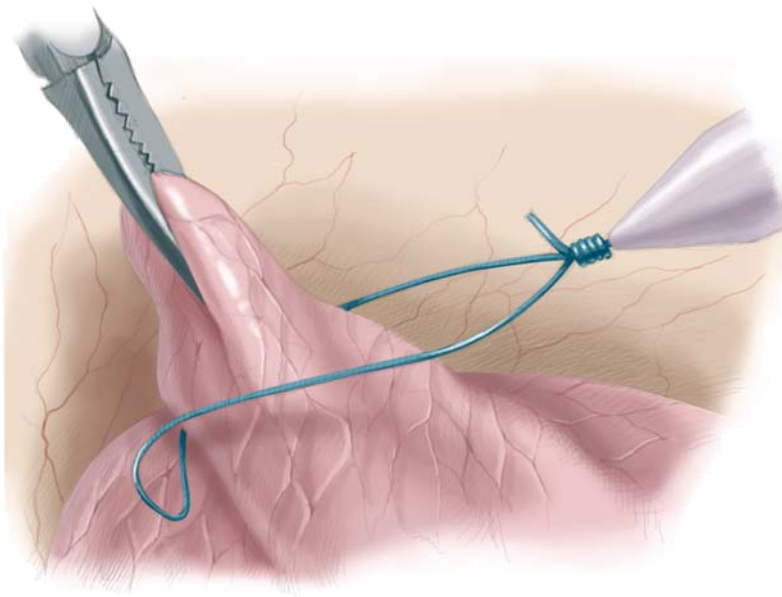
Stapling devices require an 11-mm diameter cannula, which is enormous for small children. Such a cannula will damage the intercostal space in small children and should therefore be avoided. Moreover, these staplers need a deep working space to allow the stapling beak to be opened and closed.

Tying and especially suturing of structures are considered to be the most difficult endoscopic surgical tasks and are the Achilles heel of endoscopic surgery.

Tying of blood vessels structures has been largely eliminated by the availability of new energy-applying systems, which allow even large blood vessels to be well sealed. Pre-tied loops can be used for, for example, tying-off leaking lung tissue. There are also disposable suturing devices on the market but these have a diameter of 10 mm.

The problem of suturing is certainly not solved at the present. A major problem in endoscopic suturing is the introduction of the needle. Most needles just don't fit 3.8 mm cannulae. In small children, the needle can be put directly through the body wall. Once the suturing has been finished, the needle has to be directed back through the wall. This process is time consuming especially when many sutures have to be applied as, for example, in oesophageal anastomosis. Another possibility is to straighten the curved needle so that it will fit together with the needle holder through the cannula. The tying of the knot can be done extracorporeally or intracorporeally.

Figure 10.5



CONCLUSION

VATS has revolutionized surgery not only in adults but also in infants and children. Almost all operations were classically performed through a thoracot-

omy can now be performed using VATS. VATS gives a perfect view of the anatomy and dissection is not particularly difficult. The difficulty is suturing.

SELECTED BIBLIOGRAPHY

- Bax KM, van der Zee DC (2002) Feasibility of thoracoscopic repair of esophageal atresia with distal fistula. *J Pediatr Surg* 37:192–196
- Cury EK, Schraibman V, De Vasconcelos Macedo AL, Echenique LS (2001) Thoracoscopic esophagectomy in children. *J Pediatr Surg* 36:E17
- Maher JW, Conklin J, Heitshusen DS (2001) Thoracoscopic esophagomyotomy for achalasia: preoperative patterns of acid reflux and long-term follow-up. *Surgery* 130:570–576
- Rothenberg SS (2000) Thoracoscopic lung resection in children. *J Pediatr Surg* 35:271–274
- Roviaro GC, Varoli F, Vergani C, Maciocco M (2002) State of the art in thoracoscopic surgery: a personal experience of 2000 videothoracoscopic procedures and an overview of the literature. *Surg Endosc* 16:881–892
- Smith TJ, Rothenberg SS, Brooks M, Bealer J, Chang J, Cook BA, Cullen JW (2000) Thoracoscopic surgery in childhood cancer. *J Pediatr Hematol Oncol* 24:429–435

Repair of Pectus Excavatum

Robert C. Shamberger

INTRODUCTION

Pectus excavatum is a congenital deformity of the anterior chest wall. It consists of two primary elements. The first component is posterior depression of the body of the sternum generally beginning at the level of the insertion of the second or third costal cartilages. The second component is posterior depression of the attached costal cartilages. This depression generally involves ribs 3–7 and sometimes will extend to the level of the second costal cartilage. In older teenagers the posterior depression of the ribs will involve part of the osseous as well as the cartilage component. This is a congenital deformity and in greater than 90% of children it will be apparent within the first year of life. It has an increased frequency of occurrence in families with a history of chest wall deformity, and has been estimated to have an incidence of 1 in 300 to 1 in 400 births.

The physiologic implications of pectus excavatum have been evaluated for the last four decades. It has been demonstrated that a “restrictive” defect occurs in individuals with pectus excavatum. The total lung capacity and the vital capacity are decreased relative to normative values. The values for an individual often do not fall out of the “normal range” but, taken as a group, individuals with pectus excavatum do have decreased pulmonary volume compared with normals. The extent of this impairment is variable and it depends upon the severity of the depression and the depth of the chest. The second physiologic impairment which has been demonstrated is a decrease in the filling capacity of the heart, in particular the right ventricle. This is produced by anterior compression from the depressed sternum. Studies dating back to those of Beiser have shown a decreased stroke volume, particularly in the upright position, associated with significant chest wall deformity. While subsequent studies have shown variable results when using radioisotope techniques, this impairment is clearly one of the components of decreased cardiopulmonary function in patients with severe pectus excavatum. Workload studies have demonstrated that individuals with pectus excavatum develop symptoms of fatigue earlier in gaited exercise protocols than do normal probands. Two studies by Cahill in 1984 and Peterson in 1985 have also demonstrated that following repair of the chest wall deformity, the level of the exercise tolerance has increased.

Determination of the subject’s appropriateness for repair is dependent upon multiple considerations. These include the degree of psychologic distress created by the deformity, the extent of impairment of physical activity by cardiopulmonary symptoms, and results of the pulmonary function and physiologic exercise studies.

Techniques for repair of pectus excavatum have evolved significantly since it was first repaired in 1911. Modern approaches date to 1949 when Ravitch first reported a technique that involved excision of all deformed costal cartilages with the perichondrium, and division of the xiphoid and the intercostal bundles from the sternum. A sternal osteotomy was created and the sternum was secured anteriorly with Kirschner wire fixation. This approach was modified by Baronofsky (1957) and Welch (1958) when they stressed the need for preservation of the perichondrial sheaths to allow optimal cartilage regeneration for durability of the repair. Fixation with metallic struts anterior to the sternum was the next modification developed by Rehbein and Wernicke in 1957. Retrosternal strut fixation was described by Adkins and Blades in 1971. While recent innovations for strut fixation have included the use of such materials as bioabsorbable struts, Marlex mesh or Dacron vascular graft, no evidence demonstrates that these are better than traditional metallic struts.

In 1998 Donald Nuss first described a method for repair of pectus excavatum utilizing a heavy metal strut to displace anteriorly the sternum and depressed costal cartilages. It did not require resection or remodelling of any of the costal cartilages. In this chapter, I will present both the current open technique with its modifications that I utilize, as well as the innovative Nuss technique, which is also known as the minimally invasive repair of pectus excavatum (MIRPE). The latter technique is still awaiting outcome analysis. The first report by Nuss of 42 patients utilized a fairly young cohort in which the median age was 5 years. A subsequent report by Croitoru in 2002 utilizing this method included a larger and older cohort of 303 patients. In that group only 23.4% of the patients had the bars removed.

Figure 11.1a,b

A transverse skin crease incision is placed below and within the nipple lines (a). In females, it is of particular importance to see that this is placed in the future inframammary crease to avoid unsightly tethering of a scar between the two breasts. The skin flaps are then elevated superiorly to the level of the apex of the

deformity and inferiorly to the tip of the xiphoid (b). The flaps are developed just anterior to the pectoral fascia to keep them well vascularized. The pectoral muscles are then elevated off the sternum being cautious to preserve all of the muscle and overlying fascia intact.

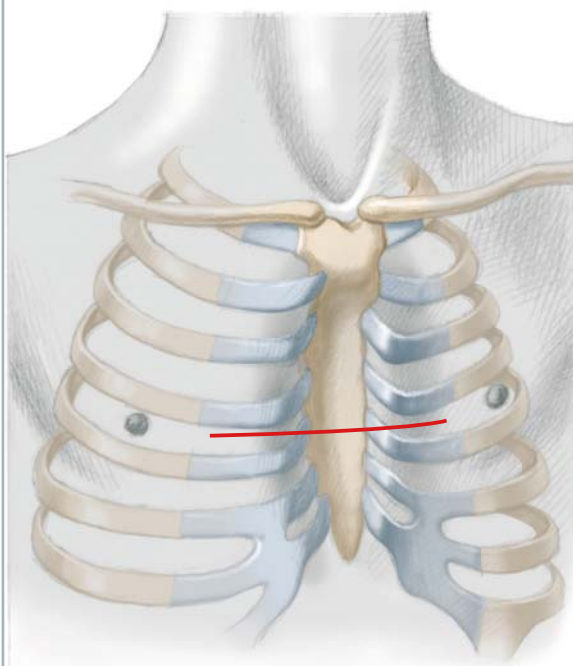
Figure 11.2

To facilitate identification of the appropriate plane of dissection, the muscle is first elevated just anterior to one of the costal cartilages. When this plane is defined, an empty knife handle is then inserted anterior to the costal cartilage and passed laterally. It is then replaced with a right angle retractor to elevate the muscle anteriorly. This step is then repeated anterior to the next costal cartilage just above or below the first rib defined. Elevation of the muscle flap in between the two right angle retractors facilitates identification of the correct plane of dissection. The origin of the salmon-coloured pectoral muscles are divided with electrocautery making certain to stay out of the intercostal bundles, which are covered with a glistening white fascia. Injury of the intercostal bundles can result in significant bleeding. The muscle flaps are mobilized laterally to the costochondral junction or to the lateral extent of the deformity. Generally cartilages 3–7 are involved, but sometimes the second cartilage is as well.

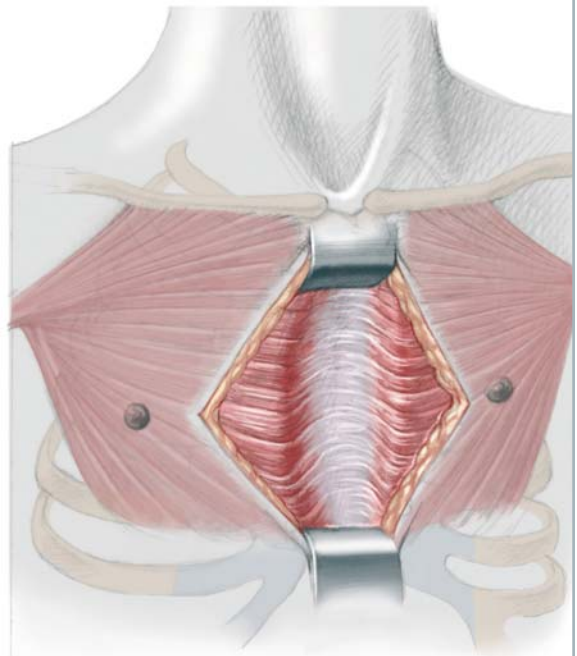
Figure 11.3

Incisions are then placed through the perichondrial sheaths parallel with the axis of the cartilage. It is helpful to keep the incision on the flat anterior aspect of the rib. The perichondrial sheaths are dissected off the costal cartilage utilizing perichondrial elevators. Freeing the edge of the perichondrium from the medial aspect of the rib provides better visualization of the posterior aspect of the cartilage facilitating this process. The cross-sectional shape of the ribs must be remembered. Ribs 2 and 3 are fairly flat. Ribs 4 and 5 are round, and ribs 6 and 7 have a narrow width and greater depth.

Figure 11.1a,b



a



b

Figure 11.2

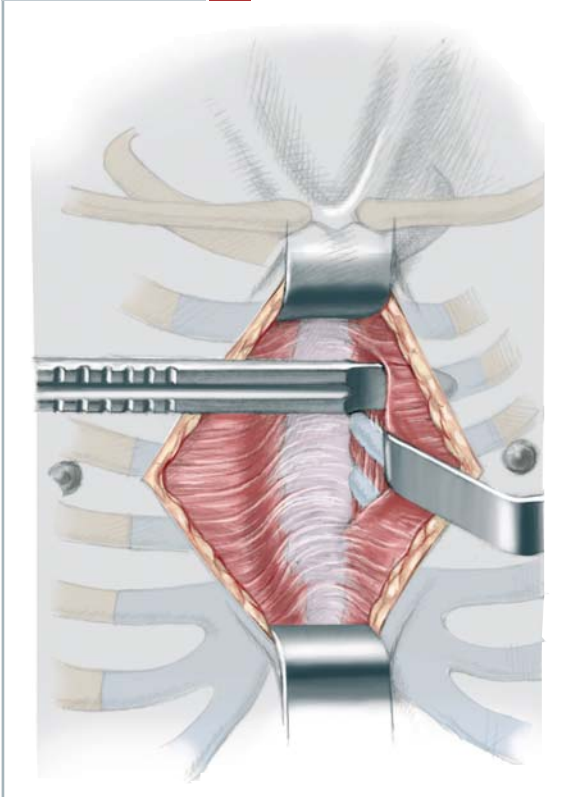


Figure 11.3

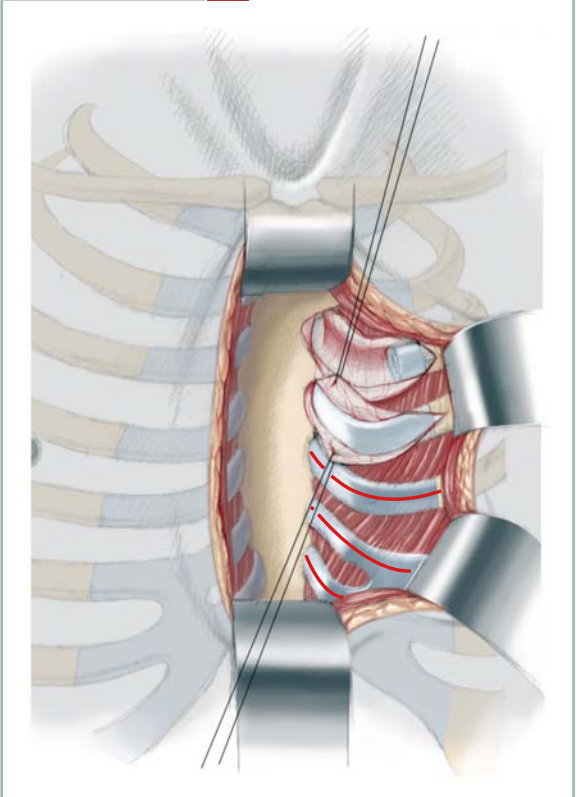


Figure 11.4

The medial aspect of the cartilage is then incised from the sternum (see *insert*) with the posterior aspect protected by the perichondrial elevator. Incising the cartilage directly adjacent to the sternum will also minimize the risk of injury to the internal mammary vessels, which are generally 1 to 1.5 cm lateral to the margin of the sternum. To minimize any impairment of subsequent growth of the ribs, 1 to 1.5 cm of the costal cartilage is preserved with the costochondral junction.

Figure 11.5

The wedge osteotomy is then created on the anterior surface of the sternum at the apex of the deformity. The segment of bone is then mobilized using one of the wings of the perichondrial elevators, but without entirely dislodging it from the sternum. Leaving it partially in place will facilitate more rapid healing of the fracture.

Figure 11.6

The sternum is then elevated with a towel clip and posterior pressure is applied to the upper portion of the sternum to fracture the posterior sternal plate. While in the past the xiphoid was divided along with the rectus muscle from the tip of the sternum, I currently avoid this step. This minimizes the occurrence of an unsightly depression at the base of the sternum. Using a posterior sternal strut it is also unnecessary to divide the lower perichondrial sheaths as was done in the past. This division of the lower perichondrial sheaths also contributed to the depression below the sternum. If the xiphoid produces an unsightly protrusion when the sternum is in its corrected position, it can be divided from the sternum using a lateral approach with cautery. This avoids taking down the rectus attachment.

Figure 11.7

A retrosternal strut is tunnelled posterior to the sternum. This retrosternal tunnel is made by partially dividing one of the perichondrial sheaths directly adjacent to the sternum. A tunnel is then created posterior to the sternum with a Schnidt clamp, which is brought out directly adjacent to the sternum to avoid injury to the internal mammary vessels on the contralateral side. Prior to passing the strut behind the sternum, it is preformed so that there is a slight indentation in which the sternum will sit and the strut is curved somewhat posteriorly on each end to allow it to conform to the shape of the ribs and avoid any unsightly protrusions into the skin and the muscle. The Schnidt clamp is then used to draw the strut behind the sternum with the concave portion of the strut anterior. Once it is behind the sternum and in an appropriate position just anterior to the ribs on each side, it is rotated 180°. It is important in this step to make certain that the strut is deep to the pectoral muscle flap to provide adequate soft tissue coverage over the strut. The strut is then secured to the periosteum laterally with two heavy no. 0 absorbable sutures. This will secure the strut in position.

Figure 11.4

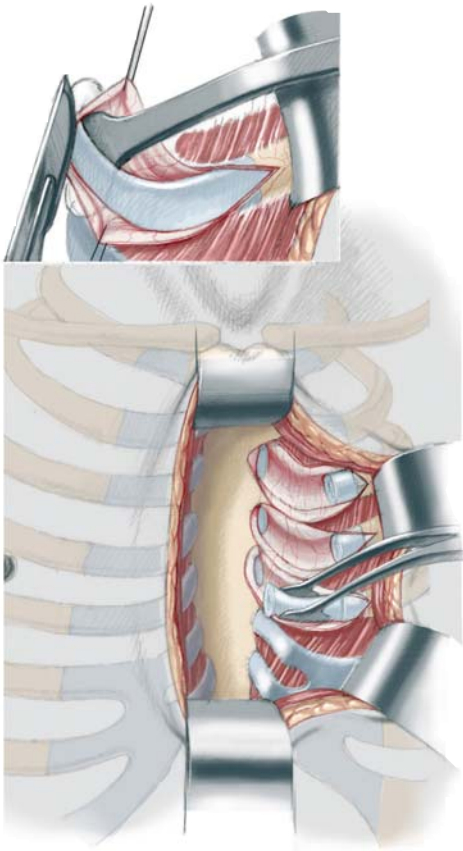


Figure 11.5

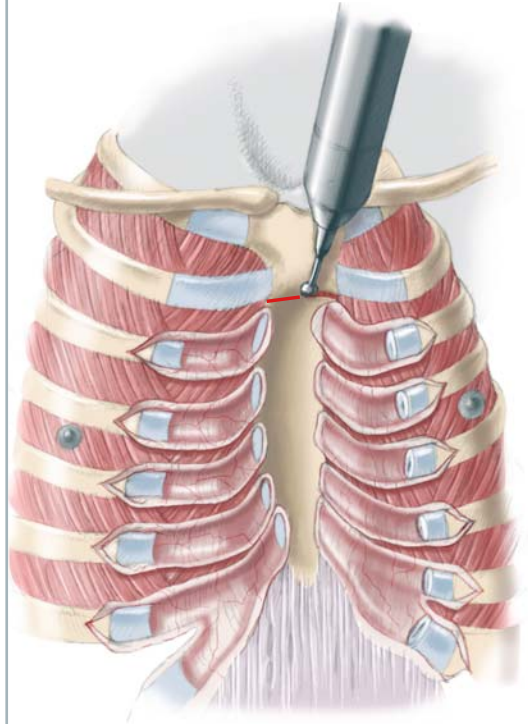


Figure 11.6

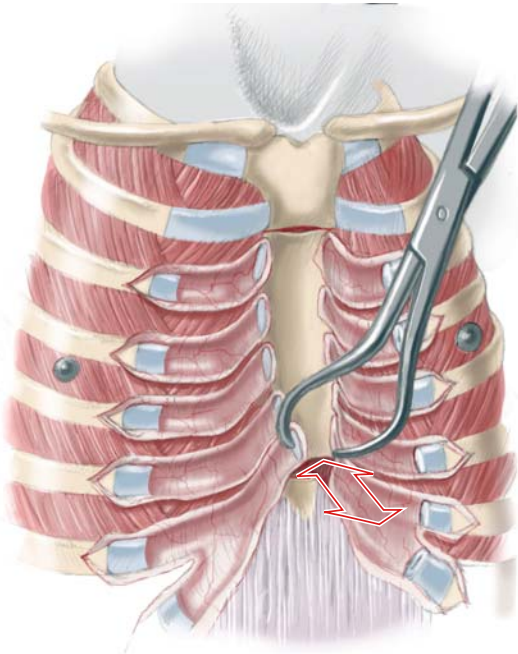


Figure 11.7

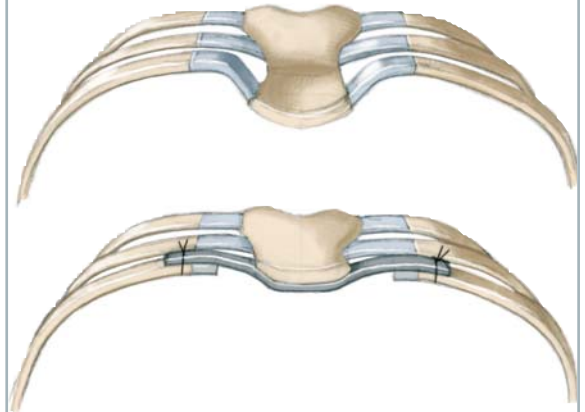


Figure 11.8

This depicts the position of the retrosternal strut from an anterior perspective with it secured to the ribs on each side. The pectoralis major muscle flaps are then approximated over the sternum. The flaps are advanced inferiorly to compensate for the fairly bare lower portion of the sternum. This allows it to be covered with soft tissue. At the inferior aspect the flap is attached to the rectus muscle with interrupted absorbable sutures.

Figure 11.9

For the Nuss procedure two incisions are made at the mid-axillary line at the level of maximal sternal depression. A Lorenz tunneller or long clamp is then passed through one lateral incision along the chest wall, and enters into the pleural cavity at the inner aspect of the pectus ridge. It is tunnelled behind the sternum and anterior to the pericardium and it is brought out the contralateral side. The point of exit from the thorax is also aimed at the inner aspect of the pectus ridge. Thereafter, it is passed along the outside of the chest wall and out through the skin at the anterior axillary line. An umbilical tape is then grasped by the clamp or Lorenz tunneller and brought through the tunnel. Two tapes are often used in case one breaks. Several adaptations have been utilized to minimize the risk of cardiac injury from this manoeuvre. The first adaptation now widely utilized involves a thoracoscope to monitor the passage of the tunneller behind the sternum. A second adaptation less frequently used is to make a small incision at the tip of the sternum through which a bone hook can be inserted. The sternum is elevated anteriorly as the clamp is passed across the chest to broaden the retrosternal space.

Figure 11.10

The preformed strut which has been pre-measured and bent to make certain that it fits the breadth of the

patient's chest is then brought through the chest and passed so that the concave surface is anterior.

Figure 11.8

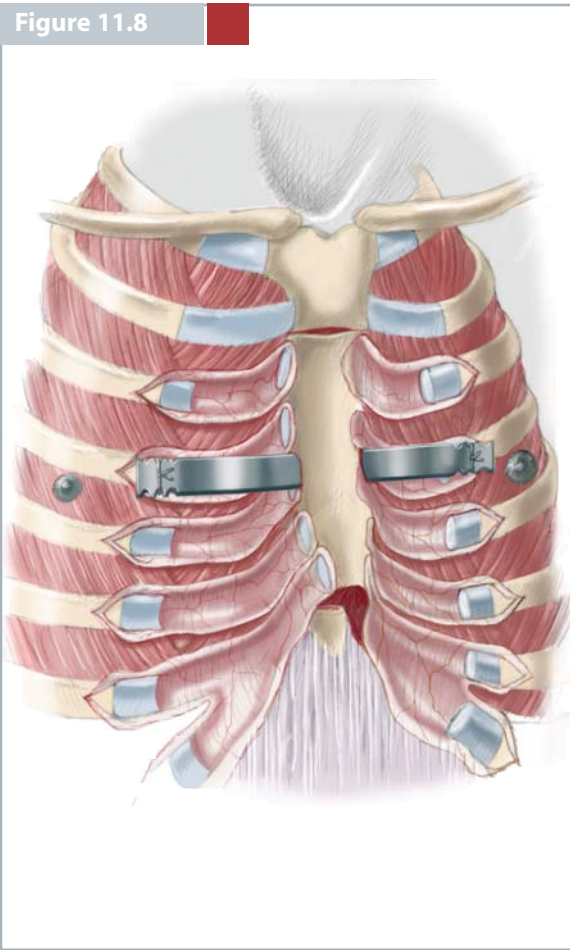


Figure 11.9

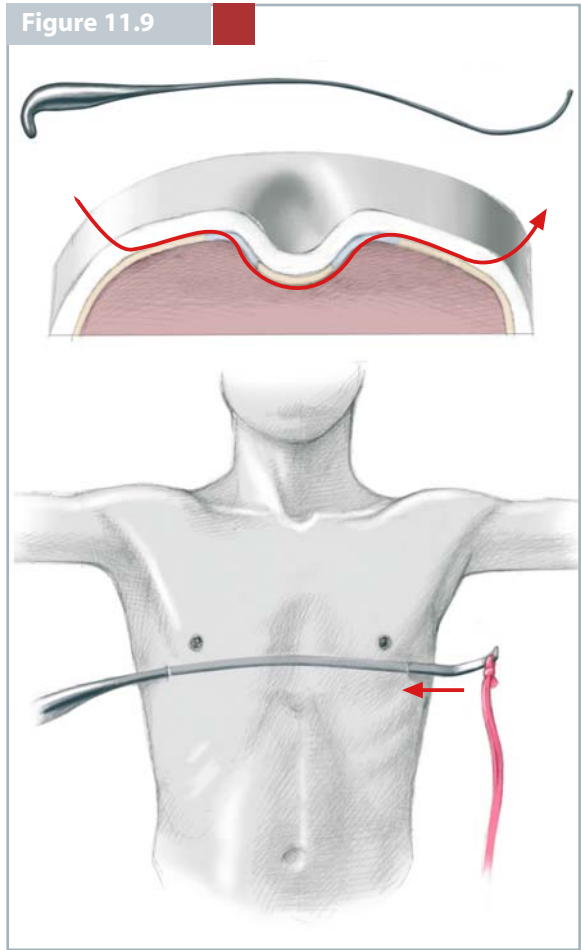


Figure 11.10

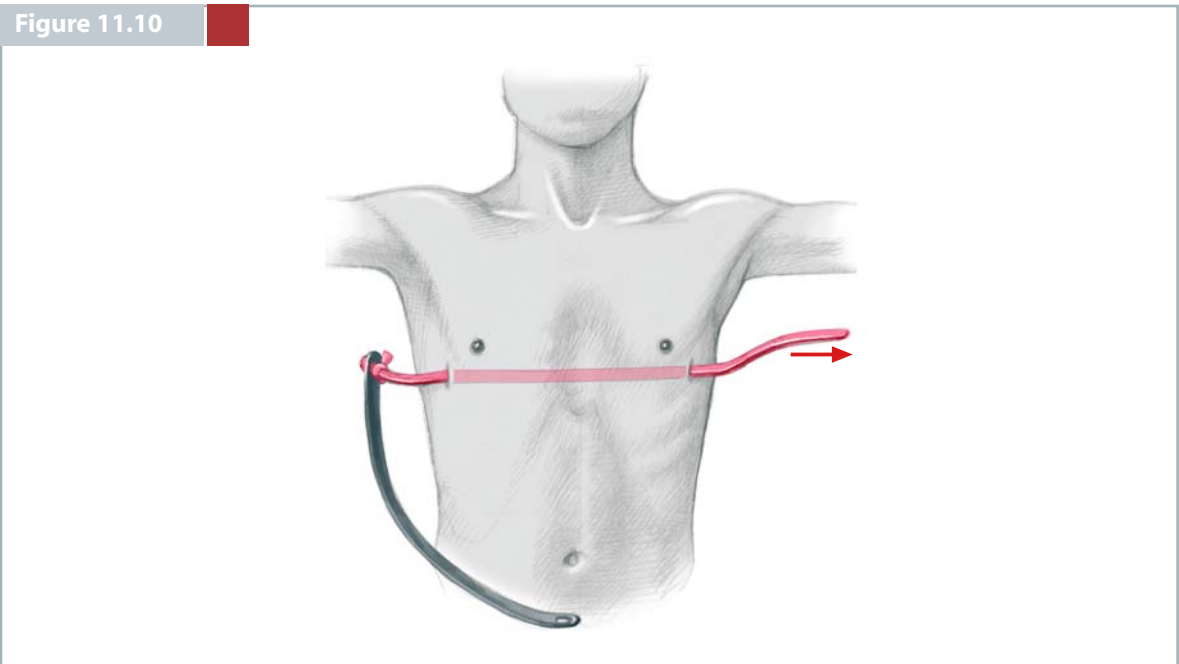


Figure 11.11

Once the bar is in position, it is rotated 180° with a special “Lorenz flipper” to elevate the sternum and costal cartilages. During this manoeuvre the skin and muscle flaps are elevated over the end of the bar so that the bar sits directly along the chest wall.

Figure 11.12

The most frequent complication of this procedure when it was initially performed was rotation of the Lorenz strut. To reduce this risk, a “stabilizer” may be attached to both sides of the strut with heavy no. 3 wire or suture. Once attached to the strut, it is then sutured to the soft tissues of the chest to provide secure fixation and prevent rotation of the bar and loss of correction of the deformity.

Figure 11.13, 11.14

This diagram shows the Lorenz strut in position prior and after rotation. The bar in the final position is displacing the sternum anteriorly along with the

costal cartilages to correct the pectus excavatum deformity. The bar is electively removed in 2 to 3 years.

Figure 11.11

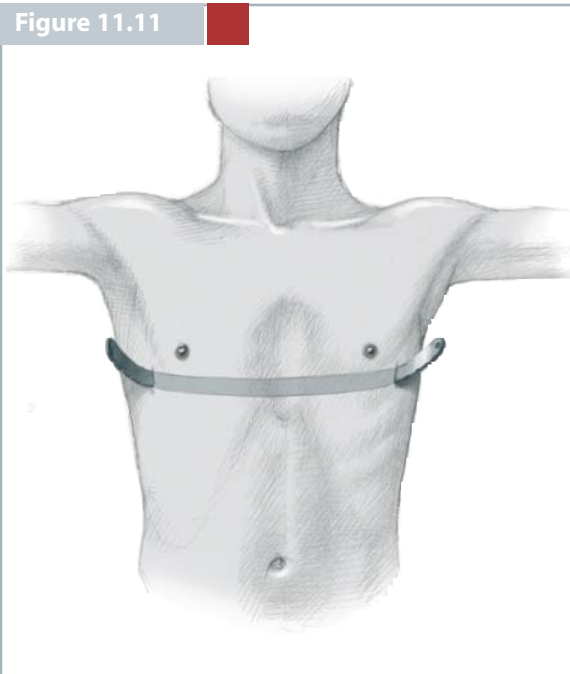


Figure 11.12




Figure 11.13

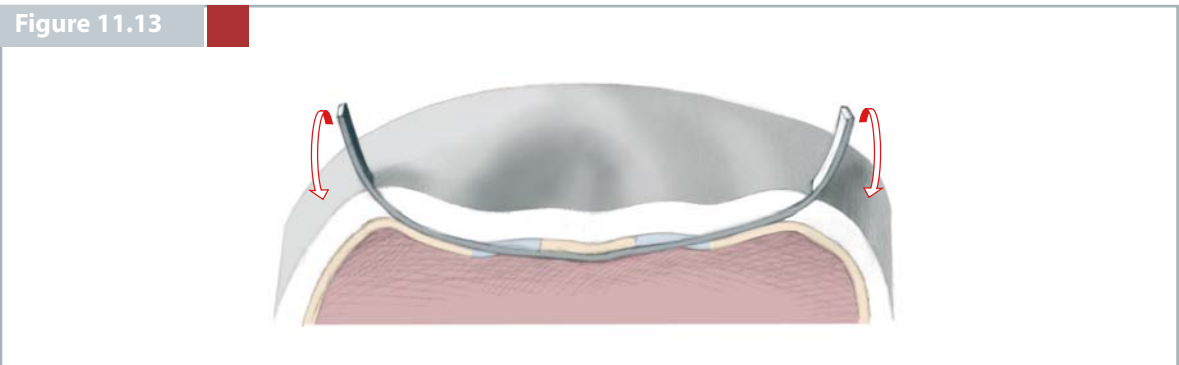
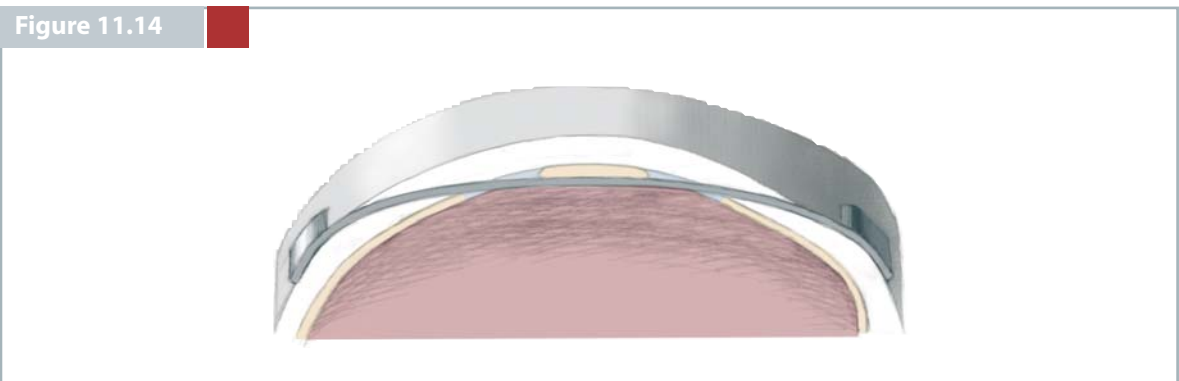


Figure 11.14



CONCLUSION

The overall results of repair of pectus excavatum should be excellent. The peri-operative risks must be limited. The most significant complication is a major recurrence, which has been described in large series as occurring in 5 to 10% of patients. A limited pneumothorax requiring aspiration is infrequent and rarely requires a thoracostomy tube. Wound infection should be rare with the use of peri-operative antibiotic coverage and protective coverage of the skin during the operative procedure to minimize any contamination by skin flora.

Long-term outcome of the Nuss procedure in teenagers is not well documented at this time as it has been used for less than a decade in older patients. The most frequent complication described in early use of the minimally invasive procedure was rotation of the strut. Lateral stabilizers have significantly decreased the incidence of this complication. Other complications described include pneumothorax, pericarditis, and hemothorax. Complications unique to

the minimal access procedure which have not occurred with the standard open technique include thoracic outlet syndrome and the rare occurrence of a carinate deformity after repair. Occurrence of an allergic reaction to the metal Lorenz struts has also occurred in 1% of patients who present with rashes along the area of the bar requiring replacement with bars composed of other alloys. Older patients seem to encounter significant pain with the minimally invasive procedure, but quantitative comparisons to the standard open operation have not yet been reported.

Both techniques appear to achieve excellent correction of the deformity. Comparison of complication rates of each technique has not yet been accomplished, but hopefully a multi-institutional prospective study of these surgical techniques will define their relative benefits and risks. Repair of pectus excavatum is important for children who are either psychologically distressed or physiologically impaired by their deformity.

SELECTED BIBLIOGRAPHY

- Croitoru DP, Kelly RE Jr, Goretsky MJ et al (2002) Experience and modification update for the minimally invasive Nuss technique for pectus excavatum repair in 303 patients. *J Pediatr Surg* 37: 437-445
- Hebra A, Swoveland B, Egbert M et al (2000) Outcome analysis of minimally invasive repair of pectus excavatum: review of 251 cases. *J Pediatr Surg* 35: 252-258
- Nuss D, Kelly RE Jr, Croitoru DP et al (1998) A 10-year review of a minimally invasive technique for the correction of pectus excavatum. *J Pediatr Surg* 33: 545-552
- Shamberger RC (2003) Congenital thoracic deformities. In: Puri P (ed) *Newborn surgery*. Arnold, London, pp 239-246
- Sidden CR, Katz ME, Swoveland BC, Nuss D (2001) Radiologic considerations in patients undergoing the Nuss procedure for correction of pectus excavatum. *Pediatr Radiol* 31: 429-434

Brian T. Sweeney, Keith T. Oldham

INTRODUCTION

Congenital lung abnormalities are uncommon and diverse in their presentations. Congenital lobar overinflation (CLO), otherwise known as congenital lobar emphysema, is among the most common of the congenital lung anomalies. It is characterized by air trapping and overdistension of one or more lobes which are otherwise anatomically normal. This distension causes compression of adjacent normal lung parenchyma and can result in mediastinal shift and cardiorespiratory compromise. CLO is believed to result most commonly from structural deficiency or absence of supportive cartilage in the affected lobar bronchus, thereby causing expiratory collapse of the conducting airway with impedance to expiratory flow. CLO is most often seen in the Caucasian population with a male preponderance of two or three to one. It is most common in the left upper lobe (40–50%), with other sites affected less frequently: right middle lobe 30–40%, right upper lobe 20%, and lower lobes 1%. Approximately half of the patients develop respiratory distress within the newborn period while the remainder present up to 4 to 6 months of age or later. Presenting signs are those of respiratory embarrassment, including dyspnea, tachypnea, agitation and wheezing.

Congenital cystic adenomatoid malformations (CCAM) are a rare group of cystic lobar hamartomatous lesions, represent up to 50–70% of the bronchopulmonary foregut malformations in some reports. The lesions are generally large, firm, multicystic masses that are composed of terminal respiratory structures, usually bronchiolar in origin.

Since the advent of routine ultrasound in obstetric practice, the majority of cystic lung lesions are now discovered prenatally in many institutions. Serial ultrasonographic examinations may demonstrate shrinkage or even spontaneous resolution in up to 40% of fetal CCAMs. After birth, some neonates demonstrate tachypnea, dyspnea, cyanosis or impending respiratory failure. Of the remainder, most will present within the first years of life with recurrent or persistent respiratory infections, pulmonary abscesses, reactive airway disease or failure to thrive. As for all bronchopulmonary foregut malformations,

the plain chest radiograph is the best initial diagnostic test in the neonate.

Pulmonary sequestrations make up 10–30% of the cystic bronchopulmonary foregut malformations. They are classified according to whether the sequestration resides within the visceral pleura of the normal lung (intralobar sequestration) or is invested by its own visceral pleura (extralobar sequestration). In both types of pulmonary sequestration, however, there is no bronchial communication between the sequestrum and the normal tracheobronchial tree. In addition, the malformation receives its blood supply from aberrant systemic arterial vessels.

Intralobar sequestrations make up about 50–70% of the pulmonary sequestrations and most commonly involve the posterior and basal segments of the left lower lobe. The arterial supply is usually derived from aberrant branches of the descending thoracic aorta, although occasionally intercostal, brachiocephalic, or abdominal aortic aberrant vessels are encountered. Venous drainage is usually via the associated pulmonary vein. Extralobar sequestrations are completely separated from the normal lung and invested by an individual pleura. They are completely separate from the functional airways. They are found in the left lower chest most commonly, but may occur anywhere. Rarely, subdiaphragmatic locations are reported. A 3:1 male predominance is reported in most series for extralobar sequestrations. These sequestrations also derive arterial blood supply from the descending aorta, with up to 20% having an aberrant vessel traversing the diaphragm.

Patients with intralobar sequestration will typically present with pulmonary infections due to abnormal air-space connections with inadequate drainage, or from compressive atelectasis of adjacent parenchyma. Extralobar sequestrations, on the other hand, are frequently seen on prenatal ultrasound.

Congenital lung cysts comprise up to one-third of bronchopulmonary foregut malformations in some reports. The most common of these lesions are bronchogenic cysts. Bronchogenic cysts arise from the trachea, bronchus or other conducting airways but have usually lost their connection with the parent

structure. They are usually simple, and contain mucus; however, air-fluid levels and infection may be seen if there is continuity with the tracheobronchial tree. In contrast to sequestrations, bronchogenic cysts have a normal bronchial blood supply. Although bronchogenic cysts may reside anywhere in the respiratory tract, including paravertebral, paraoesophageal, subcarinal and cervical areas, the majority are found in the lung parenchyma or mediastinum.

Some patients with bronchogenic cysts are asymptomatic. Of those with symptoms, the most common presentations are wheezing, tachypnea or dyspnea, all related to compression of the adjacent conducting airway with partial obstruction.

Plain radiograph of the chest will usually demonstrate the pathology of the congenital malformation of the lung. In most infants and children with congenital malformations of the lung additional imaging is required. Ultrasound with Doppler, computed tomography scan with contrast, or magnetic resonance imaging provide good anatomical details and demonstrate relationship to the neighbouring structures.

Treatment of congenital malformations of the lung is usually by lobectomy of the affected lobe, which is very well tolerated in the infant population.

Figure 12.1–12.2

Lung surgery in children is generally similar to that in adults except that the diminutive size, the associated lesions, and the unique pathologic entities require certain special considerations. Lobectomy can be performed by conventional thoracotomy or video-assisted thoracoscopy.

Lobectomy is the procedure of choice for the treatment of congenital lobar emphysema, CCAM, intralobar sequestrations and some parenchymal lung cysts. The patient is positioned in the lateral decubitus position, with the upper arm extended and placed over the head. Rolled towels and other positioning devices may be placed in order to optimize stabilization and exposure of the operative field.

Optimal exposure is gained by transverse or oblique incision over the fourth or fifth intercostal space, below and lateral to the nipple to avoid cosmetic and functional damage to the breast tissue. There should be some space between the tip of the scapula and the posterior extent of the incision. This becomes important during closure of the muscle layers, especially if the incision must be extended posterolaterally. Underlying muscle and subcutaneous tissue is divided along the line of incision by electrocautery. To limit postoperative morbidity, it is desirable and usually possible to employ a muscle sparing approach. This affords adequate exposure yet avoids division of the serratus anterior and chest wall musculature other than the latissimus dorsi. The scapula is elevated off the chest wall by retractor to gain exposure, and palpation is used to count the ribs to the correct interspace. In most situations in infants, the highest palpable rib is the second. Generally, the fourth interspace is used for a lobectomy although the fifth can be used effectively as well.

Figure 12.1

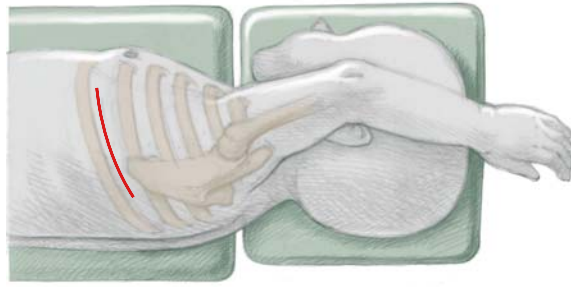

Figure 12.2

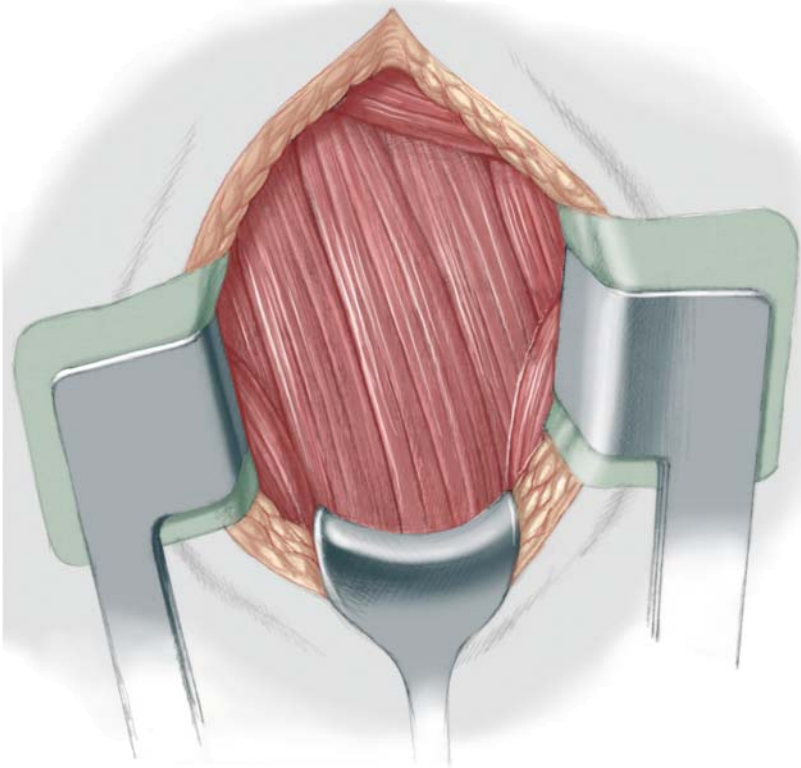


Figure 12.3, 12.4

The incision is then continued with electrocautery just superior to the lower rib of the selected intercostal space to avoid damage to the neurovascular bundle that runs along the inferior border of each rib. Care must be taken when entering the pleura to avoid

injury to the lung parenchyma beneath. A rib spreader is then placed to facilitate retraction. The incision may then be continued anteriorly or posteriorly from inside the chest if further exposure is needed.

Figure 12.5

The following technique and illustrations are described for left upper lobectomy, however, the principles are the same for any lobe resection. Gentle later-

al and inferior traction on the lobe exposes the hilum. The visceral pleura is carefully incised circumferentially, exposing the hilar structures.

Figure 12.3

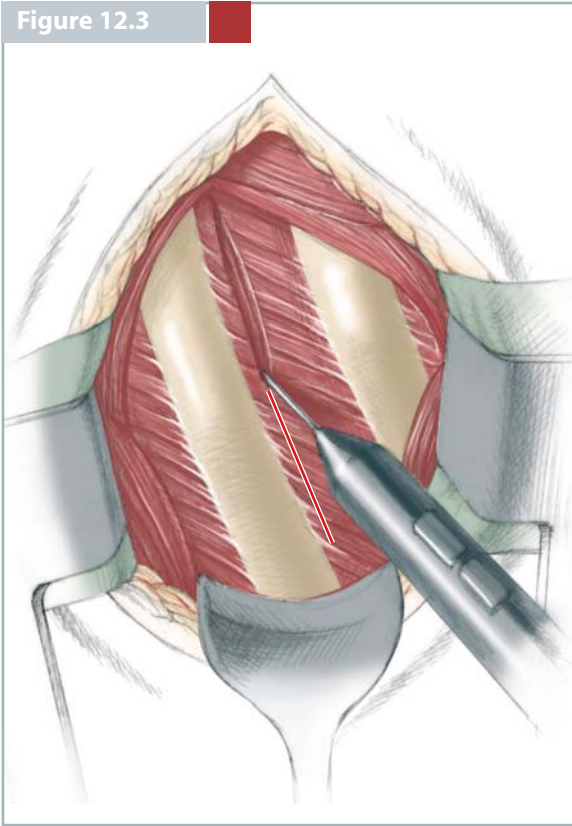


Figure 12.4

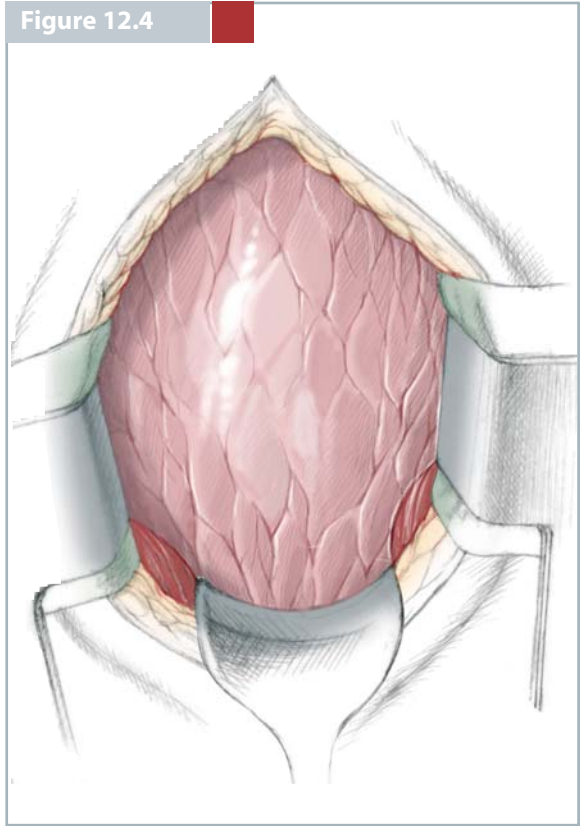


Figure 12.5

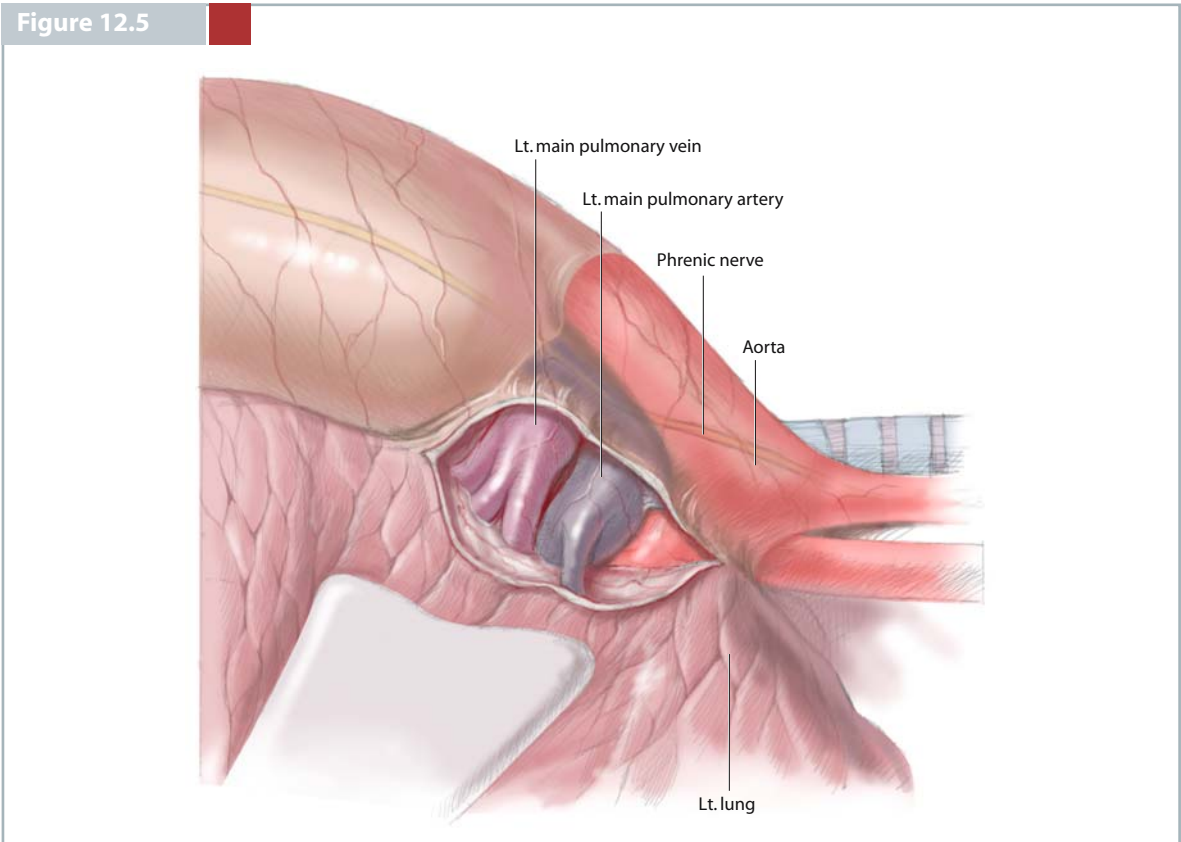


Figure 12.6, 12.7

Meticulous dissection reveals the left main pulmonary artery as it courses under the aortic arch and crosses the left upper lobe bronchus. Nearby structures to be noted are the left phrenic nerve anteromedially along the mediastinum, and the recurrent laryngeal nerve branching from the vagus under the aortic arch. A review of segmental anatomy of the lung describes four main arterial branches supplying the left upper lobe, however this can be variable.

These are individually encircled, ligated and divided. This is typically done with heavy silk and using double proximal ligatures. The bronchial blood supply travelling with the left upper lobe bronchus is likewise identified and ligated. Attention is then directed to the left upper lobe venous drainage. Again, individual branches are circumferentially dissected and ligated using the same approach as for the arterial circulation.

Figure 12.8

The bronchus is then clamped and divided. Closure of the bronchial stump with commercial surgical stapling devices is appropriate in older children; however, size and other technical limitations make this undesirable in infants where a simple sewn closure is best. Air leaks may be identified for suture repair by filling the chest with warm saline coincident with inflation of the residual lobe by the anaesthesiologist. The inferior pulmonary ligament should be divided at this time to facilitate expansion of the left lower

lobe, or it may be done early in the dissection to facilitate exposure. The superior and inferior pulmonary vein sometimes have a common stem outside the pericardium, which if unrecognized, may necessitate total pneumonectomy. A chest tube is placed within the pleura for drainage, and the wound is closed in anatomical layers using absorbable suture. Post-operatively, drains can be removed early, provided no air leak is demonstrable.

Figure 12.6

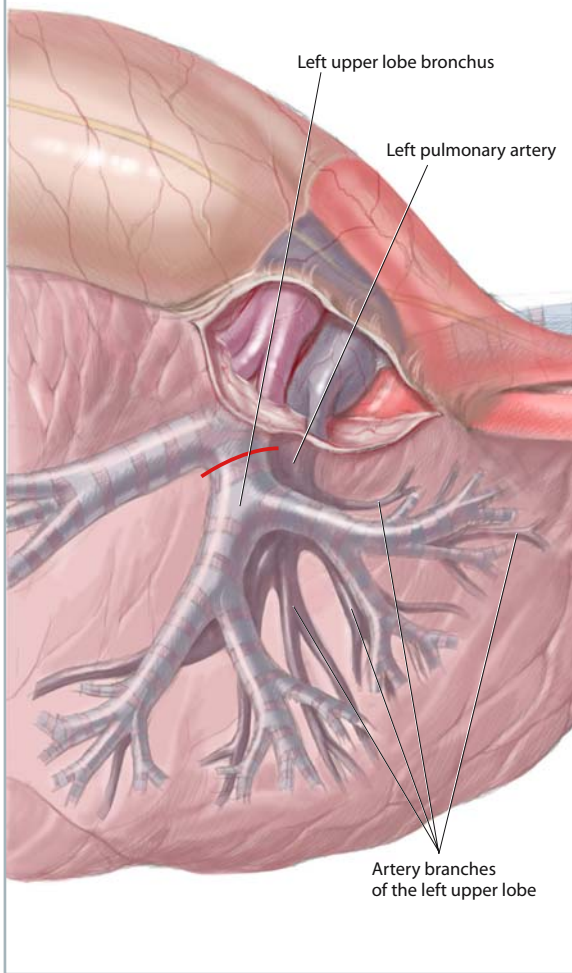


Figure 12.7

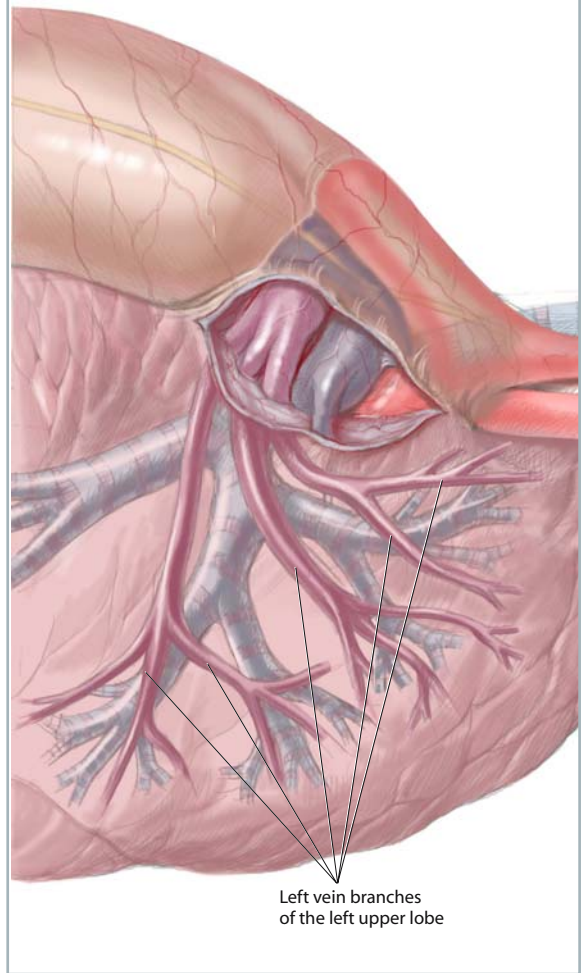


Figure 12.8



CONCLUSION

Lung surgery in neonates and infants is generally similar to that in adults except that the diminutive size, the associated lesions and the unique pathologic entities require certain special considerations. Of course, the smaller the child, the more care must be taken in order to avoid technical injury. As with all

lung surgery, technical problems may result in serious and irreversible consequences. Collaboration with paediatric anaesthesiologists familiar with the unique circumstances of paediatric chest surgery is essential.

SELECTED BIBLIOGRAPHY

- Black TL (2003) Pulmonary sequestration and congenital cystic adenomatoid malformation. In: Ziegler MM, Azizkhan RG, Weber TR (eds) *Operative pediatric surgery*. McGraw-Hill, New York, pp 445–454
- Adzick NS, Harrison MR, Crombleholme TM et al (1998) Fetal lung lesions: management and outcome. *Am J Obstet Gynecol* 179: 884–889
- Albanese CT, Sydorak RM, Tsau K (2003) Thoracoscopic lobectomy for prenatally diagnosed lung lesions. *J Pediatr Surg* 38: 553–555
- Lo, HP, Oldham KT (2003) Congenital malformations of the lung. In: Puri P (ed) *Newborn surgery*. Arnold, London, pp 295–307
- Oldham KT (1997) Lung. In: Oldham KT (ed) *Surgery of infants and children: scientific principles and practice*. Lippincott-Raven, Philadelphia

Congenital Diaphragmatic Hernia and Eventration

Prem Puri

INTRODUCTION

Congenital Diaphragmatic Hernia

Congenital diaphragmatic hernia (CDH) is a malformation characterized by a defect in the posterolateral diaphragm, the foramen of Bochdalek, through which the abdominal viscera migrate into the chest during fetal life. The reported incidence of CDH varies from 1 in 2200 to 1 in 5000 births. Polyhydramnios is present in 20% of pregnancies involving an infant with CDH and in 50% of pregnancies associated with infants with CDH who are stillborn. In most series, 80% of posterolateral diaphragmatic hernias have been reported to occur on the left side and 20% on the right side. Bilateral CDH are rare. The size of the defect varies from small (2 or 3 cm) to very large, involving most of the hemidiaphragm. A rim of muscle is usually present around the defect which is often covered posteromedially with peritoneum. A hernial sac, composed of pleura and peritoneum, has been reported in about 20% of patients.

Widespread use of obstetric sonography has led to an increase in the frequency of antenatal diagnosis of CDH, which is established by demonstration of the abdominal viscera in the chest. Three easily detectable features – polyhydramnios, mediastinal shift and the absence of an intra-abdominal stomach bubble – should prompt a more careful search for herniated abdominal organs in the chest. Polyhydramnios is present in about 80% of the pregnancies with fetuses who have CDH and has also been associated with poor outcome.

Postnatally, the most severely affected babies present with respiratory distress (cyanosis, tachypnoea and sternal recession) at birth. Other infants develop cyanosis, tachypnoea and grunting respirations within minutes or hours after birth. Physical examination reveals a scaphoid abdomen, an increased anteroposterior diameter of the thorax and mediastinal shift. Breath sounds are absent on the affected side. Associated congenital anomalies may also be seen or revealed on further examination. CDH presents beyond the first hours of life in 10–20% cases.

Diagnosis of CDH is made postnatally by plain radiography of the chest and abdomen by demonstration of air-filled loops of the bowel in the chest and a paucity of gas in the abdomen. The diaphragmatic margin is absent, there is a mediastinal shift to the opposite side and only a small portion of the lung may be seen on the ipsilateral side.

The mortality rate of infants born with CDH remains high, despite optimal perinatal care. The high mortality rate in CDH has been attributed to pulmonary hypoplasia and associated persistent pulmonary hypertension. In recent years, newer management strategies such as permissive hypercapnia, high frequency ventilation, extracorporeal membrane oxygenation and delayed surgical repair have emerged in the care of high-risk CDH patients, which offer some hope of improving overall survival.

Congenital Eventration of the Diaphragm

Eventration of the diaphragm has been described as an abnormally high or deviated position of all or part of the hemidiaphragm. Eventration may be congenital or acquired as a result of phrenic nerve palsy. Congenital eventration is a developmental abnormality which results in muscular aplasia of the diaphragm. In acquired eventration, the diaphragm, which initially had fully developed musculature, becomes atrophic secondary to phrenic nerve damage and disuse. Although this section deals with congenital eventration, the clinical features and principles of management are similar in congenital and acquired forms of eventration.

Clinical features range from being asymptomatic to severe respiratory distress. Patients may present later in infancy with repeated attacks of pneumonia, bronchitis or bronchiectasis. Occasionally, patients present later in childhood with gastrointestinal symptoms of vomiting or epigastric discomfort. In patients with phrenic nerve palsy, there may be a history of difficult delivery. They may present with tachypnoea, respiratory distress or cyanosis. Physical

examination reveals decreased breath sounds on the affected side, mediastinal shift during inspiration and a scaphoid abdomen.

The diagnosis of eventration is usually made on a chest X-ray. Frontal and lateral chest X-rays will show an elevated diaphragm with a smooth, unbroken outline. Fluoroscopy is a useful investigation for differentiating a complete eventration from a hernia. Paradoxical movement of the diaphragm is seen if complete eventration is present. Ultrasonography is the most useful study in the diagnosis of eventration of the diaphragm and for identification of abdominal organs underneath the eventration. Other investigation modalities include pneumoperitonography, contrast peritonography, radioisotope scanning and computed tomography scans but these are rarely required.

Symptomatic patients, especially those with respiratory distress, need prompt supportive care with endotracheal intubation and ventilation with humidified oxygen to minimize the diaphragmatic excursions. A nasogastric tube is passed to decompress the stomach and intravenous fluids are commenced. Surgery is undertaken once the patient's condition is stabilized.

Figure 13.1

General anaesthesia with muscle relaxation is used. The baby is positioned supine on a warm blanket. The most commonly preferred approach is abdominal. This offers good exposure, easy reduction of the abdominal viscera and recognition and correction of associated gastrointestinal anomalies. A subcostal transverse muscle cutting incision is made on the side of the hernia.

Figure 13.2

The contents of the hernia are gently reduced in the abdomen. On the right side, the small intestine and colon are first reduced and the liver is withdrawn last. After the hernia is reduced, an attempt is made to visualize the ipsilateral lung. This is usually done by retracting the anterior rim of the diaphragm. Often, a hypoplastic lung can be observed at the apex.

A hernial sac, composed of pleura and peritoneum, is present in about 20% of patients. The sac, if present, is excised to avoid leaving a loculated space-occupying lesion in the chest.

Figure 13.1

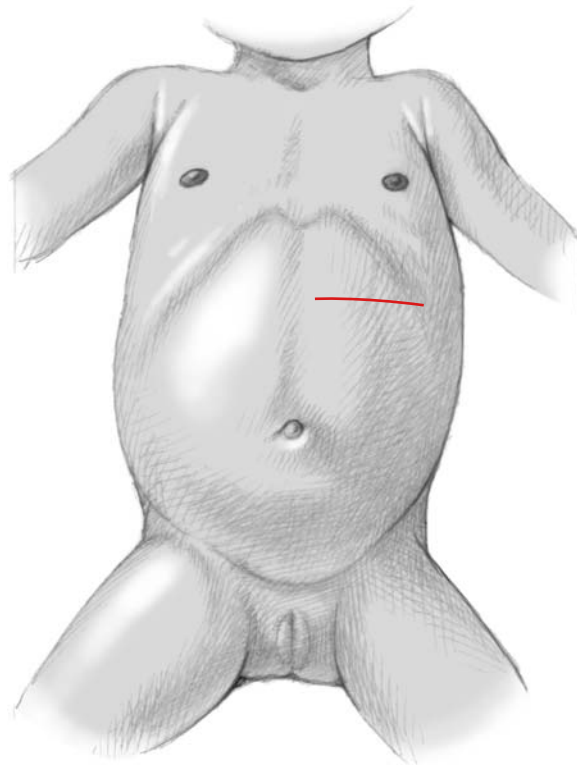


Figure 13.2

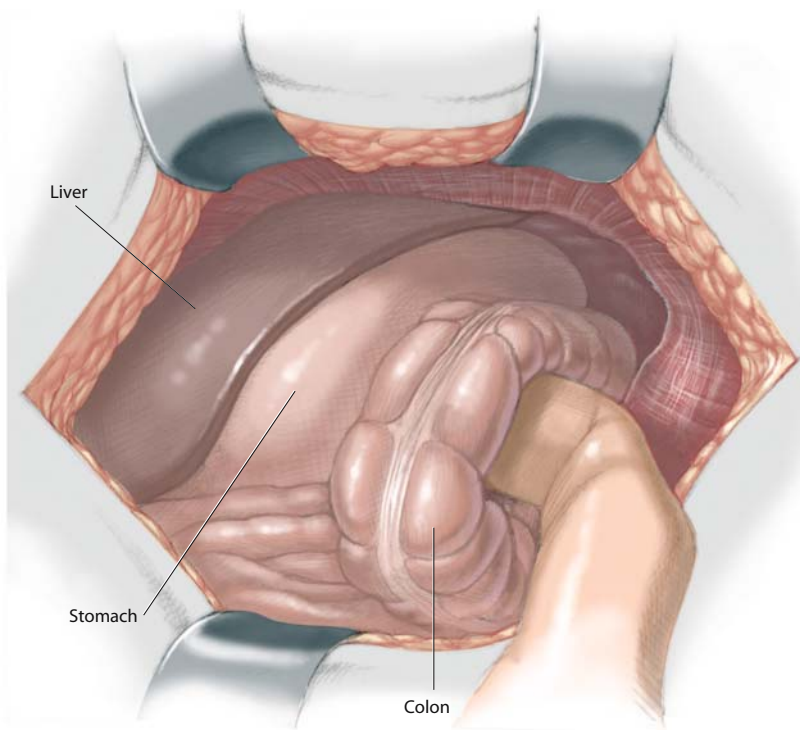


Figure 13.3

Most diaphragmatic defects can be sutured by direct sutures of the edges of the defect. Usually the anterior rim of the diaphragm is quite evident. However, the posterior rim may not be immediately apparent

and may require dissection for delineation. The posterior rim of the diaphragm is mobilized by incising the overlying peritoneum.

Figure 13.4, 13.5

The defect is closed by interrupted non-absorbable sutures. Occasionally, the posterior rim is absent altogether, in which case the anterior rim of the dia-

phragm is sutured to the lower ribs with either periostial or pericostal sutures.

Figure 13.3

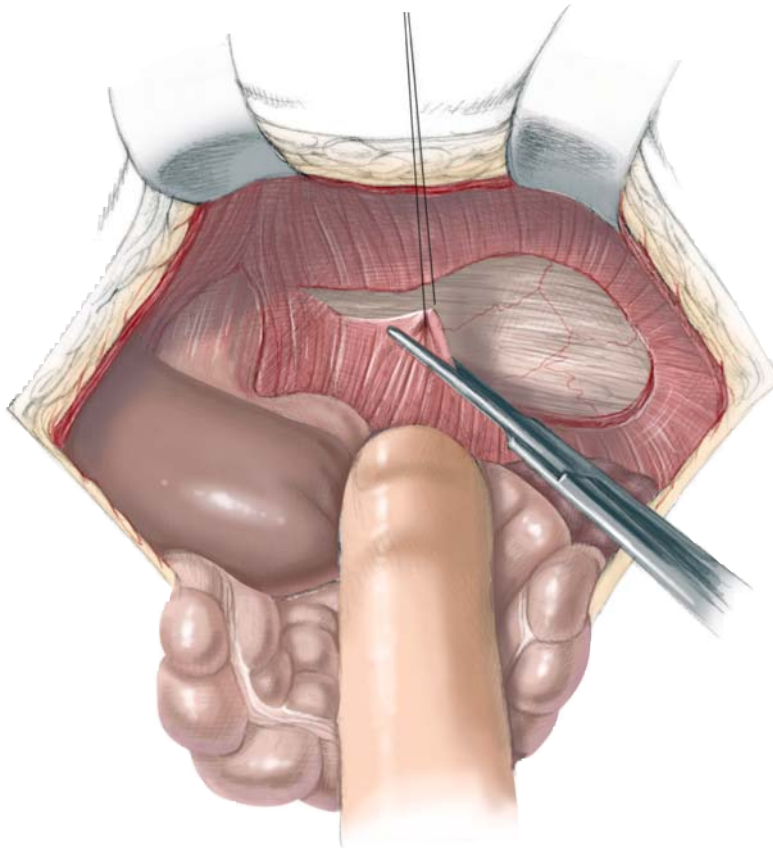


Figure 13.4

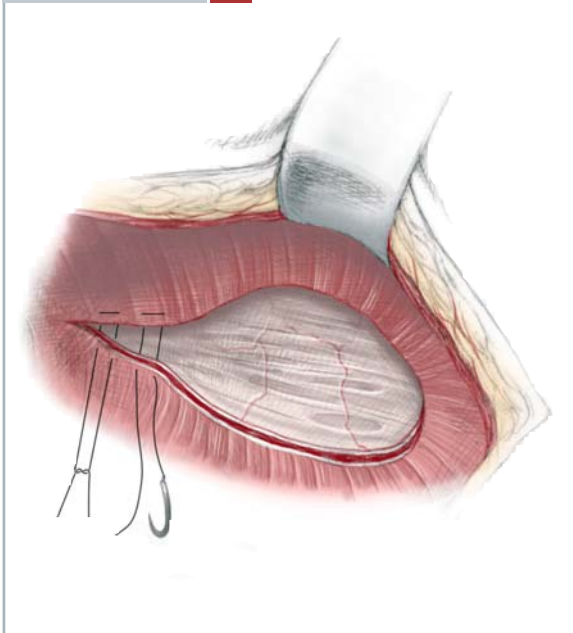


Figure 13.5

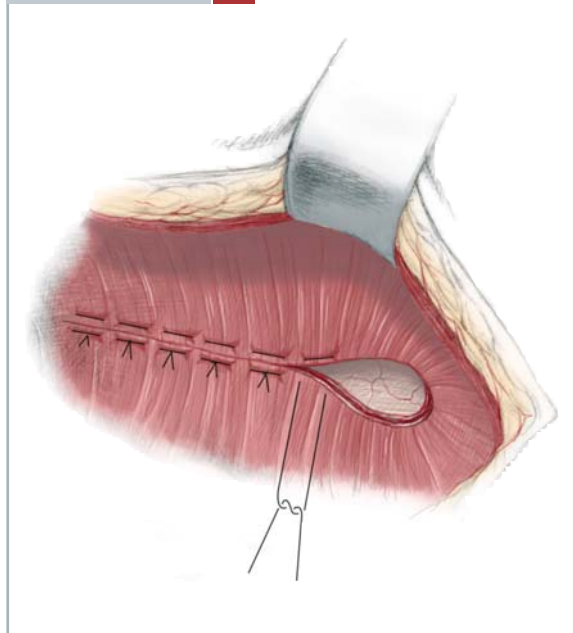


Figure 13.6

If the defect is large, it may not be possible to repair it by direct suture. Various techniques have been described and include the use of prerenal fascia, rib structures, the latissimus dorsi muscle, rotational muscle flaps from the thoraco-abdominal wall and prosthetic patches. The operations involving muscle flaps are too long and complex for critically ill patients and can lead to unsightly chest deformities. Prosthetic materials, including Marlex mesh, reinforced silicone elastomer, preserved pericardial heterografts, preserved dura and the polytetrafluoroethylene patch (PTFE), have been advocated. The most

commonly used prosthetic material presently is Surgisis soft tissue graft, which is incorporated into adjacent tissue, and this tends to lessen the risk, extension or displacement, with a decreased risk of infection.

Abdomen is closed in layers. If the abdominal cavity is small, gentle stretching of the abdominal wall will enable safe closure in most of the patients. Chest drain should be avoided. The argument against the use of a chest drain is in avoidance of barotraumas as it increases the transpulmonary pressure gradient.

Figure 13.7

Plication of the diaphragm has been used for many years to treat eventration. Plication increases both tidal volume and maximal breathing capacity and has been successful in many clinical series. An abdominal approach through a subcostal incision is preferred for left-sided eventration but a thoracic ap-

proach through a posterolateral incision via the sixth space may be used for right-sided lesions. The trans-abdominal approach allows good visualization of the entire diaphragm from front to back and easier mobilization of abdominal contents.

Figure 13.6

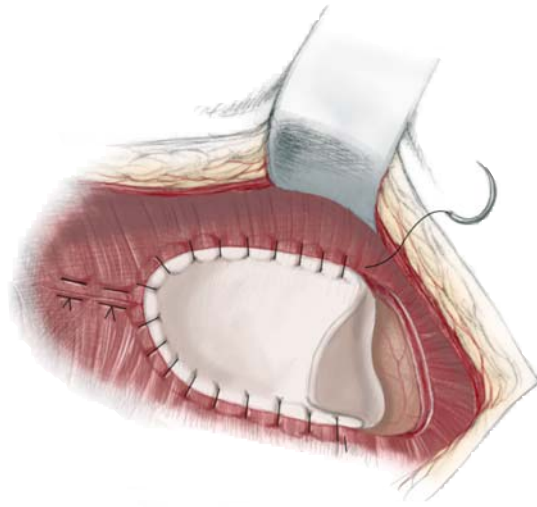


Figure 13.7

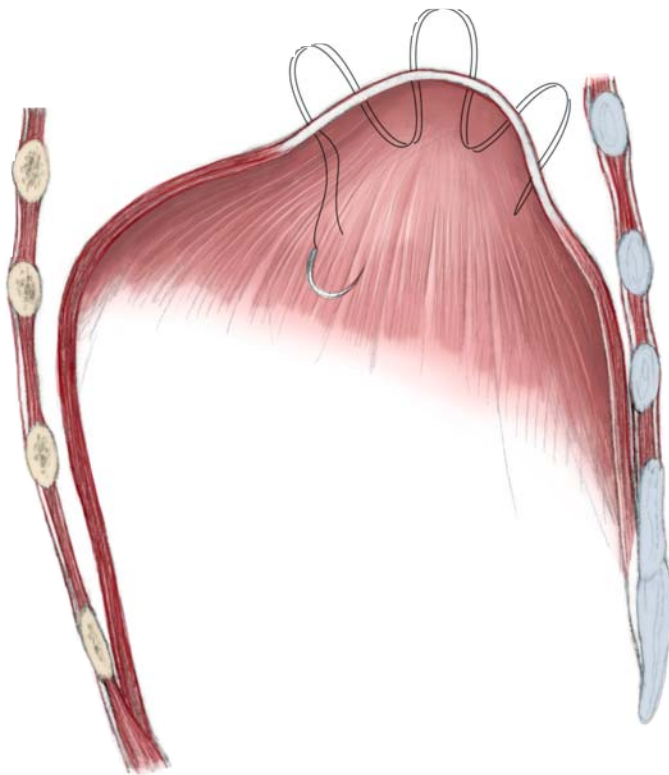


Figure 13.8, 13.9

Plication of the diaphragm is carried out using non-absorbable sutures and avoiding injury to the phrenic nerve. In cases of complete eventration, the diaphragm may be strengthened by a muscle flap or prosthetic patch.

Figure 13.8

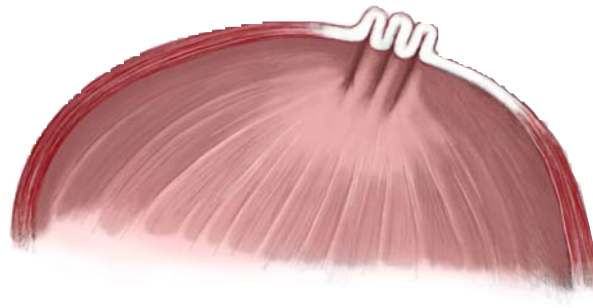
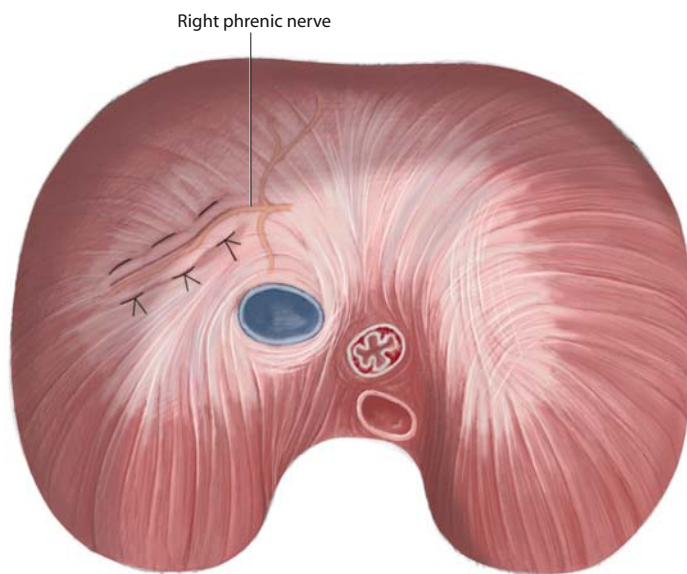


Figure 13.9



CONCLUSION

After transfer to the intensive care unit, the infant is kept warm, given maintenance requirements of intravenous fluids and has vital signs monitored closely with regular blood gas analyses and monitoring of preductal and postductal oxygenation. Ventilatory support is continued postoperatively with the aim of maintaining preductal PO_2 around 80–100 mmHg, PCO_2 up to 60 mmHg, and pH greater than 7.25 with hyperventilation (rates up to 150 per min) and the

lowest possible pressures and low tidal volumes. The intrathoracic air pocket will usually reabsorb but evidence of increasing air and fluid with mediastinal shift requires insertion of a chest drain. Weaning from ventilation should be meticulous and slow as small variations in pH, PO_2 and PCO_2 will lead to persistent pulmonary hypertension. Weaning should commence with lowering of FiO_2 , then peak pressures and finally respiratory rate.

SELECTED BIBLIOGRAPHY

- Bohn D (2002) Congenital diaphragmatic hernia. *Am J Respir Crit Care Med* 166:911–915
- Downard CD, Jaksic T, Garza JJ et al (2003) Analysis of an improved survival rate for congenital diaphragmatic hernia. *J Pediatr Surg* 38:729–732
- Granrholm T, Albanese CT, Harrison MR (2003) Congenital diaphragmatic hernia. In: Puri P (ed) *Newborn surgery*. Arnold, London, pp 309–314
- Puri P (1994) Congenital diaphragmatic hernia. In: Freeman NV, Burge DM, Griffiths DM, Malone PSJ (eds) *Surgery of the newborn*. Churchill Livingstone, London, pp 331–325
- Sydorak RM, Harrison MR (2003) Congenital diaphragmatic hernia: advances in prenatal therapy. *Clin Perinatol* 30:465–479

Extracorporeal Membrane Oxygenation

Jason S. Frischer, Charles J.H. Stolar

INTRODUCTION

Extracorporeal membrane oxygenation (ECMO) is a life-saving technology that affords partial heart/lung bypass for extended periods. ECMO is a supportive rather than a therapeutic modality as it provides sufficient gas exchange and perfusion in patients with acute, reversible cardiac or respiratory failure. It provides a finite period to “rest” the cardiopulmonary systems at which time they are spared insults from traumatic mechanical ventilation and perfusion impairment. ECMO was first implemented in newborns in 1974. Since then, the Extracorporeal Life Support Organization (ELSO) has recorded approximately 24,000 neonatal and paediatric patients treated with ECMO for a wide range of cardiorespiratory disorders. In the neonatal period the most common disorders treated with ECMO are meconium aspiration syndrome (MAS), congenital diaphragmatic hernia (CDH), sepsis, persistent pulmonary hypertension of the neonate (PPHN), and cardiac support. For the paediatric population, viral and bacterial pneumonia, acute respiratory failure (non-ARDS), acute respiratory distress syndrome (ARDS), and cardiac disease are the most common pathophysiologic processes requiring ECMO intervention.

Candidates for ECMO are expected to have a reversible cardiopulmonary disease process, with a predictive mortality greater than 80–90%, and exhaustion of ventilatory and pharmaceutical therapies. Obviously, these criteria are subjective and vary between institutions. Subjective criteria for mortality risk in neonatal respiratory failure have been suggested to identify infants with a >80% mortality. These include (a) the oxygenation index (OI), calculated as $\text{FiO}_2 \text{ mean airway pressure } 100/\text{PaO}_2$ ($\text{OI} > 40$ equates with 80% mortality), and (b) an alveolar-arterial oxygen gradient (A-aDO_2) > 625 mmHg for more than 4 h, or an $\text{A-aDO}_2 > 600$ mmHg for more

than 12 h. Older infants and children do not have as well defined criteria for high mortality risk. The combination of a ventilation index (respiratory rate PaCO_2 peak inspiratory pressure/1000) greater than 40 and an $\text{OI} > 40$ correlates with a 77% mortality, whereas a mortality of 81% is associated with an $\text{A-aDO}_2 > 580$ mmHg and a peak inspiratory pressure of 40 cmH_2O . Indications for support in patients with cardiac pathology are based on clinical signs such as hypotension despite the administration of inotropes or volume resuscitation, oliguria (urine output < 0.5 cc/kg per h), and decreased peripheral perfusion.

In addition, the gestational age should be at least 34–35 weeks due to the increased risk for intracranial haemorrhage (ICH), and the birth weight at least 2 kg secondary to cannula size limitations. The length of mechanical ventilation, and its associated toxicity from prolonged exposure to high concentration oxygen and positive pressure ventilation, prior to ECMO should be no longer than 10–14 days due to the development of bronchopulmonary dysplasia. Babies with lethal congenital anomalies should not be considered for ECMO support. Treatable conditions such as total anomalous pulmonary venous return and transposition of the great vessels, which may masquerade initially as pulmonary failure can be corrected with surgery, but may require ECMO resuscitation initially. Therefore, echocardiogram should be rapidly obtained to determine cardiac anatomy. There should be no evidence of significant neurologic injury such as seizures. Suggestion of a small ICH (grades I–II) should be considered on an individual basis and monitored very closely for worsening bleeding. In fact, all patients with gross active bleeding or major coagulopathy should be corrected prior to initiating ECMO.

Figure 14.1a–c

The goal of ECMO support is to provide gas exchange and oxygen delivery. Three different extracorporeal configurations; venoarterial (VA), venovenous (VV), and double-lumen single cannula venovenous (DLVV) bypass are available. VA bypass allows for support of both the pulmonary and cardiac systems. Venous blood is drained from the right atrium (RA) through the internal jugular vein (IJ), and oxygenated blood is returned via the carotid artery (CA) to the aorta. Potential disadvantages of this arrangement include the sacrifice of a major artery, risk of gaseous or particulate emboli into systemic circulation, reduced pulmonary perfusion, decreased preload and increased afterload, which may reduce cardiac output, non-pulsatile flow, and the coronaries are perfused by left ventricular blood which is relatively hypoxic and is compensated by arterialized re-

turn. VV and DLVV avoid these disadvantages and provide pulmonary support but do not assist with circulation. VV bypass is accomplished with drainage from the RA via the IJ with reinfusion into the femoral vein. DLVV is carried out by means of the IJ. A major disadvantage of VV and DLVV ECMO is that a fraction of freshly infused blood recirculates back into the circuit and requires approximately a 20% increase in flow rate. A limitation in DLVV catheter size confines use of this method of support since it cannot accommodate very small infants or larger patients. In summary, it is recommended that patients who require only respiratory support use VV or DLVV bypass and those that necessitate cardiac support use VA ECMO and, if necessary, one can convert VV or DLVV to a VA circuit.

Figure 14.1a-c

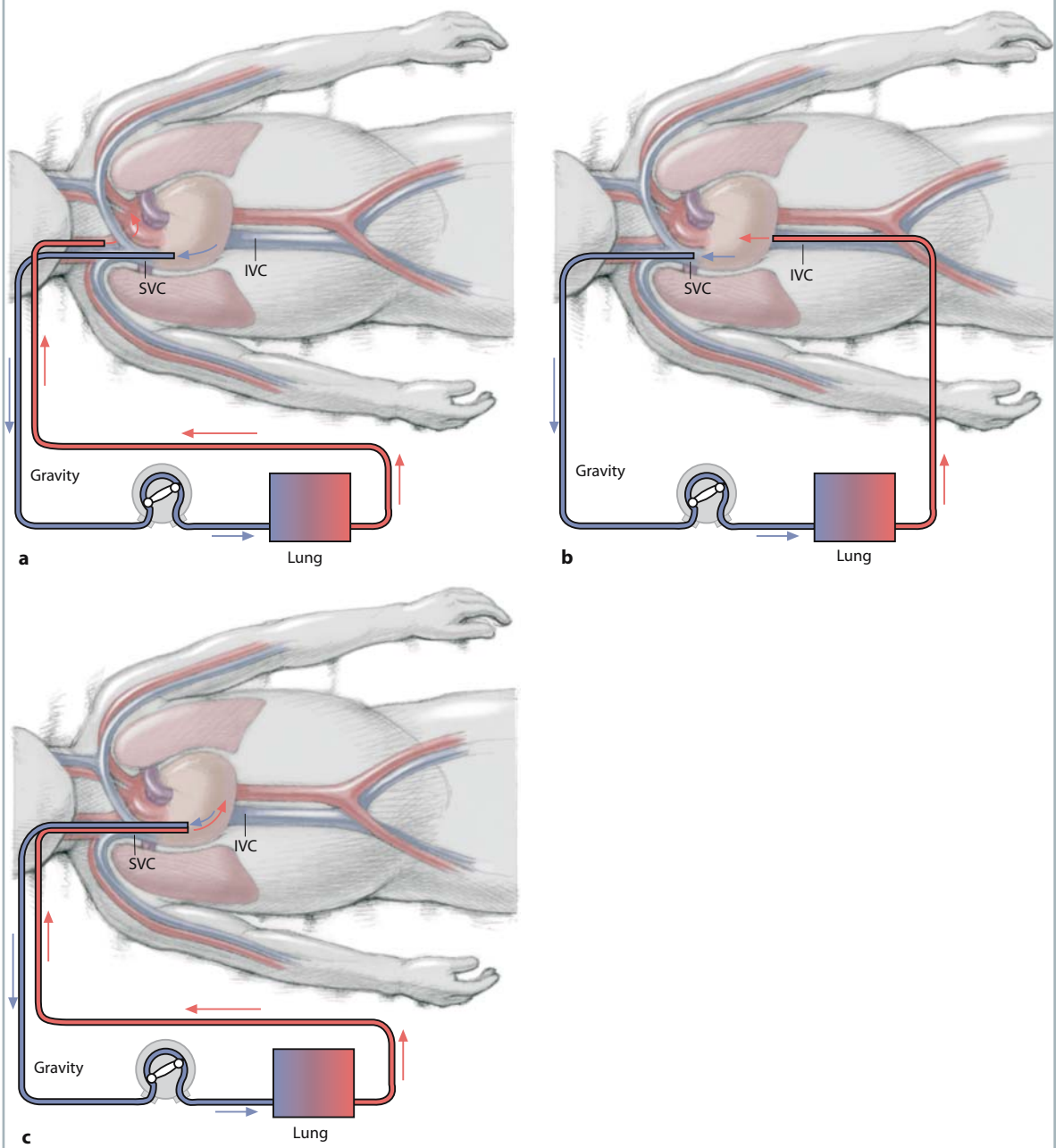


Figure 14.2

The circuit is comprised of three main components; a roller pump, a membrane oxygenator, and a heat exchanger. Right atrial blood is drained by gravity siphon into a venous servo-mechanism, which acts as a safety valve. The servo detects diminished venous return, slows or shuts off the pump and sounds an alarm, hence stopping blood flow and relieving the risk of introducing air into the circuit and a cavitation. Next, a roller pump, with continuous servoregulation and pressure monitoring, perfuses the blood through the membrane oxygenator. The oxygenator

is a two-compartment chamber composed of a spiral wound silicone membrane and a polycarbonate core, with blood flow in one direction and oxygen flow in the opposite direction. The size of the oxygenator is chosen based on the patient's size. The oxygenated blood flows through a heat exchanger and is then returned to the patient. A bridge is constructed to connect the venous line shortly after exiting the patient and the arterial line just prior to entering the patient so that during weaning the patient and the circuit can easily form two separate circuits.

Figure 14.2

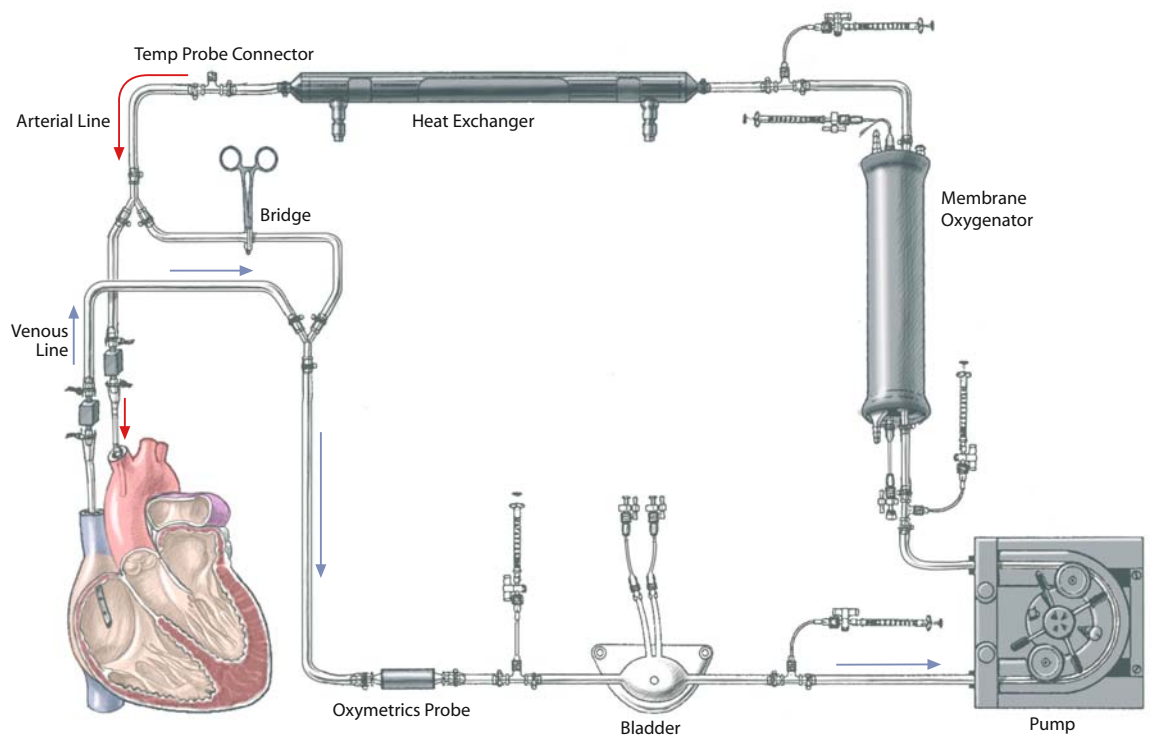


Figure 14.3, 14.4

Cannulation can be performed in the neonatal or paediatric intensive care units under adequate sedation, with proper monitoring. The patient is positioned with the head at the foot of the bed, supine, and the head and neck hyperextended over a shoulder roll and turned to the left. Local anaesthesia is administered over the proposed incision site. A transverse cervical incision is made along the anterior border of the sternomastoid muscle, one finger's breadth above the right clavicle. The platysma muscle is divided with electrocautery. Self-retaining retractors are placed and dissection is carried out with

the sternomastoid muscle retracted to expose the carotid sheath. Using sharp dissection and meticulous haemostasis, the sheath is opened and the internal jugular vein, common carotid artery, and vagus nerve are identified. All vessels must be handled with extreme care as to avoid spasm. The vein is dissected free first and mobilized over proximal and distal ligatures. Occasionally it is necessary to ligate the inferior thyroid vein. The common carotid artery lies medial and posterior, contains no branches, and is mobilized in a similar fashion. The vagus nerve should be identified and protected from injury.

Figure 14.3

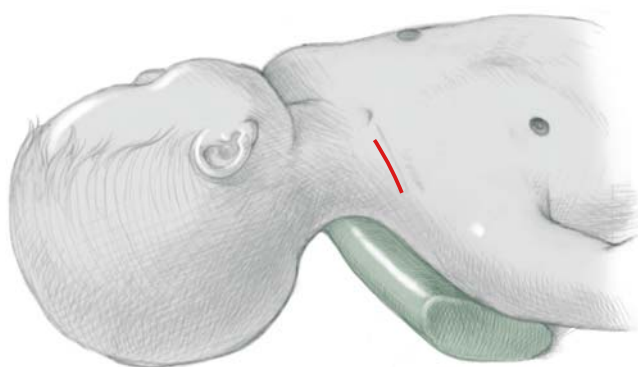


Figure 14.4

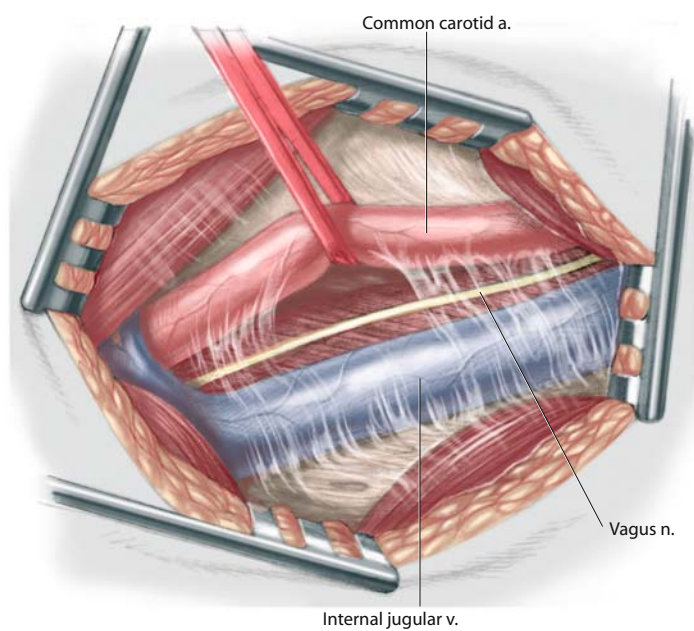


Figure 14.5

The patient is then systemically heparinized with 50–100 U/kg heparin, which is allowed to circulate for 3 min so that an activating clotting time (ACT) of >300 s is attained. The arterial cannula (usually 10F for newborns) is measured so that the tip will lie at the junction of the brachiocephalic artery and the aorta (2.5–3 cm, one-third the distance between the sternal notch and the xiphoid). The venous cannula (12–14F for neonates) is measured to have its tip in the distal RA (6–8 cm, one-half the distance between the suprasternal notch and the xiphoid process). For VA bypass, the carotid artery is ligated cranially. Proximal control is obtained with an angled clamp,

and a transverse arteriotomy is made near the ligature. Stay sutures, using 5/0 or 6/0 prolene, are placed through the full thickness of the medial, lateral, and proximal edges of the arteriotomy. To help prevent subintimal dissection, the sutures are gently retracted and the clamp slowly released as the arterial catheter is inserted into the carotid artery to its proper position. The cannula is then fastened into place with two silk ligatures (2/0 or 3/0), with a small piece of vessel loop, on the anterior aspect, inside the ligatures to protect the vessel from injury during decannulation.

Figure 14.6, 14.7

In preparation for the venous cannulation, the patient is given succinylcholine to prevent spontaneous respiration. The vein is then ligated cranially. Gentle traction is placed on the lower ligature to help decrease back bleeding, and a venotomy is made close to the proximal ligation. The drainage catheter is passed to the level of the RA and secured in a manner similar to that used for the arterial catheter. The cannulas are then debubbled with back bleeding and heparinized saline. Then they are connected to the ECMO circuit and bypass is initiated. Both cannulas are then secured to the mastoid process using monofilament. The wound is irrigated, meticulous haemostasis obtained, and closed in layers with a running nylon for skin closure. The site is covered with a sterile dressing and the cannulas are fixed securely to the bed.

For VV and DLVV bypass the procedure is exactly as described above including dissection of the artery, which is marked with a vessel loop, so that a future switch from VV to VA ECMO can be accomplished, if necessary, with as little complication as possible. The catheter tip should be in the mid-right atrium (5 cm in the neonate) with the arterial portion of the catheter pointed toward the ear. This directs the oxygenated blood flow towards the tricuspid valve.

Cannula position is confirmed by chest X-ray and transthoracic echocardiogram. The venous catheter should be located in the inferior aspect of the right atrium, and the arterial catheter at the ostium of the innominate artery and the aorta. With a double-lumen venous catheter, the tip should be in the mid-right atrium with return oxygenated blood flow towards the tricuspid valve.

Figure 14.5

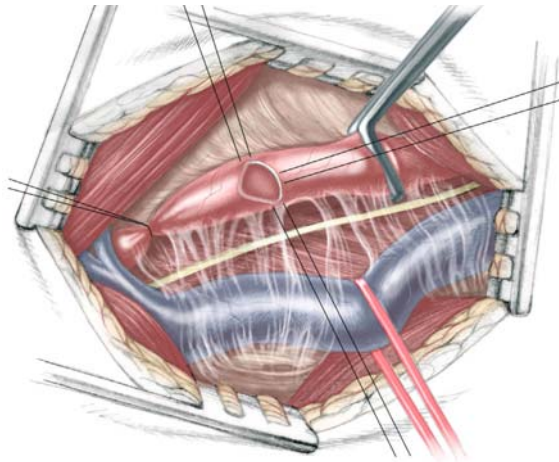


Figure 14.6

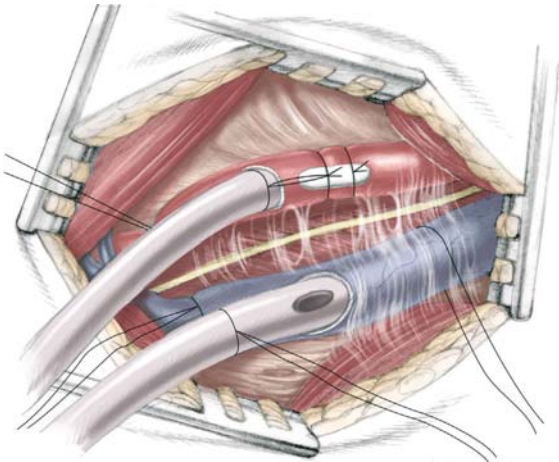
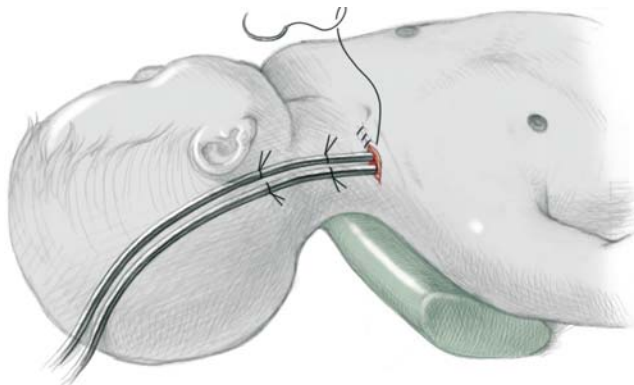


Figure 14.7



PATIENT MANAGEMENT IN ECMO

Once the cannulas are connected to the circuit, bypass is initiated and flow is slowly increased to 100–150 ml/kg per min so that the patient is stabilized. Continuous inline monitoring of the venous (prepump) SvO_2 and arterial (postpump) PaO_2 as well as pulse oximetry is vital. The goal of VA ECMO is to maintain a mixed venous PO_2 (SvO_2) of 37–40 mmHg and saturation of 65–70%. VV ECMO is more difficult to monitor due to recirculation, which may produce a falsely elevated SvO_2 . Inadequate oxygenation and perfusion are indicated by metabolic acidosis, oliguria, hypotension, elevated liver function tests, and seizures. Arterial blood gasses should be monitored hourly with PaO_2 and $PaCO_2$ maintained at as close to normal level as possible. As soon as these parameters are met, all vasoactive drugs are weaned, and ventilator levels are adjusted to “rest” settings. Gastrointestinal prophylaxis is initiated and mild sedation and analgesia is provided usually with fentanyl and midazolam, but the use of a paralyzing agent is avoided. Ampicillin and either gentamicin or cefotaxime are administered for prophylaxis. Routine blood, urine, and tracheal cultures should be taken.

Heparin is administered (30–60 mg/kg per h) throughout the ECMO course in order to preserve a circuit free of thrombus. ACTs should be monitored hourly and maintained at 180–220 s. A complete blood count should be obtained every 6 h and coagulation profiles daily. In order to prevent a coagulopathy, platelets are transfused to maintain a platelet count above 100,000/mm³ and some authors sustain fibrinogen levels above 150 mg/dl. The haematocrit should remain above 40% using red blood cell transfusions so that oxygen delivery is maximized.

Volume management of patients on ECMO is extremely important and very difficult. It is imperative that all inputs and outputs be diligently recorded and electrolytes monitored every 6 h. All fluid losses should be replaced and electrolyte abnormalities corrected. All patients should receive maintenance fluids as well as adequate nutrition using hyperalimentation. The first 48 to 72 h of ECMO typically involve

fluid extravasation into the soft tissues. The patient becomes oedematous and may require volume replacement (crystalloid, colloid, or blood products) in order to maintain adequate intravascular and bypass flows, haemodynamics, and urine output greater than 1 cc/kg per h. By the third day of bypass, diuresis of the excess extracellular fluid begins, and can be facilitated with the use of furosemide if necessary.

Surgical procedures, such as CDH repair, may be performed while the child remains on bypass. Haemorrhagic complications are a frequent morbidity associated with this situation, and increases mortality. To avoid these complications, prior to the procedure the platelet count should be greater than 150,000/mm³, a fibrinogen level above 150 mg/dl, an ACT reduced to 180–200 s, ECMO flow increased to full support, and it is imperative meticulous haemostasis be obtained throughout the surgery. Fibrinolysis inhibitor aminocaproic acid (100 mg/kg) just prior to incision followed by a continuous infusion (30 mg/kg per h) until all evidence of bleeding ceases is a useful adjunct.

As the patient improves, the flow of the circuit may be weaned at a rate of 10–20 ml/h as long as the patient maintains good oxygenation and perfusion. Flows should be decreased to 30–50 ml/kg per min and the ACT should be at a higher level (200–220 s) to prevent thrombosis. Moderate conventional ventilator settings are used, but higher settings can be used if the patient needs to be weaned from ECMO urgently. If the child tolerates the low flow, all medications and fluids should be switched to vascular access on the patient, and the cannulas may be clamped with the circuit bypassing the patient via the bridge. The patient is then observed for 2–4 h, and if this is tolerated, then decannulation should be performed. This should be executed under sterile conditions in the Trendelenberg position with muscle relaxant on board to prevent air aspiration into the vein. The catheters are removed and the vessels are ligated. The wound should be irrigated and closed over a small drain, which is removed 24 h later.

COMPLICATIONS

Extracranial bleeding is a common complication of the heparinized ECMO patient either at the site of cannulation or at other sites. Bleeding is noted in 21% of neonatal cases, 44% of paediatric respiratory cases, and 40% of all cardiac cases. Bleeding at the site of cannulation can often be treated with local pressure or the placement of topical haemostatic agents such

as Gelfoam, Surgicel, or topical thrombin. For all sites of bleeding, the platelet count should be increased to >150,000 mm³ and the ACT lowered to 180–200 s. Sometimes the temporary discontinuation of heparin and normalization of the coagulation status is warranted to help stop the haemorrhage. Aggressive surgical intervention is warranted if bleeding persists.

Neurological sequelae are a serious morbidity of the ECMO population and include learning disorders, motor dysfunction, and cerebral palsy. These outcomes appear to be due to hypoxia and acidosis prior to the ECMO course. ICH is the most devastating complication of ECMO and occurs in 5.9% of patients and carries with it a 54% mortality. Frequent comprehensive neurologic exams should be performed and cranial ultrasounds obtained daily for the first 3 days of ECMO and then every other day. Blood pressure should be carefully monitored and maintained within normal parameters to help decrease the risk of ICH. If necessary, electroencephalograms may be helpful in the neurologic evaluation.

Acute tubular necrosis (ATN), marked by oliguria and increasing blood urea nitrogen and creatinine levels, is often seen in the ECMO patient during the initial 48 h, at which time renal function is expected to improve. If this does not occur, consideration must be towards poor tissue perfusion. This may be due to low cardiac output, insufficient intravascular volume, or inadequate pump flow, all of which should be corrected. In the event of continued renal failure, haemofiltration or haemodialysis can be attached to the circuit to maintain proper fluid balance and electrolyte levels and are reported to be required in 14% of cases.

CONCLUSION

As of January 2003, more than 19,000 neonates (74% survival) and 4,800 paediatric patients (48% survival) have been treated with ECMO. In the neonatal population, MAS is the most common indication for ECMO and carries with it a survival rate of 94%. Other frequent diagnosis (with survival rates in parentheses) include PPHN (79%), sepsis (75%), and CDH (54%). Viral pneumonia is the most common aetiology amongst the paediatric population requiring ECMO and has a 62% survival. Aspiration carries the greatest survival at 65%, whereas non-ARDS respiratory failure has a 47% survival, ARDS 55%, and bacterial pneumonia 52% survival. Cardiac patients have an overall survival of 39%. Specifically, congenital de-

fects have a 38% survival, bridge to transplant 43%, cardiomyopathy 49%, and the highest survival rate is for myocarditis, 58%.

Recent medical advances, such as permissive hypercapnea and the use of oscillatory ventilation have spared numerous babies from ECMO, yet many children still benefit from this modality. In summary, any patient with reversible cardiopulmonary disease, who meets criteria, should be considered an ECMO candidate. ECMO provides an excellent opportunity to provide "rest" to the cardiopulmonary systems and allows the patient to recover using pharmacologic and surgical therapies.

SELECTED BIBLIOGRAPHY

- Campbell BT, Braun TM, Schumacher RE et al (2003) Impact of ECMO on neonatal mortality in Michigan (1980–1999). *J Pediatr Surg* 38:290–295
- Extracorporeal Life Support Organization (2003) International Registry Report of the Extracorporeal Life Support Organization. January 2003. University of Michigan Medical Center, Ann Arbor
- Hirschl RB, Bartlett RH (1998) Extracorporeal life support in cardiopulmonary failure. In: O'Neill JA Jr, Rowe MI, Grosfeld JL, Fonkalsrud EW, Coran AG (eds) *Pediatric surgery*, 5th edn. Mosby, New York, pp 89–102
- Kim ES, Stolar CJ (2000) ECMO in the newborn. *Am J Perinatol* 17:345–356
- Kim ES, Stolar CJH (2003) Extracorporeal membrane oxygenation for neonatal respiratory failure. In: Puri P (ed) *Newborn surgery*. Arnold, London, pp 317–327

Hernias – Inguinal, Umbilical, Epigastric, Femoral and Hydrocele

Juan A. Tovar

INTRODUCTION

Inguinal hernia is one of the most common surgical conditions in infancy, with a peak incidence during the first 3 months of life. The diagnosis of inguinal hernia is made with increasing frequency in newborns; this period carried a particularly high risk of incarceration. On the other hand, the incidence of hernia is much higher in premature infants who survive in growing numbers after sophisticated intensive care management. Direct hernia is exceedingly rare at this age and practically all congenital indirect inguinal hernias develop because the processus vaginalis remains patent after birth. The most common presentation of inguinal hernia in a child is a groin bulge, extending towards the top of the scrotum. The treatment of inguinal hernia is always surgical. In infants and toddlers, herniotomy can be performed through the external inguinal orifice without any attempt at parietal reinforcement. In older children, however, the length of the canal makes it advisable to open the external oblique aponeurosis in order to achieve a high ligation of the sac. The incidence of congenital indirect inguinal hernia in full-term neonates is 3.5–5%. The incidence of inguinal hernia in preterm infants is considerably higher and ranges from 9–11%. The incidence approaches 60% as birth weight decreases from 500 to 750 g. Inguinal hernia is more common in males than in females. Most series report a male preponderance over females ranging from 5:1 to 10:1. Of all inguinal hernias, 60% occur on the right side, 25–30% on the left, and 10–15% are bilateral.

The anatomy of the inguinal canal varies slightly with age. In adults and children, the internal and external inguinal orifices are widely separated, whereas in young infants they practically overlap. In girls, the anatomy is similar except for the absence of spermatic elements which are replaced by the round ligament.

A hydrocele of the tunica vaginalis usually presents as a soft, nontender fluid filled sac that may transilluminate. Most hydroceles usually involute spontaneously during the first 12 months of life. Those that persist beyond 1 year of age are associated with a patent processus vaginalis and require operative intervention, the same as for an inguinal hernia.

Femoral hernias are rare in children. The diagnosis is based on the observation of a groin swelling located underneath the external inguinal orifice, although this location is easily missed because, unless the bulge is visible upon examination, relatives and doctors will first interpret its appearance as the expression of an inguinal hernia. This explains why 50% of these patient are mistakenly operated upon for inguinal hernia and why, only when the sac is not found, exploration of the femoral area allows diagnosis and repair. The femoral orifice, located below the inguinal ligament, allows passage of the femoral vein, artery and nerve from the pelvis to the thigh. The hernial orifice is always medial and the sac is therefore in close contact with the femoral vein.

Umbilical hernia is as a result of failure of closure of the umbilical ring. The hernial sac protrudes through the defect. Most umbilical hernias have a tendency to resolve spontaneously. In view of the favourable natural history of umbilical hernias, surgical indications are limited to those hernias located above the umbilicus, to those that persist beyond the age of 4 years and to those occurring in children with connective tissue disorders.

Epigastric hernia (fatty hernia of linea alba) usually occurs in the midline of the anterior abdominal wall. It is usually a small defect through which preperitoneal fat protrudes and may cause pain.

Figure 15.1

General anaesthesia with endotracheal intubation is preferred in small infants. Premature infants undergoing surgery have an increased risk of life-threatening post-operative apnea. The use of spinal anaesthesia in low birth-weight infants undergoing inguinal

hernia repair is associated with a lower incidence of post-operative apnea. The infant is placed in the supine position on a heating blanket. A 1.5-cm transverse inguinal skin crease incision is placed above and lateral to the pubic tubercle.

Figure 15.2, 15.3

The subcutaneous fat and the fascia of Scarpa (which is surprisingly dense in infants) are opened, grasping them with small-toothed Adson forceps. Using blunt scissors or cautery, the external oblique aponeurosis

and external ring are exposed. The external inguinal ring is not opened except in older children and adolescents.

Figure 15.1

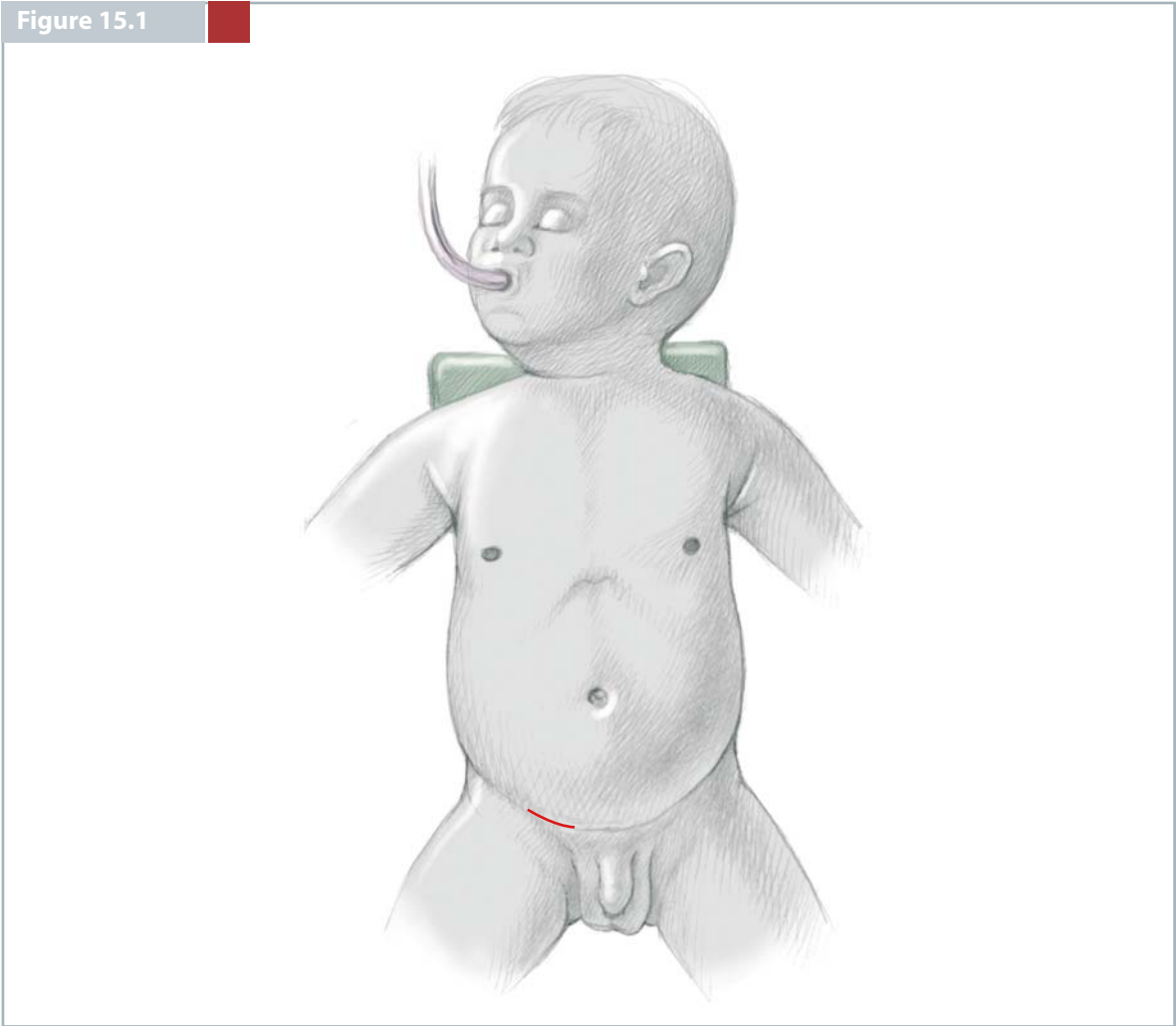


Figure 15.2

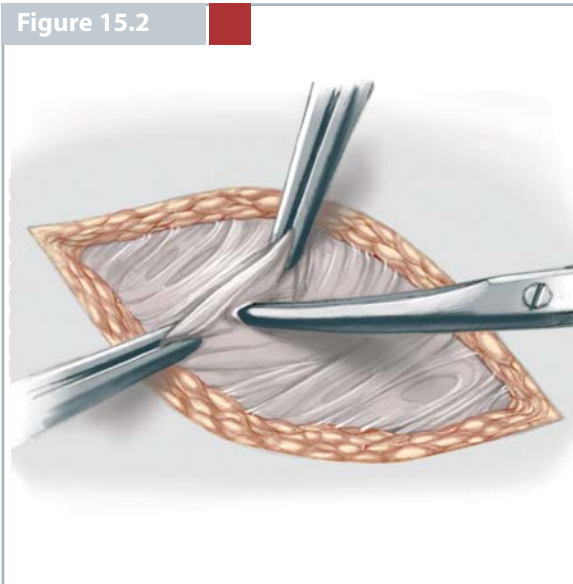


Figure 15.3

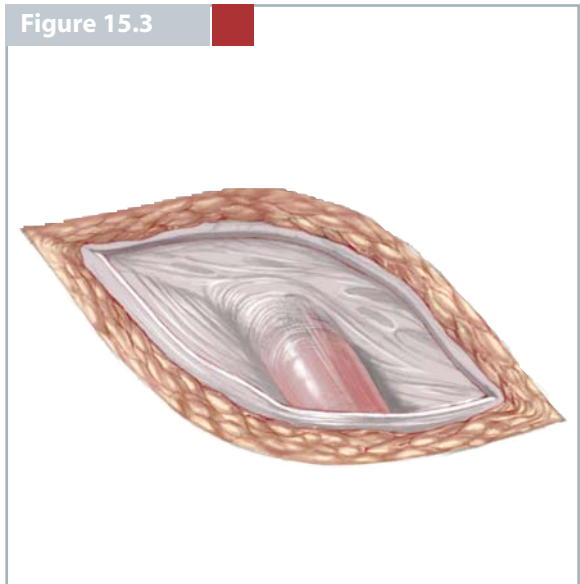


Figure 15.4

The external spermatic fascia and cremaster are separated along the length of the cord by blunt dissection. The hernial sac is seen and gently separated from the vas and vessels. A haemostat is placed on the fundus of the sac.

Figure 15.5

The sac is divided between the clamps and twisted so as to reduce its content into the abdominal cavity. The spoon can be used to keep vas and vessels away from the neck of the sac. The sac is transfixed with a 4/0 stitch at the level of internal ring, which is marked by an extraperitoneal pad of fat. The part of the sac beyond the stitch is usually excised. In the case of hydrocele, the distal part of the sac is widely slit allowing adequate drainage of fluid. In girls, the operation is even more straightforward since there is no risk for the vas or the vessels and the external orifice can be closed after excising the sac.

Figure 15.6, 15.7

Subcutaneous tissues are approximated using two or three 4/0 absorbable interrupted stitches and the skin is closed with a 5/0 absorbable continuous subcuticular suture. A small dressing can be applied over the wound if necessary. At the end of the operation, the testis, always tractioned upwards during operative manoeuvres, must be routinely pulled back into the scrotum to avoid iatrogenic ascent.

Figure 15.4

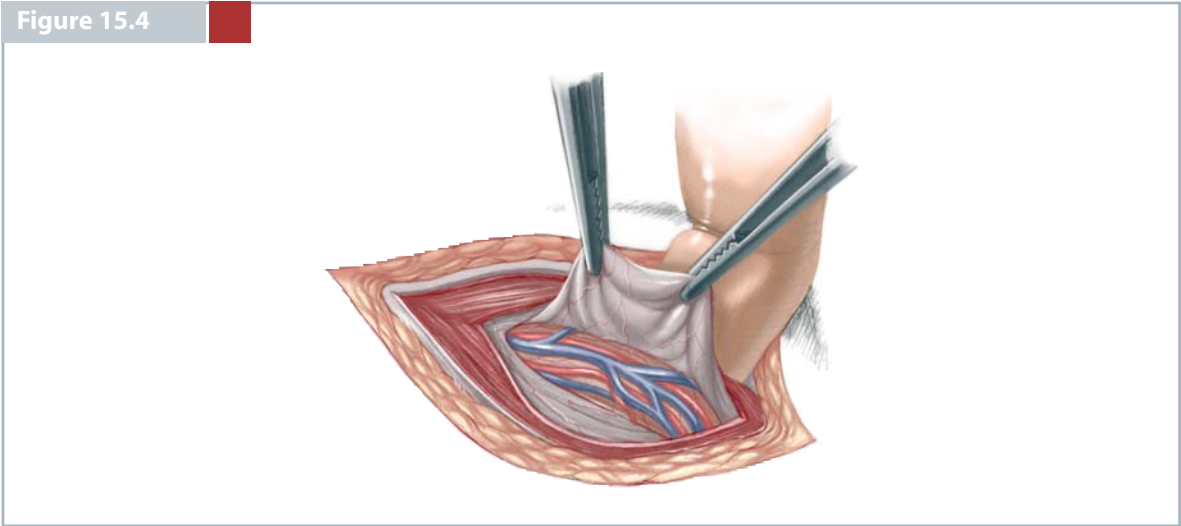


Figure 15.5

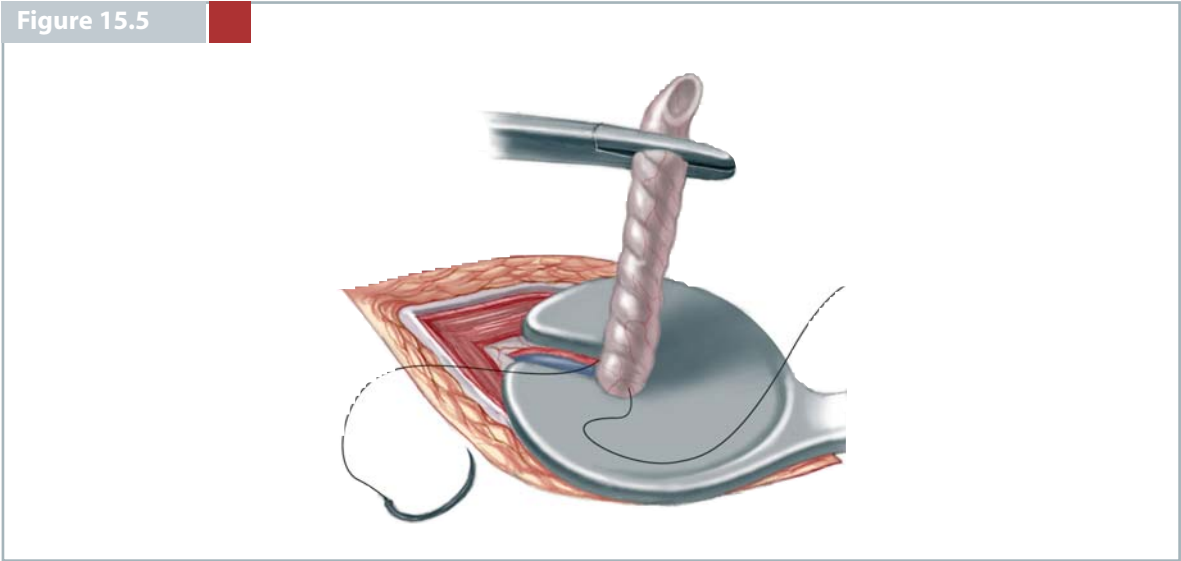


Figure 15.6

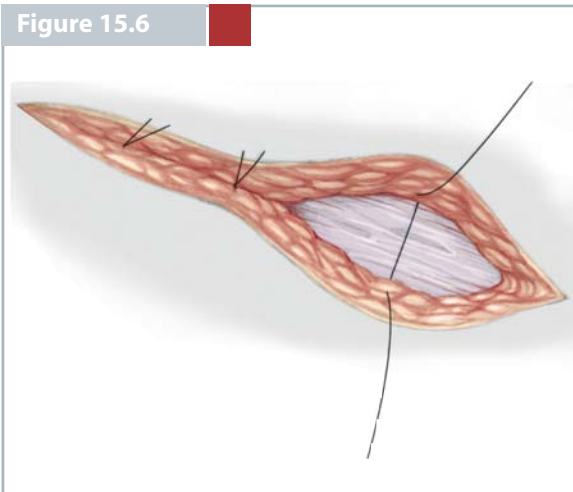


Figure 15.7

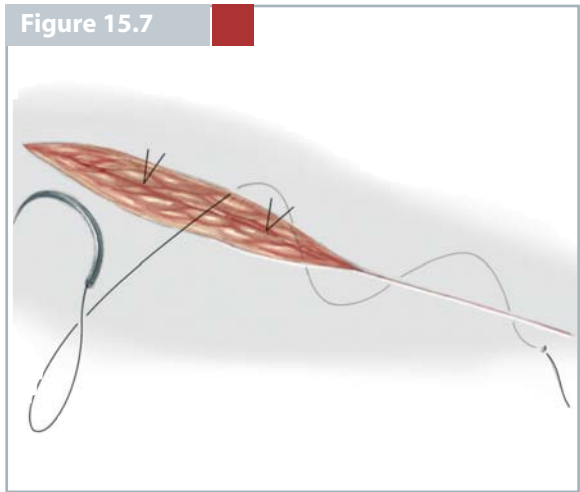


Figure 15.8 (Femoral Hernia)

The operative approach for femoral hernia is initially identical to the more commonly used approach for inguinal hernia. An inguinal skin crease incision is made and the subcutaneous layers and Scarpa's fascia are opened in order to expose the external oblique aponeurosis at the level of the external inguinal ring. The aponeurosis is incised longitudinally taking care to preserve the ilio-inguinal nerve. The inguinal canal is open dorsally sectioning with cautery the conjoined tendon and the fascia transversalis.

Figure 15.9

The spermatic cord is retracted in order to obtain access to the femoral region. The sac is identified and delivered into the wound avoiding damage to the femoral vein which is in close contact with the sac laterally. It may be convenient to ligate and divide the inferior epigastric vessels in order to better expose the femoral area from behind.

Figure 15.10

The sac is then opened to ensure that it has no contents and it is subsequently suture-ligated with a fine stitch flush with the peritoneum. The femoral defect is then narrowed by approximating the internal insertions of the Cooper ligament and the inguinal ligament with two or three fine non-absorbable stitches

taking care of not compressing the femoral vessels. The inguinal canal is reconstructed and the superficial layers and the skin are closed like those in inguinal hernias. Femoral hernia repair can also be accomplished by an infra-inguinal approach.

Figure 15.8

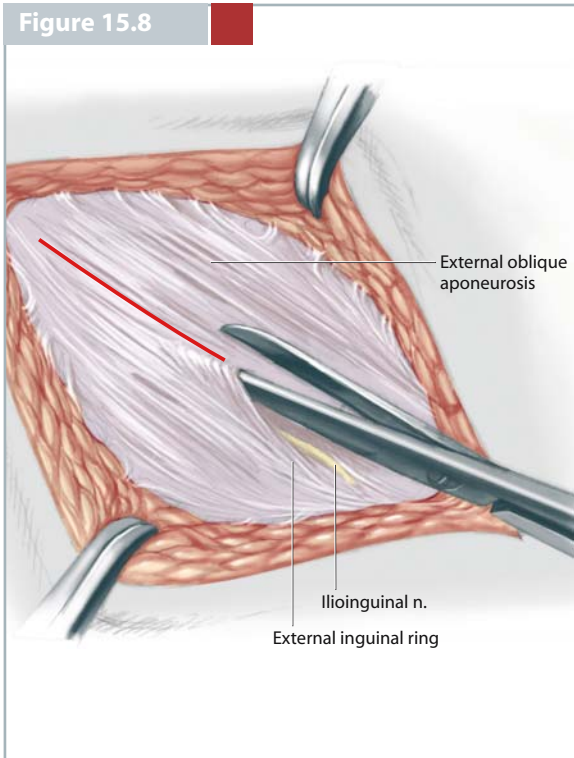


Figure 15.9

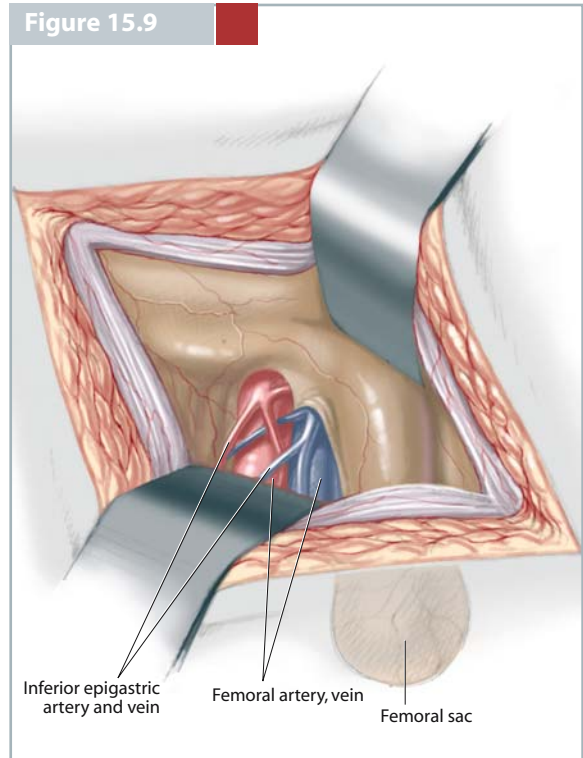


Figure 15.10

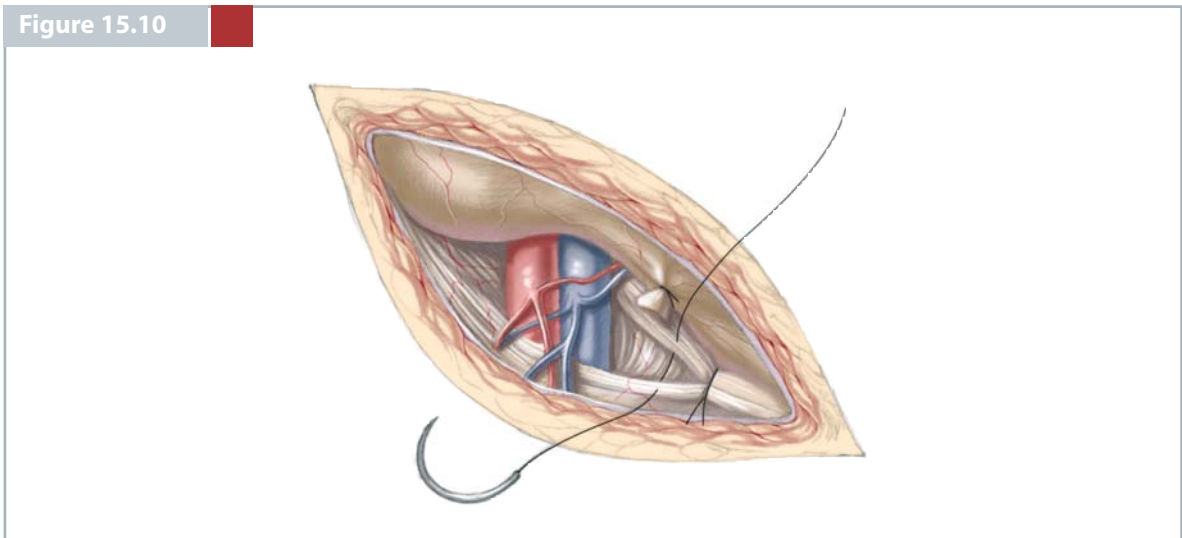


Figure 15.11, 15.12 (Umbilical Hernia)

Umbilical hernia repair is carried out under general anaesthesia. A semicircular incision is made in the skin crease immediately below the umbilicus. The subcutaneous layers are dissected in order to expose

the hernial sac. By blunt dissection with a mosquito clamp, a plane is developed on both sides of the sac and the sac is encircled with a haemostat and is divided.

Figure 15.11

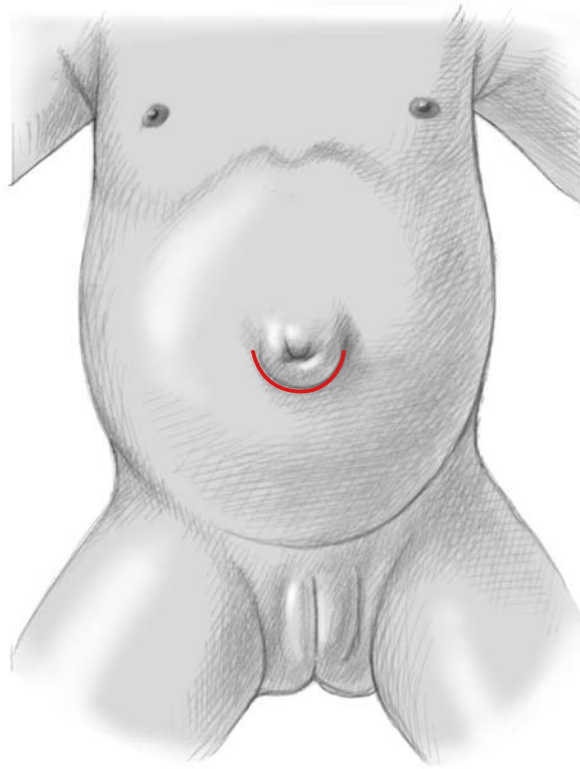


Figure 15.12

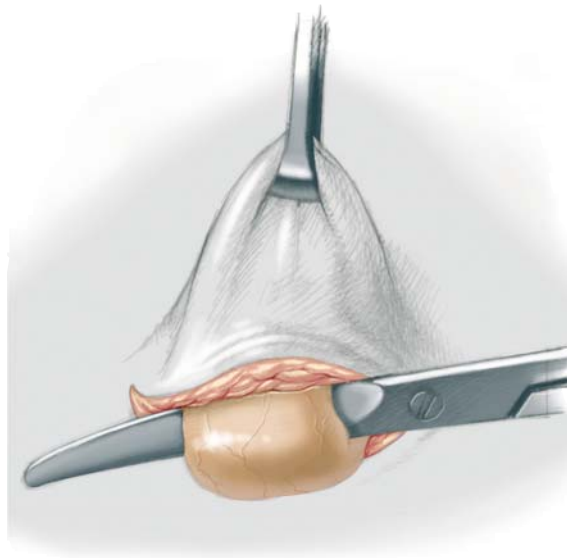


Figure 15.13–15.15

A clamp is placed on either side of the umbilical defect for traction. The defect is closed by interrupted 2/0 absorbable sutures. A stitch is used to invaginate the umbilical scar, tractioning it downwards and fix-

ing it to the subcutaneous layer in the midline. The wound is closed with several interrupted sutures placed in the subcuticular plane. A slightly compressive dressing is maintained for 24 h.

Figure 15.13

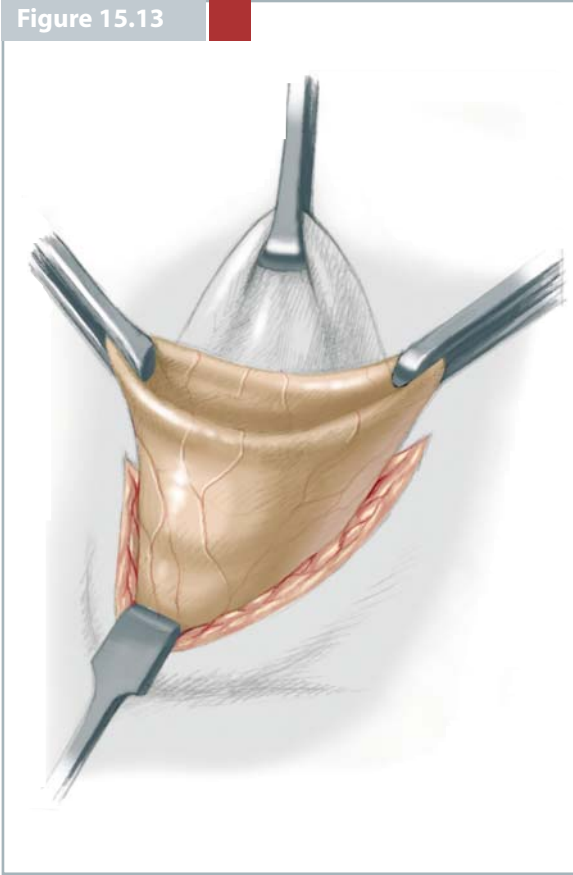


Figure 15.14

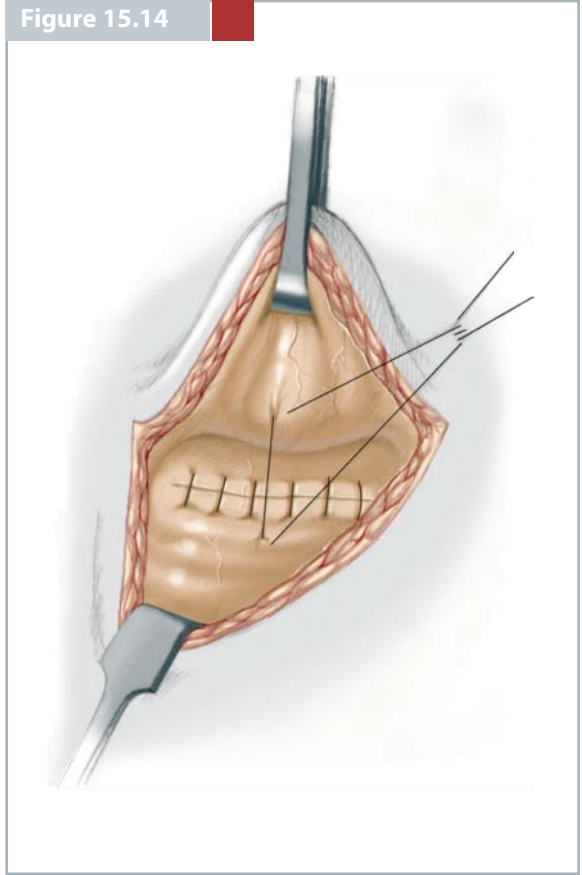


Figure 15.15

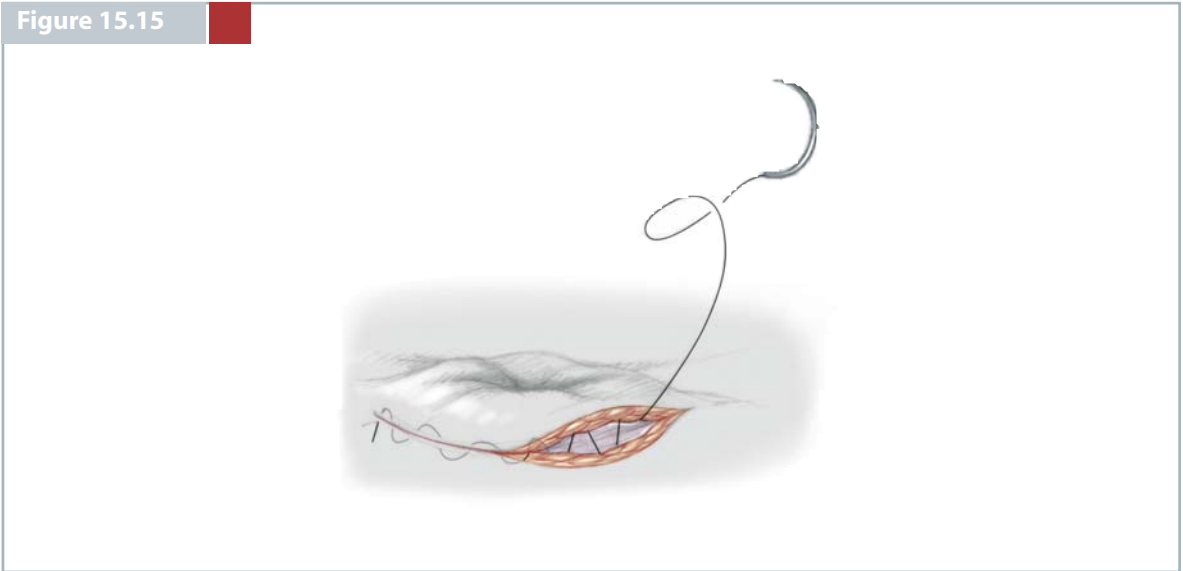


Figure 15.16–15.18 (Epigastric Hernia)

Epigastric hernias are repaired when they are prominent or when they are symptomatic. It is important to mark the location of the defect before anaesthesia, because in the recumbent position they are often impossible to palpate along the widened linea alba. A transverse incision is made directly over the previ-

ously marked location of the hernia. The fatty mass protruding through the linea alba defect is excised after a transfixation stitch. The defect in the linea alba is closed with interrupted 3/0 absorbable sutures. The skin is approximated using subcuticular sutures.

Figure 15.16

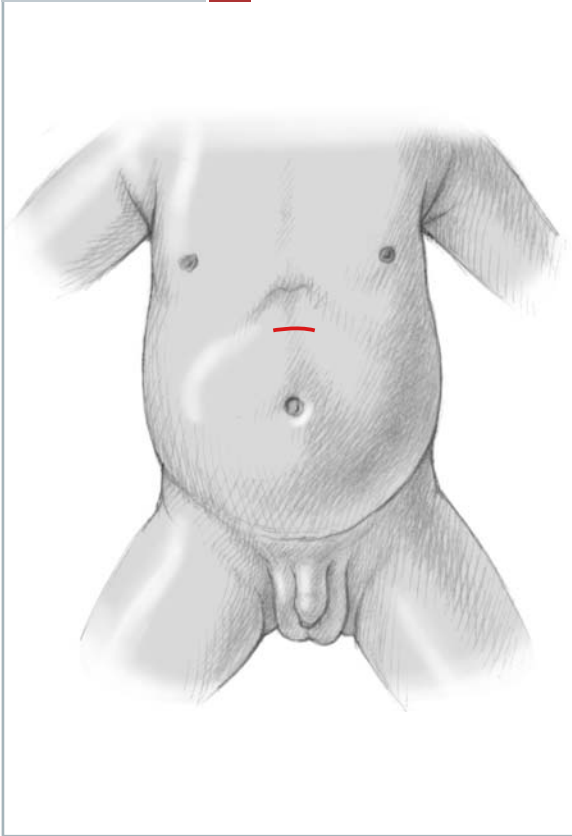


Figure 15.17

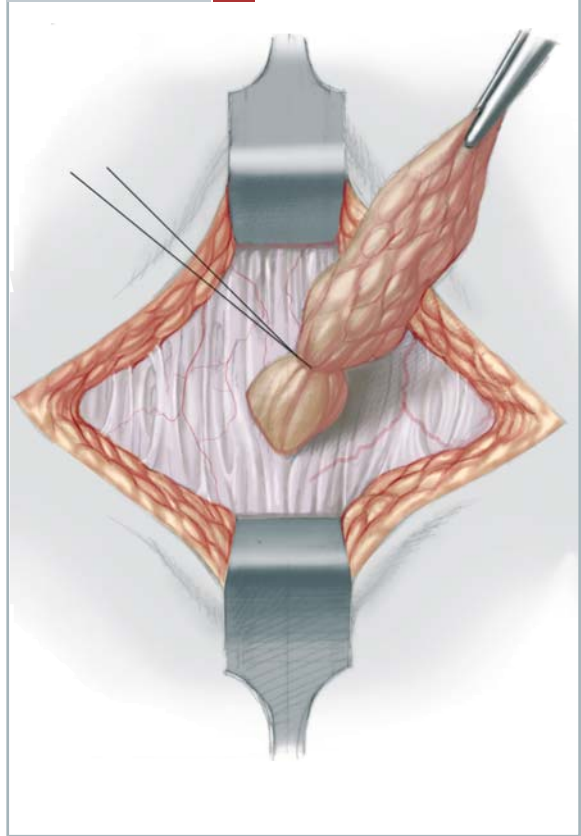
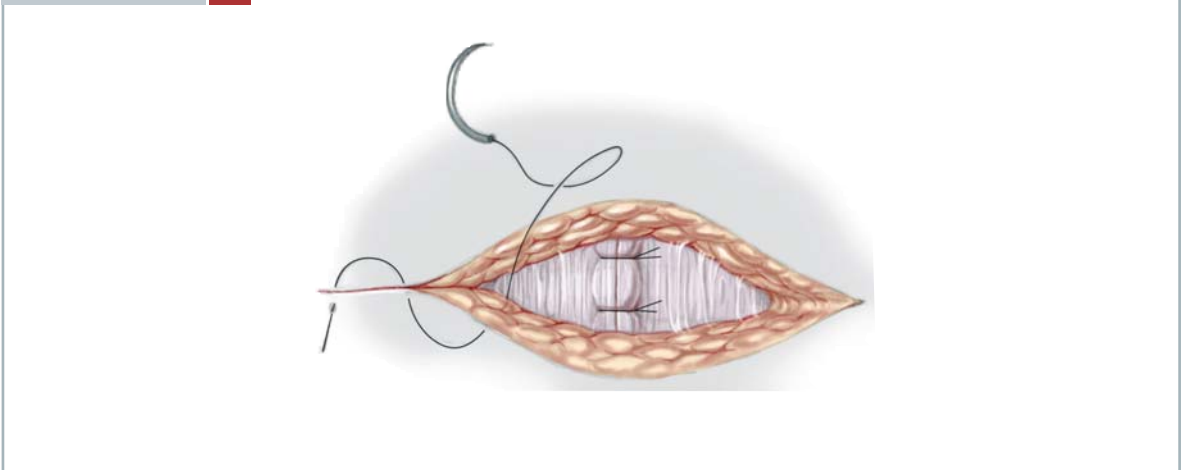


Figure 15.18



CONCLUSION

The overall complication rates after elective hernia repair are low at about 2%, whereas these are increased to 8–33% for the incarcerated hernias requiring emergency operations. Complications of inguinal hernia repair include:

- Haematoma – can be avoided with meticulous attention to haemostasis. It is rarely necessary to evacuate wound, cord or scrotal hematoma.
- Wound infection – low risk and should not exceed 1%.
- Gonadal complications – occur due to compression of the vessels by incarcerated viscera. Though large numbers of testes look nonviable in patients with incarcerated hernia, the actual incidence of testicular atrophy is low and therefore, unless the testis is frankly necrotic, it should not be removed.
- Intestinal resection. This is necessary in about 3–7% of patients in whom the hernia is not reduced and it may cause some additional morbidity corresponding to resection itself and contamination of the field.
- Iatrogenic ascent of the testes. This event is relatively rare since slightly more than 1% of patients operated upon for inguinal hernia during infancy required subsequently orchidopexy. This complication is probably due to entrapment of the testis in the scar tissue or failure to pull it down into the scrotum at the end of the operation and to maintain it there.
- Recurrence. The acceptable recurrence rate for inguinal hernia repair is less than 1% but when operation is performed in the neonatal period this complication can occur in up to 8%. The factors that predispose to recurrence are ventriculoperitoneal shunts, sliding hernia, incarceration and connective tissue disorders. Recurrence may be indirect or direct. Indirect recurrence is due to either failure to ligate the sac at high level, tearing of a friable sac, a slipped ligature at the neck of the sac, missed sac, or wound infection. Direct hernia may be due to inherent muscle weakness or to injury to the posterior wall of the inguinal canal.
- Mortality. In the present-day situation, the mortality rate of inguinal hernia operation should be zero.

SELECTED BIBLIOGRAPHY

- Coats RD, Helikson MA, Burd RS (2000) Presentation and management of epigastric hernias in children. *J Pediatr Surg* 35:1754–1756
- De Caluwe D, Chertin B, Puri P (2003) Childhood femoral hernia: a commonly misdiagnosed condition. *Pediatr Surg Int* 19:608–609
- Levitt MA, Ferraraccio D, Arbesman MC, Brisseau GE, Caty MG, Glick PL (2002) Variability of inguinal hernia surgical technique: a survey of North America pediatric surgeons. *J Pediatr Surg* 37:439–449
- Skinner MA, Grosfeld JL (1993) Inguinal and umbilical hernia repair in infants and children. *Surg Clin North Am* 73:439–449
- Tovar JA (2003) Inguinal hernia. In: Puri P (ed) *Newborn surgery*. Arnold, London, pp 561–568

INTRODUCTION

Exomphalus (also known as omphalocele) is a condition that is seen in newborn infants, and is thought to result from failure of the intestines to return to the abdomen after the migration into the umbilical cord that occurs between the sixth and tenth week after conception. The incidence of exomphalus has not changed over the last several decades. There is no known environmental, racial or geographic predilection, although in rare cases there may be a familial predisposition. Exomphalus is also associated with a lower than normal birth weight and gestational age.

Exomphalus is characterized by a central defect at the umbilical ring; a membrane composed of visceral peritoneum, Wharton's jelly and amnion covers the eviscerated abdominal contents. The umbilical cord inserts onto the exomphalus sac. The sac usually contains loops of small and large intestine, stomach and, in approximately 50% of cases, liver. The abdominal muscles are normally developed. Rupture of the sac is reported in 10–18% of cases. This can happen in utero, at time of delivery or after delivery.

Exomphalus is frequently associated with other anomalies, the most common of which are cardiac and gastrointestinal tract abnormalities. Chromosomal abnormalities are often seen, particularly in children with small defects that do not contain liver. Exomphalus is also associated with Beckwith-Wiedeman syndrome, cloacal exstrophy, and pentalogy of Cantrell.

■ **Prenatal Diagnosis and Management.** Exomphalus is often suspected because of an elevated level of maternal serum α -fetoprotein. Prenatal diagnosis can be accurately made using prenatal sonography. Exomphalus can be differentiated from gastroschisis because of the location of the defect and the presence of a sac, although this may be more difficult if the sac has ruptured. If exomphalus is detected or suspected it is important to search for other abnormalities. In addition to a thorough ultrasound examination, amniocentesis for karyotype analysis should be recommended and fetal echocardiography should be done to look for major cardiac abnormalities. The mother should be transferred to a perinatal centre with experienced neonatal and surgical support. Although there is no clear evidence to support routine caesarean section, most practitioners will recommend cae-

sarean delivery for fetuses with a large exomphalus to avoid liver injury and rupture of the sac.

- **Postnatal Management.** Immediate postnatal management consists of:
 - Nasogastric tube placement to decompress the stomach
 - Intubation, if the child is in respiratory distress
 - Coverage of the sac with moist gauze and plastic foil
 - Intravenous fluids
 - Routine neonatal bloodwork
 - Temperature control with a heating lamp
 - Vitamin K administration
 - Antibiotics, if the sac is ruptured

In addition, a thorough assessment for other abnormalities must be performed, which will directly affect decisions related to the care of the child. Detailed physical examination, radiological studies, echocardiography and abdominal ultrasound are important to identify any associated anomalies. Since some large defects are associated with pulmonary hypoplasia, careful assessment of oxygenation and ventilation should be done and respiratory support using intubation and mechanical ventilation should be instituted if necessary. The exomphalus itself should be evaluated to determine its size, contents, and integrity.

Newborns with abdominal wall defects require more intravenous fluids in the first few days of life than a normal infant, due to evaporative loss and third spacing. The daily intravenous fluid requirement must be adjusted based on the hourly urine output and other parameters for end-organ perfusion. Infants with a silo are at a particularly high risk of fluid, protein and temperature loss.

Based on the clinical status of the patient and the characteristics of the exomphalus, there are three broad categories of options for the surgical management of this condition:

1. Primary closure
2. Staged closure
 - a. Skin
 - b. Silo
 - c. Sequential sac ligation
3. Nonoperative management with late closure

Figure 16.1, 16.2

Small to moderate defects, particularly those in whom the liver is not in the sac, may be closed primarily. The sac is removed.

Figure 16.3

The skin is undermined enough that a secure fascial closure can be accomplished. Absorbable or nonabsorbable sutures may be used. The skin is then closed. For very small defects, the umbilical cord can be left behind to give better cosmetic results.

Figure 16.1

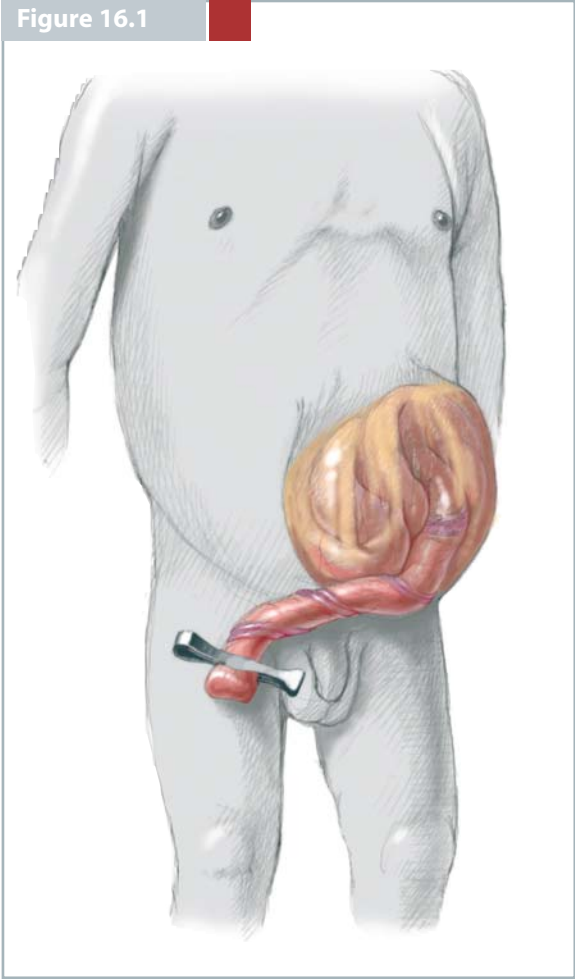


Figure 16.2

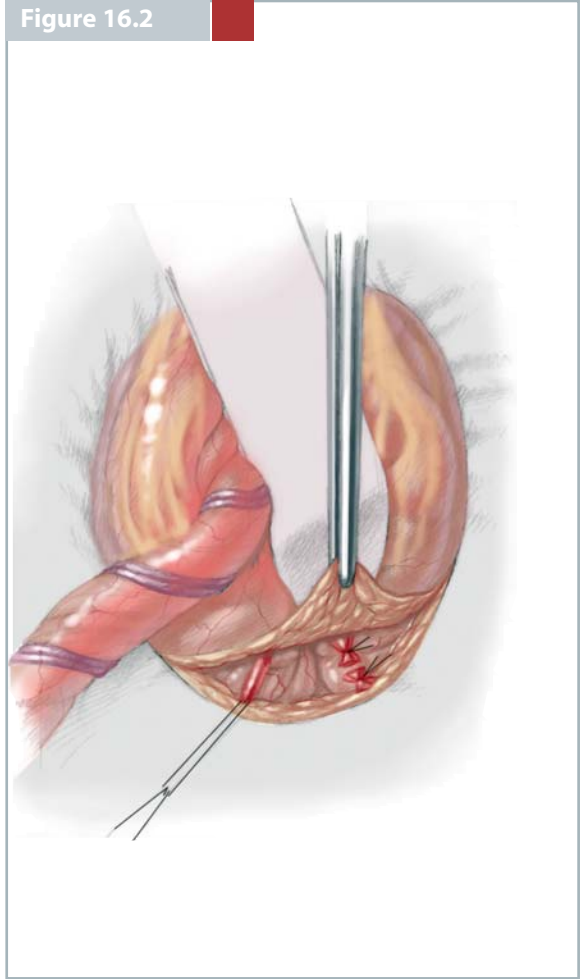


Figure 16.3

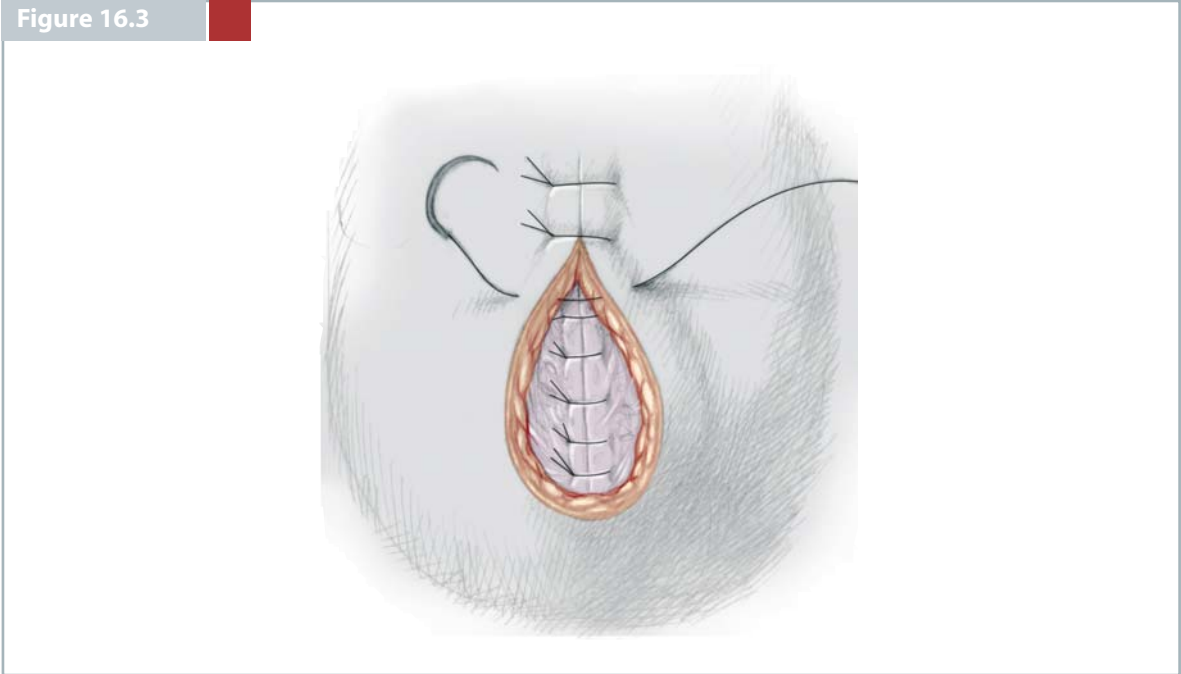


Figure 16.4–16.6

For larger defects, it may not be possible to close the fascia, but there may be enough skin to achieve skin closure over the viscera. This technique was originally described by Gross in 1948. The sac is usually removed, although some surgeons prefer to leave the sac intact and dissect between the edge of the sac and the skin to the level of the abdominal wall muscle.

The skin is undermined as far out as possible, to permit skin closure with minimal tension. At this point, some surgeons opt to insert a patch into the fascia. The skin is then closed over the patch. In most cases of skin closure, the patient is left with a ventral hernia, which must be closed at a later time.

Figure 16.7

The use of a silo was first described by Schuster in 1967. The concept of a silo is to use a sheet of silastic reinforced with Dacron to gradually reduce the viscera over several days to a week, and then to definitively close the fascia and skin. This technique is useful for children with a large or ruptured exomphalus. The silastic sheeting is sutured to the edges of the musculae fascial layer, after as much of the intestine and liver as possible have been returned to the abdomen. Some surgeons also include the skin in these sutures. Although most surgeons remove the sac, some prefer to leave it intact and dissect between the

edge of the sac and the skin to the level of the abdominal wall muscle. In some infants, the neck of the sac at the abdominal wall is relatively small, and the fascial opening must be enlarged to allow gradual reduction of the viscera.

Monofilament nonabsorbable sutures are then placed around the edges to avoid any gaps through which intestine can herniate. The silo is then closed over the top, by suturing it to itself. It should be perpendicular and suspended or supported to avoid any kinks in the intestine.

Figure 16.4

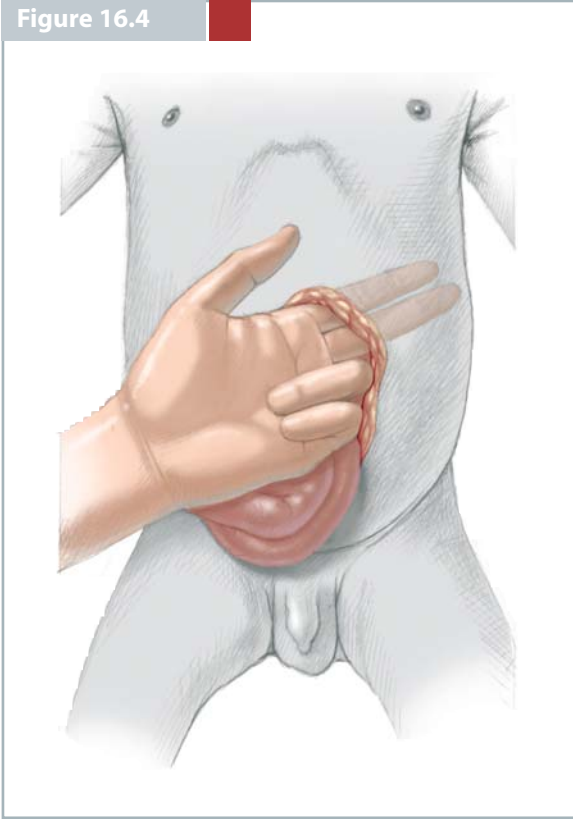


Figure 16.5

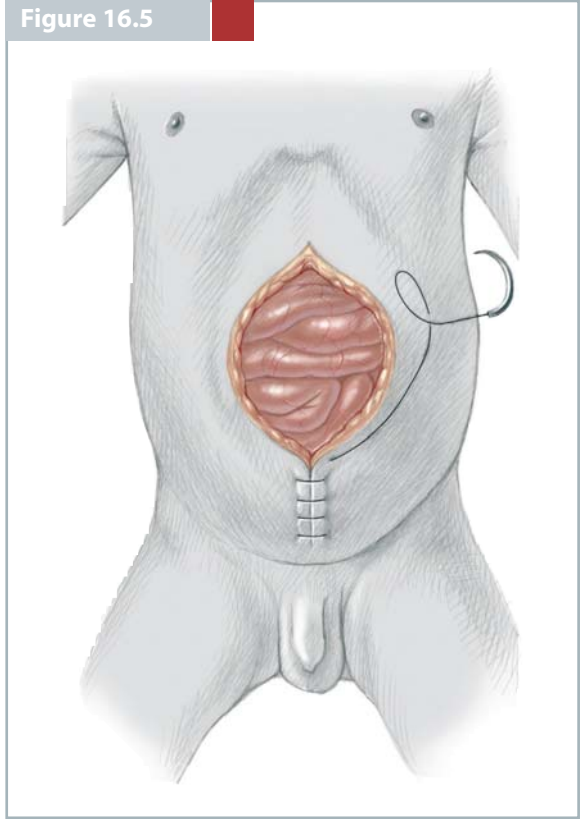


Figure 16.6

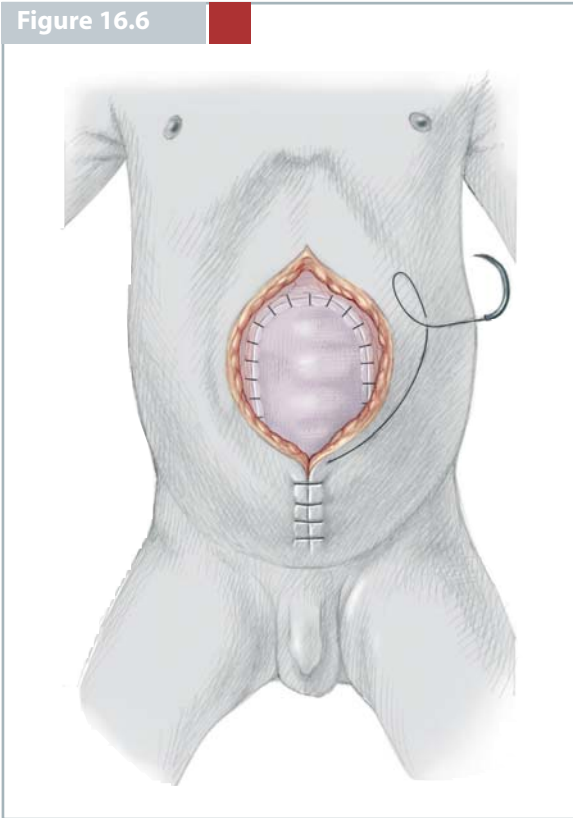


Figure 16.7

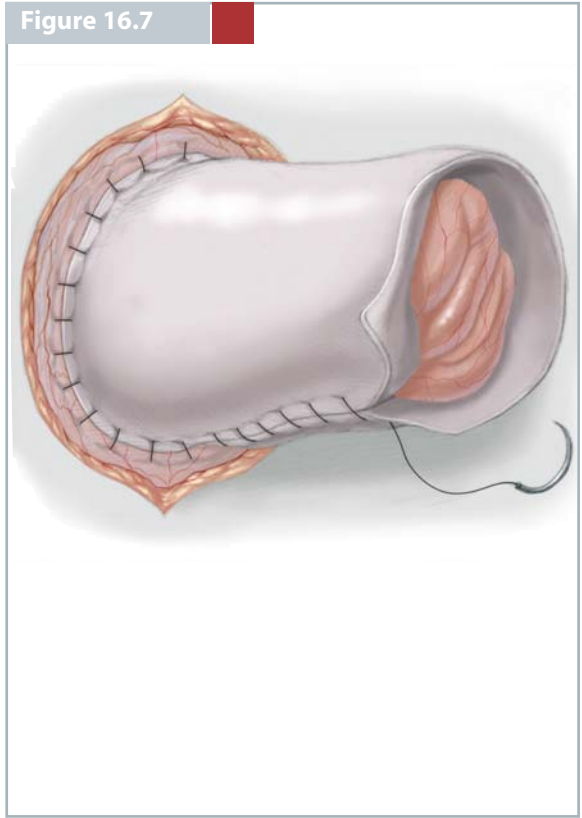


Figure 16.8

The sac is then gradually reduced at least once daily until all of the viscera have been reduced. Various techniques have been used to close the top of the silo, including sutures, umbilical cord clamps, umbilical

tapes, and roller devices. Once the viscera are completely reduced, the child is brought back to the operating room usually after a week and the fascia and skin are closed. Several years in some cases.

Figure 16.9, 16.10

This recently described technique uses the exomphalus sac as a silo. It requires a sac which is relatively strong, and it is relatively difficult if the liver is adherent to a large part of the sac. However, it can be performed at the bedside in the nursery, with only minimal sedation. The technique involves gently kneading the sac to release minor adhesions between the sac and the intestine or liver. Traction is applied to the sac to slowly reduce the contents, and the sac is then twisted and ligated with umbilical ties. Once the viscera are reduced as much as possible, the child is taken to the operating room for definitive closure.

Some infants with exomphalus are very poor candidates for any kind of surgical intervention. This includes premature infants, those with chromosomal abnormalities, and those with significant congenital

heart disease or pulmonary hypoplasia. For these children it is best to cover the sac with a material which allows it to form granulation tissue and eventually epithelialize. Early on mercurochrome or iodine solution were used for this purpose, but there were problems with toxicity; this resulted in the abandonment of this practice. The use of plastic sheeting ("Op-site") has been described. We currently recommend silver sulfadiazine, which prevents infection and results in a good bed of granulation tissue. It takes several months for this to occur, and another several months for the granulation tissue to epithelialize. The resulting huge ventral hernia can be repaired electively whenever the child's underlying cardiac, pulmonary, or other conditions have improved. This may take several years in some cases.

Figure 16.8

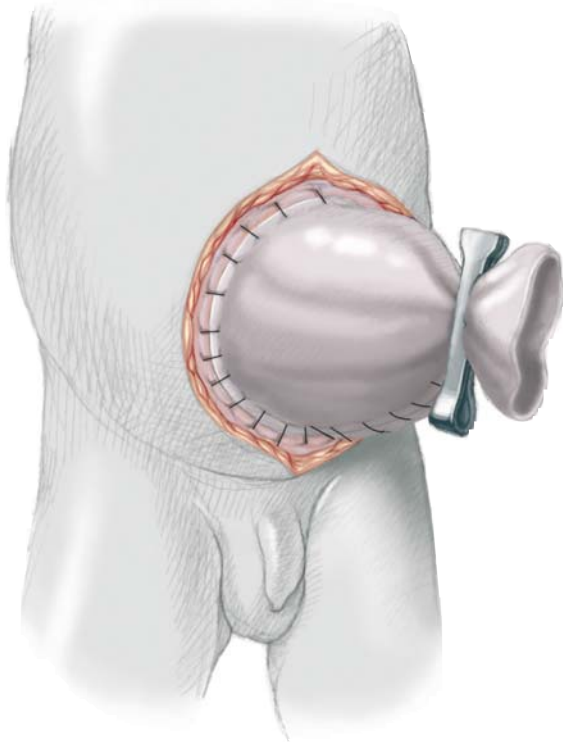
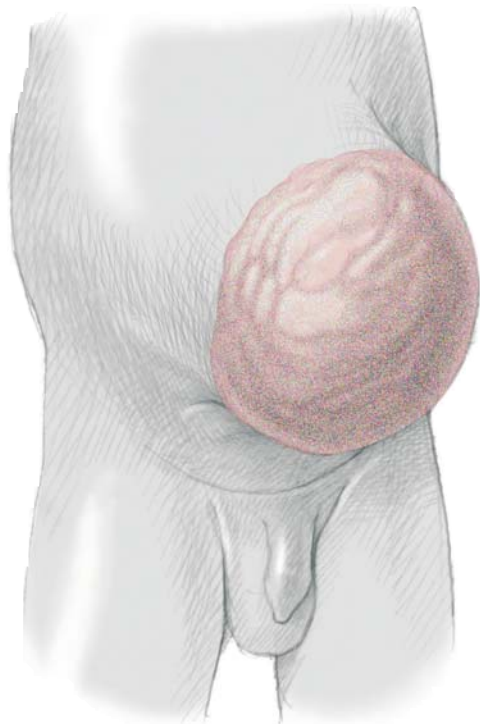


Figure 16.9

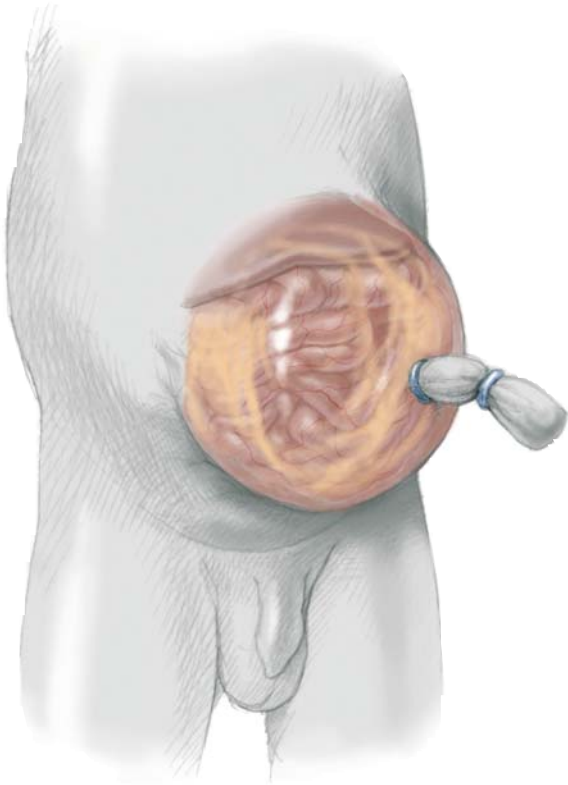

Figure 16.10



CONCLUSION

Care of the infant following definitive closure requires a neonatal intensive care unit for all but the smallest defects. Infants that have undergone repair of larger defects usually require postoperative mechanical ventilation for days to weeks, depending on their pulmonary status. It is important to carefully observe the child for signs of abdominal compartment syndrome, such as oliguria, acidosis, intestinal ischemia, and liver dysfunction. Infants with other congenital malformations require continued investigation and management as needed.

After closure of the abdomen, infants with exomphalus often develop an ileus, although intestinal function usually returns more quickly than seen in infants with gastroschisis. A nasogastric tube is therefore necessary initially. Total parenteral nutrition should be initiated early. Many surgeons place a central venous catheter at the time of the initial operation.

Intra-abdominal pressure monitoring using intra-gastric or intravesical catheters during closure can be

an important adjunct to prevent abdominal compartment syndrome, which may result in high airway pressures, oliguria and intestinal ischemia due to decreased organ perfusion. Intra-abdominal pressures above 15 to 20 mmHg, or an increase in central venous pressure of more than 4 mmHg are associated with visceral ischaemia in both animal and human studies, and should stimulate consideration of conversion to a staged closure technique.

The outcome for infants with exomphalus is dependent on gestational age, the presence of associated chromosomal and structural anomalies, the presence or absence of pulmonary hypoplasia, and the size of the defect. Long-term problems that are commonly seen in these infants include gastro-oesophageal reflux, feeding disorders, and adhesive bowel obstruction. However, most of these issues can be corrected or improve on their own with time, and most infants with exomphalus who do not have severe additional anomalies or pulmonary hypoplasia do very well, and grow up to be normal individuals.

SELECTED BIBLIOGRAPHY

- Bruch SW, Langer JC (2003) Omphalocele and gastroschisis. In: Puri P (ed) *Newborn surgery*. Arnold, London, pp 605–613
- Grosfeld JL, Weber TR (1982) Congenital abdominal wall defects: gastroschisis and omphalocele. *Curr Probl Surg* 19: 157–213
- Hendrickson RJ, Patrick RJ, Janik JS (2003) Management of giant omphalocele in a premature low birth weight neonate utilizing a bedside sequential clamping technique without prosthesis. *J Pediatr Surg* 38: E14–E16
- Hong AR, Sigalet DL, Guttman FM, Laberge JM, Croitoru DP (1994) Sequential sac ligation for giant omphalocele. *J Pediatr Surg* 29: 413–415
- Langer JC (2003) Abdominal wall defects. *World J Surg* 27: 117–124
- Schuster SR (1967) A new method for staged repair of large omphaloceles. *Surg Gynecol Obstet* 125: 837–850

Marshall Z. Schwartz

INTRODUCTION

Gastroschisis is one of several congenital abdominal wall defects that evolves in the first four post-conception weeks. It is generally accepted that this congenital abdominal wall defect is embryologically different from omphalocele. The anomaly is thought to be the result of a defect at the site where the second umbilical vein involutes. Nonrotation of the bowel always accompanies this anomaly and there is an increase in intestinal abnormalities including atresia (mostly involving the small intestine) perforation, and infarction resulting from in utero midgut volvulus or vascular thrombosis. However, unlike omphalocele, there is no increase in anomalies of other organs. The incidence of gastroschisis is approximately 1 in 4,000–6,000 live births. Infants with gastroschisis typically are slightly premature (35–37 weeks of gestation) and frequently have growth retardation with birth weights from approximately 2000–2500 g.

Most abdominal wall defects can be diagnosed in utero after 14 weeks gestation when the fetal midgut has returned to the peritoneal cavity. If gastroschisis is noted on fetal ultrasonography it is strongly recommended that serial examinations be performed looking for changes in the size and thickness of the bowel as well as the diameter of the abdominal wall defect. Significant bowel wall thickening and bowel dilatation, especially associated with a decrease in

the diameter of the abdominal wall defect, may be indications for earlier delivery to avoid bowel infarction. It is important to provide an opportunity for the family to meet with a fetal management team including perinatology, paediatric surgery, and neonatology to review the problem and likely course following delivery. The recommended mode of delivery over the past several decades has been somewhat controversial. It is generally believed that caesarian section is not necessary unless for obstetric reasons. Elective premature delivery is also unnecessary.

Management immediately following delivery and prior to surgical correction requires prompt attention and is critical to the outcome. The two most important goals are to provide a mechanism of maintaining normal thermogenesis and establishing intravenous access to provide appropriate fluid resuscitation. Infants with gastroschisis are usually hypovolemic and require at least 125–150% of maintenance intravenous fluid to establish and maintain adequate hydration. Establishing intravenous access initially can be done through a peripheral intravenous site. Infants with gastroschisis require central venous access. Once intravenous access is established, it is optimal to institute broad spectrum antibiotic coverage. To avoid having the bowel get more distended, a nasogastric tube should be inserted and placed on suction.

Figure 17.1

The specific features of gastroschisis include an abdominal wall defect measuring 2–4 cm in diameter, which is almost always to the right of a normal umbilical cord. There is no sac covering the herniated contents. The herniated contents typically include the entire intestinal mid-gut. There is shortening of the mesentery and thickening of the bowel wall. The bowel surface may be covered with a fibrin “peel”. Depending on the size of the abdominal wall defect, it is possible that the stomach, and/or the urinary bladder, and the fallopian tubes and ovaries in a female may be herniated through the abdominal wall defect.

General anaesthesia including muscle relaxation is required for the appropriate intra-operative management of gastroschisis. The bowel and anterior abdominal wall should be prepped. It is my preference to use a warm, dilute 50/50 mixture of povidone iodine and saline. The umbilical cord should be clamped and tied 2–3 cm above the abdominal wall and the excess umbilical cord then removed. At this point, appropriate draping is indicated.

Figure 17.2

Because the abdominal wall defect in gastroschisis is relatively small (2–3 cm) it may be difficult to reduce the herniated mid-gut through this small opening. Thus, it may be necessary to enlarge the abdominal wall opening. The optimum way to do this is extending the gastroschisis defect superiorly by incising the fascia along the midline with a finger placed below the fascia to avoid an injury to the bowel.

Extending the defect superiorly is safer than a caudal incision because the bladder is very close to the inferior aspect of the abdominal wall defect and this limits the ability to extend the opening inferiorly.

Figure 17.1

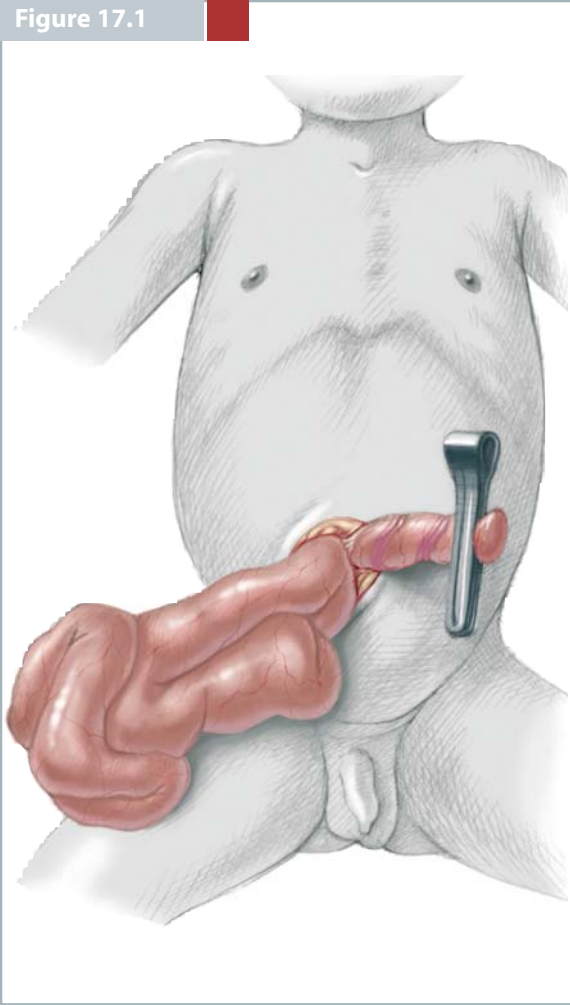


Figure 17.2

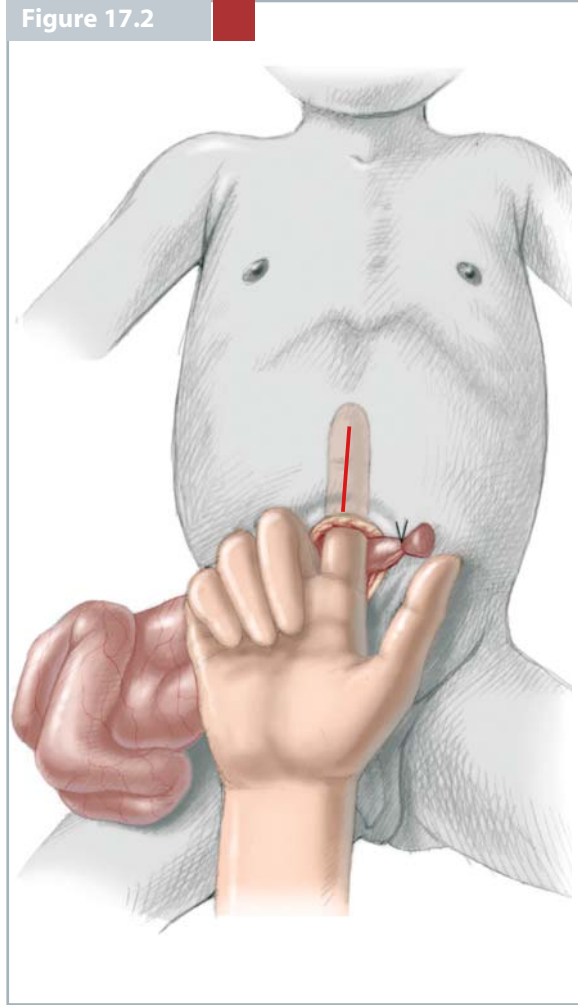


Figure 17.3

After enlarging the abdominal wall defect, the bowel can be reduced into the peritoneal cavity. The degree of thickening and fibrin peel determines how malleable the herniated bowel is and how easily it is to place it within the abdominal cavity. If the initial assessment suggests that primary closure may not be obtainable, two techniques have been described to increase the chances of a primary abdominal wall closure. The first approach is to attempt to empty the intestinal contents either retrograde into the stomach which then can be aspirated through the nasogastric tube or antegrade into the colon and out the rectum. A second technique is manual stretching of the anterior abdominal wall to increase the size of the peritoneal cavity. Although gentle stretching is potentially advantageous, vigorous stretching can result in haemorrhage and swelling of the rectus muscles in the rectus sheath.

Figure 17.4

If it is possible to reduce all of the herniated intestinal contents into the peritoneal cavity, primary closure should be undertaken. It is important to identify good fascial edges for the closure. The choice of suture material and the technique for placement of sutures, whether they are interrupted, figure-of-eight sutures, or a running suture is personal preference. It has been my approach to use 3/0 or 2/0 absorbable braided suture if there is mild to moderate tension and 3/0 or 2/0 monofilament sutures if there is moderate-to-significant tension. These sutures are placed in a figure-of-eight fashion.

It is preferable to place all of the sutures prior to tying them. An important point in patients with gastroschisis is the placement of sutures at the level of the umbilicus. The incidence of an umbilical defect following gastroschisis closure is high. To avoid this, the fascia lateral to the umbilical ring should be clearly identified and used for placement of the suture. If the sutures are placed medial to the umbilical ring, then it is highly likely that an umbilical defect will result in requiring subsequent repair. In tying the sutures in sequence a thin ribbon retractor placed in the peritoneal cavity underneath the fascia is advantageous to avoid trapping the bowel during tying of the sutures. Prior to closing the skin, any compromised or ischaemic skin should be trimmed. The degree of tension on the skin sutures can dictate the type of closure.

Figure 17.3

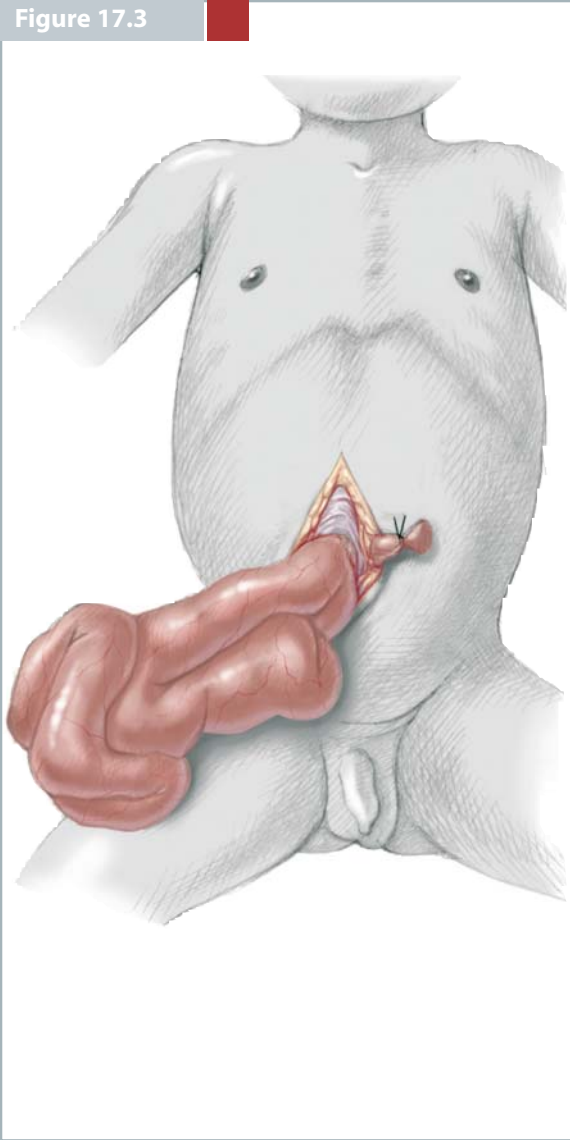


Figure 17.4

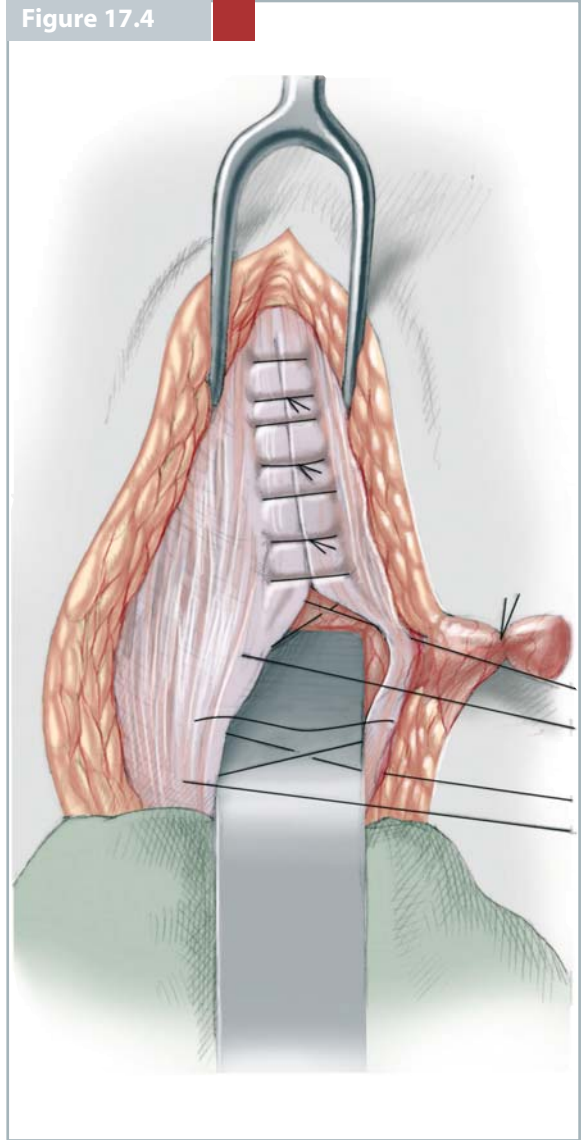


Figure 17.5

A significant percentage of infants with gastroschisis can undergo reduction of the herniated intestinal contents and primary abdominal wall closure. The reported percentage ranges from 60% to nearly 100%.

If it is determined at the time of the initial operative procedure that primary closure is not possible, then an abdominal wall “silo” can be created. This technique, initially described by Schuster and colleagues, has undergone several modifications since its initial description in 1967. However, the concept remains the same. Creation of a sac, which is sewn to the abdominal fascia circumferentially and then around the herniated contents, allows for staged reduction of the sac with resulting reduction of the herniated contents into the abdominal cavity. This approach produces progressive stretching of the abdominal cavity with simultaneous reduction of the swelling and rigidity of bowel. Shown in this illustration is placement of reinforced silastic sheeting which is sutured to the fascial edges with horizontal mattress sutures of interrupted 3/0 silk suture.

Figure 17.6

After the sheets are attached to the fascia on either side of the defect, they are then sewn around the herniated contents with a running suture. As much bowel as will be tolerated is reduced into the peritoneal cavity and then a running suture line is placed across the top of the silastic sac. On successive days the sac is squeezed as much as possible to reduce the herniated contents. A row of running suture in the silo is placed to maintain the reduction. Once the bowel has been reduced into the peritoneal cavity, the fascial edges approximate enough to allow removal of the silo, then primary fascial and skin closure is performed in the operating theatre.

Figure 17.5

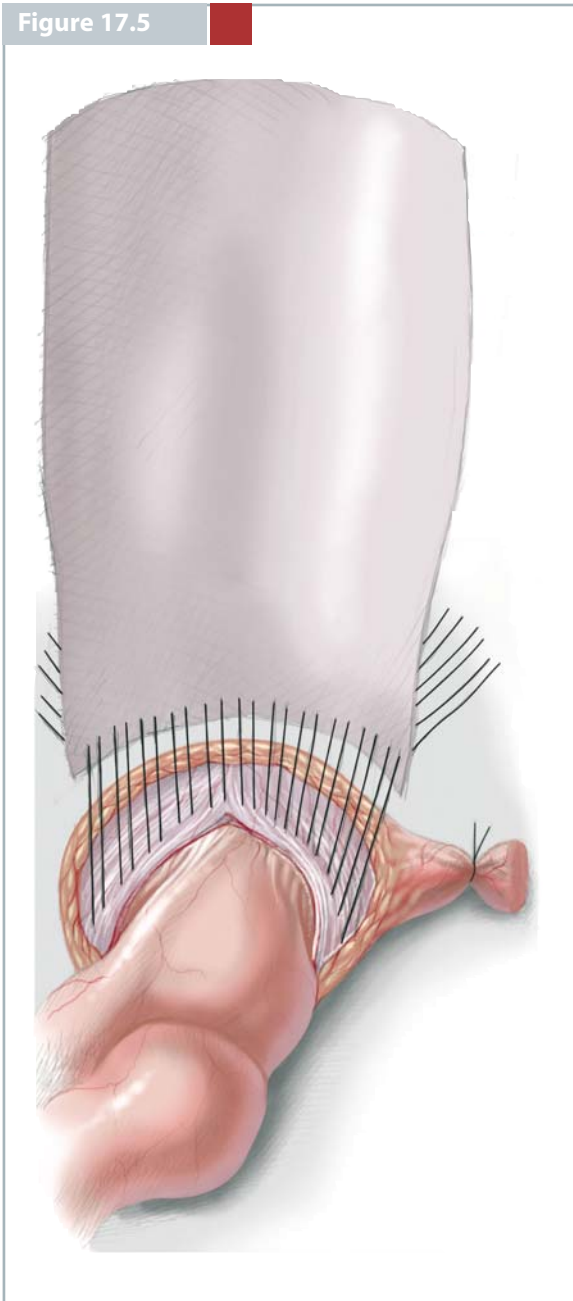


Figure 17.6



Figure 17.7, 17.8

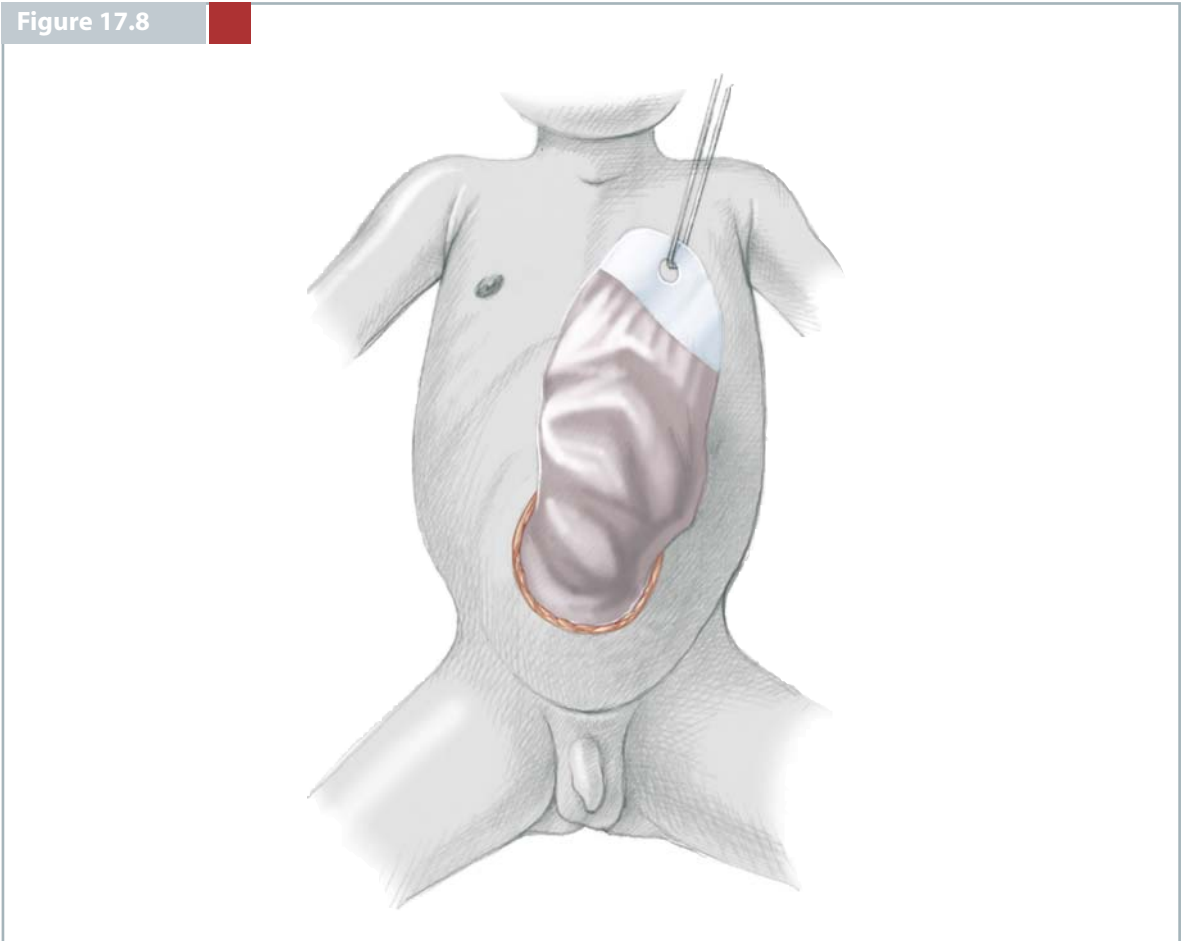
Recently, the use of a preformed spring-loaded silo bag in infants with gastroschisis has been shown to be associated with improved fascial closure rates, fewer ventilator days, more rapid return of bowel

function and fewer complications. Also recently, reduction of gastroschisis bowel has been successfully performed with and without anaesthesia, and without enlarging the abdominal wall defect.

Figure 17.7



Figure 17.8



CONCLUSION

The outcome for patients with gastroschisis has dramatically improved. Whereas the mortality was 80 to 90% three or four decades ago, the survival is now more than 90%. The improvement in outcome is related to the availability of intravenous nutrition and the use of staged closure when indicated. Late complications and mortality are related to sepsis either from an intra-abdominal or wound complication or from a central venous catheter placed for parental nutrition.

Once there is evidence of bowel function it is appropriate to begin enteral feeding. An elemental formula may be better tolerated. When the infant has reached adequate caloric intake enterally then discharge is appropriate.

In the absence of complications during the recovery from surgery and resolution of the bowel oedema, infants with gastroschisis usually reach goal feedings within 3–4 weeks. Long-term complications are unusual once the infants are discharged from the hospital.

SELECTED BIBLIOGRAPHY

- Baerg J, Kaban G, Tonita J et al (2003) Gastroschisis: a sixteen year review. *J Pediatr Surg* 38:771–774
- Driver CP, Bruce J, Bianchi A et al (2000) The contemporary outcome of gastrochisis. *J Pediatr Surg* 35:1719–1723
- Schlatter M, Norris K, Uitvlugt N et al (2003) Improved outcomes in the treatment of gastroschisis using a preformed silo and delayed repair approach. *J Pediatr Surg* 38:459–464
- Schuster SR (1967) A new method for the staged repair of large omphaloceles. *Surg Gynecol Obstet* 125:837–850
- Schwartz MZ, Tyson KR, Milliorn K et al (1983) Staged reduction using a silastic sac is the treatment of choice for large congenital abdominal wall defects. *J Pediatr Surg* 18:713–719

Hypertrophic Pyloric Stenosis

Takao Fujimoto

INTRODUCTION

Infantile hypertrophic pyloric stenosis (IHPS) is a common surgical condition encountered in early infancy, occurring in 2–3 per 1,000 live births. It is characterized by hypertrophy of the circular muscle, causing pyloric narrowing and elongation. The incidence of disease varies widely with geographic location, season and ethnic origin. Boys are affected four times more than girls.

There is evidence of a genetic predisposition to the development of this condition. Siblings of patients with IHPS are 15 times more likely to suffer the condition than children who have no family history of IHPS. The cause of hypertrophic circular muscle of pylorus is still obscure and various hypotheses have been advocated including abnormal peptidergic innervation, abnormality of nitrergic innervation, abnormalities of extracellular matrix proteins, abnormalities of smooth-muscle cells and abnormalities of intestinal hormones.

Typical clinical presentation of infants with IHPS is non-bilious vomiting usually occurring at 2–8 weeks of age. Initially there is only regurgitation of feeds, but over several days vomiting progresses to be characteristically projectile. It occasionally contains altered blood in emesis appearing as brownish discoloration or coffee-ground as a result of gastritis and/or oesophagitis.

The diagnosis is usually based on the clinical history and physical examination of a “palpable pyloric tumour”. Ultrasonographic scanning of abdomen re-

veals typical hypoechoic ring with echogenic centre of increased muscle thickness. A contrast meal may be required in difficult and/or complicated presentation and shows characteristic narrowed elongated pyloric canal.

Persistent non-bilious vomiting in these patients results in chloride depletion, metabolic alkalosis and dehydration. Haematological and biochemical analysis should be undertaken. Any fluid and electrolyte and acid base imbalance should be corrected prior to surgery. Oral feeding should be discontinued and a nasogastric tube inserted prior to surgery to keep the stomach empty. The operation for pyloric stenosis is not an emergency and should never be undertaken until serum electrolytes have returned to normal.

Ramstedt’s pyloromyotomy is the universally accepted operation for pyloric stenosis. A 3-cm transverse right upper quadrant, muscle-splitting incision provides excellent exposure and direct access to the pylorus with minimal retraction. Another incision that is commonly used is a supra-umbilical fold incision. Although supra-umbilical skin-fold incision has a better cosmetic result, it has been argued that delivery of the pyloric tumour can be difficult and time consuming and may damage the serosa of the stomach or duodenum by tearing. Recently, laparoscopic pyloromyotomy has been advocated. The main advantage of the laparoscopic pyloromyotomy is the superior cosmetic result.

Figure 18.1

A nasogastric tube must be placed before the induction of anaesthesia if the tube was not placed pre-operatively. And if the barium meal study has been carried out prior to surgery, it may be necessary to remove the residual barium meal by gastric aspiration and irrigation. The patient is placed in the supine position. After the induction of anaesthesia and endotracheal intubation, careful abdominal palpation will usually identify the site of the pyloric tumour. A 2.5- to 3-cm long transverse incision is made lateral to the lateral border of the rectus muscle. The incision is deepened through the subcutaneous tissue and the

underlying external oblique, internal oblique and transverse muscles are split. The peritoneum is opened transversely in the line of the incision.

When supra-umbilical skin fold incision is employed, a circumumbilical incision is made through about two-thirds of the circumference of the umbilicus. The skin is undermined in a cephalad direction above the umbilical ring and the linea alba is exposed. The linea alba is divided longitudinally in the midline from the umbilical ring to as far cephalad as necessary to allow easy delivery of the pyloric tumour.

Figure 18.2

The stomach is identified and is grasped proximal to the pylorus with non-crushing clamp and brought through the wound. Then, the greater curvature of the stomach can be held in a moist gauze swab, and with traction inferiorly and laterally, the pylorus can

be delivered through the wound. Grasping the duodenum or pyloric tumour directly by forceps often results in serosal laceration, bleeding or perforation, therefore should be avoided.

Figure 18.1

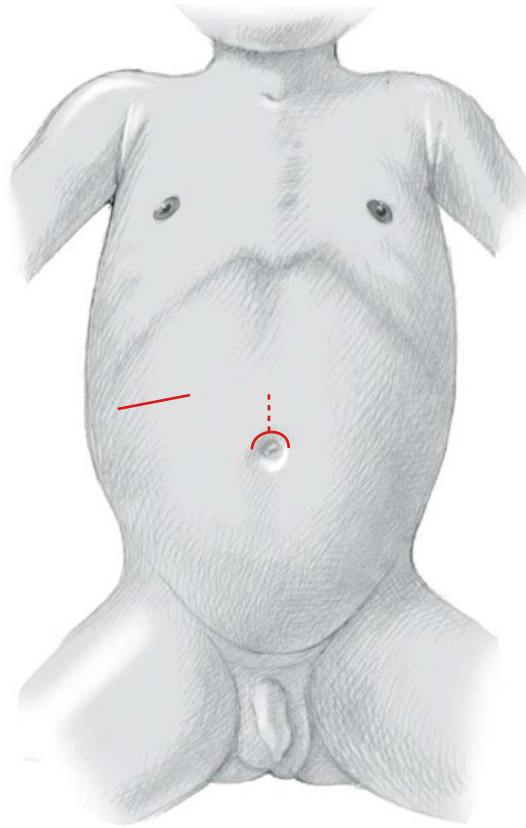


Figure 18.2

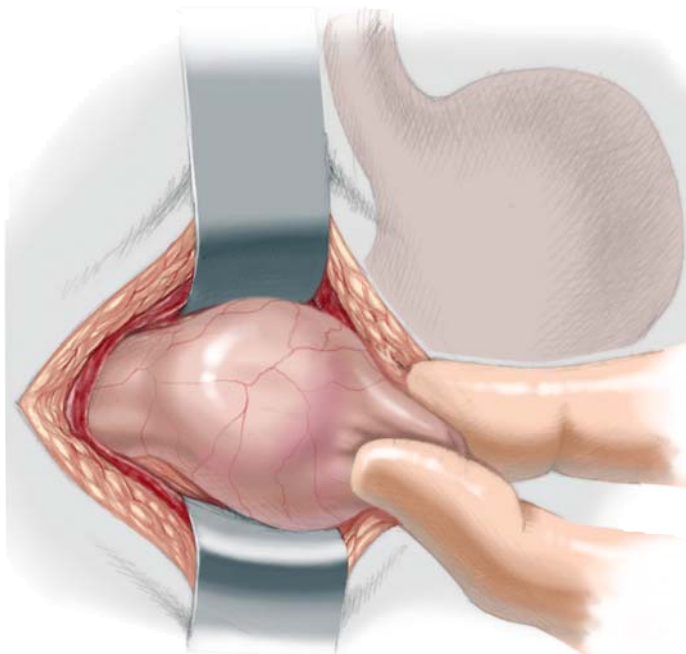


Figure 18.3

The pylorus is held with surgeon's thumb and forefinger to stabilize and assess the extent of hypertrophied muscle. A seromuscular incision is made over the avascular area of pylorus with a scalpel, commencing 1~2 mm proximal to the pre-pyloric vein

along the gastric antrum. The incision should go far enough onto the gastric antrum at least 0.5~1.0 cm from the antropyloric junction where the muscle is thin.

Figure 18.4, 18.5

The scalpel handle is used to further split the hypertrophied muscle down to the submucosal layer. Then pyloric muscle is spread widely. Spreader is placed at the midpoint of incision line and muscle is spread perpendicularly and spreading must be continued proximally and distally. Gentle spreading is required to obtain a complete myotomy. Mucosal tears are most common at the pyloroduodenal junction because of the attempt to split all remaining muscle fibres. In order to reduce the risk of mucosal tear, care should be taken when spreading pyloric muscle fibres at the duodenal end.

Loose prolapsing of intact mucosa is evidence of a satisfactory myotomy. To test the mucosal injury, the stomach is inflated through the nasogastric tube, and passage of air through the pylorus to duodenum is confirmed. Then the pylorus is dropped back into the abdomen. Bleeding from the myotomy edge or submucosal surface is frequently seen; however, it is generally venous and always stops after returning the pylorus to the abdominal cavity. Posterior rectus fascia and peritoneum is approximated with a running 4/0 absorbable suture material and anterior fascia is closed with 5/0 absorbable suture material.

Figure 18.3

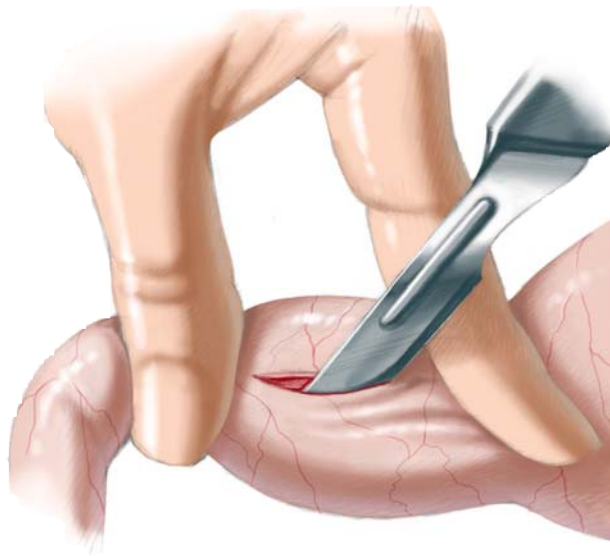


Figure 18.4

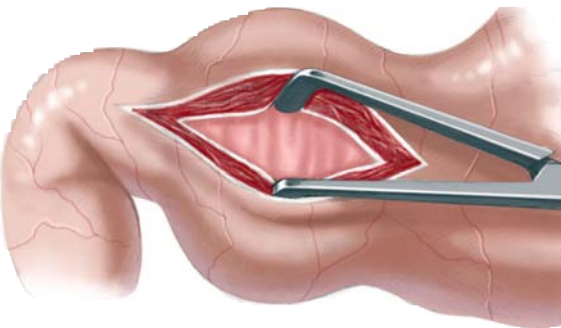


Figure 18.5

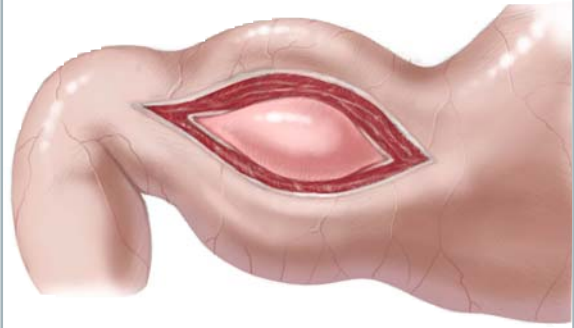


Figure 18.6

For the laparoscopic procedure the patient is placed in the supine position at the end of the operating table (or 90° to the anaesthesiologist). The video monitor is placed at the head of the table, and the surgeon stands at the end of the table with the assistant to the patient's right. The abdomen is scrubbed and draped in a sterile fashion. Attention must be paid to ensure the appropriate preparation of the umbilicus.

The access sites are injected with local anaesthetic (0.25% bupivacaine) with epinephrine, which is used to reduce the post-operative pain and reduce the risk of bleeding from the stab wound. The author prefers an open procedure for insertion of the primary port. A 4.0- to 5.0-mm curvilinear supra-umbilical incision is made and carried down to the peritoneal cavity. At the level of umbilical fascia, 4/0 absorbable suture material is placed circumferentially to anchor the port and to use for closure of the peritoneal cav-

ity after laparoscopic pyloromyotomy is completed. Intra-abdominal pressure is maintained at 8 mmHg, and insufflation rate is set at 0.5 l/min. In the right mid-clavicular line just below the costal margin (just above the liver edge), a no. 11 scalpel blade is used to make a 2- to 3-mm stab incision under direct vision. Also using the no. 11 scalpel blade, a second stab incision is made under direct vision, just below the costal margin in the left mid-clavicular line.

An atraumatic grasper is placed directly through the right upper quadrant stab wound and is used to retract the inferior border of the liver superiorly and expose the hypertrophic pylorus. A retractable myotomy knife (retractable arthrotomy knife or Endotome) is inserted directly through the left stab wound. Working ports are usually not necessary and instruments are directly introduced through these stab wounds.

Figure 18.6

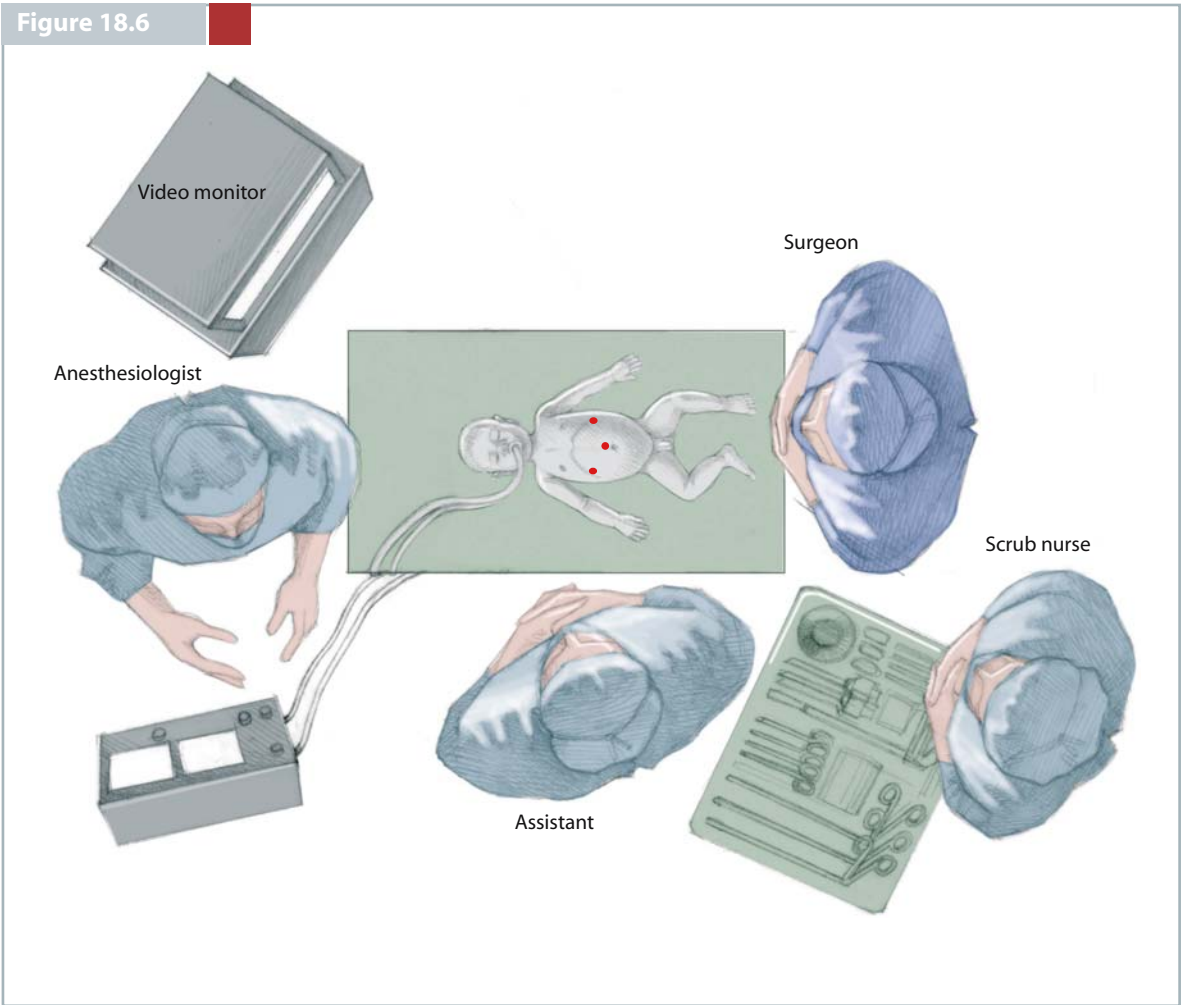


Figure 18.7

The working instruments, retractable myotomy knife, atraumatic laparoscopic grasper are used to assess the extent of the hypertrophied pylorus by palpating the margins of the pylorus as one would use with thumb and forefinger in the open procedure.

The duodenum is then grasped just distal to the pyloric vein (pyloroduodenal junction) and retracted using the atraumatic grasper to expose the avascular surface of hypertrophic pylorus. The tips of positioning the pylorus for myotomy is that lateral and slightly anterocephalad retraction of the distal pylorus achieve excellent exposure of the avascular surface of hypertrophic pylorus. This manoeuvre also expos-

es the proximal margin of hypertrophied muscle that is seen as a deep fold in the wall of stomach.

A seromuscular incision is made over the hypertrophic pylorus with retractable myotomy knife commencing at 1–2 mm proximal to the pyloroduodenal junction extending to the gastric antrum. The incision should go far enough onto antrum at least 0.5–1.0 cm proximal to antropyloric junction. Care must be taken at this stage that this incision is deep enough to allow the insertion of the pyloric spreader blades and must penetrate the pyloric muscle somewhat deeper than is usual with the conventional open procedure.

Figure 18.8

After the muscle is incised, the blade is then retracted and the sheath of the knife is used to further split the hypertrophied muscle fibre, as the scalpel handle is used in open procedure, until mucosa is visualized. The retractable myotomy knife is removed and a laparoscopic pyloromyotomy spreader is introduced into abdominal cavity directly through the left stab wound to complete the pyloromyotomy. The spreader is placed in the midpoint of the seromuscular incision line and the muscle is spread perpendicularly. Once the initial spread reaches the mucosa, spreading must be continued proximally and distally. Pushing the spreader towards the mucosa or rapid spreading can result in mucosal tear. In order to avoid the mucosal tear, the spreader should not be placed at the proximal and distal edges of the incisional (myotomy) line.

To test for the mucosal injury, the stomach is inflated through the nasogastric tube (160–180 ml) as is usually done in open techniques. Bulging of the mucosal layer with no evidence of defect should be confirmed. Greenish or yellowish fluid at the myotomy area is a sign of mucosal tear.

After the successful myotomy, the instruments are withdrawn under direct vision and the pneumoperitoneum is evacuated. The nasogastric tube is also removed after completing the surgery. The umbilical fascia is reapproximated with 4/0 absorbable suture material, which is already in place, and the skin of all the wound is reapproximated with skin adhesive tapes.

Figure 18.7

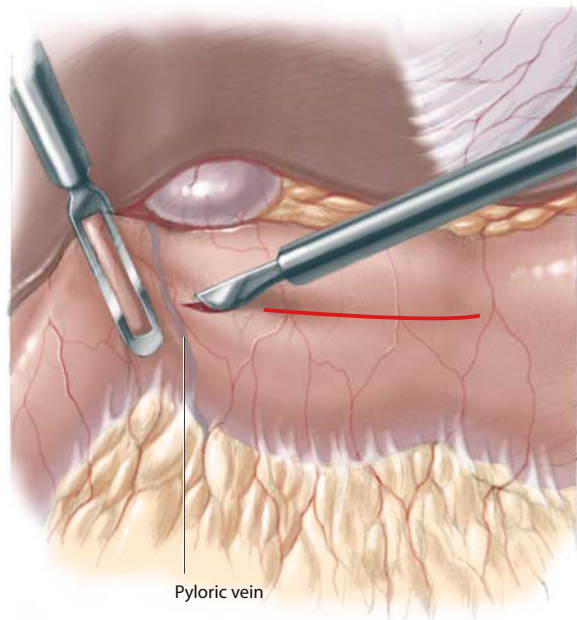
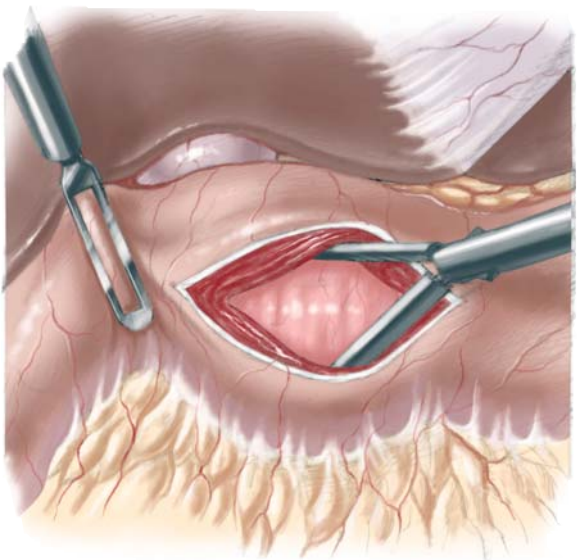


Figure 18.8



CONCLUSION

Pyloromyotomy is the standard therapy for IHPS. Mortality associated with this operation is very uncommon today. Early diagnosis and proper peri-operative management reduces complications. In spite of these advances, there remains about an 8–10% incidence of associated peri-operative morbidity such as perforation, wound infection and wound dehiscence.

In an open procedure, essentially right umbilical incision and circumumbilical incision, manipulation

of and tension on the pylorus to deliver it through the wound can induce oedema in muscle layer, mucosal swelling and, occasionally serosal laceration. A laparoscopic pyloromyotomy (LP) is a less traumatic operation. The tolerance of an early feeding regimen in the LP confirms that there is lack of trauma to the pylorus during the procedure. We feel this is the most considerable benefit of LP. Use of 3.0-mm instruments allow us to improve the cosmesis.

SELECTED BIBLIOGRAPHY

- Fujimoto T, Lane GJ, Segawa O et al (1999) Laparoscopic extramucosal pyloromyotomy versus open pyloromyotomy for infantile hypertrophic pyloric stenosis: which is better? *J Pediatr Surg* 34: 370–372
- Leinwand MJ, Shaul DB, Anderson KD (1999) The umbilical fold approach to pyloromyotomy: is it a safe alternative to right upper quadrant approach. *J Am Coll Surg* 189: 362–367
- Puri P, Lakshmanadaas G (2003) Hypertrophic pyloric stenosis In: Puri P (ed) *Newborn surgery*. Arnold, London, pp 389–398
- Tan KC, Bianchi A (1986) Circumumbilical incision for pyloromyotomy. *Br J Surg* 73:399

INTRODUCTION

In infants and children, gastrostomies are indicated primarily for long-term enteral feedings and less frequently for decompression or a combination of both. In the last three decades, advances in peri-operative management have led to a more selective use of gastrostomies in patients with various typical paediatric surgical conditions such as congenital anomalies of the gastrointestinal tract and the abdominal wall. On the other hand, there has been a markedly increased utilization of gastrostomies in infants and children without surgical pathology. The main indication for direct gastric access in these patients is an inability to swallow, usually secondary to central nervous system impairment. An additional indication for a gastrostomy is the need to provide feeding supplementation in children unable or unwilling to consume adequate calories orally. Other uses of gastric stomas include access for oesophageal bougienage and the long-term administration of unpalatable diet or medications.

When feeding is the main indication, two important questions must be addressed.

First, *nasogastric tube or gastrostomy?* Nasogastric tubes should be preferred if the expected duration of enteral access is less than 1 or 2 months, because the newer small feeding tubes are highly biocompatible and remain smooth and soft for prolonged periods of time. Gastrostomies should be considered when gastric access is expected to last more than several months.

Second, *gastrostomy only or gastrostomy plus anti-reflux operation?* Neurologically impaired children, the main candidates for a gastrostomy, frequently have foregut dysmotility and associated gastro-oesophageal reflux. Because gastrostomies can unmask reflux, these children should be evaluated prior to placing a stoma, usually with an upper gastrointestinal contrast series and a pH probe study. Endoscopy with biopsy, manometry and gastric emptying studies may be added, if deemed necessary. Unfortunately, these studies are not particularly helpful in predicting post-gastrostomy reflux. For this reason, we employ a trial of nasogastric tube feedings for 1 to 2 weeks. If these are well tolerated, we place the gas-

trostomy only. If, on the other hand, they are not, an anti-reflux operation is done in conjunction with the gastrostomy. If the need to control reflux surgically arises at a later date, an anti-reflux operation may be added, usually without taking down the gastrostomy.

There are three *basic methods* of constructing a gastrostomy.

First is the formation of a serosa-lined channel from the anterior gastric wall around a catheter. This catheter is placed in the stomach and made to exit either parallel to the serosa as in the Witzel technique, or vertically as in the Stamm or Kader methods. The anterior gastric serosa is apposed to the peritoneal surface of the anterior abdominal wall with sutures. The Stamm technique is the most widely employed gastrostomy with celiotomy. It can be used in children of any size and even on the smallest stomach (e.g., in newborns with oesophageal atresia without fistula).

Second is the formation of a tube from a full-thickness gastric flap, leading to the skin surface where it is anchored with sutures. A catheter is then introduced intermittently for feeding. The construction of a gastric wall tube is seldom used in children. The technique is more time consuming, difficult to perform in small children, not suited for the passage of dilators and is more prone to leakage at the skin level unless an anti-reflux manoeuvre is added, further complicating this approach. This method also interferes with reoperations on the stomach, because part of the gastric wall has been used for the conduit.

The third method consists of percutaneous techniques in which the introduced catheter holds the gastric and abdominal walls in apposition. These procedures are based on the principle of sutureless approximation of a hollow viscus to the abdominal wall. In addition to the original method, in which gastroscopy was employed, the catheter may also be placed with radiological or, more recently, laparoscopic assistance. Laparoscopic control can also be employed to enhance the safety of percutaneous gastrostomy placement in select patients with abnormal upper abdominal anatomy in whom injury to adjacent organs, such as the colon, is a concern.

Percutaneous endoscopic gastrostomy (PEG) was initially developed for high-risk paediatric patients to allow precise tube placement with endoscopic assistance, without celiotomy. Depending on how the catheter is inserted, the three main variations are: *pull* (Gauderer-Ponsky), *push* (Sachs-Vine) and *introducer* or “*poke*” (Russell) methods. The first gastrostomy without celiotomy, the Gauderer pull PEG remains the most widely employed gastrostomy, both in adult and paediatric patients. The procedure time is short and there is practically no postoperative ile-

us, potential for gastric bleeding or wound disruption. There is only minimal interference with subsequent operations on the stomach. The likelihood of an infection is very small and similar to that of the Stamm procedure. PEG is not generally suited for the passage of dilators.

With certain modifications, either one of these basic interventions can be performed by minimally invasive techniques or in conjunction with laparoscopy.

Figure 19.1

The Stamm gastrostomy operation is performed using general endotracheal anaesthesia. A single dose intravenous antibiotic is administered. A nasogastric tube may be inserted to evacuate the contents and help identify the stomach in children with abnormal upper abdominal anatomy. The child is positioned with a small roll behind the back to elevate the epigastrium, then prepared and draped. In infants, a thin plastic, small-aperture drape is used to help with temperature maintenance. We prefer to use silicone rubber de Pezzer-type catheters ranging in size from 12F (full-term neonates) to 20F for adolescents, or PEG-type catheters in which the “dome” has been modified to allow insertion with a stylet. For pre-term infants or neonates with a very small stomach, a 10F T-tube or Malecot catheter is employed. The procedure may be modified slightly to accommodate the initial placement of a skin-level device or “button”. (See Fig. 7).

The stomach is approached through a short transverse supra-umbilical incision. Fascial layers are in-

cised transversely and the muscle retracted or transected. The catheter exit site should be approximately at the junction of the lower two-thirds and the upper one-third of a line drawn from the umbilicus to the mid-portion of the left rib cage, over the mid-rectus muscle. A vertical incision may be useful in children with a high-lying stomach or a narrow costal angle. The catheter exit site should not be too close to the rib cage because, with the child’s growth, this distance tends to become shorter. A gastric access device that is too close to the ribs will cause discomfort and interfere with care. Additionally, the excessive pivoting motion resulting from breathing and moving will lead to stoma enlargement and leakage. Catheters should not be brought out through the incision because this approach predisposes the site to wound complications and leakage. The linea alba tends to be broad and very thin in small children and should also be avoided as an exit site.

Figure 19.1

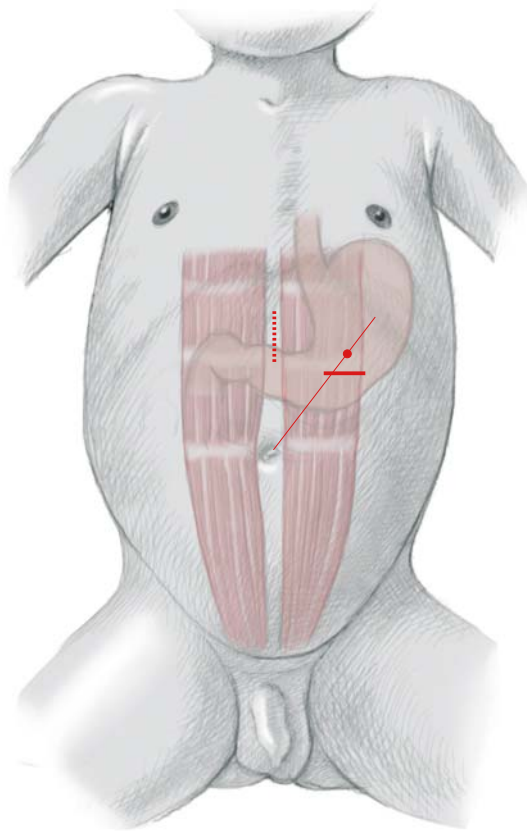


Figure 19.2

The selection of the gastrotomy site on the anterior gastric wall is very important. The mid body is best suited for the catheter insertion. The opening should be away from the gastric pacemaker at the level of the splenic hilum; away from the greater curvature because that site may be needed for construction of a gastric tube and because proximity to the transverse colon could eventually lead to a gastro-colic fistula; away from the fundus to allow for a possible future fundoplication. It is critical to avoid the antrum to prevent pyloric obstruction by the catheter tip and interference with gastric emptying. A stoma in this position is also more likely to leak. If the catheter is to be placed cranially and close to the lesser curvature of the stomach with the intent of creating an anti-reflux mechanism, care must be taken to avoid the vagus nerve.

Traction guy sutures lifting the gastrotomy site, and a purse-string suture of age appropriate synthetic absorbable material are placed. The diameter of the purse-string should be adequate for invagination of the gastric wall upon insertion of the catheter, but not excessive to avoid narrowing of the stomach.

Figure 19.3

A lower guy suture may be added to pull the stomach caudally, enhancing the exposure and allowing better gastric access. The gastrotomy is performed with fine scissors or cautery while the upper guy sutures are lifted to prevent injury to the posterior gastric wall. The de Pezzer catheter is introduced using a simple stylet while the sutures are elevated.

Figure 19.4, 19.5

A continuous synthetic absorbable monofilament suture (polydioxanone) is used to anchor the stomach to the anterior abdominal wall. A clamp is placed through the counter-incision and the abdominal wall layers pushed inward. After the posterior 180° of the “anastomosis” are completed, the peritoneum and fascia are incised and the tip of the clamp pushed

through. The catheter end is grasped and the tube brought out through the counter incision.

Placement of the continuous monofilament suture is then completed. When tied, this suture provides a 360° fixation of the stomach to the abdominal wall and a watertight seal. In most cases, this manoeuvre obviates the need for a second purse-string suture.

Figure 19.2

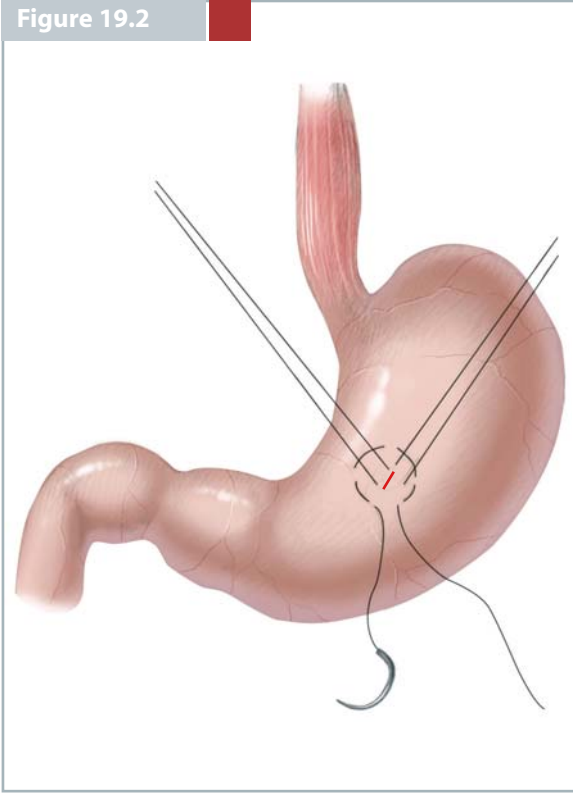


Figure 19.3

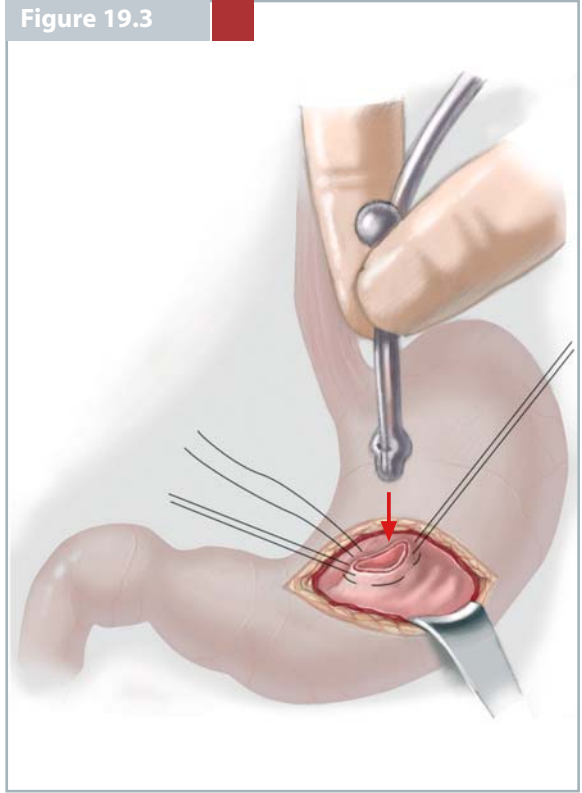


Figure 19.4

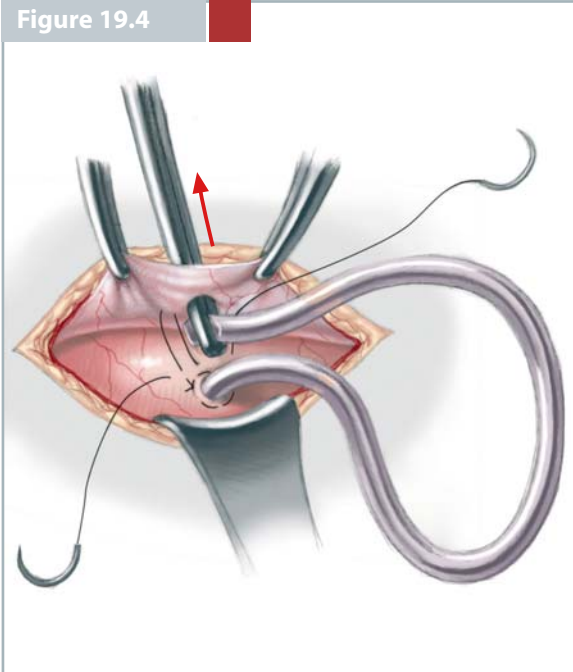


Figure 19.5

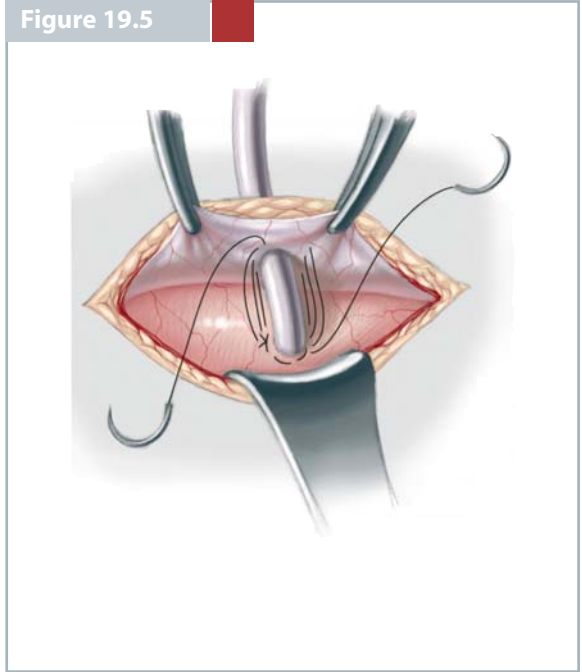


Figure 19.6

The abdominal wall layers are closed with synthetic absorbable sutures and the skin is approximated with subcuticular stitches and adhesive strips. The wound is infiltrated with a long-lasting local anesthetic. The catheter is secured with synthetic

monofilament sutures (polypropylene or nylon). These are removed 1–2 weeks after the operation. If the tube is to remain long, a small immobilizing crossbar is added to prevent distal catheter migration.

Figure 19.7

The standard procedure shown may be modified to allow for the primary insertion of a skin-level gastrostomy device. The gastrostomy balloon-tipped “buttons” are available in different shaft sizes and diameters. The shaft’s length should encompass the invaginated gastric wall, the abdominal wall and an ad-

ditional few millimetres of “play” to allow for postoperative oedema, ease of care and subsequent growth and weight gain. Following insertion, the stomach is vented through the skin-level device or by means of a nasogastric tube.

Figure 19.6

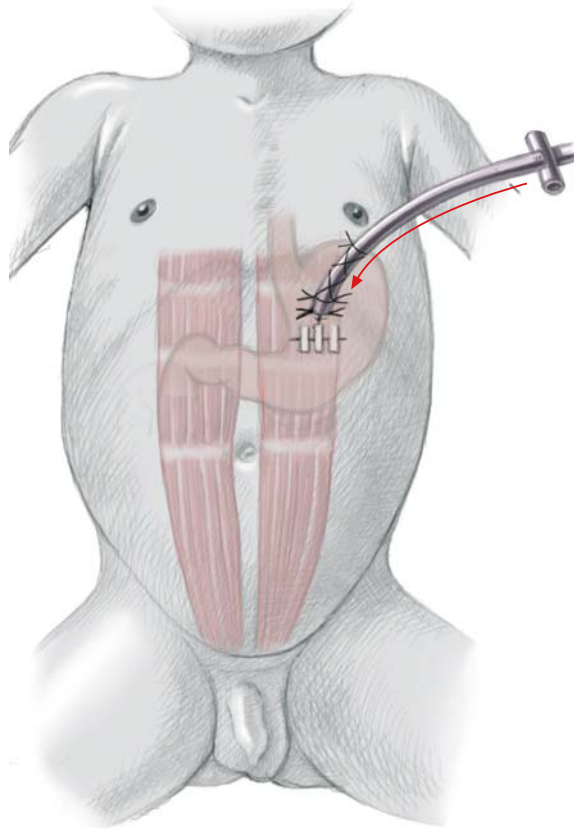


Figure 19.7

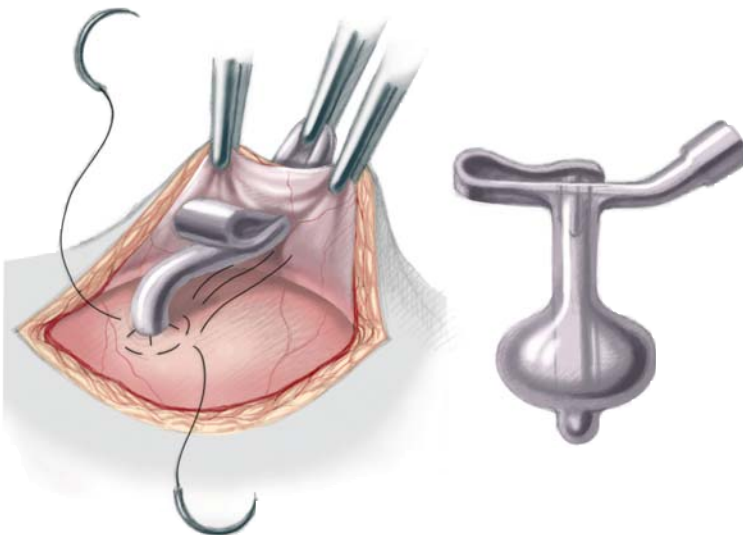


Figure 19.8

Percutaneous endoscopic gastrostomy (PEG) is best performed in the operating room. In older children and those able to tolerate endoscopy without compromising the upper airway, the procedure may be undertaken using local anaesthesia with sedation as needed. Younger children require general endotracheal anaesthesia primarily because of anticipated difficulties with the airway management. Two individuals are required – one for the endoscopy and one for the insertion of the guide wire and pulling back the catheter. A single dose of a broad-spectrum intravenous antibiotic is given shortly before the procedure. For the endoscopy, the smallest available flexible paediatric gastroscope is used. The catheter with its retaining internal crossbar, “cup”, “dome” or disk must be soft and collapsible enough to glide atraumatically through the oropharynx and oesophagus. A 14F to 16F silicone rubber catheter is well suited for younger children and a 20F tube is used for older

children and adolescents. Hybrid catheters leading to the primary implantation of skin-level devices are also available. Immediate conversion to a skin-level device is our favoured approach.

Contraindications to PEG are inability to perform upper tract endoscopy safely or to identify transabdominal illumination and clearly recognize an anterior gastric wall indentation. Anatomical abnormalities such as intestinal malrotation or marked scoliosis, ascitis, coagulopathy, and intra-abdominal infection, if severe, may render the procedure inadvisable. One must also be cautious in the presence of intraperitoneal shunts.

The site for catheter placement is similar to the one described for the Stamm procedure. The stoma should be away from the rib cage for the reasons mentioned above and to allow placement of an incision if a fundoplication becomes necessary in the future.

Figure 19.9

The abdomen is prepared and draped. The catheter site is tentatively selected. The gastroscope is inserted but the stomach is not immediately insufflated. The snare is advanced into the operating channel of the scope. Once all necessary equipment is available and ready for use, the room lights are dimmed and the stomach insufflated. Under-insufflation or, more importantly, over-insufflation should be avoided to minimize the possibility of accidentally piercing the colon. Excessive insufflation of the small intestine tends to push the transverse colon in front of the stomach and into harm's way. It also distorts the stomach, which may interfere with correct catheter placement.

Once the stomach is appropriately distended, digital pressure is applied to the proposed gastrostomy site, which usually corresponds to the area where transillumination is brightest. Transillumination and clear visualization of an anterior gastric wall indentation are key points. Without these, laparoscopic control or an open gastrostomy should be employed. If additional confirmation of proper relation of the structures is desired, a fine spinal needle may be introduced through abdominal and gastric walls. Because the length of the needle is known, one can estimate the distance between the gastric mucosa and the skin. Excessive length warrants caution.

Figure 19.8

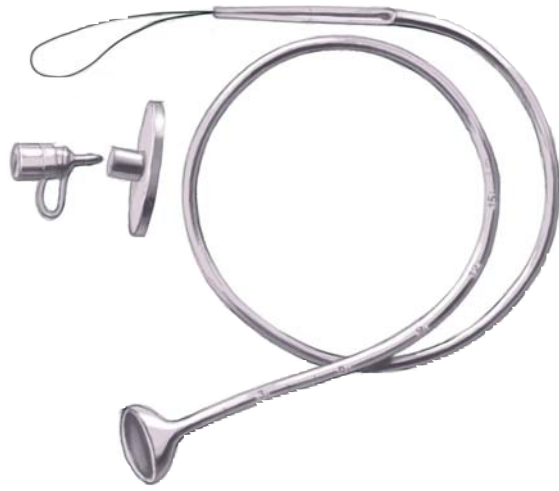

Figure 19.9

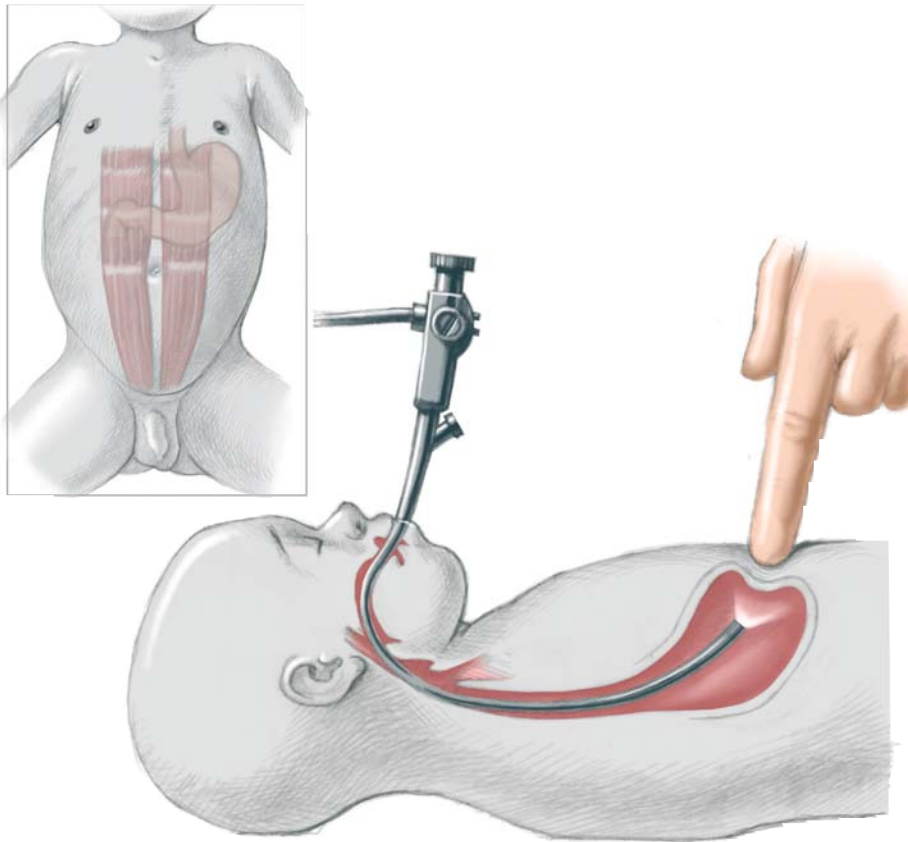


Figure 19.10, 19.11

The stoma site is infiltrated with a long acting local anaesthetic. An incision of 8–10 mm is made transversely in the skin and a curved haemostat applied to maintain the intragastric indentation. The gastroscope is moved gently in small increments. The endoscopist then places the polypectomy snare around or over this “mound”. The intravenous needle-cannula,

which will allow the placement of the guide-wire, is placed in the incision between the slightly spread prongs of the haemostat. The needle-cannula is then firmly thrust through the abdominal and gastric walls, exiting through the tip of the mound into the loop of the polypectomy snare. The snare is partially closed, but not tightened around the cannula.

Figure 19.10

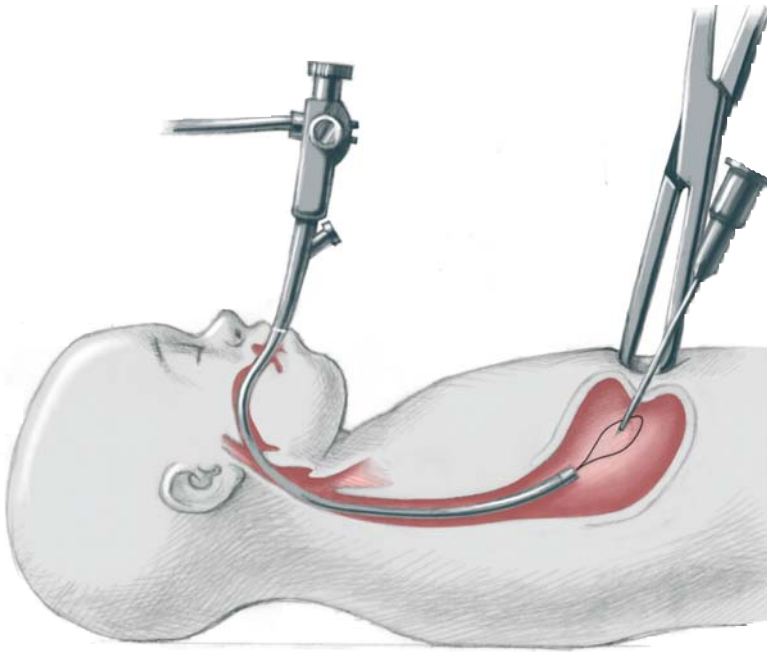


Figure 19.11

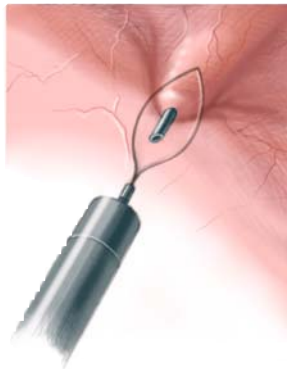


Figure 19.12, 19.13

The needle is removed and the plastic-coated looped steel guide-wire inserted through the cannula. The polypectomy snare is allowed to slide away from the cannula and is tightened around the guide-wire. (An alternative method is to retrieve the wire with alligator or biopsy forceps.) The guide-wire is then pulled back with the endoscope from the stomach, through the oesophagus, exiting from the patient's mouth. The guiding tract is thus established.

Figure 19.12

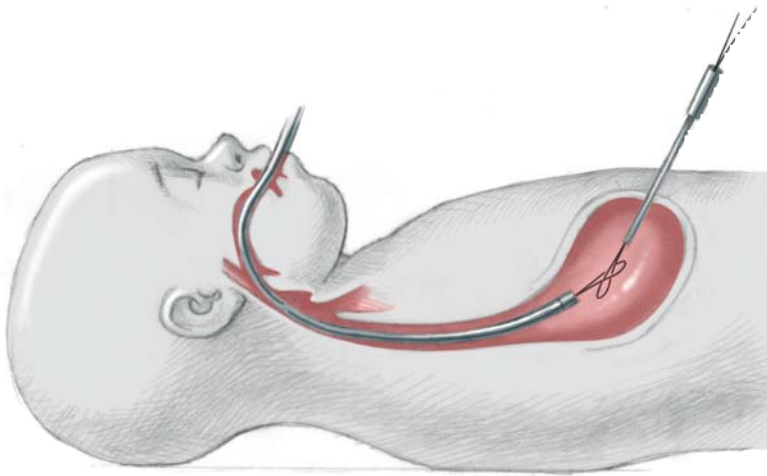


Figure 19.13

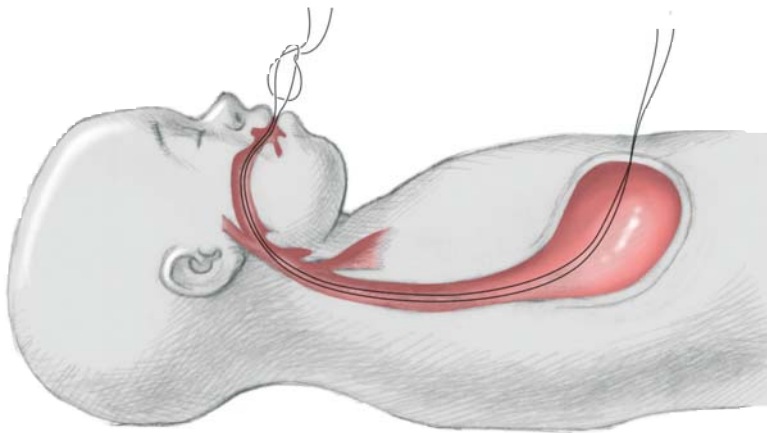


Figure 19.14, 19.15

The catheter is attached to the guide-wire by interlocking the two steel wire loops and lubricated. Traction is applied to the abdominal end of the guide-wire, guiding the catheter through oesophagus, stomach and across gastric and abdominal walls. With the age appropriate catheter, the gastric retainer collapses enough to slide through the oesophagus without producing injury (for diagrammatic purposes, a shortened catheter is shown). The commercially available catheters are long enough to permit the tapered end of the tube to exit through the abdominal wall before the gastric retainer enters the patient's mouth, allowing complete control of the catheter during placement. Traction is continued until the gastric and abdominal walls are in loose contact. The

markings on the catheter shaft help in judging the correct distance from mucosa to skin. The external crossbar is slipped over the catheter and guided to the skin level. The cross bar is advanced only enough to produce a good approximation of the gastric serosa to the abdominal peritoneum. Excessive approximation can lead to ischemia with tissue necrosis and embedding of the retainers. The catheter is cut to the desired length and the feeding adaptor is attached. No sutures are used and the catheter is connected to a small clear plastic trap. A dry gauze pad and tape are applied without kinking the tube. Alternatively, the catheter can be converted to a skin-level device with the changeable port-valve.

Figure 19.14

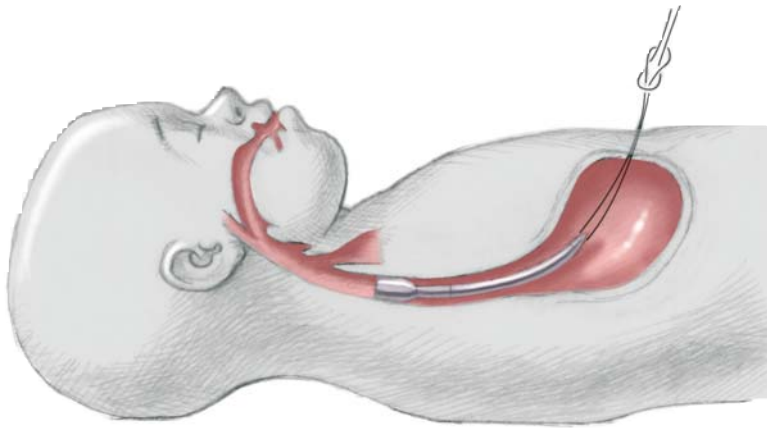
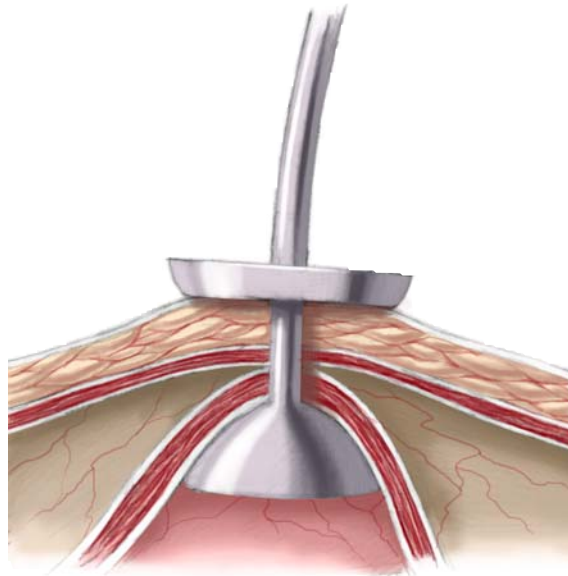


Figure 19.15



CONCLUSION

Enteral feedings are begun following an open gastrostomy once the ileus has resolved, and on the day after the operation following a PEG or a laparoscopic gastrostomy. Although it has been shown that enteral feedings following PEG can be started as early as a few hours post-procedure, we have maintained the original, more conservative approach. The dressing is removed after 24–36 h, the wound is examined and the external retaining crossbar loosened if necessary. Thereafter, the wound is cleaned with mild soap and water only. Granulation tissue tends to form after a few weeks and is controlled with silver nitrate sticks. If excessive, the area is anaesthetized locally, the granulation tissue excised and the tract cauterized. If the problem is recurrent, we have had good results with a cream containing a mixture of topical steroid and an anti-fungal. The abnormal growth ceases once the skin rim grows inward creating a lined gastro-cutaneous tract. If a long catheter needs to be removed in order to be replaced by another catheter or a skin-level device other than the port-valve, this manoeuvre should be done with great care. This is particularly true for the initial change following a PEG. The time required to form a firm adherence between the gastric serosa and the abdominal wall peritoneum following percutaneous techniques, varies. We have used 3 months as a guideline, but shorter periods may be adequate, provided appropriate safeguards are used. Patients on steroids or children with cyanotic heart disease are at particular risk of separation during early catheter change.

■ **Complications.** Although generally considered a basic procedure, gastrostomy is associated with a long list of complications related to technique, care and catheter use. Serious technique-related problems include separation of the stomach from the abdominal wall, wound separation, haemorrhage, infection, injury to the posterior gastric wall or other organs, and placement of the tube in an inadequate site. The most common and potentially lethal complication is early complete or partial gastric separation. If the stomach was initially secured to the abdominal wall as in the Stamm procedure or secured with T-fasteners (advocated by some surgeons managing adults as

a supplement in the introducer-type PEG technique), it is acceptable to insert a balloon-type catheter in the stomach and obtain an immediate water-soluble contrast study to ascertain the correct position. However, if no fixation was used, as in the case of the described PEG, a more aggressive approach is needed and a celiotomy usually indicated. Laparoscopy may be used as a safe alternative. A re-do PEG alternative has also been described. Fortunately, accidental PEG catheter removal is very rare in children. Most separations stem from a catheter change. Pneumoperitoneum following a percutaneous gastrostomy is common but, fortunately, without sequelae.

One of the most troublesome long-term problems is severe leakage from the gastrostomy tract. Initially, this should be managed using conservative measures, such as using smaller catheters to allow the widened fistula to contract. If these fail, the stoma may be relocated using a simple non-endoscopic variation of the percutaneous endoscopic gastrostomy. A new stoma site is selected and a small incision made. A large curved needle is placed through the leaking stoma, exiting through the new site. The suture is pulled through, establishing a tract. The catheter follows the tract, entering through the malfunctioning stoma and exiting through the new one. Once the catheter is in place – as following the described pull PEG here – the leaking stoma is closed extraperitoneally.

If a long-standing gastrostomy is no longer needed, the gastric access device is simply removed. If the tract is roughly less than 1 year old, it will usually close fully spontaneously. However, well-established, skin- and mucosa-lined older gastro-cutaneous fistulae will continue to drain. Simple, extraperitoneal excision of the tract with a few sutures in the fascia, subcutaneous layer and skin suffice to close the communication.

■ **Follow-up.** All children with gastrostomies must be carefully followed to prevent long-term gastric access device-related complications and monitored for adequate nutritional management as well as manifestations of foregut dysmotility, particularly gastroesophageal reflux.

Figure 22.1

Gauderer MWL (2002) Percutaneous endoscopic gastrostomy and the evolution of contemporary long-term enteral access [Review]. *Clin Nutr* 21:103–110

Gauderer MWL, Stellato TA (1986) Gastrostomies: evolution, techniques, indications, and complications [Monograph]. *Curr Probl Surg* 23:658–719

Gauderer MWL, Ponsky JL, Izant RJ Jr (1980) Gastrostomy without laparotomy: a percutaneous endoscopic technique. *J Pediatr Surg* 15:872–875

Gauderer MWL, Abrams RS, Hammond JH (1998) Initial experience with the changeable skin-level port-valve: a new concept for long-term gastrointestinal access. *J Pediatr Surg* 33:73–75

Sampson LK, Georgeson KE, Winters DC (1996) Laparoscopic gastrostomy as an adjunctive procedure to laparoscopic fundoplication in children. *Surg Endosc* 10:1106–1110

Vanek VW (2003) Ins and outs of enteral access. Part 2 – long-term access – esophagostomy and gastrostomy [Review]. *Nutr Clin Pract* 18:50–74

INTRODUCTION

Malrotation is congenital abnormal positioning of the midgut. Intestinal development is traditionally described as a process of elongation, rotation and fixation. The process begins in the fifth week of gestation. Elongation of the bowel exceeds abdominal cavity expansion and the bowel herniates from the abdomen. As the bowel returns to the abdomen, it rotates 270° anticlockwise around the superior mesenteric artery (SMA). Rotation is completed by week 10 of gestation, with the SMA contained within a broad mesenteric base attachment. The distal duodenum comes to lie across the midline towards the left upper quadrant, attached by the ligament of Treitz at the duodeno-jejunal (D-J) flexure to the posterior abdominal wall. The caecum passes to the right and downwards and becomes fixed to the posterior abdominal wall. This latter process may be incomplete at birth giving rise to a “high” caecum, a variant of normal in the neonate.

The commonest features of malrotation are: (1) the D-J flexure lies right of midline, (2) the dorsal mesenteric attachment is narrow, and (3) peritoneal folds cross from colon and caecum to duodenum, liver and gallbladder (Ladd’s bands), thus possibly obstructing the duodenum. Whether Ladd’s bands are substantial enough to cause mechanical obstruction is debatable. The narrowed mesenteric base can lead to midgut volvulus, bowel obstruction and mesenteric vessel occlusion. Antenatal volvulus can result in bowel atresia.

Malrotation is estimated from autopsy studies to occur in 0.5–1% of the population, although only 1 in 6000 live births will present with clinical symptoms. Incidence is slightly higher in males than females. Fifty to 75% of patients become symptomatic in the first month of life and 90% will present before 1 year of age but presentation can occur at any age. Malrotation is present in patients with gastroschisis, exomphalos and congenital diaphragmatic hernia. Coexistent congenital anomalies (cardiac anomalies, bowel atresia, duodenal web, anorectal anomalies, orthopaedic anomalies) are common and affect 50% of children with malrotation. Malrotation is also asso-

ciated with situs inversus, asplenia and polysplenic syndromes.

Acute bowel obstruction due to Ladd’s bands or intermittent midgut volvulus can present with vomiting, typically bilious, as the commonest presenting feature accompanied by colicky abdominal pain and abdominal distention. An infant with abdominal tenderness and blood per rectum is suggestive of bowel ischaemia due to midgut volvulus. Older children without acute volvulus more often present with chronic episodic obstructive symptoms, failure to thrive, malabsorption, diarrhoea and non-specific colicky abdominal pain. Up to 10% of diagnoses of malrotation are made as an incidental finding.

Plain abdominal radiograph is often normal but features suggestive of malrotation with or without midgut volvulus are a distended stomach and proximal duodenum with a paucity of gas distally, either throughout or unilaterally. An upper gastrointestinal contrast study is the investigation of choice for any child presenting with bilious vomiting and should be performed urgently. Findings in malrotation are: (1) D-J flexure right of left vertebral pedicle and/or inferior to pylorus, (2) the duodenum passes caudally and anteriorly, and (3) contrast tapering or a “corkscrew” appearance suggests obstruction and/or volvulus.

In a recent series, sensitivity and specificity of this test were 92% and 20%, respectively. Caecal position is highly variable and may be normal in up to 15% of cases of malrotation. Contrast enema is therefore not always helpful.

Abdominal ultrasound may show reversal in the relationship of SMA to superior mesenteric vein (SMV). In a normal situation the SMV is located to the right of the SMA, while SMV to the left of the artery is suggestive of malrotation.

All symptomatic patients with positive investigative findings should undergo urgent laparotomy. Management of the asymptomatic patient is more controversial. The risk of bowel ischaemia due to midgut volvulus is invariably present and the majority of surgeons would proceed to prompt operation.

Figure 20.1

The principles of the procedure have remained almost unchanged since originally described by Ladd in 1936. The patient is positioned supine, legs extended. A right upper quadrant transverse incision is made. The umbilical vein is divided and ligated. The

peritoneal fluid is examined. Frequently it is clear; bloodstained fluid implies bowel ischaemia and volvulus; faecal staining indicates bowel perforation and should be cultured.

Figure 20.2, 20.3

The midgut is delivered from the wound and the base examined. Any volvulus should be derotated anti-clockwise, noting the number of turns. The bowel is examined for viability and any ischaemic bowel should be wrapped in a damp swab and re-examined after 5–10 min. Non-viable bowel is resected and a

primary anastomosis formed. If extensive ischaemic bowel of doubtful viability is present, a second-look laparotomy is performed after 24 h with the aim of minimizing the extent of bowel resection required. Ladd's bands are divided.

Figure 20.1

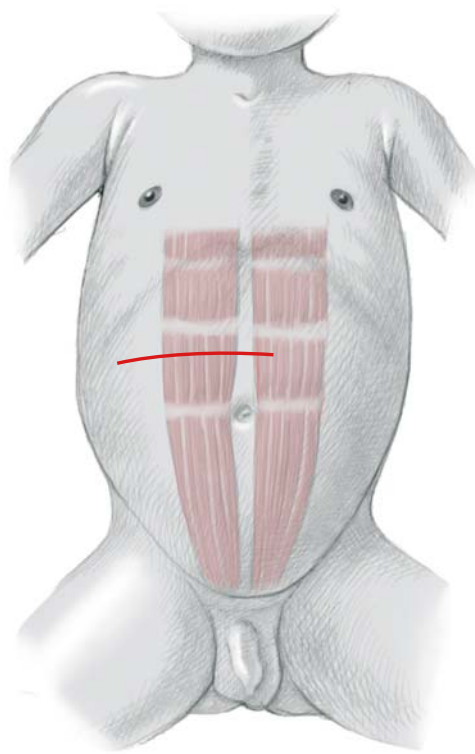


Figure 20.2

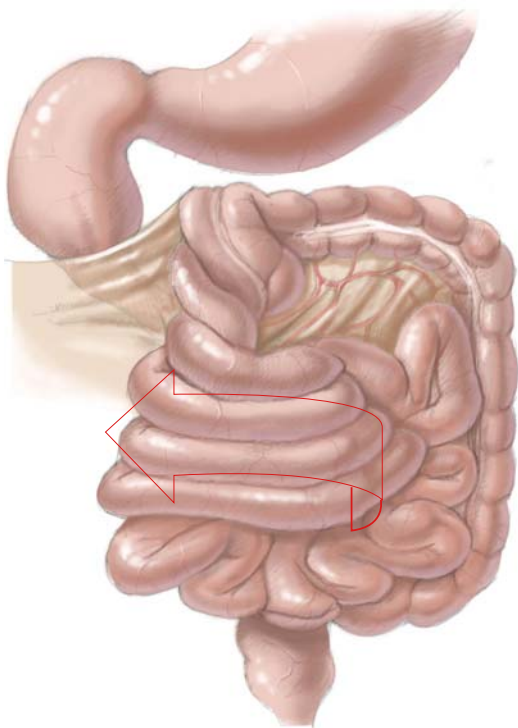


Figure 20.3

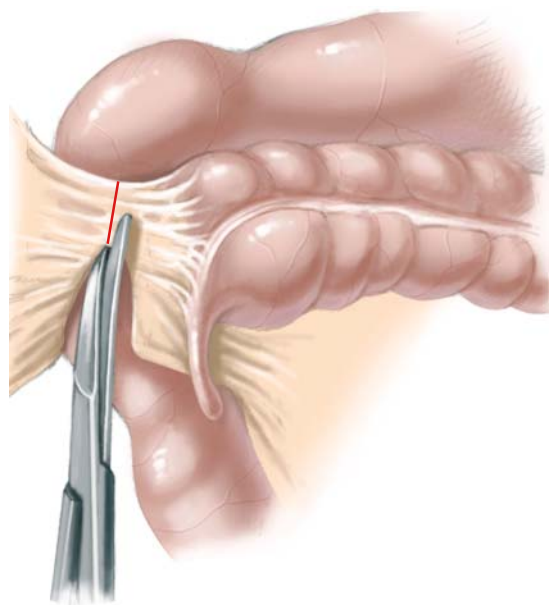


Figure 20.4

The SMA is identified and mesenteric base broadened as much as possible by division of the peritoneal folds. Care must be taken not to injure the superior mesenteric vessels. The abnormal position of the appendix may cause diagnostic problems in future and, therefore, removal is advocated. The bowel is replaced with the duodenum to the right and the caecum in the left upper quadrant. The abdomen is

closed. The nasogastric (NG) tube is aspirated hourly for the first 24 h. Intravenous fluids are continued postoperatively and NG tube fluid loss is replaced, millilitre for millilitre, with normal saline and potassium chloride (20 mmol/l saline). Enteral feeds are restarted when aspirates are clear and reducing in volume, usually after 24 h.

Figure 20.5

Laparoscopy may be used in non-acute cases of malrotation without volvulus, e.g., in incidentally diagnosed malrotation. The patient is positioned supine with the legs abducted. The surgeon stands between the patient's feet with the assistant to the left of the patient. The umbilical port is placed first. A periumbilical incision is made. The midline fascia is held in two arterial clips, one on either side of the midline. The linea alba is divided and a 5- or 10-mm port placed into the abdominal cavity under direct vision. The port is secured with a purse-string and the ends of the sutures attached to an anchor on the port. Carbon dioxide is insufflated via the port until a final intra-abdominal pressure of 8–10 mmHg is reached in an infant, or 10–12 mmHg in an older child. During insufflation the abdomen is palpated and percussed to ensure adequate pneumoperitoneum is achieved. The flow rate of carbon dioxide is set between 0.5 and 1.5 l/min. The laparoscope is then inserted into this port. Two further 5-mm ports are placed under direct camera vision – left lower quadrant and right lower quadrant. Non-traumatic grasping forceps are inserted into these ports to manipulate the bowel.

Figure 20.6

The anatomy is defined and Ladd's bands identified. Care must be taken to correctly identify landmarks such as the duodenum and ascending colon. To gain access to the duodenum, it is useful to raise the head of the operating table and elevate the right flank. The ascending colon falls towards the left side of the abdomen. The duodenum is exposed and Ladd's bands are divided using either an ultrasonic blade or a combination of sharp dissection and electrocautery. After division, the bowel is examined along its length for any further causes of obstruction. The root of the mesentery is broadened by dividing the peritoneal folds. Care must be taken not injuring the superior mesenteric vein. Appendicectomy is carried out either using an endoloop for intracorporeal ligation or by delivering the appendix through a trocar site and excising it extra-abdominally in smaller patients. Trocar sites are closed.

Figure 20.4

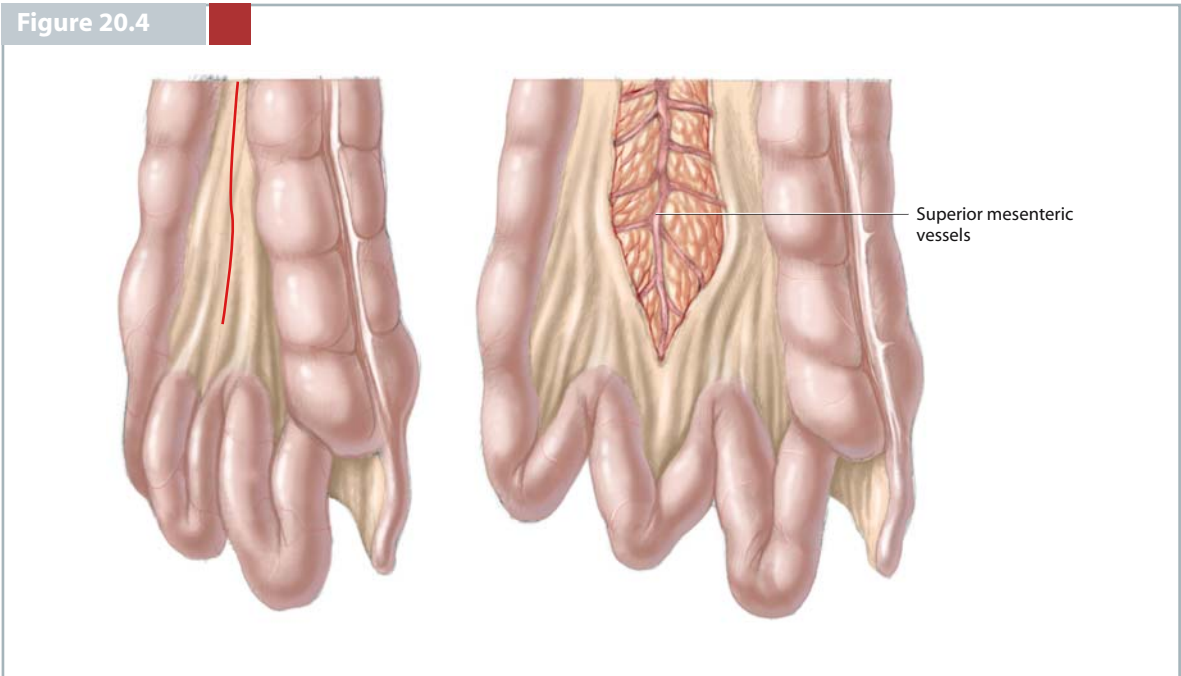


Figure 20.5

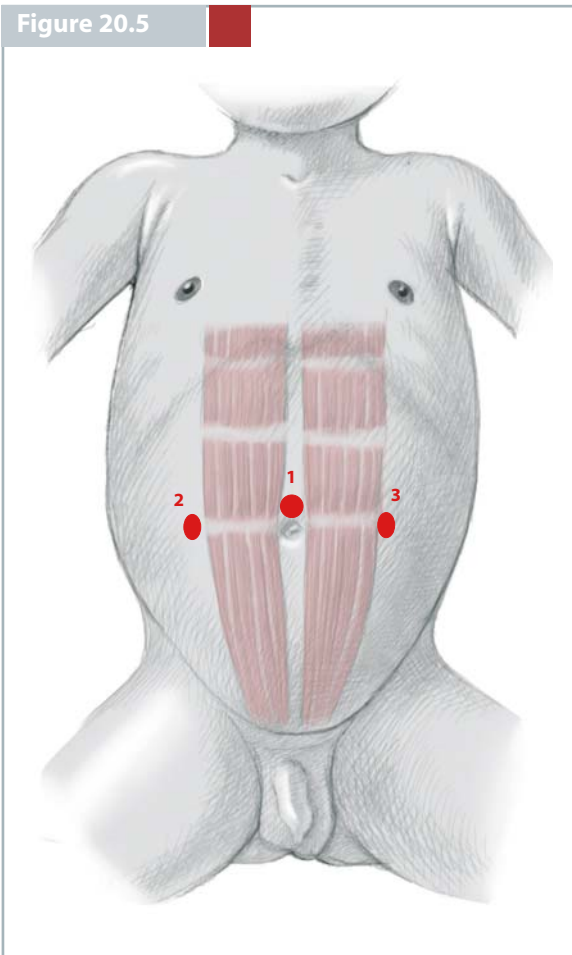
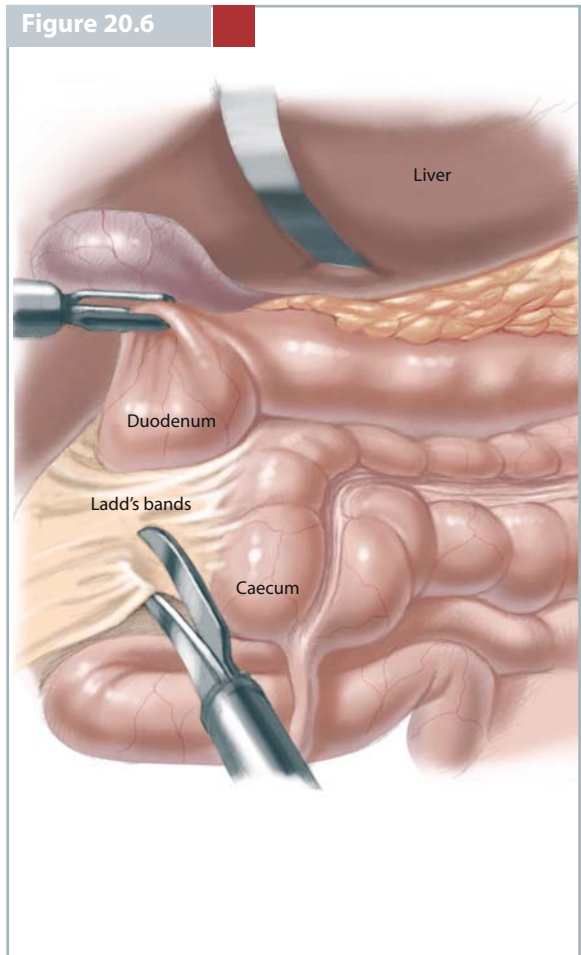


Figure 20.6



CONCLUSION

The outcome of patients undergoing Ladd's procedure for isolated malrotation is very good and the majority make a full recovery. The commonest post-operative complication is adhesional obstruction (3–5%). Midgut volvulus occurs in 45–65% of children with malrotation and still carries a mortality

rate of 7–15%; necrosis of more than 75% of the midgut is associated with short bowel syndrome. Up to 18% of children with short bowel syndrome on long term total parenteral nutrition have an original diagnosis of midgut volvulus.

SELECTED BIBLIOGRAPHY

- Bass KD, Rothenberg SS, Chang JH (1988) Laparoscopic Ladd's procedure in infants with malrotation. *J Pediatr Surg* 33: 279–281
- Clark LA, Oldham KT (2002) Malrotation. In: Ashcraft KW, Murphy JP, Sharp RJ, Sigalet DL, Snyder CL (eds) *Pediatric surgery*, 3rd edn. WB Saunders, Philadelphia, pp 425–434
- Kluth D, Fiegel H (2003) The embryology of foregut. *Semin Pediatr Surg* 12: 3–9
- Prasil P, Flageole H, Shaw KS, Nguyen LT, Youssef S, Laberge JM (2000) Should malrotation in children be treated differently according to age? *J Pediatr Surg* 35: 756–758
- Spitz L (2003) Malrotation. In: Puri P (ed) *Newborn surgery*. Arnold, London, pp 435–439

Yechiel Sweed

INTRODUCTION

Congenital duodenal obstruction is the result of several embryologic defects in foregut development, canalization or rotation. In addition, abnormal embryologic relationships between the duodenum and other structures in close anatomic proximity such as pancreas and portal vein may also lead to congenital duodenal obstruction.

Ladd classified these lesions as either intrinsic or extrinsic. Intrinsic lesions include duodenal atresia, duodenal stenosis or duodenal web, whereas annular pancreas, malrotation, peritoneal bands and anterior portal vein are classified as extrinsic.

The incidence of duodenal obstruction is reported to be 1 in 5,000 to 10,000 births. There is a high incidence of associated anomalies in patients with intrinsic duodenal obstruction, especially Down's syndrome that occurs in about 30% of these patients. Other associated anomalies include: congenital heart disease, malrotation, annular pancreas, oesophageal atresia, urinary tract malformations, anorectal anomalies and other bowel atresias.

The diagnosis of duodenal obstruction may be suspected prior to the child's birth by prenatal ultrasonography. It may identify maternal polyhydramnios and demonstrate distension of the stomach and the first portion of the duodenum with swallowed amniotic fluid.

Although prenatal ultrasonography is an accurate predictor of duodenal obstruction and allows preparation of parents, physicians, and institutions for the anticipated arrival of the patient needing prompt care at birth, it has neither influenced the incidence of associated life-threatening anomalies nor changed the survival rate.

The clinical presentation of duodenal obstruction is usually characterized by feeding intolerance and by onset of vomiting in the first 24 to 48 h of life. Since 80% of obstructions are located in the postampullary region of the duodenum, vomitus in the majority of cases is bile stained. A careful physical evaluation for associated anomalies is performed. Cardiac and renal ultrasonographic examinations are al-

so indicated because of the high incidence of associated malformations in other organ systems.

Diagnosis is achieved in most cases by plain abdominal radiographs, which demonstrate dilated stomach and duodenum, giving the characteristic appearance of a "double-bubble" sign. No gas is observed beyond the second bubble in instances of complete obstruction. In this setting, the plain film is sufficiently diagnostic so that no further imaging of the gastrointestinal tract is necessary. In partial duodenal obstruction a plain film of the abdomen will show a double-bubble appearance but there is usually some air in the more distal intestine. Early upper gastrointestinal contrast radiography is indicated in these patients in order to establish the cause of incomplete duodenal obstruction.

Although duodenal atresia is a relative emergency, the infant should not be rushed to the operating room until his haemodynamic and fluid and electrolyte status is stable. If the clinical history and findings on physical examination indicate that the baby is in no distress, and the radiograph is consistent with the usual presentation of duodenal atresia with no air beyond the second bubble, surgery should be performed within the first 2 days of life. However, in patients with duodenal obstruction caused by malrotation resulting in extrinsic compression related to Ladd's bands across the duodenum, or to acute volvulus of the midgut, an immediate surgical exploration should be performed.

Incomplete duodenal obstruction may lead to delayed onset of symptoms, and the diagnosis of duodenal diaphragm with a central aperture is sometimes delayed for months or years.

Pre-operative management consists of nasogastric decompression and fluid and electrolyte replacement. Care is taken to preserve body heat and avoid hypoglycaemia, since most of these newborn patients are premature or small for date. Pre-operative systemic antibiotics are administered at least 30 min prior to the start of the operation.

Figure 21.1

The baby is placed supine on the table with a small roll under his upper abdomen and on a warming blanket. Endotracheal anaesthesia is used. A nasogastric tube is passed to decompress the stomach. An intravenous infusion is set up. The abdominal skin is prepared by cleaning with prewarmed povidone-iodine.

A transverse supra-umbilical abdominal incision is made 2 cm above the umbilicus starting in the

midline and extending laterally into the right upper quadrant. A small incision is made in the posterior fascia and peritoneum after these are drawn up with forceps. To enlarge this initial incision, two fingers are inserted and the fascia and peritoneum are cut along the length of the wound. The underlying structures are retracted.

Figure 21.2

After exposing the peritoneal cavity, the surgeon inspects the entire bowel for the presence of other anomalies. There may be an associated annular pancreas or malrotation in one-third of the patients. If the colon is in a normal position, malrotation is probably not a coexisting factor.

The stomach and first portion of the duodenum are usually thickened and dilated. The liver is carefully retracted superiorly. The ascending colon and the hepatic flexure of the colon are mobilized medially and downwards to expose the dilated duodenum.

The duodenum is then adequately mobilized and freed from its retroperitoneal attachments – Kocher manoeuvre. Great care must be exercised not to dissect or manipulate either segment of the duodenum medially, to avoid injury to the ampulla of Vater or the common bile duct. The tube in the stomach is

then passed distally into the dilated duodenum and helps to locate the point of obstruction and determine if a “windsock” abnormality is present.

The type of atresia as well as any pancreatic abnormality (annular pancreas) or the presence of a rare preduodenal portal vein are noted. In patients with an annular pancreas, the pancreatic tissue should never be divided and should be bypassed. The duodenum distal to the site of obstruction is small and decompressed. The requirements for distal mobilization vary according to the location of the atresia and to the gap between the two segments. If necessary, the ligament of Treitz is divided, and mobilization and displacement of the distal duodenum is performed behind the superior mesenteric vessels, thus allowing a satisfactory anastomosis to be performed without any tension.

Figure 21.1

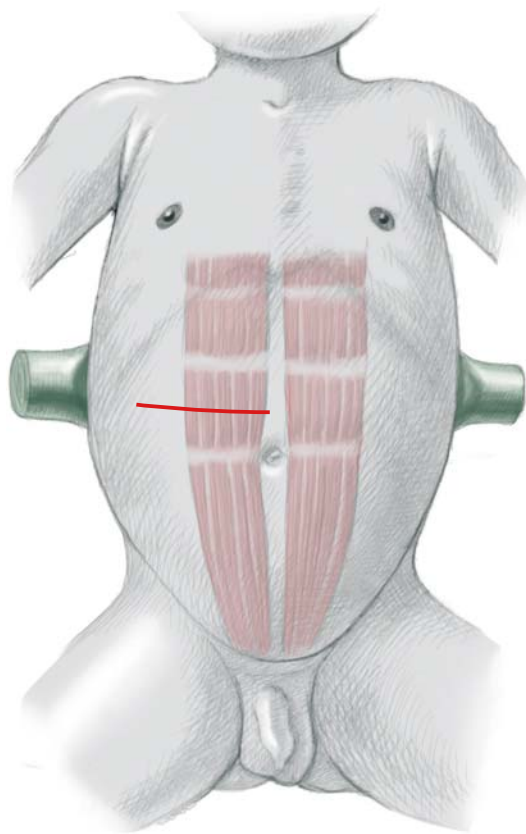


Figure 21.2

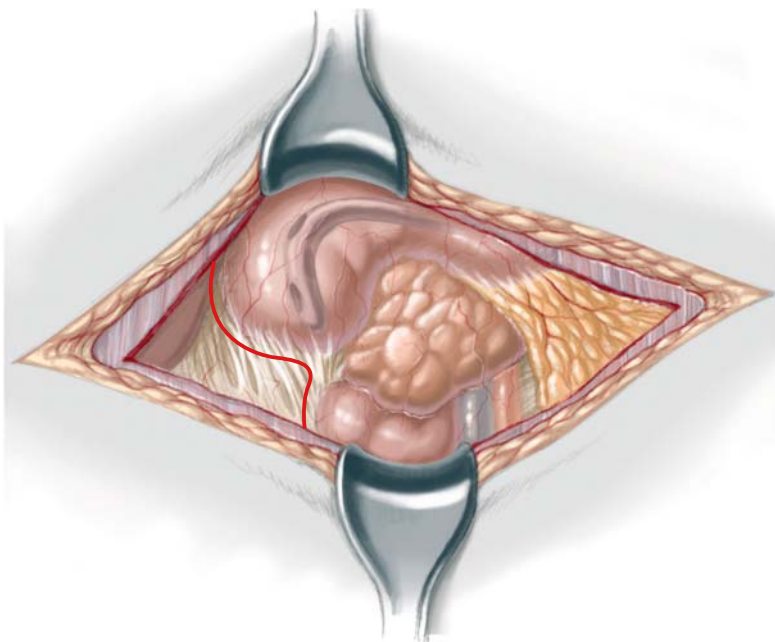


Figure 21.3, 21.4

Duodenoduodenostomy is the procedure of choice for patients with duodenal atresia, stenosis and annular pancreas. The two surgical techniques, either side-to-side duodenoduodenostomy or proximal transverse to distal longitudinal – “diamond-shape” anastomosis – may be performed. Diamond-shaped duodenoduodenostomy has been reported to allow earlier feeding, earlier discharge and good long-term results. With two traction sutures, the redundant wall of the proximal duodenum is pulled downward to overlie the proximal portion of the distal duodenal segment. A transverse incision is made in the distal end of the proximal duodenum and a longitudinal incision is made in the smaller limb of the duodenum

distal to the occlusion. These are made in such a position as to allow good approximation of the openings without tension. The papilla of Vater is located by observing bile flow. This is performed by gentle compression of the gall bladder.

The orientation of the sutures in the diamond-shape anastomosis and the overlapping between the proximal transverse incision and the distal longitudinal incision are shown. At this stage a small Nelaton catheter is passed distally through the opening made in the distal segment. 20–30 ml of warm saline is injected to rule atresias distally. The catheter is then removed.

Figure 21.3

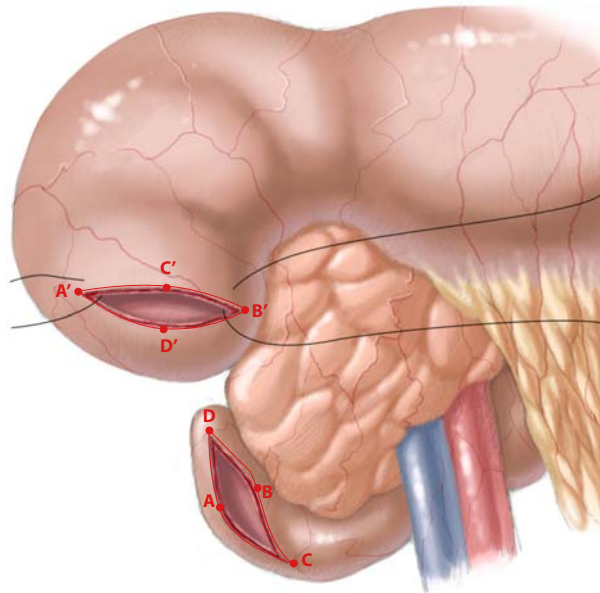


Figure 21.4

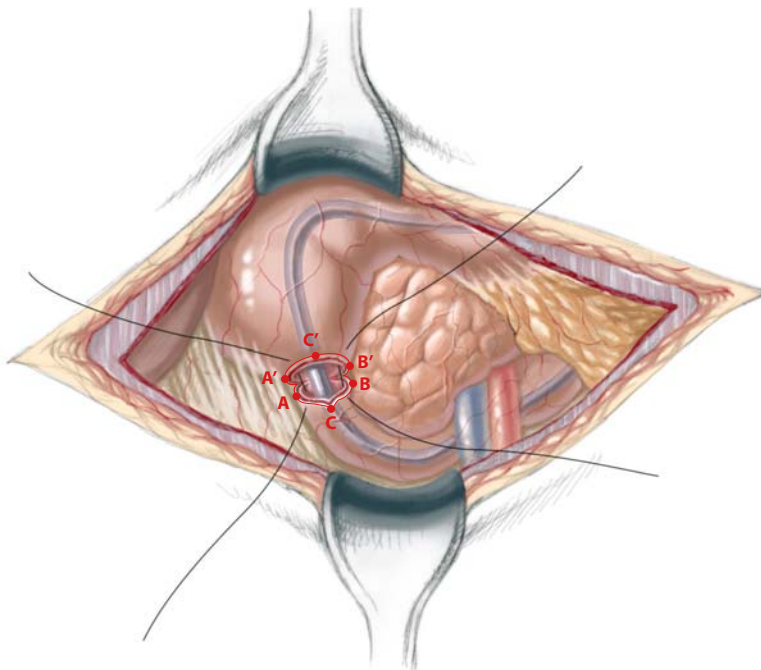


Figure 21.5

A single layer anastomosis using interrupted 5/0 or 6/0 Vicryl sutures with posterior knots tied inside the posterior wall of the anastomosis and interrupted sutures with anterior knots tied outside the anterior wall. Before completion of the anterior part of the anastomosis, a transanastomotic feeding tube (5F silicone) may be passed down into the upper jejunum for an early post-operative enteral feeding.

Figure 21.6

After abdominal exploration and the diagnosis of duodenal web (identified by the advancement of the gastric tube into the proximal dilated duodenum) two stay sutures are placed at the anterior dilated duodenal wall. A longitudinal incision of 2.5–3 cm is performed above the “transitional zone” between the wide and the narrow segments of the duodenum, and the duodenum is opened.

Figure 21.5

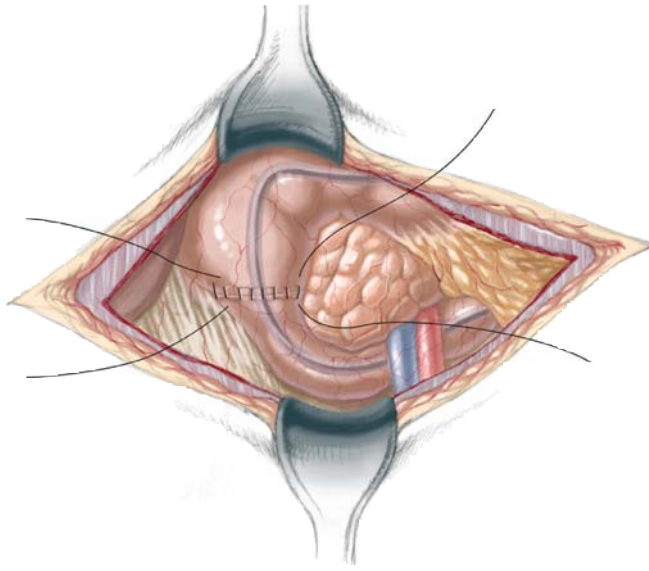


Figure 21.6

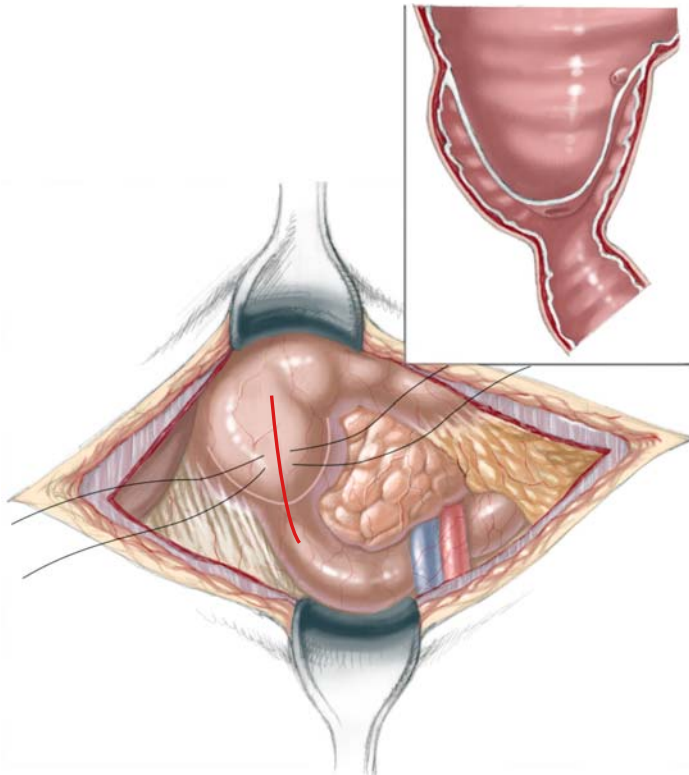


Figure 21.7, 21.8

Two other stay sutures are placed at the margins of the duodenal incision. The windsock duodenal web must be clearly identified because the visible transition from the distended proximal duodenum to the small downstream duodenum may be several centimetres distal to the base of the web. Traction applied at the apex of the web deforms the duodenum at its point of attachment and allows excision at the base.

The duodenal membrane is usually localized in the second part of the duodenum and occasionally in the third portion. It can be complete or with a central hole. Anatomically, the ampulla of Vater may open directly into the medial portion of the web itself – anteriorly, posteriorly, or with dual openings into the membrane – or it may open close to it.

Thus, the close relationship of the membrane to the papilla of Vater makes its identification mandatory, before excision of the web.

A single 4/0 Vicryl stay suture is placed at the centre of the membrane. The web is opened along the lateral side of the membrane and excision from the duodenal wall takes place, leaving a rim of tissue of 2–3 mm. The medial portion of the membrane should remain intact, thus avoiding damage to the ampulla of Vater. An intermittent bile flow is usually seen via the papilla of Vater indicating to the surgeon the exact line of excision.

Figure 21.9

Then the resection line is over sewn using interrupted 5-0 absorbable sutures. The duodenum is then closed transversely with interrupted sutures. Because of the pitfalls in cases of lax membrane that may bulge downwards distally into the distended duodenum (the so-called windsock phenomenon), and in order to avoid missing the anomaly, the patency of the distal duodenum must be identified by inserting a catheter through the duodenotomy before its closure. Following completion of the web resection and closure of the duodenum, the abdominal cavity is irrigated with 50 ml sterile warm saline. The wound is closed in layers: the peritoneum and the posterior fascia and the anterior fascia by two layers using continuous 4/0 Dexon or Vicryl sutures. The skin is closed with a running intracuticular suture using 5/0 Vicryl or Dexon suture.

A nasogastric tube is left in place for post-operative gastric drainage. A gastrostomy may be performed if the need is anticipated. Intravenous therapy and antibiotics are continued post-operatively. The patient is kept without oral intake until stool is passed and limited clear or pale-green gastric drainage is noted (<1 ml/kg per h). The commencement of oral feeding may be delayed for several days and occasionally for 2 weeks or more. Post-operatively, patients may have a prolonged period of bile-stained aspirate, which is mainly due to the inability of the markedly dilated duodenum to produce effective peristalsis. Many surgeons therefore use transanastomotic tubes for feeding in the early post-operative period.

Figure 21.7

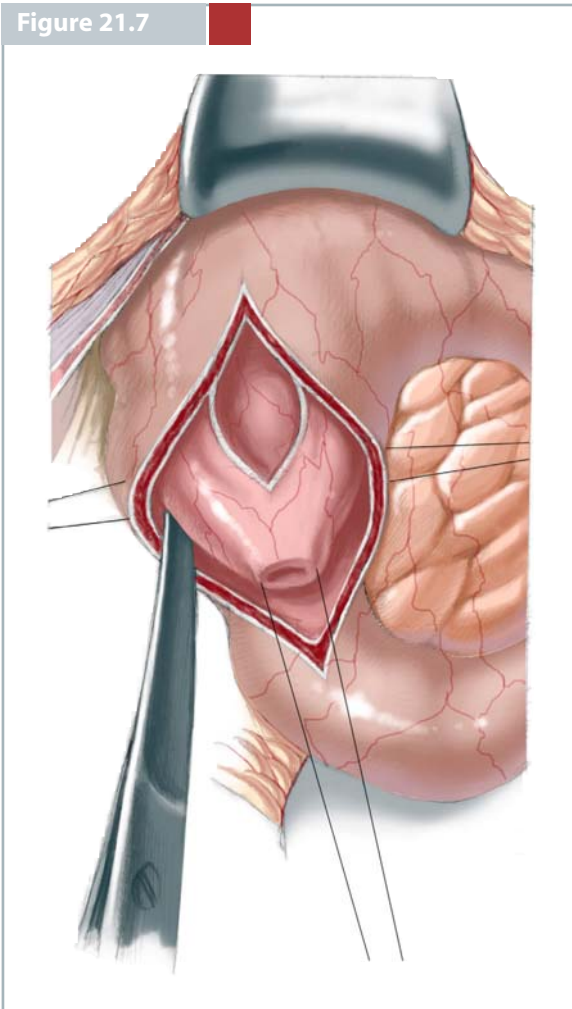


Figure 21.8

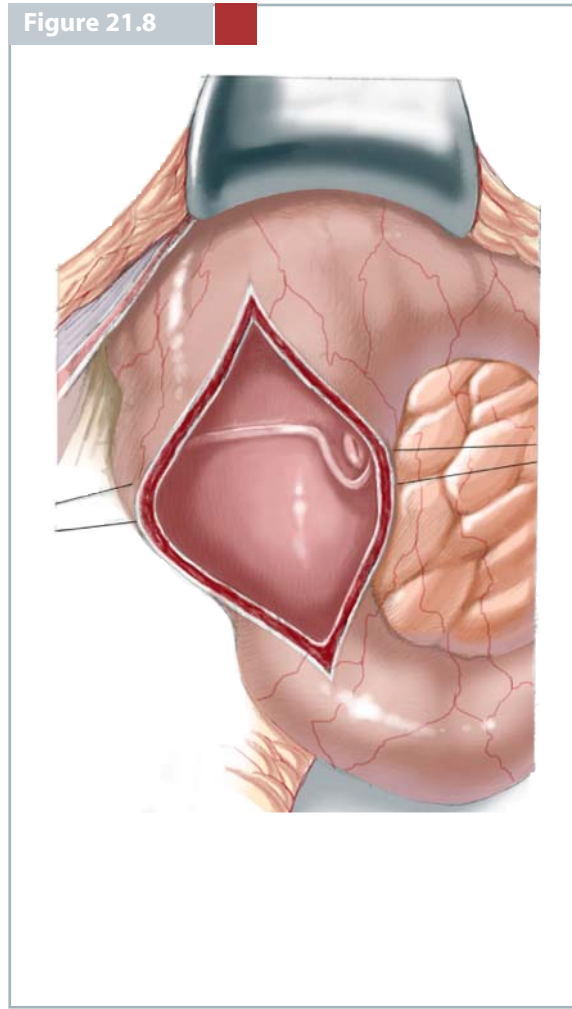
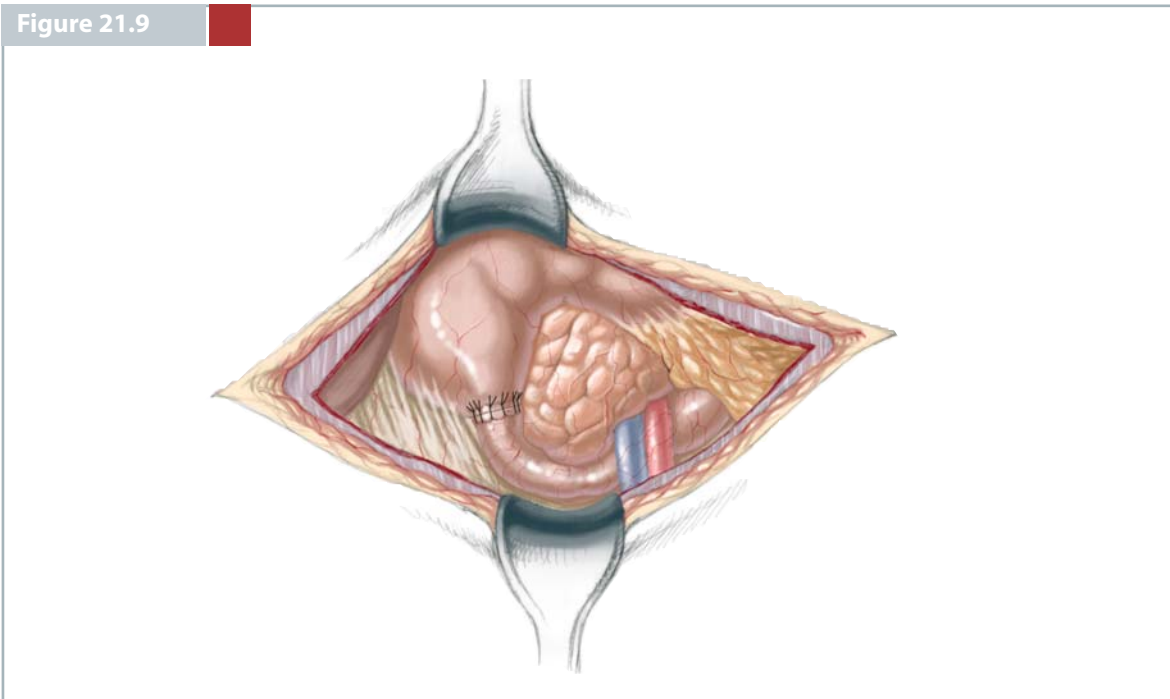


Figure 21.9



CONCLUSION

Long-term outcome after repair of congenital duodenal obstruction is excellent with contemporary operative survival exceeding 95% and with the majority of patients reported as asymptomatic and with normal growth.

The main factors contributing to the mortality in patients with duodenal obstruction are a high incidence of associated anomalies, prematurity and low birth weight. The associated complex cardiac defects continue to be the leading cause of death in particular in infants with trisomy 21. However, recent reviews document that advances in both paediatric cardiology, and cardiac surgery in neonates and infants have reduced this mortality significantly.

Early post-operative complications include anastomotic obstruction, continuing obstruction due to missed anomalies, leakage at the anastomosis and prolonged adynamic ileus. Upper intestinal radiographic studies are necessary to reveal the source of the problem.

The late gastrointestinal complications include megaduodenum, duodenogastric reflux, gastritis, peptic ulcer and gastro-oesophageal reflux. Megaduodenum is a particularly troublesome problem, which may result either from anastomotic obstruction or from an inherent motility disorder of the proximal duodenum.

SELECTED BIBLIOGRAPHY

- Arnbjornsson E, Larsson M, Finkel Y (2002) Transanastomotic feeding tube after an operation for duodenal atresia. *Eur J Pediatr Surg* 12: 159–162
- Bailey PV, Tracy TFJ, Connors RH et al (1993) Congenital duodenal obstruction: a 32-year review. *J Pediatr Surg* 28: 92–95
- Kimura K, Mukohara N, Nishijima E et al (1990) Diamond-shaped anastomosis for duodenal atresia: an experience with 44 patients over 15 years. *J Pediatr Surg* 25: 977–979
- McCollum MO, Jamiesson DH, Webber EM (2002) Annular pancreas and duodenal stenosis. *J Pediatr Surg* 37: 1776–1777
- Sweed Y (2003) Duodenal obstruction. In: Puri P (ed) *Newborn surgery*. Arnold, London, pp 423–433

INTRODUCTION

Defects in the continuity of the small bowel can morphologically be divided into either stenosis or atresia and represent one of the most common causes of neonatal intestinal obstruction. Jejuno-ileal atresia has a prevalence rate of approximately 1:1000 live births, with a third of the infants being either born prematurely or small-for-date. The anomaly is rarely genetically determined and <1% of babies will have chromosomal or other associated anomalies.

Most jejuno-ileal atresias or stenoses result from a localized intra-uterine vascular insult to the developing bowel with ischaemic necrosis and subsequent reabsorption of the affected segment(s). Additional pathology in the form of intra-uterine fetal intussusception, malrotation and midgut volvulus, thromboembolic occlusions, transmesenteric internal hernias and incarceration or snaring of fetal bowel in a gastroschisis or exomphalos further supports the ischaemic hypothesis. The ischaemic insult also adversely influences the structure and subsequent function of the remaining bowel. Histological and histochemical abnormalities can be observed up to 20 cm cephalad from the end of the atretic proximal segment. The distal bowel is unused and potentially normal in function.

Prompt recognition of intestinal atresia is essential for the early institution of management. A prenatal history of polyhydramnios and ultrasonography showing dilated and obstructed fetal intestine are strong indicators of congenital intestinal atresia. A positive family history will help to identify hereditary forms. Postnatally, intestinal atresia or stenosis may present initially with large intragastric volumes at birth (>20 ml gastric aspirate) followed by persistent bile-stained vomiting. In 20% of children symptoms may be delayed for more than 24 h. Abdominal distension is frequently present from birth and the

more distal the obstruction the more generalized the abdominal distension. Proximal jejunal atresia often presents with gastric distension and one or two loops of visible bowel in the upper abdomen relieved by nasogastric tube aspiration. With delay in presentation increasing intraluminal pressure and/or secondary torsion of the proximal atretic distended bowel may lead to ischaemia, perforation and peritonitis.

The differential diagnosis includes midgut volvulus, intestinal stenosis, meconium ileus, duplication cyst, internal hernia, strangulated inguinal hernia, Hirschsprung's disease and ileus due to sepsis, birth trauma, maternal medications, prematurity or hypothyroidism.

The diagnosis of jejuno-ileal atresia can be established in most cases by an abdominal roentgenogram with air as contrast medium. Erect and supine abdominal radiographs show distended air and fluid filled loops of bowel.

The lower the obstruction the greater the number of distended loops of bowel and fluid levels that will be observed. Occasionally intraperitoneal calcification may be seen on the plain radiographs signifying intrauterine bowel perforation, meconium spill and dystrophic calcification. In the presence of complete obstruction a contrast enema is usually performed to confirm the level of obstruction and document the calibre of the colon, exclude colonic atresia, and to locate the position of the caecum as an indication of malrotation. With incomplete upper small bowel obstruction an upper gastrointestinal contrast study is indicated to demonstrate the site and nature of the obstruction and to exclude midgut volvulus.

The clinical and radiological presentation of jejuno-ileal stenosis will be determined by the level and degree of stenosis. The diagnosis is often delayed for years because of subclinical symptoms and findings.

Figure 22.1–22.3

The morphological classification of jejuno-ileal atresia into types I–IV has significant prognostic and therapeutic implications. The most proximal atresia determines whether it is classified as jejunal or ileal. Although single atresias are most commonly encountered, 6–12% of infants will have multiple atretic segments and up to 5% may have a second colonic atresia. The appearance of the atretic segment is determined by the type of occlusion, but in all cases the maximum dilatation of the proximal bowel occurs at the site of the obstruction and is often hypoperistaltic and of questionable viability when presentation is delayed.

- Stenosis (12%) is characterised by a short localized narrowing of the bowel without discontinuity or a mesenteric defect. The bowel is of normal length.
- Atresia type I (23%) is represented by a transluminal membrane or short atretic segment causing complete intestinal obstruction. The bowel remains in continuity, has no mesenteric defect, and is of normal length.
- Atresia type II (10%) has the blind-ending proximal bowel attached to the collapsed and underde-
- veloped distal bowel by a fibrous cord along the edge of the mesentery. The proximal bowel is distended and hypertrophied for several centimetres. There is no mesenteric defect and the bowel length is not foreshortened.
- Atresia type III(a) (16%) is similar to type II except that the fibrous connecting cord is absent and there is a V-shaped mesenteric defect. The bowel length may be foreshortened.
- Atresia type III(b) (apple peel) (19%) consists of a proximal jejunal atresia often with associated malrotation, absence of most of the superior mesenteric artery and a large mesenteric defect. The distal bowel is coiled in a helical configuration around a single perfusing artery arising from the right colic arcades. There is always a significant reduction in intestinal length. The infants are usually of low birth weight and may have associated anomalies.
- Atresia type IV (20%) represents multiple segment atresias like a string of sausages or a combination of types I–III. Bowel length is always reduced.

Figure 22.1

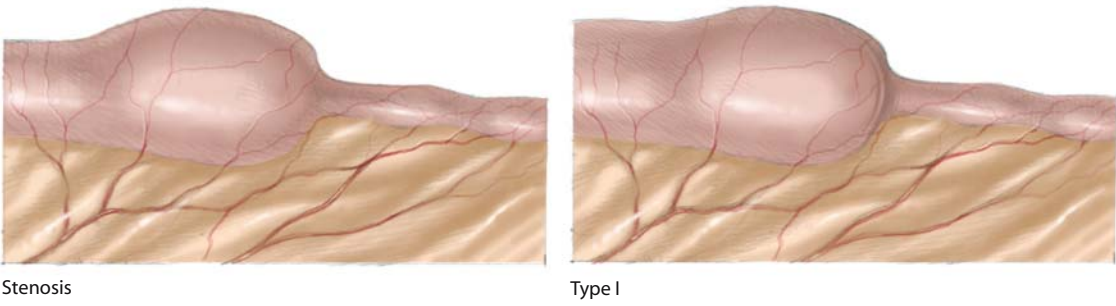


Figure 22.2

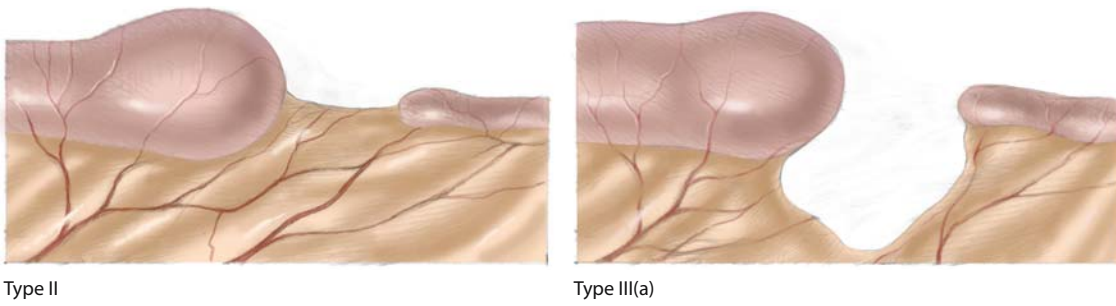


Figure 22.3

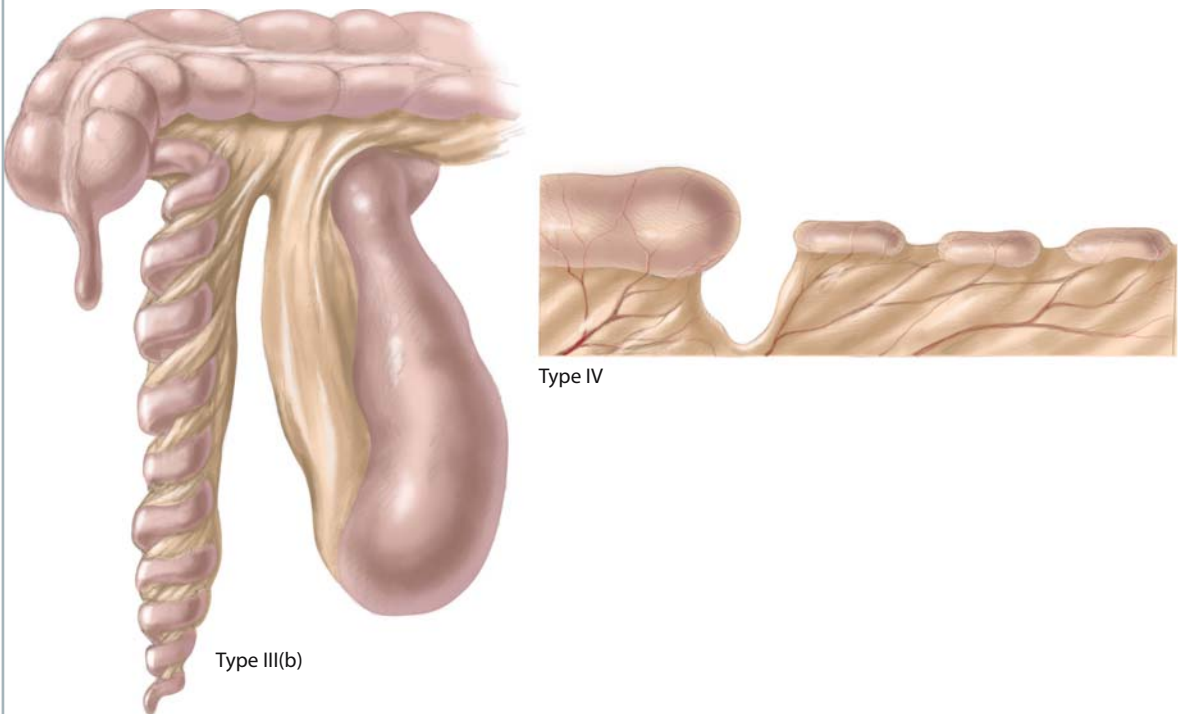


Figure 22.4

The infant is placed supine on a warming blanket and the exposed abdomen cleaned and sealed with plastic adherent drapes. Access to the abdominal cavity is obtained through an adequate transverse supra-umbilical incision transecting the rectus abdominis muscles. The ligamentum teres is divided between ligatures.

Exploration and basic surgical considerations: the small intestine can easily be exteriorised from the abdominal cavity by gentle pressure on the wound edges and manual delivery of the intestine. Anatomic-pathological findings will determine the operative procedure.

Steps in the operative procedures are:

- Identification of pathological type and possible aetiology.
- Confirmation of patency of distal small and large bowel with saline injection (patency of the colon could have been demonstrated by contrast enema prior to surgery).
- Resection of the proximal bulbous atretic segment.
- Volvulated bowel must be untwisted carefully, especially in type III(b) atresia.
- Limited distal bowel resection.
- Accurate measurement of residual bowel length proximal and distal to the anastomosis.
- Single-layer end-to-end or end-to-back anastomosis.
- Bowel lengthening procedures have no place during the initial surgery.
- Gastric decompression post-operatively is best achieved with a Replogle tube on low continuous suctioning. Neither decompression Stamm gastrostomy nor transanastomotic feeding tubes are recommended.
- The fashioning of proximal or distal stomas are only indicated in the presence of established peritonitis, or with compromised vascularity of the remaining intestine.
- Additional steps may include derotation of a proximal jejunal atresia, back resection to the distal second part of the duodenum and excision or inversion tapering of the duodenum if very dilated. Where total bowel length is significantly reduced (type III and type IV), the bulbous dilated segment proximal to the atresia is conserved. As prograde peristalsis of this bowel is deficient the lumen calibre should be reduced. Maximum mucosal conservation is achieved by inversion plication prior to anastomosis to the distal bowel.

Figure 22.5

■ **Detection of Distal Atretic Areas.** It is imperative to exclude distal atresia, which have a prevalence rate of 6–21%. This is best achieved with a preoperative barium enema to exclude an associated colonic atresia and by injecting saline into the distal collapsed small bowel and following the fluid column distally until it reaches the caecum.

■ **Bowel Length Measurement.** The total length of the small bowel is measured along the antimesenteric border. Once bowel resection has been completed, residual bowel length is of prognostic significance and may determine the method of reconstruction especially in types III and IV atresia. The normal bowel length at full term is approximately 250 cm and in the premature infant it is 115–170 cm.

Figure 22.4

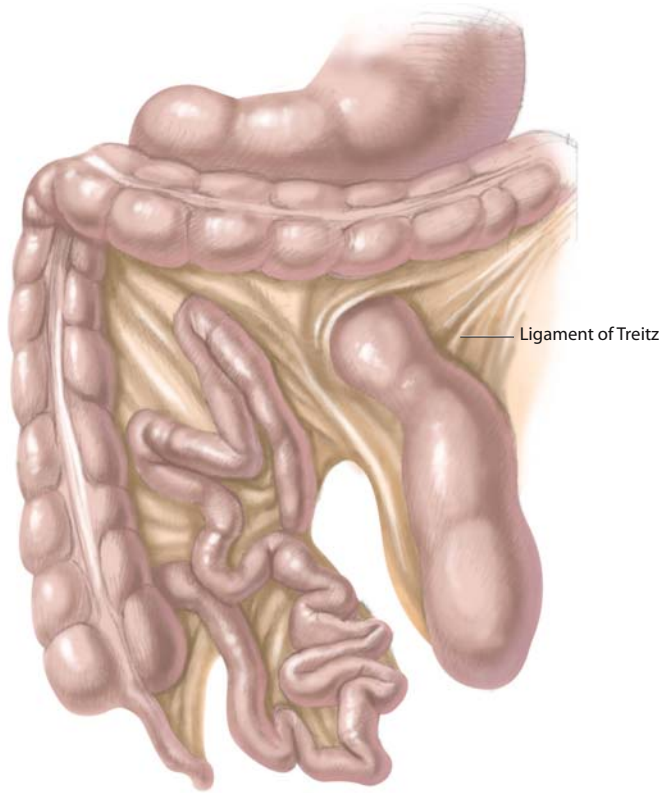


Figure 22.5

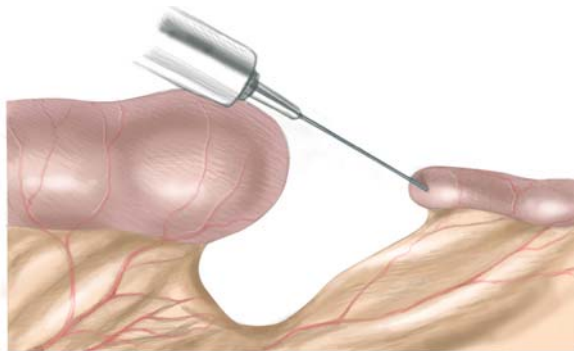


Figure 22.6

The atretic region and the adjacent distended proximal and collapsed distal bowel are isolated with sterile moist swabs. The intestinal content is milked backwards into the stomach from where it is aspirated and a bacteriology swab is sent for culture and sensitivity. Alternatively, proximal bowel contents are milked into the bulbous blind end if it is to be resected. An atraumatic bowel clamp is then placed across the bowel a few centimetres proximal to the elected site for transection.

If total bowel length is deemed of adequate length (>80 cm + ileocaecal valve) the bulbous hypertrophied proximal bowel is resected (5–15 cm) alongside the mesenteric bowel border in order to preserve maximal mesentery for later use, until normal diameter bowel has been reached. The bowel should then be divided at right angles leaving an opening of approximately 0.5–1.5 cm in width. The blood supply should be adequate to ensure a safe anastomosis. This is followed by very limited distal small bowel resection over a length of 2–3 cm. The resection line should be slightly oblique towards the antimesenteric border to ensure that the openings of the proximal

and distal bowels are of approximately equal size to facilitate easy axial or end-to-back (Denis-Browne) single-layer anastomosis. However, the discrepancy in luminal width of the proximal and distal bowel may vary from 2–5 cm depending on the distance from the stomach.

With type III(b) or high jejunal atresia the proximal bowel should be derotated and resection of the bulbous portion may be extended into the third or second part of the duodenum without jeopardizing the ampulla of Vater. The distal “apple peel” component of Type III(b) atresia may require release of restricting bands along the free edge of the distally coiled and narrow mesentery to avoid kinking and interference with the blood supply. The large mesenteric defect is usually left open but with proximal bowel resection the residual mesentery can be used to obliterate the defect. Furthermore, to prevent kinking of the marginal artery after completion of the anastomosis, the bowel needs to be replaced very carefully into the peritoneal cavity in a position of non-rotation.

Figure 22.7, 22.8

The anastomosis is either end-to-end or end-to-back (Denis-Browne method); 5/0 or 6/0 absorbable sutures stitches are used. The mesenteric border of the divided ends is united with a stay suture and a matching stitch is placed at corresponding points of the

anti-mesenteric borders of the divided ends. The “anterior” edges of the bowel are then united with interrupted through-and-through extramucosal stitches, which are tied on the serosal surface.

Figure 22.6

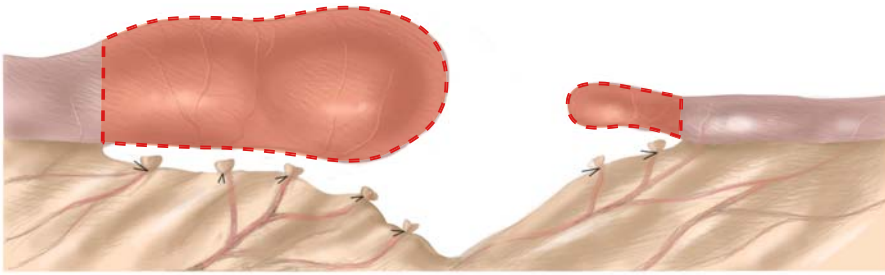


Figure 22.7

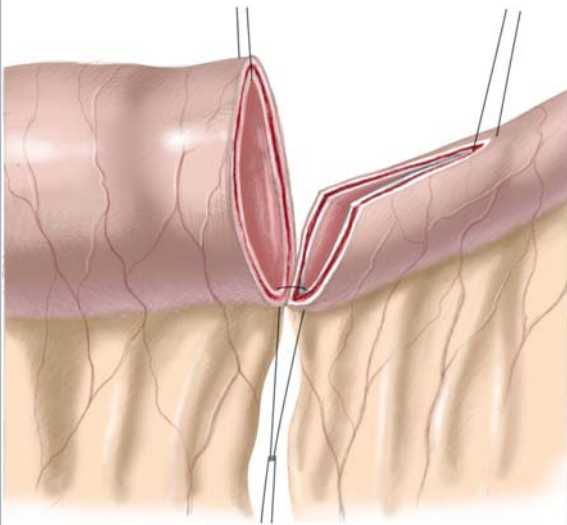


Figure 22.8

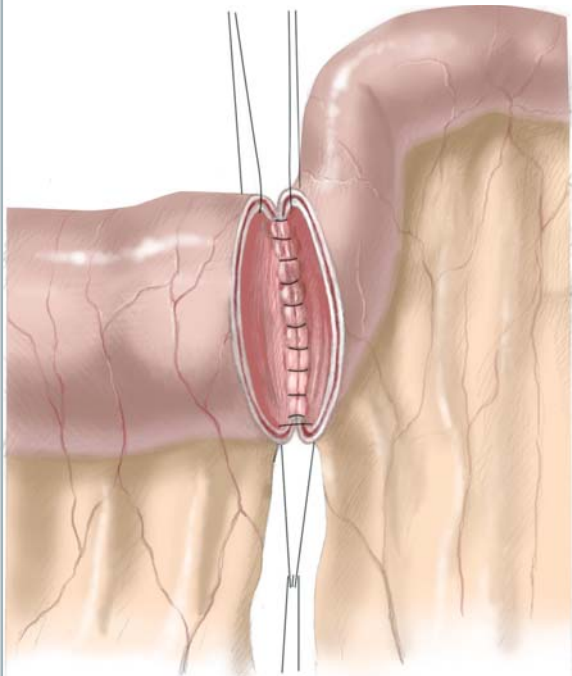


Figure 22.9

After completion of one-half of the anastomosis the bowel is rotated through 180° and the “posterior” anastomosis completed. Alternatively the posterior edge of the bowel is anastomosed with the stitches tied on the mucosal surface followed by anastomosis of the “anterior” edges with interrupted stitches tied on the serosal surface. The suture lines are inspected for anastomotic integrity or tested with saline injection on completion.

Although isolated type I atresia is best dealt with by primary resection and anastomosis, multiple diaphragms have been successfully perforated with transluminal bougies being passed along the entire length of the affected small bowel.

Multiple type IV atresias, present in 18% of infants, are often localized necessitating en-bloc resection and a single anastomosis, rather than multiple anastomosis. It is important, however, to maintain maximum bowel length to avoid the short bowel syndrome.

Similar techniques are used for intestinal stenosis and type I atresias. Procedures such as simple transverse enteroplasties, excision of membranes, bypassing techniques or side-to-side anastomosis are no longer utilized. They fail to remove the abnormal dysfunctional segments of intestine, thus increasing the risk of the blind loop syndrome.

Figure 22.10

The defect in the mesentery is repaired by approximating or overlapping the divided edges with interrupted sutures taking great care not to incorporate blood vessels or kinking the anastomosis. Closure of the large mesenteric defect can be facilitated by using the preserved mesentery of the resected proximal bowel.

■ **Wound Closure.** The peritoneal cavity is thoroughly irrigated with warm saline to remove all macroscopic debris and the bowel then returned to the abdominal cavity. Care is taken not to kink the anastomosis. The abdomen is closed by approximating en mass all the layers of the abdominal wall, excluding Scarpa’s fascia, with a single continuous 4/0 monofilament absorbable suture, followed by subcutaneous and subcuticular absorbable stitches. No drains or trans-anastomotic tubes are used.

Figure 22.9

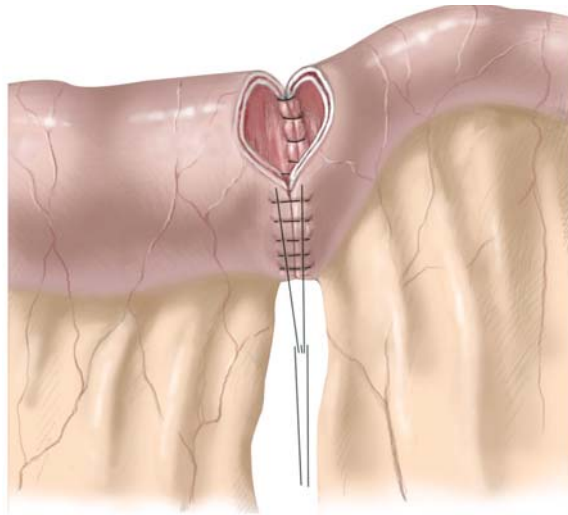


Figure 22.10

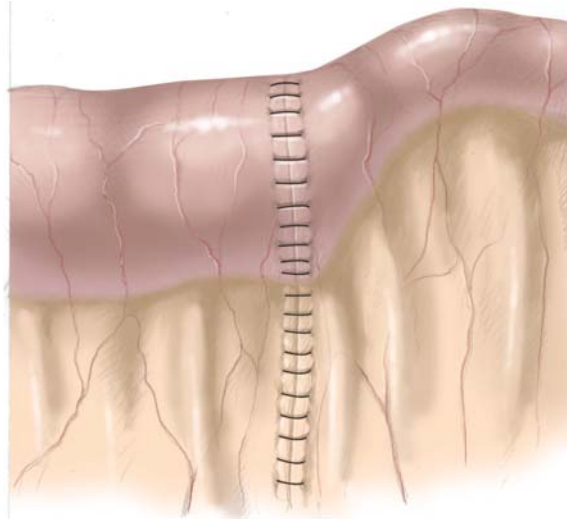


Figure 22.11, 22.12

Alternative surgical techniques may be required if the ischaemic insult has resulted in an atresia with markedly reduced intestinal length, where large resections of abnormal or multiple atretic segments are required or if the measured residual small intestinal length is <80 cm.

Indications for tapering are:

- As part of bowel length preservation where the proximal atretic segment is grossly dilated and hypertrophied over an extended distance – typical in type III(b) atresia and high jejunal atresia
- To equalize disparity in anastomotic lumen size
- For the correction of a failed inversion plication procedure
- To improve function in a persistently dilated non-functioning mega-duodenum following surgery for upper jejunal atresia

■ **Tapering duodeno-jejunoplasty.** This method is primarily indicated to conserve bowel length (high jejunal atresia, type III(b) atresia) and to reduce disparity in anastomotic diameter size. The atretic jejunoduodenum is derotated and the antimesenteric segment of the dilated proximal segment is resected over a 22–24F catheter. The resection may extend cephalad to the second part of the duodenum. An intestinal auto-stapling device may be used to facilitate the resection and anastomosis. The longitudinal anastomotic line is reinforced with an absorbable 5/0 or 6/0 Lambert suture. Tapering can safely be done over a length of 20–35 cm. The tapered bowel is then primarily anastomosed to the distal bowel (with or without equal bowel diameters) and left in a dependant position as for corrected malrotation with the caecum in the left hypochondrium.

Figure 22.11

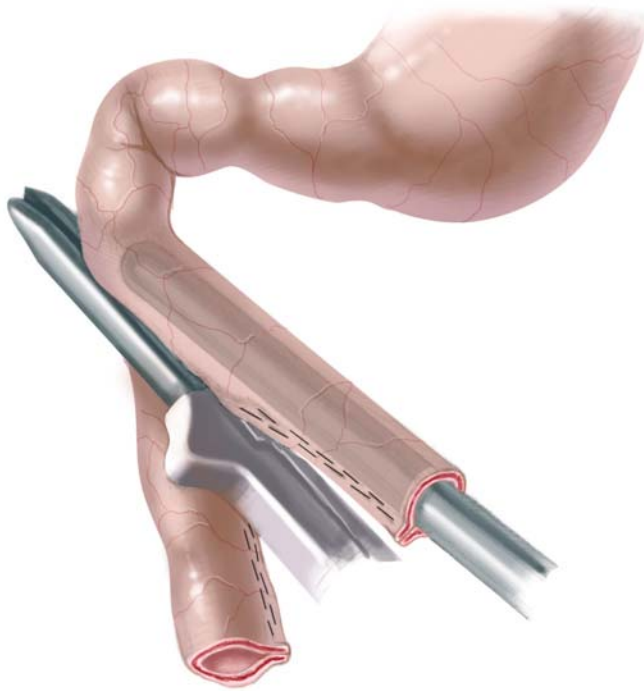

Figure 22.12

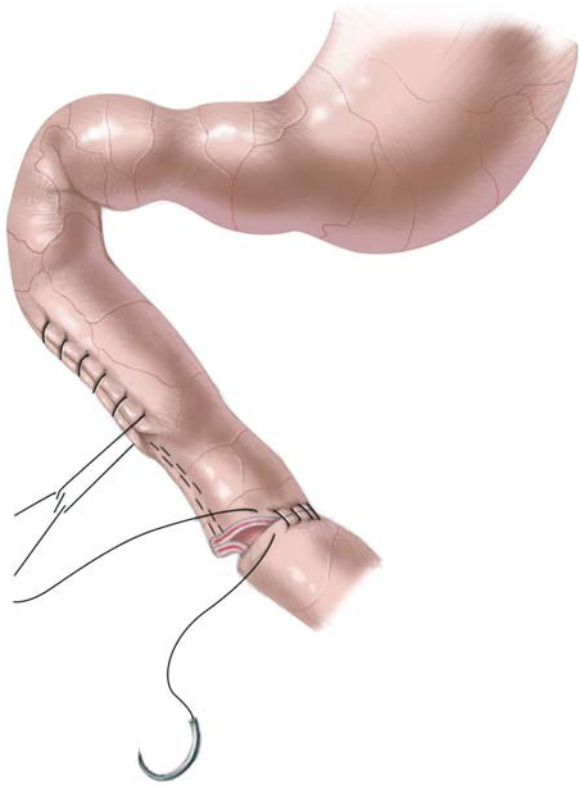


Figure 22.13, 22.14

■ **Plication and Folding.** The basic derotation and back resection methods are used as previously described for tapering procedures. The plication method has the advantage of reducing the risk of leaking from the antimesenteric suture line, conserves mucosal surface area and may even facilitate return of bowel peristalsis. More than half of the antimesenteric bowel circumference may be infolded into the lumen over an extended length without causing an obstruction with care being taken not to narrow the lumen excessively. The “keel” must be trimmed and closed with interrupted sutures. The main drawback of this method is unravelling of the suture line within a few months, necessitating revision. The bowel is left in a position of derotation with the duodenojejunum dependant, the mesentery broad based and the caecum in the left hypochondrium.

Figure 22.13

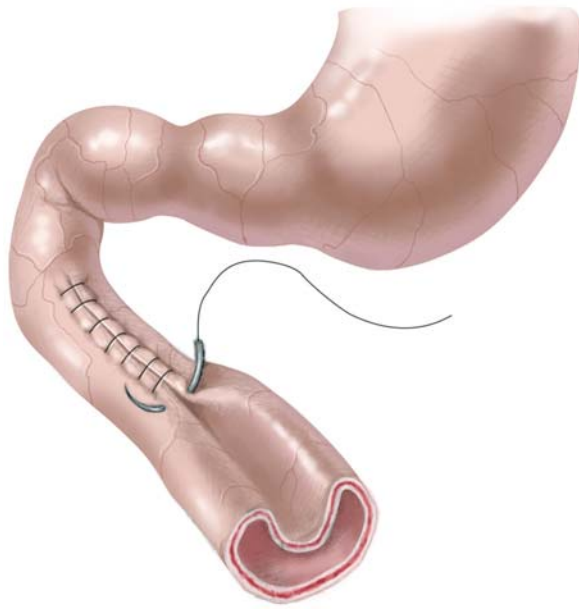


Figure 22.14

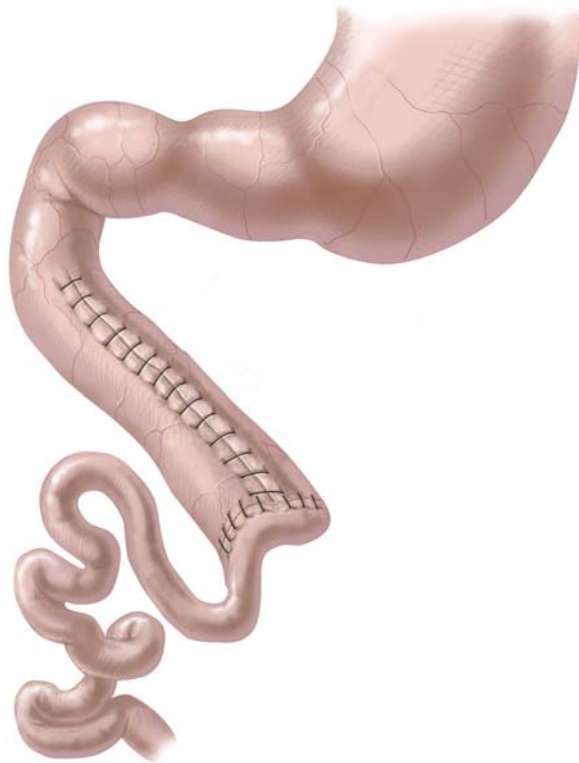


Figure 22.15–22.17

■ **Antimesenteric Seromuscular Stripping and Inversion Plication.** This technique prevents unravelling of the plication method and preserves maximal mucosal surface for absorption. A single or two antimesenteric converging seromuscular strips ± 2 mm in width are resected. This is easily performed by stabilizing the proposed line of resection with straight non-toothed forceps. A seromuscular strip is then

excised taking care not to damage the mucosa. The two denuded mucosal strips are then approximated with a running monofilament suture. The keel of the inverted bowel should be trimmed and bowel edges approximated with interrupted sutures prior to anastomosis to the distal bowel. Proximal and distal luminal size can be approximated to facilitate the anastomosis.

Figure 22.15

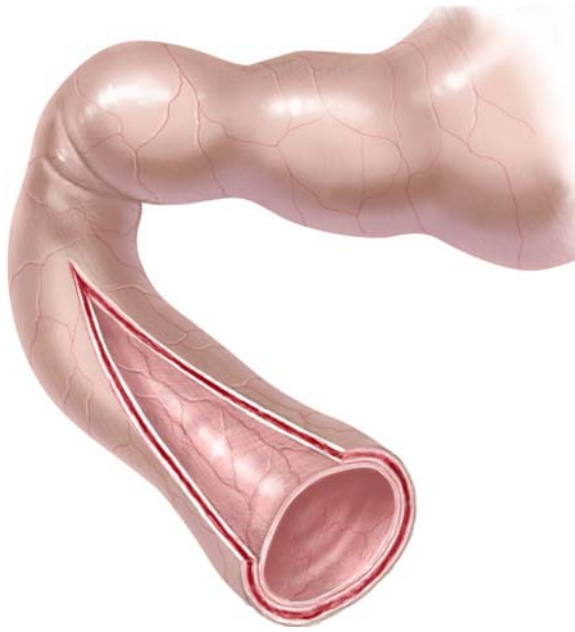

Figure 22.16

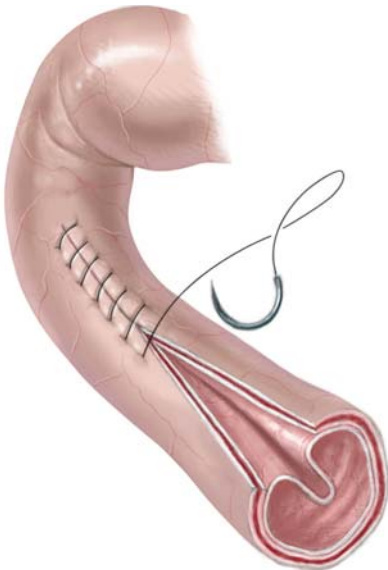
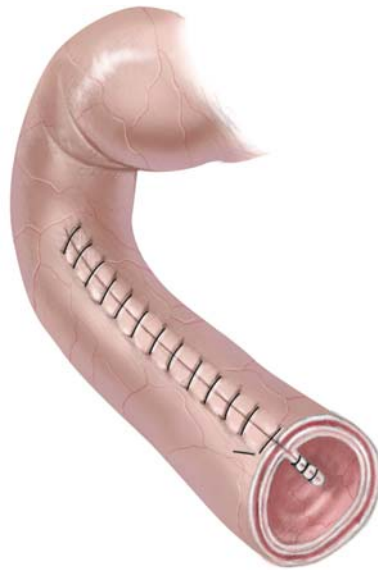

Figure 22.17



CONCLUSION

The overall survival amongst newborn babies with intestinal atresia has increased from a dismal 10% in 1952 to 90% at present. This came about primarily from a change in the surgical procedure from primary anastomosis without resection to liberal resection of the blind proximal and distal ends followed by end-to-end anastomosis.

Understanding the pathogenesis of atresia and adapting surgical procedures to minimize loss and conserve bowel length ensured that most infants will have sufficient bowel length for normal alimentary tract function and overall growth and development. Despite improvement in surgery, anaesthesia and peri-intra- and post-operative care, type III(b) atresia still carries a mortality of 19% predominantly due to gangrene of the proximal end of the distal segment (7%), anastomotic leak (15%) and stricture formation (15%). The prognosis of intestinal atresia is further determined by genetic factors, prematurity (30%), delay in presentation, associated diseases, i.e., cystic fibrosis, malrotation (45%), exomphalos, gastroschisis and Hirschsprung's disease, together with other gastro-intestinal atresias, infarction of the proximal atresia with peritonitis, sepsis, pneumonia and the complications of prolonged parenteral nutrition.

The incidence of post-surgical complications such as anastomotic leaks, stricture formation, transient

intestinal dysfunction, blind loop syndrome and the short bowel syndrome can be minimized by careful attention to the presenting anatomical detail, meticulous surgical technique and maximal bowel length conservation methods. Because of the high incidence of unravelling, the plication technique is rarely used.

The short bowel syndrome is a major factor influencing outcome. It may be due to predisposing factors such as extensive intra-uterine bowel loss, operative factors, i.e., over-zealous bowel resection and ischaemic injury to the bowel or post-operative complications. Under ideal circumstances a survival rate of 46–70% can be expected in most infants with less than 25 cm jejunum-ileum.

Several surgical procedures have been identified to improve the outcome of the short bowel syndrome including reversal of segments of bowel, interposition of colonic segments and methods to increase mucosal surface area for absorption purposes. Most are of experimental value only except for bowel-lengthening procedures. The latter should not be performed initially until conservative methods to stimulate and allow maximum bowel adaptation to occur, have failed. Full bowel adaptation may require 6–18 months to become achieved.

SELECTED BIBLIOGRAPHY

- Kling K, Applebaum H, Dunn J, Buchmiller T, Atkinson J (2000) A novel technique for correction of intestinal atresia at the ligament of Treitz. *J Pediatr Surg* 35: 353–356
- Louw JH, Barnard CM (1955) Congenital intestinal atresia: observations on its origin. *Lancet* 2: 1065–1067
- Malcynski J T, Shorter N A, Mooney D P (1994) The proximal mesenteric flap: a method for closing large mesenteric defects in jejunal atresia. *J Pediatr Surg* 29: 1607–1608
- Rode H, Millar AJW (2003) Intestinal atresia and stenosis: In: Puri P (ed) *Newborn surgery*. Arnold, London, pp 445–456
- Weber TR, Wane DW, Grosfeld JL (1982) Tapering enteroplasty in infants with bowel atresia and short bowel syndrome. *Arch Surg* 117: 684–688

INTRODUCTION

Meconium ileus is the earliest clinical manifestation of cystic fibrosis (CF) and occurs in 8–10% of patients with CF at birth. The clinical features are mainly due to the presence of abnormal, inspissated and viscid mucus of intestinal origin. In neonates affected by this condition, the impacted meconium produces an intraluminal obstruction occurring in the midileum, leading to a progressive distension. About 40% of patients with meconium ileus are complicated by intestinal volvulus, atresia, gangrene and necrosis, perforation, peritonitis with abdominal calcifications and, finally, meconial pseudocyst.

More recently relief of the intestinal obstruction has been obtained by irrigating the intestine with various solutions such as normal saline, 1% *N*-acetylcysteine, hyperosmolar Gastrografin enema, surfactant, or DNase. With respect to different types of surgical and medical efforts, the survival rate at 1 year increased from 10 to 90%, and the operative mortality is drastically decreased to 15–23% of the treated newborn.

Meconium ileus accounts for 9–33% of all neonatal intestinal obstructions (300 new cases in Italy each year), with an incidence of 1:2500 newborns, representing the third most common cause of neonatal small bowel obstruction after ileal and duodeno-jejunal atresia and malrotation. Polyhydramnios is the most frequent feature observed in prenatal diagnosis of complicated forms of meconium ileus. The presence of fetal hyperechogenic bowel on the ultrasound, associated with dilated bowel and/or ascites could be indicative of an intestinal obstruction. A family history of CF is clearly evident in almost 25% of these patients. Meconium ileus is uncommon in premature infants (5–12%), and associated congenital anomalies are rare.

In the meconium ileus, the intestine shows different aspects if we consider the *proximal*, the *middle* and the *distal* ileum. In the first portion, nearly normal evidence is present, with a progressive dilatation at the mid-portion borderline. In the *proximal ileum*, the content has a semi-liquid consistency and is not yet viscous. A marked and severe dilatation of the *middle ileum* is always seen: the intestine contains

thick, dark green and putty-like meconium, firmly adherent to the walls. The intestinal obstruction causing a hyper peristalsis is responsible for the congestion and hypertrophy of the walls. The *distal ileum* is full of concretions called “rabbit pellets”, grey stained and with a typical beaded appearance. This small bowel condition is responsible for a narrow, empty and small colon, never used, which is called *microcolon*.

Main symptoms include abdominal distension (96%), bilious vomiting (50%) and delayed passage of meconium (36%). From a clinical point of view, it is possible to recognize two different conditions: a simple, uncomplicated and non-surgical type, and a complicated, severe type, with a mortality of at least 25% of all cases. In the first type (58%), signs and symptoms of a distal ileal obstruction are seen not later than 48 h after birth: generalized abdominal distension with dilated and visible as well as palpable loops of bowel, bilious vomiting, no stools and narrowing of the anus and rectum, with only a dense and rubber-like grey meconium sticking to the anal wall. In the second type (42%), the neonate represents a surgical emergency, which must be treated within 24 h of birth, when the signs of a hypovolemic shock or sepsis are not well established. A fetus with complex meconium ileus is at increased risk of postnatal bowel obstruction and perforation. A usual X-ray image of fine, granular soap-bubble (“Singleton’s sign”) or ground-glass appearance (“Neuhauser’s sign”) is due to a dense meconium mixed with air, typical of the distal ileum; this picture is usually located in the mid-abdomen or in the right iliac fossa. When the meconium ileus is complicated, the abdominal radiograph may show calcification as a result of meconium peritonitis due to a fetal perforation of the intestine. A double-bubble image or air-fluid levels can be seen when a secondary ileal atresia (single or double) is the final bowel remodelling after a complete volvulus associated with a severe ischaemic damage. If the intestinal perforation occurs early in the antenatal period, the X-ray appearance of a round rim of calcification underlines a meconium pseudocyst.

Figure 23.1, 23.2

The first step of the treatment includes a nasogastric tube decompression, antibiotic prophylaxis, and correction of dehydration, electrolytes and hypothermia.

A contrast enema with water-soluble and hyper- or iso-osmolar contrast is the medical treatment of choice and mucosal safe, for uncomplicated cases. A recent study that used various enema solutions administered in a mouse model showed that surfactant and Gastrografin were the most efficacious for the in vivo relief of constipation in comparison with perflubron, Tween-80, Golytely, DNase, *N*-acetylcysteine and Viokase. Intestinal mucosal damage was absent and viscosity had been significantly reduced in vitro.

The enema evacuation should be obtained under fluoroscopic control, with a gentle and progressive increasing of the intraluminal pressure, thus avoiding unexpected fractures of the colon. A correct pro-

cedure prevents leakage of the contrast medium by taping the buttocks as well as the catheter dislocation. If the contrast medium fails to progress into dilated small bowel loops, the presence of an acquired atresia is definite and the radiologist must stop the examination because of a high risk of perforation. Of those submitted to this procedure, 50% of neonates benefit from enema alone over the next 48 h, without any additional treatment; in some cases, a second enema may be used with a complete evacuation of the meconium filling the ileal loops. Acetylcysteine administered by mouth is useful and helps to relieve the obstruction. Radiographs are taken at 3, 6, 12, 24 and 48 h with the aim of evaluating progression and possible complications. At this time feeding is begun. Hypovolemic shock and early perforation are around the corner, but an appropriate and meticulous procedure can avoid these complications.

Figure 23.1

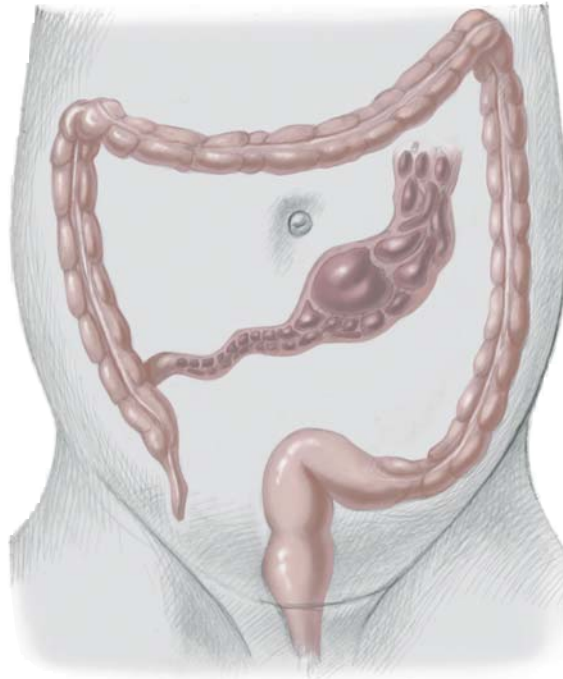


Figure 23.2

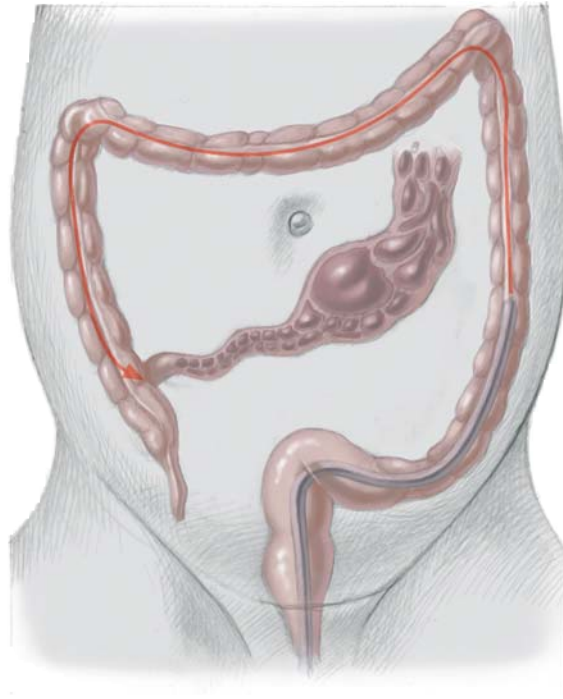


Figure 23.3

Only 6% to 10% of uncomplicated forms fail the non-operative management using a water-soluble contrast enema. If no significant difference in intestinal diameters and no microcolon is present, a limited enterotomy and repeated warm saline irrigations through a smooth catheter provide for the best result. Meconium discharge may be manually supported,

using an enterotomy placed in the dilated hypertrophic ileum. The catheter is two-way directed with care, clearing the small as well as the large bowel. After exclusion of an atretic intestinal segment, the enterostomy is closed by single interrupted seromuscular stitches.

Figure 23.4, 23.5

In contrast, approximately half of neonates with meconium ileus cannot be treated adequately with irrigations and/or present additionally an intestinal obstruction complicated by neonatal intestinal perforation or ileal atresia secondary after intrauterine perforation. They always require a surgical procedure such as resection of the dilated meconium-filled ileum and ileal anastomosis (as shown in Chap. 22). Additionally, complicated cases of meconium ileus are seen in newborns with an extreme difference in diameters of the proximal and distal ileum, and a significant microcolon. In those cases, the double-tube ileostomy technique according to Rehbein has proved to be an effective treatment and avoids the secondary laparotomy for stoma closure.

A horizontal predominantly right-sided laparotomy, approximately 2 cm below the umbilicus, is performed. A small transverse incision into the enlarged ileum is performed, approximately 5–7 cm in front of the narrow part filled with stool pellets. Four stay sutures are inserted into the margins of the incision. If an atresia exists, the atretic part is resected and the thickened meconium from the proximal part and the grey stool pellets from the distal part are evacuated by numerous irrigations with warm saline through a 5–8 Ch feeding tube supporting the manoeuvre by gentle manual forward and backward manipulation.

Once all intestinal contents are evacuated, a 10 Ch feeding tube with larger cut openings is inserted through the enterotomy in the proximal non-dilated ileum, and a second 5 Ch tube is inserted into the distal narrow ileum or microcolon in a T-tube fashion.

The enterotomy is closed around the tubes and is tightly fixed to the appropriate part of the ventral abdominal wall – in a similar fashion as in a gastrostomy. Both tubes are carefully fixed with nonabsorbable sutures to the skin. If a bowel segment had to be resected, the stoma for the tubes is best situated approximately 5 cm in front of the anastomosis, and the small tube is passing the anastomosis far into the narrow intestine. Post-operatively the large tube serves for suctioning and evacuation of the intestinal contents; the small distal tube serves for constant irrigation with increasing amounts of fluid (first saline, later pre-digested milk), thereby promoting a rapid enlargement of the ileum and the microcolon. As soon as the evacuations through the large tube become less and normal bowel movements occur, it is indicative that most of the intestinal contents are passing by distally. The double tubes can then be simply removed. We have treated our patients since the 1980s by this double-tube method successfully, and cutaneous enterostomy is no longer performed.

Figure 23.3

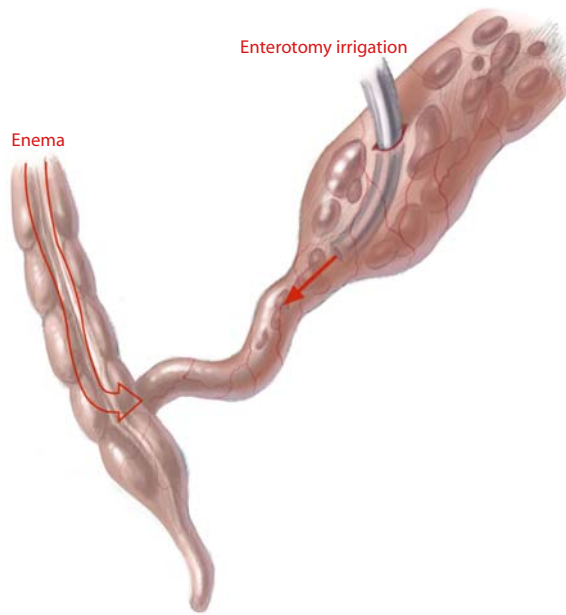


Figure 23.4

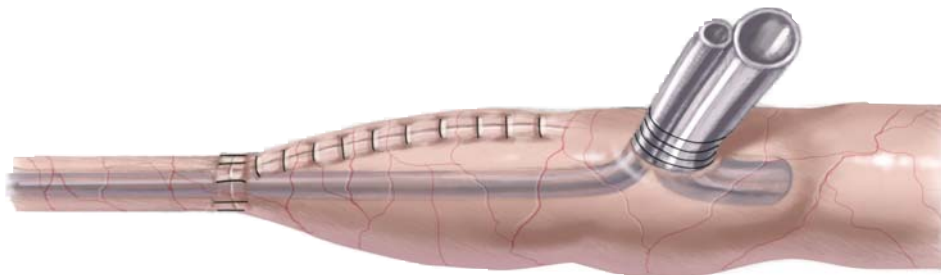


Figure 23.5

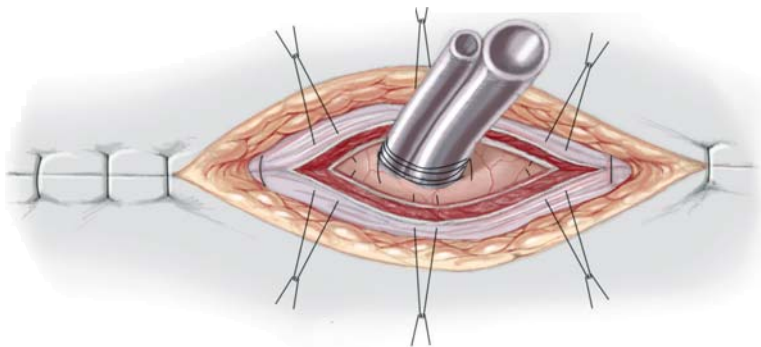


Figure 23.6–23.9

Different surgical techniques have been developed in the past consisting of a resection of the enlarged bowel segment and temporary decompression by means of a distal or proximal enterostomy. The most simple form is a double-barrelled ileostomy according to Mikulicz, with the two loops brought out side-to-side. This solution is quick and avoids an intra-abdominal anastomosis. More technical alternatives have been described thereafter: a distal ileostomy with end-to-side ileal anastomosis (Bishop-Koop) has been called “distal chimney enterostomy”. This procedure consists of a Roux-en-Y anastomosis between the end of the proximal segment and the side of the distal segment, at least 3 to 5 cm from the open end. The open limb of the distal segment is used

as an ileostomy. A variation of this technique has been described, using an angulating proximal segment, which is obliquely anastomosed with the distal stump. Proximal chimney enterostomy, the so-called Santulli procedure, consists of a proximal ileostomy with end-to-side ileal anastomosis. The end of the distal limb is anastomosed to the side of the proximal limb, the end of which is used as the enterostomy. This technique should facilitate irrigation as well as decompression of the proximal small bowel.

The enterostomies can be closed by an end-to-end anastomosis when uninhibited passage of intestinal contents is established, mostly between 7 and 12 days after.

Figure 23.6

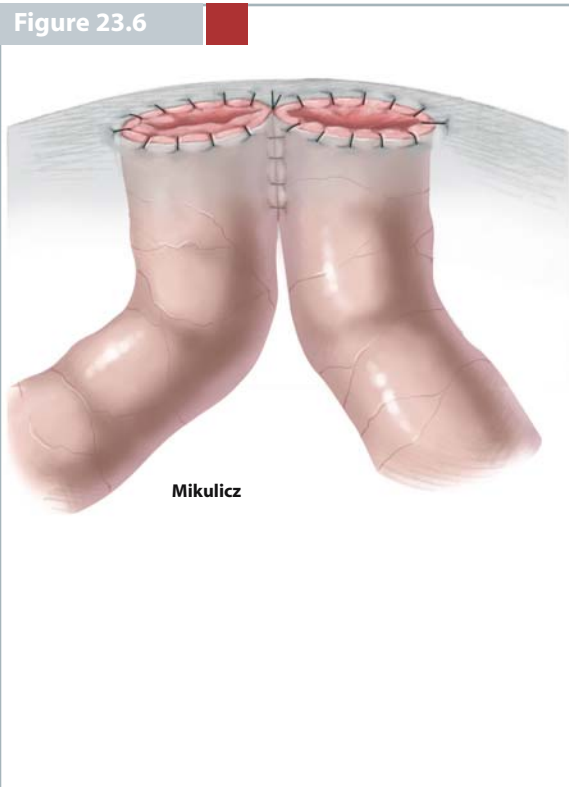

Figure 23.7

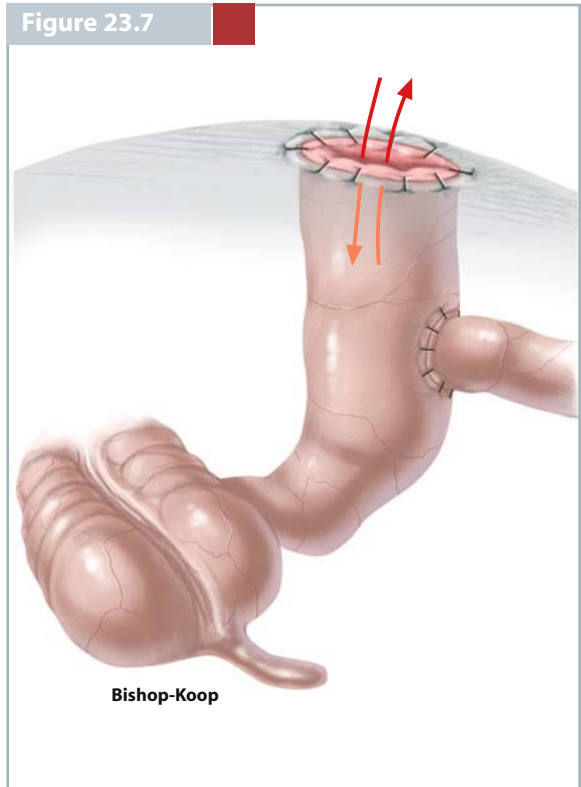


Figure 23.8

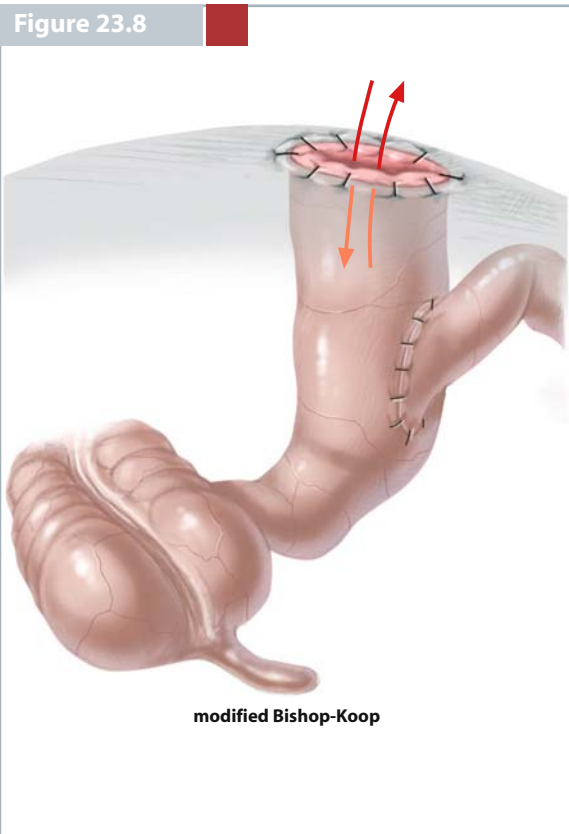


Figure 23.9

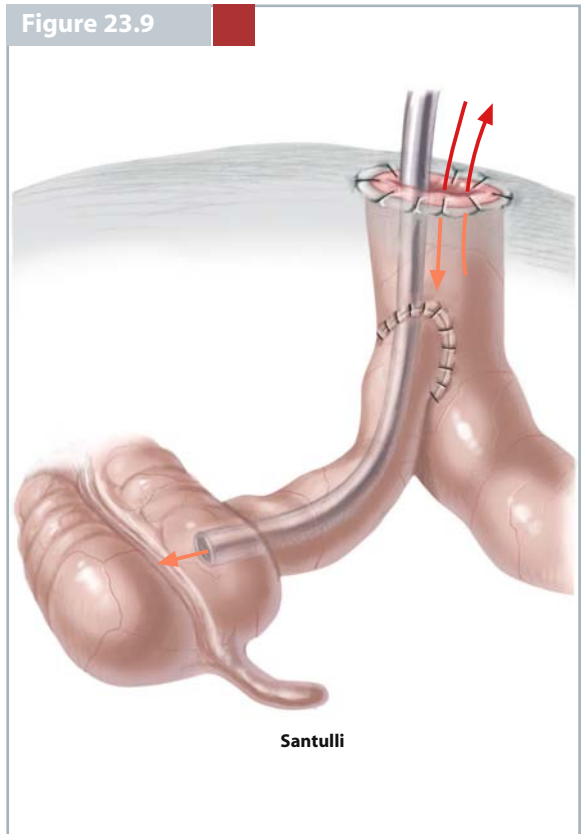


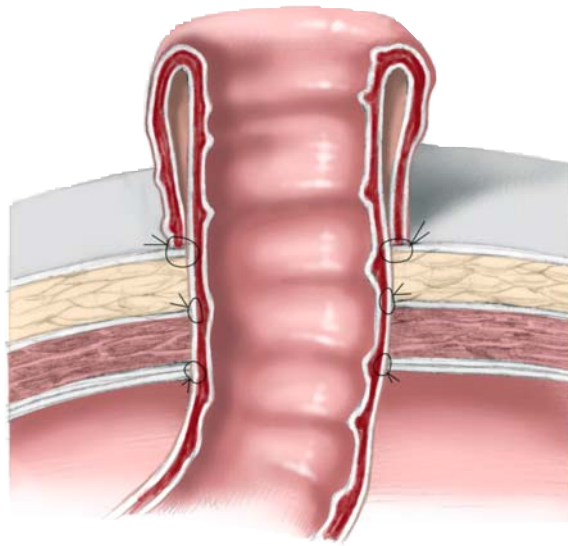
Figure 23.10

When a terminal ileostomy or colostomy is desired in neonates and/or children, the preferred method used is the nipple-valve system formation. This is an easy technical procedure and avoids any kind of infiltration or stricture or retraction of the neostoma.

A 2- to 3-cm-long intestinal segment is used with a serosal surface free of fat and with a good vascular

supply. Seromuscular wall is sutured to the fascia in four quadrants. Next the stitch is taken through the skin seromuscular wall and edge of the stoma, thereby creating the nipple. Four to six sutures are normally needed depending upon the size of the stoma.

Figure 23.10



CONCLUSION

Generally, the lesser the extend of to bowel resection the earlier is the recovery of peristalsis.

Actually, bowel resection with primary anastomosis has been proved to be as well effective and safe as stoma formation, but is associated with a reduced length of initial hospital stay. Complications include pulmonary infections, which is the most important one with an incidence of at least 8 to 10%. Anastomotic leakage occurs for different reasons: a technical mistake, an insufficient blood supply, or an unrecognized distal obstruction. Delayed recovery of peristalsis is another frequently observed complication and is due to an abnormal stretching of the intestinal walls during the fetal life. Total parenteral nutrition is the support of choice and a central venous catheter is mandatory in these situations.

Meconium ileus may be an early indication of a more severe phenotype of CF. This was suggested by the significantly lower pulmonary function found in children with a history of meconium ileus compared to age- and sex-matched children who did not have meconium ileus. In this view, patients without CF demonstrated better growth and functional status, and had a lower incidence of lung diseases as well as gastrointestinal problems. It is also possible that patients affected by meconium ileus have a more severe form of CF that, from a pathological point of view, consists of a more severe compromise of mucous glands

The complicated forms are susceptible to a higher number of long-term surgical complications, including especially small bowel obstructions (of adhesive

origin) and blind loop syndromes (30% of the cases). These long-term problems are more commonly ascribed to a higher incidence of peritonitis and small bowel ischaemia. Nearly all patients undergoing enterotomy and irrigation do not manifest long-term surgical morbidity. There is general agreement that resection and stomas could be avoided with a more meticulous attention to care and clearing the intestinal walls from the more dense concretions.

Long-term complications in neonates affected by uncomplicated meconium ileus who were not operatively treated are rarely seen, and only mild and transient complications have been observed in newborns treated with minor surgical procedures, such as enterotomies and irrigations. However, meconium ileus did not directly affect long-term functional or social status in children with CF, and the quality of life is mainly correlated with the extension of lung lesions, which is the most limiting factor with respect to the school, social life and physical activity.

Survival of neonates with meconium ileus has improved over the last two decades because of neonatal intensive care, improved surgical technique and medical treatment. In general, an overall immediate survival of 90% is achieved using the modern protocols and nearly all deaths are pertinent to the adolescents. Only few children die because liver and or septic complications. Deaths are mainly due to sepsis, primary or secondary to pulmonary interstitial emphysema, or due to aspiration pneumonia. In a large series reported and analysed by Fuchs, only one child died because of the meconium ileus itself.

SELECTED BIBLIOGRAPHY

- Burke MS, Ragi JM, Karamanoukian HL, Kotter M, Brisseau GF, Borowitz DS, Ryan ME, Irish MS, Glick PL (2002) New strategies in nonoperative management of meconium ileus. *J Pediatr Surg* 37:760-764
- Fanconi G, Uehlinger E, Knauer C (1936) Das Coeliakiesyndrom bei angeborener zystischer Pancreasfibromatose und Bronchiektasien. *Wien Med Wochenschr* 28:753-766
- Fuchs JR, Langer JC (1998) Long-term outcome after neonatal meconium obstruction. *Pediatrics* 101:4-7
- Irish MS, Ragi JM, Karamanoukian HL, Borowitz DS, Schmidt D, Glick PL (1997) Prenatal diagnosis of the fetus with cystic fibrosis and meconium ileus. *Pediatr Surg Int* 12:434-436
- Rehbein F (1976) Dünndarmatresie. In: Rehbein F (ed) *Kinderchirurgische Operationen*. Hippokrates Verlag, Stuttgart, pp 273-293

Gastrointestinal Duplications

Mark D. Stringer

INTRODUCTION

Alimentary tract duplications are rare congenital malformations that may occur anywhere from mouth to anus. They are usually single, vary widely in size, are more often cystic than tubular, and are lined by alimentary tract mucosa. Intestinal duplications are typically located on the mesenteric aspect of the intestine and usually share a smooth muscle wall and common blood supply with the adjacent bowel. Occasionally, they are found separate from the alimentary tract. They may communicate with the lumen of the gut and can contain heterotopic gastric mucosa; both features are more likely with tubular lesions. Some duplications are associated with vertebral anomalies. Foregut duplications may be associated with intraspinal pathology when they are sometimes termed neurenteric cysts.

There is no satisfactory single explanation to account for the development of gastrointestinal duplications. The pathogenesis of those with associated vertebral anomalies can be explained by the abnormal adherence of the endoderm of the roof of the primitive gut to the notochord (the split notochord theory). Some hindgut duplications are an expres-

sion of caudal twinning and some intestinal lesions may result from an intrauterine mesenteric vascular accident. Alimentary tract duplications are best treated by *early complete excision* to avoid future complications. In addition to the problems described above, there is a risk of late malignant degeneration, particularly with rectal and gastric duplications. Early resection avoids the additional operative difficulties arising from inflammation or perforation of the duplication cyst. The surgeon must be familiar with the local anatomy and the range of available operative techniques. Rarely, complete resection is excessively hazardous and alternative techniques such as mucosal stripping or fenestration are necessary. Incomplete excision may lead to late, potentially fatal, complications such as cyst recurrence, infection, meningitis (neurenteric cysts), gastrointestinal bleeding and perforation. At operation, a careful search is made for additional duplications and other congenital gastrointestinal malformations. Asymptomatic appendiceal duplications found in association with cloacal or bladder exstrophy may be preserved for use in subsequent reconstructive surgery.

Figure 24.1

Nearly half of all duplications occur in the midgut while a third is localized in the foregut. Most duplications cause symptoms in infancy or childhood. Some are found incidentally in infants undergoing evaluation of another congenital malformation or in children with unrelated symptoms investigated by ultrasound or other imaging modalities. In recent years, an increasing number of gastrointestinal duplications have been detected during prenatal ultrasound scanning. The diverse presenting features of duplications reflects their wide distribution and variety. Symptoms and signs arise from obstruction (e.g., respiratory, oesophageal, intestinal), haemorrhage, infection/inflammation, perforation, or intussusception. Some are discovered as an asymptomatic mass.

Vertebral anomalies such as bifid or hemi-vertebrae are important diagnostic pointers, particularly with foregut duplications. Other congenital malformations are found in about half of all patients. For example, intestinal malrotation or atresia may be associated with midgut duplications and genitourinary anomalies or bladder exstrophy with hindgut lesions.

Imaging is a critical aspect of preoperative preparation. Isolated small bowel duplications require few

pre-operative investigations – plain and contrast radiography, abdominal sonography and occasionally a radioisotope technetium scan to detect heterotopic gastric mucosa.

In contrast, thoracoabdominal lesions demand detailed radiologic imaging of mediastinal, abdominal and spinal components. Magnetic resonance imaging (MRI) and computerised tomography (CT) enable evaluation of the cranial and caudal extent of the cyst. Upper gastrointestinal contrast studies and endoscopy may be necessary in some cases. The possibility of a separate intestinal duplication must be considered with all foregut duplications.

In older children, endoscopic retrograde cholangiopancreatography or magnetic resonance cholangiography are helpful in the assessment of pancreatic and selected duodenal duplications and magnetic resonance angiography may help to plan surgery for large retroperitoneal lesions. Pelvic duplications are best imaged by CT or MRI in conjunction with a contrast enema, fistulogram, endoscopy, and urinary tract sonography.

Figure 24.1

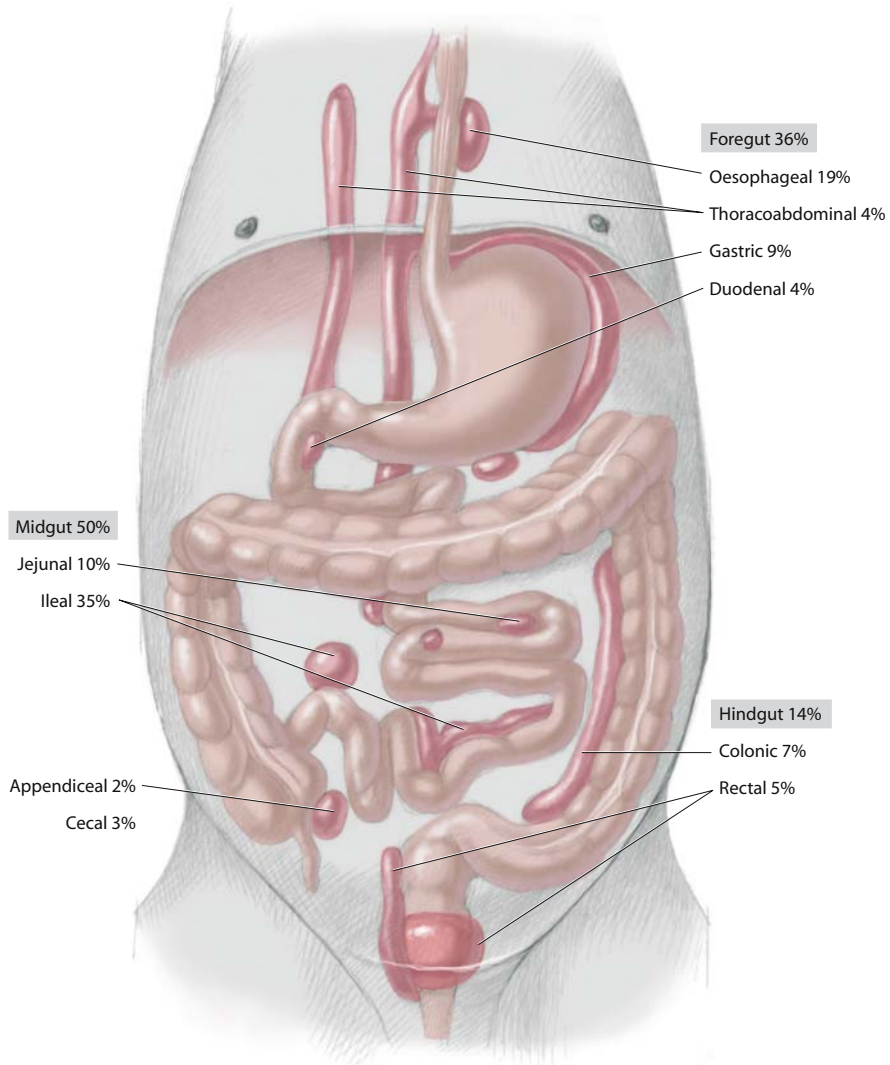


Figure 24.2–24.4

■ **Oesophageal Duplications.** These are usually intramural non-communicating cystic lesions, more often related to the right side of the oesophagus. A few are separate from the oesophagus and do not share a common muscular wall. Intrathoracic oesophageal duplication cysts can be approached transpleurally through a posterolateral thoracotomy (typically right sided).

Cervical oesophageal duplications can be removed via a supraclavicular approach. The neck must be extended with a sandbag between the shoulders. The cyst is fully mobilized by dissecting close to its wall. Excision of the cyst is most easily achieved by transecting the lesion close to the oesophagus and removing the residual mucosa. The proximity of the vagus and phrenic nerves and the right lymphatic duct/thoracic duct should be noted. Any communication with the oesophagus should be closed and the residual muscular defect can be repaired using the muscular fringe from the duplication. Complete mucosal excision is essential to avoid recurrence – mar-

supialization alone is inadequate. Mucosal integrity can be checked before closing the muscle layer by insufflating air through a nasogastric tube. Occasionally, an adjacent oesophageal stricture or ulcer will require segmental oesophageal resection. The neck (or chest in the case of intrathoracic oesophageal duplications) is closed and pleural drainage is not usually necessary.

Video-assisted thoracoscopic resection of a thoracic oesophageal duplication is feasible in some cases. Single lung ventilation with collapse and retraction of the ipsilateral lung facilitates surgical exposure. A 10-mm 0° end-viewing telescope is introduced under direct vision after gentle finger dissection of the port site. Two or more 5-mm instrument ports are subsequently sited. After dissection, if the cyst remains intact, it is aspirated to enable removal through a port site. Prior to removing the viewing telescope, the lung is re-expanded and checked for air leaks. A thoracostomy drain is left in situ.

Figure 24.2

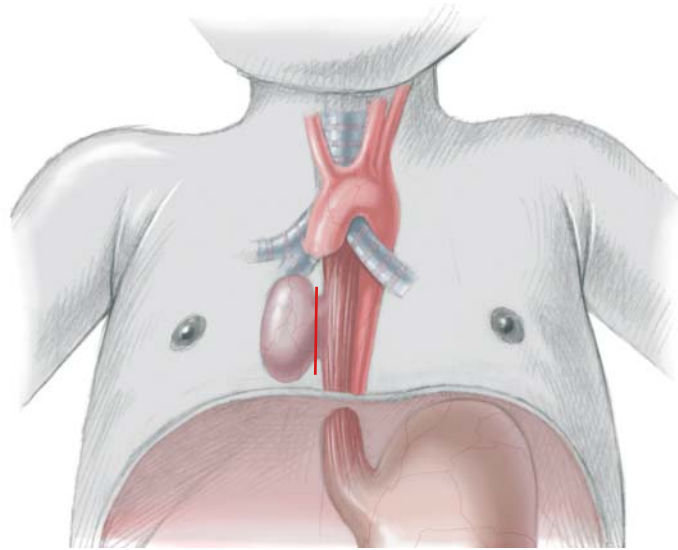


Figure 24.3

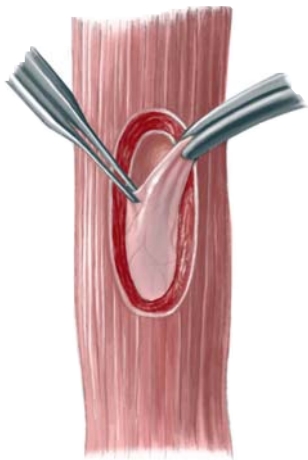


Figure 24.4

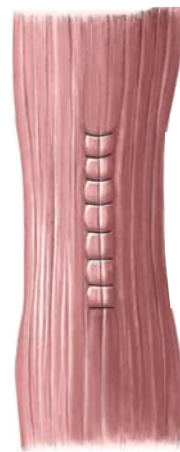

Figure 24.5

■ **Thoracoabdominal Duplications.** Thoracoabdominal duplication usually descends to the right of the oesophagus, but often separate from it, in the posterior mediastinum. It communicates through the diaphragm with the stomach, duodenum, jejunum or ileum. These lesions are best approached by separate thoracic (posterolateral thoracotomy) and abdominal incisions. Occasionally, a laminectomy is also necessary to deal with an intraspinal component of the cyst but this should be anticipated by prior imaging. The connection with the spinal cord may be tenuous and easily overlooked at operation, underlining the importance of adequate detailed preoperative imaging. Multidisciplinary planning involving neurosurgical expertise is necessary in such cases. A staged approach, excising each component of the thoracoabdominal duplication cyst sequentially, should be avoided if possible. Although an asymptomatic abdominal component can be temporarily left in situ, an undrained thoracic segment is hazardous.

Complete excision of the duplication may involve dissecting its upper extremity free from any bony vertebral attachment. This sometimes requires a gouge or chisel. Some thoracoabdominal duplications are complicated by peptic ulceration which may erode into the lung parenchyma causing haemoptysis; in these cases, excision may require oversewing the fistula or rarely a lobectomy. The duplication is traced distally where it usually passes behind the diaphragm and may become tenuous at this point. The lesion is pulled up into the chest and divided between ligatures and the chest is closed with pleural drainage before proceeding to the laparotomy. Alternatively, the thoracic component of the cyst is passed through the diaphragmatic defect into the abdomen where it is subsequently retrieved. The abdominal portion most often appears as a tubular lesion communicating with the jejunum but may occasionally end blindly along the greater curve of the stomach. It can usually be excised without difficulty.

Figure 24.5

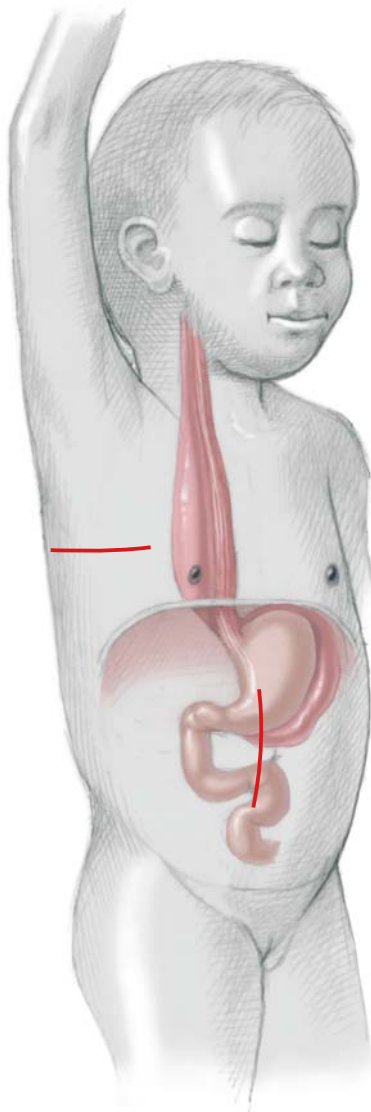


Figure 24.6, 24.7

■ **Gastric Duplications.** Cystic gastric duplications rarely communicate with the stomach lumen. Very rarely, they may communicate with the pancreas. Most greater curve or pyloric duplication cysts can be completely excised by dissecting the cyst off the gastric submucosa and repairing the residual seromuscular defect with inverting absorbable sutures. Gastric mucosal integrity can be checked prior to repair of the stomach wall by insufflating air via a nasogastric tube.

Small gastric duplications are sometimes more simply excised by a wedge resection of the cyst and a margin of stomach followed by a two layer gastric

closure. Extensive duplications of the greater curve of the stomach are best treated by partial resection, stripping of the residual mucosal lining, and repair. A less optimum approach is to divide the septum separating the tubular duplication from the gastric lumen with linear staplers introduced via proximal and distal gastrotomies. This division should be as complete as possible but since the mucosal lining of the duplication is not removed, there remains some risk of long-term complications.

Laparoscopic staple excision of smaller gastric duplication cysts is an alternative technique.

Figure 24.8

■ **Duodenal Duplications.** Some of these are simple cystic lesions which are easily excised. Others related to the medial aspect of the second part of the duodenum may be complex and communicate with the pancreatic and/or common bile duct. Previous pancreatitis or peptic ulceration secondary to heterotopic gastric mucosa may compound the surgical difficulties. Facilities for intra-operative cholangiopancreatography should be available with prior positioning of the child on a radiolucent operating table.

Surgical alternatives are dictated by the anatomy and include complete excision of the cyst with division of any ductal communication, partial excision and mucosectomy of the remaining part of the cyst or, when the duplication is adjacent to the ampulla of Vater, it can be fenestrated into the duodenal lumen. If the latter is performed, the presence of gastric mucosa should be excluded by intraoperative biopsy and the window must be of sufficient size to allow free dependent drainage without the tendency to form a cul de sac.

The duodenum is approached via a right upper quadrant incision and “Kocherised” to elevate it into the wound. The adjacent peritoneal cavity is packed off with swabs soaked in dilute aqueous povidone io-

dine and an oblique incision is made in the lateral duodenum to expose the medially situated duplication cyst. If needle aspiration of the cyst yields bile it should be cautiously deroofted, the ampulla identified and protected. Most of the cyst can be excised and the edges of a residual medial disc of mucosa (centred on the ampulla) should cautiously be oversewn with fine absorbable sutures to achieve haemostasis.

If the opening of the common bile duct or pancreatic duct is uncertain, intra-operative cholangiography may be helpful. Alternatively, a cholecystectomy can be performed and a fine probe passed distally through the cystic duct into the duodenum.

Rarely, a duodenal duplication cyst is located exclusively within the head of the pancreas and causes recurrent pancreatitis. Therapeutic alternatives are *complete* local excision with Roux loop drainage of the residual cavity or a Whipple-type pancreatoduodenectomy. Roux loop drainage of the cyst alone is inadequate – the mucosal lining of the cyst must be completely excised if pancreatitis is to be prevented. Where the duplication lies in the tail of the pancreas, distal pancreatectomy with splenic preservation (laparoscopic or open) can be performed.

Figure 24.6

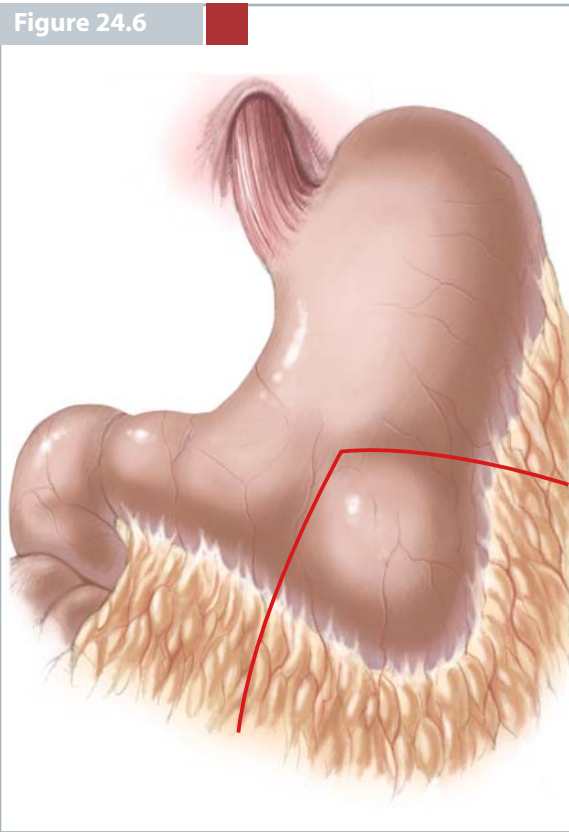


Figure 24.7

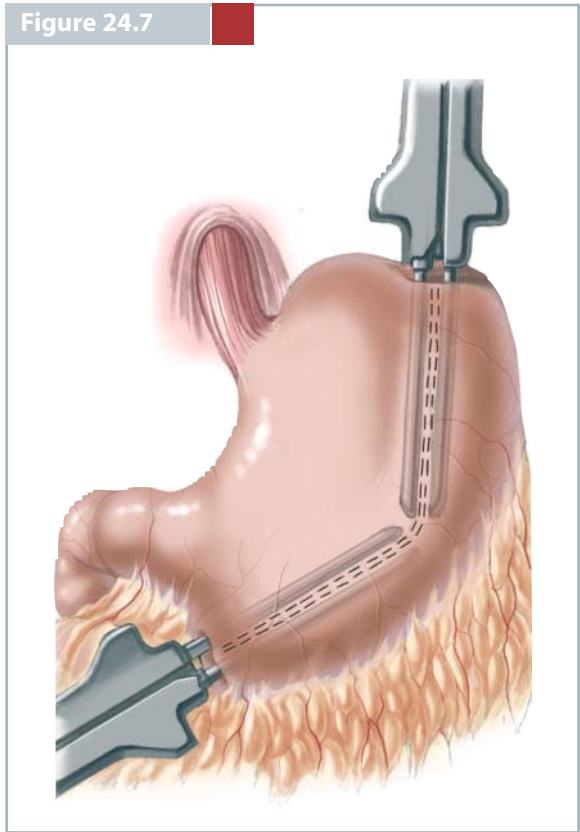


Figure 24.8

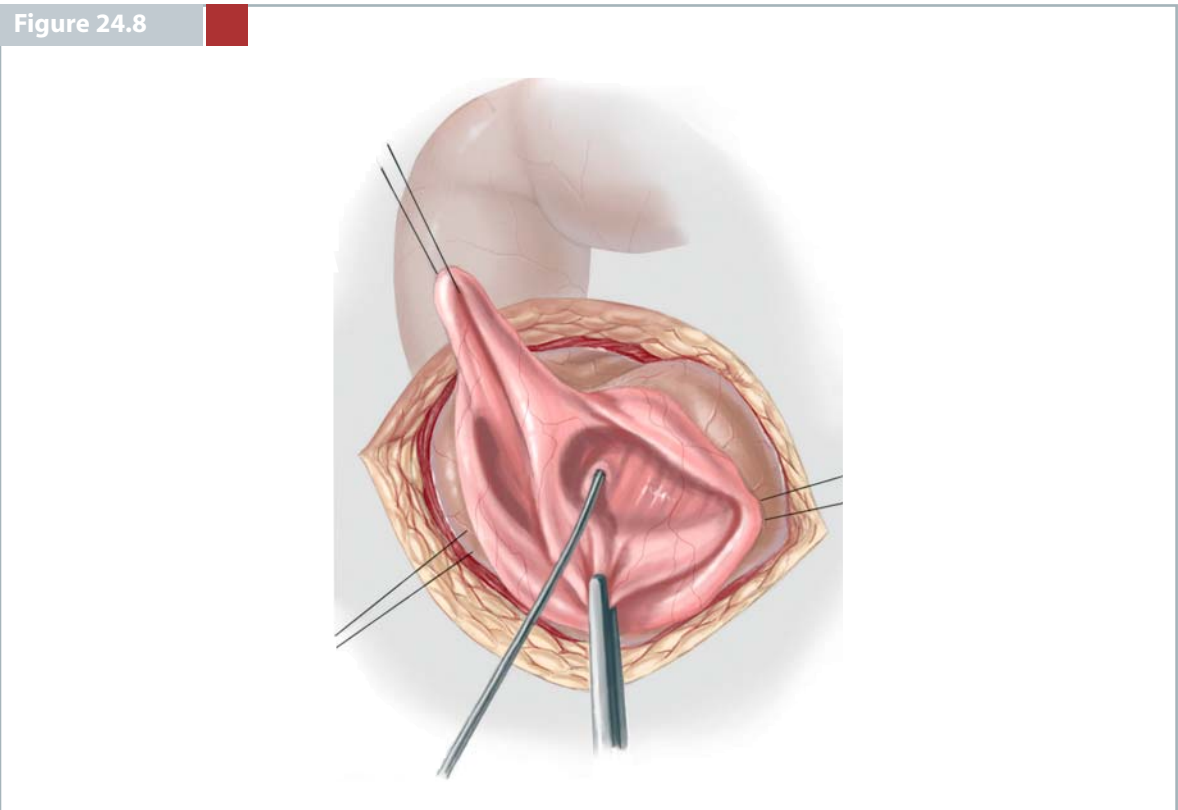


Figure 24.9–24.11

■ **Small Bowel Duplications.** Cystic lesions of the ileum or jejunum are the commonest duplications and complete excision is relatively straightforward. The continuous muscle coat of the normal bowel and duplication cyst usually make excision of the cyst alone impractical. For localised lesions, the duplication should be resected with the adjacent intestine after ligation and division of associated mesenteric vessels. If the bowel is obstructed, atraumatic clamps

placed across the intestine (but not the mesentery) will help prevent contamination. Before dividing the bowel with needle cautery or scissors, the surgical field should be protected by surrounding gauze swabs soaked in dilute aqueous povidone iodine. End-to-end anastomosis is performed using a single layer of interrupted extramucosal absorbable sutures such as 5/0. Laparoscopic techniques are applicable in selected cases.

Figure 24.9

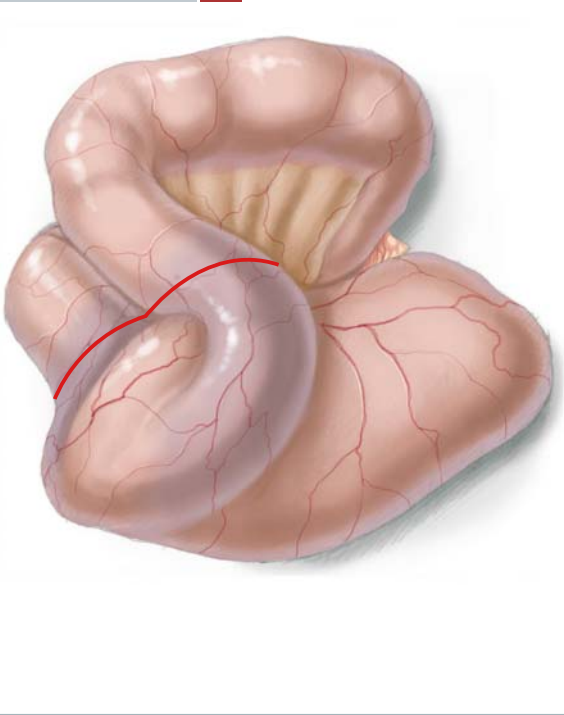


Figure 24.10

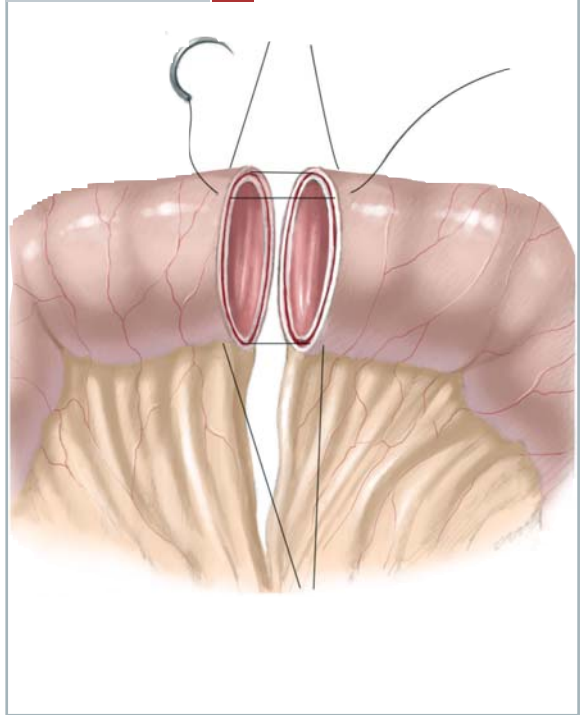


Figure 24.11

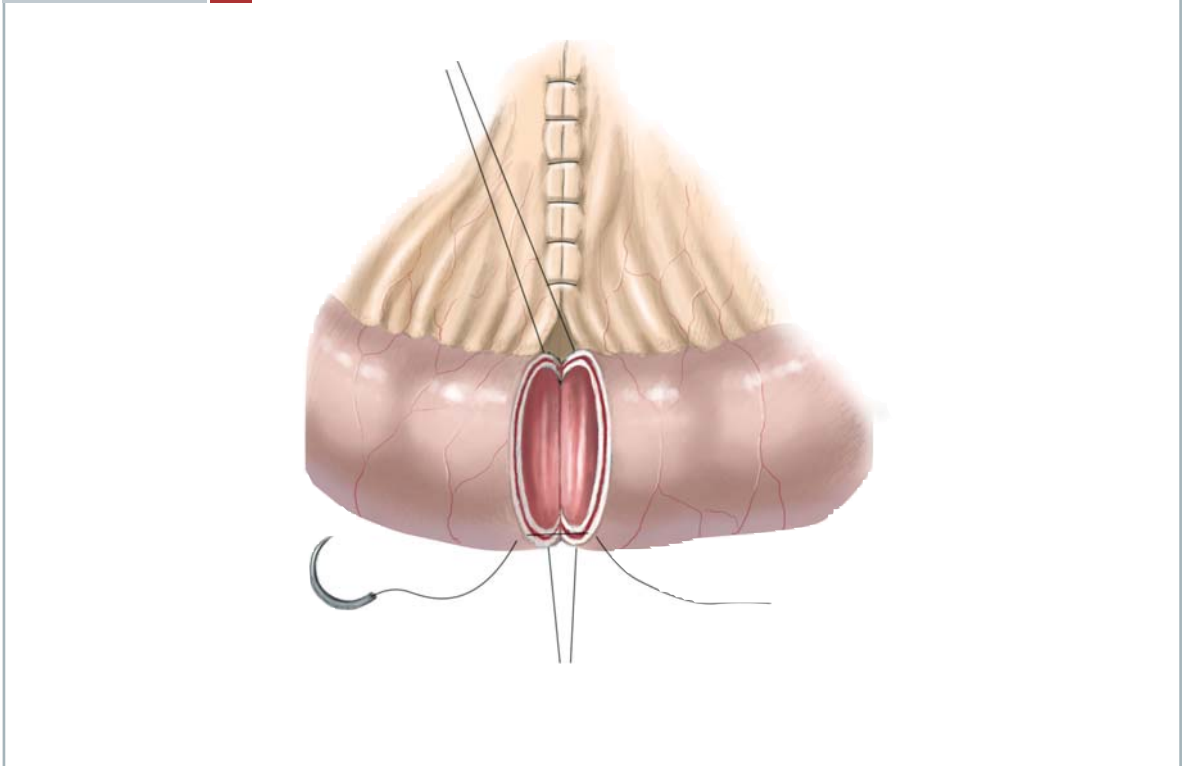


Figure 24.12, 24.13

Short tubular duplications may also be excised in continuity with adjacent bowel. Care is required to obtain a complete excision at the proximal and distal margins of tubular lesions since the exact point of termination of the duplicated bowel can sometimes be difficult to determine.

Very extensive tubular duplications, which if resected would risk a short bowel syndrome, pose a much more difficult problem. In such cases, submucosal resection is an alternative option. The mucosal lining is stripped out using a series of longitudinal seromuscular incisions in the duplication. Bipolar diathermy and gentle blunt pledget dissection are useful. The residual seromuscular sleeve of the duplica-

tion may be safely left in situ provided haemostasis has been achieved. For tubular duplications within the mesentery but separate from the intestine, careful separation of the two leaves of the mesentery and division of vessels on one side only may enable enucleation of the duplication without jeopardizing the blood supply of the adjacent bowel. Whichever technique is used, it is essential to check the viability of the remaining intestine and to resect the junction of duplicated and normal bowel since heterotopic gastric mucosa is frequently present in tubular intestinal duplications. Associated intestinal malrotation will require a Ladd's procedure.

Figure 24.12

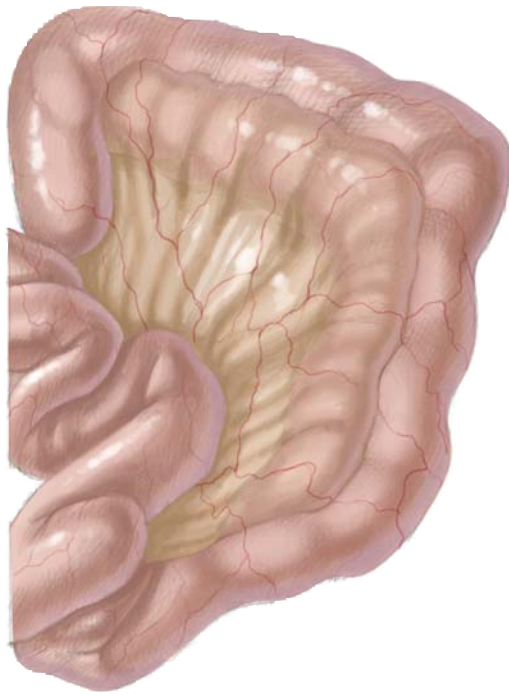


Figure 24.13a

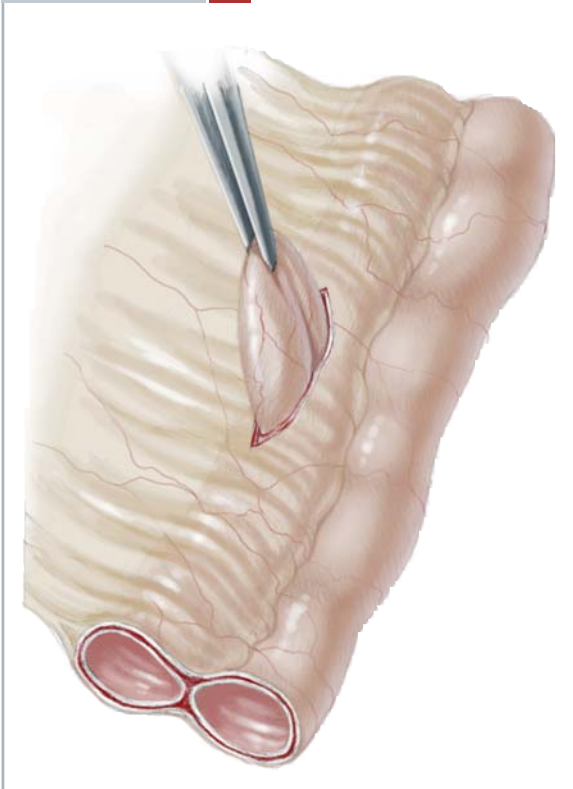

Figure 24.13b

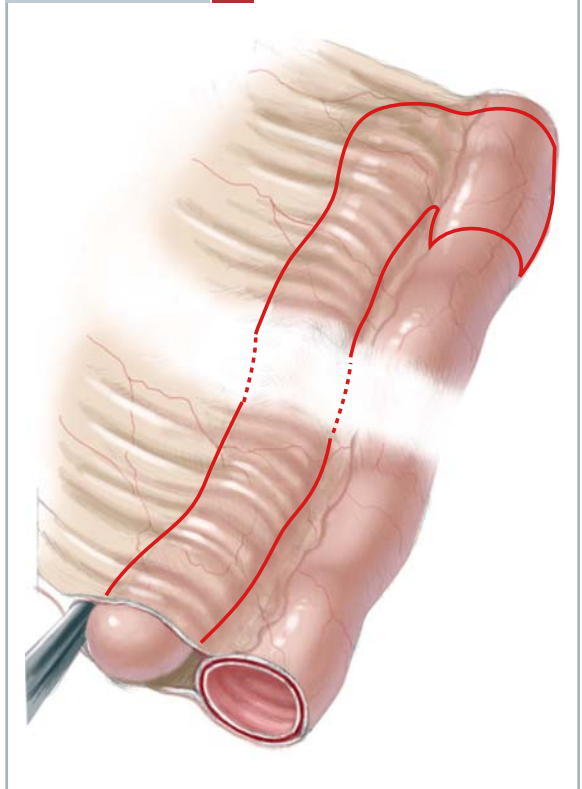


Figure 24.14, 24.15

■ **Colonic (and Appendiceal) Duplications.** All cystic and most tubular duplications can be excised by segmental colonic resection. The bowel is reanastomosed with an end-to-end, single layer, extramucosal suture technique. With rare total colonic duplications, the duplicated bowel may lie lateral or medial to the normal colon and often has a proximal connection. Heterotopic gastric mucosa is rarely found and thus distal fenestration is possible. This can be done with a linear stapling device introduced

through an enterotomy near the distal margin of the duplication. To avoid leaving a problematic spur, the distal end of the septum must be divided completely. If there is complete hindgut duplication with two perineal openings, then a preliminary double de-functioning colostomy is recommended. The duplicated bowel can later be transected at the level of the rectum and anastomosed to the normal rectum. The mucosa of the redundant distal segment is excised.

Figure 24.14

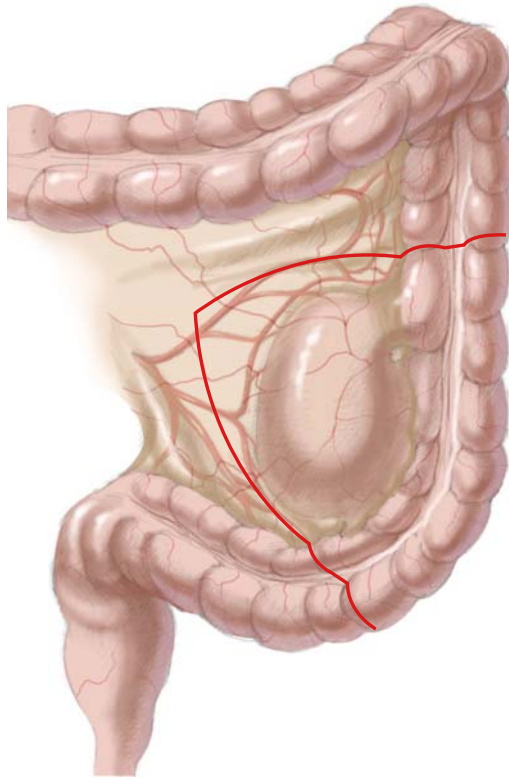


Figure 24.15a

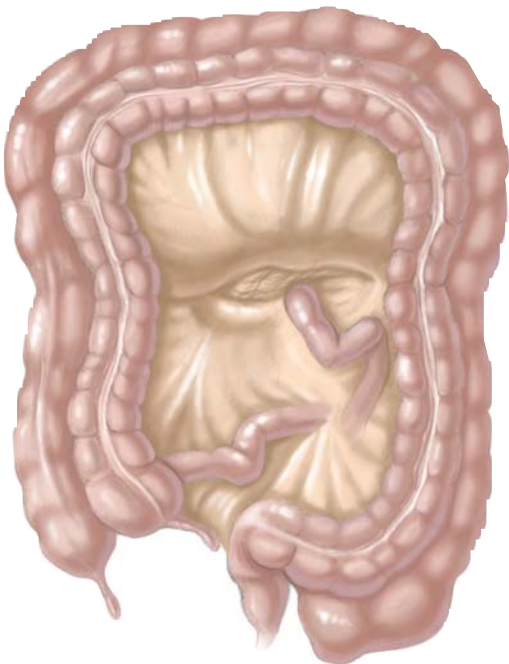


Figure 24.15b

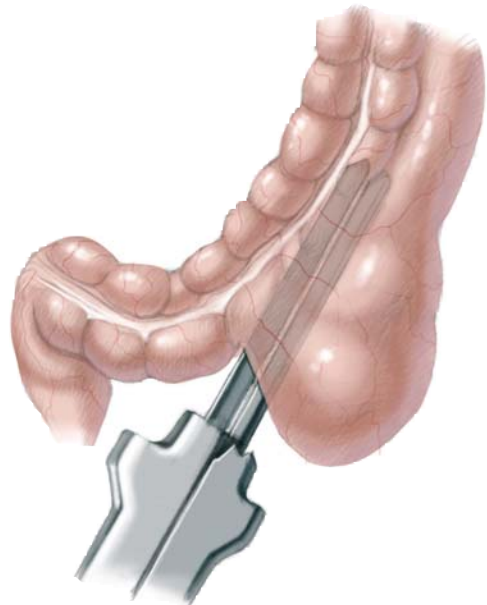


Figure 24.16, 24.17

■ **Rectal Duplications.** Rectal duplications often present in the neonatal period as a perineal mucosal swelling and/or a fistula extending to the perianal area or anorectum. Some are cystic lesions with no external or internal communication. They extend

into the retro rectal space and do not communicate with the urinary tract. Rarely, they first manifest as rectal prolapse in an infant. They may be excised by one of several approaches.

Figure 24.18, 24.19

Small submucosal rectal lesions can be excised endorectally. As the anus is dilated with an anal retractor, the cyst bulges forward. The rectal mucosa over the cyst is incised and, working within the submucosal plane of the rectum, the cyst is gradually dissected free. Local injection of 1:200,000 adrenaline and bipolar diathermy are helpful in the dissection. The cyst should not be decompressed until near the end of the dissection as the wall tension can facilitate the dissection. The incision in the rectal mucosa is repaired with interrupted absorbable sutures.

A limited perineal excision is all that is required for a localised small mucosal duplication. In the case

of larger or more complex duplications, some of which have a lateral or cranial diverticulum, the posterior sagittal approach provides excellent exposure of the retrorectal space. With attention to bowel preparation and antibiotic prophylaxis, a covering colostomy is rarely necessary. Infected rectal duplication cysts are best treated by preliminary drainage and then resected once the acute inflammation has settled. Rectal duplications should be completely excised if possible because numerous examples of late malignant degeneration of these cysts have been described.

Figure 24.16

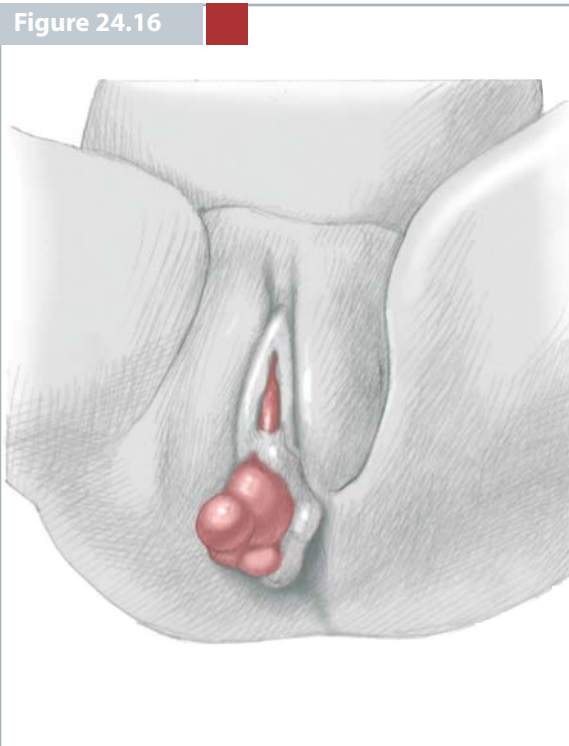


Figure 24.17

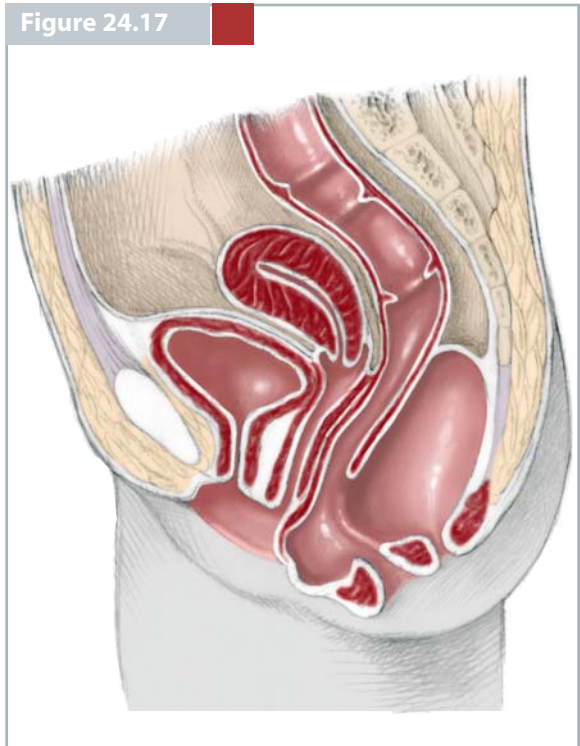


Figure 24.18

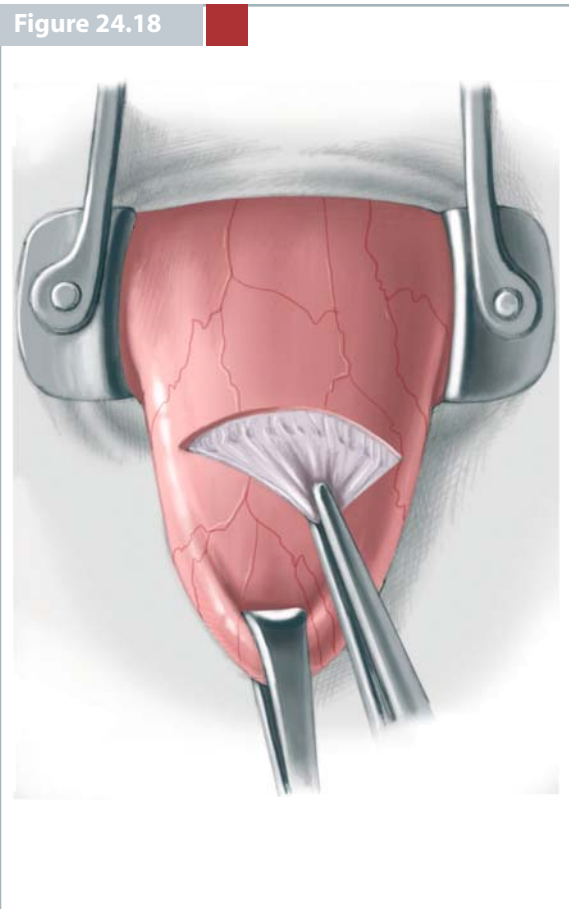
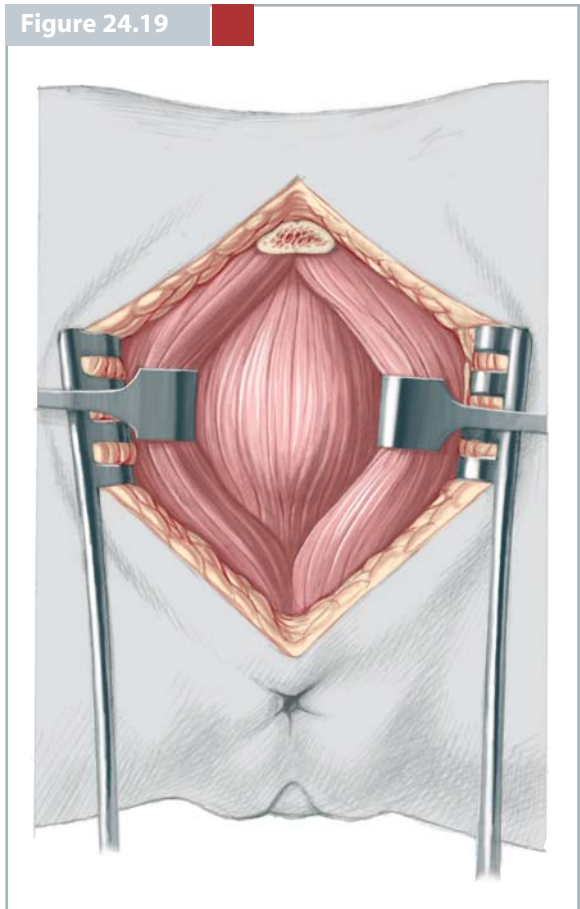


Figure 24.19



CONCLUSION

The histology of all excised duplications should be examined to assess the completeness of the excision, to document the presence of heterotopic mucosa and to exclude neoplasia. The specific features of postoperative clinical management are determined by the anatomy of the duplication cyst and the complexity of the surgical procedure. Surgical complications are related to the size and location of the cyst, the presence of a communication with the gastrointestinal tract or spinal canal, the existence of heterotopic gastric mucosa and potential involvement of mesenteric vessels. Incomplete excision is a particular risk with thoracoabdominal duplications because of their size and complexity; the consequences of incomplete excision include meningitis, gastrointestinal bleeding and perforation and respiratory complications.

In an analysis of 72 children with alimentary tract duplications referred to the Hospital for Sick Children, London, between 1973 and 1992, vertebral anomalies were found in 20% of patients (especially foregut lesions) and heterotopic gastric mucosa in

30% of duplications (more common in foregut and tubular duplications). Twelve patients had incidental, asymptomatic duplications associated with other major congenital anomalies. In 60 patients, with a median age of 3 months, the duplication was the principal pathology. In this group, thoracoabdominal lesions were responsible for much of the overall morbidity and mortality; five patients (9%) died from post-operative complications. However, adherence to the principles outlined can minimize the hazards associated with large or complex gastrointestinal duplication cysts. Mortality should now be exceptionally rare.

The key steps in the successful surgical management of gastrointestinal duplications include: a thorough understanding of the spectrum of these lesions, careful preoperative assessment of the cyst and its potential associated pathology, appropriate operative planning, complete excision where possible, and a full understanding of the alternative techniques if excision is deemed too hazardous.

SELECTED BIBLIOGRAPHY

- LaQuaglia MP, Feins N, Eraklis A, Hendren WH (1990) Rectal duplications. *J Pediatr Surg* 25:980-984
- Norris RW, Brereton RJ, Wright VM, Cudmore RE (1986) A new surgical approach to duplications of the intestine. *J Pediatr Surg* 21:167-170
- Pulligandla PS, Nguyen LT, St-Vil D et al (2003) Gastrointestinal duplications. *J Pediatr Surg* 38:740-744
- Puri P (2003) Duplications of the alimentary tract. In: Puri P (ed) *Newborn surgery*. Arnold, London, pp 479-488
- Stringer MD, Spitz L, Abel R, Kiely E, Drake DP, Agrawal M, Stark Y, Brereton RJ (1995) Management of alimentary tract duplication in children. *Br J Surg* 82:74-78

Michael E. Höllwarth

INTRODUCTION

The term “short bowel” has been defined by Rickham in 1967 as a small intestinal remnant of 75 cm or less in the newborn, which equals 30% of normal small bowel length in that age group. A more functional description is preferred by most authors defining a “short bowel syndrome” (SBS) as a state of significant maldigestion and malabsorption due to an extensive loss of functional absorptive intestinal surface area.

The prevalence of SBS has been increasing over the last two decades due to the enormous progress in intensive care of babies with either severe acquired intestinal diseases such as necrotizing enterocolitis and volvulus, or congenital malformations leading to the SBS, such as multiple intestinal atresia. Rarely SBS is caused by a genetically determined disease such as a congenital short bowel or a total intestinal aganglionosis.

Following extensive loss of small bowel, the symptoms of an individual baby depend on the absorptive capacities of the intestinal remnants. Resection of the jejunum is well tolerated due to an enormous adaptive capacity of the ileum, the intact enterohepatic circulation of bile salts and the preserved absorption of vitamin B₁₂. In contrast, if the entire ileum is lacking, absorption of nutrients is significantly more difficult due to the limited intestinal adaptation capacities of the jejunum. Non-absorbed intestinal contents, including bile acids, spill over into the colon and may cause significant diarrhoea. Furthermore, loss of the ileum leads to a reduction of the bile salt pool, malabsorption of fat and fat soluble vitamins, as well as to a vitamin B₁₂ deficiency.

The pathophysiological process that follows an extensive loss of small bowel is called intestinal adaptation. It includes, firstly, morphological changes leading to an increase of absorptive surface area, secondly, functional changes resulting in an augmentation of the absorptive capacity of the remaining enterocytes, and thirdly, an increased intestinal diameter with a concomitant reduction of the motility thereby slowing down the intestinal transit time of chyme.

The presence of intraluminal food is the most important driving force for intestinal adaptation. Enteral nutrients stimulate gastrointestinal secretions and hormones that are known to exert trophic effects on the mucosa. Recent evidence suggests that glucagon-like peptide 2, human growth hormone, epidermal growth factor, and insulin-like growth factor-I may play an important role in the process of intestinal adaptation.

Surgery is indicated in selected patients only, firstly when the *absorptive surface area is definitely too small* to allow enteral feeding, secondly, when severe *dysmotility in grossly dilated loops* entails stagnation of chyme, and thirdly, when *intestinal transit time is too fast* to allow sufficient absorption of nutrients. Whereas in the first group of patients intestinal transplantation is the mainstay of surgical therapy, peristalsis can be improved in the second group by intestinal tapering or tapering and lengthening. In the third group, antiperistaltic segments, colonic interposition, intestinal valves, and/or artificial invagination have been used in selected patients. These surgical techniques are described in detail on the following pages.

Figure 25.1

■ **Tapering.** In patients with enough absorptive surface area – at least 50 cm with ileocecal valve – the tapering can be performed by resection of a long triangular (or elliptical) antimesenteric segment. The bowel segment is isolated from surrounding adhesions and the chosen length for the tapering is marked by 5/0 stay sutures, which indicate the later-

al margins of the planned triangular resection. One stay suture is located exactly at the antimesenteric line and indicates the end of resection which is at the tip of the triangle. The resection can be performed by means of a GIA stapler in very large dilated loops (see Chap. 22)

Figure 25.2, 25.3

We prefer to resect in small babies the antimesenteric redundant part with sharp scissors, thus allowing some bleeding from the resected margins, and we try to avoid carefully any disturbance of the local circu-

lation, which inevitably would result if we use cautery. The antimesenteric anastomosis can be accomplished either by a continuous running 6/0 absorbable suture or by 6/0 interrupted sutures.

Figure 25.1

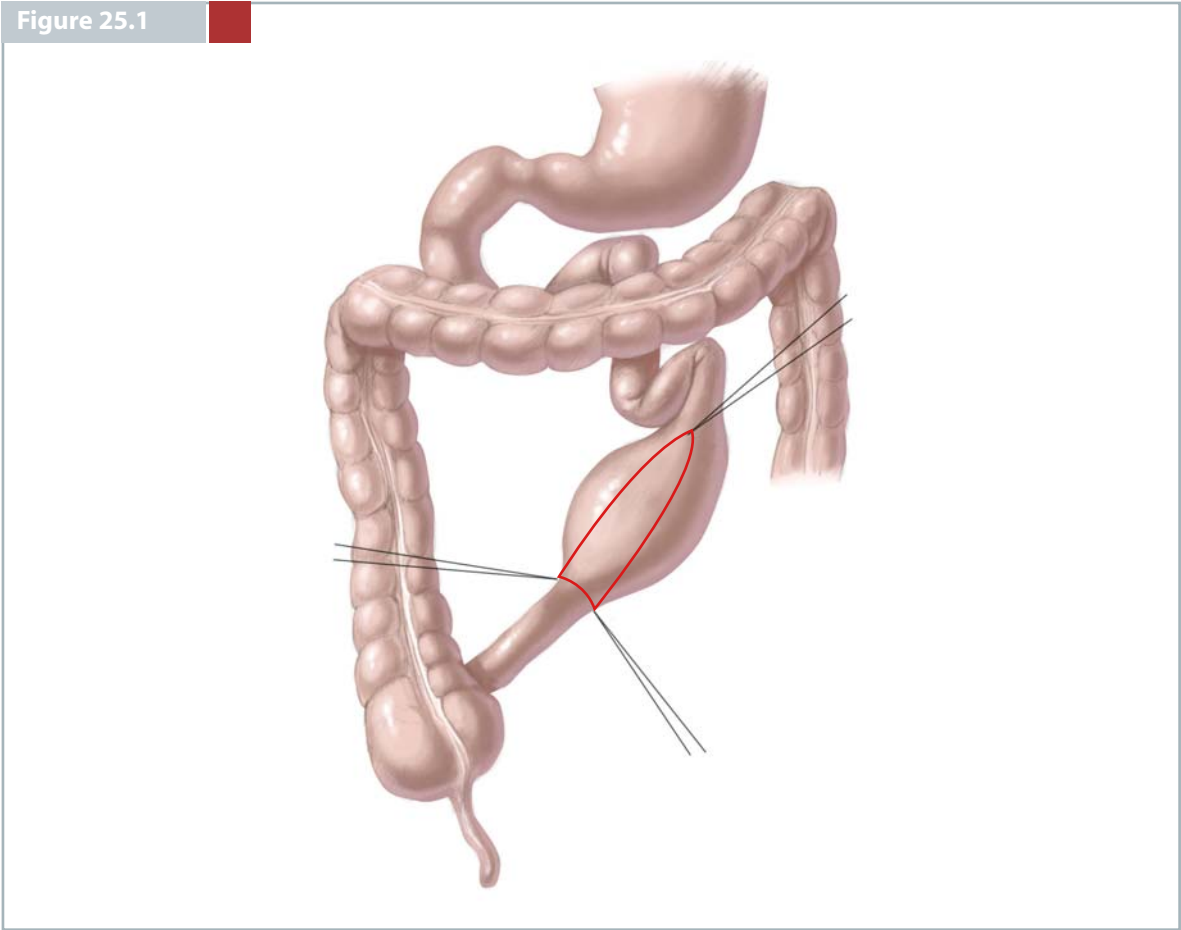


Figure 25.2

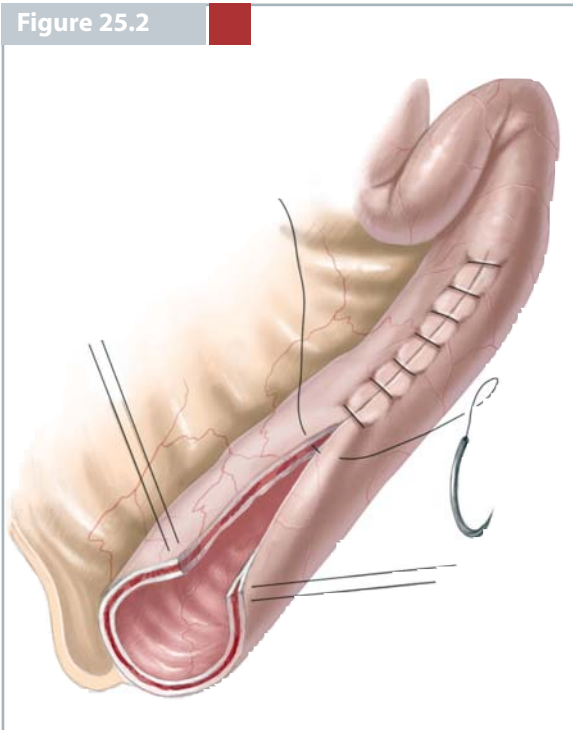


Figure 25.3

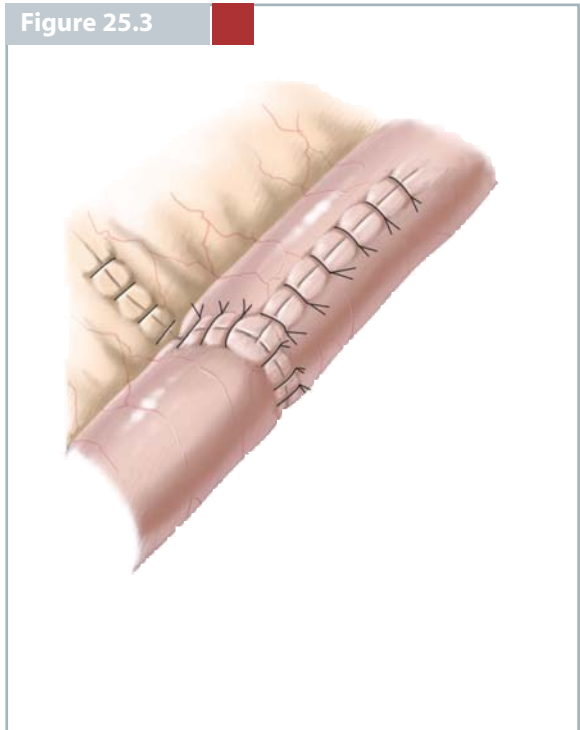

Figure 25.4–25.7

The important part in performing any kind of intestinal anastomosis lies in the technique that the stitches should include only the seromuscular layer, thereby leaving out the mucosal layer. If the stitches take equal amounts of tissue on either side, both segments of the bowel are perfectly adapted and the mucosal edges are lying side by side. Another important part of this technique is to avoid too much tension when tying knots, thus not compromising circulation. This technique was originally described by Halsted in 1912 and has the advantage of preventing mucosal necrosis just under the stitch, thereby supporting a rapid and perfect healing of the anastomosis.

If, additionally, an anastomosis to the distal or proximal part of the intestinal tract has to be performed, the same surgical technique is useful. First, the two intestinal ends are brought together with two to four 5/0 stay sutures. Thereafter, the anastomosis with interrupted 6/0 stitches begins at anterior wall. The needle takes a good part of the seromuscular layer on either side. The suture is tied carefully, avoiding any strangulation. The single interrupted sutures are continued in the same way until the whole anterior wall is anastomosed.

The posterior wall is sutured in a similar way, after turning around.

Figure 25.4

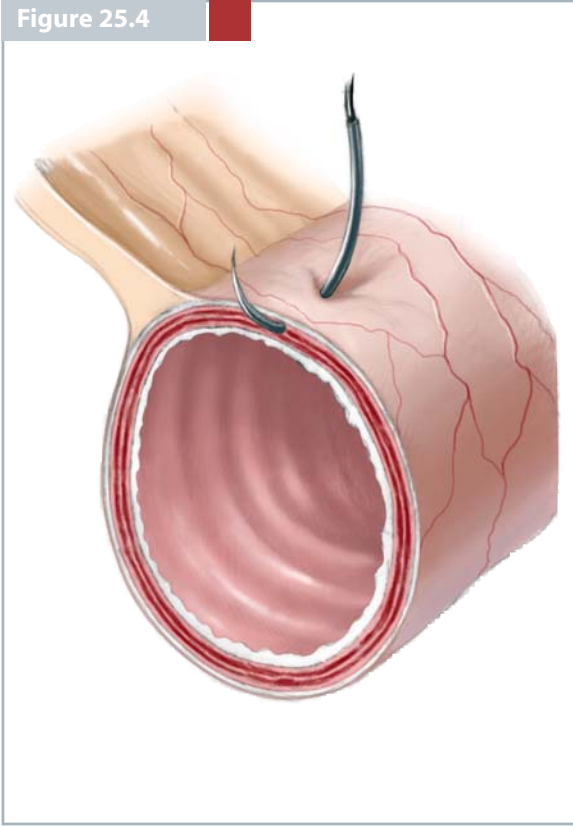


Figure 25.5

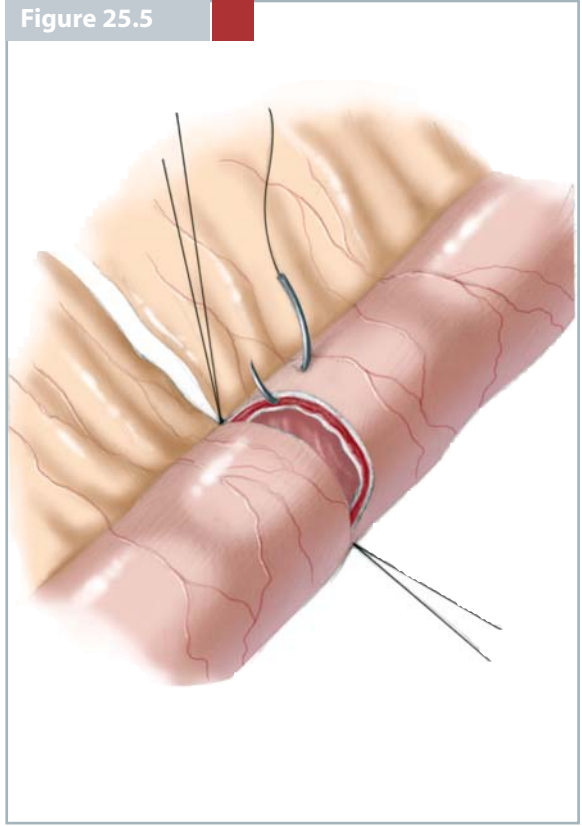


Figure 25.6

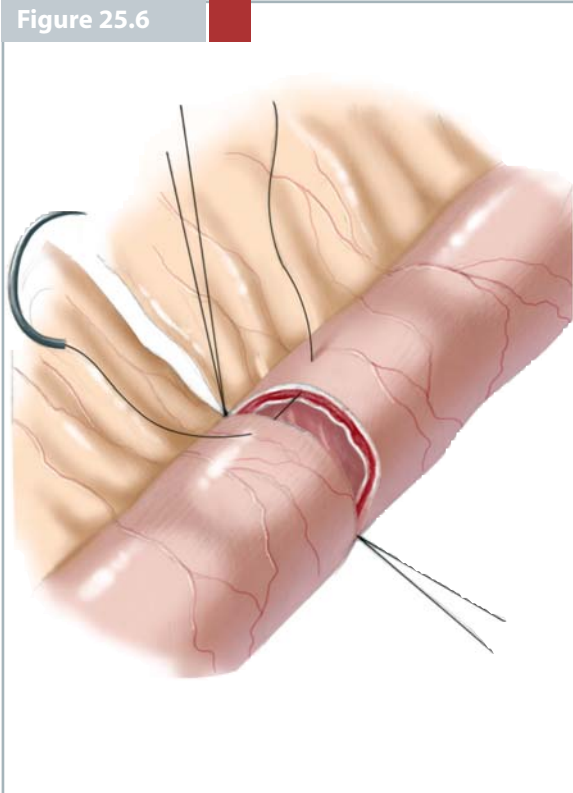


Figure 25.7

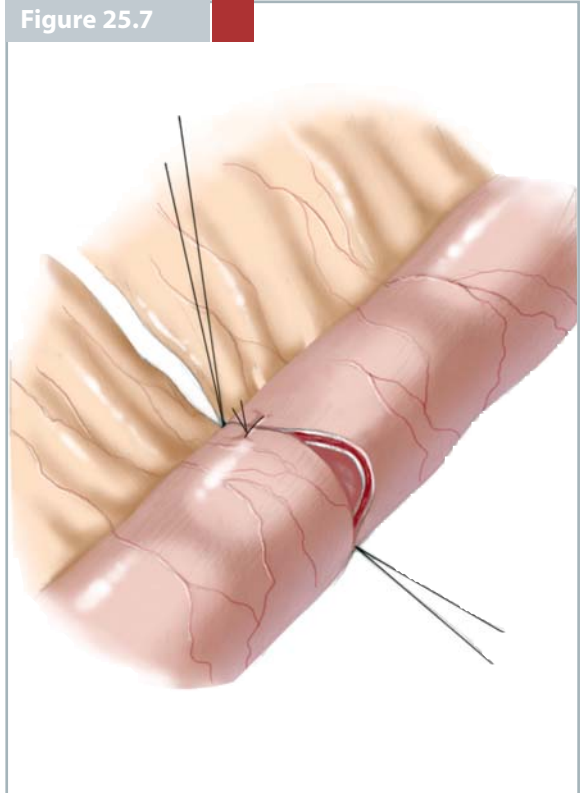


Figure 25.8–25.11

The abdominal wall is closed using 3/0 or 4/0 interrupted single-layer figure-of-eight absorbable sutures. The knot must be tied rather loosely without strangulating the tissue.

Figure 25.8

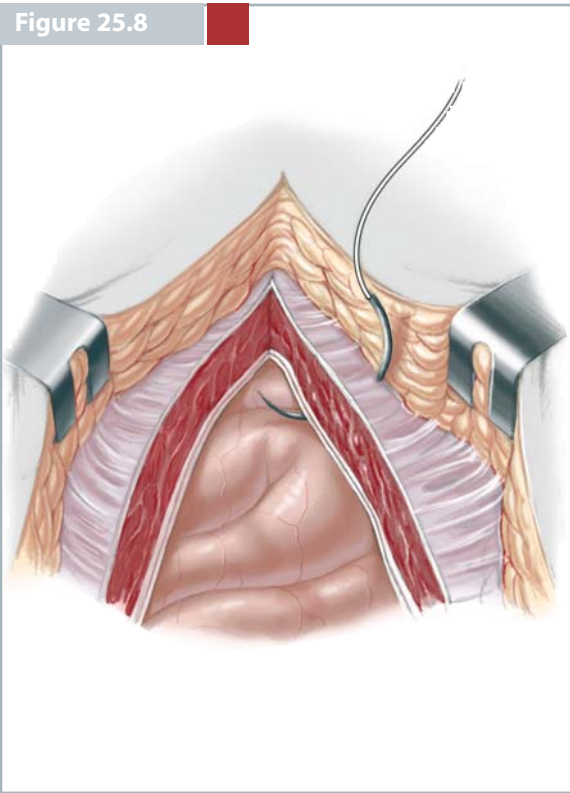


Figure 25.9

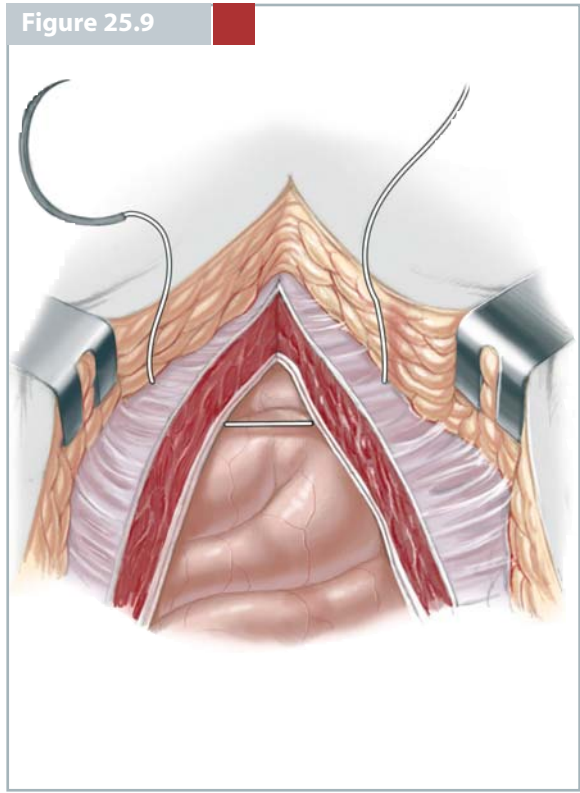


Figure 25.10

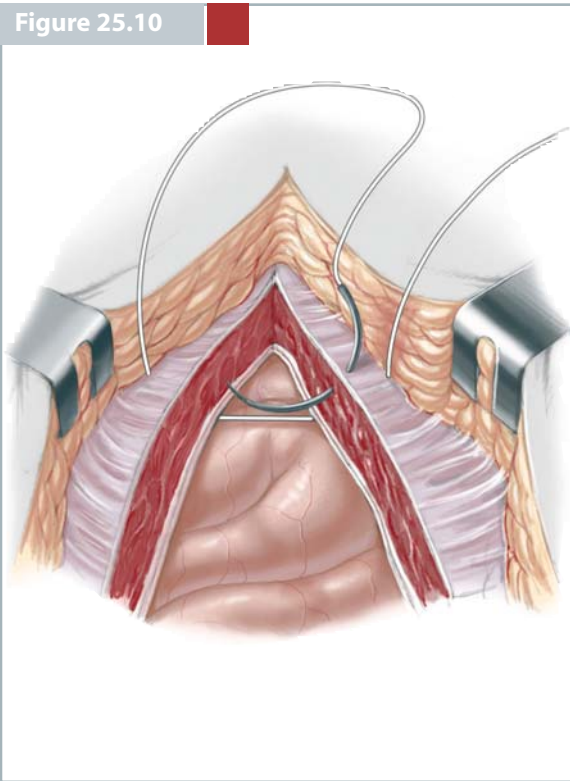


Figure 25.11

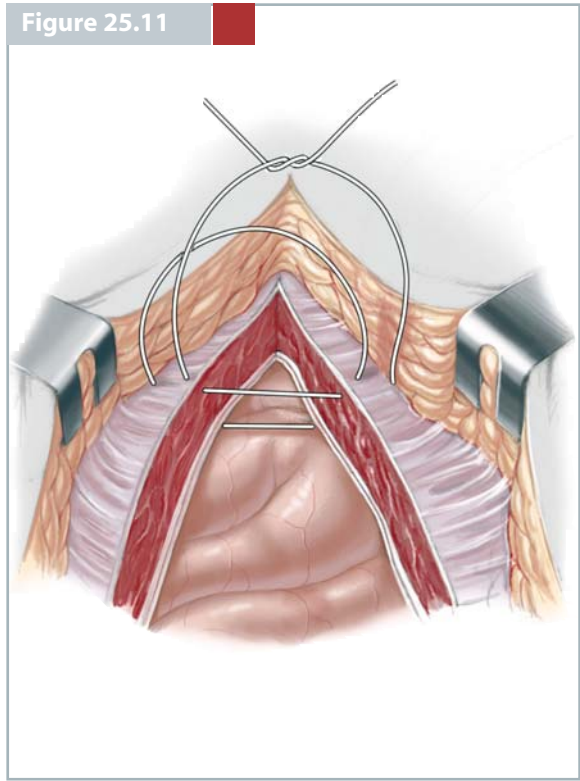


Figure 25.12

■ **Infolding.** This method has the same effect as tapering but saves all existing absorptive surface area. Therefore, it is indicated in cases with a rather short intestinal tract when it seems advisable not to sacrifice any mucosal surface. The intestinal tract can remain closed in most of the patients. The intestinal loops that are selected for the infolding method are marked with 5/0 stay sutures on the lateral side and

on both ends. The lateral margins are approximated with 5/0 or 4/0 nonabsorbable seromuscular stitches, thereby enfolding the tissue in-between. It is reported that the plicated segments are prone to breakdown with time and some authors suggest resecting on each side a serosal strip or a triangular segment in order to support the development of dense adhesions (see Chap. 22)

Figure 25.13, 25.14

■ **Tapering and Lengthening.** Bianchi first reported an experimental procedure combining the method of tapering with the use of the redundant tissue for lengthening the bowel. Indications for this method are patients with very short bowel segments but largely dilated loops characterised by inefficient to-and-fro peristalsis, stasis of chyme and bacterial overgrowth. The technique is based on the fact that the vessels coming from the mesentery are divided extramurally in branches supplying either side of the bowel separately. Therefore, careful longitudinal division of a dilated intestinal segment between the branching vessels results in two intestinal halves

with an intact blood supply for each side. The first step of the procedure consists of careful separation of the vessel branching in the right and left group and supplying either part of the selected intestinal tract. The space between the vessel layers can be opened by introducing a haemostat and spreading the two layers. The small vessel groups on each side are secured by fine vessel loops of different colours for the right and left parts.

If the space between the branches is large enough that a GIA stapler can be introduced, the intestinal loop can be divided in the midline and anastomosed longitudinally, step by step.

Figure 25.12

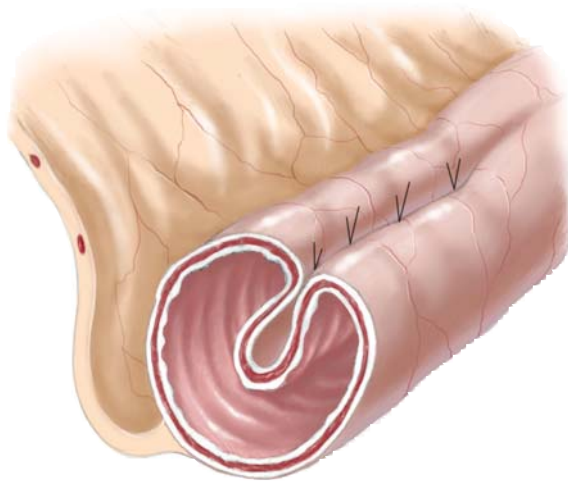


Figure 25.13

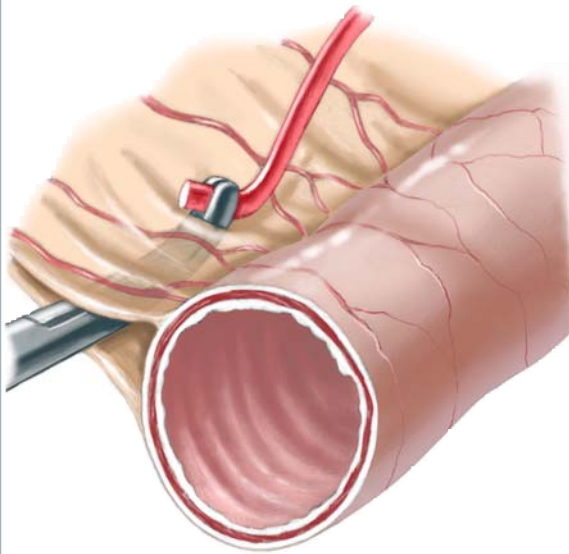


Figure 25.14

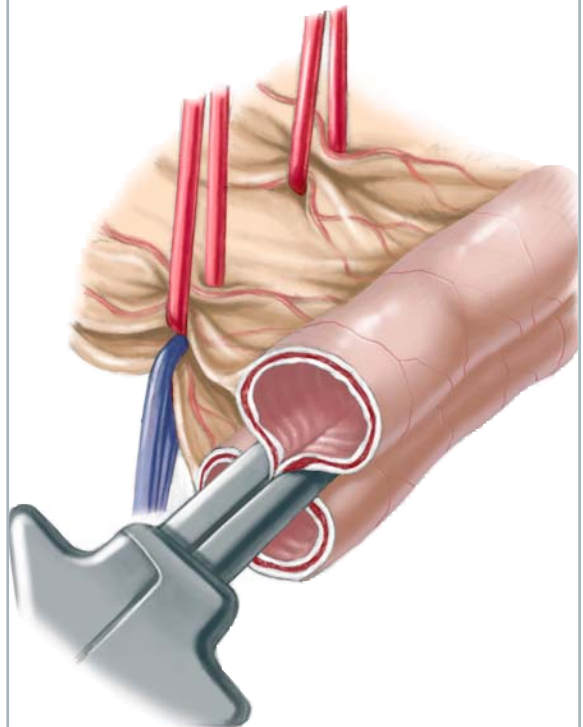


Figure 25.15, 25.16

However, if the space is too small to insert a stapler – which is the case when the bowel is not extremely dilated – then a sharp longitudinal division is our preferred method. As already mentioned above, we try to

avoid any cautery or to use it very cautiously. Serosomuscular 6/0 absorbable sutures are used for the longitudinal anastomosis of the divided segments of the bowel.

Figure 25.17, 25.18

Since both sections of the bowel hang on the same mesenteric segment, a helix-like isoperistaltic anastomosis is easier to perform than an anastomosis with the two segments sliding one on the other. The

helix technique avoids traction on the nutrient vessels, which is critical because necrosis of the divided segments has been reported.

Figure 25.15

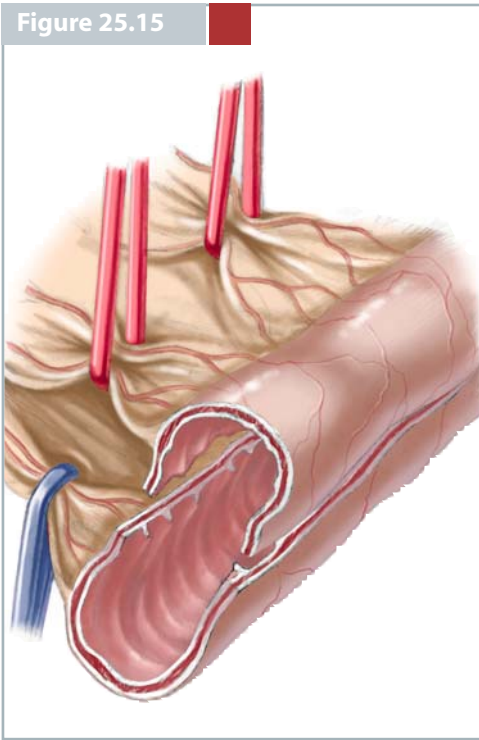


Figure 25.16

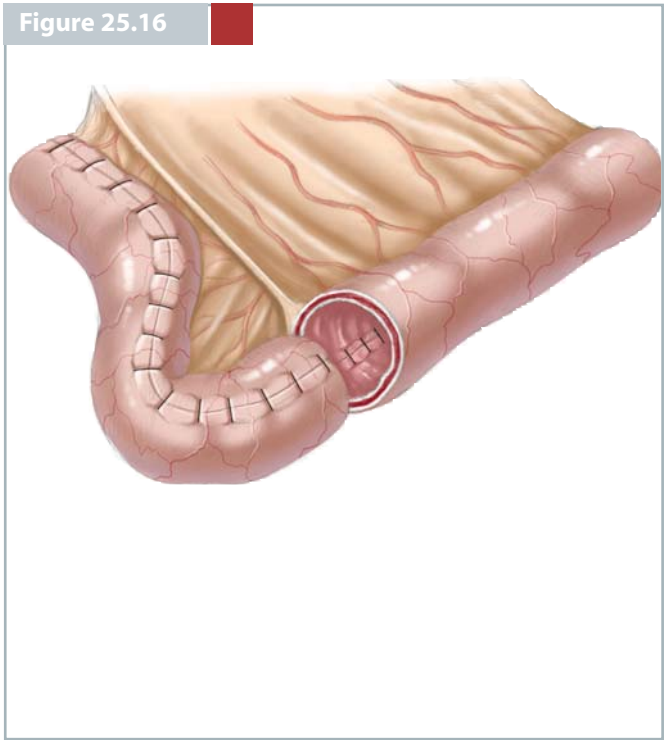

Figure 25.17

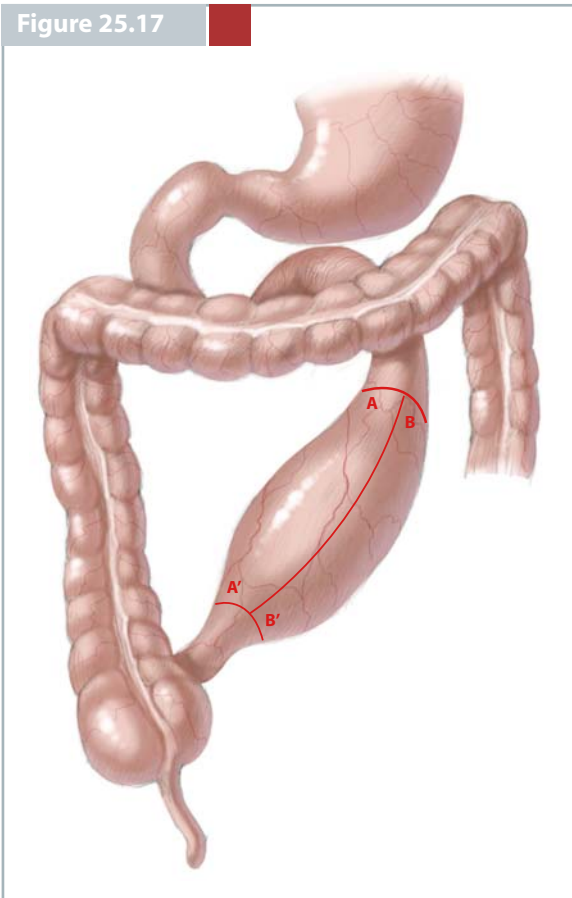


Figure 25.18

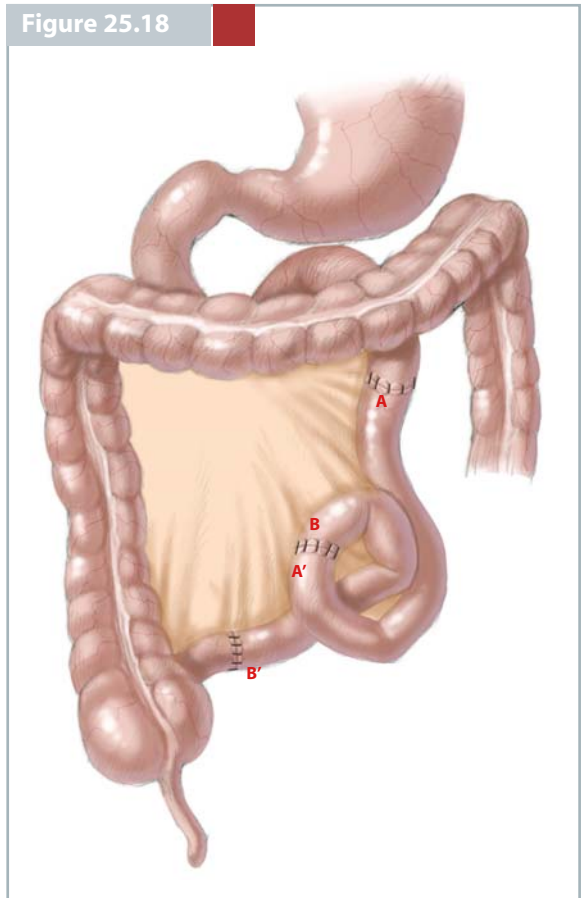


Figure 25.19–25.21

Antiperistaltic segments are only indicated in cases with good propulsion of the luminal chyme, while it would be contraindicated in cases with a disturbed motility. A number of different intestinal interpositions have been used in the past, both experimentally and in some selected cases clinically. In the following paragraph the method of antiperistaltic small or large bowel segment, as well as the interposition of an isoperistaltic colonic segment will be briefly demonstrated.

Reversal of distal small bowel loops has been studied experimentally for years. The ideal length of the reversed segment appears to be 10 cm in adults and 3 cm in infants. The antiperistaltic segment acts as a physiological valve by causing either a retrograde peristalsis or by functioning as an effective brake for the passage of chyme. Since the ideal length is difficult to estimate for a given patient, this method has not consistently resulted in clinical improvement. The distal ileum – if available – is best used as antiperistaltic segment shortly before the ileocecal valve.

In an infant, a 3-cm segment of small bowel is first identified in regard to its blood supply, which should come from one major branch of the mesenteric vessels. Care must be taken that neither the blood supply to the remainder small intestine nor to the colon, if present, is disturbed. The segment is isolated and the appropriate mesenteric base is isolated in a way that the segment can be reversed by 180° without impairing the blood flow. Finally the proximal and distal intestinal anastomoses are performed as described above.

In the same way as described above a 3 cm to 5 cm antiperistaltic segment of the colon can be used. If no ileocecal valve is present, the best way is to reverse the first part of the colon immediately after the small intestine. However, if the ileocecal valve has been preserved the antiperistaltic colonic segment can be interposed between the distal small bowel and the valve. The method has rarely been used in humans and long term results are not available.

Figure 25.19

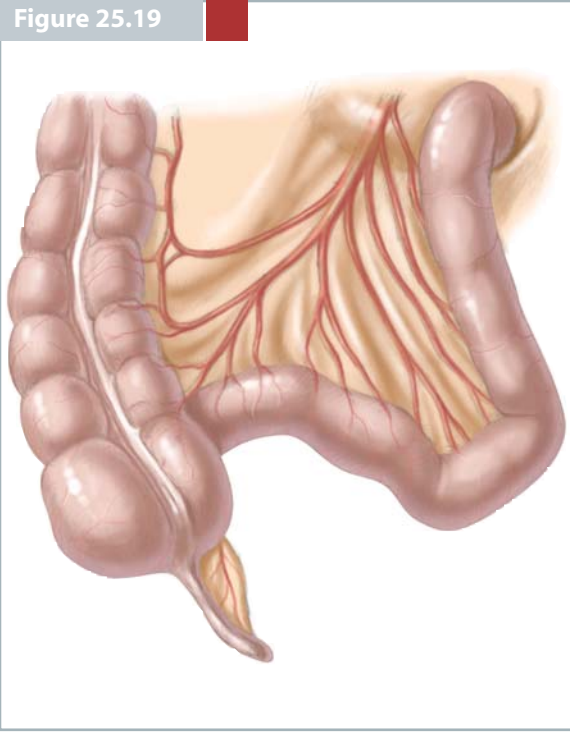


Figure 25.20

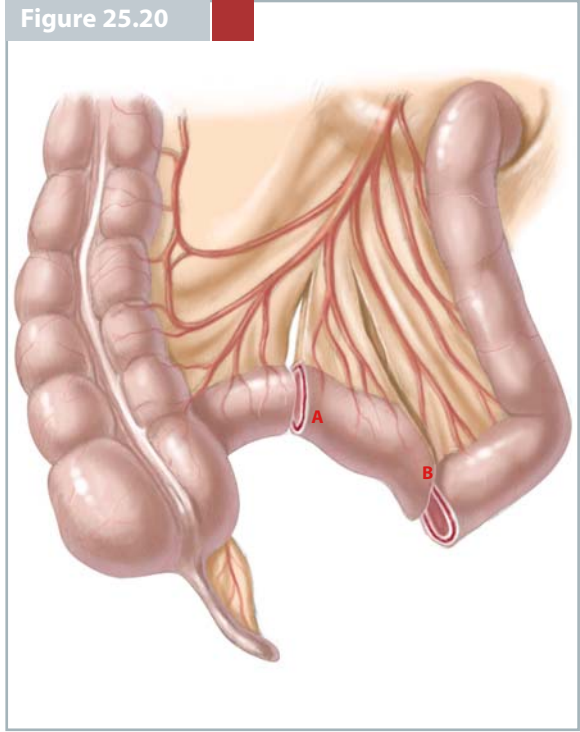


Figure 25.21

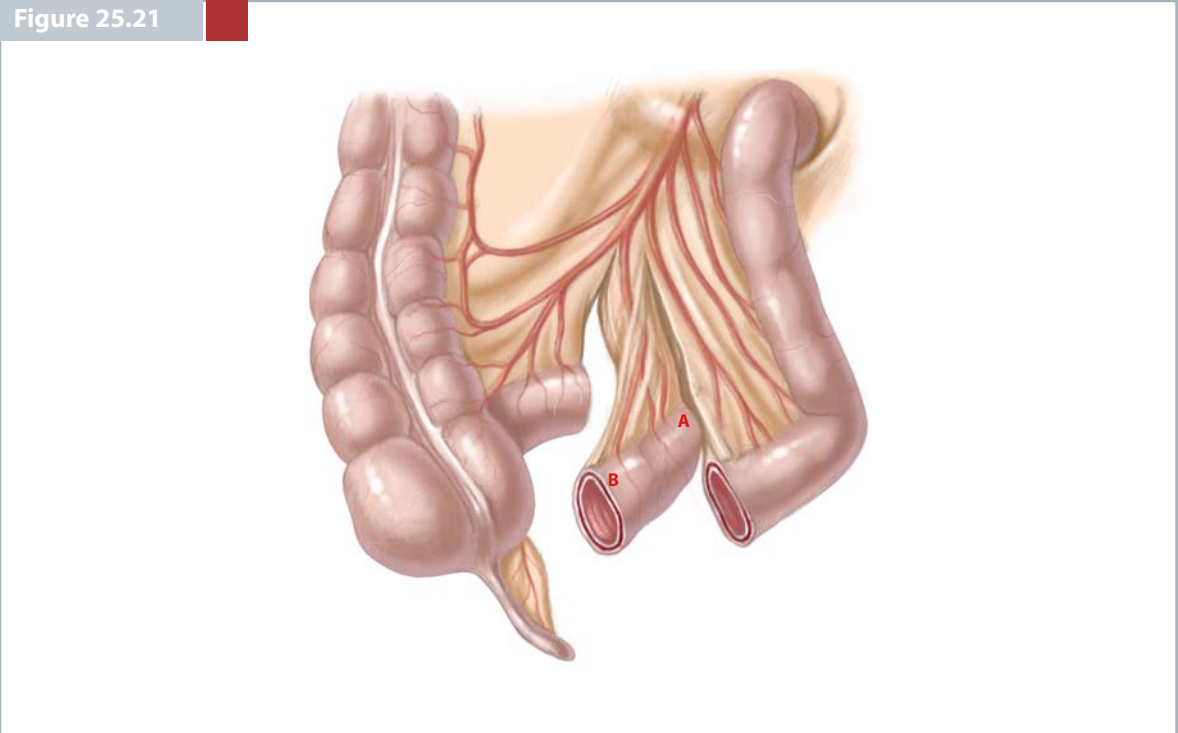


Figure 25.22, 25.23

Isoperistaltic interposition of colon has the advantage of using none of the small bowel remnants. Isoperistaltic colonic interposition is best done with a 10- to 15-cm segment into the proximal part of the small intestine. Experimental evidence exists that the isoperistaltic colon prolongs transit time and gains

some absorptive qualities. Favourable but highly variable results have been reported from the use of this method in children, and some groups have reported improved nutrient absorption and weaning from parenteral nutrition.

Figure 25.22

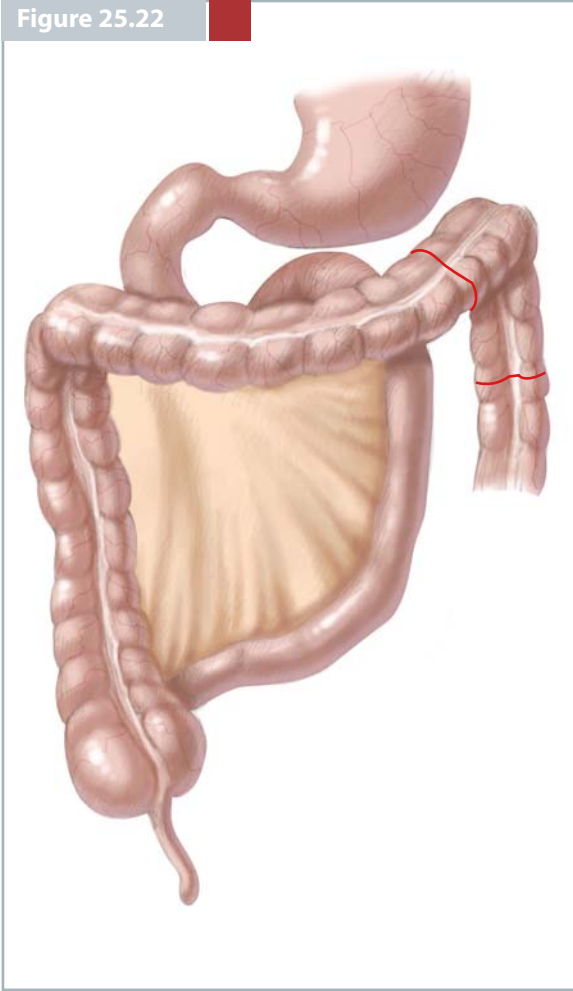


Figure 25.23

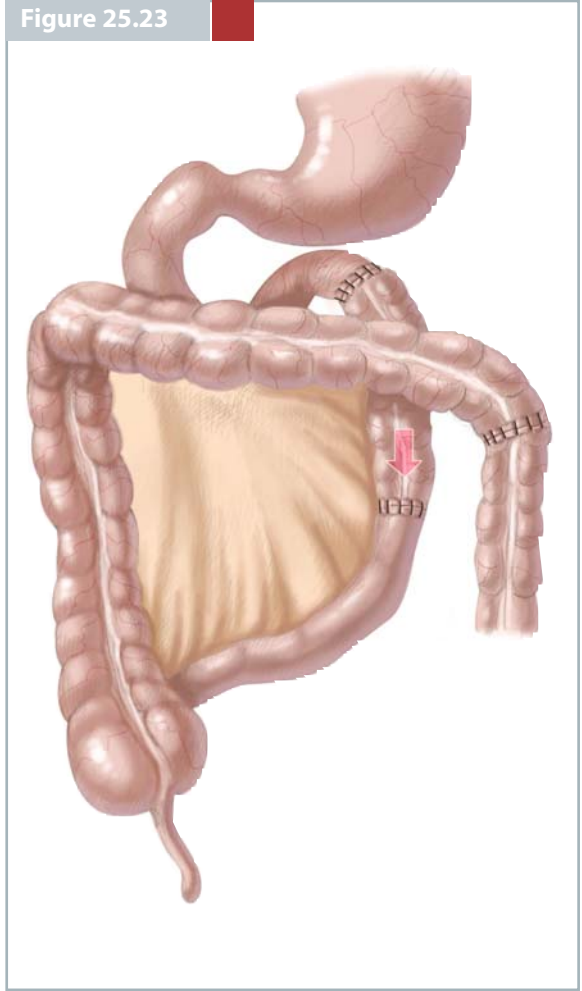


Figure 25.24–25.26

The benefits of the ileocecal junction on long-term outcome of babies with SBS has been questioned, there exists a large body of evidence concerning its powerful impact on intestinal transit time by slowing the passage of intraluminal nutrients into the colon. Therefore, a variety of experimental surgical procedures have been devised to slow down the intestinal transit time by creation of artificial valves. The valve must be placed at the distal end of the small bowel. The intestine is transected at an appropriate level and the last 2–4 cm of the end of the proximal bowel are everted and firmly fixed by 4/0 or 5/0 seromuscular

interrupted sutures onto the underlying seromuscular bowel wall. The distal intestinal segment is then pulled over the everted bowel and finally anastomosed to the everted segment and to the proximal intestine by seromuscular interrupted stitches. The result corresponds to a typical prograde intussusception and may act as a valve similar to the ileocecal valve. A valve less than 3 cm can also be constructed in a reversed manner by everting the distal end of small bowel, thereby creating a retrograde intussusception. This method may be more efficient, but definite clinical experience is very scarce.

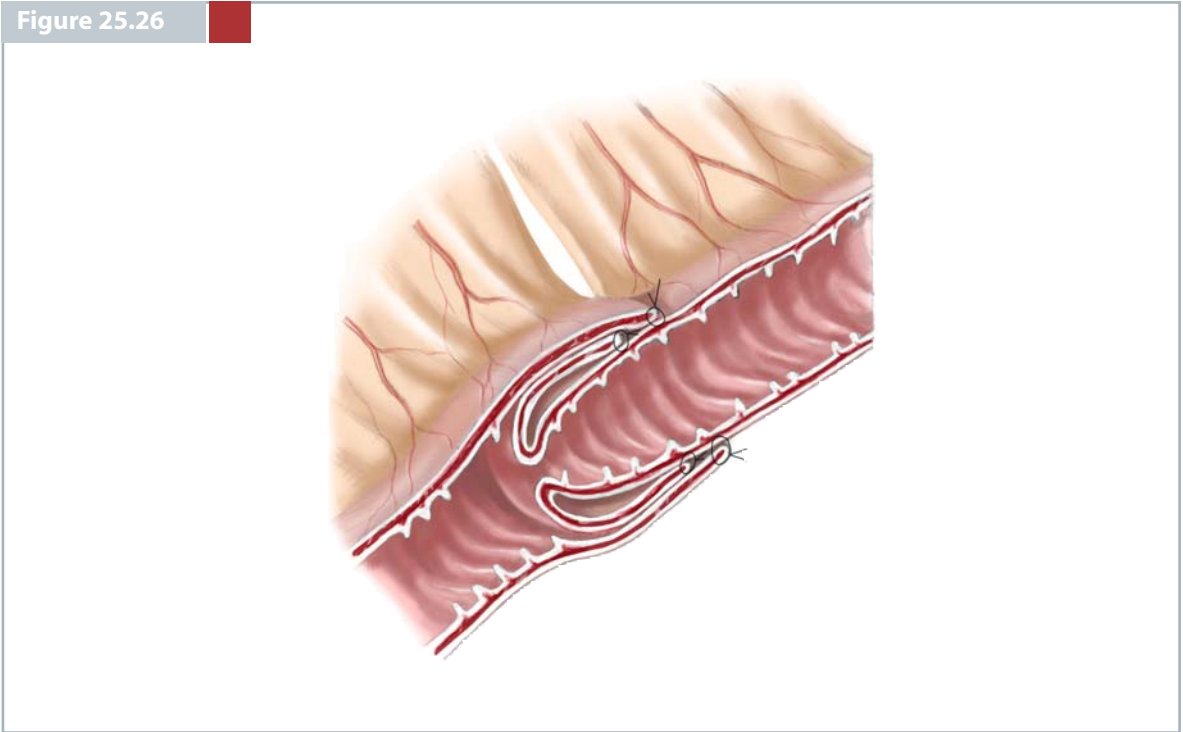
Figure 25.24

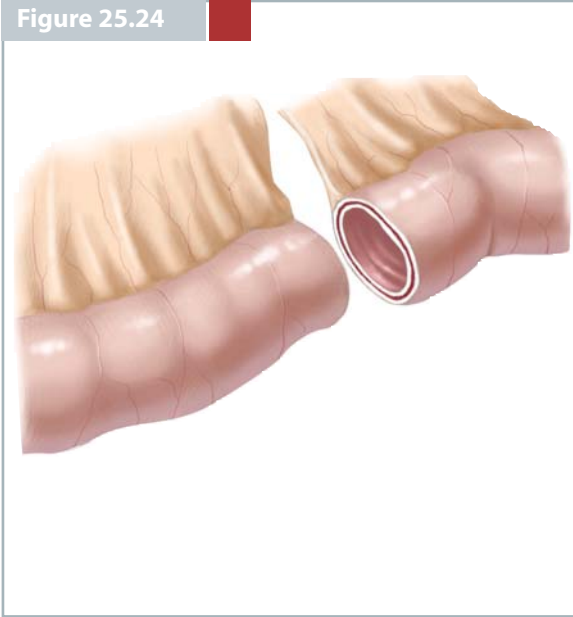

Figure 25.25



Figure 25.26



CONCLUSION

The mainstay of the treatment of a newborn or child with an SBS consists of a sophisticated enteral stimulation with an individually balanced nutritional equilibrium among carbohydrates, proteins and fatty acids. The enteral nutrition is the best stimulus for intestinal adaptation. The use of additional hormonal therapies has not yet proved sufficiently effective by controlled studies. Weaning from parenteral nutrition should be possible in more than 80% of the patients. Crucial for a successful weaning is the presence of a good propulsive intestinal motility – with or without adjunct surgical measures. Therefore, the above described methods are indicated only in some individuals as a helpful adjunct therapy to the enteral nutritional program and must be planned very carefully.

Tapering is indicated in patients with sufficient amount of intestinal length but severely dilated small bowel with impaired propulsive peristalsis. The intestinal content in the enlarged intestinal loops causes bacterial overgrowth, inflammation, and bacterial translocation with recurrent sepsis. Grossly dilated loops exist either primarily due to an intentionally limited resection of small bowel in patients with intestinal atresia, or they are the result of the process of intestinal adaptation with a subsequent dilatation of the intestinal tract.

The method of intestinal tapering and lengthening has attracted large attention in the past and has been used even in newborns with atresia and very

short bowel remnants. However, many of these children died later on a total parenteral nutrition (TPN)-associated liver failure, predominantly those with severe motility disorders. Therefore, today, the method is recommended only in carefully selected patients, that means in SBS children around 1 year of age and not suffering from a life-threatening TPN-associated liver failure. Furthermore, the method is indicated only in patients with a small intestinal length of a maximum of 30 to 40 cm. In patients with longer bowel remnants tapering alone is more appropriate and technically easier.

Basically, all surgical measures with the intention to prolong intestinal transit time must be located at the distal end of the small bowel in order to allow as much digestion and absorption as possible in the proximal band. One exception is the isoperistaltic interposition of a colonic segment that must be placed in the proximal part of the small bowel because not only it prolongs the passage time, but it seems to adapt by time some resorptive capacities thereby increasing additionally the absorptive surface area. A difficulty of all these surgical methods is to find the ideal balance between the desired prolongation of the transit time without producing an ileus. None of these techniques have been used extensively in patients. Therefore, prospective studies are lacking, mostly due to the small number of relevant cases who may profit from such a particular procedure.

SELECTED BIBLIOGRAPHY

- Höllwarth ME (1999) Short bowel syndrome: pathophysiology and clinical aspects. *Pathophysiology* 6 : 1–19
- Höllwarth ME (2003) Short bowel syndrome and surgical techniques for the baby with short intestines. In: Puri P (ed) *Newborn surgery*. Arnold, London, pp 569–576
- Mayr J, Schober PH, Weissensteiner U, Höllwarth ME (1999) Morbidity and mortality of the short bowel syndrome. *Eur J Paediatr Surg* 9 : 231–235
- Sukhotnik I, Siplovich L, Shiloni E, Mor-Vaknin N, Harmon CM, Coran AG (2002) Intestinal adaptation in short-bowel syndrome in infants and children: a collective review. *Pediatr Surg Int* 18 : 258–263
- Thompson JS, Pinch LW, Young R, Vanderhoof JA (2000) Long-term outcome of intestinal lengthening. *Transplant Proc* 32 : 1242–1243

INTRODUCTION

Hirschsprung's disease (HD) is characterised by an absence of ganglion cells in the distal bowel and extending proximally for varying distances. The absence of ganglion cells has been attributed to failure of migration of neural crest cells. The earlier the arrest of migration, the longer the aganglionic segment. The pathophysiology of Hirschsprung's disease is not fully understood. There is no clear explanation for the occurrence of spastic or tonically contracted aganglionic segment of bowel.

The aganglionosis is confined to rectosigmoid in 75% of patients, sigmoid, splenic flexure or transverse colon in 17% and total colon along with a short segment of terminal ileum in 8%. The incidence of HD is estimated to be 1 in 5000 live births. The disease is more common in boys with a male-to-female ratio of 4:1. The male preponderance is less evident in long-segment HD, where the male-to-female ratio is 1.5–2 to 1.

Of all cases of HD, 80–90% produce clinical symptoms and are diagnosed during the neonatal period. Delayed passage of meconium is the cardinal symptom in neonates with HD. Over 90% of affected patients fail to pass meconium in the first 24 h of life. The usual presentation of HD in the neonatal period is with constipation, abdominal distension and vomiting during the first few days of life. About one-third of the babies with HD present with diarrhoea. Diarrhoea in HD is always a symptom of enterocolitis, which remains the commonest cause of death.

The diagnosis of HD is usually based on clinical history, radiological studies, anorectal manometry and in particular on histological examination of the rectal wall biopsy specimens. Barium enema performed by an experienced radiologist, using careful technique, should achieve a high degree of reliability in diagnosing HD in the newborn. It is important that the infant should not have rectal washouts or even digital examinations prior to barium enema, as such interference may distort the transitional zone appearance and give a false-negative diagnosis. A typical case of HD will demonstrate flow of barium from the undilated rectum through a cone-shaped

transitional zone into dilated colon. In the presence of enterocolitis complicating HD, barium enema may demonstrate spasm, mucosal edema and ulceration.

The diagnosis of HD is confirmed on examination of rectal biopsy specimens. The introduction of histochemical staining technique for the detection of acetylcholinesterase activity in suction rectal biopsy has resulted in a reliable and simple method for the diagnosis of HD. Full thickness rectal biopsy is rarely indicated for the diagnosis of HD. Once the diagnosis of HD has been confirmed by rectal biopsy examination, the infant should be prepared for surgery. Biopsies for frozen sections are taken to determine the extent of aganglionosis and level of transition zone.

In recent years, the vast majority of cases of HD are diagnosed in the neonatal period. Many centres are now performing one-stage pull-through operations in the newborn with minimal morbidity rates and encouraging results. The advantages of operating on the newborn are that the colonic dilatation can be quickly controlled by washouts and at operation the calibre of the pull-through bowel is near normal, allowing for an accurate anastomosis that minimizes leakage and cuff infection. Recently, a number of investigators have described and advocated a variety of one-stage pull-through procedures in the newborn using minimally invasive laparoscopic techniques. More recently, a transanal endorectal pull-through operation performed without opening the abdomen has been used with excellent results in rectosigmoid HD.

A number of different operations have been described for the treatment of HD. The four most commonly used operations are the rectosigmoidectomy developed by Swenson and Bill, the retrorectal approach developed by Duhamel, the endorectal procedure developed by Soave and deep anterior colorectal anastomosis developed by Rehbein. The basic principle in all these procedures is to bring the ganglionic bowel down to the anus. The long-term results of any of these operations are very satisfactory if they are performed correctly.

Figure 26.1

The abdomen is opened via the Pfannenstiel incision. The biopsy site is selected by observing the apparent transitional zone. In the usual case of rectosigmoid aganglionosis, three seromuscular biopsies are taken along the antimesenteric surface without entering the lumen. One biopsy is taken from the

narrowed segment of bowel, a second biopsy from the transition zone and a third biopsy from the dilated portion above the transition zone. Biopsies are assessed intra-operatively by frozen section, to determine the level of ganglionic bowel.

Figure 26.2

Many surgeons prefer right transverse colostomy; others advocate performing colostomy just above the transition to ganglionic bowel. Ileostomy is indicated in patients who have total colonic aganglionosis. A right transverse colostomy is convenient in usual cases. We perform a loop colostomy over a skin bridge. A

V-shaped incision is made in the right upper quadrant. The V-skin-flap is reflected upwards. The external oblique is split and the internal oblique and transverse abdominis muscles are divided with diathermy. The peritoneum is opened.

Figure 26.1

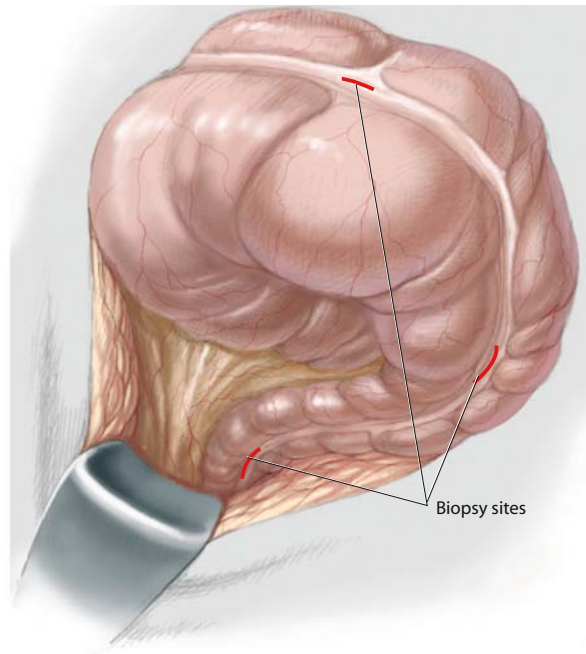


Figure 26.2

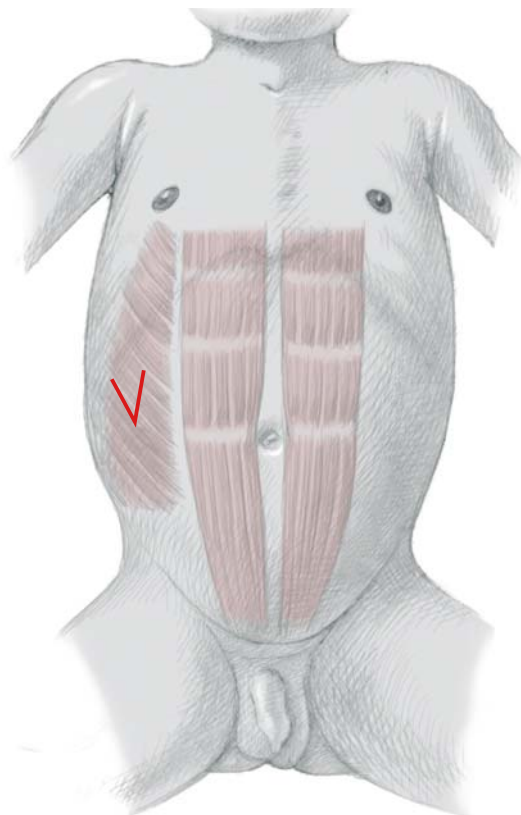


Figure 26.3–26.5

An opening is made in the mesocolon of the selected segment of transverse colon. The skin flap is pulled through the opening in the mesocolon and sutured to the opposite skin margin. A few interrupted absorbable sutures of 4/0 or 5/0 are placed between the peri-

toneum, the muscle layers of abdominal wall and the seromuscular layer of colon. The colon is opened longitudinally along the antimesenteric border using diathermy. The bowel is sutured to the skin using interrupted 4/0 absorbable sutures.

Figure 26.3

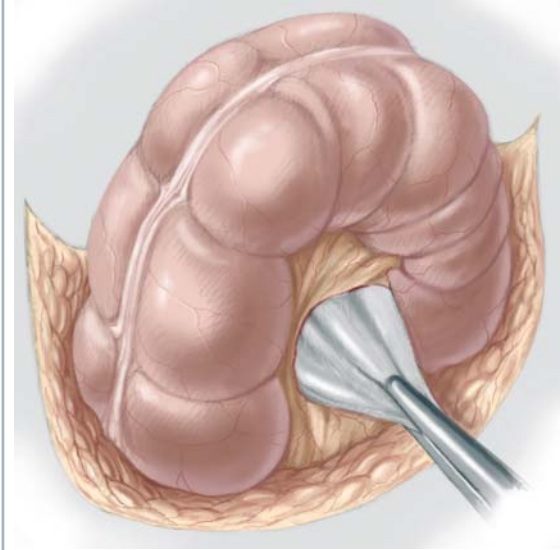


Figure 26.4

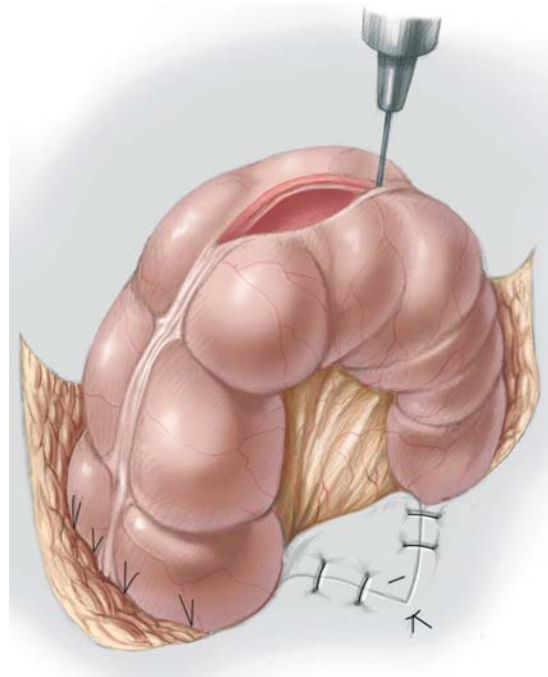


Figure 26.5

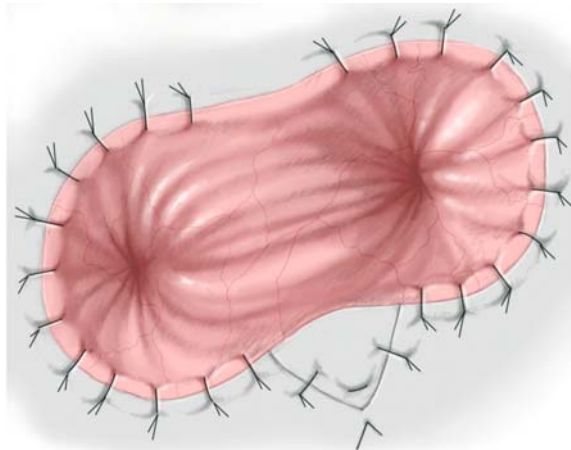


Figure 26.6

Many surgeons have reported good results with the primary neonatal pull-through operation for HD. The author prefers the one-stage transanal endorectal pull-through operation for classical recto-sigmoid HD and Swenson's pull-through operation for long-segment HD because of their simplicity and lack of complications. We have not used diversionary colostomy for usual cases.

Of patients with HD, 75–80% have rectosigmoid aganglionosis. A one-stage pull-through operation can be successfully performed in these patients using a transanal endorectal approach without opening the abdomen. This procedure is associated with excellent clinical results and permits early postoperative feeding, early hospital discharge and no visible scars. Once the diagnosis of HD is confirmed, rectal irriga-

tions are carried out twice a day for 3 days before surgery. Intravenous gentamicin and metronidazole are started on the morning of operation.

The patient is positioned on the operating table in the lithotomy position. The legs are strapped over sandbags. A Foley catheter is inserted into the bladder. A Denis-Browne retractor or anal retractor is placed to retract perianal skin. The rectal mucosa is circumferentially incised using the cautery, approximately 5 mm above the dentate line, and the submucosal plane is developed. The proximal cut edge of the mucosal cuff is held with multiple 4/0 silk sutures, which are used for traction. The endorectal dissection is then carried proximally, staying in the submucosal plane.

Figure 26.7, 26.8

When the submucosal dissection has extended proximally to a point above the peritoneal reflection, the rectal muscle is divided circumferentially, and the full thickness of the rectum and sigmoid colon is mo-

bilized out through the anus. This requires division of rectal and sigmoid vessels, which can be done under direct vision using cautery or ligatures.

Figure 26.6

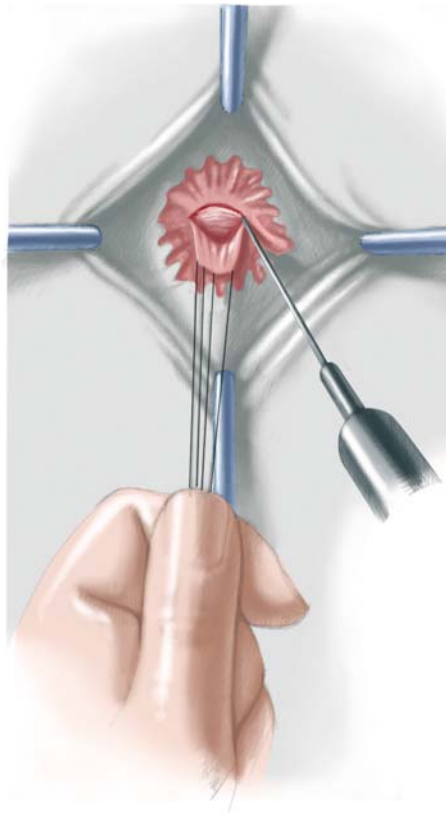


Figure 26.7

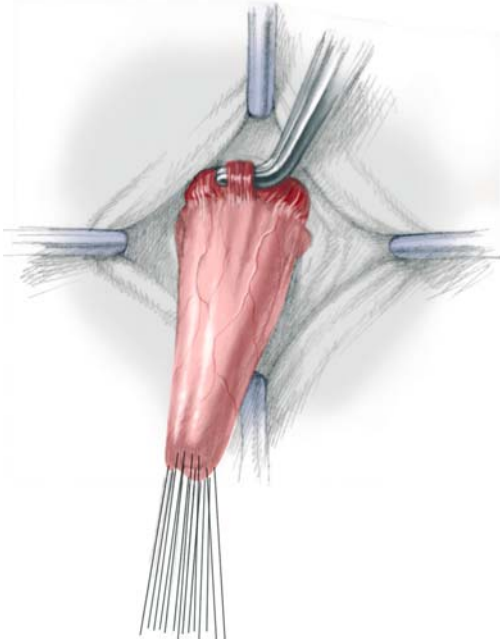


Figure 26.8

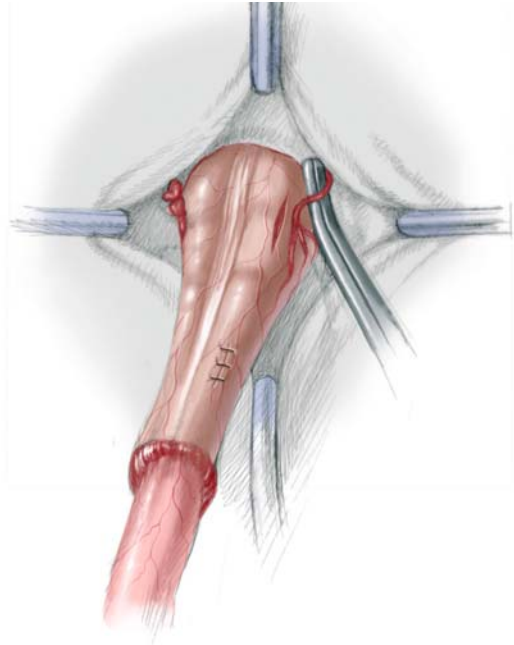


Figure 26.9

When the transition zone is encountered, full-thickness biopsy sections are taken and frozen section confirmation of ganglion cells is obtained. The rectal

muscular cuff is split longitudinally either anteriorly or posteriorly. The colon is then divided several centimetres above the most proximal normal biopsy site.

Figure 26.10

A standard Soave-Boley anastomosis is performed. No drains are placed. The patient is started on oral feeds after 24 h and discharged home on the third post-operative day. Digital rectal examination is per-

formed 2 weeks after the operation. Routine rectal dilation is not performed unless there is evidence of a stricture.

Figure 26.9

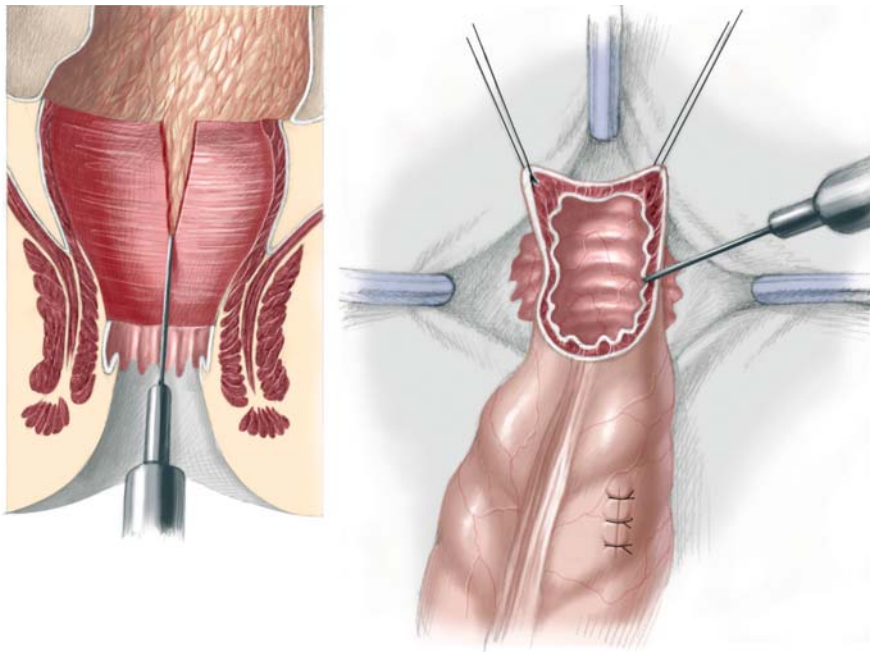


Figure 26.10

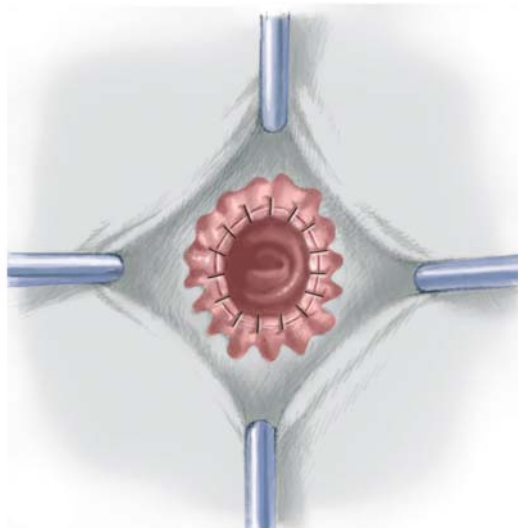


Figure 26.11

For Swenson's pull-through operation the patient is positioned on the operating table to provide simultaneous exposure of the perineum and abdomen. The pelvis is allowed to drop back over the lower end of the table and the legs are strapped over sandbags. A Foley catheter is inserted into the bladder. The abdomen is opened via a paramedian incision. Some surgeons prefer a Pfannenstiel incision when performing a Swenson's pull-through operation in the neonate. Extramucosal biopsies are taken at intervals along the antimesenteric border and assessed by frozen section to determine the level of ganglionated bowel. The sigmoid colon is mobilized by dividing the sigmoid vessels and retaining the marginal vessels. It may be necessary to mobilize the splenic flexure to obtain adequate length. The proximal level of resection above the ganglionated level, previously determined by frozen section, is selected and the bowel is divided between intestinal clamps or staples.

The peritoneum is divided around its lateral and anterior reflection from the rectum, exposing the muscle coat of the rectum. At this point, the bowel is divided at the rectosigmoid junction and removed. Dissection extends around the rectum, keeping very close to the bowel wall. It is essential to maintain the dissection close to the muscular wall in order to prevent damage to the pelvic splanchnic innervation. All

vessels are electro-coagulated under direct vision. Sufficient tension-free length is obtained by dividing the inferior mesenteric pedicle, carefully preserving the marginal vessels. Dissection is carried down to the level of the external sphincter posteriorly and laterally, but does not extend as deeply anteriorly, leaving around 1.5 cm of intact rectal wall abutting against the vagina or urethra.

The mobilized rectum is intussuscepted through the anus by passing a curved clamp or a Babcock forceps through the anal canal; an assistant places the closed rectal stump within the jaws of the clamp. When the dissection has been completed, it should be possible to evert the anal canal completely when traction is applied to the rectum. An incision is made anteriorly through the rectal wall about 1 cm from the dentate line, extending halfway through the rectal circumference. A clamp is inserted through this incision to grasp multiple sutures placed through the cut end of the proximal colon. An outer layer of interrupted 4-0 absorbable sutures is placed through the cut muscular edge of the rectum and the muscular wall of the pull-through colon. When the outer layer has been completed, the proximal bowel is opened and an inner layer of interrupted 4-0 absorbable sutures is placed. When anastomosis is completed, the sutures are cut, allowing the anastomosis to retract within the anus.

Figure 26.12

The advantage of the Duhamel pull-through is that very little manipulation of the rectum is performed anteriorly thus avoiding injury to the genitourinary innervation. The rectum is divided and closed just above the peritoneal reflection. The redundant aganglionic bowel is resected. The retrorectal space is created by blunt dissection down to the pelvic floor. The posterior rectal wall is incised 1.5 to 2 cm above the dentate line and sponge holding forceps is inserted into the retrorectal space and ganglionic bowel pulled through. The anterior half of the pulled-through ganglionic bowel is anastomosed to the pos-

terior wall of the aganglionic rectum and remainder of the colo-rectal anastomosis completed by approximating the aganglionic rectum to the posterior wall of the pulled-through ganglionic bowel. Finally an extra long automatic stapling device is used to complete the side to side anastomosis between the aganglionic rectum and the ganglionic pulled-through bowel. Some surgeons complete the side to side anastomosis prior to closing the rectal stump, thereby preventing any residual septum.

Figure 26.11

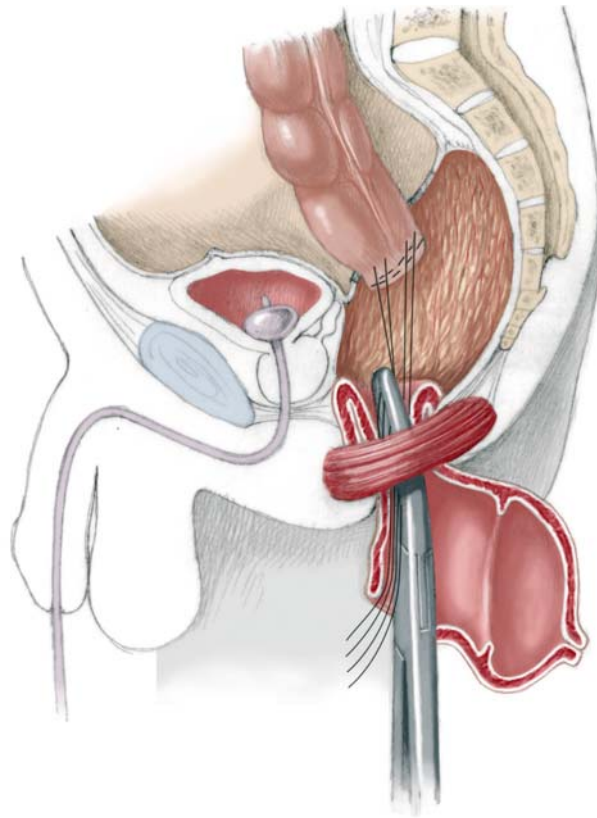


Figure 26.12

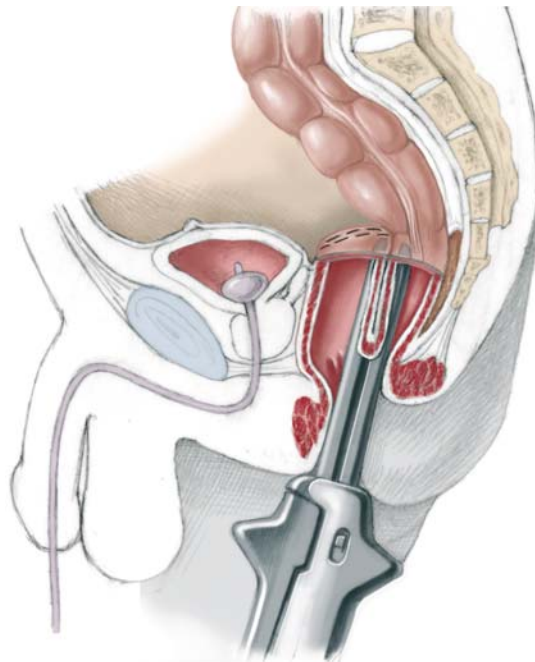


Figure 26.13

In Soave or endorectal pull-through the first steps of the operation are similar to those described for Swenson's or Duhamel operation. The colon is mobilized and resected about 4 cm above the peritoneal reflection. The endorectal dissection begins 2 cm below the peritoneal reflection. The seromuscular layer is incised circumferentially and the mucosal-submu-

cosal tube is freed distally. The mucosal dissection is continued distally to the level of the dentate line. The mucosa is incised circumferentially 1 cm above the dentate line. A Kelly clamp is inserted from below and the ganglionic bowel is pulled through. Coloanal anastomosis is completed using 4/0 absorbable sutures.

Figure 26.14

Rehbein's technique differs from the Swenson's procedure, in that the anastomosis is a low, anterior colorectal anastomosis. In this procedure, 3 to 5 cm of

the terminal aganglionic rectum is left behind, which is anastomosed to the ganglionic bowel.

Figure 26.13

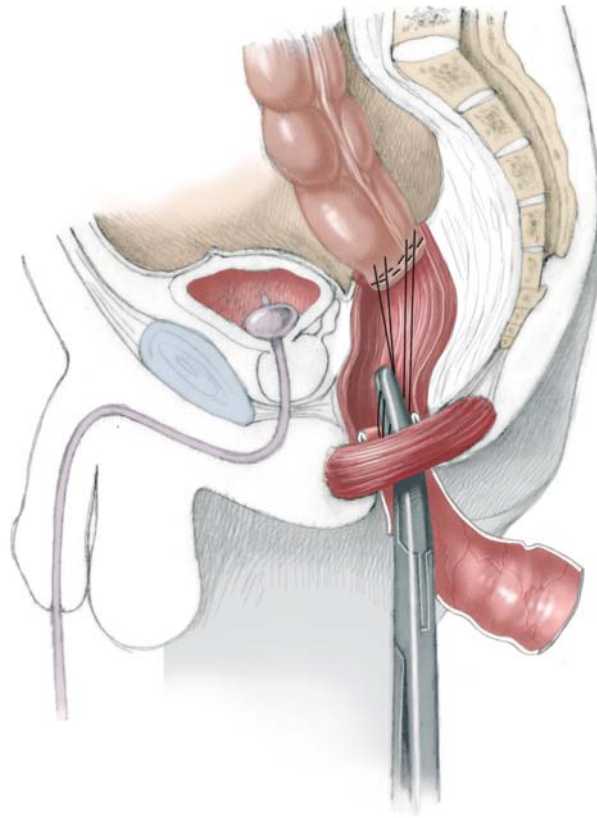
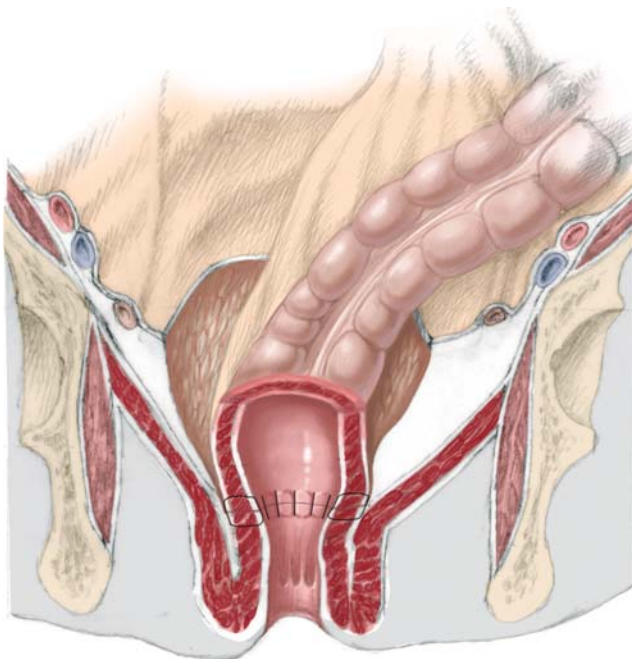


Figure 26.14



CONCLUSION

The vast majority of patients treated with any one of the standard pull-through procedures achieve satisfactory continence and function with time. The attainment of normal continence is dependent on the intensity of bowel training, social background and respective intelligence of patients. Mental handicap, including Down syndrome, is invariably associated with long-term incontinence.

SELECTED BIBLIOGRAPHY

- Georgeson KE (2002) Laparoscopic-assisted pull-through for Hirschsprung's disease. *Semin Pediatr Surg* 11: 205–210
- Langer JC, Durrant AC, de la Torre L, Teitelbaum DH, Minkes RK, Caty MG, Wildhaber BE, Ortega SJ, Hirose S, Albanese CT (2003) One-stage transanal Soave pullthrough for Hirschsprung's disease: a multicenter experience with 141 children. *Ann Surg* 238: 569–583
- Puri P (2003) Hirschsprung's disease. In: Puri P (ed) *Newborn surgery*. Arnold, London, pp 513–533
- Rolle U, Nemeth L, Puri P (2002) Nitroergic innervation of the normal gut and in motility disorders of childhood. *J Pediatr Surg* 37: 551–567

Alberto Peña, Marc A. Levitt

INTRODUCTION

Anorectal malformations, represent a wide spectrum of defects. Surgical techniques useful to repair the most common types of anorectal malformations seen by a general pediatric surgeon are presented following an order of complexity from the simplest to the most complex.

Malformations considered “low” have traditionally been approached perineally, without a protective colostomy, whereas malformations that are considered “high” were treated by colostomy in the newborn period, subsequent definitive repair of the malformation, and eventual closure of the colostomy. Surgical management has been evolving towards fewer operations and minimally invasive procedures. Anorectal malformations have been included in this trend.

Colostomy is still a widely accepted procedure for children born with rather high and complex malformations. The circumstances in which this procedure is performed vary from one institution to another and from one country to another. Some surgeons feel confident approaching newborns without a protective colostomy. This is feasible and safe, provided the surgeon has experience in the management of these defects. Some surgeons do not feel confident with this approach and prefer a safer path in which they open a protective colostomy, particularly when the baby is premature or has severe associated anomalies.

Figure 27.1

The colostomy that we recommend in the management of anorectal malformations is a descending colostomy. The surgeon must understand that all colostomies performed in a mobile portion of the colon have a tendency to prolapse. The mobile portion, in the type of colostomy that we propose, is the distal stoma (mucous fistula) and therefore the surgeon must either to fix this distal sigmoid colon to the anterior abdominal wall or make the mucous fistula very small (4 mm in diameter) since it will be used only for colonic irrigations or distal colostogram imaging procedures. The incision is created in the left lower quadrant, long enough as to be sure that both the stomas are sufficiently separated as to be able to accommodate the stoma bag over the proximal stoma. The mucosa fistula should not be included under the stoma bag.

When creating the colostomy in the newborn, the surgeons should look for the descending colon and select the first portion of mobile sigmoid to open the colostomy. That part of the colon is usually very distended and full of meconium. The surgeon can place a purse-string suture, make an orifice in the centre, and pass a catheter to irrigate the sigmoid until all the meconium has been removed. This simple maneuver facilitates the manipulation of the colon and helps to create a better colostomy.

Loop colostomies are contraindicated in children with anorectal malformations. They have a tendency to prolapse, and with them stool can pass into the distal stoma, which may provoke faecal impaction in the distal rectum and also contaminate the urinary tract with faeces.

MALE DEFECTS

Figure 27.2

■ **Perineal Fistula.** This malformation represents the simplest of the spectrum. In this defect, the rectum opens immediately anterior to the centre of the sphincter, yet, the anterior rectal wall is intimately attached to the posterior urethra. The anal orifice is frequently strictured. These patients will have bowel control with and without an operation. Some surgeons decide not to operate on these patients. In such a case, the anus should be dilated to allow the easy passing of stool, and the orifice should be sequentially dilating up to no. 12 Hegar in a newborn baby. We prefer to operate on these babies to achieve a better cosmetic effect. We also believe that the operation must be done as soon as the diagnosis is made. We perform these operations without a colostomy in the newborn baby.

The baby is placed in prone position with the pelvis elevated. It is *mandatory* to place a catheter in the urethra of the patient. The most common intra-operative complication is a urethral injury. The incision usually extends mid-sagittally approximately two cm posterior to the anal orifice, dividing the entire sphincter mechanism. Multiple very fine nonabsorbable sutures are placed in the anal orifice in order to exert traction to facilitate the dissection of the rectum. The posterior incision divides the entire sphinc-

ter until the posterior rectal wall that has a characteristic whitish appearance is identified. The surgeon continues dissecting in this plane, first the lateral walls of the rectum and eventually the anterior rectal wall. While dissecting the anterior rectal wall, the surgeon must put special emphasis in trying to avoid urethral injury since there is no plane of separation between rectum and urethra. Once the rectum has been mobilized enough as to be moved back to be placed within the limits of the sphincter. The limits of the sphincter are determined with an electrical stimulator. The perineal body is then reconstructed with long-term fine absorbable sutures and the rectum is anchored to the posterior edge of the muscle complex. An anoplasty is performed within the limits of the sphincter with 16 circumferential 6/0 long-term absorbable sutures. The baby does not have any diet limitations and receives intravenous antibiotics for 24–48 h.

Dilatations are performed twice per day beginning 2 weeks after surgery. The parents learn to advance one size (1 mm) every week until they reach the size adequate for the patient's age, which is no. 12 for a newborn baby, no. 13 for a 4-month-old, no. 14 for an 8-month-old, no. 15 for a 1-year-old, and no. 16 for older patients.

Figure 27.1

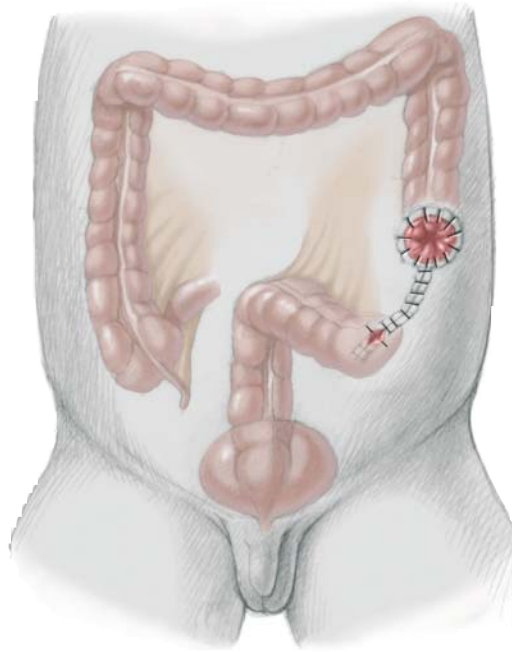


Figure 27.2

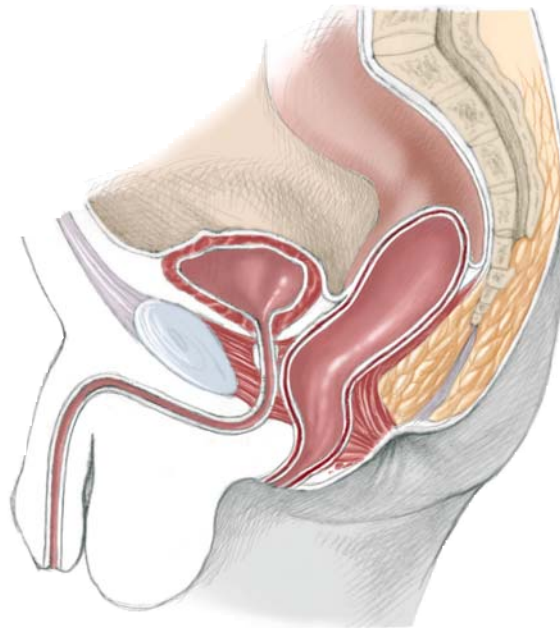


Figure 27.3, 27.4

■ **Rectourethral Fistula.** This group of patients include two specific categories: (a) rectourethral bulbar fistula (Fig 3), and (b) rectoprostatic fistula (Fig 4). These two variants represent the majority of male patients with anorectal malformations. We believe that it is important to recognize the difference between these types because of the prognostic and therapeutic implications. Rectourethral bulbar fistula patients, in our experience have an 80% chance of having bowel control by the age of 3, whereas the rectoprostatic fistula patients only have a 60% chance. Patients with a rectoprostatic fistula have a higher incidence of associated defects (60%) compared to patients with rectourethral bulbar fistula for whom the incidence is 30%. The rectoprostatic patients require a more demanding perirectal dissection to mobilize the rectum that is located higher in the pelvis. These operations are performed at our institution when the babies are 4 weeks old. If the neonatal approach with no colostomy is to be attempted, per-

haps the kind of patient for this management would be the one who has a rectal pouch located below the coccyx. In that way, the surgeon knows for sure that, when he or she opens posteriorly, the rectum is going to be found. The dissection of this distal rectum must be meticulous as it is intimately attached to the urethra.

If the surgeon does not have a specific and reliable image that shows the rectum is located below the coccyx, he or she should *never* approach a patient posteriorly without a colostomy and without a distal colostogram. The distal colostogram is by far the most valuable study in defining the anorectal anatomy. That study is done in patients with anorectal malformations and can only be done when the patient already has a colostomy. We have seen catastrophic complications during the performance of posterior sagittal operations in male patients, that did not have a distal colostogram.

Figure 27.5a–c

We like to perform a cystoscopy in all patients, which helps the surgeon confirm the location of the fistula. A Foley catheter is inserted and the patient is placed in prone position with the pelvis elevated. The incision is a posterior sagittal one, in between both buttocks, running from the middle portion of the sacrum down to the anal dimple, which is electrically determined. The incision goes through skin, subcutaneous tissue, parasagittal fibres, muscle complex and levator muscle. When the surgeon is dealing with a rectourethral bulbar fistula (Fig. 4), he expects to see a bulging rectum as soon as he opens the levator

muscle. In cases of the rectoprostatic fistula, (Fig. 5) the rectum is much smaller, it may not bulge through the incision, and the surgeon expects to find the rectum immediately below the coccyx. The surgeon should not look for the rectum in the lower part of the incision in patients with rectoprostatic fistula. Looking for a rectum without evidence that the rectum is there is the main source of complications in this approach. The surgeon will find the urethra, vas deferens, prostate, and seminal vesicles and will damage the nerves important for urinary control and sexual potency.

Figure 27.3

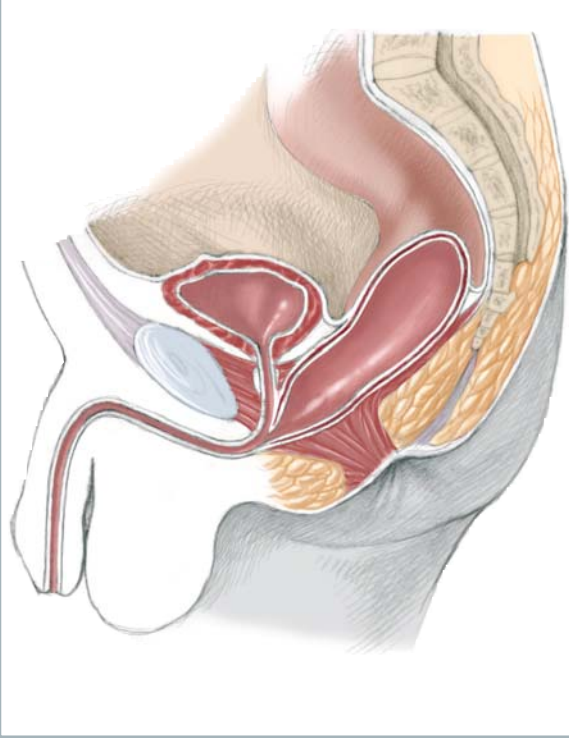


Figure 27.4

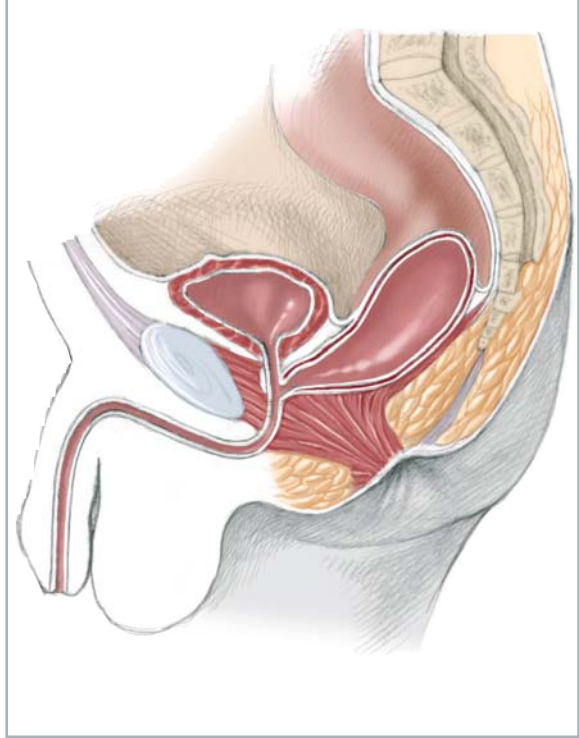


Figure 27.5a-c

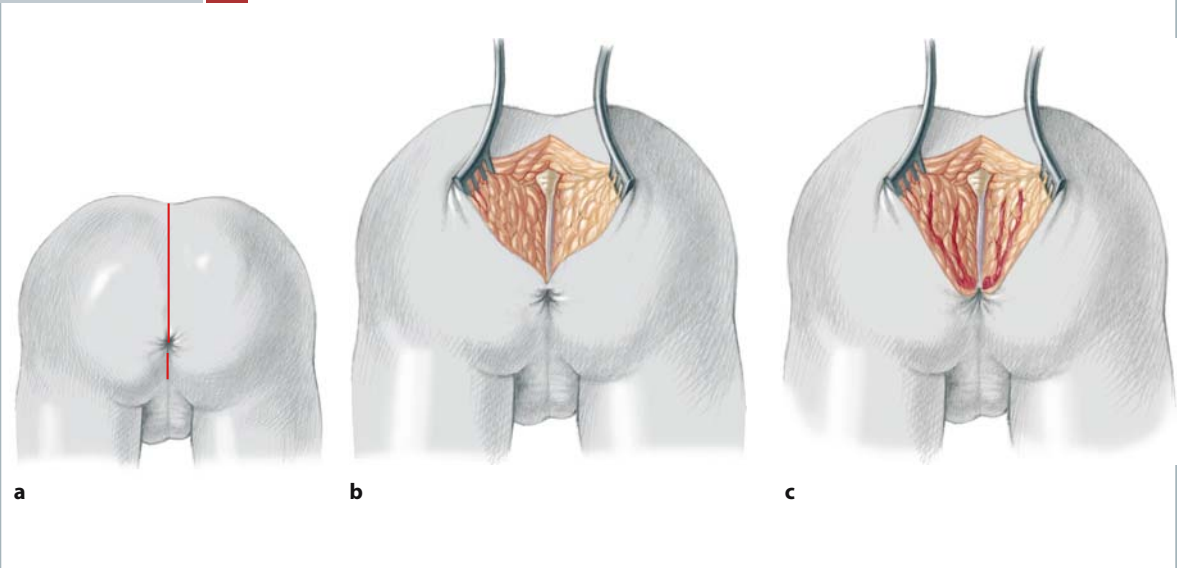


Figure 27.6, 27.7

The posterior rectal wall is easily identified by its characteristic whitish appearance. The surgeon must keep in mind that there is a fascia that covers the rectum posterior and laterally that must be removed. The dissection of the rectum must be performed staying as close as possible to the rectal wall without injuring the rectal wall itself. The posterior rectal wall is opened in the midline, in between two 5/0 silk

stitches. The incision is continued distally, staying in the midline while applying stitches in the edges of the rectum. The traction on these stitches will allow the surgeon to see the lumen of the rectum. When the incision continues, extending distally in the midline, it ends directly into the rectourethral fistula that is identified usually as a 1–2 mm orifice.

Figure 27.6

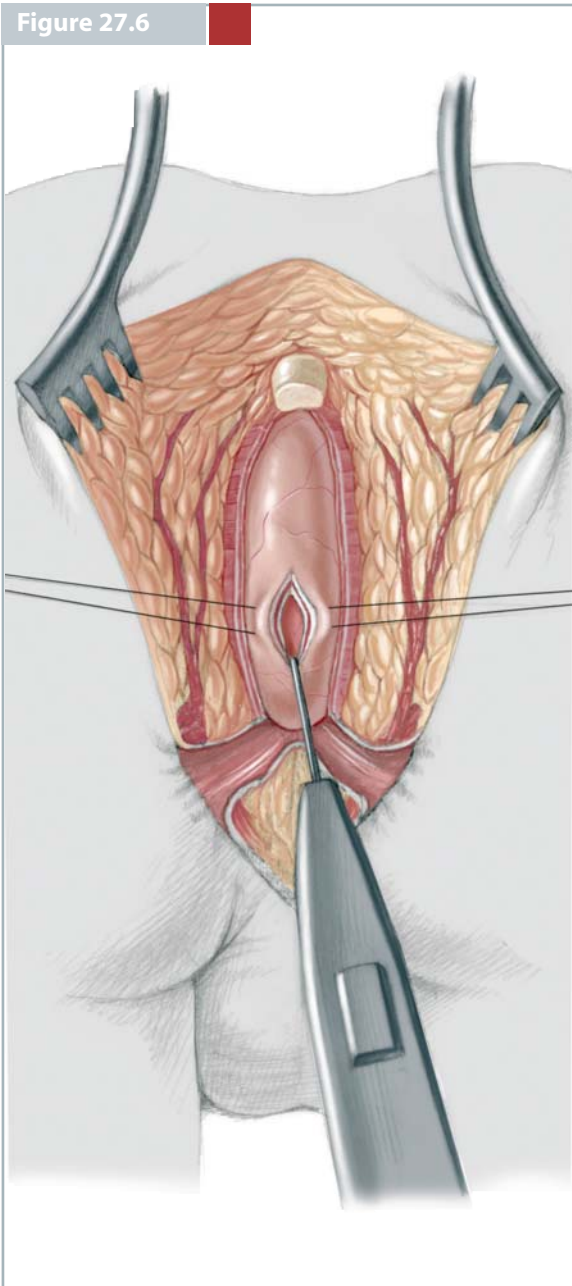


Figure 27.7

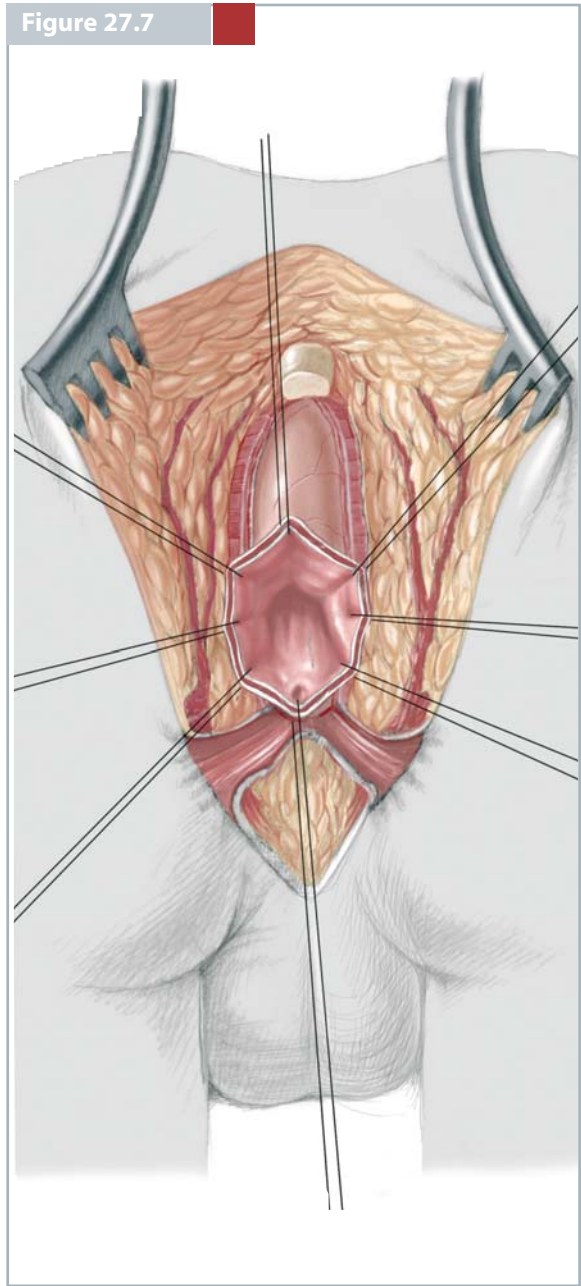


Figure 27.8

Multiple 6/0 silk sutures are placed in a semi-circumferential fashion surrounding the fistula site above and lateral to the fistula. These multiple sutures serve the purpose of exerting uniform traction on the rectal mucosa to facilitate the separation of the rectum

from the urinary tract. The fascia that covers the rectum is removed, creating the lateral planes of the rectum. The mucosa of the anterior rectal wall distal to the multiple 6/0 silk sutures is divided about 1 mm deep.

Figure 27.9, 27.10

The dissection continues between the rectum and urinary tract in a submucosal plane for approximately 5–10 mm and then gradually becomes a full-thickness dissection, looking at the lateral planes until the rectum is completely separated from the urinary

tract. The separation of the urethra from the rectum is the most delicate part of the operation. Most of the serious complications occur during this part of the procedure. The fistula site is closed with three or four 6/0 long-term absorbable sutures.

Figure 27.8

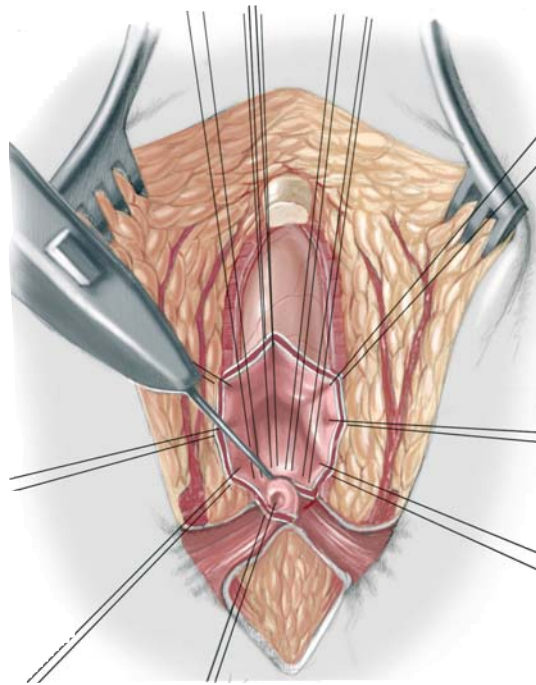


Figure 27.9

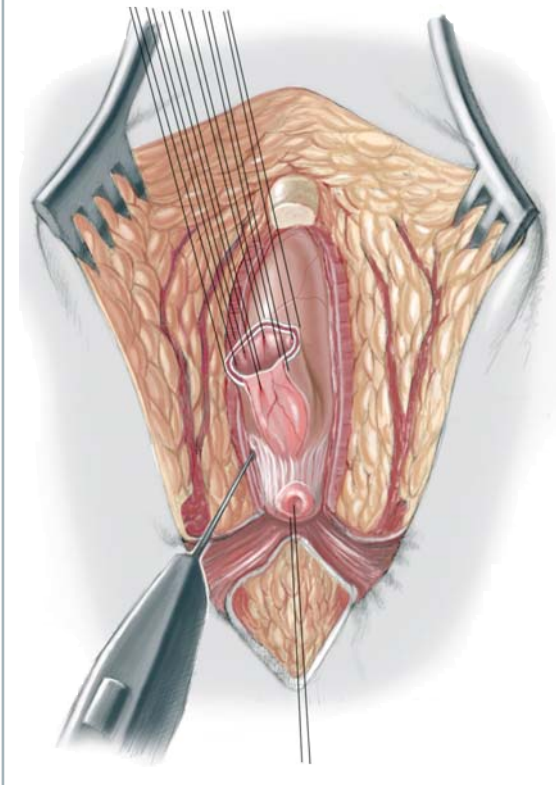


Figure 27.10

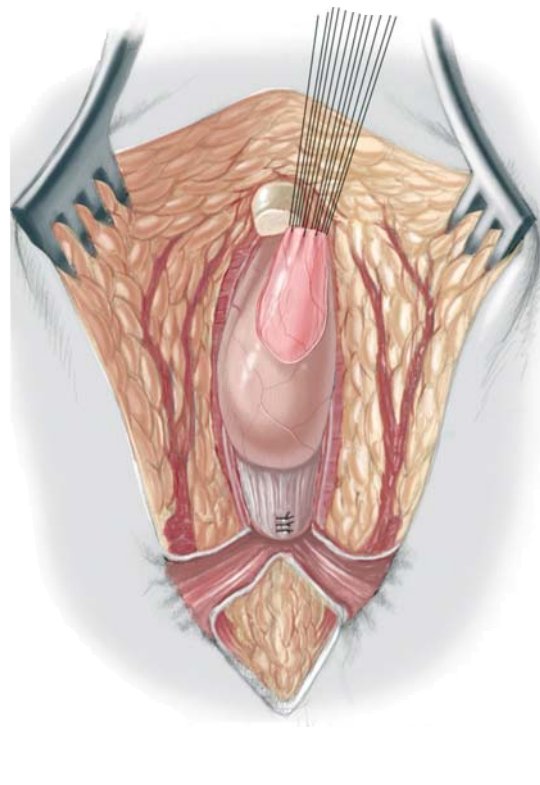


Figure 27.11

The surgeon should then evaluate the size of the rectum and compare it to the available space to decide if the rectum has to be tapered to be accommodated within the limits of the sphincters. In the past, we performed many of these tapering procedures and we believe that is because patients came later in life, had inadequate colostomies, and therefore suffered from severe megarectum. Currently, babies are referred to us earlier, surgeons are opening better, totally diverting colostomies, and we therefore do not see megarectums as often. Consequently, tapering is rarely necessary.

When a tapering procedure is required, we recommend to remove an adequate portion of the posterior rectal wall, closing this wall into two layers of interrupted long-term absorbable sutures. Tapering on the anterior wall is absolutely contraindicated as it would leave a rectal suture line against the urethral fistula repair and a recurrent fistula may develop.

Figure 27.12

The limits of the sphincter are then electrically determined and marked with temporary silk sutures. The perineal body is reconstructed when the incision extends anterior to the centre of the sphincter. The anterior limits of the sphincter must be reconstructed.

Figure 27.13

The posterior edge of the levator muscle is electrically determined, and the rectum is placed in front of the levator. The posterior edges of the levator muscle are sutured together with interrupted 5/0 long-term absorbable sutures. The distal continuation of the levator muscle is arbitrarily called the muscle complex.

The posterior edge of this muscle structure is sutured together in the midline with interrupted 5/0 long-term absorbable sutures. These sutures also take a bite of the posterior rectal wall in order to anchor the rectum in a good position to avoid retraction and/or prolapse.

Figure 27.11

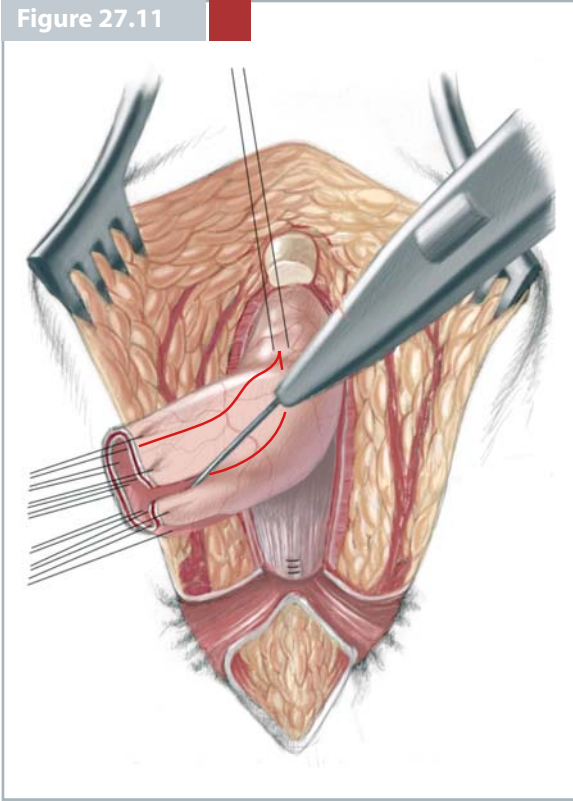


Figure 27.12

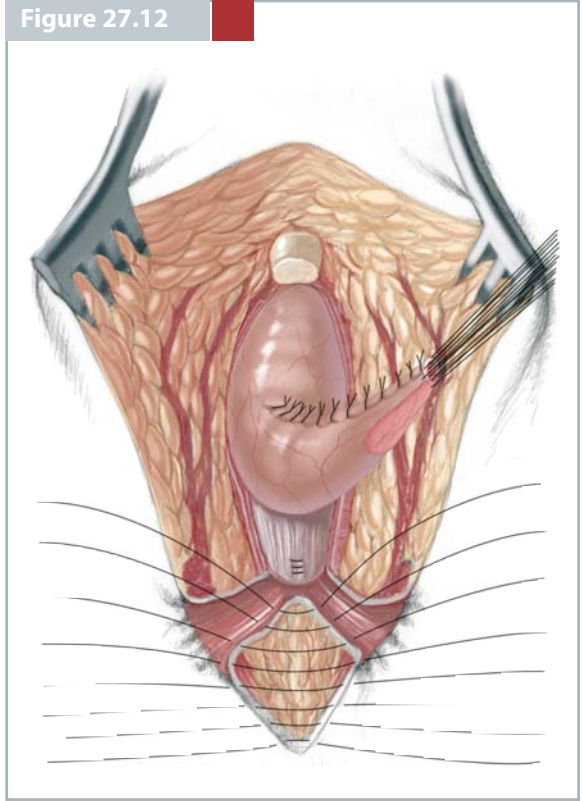


Figure 27.13

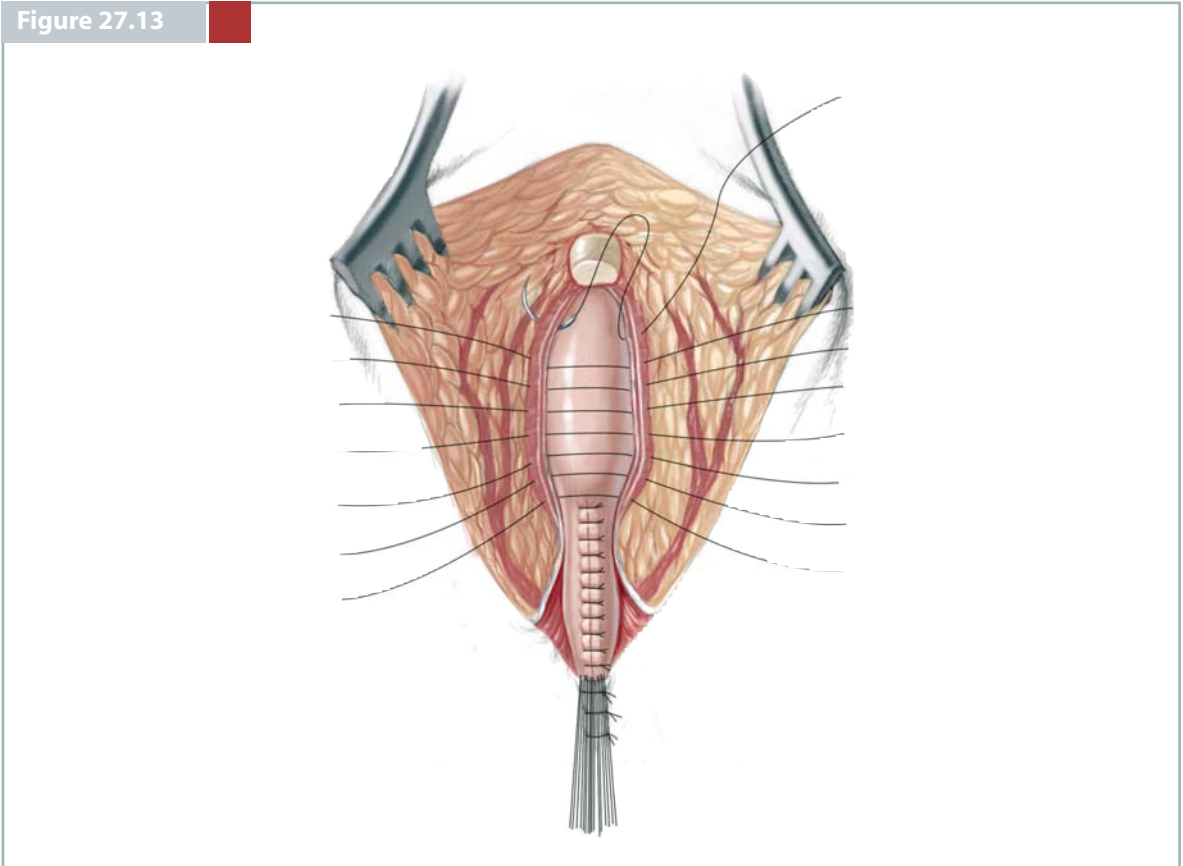


Figure 27.14, 27.15

The rest of the incision is closed meticulously reapproximating all the layers of the wound. An anoplasty is performed with 16 circumferential stitches of

6/0 long-term absorbable sutures, trimming off that part of the rectum that has been damaged or does not have adequate blood supply.

Figure 27.16

■ **Recto-Bladder Neck Fistula.** This malformation is the highest of all defects seen in male patients. Fortunately, only 10% of male patients suffer from this particular defect. Associated defects occur in 90% of these patients. Usually, the sacrum is hypodeveloped. This particular group of malformations is the only one that, in order to be repaired, requires not only a posterior sagittal approach, but also an abdominal one, either by laparotomy or laparoscopy.

The advent of minimally invasive procedures has been extended to anorectal malformations and we believe that it has specific indications in those patients that formerly required a laparotomy. We still do not believe that the laparoscopic repair of a rectourethral fistula is less invasive than the posterior

sagittal approach alone. However, in a case of recto-bladder neck fistula, the rectum can be separated from the urinary tract laparoscopically avoiding a laparotomy. These patients, unfortunately, do not have a good functional prognosis. In our experience, only 15% of them have voluntary bowel movements by the age of 3. These patients require a posterior sagittal approach to create the space through which the rectum will be pulled down. During the laparotomy or laparoscopy, the surgeon must separate the rectum from the urinary tract. Fortunately, in these very high malformations, the common wall between the rectum and the urinary tract is very short. In other words, the rectum connects to the bladder neck in a “T” fashion.

Figure 27.14

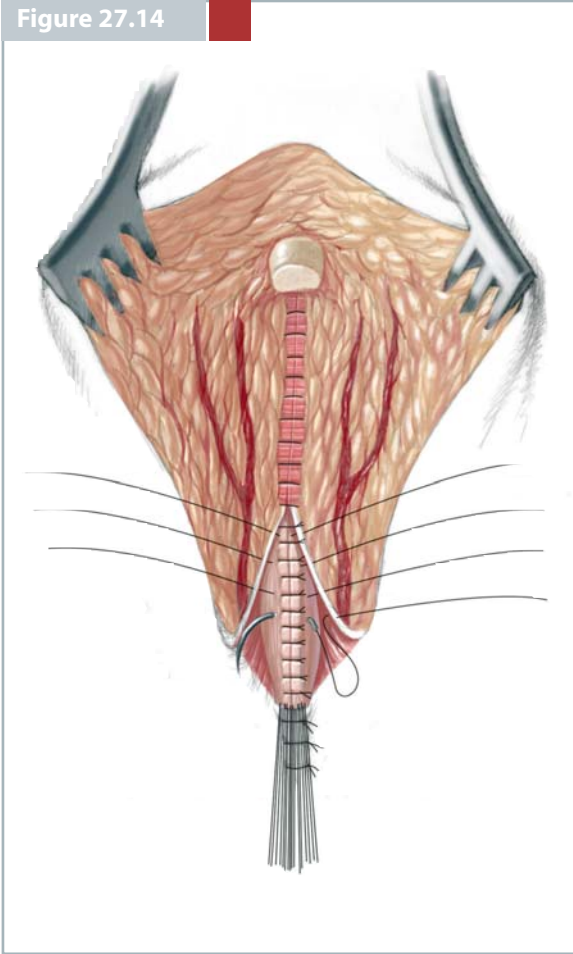


Figure 27.15

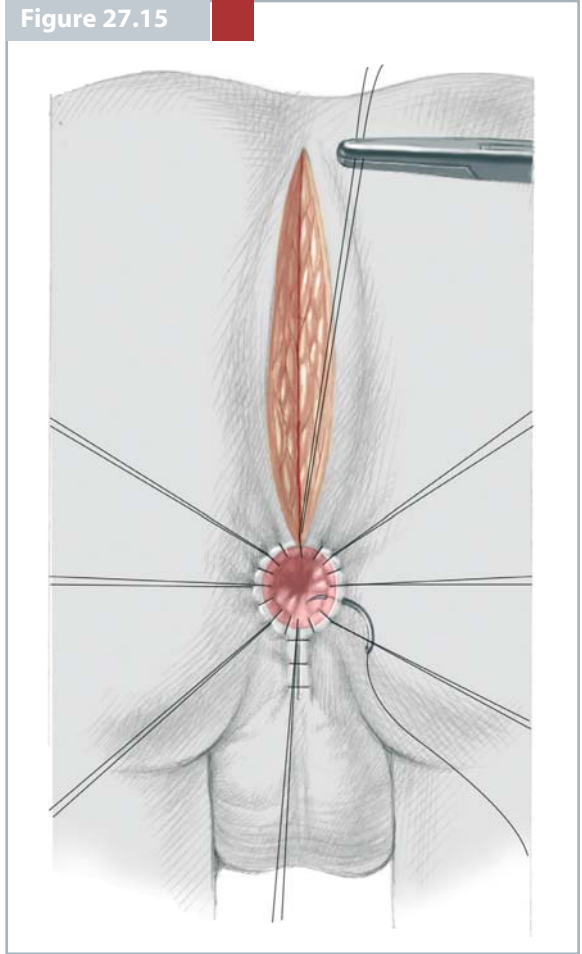


Figure 27.16

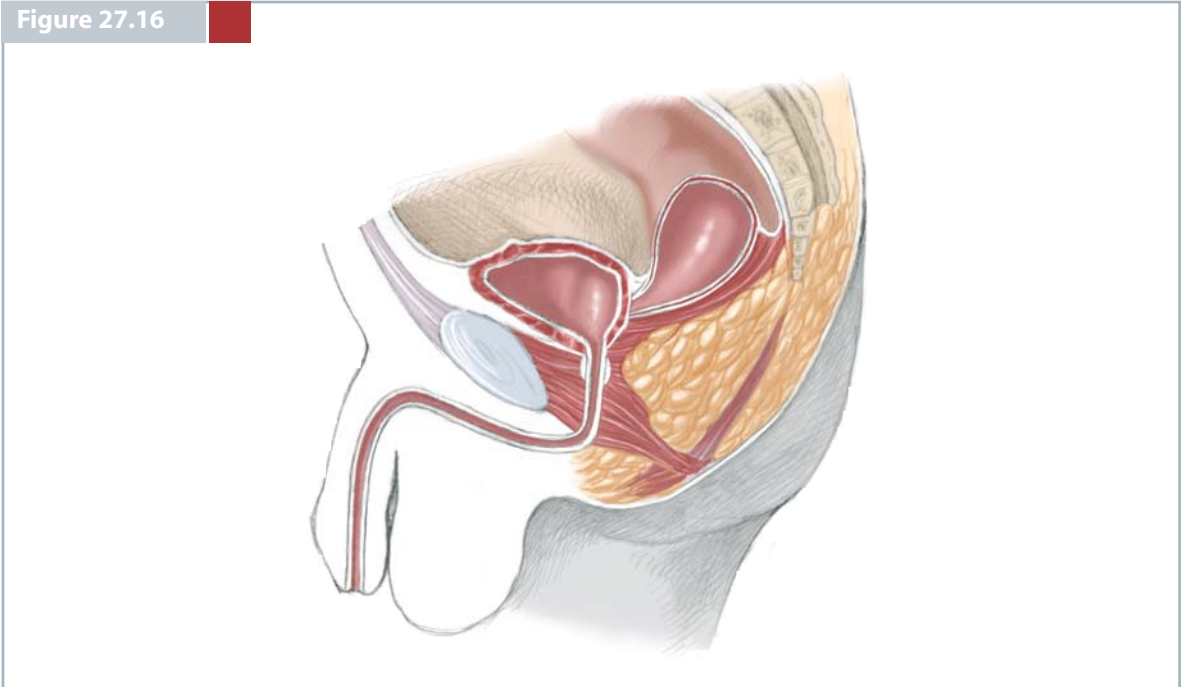


Figure 27.17, 27.18

When we operate on these patients, we perform what we call a total body preparation. The purpose is to have access to the perineum and to the abdomen, when necessary. The operation is started via a posterior sagittal approach. All the sphincter mechanisms are divided in the midline. No attempt should be made to find the rectum through this approach. A rubber tube is placed in the presacral space behind the urethra and located, following the tract the rectum will subsequently occupy. The perineal body, the posterior edge of the levator muscle as well as the muscle complex are reconstructed around the rubber tube that represent the rectum. The patient is then turned onto a supine position and a laparotomy is performed. The bladder is pulled anteriorly and the rectosigmoid is found. In these very high defects, the rectobladderneck fistula is usually located within 1 to 2 cm below the peritoneal reflection and, therefore,

the pelvic dissection necessary to mobilize it is minimal. Ureters and vas deferens run very close to the rectum to approach the trigone of the bladder. This should be kept in mind to avoid any damage. The dissection of the rectosigmoid must be performed while staying in direct contact with the bowel wall itself. The rectum opens into the bladderneck in a T fashion. This means that there is no common wall above the fistula as described in lower malformations. The fistula is divided and the bladder end is sutured with interrupted long-term absorbable sutures. The rubber tube is easily found in the presacral space. The decision is made to taper the rectum when necessary and then to anchor the rectum to the rubber tube. The legs are lifted up and the rubber tube is pulled down, pulling together the rectum that will be placed in the desired location. The anoplasty is performed as previously described and the abdomen is closed.

Figure 27.19

■ **Imperforate Anus Without Fistula.** This particular malformation is unique. When we say imperforate anus without fistula, we do not have to refer to the height of the defect because in all cases the rectum is located approximately 1–2 cm above the perineal skin, at the level of bulbar urethra. This malformation only happens in 5% of all cases and half of these have Down's syndrome. The patients with these defects have good prognosis, good sacrum and good sphincters. Ninety percent of our patients with this

defect without Down's syndrome have bowel control and 80% of our Down's syndrome patients have bowel control. The technique to repair this malformation is not necessarily simpler than the one for rectourethral bulbar fistula since the rectum is intimately attached to the posterior urethra. The surgeon has to open the posterior rectal wall and still has to create a plane of dissection between the anterior rectal wall and the urethra, a manoeuvre that requires a meticulous dissection.

Figure 27.17

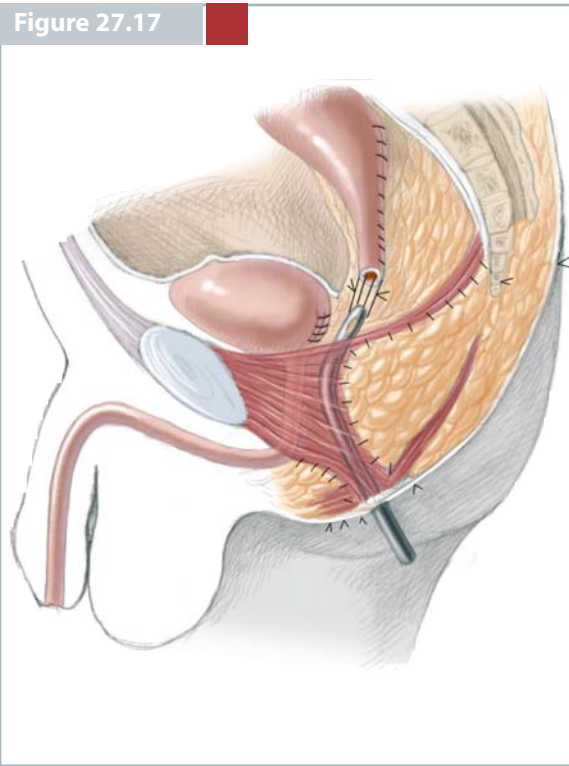


Figure 27.18

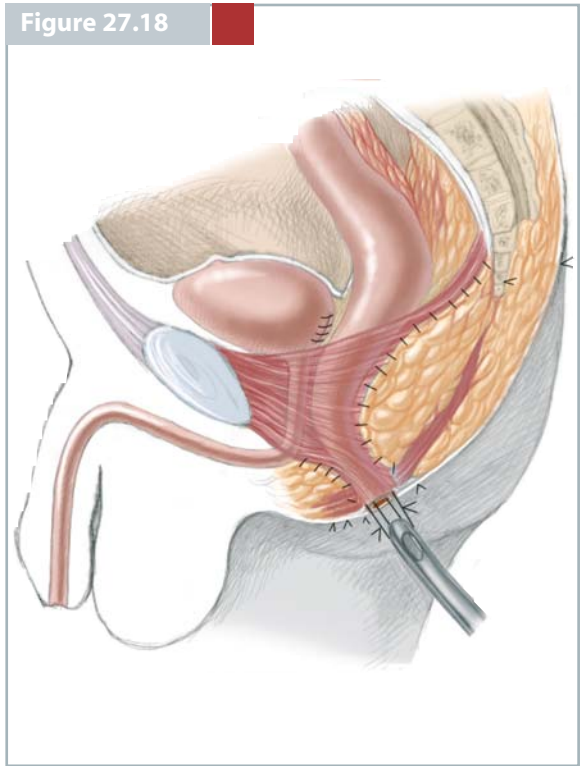
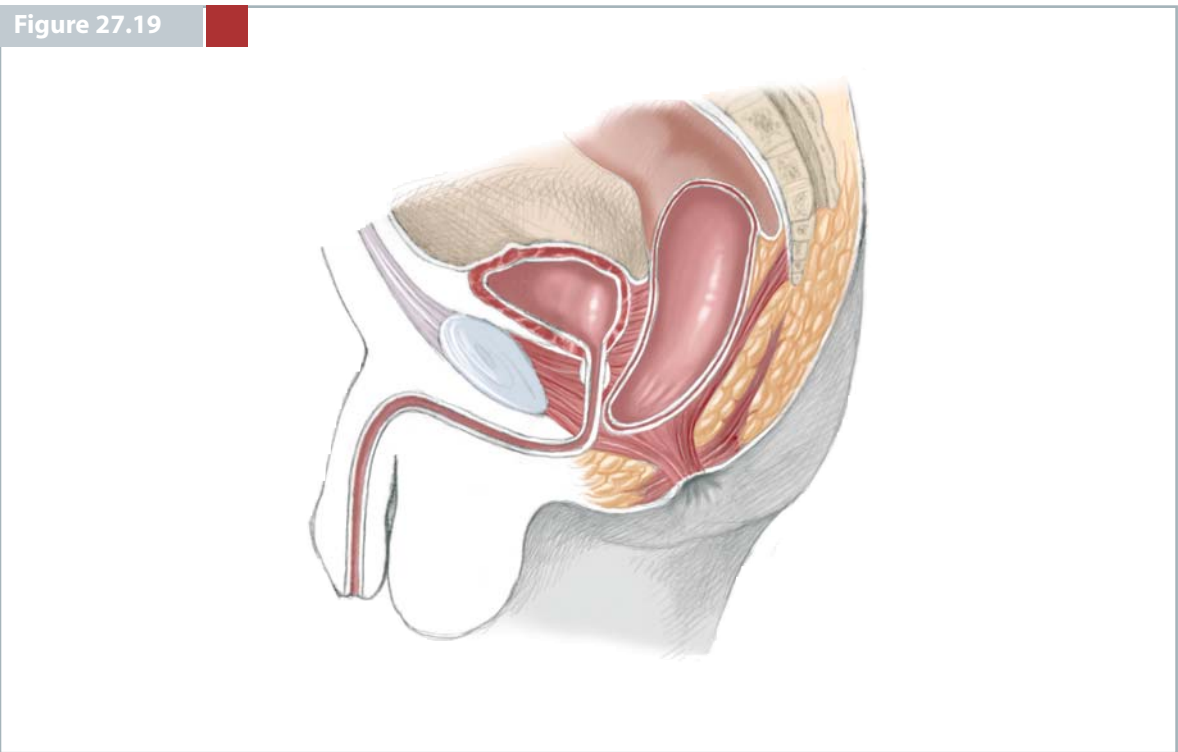


Figure 27.19



FEMALE DEFECTS

Figure 27.20

Female defects are represented by a similar spectrum. However, over the last 22 years, we have been learning a great deal about these defects, particularly with regard to cloacas. We have learned, for instance, that the so-called rectovaginal fistula is an almost nonexistent defect. Most of the patients that were referred to us after having an operation to repair a “rectovaginal fistula”, actually never suffered from that particular defect. Most of them suffered originally from a cloaca that was misdiagnosed; the surgeon repaired the rectal component of the defect and left the patient with a persistent urogenital sinus. In other more unfortunate cases, the babies were born with rectovestibular fistulas, the surgeons mislabelled and misdiagnosed it as a rectovaginal fistula and performed an abdominal perineal procedure for a malformation that could otherwise have been repaired posterior sagittally with good results, leaving the patient totally incontinent for faeces.

■ **Rectoperineal Fistula.** This defect is equivalent to the recto-perineal fistula in males already described. Bowel control exists in 100% of our patients and less than 10% of them have associated defects. The patients are faecally continent with and without an operation. Constipation is a constant sequela and should be treated energetically. This is true also for the male patients with perineal fistulas. We have learned that the lower the defect the more there is a chance of constipation. We have also learned that constipation is a self-perpetuating and self-aggravating condition that eventually produces severe megacolon, chronic faecal impaction and overflow pseudo-incontinence, and must vigilantly be avoided.

At our institution, the operation to repair this defect is performed at birth. We offer this operation to our patients mainly to avoid cosmetic, psychological and potential obstetric sequelae in the future. We perform this operation before the baby leaves the hospital during the newborn period.

The patient is placed in prone position with the pelvis elevated. Multiple 6/0 silk stitches are placed around the fistula site. The incision is about 1.5–2 cm long and divides the entire sphincter mechanism in the posterior midline. We dissect the rectum as previously described in the case of perineal fistulas in male patients. The perineal body is reconstructed as shown and the rectum is anchored to the posterior edge of the muscle complex. An anoplasty is performed.

These patients can eat on the same day of the surgery, and since they are only passing non-colonized meconium, we give antibiotics for 48 h.

Figure 27.21

■ **Rectovestibular Fistula.** This defect is perhaps the most important anorectal malformation in females. This is because it is by far the most common defect seen in the females. It is also a malformation that has an excellent functional prognosis when managed correctly. Also, paradoxically and unfortunately, girls with these defects are the ones that we have seen suffer from more complications after a failed attempt to repair. For many years, it has been very controversial whether this malformation should be treated with a previous protective colostomy or should be operated primarily at birth. Again, we believe that this depends very much on the experience of the surgeon. When a baby is born with this malformation at our institution and the baby is otherwise healthy, we repair this malformation during the newborn period. If the baby is premature or has associated defects, it is always safer to open a protective colostomy. The surgeon must keep in mind that dehiscence and infection in patients with anorectal malformations not only represent a few more days in the hospital and an ugly scar but also represents the possibility of changing the prognosis for bowel control.

Patients with a vestibular fistula have an excellent prognosis. Bowel control exists in 93% of our patients; 70% of them have constipation that is incurable but manageable and it should be treated aggressively.

The most important anatomical feature that should be recognized by the surgeon is that the rectum and vagina share a long common wall that must be separated, creating a plane of dissection where it does not exist, in order to mobilize the rectum and put it in the right place.

We believe that most of the complications that we have seen from treatment of this malformation originate from the lack of separation of these two structures, or the defective separation of these two structures.

Figure 27.20

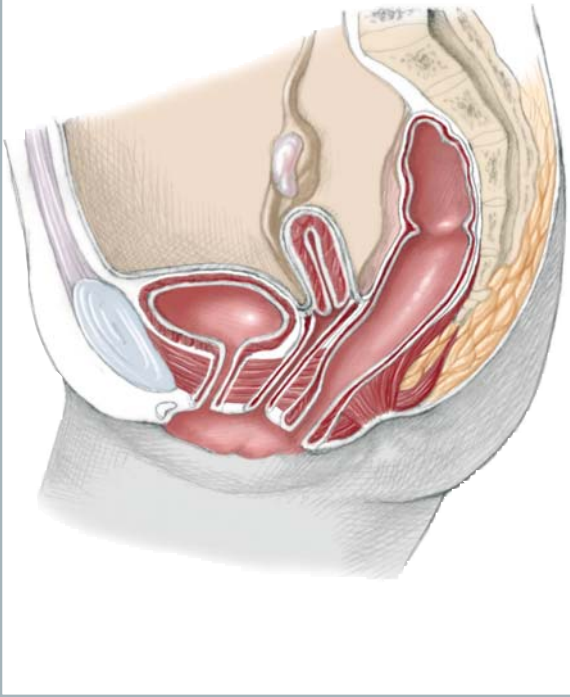


Figure 27.21

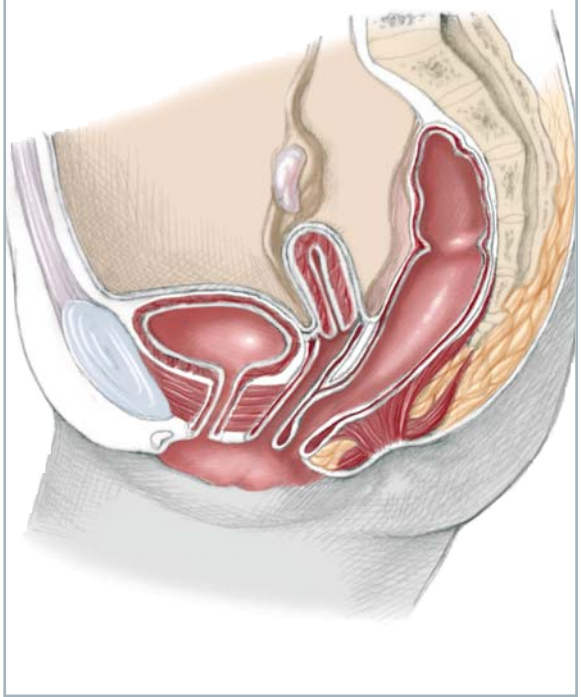


Figure 27.22, 27.23

These patients are also placed in prone position with the pelvis elevated. The incision runs usually from the coccyx down to the fistula site. Again, multiple 6/0 sutures are placed in a circumferential manner in the fistula opening. Traction always facilitates the dissections of these delicate structures. The entire sphincter mechanism is divided posteriorly until we identify the posterior rectal wall, and then the plane of dissection is established removing the fascia that covers the rectum. The dissection then continues laterally. The surgeon must put a special emphasis on a very meticulous separation of the rectum from the vagina. The purpose of this dissection is to make two walls out of one. He or she should try at all costs to avoid making perforations in the rectal wall or the vaginal wall. Once the rectum has been completely separated from the vagina, the surgeon determines the limits of the sphincter electrically and reconstructs the perineal body, bringing together the anterior limits of the sphincter.

The rectum is then placed within the limits of the sphincter as well as the muscle complex. We can see only the lower part of the levator because the incision is rather limited in this operation. The rectum is anchored to the posterior edge of the muscle complex and the anoplasty is performed like we discussed in the previous cases.

When the patient is a newborn, we keep the baby 2 or 3 days with nothing by mouth post-operatively, while receiving intravenous antibiotics. Occasionally, we see patients that come later in life without a colostomy; in those cases, we clean the bowel meticulously the day before surgery with a balanced electrolyte solution, insert a central line in the operating room and keep the patients 10 days with nothing by mouth, while receiving parenteral nutrition. Following this routine, we have never had a case of a wound infection.

Figure 27.22

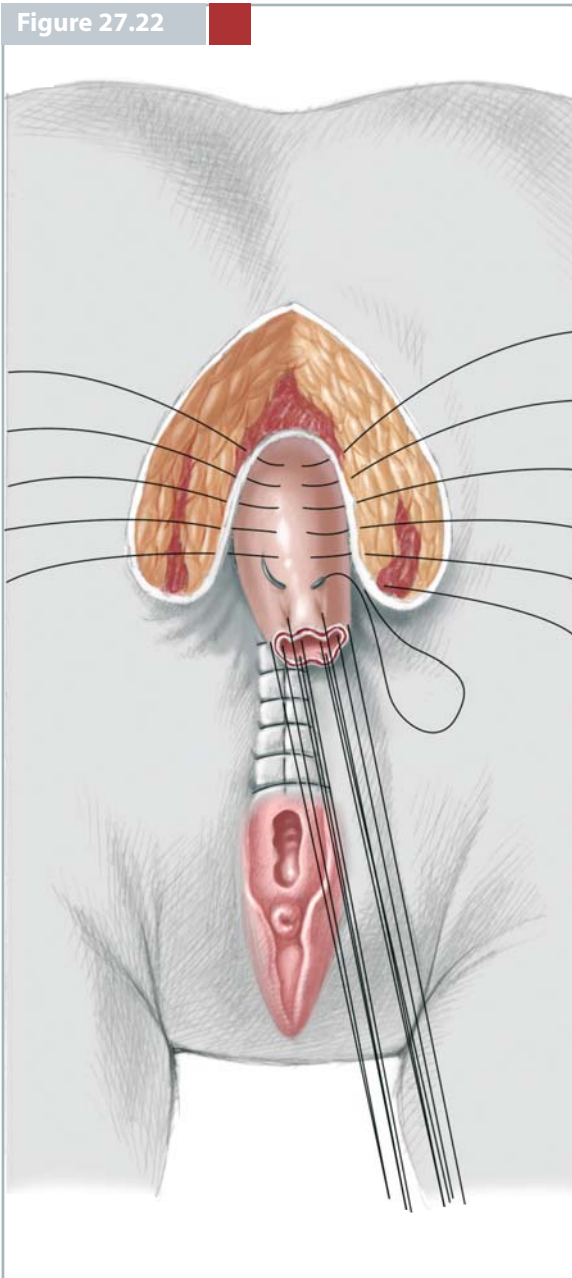


Figure 27.23

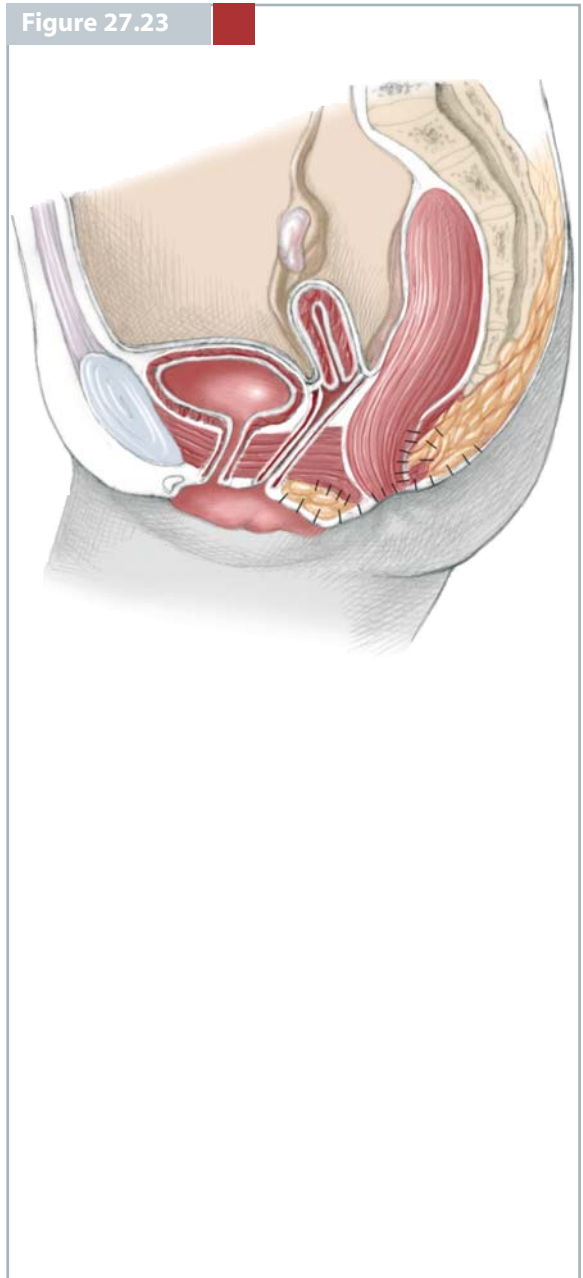


Figure 27.24

■ **Cloaca.** It was 1982 when we operated on the first patient with a cloaca using the posterior sagittal approach. Since that time, until the writing of this chapter, we have operated on 342 patients with cloaca. Cloacas represent a spectrum of malformations. We have been learning many important lessons about the treatment of these malformations. Based on that experience, we now believe that there are two distant groups of cloaca. This separation, we think is important for the pediatric surgeon and pediatric urologist to recognize. In the first group are patients with a common channel shorter than 3 cm, and the second group comprises patients with a common channel longer than 3 cm.

A cloaca is defined as a malformation in which the rectum, vagina and urethra are congenitally fused, forming a common channel and opening in a single perineal orifice at the same location where the normal female urethra is located. These three structures share common walls that are very difficult to separate. We have learned that the length of the common channel has important therapeutic and prognostic implications.

The group of cloacas with a short common channel (<3 cm) represents 68% of all our cloaca patients and, therefore, we believe that perhaps there are enough cloacas of this type in the world for the general pediatric surgeons to learn to repair them successfully. On the other hand, 32% of all cloaca have a common channel longer than 3 cm, and we believe that because of their complexity and rarity, they should be repaired by individuals with special training that includes a special dedication to pediatric urology.

Patients suffering from cloaca with a short common channel (<3 cm), have a relatively low incidence of associated urologic, spinal, and vertebral defects, whereas patients with long cloacas have a very high frequency of association with complex pelvic anomalies, mainly urologic, as well as vertebral. That is what makes the repair of this group very challenging.

Patients with a short common channel can be repaired posteriorly sagittally only, without opening of the abdomen.

When a baby is born with cloaca, the surgeon must keep in mind that approximately 50% of these patients suffer from a very giant vagina full of fluid called "hydrocolpos". The hydrocolpos may compress the trigone interfering with the drainage of the ureters and therefore provoke bilateral megaureters and hydronephrosis. It is imperative that the surgeon to keep this in mind.

All babies with cloaca should have a complete urological evaluation at birth, as well as an ultrasound of the kidneys and ultrasound of the pelvis. The baby should not be taken to the operating room without this evaluation. If the baby suffers from hydrocolpos, it is mandatory that the surgeon drain the hydrocolpos at the same time that he or she opens a colostomy. Not draining a hydrocolpos may produce persistent hydronephrosis and induce an inexperienced pediatric urologist to perform ureterostomies or nephrostomies when they are not indicated. The drainage of the vagina most frequently takes care of the problem of hydronephrosis. Also, the lack of drainage of a tense hydrocolpos may produce infection of the vagina (pyocolpos), perforation and sepsis.

The colostomies must be completely diverting (separated stomas) to avoid contamination of the urinary tract. We now repair cloacas when the babies are 1-month-old, provided they are growing and developing normally.

About 30% of the patients also have duplicated Mullerian structures. In other words, they have different degrees of septation and separation of the hemi-vaginas and two hemi-uterii. These have significant potential obstetric implications.

Before we begin this operation, the patients are placed in lithotomy position and a cystoscopy is performed. If the surgeon finds that the patient has a cloaca with a common channel shorter than 3 cm, it may be assumed that he or she will be able to repair the malformation posteriorly sagittally only. Surgeons may assume that they do not have to open the abdomen and that the final functional prognosis, both for urinary and faecal function, is going to be reasonably good. On the other hand, if the patient has a longer common channel, she must be operated on by a highly experienced and skilled surgeon or team of surgeons.

In cases of a short common channel, the patient is placed in a prone position with the pelvis elevated and the incision runs from the middle portion of the sacrum all the way down to the single perineal orifice. The entire sphincter mechanism is divided posteriorly and then the visceral structure (usually the rectum) is exposed. For many years, the way we repaired these cloacas consisted of separating the rectum from the vagina and then separating the vagina from the urinary tract, reconstructing what used to be the common channel as a neourethra and then placing the vagina behind the neourethra and the rectum within the limits of the sphincter mechanism.

Figure 27.24

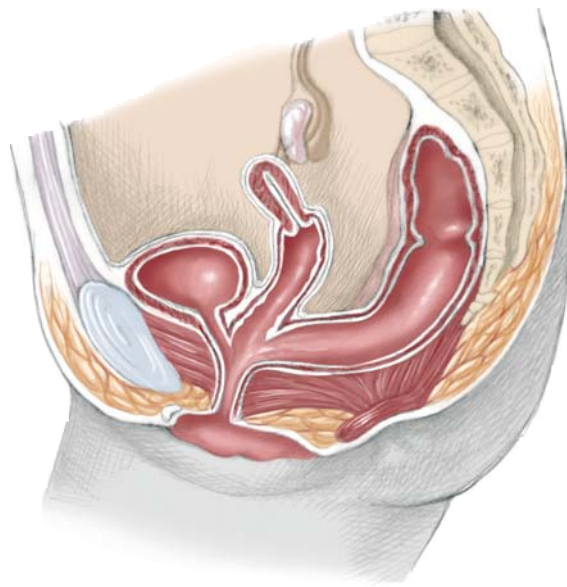


Figure 27.25, 27.26

In the last 125 patients, we introduced a technical variant called total urogenital mobilization. The rectum is separated from the vagina in the same way that they were separated in the cases of rectovestibular fistula. Once we expose the malformation, multiple 6/0 silk stitches are placed taking the edges of the common channel and the edges of the vaginal walls. We use those stitches to exert a uniform traction. Then urethra and vagina together are mobilized in what we call total urogenital mobilization. Another set of sutures is placed in a transverse fashion taking the mucosa of the common channel 5 mm proximal to the clitoris and then the entire common channel is divided, full thickness, creating a plane of dissection between the pubis and the common channel. This is a natural plane of dissection and therefore it is very easy to dissect. We reach the upper part of the pubis and there we can identify avascular fibrous structures that fix the genitourinary structures to the pelvis. These are divided and that allows an immediate gain of length of the urogenital structures of approximately 2–4 cm, which is enough to repair the malformations with short common channels.

The goal of this mobilization is to move what used to be a urethral meatus all the way down, to be placed immediately behind the clitoris to be visible and accessible for future urethral catheterizations when indicated. The vagina comes down together with the urethra and the edges of the vagina are sutured to the skin of the perineum forming the new labia. What used to be the common channel is divided in the midline creating two flaps that are preserved and sutured to the new labia to enrich that tissue. All this reconstruction is performed with interrupted 6/0 long-term, absorbable sutures. With these kinds of techniques, in patients with a good sacrum, 80% of them have bowel control and approximately 80% of them can empty the bladder voluntarily without intermittent catheterization, and remain dry of urine; 20% of them require intermittent catheterization to empty the bladder. Fortunately, they have a good bladder neck and they remain dry between catheterizations. When the sacrum is very abnormal, the results are not as good.

The repair of patients suffering from cloacas with longer common channels (>3 cm) represents a real technical challenge and requires a great deal of expe-

rience in the management of these cases. For that kind of patient, the surgeon should have experience in the management of the urinary structures including bladder reconstructions, bladderneck reconstructions, ureteral reimplantations, bladder augmentation and Mitrofanoff procedures.

In cases with long common channels, if the pediatric surgeon and/or pediatric urologist both have experience with these malformations they continue with the repair, performing first what we call a total body preparation in order to have access both to the perineum and the abdomen.

If the common channel is longer than 5 cm, we recommend opening the abdomen directly in the midline because, in that particular case, rectum and vaginas are not accessible posteriorly sagittally and are more easily accessed through the abdomen.

If the common channel is between 3 and 5 cm, the surgeon can open posteriorly sagittally, still will find the vagina or vaginas and can try to repair them by performing the total urogenital mobilization. If the total urogenital mobilization proves not to be enough to repair the malformation then the operation must be completed through a laparotomy. The separation of the rectum from the vagina is not difficult in very high malformations since it is similar to what we described in the separation of the rectum from the bladder neck in male patients. On the other hand, the separation of the vagina from the urinary tract in a case of a cloaca with a long common channel is a very delicate manoeuvre that requires expertise and finesse. Once the vagina has been completely separated, which is a manoeuvre that may take several hours, the surgeon then has to make important decisions considering the way to repair the vagina. The separation of the vagina from the urinary tract should be performed with the bladder open in the midline and with ureteral catheters. The ureters run through the common wall that separates the vagina from the bladder and therefore, the surgeon should be ready to deal with the fact that the ureters may be right in the plane of separation. Once the vagina has been separated, the surgeon should evaluate the size of the mobilized vaginas and the length that he needs to bring the vagina down. It may be that the patient has a very large vagina that reaches the perineum.

Figure 27.25

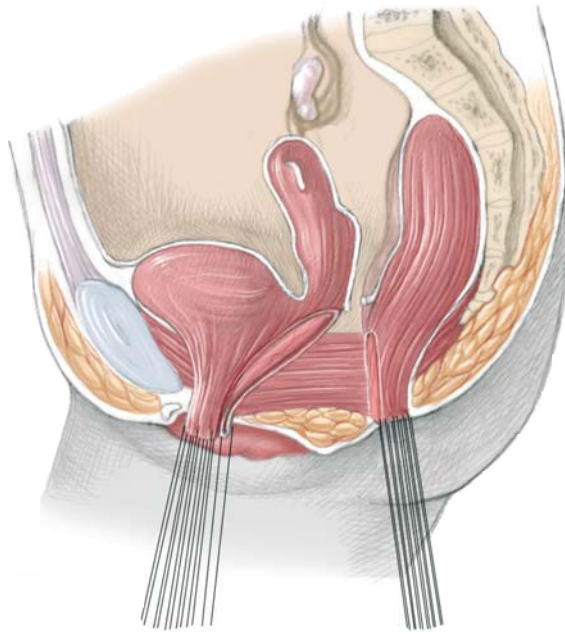
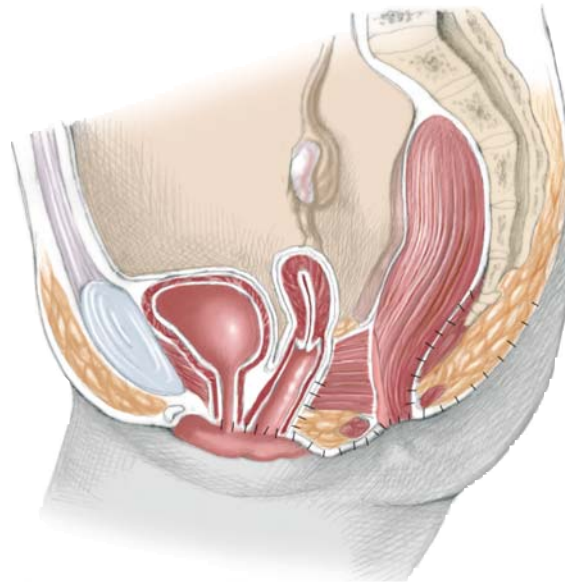


Figure 27.26



CONCLUSION

Clinical results are different for each type of the malformations. A recent review of the authors' series showed that 100% of patients with rectal atresia and perineal fistula had voluntary bowel movements, those with vestibular fistula 93.8%, bulbar urethral fistula 87.5%, imperforate anus without fistula 85%, cloaca 83.3%, rectourethral prostatic fistula 76.5%, and bladderneck fistula 28.6%. Soiling in patients who enjoy voluntary bowel movements usually represents a manifestation of faecal impaction and when the constipation is treated properly, the soiling usually disappears. Patients who enjoy voluntary bowel movements and never soil are considered "totally continent".

Constipation is a common sequela seen after the repair of an anorectal malformation. Interestingly, patients with lower defects, and therefore with better prognosis for bowel control, suffer a higher incidence of constipation and vice versa. Constipation correlates directly with the degree of rectosigmoid dilation at the time of colostomy closure. Therefore, eve-

ry effort should be made to try to keep the rectosigmoid empty and decompressed from day 1 in these patients.

Urinary control can be expected in the overwhelming majority of male patients after repair of imperforate anus provided a good surgical technique was performed. Urinary incontinence is a concern only in male patients with absent sacrum or in some female patients with cloaca. In this last defect, when the common channel is shorter than 3 cm, approximately 20% of patients require intermittent catheterization to empty the bladder. The remaining 80% enjoy urinary control. When the common channel is longer than 3 cm it was observed that 68% of the patients require intermittent catheterization to empty the bladder. Fortunately, after the repair of a cloaca, patients have a good bladderneck; they have the capacity to empty the bladder. Thus, when the bladder becomes completely full, the patients start suffering from overflow urinary incontinence. Intermittent catheterization keeps these patients completely dry.

SELECTED BIBLIOGRAPHY

- Hong AR, Rosen N, Acuña MF, Peña A, Chaves L, Rodriguez G (2002) Urological injuries associated with the repair of anorectal malformations in male patients. *J Pediatr Surg* 37:339-344
- Levitt MA, Stein DM, Peña A (1998) Gynecological concerns in the treatment of teenagers with cloaca. *J Pediatr Surg* 33:188-193
- Peña A (1995) Anorectal malformations. *Semin Pediatr Surg* 4:35-47
- Peña A (1997) Total urogenital mobilization-an easier way to repair cloacas. *J Pediatr Surg* 32:263-268
- Peña A (2003) Anorectal malformations. In: Ziegler M, Azizkhan R, Gauderer M, Weber TR (eds) *Operative pediatric surgery*. Appleton & Lange, Norwalk CT
- Peña, A (2003) Anorectal anomalies. In: Puri P (ed) *Newborn surgery*. Arnold, London, pp 535-552

INTRODUCTION

Intussusception means by definition that one portion of the gut is telescoping in another distal part with further motion of the intussusception into the intussusciens by ongoing peristalsis. The most common form is ileo-colic in 80–90% of cases, less often ileo-ileal occurs in up to 15% and rarely caecocolic, jejuno-jejunal or even ileo-ileo-colic occur in a double or three-fold manner. Colo-colic is found more often in parasitic diseases.

As far as aetiology is concerned, a mobile ascending colon, malrotation or non-rotation facilitates intussusception. A leading point serves as head of intussusception, which is drawn into the distal gut by peristaltic activity, often in hyperperistalsis, as found concomitantly in episodes of gastro-enteritis or upper respiratory infections. The vast majority of cases are idiopathic (80–90%).

Swollen Payer's plaques in adenovirus or rotavirus infection protrude into the lumen of the bowel, initiating intussusception; so, lymphoid hypertrophy may be primary but is secondary as well, since swollen lymph nodes are found routinely. Mesentery is drawn into the intussusciens and is more and more compressed with lymphoid and vascular compromise, resulting in lymphatic and venous obstruction. Progressive oedema of the bowel wall finally leads to mucosal bleeding and possibly to arterial insufficiency and bowel necrosis.

Typical symptoms are explained by this pathological pattern. In an early state initial vomiting – found in 80% – and lethargy are caused by tearing of the mesentery; so far there is no obstruction, as well as no abdominal distension. Colicky, intermittent ab-

dominal pain with pulling legs up to the abdomen begins acutely at the rate of regular peristaltic activities – initially around every 20 min – but with increasing frequency. Typically these attacks cease as promptly as they started and the child is quiet in between these regular recurrent attacks.

Examining the child, the right lower quadrant seems empty but a tender mass – mostly in the right upper quadrant – can be felt in about 85% of cases. In a later stage of intussusception, on rectal examination, mucous clots, currant jelly-like and occult, or even gross, blood may be seen. As soon as oedema and venous compression has developed, clinical obstruction of the bowel becomes obvious, leading to bilious vomiting, abdominal distension, dehydration, tachycardia, fever and shock.

Typical patients affected are usually 3–12 months old, well nourished and healthy infants. Incidence overall is 1–4%. Less than 1% of intussusceptions are found in neonates and up to 95% occur within the first 2 years (van der Laan et al. 2001). With increasing age a pathological lead point should be expected, especially when the child is outside the usual age range. In children older than 5 years a pathological lesion is found in 75–90%. Leading points often found are Meckel's diverticulum, polyps, appendix or lymph nodes; rarely found but well known are neoplastic lesions like carcinoid tumour or Hodgkin lymphoma, foreign bodies, ectopic tissue of pancreas or gastric mucosa, duplication cyst or, in newborns, atresia. Intramural haematoma may induce intussusception especially in Schönlein-Henoch disease.

Figure 28.1

■ **Diagnostics.** Plain abdominal radiograph is only indicated in unclear diagnosis, showing only late specific signs of abdominal gas distribution or faecal contents and, finally, signs of bowel obstruction or

perforation. In retrograde barium enema formerly used, the contrast medium is outlining the apex of the intussusceptum.

Figure 28.2

Ultrasonography as well as fluoroscopy with contrast enema is well established; ultrasonography is preferred mostly because there is no irradiation and diagnostic sensitivity of ultrasound (US) is 98.5% and the specificity is 100%. Typical patterns of US are target – or doughnut or pseudo-kidney sign. This means “ring in the ring” in the transverse section or a kidney-like formation in longitudinal section of the intussusceptum. Absence of colour flow in colour Doppler suggests compromise of the mesenteric vasculature, indicating a difficult reduction and a lower reduction rate.

Figure 28.3

■ **Non-surgical Treatment.** Before preparing for conservative treatment radiologists should inform the pediatric surgeon and the operating room. In recent literature there is no contraindication for a conservative trial of reduction in respect to hours of case history or position of the apex. But non-surgical treatment should not be undertaken in a patient with clinical signs of shock, peritonitis or heavy obstruction. Hydrostatic reduction was formerly done by a barium or soluble isotonic contrast enema. Nowadays, saline (Hartmann’s solution) or air is preferred needing less fluoroscopy or even no irradiation at all, since hydrostatic reduction can be visualized and controlled easily by ultrasound. In comparison to barium enema, air reduction is reported to be quicker, less messy, decreases time of irradiation and shows a higher reduction rate (75 vs. 90%). In air reduction there is no risk of barium peritonitis. Hydrostatic reduction under ultrasound monitoring is, in the meantime at 89%, as effective as air reduction in experienced hands. Ultrasound during hydrostatic reduction reveals the head of the intussusceptum in transverse and longitudinal sections.

Figure 28.1

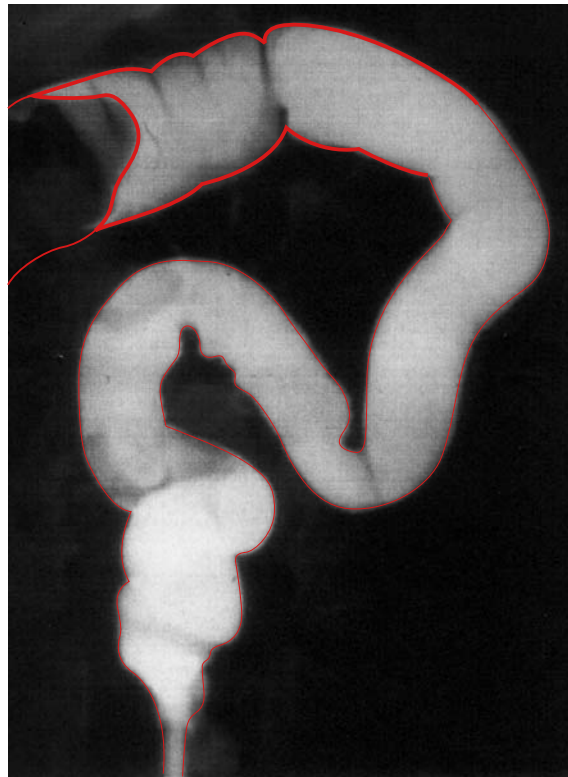

Figure 28.2

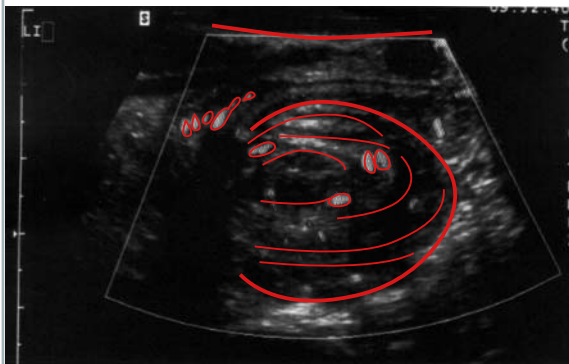


Figure 28.3

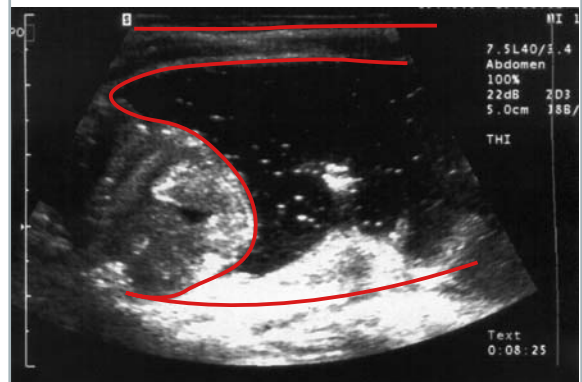


Figure 28.4

The technique of reduction is uniformly well accepted. The infant lies prone and should be on sedation and analgesics. A Foley catheter as big as possible is inserted into the ampulla of the rectum. The buttocks are squeezed together and taped to prevent leakage. Pressure used for reduction should not exceed 3 ft, i.e., 90–100 cmH₂O or 80–120 mmHg using air. Pressure can be maintained as long as reduction is occurring. In absence of progress for more than 3–4 min, hydrostatic pressure is reduced before reduction is started again for a second or a third time. Reduction may be continued for even 45–60 min as long as steady progress is being made. Often a delay in the caecum region is observed before free flow of air, saline or contrast medium into the distal small bowel is seen as well as the disappearance of the mass. Return of flatus or faeces indicates the complete reduction. Clinically the infant must show an overall complete

improvement and lethargy should disappear in the following routine observation for 24–48 h. Prognosis of non-surgical reduction can be predicted according to sonographic pattern. If it is target-like, a reduction is to be expected in 100% of cases. In doughnut sign, patient's reduction rate is related to thickness, being 100% effective for a thickness less than 7.2 mm. Whenever it is more than 14 mm a resection is very likely required. Fluid within the head of intussusception means unsuccessful reduction is expected to be very likely. In unsuccessful or incomplete reduction the manoeuvre may be repeated after 2–3 h when the infant is still in good condition. The rate of recurrent intussusception after non-operative reduction is 13% in the typical age group. Complications of the reduction manoeuvre are perforation, marked by free air, and fluid or contrast medium intraperitoneally.

Figure 28.5

■ **Indication for Surgery.** A residual intraluminal filling defect even with terminal reflux into the ileum has to be considered as incomplete reduction. Early or multiple recurrences mean a likely leading point exists. Whenever a pathological leading point is suggested a straight-forward surgery is recommended. With evidence of a seriously ill patient with peritonitis by bacterial translocation, by perforation or by necrosis, as well as in a septic status, the treatment of choice is primarily surgical. Whenever no intussusception in the colon is found in obvious bowel obstruction by ultrasound or enema fluoroscopy, the operation should be started at once because intussusception is likely to be located in the small gut. Preparation of the patient for surgery in cases of intussusception should include decompression of gastrointestinal tract by open nasogastric tube, and monitoring of body temperature and oxygen. Laboratory studies show dehydration, electrolyte deficiencies, base excess abnormalities and inflammatory pa-

rameters. Antibiotics may be started even pre-operatively when there are signs of peritonitis or sepsis.

On the operating table, the child lies on his or her back with a roll under his middle abdomen and is under general anaesthesia including full relaxation. Mostly, a right transverse incision supra-umbilical at the umbilicus or lower is recommended, adapted to the position of the apex of intussusception. A midline longitudinal incision is an easier and quicker approach and may be used as well. Pararectal incision has been abandoned. Extensions of the incisions mentioned are readily possible if required. In right transverse line the skin is cut. Fat, anterior rectus sheet, rectus muscle, posterior rectus sheet and lateral abdominal muscles, i.e., *m. obliquus externus*, *internus* and *transversus*, are incised, mostly using diathermy. As soon as abdominal cavity is entered, free peritoneal fluid is aspirated and a swab is taken. Cloudy or sanguineous fluid raises the suspicion that a perforation or necrosis is going to be found.

Figure 28.4

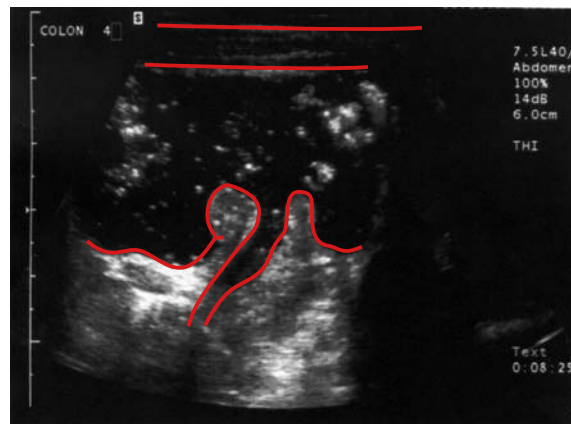


Figure 28.5

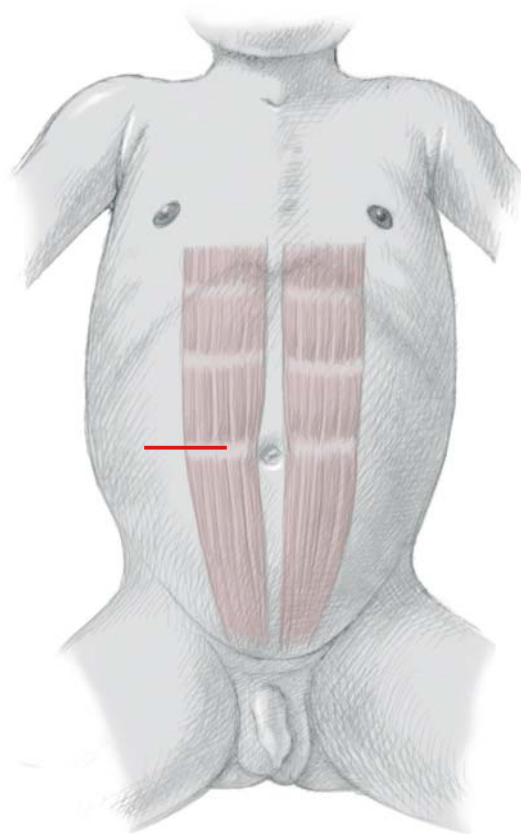


Figure 28.6

If the intussusception can be reduced easily and rapidly there is no need to deliver the intussusception. Thus, the incision may remain smaller, not bringing the whole intussusception outside the abdomen, as well as when a partial reduction could be managed intra-abdominally. But whenever the manoeuvre of reduction is difficult and an inspection of viability is necessary, it is easier to be done with the intussusception outside. In order to deliver the intussusception it may be wise to mobilize the bands of right ascending colon to lateral abdominal wall by division. Often this is not necessary because of a mobile caecum and ascending colon. Fluid contaminated by bacterial translocation may escape from the space between intussusception. Therefore, positioning of packs should avoid further contamination during reposition. Manual reduction has to be performed very carefully and slowly. Taking the apex of intussusception between fingers and cup of the surgeon's hand at the distal end, the intussusception is squeezed gently in a retrograde direction distally to proximally. A layer of gauze between bowel and fingers may facilitate this procedure. This gentle manipulation should be more pushing at the apex rather than pulling proximally at the intussusception. Time is an important factor since oedema must be allowed to dissipate in order to avoid serosal or even seromuscular tearing. Should this happen, serosal defects are left alone, seromuscular flaps are repositioned and fixed by 5/0 stitches. Attempts to perform reduction with instruments are followed by heavy laceration due to oedema and fragility. The reduced bowel wall is always oedematous with a non-shiny serosa, but may be discoloured or even blue or black. As a test of viability, administering moist and warm wraps may serve in order to check whether there is a regular colour coming back after some minutes of waiting.

Figure 28.7

A check for a leading point is very important. It is regularly found after a full reduction that the circumference of the bowel formerly intussuscepted is thickened and oedematous and a typical dimple is recognised at the site of the former leading point. This dimple, a Payer's patch or an oedematous ileocecal valve can mimic an intraluminal pathological mass as lead point, but careful palpation and the knowledge of this likely condition of dimple formation should prevent excising local tissue as a probe or even an unnecessary resection, particularly in the typical infant age group.

Appendectomy is usually performed. Additional fixation of terminal ileum is hardly mentioned in the literature. To preventing a second intussusception, it does make sense to fix that part where the disease is starting most often, i.e., the terminal ileum. Three sero-serosal stitches, 5/0 or 4/0, from terminal ileum to ascending colon are performed quickly and not interfering with mesenteric vessels. Since the rate of recurrence is not high, it remains a personal decision regarding whether to do a fixation at initial intussusception. In recurrent intussusception it is of definite benefit, since the ileocecal valve is widened.

For closure the abdominal cavity is irrigated with warm saline. No drainage is used. The peritoneum and posterior rectus sheet is closed at the same time by running 3/0 sutures. Continuous suturing is also sufficient for anterior rectus sheet. A subcuticular 4/0 running suture provides a good skin adaptation and a cosmetically good scar. Skin closure by intracuticular suture line, by fibrin sealant or metal clips is optional.

Indications for resection include irreducible intussusception, gangrenous bowel or perforation of the bowel. After resection of the bowel, end-to-end intestinal anastomosis is completed in a similar way as shown in Chap. 22.

Figure 28.6

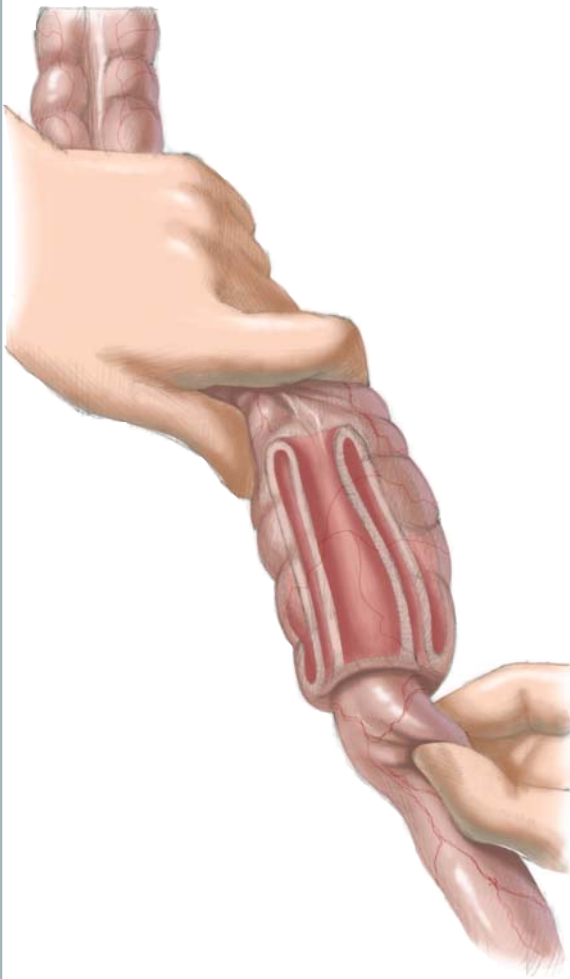
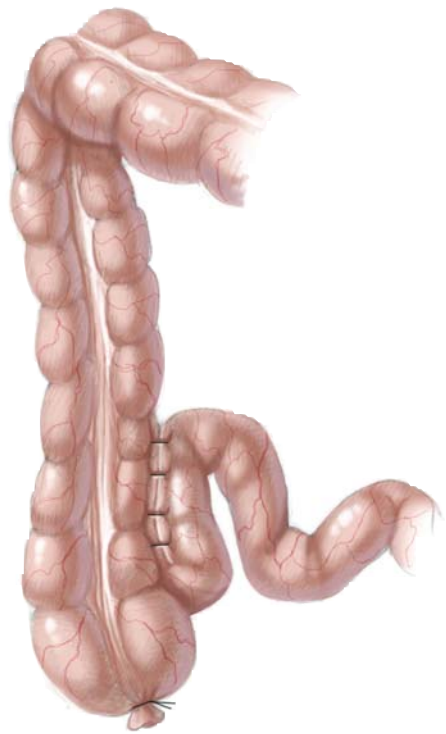


Figure 28.7



CONCLUSION

■ **Postoperative Care.** In a regular case without resection nasogastric tube delivers decompression of the upper gastrointestinal tract for 1 or 2 days and patients are kept on intravenous lines for substitution of fluid and glucose. As soon as oedema of the bowel wall is dissipated, the passage and peristalsis recovers early. Satisfactory bowel function is indicated by an absence of spontaneous bile-stained flow out of nasogastric tube. The abdomen is soft early on, is not distended and during gentle palpation it does not hurt. Post-operatively there might be a short period of elevated body temperature but patients should clinically recover rapidly. Antibiotics are administered according to the intra-operative situs. Single shot is sufficient in most cases with normal reduction manoeuvres. In cases of resection and opening the gut, the post-operative course is prolonged. Patients may be discharged as soon as taking sufficient fluid and having bowel motion. Parents should be informed whether an appendectomy has been performed or not.

■ **The Role of Laparoscopy.** In a suspected jejunal or ileal intussusception or in the case of post-operative or chronic intussusception, laparoscopy might be a diagnostic tool or the treatment might even be laparoscopically. A routine diagnosis of a primary intussusception by laparoscopy should be exceptional since ultrasound is perfect. A primary attempt to reduce an ileo-colic intussusception by laparoscopic instruments does not correspond to the treatment of gentle squeezing the apex instead of pulling. In the literature a warning is given because laparoscopic instruments may easily damage the vulnerable bowel.

■ **Recurrence of Intussusception.** Recurrent intussusception is seen after hydrostatic or air reduction over all in around 13% of cases. Recurrence is less

likely after surgical reduction, especially when a fixation of terminal ileum was performed. A secondary intussusception may be reducible at the same rate as in the initial episode. It may be expected in around 30% of cases within the first post-operative day. Clinically irritability and discomfort are the first signs of an early recurrence. Therefore, it makes sense that these patients, even with a definite non-surgical reduction approach, are observed for this period of 24–48 h in the hospital. Indication for surgery in recurrences is given in patients with more than one episode of recurrence, because success rate diminishes with multiple recurrences. Here, additional suspicion of an anatomical leading point arises, especially when children are older than 2 years of age.

Post-operative intussusception after abdominal and thoracic procedures do not occur often but are well known in the literature. Especially prone to this condition are those procedures due to gastro-oesophageal reflux, Hirschsprung's disease and neuroblastoma. Intussusception is found in up to 10% of all post-operative intestinal obstructions. These are mostly ileo-ileal. Prolonged bilious nasogastric reflux, bile-stained vomiting, diffuse pain and abdominal distension are the clinical signs but are hardly to be distinguished from other usual post-operative problems like adhesions, the beginning of anastomotic leakage or abscess formation.

Chronic intussusception is a rare condition. This means a non-strangulating, long-lasting intussusception of a minimum of 14 days, mostly due to anatomical leading points. The clinical picture is dominated by chronic diarrhoea, which is resistant to any therapy. Patients are evacuating bloody or mucous stools and suffer from colicky pain including episodes of vomiting all the time, leading finally to weight loss. Diagnosis can be achieved by ultrasound, contrast studies or even by laparoscopy.

SELECTED BIBLIOGRAPHY

- van der Laan M, Bax NM, van der Zee DC, Ure BM (2001) The role of laparoscopy in the management of childhood intussusception. *Surg Endosc* 15: 373–376
- Linke F, Eble F, Berger S (1998) Postoperative intussusception in childhood. *Pediatr Surg Int* 14: 175–177
- Littlewood Teele R, Vogel SA (1998) Intussusception: the pediatric radiologist's perspective. *Pediatr Surg Int* 14: 158–162
- Shehata S, Kholi N El, Sultan A, Sahwi E El (2000) Hydrostatic reduction of intussusception: barium, air, or saline. *Pediatr Surg Int* 16: 380–382
- Stringer MD, Pablot SM, Brereton RJ (1992) Paediatric intussusception. *Br J Surg* 79: 867–876

INTRODUCTION

Acute appendicitis is the most common surgical emergency in childhood. Appendicitis may present at any age, although it is uncommon in preschool children. Approximately one-third of children with acute appendicitis have perforation by the time of operation. Despite advances in improved fluid resuscitation and better antibiotics, appendicitis in children, especially in preschool children, is still associated with significant morbidity.

The diagnosis of acute appendicitis in childhood can sometimes be difficult. Definite diagnosis is made in only 50–70% of patients at the time of initial assessment. The rate of negative pediatric appendectomy is in the range 10–50% in various reports. The patient's history and clinical examination are the most important tools for the diagnosis of appendicitis. Peri-umbilical pain is often the first symptom followed by vomiting and fever. When the inflammation progresses, the pain localizes to the right lower quadrant, and right lower quadrant tenderness de-

velops. Laboratory investigations and plain radiographs are neither sensitive nor specific in the diagnosis of appendicitis. In recent years, graded compression ultrasonography of the right lower quadrant has been shown to be a useful tool in the evaluation of patients with clinical findings that are suggestive but not diagnostic of appendicitis, having a sensitivity of 80–94%, a specificity of 90% and an overall accuracy of 90%. Computed tomography (CT) may be helpful in selected cases but is rarely needed.

In patients with an uncertain diagnosis of acute abdominal pain, a policy of active observation in hospital is usually practised. A repeated structured clinical examination is simple and non-invasive.

Children with perforated appendicitis must be treated pre-operatively to prevent dehydration and generalized sepsis. Antibiotics against aerobic and anaerobic bacteria are essential to reduce complications and to prepare the patient for surgical procedure.

Figure 29.1, 29.2

A transverse right lower quadrant skin crease incision across McBurney's point is recommended. The muscular layers are split in the direction of their fibres. The peritoneum is opened and fluid sent for culture.

Figure 29.1

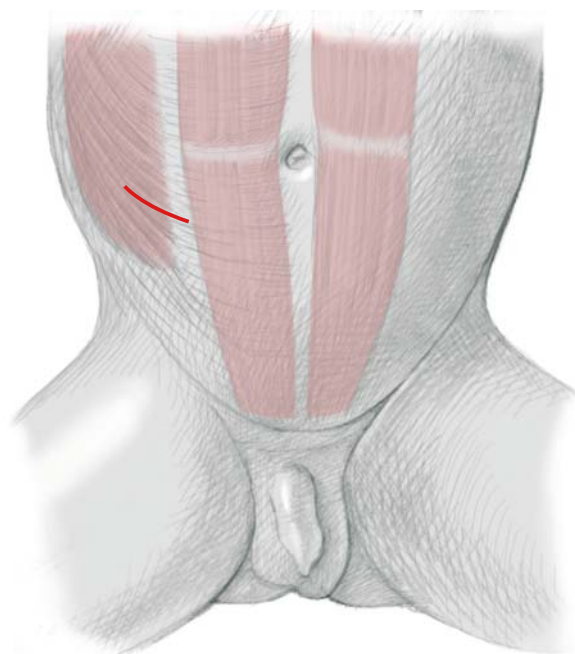


Figure 29.2

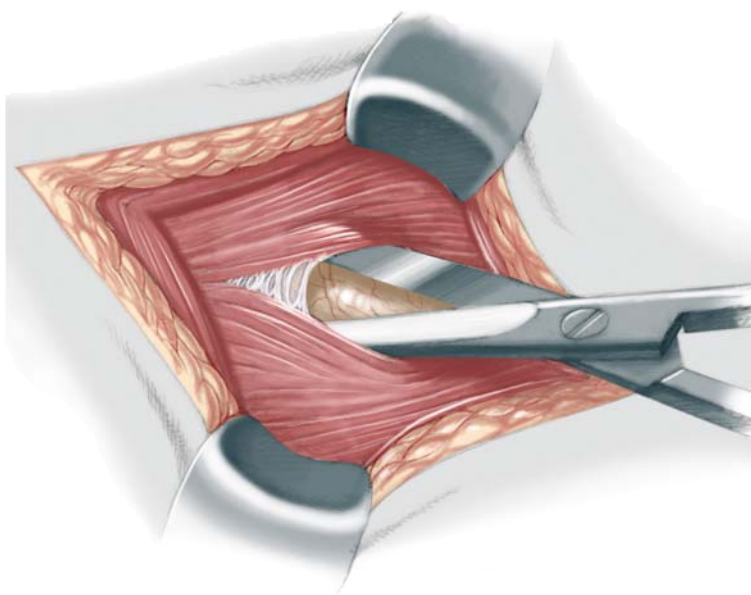


Figure 29.3, 29.4

The mesoappendix is divided and the appendiceal base clamped and ligated. Stump inversion is optional. Several studies have reported no difference as regards wound infection and post-operative fever between one group in which the appendix was ligated and doubly invaginated and another group in which it was simply ligated. If pus is present, the ab-

domen should be irrigated with saline. Drains are not necessary. The abdominal wall is closed in layers. The skin is usually closed by subcuticular absorbable sutures, even in the case of perforation. Primary wound closure after perforated appendicitis is safe, economical and advantageous in pediatric practice.

Figure 29.5

Laparoscopy-assisted removal of the appendix can be performed using two different methods: first, the complete laparoscopic approach and, second, the transumbilical laparoscopic appendectomy (TULAP). The complete laparoscopic procedure is performed using three ports. The first is inserted through the navel, initially for the telescope and afterwards for the operating instruments and the stapler and to extract the appendix. The second port is positioned in the left iliac region for the telescope and for the operating instruments. The third port is positioned in the right iliac region to grab the appendix. A direct transparietal suture is inserted in the right iliac flank to keep the appendix in tension during the dissection. Before resecting the appendix, an exhaustive evaluation of the entire abdominal cavity must be done.

Figure 29.6

Skeletonizing of the appendix is performed using a bipolar instrument or a monopolar hook; large vessels are ligated using clips or regular sutures. Generally, in the case of inflamed tissues and small-sized vessels, clips or sutures are not required. The base of the appendix is closed using staplers or is ligated with two preformed loops.

TULAP is performed using a 10-mm telescope with an operating channel through the umbilicus. The appendix is grabbed and pulled through the umbilicus. The procedure is thereafter completed from outside using a conventional approach through the umbilicus. The advantages of TULAP are the limited dimension of the scars and good cosmetic results.

Figure 29.3

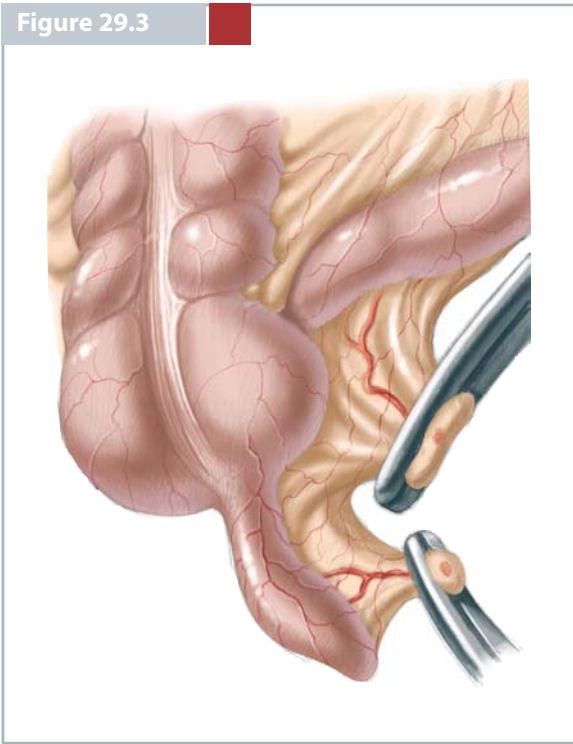


Figure 29.4

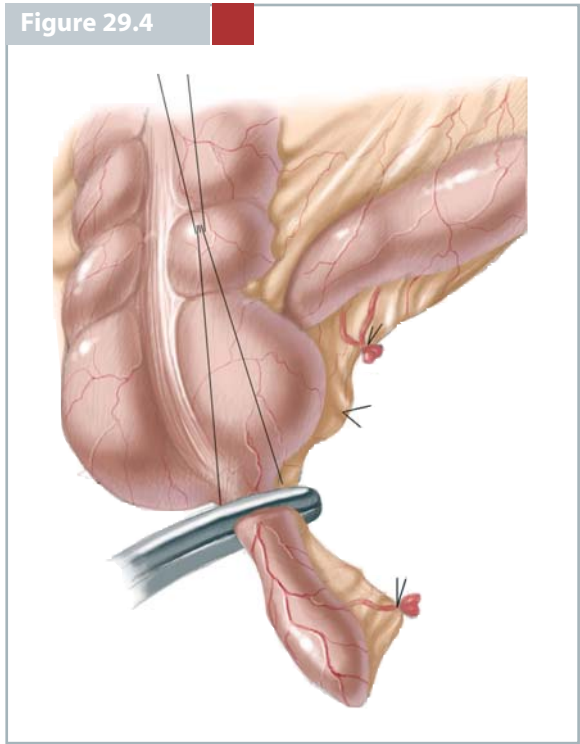


Figure 29.5

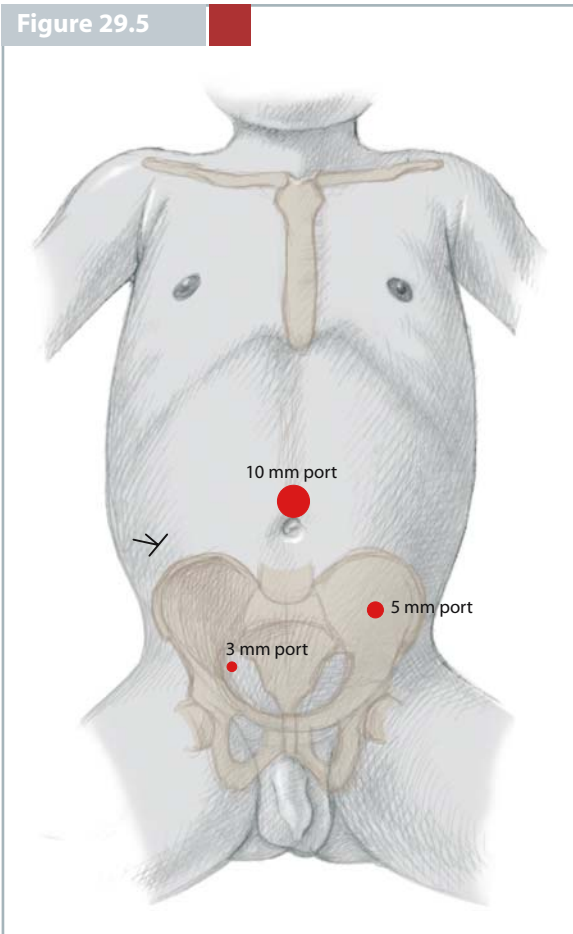
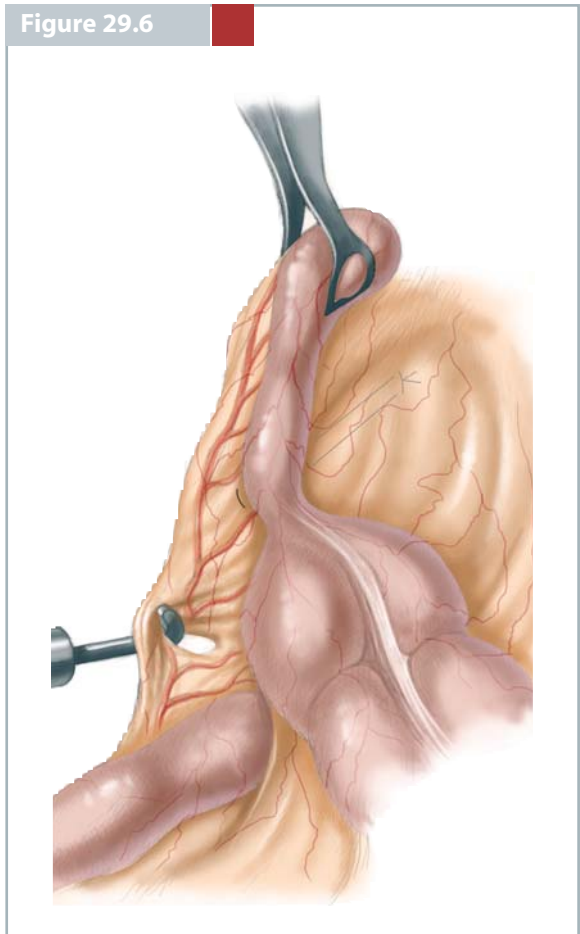


Figure 29.6



CONCLUSION

Advances in peri-operative care and antibiotics have resulted in a zero mortality rate and low morbidity in children with appendicitis. The long-term outcome of the vast majority of patients who undergo appen-

dectomy in childhood is very good. A small number of patients may develop late adhesive intestinal obstruction.

SELECTED BIBLIOGRAPHY

- Emil S, Mikhail P, Laberge JM et al (2001) Clinical versus sonographic evaluation of acute appendicitis in children: a comparison of patient characteristics and outcomes. *J Pediatr Surg* 36: 780–783
- Gauderer MWL, Crane MM, Green JA et al (2001) Acute appendectomy in children: the importance of family history. *J Pediatr Surg* 36: 1214–1217
- Meguerditchian AN, Prasil P, Cloutier R (2002) Laparoscopic appendectomy in children: a favourable alternative in simple and complicated appendicitis. *J Pediatr Surg* 37: 695–698
- Moir CR (1992) Appendectomy: open and laparoscopic approaches. In: Spitz I, Coran AG (eds) *Rob and Smith's operative surgery*. Chapman & Hall, London, pp 402–410
- Puri P (1998) Appendicitis. In: Stringer MD, Oldham KT, Mouriquand PDE, Howard ER (eds) *Pediatric surgery and urology: long-term Outcomes*. WB Saunders, London, pp 321–328

Omphalomesenteric Duct Remnants

David Lloyd

INTRODUCTION

The embryonic yolk sac communicates with the alimentary canal via the viteline duct, which normally regressed by the sixth or seventh week of gestation. Incomplete regression results in various abnormalities which may be apparent in the newborn infant at birth. These include patency of the duct (omphalomesenteric or vitello-intestinal duct), persistence of the patent intestinal end of the duct as a Meckel's diverticulum, persistence of the omphalo-mesenteric duct as a fibrous cord (Meckel's band), the presence of a cyst within a Meckel's band, or an isolated remnant of intestinal mucosa at the umbilicus (umbilical polyp). Each of these may give rise to problems requiring operation to remove the anomaly in the newborn period or beyond.

The indications for resection of a Meckel's diverticulum include bleeding, diverticulitis, intussusception, or Meckel's band obstruction. The Meckel's diverticulum is lined by ileal mucosa. Islands of ectopic gastric tissue may also be present in a Meckel's diverticulum and secrete gastric acid, which may lead to ulceration of the adjacent ileal mucosa and bleeding which at times is severe. This is a common cause of rectal bleeding in infancy. Ectopic gastric tissue may be identified by Technetium⁹⁹ scanning.

Diverticulitis: inflammation of a Meckel's diverticulum produces symptoms identical to those of acute appendicitis, which is the usual pre-operative diagnosis. The true diagnosis is seldom made prior to laparotomy. Meckel's diverticulitis may lead to formation of an inflammatory mass and occasionally is complicated by perforation.

Intussusception: a Meckel's diverticulum may invert into the lumen of the ileum and be dragged along by peristaltic contractions. This leads to intussusception, which will present with acute abdominal pain and evidence of intestinal obstruction. At operation the intussusception is reduced as far as possible prior to resection of the diverticulum and adjacent ileum.

Meckel's band obstruction: loops of small intestine may become trapped around a Meckel's band leading to intestinal obstruction with a high risk of strangulation. Division of the band and excision of the diverticulum are required.

Asymptomatic Meckel's diverticulum: there is no sound evidence to support routine resection of an asymptomatic diverticulum encountered incidentally at operation.

Figure 30.1

General anaesthesia is used. No pre-operative preparation is required other than routine withholding of feeds. A single dose of broad spectrum antibiotics is given on induction of anaesthesia to reduce the risk of wound infection.

When the diagnosis is known, a bleeding or inflamed Meckel's diverticulum may be approached through a right transverse abdominal incision situated just below the level of umbilicus. For intestinal obstruction, particularly when the cause is not known, a right transverse incision situated above the umbilicus will provide good exposure and is easier to extend across the abdomen should this be necessary.

The Meckel's diverticulum may be folded over and adherent to the adjacent small bowel mesentery. It is mobilized easily by dividing these peritoneal adhesions.

Figure 30.2

In most cases the diverticulum is excised with the adjacent segment of ileum. This ensures a straight anastomosis of the ileum and ensures removal of any ectopic gastric tissue. The lines of resection are illustrated. Note that the blood supply to the Meckel's diverticulum runs from the small bowel mesentery across the ileum to the diverticulum; this vessel must be separately divided.

Figure 30.3, 30.4

A narrow-based Meckel's diverticulum may be excised using a transverse elliptical incision as illustrated. A stay suture is inserted on either side of the ileum at the corners of the proposed excision. The diverticulum is excised with a cuff of adjacent ileum.

The open ileum is inspected for islands of ectopic gastric tissue, which must be excised if present, and then is closed with interrupted inverting absorbable sutures. The abdomen is closed in a routine manner.

Figure 30.1

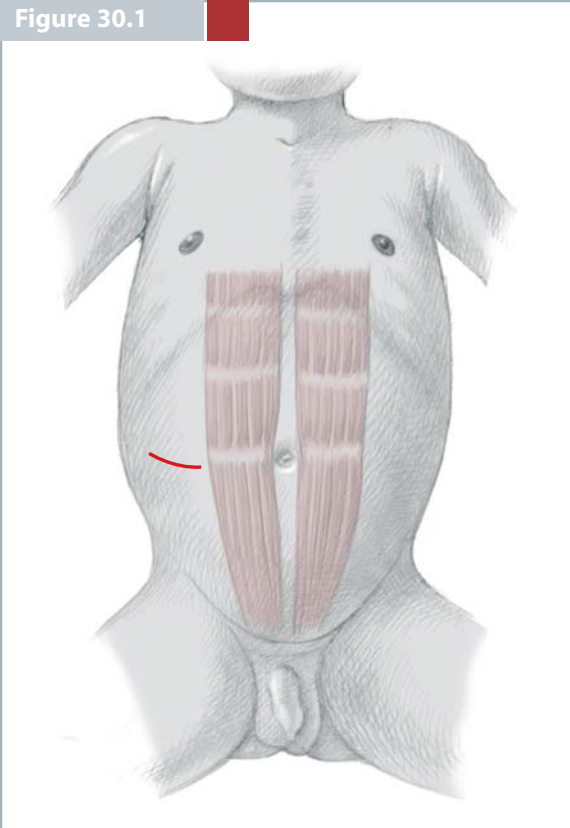


Figure 30.2

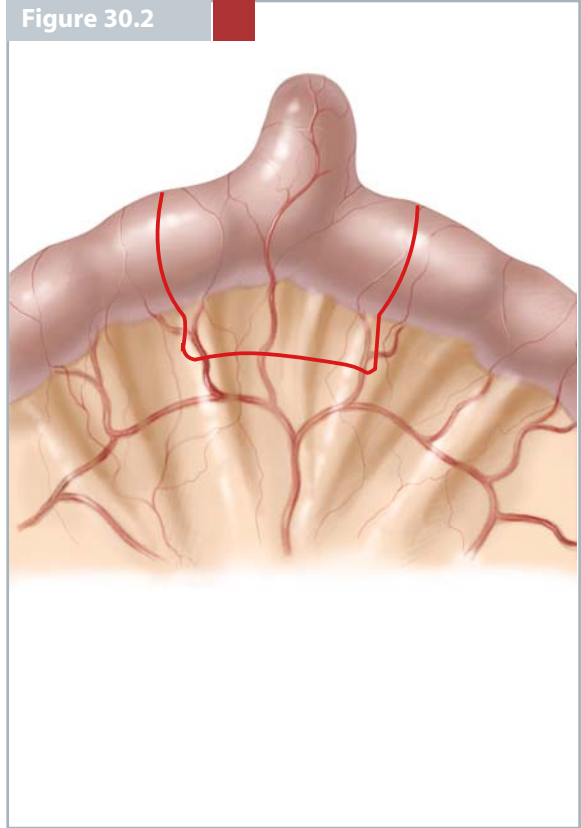


Figure 30.3

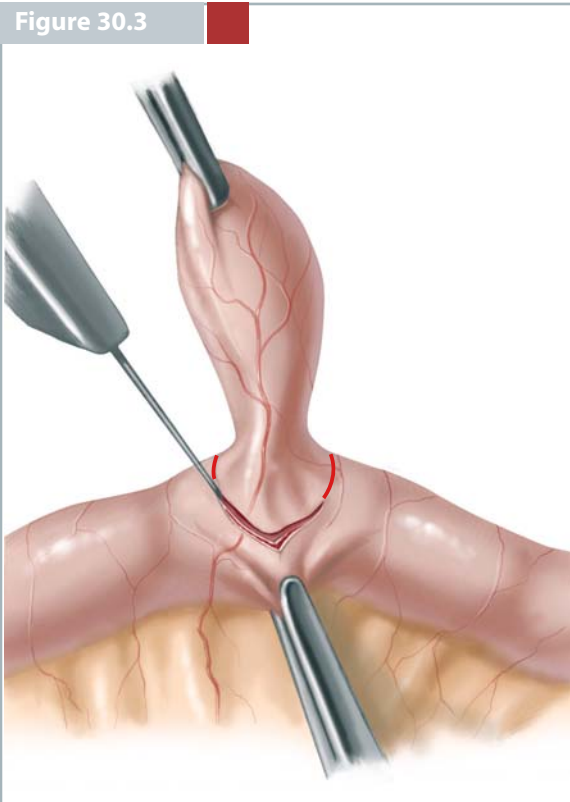


Figure 30.4

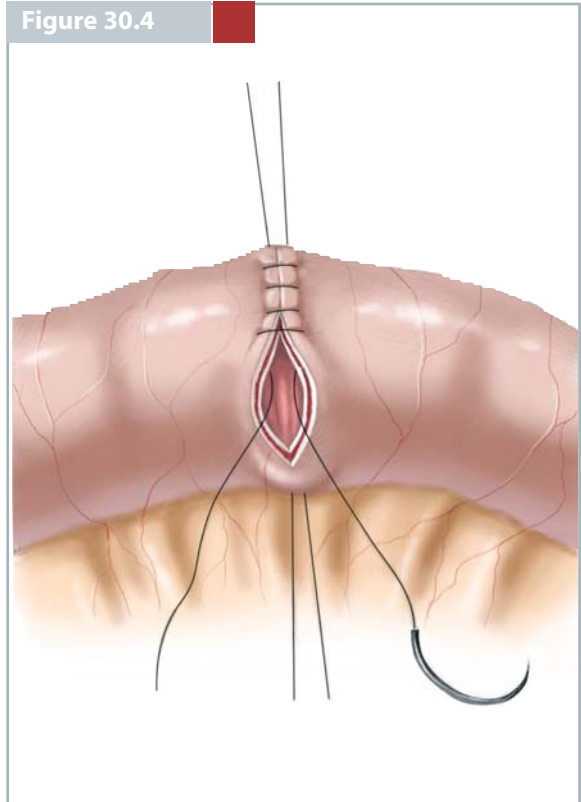


Figure 30.5, 30.6

A patent omphalomesenteric duct presents with a fistula at the umbilicus through which small bowel content is discharged. There may or may not be an associated mucosal remnant at the umbilicus. Surgical management is excision of the entire fistula, the intestinal end of which usually widens into a Meckel's diverticulum.

The umbilical end of the fistula is excised circumferentially. The omphalomesenteric duct is then approached through a sub-umbilical incision. After incising the skin and subcutaneous tissues, these are retracted, and the patent omphalomesenteric duct is identified by blunt dissection. The abdominal wall

fascia is opened transversely on either side of the fistula, or a midline incision may be used. Both umbilical arteries, the single vein and the urachal remnant are ligated and divided. The umbilical end of the fistula is brought out through the sub-umbilical incision. The omphalomesenteric duct is dissected into the peritoneal cavity and its insertion into the terminal ileum is identified, exteriorized through the sub-umbilical incision, and resected as described for excision of a Meckel's diverticulum. The ileum is repaired by end-to-end anastomosis. The umbilical incision is closed using a purse-string suture and the abdominal incision is closed in layers using absorbable sutures.

Figure 30.5

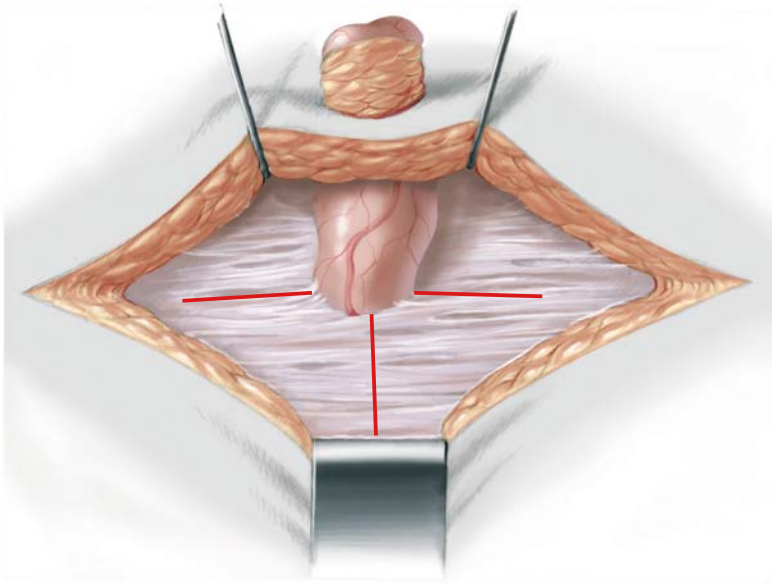
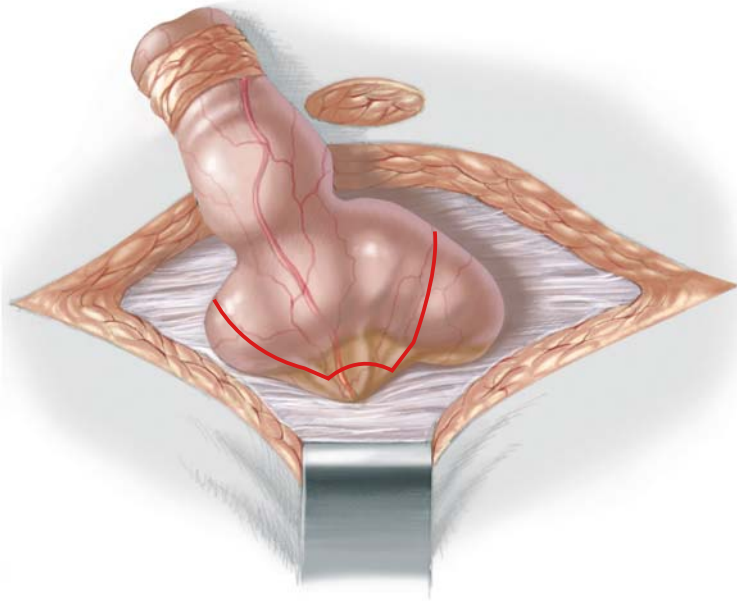


Figure 30.6



CONCLUSION

Post-operative care includes nasogastric tube drainage of the stomach and intravenous fluids are required until normal gastrointestinal function is re-established. Post-operative antibiotics may be given for prophylaxis against wound infection if indicated.

Failure of the viteline duct to regress results in anomalies that may require resection to prevent or

treat complications. The risk of post-operative complications, notably wound infection, is low and the outcome of surgery is excellent. Successful use of a laparoscopic approach for these anomalies has been reported.

SELECTED BIBLIOGRAPHY

Moore C (1996) Omphalomesenteric duct malformations. *Semin Pediatr Surg* 5: 116–123

Swaniker F, Soldes O, Hirschl RB (1999) The utility of technetium 99^m pertechnetate scintigraphy in the evaluation of patients with Meckel's diverticulum. *J Pediatr Surg* 34: 760–764

Teitlebaum DH, Polley TZ, Obeid F (1994) Laparoscopic diagnosis and excision of Meckel's diverticulum. *J Pediatr Surg* 29: 495–497

St Vil D, Brandt ML, Panic S (1991) Meckel's diverticulum in children: a 20 year review. *J Pediatr Surg* 26: 1289–1292

Risto J. Rintala

INTRODUCTION

Approximately 10% of all cases of ulcerative colitis have their onset during childhood. In the Western World the incidence of pediatric ulcerative colitis increased until the 1970s and 1980s but has remained at the same level thereafter. A typical age at the onset of symptoms is prepuberty or puberty. A trend towards earlier appearance of symptoms has been noted recently; some patients develop symptoms as early as their primary school ages.

The aetiology of ulcerative colitis is still unclear; therefore, there is no curative treatment. The medical therapy of ulcerative colitis is based on systemic or local suppression of the immune response of the large bowel. This is best achieved by using acetylsalicylic acid derivatives, and systemic or locally acting corticosteroids.

In children, ulcerative colitis is more aggressive than in adults. Children present more often with widespread disease and develop pancolitis more often than adults. Therefore, children require more aggressive medical treatment than adults; corticosteroids are usually needed to control the initial disease. Systemic corticosteroids are a major concern; the side-effects of high-dose corticosteroid treatment on a growing and developing body are significant and are often an indication for surgical treatment.

Between 40–70% of children with ulcerative colitis undergo surgical treatment. As most patients can be stabilized by medical treatment, emergency operations for toxic megacolon, unremitting bleeding or refractory fulminant colitis are not common today. The typical indications for surgery of ulcerative colitis are poor response to optimal medical treatment, dependence on high-dose corticosteroids with significant side-effects, delay in growth and maturation and severe extra-intestinal manifestations of the disease. Surgery should not be considered as a primary or early treatment of ulcerative colitis. A significant proportion of patients achieve long-term symptom relief with conservative treatment and may remain in remission with minimal or no medication. Moreover, the functional outcome following restorative proctocolectomy is not comparable with normal bowel function. When patients go through several exacerbation phases of the disease they gradually learn to accept that their bowel will function between a few to several times a day. Before proctocolectomy is under-

taken Crohn's disease should be ruled out by every possible measures. Crohn's disease patients should not undergo restorative proctocolectomy

The gold standard of surgery for ulcerative colitis had been proctocolectomy and permanent ileostomy. Limited colonic resections, and colectomy and ileorectal anastomosis have been abandoned because these have been associated with a high incidence of complications and recurrence of the disease. Proctocolectomy and permanent ileostomy gives excellent control of ulcerative colitis and related symptoms, but is not very well tolerated by children and adolescents because of significant social restrictions and permanently altered body image that are related to this operation. Since the late 1970's restorative proctocolectomy with ileoanal anastomosis has gained overall acceptance as the standard operative procedure for adult and also pediatric ulcerative colitis. Many pediatric surgeons advocate use of an ileal reservoir; the most popular and easiest to construct is the J-pouch. Some pediatric surgeons still use straight ileoanal anastomosis without a reservoir.

Restorative proctocolectomy is a major operation with significant incidence of post-operative complications. Septic complications are common as most patients with refractory ulcerative colitis are immunosuppressed because of high-dose corticosteroid treatment. The nutritional status of many patients is often not very good due to long-term diarrhoea and poor nutrient intake. To avoid septic complications it is imperative that systemic corticosteroids are tapered to as low a level as possible, or preferably changed to locally acting budesonide that has less systemic immunosuppressive effects. The nutritional status should also be improved. It is usually possible to do this by dietary measures. Parenteral nutrition is sometimes but rarely required to restore proper nutritional status.

If the patient has chronic diarrhoea, as many of them have, the bowel may be emptied by a simple colonic washout. If the patient does not have diarrhoea a whole-bowel washout with polyethyleneglycol (PEG) solution is advisable. The site of the covering loop ileostomy should be marked with a water-resistant marker pen before the operation. A stoma site in the right lower abdominal quadrant is best determined when the patient is sitting.

Figure 31.1

Prophylactic antibiotic treatment (cefotaxime and metronidazole) is started at the induction of the anaesthesia. The operation is undertaken under general anaesthesia; the use of nitrous oxide as an anaesthetic is best avoided as it may distend the bowel. Insertion of an epidural catheter for local anaesthetic infusion to control post-operative pain is advisable. Additional pain control can be achieved by administering opioids by a PCA (patient controlled analgesia) system. A bladder catheter is inserted and left in place until pain control with opioids and epidural catheter can be discontinued.

The patient is positioned in a lithotomy position with a 10–15° Trendelenburg tilt. The abdomen is prepped from lower chest to perineum. A midline incision starting from the midpoint between the xiphoid process and umbilicus and extending through the umbilicus down to suprapubic region is used to get free access to the whole length of colon. Usually there is no need to use self-retaining wound retractors; they may cause wound edge ischaemia and increase postoperative wound pain. The whole length of the bowel is inspected to rule out Crohn's disease.

Figure 31.2

It is important that the surgeon assesses that the terminal ileum reaches down to perineum before colectomy is started. If the rotation of the bowel is normal and the terminal ileum reaches the pubic bone, it is very likely that an ileoanal anastomosis can be performed without undue tension. After mobilization of ileocecal region, the ileum is transected by a GIA stapler, flush to the ileocecal junction.

Figure 31.3

The peritoneal reflections of the ascending colon and hepatic flexure are mobilized. The splenocolic ligament is severed and splenic flexure mobilized. The greater omentum can be preserved provided it does not tear much during its dissection off from the transverse colon. The dissection of the omentum is best performed by bipolar cautery or scissors; the attachments between transverse colon and omentum are transected flush to the colonic wall. The lateral

peritoneal reflections of the descending and sigmoid are transected. The vessels in the colonic mesentery are ligated or cauterized near the bowel wall; usually only the main arteries to the colon, right, middle and left colic arteries need ligatures. The colon is transected at the junction of the sigmoid and rectum with a GIA stapler. The whole colon can be now removed from the operative field.

Figure 31.1

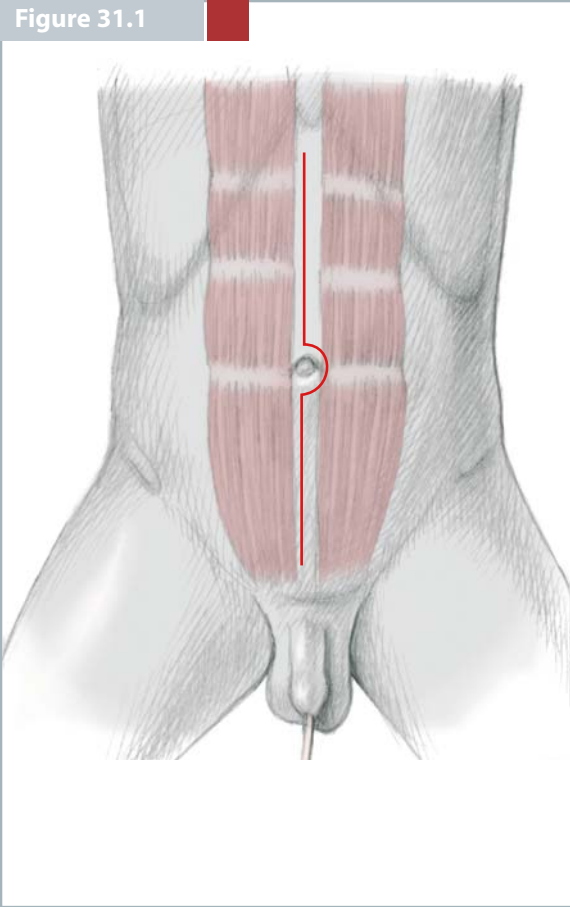


Figure 31.2

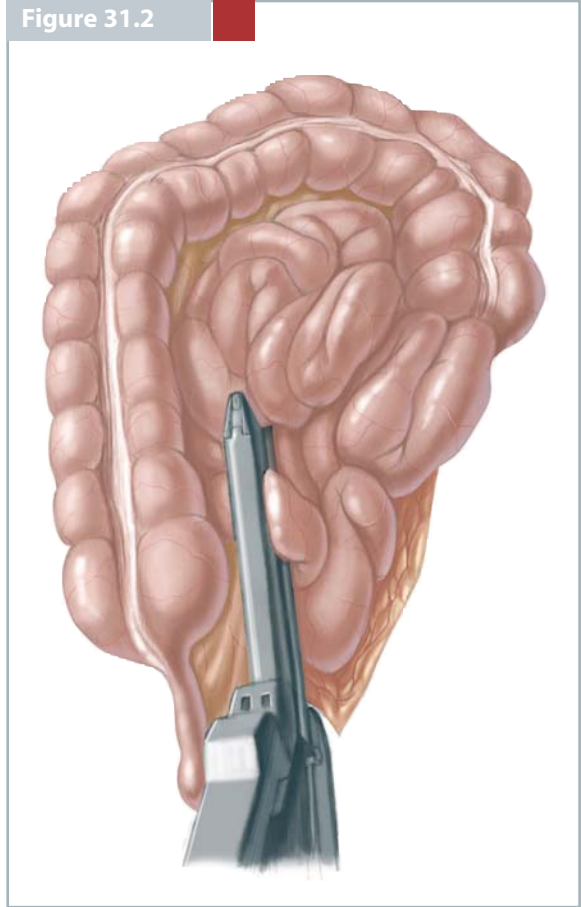


Figure 31.3

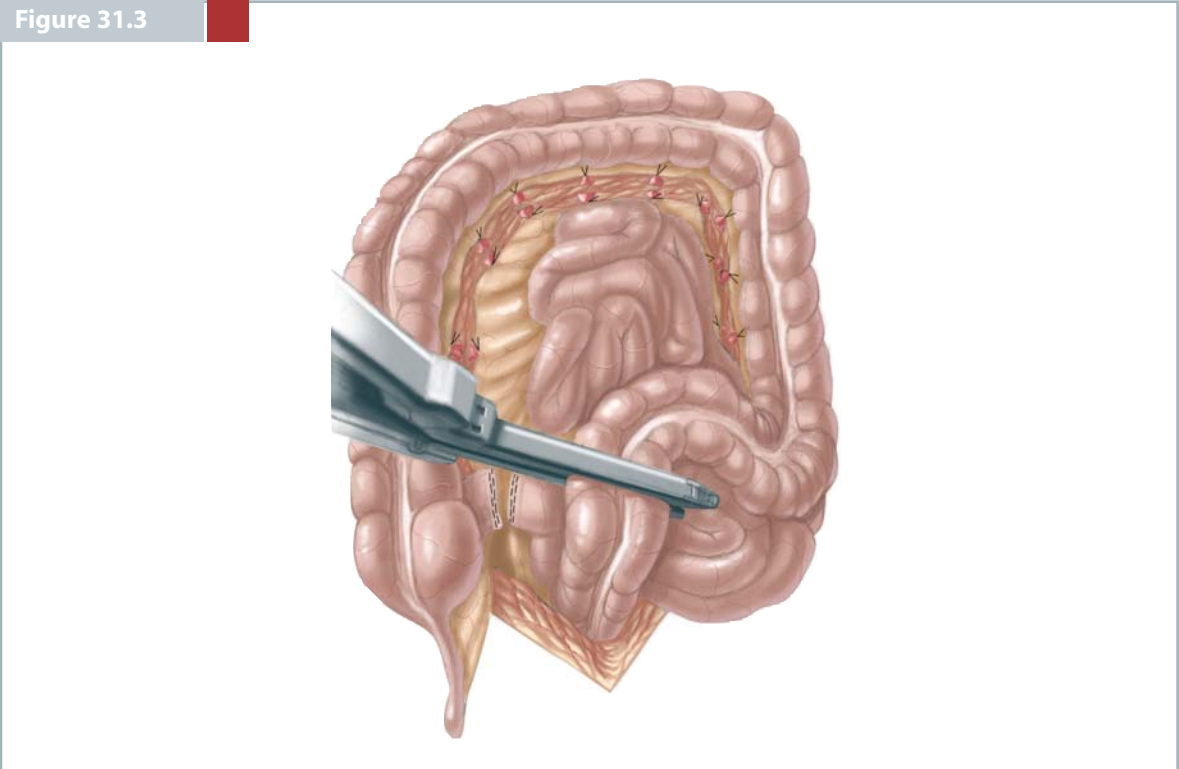


Figure 31.4, 31.5

Stay sutures or a right-angled large clamp on the proximal rectal stump facilitate the dissection of the rectum. These allow the surgeon to pull and move the bowel on either side freely. The mesentery of the rectum in patients with severe ulcerative colitis is often inflamed and very thick. Dissection within the mesentery is time consuming and bloody. The easiest way to proceed is to keep the plane of dissection right on the rectal wall. The small vessels entering the bowel are cauterised flush to the bowel wall. Broad and

long-bladed retractors and cranial pulling from the rectal stump facilitate the dissection.

The dissection is continued down to the level of pelvic floor. Rectal finger-examination is useful to assess the adequacy of abdominal dissection. If the lowest level of abdominal mobilization is within 3–4 cm from the anal verge, no problems are expected in the transanal mucosectomy and rectal pull-through.

Figure 31.4

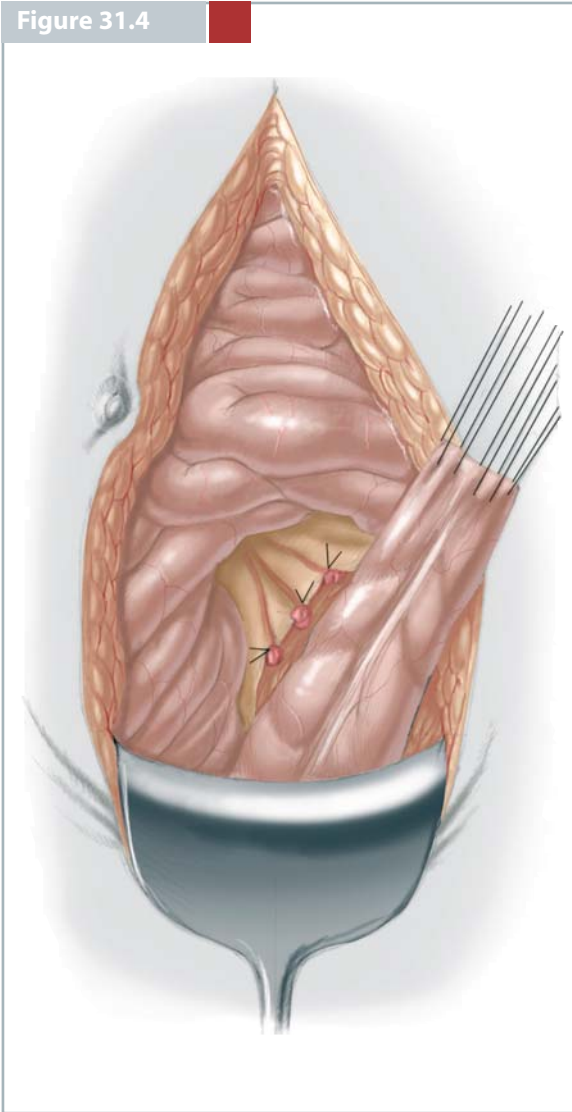


Figure 31.5

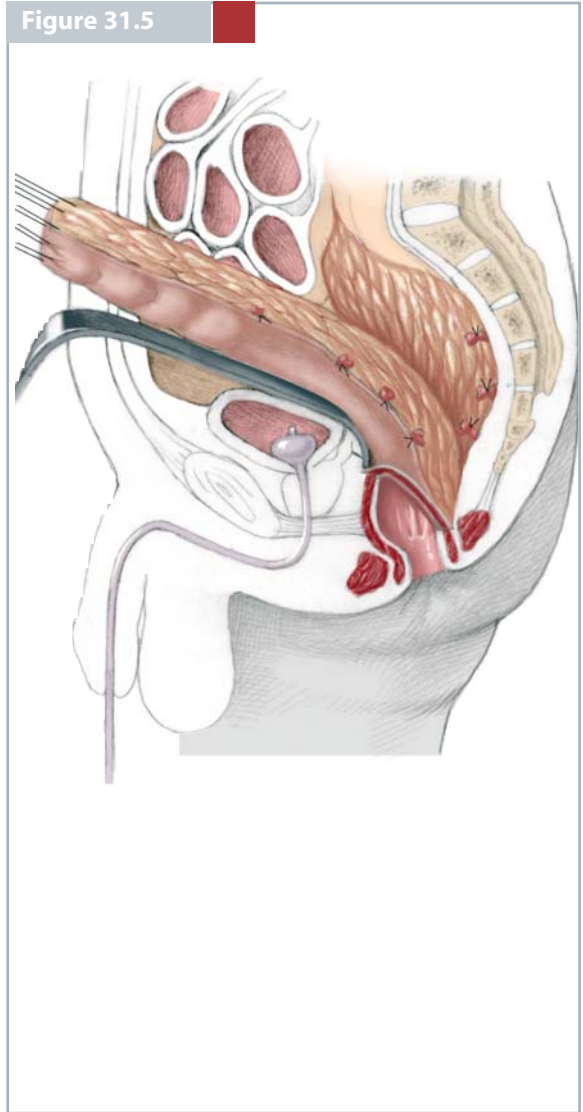


Figure 31.6

The next stage in the operation is the mobilization of the ileum to reach to anal canal. The ileocolic artery is ligated and transected. The mesentery of the ileum is mobilized up to the level of proximal superior mesenteric artery. This may require mobilization of the root of the mesentery from duodenum and lower rim of pancreas. The mesenteric arteries to the distal two or three vascular arcades of the terminal ileum are ligated and transected proximally. In order to ensure tension-free ileoanal anastomosis, the distal end of the ileum or the tip of the J-pouch should reach in front of the pelvic rim to the base of penis in males or anterior vestibulum in females.

Figure 31.7

The length of the J-pouch is between 7–10 cm. The terminal ileum is folded and the antimesenteric tip of the future pouch longitudinally opened with a cautery needle. The opening should be kept short, from 1.5 to 2 cm, as it widens significantly when pulled through to the anus. The GIA-stapler blades are inserted into each arm of the pouch; the stapler is closed and fired. One firing of a 75-mm stapler, or two of a 50-mm stapler, is usually sufficient to construct a pouch. The stapled suture line can be reinforced with 4/0 or 5/0 absorbable sutures. The pouch and terminal ileum are wrapped in warm and moist swabs and returned the abdomen. The abdominal incision is loosely packed with warm and moist swabs.

Figure 31.6

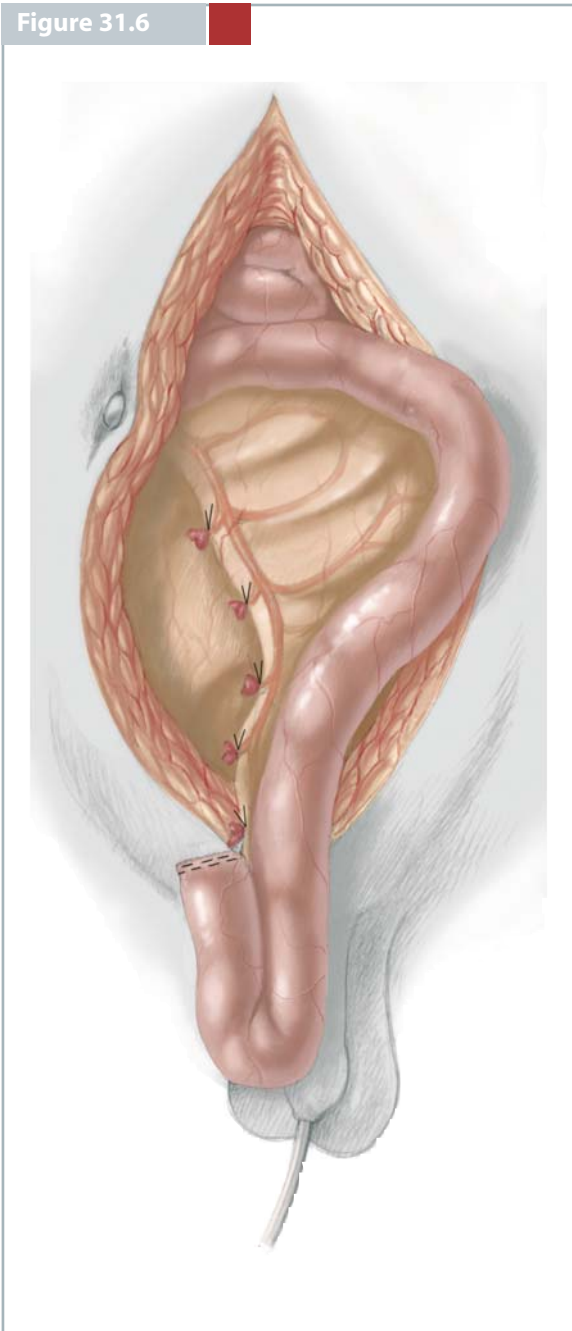


Figure 31.7

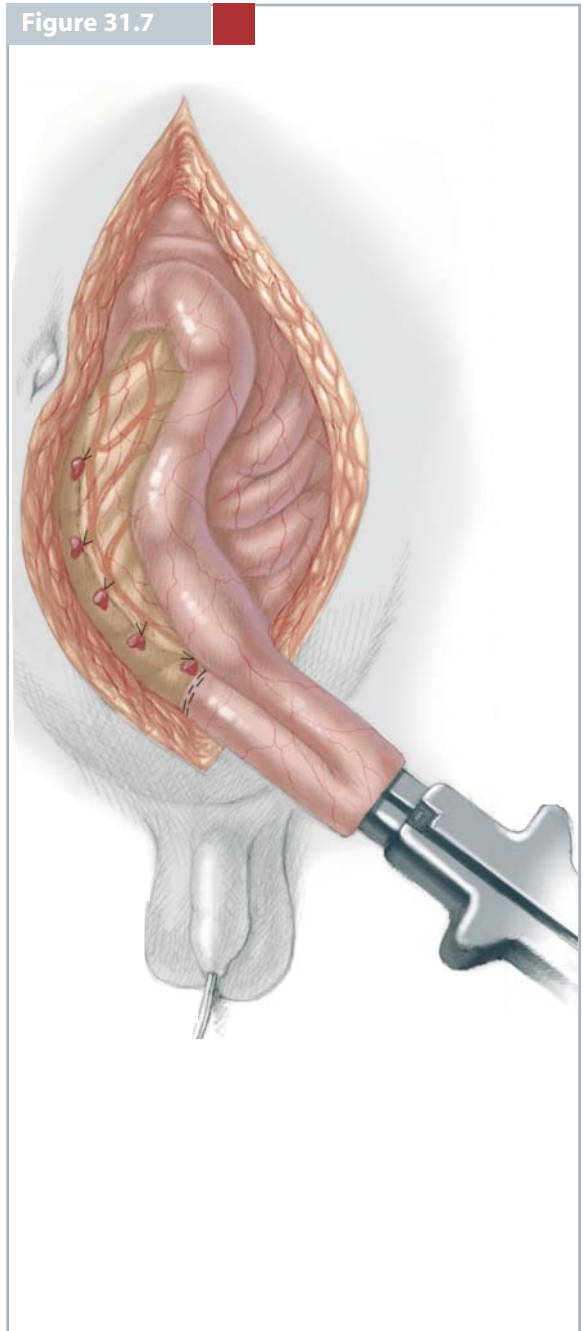


Figure 31.8

The perineal phase of the operation starts by insertion of holding stitches between the mucocutaneous junction of the anal canal and a colostomy ring. These keep the anus open and dilated, and give excel-

lent access to the anal canal. Adrenaline in saline (1:100,000) is injected under the mucosa to lift it up and decrease bleeding during the initial phases of transanal mucosectomy.

Figure 31.9, 31.10

The transanal mucosectomy is started at the dentate line. A small rim (5–6 mm) of anal transitional epithelium should be left in situ, otherwise the sensibility of the anus is significantly decreased and the anal sampling reflex may be lost. Disease recurrence in the transitional anal epithelium is unlikely. The whole circumference of the anal canal mucosa is incised and the mucosectomy started. The *red line* in Fig. 9 depicts the line of dissection between the mucosa and rectal muscle. Some surgeons prefer to use multiple stay sutures in the mucosa just above the level of the mucosal incision to facilitate mucosecto-

my. The author uses small triangular clamps to grasp the edge of the mucosal cuff. The mucosectomy is performed by a combination of sharp and blunt dissection with scissors. In colitis ulcerosa, the mucosectomy is much more difficult than in non-inflammatory conditions; blood loss is often also significant. Pre-operative treatment with locally acting cortisone foam or suppositories may decrease blood loss and make the dissection easier. The mucosectomy is continued for 5–8 cm until the level above pelvic floor is reached.

Figure 31.8

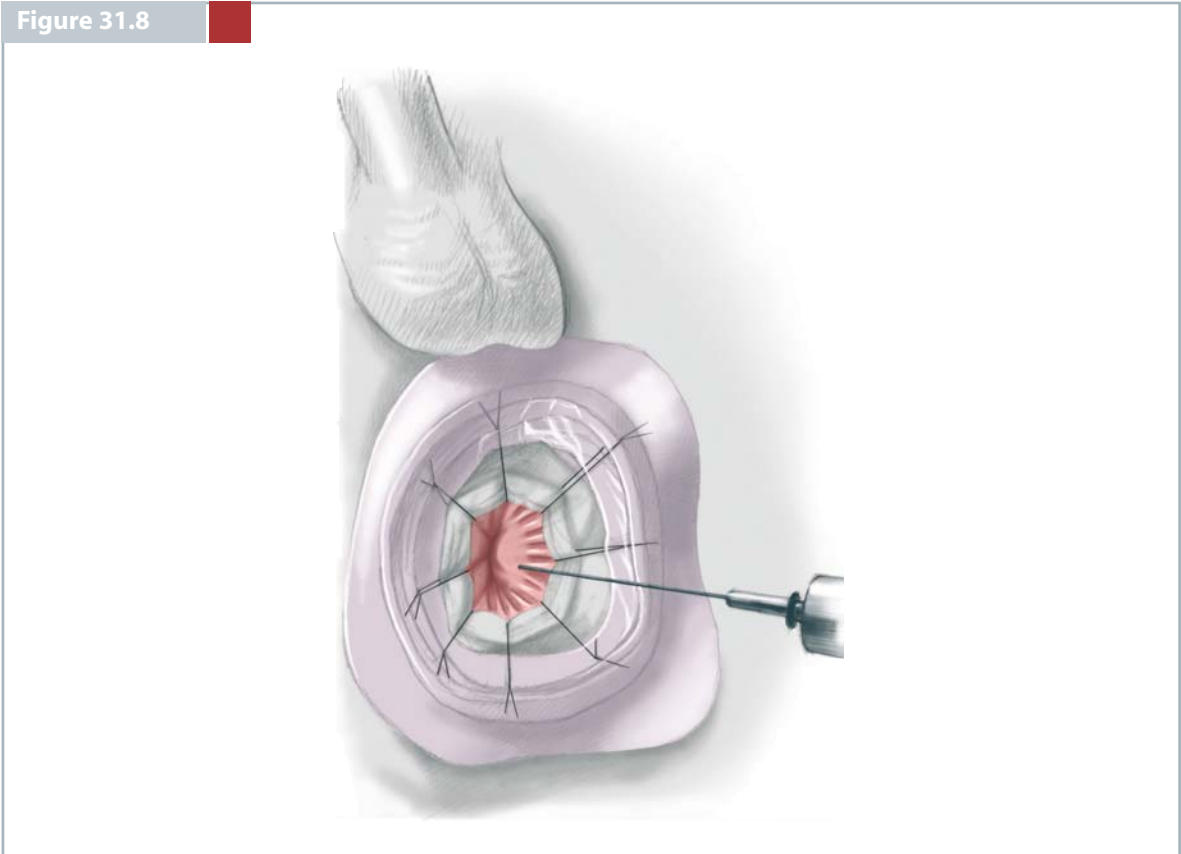


Figure 31.9

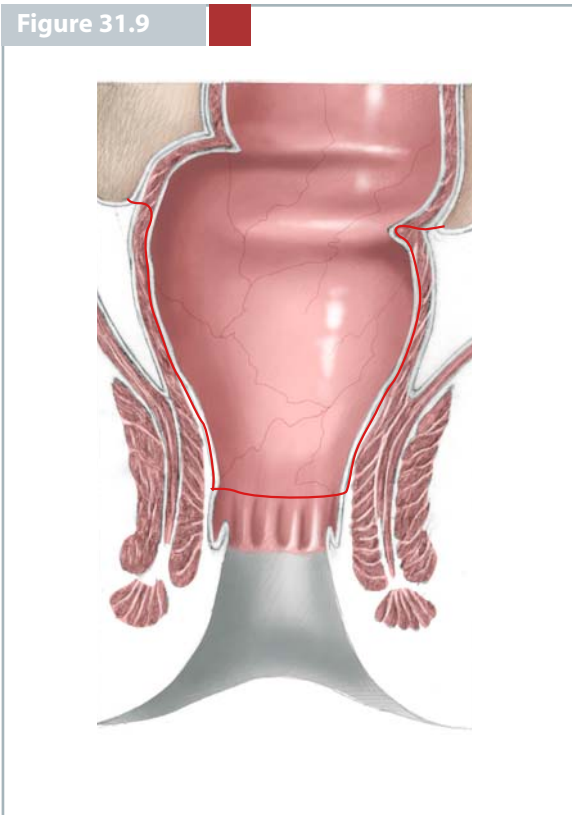


Figure 31.10

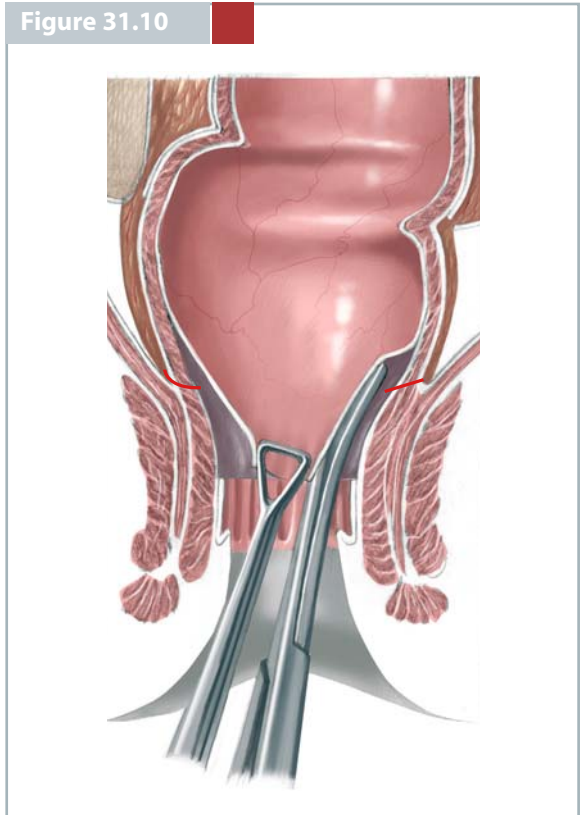


Figure 31.11, 31.12

The cuff consisting of muscular lining of the anal canal and distal rectum can be transected transanally when the pelvic cavity is entered at the upper end of the mucosectomy. Pulling from the mucosal tube tents the proximal end of muscular cuff inside the more distal cuff; thus, the cuff can be safely transected without damaging urethra and prostate. Another option is to evert the rectum through anus and sever the muscular cuff outside the anus at the upper end of mucosectomy. Bleeding from small vessels in the cuff can be controlled by cautery.

A long soft clamp is inserted through the anal muscular cuff to pelvis. The J-pouch (or distal ileum

in case of straight pull-through) is grasped with the clamp and pulled through to the anus. The assistant confirms through the laparotomy incision that the mesentery of the pulled-through pouch is not twisted. The mesentery of the pulled-through J-pouch (or distal ileum) is the tightest component of the pulled-through segment and requires the shortest route. Therefore, it is natural that in the pelvis the mesentery is positioned anteriorly to the bowel; this does not mean that the pull-through segment would be kinked.

Figure 31.11

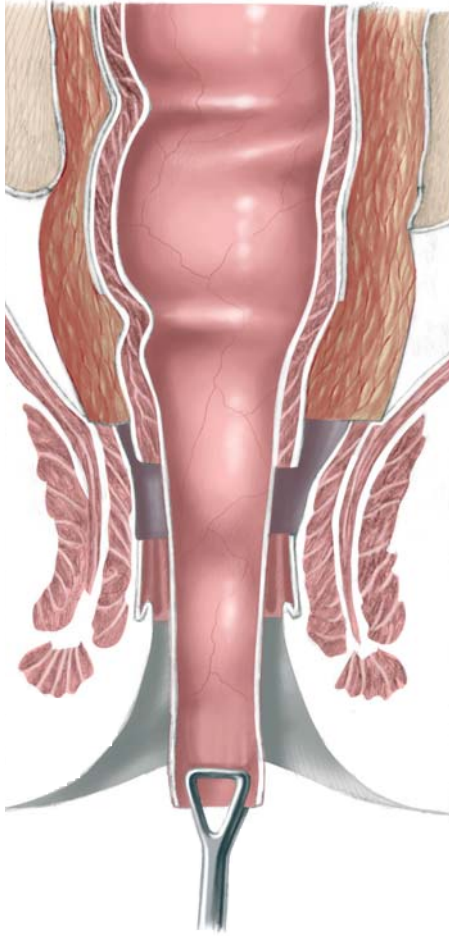


Figure 31.12

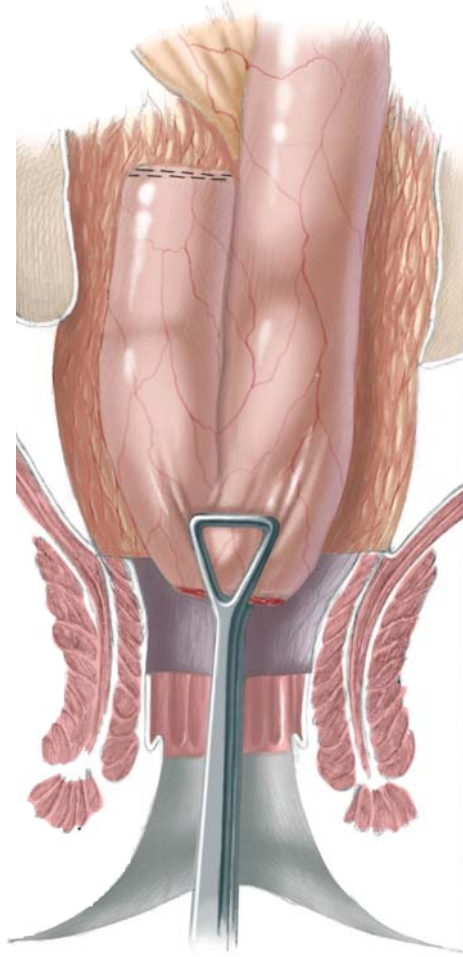


Figure 31.13

As there is often significant tension when the first anastomotic stitches are inserted, it is advisable to use four-quadrant holding stitches to initiate the suturing of the anastomosis. The anastomosis is performed in one layer with interrupted sutures between full-thickness ileum and anal canal. A suitable material is absorbable 4/0 sutures. The tension in the suture line is usually relieved when the sutures between the anus and the stoma ring are cut. This allows the suture line to retract within the anal canal.

Figure 31.14

The space between pulled-through bowel and posterior peritoneum is closed with running 4/0 absorbable sutures. The pelvic cavity is inspected for bleeding sites. A round skin disk is cut off the stoma site. A cruciate incision is made to the abdominal muscle fascia at the site of the stoma. The opening in the fascia and abdominal muscles are bluntly enlarged to accommodate two fingers. An opening is made in the anterior peritoneum and a loop of ileum as near as possible to the ileoanal anastomosis is pulled out for stoma formation. The abdominal incision is closed in layers and the stoma is matured over a stoma rod. Generally there is no need to drain the pelvic cavity.

Post-operative gastric decompression by nasogastric tube is usually not required. The bladder catheter can be removed when epidural anaesthesia is discontinued. Antibiotic prophylaxis is continued for 72 h post-operatively. If the patient has been on high-dose corticosteroids pre-operatively, post-operative parenteral corticosteroid therapy is required until oral intake of medication is possible. Post-operative corticosteroids can be discontinued when sufficient function of patient's own adrenal glands is confirmed by an ACTH-stimulation test.

Enteral feeding is encouraged and most patients tolerate full enteral feeding within the first 5 post-operative days. Stoma output is often excessive and should be replaced according to output and electrolyte content of the stoma fluid. In most cases Ringer's lactate is sufficient for replacement. Oral sodium supplementation to decrease stoma output is started as soon as the patient tolerates intake of salt tablets.

Post-operative dietary management consists of lactose-free low residue diet. The amount of sodium supplementation can be monitored by spot urinary sodium measurements. The urinary sodium concentration should be kept higher than 20 mmol/l. Insufficient salt intake leads to increased and watery stoma output.

The covering stoma can be taken down when the healing of the pouch and the ileoanal anastomosis is confirmed. A distal loopogram 3–6 weeks after the operation is used to assess the integrity of the ileoanal anastomosis and J-pouch. The immediate post-operative phase is characterized by loose and frequent bowel movements up to 10–12 times per 24 h. Antipropulsive medication (loperamide) is useful in slowing down gut motility. The bowel frequency gradually decreases to 2–7 bowel movements per 24 h within 3–6 months. Low residue diet and salt supplementation are helpful during the adaptation phase.

Figure 31.13

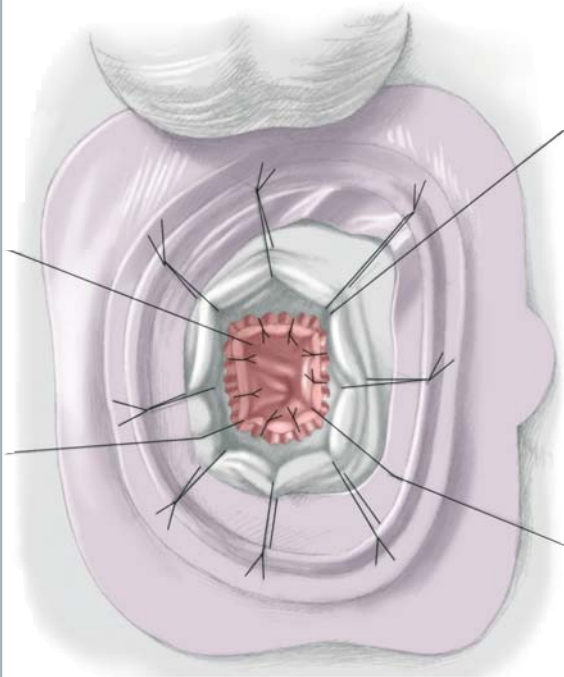
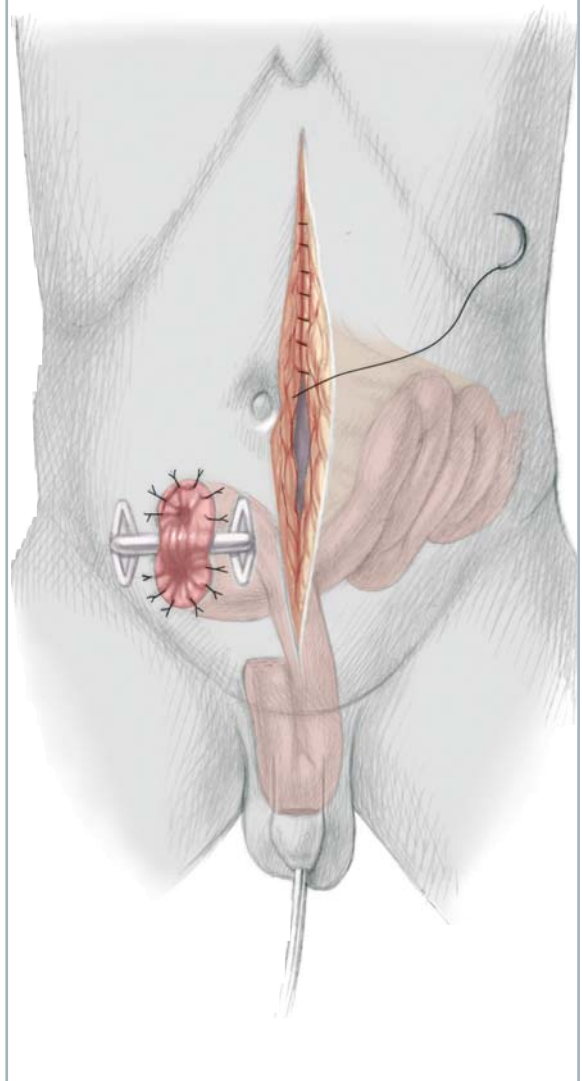


Figure 31.14



CONCLUSION

Ileoanal anastomosis has revolutionized the treatment of ulcerative colitis also in children. Long-term patient satisfaction following the operation is excellent despite a high incidence of post-operative complications. In children with a pouch ileoanal anastomosis, the functional outcome in terms of fecal continence is good. Usually all patients resume full daytime faecal continence within 6 months following closure of the stoma. A few patients suffer from slight night-time staining that may require protective pads. In the absence of major post-operative complications, gross faecal soiling is practically nonexistent. The frequency of bowel movements 6–12 months post-operatively is between two and seven times per 24 h. In the series of Children's Hospital, University of Helsinki, the median bowel frequency 6 months post-operatively is four, ranging from two to seven per 24 h.

Early and late complications occur in 20–50% of patients; most common are wound infections in patients who have been using high-dose corticosteroids prior to the operation, and bowel obstructions. Pelvic septic complications or separation of the ileoanal anastomosis occur in less than 10% of the cases. Acute or

chronic inflammation in the pouch (pouchitis) is an innate problem related to ileoanal pull-through for ulcerative colitis. Its incidence varies between 20% and 50% of the patients. Most acute bouts of pouchitis respond rapidly to a short course of oral antibiotics, for example metronidazole. Chronic pouchitis is much less common and occurs in less than 10% of the patients. The treatment of chronic pouchitis consists of long courses of low-dose antibiotics and in recalcitrant cases oral corticosteroids, preferably budesonide. Chronic pouchitis may be a presentation of Crohn's disease; eventually 5–15% of patients who have undergone ileoanal anastomosis for ulcerative colitis are discovered to have Crohn's disease. Another symptom that should raise suspicion of Crohn's disease is pouch fistulization, especially recurrent fistulas.

Despite the multitude of potential post-operative problems, a great majority of patients who have had restorative proctocolectomy for ulcerative colitis resume highly satisfactory lifestyle with complete faecal continence and acceptable frequency of daily bowel movements.

SELECTED BIBLIOGRAPHY

- Coran AG (1990) A personal experience with 100 consecutive total colectomies and straight ileoanal endorectal pull-throughs for benign disease of the colon and rectum in children and adults. *Ann Surg* 212: 242–248
- Durno C, Sherman P, Harris K et al (1998) Outcome after ileoanal anastomosis in pediatric with ulcerative colitis. *J Pediatr Gastroenterol Nutr* 27: 501–507
- Rintala RJ, Lindahl H (1996) Restorative proctocolectomy for ulcerative colitis in children – is the J-pouch better than straight pull-through. *J Pediatr Surg* 31: 530–533
- Sawczenko A, Sandhu BK (2003) Presenting features of inflammatory bowel disease in Great Britain and Ireland. *Arch Dis Child* 88: 995–1000
- Stavlo PL, Libsch KD, Rodeberg DA et al (2003) Pediatric ileal pouch – anal anastomosis: functional outcomes and quality of life. *J Pediatr Surg* 38: 935–939

Risto J. Rintala

INTRODUCTION

The incidence of Crohn's disease in children has clearly been increasing since 1970s. The age at onset of the disease is similar to that of ulcerative colitis; however, patients with Crohn's disease tend to be younger than those with ulcerative colitis. The diagnostic delay in Crohn's disease is usually significantly longer than in ulcerative colitis, usually longer than 1 year from the onset of symptoms. The symptoms are usually relatively vague at the early stages of disease. The most common symptom is non-specific abdominal pain. General symptoms are more common in patients with Crohn's disease. Growth failure and delay of sexual maturation are significantly more common in Crohn's disease patients than in those with ulcerative colitis. The presentation of Crohn's disease in children is usually less localized than in adults.

As in ulcerative colitis the aetiology of Crohn's disease is unclear. It is likely that a genetic preponderance exists for Crohn's disease since Crohn's patients have family history of the disease more commonly than those with ulcerative colitis. There is no definitive curative treatment for Crohn's disease. As Crohn's disease is an affliction of the whole gastrointestinal tract surgery does not offer any permanent cure. Unlike in ulcerative colitis, surgical treatment is palliative in nature and aimed at treating the complications of the disease.

The medical treatment of Crohn's disease has evolved significantly during the last decade. The mainstay of medical management is immunosuppression. The modality of medical management is different in different localisations of the disease. Generally speaking, the more widespread and more distal in the bowel the disease activity is, the more an aggressive medical management is required. Predominantly, ileal disease can be managed with corticosteroids, preferably with locally acting budesonide, and aminosalicylates. Colonic involvement requires often antibiotics such as metronidazole or ciprofloxacin in addition to the regimen used for ileal disease. Exacerbations, relapses or refractory Crohn's disease require more effective medication; azathioprine or cyclosporin is often helpful in inducing remission. Novel biological immunomodulatory drugs, tumour ne-

crisis factor- α antibodies (infliximab), have been adopted for management of fistulizing and refractory Crohn's disease. Internal and severe rectoperineal fistulas respond well to infliximab therapy and most patients resume a longer period of remission. Similar results have been reported in patients who have disease refractory to conventional medication. However, long-term efficacy and safety of biological treatment of Crohn's disease still remains unclear.

It is evident that the development of drug therapies has reduced the need for surgical therapy for Crohn's disease. The indications for surgery are limited to cases that are refractory to medical therapy or medical therapy that is poorly tolerated. Acute indications include medically unmanageable toxic megacolon or acute bleeding, both of which are rare. Subacute or chronic conditions that may require surgery include refractory strictures, internal or external fistula and intra-abdominal abscesses.

The main principle in the surgical treatment of Crohn's disease is to save bowel length. Resection should be limited to the segment of bowel that is causing symptoms. Isolated skip lesions are left alone if they do not cause obstruction. In case of internal fistulization, the fistula usually originates from the diseased proximal segment; distal target bowel is usually healthy except for the fistula site. The strategy in these cases is to resect the diseased proximal bowel and close the distal fistula site. In adults strictureplasty has been shown to be an effective bowel saving surgical method for multiple fibrotic stenoses. The long-term outcome in terms of disease activity, risk of recurrence and quality of life has been very similar than following resectional surgery. There are only a few reports of strictureplasty for Crohn's disease in children but the preliminary results are similar as in adults.

Major bowel resections are sometimes required in association with severe and widespread colonic disease. In these cases the rectum should be spared. Ileoanal anastomosis with or without a pouch is not indicated for Crohn's disease; long-term outcome is very unpredictable and often poor and, moreover, pouch complications are very common.

Figure 32.1, 32.2

The most often needed surgical procedure is the resection of a localised stricture. The resection margin to healthy bowel does not need to be longer than a few centimetres. Anastomosis is performed with an absorbable suture material and one-layer interrupted stitches.

Figure 32.1

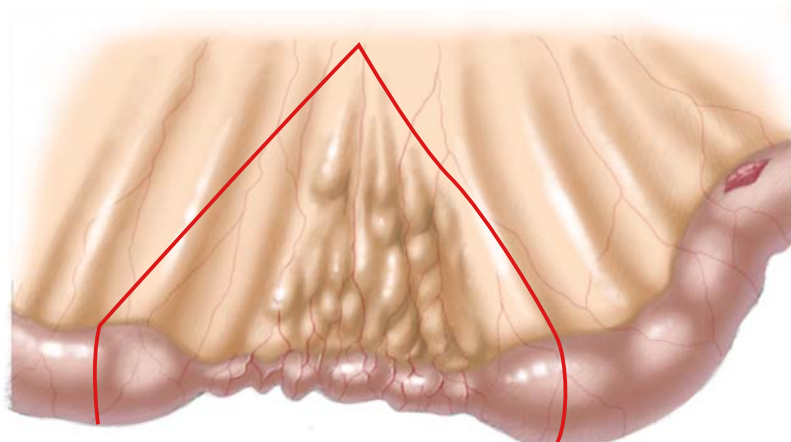


Figure 32.2

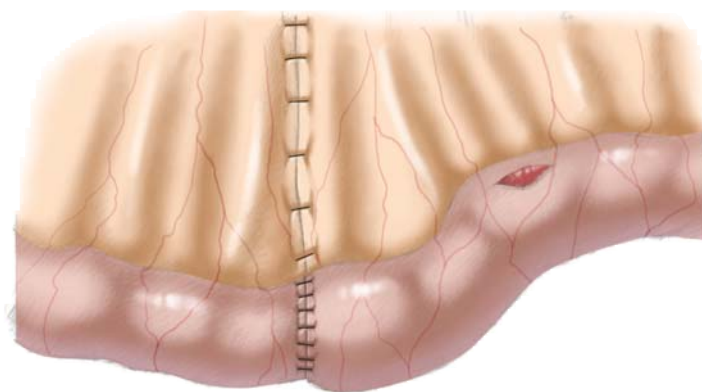


Figure 32.3, 32.4

In children, an internal fistula is often between ileum and sigmoid bowel. The ileum is usually affected by the disease and sigmoid healthy except the fistula site. Proximal disease segment is resected with primary anastomosis and the distal fistula opening excised and closed with interrupted sutures.

Figure 32.3

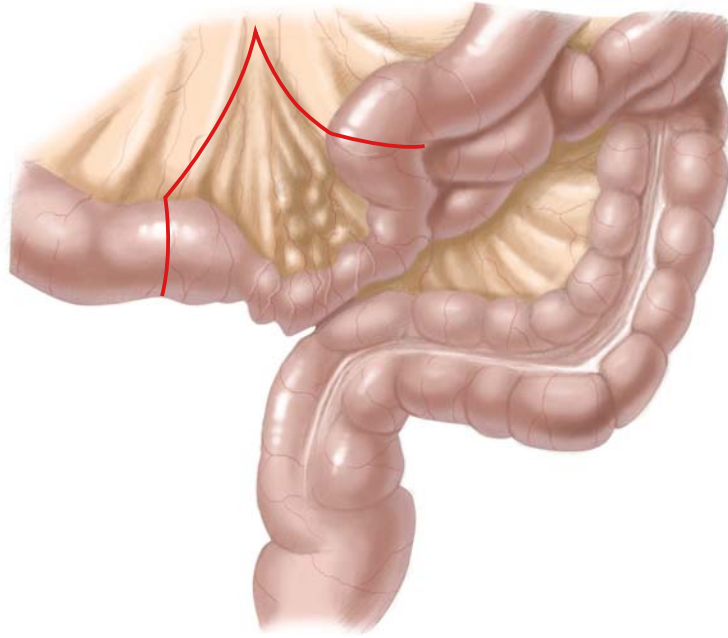


Figure 32.4

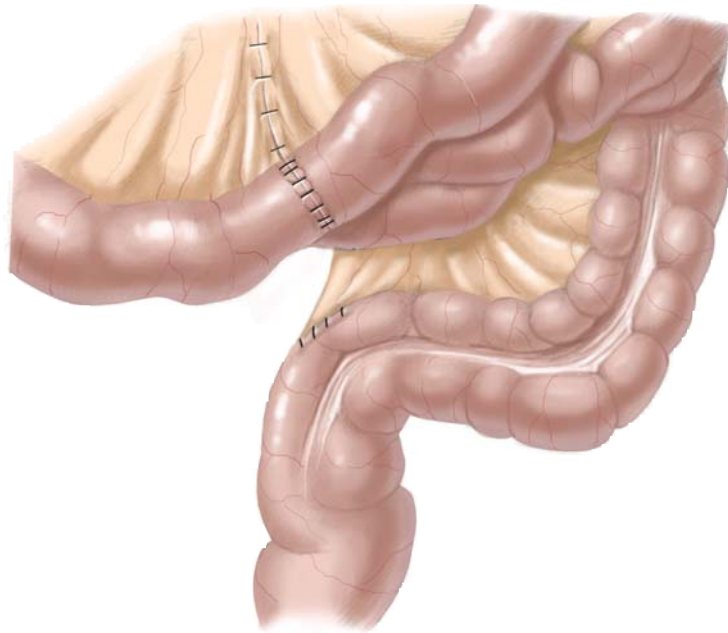


Figure 32.5, 32.6

Strictureplasty for multiple short jejunoileal strictures. Strictureplasty can be combined with resection of longer stricture segments. The stricture site is opened longitudinally so that the incision extends to

the macroscopically healthy bowel. The longitudinal opening is closed transversely with interrupted sutures.

Figure 32.5

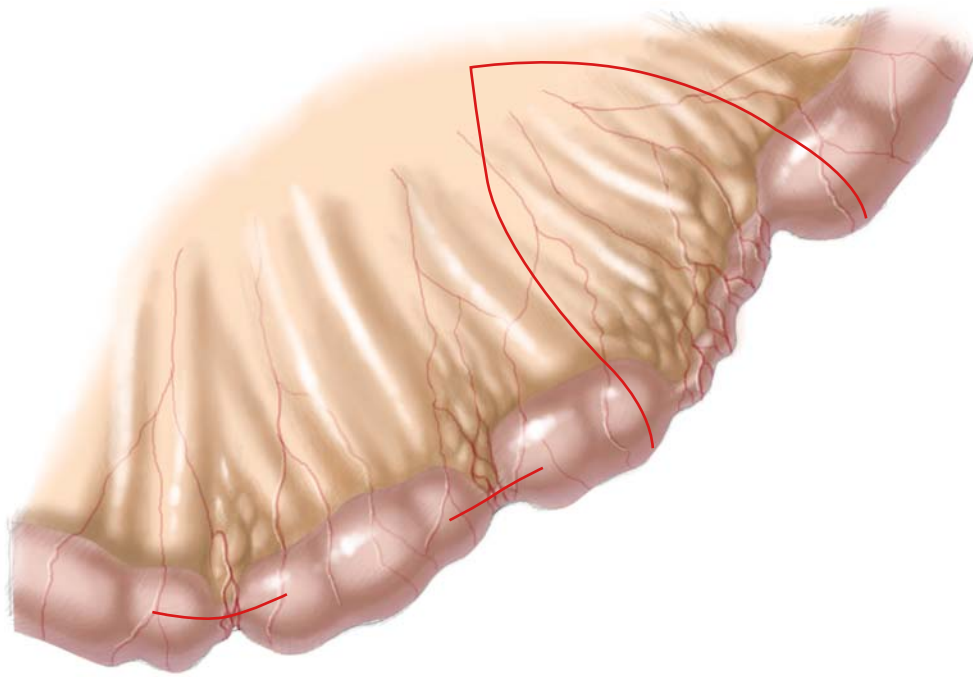
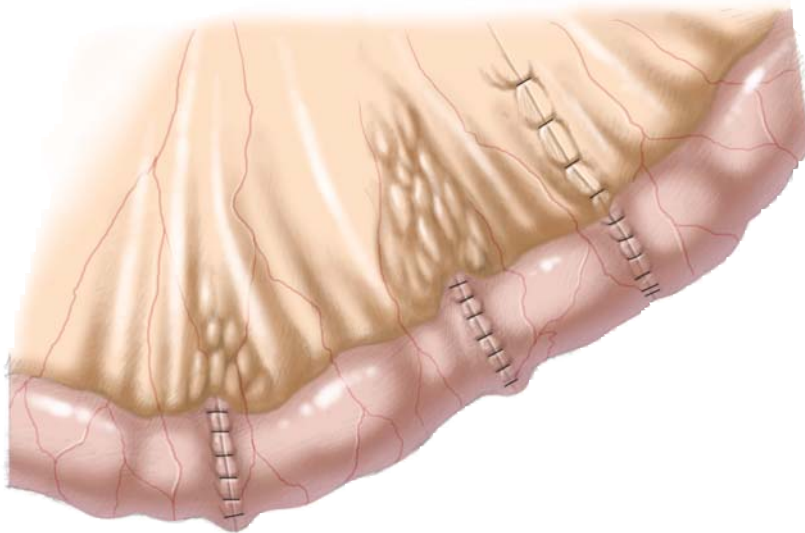

Figure 32.6



CONCLUSION

Operative treatment of Crohn's disease is aimed at management of complications of the disease that are refractory to medical treatment. Although permanent cure cannot be expected following surgery, many patients resume longer periods of full remission with a normal lifestyle. Proper surgical treatment in selected patients can also decrease or even abolish the need for immunosuppressive and potentially harmful medication for months and years.

Perianal manifestations of Crohn's disease are very common in children. These include skin tags, fissures and fistulas. In most cases perianal manifestations cause mild symptoms or are asymptomatic. A

conservative approach is warranted and surgical treatment should be considered only in severely symptomatic high rectoperineal or rectovaginal fistulas that do not respond to infliximab or increased immunosuppressive therapy. If surgery is required for a high perianal fistula resection of the mostly diseased usually left colonic segment and temporary bowel diversion may increase the success rate of the fistula repair. In very severe perianal disease, especially if it is associated with severe rectal manifestation, proctectomy may be the only possibility to guarantee a reasonable quality of life.

SELECTED BIBLIOGRAPHY

- Baldassano RN, Han PD, Jeshion WC, Berlin JA, Piccoli DA, Lautenbach E, Mick R, Lichtenstein GR (2001) Pediatric Crohn's disease: risk factors for postoperative recurrence. *Am J Gastroenterol* 96: 2169–2176
- Besnard M, Jaby O, Mougnot JF, Ferkdadji L, Debrun A, Faure C, Delagausie P, Peuchmaur M, Aigrain Y, Navarro J, Cezard JP (1998) Postoperative outcome of Crohn's disease in 30 children. *Gut* 43: 634–638
- Escher JC, Taminiau JA, Nieuwenhuis EE et al (2003) Treatment of inflammatory bowel disease in childhood: best available evidence. *Inflamm Bowel Dis* 9: 35–58
- Kim S, Ferry G (2002) Inflammatory bowel diseases in children. *Curr Probl Pediatr Adolesc Health Care* 32: 108–132
- Patel HI, Leichtner AM, Colodny AH, Shamberger RC (1997) Surgery for Crohn's disease in infants and children. *J Pediatr Surg* 32: 1063–1067

Liver, Pancreas and Spleen

INTRODUCTION

Biliary atresia still remains one of the most intractable gastrointestinal surgical diseases in infancy. The introduction of liver transplantation has revolutionized the protocols for the treatment of this condition, but hepatic portoenterostomy, e.g., the Kasai procedure, is still the first-choice surgical treatment.

The main clinical manifestations of biliary atresia are persistent jaundice, clay-coloured faeces and hepatomegaly. Although symptoms do not show a great difference, anatomical findings in the biliary tract vary from case to case. Only about 10 to 20% of the patients with biliary atresia have an extrahepatic bile duct large enough to perform a mucosa-to-mucosa anastomosis to the intestine. These correctable-type cases can undergo hepatico-enterostomy. The remaining patients, about 85 to 90%, do not have any bile duct amenable to a conventional anastomosis. For these non-correctable types of patient, hepatic portoenterostomy should be performed.

Hepatic porto-enterostomy was first devised in 1957 as a corrective operation for patients with a non-correctable type of biliary atresia. The basis of this procedure is that the intrahepatic bile ducts are patent in early infancy and minute intrahepatic bile ducts are present in the cone-shaped fibrous tissue, replacing extrahepatic biliary radicles. In hepatic portojejunostomy, the extrahepatic bile ducts, including fibrous remnants at the porta hepatis, are totally removed and bile drainage established by anastomosis of an intestinal conduit to the transected surface at the porta hepatis. Microscopic biliary structures at the liver hilus drain bile into the intestinal conduit and, in time, an autoapproximation

between the intestinal and ductal epithelial elements occurs.

Successful hepatic portoenterostomy depends on early diagnosis and operation (preferably before 60 days of age), adequate operative technique, prevention of post-operative cholangitis, and precise post-operative management.

Post-operative cholangitis is the most frequent and serious post-operative complication, resulting in fatal septicemia or re-obliteration of hepatic portoenterostomy. Although various modified reconstruction procedures for prevention of cholangitis exist, the authors now perform a double-valved (spur valve and intussuscepted valve) hepatic portojejunostomy. The incidence of cholangitis, however, remains almost the same as the original Kasai procedure using a long Roux-en-Y anastomosis with a length of the limb from 50 to 70 cm. As late complications, liver cirrhosis and portal hypertension and/or hypersplenism have been documented. It has been shown that both a late operation and complication of cholangitis aggravate hepatic fibrosis and induce portal hypertension.

As to pre-operative management, in addition to the routine pre-operative care for abdominal surgery, vitamin K, 1~2 mg/kg per day, is usually given for several days before surgery. The bowel is prepared with tobramycin sulfate and metronidazole orally, at a dose of 10 mg/kg per day, each starting 36 h before operation. Early discontinuation of oral feeding and enema are properly enforced. Blood is cross-matched, and pre-operative broad-spectrum antibiotics are administered.

Figure 33.1

The operation is undertaken under general anaesthesia with tracheal intubation. The patient is placed in the supine position. A pillow is put under the back of the patient for better exposure. A laparotomy is performed through an right subcostal incision from the

costal margin to the medial border of the left rectus muscle. Some pediatric surgeons recommend mobilizing and completely exposing the liver to allow adequate visualization of the porta hepatis.

Figure 33.2

A liver biopsy is taken. A catheter is inserted into the small gallbladder to take a cholangiogram. After the occlusion of the extrahepatic bile duct is confirmed by cholangiography, the gallbladder is freed from the liver and dissection is advanced along with the cystic duct toward the common hepatic duct. The dissection is helped by the use of binocular loupes.

A superficial peritoneum on the hepatoduodenal ligament is opened and the anatomy of the involved bile duct and the hepatic arteries is assessed. Dilated lymphatic channels around the hepatoduodenal ligament should be carefully ligated and divided to avoid excessive lymphatic fluid loss. The common bile duct remnant is carefully dissected, since it is often adherent to the surrounding tissues.

Figure 33.1

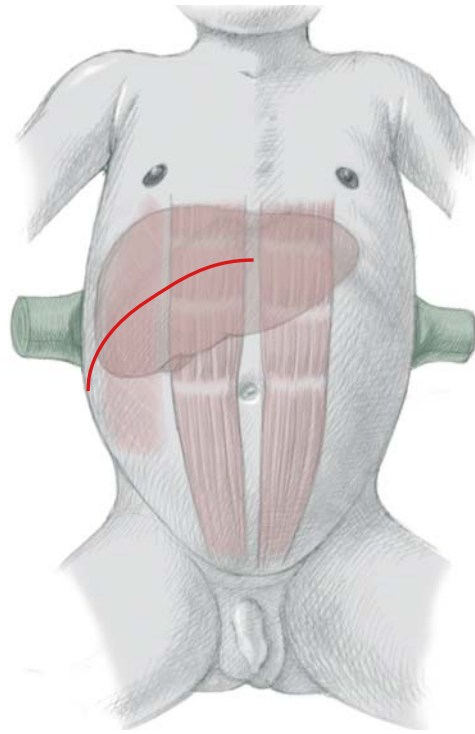


Figure 33.2

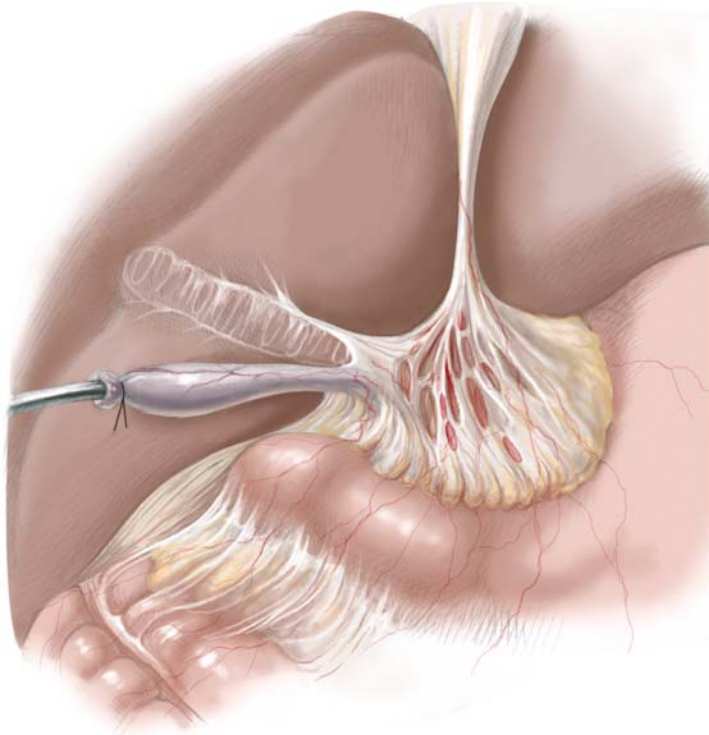


Figure 33.3, 33.4

The common bile duct is clamped and divided adjacent to the duodenum. After the common bile duct is severed, it is pulled up and the hepatic duct remnant is freed from underlying hepatic arteries and the portal vein. The hepatic duct usually transforms into a cone-shaped fibrous tissue, which is situated cranial to the bifurcation of the portal vein. It continues to the portal tracts in the liver. Even if a cyst-like structure is present, it should be removed and should not be used for anastomosis to the intestine.

The separation of the fibrous remnants from the right and left portal veins is carefully advanced posteriorly. The bifurcation of the right and left portal veins must be retracted to obtain proper exposure of the porta hepatis. Several small branches bridging from the portal vein to the fibrous remnants are identified and divided between ligatures, facilitating downward displacement of the portal vein. The posterior aspect of the fibrous remnants is exposed deep and wide enough behind the bifurcation of the portal vein.

Figure 33.3

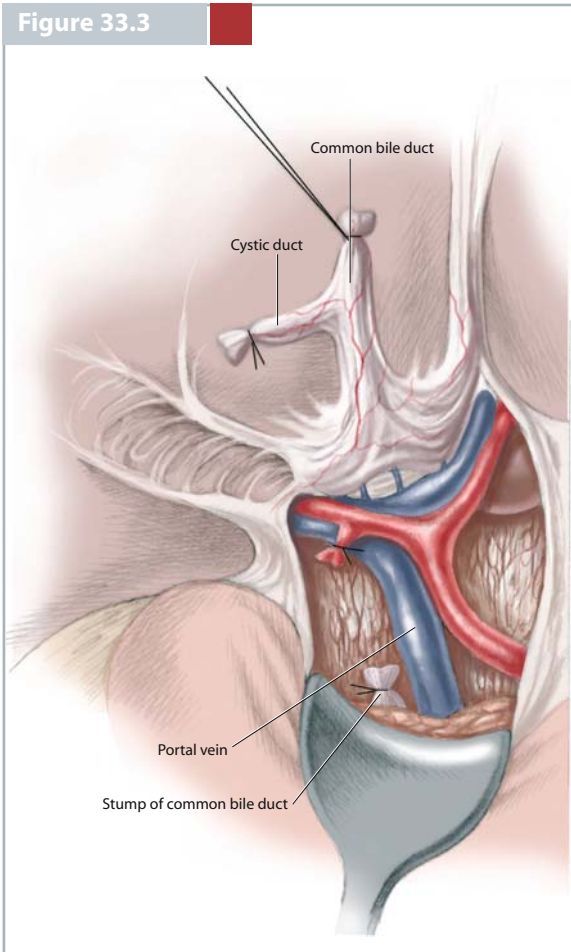


Figure 33.4

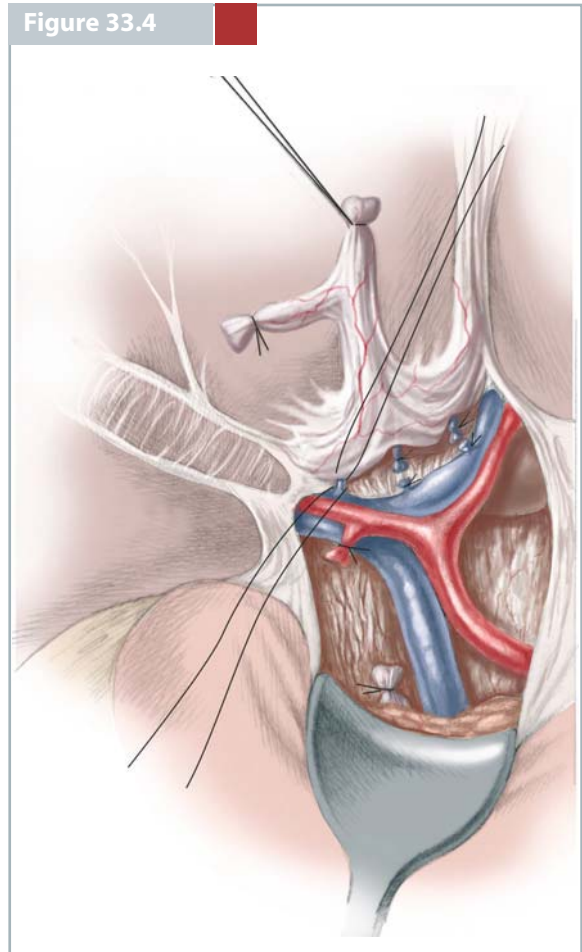


Figure 33.5

The dissection between the anterior aspect of the fibrous remnants and the quadrate lobe of the liver is also sharply and sufficiently advanced. The dissection of the fibrous remnants must be accomplished as widely as possible, i.e., to 5 to 6 mm proximal of the anterior branch of the right hepatic artery at the right side and to the umbilical point of the left portal vein at the left side.

Figure 33.6

The transection of the fibrous remnants is carefully carried out by the use of small-sized round-shaped scissors or a sharp knife at the level of the posterior surface of the portal vein. Although some surgeons confirm the presence of microscopically patent ducts at the level of anastomosis by using frozen sections during surgery, the authors do not use frozen-section guidance because they always transect the portal bile duct remnants at the same level. Haemorrhage from the cut surface of the porta hepatis is occasionally considerable. Irrigation with warm saline stops the bleeding, usually within 10 min. Ligation or cautery should not be applied because of the possibility of accidental obliteration of small bile ducts that may be opening on the transected surface.

Figure 33.5

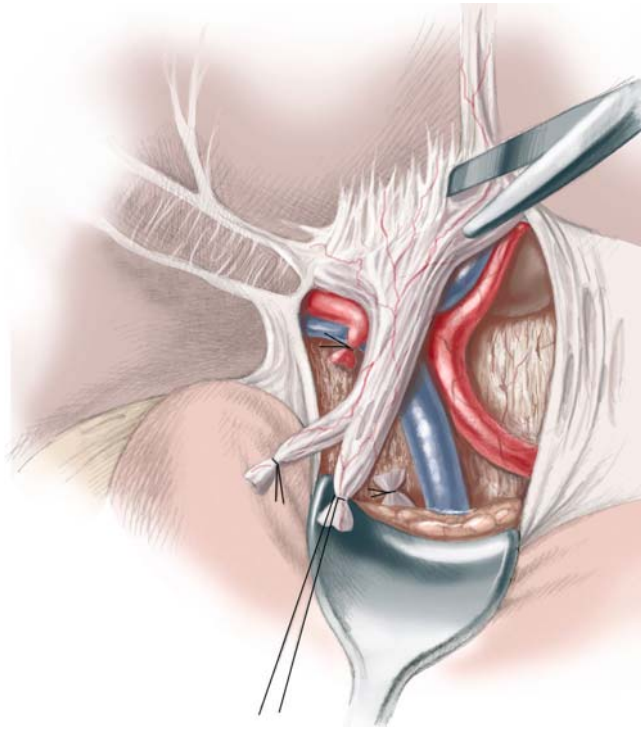


Figure 33.6

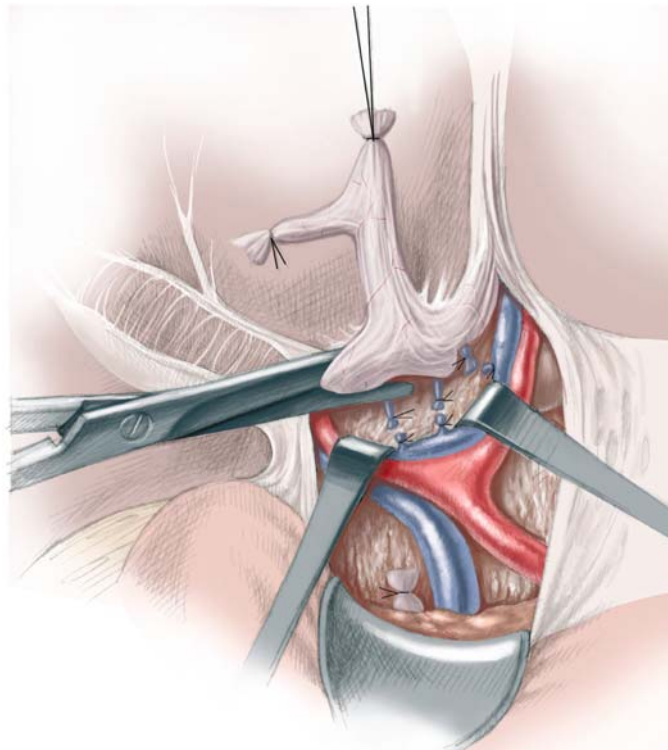


Figure 33.7

The next step is the construction of a Roux-en-Y loop of the jejunum. A Roux-en-Y anastomosis with the ascending limb, approximately 50 cm in length, is made. The end of the gastric limb of the intestine is anastomosed not to the back, but to the lateral side of the hepatic limb of the intestine. Most surgeons cur-

rently do not use a cutaneous stoma because of the frequent bleeding that occurs when the patient develops portal hypertension, and the technical difficulties that arise when subsequent liver transplantation may become necessary. Further, there was no reduction in incidence of cholangitis.

Figure 33.8, 33.9

A spur valve (A) and an intussuscepted valve (B) are made, which may prevent cholangitis. Three centimetres of the antimesenteric half of the seromuscular coat is removed from the biliary limb proximal to the anastomosis. The gastric and biliary limbs are then coapted over the denuded mucosa with sutures along the edges of the incised seromuscular layer. Subsequently, the intussuscepted valve is created in

the biliary limb proximal to the spur valve. The vasa recti of the conduit are divided by the width equal to the intestinal diameter. The seromuscular layer of the devascularized intestine is then removed. The denuded segment and an equivalent length of its proximal portion of the intestine is intussuscepted into the distal segment. This valve with fixed with eight to ten interrupted sutures.

Figure 33.7

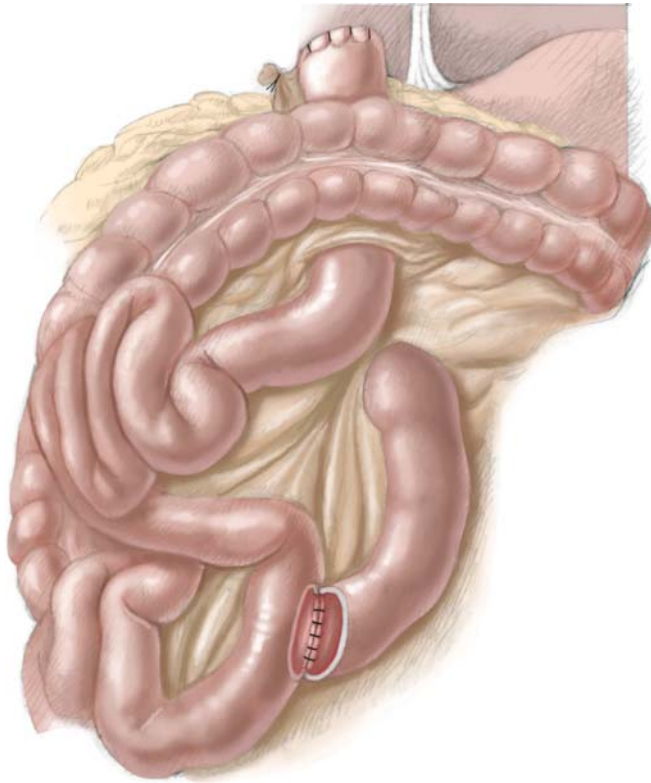


Figure 33.8

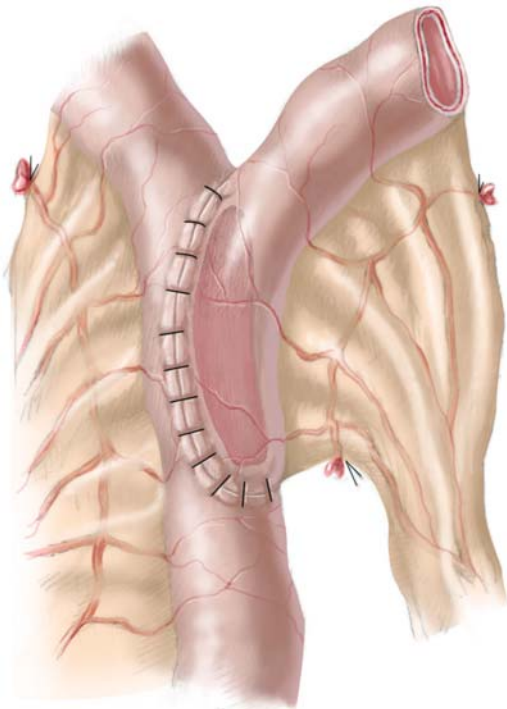


Figure 33.9

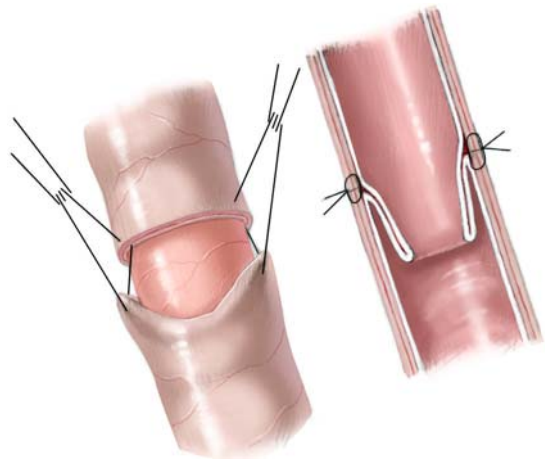


Figure 33.10

After completion of valves, the hepatic limb is brought up retrocolically. The end of the intestine is anastomosed around the transected end of the fibrous remnants at the porta hepatis by full-thickness interrupted sutures using 5/0 absorbable sutures.

Stitches must not be placed in the transected surface of the fibrous remnants in which minute bile ducts are present. After all interrupted sutures of the posterior row are placed in position, they are tied.

Figure 33.10

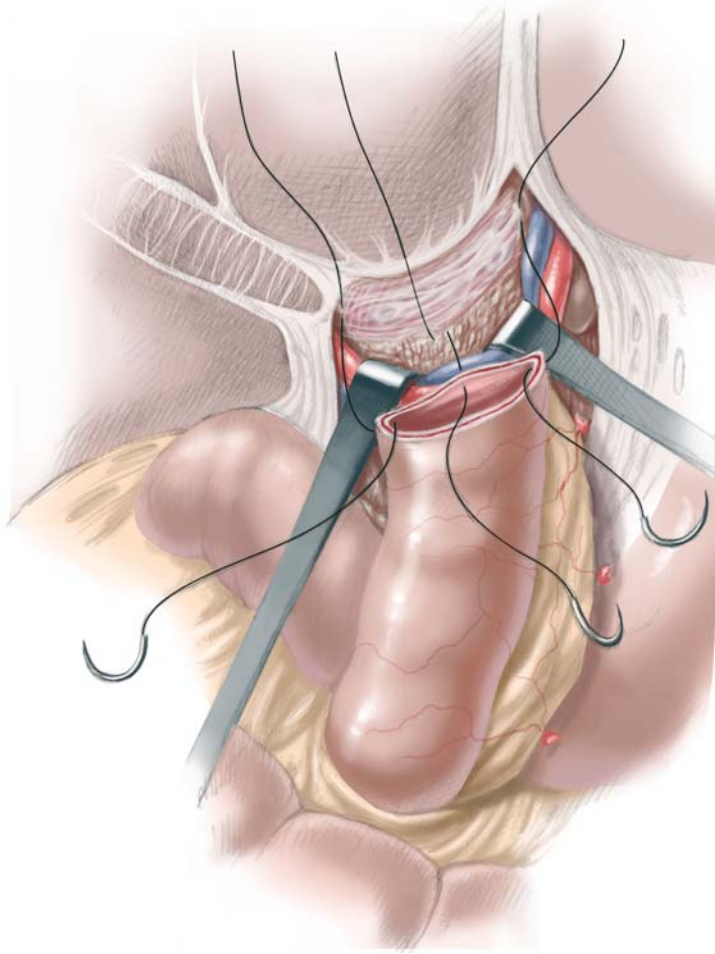


Figure 33.11, 33.12

The anterior row of suture is made as same as the posterior row of the anastomosis. Again, it should be emphasized that stitches must not be placed in the transected surface of the fibrous remnants, but around the transected area.

Interrupted seromuscular sutures are made using 5/0 silk between the anterior wall of the jejunum and the quadrate lobe of the liver to fix the intestine at the porta hepatis. Several stitches are placed between the posterior wall of the jejunum and the hepatoduodenal ligament. Irrigation of the abdominal cavity with saline should be done sufficiently. Intestine, especially the jejunum including the biliary limb is carefully placed in order in the abdominal cavity to prevent ileus. A Penrose drain is placed in the foramen of Winslow. After the intestine in the upper abdomen, including hepatic limb, is covered by Seprafilm, the abdominal cavity is closed in layers.

Patients are placed in an oxygen tent and intravenous fluid is given.

Decompression of the gastrointestinal tract should be performed by nasogastric aspiration and enema.

Oral feeding is usually started on the fifth or sixth post-operative day when bowel activity resumes. Prevention of post-operative cholangitis is a main goal of the post-operative management. For this purpose, we routinely use antibiotics, choleretics and steroids as post-operative medication. For antibiotics, amikacin sulfate in a dose of 8 mg/kg per day, q8h, is administered for 7 days after the operation and then cephalosporin in a dose of 50–80 mg/kg per day is given intravenously for a few months until the serum bilirubin level falls below 2 mg/dl. As choleretics, intravenous injection of 3 ml 10% dehydrocholic acid diluted with 7 ml 5% glucose is started on the day of operation and is given every 12 h. Ursodeoxycholic acid at a dose of 0.5 g/day is also given orally. Prednisolone, 10 mg twice a day intravenously, is started after the seventh post-operative day. Steroid therapy is continued intravenously for 4 days and it is switched to oral administration of 20 mg bid prednisolone every other day for several months.

Figure 33.11

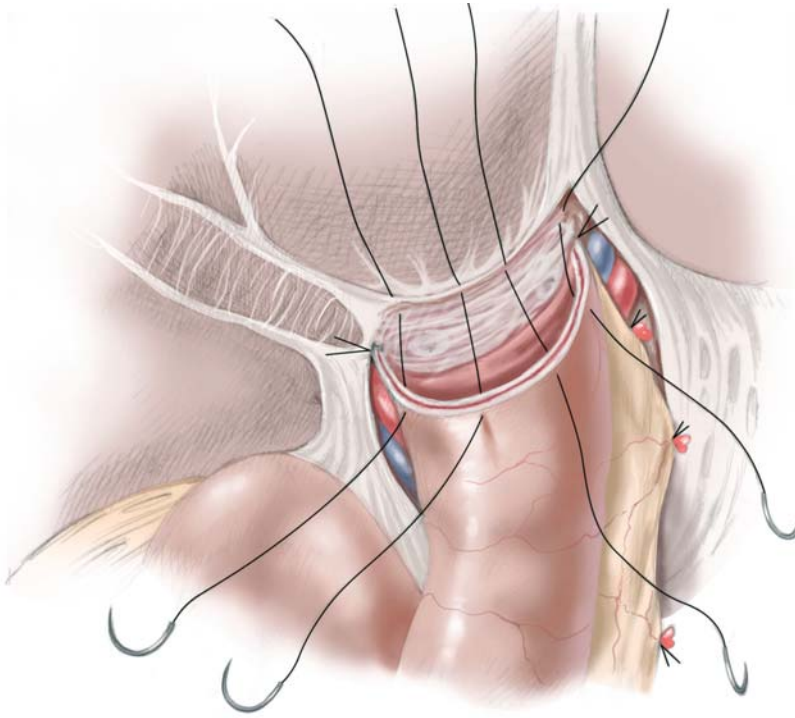
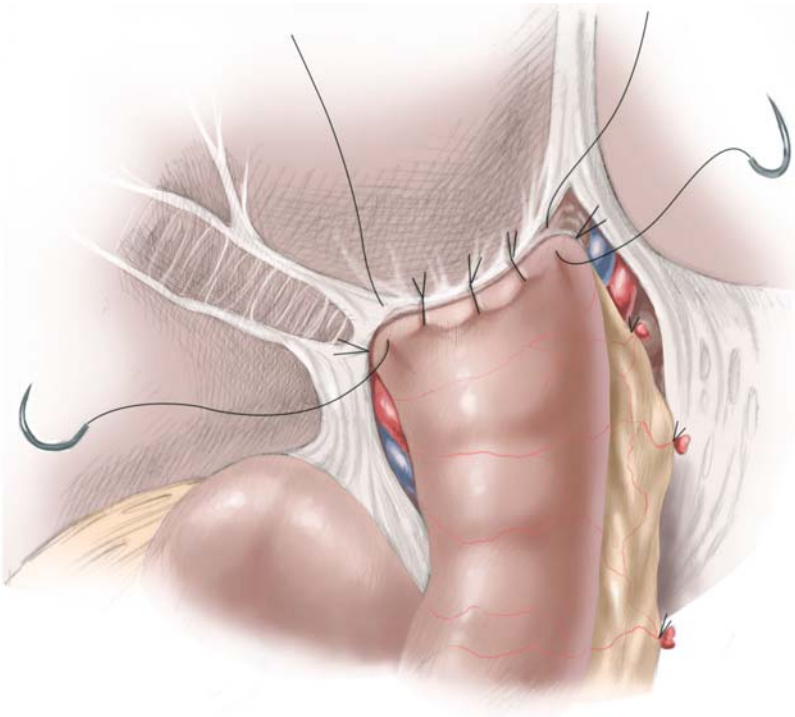


Figure 33.12



CONCLUSION

Between 1953 and 2001, a total of 321 patients with biliary atresia underwent surgery in our hospital. Among them, 43 patients underwent double-valved hepatic portoenterostomy (the valved procedure). Bile drainage after surgery was obtained in 95% of the cases. The incidence of post-operative cholangitis was 56% in the valved procedure. Of the cases treated by this procedure, 49% are still alive without jaundice after hepatic portoenterostomy alone, and 30% are alive after subsequent liver transplantation.

The combination of hepatic portoenterostomy with subsequent liver transplantation is the treatment of choice for patients with biliary atresia. It is important, however, to attempt to keep the patient's own organ by continuing efforts to achieve the best possible results with hepatic portoenterostomy.

The authors' current strategy for surgical treatment for patients with this disease include (1) early diagnosis, including prenatal diagnosis, (2) hepatic portoenterostomy without stoma formation, (3) close postoperative care, especially for prevention of post-operative cholangitis, (4) revision of hepatic portoenterostomy only in selected cases who showed good bile drainage after the first procedure, (5) early liver transplantation in patients with absolutely failed hepatic portoenterostomy, (6) avoidance of laparotomy for the treatment of oesophageal varices and hypersplenism (injection sclerotherapy and splenic artery embolization), and (7) consideration of exploratory laparotomy or primary liver transplantation for patients with advanced liver disease at the time of referral.

SELECTED BIBLIOGRAPHY

- Kasai M (1974) Treatment of biliary atresia with special reference to hepatic porto-enterostomy and its modifications. *Prog Pediatr Surg* 6:5-52
- Ohi R (1988) A history of the Kasai operation: hepatic portoenterostomy for biliary atresia. *World J Surg* 12:871-874
- Ohi R (1991) Biliary atresia: modification to the original portoenterostomy operation. In: Howard ER (ed) *Surgery of liver diseases in children*. Butterworth, Oxford, pp 72-77

- Ohi R (2000) Biliary atresia; a surgical perspective. *Clin Liver Dis* 4:779-804
- Ohi R, Nio M (1998) The jaundiced infant: biliary atresia and other obstructions. In: O'Neill JA, Rowe MI, Grosfeld JL, Fonkalsrud EW, Coran AG (eds) *Pediatric Surgery*, vol II. Mosby, St Louis, pp 1465-1481

Takeshi Miyano, Masahiko Urao,
Atsuyuki Yamataka

INTRODUCTION

There are various types of choledochal cysts. Cystic or fusiform types are most common, and other types such as diverticulum of the common bile duct, choledochoceles and Caroli's disease are rare. In our series of 356 choledochal cyst patients, 316 were children and 40 were adults. There were 213 of the cystic type and 143 of the fusiform type. Choledochal cyst is nearly always associated with pancreatico-biliary malunion (PBMU) and is often associated with dilatation of the intra-hepatic bile ducts (IHBD).

Recent advancements in imaging technology such as magnetic resonance cholangio-pancreatography (MRCP) and improvement in endoscopic retrograde cholangio-pancreatography (ERCP) allow the precise anatomy of the hepato-biliary-pancreatic ductal system to be visualized pre-operatively in most cases of choledochal cyst. Before cyst excision, detailed information must be obtained about both intra-hepatic bile duct abnormalities such as ductal stenosis, dilata-

tion and presence of debris/stones, as well as intra-pancreatic bile duct anomalies such as the PMBU type, presences of debris/protein plugs in the common channel and dilatation of the pancreatic duct.

Although MRCP is highly accurate, it may not clearly visualize PBMU if the patient is an infant or young child, and ERCP is generally contraindicated if pancreatitis is present. In such cases, intra-operative cholangiography is indicated.

Major steps in the surgical management of choledochal cyst are: (1) intra-operative cholangiography if pre-operative imaging studies fail to demonstrate the entire hepato-biliary-pancreatic tract, (2) excision of extrahepatic bile duct, (3) intra-operative endoscopy, if indicated, (4) dissection and excision of distal choledochus, (5) Adequate excision of the common hepatic duct at the correct level, (6) hepatico-jejunostomy, end-to-end anastomosis being preferable, and (7) Roux-en-Y biliary reconstruction.

Figure 34.1 a–f

Choledochal cyst is commonly associated with PBMU involving concurrent abnormalities of the common channel, pancreatic duct and intrahepatic ducts. Choledochal cysts with PBMU are classified as: **a** cystic dilatation, **b** fusiform dilatation, **c** without biliary dilatation and choledochal cysts without PBMU are classified as: **d** cystic diverticulum of the bile duct, **e** diverticulum of the distal bile duct (choledochocele), and **f** intrahepatic bile duct dilatation alone (Caroli's disease).

Surgical problems in the cystic type of choledochal cyst are most often encountered on the proximal

side of the pathology occurring as a result of anatomical variants of the common hepatic duct, uncertainty in relation to the excision level of common hepatic duct, dilated intrahepatic bile ducts, and debris and/or stenosis in the intrahepatic bile ducts. By contrast, surgical problems in the fusiform type most often arise in the distal side of the malformation and these are due to uncertainty in relation to the excision level of the distal choledochus, debris in the common channel, and complicated PBMU.

Figure 34.1a-f

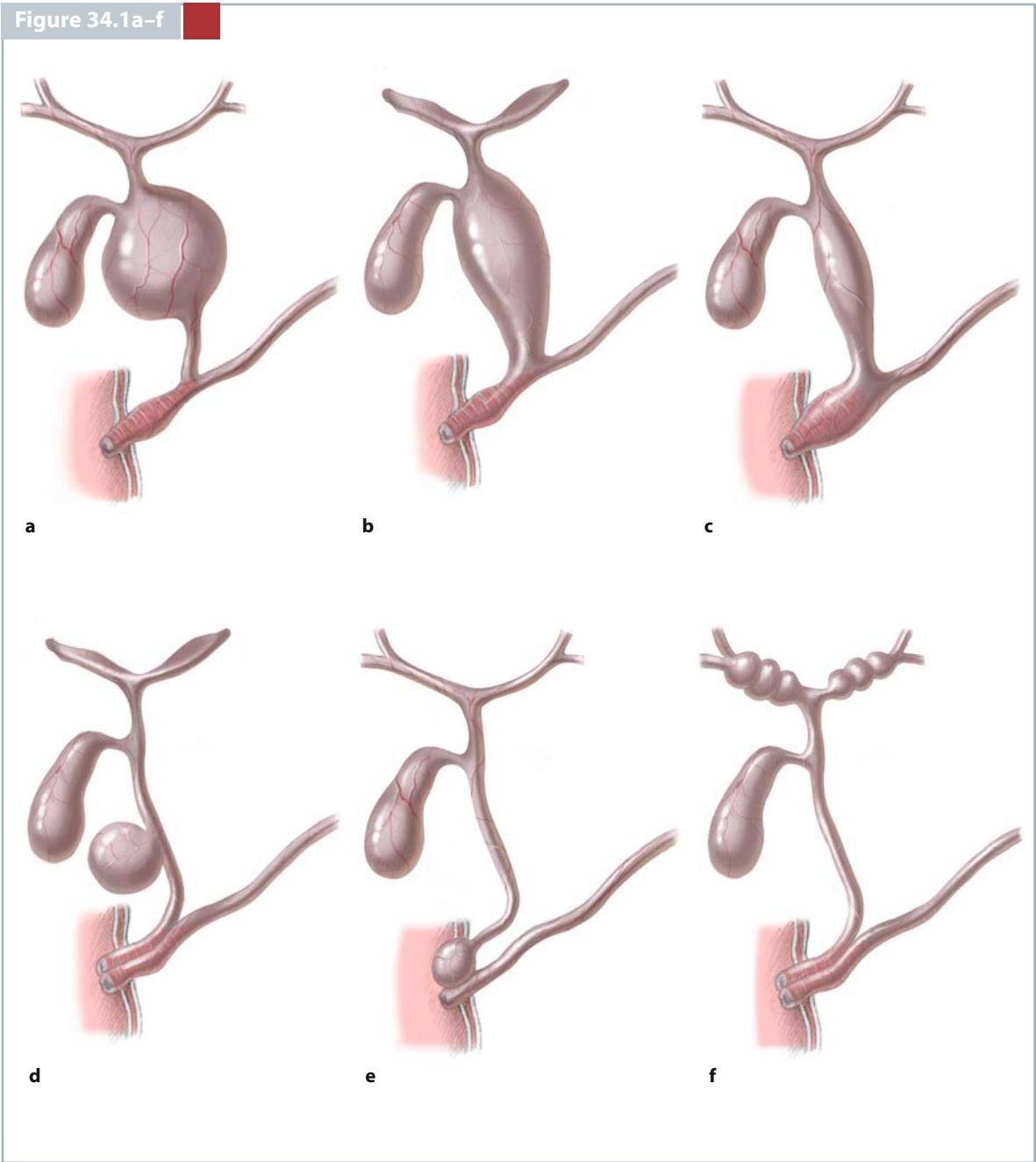


Figure 34.2, 34.3

The patient is placed supine on an operating table with facilities for intra-operative cholangiography. We prefer an extended right sub-costal incision. After careful macroscopic examination of the choledochal cyst and liver, the gallbladder is mobilized from its bed while maintaining its continuity with the choledochal cyst. In comparison with the fusiform type of choledochal cyst, there are usually more adhesions between a cystic type and surrounding vital structures such as the portal vein and hepatic artery, especially in older children. In adolescents and adults, the adhesions are often very dense, and great care is required during cyst excision.

Prior to dissection of the cyst, we always open the anterior wall of the choledochal cyst transversely. Because anatomical variants of the common hepatic duct are often found in cystic-type choledochal cyst, this incision should be made below the centre of the cyst. By opening the anterior wall of the cyst, the posterior wall of the cyst is visible directly from the inside, and the choledochal cyst can be freed from surrounding tissues including the portal vein and hepatic artery more easily than by dissecting the cyst free without incising the anterior wall.

Figure 34.2

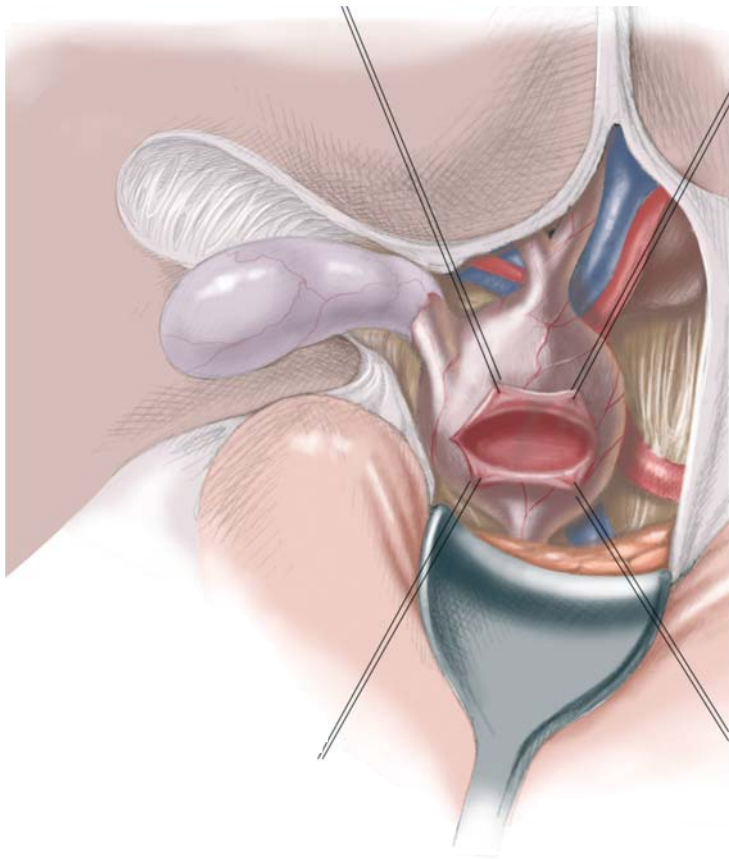


Figure 34.3

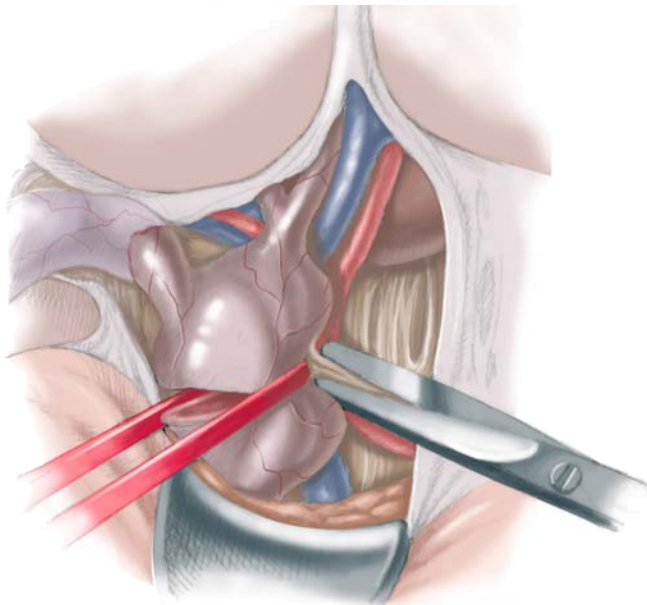


Figure 34.4–34.6

If the cyst is extremely inflamed and adhesions are very dense, mucosectomy of the cyst should be performed rather than full-thickness dissection to minimize the degree of surgical stress the patient is exposed to. In order to prevent post-operative pancreatitis and/or stone formation due to the formation of a residual cyst, the distal common bile duct should be resected as close as possible to the pancreatobiliary junction. In the cystic type, the distal common hepatic duct is narrow, and sometimes so narrow that it looks blind-ended and cannot be identified specifically. Thus, in cystic-type choledochal cyst, if mucosectomy is completed up to the pancreatobiliary

junction, it is unlikely that a residual cyst will develop within the pancreas. By contrast, in fusiform-type choledochal cyst, excision of the distal common hepatic duct is more difficult since the distal common bile duct is still wide at the pancreatobiliary junction and, if not excised properly, the likelihood of the distal common bile duct being left within the pancreas is high.

Following mucosectomy, the distal end of the cyst is transfixed twice using 3/0 or 4/0 absorbable sutures. The distal stump is either left or buried in the muscle wall of the surrounding cyst.

Figure 34.4

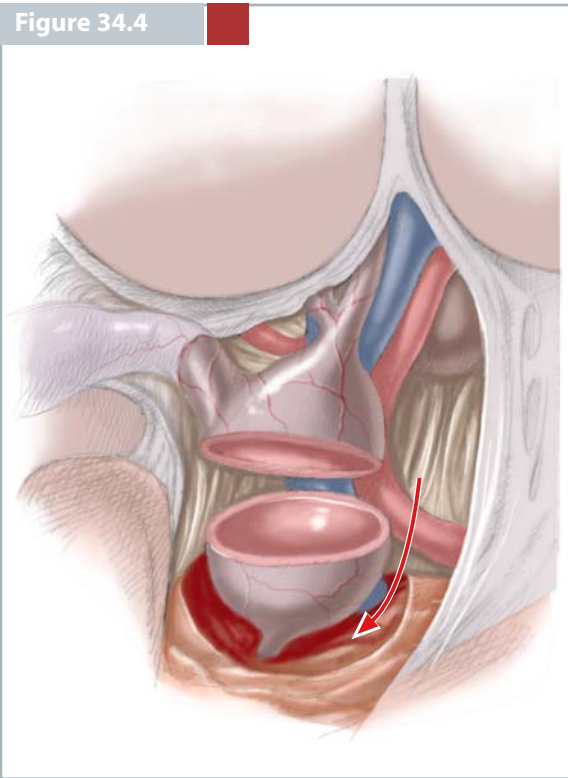


Figure 34.5

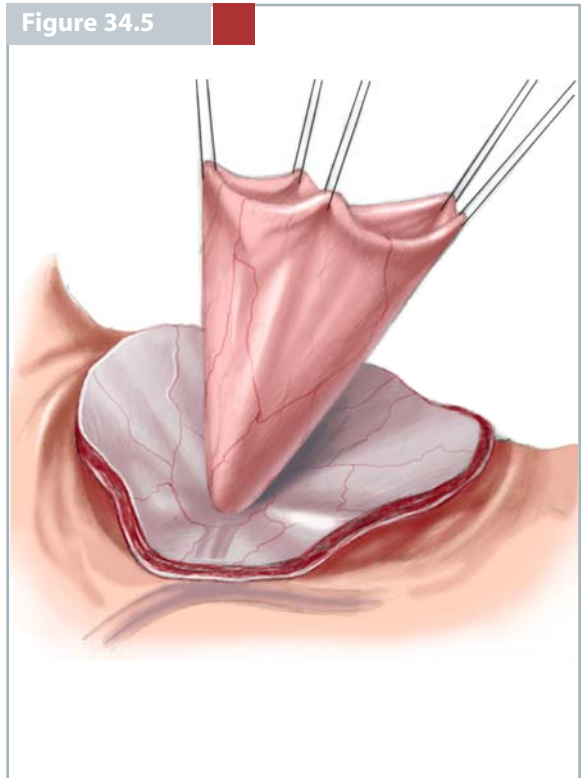


Figure 34.6

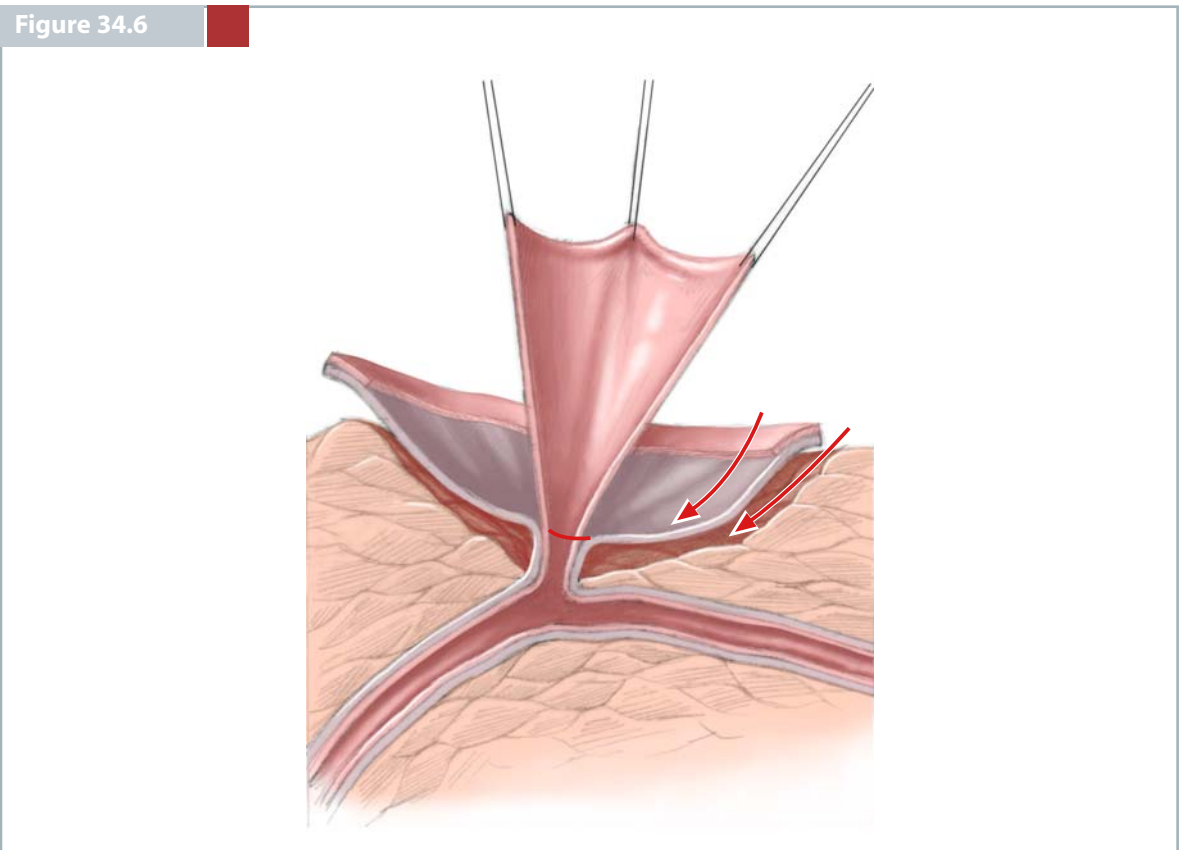


Figure 34.7, 34.8

In the fusiform type of choledochal cyst, adhesions between the extra-hepatic bile duct and surrounding tissues are less dense than with the cystic type, especially in younger children. As a result, the common bile duct can be safely dissected free from surrounding tissues, the portal vein and the hepatic artery, after the anterior wall of the common bile duct was incised.

Because there are fewer adhesions associated with the fusiform type, dissection of the proximal common bile duct is relatively easy, and the common hepatic bile duct can then be prepared for the hepatico-jejunojejunostomy anastomosis.

Figure 34.7

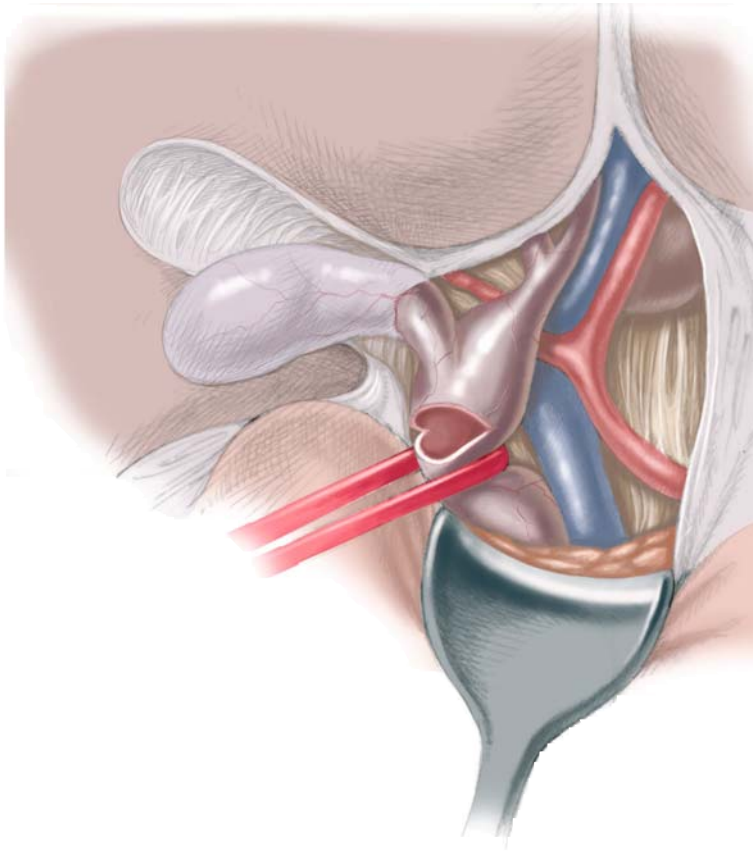


Figure 34.8

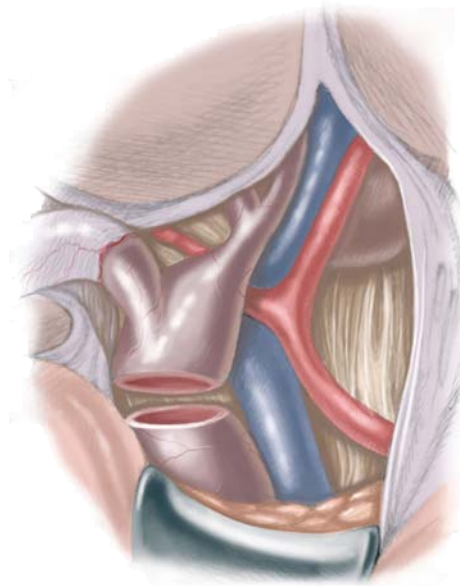


Figure 34.9–34.12

A fusiform-type choledochal cyst is usually associated with complicated PBMU as well as debris and/or protein plugs in the common channel. Pancreatic duct anomalies are also often present. Thus, dissection of the distal common bile duct in fusiform choledochal cyst should be performed with great care, making sure not to leave the intra-pancreatic portion of the common bile duct behind and not to injure the pancreatic duct. Intra-operative endoscopy up to the distal common bile duct should be performed to safely dissect the distal common bile duct adequately in cases of fusiform choledochal cyst.

We started performing routine intra-operative endoscopy with a pediatric or neonatal cystoscope in 1986. Using intra-operative endoscopy, it is possible to determine the level of resection of the distal common bile duct, to irrigate the common channel and wash out any debris or protein plugs, to examine the ampulla of Vater for stenosis and to examine the proximal intra-hepatic bile ducts.

If the distal common bile duct is resected along the red line, over time a cyst will reform around the distal duct left within the pancreas, leading to recurrent pancreatitis, stone formation in the residual cyst, or malignant changes in the residual cyst. In contrast, if the distal duct is resected along the blue line, i.e., just above the pancreatico-biliary junction, cyst reformation due to residual duct within the pancreas is unlikely.

Before the introduction of intra-operative endoscopy it was difficult to excise the pancreatic portion of a fusiform-type choledochal cyst completely and safely because of risk of injury to the pancreatic duct. Endoscopy now allows safe excision of most of the wall of a fusiform choledochal cyst in the pancreas without damaging the pancreatic duct, and we believe that this reduces the risk of post-operative complications such as recurrent pancreatitis, stone formation and carcinoma.

Figure 34.9–34.12

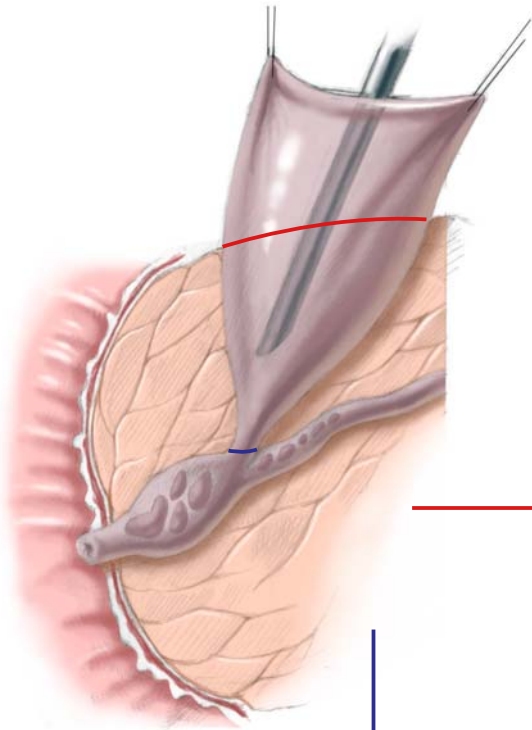


Figure 34.9

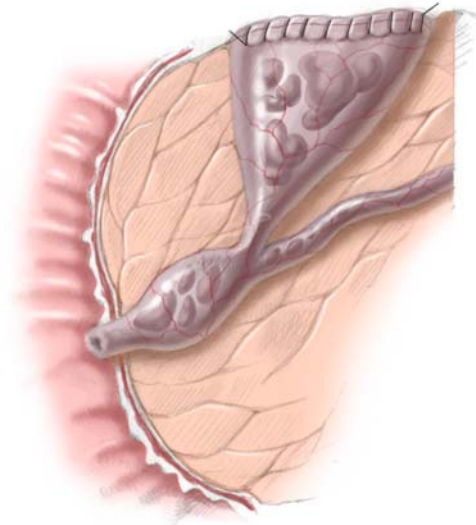


Figure 34.10

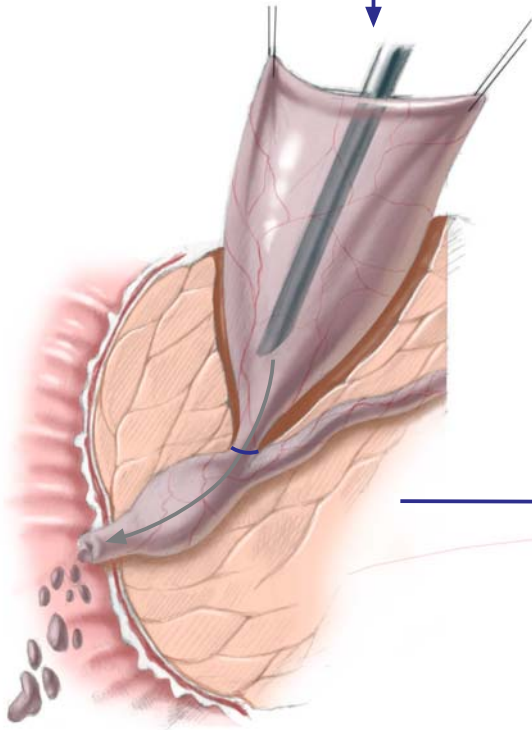


Figure 34.11

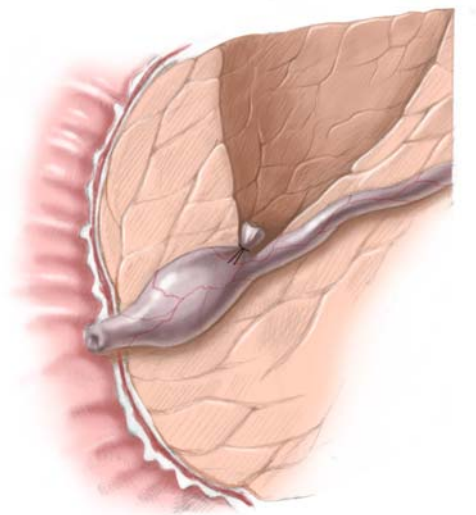


Figure 34.12

— wrong
— recommended

Figure 34.13

Cystic-type choledochal cyst is often associated with stenosis and dilatation of intra-hepatic ducts. If stenosis is present and left untouched at the time of cyst excision, it may induce stone formation in the intra-hepatic ducts and cholangitis later in life. The incidence of post-operative complications such as recurrent cholangitis, stone formation, and anastomotic stricture is increased in patients with dilated intra-hepatic bile ducts.

Intra-operative endoscopy is useful for examining for the presence of debris in the dilated intra-hepatic ducts, for determining the ideal level of resection of the common hepatic duct, and for examining whether there is stenosis in the intra-hepatic ducts present and, if so, its degree.

Surgical correction is required for congenital intra-hepatic duct stenosis if it is severe and the intra-hepatic duct distal to the stenosis is extremely dilated. When stenosis exists at the hepatic hilum or at the first branch of the intra-hepatic ducts, surgical correction such as dilatation or ductal plasty can be performed; however, if the stenosis is located distal to the first branch of the intra-hepatic ducts, treatment is difficult. Large diffusely dilated intra-hepatic ducts in both lobes cannot be corrected; however, liver resection such as segmentectomy and lobectomy may be recommended at a later stage if the dilatation is localized to a single lobe.

Figure 34.14a–d

Anatomical Variations of the Hepatic Ducts. The ideal length of common hepatic duct required for the anastomosis is up to approximately 10 mm, since a longer common hepatic duct may become kinked leading to bile stasis in the intra-hepatic bile ducts (a). However, the lumen of the common hepatic duct should be inspected before trimming it to make it shorter because there may be ductal anomalies such as a luminal stenosis (b), separate opening (c) or septum (d).

These variations in the anatomy of the common hepatic duct have been described in the literature and were also encountered in our series. Such variations can affect the success of hepatico-enterostomy after transection of the cyst, but have been less significant after routine intra-operative endoscopy was introduced.

Figure 34.13

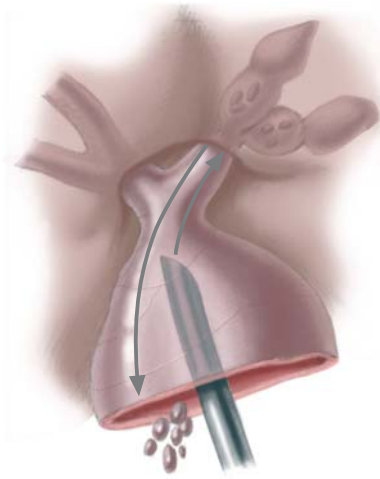
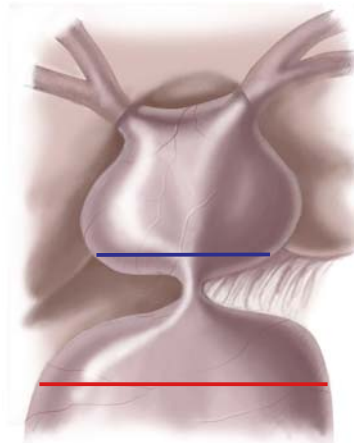
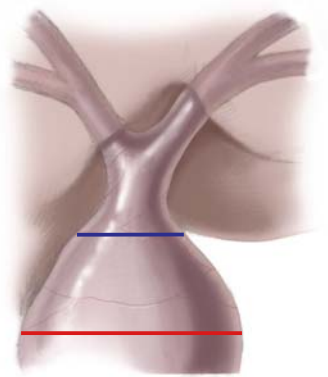
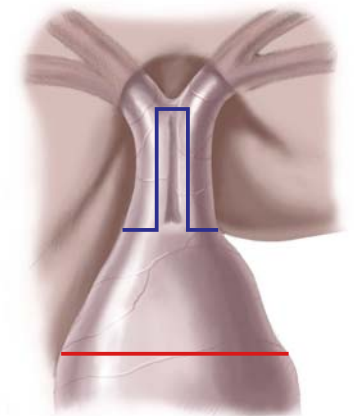
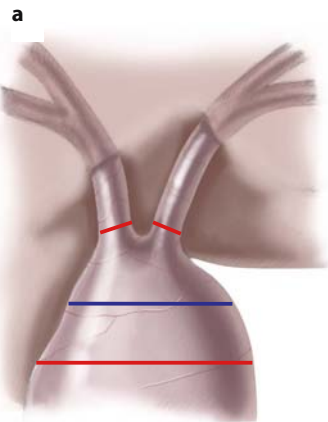


Figure 34.14



— recommended
— wrong



a

d

Figure 34.15a,b

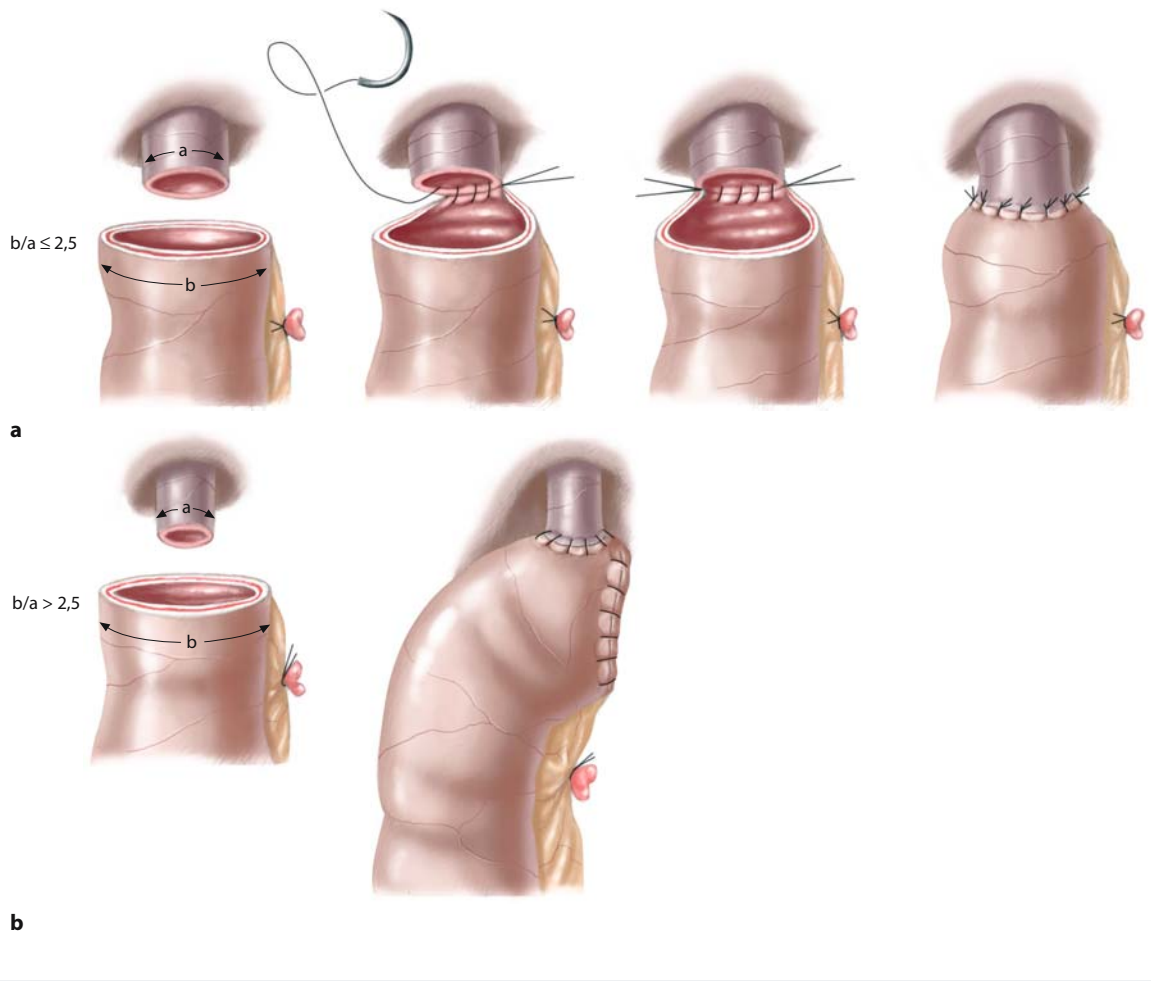
Cyst excision and Roux-en-Y hepatico-jejunostomy (RYHJ) is the treatment of choice for choledochal cyst in children. End-to-end anastomosis during RYHJ is recommended to prevent elongation of the blind pouch if the ratio between the diameters of the common hepatic duct and the proximal Roux-en-Y jejunum at the proposed site of anastomosis is less than or equal to 1:2.5 (common hepatic duct:jejunum). If end-to-side anastomosis is unavoidable, the common hepatic duct should be anastomosed as close as possible to the closed end of the blind pouch so there will be no blind pouch at the hepatico-jejunostomy anastomosis site; if an end-to-side anastomosis is performed far from the closed end of the blind pouch, elongation of the blind pouch will occur later in life as the child grows. Elongation of the blind pouch can cause bile stasis in the blind pouch and intra-hepatic bile ducts (especially if they are dilated) leading to stone formation. We believe end-to-end hepatico-jejunostomy anastomosis and our end-to-side anastomosis technique prevent stone formation in the blind pouch (or intra-hepatic ducts) and cholangitis.

Some surgeons predetermine the length of the Roux-en-Y jejunal limb, e.g., 30, 40, 50 or 60 cm, without considering the size of the child, which causes the

Roux-en-Y jejunal limb tends to be unnecessarily long, especially in infants and younger children. Redundancy of the Roux-en-Y limb is likely to occur later in life as the patient grows and may cause bile stasis in the Roux-en-Y limb itself as well as in the intra-hepatic bile ducts, leading to cholangitis or stone formation. Thus, the length of the Roux-en-Y limb should be individualized so that the Roux-en-Y jejunostomy fits naturally into the splenic flexure after the jejunostomy is completed and returned to the peritoneal cavity. In this situation, redundancy of the Roux-en-Y limb will not occur.

When a jejunostomy and Roux-en-Y limb are used, we recommend that both the native jejunum and the Roux-en-Y jejunal limb proximal to the jejunostomy be approximated for up to 8 cm cranially from the jejunostomy to ensure both bile in the Roux-en-Y limb and contents of the native jejunum flow smoothly down into the jejunum distal to the jejunostomy. Without performing this, the jejunostomy can tend to be T-shaped, and there may be reflux of jejunal contents into the Roux-en-Y limb, leading to dilatation of the jejunal limb and biliary stasis in the Roux-en-Y limb, a situation we recently encountered in a patient who was operated on at another hospital.

Figure 34.15a,b



CONCLUSION

We have performed a total of 92 Roux-en-Y hepatico-jejunostomy (70 end-to-end anastomoses and 22 end-to-side anastomoses) using our cyst excision technique with intra-operative endoscopy, according to our recommendations for the procedure, and all patients are well without any complications after a mean follow-up period of 8.0 years (range 9 months to 16 years).

Cyst excision and Roux-en-Y hepatico-jejunostomy is the treatment of choice in both children and adults with choledochal cyst. Intra-operative endos-

copy at the time of cyst excision is useful to prevent post-operative complications, especially those that develop in over time. Roux-en-Y hepatico-jejunostomy in children is different from that in adults, since the Roux-en-Y limb or blind pouch can grow and elongate as the child grows.

Our techniques for cyst excision and biliary reconstruction effectively prevent post-operative complications, and we recommend their use in children with choledochal cyst.

SELECTED BIBLIOGRAPHY

- Miyano T, Yamataka A, Kato Y, Kohno S, Fujiwara T (1995) Choledochal cysts: special emphasis on the usefulness of intra-operative endoscopy. *J Pediatr Surg* 30:482-484
- Miyano T, Yamataka A, Kato Y, Segawa O, Lane G, Takamizawa S, Kohno S, Fujiwara T (1996) Hepaticoenterostomy after excision of choledochal cyst in children: a 30-year experience with 180 cases. *J Pediatr Surg* 31:1417-1421
- Shima H, Yamataka A, Yanai T, Kobayashi H, Miyano T (2004) Intracorporeal electro hydraulic lithotripsy bile duct stone formation after choledochal cyst excision. *Pediatr Surg Int* 20:70-72
- Yamataka A, Segawa O, Kobayashi H, Kato Y, Miyano T (2000) Intraoperative pancreatoscopy for pancreatic duct stone debris distal to the common channel in choledochal cyst. *J Pediatr Surg* 35:1-4
- Yamataka A, Ohshiro K, Okada Y, Hosoda Y, Fujiwara T, Kohno S, Sunagawa M, Futagawa S, Sakakibara N, Miyano T (1997) Complications after cyst excision with hepaticoenterostomy for choledochal cysts and their surgical management in children versus adults. *J Pediatr Surg* 32:1097-1102

Thom E. Lobe

INTRODUCTION

Cholecystitis and cholelithiasis are increasing in frequency in infancy, childhood and adolescence, and the incidence is reported to be between 0.15% and 0.22%. Congenital anomalies of the gallbladder are rare. While total parenteral nutrition often results in cholestasis and stone formation in infants, haematological disease such as sickle cell disease, hereditary spherocytosis and thalassaemia are more often seen in older children and adolescents. In the absence of an underlying haematological disorder, most gallstones are associated with obesity, adolescent pregnancy, a positive family history for cholelithiasis, the use of oral contraceptives, or as a complication of a choledochal cyst. Yet the origin of gallstones in approximately 80% of pediatric patients remains unknown. While there is no sex predilection, females begin to predominate in incidence of gallstones among children who are heart transplant recipients, where the overall incidence is approximately 16% post-transplant. Patients who have been on extracorporeal membrane oxygenation (ECMO), also are at risk for gallstones, and should undergo cholecystectomy if stones develop.

Patients usually present with pain, jaundice or both. Less often than in adults, patients present with fever, right upper quadrant tenderness and leukocytosis, suggesting the presence of cholecystitis. These patients are placed on antibiotics and oral intake is withheld until it is clear that their acute inflammation is resolving.

When possible, we prefer to perform cholecystectomy as an elective procedure after the inflammation has resolved. When pain or cholecystitis persists, however, cholecystectomy is performed without delay.

Today, laparoscopy is recognized as the standard procedure for cholecystectomy. The principles of the open and laparoscopic procedures are essentially the same (except for the incision). These procedures are routinely performed under general anaesthesia with endotracheal intubation. A nasogastric tube is placed for gastric decompression and a bladder catheter or Crede manoeuvre is used to empty the bladder.

Figure 35.1

The patient is placed supine on the operating table. To facilitate access to the patient, we place the patient's arms at the patient's side rather than at right angles to the patient. The patient is placed on a table suitable for fluoroscopy under the assumption that an operative cholangiogram may be necessary. The

abdomen is prepped and draped as is customary so that the entire abdomen from xiphoid to pubis and from posterior axillary line to posterior axillary line is accessible. Four cannulas are used in general. Their position depends somewhat on the patient's size.

Figure 35.2

We begin the procedure with the insertion of an umbilical cannula of 10 mm diameter. We believe that, while many are comfortable with the use of a Veress needle, the safest approach is an open, Hasson, approach to cannula insertion. A 10-mm incision first is made in the umbilical ring, either cephalad or caudad to the umbilicus. We make this with a number 15 blade and carry the incision through the skin to the fascia.

Two haemostat clamps are then used to grasp the fascia so that it can be incised. This incision is carried down to the peritoneum, which is opened sufficiently so that the cannula can be inserted. A right-angled retractor can be used to elevate the abdominal wall to facilitate cannula insertion. The cannula is fixed to the abdominal wall by placing a suture through the skin to a small ring of rubber catheter that was cut and placed around the outside of the cannula for this purpose. Proper cannula position is checked using a

5-mm telescope. The abdomen then is insufflated with CO₂ gas to 15 torr.

Three other cannulas are inserted. Their position depends somewhat on the patient's size. In general, one needs a cannula for the gallbladder and liver retractor, one for a grasper to hold and manipulate the neck of the gallbladder and another for dissection, duct and vessel ligation, and for the telescope when it is time for removal of the gallbladder. The gallbladder liver retractor is placed in the mid to anterior axillary line between the level of the umbilicus and the level of the superior iliac crest (for smaller patients). A cannula is inserted at about the mid-clavicular line between the umbilicus and the costal margin (usually closer to the costal margin). The final cannula is inserted at about the midline and the mid-clavicular line (smaller patients). These cannulas can all be inserted directly under the watchful eye of the surgeon's telescope/camera.

Figure 35.1

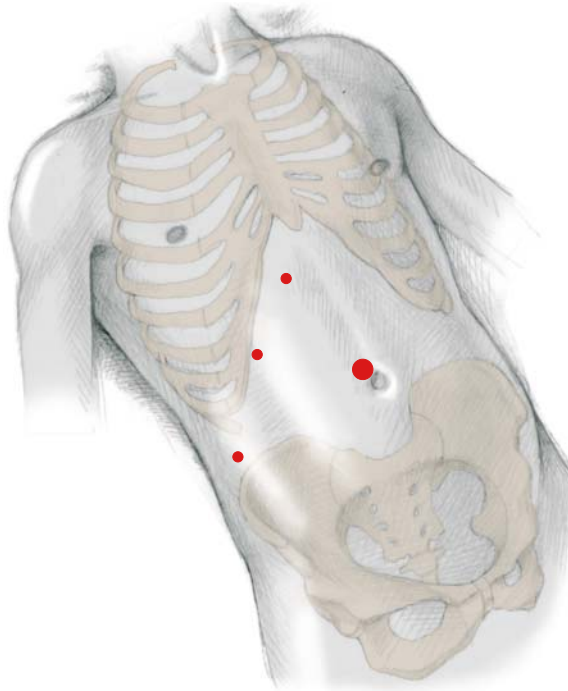


Figure 35.2

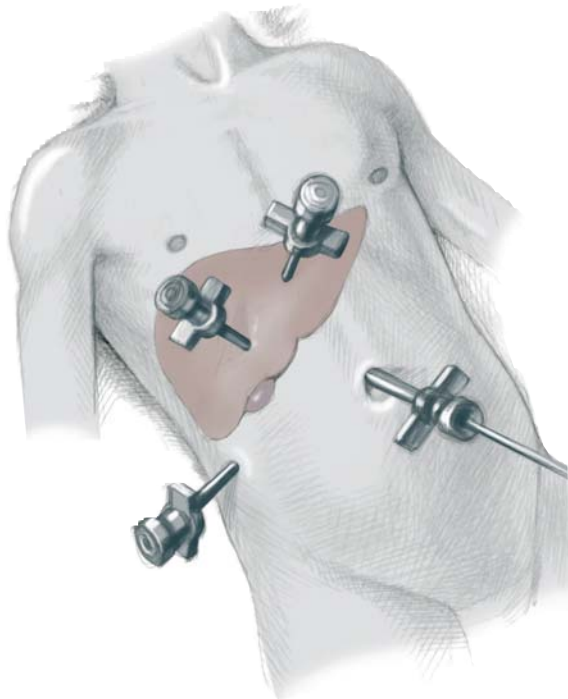


Figure 35.3

The gallbladder is grasped at the fundus and this is used to retract the gallbladder and liver superiorly and anteriorly. We use a self-retraining retractor to secure this cannula in place for most of the procedure. The right sub-costal cannula is used for the re-

tractor while we begin the dissection with a Maryland dissector. It is helpful to position the patient in a reversed Trendelenburg position with the right side up.

Figure 35.4

Dissection is begun by stripping away the peritoneum to expose the cystic duct and artery. Once the duct and artery are exposed, we apply clips to these structures and then divide them. We advise against using electrocautery here so as to avoid any injury.

Figure 35.3

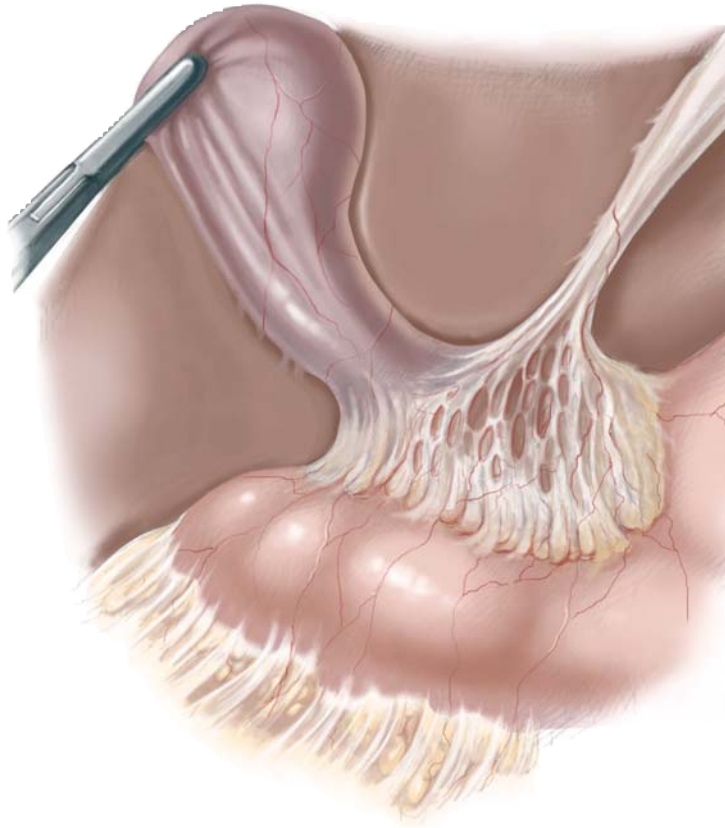


Figure 35.4

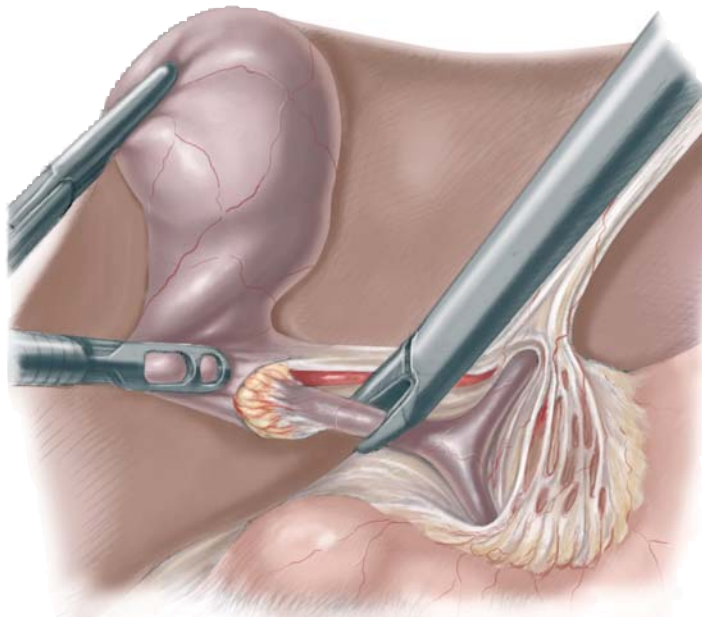


Figure 35.5

If there is any doubt as to the anatomy or if the duct is larger than it should be, or if the pre-operative studies suggest the possibility of stones, an operative cholangiogram is performed. We do this by clipping the cystic duct as it joins the gallbladder and making a small nick in its wall, large enough to insert the cannula for the study. We then use a 8-12 gauge plastic catheter as an “access port” for the cholangiogram catheter, and insert this directly through the abdominal wall. We prefer a balloon-tipped catheter, as this minimizes the risk for injury, and insert this directly into the duct through a nick in the duct midway between the gallbladder and the common bile duct. Inflation of the balloon holds it in place. The cholan-

giogram can then be done under fluoroscopic control while the duct is observed to assure that there is no leak of contrast.

If the cholangiogram is negative for retained stones, another clip is applied after the catheter is removed. If the cholangiogram demonstrates stones to be present, there are three options. First, the patient can be opened for exploration. Second, the operation can be completed and the patient referred for post-operative endoscopic retrograde cholangiography. Finally, a flexible endoscope can be used to examine and free the duct of stones (larger patients), or (in smaller patients) a pediatric cystoscope can be introduced into the duct for passage of a stone basket.

Figure 35.6

After the cystic artery and duct are divided, a right-angled hook electrocautery device or endoscopic shears connected to cautery are used to free the gallbladder from its bed. After this is accomplished, the gallbladder bed is inspected for haemorrhage, which is controlled if found.

We then move the telescope from its umbilical site to the midline or left subcostal cannula to visualize removal of the gallbladder from the 10-mm umbilical cannula site. When there are stones present, we open the gallbladder (after it has been partially exteriorised) and use a stone forceps to remove the stones

until the gallbladder can be extracted. The abdomen then is inspected for haemorrhage and lavaged if bile has been spilled during the procedure.

We then close the fascia for all wounds of 5 mm or greater (small children), or close the umbilical wound to prevent later herniation. All wounds are infiltrated with a long-acting local anaesthetic for post-operative analgesia. Patients are awakened from anaesthesia and discharged from the hospital when they can ambulate and tolerate liquids, usually on the day of surgery or after overnight hydration in the case of patients with sickle cell disease.

Figure 35.5

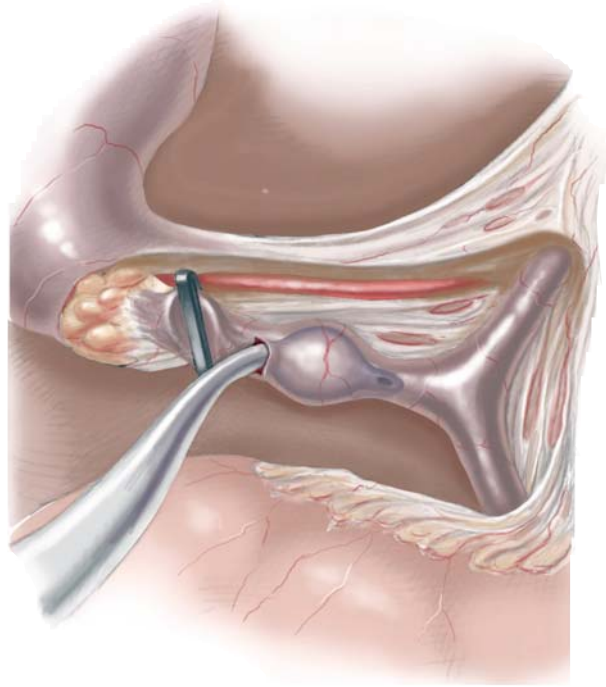
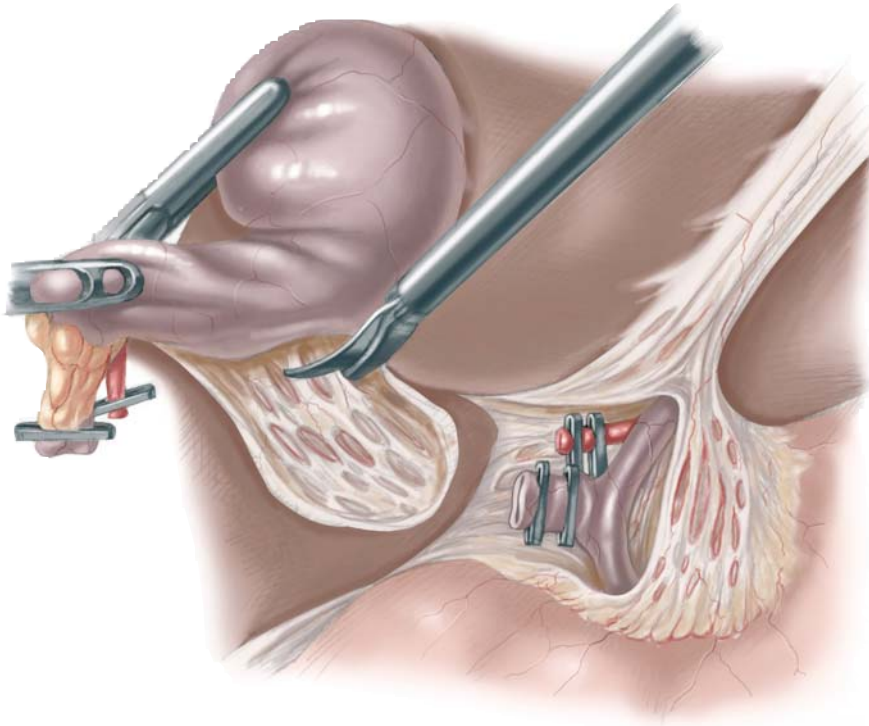


Figure 35.6



CONCLUSION

Patients with asymptomatic cholelithiasis are not scheduled for surgery unless they develop complications. Laparoscopic cholecystectomy has replaced open cholecystectomy for the vast majority of cases. Rarely, access cannot be achieved due to previous surgery, or the patient cannot tolerate the abdominal insufflation. In those cases a subcostal or midline abdominal incision is made, the intestines and liver are retracted out of the way and essentially the same procedure is carried out.

More recently, some surgeons have elected to perform the cholecystectomy from the fundus toward the porta hepatis. This may be helpful in cases of severe inflammation or marked oedema.

The most serious complication of this procedure is an unrecognized injury to the bile ducts. This can

occur when the anatomy is unclear; thus, the advice is to perform a cholangiogram when there is any doubt. Such injury can also occur from an electrical burn while using electrocautery near the portal area, thus the recommendation to avoid this practice.

When the gallbladder is opened accidentally during its dissection, bile and stones can spill into the peritoneal cavity. We make a modest effort to lavage and evacuate this spilled material, but rarely have we had post-operative problems from this.

Laparoscopic cholecystectomy is one of the more gratifying procedures we do. It is quick, simple and effective, and we see few problems afterwards.

SELECTED BIBLIOGRAPHY

- Clements RH, Holcomb GW 3rd (1998) Laparoscopic cholecystectomy. *Curr Opin Pediatr* 10:310–314
- Georgeson KE, Owings E (2000) Advances in minimally invasive surgery in children. *Am J Surg* 180:362–364
- Hugh TB (2002) New strategies to prevent laparoscopic bile duct injury—surgeons can learn from pilots. *Surgery* 132:826–835
- Lobe TE (2000) Cholelithiasis and cholecystitis in children. *Semin Pediatr Surg* 9:170–176
- Tagge EP, Hebra A, Goldberg A, Chandler JC, Delatte S, Othsen HB Jr (1998). Pediatric laparoscopic biliary tract surgery. *Semin Pediatr Surg* 7:202–206

Surgery for Persistent Hyperinsulinaemic Hypoglycaemia of Infancy

Lewis Spitz

INTRODUCTION

Hyperinsulinism as a cause of persistent hypoglycaemia in infancy and childhood is very uncommon (1:50,000). The importance of preventing hypoglycaemia (and reducing the likelihood of neurological damage) by the administration of adequate quantities of carbohydrate cannot be over stressed. The diagnosis of persistent hyperinsulinaemic hypoglycaemia of infancy (PHHI) is based on:

- Inappropriately raised plasma insulin levels for blood glucose concentration
- Glucose infusion rate greater than 10 mg/kg per minute to maintain a blood glucose level above 2.6 mmol/l
- Low free fatty acid and blood ketone bodies during hypoglycaemia
- Glycaemic response to glucagons despite hypoglycaemia
- Pancreatic venous sampling. This involves trans-hepatic catheterization of the pancreatic venous system and sampling blood at various levels while maintaining blood glucose levels below 3 mmol/l. The results may show suppression of insulin secretion throughout most of the pancreas with one “hot spot” indicative of a focal lesion or generalised dysregulation (diffuse disease).
- Intra-atrial stimulation test where calcium is injected into the gastroduodenal, superior mesenteric and splenic arteries to stimulate insulin secretion.
- Magnetic resonance imaging, computed tomography and positron emission tomography scans have not been proven to be of diagnostic value.

In essence, the diagnosis is established by measuring insulin in a blood sample taken during hypoglycaemia (blood glucose <2.6 mmol/l). Among lesions, 40–50% are focal and it is important to identify these in order to avoid unnecessarily performing a near-total pancreatectomy. Pre-operative methods of distinguishing focal from diffuse disease include:

It is essential to insert a central venous catheter to monitor blood glucose levels and to provide a reliable route for intravenous glucose administration. Drug treatment consists of diazoxide with chlorothiazide, somatostatin and nifedepine; indication for surgery is the failure to respond to intensive medical treatment.

Figure 36.1

The pancreas is exposed by dividing the vessels in the gastro-colic omentum to expose the head, body and tail of the pancreas.

Figure 36.2

Any suspicious nodules, particularly if the pre-operative studies have indicated focal disease, should be excised and sent for frozen-section histopathological examination.

Figure 36.1

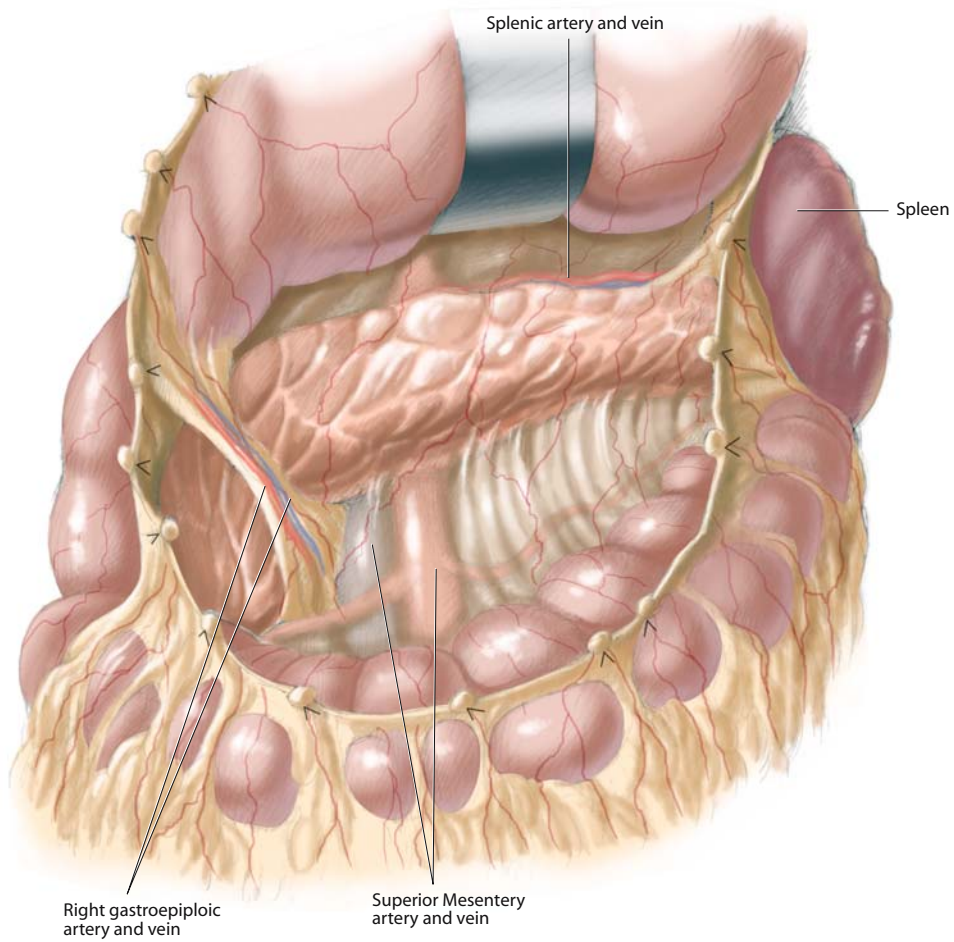


Figure 36.2

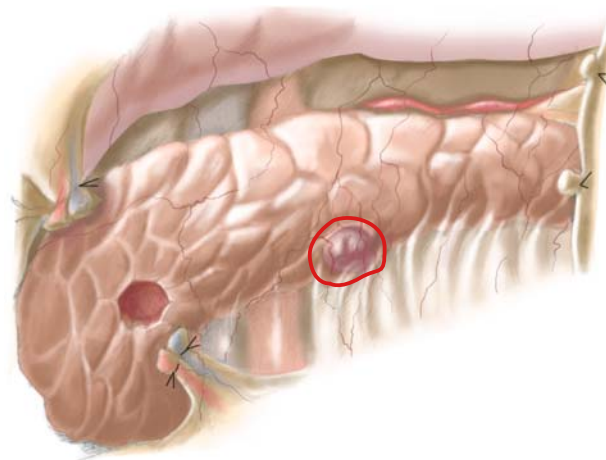


Figure 36.3

Near-total pancreatectomy for diffuse disease starts with mobilizing the tail and body of the pancreas. Bipolar coagulation of short pancreatic vessels is carried out, following which the vessels are divided. Starting at the tail of the pancreas in the hilum of the

spleen, the dissection proceeds towards the neck of the pancreas. The distal part of the tail of the pancreas is divided and the end sent for frozen-section histopathology to confirm the diffuse nature of the condition.

Figure 36.4

In order to perform the resection of the uncinate process, the superior mesenteric vein is retracted to the left and the uncinate process is carefully dissected out from behind the vein until it is completely free from any attachments.

Figure 36.3

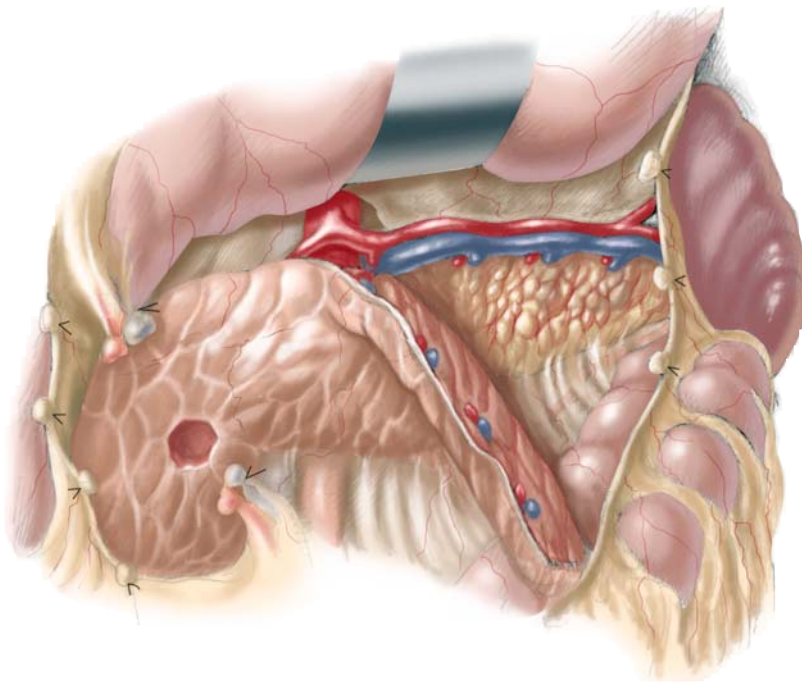


Figure 36.4

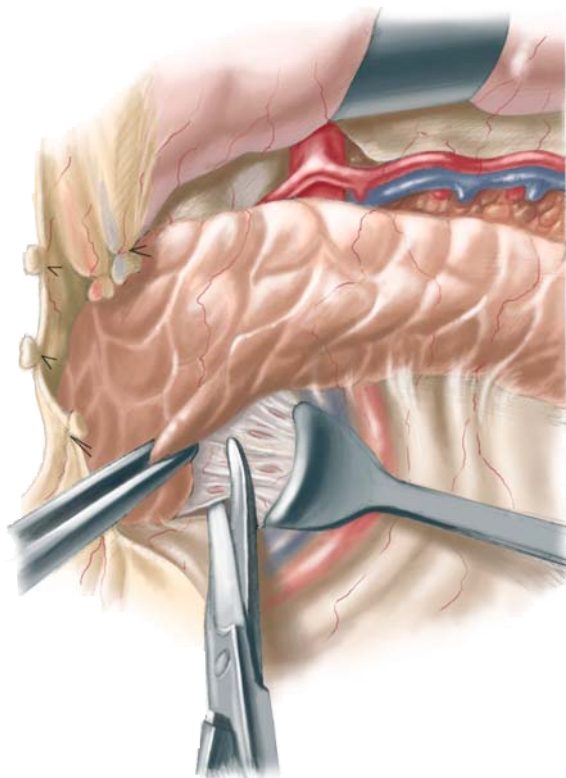


Figure 36.5

The common bile duct is defined above the first part of the duodenum and a soft rubber sling is passed around the duct at this point. From within the C-loop of the duodenum a passage is created behind the first part of the duodenum and the rubber sling is trans-

posed behind the duodenum to appear within the C-loop. The aim of this manoeuvre is to identify the distal course of the common bile duct in or posterior to the head of the pancreas and to preserve its integrity during resection of the head of the pancreas.

Figure 36.6

The resection includes the head, body and tail of the pancreas including the uncinate process, leaving a small sliver of pancreatic tissue within the C-loop of the duodenum and that part of the pancreas that lies around the common bile duct and between the duct and the duodenum. Before closing the abdominal in-

cision it is important to check the integrity of the common bile duct by applying gentle pressure on the gallbladder and observing for any bile leak. A suction drain is left in the pancreatic bed for 24–48 h post-operatively.

Figure 36.5

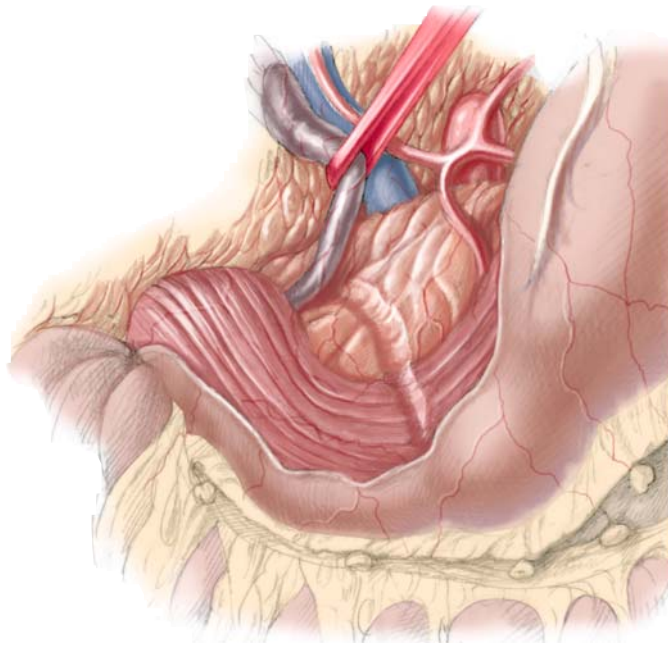
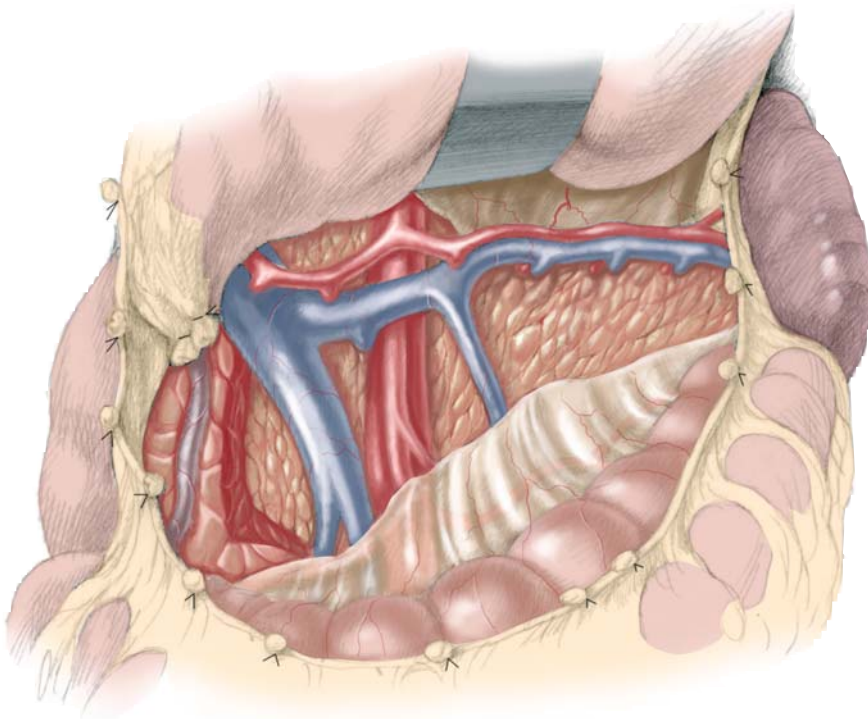


Figure 36.6



CONCLUSION

Intra-operative haemorrhage should not occur and the most frequently encountered problem is trauma to the bile duct. The duct may be injured only in the near-total resections – incidence of 12%. The injury can occur intra-operatively and, if detected, repaired immediately by direct suture or by choledochoduodenostomy. Late stricture from ischaemia can occur

weeks to months post-operatively and these too require drainage by choledocho-enterostomy. Other complications include wound sepsis, adhesion intestinal obstruction and prolonged ileus. The long-term requirements for insulin therapy and exocrine pancreatic replacement need to be carefully assessed.

SELECTED BIBLIOGRAPHY

- Adzick NS, Thornton PS, Stanley CA, Kaye RD, Ruchelli E (2004) A multidisciplinary approach to the focal form of congenital hyperinsulinism leads to successful treatment by partial pancreatectomy. *J Pediatr Surg* 39: 270–275
- Aynsley-Green A, Hussain K, Hall J, Saudubray JM, Nihoul-Fekete C, Lonlay-Debeney P, Brunelle F, Otonkoski T, Thornton P, Lindley KJ (2000) Practical management of hyperinsulinism in infancy. *Arch Dis Child Fetal Neonatal Ed* 82: F98–F107
- de Lonlay P, Fournet JC, Touati G, Groos MS, Martin D, Sevin C, Delagne V, Mayaud C, Chigot V, Sepouz C, Brusset MC, Laborde K, Bellane-Chantelot C, Vassault A, Rahier J, Junien C, Brunelle F, Nihoul-Fekete C, Saudubray JM, Robert JJ (2002) Heterogeneity of persistent hyperinsulinaemic hypoglycaemia. A Series of 175 cases. *Eur J Pediatr* 161: 3–48
- Lonlay-Debeney P, Poggi-Travert F, Fournet JC, Sempoux C, Vici CD, Brunelle F, Touati G, Rahier J, Junien C, Nihoul-Fekete C, Robert JJ, Saudubray JM (1999) Clinical features of 52 neonates with hyperinsulinism. *N Engl J Med* 340: 1169–1175
- McAndrew HF, Smith V, Spitz L (2003) Surgical complications of pancreatectomy for persistent hyperinsulinaemic hypoglycaemia of infancy. *J Pediatr Surg* 38: 13–16

INTRODUCTION

The spleen provides important phagocytic clearance of senescent red cells and platelets as well as entrapment and destruction of encapsulated bacteria, e.g., *Streptococcus pneumoniae* and *Neisseria meningococcus*. This normal clearing mechanism becomes pathological when target red cells or platelets are seen as abnormal by the spleen or when increasing splenic mass sequesters or destroys otherwise normal cells. In childhood, most commonly, congenital spherocytosis, sickle cell disease and auto-immune haemolytic anaemia can precipitate acute haemolytic crises, profound anaemia and jaundice as well as a chronic compensated anaemia from splenic hyperfunction.

Idiopathic thrombocytopenic purpura (ITP) secondary to splenic platelet destruction manifests as petechiae, bruising and, rarely, non-active overt bleeding, e.g., mucous membrane bleeding. Giant splenomegaly can produce combinations of thrombocytopenia, anaemia and possibly leucopenia. Infiltrated processes such as lipid deposition disorders, e.g., Gaucher's disease and malignancy such as Hodgkin disease or juvenile chronic myeloid leukaemia and portal hypertension, can create enormous splenic enlargement, hyperfunction and risk of rupture from minor trauma

Splenectomy will reverse some of the above adverse consequences but at the cost of thrombocytosis and increased senescent red cells (Howell-Jewell bodies on blood smear). With loss of efficient clear-

ance of encapsulated bacteria comes an increased risk of overwhelming post-splenectomy infection (OPSI). In general OPSI is a small risk when compared with the pathological effects of the spleen. In the presence of a dysfunctional reticuloendothelial system, e.g., immunosuppression, malignancy, radiation therapy or in the very young (<5 years), OPSI is seen with greater frequency. Caution is recommended when considering splenectomy in the presence of these clinical states.

Pre-operative immunization is obligatory in elective splenectomy. Commercial vaccinations are available for pneumococcus, meningococcus and *Haemophilus influenzae* and ideally they should be administered at least three to four weeks pre-operatively if possible. Splenic preservation is therefore the surgical objective when laparotomy is needed for uncontrolled splenic bleeding secondary to abdominal trauma.

Splenectomy traditionally is carried out as an open procedure. In recent years, increasingly laparoscopic splenectomy is becoming more widely applied, initially to small spleens and when concomitant cholecystectomy is indicated. With experience moderate or giant spleens can be removed as a complete laparoscopic procedure, or as laparoscopic-assisted or hand-assisted laparoscopic splenectomy (HALS).

Figure 37.1

Splenectomy can be performed in the supine, semi-lateral or lateral positions. Except in the presence of enormous splenomegaly when there is a need to access the splenic hilum early in dissection, it is preferable to utilize gravity and positioning to enhance exposure by encouraging stomach, liver, colon and small bowel to fall away from the operative site. The semilateral and lateral positions with the patient supported and strapped to the operating table allow reasonable intraperitoneal positioning including reverse Trendelenberg during laparoscopic splenectomy. Intra-operative orogastric decompression is imperative to enhance exposure especially at the upper short gastric vessels

With elective splenectomy a transverse subcostal incision with possible extension across the midline allows good exposure and the ability to retrieve the spleen after mobilization and devascularization. Port sites for laparoscopy are somewhat variable but a more commonly used strategy is shown. The dorsal and epigastric ports may change depending on the size of the spleen. The need for other procedures such as cholecystectomy requires additional port placements. The epigastric or right-sided port may be extended to allow the insertion of a hand-assisted device for HALS.

Figure 37.2

Knowledge of the anatomical attachments and vascular anatomy is essential for completing an uncomplicated splenectomy. In particular, the splenic, splenorenal and phrenosplenic ligaments maintain splenic attachment to the posterior abdominal wall and diaphragm. The gastrosplenic ligament above and the gastrocolic ligament below cover the omental bursa, the distal pancreas and splenic vessels.

Initial release of the phrenocolic and splenocolic ligaments allow the splenic flexure and adjacent transverse colon to fall away from the inferior splenic pole. Extending this dissection superomedially, one may encounter the left gastro-epiploic artery before entering the lesser sac. Division of the lower short gastrics creates a window onto the distal pancreas and allows isolation of the splenic artery and vein in its more accessible and tortuous distal segment before entering the splenic hilum. These vessels can be tied or clipped in continuity more proximally if hilar dissection seems difficult, particularly when dealing with an enormous spleen. Continued release of the upper short gastrics completes the anterior dissection.

Medial retraction of the spleen gives good exposure to the splenorenal ligament and the embedded tail of the pancreas. This posterior mobilization is continued with release of the phrenosplenic ligament. In this stage of mobilization, the spleen can be retrieved from the splenic bed onto the abdominal wall for closer inspection of the pancreatic tail and vascular pedicle.

With laparoscopic splenectomy, splenic mobilization usually progresses with a similar anatomical dissection. Following complete release of the short gastric vessels, the dissection returns to detachment of the splenorenal ligament inferiorly only. This allows access to the retropancreatic and hilar plane passing superiorly above the pedicle through the posterior peritoneum of the upper lesser sac. The splenic pedicle is then isolated on all sides leaving the upper splenorenal and phrenosplenic ligaments intact gives better stability and controlled exposure to the pedicle than a floppy and totally mobilized spleen. Early ligation of the splenic vessels above the pancreas is preferable if hilar exposure difficulties are expected, but it is generally not mandatory.

Figure 37.1




Figure 37.2

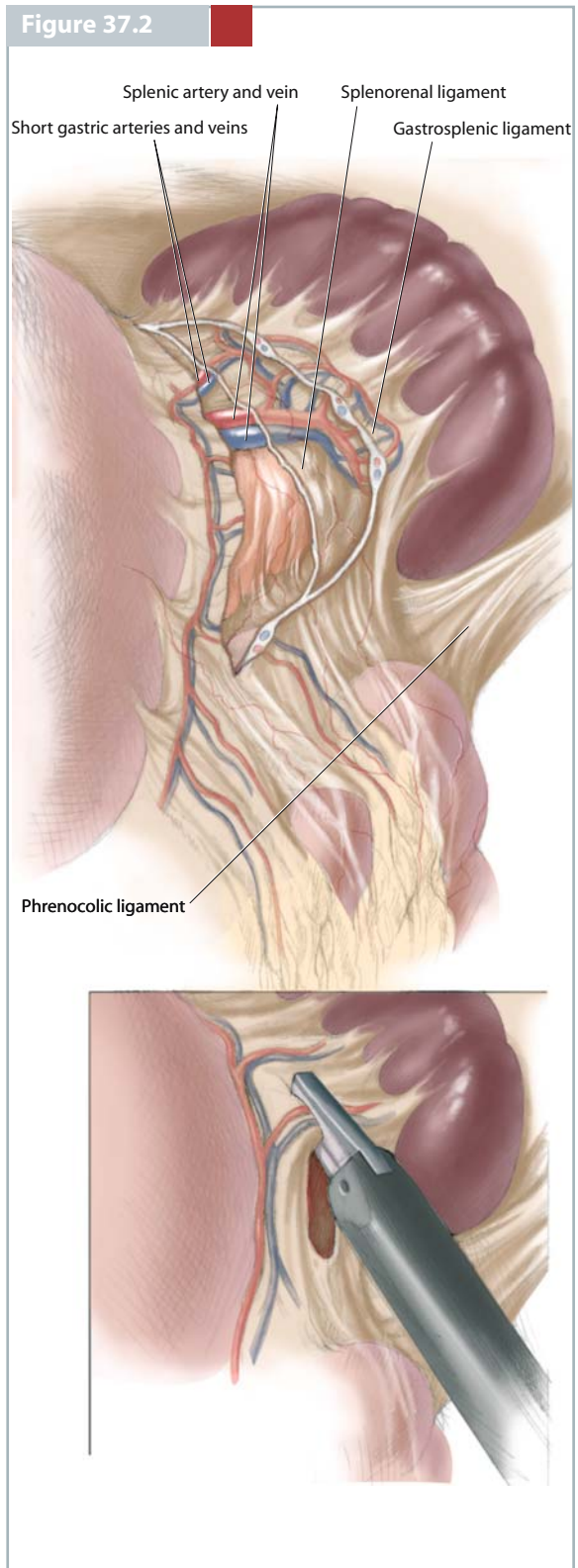


Figure 37.3

The prevalence of accessory spleens at the time of splenectomy has been variably reported to occur between 10 and 31%. Greater than 90% occur in the supra-colic compartment in and around the splenic hilum. In particular, they are found along the line of the distal splenic artery and adjacent hilum, and the gastrosplenic and splenorenal ligament, as well as adjacent to the greater omentum. After entering the abdominal cavity, these sites of accessory spleniculi

need to be sought out early. At splenic mobilization, again one needs to be observant and remove any accessory splenic tissue encountered. This will avoid possible recurrent haemolysis or thrombocytopenia at a later stage resulting from hypertrophy of the spleniculi.

In most patients (63.3%), there is only one accessory spleen present, with 17% having three or more to find.

Figure 37.3

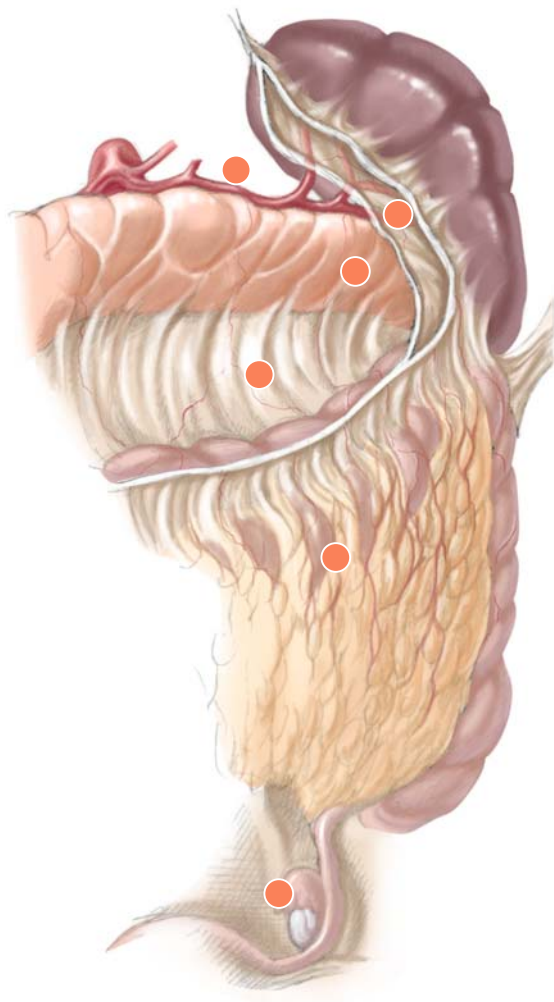


Figure 37.4

In the presence of a traumatic splenic injury with continuing uncontrolled haemorrhage, rapid mobilization and isolation of the pedicle is the priority to reduce continued blood loss and maximize the chance of splenic preservation. The incision may need to be modified depending the possibility of other visceral injuries. After rapid entry into the peritoneal cavity, large clots and free blood are removed and air is introduced into the left subphrenic space from which often the spleen becomes more mobile descending closer to the wound. The splenic mass and fossa is packed with surgical sponges. With medial retraction of this splenic mass, lateral inci-

sion of the splenorenal and upper phrenosplenic ligaments superiorly and medially allows greater mobility. Delivery of the inferior splenic pole into the wound can achieve progressive retrieval of the spleen onto the anterior abdominal wall taking care not to avulse the upper short gastric vessels or damage the splenic flexure. In this position the potential for splenic salvage can be assessed. Polar devascularization may be required or direct suture with haemostatic gauze and/or omental plug may be necessary to preserve the integrity of functioning splenic tissue.

Figure 37.5

Early splenic devascularization by splenic vessel ligation through the lesser sac is generally considered safe practice in elective splenectomy and giant splenomegaly, or where there is expected dense diaphragmatic and gastric adherence to the spleen. Alternatively, initial anterior and posterior ligamentous splenic release and subsequent pedicle ligation can be applied also in the setting of elective splenectomy but is definitely indicated in the presence of splenic trauma. Laparoscopic splenectomy can be performed by either above methods with the polar vessels either divided individually with clips or suture ligation as well as with a linear stapling device

after initial mobilization of the tail of the pancreas. Care must be taken to avoid splenosis during splenic retrieval, particularly in the presence of haemolytic disorders. Laparoscopically, the mobilized and devascularized spleen is placed in a sturdy, impermeable bag with the open end delivered through the retrieval port site. The wound edges are protected while the specimen is fragmented and removed. Devices such as Endocatch II (Tyco Healthcare, Mansfield, MA, USA) allow somewhat easier insertion of the spleen into the retrieval pouch.

Figure 37.4

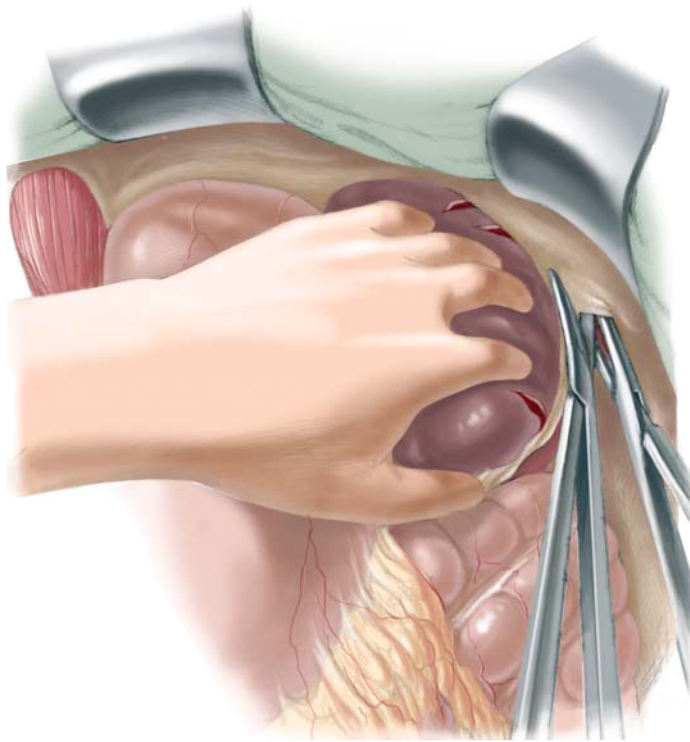
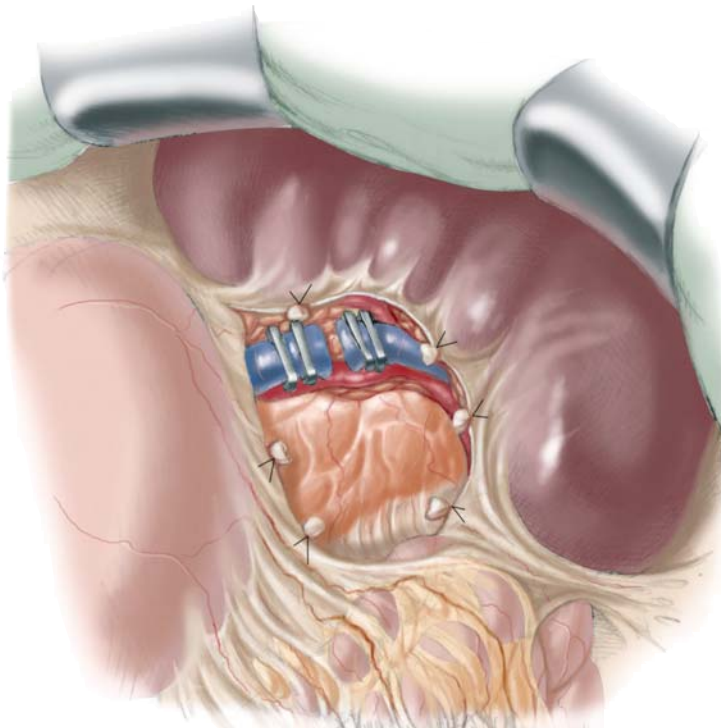


Figure 37.5



CONCLUSION

Depending on the size of the spleen, the circumstances at the time of removal and the need for concomitant cholecystectomy, post-operative paralytic ileus from the intraperitoneal and retroperitoneal dissection may be expected. Nasogastric decompression during the perioperative period may need to be extended for 24–48 h post-operatively. Persistent ileus and continuing vomiting raises the suspicion of a possible pancreatic injury. Slow mobilization and inadequate diaphragmatic movement predisposes to left lower lobe pulmonary collapse. Subphrenic collections can similarly attract a sympathetic pleural effusion and pulmonary infection. Finally, injury to the stomach, although very uncommon, can evolve where extensive adhesions between the greater curve of the stomach and an inflammatory spleen are encountered.

OPSI should be minimized by pre-operative immunization, intra-operative and continued post-operative antibiotic prophylaxis. In the long term,

any procedures such as dental, gastrointestinal or genitourinary surgery that increases the risk of potential sepsis needs antibiotic prophylaxis for the duration of the operation and immediate convalescence. Rebound thrombocytosis is generally not of clinical concern in childhood in the presence of pre-operative ITP. In more than 90% of cases, it would be expected to achieve complete reversal of symptomatic thrombocytopenia and return of the platelet count to the normal range or above. Unfortunately, in the presence of more non-specific haemolytic disorders, 60–70% will recover with the majority of the rest having some transient recovery of platelet count and with bleeding tendency remaining subclinical.

Clinically significant recurrent thrombocytopenia needs further evaluation for missed accessory spleens. Contrast computed tomography or red cell labelled-isotope scans are suggested with consideration being given to a second-look laparotomy or laparoscopy being undertaken.

SELECTED BIBLIOGRAPHY

- Curtis GM, Movitz D (1946) The surgical significance of the accessory spleen. *Ann Surg* 123: 276–298
- Eraklis AJ, Filler RJ (1972) Splenectomy in childhood: a review of 1413 cases. *J Pediatr Surg* 7: 382–388
- King H, Shumacker HB Jr (1952) Splenic studies. 1. Susceptibility to infection after splenectomy performed in childhood. *Ann Surg* 136: 239–242
- Poulin EC, Thibault C (1993) The anatomical basis of laparoscopic splenectomy. *Can J Surg* 36: 484–488
- Rescorla FJ (2002) Laparoscopic Splenectomy. *Semin Pediatr Surg* 11: 226–232

Spina Bifida and Hydrocephalus

INTRODUCTION

Disorders of neural tube closure are generally either myelomeningocele or the less common and less severe meningocele. Although antenatal screening and the widespread use of peri-conceptual folic acid have reduced the incidence of this debilitating condition it remains a significant part of the pediatric surgeon's workload. While both types are associated with vertebral body defects the severity of vertebral anomaly is much greater in patients with myelomeningocele. Similarly, the extent of associated neurological, bladder, bowel and lower limb abnormalities are significantly greater in this group.

In myelomeningocele the vertebral arches and overlying vertebral fascia is absent over a variable number of vertebral segments. The spinal cord lies superficially at skin level and cerebrospinal fluid usually leaks from the exposed neural plaque. Neurological development to the lower limbs, the bladder and the bowel is incomplete and virtually all children with myelomeningocele have some degree of paralysis of the lower limbs, with sensory loss in addition. Muscle power is imbalanced and results in flexion deformity of the hips and hyperextension of the knees. Bilateral hip dislocation and club foot deformity are common associated problems. Innervation to the bladder and bowel is abnormal resulting in problems with continence and more typically a neuropathic bladder. The resultant morbidity is significant and affects normal ambulation, preservation of renal function, and social continence. The majority of patients have the associated Arnold-Chiari malformation resulting in significant hydrocephalus requiring a ventriculo-peritoneal shunt in approximately 90% of children.

In meningocele patients the spinal cord is well covered by an epithelial lined sac. This sac communicates with the arachnoid space and contains cerebrospinal fluid (CSF). Leakage from this sac is rare, as are serious associated abnormalities. Limb innervation is normal and these patients look forward to normal activities. Screening for bladder function is required, however, as a small percentage are at risk of developing a neuropathic bladder.

While the aetiology is not fully known there is a clear genetic link in those of Celtic ancestry. There is an established link between dietary folic acid and neural tube defects and high doses taken peri-conceptually confer significant protection.

There are serious ethical factors to consider before any child with a myelomeningocele undergoes surgical closure. These relate to the quality of life, the anticipated life expectancy of the child and other factors beyond the scope of this chapter. While the majority of children with myelomeningocele should undergo surgical closure within the first 2 days of life there are a minority with such severe deformity that primary closure may not be indicated. These patients are usually managed by supportive nursing care and closure performed later if the child survives. Before closure, informed consent is obtained from both parents. The lesion is kept clean with chlorhexidine soaks and cleaned of meconium frequently. A pre-operative muscle charting is obtained and a cranial and renal ultrasound performed. Consultations are obtained from physiotherapy, orthopedic and social workers where necessary.

Figure 38.1

Following general anaesthesia and insertion of an endotracheal tube the patient is turned prone and cotton (Gamgee) supports placed under the pelvis and chest. It is important to place additional supports beneath each foot. It is not necessary to have blood available for this procedure but most surgeons

would have a group and hold order with the laboratory. A neonatal diathermy pad is usually applied to the abdomen or chest. A warming bear-hugger is routinely used. Bipolar diathermy should be used throughout. A swab for culture may be obtained at this point.

Figure 38.2

The skin is prepped with a povidone iodine solution and the lesion with chlorhexidene and draped with generous margins to facilitate additional skin dissection if required. An incision is made at the lowermost portion of the sac using a sharp scissors or scalpel. This incision is carried cranially staying away from the neural plaque, which should not be handled where possible, and close to the sac-skin junction. Incision into the sac results in a release of CSF and some bleeding, which is easily dealt with using bipolar diathermy. Nerve roots and blood vessels are now seen traversing the sac and disappearing anteriorly through the dural layer, and they should be preserved. The dural layer is clearly visible as a whitish fibrous layer. The sac is elevated taking care not to traumatize the neural plaque and the skin excised completely from the plaque. Bleeding from the neural edge is dealt with using bipolar diathermy and with minimal handling of the plaque itself. At intervals, chlorhexidene soaks may be applied to the area. Tubal reconstruction of the plaque is rarely indicated.

Figure 38.3

The plaque will now be seen to lie on an easily recognizable dural layer. This fibrous layer is incised as far laterally as possible and the layer carefully dissected from the underlying fascia. This dissection is carried medially until the nerve roots come into view. Epidural veins may prove difficult at this point but these can be controlled by bipolar diathermy.

Figure 38.1

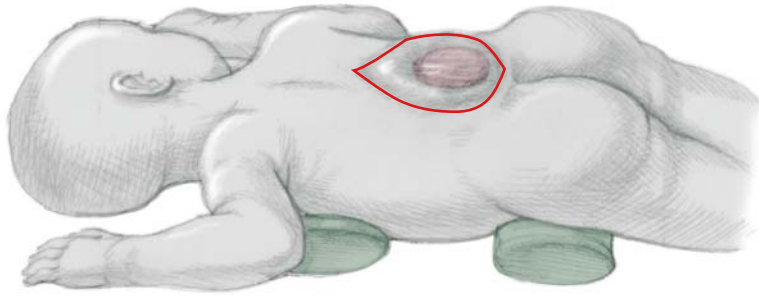


Figure 38.2

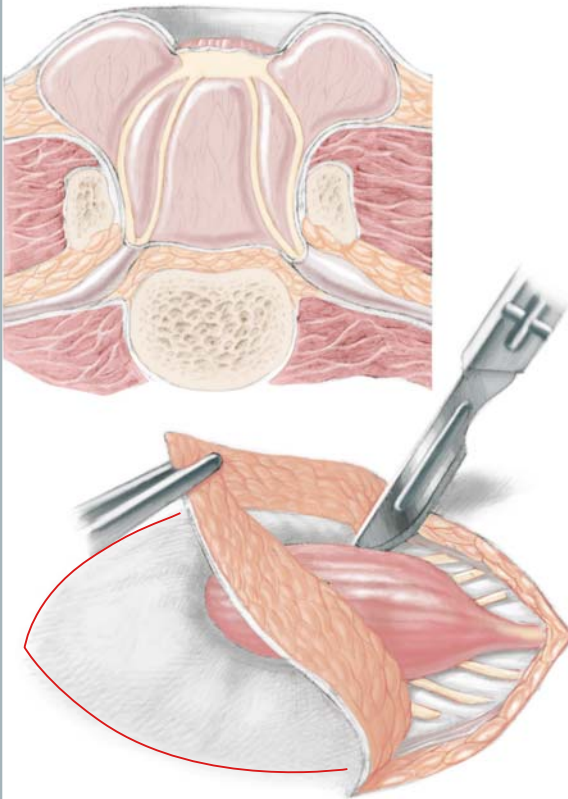


Figure 38.3

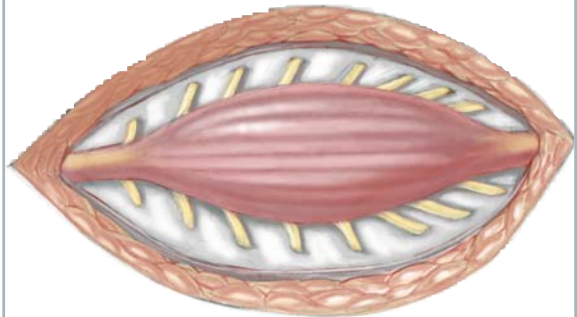


Figure 38.4

The mobilized dural layer is now tubularized over the exposed neural plaque using a running suture of 6/0 absorbable suture on an 11-mm round-bodied needle. A watertight closure is the expected aim of closure. Occasionally it is not possible to complete the dural tube completely, and a small portion of vertebral fascia is used to achieve closure. This is preferable to compromising the plaque. A small suction drain is placed to lie lateral to the dural tube and

exited far laterally. This deals with any leakage of CSF, which is usually short lived. Troublesome leakage usually responds to the insertion of a ventriculo-peritoneal shunt.

Where possible the dural tube is reinforced using an additional fascial covering obtained by mobilizing the fascia from the underlying muscle. It is usually impossible to cover the dural tube completely with fascia especially at the lower end.

Figure 38.5

The subcutaneous layer is approximated using a 3/0 absorbable suture. It is nearly always possible to close the skin layer using interrupted (4/0) sutures, but occasionally this requires considerable skin

undermining and rarely the use of lateral releasing skin incisions or complex flap repairs. The skin closure is supported with wound strips and a dressing applied.

Figure 38.4

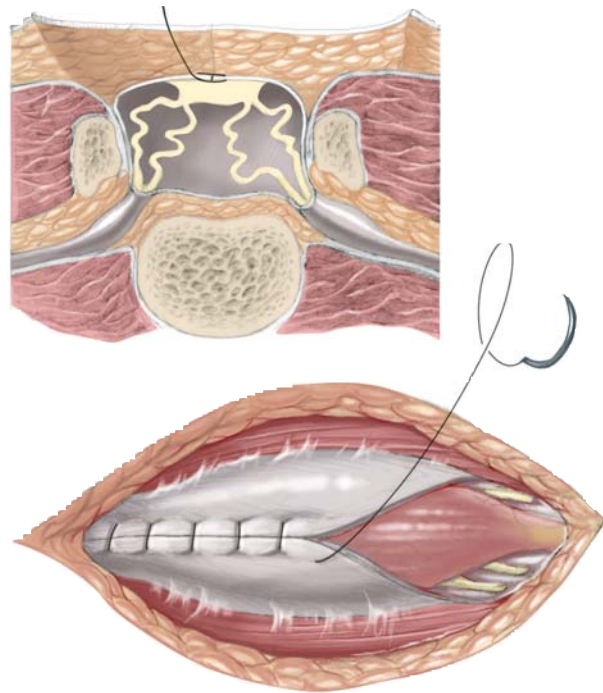
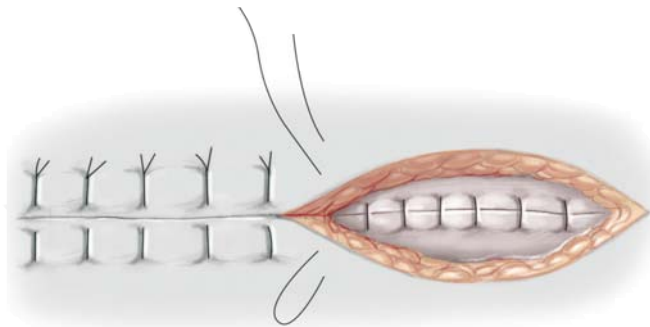


Figure 38.5



CONCLUSION

The baby is nursed prone or in a lateral position. Careful attention is paid to keeping the area clean. Feeds are not restricted. Weekly estimates of head circumference are performed and this is supplemented with cranial ultrasound to monitor progress of the associated hydrocephalus. A ventriculo-peritoneal shunt is inserted when the head circumference rises precipitously or when the ventricular diameter increases beyond 50–60% of the diameter of the skull.

Other surgical considerations include:

- Associated vertebral kyphosis may occasionally require an osteotomy to facilitate closure in the primary setting. This is more likely with lesions treated conservatively initially and back closure performed as a secondary event.
- Meningocele is closed as an elective procedure. Since there is no exposure of neural elements, closure is straightforward with sac excision and closure over a drain.

Patients with spina bifida pose serious problems to the family and the medical profession. They therefore need a multidisciplinary approach for their management with special emphasis on monitoring of renal and bladder function, provision of physiotherapy services both in the community and hospital, proper evaluation of hearing and visual acuity, orthopedic review and assistance with mobility either using callipers or modified wheelchair. In addition, the mobilization of local pediatric and medical services with input from social services is vital to optimize their ultimate quality of life. Quality of life in these patients can be actively enhanced using clean intermittent catheterization and bowel washout programmes.

SELECTED BIBLIOGRAPHY

- Atwell JD (1998) Spina bifida. In: Atwell JD (ed) Paediatric surgery. Arnold, London, pp 279–289
- Li V, Dias MS, Azizkhan RG (2003) In: Ziegler MM, Azizkhan RG, Weber TR (eds) Operative paediatric surgery. McGraw-Hill, New York, pp 1009–1032
- Muraszko KM (1995) Myelomeningocele. In: Spitz L, Coran AG (eds) Pediatric surgery. Chapman & Hall, London, pp 787–795
- Puri P, Surana R (2003) Spina bifida and encephalocele. In: Puri P (ed) Newborn surgery. Arnold, London, pp 761–774

INTRODUCTION

Hydrocephalus is defined as an excessive amount of cerebrospinal fluid (CSF) under increased pressure with abnormal enlargement of the ventricular system. The incidence is approximately 0.4 to 2.5 per 1,000 live births. CSF is produced mainly by the choroid plexuses of the ventricular system and is circulated through the foramen of Monroe to the third ventricle and then through the aqueduct of Sylvius into the fourth ventricle. The CSF enters the subarachnoid space through the foramina of Luschka and Magendie to the cisterna magna, and finally reaches the subarachnoid space over the surface of the brain. It is absorbed through the arachnoid villi into the blood stream. The volume of CSF produced per day is age-dependent, and neonates produce approximately 25 ml/24 h whereas adults produce approximately 700 ml/24 h. The intraventricular pressure at rest varies from about 0 to 10 cmH₂O.

The aetiology of hydrocephalus can be obstruction to the flow of CSF, resulting in non-communicating hydrocephalus, and overproduction of CSF or failure of its re-absorption, described as communicating hydrocephalus. The pathological process that causes hydrocephalus may be congenital or acquired. Several conditions can result in hydrocephalus, for instance, congenital malformations, neoplasm, bacterial meningitis, prenatal infection with toxoplasmosis, listeriosis or cytomegalovirus, subarachnoid or intraventricular haemorrhages, especially perinatal, and overproduction of CSF by choroid plexus papillomas. The three most important malformations that cause congenital hydrocephalus due to obstruction of the CSF flow are aqueductal stenosis, Arnold-Chiari II malformation, and Dandy-Walker malformation. Aqueductal stenosis accounts for about 15% of cases of hydrocephalus and occurs in several anatomical forms. Myelomeningocele, when combined with Arnold-Chiari II malformations, is associated with hydrocephalus in about 90% of cases. These malformations lead to CSF flow obstruction due to herniation of the medulla oblongata and cerebellar tonsils and vermis through the enlarged foramen magnum and caudal displacement and compression of the fourth ventricle. The Dandy-

Walker malformation results from lack of development of foramina of Luschka and Magendie, and comprises an absence of the cerebellar vermis, a distended fourth ventricle and an enlarged posterior fossa. Hydrocephalus can be an isolated finding but it can also be part of various malformation syndromes, such as Meckel-Gruber, Walker-Warburg, and X-linked hydrocephalus.

The clinical features of hydrocephalus in neonates and infants comprise enlargement of the head, which can easily be overlooked in mild cases unless the head circumference is measured repeatedly. Also, the shape of the head becomes abnormal. The anterior fontanelle is large and may be bulging, cranial suture separation may be palpated, and the scalp veins may be distended. The “sunset sign” may be present. The commonest symptoms in infants and young children with hydrocephalus are vomiting, behavioural changes, drowsiness and headache. Other symptoms comprise failure to thrive, irritability, delayed motor and social development, and mental retardation.

Ultrasound, computed tomography (CT), and magnetic resonance imaging (MRI) distinguish hydrocephalus from other causes of macrocephaly. Hydrocephalus is frequently diagnosed with antenatal ultrasound. Ultrasound is also the method of choice for serial examinations of premature newborns to detect intracranial haemorrhages and hydrocephalus. CT and particularly MRI are useful to show the detailed anatomy and reveal the cause of hydrocephalus as well as associated abnormalities and distribution of neoplasms. The investigation of the patient with hydrocephalus also comprises a TORCH screen and chromosomal analysis if a prenatal infection or a chromosomal abnormality is suspected. The patient should also undergo an ophthalmological examination, and associated anomalies such as a cardiovascular anomaly should be excluded.

Mild hydrocephalus caused by intracranial haemorrhage can be monitored by repeated measurement of head circumference, ultrasound scans and clinical signs of progressive hydrocephalus, and it usually resolves. On the other hand, in cases with

progressive ventricular dilatation, abnormally increased head circumference and clinical features of increased intracranial pressure, the condition requires treatment by surgical diversion of CSF. Today ventriculo-peritoneal shunts are the primary option for infants and children. Ventriculo-atrial shunts are only used under certain rare circumstances, because of the risk of serious sequelae such as thrombosis, pulmonary embolism and septicaemia. Many different shunt systems are available. We prefer to use a system with a programmable valve. In recent years endoscopic third ventriculotomy has become an option for treatment of aqueductal stenosis.

However, its role as an alternative to CSF shunts still has to be determined.

The pre-operative routines are important to reduce the risk of *Staphylococcus epidermidis* shunt infections to a minimum. The patient is carefully washed at least three times during the last 24 h before the operation. The first time ordinary shampoo is used for the hair and the next two times Hibiscrub is used. Scurf is treated if necessary. The hair is carefully shaved in the theatre. Cloxacillin is administered as prophylaxis at induction of general anaesthesia and post-operatively another two doses are given.

Figure 39.1

The child is placed in a supine position on the operating table with the head turned to the left if the shunt is to be placed on the right side. The right shoulder and neck are elevated to stretch the skin and avoid creases that make the subcutaneous tun-

neling of the abdominal catheter difficult. The scalp should be shaved and well prepared. The placement of the incision depends upon whether a frontal or parieto-occipital approach is selected for ventriculo-peritoneal shunting.

Figure 39.2

Frontal approach has several advantages. Less brain is traversed than with the posterior approach and distance to the ventricle is shorter making cannulation of very small ventricles easier. The disadvantage of frontal approach is that a longer subgaleal tunnel is required and an extra occipital incision is needed for tunnelling. The sagittal and coronal sutures are marked as well as the place of entrance of the ventricular catheter, which should be located 2 cm from midline and 2 cm anterior of the coronal suture. In neonates and infants with massive hydrocephalus the catheter will be placed in the fontanel. In a majority of cases, the ventricular catheter will be inserted at the edge of the fontanelle or through the frontal bone. Mark the scalp incision, and avoid the situation that any part of the shunt system will lie under the scar. Prepare the child and drape it in a sterile fashion. The entire operation field is covered with a plastic sheet to avoid contact between the shunt system and the skin. The skin is very thin in neonates, particularly in preterm babies, and the blood supply is vulnerable. Hence, infiltration with xylocaine and adrenaline is not used. Bipolar diathermy is preferred for haemostasis. The flap is carefully dissected

from the underlying galea and a subcutaneous stay suture is put in the flap. When the entrance is at the edge of the fontanel the galea is opened and a circular hole is nipped in the bone edge. In the older children with bone under the flap the periosteum is removed with a raspator at the site of entrance of the ventricular catheter. A drill hole is made for the catheter, while saline is irrigated. The bone is very thin in neonates and infants, and, hence, it is important to be careful. The dura is coagulated using a fine-pointed forceps and a small opening is made. There are different ventricular catheters that are straight or pre-bent. In the neonates and infants, a pre-bent catheter is recommended. From a CT scan, the optimal intracranial length of the ventricular catheter can be estimated. The ventricular catheter is introduced through the small opening to get a snug fitting and avoid leakage of CSF. The direction of the ventricular catheter is chosen so that the tip will be located in the anterior horn of the right ventricle. The catheter is passed through the brain perpendicular to the skull aimed at the inner canthus of the ipsilateral eye.

Figure 39.1

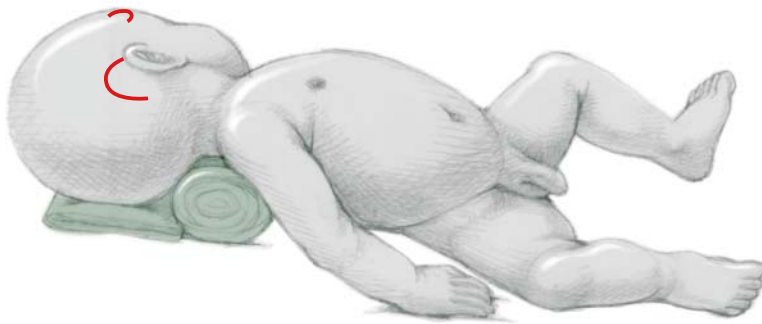


Figure 39.2

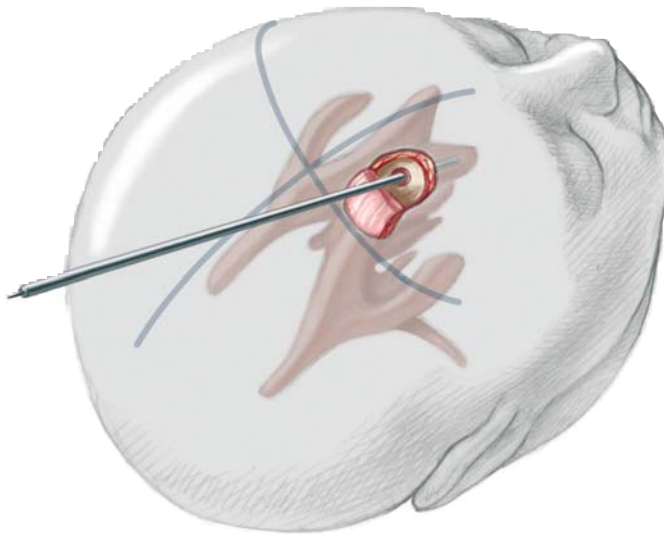


Figure 39.3

In a parieto-occipital approach, the scalp incision is a semicircular one lying well behind the posterior parietal eminence. In choosing the site of the burr-hole, care must be taken that at the end of the operation no part of the shunt system should lie under the wound, which would predispose to breakdown of the

wound and infection. The burr-hole is placed 3 cm above and behind the ear. The catheter is passed parallel to the sagittal suture, aimed at the glabella. The length of the ventricular catheter should allow the tip to extend 1 cm anterior to the coronal suture in order for the catheter to be placed in the anterior horn.

Figure 39.4

The abdominal incision is made 2 cm below the right costal margin over the rectus abdominus muscle.

The muscle fibres are split longitudinally and the peritoneal cavity opened.

Figure 39.3

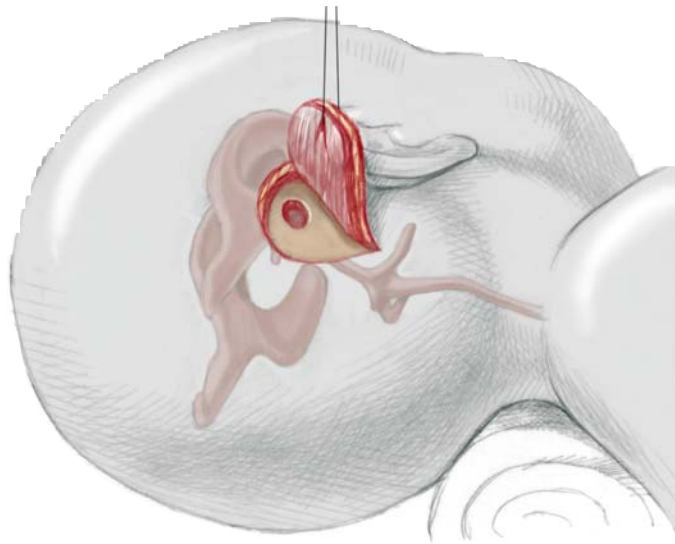


Figure 39.4

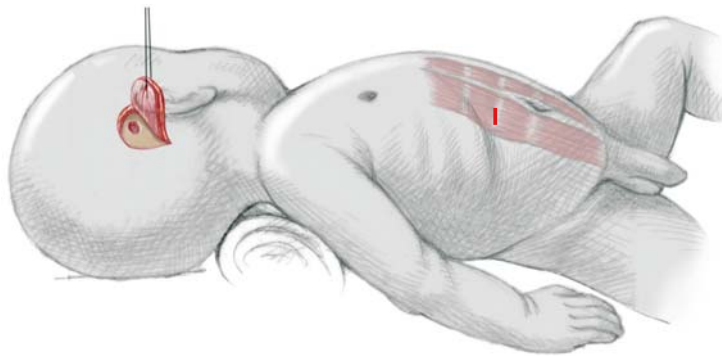


Figure 39.5

The majority of surgeons use a low-pressure uni-shunt for ventricular peritoneal drainage. The abdominal catheter tunneller is pushed from the scalp incision subcutaneously to the abdominal inci-

sion. The passage over the clavicle is controlled to avoid skin contusion or perforation. The stylet is withdrawn and the peritoneal end of the catheter is pushed through the tunneller.

Figure 39.6

The ventricular catheter is introduced into the lateral ventricle in the direction of the glabella and the stylet is withdrawn. The valve is pressed to test the function. CSF should be seen dripping distally. The ventricular end of the shunt is secured to the periosteum with two interrupted 5/0 sutures. The scalp incision is closed with absorbable subcuticular sutures.

Once again the system is tested before the abdominal catheter is inserted through the small opening into the peritoneal cavity. At least 35–40 cm of the catheter can be placed in the abdomen without any problems. The peritoneum is closed in a watertight manner, as well as the different layers of the abdominal wall. Absorbable sutures are used for the skin closure.

Figure 39.5

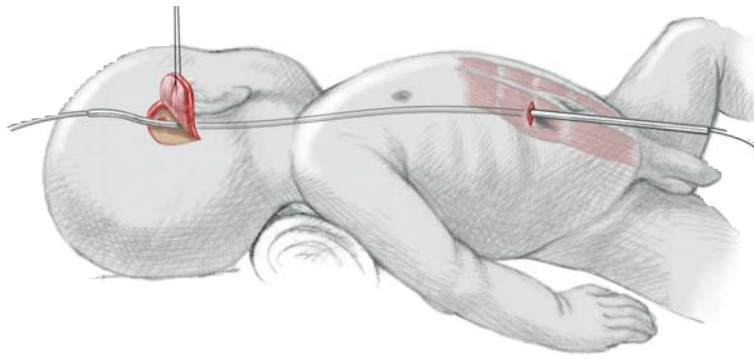
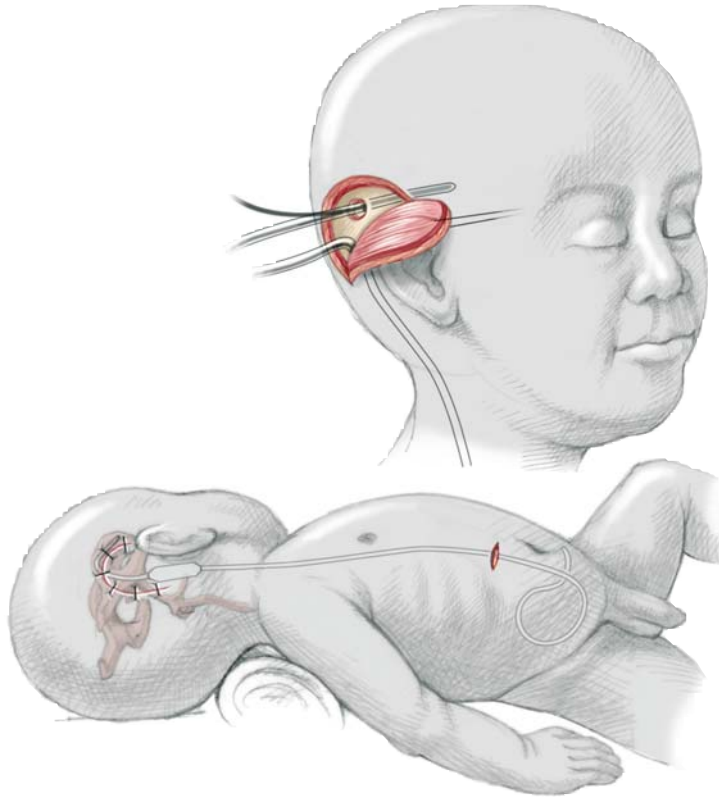


Figure 39.6



CONCLUSION

Technical advances have made it possible to develop shunt systems that are very sophisticated compared with those initially produced more than 40 years ago. The programmable valves can be non-invasively adjusted to a suitable pressure giving the brain optimal conditions for development. However, there is still a risk of shunt malfunction due to infection, catheter obstruction, improper placement of the catheters, and short or disconnected catheters.

Despite careful preparation and antibiotic prophylaxis there is a risk of peri-operative infections with, for example, *Staphylococcus epidermidis*, *Staphylococcus aureus* or *Propionibacterium* species. Neonates and infants are more sensitive to infections and can have haematogeneous infections with origin in the urinary tract or respiratory tract. The incidence of infections has been reported to range from 10 to 15%. The infections are treated by removal of the infected shunt system external ventricular drainage, and intravenous as well as intraventricular antibiotics before a new system can be inserted.

In spite of the introduction of programmable valves problems due to overdrainage are encountered, resulting in slit ventricles. An anti-siphon device can be inserted between the valve and the abdominal catheter to reduce this problem. There are also valves available that include an anti-siphon mechanism.

Previously the incidence of re-operations due to shunt malfunction was very high. Today the incidence has decreased because of the awareness of strict pre-and peri-operative routines, antibiotic prophylaxis and also the use of longer catheters.

The long-term outcome of children with hydrocephalus depends on many factors, such as the severity and duration of the ventricular dilatation, the aetiology of the hydrocephalus, associated intracranial malformations and whether severe infections have occurred.

SELECTED BIBLIOGRAPHY

- Dauser RC (1995) Ventricular shunting procedure. In: Spitz L, Coran AG (eds) Pediatric surgery. Chapman & Hall, London, pp 797–806
- Drake JM, Kestle JRW, Tuli S (2000) CSF shunts 50 years on – past, present and future. *Child Nerv Syst* 16: 800–804
- Fitzgerald RJ (2003) Hydrocephalus. In: Puri P (ed) Newborn surgery. Arnold, London, pp 775–783
- Peacock WJ (1998) Management of spina bifida, hydrocephalus, central nervous system infections, and intractable epilepsy. In: O'Neill JAB Jr, Rowe MI, Grosfeld JL, Fonkalsrud EW, Coran AG (eds) Pediatric surgery, 5th edn. Mosby Year Book, St. Louis, pp 1852–1855
- Reinprecht A, Dietrich W, Bertalanfy A, Czeck (1997) The Medos Hakim programmable valve in the treatment of pediatric hydrocephalus. *Child Nerv Syst* 13: 588–594

Andrew B. Pinter

INTRODUCTION

Dermal sinus represents an abnormal communication between dermis and intravertebral or intracranial structures. They are remnants of incomplete neural tube closure and are lined with epithelium. Although dermal sinus can occur from the upper cervical region to the midsacrum, it is most commonly found in the lumbar or lumbosacral area and may connect at any point with the central nervous system.

Some dermal sinuses end blindly within the soft tissues superficial to the underlying lamina; however, most penetrate the vertebral canal and enter the dura immediately beneath, or to the cutaneous lesion. From this point the dermal sinuses extend cephalad to a variable degree, ending as high as the conus medullaris.

The tract leading to the vertebral column or skull may have a cystic termination (dermoid, epidermoid) or may be associated with spinal cord tethering. The cystic expansion may act as any other mass lesion and affect neurological function by local compression, or it may obstruct the normal circulation of cerebrospinal fluid. A small sinus ostium may be overlooked on physical examination, and frequently the diagnosis is not considered until a child has suffered unexplained or recurrent meningitis, rapid spinal cord compression, or evidence of a rapidly expanding intracranial mass. Therefore, the entire midline area of the skin from the skull to the sacrococcygeal region should be examined carefully for evidence of a dermal sinus. Cutaneous anomalies are frequently present and include skin dimples, hairy patches and nevi skin tags, subcutaneous lipomas or haemangiomas. Bacterial infection can occur through the sinus because all midline skin pits above the intergluteal fold are assumed to communicate with the intrathecal sac.

Recommended investigations include conventional X-ray films of the lumbosacral spine which may demonstrate spina bifida or dysraphic lesions, including vertebral anomalies or diastematomyelia. The usefulness of plain radiographs may be limited because of immature calcification in children less than 18 months of age. Ultrasonography readily demonstrates the subcutaneous tract, intraspinal inclusion tumours, and diminished cord pulsations. The infection risk from probe insertion or injection of radiographic contrast agents into dermal sinuses is not justified and provides little diagnostic information. Invasive contrast studies have largely been replaced by magnetic resonance imaging (MRI), which visualizes in three dimensions the extra spinal tract path, inclusion tumours and other malformations associated with spinal cord tethering, and provides greater sensitivity than contrast-enhanced tomography (CT) and non-invasively confirms the diagnosis of dermal sinuses and associated malformations. In patients with abnormal neurologic examination, bladder function is studied with renal/bladder ultrasound, urodynamic studies, and dynamic contrast voiding studies.

It is important to distinguish between the sacral dermal sinus and pilonidal sinus. Dimples below the top of the intergluteal crease are sacral pits. They end blindly and superficially and, regardless of their depth, never extend intraspinally; therefore, they require no investigation other than physical examination. They are encountered in nearly 5% of newborns and although they are present from birth, they rarely manifest themselves before adult life. In later years, these small pits or dimples may become pilonidal sinuses or abscesses.

Figure 40.1

After induction of general anaesthesia and placement of a Foley catheter into the bladder, the patient is positioned prone with lateral padded rolls supporting the chest and abdomen. The arms of children less than 2 years of age are best supported alongside the trunk, whereas in older patients elevation above the shoulder positions the surgeon closer to the patient. Betadine solution is used to prepare the skin from the intergluteal fold to many spinal lev-

els above the sinus tract. Peri-operative administration of intravenous antibiotics is strongly recommended.

An elliptical skin incision encircling the sinus opening, and any abnormal skin surrounding it, is made to excise fully the dermal sinus. Purulent material or drainage should be cultured in aerobic and anaerobic medium.

Figure 40.2

The subcutaneous tissue is divided to expose the fascial defect, and the sinus stalk is circumferentially dissected. Cephalad to the stalk, the paraspinal muscles are elevated with electrocautery in a subperios-

teal fashion from the first intact spinous process and lamina. Preparations must be made to continue bone removal across several laminae until the site of attachment to the dura is identified.

Figure 40.1

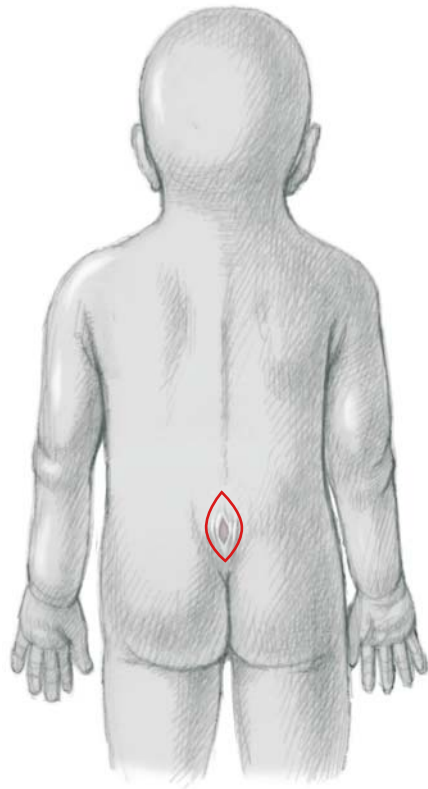


Figure 40.2

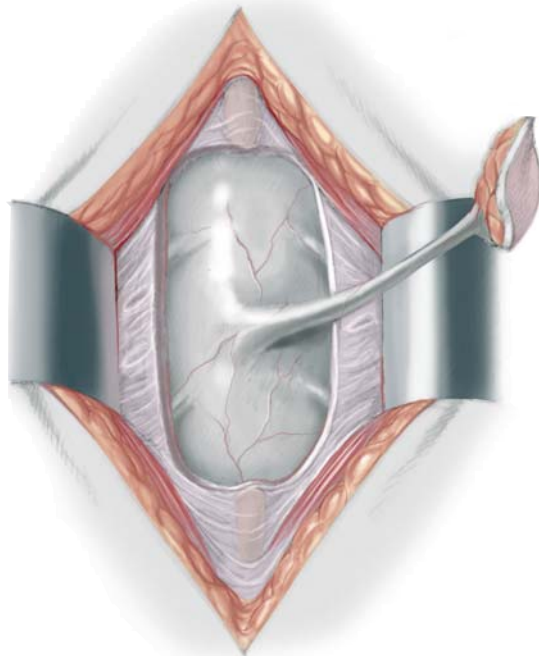


Figure 40.3

If imaging studies indicate that the lesion penetrates deeper than the fascia or if this is observed intra-operatively, the dissection should proceed along the tract until its termination is reached.

The dura is opened with an elliptical incision encompassing the tract. Some sinus tracts abruptly end with dural attachment, which is readily apparent after dural opening. In these cases after confirming normal intradural anatomy, the dura is closed and the wound closed in layers. When the stalk continues

and intradural lesions such as a dermoid or epidermoid cyst, tethered spinal cord are present then the dissection must proceed into intradural space. Further dissection is performed with loop or microscope magnification. Dissection of the stalk from this disordered glial mass may be accomplished using sharp microsurgical technique.

Intra-operative ultrasonography is useful for identifying syringomyelia or intramedullary dermoid at site of stalk attachment.

Figure 40.4

Regardless of the attachment anatomy, a comprehensive inspection should be carried for arachnoid adhesions, dermoid tumours, and a thickened filum terminale. Dermoid inclusion tumours are frequently multiple and can be solidly adherent to the filum and nerve roots within the cauda equina, especially when meningitis has occurred.

Intradural cysts are completely removed, without opening if this is possible and does not endanger nervous elements. Intraspinous and adherent intradural cysts are emptied of their contents and as much as possible removed. However, attempts to remove the hard fibrous capsule densely adherent to neural tissue or capsule of infected intraspinal cysts are fruitless and may lead to additional and avoidable cord or root injury. Duraplasty performed if necessary and the muscles and skin are closely approximated without drainage. Drainage of an extradural abscess after operation may be necessary. Incompletely resected dermoid tumours may grow slowly over time, and the

density of post-operative adhesions and scar preclude total resection at re-operation.

Following complete tract and inclusions tumour resection, the subarachnoid space should be irrigated with a saline solution. Dermoid and epidermoid debris are highly irritative to the spinal fluid, and this manoeuvre may diminish post-operative inflammatory meningitis. If an intramedullary mass has been resected the pia-arachnoid might be sutured and the tubular spinal cord reconstituted. To minimize post-operative spinal cord tethering, a dural patch graft is incorporated to ensure a wide contact of cerebrospinal fluid around the lower spinal cord and cauda equina. Fibrin glue may be employed if necessary. The wound is closed in layers, and the paraspinous muscle fascia is reapproximated with running and interrupted sutures in a watertight manner. Skin closure with vertical mattress sutures is preferred, especially if there has been previous infection.

Figure 40.3

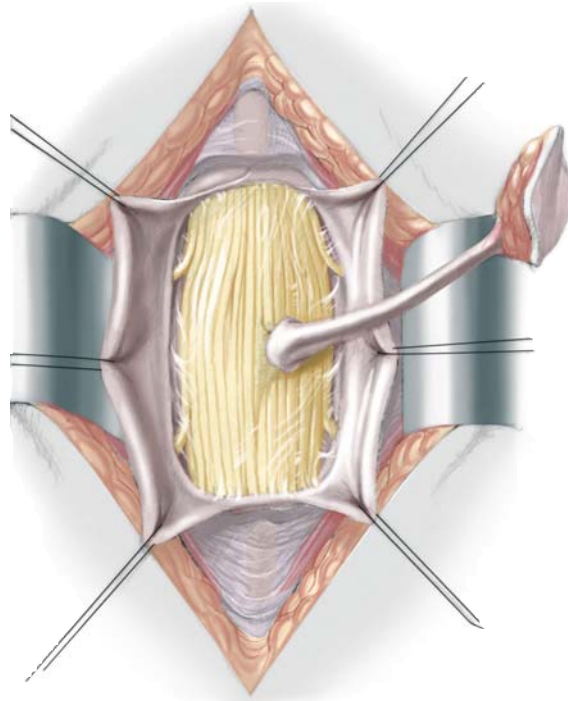
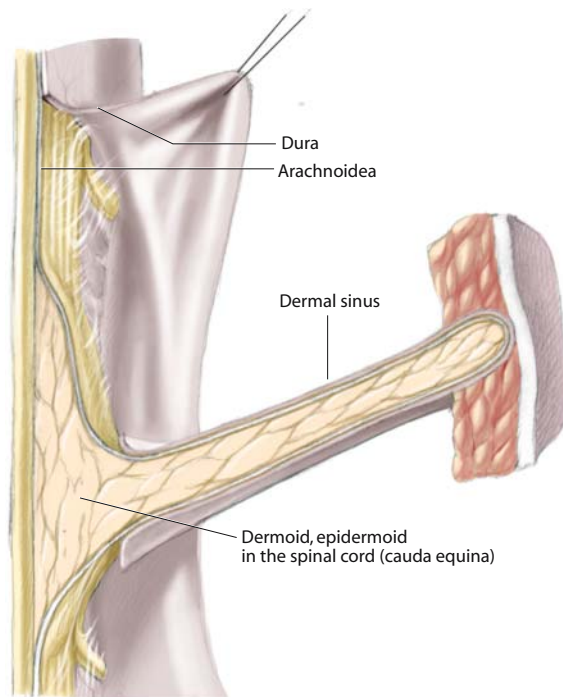


Figure 40.4



CONCLUSION

Conservative management of dermal sinuses is not justified, and these lesions should be electively resected at the time of diagnosis, because they may lead to progressive neurologic deterioration.

Dermal sinuses above the intergluteal crease should be surgically excised at the time of diagnosis in all patients prior to deficits to maintain neurologic function, regardless of patient age. If the lesion is discovered during an episode of meningitis, laminoplasty and intradural exploration should follow after infection has been controlled by antibiotics. Emergency surgery is required in cases of rapid neurologic deterioration, recurrent infection during antibiotic therapy, or when infection cannot quickly be controlled.

The foundations of surgical repair are based on the embryology and anatomy of the malformations. Surgical treatment consists of excision of the dimple and the tract from the skin surface to the deepest projection, as well as intradural connections or masses even when MRI reveals normal findings.

Chance of preserving the neurological function is high (95.4%).

Post-operative complications are limited following intradural exploration and complete resection of sinus tracts and cutaneous elements. Regardless of patient age, post-operative infection is the most common complication, and neurological deficits or cerebrospinal leaks can frequently occur after opening the dura. The prognosis in those patients who already have some neurological deterioration is frequently unfavourable, although some improvement may occur in the majority of the patients. Therefore, the surgery is done to prevent neurological deficit in those who do not have it. In patients with incomplete tumour resection, yearly follow-up MRI is recommended.

Optimum management of children requires close co-operation between pediatricians, pediatric surgeons, neurosurgeons and multiple specialists involved with congenital defects and infectious diseases.

SELECTED BIBLIOGRAPHY

- Elton S, Oakes WJ (2001) Dermal sinus tracts of the spine. *Neurosurg Focus* 10:1-4
- Hattori H, Higuchi Y, Tashiro Y (1999) Dorsal dermal sinus and dermoid cysts in occult spinal dysraphism. *J Pediatr* 134:793
- Kanev PM, Park TS (1995) Dermoids and sinus tracts of the spine. *Neurosurg Clin North Am* 6:359-366
- Weprin BE, Oakes WJ (2000) Coccygeal pits. *Pediatrics* 105:E69

INTRODUCTION

Sacrococcygeal teratoma is a rare tumour, occurring in approximately 1 in 40,000 live births. They arise from the caudal end of the spine, usually protruding from the inferior end of the infant's spinal column and displacing the anus forwards. They are much more common in girls, with the female to male ratio being at least 3:1. It is generally agreed that sacrococcygeal teratoma is the result of continued multiplication of totipotent cells from Hensen's node, which fail to involute at the end of embryonic life.

These are true neoplasms. Willis defined the term teratoma as follows: "A teratoma is a true tumour or neoplasm composed of multiple tissues of kinds foreign to the part in which it arises". By definition, then, sacrococcygeal teratomata are composed of several types of tissue, usually derived from two or three germ layers. Within any one tumour, the cells can vary from totally benign (even forming well-formed teeth, hair or other organs) to cells that appear frankly malignant. However, many sacrococcygeal teratomata contain malignant-looking cells (usually described as "immature"), but if they are completely excised they do not recur. For this reason, the diagnosis of malignant sacrococcygeal teratoma can only be made if there are distant metastases. The risk of malignancy depends on the site and the extent of the tumour and the age at diagnosis. Tumours diagnosed after 2 months of age have a high risk of being malignant. Tumours that are largely "exophytic", i.e. those that protrude from the caudal end of the baby with only a small intra-abdominal component, tend to be benign. However, those that have a large intra-abdominal component, have a higher risk of behaving in a malignant fashion. In general, as long as a complete resection is obtained, the risk of recurrence is low.

These tumours used to be diagnosed when they presented as a large sacral mass after a difficult delivery, or with an obstructed delivery. However, the most common presentation now is an antenatal diagnosis by ultrasound. Series reporting the antenatal diagnosis of sacrococcygeal teratomata have revealed that the majority of the fetuses diagnosed as having a sacrococcygeal teratoma are likely to die before delivery. Most of the fetuses who have died following antenatal diagnosis had tumours with a mass as great as or greater than the rest of the fetus.

It is, therefore, entirely possible that these fetuses die of heart failure as the fetal heart is unable to pump sufficient blood to nourish both the tumour and the rest of the fetus. Certainly, in most of the antenatal series reported, fetal hydrops (non-immune hydrops) is very common, and is associated with an increased risk of fetal demise.

Most cases presenting as neonates to paediatric surgeons will have a large skin-covered mass protruding from the coccygeal region, pushing the anus and vagina anteriorly. There may be large veins visible on the surface, and these usually drain into the surrounding structures. Large tumours may have ruptured (in which case they will bleed profusely) or may have an ulcerated area on the surface. Neonates with a tumour approaching the size of the rest of their body may be delivered prematurely and will often have features of non-immune hydrops. In all cases, the tumour is firmly attached to and may be said to arise from the anterior surface of the coccyx. It may displace the coccyx posteriorly, but almost without exception, the sacrum is normal.

An abdominal ultrasound will determine the size and consistency of any pelvic or abdominal component. It may be necessary to fill the bladder with water to allow it to be used as a sonic window. Magnetic resonance imaging should clearly distinguish between sacrococcygeal teratoma and anterior meningocele, and may be able to detect the occasional extension of the tumour through the sacral hiatus into the spinal canal.

These lesions are best resected within the first 24 h after birth, since the gut is not usually colonized in the first 24 h after birth, reducing the risk of infection if the field is contaminated by stool during the resection. Peri-operative antibiotics are given immediately before surgery commences and continued for 24–48 h post-operatively. If the infant has been fed, or is several days old, then a formal bowel preparation may be advisable. Blood should be cross-matched, and adequate intravenous access is vital. An arterial line may also be useful during the operation. It is useful to obtain blood for α -fetoprotein levels before surgery as a baseline, in order to confirm post-operatively that α -fetoprotein levels continue to fall at a normal rate.

Figure 41.1

The patient is anaesthetized, intubated and positioned prone with a roll under the hips. The roll is positioned so that the infant's weight is taken on the anterior superior iliac spines. It is vital that the abdomen be left hanging free to ensure that respiration is not inhibited by the baby's weight. For this reason, the baby's shoulders should be supported either by a smaller roll lying transversely across the apex of the chest at the level of the medial ends of the clavicles, or by two rolls running parallel to the spine, each supporting the glenohumeral joints. A catheter should be placed in the bladder to measure urine output throughout the procedure. Many authorities state that the anus should be prepared out of the field. The author finds that approach both inconvenient and impractical, as access to the anus is often

required during the procedure. The cautery pad can usually be placed across the shoulders. A clear plastic drape may conserve body heat and assist in prevention of hypothermia.

A chevron incision is made in the skin over the dorsum of the mass. It is continued down to fascial layers. It is preferable not to dissect beyond the level of the deep fascia at this stage of the dissection. There are often several large veins in the subcutaneous tissue on either side of the midline. These should be divided between ties. The incision should be placed so as to preserve as much normal skin as possible. Excess skin can always be trimmed later if necessary. The apex of the chevron should be over the lower sacrum.

Figure 41.2

In the midline, the dissection should continue directly down to the sacrococcygeal junction, or even down to the fourth or fifth sacral vertebra. The edges of the sacrum are defined, and a clamp is passed across the sacrum at this level, keeping the tips of the forceps against the ventral surface of the bone (or cartilage) to ensure that the forceps pass between the sacrum and the underlying middle sacral vessels, which are usually substantial vessels, supplying the bulk of the blood supply to the tumour. Once this manoeuvre is complete, the sacrum (which is usually completely, or at least largely, cartilaginous) can be divided with a scalpel and the tumour displaced slightly inferiorly to expose the middle sacral vessels. This manoeuvre needs to be carried out with caution, as occasionally the bulk of the venous drainage from the tumour passes through the sacral hiatus and into the epidural plexus. Failure to recognize this possibility can result in a substantial, rapid loss of blood. This can usually be controlled using simple pressure, taking care to maintain the pressure until the bulk of the arterial inflow has been divided. However, even after that has been accomplished,

there may be continuing blood loss from the epidural plexus, requiring the use of bone wax to control it. It may be necessary to divide some of the attachments of the thinned-out remnants of the levators to the edges of the lower end of the sacrum and coccyx to enable the distal portion of the sacrum and coccyx to be displaced caudally. The middle sacral vessels are then ligated in continuity and divided. This early division of the middle sacral vessels is essentially the same as the procedure advocated by Smith and colleagues. This manoeuvre opens a plane of dissection that is outside the tumour capsule, but deep to the thinned-out remnants of the levators and the gluteus maximus. The levators may be so thin as to be almost invisible, but they will contract on stimulation, either with a muscle stimulator or the electrocautery. The dissection should continue laterally in this plane either side of the midline until the muscles are lost in the fascia of the tumour. At this point, they can be divided along a line parallel to the skin incision. This will allow the tumour to be further displaced in a caudal direction.

Figure 41.1

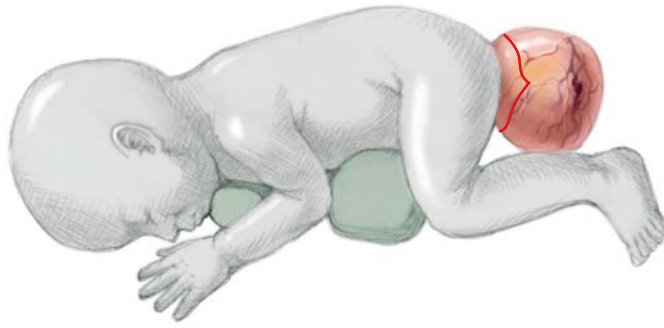


Figure 41.2

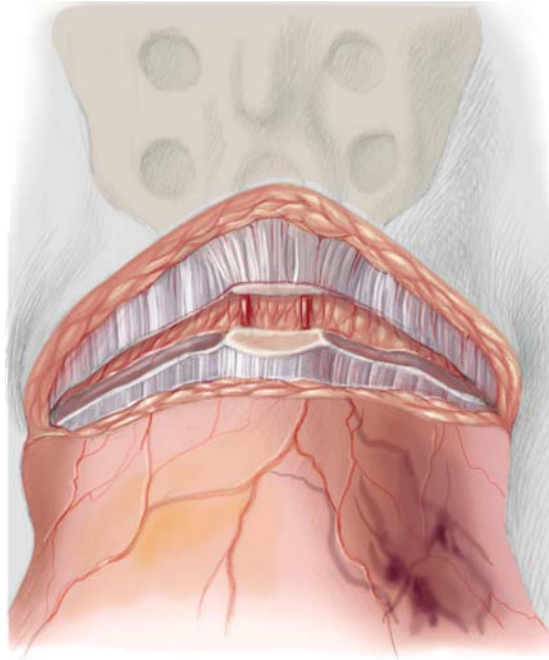


Figure 41.3

Attention is then directed to the pelvic extension of the tumour. Using blunt dissection with peanut swabs in the plane anterior to the middle sacral vessels, it is usually possible to displace the pelvic component of the tumour anteriorly until its upper extent is reached. This is normally an essentially avascular plane anterior to the sacrum, although some vessels feeding into the tumour from the internal iliac vessels may be encountered laterally. These can usually be controlled with cautery. In most cases, the tumour can be dissected out from the pelvis and rolled inferiorly over the patient's legs.

Figure 41.4

This manoeuvre exposes the upper end of the rectum, which can be identified by a Vaseline gauze pack or by passing a finger in through the anus. The tumour can be dissected off the rectum with a combination of sharp and blunt dissection, and rolled inferiorly until the plane of dissection moves away from the rectum and the anal canal. At all times during this dissection, it is best to try to maintain the plane of dissection on the capsule of the tumour and to preserve all normal structures no matter how distorted and thinned-out they are. As the tumour is rolled inferiorly, it eventually becomes apparent that the plane of dissection has reached the subcutaneous tissue along the inferior surface of the tumour, posterior to the anus. Once the dissection has reached this point, the dissection can be terminated as long as the inferior skin flap that has been developed is of sufficient length to allow easy closure of the wound. The inferior skin flap can then be divided from the tumour and the tumour delivered from the field. A careful check of the tumour bed is carried out to ensure that meticulous haemostasis has been achieved.

Figure 41.5

Attention is then directed to reconstruction of the pelvic floor and closure of the wound. The remnants of the levator sling are identified and the central portion is sutured to the perichondrium of the anterior surface of the sacrum using a 5/0 monofilament absorbable suture. This same suture is used for all subsequent muscle and fascial reconstruction. These initial fascial sutures, rather than the skin closure, should determine the siting of the anus. This aspect

of the reconstruction, therefore, should be carried out with care to ensure both a functional and a cosmetically pleasing result.

If a drain is to be placed, then it is placed at this stage, in the presacral space, led out through the gap in the levators and tunnelled out through the subcutaneous tissue of the buttock. A closed suction drain is preferred.

Figure 41.3

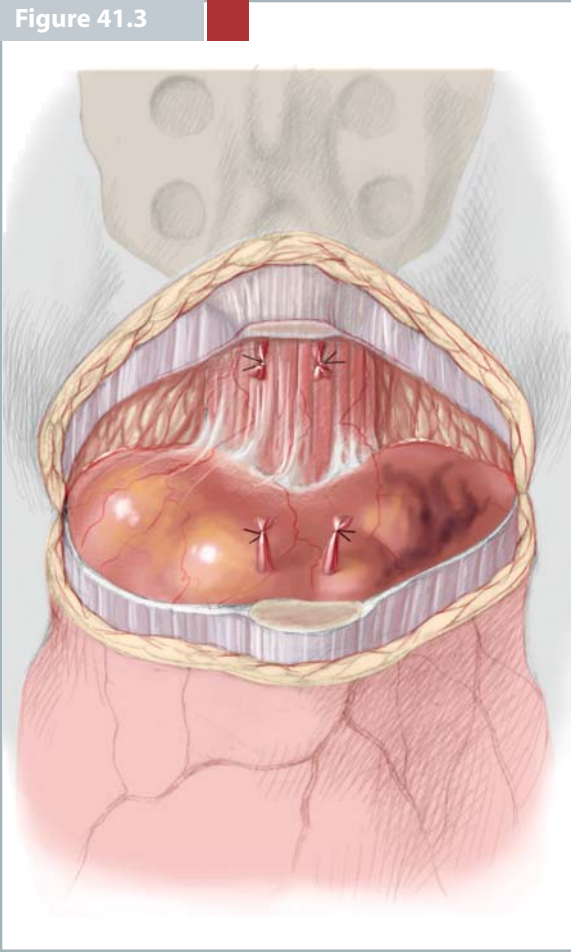


Figure 41.4

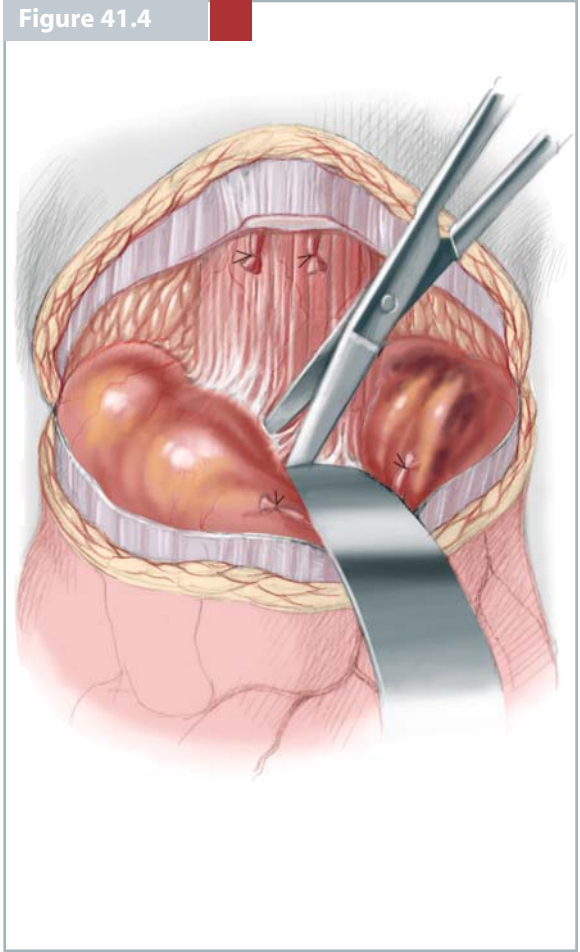


Figure 41.5

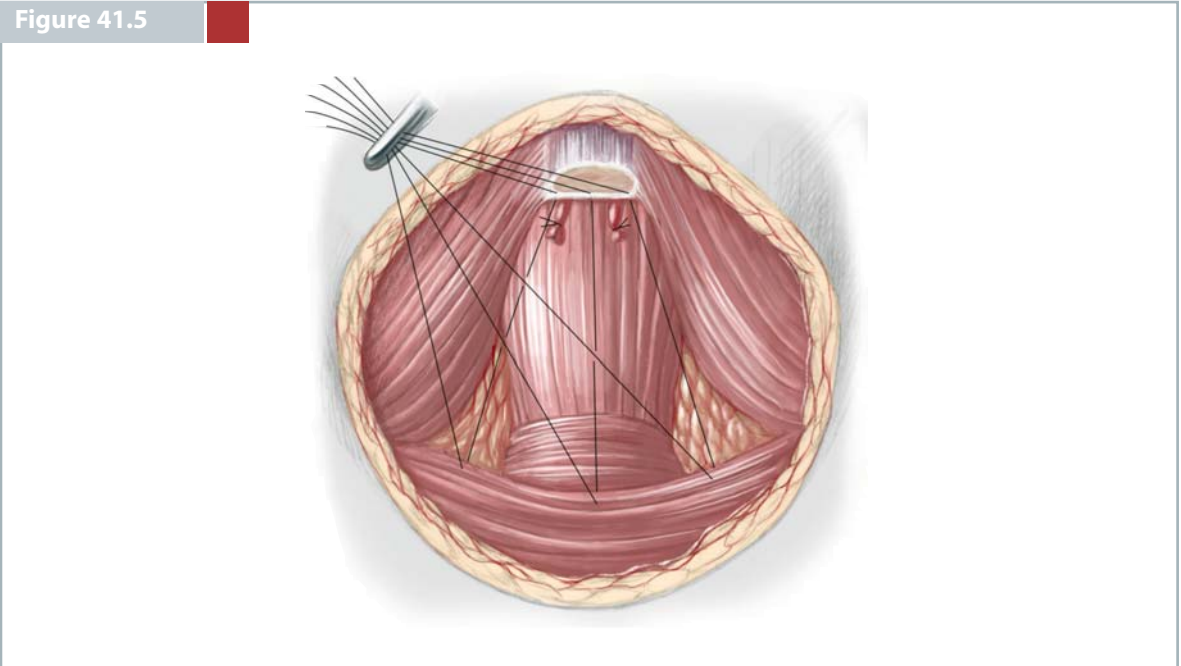


Figure 41.6, 41.7

If there are remnants of the levators recognizable lateral to the midline, these are repaired with interrupted 5/0 monofilament absorbable suture. The medial edges of gluteus maximus are then closed in the midline over the sacrum and the lower part of the levator sling. The skin flaps are then trimmed to length. If possible, the subcutaneous tissues are closed with a running 5/0 polyglycolic acid suture and the skin is closed with a running 5/0 polyglycolic acid subcuticular suture. A Steristrip and collodion dressing is then applied. If it is not possible to close the subcutaneous tissue, then a subcuticular suture may not be adequate for skin closure. In this case, 5/0 nylon skin suture are placed. The rectum is packed with Vaseline ribbon gauze at the completion of the procedure in an attempt to obliterate dead space. It is useful to suture a 2/0 silk suture to the end of this

pack to aid its retrieval, should the pack become displaced higher up the rectum in the immediate post-operative period.

The infant is nursed in a prone position for several days post-operatively. The urinary catheter can be removed as soon as the baby's condition is stable and the infant can be extubated as soon as its respiratory condition allows. The infant can usually be fed as soon as it is extubated. The Vaseline pack is usually removed in the first post-operative day by pulling on the 2/0 silk suture left attached to the distal end. Any drain can usually be removed within the first few days of the procedure. α -Fetoprotein levels should be determined immediately post-operatively and on discharge. The infant should then be followed at monthly intervals for 3 months and then at 3-monthly intervals for a year.

Figure 41.6

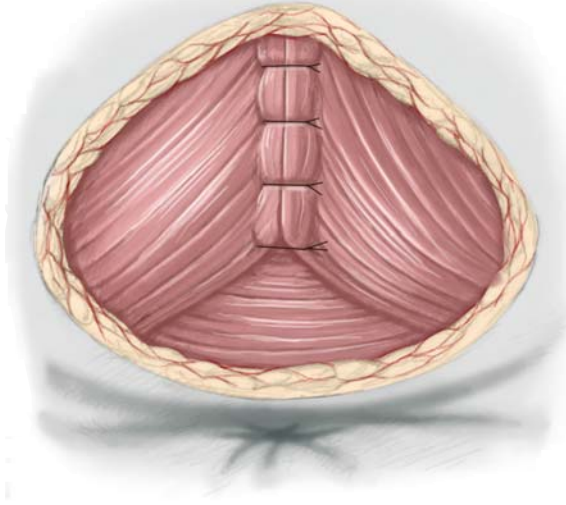
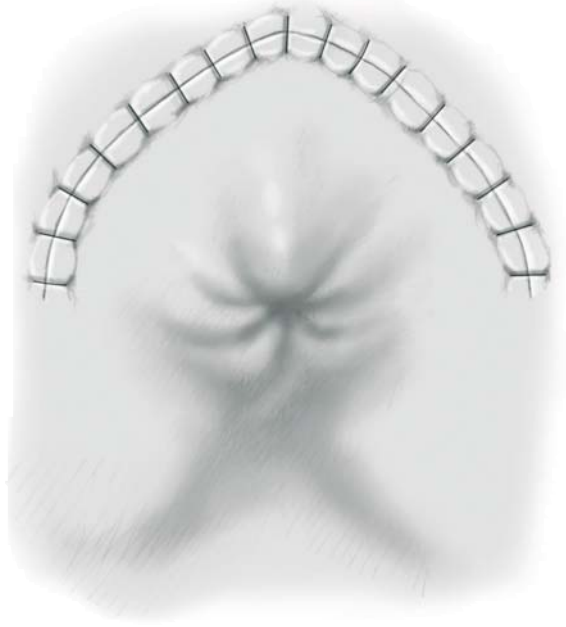


Figure 41.7



CONCLUSION

Follow-up should continue for at least 5 years. At each visit, a rectal examination will detect any local recurrence and an α -fetoprotein level will detect any distant spread. The α -fetoprotein level is often very high (of the order of 100,000 U or more) and even in normal babies may be over 10,000 U. These high levels usually take over a year to fall to normal adult levels. It is generally thought that as long as the α -fetoprotein level continues to fall steadily, recurrence is unlikely. In the author's experience, a steadily falling α -fetoprotein level does not rule out the possibility of either a local recurrence, or even a malignant recurrence. All of the local recurrences in the author's series, and the malignant recurrence all developed in the context of a steadily falling α -fetoprotein level. For this reason, the author has now developed a protocol of routine ultrasound examinations and rectal examinations at regular intervals for the first 3 years of life.

In the absence of distant metastases at presentation, and if the excision is complete, then life expectancy should be normal, although the appearance of the buttocks usually leaves something to be desired. Continence, surprisingly, is usually normal. However, the relatively late development of a hostile neurogenic bladder at the age of 3 years in one patient, does suggest that normal bladder function cannot be assumed to be present until well into the school years.

The prognosis for patients presenting with a malignant sacrococcygeal teratoma must be guarded. Modern chemotherapy has produced some improvement in survival, although the chemotherapy regimens are toxic and the tumour tends to be relatively resistant to therapy. However, this is a relatively uncommon circumstance.

SELECTED BIBLIOGRAPHY

- Altman RP, Randolph JG, Lilly JR (1974) Sacrococcygeal teratoma: American Academy of Paediatrics Surgical Section Survey - 1973. *J Pediatr Surg* 9: 389-398
- Ein SH, Mancier K, Adyemi SD (1985) Malignant sacrococcygeal teratoma - endodermal sinus, yolk sac tumor - in infants and children: a 32-year review. *J Pediatr Surg* 20: 473-477
- Pringle KC, Weiner CP, Soper RT et al (1987) Sacrococcygeal teratoma. *Fetal Ther* 2: 80-87
- Smith B, Passaro E, Clatworthy HW (1961) The vascular anatomy of sacrococcygeal teratomas: its significance in surgical management. *Pediatr Surg* 49: 534-539
- Willis RA (1962) *The borderland of embryology and pathology*, 2nd edn. Butterworth, London

Edward Kiely

INTRODUCTION

Neuroblastomas arise in neuroblasts of the sympathetic nervous system. The largest concentration of these cells is in the adrenal medulla and in the sympathetic ganglia. Other collections of sympathetic neuroblasts lie within the pre-aortic ganglia.

The incidence of neuroblastoma in children is about 1 in 10,000 and it accounts for 6–7% of all childhood cancers. It is the commonest abdominal malignancy of childhood. About one-third of neuroblastomas occur in infancy, a further 50% are detected under the age of 4 years and all but 5% are found under the ages of 10 years.

At the time of clinical presentation about two-thirds have locally advanced or metastatic disease. The presence of bone and joint pain, a consequence of metastasis, may bring the condition to attention.

The tumour occurs in the abdomen in the great majority of patients (about 70%), the adrenal being the commonest site of origin (about 50% of the total). Tumours arising in the mediastinum (10%) or the pelvis (6%) are much less common.

Different classification and staging systems have evolved over the years in an attempt to predict outcome, compare results and direct therapy. The International Neuroblastoma Staging System (INSS) is currently the system which is most widely applied. In this system tumours are staged 1–4S. Stages 1 and 2 are localized and amenable to excision; stage 3 implies extension across the midline with a non-resectable tumour, and stage 4 implies a tumour with distal metastases. Stage 4S is limited to infants with metastases to liver, skin or mild bone marrow involvement.

Staging is undertaken using cross-sectional imaging (computed tomography or magnetic resonance imaging), isotope scanning together with bone marrow aspirates and trephines.

In addition to clinical staging systems, serum markers of disease behaviour are also widely used:

these include neurone specific enolase (NSE), lactate dehydrogenase (LDH) and ferritin – elevated levels of these markers are associated with a worse prognosis.

Biological markers of disease activity include MYCN amplification, 1p deletion and polyploidy. The first two of these are associated with a worse outcome regardless of age and stage and polyploidy is associated with a better outcome. Other markers are being studied.

Current chemotherapy regimes are directed by the clinical staging systems but advancing understanding of tumour biology is all playing a part in directing therapy, particularly toward the tumours with a worse prognosis.

Histologically the appearance of these tumours varies from the more benign ganglion cell and nerve fibre mixture, to an undifferentiated small blue round cell appearance. The classical rosette appearance is sometimes seen. Although histological grading systems are in use they are not universally applied.

Most children with neuroblastoma are treated by pediatric oncologists according to agreed national or international protocols. In general, low stage tumours with favourable biological profiles are managed by excision alone. Aggressive chemotherapy is utilized with low stage tumours with a poor biological profile or for those (the majority) who have locally advanced or metastatic disease.

When planning surgery for any of these children, cross-sectional imaging provides useful information on the site of the tumour and the degree of anatomical distortion. As the tumours are intimately related to major blood vessels, imaging provides some useful information on which vessels will need to be dissected.

Figure 42.1

The surgery for neuroblastoma is undertaken under full intubated general anaesthesia with indwelling vascular monitoring. The procedure described is for resection of a left adrenal primary with nodal disease around the aorta and its branches. The principle of the operation is the same regardless of the site of the primary tumour. Neuroblastomas do not usually invade the tunica media of major blood vessels. Consequently, a plane of dissection may be developed with a knife between the tunica adventitia and the tunica media. The initial phase of the operation is to display part of the circumference of all the relevant vessels as

they traverse the tumour. Each vessel is then cleared in turn and the tumour may be excised once the vascular anatomy is completely displayed.

The abdomen is opened through an upper transverse abdominal incision. After a full laparotomy the sigmoid and descending colons are reflected medially leaving Gerota's fascia intact. The spleen is then mobilized and reflected medially with the pancreas and stomach. All mobile intestine and spleen are placed in an intestinal bag and a table mounted retractor is used to maintain a clear operative field.

Figure 42.2

The lower limit of the tumour is then established and the artery is dissected as it emerges from the tumour. This is done by incision of the tunica adventitia longitudinally along the middle of the vessel. If the adventitia is put under tension by the surgeon and the assistant it opens cleanly once it is incised.

Figure 42.3

The plane of dissection is now established for the remainder of the operation. The dissection advances proximally in the same fashion, incising tumour and adventitia down to media in 1- to 2-cm steps. It is important for the surgeon and assistant to apply tension to the tissue to be divided as this eases the dissection. The aortic bifurcation is then reached and the direction of the dissection moves along the middle of the aorta. The origin of the inferior mesenteric artery is encountered shortly thereafter and does not usually present many problems.

Figure 42.1

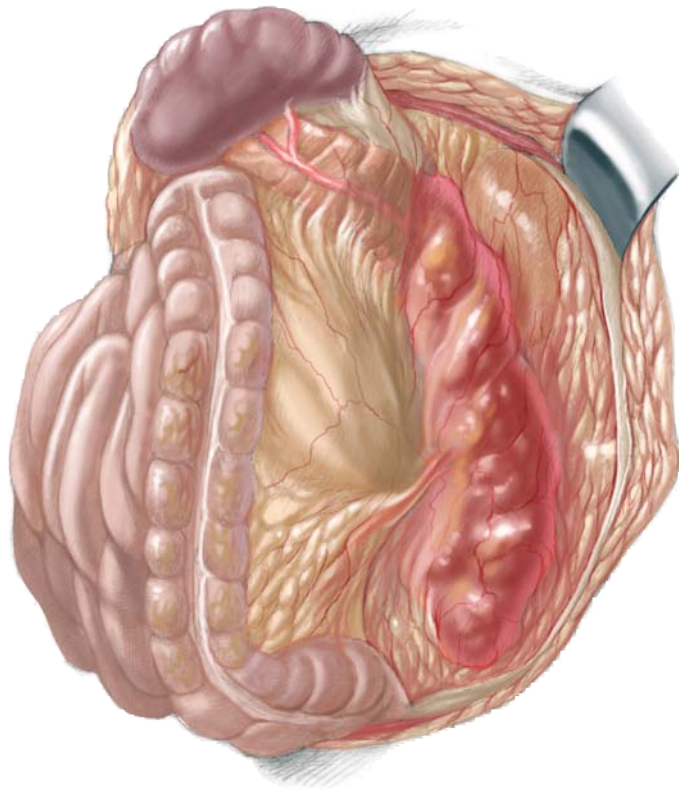


Figure 42.2

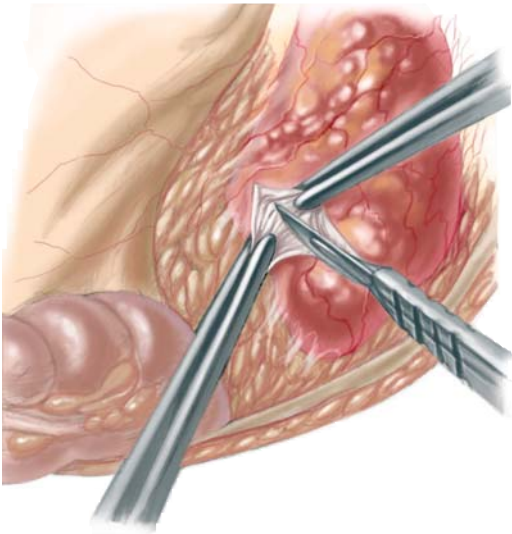


Figure 42.3

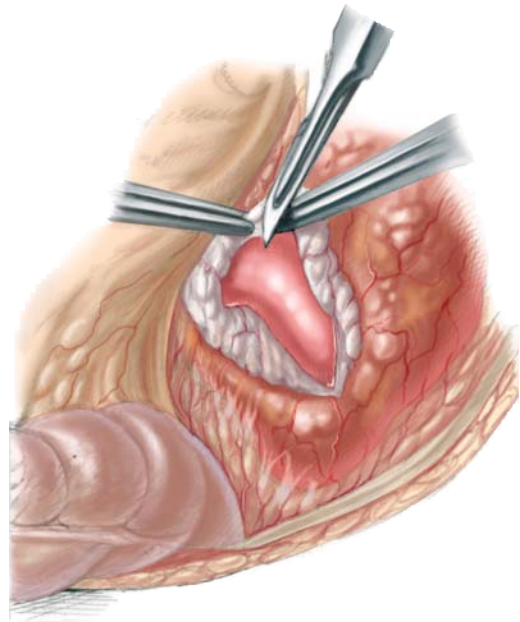


Figure 42.4

When the left renal vein is reached it is mobilized in a similar fashion and the tumour beneath it divided and cleared from the anterior wall of the aorta. The origin of the left renal artery is encountered shortly thereafter and the axis of dissection moves towards the 2 o'clock, rather than the 12 o'clock, position to avoid the origin of the main visceral arteries. The origin of the left renal artery is cleared as before by longitudinal incision of the tumour down to media. The dissection then continues along the aorta until the diaphragm and upper limits of the tumour are resected.

Figure 42.5

At this time the origin of the coeliac axis is visible and this artery is exposed as before. Once the coeliac has been cleared, tumour overlying the superior mesenteric artery is managed in similar fashion.

If the tumour extends deeply towards the right crus of the diaphragm then the splenic vein and its junction with superior mesenteric and portal veins are cleared in the same way.

Figure 42.6

Once all the vessels are in view they are mobilized circumferentially and the tumour is removed.

Figure 42.4

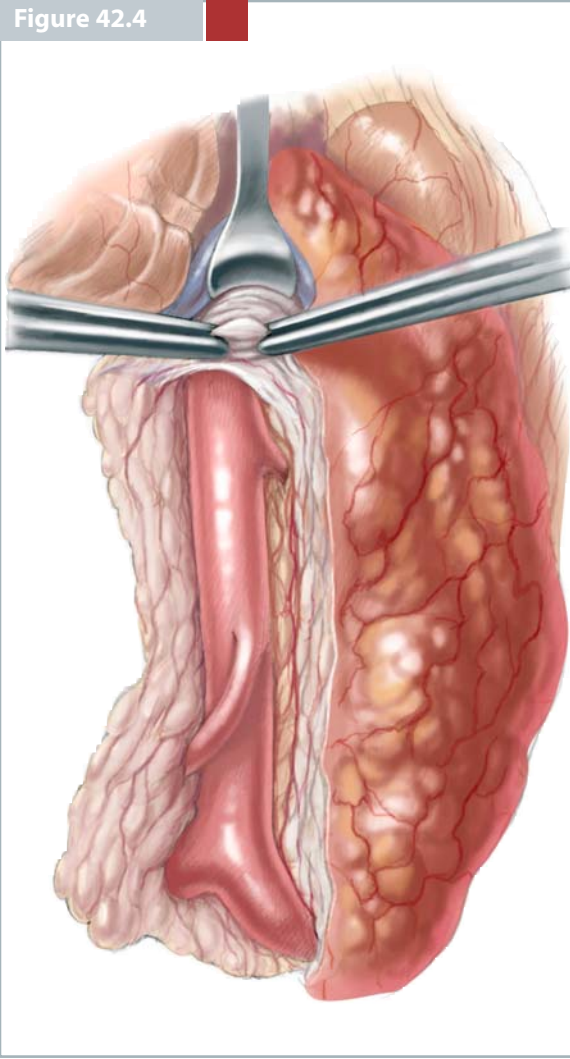


Figure 42.5

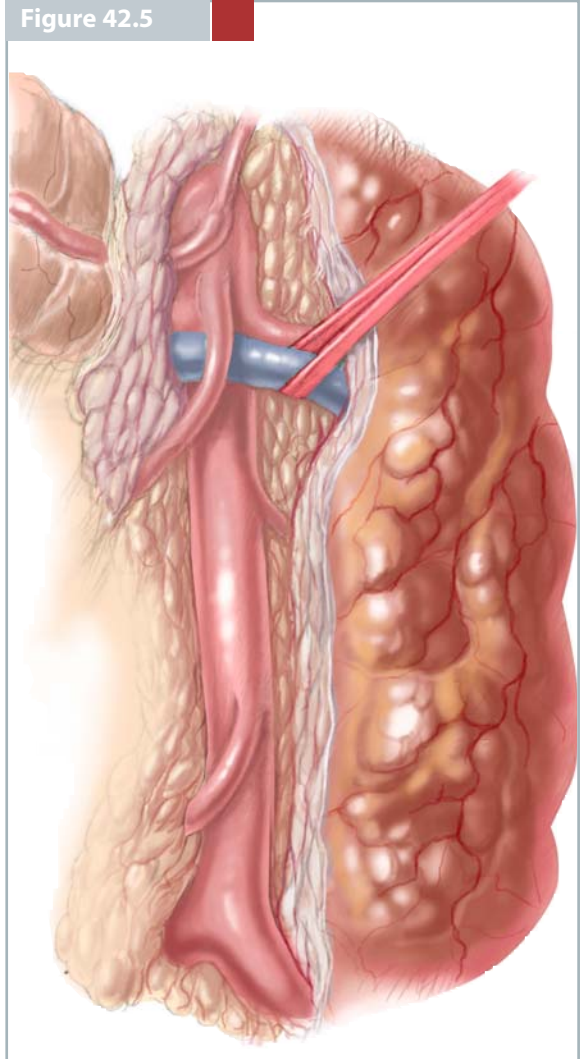


Figure 42.6

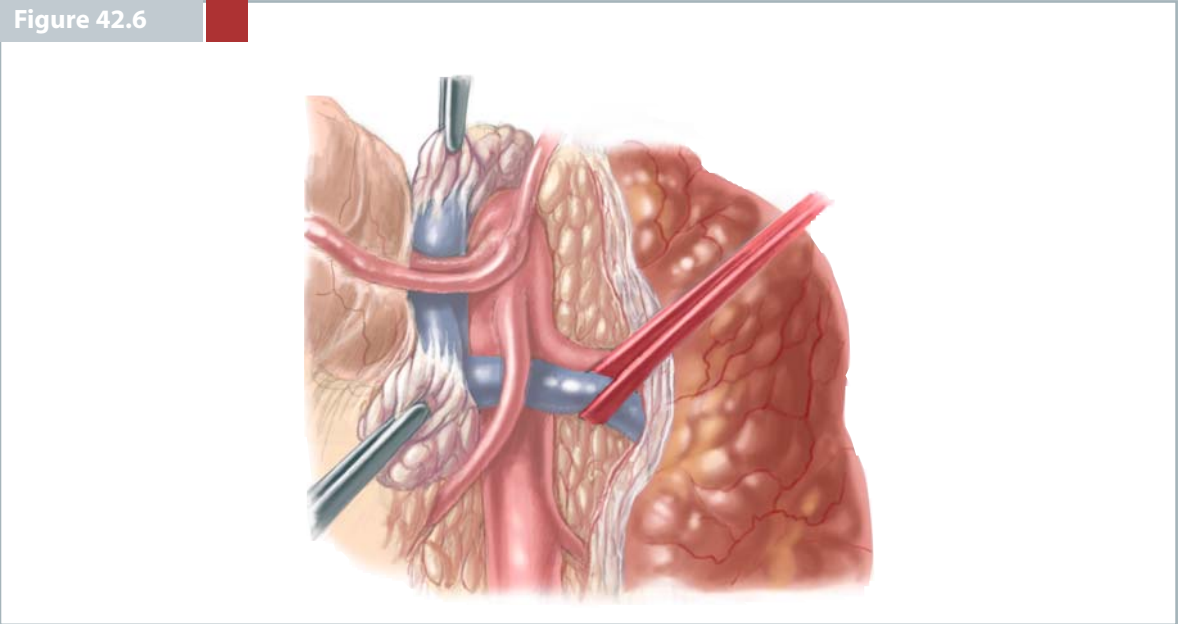


Figure 42.7, 42.8

After complete excision of the tumour, All vessels can be clearly seen. Any suspicious lymph glands should be removed for histological examination.

Figure 42.7

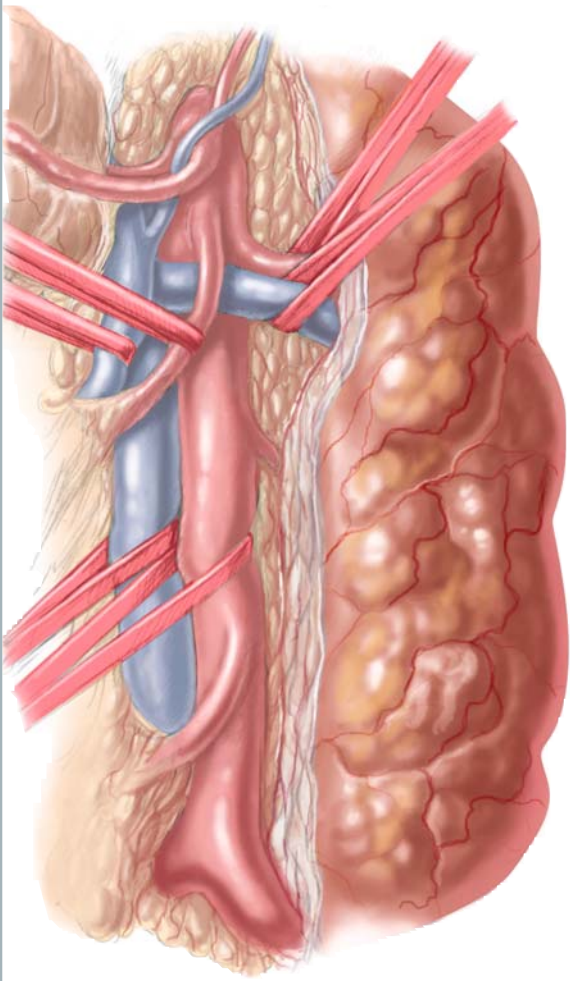
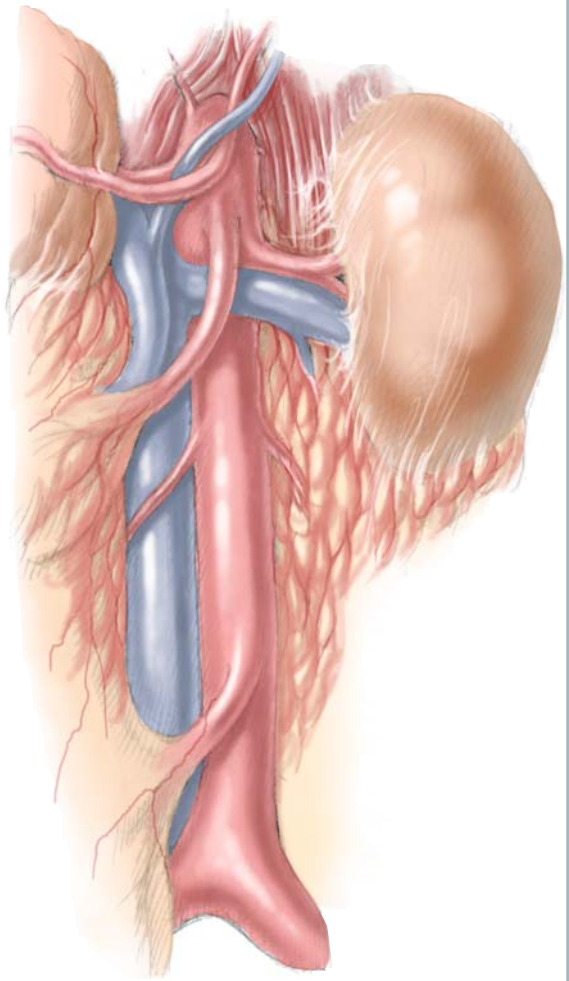


Figure 42.8



RESULTS AND CONCLUSION

The operative mortality is about 1–2%. For those undergoing clearance of coeliac and superior mesenteric arteries, diarrhoea has been a particular problem. At the present time age and stage are the main determinants of survival – age under 1 year and low stage are associated with an improved outcome. For those with localized tumours survival is in the region

of 90–100%. The role of surgery in managing those with locally advanced or metastatic disease is unclear. However, recent evidence suggests that complete excision confers a survival advantage for those with stage 3 disease, although it is not clear that complete excision improves survival in those with metastatic disease. This remains at about 30%.

SELECTED BIBLIOGRAPHY

- Brodeur GM, Pritchard J, Berthold F (1993) Revisions of the international criteria for neuroblastoma diagnosis, staging and response to treatment. *J Clin Oncol* 11:1466–1477
- Carachi R (2002) Perspectives on neuroblastoma. *Pediatr Surg Int* 18:299–305
- Evans AE, Silber JH, Shpilsky A (1996) Successful management of low-stage neuroblastoma without adjuvant therapies: a comparison of two decades, 1972 through 1981 and 1982 through 1992, in a single institution. *J Clin Oncol* 14:2504–2510
- Shorter NA, Davidoff Am, Evans AE (1995) The role of surgery in the management of stage IV neuroblastoma: a single institution study. *Med Pediatr Oncol* 24:287–291
- Weinstein JL, Katzentein HM, Cohn SL (2003) Advances in the diagnosis and treatment of neuroblastoma. *Oncologist* 8:278–292

Robert Carachi

INTRODUCTION

Renal neoplasms in childhood are usually malignant, the most common being nephroblastoma Wilms tumour (WT). The incidence varies from 10.9 per million in the USA to 2.5 per million in Chinese. A genetic predisposition exists and nephrogenic cell clusters, a premalignant lesion is found in a third of patients with WT. Some syndromes are associated with Wilms tumour and these are WAGR syndrome (WT, aniridia, genitourinary anomalies, mental retardation). The Denys-Drash syndrome (WT, intersex, nephropathy) and Beckwith Wiedemann syndrome (exomphalos, macroglossia, visceromegaly). Hemihypertrophy is associated with an increased incidence of Wilms tumour. WT1 and WT2 genes are associated with WT, especially WT2 with Wiedemann Beckwith syndrome.

WT presents as a palpable asymptomatic abdominal mass in a toddler, which is discovered when the parents are usually bathing or dressing the child. Weight loss, malaise, abdominal pain, hypertension and haematuria may be present. Rarely they may present with a varicocoele where the left renal vein is occluded by tumour thrombus. On examination it is a smooth rounded tumour occupying most of the abdomen, and in about 10% of patients the tumour thrombus from the nephroblastoma may invade the inferior vena cava. This may at times extend to the right atrium causing cardiac dysfunction or even a pulmonary embolus. Obstruction of the hepatic veins may rarely cause an acute hepatic encephalopathy and produce a Budd-Chiari syndrome. Patients with syndromes, i.e., WAGR, Denys-Drash, Beckwith Weidemann and hemihypertrophy, should receive 6-monthly screening and examinations, usually by ultrasound, because they have an increased risk of developing Wilms tumour.

The main stay of investigation is imaging; a plain X-ray of the abdomen usually shows a soft tissue mass and calcification may be seen in about 10% of patients. A plain chest radiograph may show pulmonary metastases. Abdominal ultrasound confirms that the tumour is renal in origin and can demonstrate a normal contralateral kidney. It evaluates the inferior vena cava for blood flow and for the presence

of tumour thrombus within it. A computed tomography scan will outline the tumour and may show a lesion in the contralateral kidney. Magnetic resonance image scanning can add a further dimension to renal evaluation with visualisation of blood vessels. Echocardiography may be necessary to exclude the presence of an intra-atrial extension of the tumour thrombus.

The histology of WT mimics the development of the normal kidney with the proportion of the three components, blastema, tubules and stroma varying greatly in different tumours. Histological differentiation allows good clinical correlation between a “low risk” group of patients who are cured and a “high risk” group who need more intensive treatment and do less well.

The surgical treatment of Wilms tumour involves three stages: (1) making a diagnosis by biopsy, (2) operative excision of the tumour and (3) staging of the patient.

Staging System of National Wilms Tumour (NWTs)

- *Stage I* Tumour limited to the kidney and completely excised. Surface of the renal capsule intact; no tumour rupture; no residual tumour apparent beyond margin of excision.
- *Stage II* Tumour extends beyond kidney but is completely excised; regional extension of tumour; vessel infiltration; tumour biopsy or local spillage or tumour confined to flank; no residual tumour apparent at or beyond margins of excision. *The SIOP (International Society of Pediatric Oncology) group subdivides this group in IIa and IIb, the latter one with tumour positive regional (hilar) lymph nodes, while the former one has free lymph nodes.*

- *Stage III* Residual non-hematogenous tumour confined to the abdomen, lymph node involvement of the hilum, periaortic chains or beyond; diffuse peritoneal contamination by tumour spillage; peritoneal implants; tumour extends beyond resection margins, either microscopically or macroscopically; tumour not completely resectable because of local infiltration into vital structures.
- *Stage IV* Deposits beyond stage III in lung, liver, bone or brain.
- *Stage V* Bilateral renal involvement at diagnosis.

Pre-operative Chemotherapy

A variety of protocols have been devised that show benefit from pre-operative chemotherapy once the diagnosis has been established. Thus on suspicion of a Wilms tumour, pre-operative chemotherapy may shrink the tumour and downgrade the staging and reduce the incidence of intra-operative tumour rupture. Pre-operative chemotherapy has been very effective in Europe where the SIOP trials have demonstrated a reduced incidence in operative tumour rupture in the patients who had received chemotherapy. The effect of chemotherapy is to shrink the tumour considerably, which happens in 80% of cases and, therefore, makes the surgery a lot safer. The current Wilms tumour trial in the UK is evaluating the pre-operative chemotherapy versus primary surgery. Those patients who are receiving pre-operative chemotherapy will have percutaneous biopsies to obtain histological confirmation of the tumour prior to starting chemotherapy. Surgery is delayed in this group for several weeks while they receive their chemotherapy according to the protocol.

Figure 43.1

The operation performed for Wilms tumour is a transabdominal nephrectomy. It is essential to have all the necessary prerequisites done before surgery can start, such as central venous catheter with central venous pressure monitoring, arterial line with continuous arterial pressure monitoring, urinary catheter, etc. Epidural block is part of the routine procedure and cross-matched blood should be available if needed.

The abdomen and chest are prepared and draped. It is best to have the flank raised with a roll underneath the patient. The operative procedure begins with a large transverse incision. The incision is carried out well into the flank on the involved side and across to the flank on the opposite side. The incision must be large enough to allow large tumours to be mobilized without risking intra-operative rupture. The incision is deepened through the subcutaneous fat and the rectus and oblique muscles.

Figure 43.1

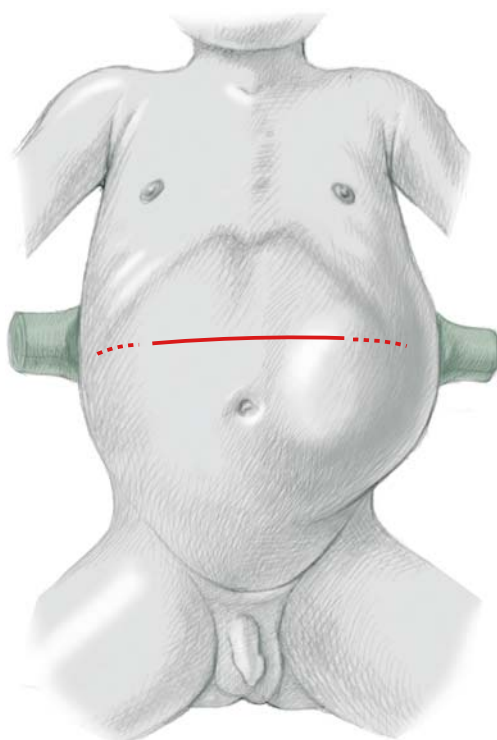


Figure 43.2

The peritoneum is then opened and the ligamentum teres is divided between ligatures. Any free fluid should be noted whether it is blood stained and should be sent for cytology. The small intestine is then delivered out of the abdomen and protected by warm moist packs in order to assess the tumour. A full assessment should be made by palpating the tumour, the liver, the opposite kidney and the lymph nodes.

The retroperitoneal space is opened by an incision made lateral to the reflection of the peritoneum of the ascending colon for a right-sided tumour or lateral to the descending colon for a left-sided tumour. The colon is mobilized off the tumour and reflected medially. Occasionally the tumour invades the mesentery and the vessels and these need to be ligated and divided preserving the marginal artery to avoid unnecessary resection of bowel.

Figure 43.3

A sling is passed around the renal vein or veins and visualize the contralateral renal vein (tumour may distort the normal anatomy). A sling around these structures would prevent any risk of embolization when mobilizing the tumour. Sling the renal artery or

arteries and the ureter. Dissection of the hilum of the kidney before mobilization is not always possible, especially when the tumour crosses the midline or if large lymph nodes are in the way.

Figure 43.2

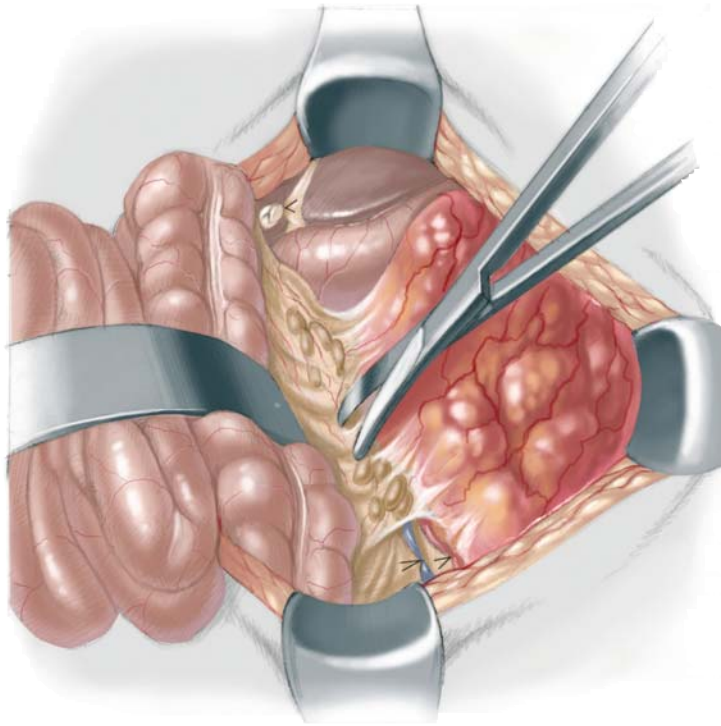


Figure 43.3

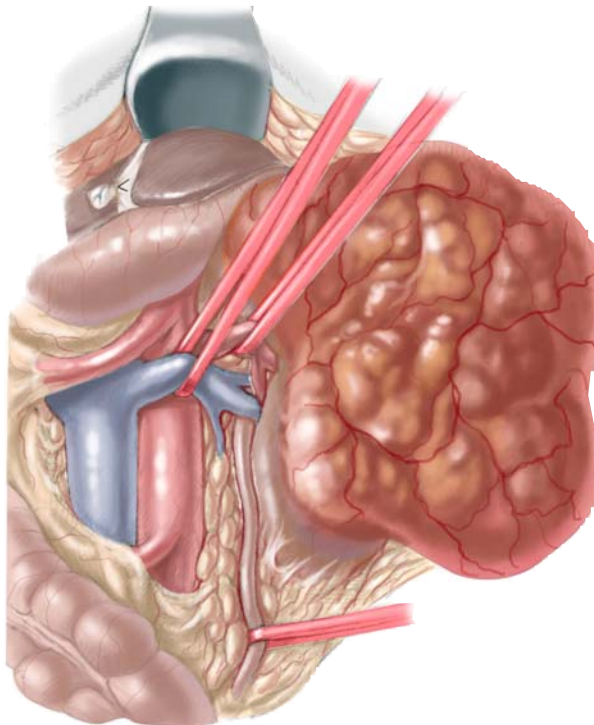


Figure 43.4

The renal vein and inferior vena cava should be palpated early for an assessment of whether an intravascular thrombus is present. Careful palpation of the contralateral vein is also indicated at this step of the surgical procedure. If a thrombus is detected in the renal vein, or the thrombus is extending into the vena cava, the appropriate vessels can be opened by a transverse incision between slings or after placement of vascular clamps, and the thrombus can be removed with an open-ended suction cannula or a Fogarty balloon catheter. The vein is then closed with a 5/0 monofilament absorbable continuous running suture.

Figure 43.5

In cases without intravascular tumour involvement, the renal artery or arteries are transfixed and the ends are ligated. Double-ligate the renal veins with nonabsorbable suture material. The renal artery (or arteries) should be ligated and divided before the renal vein (veins) to avoid excess congestion of the tumour. The para-aortic lymph nodes should be sampled both on the ipsilateral side and the contralateral side and carefully labelled. Ipsilateral and contralateral lymph nodes must be biopsied and carefully labelled, as well as the para-aortic glands on the ipsilateral side and the contralateral side. A sling is passed around the ureter at the pelvic brim and divide the ovarian vessels or testicular vessels. The ureter should be isolated off the pelvic brim and transfixed as low down as possible using absorbable suture material.

Figure 43.6

The kidney is mobilized from the retroperitoneal space. Large veins may need to be divided. Meticulous dissection is needed. If adherent to muscle or diaphragm this needs to be removed as well. Finger dissection is useful for tissue planes.

The adrenal needs to be removed as well in most cases. Any lymph nodes should be included in the mobilization and removed en bloc with the perinephric fat. These should be secured with double sutures and transfixed where appropriate as in the case of the renal artery. Sometimes large veins in the perinephric fat have to be ligated and divided. Direct infiltration of the posterior abdominal wall by the tumour can occur. Similarly, invasion of the diaphragm may require dissection of the muscle together with the tumour. The adjacent liver is usually adherent rather than actually invaded but invasion of the diaphragm is common and sometimes a portion of the diaphragm must be removed.

It is important to recognize that large tumours may displace the aorta, the vena cava, and the tumour may actually grow behind these large vessels.

Accidental ligation of the aorta or the contralateral renal vein and vena cava as well as injury to the superior mesenteric vessels have been known in the past. To avoid any doubt about which type of blood vessel is being sacrificed a loop around the vein or artery before ligating is essential. If the adrenal gland is adherent it may be removed with the tumour. The tumour must be removed en bloc with the hilar lymph nodes. This must be sent fresh to pathology.

The tumour bed should be inspected for haemostasis or residual tumour. Any suspicious area should be removed and sent for biopsy. The contralateral kidney must be carefully inspected for evidence of disease in the kidney.

Haemostasis needs to be meticulous and the tumour bed should be dry before closure of the wound. Rarely, where there is uncontrolled bleeding, a pack may need to be left in and removed 48 h later. The abdomen is closed in layers and no drain is left in situ.

Figure 43.4

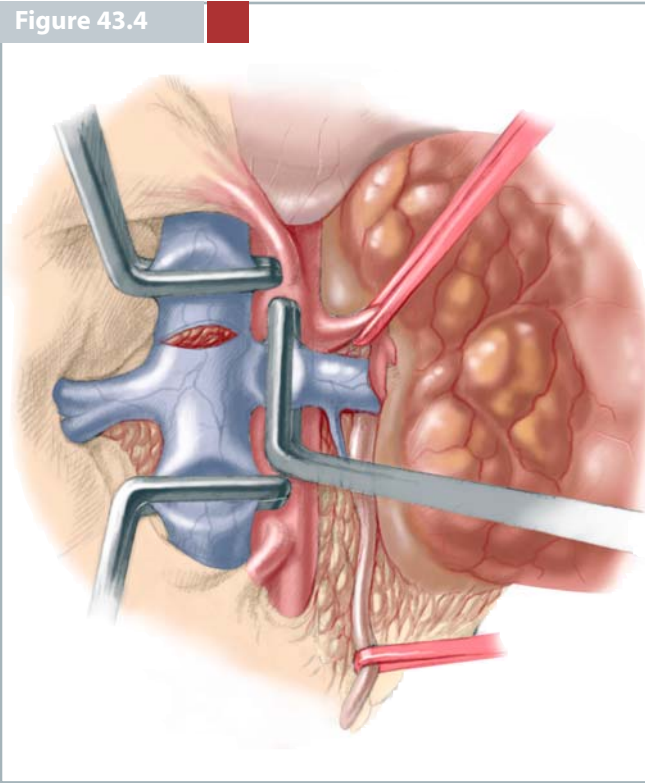


Figure 43.5

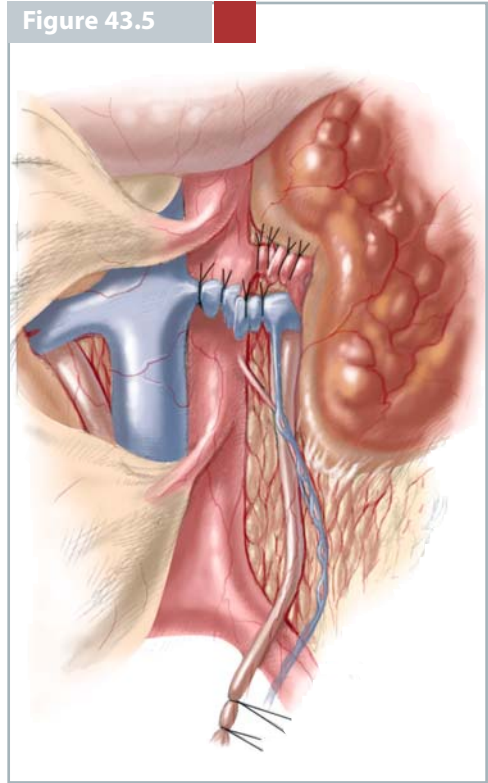
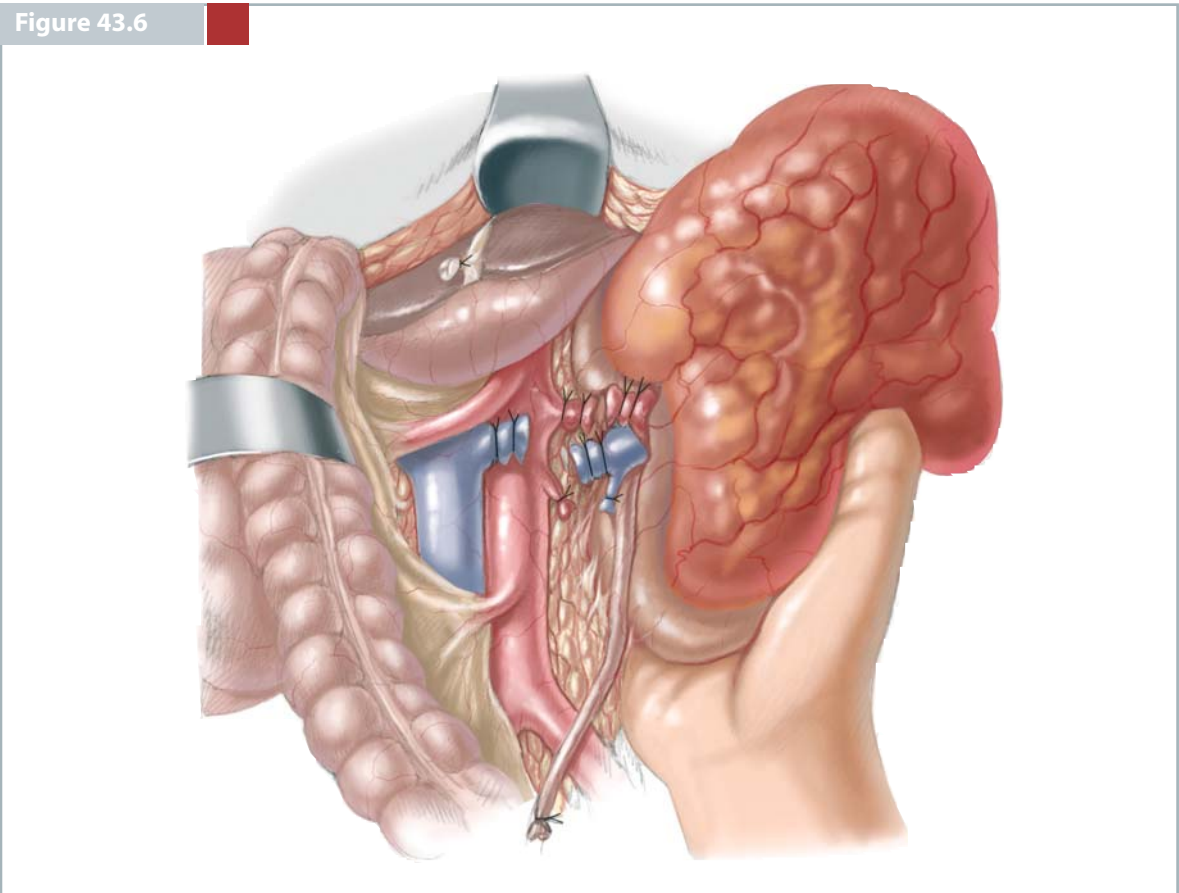


Figure 43.6



CONCLUSION

The history of the treatment of patients with a Wilms tumour is one of the most impressive success stories in pediatric surgery. While in 1941 W.E. Ladd reported a survival rate of 20%, today the relapse-free survival is close to 90% in all patients, and even 66% in the histologically high risk group. Results of the NWTs (primary surgery) and the SIOP (primary chemotherapy – with or without tumour biopsy) are similar: the rate of complications and tumour rupture is significantly higher with the primary surgery strategy. Long-term follow-up is important to detect early a metachronous tumour in the contralateral kidney. Synchronous bilateral tumours have an inci-

dence of about 10% and after initial biopsy, chemotherapy should be instituted and then partial nephrectomy carried out as well as lumpectomies. This has been found to be effective in the past. There is no place for total nephrectomy in these patients. Biopsy only and chemotherapy is indicated in patients with diffuse nephroblastomatosis; however, long-term follow-up is also crucial because late Wilms tumour occurrence is known. Recently, experiences with kidney-sparing surgery in unilateral Wilms tumours have been reported in patients with excellent response to pre-operative chemotherapy.

SELECTED BIBLIOGRAPHY

- Carachi R (2003) Congenital mesoblastic nephroma and Wilms' tumor. In: Puri P (ed) *Newborn surgery*. Arnold, London, pp 747–750
- de Kraker J et al (2001) The SIOP nephroblastoma trial and study 93–01 results and consequences. *Med Pediatr Oncol* 37:192 Abstract 0115
- Linni K, Urban C, Lackner H, Hollwarth ME (2003) Nephron-sparing procedures in 11 patients with Wilms' Tumor. *Pediatr Surg Int* 19: 457–462
- McLorie GA, McKenna PH, Greenberg M, Babyn P, Thorner P, Churchill BM, Weitzmann S, Filler R, Khoury AE (1991) Reduction in tumor burden allowing partial nephrectomy following preoperative chemotherapy in biopsy proved Wilms tumor. *J Urol* 146: 509–513
- Mushtaq I, Carachi R, Roy G, Azmy A (1996) Childhood renal tumours with intravascular extension. *Br J Urol* 78:772–776
- Othersen Biemann H, Hebra A, Tagge EP (1999) Nephroblastoma and other renal tumors. In: Carachi R, Azmy A, Grosfeld JL (eds) *The surgery of childhood tumors*. Arnold, London, pp 124–139

INTRODUCTION

Approximately 70% of liver tumours in childhood are malignant. In Europe and North America, primary malignant liver tumours constitute about 1.1% of childhood malignancies and are the tenth most common pediatric cancer. Hepatoblastomas are the most common childhood hepatic malignancy comprising nearly 80% of all primary hepatic cancers and 43–64% of all hepatic neoplasm. Most patients present at younger than 3 years of age. Hepatocellular carcinoma comprises 23% of pediatric liver tumours but is rare in infancy with a bimodal distribution. The early cases occur before 5 years of age and the second peak occurs between 13 and 15 years of age. Complete surgical resection is the prerequisite for cure in both tumours. Other primary hepatic malignancies for which liver resections may be indicated include rhabdomyosarcoma, embryonal sarcoma, leiomyosarcoma, and angiosarcoma. Benign hepatic tumours account for about one-third of all liver tumours in children and occasionally will require liver resection. These lesions include vascular malformations or hemangiomas, mesenchymal hamartoma, hepatic adenoma and focal nodular hyperplasia. The liver is a relatively frequent site of metastatic disease in childhood. Non-Hodgkin's lymphoma, neuroblastoma, rhabdomyosarcoma, rhabdoid tumours, Wilms tumour, desmoplastic small round cell tumour, adrenal cortical carcinoma, osteogenic sarcomas and a host of other malignancies may metastasize to the liver. Criteria for surgical removal of hepatic metastases include control of the primary site, a solitary or limited number of metastases, good performance status, and a reasonable expectation of prolonged survival or cure.

Children with hepatoblastoma most commonly present with an asymptomatic abdominal mass and the child is usually in good health. Thrombocytosis is common and serum α -fetoprotein is well established as an initial tumour marker in the diagnosis of hepatoblastoma and a means of monitoring the therapeutic response. The normal level is under 20 ng/ml, but can be elevated more than 20,000 times normal. Imaging studies often show a large tumour with evidence of central necrosis.

In contrast, children and adolescents with hepatocellular carcinoma frequently present with palpable abdominal masses but many are symptomatic at diagnosis. Pain, anorexia, malaise, nausea and vomiting and significant weight loss occur with greater frequency. Hepatitis B and C infections are correlated with the incidence of hepatocellular carcinoma. The α -fetoprotein is elevated in approximately 85% of patients with most levels more than 1,000 ng/ml, but usually lower than those measured in hepatoblastoma patients. Jaundice is rare in either disease. Multifocality is more common in hepatocellular carcinoma, and up to 10% may present with tumour rupture and a haemoperitoneum.

Survival in hepatoblastoma is dependent on the complete removal of the primary liver tumour. Multiple studies support the effectiveness of systemic chemotherapy combined with complete surgical resection. Historically, the combination of doxorubicin and cisplatin has been used with great success, but the present day protocol of cisplatin, 5-fluorouracil, and vincristine is equally effective and less toxic. Very young infants who undergo complete resection may receive a shortened course (three doses) of adjuvant single agent doxorubicin, which is well tolerated.

The primary treatment of hepatocellular carcinoma is also complete surgical resection and long-term survival is unlikely without it. Unfortunately, this is often impossible because of a high incidence of multifocality within the liver, extrahepatic extension to regional lymph nodes, vascular invasion, and distant metastases. Infiltration with thrombosis of portal and hepatic venous branches is common and even the vena cava may be involved. Historically, the same chemotherapy protocols used for hepatoblastoma were also applied to hepatocellular carcinomas in childhood. Cisplatin, in particular, has had activity against hepatocellular carcinoma, but long term survival still approaches zero, and new therapies are the subject of current research.

Imaging studies are crucial in the preoperative evaluation of liver tumours and in planning major hepatic resections. Doppler ultrasonography can de-

termine whether a mass is cystic or solid, determine the patency of the portal and hepatic veins and vena cava, and identify satellite lesions. At present, magnetic resonance imaging (MRI) provides the greatest amount of information concerning both the lesion and surrounding veins and bile ducts. Computerized tomography with three-dimensional reconstructed angiogram and cholangiogram has evolved recently to provide an alternative imaging modality. Doppler sonography combined with MRI of the liver gives sufficient information concerning the vascular and biliary anatomy to assess resectability and arterio-

graphy is rarely indicated. If a malignant tumour is suspected, computerized axial tomography of the chest and a bone scan are needed to rule out pulmonary and osseous metastases respectively. Cerebral metastases are rare but have been reported and patients with neurological symptoms should undergo cranial MRI. A tissue diagnosis is mandatory. Percutaneous needle core or aspiration biopsy is useful for hepatoblastomas but may not be definitive in the case of hepatocellular carcinoma. Open or laparoscopic biopsy is also acceptable.

Figure 44.1

A thorough understanding of the functional surgical anatomy of the liver is essential. The schema of hepatic anatomy most useful for the surgeon is based on the anatomic classification of Couinaud. The liver is divided into the right and left lobe by the main portal fissure containing the middle hepatic vein, marked by the line drawn from the vena cava posteriorly to the porta hepatis anteriorly. Each lobe is again divided into a paramedian and a lateral sector by the right and left hepatic veins. The left portal fissure is identified by the falciform ligament externally but there is no external feature identifying the right

portal fissure dividing the right lobe into anteromedial and posterolateral sectors. The four sectors are subdivided into anterior and posterior segments. Each of the eight segments is supplied by a portal triad composed of a branch of the portal vein and hepatic artery and drained by a tributary of the right or left main hepatic ducts. Segment one, the caudate lobe, situated posteriorly between the vena cava and the ligamentum venosus, receives inflow from both the right and left branches of the hepatic artery and portal vein, and drains directly into the inferior vena cava (IVC) via numerous small veins.

Figure 44.2

Nonanatomic wedge resections with a satisfactory margin may be feasible in the uncommon instance of a small peripheral or pedunculated lesion. More frequently, a major anatomic resection is required. Anatomic resections are associated with less blood loss and greater frequency of clear margin. The extent of the hepatic resection is based on the consideration of several factors including the location of the tumour and proximity to major vascular or ductal structures. As much as 85% of hepatic substance may be removed, with subsequent full and rapid regeneration despite the administration of postoperative chemotherapy. Preoperative portal vein embolization of the

segments to be resected has been utilized in adult patients to increase residual hepatic volume with some success.

The major hepatic resections include left lateral lobectomy with removal of segments II and III, left hepatic lobectomy (II, III, IV), extended left hepatectomy (II, III, IV, V, VIII), right hepatic lobectomy (V, VI, VII, VIII), extended right hepatectomy or right trisegmentectomy (IV, V, VI, VII, VIII) and central hepatic resection (IV, V, VIII). Segment I can also be resected during extended right or left hepatectomy to achieve tumour clearance.

Figure 44.1

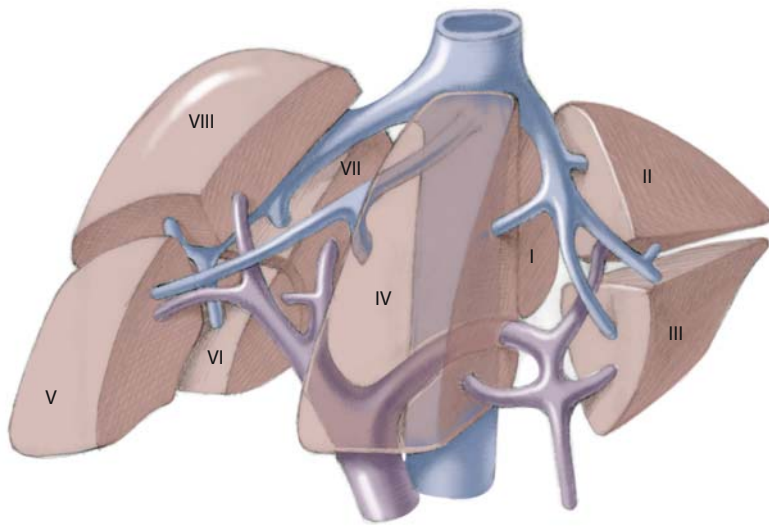


Figure 44.2

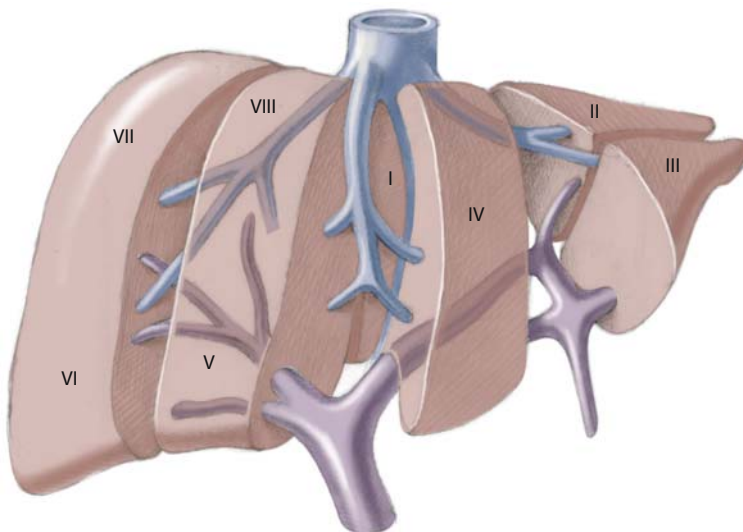


Figure 44.3

Pre-operative preparations include a comprehensive laboratory evaluation including a complete blood count, coagulation profile and liver function tests. Adequate cross-matched blood should be available. If the patient had received doxorubicin as part of the chemotherapy regimen, an echocardiogram evaluating cardiac function should be obtained. Bowel prep is carried out on the day prior to liver resection. A prophylactic antibiotic, usually a first generation cephalosporin is administered pre-operatively. Gram-negative coverage should also be instituted if the biliary tree has been previously instrumented. An epidural catheter is useful for post-operative pain control unless otherwise contraindicated. A Central venous catheter and arterial line are placed to facilitate haemodynamic management.

Pre-operative and intra-operative communication with the anaesthesiology team is extremely crucial for any major hepatic resections. The key to successful intra-operative patient care is low central venous pressure anaesthesia (LCVP) in conjunction with hepatic inflow and outflow control. LCVP is designed to preclude vena caval distension and facilitate mobil-

ization of the liver, and dissection of retrohepatic vena cava and major hepatic veins. LCVP minimizes hepatic venous bleeding during parenchymal transection and facilitates control of inadvertent venous injury. The blood loss resulting from a vascular injury is directly proportional to both the pressure gradient across the vessel wall and the fourth power of the radius of the injury as illustrated by Poiseuille's Law. In addition to decreasing the pressure component of the equation, LCVP also minimizes the radial component of flow by reducing vessel distension.

Fluid restriction is an important component of this technique and is continued until the resection is complete. Intravascular hypovolemia is counteracted with the patient in Trendelenburg position to improve venous return and preserve haemodynamic stability. The central venous pressure is kept at or below 3 mmHg and small fluid boluses may be given to maintain haemodynamic stability. With this cooperative surgical-anaesthetic technique, major hepatic resections can be carried out with minimal blood loss and morbidity.

Figure 44.4a–c

The patient is positioned supine with a roll under the upper abdomen to facilitate exposure. Slight right lateral decubitus position with the right side elevated at a 30° angle may be helpful in right hepatectomies. Hepatic resection is usually performed through a bilateral subcostal incision (chevron). Frequently, this must be extended vertically in the midline to allow visualization of the IVC at the confluence of the hepatic veins. Raising a small skin flap in the midline and incising just the midline fascia can sometimes be done. This avoids the upper skin extension and allows a more cosmetic closure. A right subcostal incision with vertical midline extension up to the base of xiphoid cartilage (hockey stick) can also be used for

patients with narrow costal margins. This approach provides similar exposure to a bilateral subcostal incision with vertical midline extension, and results in better healing. A right thoracoabdominal incision may be required in patients with large lesions that arise high in the right lobe with or without diaphragmatic invasion. This is a good approach as well if caval resection is planned because it facilitates control of the supradiaphragmatic vena cava and access to the right atrium. A left thoracoabdominal incision is rarely required. The exposure is maintained with a self-retaining retractor attached to the operating table.

Figure 44.3

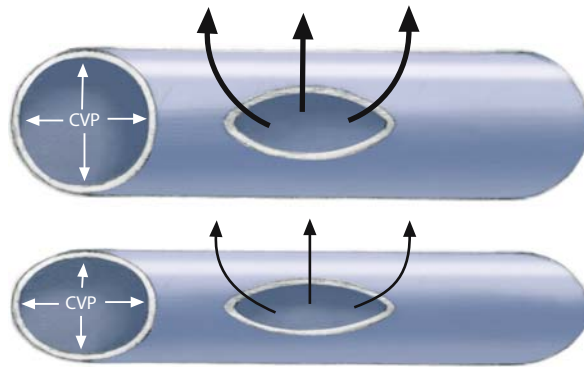


Figure 44.4a-c

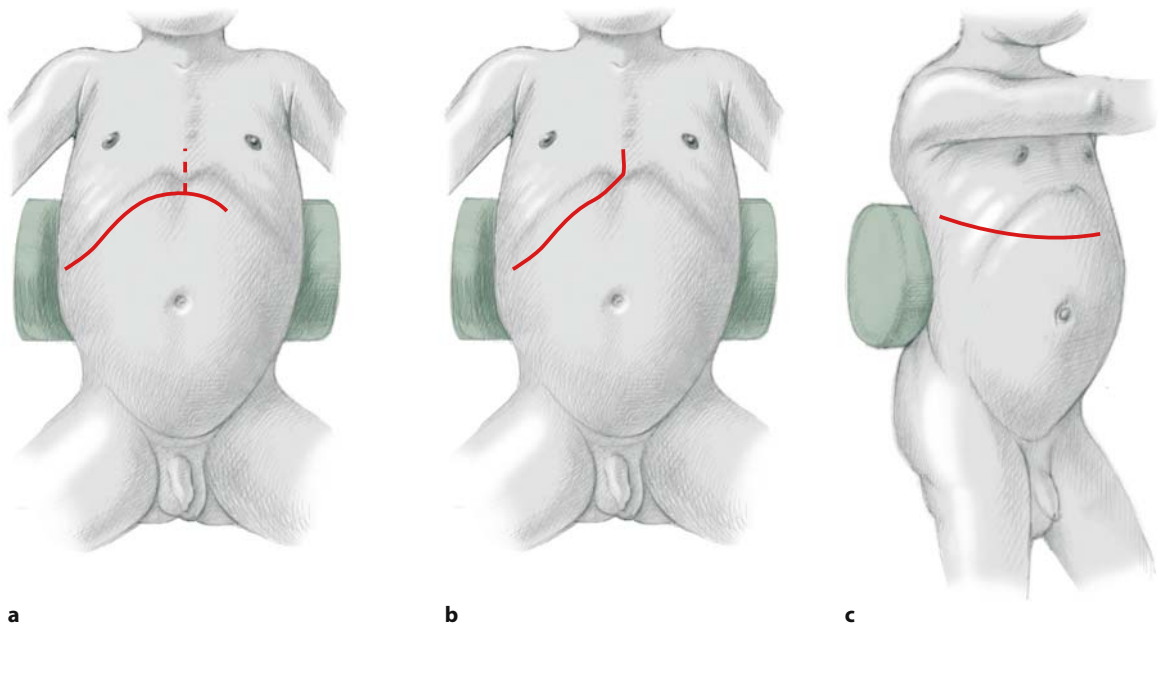


Figure 44.5

The falciform ligament is identified and the ligamentum teres (round ligament) is ligated and divided as the abdomen is entered. The falciform ligament should be divided close to the anterior abdominal wall in order to preserve for possible future use. The ligamentum teres is used later as a landmark for the umbilical fissure.

The liver is widely mobilized by sharply dividing the right triangular and coronary ligaments to the falciform ligament anteriorly and the IVC posteriorly. The left triangular ligament is also separated from

the diaphragm with care not to injure the left phrenic vein. The suprahepatic vena cava and the hepatic veins are visualized. Thorough palpation of the entire liver should be carried out to identify multifocal disease and congenital anomalies. Intra-operative ultrasound, if available, maybe performed at this stage to look for satellite lesions, and to further delineate vascular and ductal anatomy. Tumour proximity or invasion into vascular or ductal structure can be identified to better plan resection and reconstruction.

Figure 44.6

Once resectability is confirmed, the hepatoduodenal ligament is identified and surrounded with a looped vascular tape to expedite a subsequent Pringle manoeuvre. A Rumel tourniquet may also be used.

The key principle in all major hepatic resection is the control of vascular structures prior to parenchymal division. This can be achieved with extrahepatic vascular control or hepatic pedicle ligation.

Figure 44.5

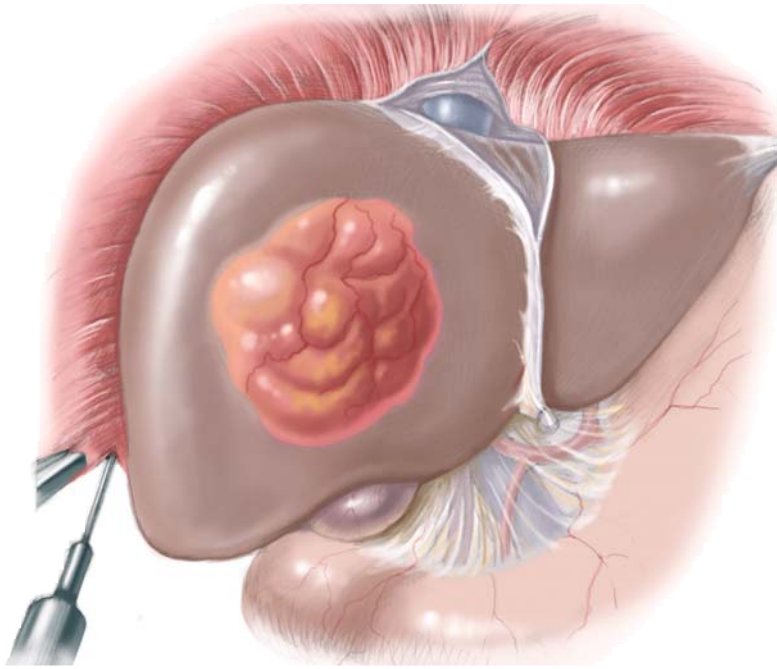


Figure 44.6

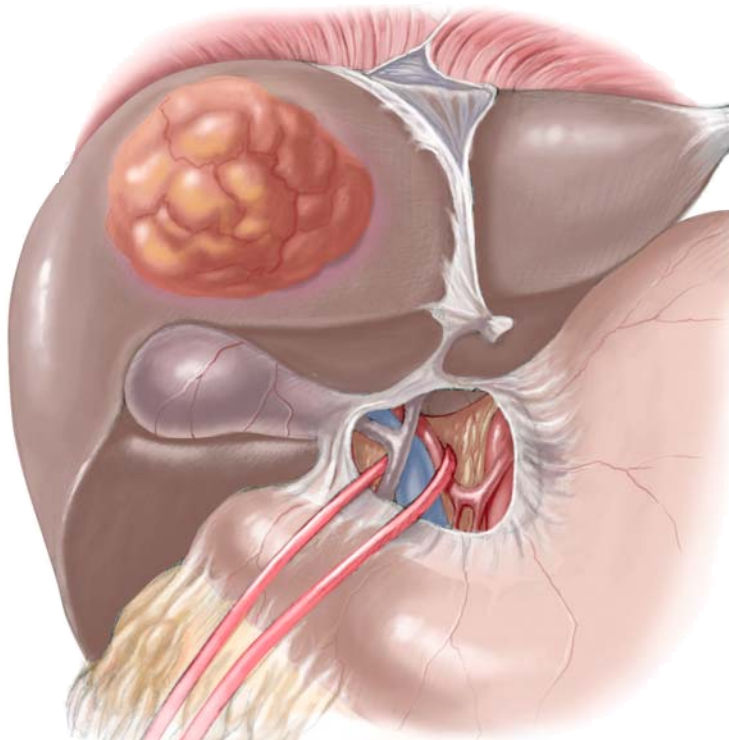


Figure 44.7

■ **Extended Right (1) – Right Lobe Inflow Control.** Right hepatic resections are the most frequently performed major liver resections (60%). Segments V, VI, VII, and VIII are removed in right hepatic lobectomy. An extended right hepatectomy or right trisegmentectomy additionally removes segment IV, and segment I may be included as well.

After mobilizing the liver and obtaining control of the hepatoduodenal ligament, the cystic duct and artery should be ligated and divided. The gallbladder infundibulum can be dissected free from the liver and retracted superiorly to expose the hilar plate.

The first step in vascular control of segments V–VIII is the exposure of the right hepatic artery and the right branch of the portal vein by lowering the hilar plate. The hilar plate is divided and lowered using sharp dissection to expose the bifurcation of the hepatic artery and portal vein, as well as the confluence of the hepatic ducts.

The right hepatic artery arises from the main hepatic trunk and usually passes posterior to the common bile duct. With the common bile duct gently retracted to the left, the right hepatic artery is isolated and divided. The right branch of the portal vein is then dissected free and then divided between vascular clamps or ligated in continuity. The proximal stump is oversewn with fine Prolene sutures. Alternatively, a vascular stapler can be used.

To minimize injury to the biliary tree, the extrahepatic biliary dissection can be withheld and the right hepatic duct controlled and divided intrahepatically later during parenchymal transection. If the right hepatic duct is divided at the hilum, it must be made certain that the confluence of the common bile duct and the left hepatic duct is well preserved.

Figure 44.8

Alternatively, a right pedicle ligation technique can be employed. Hepatotomies are made at the base of the gallbladder fossa and the caudate lobe. The right pedicle is isolated intraparenchymally through the hepatotomies and divided with a vascular stapler.

The advantage of this manoeuvre is that the left pedicle is well protected. However, if the tumour is close to the hilum, extrahepatic inflow control will be necessary to achieve tumour clearance.

Figure 44.7

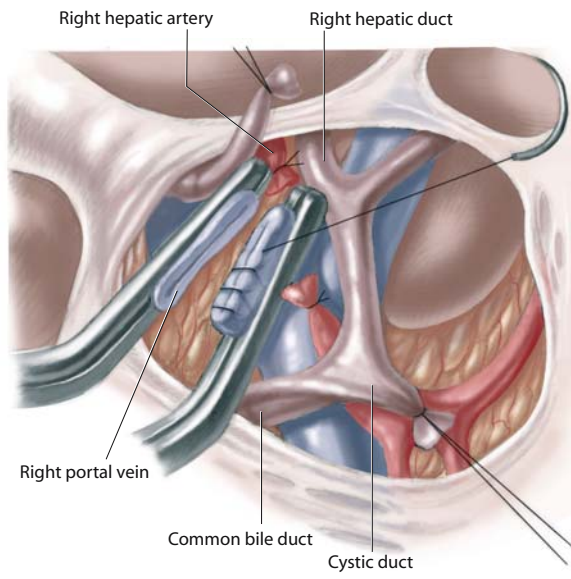


Figure 44.8

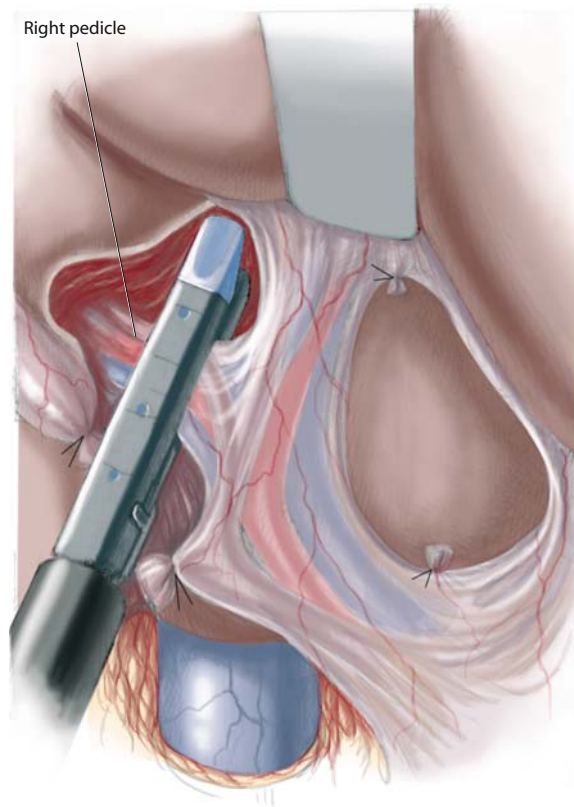


Figure 44.9

■ **Extended Right (2) – Inflow Control of Segment I.** Following inflow control to the right lobe, the next important step is to define the umbilical fissure. The left portal triad enters the liver at the base of the umbilical fissure. The umbilical fissure is exposed and opened by retracting the ligamentum teres superiorly and the left portal vein, left hepatic artery and left hepatic duct are visualized. The segmental portal

triads to segment IV can be controlled during parenchymal transection to avoid injury to the vascular supply or biliary drainage of the left lateral segment and the caudate lobe if it is to be preserved. However, if the tumour encroaches upon the umbilical fissure, these segmental IV branches can be isolated and divided within the umbilical fissure.

Figure 44.10

■ **Extended Right (3) – Outflow Control.** Control of the hepatic vein is the most delicate manoeuvre of any hepatic resection. Attempts at early control of the hepatic vein before hilar vascular control can result in hepatic vein injury and haemorrhage. Placing the patient in Trendelenburg position with 15° head down reduces pressure in the IVC and hepatic veins and minimizes the risk of air embolus.

The division of the right hilar structures will reduce blood flow through the right hepatic vein and facilitate its dissection. The right lobe is rolled toward the patient's left and the retrohepatic vena cava is exposed. The IVC ligament is a fibrous band of tissue that obscures the right upper portion of the retrohepatic vena cava. This needs to be divided sharply in order to expose the right hepatic vein. Next, small unnamed hepatic veins that extend from the retrohepatic vena cava to the right hepatic lobe and

the caudate lobe are ligated or clipped and divided individually in an inferior to superior fashion. For large right-sided tumours, a large unnamed hepatic vein is usually found before the main right hepatic vein. After this is divided, the junction of the right hepatic vein and the retrohepatic vena cava is carefully exposed and right hepatic vein is encircled with a vessel loop. The right hepatic vein is then suture ligated or oversewn or divided with vascular stapler.

The middle hepatic vein is taken in extended right hepatectomy. The middle hepatic vein usually joins the left hepatic vein but may enter the vena cava separately on occasion. Extrahepatic isolation of the middle hepatic vein can be difficult and may risk injury to the left hepatic vein. Thus the middle hepatic vein is usually controlled during parenchymal transection.

Figure 44.9

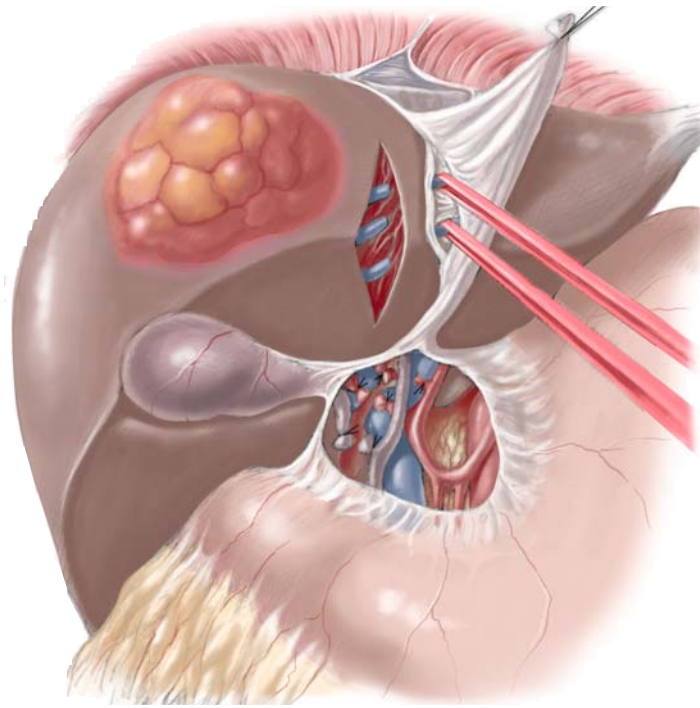


Figure 44.10

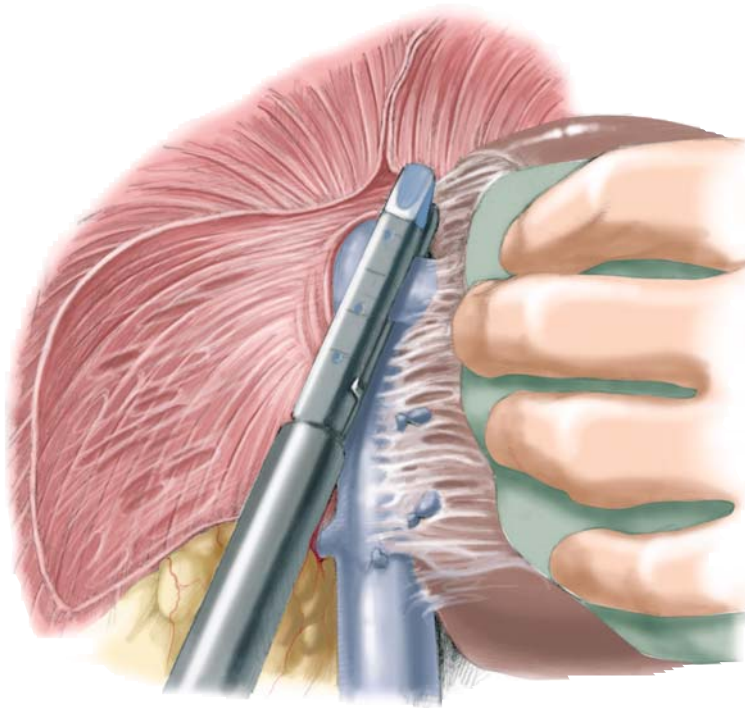


Figure 44.11

■ Extended Right (4) – Parenchymal Transection.

After a vascular isolation of segments IV–VIII is complete, the line of ischaemic demarcation becomes apparent. The liver capsule (Glisson capsule) is scored with electrocautery along the line of devascularization. The hilar vessels are occluded with the Pringle manoeuvre intermittently for intervals not exceeding 15 minutes at a time. This manoeuvre ensures minimal blood loss during parenchymal transection. The hepatic substance is divided slowly and carefully after fracture with a Kelly clamp. Vascular and biliary radicals are meticulously secured with haemoclips or suture ligatures. Cavitron ultrasonic aspirator, water jet dissector, laser, or harmonic scalpel may also be used for parenchymal division in difficult cases or based on personal preference.

If the recurrent branches to segment IV are still intact, parenchymal dissection is carried out anteri-

orly down to the base of the umbilical fissure and the arterial and portal vessels to segment IV are identified and divided. This is continued posteriorly toward the vena cava and along the plane just to the right of the falciform ligament. The middle hepatic vein is encountered and controlled by suture ligation or division with the vascular stapler. The left hepatic vein is carefully preserved.

After the specimen is removed and the Pringle manoeuvre is released, the raw cut surface is observed for haemostasis. The argon beam coagulator is useful in controlling the oozing from the cut surface. Major sources of haemorrhage should be suture ligated. A Valsalva manoeuvre will increase the hepatic venous pressure and is helpful in identifying additional bleeding. Topical agents such as thrombin, fibrin glue, or Gelfoam may also be applied.

Figure 44.12

■ **Extended Right (5) – Biliary Reconstruction.** Occasionally a large tumour in the base of segment IV may encroach upon the left hepatic duct as it enters the umbilical fissure. If this is the case, mobilizing the left hepatic duct at the hilar area can be difficult and a portion of the left hepatic duct may be resected. The biliary drainage can be re-established by a Roux-en-Y hepaticojejunostomy.

At the conclusion of an extended right hepatectomy, segments I, II and III are left intact. The remaining liver parenchyma is then inspected to ensure viability. The operative field is copiously irrigated.

Elective and uncomplicated hepatic resections do not usually need drainage

The midline portion of the incision is closed with interrupted absorbable monofilament sutures. The subcostal incision is then closed by re-approximating the peritoneum and transversus abdominus. The internal oblique and the posterior sheath are closed next followed by the external oblique and anterior rectus sheath. The subcutaneous space is irrigated again and the Scarpa's fascia is closed to eliminate dead space. Finally, the skin is closed in a subcuticular fashion.

Figure 44.11

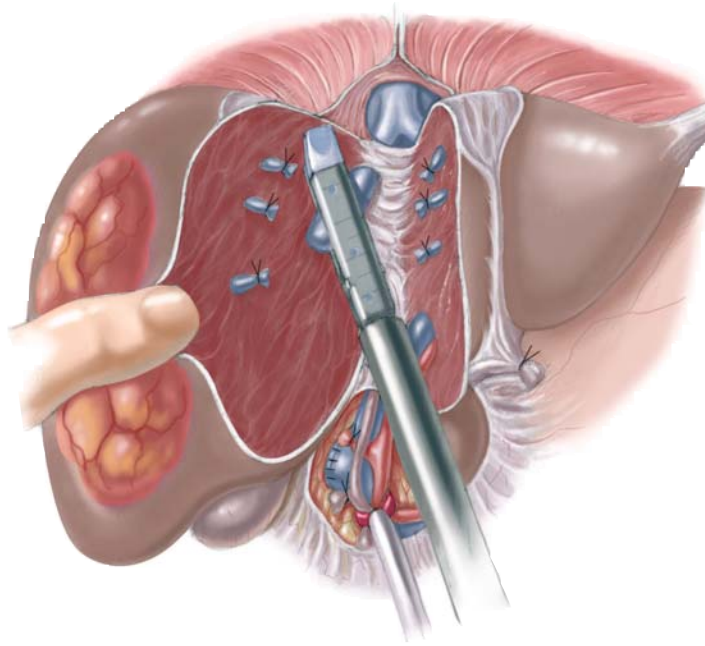


Figure 44.12

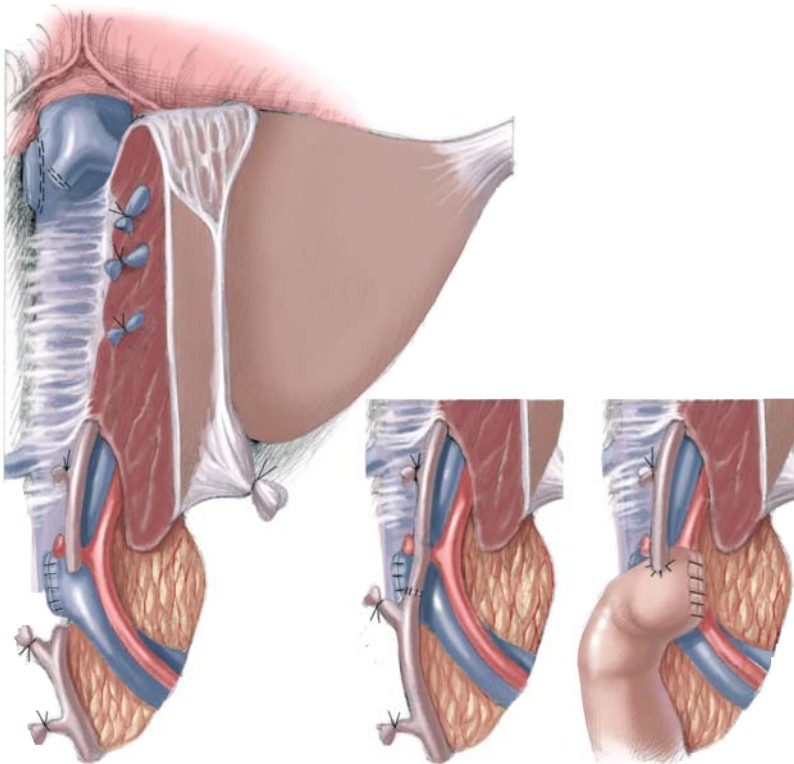


Figure 44.13, 44.14

■ **Extended Left Hepatectomy.** Extended left hepatectomy is necessary when a large tumour arising from the left lobe of the liver crosses the portal fissure into segments V and VIII. It may also be carried out to clear multifocal disease. The left lobe and the right anterior sector, which consist of segments II, III, IV, V and VIII, are removed en mass and segment I (caudate lobe) may also be included in the resection.

The liver is completely mobilized by dividing both the right and left ligamentous attachments. Inflow control is obtained by the ligation and division of the left hepatic artery at the base of the umbilical fissure. The left portal vein is exposed along the umbilical fissure and the branches to the caudate lobe are identified. The portal vein is divided distal to the take-off of the caudate branches. If the caudate lobe is to be removed, the left hepatic artery and portal vein can be controlled at the hilus. The left hepatic duct is then identified and ligated and divided.

The suprahepatic vena cava is fully exposed in the bare area of the liver. The middle and left hepatic veins are controlled next. The middle hepatic vein usually joins the left hepatic vein but may enter the vena cava separately on occasion. The liver is rotated

toward the right and the ligamentum venosum is exposed and divided. This opens up a space allowing the middle and left hepatic veins to be encircled and divided. This can be accomplished by oversewing the stump or using the vascular stapler. If the caudate lobe is also to be removed, it is carefully mobilized from the vena cava by serially ligating the short retrohepatic veins with sutures or clips.

Inflow control to segments V and VIII is accomplished via the right anterior sectoral pedicle. Hilar dissection is carried out along the right portal vein and right hepatic artery until they branch into anterior and posterior pedicles. Partial parenchymal division may be required for the dissection. The fissure of Gans is a reliable indicator of the course of the posterior pedicle and is used for orientation. Once the anterior pedicle is identified and encircled, it can be suture ligated or divided with vascular stapler.

This will result in a clear ischaemic demarcation on the surface of the liver indicating the plane of parenchymal transection. This plane lies horizontally, lateral to the gallbladder fossa, parallel and just anterior to the right hepatic vein. The parenchymal transection is then carried out as described previously.

Figure 44.13

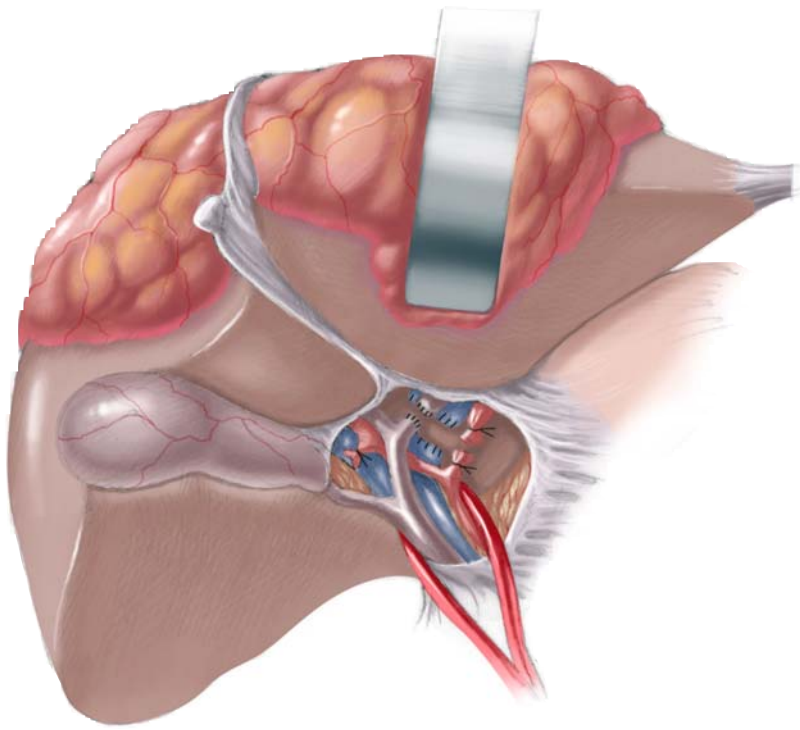


Figure 44.14

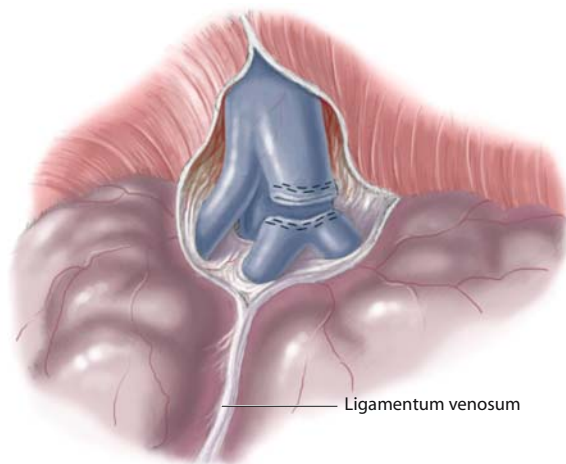


Figure 44.15

Central hepatic resection removes segments IV, V and VIII. This procedure is indicated for centrally located hepatic lesions. It avoids the use of extended hepatectomy. The major advantage is the preservation of normal hepatic parenchyma and may lower the risk of late complications such as biliary tract stricture.

The liver is mobilized and the porta hepatis is isolated and surrounded with a vascular tape. The hilar plate is lowered and the confluence of the right and left hepatic arteries and portal veins are exposed as described earlier. The recurrent branches of the left portal vein to segment IV are divided in the umbilical fissure, taking care to preserve the branches to the left lateral segment and the caudate lobe.

Figure 44.16

The middle hepatic vein is ligated as dissection approaches the vena cava. The left hepatic vein should be carefully preserved.

Control of the arterial and portal inflow to segments V and VIII is accomplished by ligation of the right anterior sectoral pedicle. This will lead to a clear demarcation of segments V and VIII anterior to the right hepatic vein used as the plane of parenchymal transection. Segments IV, V, and VIII are now de-

vascularized and isolated from the rest of the liver. A Pringle manoeuvre is performed and the remaining hepatic substance posteriorly and inferiorly is divided with gentle crushing technique with meticulous haemoclipping of vascular and biliary radicals. At the completion of central hepatic resection, the middle hepatic vein has been ligated and the right and left hepatic veins are left intact.

Figure 44.15

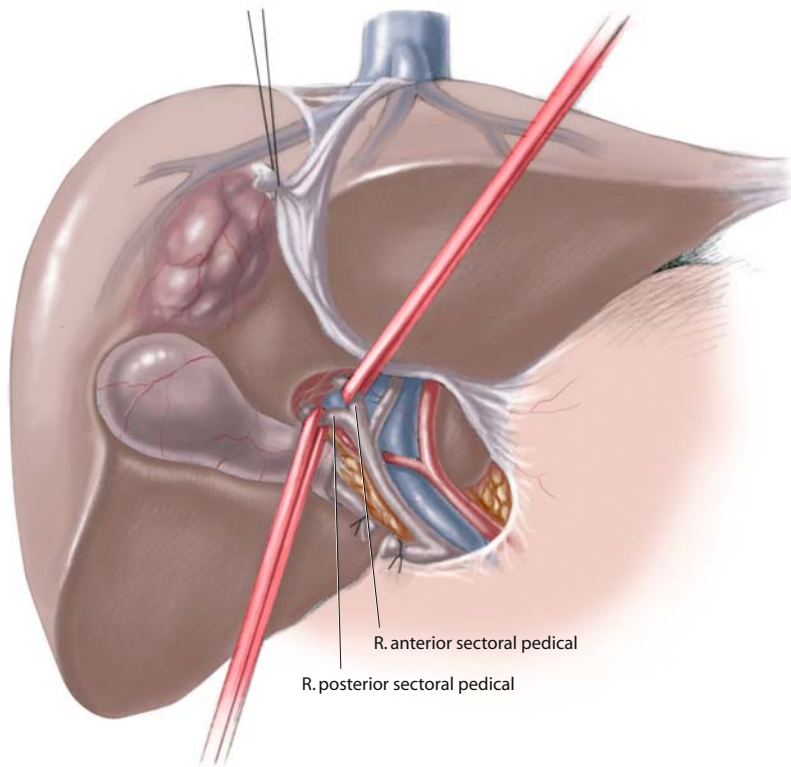
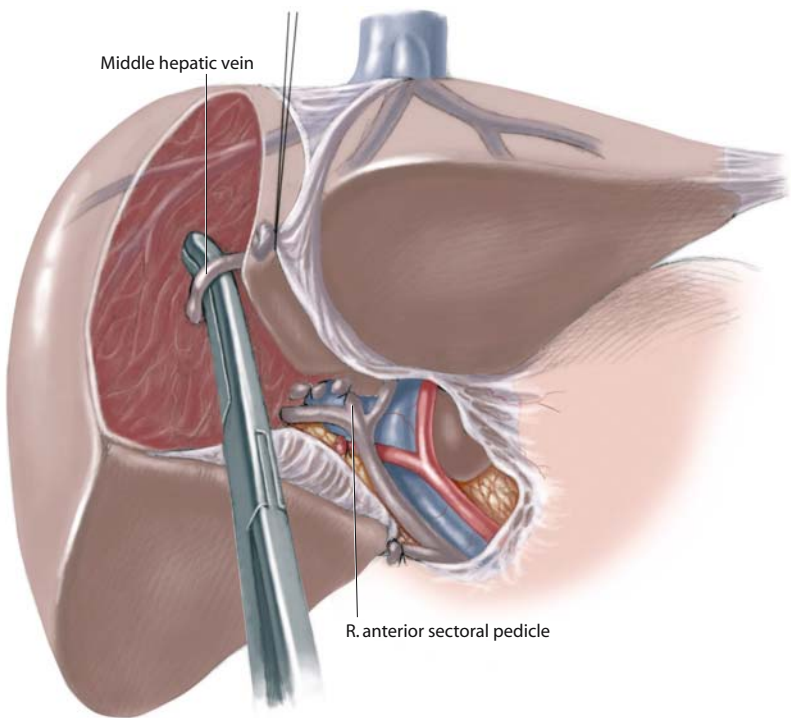


Figure 44.16



CONCLUSION

Major hepatic resection is safe even in small infants. The operative mortality is less than 5%. This can be minimized to nearly zero with judicious use of invasive monitoring, LCVP and meticulous surgical techniques.

An overall survival of 85–90% is possible after complete surgical resection of non-stage IV hepatoblastoma. Approximately 50% of patients who present with pulmonary metastases are curable. Of utmost importance is the removal of the primary hepatic lesion. If gross disease is left in-situ in the primary site, survival falls to zero. Some patients with microscopic residual are curable with continued chemotherapy and may benefit from external beam radiotherapy to the primary hepatic site. In multivariate analysis, factors that have been independent predictors of worsened prognosis include a high TNM stage, unresectable tumour, bilobar involvement and multifocality, α -fetoprotein <100 or $>10^5$ ng/ml, distant metastases, embryonal versus fetal histology, and vascular invasion.

In contrast, the overall survival from hepatocellular carcinoma in childhood is about 20% at 5 years and it remains a therapeutic dilemma. Chemotherapy is only partially effective for hepatocellular carcinoma. Complete resection of localized lesions remains the only realistic chance of cure.

About 46% of hepatic malignancies are resectable at diagnosis. Often, resection is not feasible if the tumours are large and involve both hepatic lobes. For unresectable tumours, the initial surgical procedure should include a diagnostic biopsy and placement of a vascular access device for chemotherapy. Neo-adjuvant chemotherapy will result in tumour shrinkage and make subsequent resection easier. A second laparotomy is performed after four cycles of chemotherapy if imaging studies show a good response and the

tumour appears resectable. Complete resection of the primary tumour is necessary for survival and may require extended hepatic lobectomies or complex biliary reconstructions. The patient should receive several cycles of chemotherapy after definitive resection.

The definition of resectable disease has been extended to complete hepatectomy and liver transplantation. Transplantation is a potentially curative treatment for chemosensitive hepatoblastomas when partial hepatectomy is not possible due to multifocality or suboptimal margins. Tumours with extensive extrahepatic extension or vascular invasion have poorer outcomes with total hepatectomy and hepatic transplantation. Chemoembolization is a new adjuvant treatment option that involves arteriographic injection of cisplatin and or doxorubicin followed by occluding thrombogenic materials (Gelfoam) into arteries feeding the hepatic tumour/tumours. Data have shown that chemoembolization may result in some tumour reduction but does not improve resectability. In a variation of this approach, some researchers have used superselective intraarterial radiometabolic therapy for malignant hepatic tumour. Other approaches include treatment with anti- α -fetoprotein antibodies and the use of viral transfection vectors to attack malignant hepatic cells.

In conclusion, infants and children with liver malignancies can be treated successfully with complete surgical resection using anatomic hepatectomies with little subsequent morbidity. Patients with hepatoblastoma have excellent prognosis with the combination of complete surgical resection and chemotherapy. Some patients with hepatocellular carcinoma can be cured with liver resection but the poorer prognosis obligates the development of additional treatment modality.

SELECTED BIBLIOGRAPHY

- DeMatteo RP, Fong Y, Jarnagin WR (2000) Recent advances in hepatic resection. *Semin Surg Oncol* 19: 200–207
- Ehrlich PF, Greenberg ML, Filler RM (1997) Improved long-term survival with preoperative chemotherapy for hepatoblastoma. *J Pediatr Surg* 32: 999–1003
- Glick RD, Blumgart LH, La Quaglia MP (2000) Extended left hepatectomy in childhood. *J Pediatr Surg* 35: 303–308
- Melendez JA, Arslan V, Blumgart LH (1998) Peri-operative outcome of major hepatic resections under low central venous pressure anesthesia – blood loss, blood transfusion and the risk of post-operative renal dysfunction. *J Am Coll Surg* 178: 620–625
- Reynold M (2001) Current status of liver tumors in children. *Semin Pediatr Surg* 10: 140–145

Jonathan Ross

INTRODUCTION

Testicular tumours account for 1–2% of pediatric solid tumours. Pediatric testis tumours are pathologically and clinically distinct from their adult counterparts, and these differences demand a different management algorithm. While nearly 90% of adult testis tumours are seminomas, embryonal carcinomas or non-seminomatous mixed germ cell tumours, such tumour types account for fewer than 10% of tumours in children. Conversely, the two most common prepubertal tumours – yolk sac and teratoma – account for fewer than 1% each of adult tumours. Gonadal stromal tumours are relatively common in children, but quite rare in adults. These differences in histologic sub-type result in significant differences in natural history with metastases occurring in 61% of adult patients but in only 9% of children. The critical histologic changes appear to occur at puberty. Therefore, tumours occurring in postpubertal adolescent males are best managed under adult algorithms.

Most testicular tumours present as a painless hard mass, though rarely they may present with pain related to an acute bleed. On physical examination, a mass that cannot be separated from the testis is assumed to be a testis tumour until proven otherwise. Ultrasound is very helpful in making this distinction when the physical examination is unclear. Rarely, testis tumours may present with a reactive hydrocele. If a hydrocele is large and firm enough to preclude palpation of the testis, an ultrasound should be obtained.

A significant proportion of prepubertal testis tumours are benign. Tumours may be of germ cell or stromal origin (the exception being gonadoblastomas, which contain elements of both). Yolk sac tumours, the most common, are always treated as potentially malignant. Teratomas, the second most common tumour, are universally benign in prepubertal patients. Gonadal stromal tumours have generally behaved in a benign fashion in children, except for some undifferentiated stromal tumours and occasional Sertoli cell tumours in children over 5 years of age.

Pre-operative evaluation includes an ultrasound scan and determination of the α -fetoprotein (AFP) level. Ultrasound is helpful in distinguishing intratesticular from extratesticular scrotal masses. It can also determine whether the entire testis is replaced with tumour, or if there is some normal testicle that

may be salvaged if the tumour is benign. Serum AFP is elevated in 90% of children with yolk sac tumours. AFP is very specific for yolk sac tumour, but may be physiologically elevated in normal infants (including those with benign tumours). Generally speaking, a child over 1 year of age with a testicular mass and an elevated AFP can be assumed to have a yolk sac tumour. Infants under 1 year of age with an elevated AFP may have benign tumours, though AFP levels are rarely greater than 100 ng/ml in normal children over 6 months of age. The ultrasonographic characteristics of various testis tumours have been described. However, the findings are not specific enough to alter management, which is based on the AFP level and whether salvageable testis is present. If the tumour is felt to be malignant or if it completely replaces the testis precluding testis-sparing surgery, then an inguinal orchiectomy is performed. Tumours that are likely to be benign based on AFP level, and that appear to have salvageable normal testis on ultrasound, should be managed initially with an excisional biopsy and frozen section analysis. If a benign histology is confirmed then the testis is closed with absorbable suture and returned to the scrotum. If the biopsy reveals a malignant tumour (usually yolk sac) or potentially malignant tumour (such as an undifferentiated stromal tumour or a Sertoli cell tumour in an older child), then an inguinal orchiectomy should be performed. If a teratoma is diagnosed and the child is near pubertal age, the surrounding parenchyma should be examined for its pubertal status. If the tubules are immature, then the tumour may be treated as benign. However, if the tubules show evidence of maturation, the tumour should be treated as potentially malignant since some adult teratomas behave in a malignant fashion.

Retroperitoneal lymph node dissection plays a very limited role in prepubertal testis tumours. Unlike adults, only a minority of prepubertal patients with metastases have metastases limited to the retroperitoneum, and metastatic disease is very responsive to chemotherapy. Furthermore, the complication rate following retroperitoneal lymph node dissection (RPLND) is significantly higher in children than in adults. The only clear indication for RPLND is the persistence of a retroperitoneal mass following chemotherapy – a rare occurrence.

Figure 45.1

The patient is placed in the supine position. If possible, a caudal block has been applied. An inguinal skin incision is made extending laterally from just above the pubic tubercle following Langer's lines. The subcutaneous tissue is divided with cautery. The superficial epigastric vein is often encountered in the lateral corner of the incision and should be controlled with cautery.

The superficial fat may then be separated bluntly with retractors exposing Scarpa's fascia. Scarpa's fascia is grasped with forceps and opened with scissors.

The tissue between Scarpa's fascia and the external oblique aponeurosis is developed by gentle spreading and Scarpa's fascia is then divided throughout the length of the incision.

A small incision is made in the external oblique aponeurosis near the lateral corner of the incision so that it comes through above the internal ring where it is unlikely to injure the ilioinguinal nerve. After bluntly pushing the ilioinguinal nerve down from the undersurface of the aponeurosis, the aponeurosis is opened with scissors through the external ring.

Figure 45.2

With blunt dissection the plane behind the cord is developed and a vessel loop passed behind it. With a combination of blunt and cautery dissection this plane is developed proximally to the internal ring

and a rubber shod clamp used to occlude the vessels at the internal ring. Then the testis is delivered into the operative field and the gubernaculum is divided with cautery.

Figure 45.1

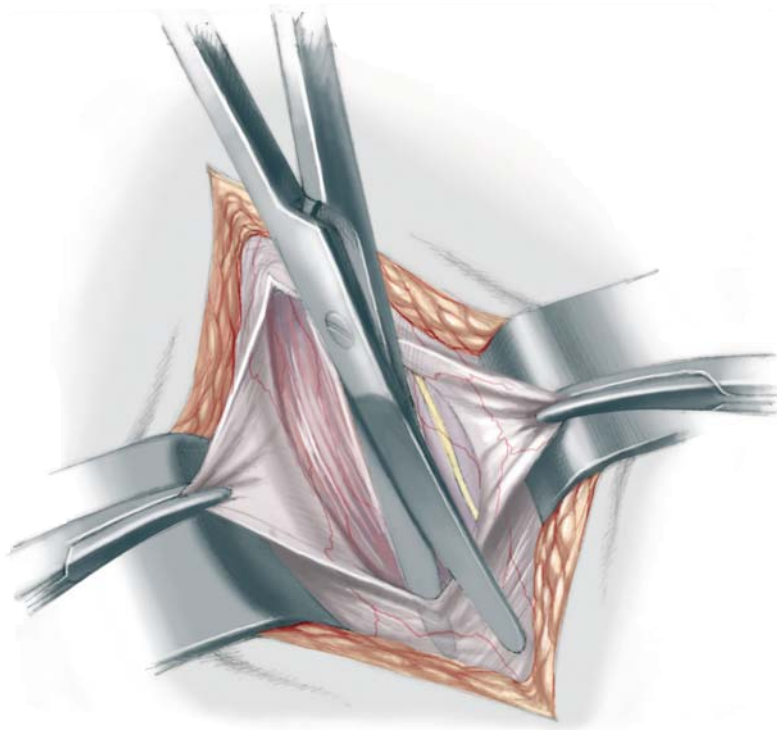


Figure 45.2

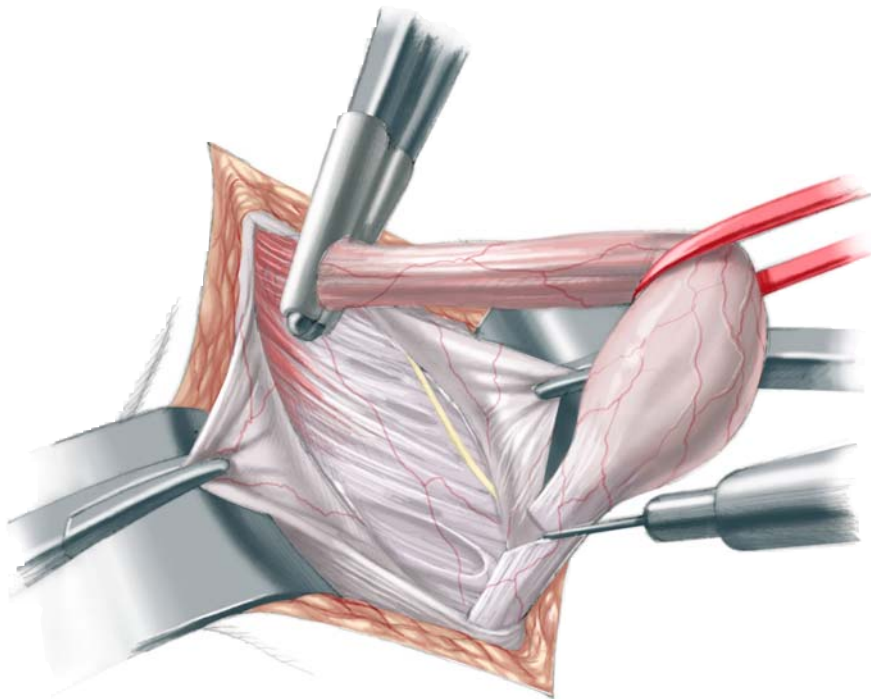
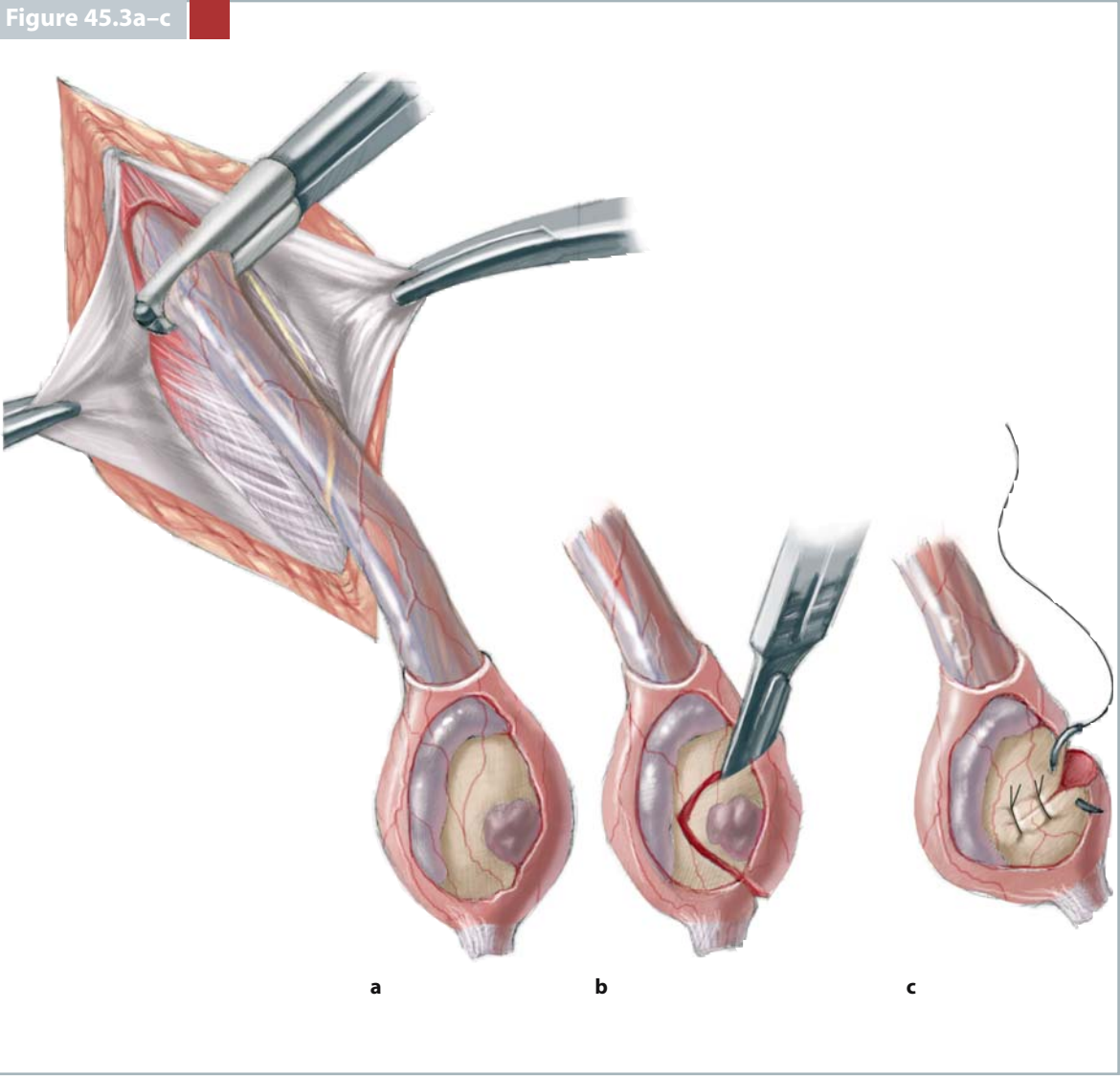


Figure 45.3a–c

If the pre-operative assessment suggests a malignancy, then the hydrocele sac is left intact and the specimen ligated and divided at the internal ring without manipulation of the testicle (not shown). If the pre-operative evaluation is equivocal with regard to the malignant nature of the tumour, then the hydrocele sac is opened after draping off the testis to isolate it from the field (drapes not shown). A wedge excision of the tumour with a margin of normal parenchyma

is undertaken and a frozen section analysis obtained. If the tumour is benign on frozen section, then the testis is closed with 5/0 absorbable suture and returned to the scrotum. If the tumour is malignant, then the cord is doubly suture-ligated with nonabsorbable suture and divided at the internal ring. The entire specimen is sent for histopathological evaluation. The incision is closed in layers with absorbable suture.

Figure 45.3a-c



CONCLUSION

Surgical complications are rare following inguinal orchiectomy or tumour excision. Local recurrence following simple excision has not been reported for benign tumours or following inguinal orchiectomy for malignancy. However, local recurrence in the scrotum has occurred following transcrotal biopsy of malignant tumours, and a scrotal approach for possible malignancies must be avoided. The occasional complications that can occur following inguinal orchiectomy are scrotal infection or haematoma and retroperitoneal haematoma. These can generally be avoided with meticulous surgical technique and thorough haemostasis of the raw surface of the inner scrotum.

The survival of children with testis tumours depends on the histology of the tumour and the presence or absence of metastatic disease. Children with teratomas, epidermoid cysts, and benign stromal tumours do well with excision alone. No long-term follow-up is required. Patients with yolk sac tumour re-

quire a metastatic evaluation consisting of a computerized tomography (CT) scan of the abdomen and pelvis, a chest X-ray, and determination of AFP level. The half-life of AFP is 5 days. Approximately 80% of patients will have stage 1 disease (disease limited to the testicle) confirmed by a negative chest X-ray and CT scan and normalization of the AFP level. These patients may be observed closely without adjuvant therapy. Follow-up includes CT scans every 2 months and chest X-rays and AFP levels monthly for 2 years, followed by observation at longer intervals. The relapse rate for stage 1 patients is approximately 20% and virtually all patients can be salvaged with chemotherapy. Patients who present with metastatic disease are treated with adjuvant chemotherapy, and survival is better than 90%. Radiation plays no role in the primary treatment of these tumours. Metastatic stromal tumours, while exceedingly rare, are resistant to treatment. Survival is low for this group.

SELECTED BIBLIOGRAPHY

- Haas RJ, Schmidt P, Gobel U, Harms D (1999) Testicular germ cell tumors an update – results of the German Cooperative Studies 1982–1997. *Klin Padiatr* 211: 300–304
- Ross JH, Rybicki L, Kay R (2002) Clinical behavior and contemporary management algorithm for prepubertal testis tumors: summary of the Prepubertal Testis Tumor Registry. *J Urol* 168: 1675–1679
- Rushton HG, Belman AB, Sesterhenn I et al (1990) Testicular sparing surgery for prepubertal teratoma of the testis: a clinical and pathological study. *J Urol* 144: 726–730
- Weissbach L, Altwein JE, Stiens R (1984) Germinal testicular tumors in childhood. *Eur Urol* 10: 73–85

INTRODUCTION

Widespread use of maternal ultrasound has significantly changed the practice of paediatric urology. Pelvi-ureteric junction obstruction (PUJ) is the most common cause of hydronephrosis detected antenatally. Controversy continues on the optimal timing of surgical intervention in children with antenatally detected hydronephrosis. However, it is beyond the scope of this chapter to discuss all the aspects of post-natal management of children with prenatal diagnosis of PUJ. The decision to intervene surgically in these infants has become more complex because spontaneous resolution of antenatal and neonatal upper urinary tract dilatations is being increasingly recognized. The recognition and relief of significant obstruction is important to prevent irreversible damage to the kidneys. Differentiating urinary tract dilatations that are significantly obstructive and require surgery from those that represent more anatomical variants with no implications for renal function is not a simple task especially in the newborns. The important aspect of post-natal investigations is to identify the group of patients who will benefit from early intervention and those who need to be carefully followed up. Currently surgery is undertaken in infants with deteriorating renal function. Before the routine fetal ultrasonography, the commonest presentation was with abdominal flank mass. Some patients present with urinary tract infection, irritability, vomiting and failure to thrive. In those patients who had prenatal diagnosis of hydronephrosis ultrasonography is performed in the first week of life. After confirmation of hydronephrosis radionuclide studies are undertaken when the child is 6–8 weeks old in order to assess renal function and rule out obstruction. In those patients who present with clinical symptoms a renal ultrasound is performed. If this shows hydronephrosis without dilated ureters, the diagnosis is confirmed with radionuclide studies. The most commonly performed radionuclides are diethylenetriaminepentaacetic acid (DTPA) and mercaptocetyl-triglycine (MAG₃). Since, MAG₃ is excreted mostly by the renal tubules and yields better images in infants with compromising renal function we have started to use routinely MAG₃ in patients with hydronephrosis and deteriorated renal function.

There are different techniques available to repair a PUJ obstruction. Current methods are classified into dismembered and flap technique, respectively. Dismembered pyeloplasty of the Anderson-Hynes type

consists of complete excision of an anatomically or functionally abnormal pelvi-ureteric junction, correction of high insertion of the ureters, reduction of renal pelvis, straightening of lengthy and tortuous proximal ureters, and transposition of the pelvi-ureteric junction if obstruction is secondary to an aberrant vessel. Dismembered pyeloplasty enjoys high success rate and has almost universal applicability. However, there is occasionally dependent PUJ with long narrow ureteric segment or small intrarenal pelvis and dismembered pyeloplasty may leave the surgeon with short ureteric segment or requires aggressive ureteric and pelvic mobilization. In these cases flap pyeloplasty of the Culp-De Weerd type is more suitable.

There are various surgical approaches to pyeloplasty. The classical traditional approach is an extraperitoneal approach via lateral flank incision. All kidneys can be approached by flank incision easily with excellent exposure. The major disadvantage is a painful incision post-operatively. The anterior extraperitoneal approach is an excellent approach in younger children with a large renal pelvis but access is more difficult in obese children. Recently the posterior (dorsal) lumbotomy has gained wide popularity. The use of muscle splitting rather than muscle cutting makes it almost a minimally invasive procedure. The location of the incision posterior and in the crease line has cosmetic advantages and allows direct access to the renal pelvis. However, this a bombsight incision, requiring precise localisation of the PUJ also there is some concern that this approach creates a scar, which crosses normal skin folds. The bilateral procedure is possible using dorsal lumbotomy if indicated under the same anaesthesia without position changes. This approach should not be used in older children or significantly obese. A transperitoneal approach can be used when access to the abdominal contents is required. Recently, several authors have reported that laparoscopic Anderson-Hynes dismembered pyeloplasty is an effective alternative treatment for symptomatic PUJ obstruction in children. The development of robust 3-mm needlescopic instruments designed to perform dismembered pyeloplasties has added a new dimension to laparoscopic suturing and will significantly enhance the ability to perform microanastomosis – the limiting factor preventing many surgeons from performing this technically demanding operation.

Figure 46.1

The child is placed on the operating table in a supine position with the affected side elevated on a roll. A horizontal skin incision is made below the 12th rib extending anteriorly.

Figure 46.2

The external and internal oblique muscles are divided by cutting diathermy in order to minimize a blood loss. The entry into retroperitoneum is made at the rib tip and extended posteriorly along the superior

edge of the rib. The transversus abdominis is separated by blunt dissection in the lines of its fibres after the lumbodorsal fascia is incised. The peritoneum is retracted medially to allow more working space.

Figure 46.1

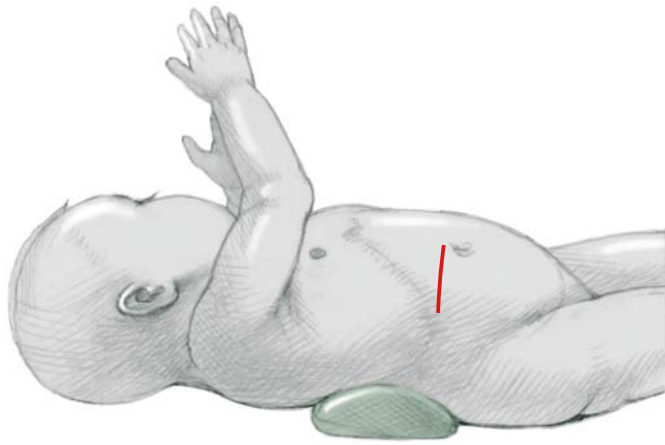


Figure 46.2

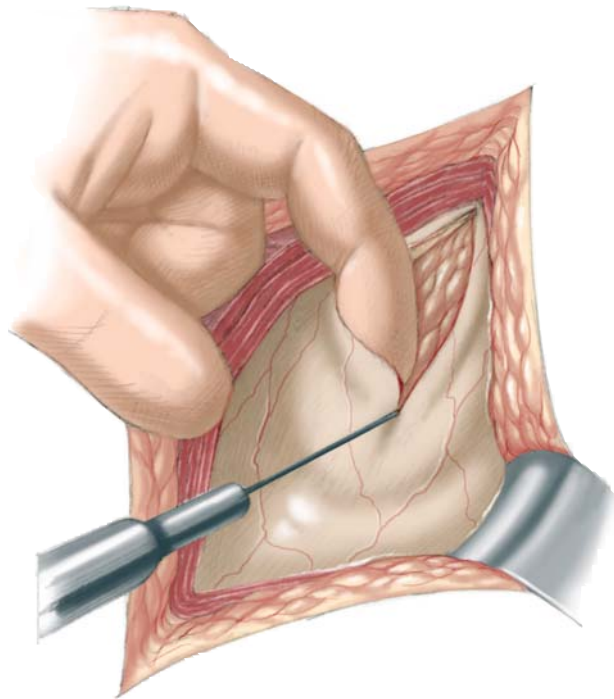


Figure 46.3

Gerota's fascia is opened longitudinally in the posterior angle of the incision. The lower kidney moiety then comes to view. The lower pole is mobilized using blunt and sharp dissection. In the majority of the patients, a PUJ is best approached anteriorly. Main renal vessels and its branches and tributaries around

the anterior renal hilum pose added risk for injury using anterior approach to renal hilum. It is easy to rotate the kidney, retracting the lower pole forwards and upwards to approach the PUJ from behind. The ureter is then identified and mobilized downward.

Figure 46.4

Three absorbable 6/0 sutures are placed (1) at the superomedial aspect of the pelvis, (2) at the inferolateral aspects of the pelvis, and (3) on the ureter about 5 mm below PUJ. The ureter is divided obliquely

above the ureteric stitch and the redundant pelvis is trimmed. The ureter is spatulated for approximately 2–3 mm by incising its posterolateral margin using fine scissors.

Figure 46.3

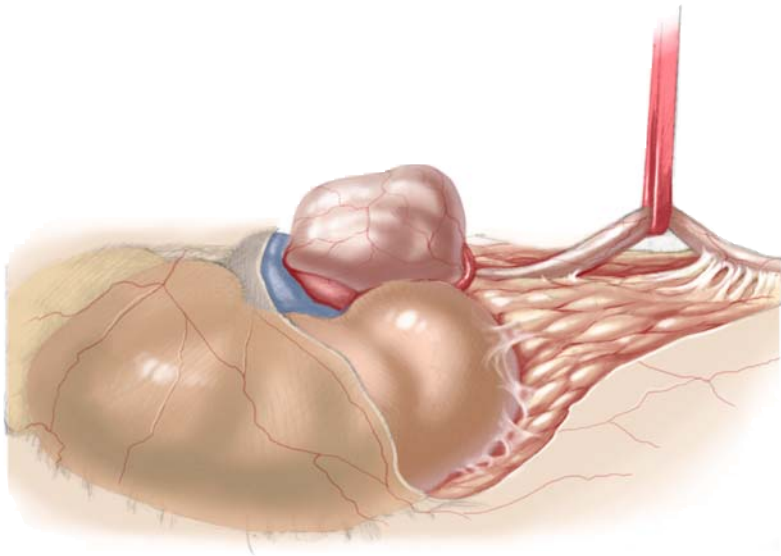


Figure 46.4

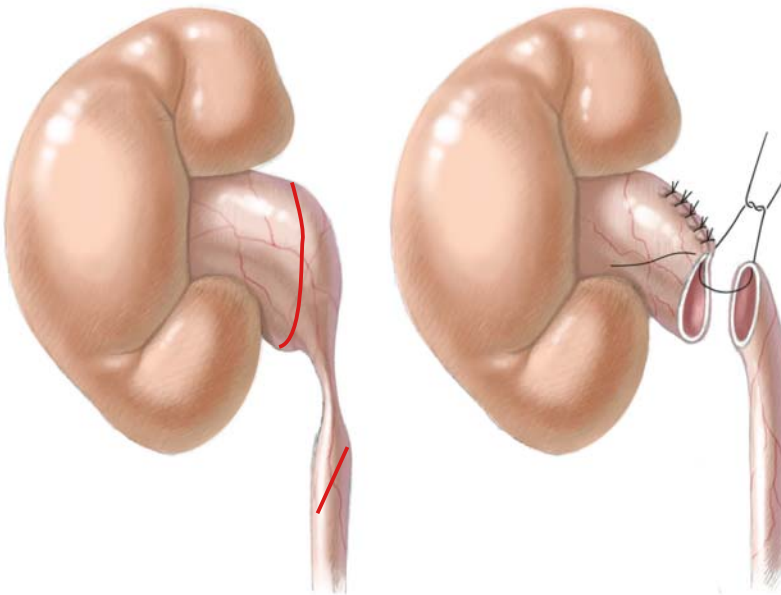


Figure 46.5, 46.6

At this stage, the decision should be made whether to utilize a nephrostomy tube or ureteric stent. Some surgeons still advocate nephrostomy tube drainage after pyeloplasty. However, we believe that this technique is outdated and in the majority of the cases a double-J stent should be used. The ureter is then anastomosed to the renal pelvis over the stent. In case of an aberrant renal artery the anastomosis is performed anterior to the vessel. The first stitch is placed approximating the lower margin of the spatulating ureters and the lower margin of the renal pelvis using absorbable 6/0 sutures.

A further interrupted suture is then placed to complete the posterior aspect of the anastomosis. Suture should advance up the posterior wall and then up the anterior wall, keeping the suture knots on the outside of the lumen of the anastomosis. All sutures should include 1 mm of tissue on each side. The sutures should be placed about 1.5 to 2 mm apart. The anterior closure of anastomosis is then performed using either interrupted or running 6/0 suture. The stent, which is passed through anastomosis prevents the inadvertent picking up and inclusion of the posterior wall into the stitch line during this stage of anastomosis.

Figure 46.7–46.9

The spiral flap (Culp) pyeloplasty is suitable for long, dependent, stenotic uretero-pelvic obstruction. The incision on the ureters must be adequate, covering

the stenotic area. The flap of equal length is based on a broad base. The posterior layer of ureters and flap is sutured using 6/0 sutures.

Figure 46.5

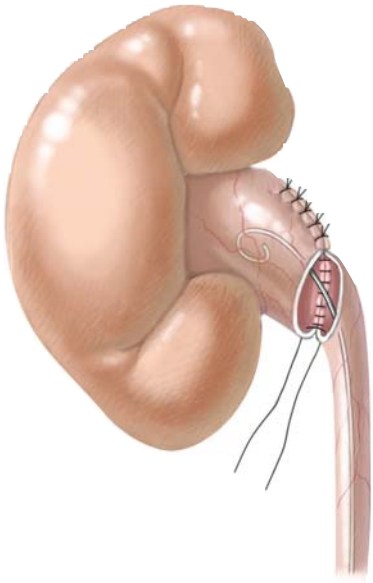


Figure 46.6

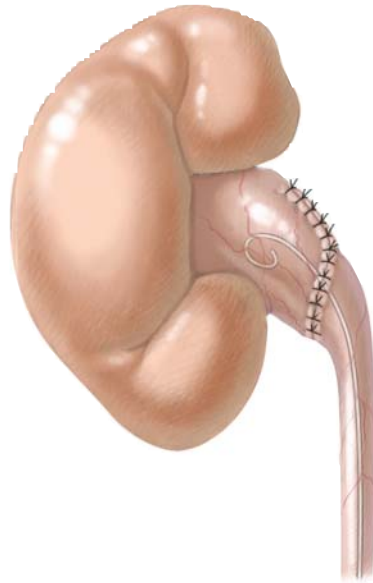


Figure 46.7

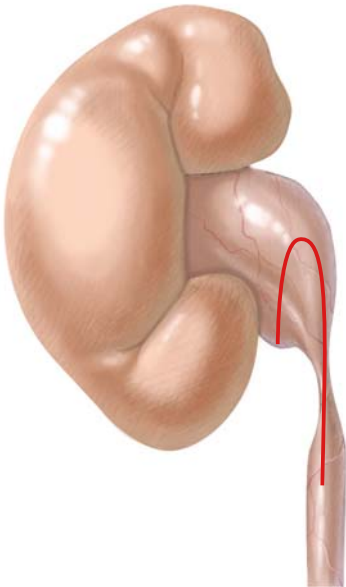


Figure 46.8

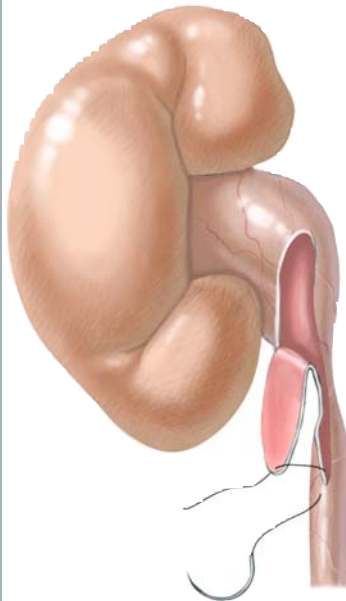
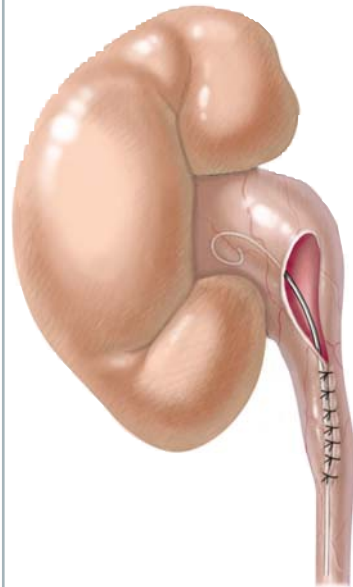


Figure 46.9



CONCLUSION

The objective of pyeloplasty is to achieve a dependent, adequate calibrated watertight pelvi-ureteric junction. There are different techniques available to repair a PUJ obstruction. The dismembered Ander-

son-Hynes pyeloplasty is suitable for the majority of patients with PUJ obstruction. Use of double-J ureteral stents has virtually eliminated ureteral leaks and early obstructions.

SELECTED BIBLIOGRAPHY

- Chertin B, Rolle U, Farkas A, Puri P (2002) Does delaying pyeloplasty affect renal function in children with prenatal diagnosis of pelvi-ureteric junction obstruction. *BJU Int* 90:70–75
- Frank JD (2002) Pyeloplasty. In: Frank JD, Gearhart JP, Snyder HM III (eds) *Operative pediatric urology*, 2nd edn. Churchill Livingstone, London, pp 1–10
- Puri P, Chertin B (2003) Upper urinary tract obstructions. In: Puri P (ed) *Newborn surgery*. Arnold, London, pp 818–829
- Stroom SB (1998) Ureteropelvic junction obstruction: open operative intervention. *Urol Clin North Am* 35:331–341
- Tan HL (2001) Laparoscopic Anderson-Hynes pyeloplasty in children using needlescopic instrumentation. *Urol Clin North Am* 28:43–51

Endoscopic Treatment of Vesicoureteral Reflux

Prem Puri

INTRODUCTION

Primary vesicoureteral reflux (VUR) is the most common urological anomaly in children and has been reported in 30 to 50% of those who present with urinary tract infection (UTI). The association of VUR, UTI and renal parenchymal damage is well known. Reflux nephropathy is the cause of endstage renal failure in 3–25% of children and 10–15% of adults. There has been no consensus regarding when medical or surgical therapy should be used. A number of prospective studies have shown low probability of spontaneous resolution of high grade of reflux during conservative follow-up. Furthermore, all of these studies revealed that observation therapy does carry an ongoing risk of renal scarring. Open surgery is the standard treatment for VUR when indicated. Although ureteral reimplantation is effective, this operation is not free of complications.

Since its introduction endoscopic correction of VUR has become an established alternative to long-term antibiotic prophylaxis and open surgical treatment. Recently, we published our data regarding

long-term effectiveness of endoscopic STING (subureteral injection of polytetrafluoroethylene) for VUR in 258 patients, and its success was confirmed in our 17-year follow-up. Our study as well as long-term studies from others have not shown any clinical untoward effects with the use of polytetrafluoroethylene for the treatment of vesicoureteral reflux.

Recently, a number of other tissue augmenting substances have been used endoscopically for subureteral injection. Dextranomer microspheres in sodium hyaluronic acid solution (Deflux) is a recently developed organic substance comprising 80 to 250 μm microspheres. It has been reported that dextranomer/hyaluronic acid copolymer is biodegradable, has no immunogenic properties and has no potential for malignant transformation. Dextranomer microspheres in sodium hyaluronic acid solution consist of microspheres of dextranomers mixed in a 1% high molecular weight sodium hyaluronan solution. Each millilitre of the system contains 0.5 ml sodium hyaluronan and 0.5 ml microspheres.

Figure 47.1

Vesicoureteric reflux is classified into five grades. The indications for endoscopic therapy for VUR include:

- High grade primary VUR (grades III–V)
- VUR in duplex renal systems
- VUR secondary to neuropathic bladder and posterior urethral valves
- VUR in failed reimplanted ureters
- VUR into ureteral stumps

Figure 47.2

The disposable Puri catheter for injection (Storz) is a 4-Fr nylon catheter onto which is swaged a 21-gauge needle with 1 cm of the needle protruding from the

catheter. Alternatively, a rigid needle can be used. A 1-ml syringe filled with Deflux paste is attached to the injection catheter.

Figure 47.1

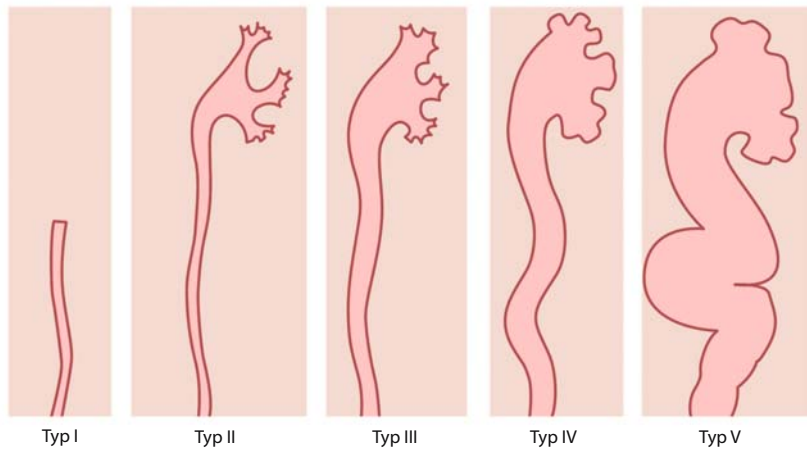


Figure 47.2

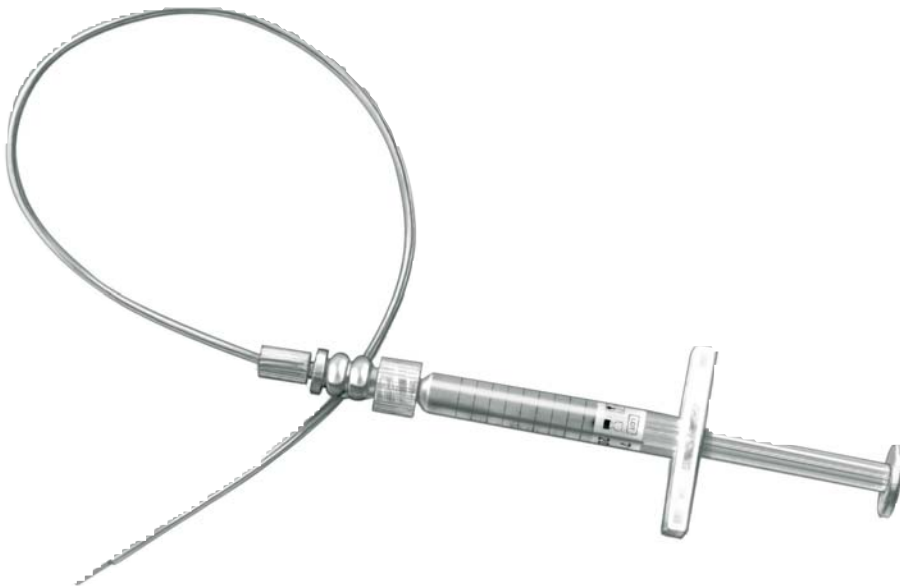


Figure 47.3

All cystoscopes available for infants and children can be used for this procedure. The injection catheter can be introduced through a 9.5F, 11F or 14F Storz cysto-

scope, or a 9.5F Wolf cystoscope, or a 9.5F or 11.5F angled Wolfe cystoscope.

Figure 47.4a–c

For the subureteric injection technique the patient should be placed in a lithotomy position. The cystoscope is passed and the bladder wall, the trigone, bladder neck and both ureteric orifices inspected. The bladder should be almost empty before proceeding with injection, since this helps to keep the ureteric orifice flat rather than away in a lateral part of the field.

The injection of Deflux paste or any other tissue augmenting substance should not begin until the operator has a clear view all around the ureteric orifice. Under direct vision through the cystoscope the needle is introduced under the bladder mucosa 2–3 mm below the affected ureteric orifice at the 6 o'clock position. In children with grade IV and V reflux with wide ureteral orifices, the needle should be inserted not below but directly into the affected ureteral orifice. It is important to introduce the needle with pinpoint accuracy. Perforation of the mucosa or the ureter may allow the paste to escape and may result in failure.

The needle is advanced about 4–5 mm into the lamina propria in the submucosal portion of the ureter and the injection started slowly. As the paste is in-

jected a bulge appears in the floor of the submucosal ureter. During injection the needle is slowly withdrawn until a “volcanic” bulge of paste is seen. The needle should be kept in position for 30–60 s after injection to avoid extrusion. Most refluxing ureters require 0.3–0.6 ml Deflux to correct reflux.

A correctly placed injection creates the appearance of a nipple on the top of which is a slit-like or inverted crescentic orifice. If the bulge appears in an incorrect place, e.g., at the side of the ureter or proximal to it, the needle should not be withdrawn, but should be moved so that the point is in a more favourable position. The non-injected ureteric roof retains its compliance while preventing reflux.

Post-operative urethral catheterization is not necessary. The majority of patients are treated as day cases. Co-trimoxazole is prescribed in prophylactic doses for 3 months after the procedure. Micturition cystography and renal ultrasonography are performed 3 months after discharge. A follow-up micturating cystogram and renal and bladder ultrasonographic scan are obtained 12 months after endoscopic correction of reflux.

Figure 47.3


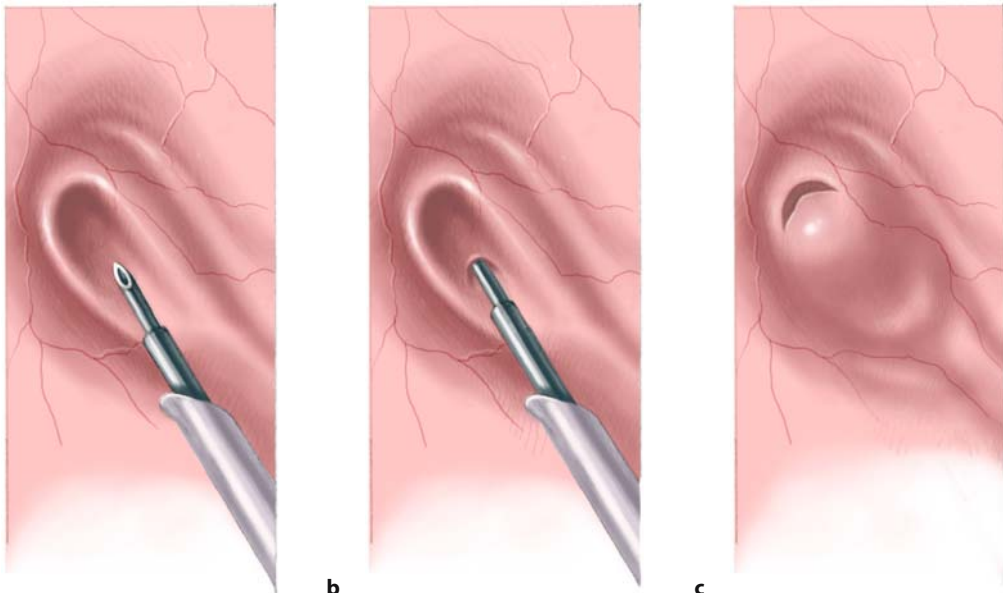


Figure 47.4a-c



CONCLUSION

Endoscopic treatment is a simple, safe and effective procedure in the management of all grades of reflux. Procedure-related complications are rare. The only significant complication with this procedure has been failure. This may be initial failure, i.e., the reflux is not abolished by the injection, or recurrence, where initial correction is not maintained. About 15–20% of refluxing ureters require more than one

endoscopic injection of paste to correct the condition. Apart from failure to correct reflux, vesicoureteric junction obstruction is the only other reported complication following STING. A recent multicentre survey of STING procedures in 12,251 ureters in 8,332 patients revealed vesicoureteric junction obstruction in 41 ureters (0.33%) requiring reimplantation of ureters.

SELECTED BIBLIOGRAPHY

- Chertin B, DeCaluwe D, Puri P (2003) Endoscopic treatment of primary grades IV and V vesicoureteral reflux in children with subureteral injection of polytetrafluoroethylene. *J Urol* 169:1847–1849
- Puri P (2000) Endoscopic correction of vesicoureteral reflux. *Curr Opin Urol* 10:593–597
- Puri P (2001) Endoscopic treatment of vesicoureteral reflux. In: Gearhart JP, Rink RC, Mouriquand PDE (eds) *Pediatric urology*. WB Saunders Philadelphia, pp 411–422
- Puri P, Chertin B, Velayudham M et al (2003) Treatment of vesicoureteral reflux by endoscopic injection of dextranomer/hyaluronic acid copolymer: preliminary results *J Urol* 170:1541–1544

Vesicoureteral Reflux – Surgical Treatment

Jack S. Elder

INTRODUCTION

Vesicoureteral reflux (VUR) affects approximately 1% of children. VUR predisposes an individual to upper urinary tract infection (UTI), i.e. pyelonephritis.

Repeated pyelonephritis can result in renal scarring (reflux nephropathy), hypertension, impaired somatic growth, renal insufficiency, end-stage renal disease, and complications during pregnancy. VUR can be managed medically or surgically.

Medical management is based on the principles that VUR often diminishes or resolves over time, and maintaining sterile urine minimizes the risk of reflux nephropathy. Medical management includes administering a daily dose of an antimicrobial, such as nitrofurantoin, trimethoprim or sulfatrim, encouraging regular micturition, and treating voiding dysfunction. The child typically undergoes regular follow-up assessment with a voiding cystourethrogram (VCUG) and renal ultrasonogram (US) every 12 to 18 months. Medical management is continued until the VUR resolves or improves sufficiently that the VUR no longer seems to increase the risk of pyelonephritis.

Surgical management is generally recommended when patients have failed medical management, e.g., breakthrough UTI while receiving antimicrobial prophylaxis, persistent VUR, and non-compliance with the prescribed therapy. In addition, children with VUR that is unlikely to resolve such as grade IV, V, and bilateral grade III, VUR associated with a simple duplicated collecting system, ureterocele, ectopic ureter, or bladder exstrophy often are managed surgically.

Surgical management can be accomplished through an incision (“open surgical treatment”), endoscopically (subureteral injection; this topic is covered in Chap. 47), and laparoscopically (not covered here). Since the bladder is an abdominal organ in children, open surgical therapy is easiest when the child is prepubertal; after puberty, the bladder descends behind the pubic symphysis, and dissection of the ureters is more difficult. The decision whether to undergo endoscopic or open surgical management should be made jointly between the patient’s family and the surgeon. This chapter will address the options for open surgical management of VUR.

The principle of surgical correction of VUR is to create a 4:1 to 5:1 ratio of submucosal tunnel length to ureteral width. The intramural ureter should be in a fixed portion of the bladder. There are numerous ways

to correct VUR, some intravesical, some extravesical, some combined, but three techniques are used commonly: transtrigonal (Cohen procedure), Politano-Leadbetter procedure, and detrusorrhaphy. The first two are intravesical techniques, whereas the detrusorrhaphy is extravesical. The advantage of the latter is that there is minimal bladder spasm and haematuria associated with the procedure, whereas with the intravesical approach, typically children experience a moderate amount of dysuria, urgency, and haematuria for one to 2 weeks post-operatively. A modified approach may be recommended if ureteral tailoring is necessary because the ureter is too wide to achieve a 4:1 ratio. With improvements in pediatric anaesthesia and post-operative pain management, children often stay in the hospital for 1 to 2 days after these procedures. The success rate is 95 to 98% for grades I through IV VUR and somewhat lower for grade V VUR.

OPERATIVE PRINCIPLES

During open surgical correction of VUR, several principles apply:

- Optical magnification with loupes is recommended.
- It is helpful to use fine cautery (Pena tip) for the operative procedure.
- Tenotomy scissors are ideal for tissue dissection throughout the entire procedure, because the tips are fine and blunt. Metzenbaum scissors are much wider and do not dissect the tissues as easily.
- The exposed bladder mucosa should not be wiped with a sponge, and suction should not be applied to the bladder mucosa. These manoeuvres will result in significant mucosal oedema, which may make submucosal dissection difficult.
- The submucosal tunnel should be 4 or 5 times as long as the width of the ureter.
- Ureteral stents are unnecessary in routine ureteroneocystostomy, but should be considered for re-operative cases, ureteral tailoring, or if there is significant detrusor hypertrophy from posterior urethral valves, neuropathic bladder, or severe voiding dysfunction.
- If there is a duplicated collecting system, both ureters may be treated as one and re-implanted together in one tunnel.

TRANSTRIGONAL (COHEN) PROCEDURE**Figure 48.1**

The abdomen and genitalia should be prepped with betadine solution, and the urethral meatus should be included in the operative field in order that a catheter may be inserted or removed when necessary. Pre-operative broad-spectrum antibiotics should be administered.

A Foley catheter should be inserted into the bladder and the bladder is filled manually with sterile water to push the peritoneum superiorly. A Pfannenstiel incision is made one finger-breadth above the pubic symphysis. The limits of the incision should be the lateral borders of the rectus muscles. The incision is carried down to the external oblique fascia and haemostasis is achieved.

Figure 48.2–48.4

Make a transverse incision in the anterior rectus sheath in the line of the incision, exposing the rectus muscles. Using the fine tip needle electrode (Pena tip) for cautery, develop rectus fascial flaps superiorly, nearly to the umbilicus. It is helpful to grasp the superior rectus fascia with straight mosquito clamps. Using an identical technique, the inferior rectus fascia is mobilized to the pubic symphysis.

Separate the rectus muscles in the midline with a Kelly clamp and use the cautery to incise the linea alba, the midline attachment of the rectus muscles. With tenotomy scissors, incise the transversalis fascia and expose the bladder. The distended bladder is dissected out bluntly. The peritoneum should be swept superiorly to prevent inadvertent peritoneotomy.

Figure 48.1

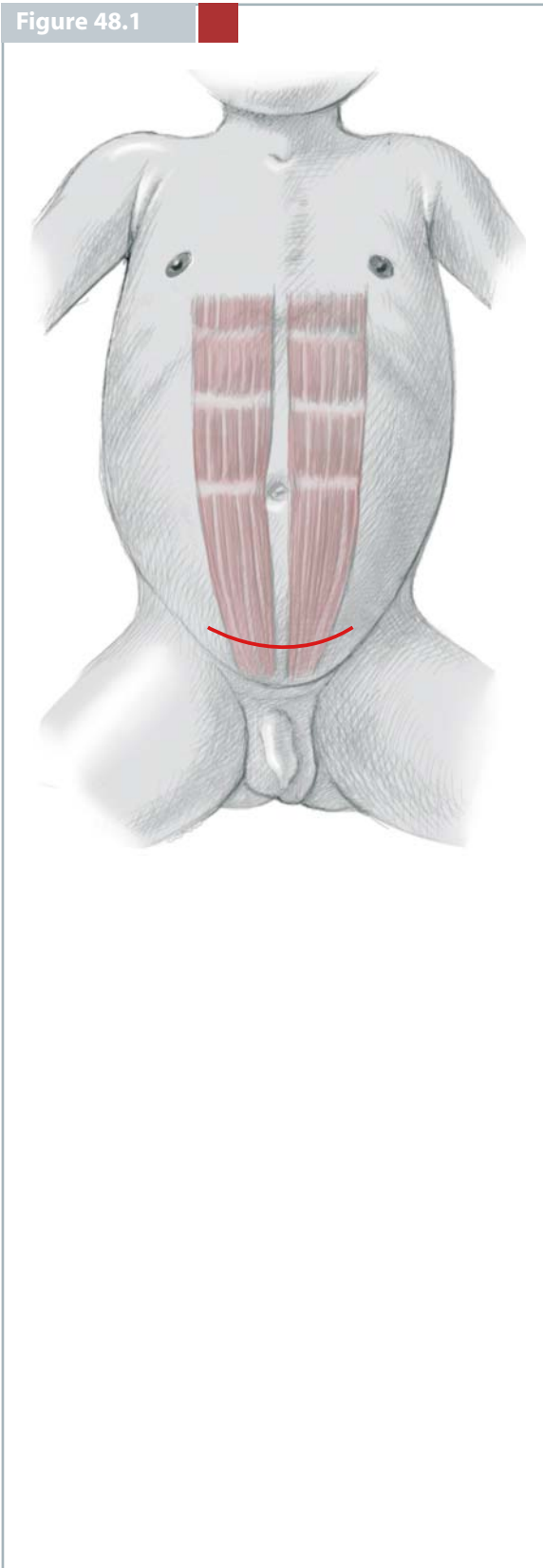


Figure 48.2

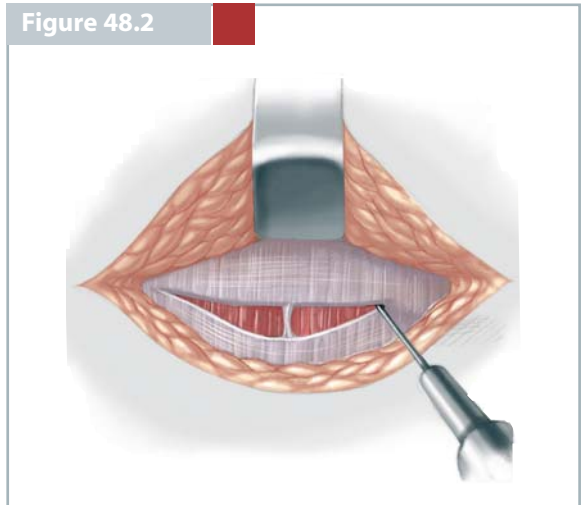


Figure 48.3

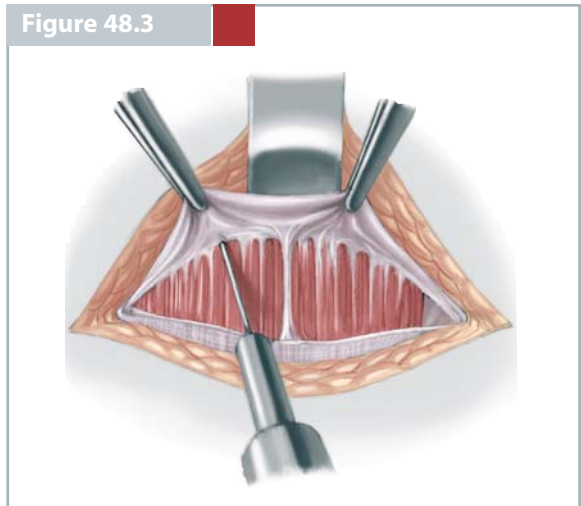


Figure 48.4

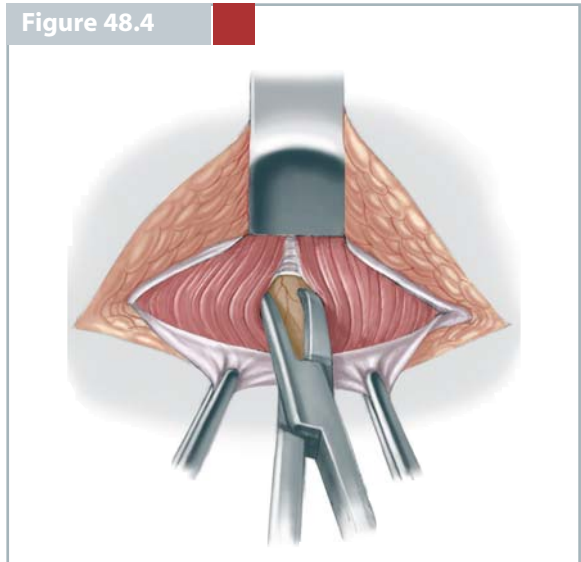


Figure 48.5

The Denis-Browne ring retractor is then used to hold the rectus muscles apart. Allis clamps are placed on either side of the midline of the bladder. The detrusor is incised in the midline with the cautery. Ideally, only the muscular layer should be divided first, allowing cauterization of the small arterial vessels in the detrusor. The mucosa then protrudes out and may be cut with tenotomy scissors or the cautery. The bladder is then drained. The bladder is then isolated with 4/0 or 3/0 absorbable traction sutures (placed with one tie) in the four corners of the bladder wall, and a figure-of-eight stitch is placed in the bladder neck to prevent it from spreading open.

The Denis-Browne ring retractor is then placed in the bladder. The side blades have two sizes; usually the larger size is necessary. Several moistened gauze

sponges are placed in the bladder dome and the malleable blade is inserted and adjusted to retract the dome superiorly. When the malleable blade is inserted, the ureteral orifices should be easily visible. The rake retractor is placed inferiorly. In older children the Denis-Browne retractor may be too small, and instead a child size Balfour retractor may be necessary, using the bladder blade for retraction superiorly.

The ureteral orifices are identified and cannulated with 8F or 5F pediatric feeding tubes; in infants and very young children it may be necessary to use a 3.5F feeding tube. The catheter should be passed up to the kidney and sutured to the bladder wall with 4/0 absorbable sutures. A clamp is placed on the feeding tube and suture for traction.

Figure 48.5

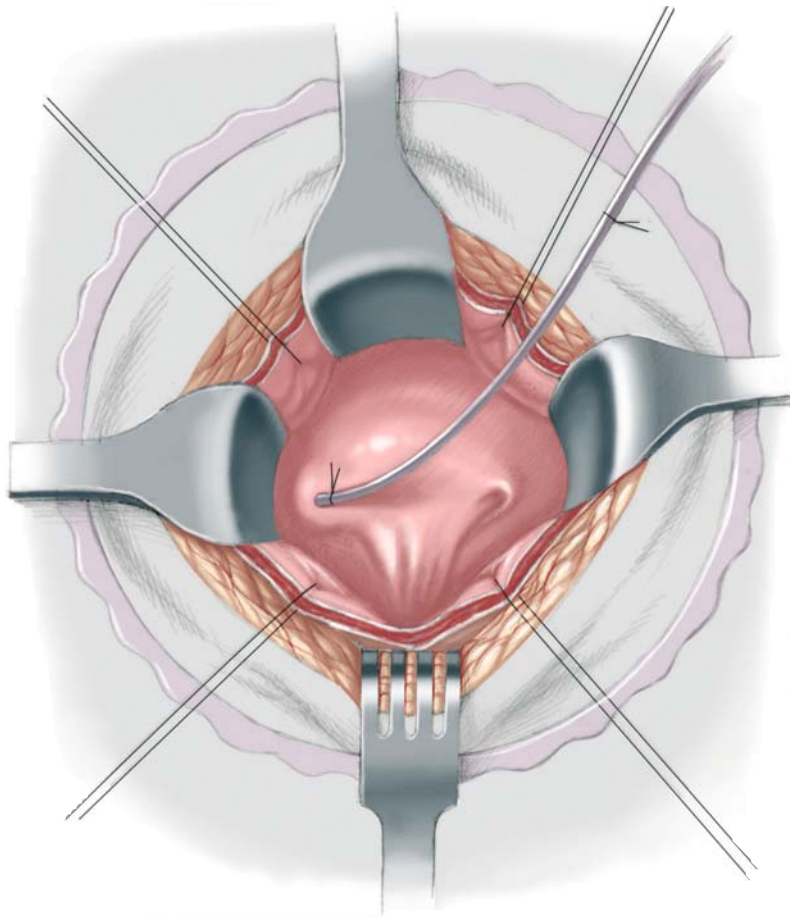


Figure 48.6

The ureter is then dissected out. A fresh number 15 scalpel is used to circumscribe the ureter. The mucosa inferomedial to the orifice is grasped with tooth Adson forceps and a deep cut is made in the space between ureter and mucosa. This plane around the ureter is developed by sharp dissection, exposing the underlying detrusor muscle.

The ureter has a pearly white appearance. Dissecting too close to the ureter risks devascularization and dissecting too far away in the detrusor often results in significant bleeding. Megaureters often have a better intrinsic blood supply, and devascularization during mobilization of the megaureter is uncommon. A small right angle clamp can be used to develop the plane between the ureter and detrusor, and the clamp may be opened to separate the muscle from the ureter. Muscular attachments to the ureter may be cauterized gently, being careful to keep the tip of the cautery away from the ureter. If there has been a recent urinary tract infection, the ureter tends to be more adherent to the muscle. The ureter is dissected out until the peritoneum is identified and can be swept away.

Figure 48.7

The ureteral hiatus must then be closed to prevent a diverticulum from forming. Three or four interrupted 3/0 absorbable sutures are placed through the muscle on each side, starting inferomedially and working superolaterally; the hiatus should not be closed too tightly.

The submucosal tunnel is then made. The mucosa medial to the hiatus should be grasped gently. Using the tenotomy scissors, with the tips pointed anteriorly, the mucosal attachment to the underlying detrusor is incised to establish the submucosal plane. Next, the tenotomy scissors are passed into the plane and spread gently. The scissors should be opened approximately twice as wide as the ureteral diameter. The submucosal tunnel is gradually lengthened. When the tunnel length is 4 or 5 times as long as the width, the tips of the scissors should be used to elevate the mucosa. The scissors should be opened slightly and the cautery should be used to open the mucosa. The tips of the scissors are advanced through the mucosa and opened further.

Figure 48.8, 48.9

The tip of the feeding tube in the ureter is cut off. A right-angled or curved mosquito clamp is passed backward through the opening in the mucosa toward the ureteral hiatus and the tip of the feeding tube is grasped. The tip of the feeding tube is then pulled through the submucosal tunnel.

The suture holding the feeding tube is cut and the tip of the ureter is trimmed slightly, being careful to excise any portion of the ureter that seems devascularized. If both ureters are being re-implanted, it is appropriate to place them in the same submucosal tunnel.

The ureter is spatulated slightly. With the feeding tube in place, the ureter is sutured to the bladder mucosa with interrupted 5/0 or 6/0 absorbable sutures; the two distal apical sutures should be placed through the bladder muscle also, to help fix the ureter in place. There should be no tension on the ureter. Small mosquito clamps are placed for traction on the proximal and distal apical sutures to allow easy identification of the new ureteral orifice. The feeding tube should be removed and then reinserted into the ureter; the feeding tube should pass easily through the

submucosal tunnel. After the ureter(s) is fixed in place, the bladder mucosa is closed with running 5/0 absorbable sutures. It is unnecessary to leave the ureter stented unless there is significant bladder wall oedema or the patient is undergoing a secondary procedure.

If a satisfactory submucosal tunnel cannot be made because of mucosal oedema, the mucosa may be incised and peeled back, creating a trough in which to lay the ureter. In fact, the mucosal edges may be sutured to the edge of the ureter, and the epithelium will grow over the ureter, creating a submucosal tunnel.

The bladder is then closed. A two-layer closure is performed. The muscular layer is closed with a running 2/0 imbricating stitch (Connell) and a second layer with a running 2/0 Lembert stitch is used. The rectus muscles are approximated with interrupted 3/0 chromic catgut. The rectus fascia is closed with a running 2/0 PGA (polyglycolic acid) or PDS (polydioxanone). A Foley catheter is left in place overnight.

Figure 48.6

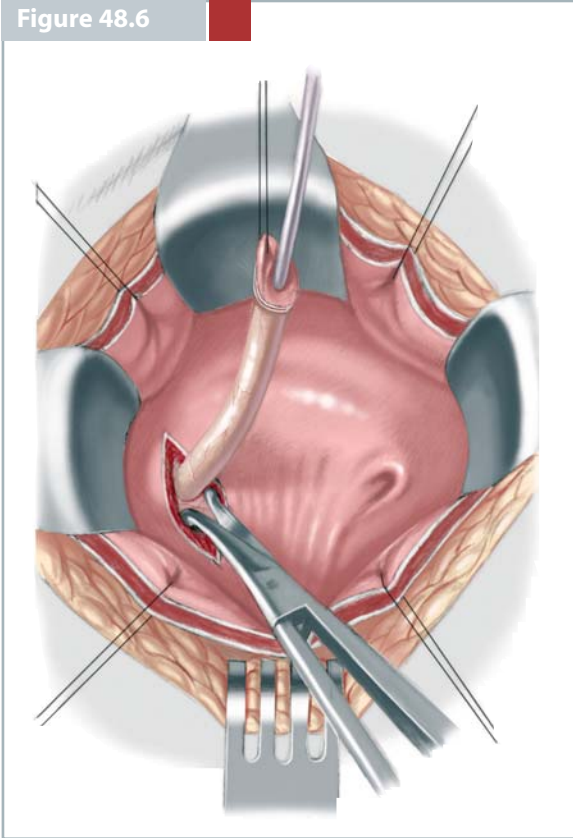


Figure 48.7

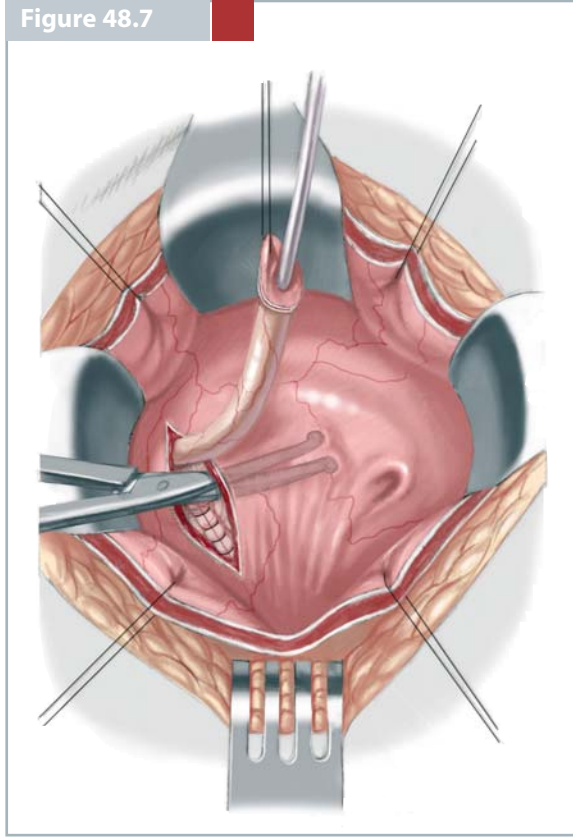


Figure 48.8

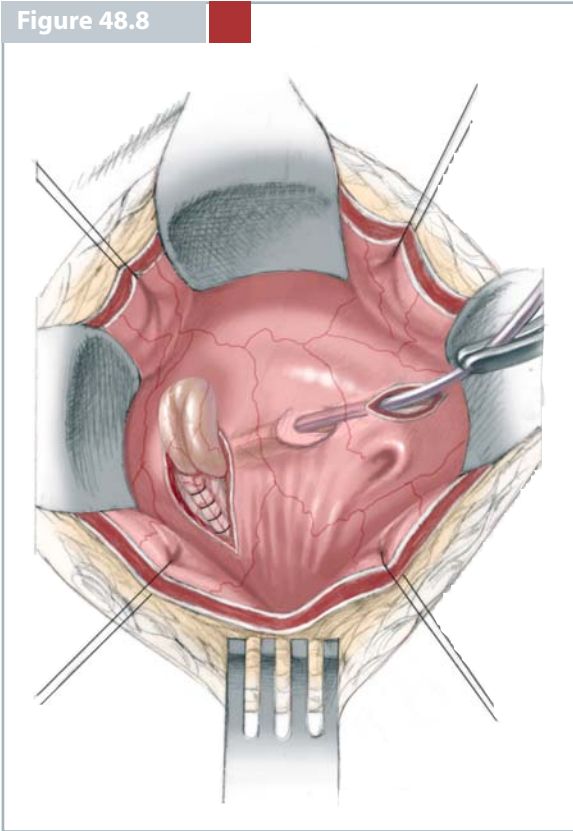


Figure 48.9

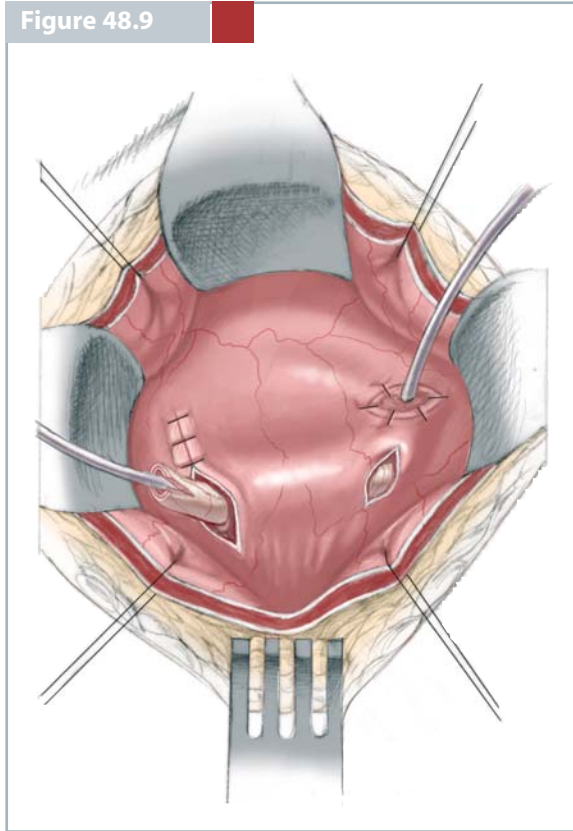


Figure 48.10

If a unilateral transtrigonal ureteroneocystostomy is performed, there is a 10% risk of contralateral reflux, probably secondary to destabilization of the contralateral ureter during mobilization of the refluxing ureter. The risk is 50% if the contralateral ureter refluxed in the past but is no longer refluxing. This complication may be prevented by performing bilateral ureteroneocystostomy or by performing a contralateral Gil-Vernet ureteral reimplant (contralateral ureteral meatal advancement).

After cannulating the ureteral orifice with a feeding tube of appropriate size and suturing it in place, a Y-shaped mucosal incision is made from the medial surface of the ureter medially to the midline of the bladder trigone. The medial wall of the ureter is dissected out, separating it from the underlying detrusor muscle. The medial extension of the mucosal incision is opened also, exposing the detrusor. The ureteral meatus is moved medial, to the midline. The ureteral meatus is fixed to the mucosa and underlying detrusor with several 5/0 absorbable sutures.

DETRUSORRHAPHY**Figure 48.11**

The ureter may be reimplanted using an extravesical technique termed detrusorrhaphy. This technique evolved from the Lich-Gregoir procedure. The success rate is identical to intravesical procedures. Following unilateral detrusorrhaphy, the incidence of contralateral VUR is less than 5%. With bilateral detrusorrhaphy there is a small but significant risk of temporary, or even permanent, atonic bladder requiring clean intermittent catheterization. Consequently, many use this procedure only for unilateral reflux.

It is often helpful to perform cystoscopy and insert a ureteral catheter into the ureter. This manoeuvre facilitates identification of the ureter after the bladder is exposed.

A tremendous asset for this procedure is the robot retractor, which attaches to the operating table and holds retractors placed to expose the ureter.

The urethral meatus should be included in the operative field. A Foley catheter should be inserted at the beginning of the procedure and the bladder should be filled to a moderate degree manually.

For bilateral cases the bladder should be exposed through a Pfannenstiel incision as described above. For unilateral cases, a unilateral 5 cm inguinal (modified Gibson) incision may be made.

The lateral wall of the bladder is mobilized by blunt dissection and 3/0 absorbable sutures muscular traction sutures are placed. These traction sutures allow the bladder to be “rolled” medially, facilitating identification of the ureterovesical junction. The bladder may need to be emptied partially to facilitate this dissection. A Deaver retractor is inserted to retract the bladder medially. If the ureter is not immediately apparent, the obliterated umbilical artery is identified, ligated and divided with 3/0 absorbable sutures. The ureter is just deep to the obliterated umbilical artery.

The ureter is isolated with a vessel loop. By blunt dissection, the ureter is followed to its junction with the detrusor, termed the ureterovesical junction (UVJ). PGA 3/0 traction sutures are placed distal to the UVJ.

Figure 48.10

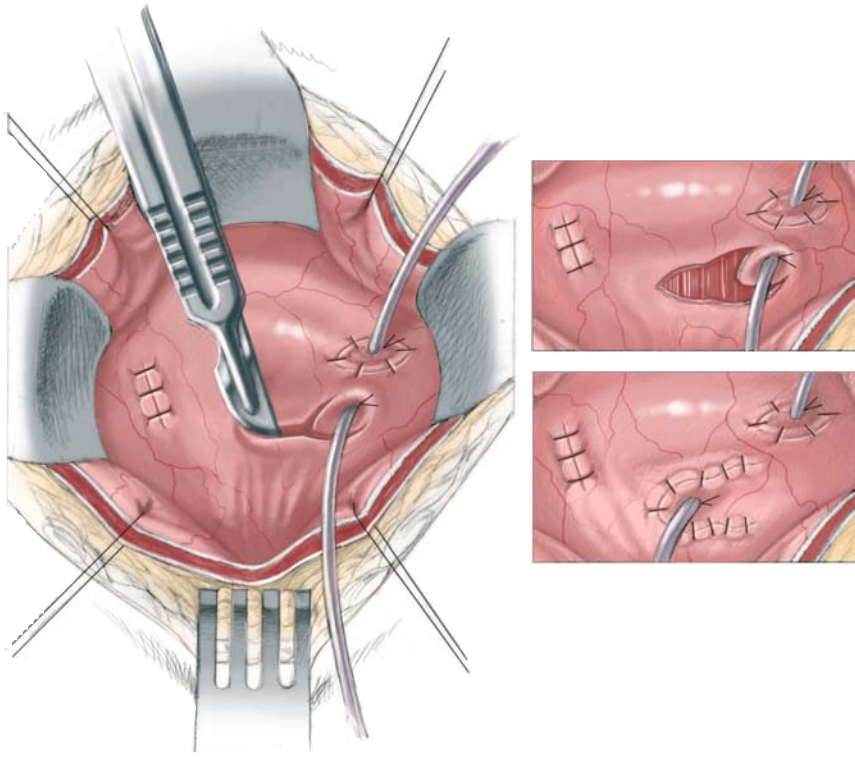


Figure 48.11

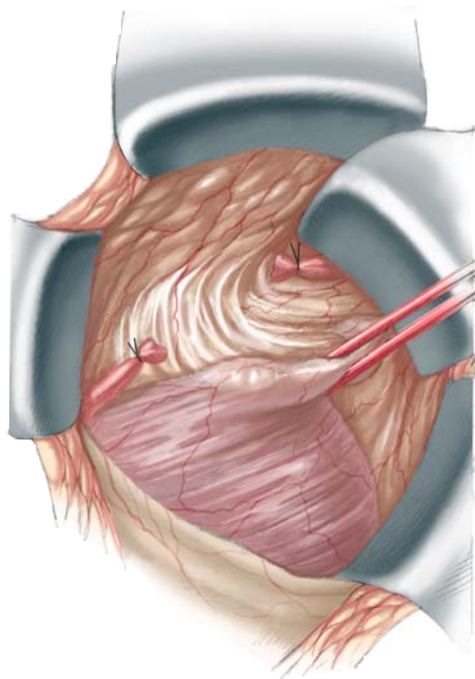


Figure 48.12, 48.13

A right-angle clamp is inserted into the plane between the detrusor and bladder mucosa and the detrusor may be incised with the cautery. It is important to keep the cautery tip away from the mucosa. The junction of the ureter with the bladder mucosa is dissected out circumferentially in this manner.

The detrusor is separated from the mucosa inferomedially and incised with the cautery. A submucosal tunnel is developed superior to the hiatus for several

centimetres, to create a submucosal tunnel that is 4 or 5 times as long as the ureteral width. If the underlying bladder mucosa is cut inadvertently, interrupted 6/0 or 5/0 absorbable sutures should be placed through the open mucosal defect. Interrupted 3/0 absorbable traction sutures should be placed on either side of the detrusor incision. The bladder is emptied further and the ureteral catheter should be removed.

Figure 48.14–48.17

The ureter must be anchored inferiorly to stabilize the UVJ during bladder filling. Two 4/0 “U” stitches are placed from the distal detrusor muscle, proximally through the inferior edge of the UVJ, and distally through the detrusor. These sutures are tied down.

The ureter is then laid into the trough created by opening the detrusor and the detrusor is brought together over it with interrupted 3/0 absorbable sutures. The sutures should be tied down as they are placed.

Periodically a right angle clamp should be placed anterior to the intramural ureter to be certain that the tunnel is not too tight. When the tunnel is completed, a suture should be placed between the detrusor muscle and the muscular layer of the ureter as it enters the tunnel, to prevent it from everting during bladder filling. The Foley catheter is then drained.

Figure 48.12

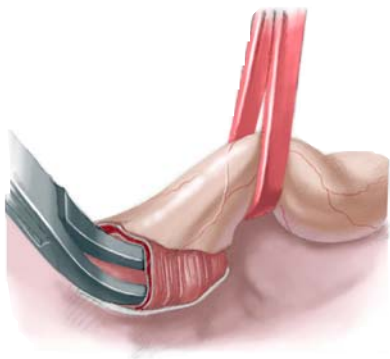


Figure 48.13

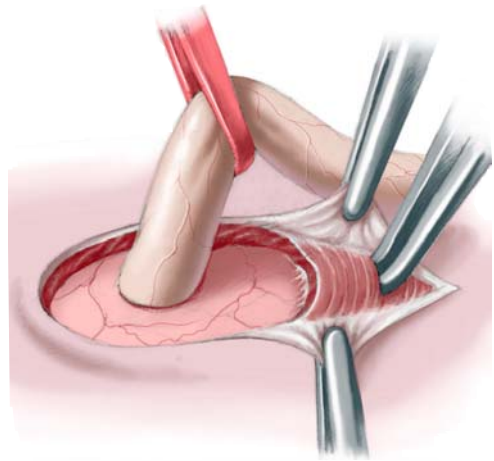


Figure 48.14

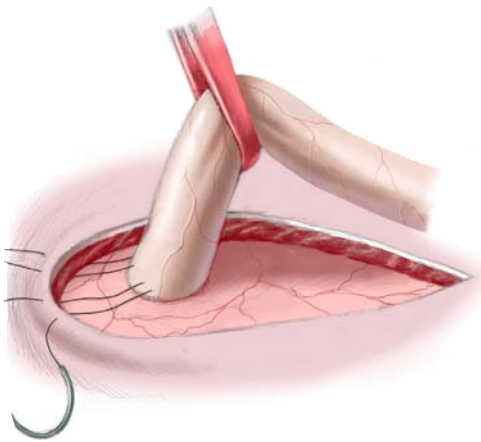


Figure 48.15

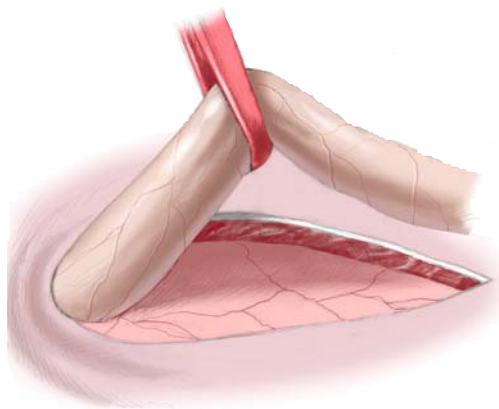

Figure 48.16

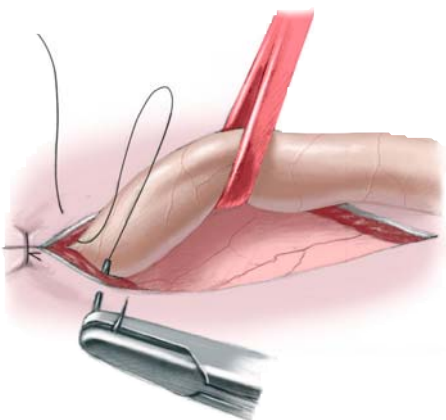
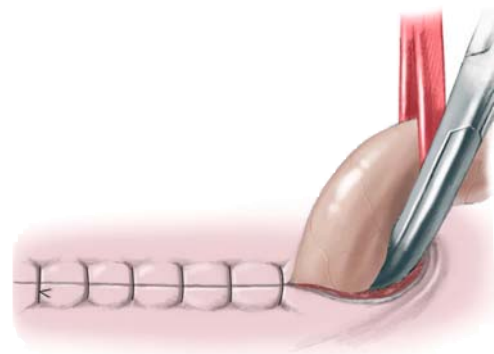


Figure 48.17



POLITANO-LEADBETTER (P-L) PROCEDURE**Figure 48.18**

This technique is another form of intravesical antireflux surgery. It may also be performed as a combined intravesical/extravesical procedure. The operation involves creating a new ureteral hiatus superiorly in the bladder and bringing the ureteral opening near its original location.

The bladder is opened and the ureters are mobilized identically as described above. A vein retractor or small Army-Navy retractor is placed in the medial wall of the hiatus. The peritoneum is teased away ei-

ther with a large right angle clamp or a Kitner dissector. A new position for the hiatus should be made in a fixed portion of the bladder base several centimetres superior to the original hiatus.

From outside the bladder, the right angle clamp is used to indent the bladder, the clamp is opened slightly, and the overlying bladder mucosa is cauterized, exposing the tip of the clamp. The right-angle clamp is then opened to create a new hiatus of satisfactory size.

Figure 48.18

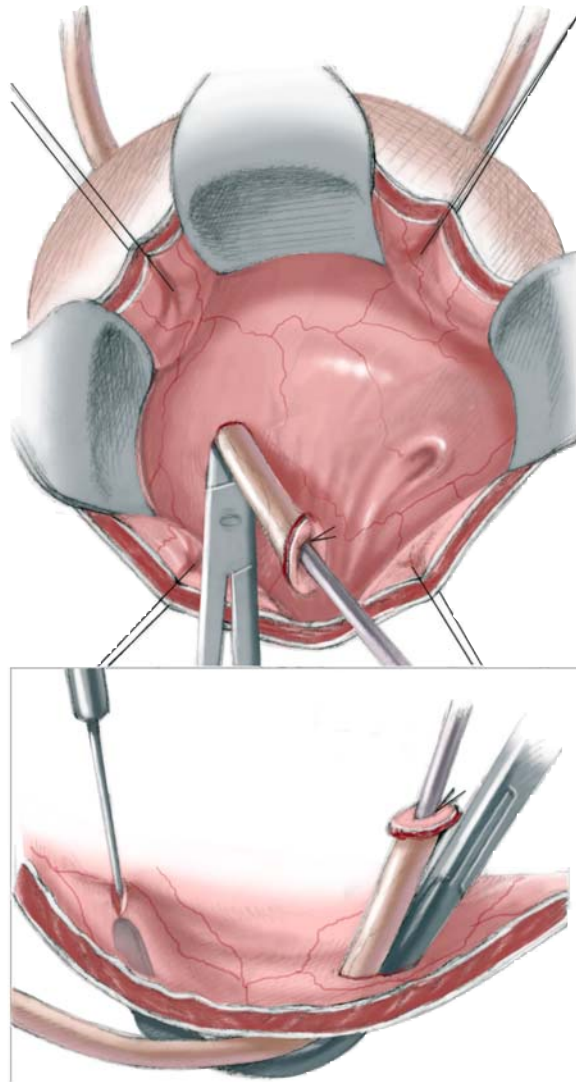


Figure 48.19, 48.20

A second right-angle clamp is passed from the inside of the bladder outside through the new hiatus, the feeding tube in the ureter is grasped, and the ureter is brought into the bladder. It is important that the ureter travel in a relatively straight direction.

At times it is necessary to perform an extravesical dissection also. If so, the Denis-Browne retractor needs to be taken out and the outside wall of the bladder retracted medially. The obliterated umbilical artery should be identified; it is a firm white structure extending from the dome of the bladder toward the hypogastric artery. The artery is ligated and divided with 3/0 absorbable suture. The bladder may then be mobilized further. Beneath the obliterated umbilical artery is the ureter. This extravesical dissection facilitates the establishment of a new hiatus with minimal risk of bowel injury.

After the ureter is brought into the bladder, the original hiatus should be closed with three or four 3/0 absorbable sutures placed through the detrusor.

A submucosal tunnel is created. Tenotomy scissors are used to incise the mucosal attachment off the underlying detrusor in the old hiatus, and then the submucosal tunnel is created toward the new hiatus by gently spreading the tenotomy scissors between the mucosa and detrusor. The width of the tunnel should be approximately twice as long as the ureteral width, and the length is four to five times as long as the width.

When the new hiatus is reached, a right-angle clamp is passed through the tunnel and the feeding

tube is grasped. The submucosal tunnel may be extended distally toward the bladder neck if necessary to create a tunnel of sufficient length. The ureter is pulled through the new submucosal tunnel. The feeding tube should be removed and the distal aspect of the ureter resected. The ureter is then spatulated slightly.

With the feeding tube in place, the ureter is sutured to the bladder mucosa with interrupted 5/0 or 6/0 absorbable; the distal apical suture should be placed through the bladder muscle also, to help fix the ureter in place. There should be no tension on the ureter. Small mosquito clamps are placed for traction on the two apical sutures to allow easy identification of the new ureteral orifice. The feeding tube should be removed and then reinserted into the ureter; the feeding tube should pass easily into the kidney. It is unnecessary to leave a feeding tube in the ureter post-operatively. After the ureter(s) is fixed in place, the bladder mucosa is closed with running 5/0 absorbable sutures. The bladder is then closed as described in the above section.

The success rates of the P-L and the Cohen (trans-trigonal) techniques are similar. The advantage of the P-L is that the ureter is much easier to catheterize for retrograde pyelography and ureteral endoscopy because the ureteral opening of the Cohen is on the opposite side of the bladder. The disadvantage is that in creating the new ureteral hiatus, there is a blind spot behind the bladder, and a peritoneotomy or even bowel injury may occur.

Figure 48.19

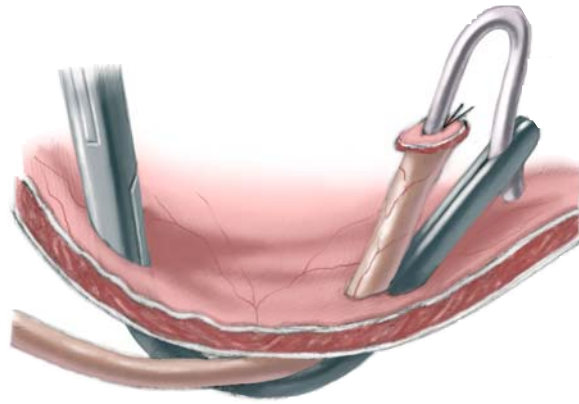
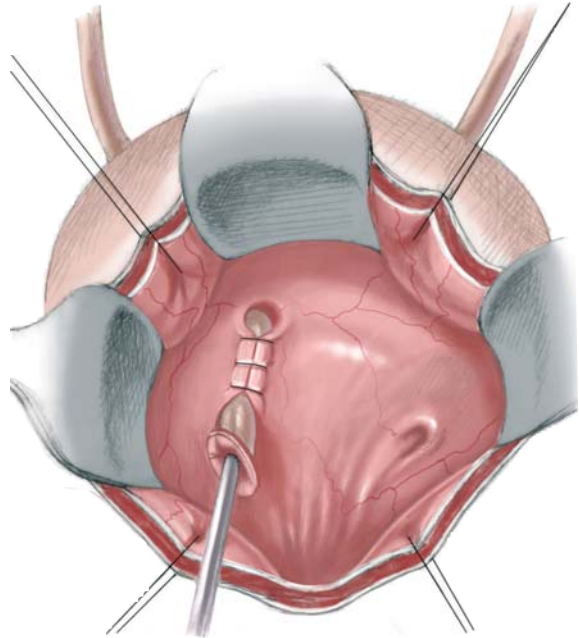


Figure 48.20



CONCLUSION

Urine output is measured in the post-anaesthesia care unit and the patient should be hydrated until the output is 1–2 ml/kg per h. Pain control is established with: (1) a caudal block that is performed at the beginning and the end of the procedure; (2) intravenous ketorolac, administered at a dosage of 0.5 mg/kg (maximum 30 mg) during wound closure, and continued at a dosage of 0.25 mg/kg every 6 h for 48 h; and (3) intravenous morphine 0.1 mg/kg every 3 h, or, in children over 6 years, a patient-controlled analgesic (PCA) pump. A regular diet may be prescribed. The Foley catheter is removed the day following the surgical procedure, and when the patient is comfortable and afebrile, discharge is appropriate. Following intravesical ureteroneocystostomy, often the child experiences moderate or significant bladder spasm, and oral administration of oxybutynin chloride three times daily for 10 to 14 days often is helpful.

The child should continue to take prophylactic antibiotics until at least 6 weeks post-operatively, at which time a renal sonogram is performed. Whether to perform a post-operative VCUG depends on the surgeon's experience. Because the success rate of ureteroneocystostomy is over 95%, many surgeons choose to perform a post-operative VCUG only if the child has a febrile UTI suggestive of pyelonephritis or if there is hydronephrosis suggestive of obstruction or persistent reflux.

RESULT AND CONCLUSIONS

The goal of surgical correction of VUR is to minimize the risk and complications of upper tract infection, including new renal scarring, reduced renal function, impaired somatic growth, and complications of pregnancy. In the International Reflux Study, medical and surgical therapy was compared for grades III and IV VUR. The incidence of new renal scarring (approximately 15%) was similar between the two groups, but the incidence of pyelonephritis was 2.5 times higher in the medical group. In the European arm, many of the surgical patients who experienced complications were not operated on by full-time pediatric urologists, whereas no surgical morbidity occurred in the US arm. More contemporary series with high surgical success rates have shown that the incidence of new renal scarring is probably around 1 to 2%.

The success rate for ureteroneocystostomy is generally over 95% for grades I–IV VUR, irrespective of technique (transtrigonal, detrusorrhaphy, or Politano-Leadbetter). Consequently, many surgeons do not perform a routine post-operative VCUG unless the child develops an upper tract UTI, and, instead, monitor their patients with serial renal sonograms. Even with successful surgical correction, however, approximately 10% will develop a febrile UTI over the following 10 years.

The late sequelae of ureteroneocystostomy continue to be studied. A disadvantage of the transtrigonal technique is that endoscopic ureteral manipulation is quite difficult whereas, with the detrusorrhaphy and Politano-Leadbetter techniques, the ureteral orifice is in normal position. The status during pregnancy is largely uncertain, because few of these women have been studied systematically. However, a recent report of four women who developed significant ureteral obstruction during pregnancy following Politano-Leadbetter procedures raises a concern regarding the long-term safety of this technique.

SELECTED BIBLIOGRAPHY

- Barrieras D, LaPointe S, Reddy PP et al (2000) Are postoperative studies justified after extravesical ureteral reimplantation? *J Urol* 162:1064–1066
- Elder JS (2000) Guidelines for consideration for surgical repair of vesicoureteral reflux. *Curr Opin Urol* 10:579–585
- Elder JS, Peters C, Arant BS et al (1997) Pediatric Vesicoureteral Reflux Guidelines Panel Summary Report on the management of primary vesicoureteral reflux in children. *J Urol* 157:1846–1851
- Flickinger JE, Trusler L, Brock JW III (1997) Clinical care pathway for the management of ureteroneocystostomy in the pediatric urology population. *J Urol* 158:1221–1225
- Mor Y, Leibovitch I, Fridmans A et al (2003) Late post-reimplantation ureteral obstruction during pregnancy: a transient phenomenon? *J Urol* 170:845–848

INTRODUCTION

Ureteric duplication is one of the most common malformations of the urinary tract. In many patients it is discovered as an incidental finding without clinical symptoms and does not require any surgical correction. With the advent of prenatal ultrasonography an increasing number of uropathies are discovered before clinical manifestations. Duplication can be associated with other anomalies, such as reflux, mega-ureter, ectopic ureter, and ureterocele.

Duplication can be complete or partial, when the two segments unite with one another somewhere between the renal pelvis and the intramural ureter above the bladder.

Bifid ureters (incomplete duplication) may join at any level from the bladder to the ureteropelvic junction. The presence of a bifid ureter does not predispose toward vesicoureteric reflux, and surgical correction is based on the same indications as for a single refluxing ureter.

Complete duplication may be associated with vesicoureteric reflux, ectopic ureters or ureterocele. Two operative possibilities exist for reflux in ureteric duplication, depending on whether reflux affects the lower pole ureter or both ureters.

The therapeutic considerations for surgical correction of reflux associated with duplication are similar to those for reflux in a single ureter, though spontaneous resolution is less likely to occur with growth of the child when reflux involves the lower pole only. When reflux affects only the lower pole and the patient has severe pyelonephretic lesions as demonstrated by ultrasound and nuclear scintigraphy, heminephrectomy should be considered. Removal of the remaining ureteric stump is rarely necessary.

An ectopic ureter exists when the ureteric opening is located outside the bladder. In approximately 80% of cases it is associated with duplication, particularly in girls. In boys, however, the ectopic ureter is more often a single ureter than related to a duplex system. Duplication in boys may be observed with a relatively high ectopic opening of the ureter (bladderneck, urethra). The upper pole parenchyma related to the ectopic ureter in a duplex kidney is commonly of little functional value, and dysplastic lesions are usual-

ly present. It is therefore pointless to try to preserve a structure that does not contribute to total renal function and is likely to maintain a source of infection.

Ureterocele associated with duplication is a rather common anomaly in pediatric always related to the upper pole, and the position of the ureteric orifice allows for distinction between an intravesical ureterocele and an ectopic (extravesical) ureterocele. In the intravesical form, the opening of the ureterocele is located between the normal position of the ureteric orifice and the bladder neck. In the extravesical ureterocele, the opening is located at the bladder neck or in the urethra. This anatomic distinction is important because both presentation and treatment of the anomalies are different. Thanks to prenatal diagnosis, asymptomatic ureteroceles are being encountered more often, allowing appropriate evaluation. Management remains however controversial but leads to be less aggressive than with clinical presentation and single extrapolation from clinical presentation with infection should not be systematic since a more conservative attitude might be better appropriate. There is a clear and unfortunate lack of more evidence based attitudes.

The main goals in the treatment of ureterocele are control of infection, protection of normal ipsilateral and contralateral renal units, preservation of renal function, facilitation of subsequent surgery and the maintenance of continence.

There is no unanimity on how to manage surgically complex ureteroceles in children; all points of view have certain advantages and drawbacks. For the surgeon who is not familiar with the condition and seldom operates on infants, upper pole nephrectomy alone is the safest initial procedure. In neonates with sepsis and in poor general condition, preliminary decompression may be necessary and simple endoscopic incision of the ureterocele is advisable, because these neonates are poor candidates for a major procedure. In neonates with an uninfected ureterocele discovered by prenatal ultrasonography, minimal endoscopic meatotomy may have merit in allowing recovery of satisfactory renal function. A even more conservative approach may be considered fol-

lowing anteral diagnosis in the presence of dysplastic upper pole without significant obstruction and in the absence of clinical problems. A wait and see policy can be considered like for single dysplastic kidneys which tend to involute without further clinical problems. There is no evidence that in such cases surgical treatment should be systematic. For older children in good general condition, the experienced surgeon should consider a total, single-stage complete reconstruction. Very occasionally, total nephroureterectomy is indicated when the lower pole is also destroyed by obstruction or reflux. Alternatively, complete excision of an ectopic ureterocele with re-implantation of the lower pole ureter and sometimes of the contralateral ureter may be performed. Upper pole nephroureterectomy is performed first, during the same operative session, through a retroperitoneal flank incision. Cautious extravesical dissection separates both ureters; great care must be taken to preserve the periureteric adventitia of the lower pole ureter with its blood supply. There is a definite need for more evidence-based attitude.

Figure 49.1, 49.2

Through a Pfannenstiel incision, the bladder is opened and a self-retaining retractor is placed. Intravesical and extravesical dissection will liberate the ureters, which could be sectioned above their point of junction, the common trunk is excised and both ureters are re-implanted as a single unit in a common submucosal tunnel using the classic antireflux procedure. Stenting of both ureters is usual for a few days, with bladder drainage.

As both ureters are bound together in a common sheath at their lower end in complete ureteric duplication they are treated en bloc as a single unit as the two elements may be devascularized in an attempt to separate them.

Any of the procedures to correct reflux may be used, either by intravesical advancement or by extravesical ureteroneocystostomy. The classic Cohen re-implantation is most widely used.

Figure 49.3

Procedures as ureteropyelostomy should only be considered in a solitary kidney or when both kidneys are damaged. A flank incision is made, the kidney is left in situ and the ureters are liberated from the renal sinus up to their point of junction. The dilated upper pole ureter is excised exactly where it opens into the lower pole ureter. It is important not to leave

any ureters that could act as a diverticulum. The excess abnormal ureter is removed and the incision in the remaining ureter is closed with interrupted polyglycolic acid sutures. A large end-to-side anastomosis between the upper ureter and the renal pelvis is created so that the end result mimics a bifid renal pelvis without functional obstruction.

Figure 49.1

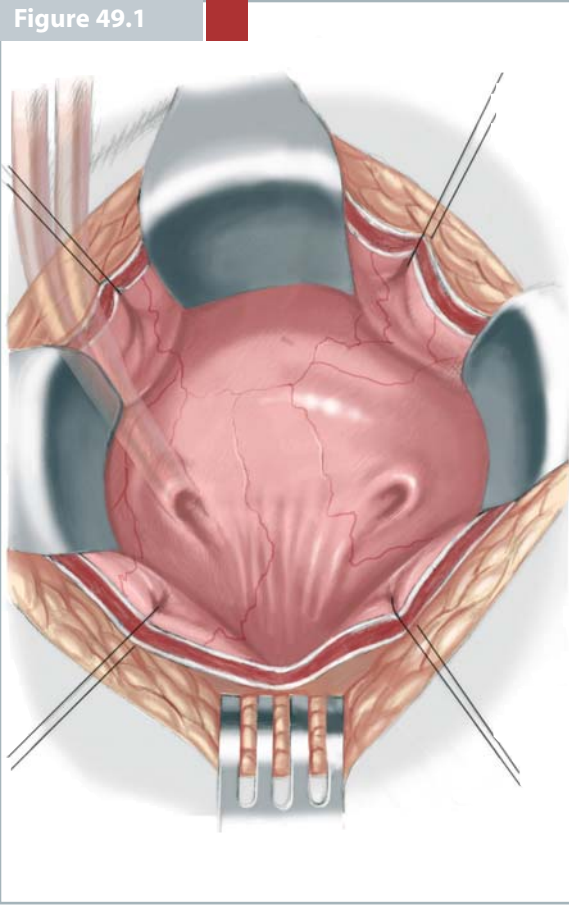


Figure 49.2

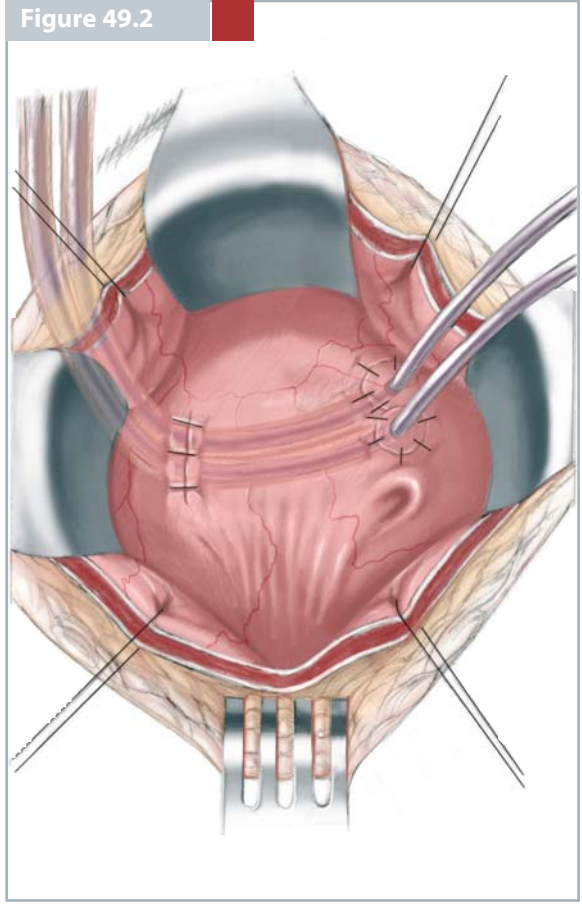


Figure 49.3

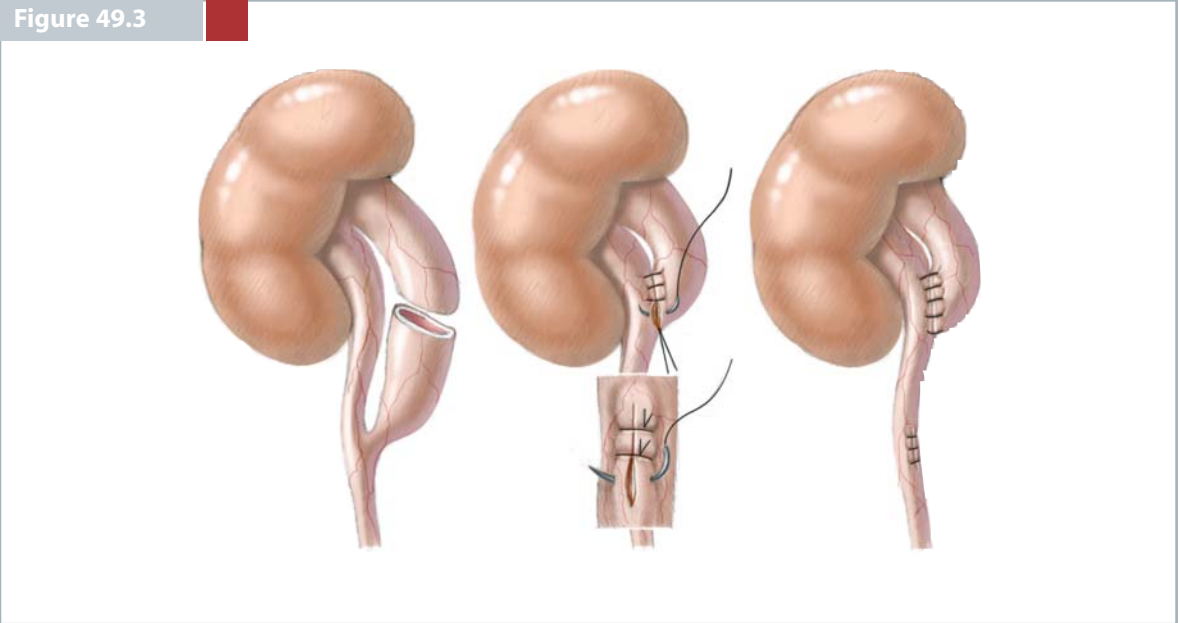


Figure 49.4, 49.5

Heminephrectomy is performed via a subcostal lumbotomy or through the last intercostals space and the atrophied and dysplastic upper pole with the corresponding dilated ureters is removed. The renal capsule on the upper pole is incised to be used later to suture over the renal parenchyma. As vascularization of the upper pole often varies and some arterial branches are likely to separate from the main artery close to the renal sinus, it may sometimes be hazard-

ous to clamp and ligate these vessels because this could cause ischaemic lesions of the remaining parenchyma.

A clear demarcation is often visible between the destroyed upper pole and normal lower pole and it is preferable to follow the cleavage plane, which is less vascularized, and to achieve haemostasis as necessary.

Figure 49.6

The procedure is completed by suturing the parenchyma of the remaining lower pole and then closing the capsule.

It is advisable to undertake simple nephropexy of the lower pole, for example, by fixing it to the poste-

rior muscular wall, to avoid its rotation around a long pedicle that has been stretched severely because of ureteric dilatation.

Figure 49.4

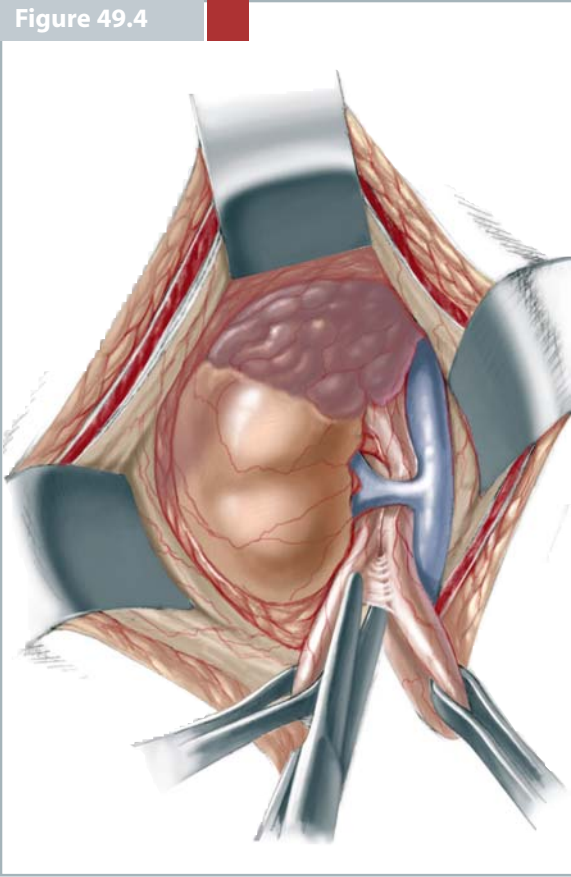


Figure 49.5

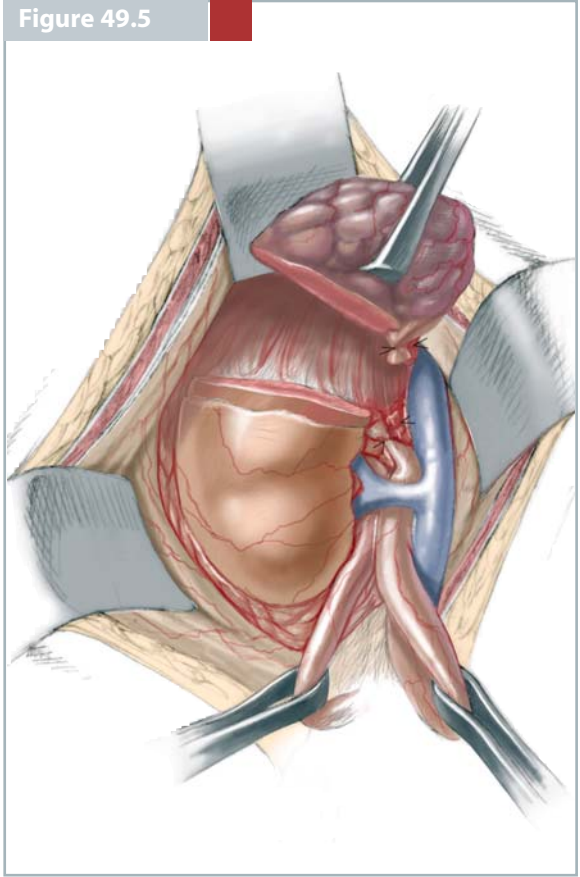


Figure 49.6

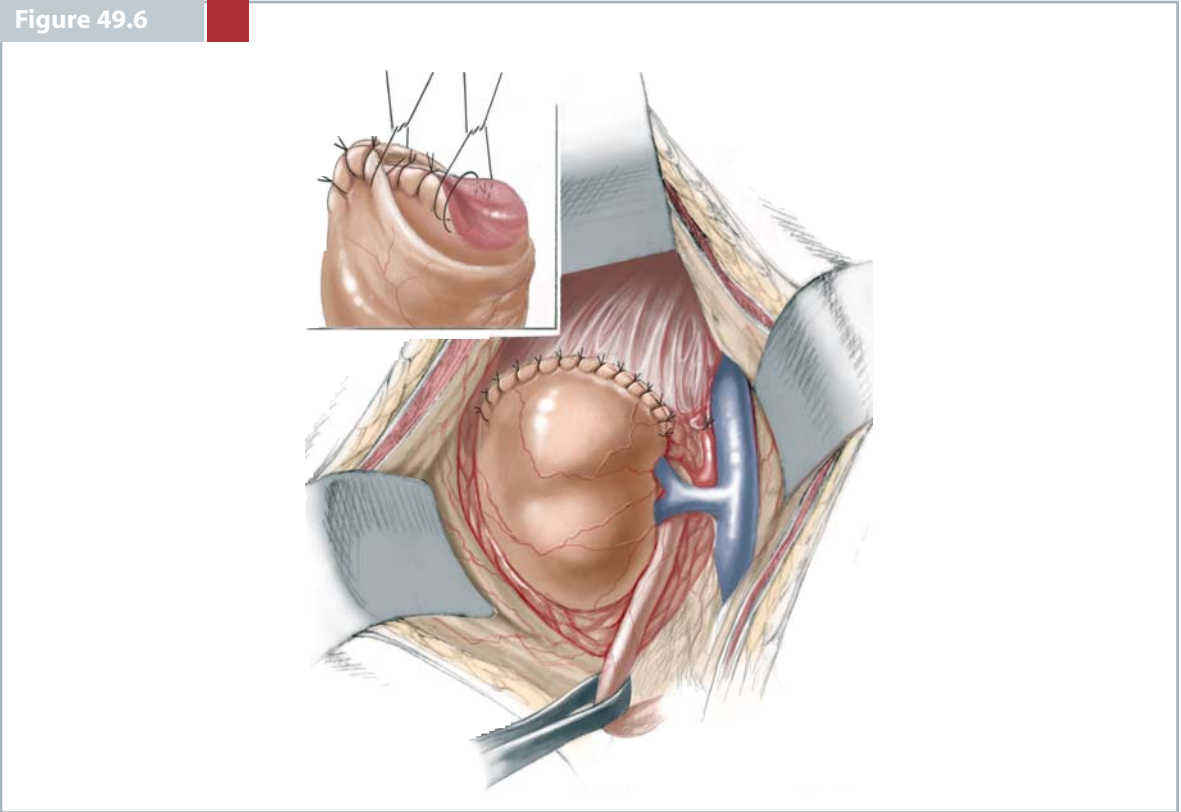


Figure 49.7

Thus, a *duplex system ureterocele* is when the ureterocele is attached to the upper pole ureter of a completely duplicated collecting system and a *single-system ureterocele* is when the ureterocele is attached to a single ureters draining the kidney. Regarding the location and extension, if the ureterocele and its orifice are located entirely within the bladder, the term *intravesical* is used. If the ureterocele and its orifice extends beyond the trigone to the bladder neck or outside of the bladder to involve the urethra the term *ectopic* is applied. Intravesical ureteroceles are usually associated with single systems, whereas ectopic ureteroceles are usually associated with the upper pole ureters of a duplex-system.

The management of the orthotopic ureterocele is straightforward. One makes an endoscopic puncture

using a pure cutting current at the distal aspect of the ureterocele just above its junction with bladder. As the Bugbee electrode is passed through the ureterocele wall, it may be moved slightly laterally in either direction to enlarge the opening. One can readily see the ureterocele deflate. In some cases, manual compression of the flank over the hydronephrotic moiety is helpful in distending the ureterocele prior to puncture, and this may demonstrate a jet urine following decompression.

For the ectopic ureterocele, a similar technique is used as the puncture is made at the base of the ureterocele at its junction with bladder wall in a clearly intravesical location. Because the ureterocele may extend distally beyond bladder neck, the location of the incision must be very clearly visualized.

Figure 49.8, 49.9

If reflux persists after endoscopic puncture of ureterocele, the treatment options are either endoscopic correction of reflux or open surgical re-implantation of duplex ureters.

Ureteric dilatation is usually moderate and treatment is similar to that used for simple ureterocele with a single ureters, consisting of excision of the ureterocele with common sheath ureteric re-implantation.

The bladder is opened and a circumferential incision is made at the base of the ureterocele. Previous

injection of saline into the ureterocele is helpful for its dissection from the trigone.

After excision of the ureterocele, the hiatus may be quite large and it is closed, treating the two ureters as a single unit.

The ureters are re-implanted, using one of the advancement techniques or the Politano-Leadbetter procedure. A transverse submucosal tunnel, as is used in the Cohen re-implantation procedure, is illustrated.

Figure 49.7

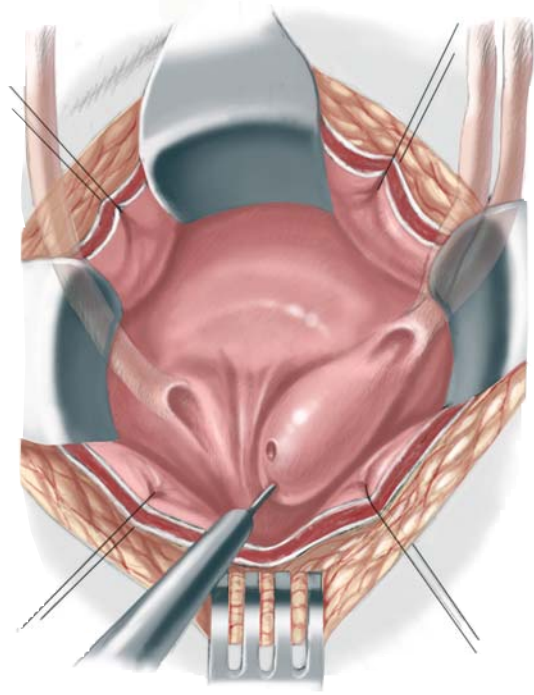


Figure 49.8

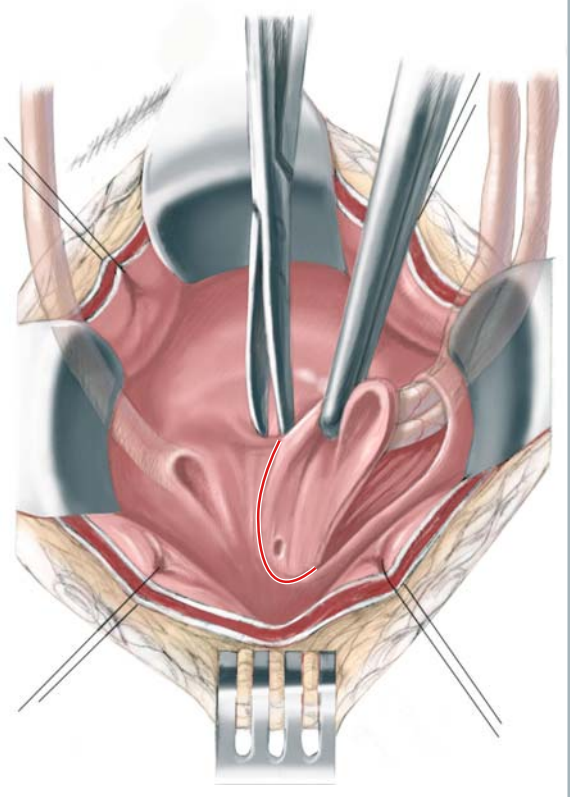
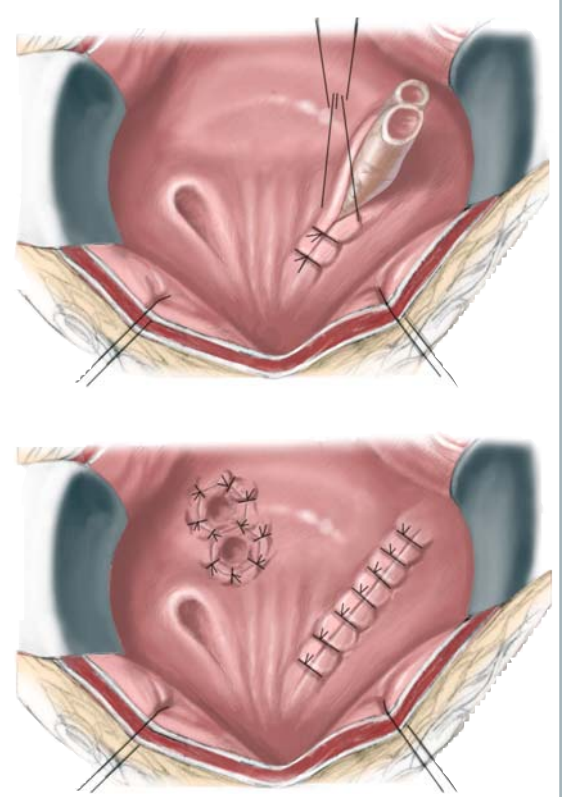


Figure 49.9



CONCLUSION

Duplication of the renal pelvis and ureters is the commonest anomaly of the upper urinary tract. It occurs in approximately 0.8% of the population and in 1.8–4.2% of pyelograms. Commonly these are asymptomatic. However, they can challenge the diagnostic acumen with a wide variety of manifestations.

SELECTED BIBLIOGRAPHY

- Diamond DA, Retek AB (2002) Endoscopic surgery of urethral valves and ureterocele. In: Frank JD, Gearhart JP, Synder III HM (eds) *Operative pediatric urology*. Churchill Livingstone, London, pp 31–37
- Chertin B, De Caluwe D, Puri P (2003) Is primary endoscopic puncture of ureterocele a long-term effective procedure. *J Pediatr Surg* 38 : 116–119
- Frey P, Mendoza-Sagron M, Meyrat BJ (2003) Ureterocele in the newborn. *Arnold, London*, pp 845–854
- Schulman CC (1995) Ureteric duplications. In: Spitz L, Coran AG (eds) *Pediatric surgery*. Chapman & Hall, London, pp 655–665

Chester J. Koh, David A. Diamond

INTRODUCTION

Posterior urethral valves (PUV) represent the most common aetiology of congenital urethral obstruction in boys and the most common urologic cause for end-stage renal disease in children.

Historically, four types of posterior urethral valves have been described. However, only types I and III are generally acknowledged as obstructing valvular lesions. Type I valves are the most common, and occur in 95% of cases. They typically arise from the posterior and inferior edge of the verumontanum, and radiate distally toward the membranous urethra, where they insert and fuse anteriorly near the proximal margin of the membranous urethra. Type II valves are not considered obstructive lesions and usually represent hypertrophy of the superficial trigonal muscle in response to distal urethral obstruction. Type III valves occur in 5% of cases, and usually consist of an obstructing circumferential membrane that sits distal to the verumontanum at the level of the membranous urethra. These may form long folds that prolapse distally and lead to a windsock appearance. Type IV valves are usually seen in prune belly syndrome, where there is a kinking of the flabby, poorly supported prostate.

Voiding cystourethrogram (VCUG) is a gold standard for confirmation of the diagnosis of PUV. On VCUG, a distended bladder with prostatic urethral

dilation is usually seen with a linear filling defect coursing from the verumontanum to the membranous urethra, which represents the obstructing valve. Other radiographic features may also be present, such as massive unilateral vesicoureteral reflux, large bladder diverticuli, and urinary ascites, all of which appear to be associated with improved prognosis, as these findings indicate the presence of a “pop-off valve” mechanism (Rittenberg et al. 1988). These are thought to reduce intraluminal pressures, thereby allowing the fetal renal parenchyma to develop more normally.

In the past, many infants with PUV presented with dehydration, severe electrolyte abnormalities, urosepsis, and renal insufficiency. In these situations, a small feeding tube should be placed transurethrally to allow for adequate vesical drainage during the initiation of parental antibiotics and rehydration. In placing the tube, one must avoid coiling in the prostatic urethra due to the elevated bladder neck and dilated prostatic urethra. Currently, however, the majority of patients are diagnosed by prenatal ultrasound, avoiding the severe illness previously associated with this anomaly. With the introduction of infant-size cystoscopes and miniature electrocautery, endoscopic ablation of the valves has become the treatment of choice for neonates with PUV.

Figure 50.1, 50.2

Endoscopic valve ablation involves three essential steps: the assessment of the urethral calibre, the delineation of the anatomy, and the ablation of the valve tissue.

Most newborn urethras will comfortably accommodate a 7.5F or 8F endoscope. For older infants and children, a 9F or 10F instrument can be used. The calibre of the urethral meatus and the fossa navicularis tend to be the limiting anatomic factors in passing an instrument. To determine the maximum capacity of the urethra, pediatric Campbell's sounds should be passed into the anterior urethra only. Calibration of the anterior urethra should occur to one size larger than the instrument to be used, with care taken to avoid overdilation of the urethra.

The anatomy can most easily be determined by passing the endoscope under direct vision into the bladder, then carefully withdrawing the scope. The bladder neck may be quite high, which will require positioning of the endoscope almost vertically to enter the bladder. Then, with the irrigation flowing, the endoscope is gradually withdrawn. In the case of a

type I valve, a prominent lip will appear posteriorly just distal to the bladder neck. Then one can visualize prominent urethral folds radiating upward from the verumontanum. The sail-like folds of the type I valve then emanate distally and laterally from the lower portion of the verumontanum and join anteriorly at the 12 o'clock position. The folds can most clearly be seen at the 5 and 7 o'clock positions, and one can see the external sphincter just distal to the valve leaflets.

To best visualize the valves, the bladder should be full, and the end of the cystoscope should be placed at the level of the external sphincter. The lower abdominal wall should then be pressed from above in a Crede fashion with the drainage channel open on the cystoscope to create a urinary flow. This should fill the valve leaflets, which usually snap into an obstructing position.

In the case of the type III valve, which appears like a narrow obstructing diaphragm in the posterior urethra, the passage of the endoscope through the aperture in this diaphragm will often disrupt this type of valve.

Figure 50.3

The optimal anatomic location for valve ablation is still the subject of debate. The 12 o'clock position has been referred to as the most critical area to ablate, as this is where the anteriorly fused membrane lies. Others have argued that fulguration at the 5 and 7 o'clock positions is optimal since the leaflets are best visualized and most safely fulgurated at these positions. Our preference is to ablate the valve leaflets at 5 and 7 o'clock positions, although we acknowledge that ablation of the valves at one location alone may disrupt the ring-like obstruction and be curative.

The 9F infant resectoscope allows one to safely ablate the valve under direct vision. Once the bladder and urethra have been inspected with the cystoscope, the resectoscope sheath can be introduced after gentle urethral calibration. The sheath of the resectoscope should be passed into the anterior urethra only with the use of the obturator, then the working element can be placed to direct the instrument into the

bladder under vision. The visibility with the resectoscope is usually slightly inferior to that with the cystoscope because of the reduced flow of irrigation, so one should re-establish landmarks at this point.

With the use of the zero degree lens, the leaflets can best be visualized at the 5 and 7 o'clock positions. Once the valves are in view, the resectoscope loop can then be used to hook the leaflets and draw them into the resectoscope sheath (Fig. 3). Applying a pure cutting current at 20–30 W will lead to ablation of the valve tissue. In addition, the instrument can be rotated 180° to visualize and ablate the obstructing valve tissue at the 12 o'clock position. One advantage of the resectoscope is its ability to distinguish insignificant leaflets, which do not produce enough resistance to be hooked by the loop. If the fossa navicularis can not accommodate the resectoscope sheath comfortably, one may use the 7.5F cystoscope and the 3F Bugbee electrode.

Figure 50.1

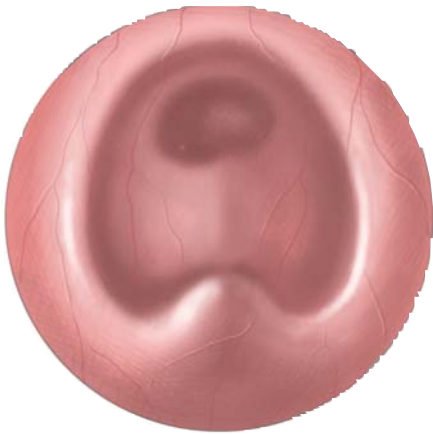

Figure 50.2

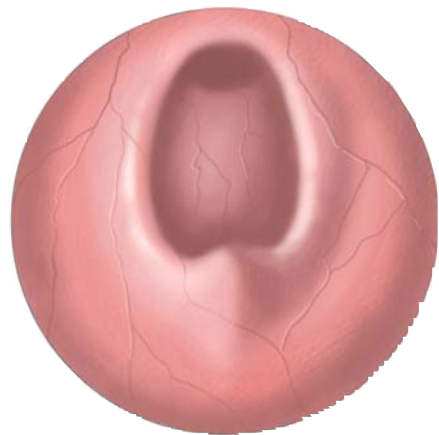


Figure 50.3

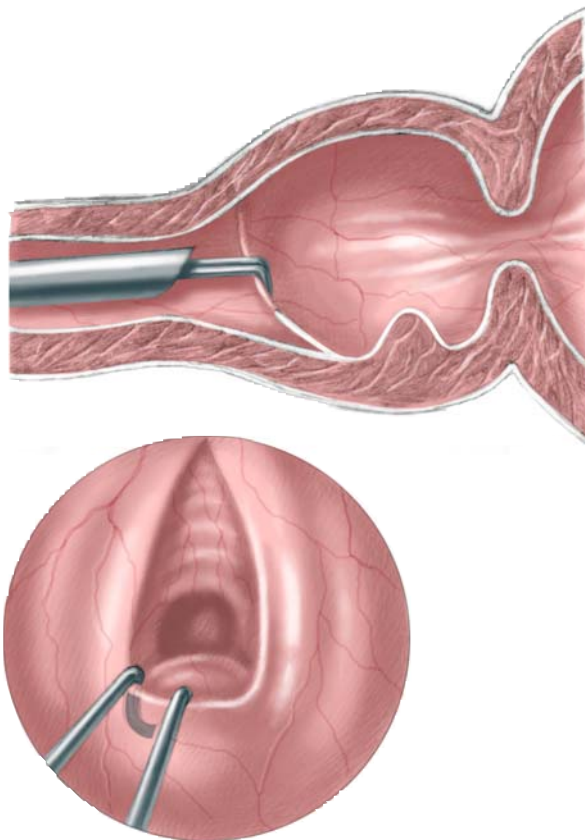


Figure 50.4

Ablation with the Bugbee electrode is performed by engaging the medial edge of the leaflet with the electrode and then gently pushing toward the bladder and applying the current. The cautery settings should be at 25 W on pure cut.

Ablation at the 5 and 7 o'clock positions should render the valve incompetent. The remnant leaflets should flutter with the expressed urine. Repeat fulguration may be necessary if residual obstructive tissue is noted.

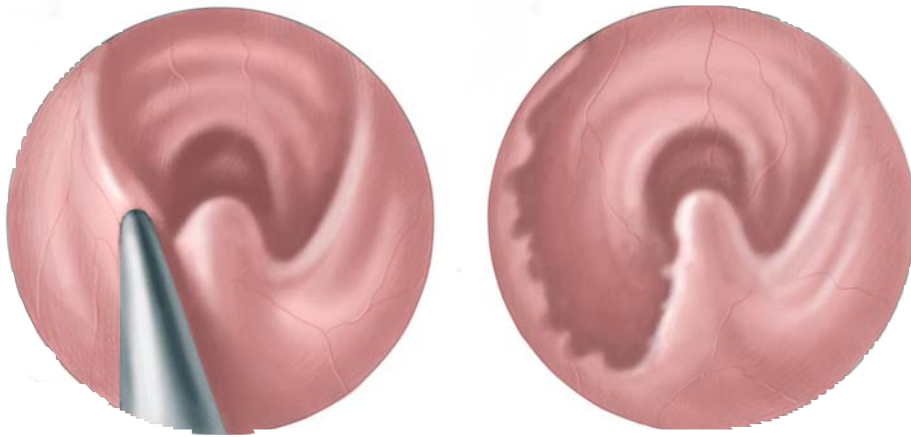For smaller infants, an alternative means of valve ablation may be necessary with the use of a 3F ureteric catheter and a wire stylet. The urethras of these children may only allow this smaller catheter to be passed through or alongside the 7.5F infant cystoscope while permitting the flow of irrigant during the procedure for adequate visualization. The wire stylet is cut distally to protude from the end of the catheter, and the proximal end is clamped to the cautery electrode. The catheter itself acts as the insulator to the wire. The catheter is usually advanced through the

cystoscope to the level of the valve before the wire is advanced. Then the wire should be advanced 2 to 3 mm out of the catheter and pushed just into the valve leaflet. Fulguration can occur in a similar fashion as with the larger Bugbee electrode; however, several short bursts of current may be necessary to effectively ablate the valves. Care should be taken to avoid overzealous fulguration, as this complication can lead to injury to the prostatic urethra and external sphincter.

Following valve ablation, an indwelling catheter is left in place for 24 h, although this may not be always necessary.

In select cases, alternative techniques may be useful. In developing countries without miniature equipment, or in premature infants in whom safe ablation is limited by urethral calibre, ablation with a Fogarty balloon catheter may be advantageous. In similar settings, the Whitaker insulated hook provides another alternative approach.

Figure 50.4



CONCLUSION

As the ability to prenatally diagnose PUV has developed over time, so has the temptation of in utero intervention to relieve urinary obstruction secondary to valves. However, the long-term benefits of in utero intervention are currently unclear, and they must be weighed against the significant risks to the mother and fetus. Currently, the most compelling scenario for proceeding with prenatal intervention is when a male fetus with signs of infravesical obstruction is initially noted to have normal amounts of amniotic fluid, but subsequently has oligohydramnios, while having evidence of good renal function based on serial urine electrolyte aspirations.

Transurethral ablation usually leads to relief of urethral obstruction and often resolution of reflux via a minimally invasive approach that entails minimal risk. The benefits of ablation include decompression of the urinary tract and the tendency toward maximum recoverability of overall renal function during a period of substantial renal growth. In addition, transurethral ablation is also believed to allow the

bladder to fill and empty on a regular cycle, which is thought to lead to more normal voiding patterns and to decreased collagen deposition and perhaps a reduction in the risk of bladder non-compliance.

Certain prognostic factors have been reported in the literature. At age 12 months, a nadir creatinine of 0.8 mg/dl or less is associated with normal long-term renal function and improved prognosis. On the other hand, the presence of daytime urinary incontinence after age 5 years is associated with abnormal long-term renal function.

Yet, even with successful fulguration of valves, bladder dysfunction, which has also been described as the valve bladder syndrome, is always a distinct possibility. In general, management of the valve bladder consists of anticholinergic medications to reduce uninhibited detrusor contractions, clean intermittent catheterization to ensure adequate bladder emptying, or bladder augmentation to improve bladder compliance and bladder volume.

SELECTED BIBLIOGRAPHY

- Diamond DA, Ransley PG (1987) Fogarty balloon catheter ablation of neonatal posterior urethral valves. *J Urol* 137: 1209–1211
- Glassberg KI (1985) Current issues regarding posterior urethral valves. *Urol Clin North Am* 12:175–185
- Parkhouse HF, Barratt TM et al (1988) Long-term outcome of boys with posterior urethral valves. *Br J Urol* 62:59–62
- Rittenberg MH, Hulbert WC et al (1988) Protective factors in posterior urethral valves. *J Urol* 140:993–996
- Warshaw BL, Hymes LC et al (1985) Prognostic features in infants with obstructive uropathy due to posterior urethral valves. *J Urol* 133:240–243
- Whitaker RH, Sherwood T (1986) An improved hook for destroying posterior urethral valves. *J Urol* 135:531–532

INTRODUCTION

Hypospadias is one of the most common urogenital anomalies, occurring in 3 in 1000 births. It is better defined as a hypoplasia of the tissues forming the ventral aspect (ventral radius) of the penis beyond the division of the corpus spongiosum. It is characterized by a ventral triangular defect whose summit is the division of the corpus spongiosum, whose sides are represented by the two pillars of atretic spongiosum and whose base is the glans itself.

In the middle of this triangle sit from the tip to the base of the penis: a widely open glans, the urethral plate, which extends from the ectopic urethral meatus up to the glans apex, the ectopic meatus and a segment of variable length of atretic urethra (not surrounded by any spongiosum), which starts where the corpus spongiosum divides.

There are two main types of hypospadias:

- The hypospadias with a distal division of the corpus spongiosum with little or no chordee when the penis is erected
- The hypospadias with a proximal division of the corpus spongiosum with a marked degree of hypoplasia of the tissues forming the ventral radius, marked by a significant degree of chordee

The causes of hypospadias remain essentially unknown although several avenues have been explored to explain this congenital defect of the genital tubercle:

- Some endocrine disorders have been described in relation to hypospadias, mainly due to an insufficient secretion of androgens, or insufficient response by the target tissues. However, in very few cases can these disorders be demonstrated.
- Some genetic disorders could explain why hypospadias may be found in several members of the same family.
- Young and old mothers are more prone to carry a baby with hypospadias. Small birth-weight babies and twins also have a higher risk of presenting with a hypospadias. This could be explained by a placental insufficiency.
- The significant increase of hypospadias in the population over the last 20 years raises the role of possible environmental factors such as oestrogen-like molecules, pesticides, fertilizers etc.

- Abnormal or insufficient growth factors could also be responsible for these penile anomalies and could also explain the significant complication rate met in this surgery.

Three surgical steps characterize hypospadias surgery:

- The correction of chordee, which is essentially the result of the atresia of the ventral radius. Degloving the penis represents the first step of this surgery and straightens the penis in 80% cases. In 15% cases, the persistent curvature is due to an abnormal tethering of the urethral plate and the hypoplastic urethra onto the ventral aspect of the corpora. Lifting the urethral plate from the corpora is a valuable additional manoeuvre that straightens the penis in most cases. There are still 5% cases where the penis remains bent although all the tissues forming the ventral radius have been freed. The residual chordee is due to asymmetrical corpora cavernosa and requires a dorsal corporeoplasty (dorsal shortening of the albuginea of the corpora cavernosa). In most cases the urethral plate can be preserved although there are situations where the urethral strip is very poor and the 2 corpora writhe around it. In these cases the urethral plate is usually sacrificed.
- Once the penis is straight, the missing urethra should be replaced. The technique chosen depends on the size and quality of the urethral plate:
 - If the urethral plate is wide and healthy, it can be tubularized following the Thiersch-Duplay technique.
 - If it is too narrow to be tubularized, the Snodgrass urethrotomy is one option or additional tissue can be laid on the urethral plate using a rectangle of pediculated preputial mucosa (onlay urethroplasty), or a flap of ventral penile skin (Mathieu procedure).
 - If the segment of urethra to replace is short (<2 cm), and if the distal urethra is not hypoplastic, a complete mobilization of the whole penile urethra may be adequate to bridge the defect. This technique (Koff), like the Thiersch-Duplay technique, has the advantage of avoiding the use of non-urethral tissue.

- If the urethral plate is not preservable, a tube needs to be made to replace the missing urethra using either a pediculized rectangle of preputial mucosa (Asopa-Duckett technique) or buccal mucosa.
- In major hypovirilization of the genital tubercle, the Koyanagi procedure mobilizing the whole mucosal tissue of the ventral radius and preputial hood is a reliable option to reconstruct the missing urethra. Two stage procedures (Bracka - Cloutier procedure) are an alternative for long urethroplasty using either preputial mucosa or buccal mucosa.
- Once the urethra is repaired, the ventral radius of the penis needs to be reconstructed. This includes:
 - Meatoplasty trying to create a slit-shaped meatus
 - Glanuloplasty to reconstruct the ventral aspect of the glans
 - The creation of a mucosal collar around the glans
 - Coverage of the reconstructed urethra (spongio-plasty) using the lateral pillars of spongiosum
 - Skin cover with a redistribution of the skin shaft bringing the excess dorsal skin to the ventrum
 - Some prefer to reconstruct the foreskin, others favour circumcision.

The patient's age at surgery for primary hypospadias repair is usually between 6 and 24 months.

Hormonal stimulation of the penis using beta human chorionic gonadotrophin (β HCG) or testosterone or dihydrotestosterone is sometimes indicated in case of small penis or re-dosurgery. It remains unclear how safe these treatments are on a long-term basis. General anaesthetic is the rule often associated with caudal or penile anaesthesia. Magnification is commonly used in this surgery. Coagulation is often not needed in this surgery when the tourniquet is used followed by a slightly compressive dressing. Other surgeons prefer bipolar coagulation or adrenaline injection prior to incision. Antibiotic protocols are extremely variable from one centre to another and, here again, their efficacy needs to be proven. Urine drainage via a suprapubic catheter, a trans-urethral bladder catheter or dripping urethral stent, varies a lot from one surgeon to another. Some even do not drain at all. The dressing is essential after this surgery and varies also. The "daisy dressing" has our favour as it is very comfortable for the patient and contains post-operative bleeding. Others prefer Op-Site dressing, silastic foam dressing or Tagaderm dressing. Post-operative pain control is essential using morphine instillations, anti-inflammatory medications, anticholinergic and diazepam to reduce bladder spasms.

Figure 51.1

From the tip to the base of the penis: the ventral aspect of the glans is wide opened (1). The urethral plate replaces the urethra (2) and extends from the apex of the glans down to the ectopic meatus (3). Behind the ectopic meatus sits a segment of hypoplastic urethra not surrounded by any spongiosum (4). The division of the corpus spongiosum (5) marks the proximal limit of the malformation. It defines a triangular defect whose summit is the division of the corpus spongiosum, whose base is the glanular cap and whose sides are represented by the two lateral pillars of atretic spongiosum.

Figure 51.2a-d

MAGPI Procedure

The MAGPI procedure was very fashionable in the 1980s to repair distal hypospadias. It is actually not a meatal advancement but a flattening of the glans, which gives the illusion that the meatus reaches the glans apex. Secondary retraction of the meatus is quite common and therefore this procedure has become less popular.

The incision line is drawn 5 mm behind the ectopic meatus and follows the cutanemucosal junction of the prepuce. A deep vertical incision into the glanular groove for a distance of about 1 cm opens the dorsal meatus generously. Transverse closure of the diamond-shaped defect that is created flattens out the glanular groove and allows a straight stream to emerge.

Figure 51.1

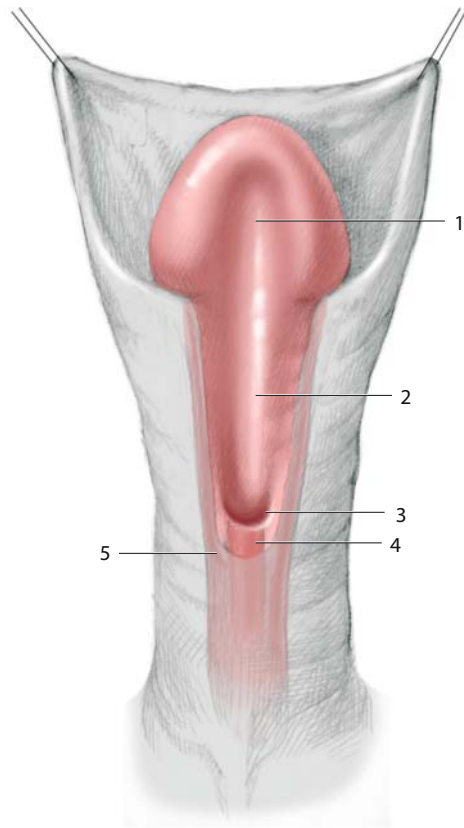


Figure 51.2a-d

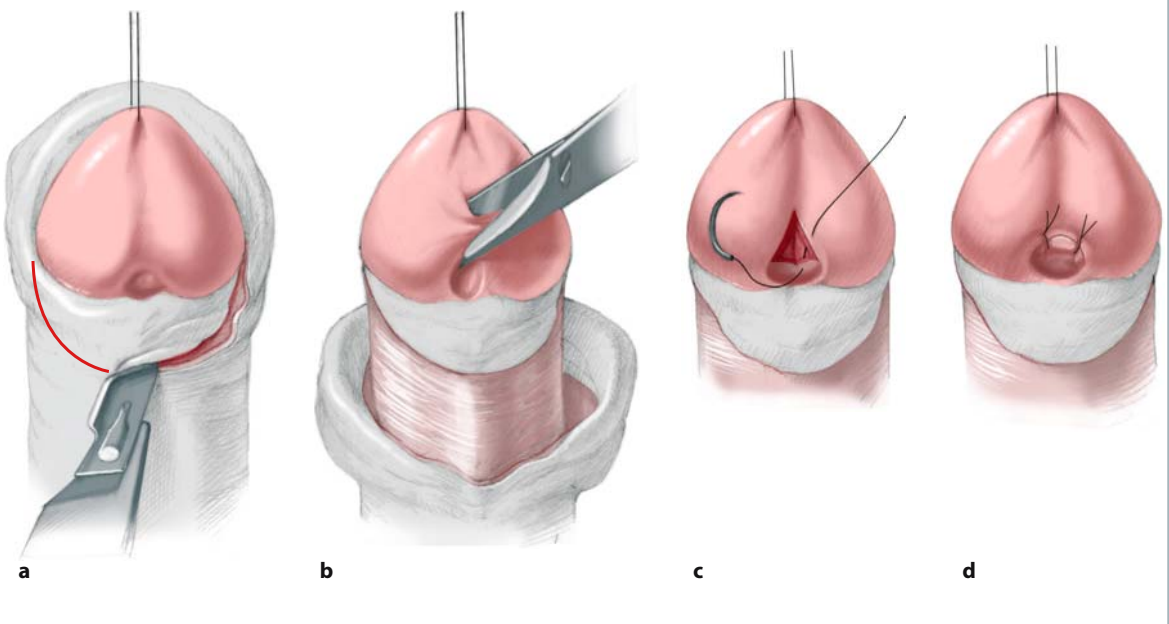


Figure 51.3a–d

The ventral lip of the urethra is fixed with a holding stitch and brought forward. This allows the lateral wings of the glans to rotate to the ventrum. A sleeve approximation of the penile skin is done, excising all redundant tissue and leaving a circumcised appear-

ance. It seems that the MAGPI procedure is particularly well indicated when the glans is broad and flat. No stent or catheters are required and the procedure can be done on outpatient basis.

Figure 51.4a–d**Mathieu Procedure**

In the Mathieu procedure, two parallel incisions are made on either side of the urethral plate up to the tip of the glans and deep down to the corpora cavernosa. The incision line delimits a perimeatal-based skin flap that is folded over and sutured to the edges of the

urethral plate. The lateral wings of the glans are generously dissected from the corpora cavernosa and approximated together producing a conical shape of the glans.

Figure 51.3a-d

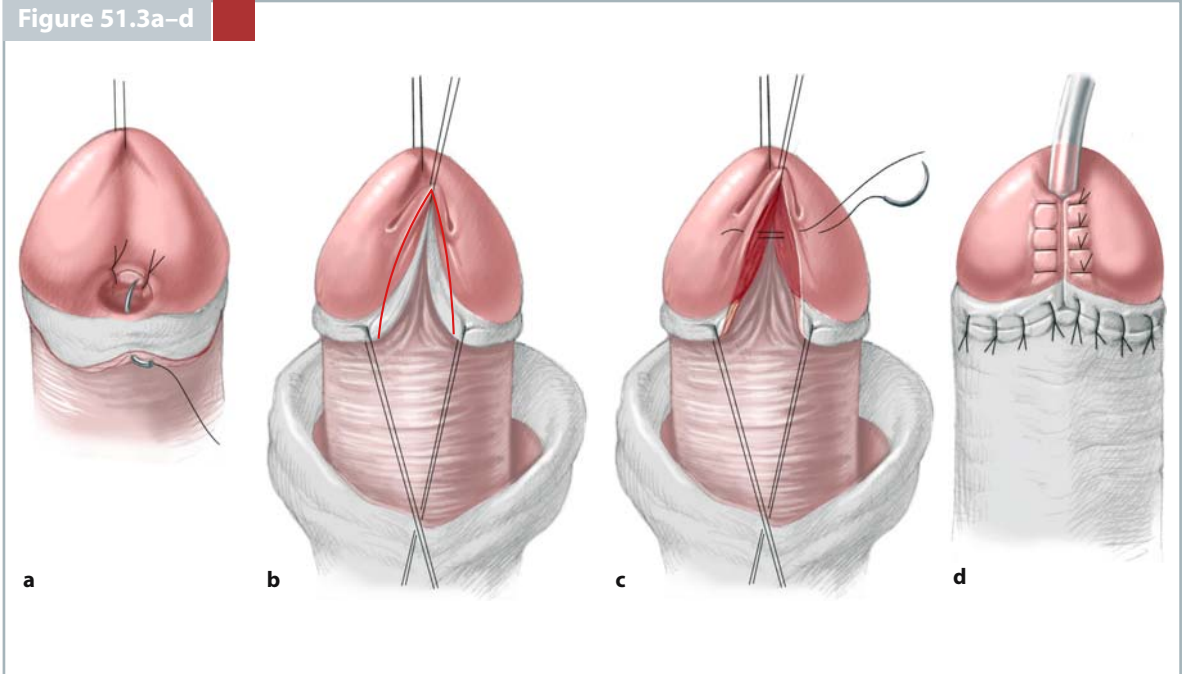


Figure 51.4a-d

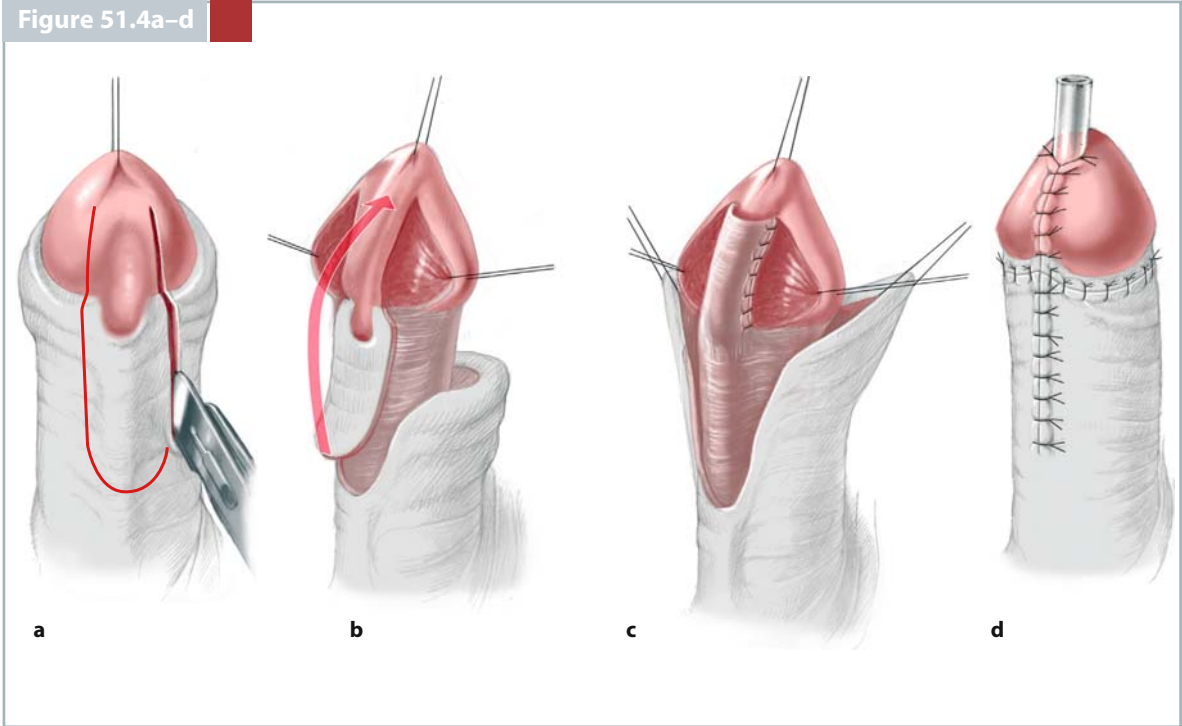


Figure 51.5a–e**Snodgrass Procedure**

The urethral plate is incised longitudinally on its midline from the ectopic meatus up the glans and subsequently tubularized around a Fr 8 catheter. This is the Snodgrass procedure which leaves a dorsal raw area in the urethra with a subsequently epithelized.

Figure 51.5a-c

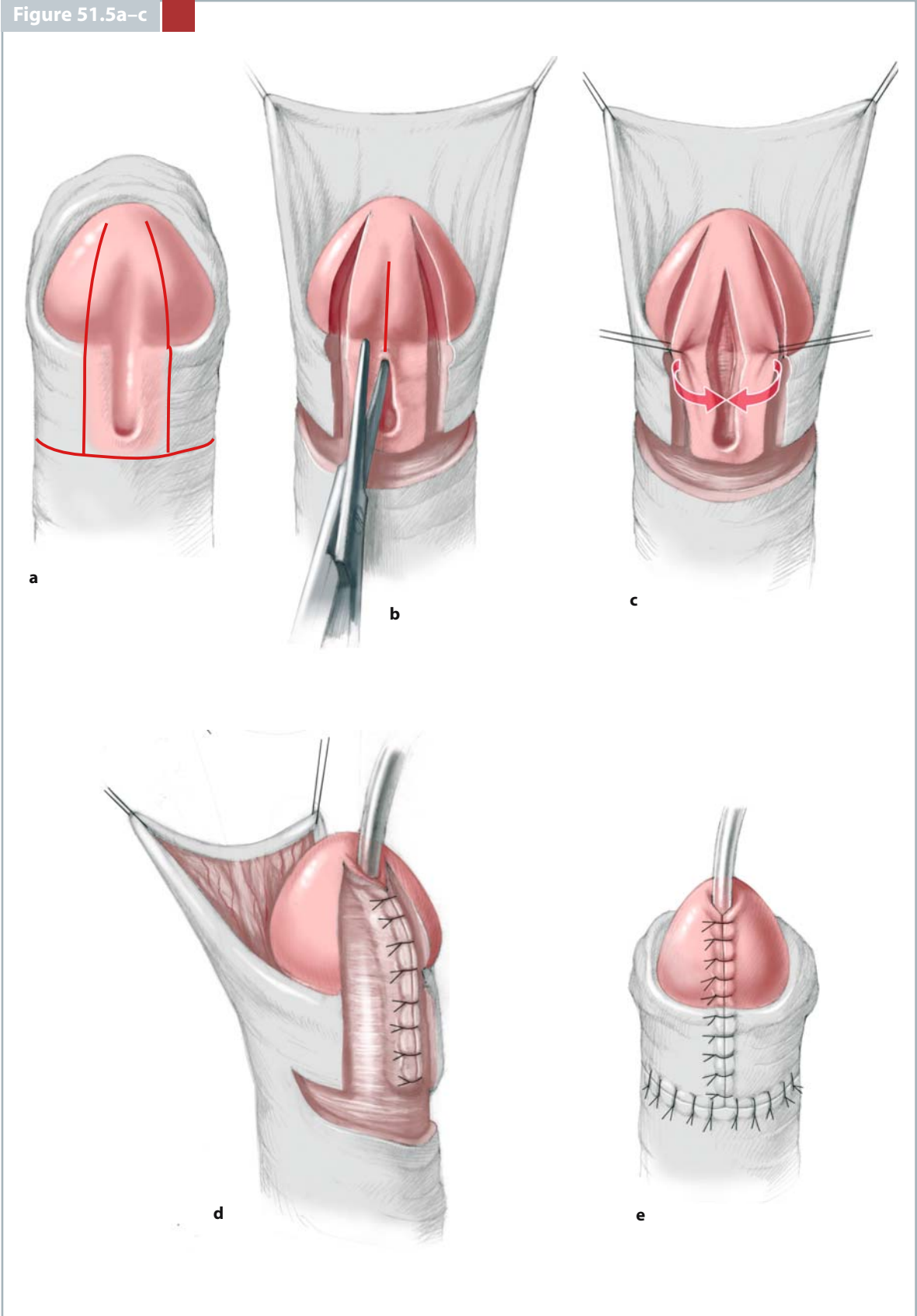
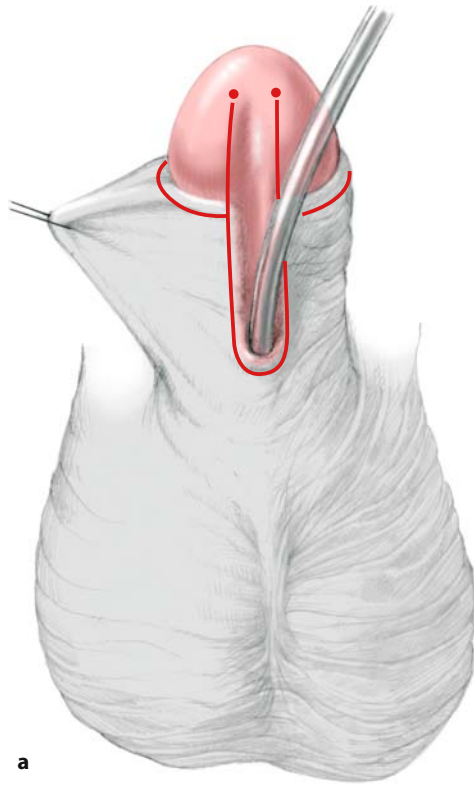


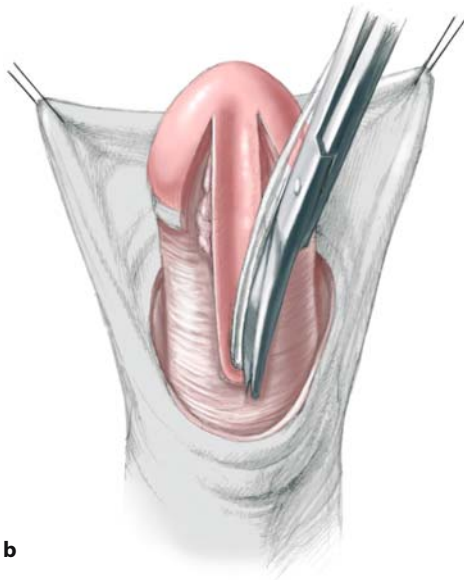
Figure 51.6a,b**Onlay Procedure**

In the onlay procedure, a rectangle of preputial mucosa is pediculated down to the base of the penis and transferred to the ventrum of the penis to be laid on the urethral plate using interrupted 6/0 or 7/0 or a running suture.

Figure 51.6a,b



a



b

Figure 51.7a–d

When the urethral plate is too poor to be kept full-tube urethroplasty needs to be performed using either a pediculated rectangle of preputial flaps or a rectangle of buccal mucosa may be used. The main

disadvantage of these techniques is that a proximal circular urethral anastomosis is performed, which increases the risk of urethral stenosis.

Figure 51.7a-d

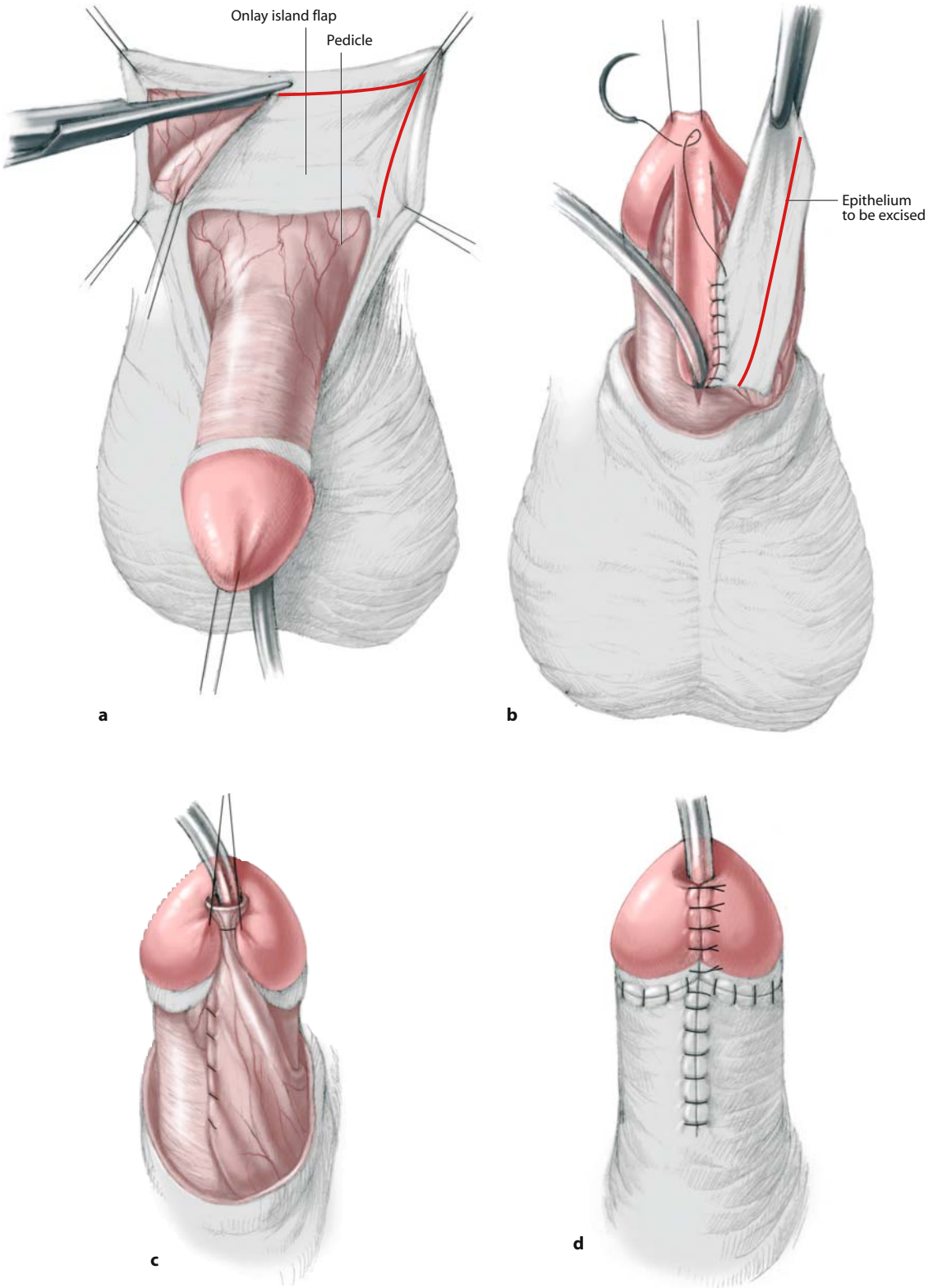


Figure 51.8a–e**Koff's Urethral Mobilisation**

When the segment of the urethra to reconstruct is short (< 2 cm) and when the distal urethra is healthy, a full mobilisation of the penile urethra can be performed following Koff's technique. In these cases the

penile urethra is detached as far proximally as necessary, and it is moved upward to bring the meatus to the tip of the glans. The gain of length may be up to 15 mm.

Figure 51.9a–d**Thiersch-Duplay Procedure**

The incision lines follow each side of the urethral plate from the tip of the glans down to the division of the corpus spongiosum. The two wings of the glans are dissected deeply and laterally until the corpora are clearly identified. The urethral plate is tubular-

ized around a French 8 catheter for children under 3 years of age, using a 6/0 or 7/0 absorbable running suture. The neourethra is then covered by 2 wings of the glans in one or two layers.

Figure 51.8a-e

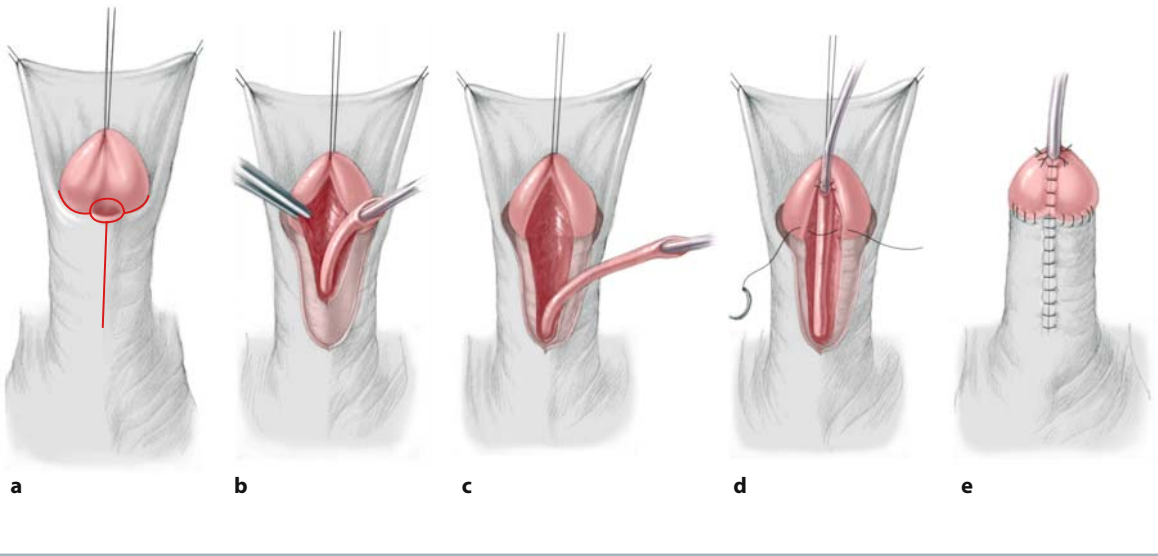
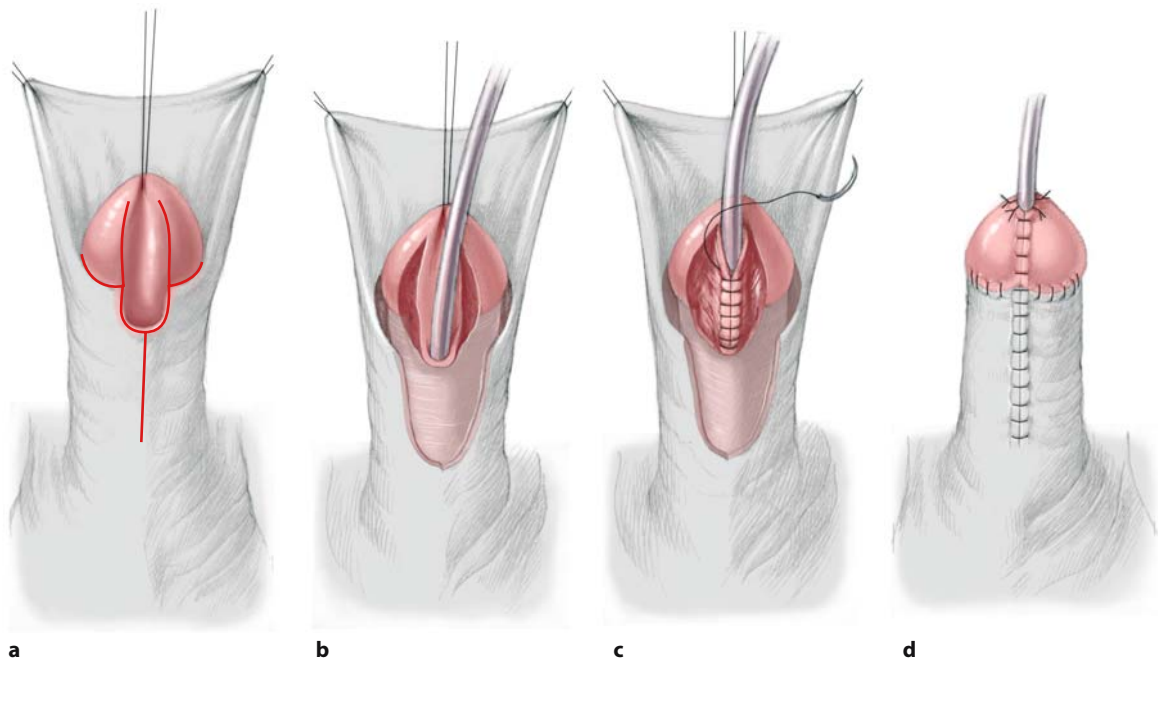


Figure 51.9a-d



CONCLUSION

Hypospadias surgery remains a difficult challenge as several factors of success remain unknown. One of the most intriguing is the variations of the “healing abilities” between patients. With the development of tissue engineering, it is hoped that urethral substitution using the patient’s urethral tissue might be the future avenue to resolve the current difficulties met. Long-term follow-up of these patients appears to be a crucial issue to assess and validate the various techniques currently available. The problem is how to follow these patients. Clinical examination of the penis is highly subjective. Assessment of the urine stream is difficult as urine flow studies are very often abnor-

mal after urethral reconstruction. At the end of the day, the experience and honesty of the pediatric urologist remain the two most important factors to progress in hypospadiology. Parents should be clearly informed that approximately 50% of hypospadias repairs will require further surgical attention during the patient's life. Minor hypospadias do not exist and this implies that this surgery should always be performed by experienced paediatric urologists. Collaboration with pediatric endocrinologists is also important to increase the chances of surgical success. Pre- and post-operative treatment may be helpful to improve the patient’s “healing abilities”.

SELECTED BIBLIOGRAPHY

- Mouriquand P, Mure PY (2001) Hypospadias. In: Gearhart J, Rink R, Mouriquand P (eds) *Pediatric urology*. WB Saunders, Philadelphia, pp 713–728
- Mouriquand PDE, Persad R, Sharma S (1995) Hypospadias repair: current principles and procedures. *BJU* 76 [Suppl. 3]: 9–22
- Snodgrass WT, Lorenzo A (2002) Tubularized incised-plate urethroplasty for proximal hypospadias. *BJU Int* 89: 90–93
- Duckett JW (2002) Hypospadias repair. In: Frank JD, Fearhart JP, Snyder HM III (eds) *Operative pediatric urology*. Churchill Livingstone, London, pp 149–160
- Snyder H (2003) The island onlay hypospadias repair. In: Hadidi AT, Azmy AF (eds) *Hypospadias surgery*. Springer, Heidelberg Berlin New York, pp 163–168

Phimosis and Buried Penis

Peter Cuckow

INTRODUCTION

The term phimosis, derived from the Greek word meaning to muzzle, is a descriptive term referring to the natural conical shape of the foreskin in early life. This prevents its retraction and keeps the glans of the penis covered. Additionally the inner surface of the prepuce is initially fused with the outer surface of the glans. Widening of the narrow tip of the prepuce combined with separation of its inner adhesions occurs during childhood to allow full retraction and uncovering of the glans by puberty.

Studies of normal infants and children have shown that the rate of this process is very variable – to the extent that in some newborns it is already fully retractile, whilst in around 20% of 5-year-olds it can remain “phimotic”. The failure to recognize this normal process of development has led many doctors to label non-retractile foreskins abnormal and refer patients for circumcision. The vast majority of prepuces are normal, however, and will become fully retractile by puberty. In the 1% that do not, most are subject to a pathological process called balanitis xerotica et obliterans (BXO), which causes clinically apparent scarring at the preputial tip. This is rarely seen in the under fives and is usually cured by circumcision, for which it is the only absolute indication in childhood.

Other foreskin problems may be related to its development and non-retraction but are usually transient rather than long-term problems. Thus ballooning during micturition and infection of the foreskin or balanitis will resolve and cause no discernable damage. Severe symptoms from these, however, do represent a relative indication for circumcision. By applying these principles several groups of British pediatric surgeons have reported circumcising only around 25% of boys referred for consideration of the operation.

There is a minority of boys whose foreskins remain narrow or tight on retraction, in which no obvious scarring can be seen. In these patients preputial-plasty or widening of the narrow tip of the prepuce can be a helpful and more conservative alternative to circumcision. Some surgeons have used this procedure to enable earlier mobility and facilitate the cleanliness of “late developing” foreskins, although this author now prefers to allow nature to take its course and reserves preputial-plasty for a few older boys.

The main long-term complication of circumcision is stenosis of the exposed urinary meatus, which is reported to occur in between 2 and 35% of patients. These patients can develop voiding difficulties and even bladder dysfunction if the outflow obstruction is severe. Relief is achieved by meatoplasty.

Penile abnormality is a contraindication for routine circumcision. Patients with hypospadias require a more complex re-construction, to achieve a more normal “circumcised” appearance and this is discussed elsewhere in this book (Chap. 51).

The buried penis is an abnormality of peno-scrotal fusion, in which the penile corpora are also tethered to the deep fascia of the lower abdominal wall. It is associated with phimosis and the appearance of the external skin suggests that the penis is small or even absent. Often the inner preputial space is enlarged and balloons during voiding, with dribbling from the preputial orifice – sometimes referred to as megaprepuce. Circumcision of the visible external prepuce in these cases does not achieve emergence of the penis and may compromise the eventual reconstruction of a more normal circumcised appearance. An operation for this condition, to release the tethered corpora and remodel the shaft skin, is presented at the end of this section.

CIRCUMCISION**Figure 52.1, 52.2**

The prepuce is fully retracted behind the glans and any residual adhesions to the glans are separated carefully. If the tip is narrow or scarred a haemostat is inserted into the preputial orifice and opened in order to dilate it and allow retraction. It may be necessary to make a small dorsal incision in the tip of the prepuce with scissors to enable this. In a patient with severe BXO (rare in the under fives) adhesions to the glans may be dense and separation of these is traumatic.

With the skin held under tension, retracted back over the penile shaft, a circumferential incision is made with a size 15-blade scalpel, 8 mm proximal to the glans on the dorsal surface. This is completed ventrally on each side, parallel to the coronal sulcus, where the frenulum and its artery are divided. Care is taken not to damage the urethra, which is quite superficial at this point.

The foreskin is replaced over the glans. A clip is placed on its edge in the midline anteriorly (usually the position of the midline raphe). A second is placed

opposite this dorsally and the foreskin is held forward, under slight tension. The second circumferential incision is made just proximal to the corona of the glans, whose profile can be seen and felt through the foreskin. Care is taken to ensure that enough skin is retained to cover the shaft. The incision is angled distally towards the ventral surface, which allows for the natural angle of the coronal sulcus with the penile shaft.

The clips are repositioned on the dorsal edge of the foreskin either side of the midline and a dorsal slit is made between them with scissors. This joins the inner and outer incisions. Scissors are used to divide the subcutaneous layers circumferentially and remove the sleeve of foreskin.

The remaining cylinder of penile skin is retracted proximally to expose the raw shaft and bleeding vessels. These are coagulated with bipolar diathermy.

Attention is paid to the frenular aspect of the penis and coagulation of the distal end of its artery beneath the ventral skin cuff.

Figure 52.1

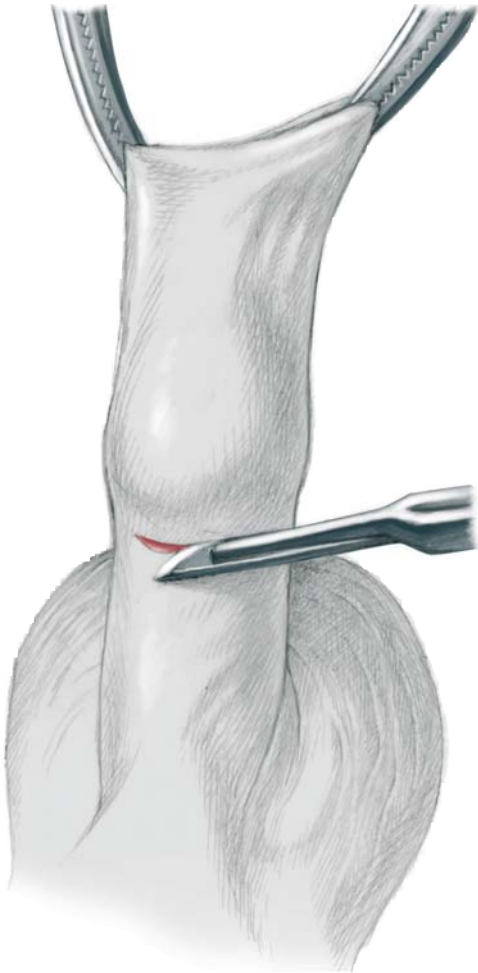


Figure 52.2

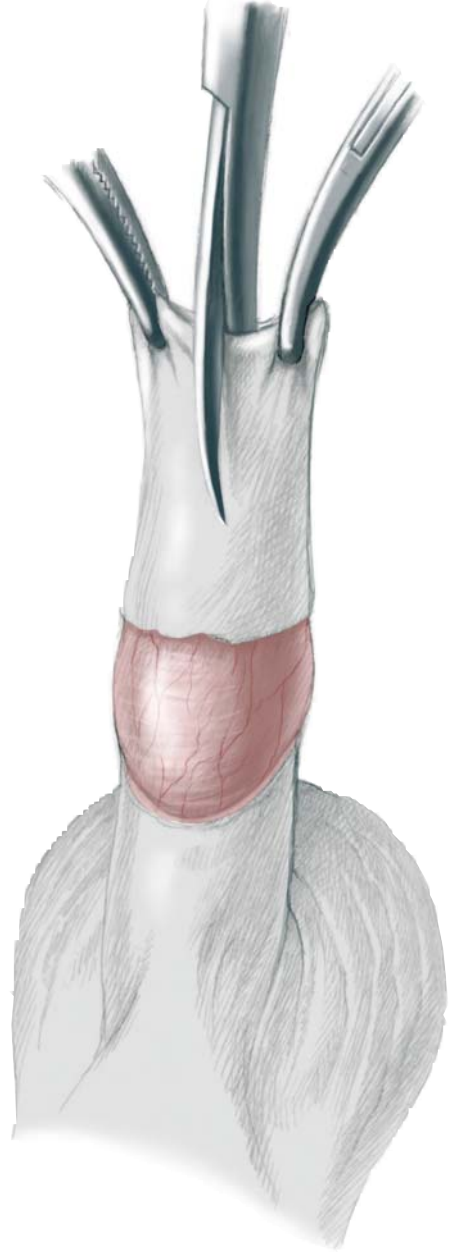


Figure 52.3, 52.4

A fine absorbable suture (5/0 or 6/0 Vicryl or Monocryl) on a round bodied needle is used to approximate the shaft skin to the cuff of distal skin. A box stitch is used to reconstitute the frenulum (*diagram*). A second stitch is placed in the midline dorsally and the penis is suspended between them.

Interrupted sutures are placed at 5-mm intervals along each side to complete the anastomosis. Following the operation the penis is wrapped in gauze and squeezed for 2 min to exclude haematoma and aid

haemostasis, before the boy is awakened. Any bleeding at this point can be stopped with a circumferential gauze dressing that can be removed before the patient goes home. With effective haemostasis this should usually be unnecessary. Patients may be given topical antibacterial cream to apply for a few days post-operatively. This may reduce local infection and prevents the exposed wound sticking to underwear or bedclothes.

MEATOTOMY**Figure 52.5–52.7**

The meatus is identified and a small lacrymal probe can be inserted to demonstrate it. The orifice is dilated sufficiently to allow one blade of a small haemostat to be inserted and directed proximally. The thin ventral tissue below the meatus is crushed in the midline by closing the haemostat. This usually incorporates at least 5 mm of tissue but does not extend more than halfway towards the corona.

The crushed tissue is now divided carefully with a fine pair of sharp pointed scissors. The crushed tissue maintains haemostasis at this point.

The neo-meatus is further secured with fine monofilament absorbable sutures (6/0 Monocryl). These are placed at its apex and on either side.

The new meatus should calibrate easily to at least 14F. If it does not the ventral incision can be extended by repeating the above steps. Post-operatively patients are supplied with chloramphenicol eye ointment. The small nozzle on the applicator can be inserted gently into the meatus to apply ointment within, twice daily for the next week. This gently opens the meatus and reduces inflammation as it heals.

Figure 52.3

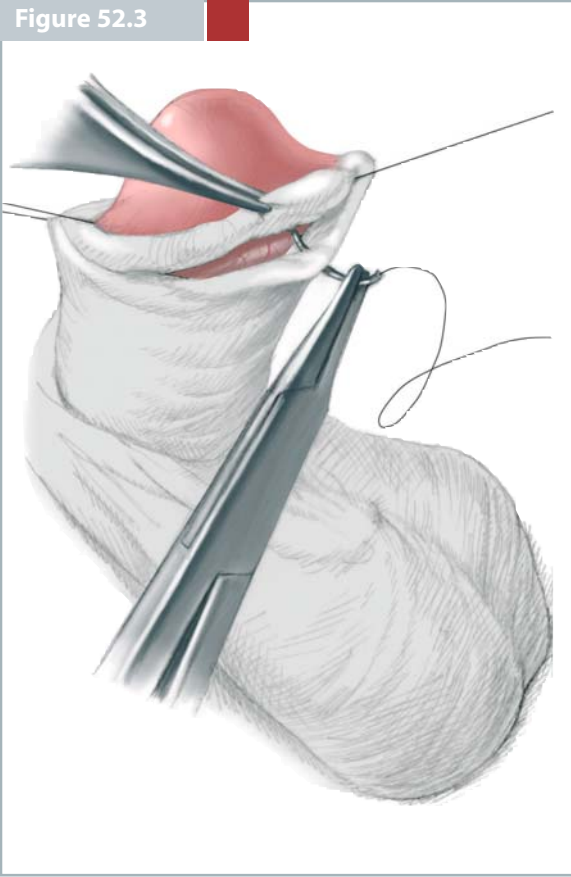


Figure 52.4

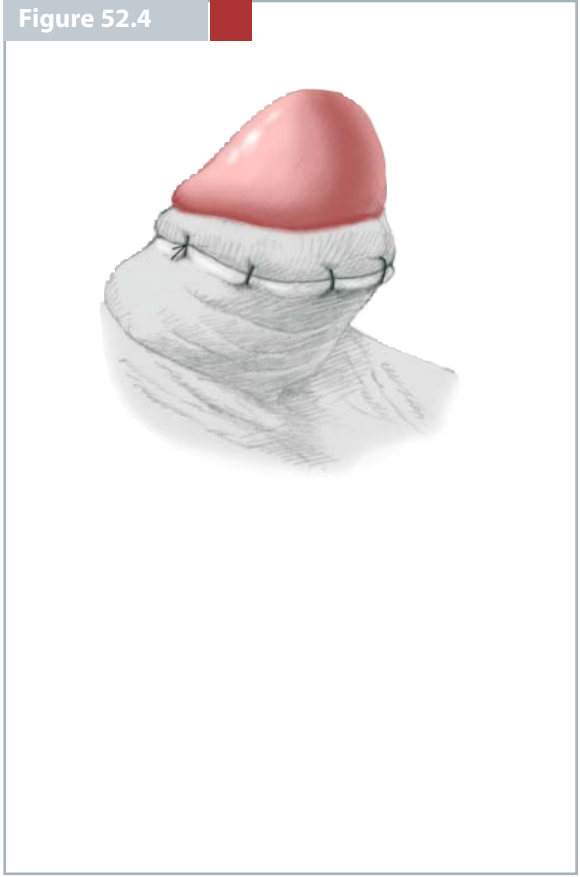

Figure 52.5

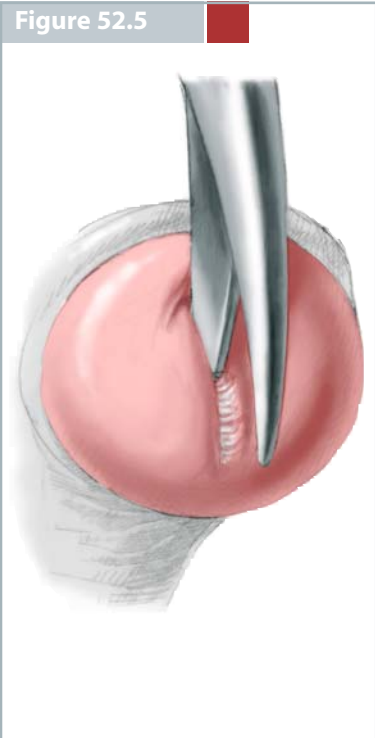
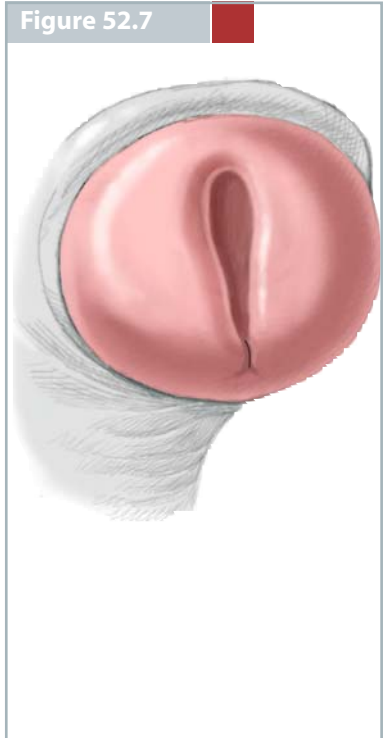


Figure 52.6

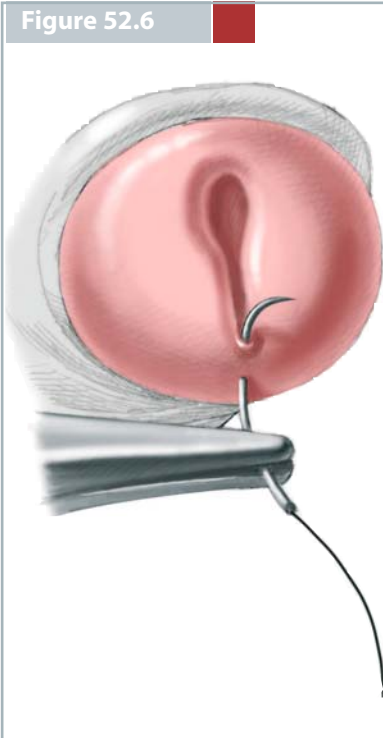

Figure 52.7



BURIED PENIS

Figure 52.8

Abnormality of peno-scrotal fusion and tethering of the penile corpora to the deep fascia, gives rise to the anomaly of buried penis. The external prepuce is small and phimotic and there may be an associated inner-preputial sac, sometimes referred to as a megaprepuce.

Pinching the tip of the prepuce and holding it forward identifies the line of demarcation between the scrotal and penile shaft skin. Deep palpation reveals normal sized corpora and glans.

A curved line is drawn along this line of demarcation to the apex of the scrotum. This marks the extent of what is to become the penile shaft skin. Care must be taken to ensure that this is broad enough to envelop the penile shaft without tension.

Figure 52.9

The incision is made along this line and deepened through the dartos fascia on to the deep fascia of the penile shaft with cutting diathermy needle. The shaft skin is lifted off the dorsum of the penis and dissection is continued around it using diathermy and blunt dissection with a gauze swab. It is important to expose the deep fascia of the penile shaft and to extend this proximally to its base, in order to completely free it.

Figure 52.10, 52.11

The preputial sac is opened by ventral incision into the orifice along the ventral raphe.

This allows retraction of the prepuce and exposure of the glans. There is a variable cuff of inner prepuce – which may be quite extensive and rugose. A

glans suture is placed at this point to aid in retraction.

The inner prepuce is pulled back along the penile shaft and circumcised 6 to 8 mm below the glans, parallel to the corona.

Figure 52.8

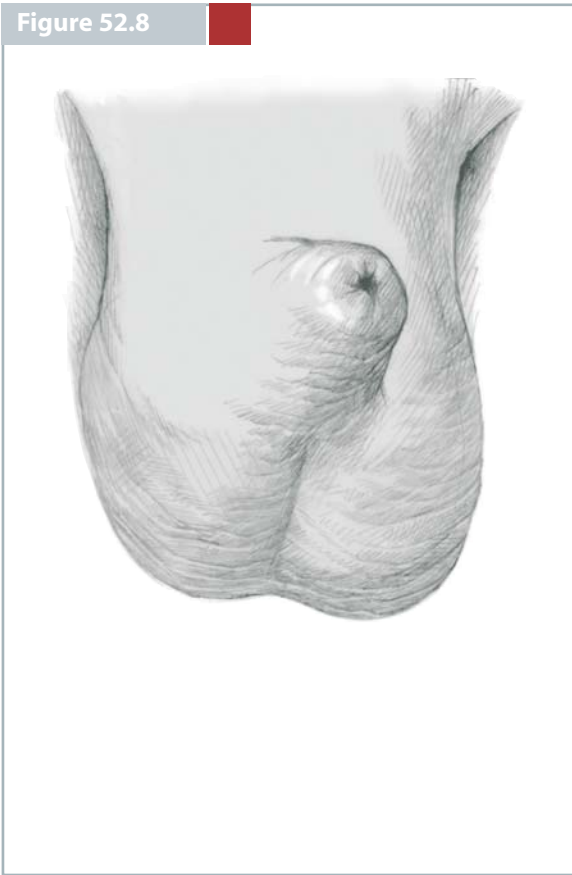

Figure 52.9

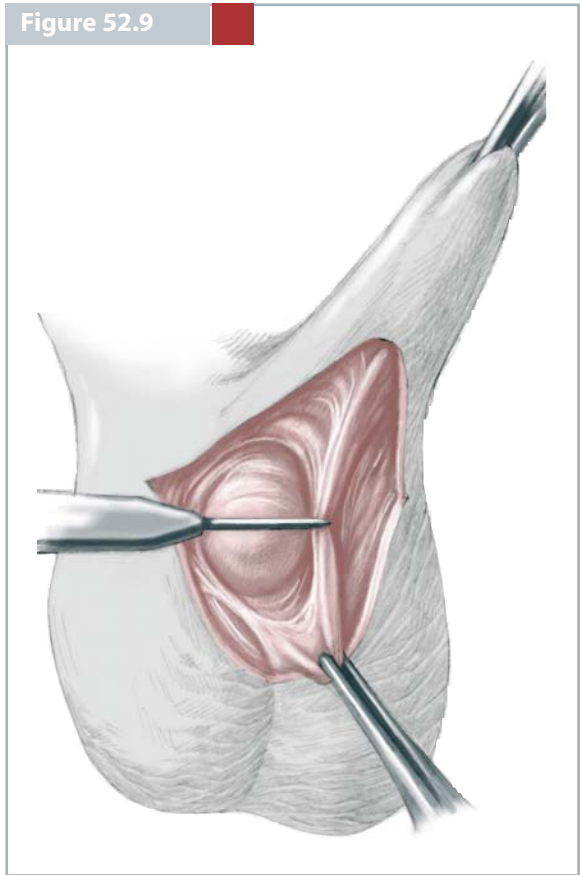


Figure 52.10

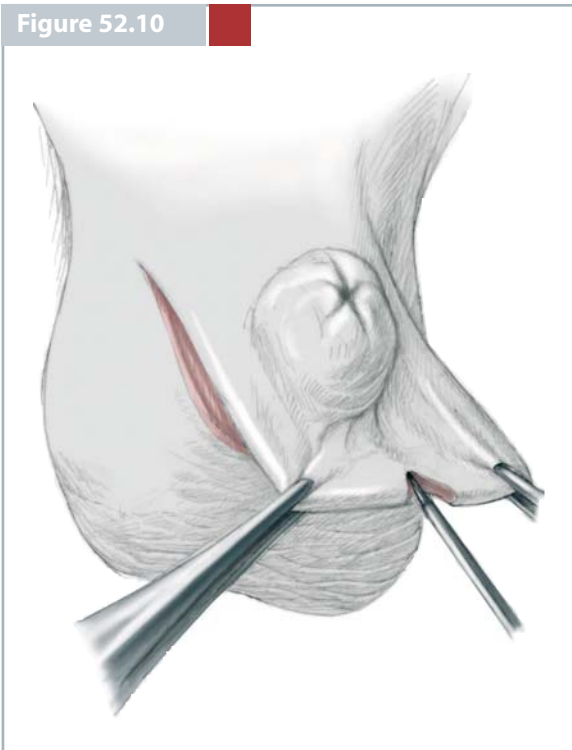


Figure 52.11

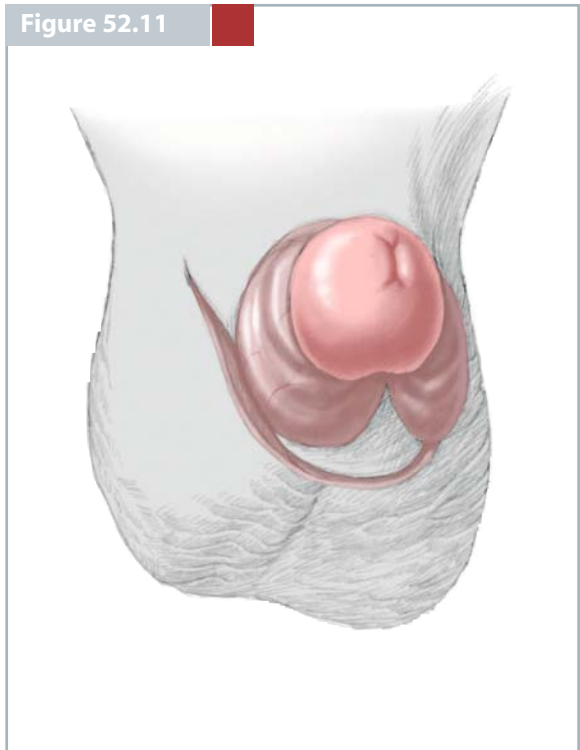


Figure 52.12, 52.13

The skin is lifted from the penis, by opening the cuff of inner prepuce ventrally. The dorsal flap of skin is thinned by removing some of its subcutaneous fat layer with sharp scissors. This leaves a quadrilateral flap of skin from which skin cover is obtained.

The base of the flap is secured using a deep suture of 5/0 PDS (polydioxanone), which also picks up the deep fascia over the urethra. This suture is placed at the apex of the original incision on each side.

Figure 52.12

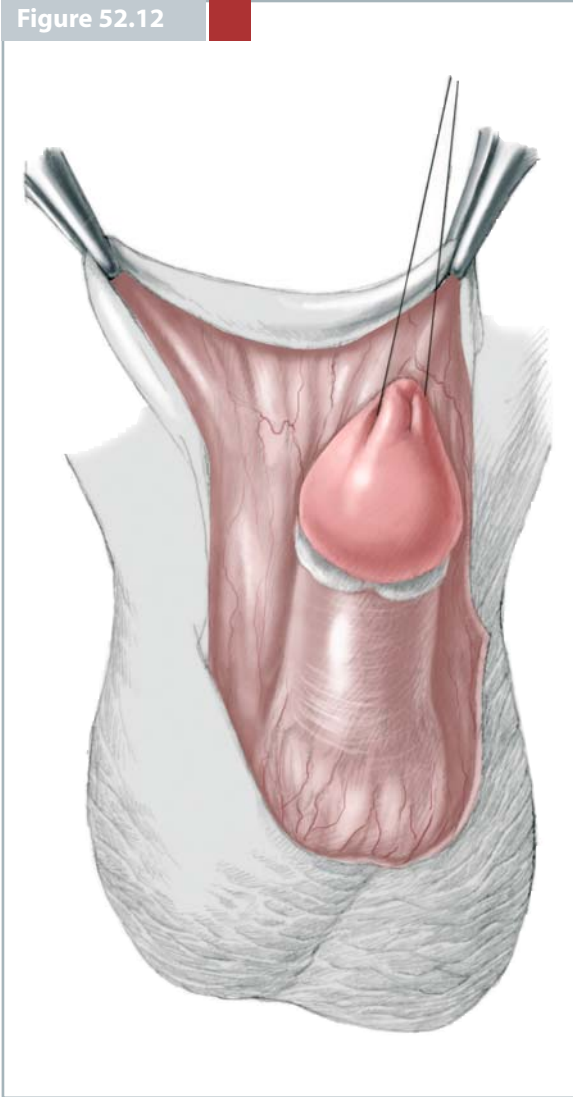


Figure 52.13

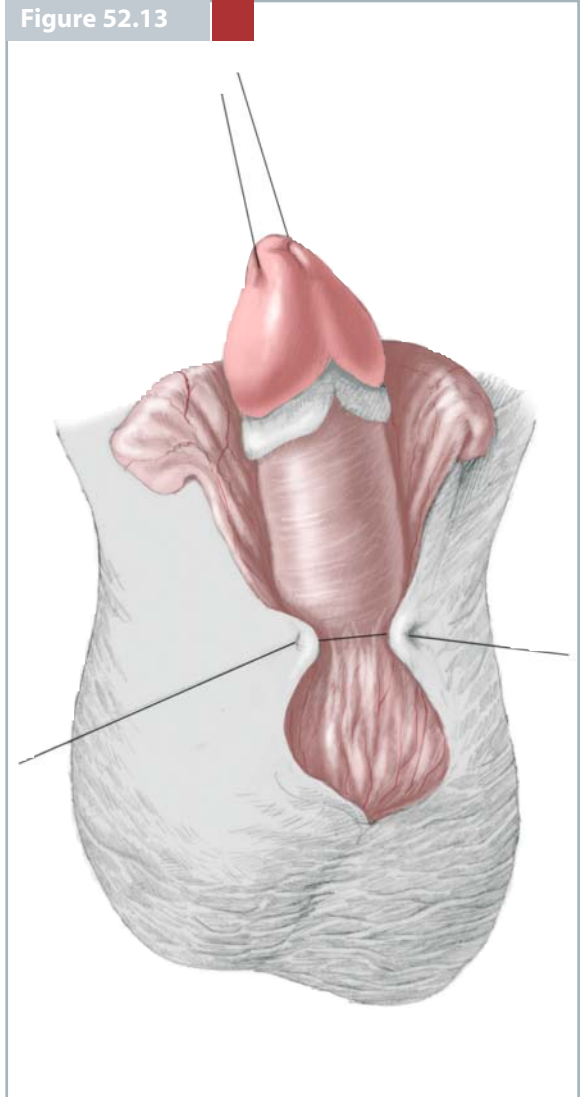
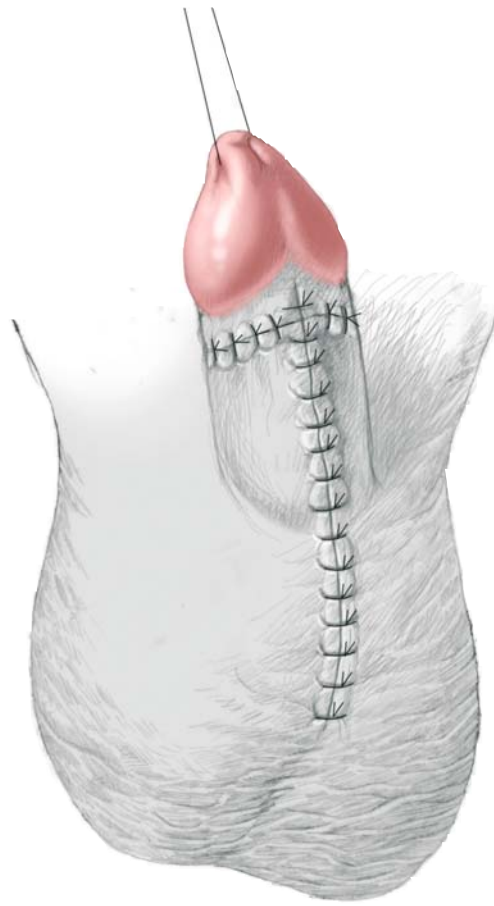


Figure 52.14

Ventral closure of the skin is continued distally with interrupted 6/0 Monocryl sutures. The excess skin is trimmed dorsally with a scalpel. The skin suturing is completed circumferentially. The scrotal raphe is sutured to the proximal end of the shaft suture line, us-

ing a box stitch. The scrotal defects on each side are closed with interrupted sutures. Post-operatively, a hypospadias dressing is used, with a dripping stent, and left in situ for 1 week. Patients are given oral antibiotics and oxybutinin during this time.

Figure 52.14



CONCLUSION

Penile surgery should always be performed under general anaesthetic. Local anaesthetic techniques can also be used to provide good intra- and post-operative analgesia and a caudal epidural is the standard. This is probably not required for meatoplasty or

preputial plasty. Sutures for this surgery should be absorbable monofilaments such as Monocryl. The author always uses round-bodied or taper-point needles.

SELECTED BIBLIOGRAPHY

Cuckow PM (1998) Circumcision. In: Stringer MD, Oldham KT, Mouriquand PDE, Howard ER (eds) *Pediatric surgery and urology – long-term outcomes*. WB Saunders, London, pp 616–624

Cuckow PM, Rix G, Mouriquand PDE (1994) Preputial plasty: a good alternative to circumcision. *J Pediatr Surg* 29: 561–563

Gairdner D (1949) The fate of the foreskin. A study in circumcision. *BMJ* 2: 1433–1437

Rickwood AMK, Hemathala V, Batcup J, Spitz L (1980) Phimosis in boys. *Br J Urol* 52: 147–150

Smeulders N, Wilcox DT, Cuckow PM (2000) The buried penis – an anatomical approach. *BJU Int* 86: 523–526

INTRODUCTION

Undescended testis (UDT) is one of the commonest abnormalities in male infants. In preterm infants, the incidence may be 20% or more, as the final stage of descent from the groin to the scrotum normally occurs at about 25–35 weeks of gestation. About 4–5% of males have undescended testes at birth, but more than half of these will continue to descend in the first 12 weeks postnatally. By 3 months post-term, the incidence of congenital cryptorchidism is 1–2%.

There is considerable controversy about whether the subsequent testicular dysfunction is primary or secondary. Some authors have proposed that germ cell loss postnatally is secondary to a primary defect of the hypothalamic-pituitary-gonadal axis. Alternatively, there is strong evidence that postnatally high temperature interferes with normal testicular function leading to germ cell depletion and risk of cancer in adulthood. Consensus is building that the crucial step in postnatal germ cell maturation is transformation of neonatal gonocytes into type A spermatogonia

in the second 6 months after birth; hence the current recommendation for orchidopexy is at 6 months of age. Prevention of germ-cell loss is the aim of surgery, although this remains unproven so far.

The testis fails to remain in the scrotum in a significant number of older boys. They appear to have acquired cryptorchidism, which has been called ascending testis, gliding testis or pathologically retractable testis. The abnormality is likely secondary to failure of the spermatic cord to elongate in proportion to the boy himself (the spermatic cord length doubles from 5 cm to 8–10 cm in the first 10 years after birth).

At surgery the major finding is a fibrous remnant of the obliterated processus vaginalis, linking acquired UDT with inguinal hernia. Occasionally the processus is still patent as a latent hernia. The indication for surgery in this acquired group is failure of the testis to remain in the scrotum without traction.

Figure 53.1

The patient is placed supine, with legs slightly apart, under full general anaesthesia (day surgery). Skin preparation includes from the umbilicus to below the scrotum. For congenital cryptorchidism a standard inguinal operation is preferred. A transverse skin crease incision is made over the inguinal canal (one finger breadth above pubic tubercle) from level with the tubercle to the mid inguinal point.

The incision is deepened through fat to expose the white fibrous layer of the superficial fascia (of Scar-

pa), which is opened formally (diathermy or scissors). The superficial inferior epigastric vein is swept aside or coagulated and divided formally.

Beneath Scarpa's fascia the external oblique muscle is distinguished by the oblique orientation of its fibres. Square retractors under Scarpa's fascia reveal the lower edge of the muscle and the inguinal ligament: sweeping movements with the closed scissors are effective to reveal the spermatic cord where it emerges from the external inguinal ring.

Figure 53.2

The inguinal canal is opened either with a scalpel incision in external oblique aponeurosis parallel to the inguinal ligament, or by opening the external inguinal ring with scissors and slitting the aponeurosis laterally. Small artery forceps on the edges of external

oblique control them and allow easy identification at the end of the procedure. The ilioinguinal nerve is identified on the surface of the cremaster fascia and avoided.

Figure 53.1

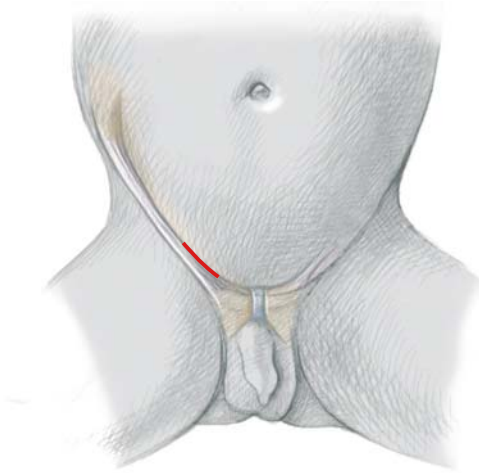


Figure 53.2

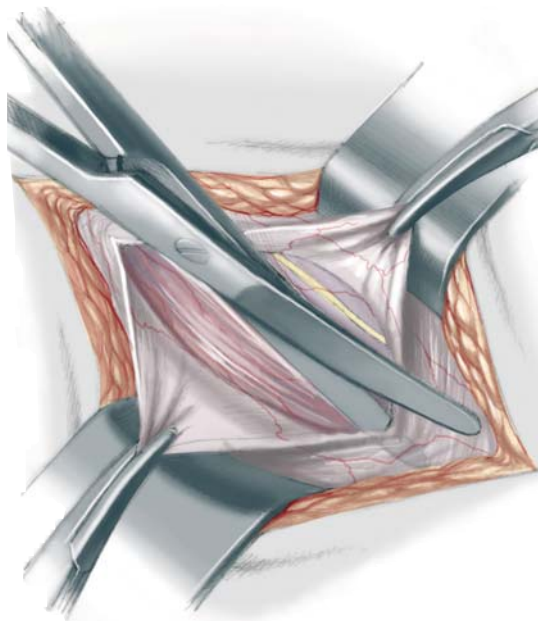


Figure 53.3

The spermatic cord is separated from the external oblique aponeurosis and the cord and testis (usually just outside the external ring) are mobilized out of the wound by blunt dissection. The distal gubernacular attachment is divided carefully (diathermy or scissors), avoiding any long-looping vas deferens. A

small clamp on the gubernaculum or distal tunica vaginalis allows traction on the spermatic cord. The spermatic cord is dissected by first isolating and stripping off with blunt forceps any cremaster muscle fibres. Occasionally the cremasteric artery (deep to the cord) needs diathermy.

Figure 53.4

The remnant of the processus vaginalis is usually obvious in cryptorchidism as a shiny white, translucent inelastic layer covering the vas deferens and testicular vessels. The hernial sac is grasped with blunt forceps and the vas and vessels are carefully swept off its posterior surface *en masse*. The vas deferens must be

identified formally during this dissection, as it is closely adherent to the posterior surface of peritoneum. The vas deferens and gonadal vessels are retracted away from the sac, which then can be clamped and divided.

Figure 53.3

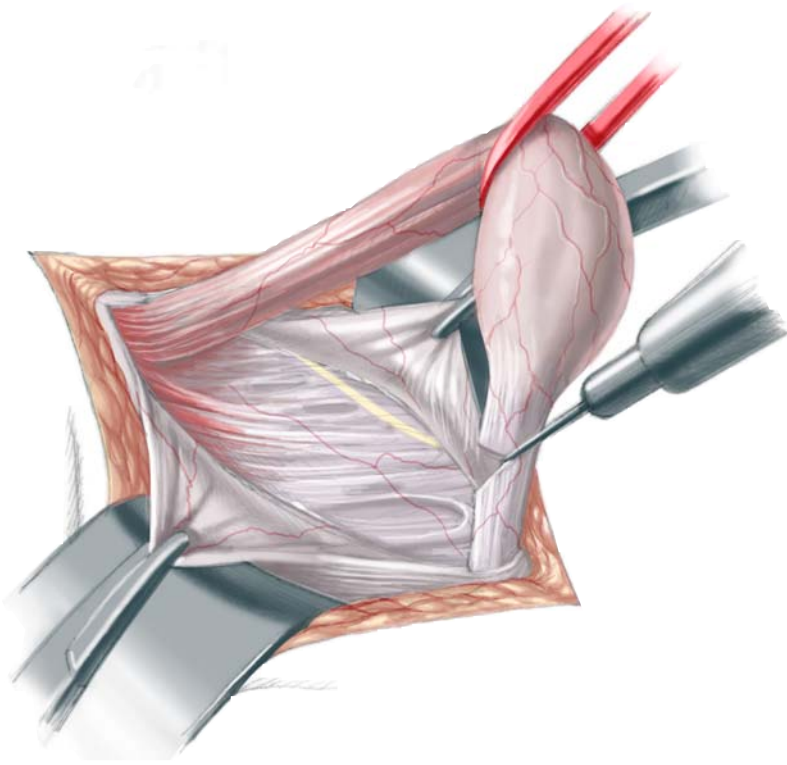


Figure 53.4

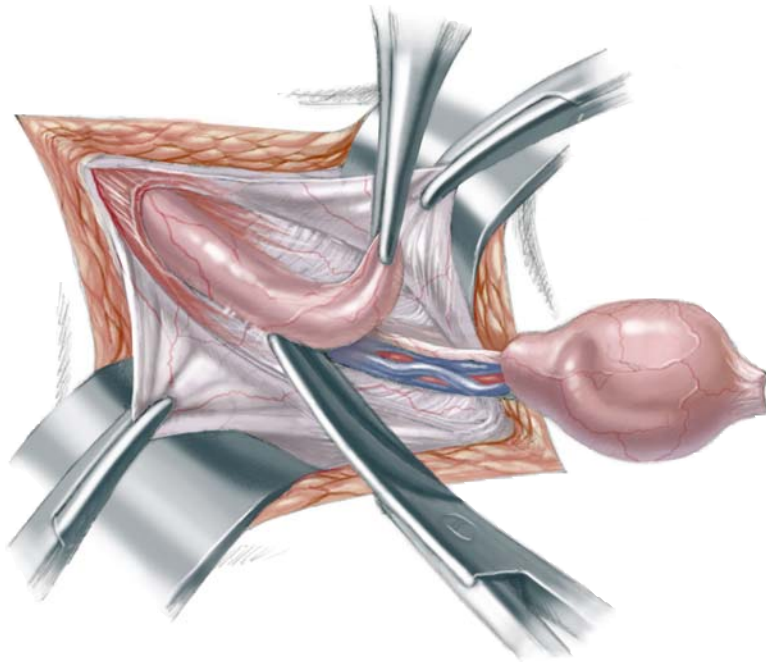


Figure 53.5

The hernial sac is pulled cranially, allowing the vas deferens and vessels to be separated bluntly from the posterior surface right up to the internal inguinal ring. At this point the vas and vessels begin to diverge and the peritoneum becomes more opaque.

Figure 53.5

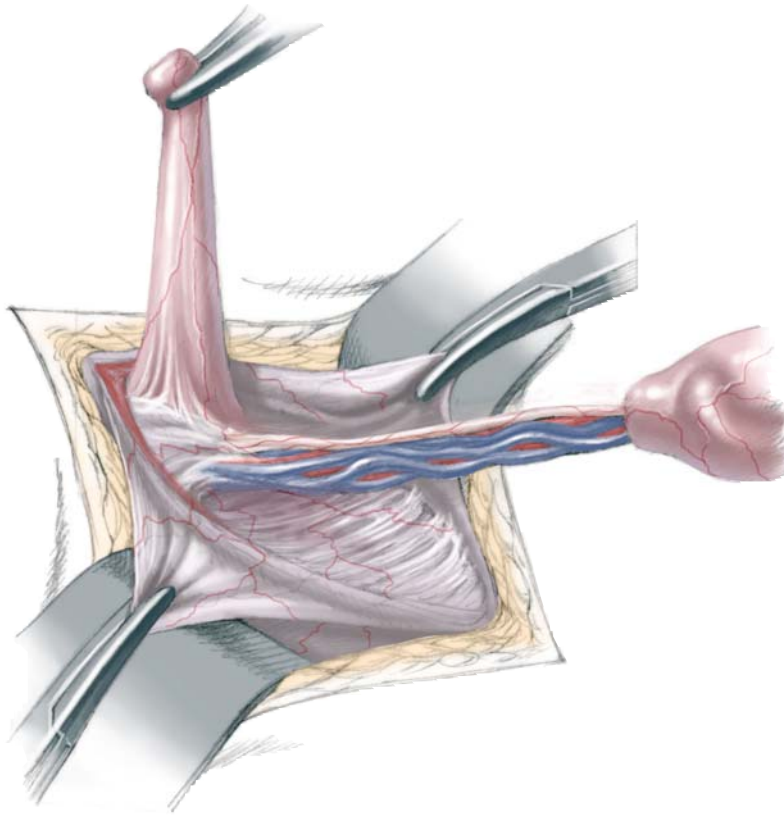


Figure 53.6

The vas deferens hooks medially around the edge of the transversalis fascia and adjacent inferior epigastric vessels, whereas the spermatic vessels pass laterally and cranially into the retroperitoneal space. A small Langenbeck retractor is placed behind the peritoneum and the retroperitoneal space is opened with blunt dissection. Any lateral fibrous attachments to the vessels are identified by traction and then divided. This should provide adequate length to allow the testis to reach the scrotum. If there is inadequate

length of the vas deferens, the inferior epigastric vessels can be isolated and a hole made in the posterior wall of the inguinal canal medial to the vessels. Once the vas deferens has been mobilized carefully, the testis is redirected medial to the vessels: further traction on the testis will identify any remaining fibrous strands that need division. The processus vaginalis is twisted to exclude intraperitoneal contents and transfixed and ligated with absorbable suture.

Figure 53.6

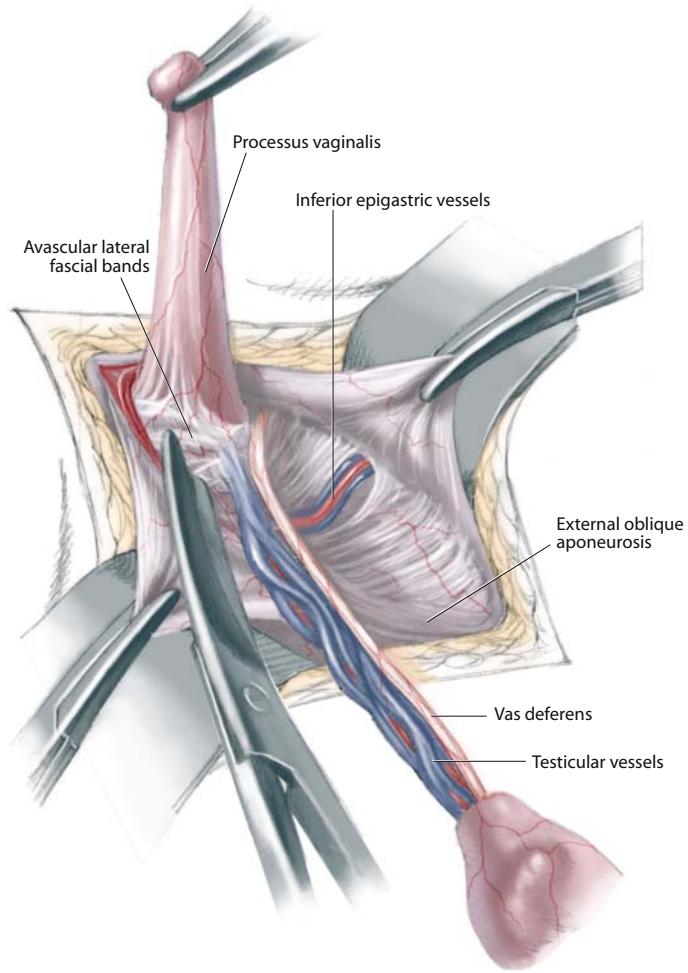


Figure 53.7, 53.8

A finger is introduced through the wound and bluntly pushed down to the scrotum. The scrotal skin is immobilized between the internal finger and the thumb and then a skin incision is made (either horizontal or vertical in the midline). A subcutaneous

pouch is developed with scissors or small artery forceps with the finger still in place. Bleeding is managed by meticulous diathermy to avoid subsequent scrotal haematoma.

Figure 53.9

A small artery forceps is passed into the pouch and pressed against the deep fascia stretched over the finger tip, which then guides the forceps back out through the inguinal incision.

The gubernaculum or tunica vaginalis is grasped by the forceps and the testis is gently drawn down to the scrotum and out through the lower incision. At this point the tunica can be opened and everted and

any testicular appendages are excised. The testis can be held in the scrotal pouch by a small suture through the lower septum and the tunica albuginea. Alternatively, the neck of the scrotum can be tightened with a suture around the spermatic cord. Sometimes the button-hole in the tissues at the neck of the scrotum is small enough to hold the testis without any suture.

Figure 53.7

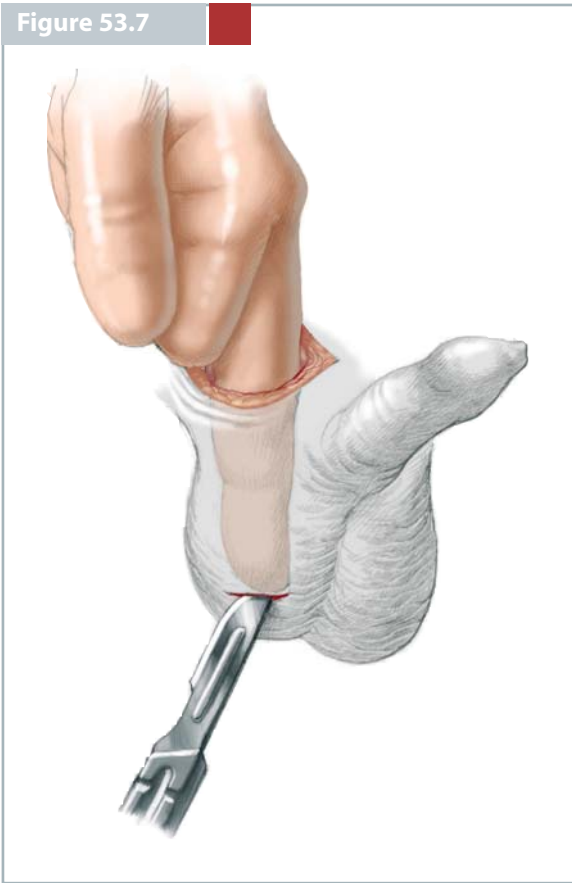

Figure 53.8

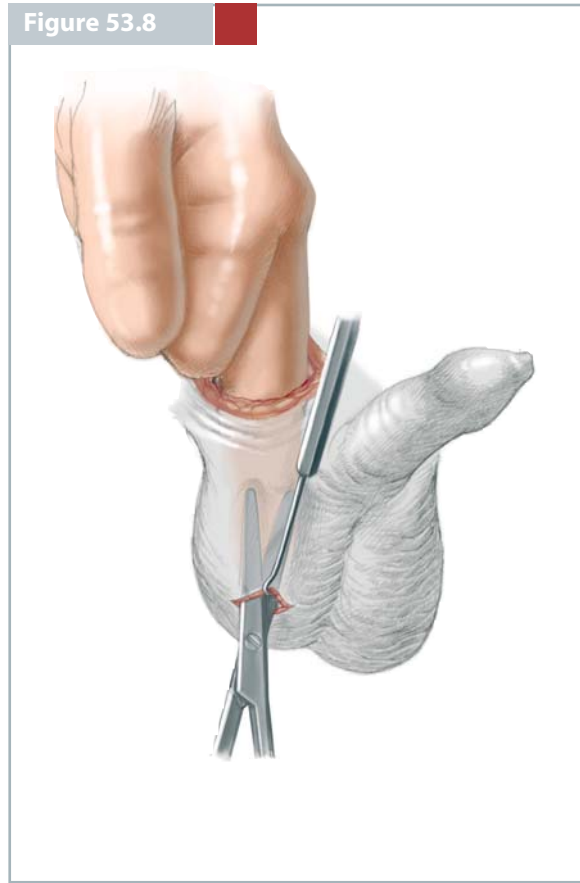

Figure 53.9

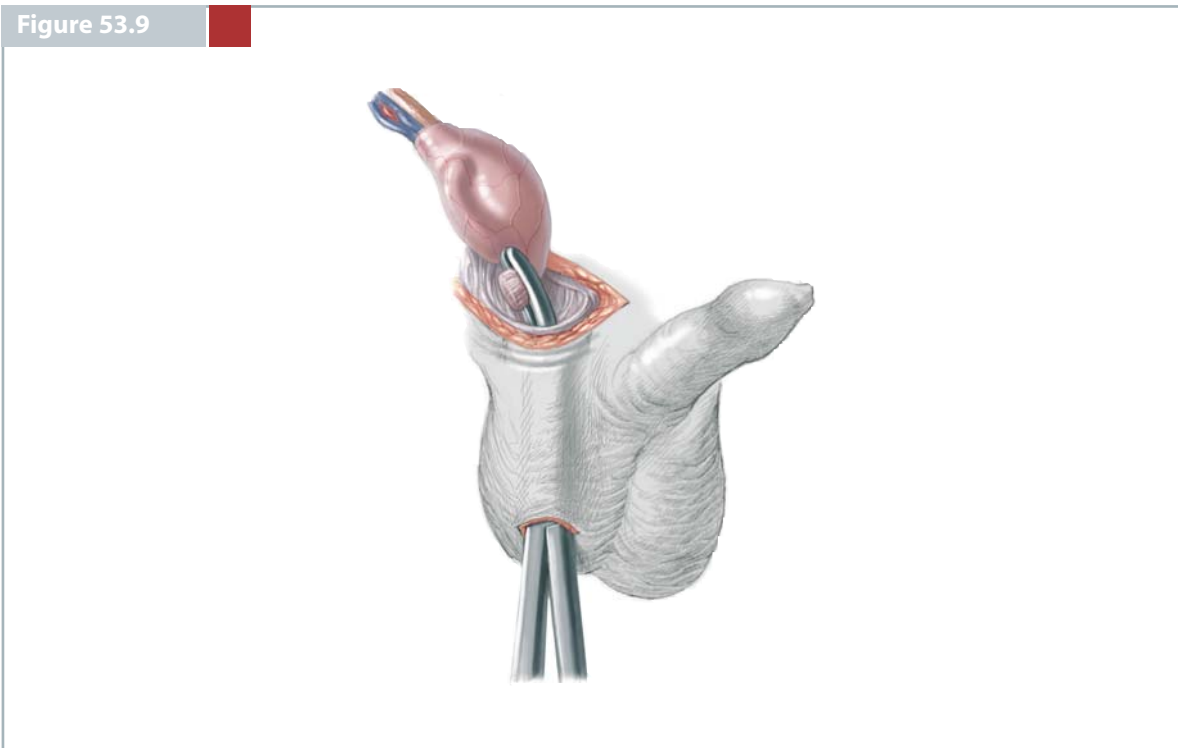


Figure 53.10

The testis is nestled into its new subcutaneous pouch and the scrotum closed with subcuticular suture. The inguinal incision is closed with a running suture in the external oblique aponeurosis (the artery forceps

placed on the edges at the start make identification easy). Scarpa's fascia is closed with one or two sutures and the skin closed with subcuticular suture. A waterproof dressing is applied to both wounds.

Figure 53.11

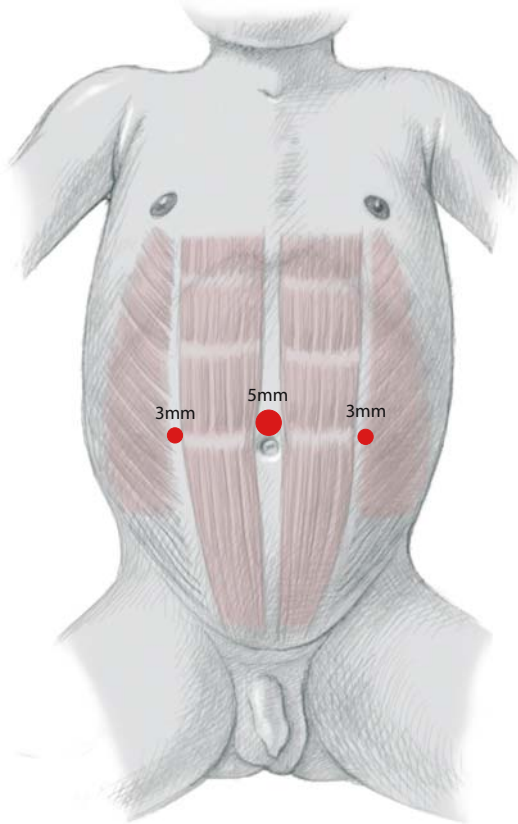
Diagnostic laparoscopy is the first step in the management of a nonpalpable testis. The three likely findings at laparoscopy are:

- Blind ending vas and vessels (vanishing testis): viable testicular remnants have been noted in 6% to 20% of vanishing testes. It has been suggested that inguinal exploration should be carried out in these patients to remove testicular "nubbins" to prevent future risk of malignancy. Contralateral fixation orchidopexy may be indicated.
- Cord structures entering the internal ring: inguinal exploration is carried out, and if a viable testis is found the testis is relocated to the scrotum. If remnant "nubbin" is found it is excised in toto to remove the nidus of germ cells to prevent the occurrence of malignancy later.
- A viable intra-abdominal testis: the limiting factor to relocate the intra-abdominal testis to the scrotum is the length of the gonadal vessels. Testis is supplied by three arteries – the main testicular, the vassal and the cremasteric arteries. The decision to perform Fowler-Stephens or one of its modifications must be made before any extensive inguinal exploration that disrupts the collaterals. The viable intra-abdominal testis is treated by laparoscopic clip ligation of the main spermatic vessels and by orchidopexy based upon vassal vessels and the collateral is performed at a later stage.

Figure 53.10

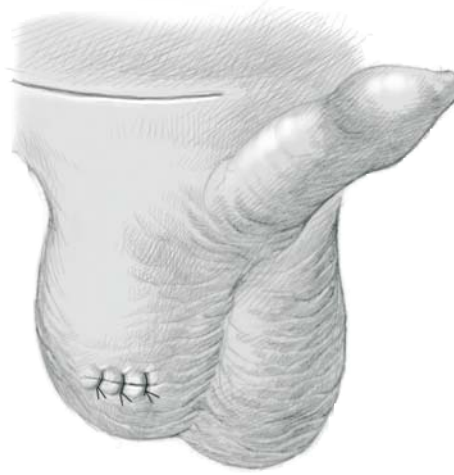

Figure 53.11



CONCLUSION

Post-operative recovery from all orchidopexy procedures is rapid, with return to full activity within a few days. Sports may need to be restricted for 1–2 weeks and the boy is reviewed again at 6–12 months to ensure atrophy has not occurred. Boys with primary maldescent (especially bilateral) and those with impalpable testes would be advised to return at 14 years of age for review of pubertal development and discussion about prognosis for cancer and fertility.

Complications that are most frequent are wound infection or haematoma, both of which can be avoided by meticulous haemostasis at operation and leaving the waterproof dressing in place for at least a week. The risk of testicular atrophy should be less than 5% and in most series it is 1–2%. Depending on the method used to fix the testis in the scrotum, there

is a small risk of retraction of the testis back into the groin, requiring secondary orchidopexy.

The estimated risk of testicular cancer (between 15 and 40 years) is approximately 5–10 times higher than in a normal testis, although most pediatric surgeons anticipate the orchidopexy in early infancy (<1 year of age) may avoid this.

The estimated risk of infertility is about 30% for bilateral undescended testes and lower (but not normal) for unilateral cases. Whether these risks will disappear with early surgery remains unknown at this time. Because epididymal anomalies are commonly associated with cryptorchidism, it is likely that a small number of boys may be infertile subsequently because of epididymal-testicular dissociation, even if germ cell maturation is normal.

SELECTED BIBLIOGRAPHY

- Baker LA, Siklva RI, Docimo STG (2001) Cryptorchism. In: Gearhart JP, Rink RC, Mouriquand PDE (eds) *Pediatric Urology*. WB Saunders, Philadelphia, pp 738–753
- Hutson JM (1995) Orchidopexy. In: Spitz L, Coran AG (eds) *Pediatric surgery*. Chapman & Hall, London, pp 717–725
- Hutson JM, Beasley SW (1992) Descent of the testis. Arnold, London
- Puri P (2003) Cryptorchism. In: Ziegler MM, Azizkhan RG, Weber TR (eds) *Operative pediatric surgery*. McGraw-Hill, New York, pp 555–562
- Smith EA, Woodard JR (2002) Standard orchidopexy techniques and microvascular orchidopexy. In: Frank JD, Gearhart JP, Snyder HM III (eds) *Operative pediatric urology*. Churchill-Livingstone, London, pp 257–272

INTRODUCTION

Testicular varicocele is characterized by variceal dilatation of the veins in the pampiniform venous plexus secondary to incompetent valves in the testicular vein. Varicoceles are almost always localized on the left side. This is supposedly related to the fact that the left testicular vein drains via the left renal vein, which offers higher resistance to the bloodstream than the right testicular vein, which enters vena cava directly. The age group most frequently affected are older boys and adolescents. Symptoms are rare. Sometimes, an ill-defined discomfort in the way of a dragging sensation in the scrotum is reported.

On physical examination, *grade III varices* may be seen through the scrotal skin. The characteristic soft nodular mass, which is described as feeling like “a bag of worms”, is as well palpable, but not visible in *grade II varicoceles*. It becomes more prominent with increased venous filling due to gravity (in erect position) or to venous outflow obstruction by an intra-abdominal pressure surge. This can be provoked by a Valsalva manoeuvre, which is necessary to render a *grade I varicocele* obvious. In contrast, in the supine patient, in particular in a Trendelenburg position, the veins empty, and the varicocele can neither be seen nor felt any more.

Clinical relevance derives from the fact that varicoceles can result in testicular atrophy and infertility.

The pathophysiological mechanism has not been elucidated yet. Production of antibodies in reaction to increased temperature within the scrotum, or to a leak in the blood-testis barrier has been suggested to explain to result in bilateral damage. Semen analysis in 30–50% of the affected men show abnormalities that may improve significantly after resolution of scrotal venous hypertension provided that the treatment is not delayed until damage has become irreversible. Therapy of varicoceles is therefore indicated in children and adolescents to prevent the above damage.

Different surgical methods are available, the most popular of which have been described by Palomo and Ivanissevich. The former consists in high mass ligation with or without resection of 3 cm of the testicular veins and artery. This can be done by an open surgical retroperitoneal approach via an incision in the left iliac fossa or by transperitoneal laparoscopy. Ivanissevich popularized dissection and ligation of two-thirds of the veins of the pampiniformis plexus via an inguinal exploration. We prefer the minimal-invasive method described by Tauber as described below, which is simple and equally effective, and can be performed under local anaesthesia in most patients.

Figure 54.1

The patient is positioned supine on the operating table. The region from the left external inguinal ring to the upper third of the scrotum is shaved. After adequate regional infiltration anaesthesia, a 3-cm longitudinal incision is made in the direction of the spermatic cord in the uppermost part of the scrotum.

Figure 54.2–54.4

The subcutaneous tissue is divided and the outer fascia of the cord opened longitudinally. With fine forceps and a right-angled clamp, one major vein is isolated from the pampiniform plexus over a distance of about 1.5 cm. The vein is ligated distally; a second suture is pulled around it proximally. The vein is then cannulated with an 18-gauge needle in cephalad direction. If saline can be injected without problems, the proximal thread is held just firmly enough to maintain the cannula in the vein.

Figure 54.1

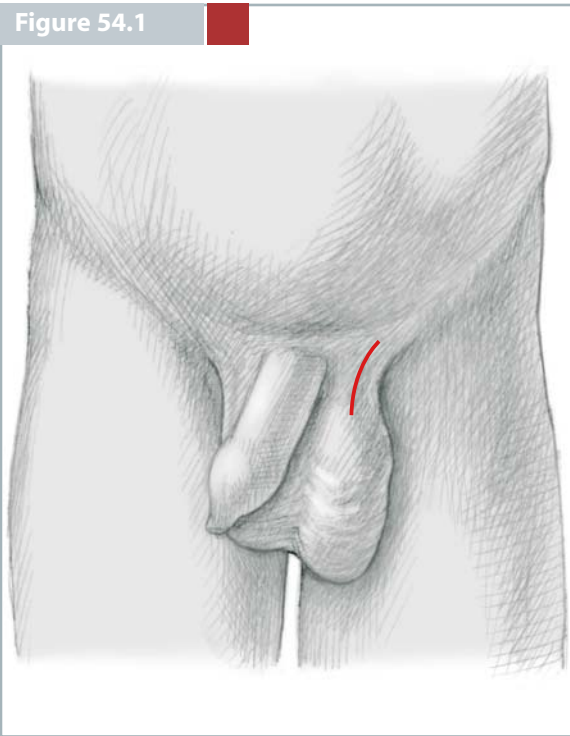


Figure 54.2

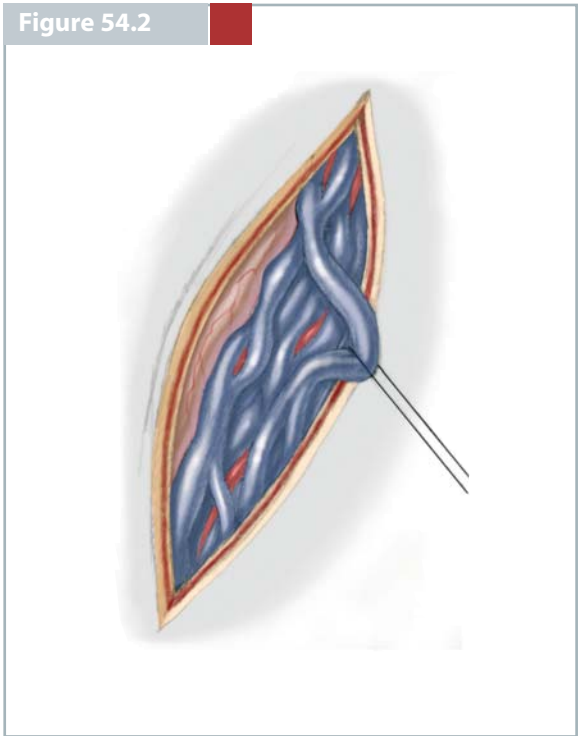


Figure 54.3

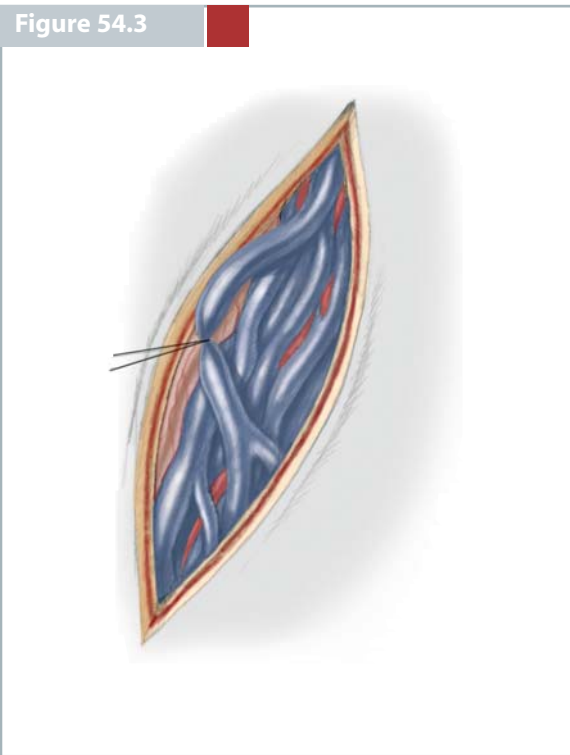


Figure 54.4

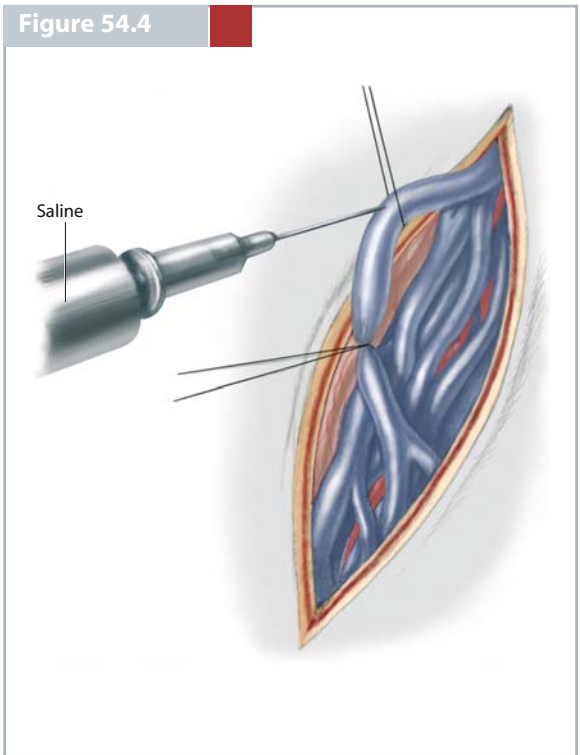


Figure 54.5, 54.6

Diluted contrast medium is injected under fluoroscopic control to ascertain that the cannulated vein drains into the left renal vein via the testicular vein without aberrant flow into pelvic veins. If pelvic collaterals are outlined, the needle must be removed and the vein ligated. Then another vein is punctured and tested for flow exclusively towards the renal vein in the same way. Once an appropriate vein has been found, 3 ml of a sclerosing agent (e.g., ethoxysclerol 1–3%) and 2 ml air are aspirated into a 5-ml syringe.

While the anaesthetist increases the inspiratory pressure simulating a Valsalva manoeuvre, the surgeon injects 1 ml air, followed by the whole amount of the sclerosing material, and then the remaining 1 ml air. The Valsalva manoeuvre is continued for approximately 30 s.

Subsequently, the needle is removed and the plexus vein is ligated proximal to the access site. The incision is closed with absorbable subcutaneous 5/0 and subcuticular 6/0 sutures.

Figure 54.7

The high retroperitoneal ligature of the testicular vein or veins was introduced by Palomo. The procedure was originally performed by a left lower quadrant extraperitoneal laparotomy (McBurney on the left side). When the peritoneum is reached, it is gently pushed away so that the left retroperitoneal space can be reached. The testicular vessels are identified and the vein (or two or three veins) is ligated and resected over a distance of 2–3 cm. Sometimes it appears difficult to identify or to separate the vein from

the artery. Therefore, some authors prefer to ligate all vessels including the artery.

Recently, the laparoscopic minimal invasive procedure is the preferred method of choice. The surgeon stands on the right side of the patient. A 5-mm laparoscope for the optic is inserted through the umbilicus. Two other instruments (2-mm or 5-mm) are inserted, one lateral to the left rectus muscle margin, the other above the bladder.

Figure 54.5

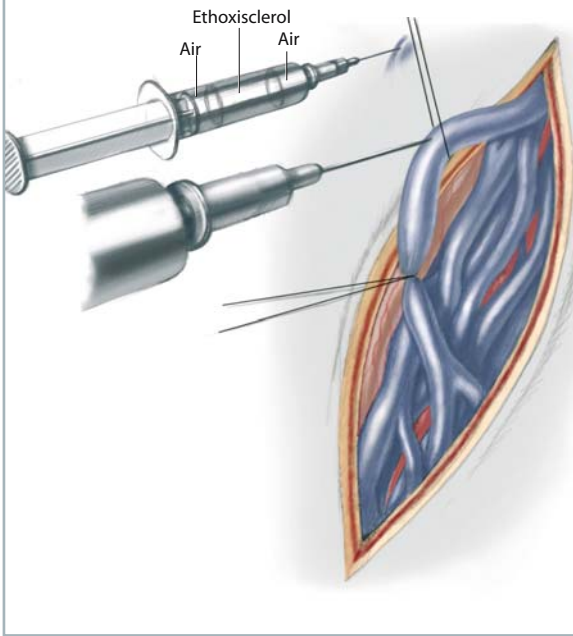


Figure 54.6




Figure 54.7

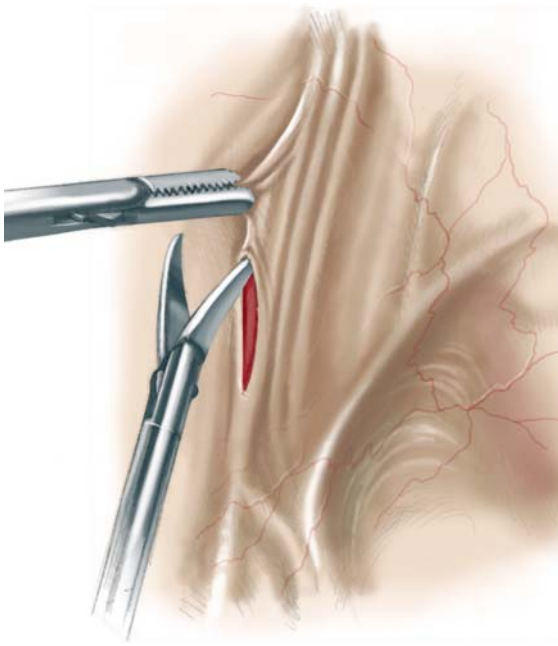


Figure 54.8a–c

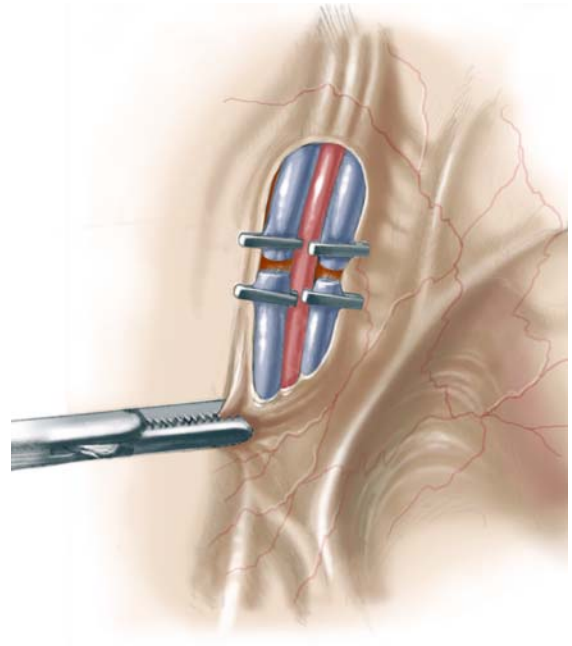
Adhesions to the sigmoid colon can be transected. The peritoneal reflection over the vessels is incised, the veins are identified and transected between clips. Electrocautery should not be used because underlying

nerve fibres may be damaged leading to dysaesthesia at the left thigh. If bleeding occurs while separating the veins, the only option is to ligate all vessels without sparing the artery.

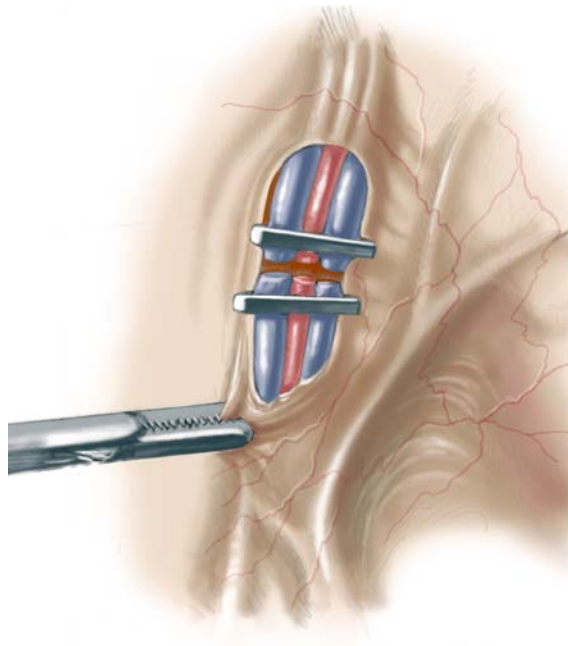
Figure 54.8a-c



a



b



c

CONCLUSION

Long-term follow-up studies of treated varicoceles have shown a small but almost invariable recurrence rate. With the Palomo technique, performed either open or by laparoscopy, the recurrence rate is between 5 and 16%. It is significantly lower when the testicular artery is ligated together with the vein, but the development of a post-operative hydrocele oc-

curs more often when the artery is ligated. Tauber's antegrade sclerotherapy is an effective and also minimal invasive method, that is even easier and faster to perform as the laparoscopic procedure. The recurrence rate after 1 year is, in our hands, 6% but repeated sclerotherapy can easily be performed, and the testicular artery is spared.

SELECTED BIBLIOGRAPHY

- Ficarra V, Porcaro AB, Righetti R, Cerruto MA, Pilloni S, Cavalieri S, Malossini G, Artibani W (2002) Antegrade sclerotherapy in the treatment of varicocele: a prospective study. *BJU Int* 89: 264–268
- Hadziselimovic F, Herzog B, Liebundgut B, Jenny P, Buser M (1989) Testicular and vascular changes in children and adults with varicocele. *J Urol* 142: 583–585
- Niedzielsky J, Paduch D (2001) Recurrence of varicocele after high retroperitoneal repair. *J Urol* 165: 937–949
- Schier F (2003) Varicocele. In: Schier F (ed) *Laparoscopy in children*. Springer, Berlin Heidelberg New York, pp 124–128
- Tauber R, Johnsen N (1994) Antegrade scrotal sclerotherapy for the treatment of varicocele: technique and late results. *J Urol* 151: 386–390

Genitoplasty for Congenital Adrenal Hyperplasia

Amicur Farkas

INTRODUCTION

Surgical management of the neonate with sexual ambiguity presents one of the most enigmatic and true emergencies in pediatric urology. This pathology requires a team approach by the neonatologist, pediatric endocrinologist, psychiatrist and urologist. It is mandatory to identify the genetic sex and the biochemical abnormality quickly, and then to schedule the timing and the type of surgical reconstruction. Surgical management of patients with intersex conditions is aimed to achieve near-normal appearance of the genitalia with good function enabling sexual relations.

Female pseudo-hermaphroditism due to congenital adrenal hyperplasia (CAH) is the most common cause of ambiguous genitalia in newborns. This condition is inherited as an autosomal recessive disorder and is associated in 75% of patients with a life-threatening salt-losing metabolic condition. Exposure of the 46XX female fetus to adrenal androgens results in varying degrees of virilization of the external genitalia and the distal vagina, although Müllerian precursors of the internal genitalia, fallopian tubes, uterus and proximal vagina develop normally in the absence of Müllerian inhibiting substance. The prognosis of these patients when reconstructed surgically and raised as females is excellent for puberty development, attainment of normal female characteristics, sexual activity and reproductive capability. Successful reconstruction depends on accurate pre-operative recognition of the anatomy while the main interest is the location of the vaginal opening into the urogenital sinus and its relations to the pelvic floor and the external sphincter mechanism. That can be achieved by ultrasound, voiding cystourethrography (VCUG), computed tomography (CT) or magnetic resonance imaging (MRI) and panendoscopy. The most common anatomical finding is that caused by the 21-hydroxylase deficiency mainly with moderate to severe virilization of the clitoris with the vaginal opening at the “veru montanum” or just below it.

Feminizing genitoplasty should achieve five main goals: (1) provide an adequate opening for the vagina into the perineum, (2) create a normal-looking, wet introitus, (3) fully separate the vagina from the urinary tract, (4) remove the phallic erectile tissue while preserving the glans with its innervation, sensation and blood supply, and (5) avoid urinary tract complications such as infection or incontinence. To fulfill the above-mentioned requirements, we have to deal

with two main problems: with the enlarged clitoris and with the vagina. This surgical challenge may be approached either separately or as a one-stage procedure. In recent years several techniques of one-stage feminizing genitoplasty have been described [1]. Our technique and experience is based on the principle of the vaginal pull-through, by the complete en bloc mobilization of the urogenital sinus via the perineum, reduction clitoroplasty and reconstruction of the introitus utilizing the mucosal redundant urogenital sinus with the phallic skin.

The issue of timing of the genital reconstruction in any intersex situation is a subject of great debate. Psychiatrists and medical ethicists have raised the issue of irreversible damage caused by early gender assignment by parents and doctors before the child reaches gender identity. Fortunately, this debate has very little relevance to our decision in the cases of the 46XX karyotype CAH, since these patients have female gender identity. Until recently, nearly all surgeons recommended that girls with CAH, especially those with high vaginal communication to the urogenital sinus, should undergo the repair in two stages: firstly clitoral reduction performed early in life in order to avoid familial and environmental anxiety, and then vaginoplasty postponed to an older age, in order to avoid vaginal stenosis. This complication of vaginal stenosis can be solved by the techniques described by Passerini-Glazel, Gonzales, Rink and Farkas, since the phallic, preputial skin and urogenital sinus are used instead of a perineal and other skin flaps. Therefore, the early one-stage operation has the major advantage of using the redundant phallic and preputial skin for reconstruction, especially in those girls who are maximally virilized. This excellent material is discarded and wasted if the clitoral surgery is performed as a separate operation. De Jong and Boemers (1995) advocate one-stage operation as early as neonate. The prenatal hyperstimulation by the maternal and placental estrogens that persists into the first 3–4 weeks of life produces vaginal enlargement by mucosal secretions and vaginal wall hypertrophy, facilitating an easier vaginal pull-through. At present, we prefer to perform the one-stage procedure as described below at the age of 3–4 months.

The preoperative management consists of complete bowel preparation, adequate steroids supplement and biochemical stabilization.

Figure 55.1

The initial and integral first step of the operation is panendoscopy. A 10-Fr pediatric cystoscope is used. The bladder is inspected and the communication of the vagina to the urogenital sinus is located. Once the opening is identified, it is almost always possible to pass the scope into the vaginal cavity. At that point the telescope is removed from the sheath and a 6F silicone Foley catheter is introduced into the vagina, through the scope sheath. The balloon is inflated to 2–3 cc. The sheath is pulled back and the catheter is

clamped at the distal end of the urogenital sinus to prevent the balloon from deflating. The distal end of the catheter is cut off to enable complete removal of the sheath. The catheter is then re-clamped at its edge. In some cases where there is a narrow vaginal opening, a Fogarty catheter can be used with the scope inserted only as far as the opening and not into the vaginal cavity. A second 8 to 10F catheter is inserted into the bladder in the conventional manner.

Figure 55.2

The patient is placed in an exaggerated lithotomy position with the thighs widely spread to maximally expose the perineum. The operation begins with a circumferential skin incision around the enlarged clitoris and around the urogenital sinus orifice. This incision is extended into two vertical incisions on the dorsal and ventral aspects of the clitoris. The ventral

incision extends distally into a Y-shape to join the circumfering incision just below the glans and terminates proximally in an inverted wide U-shape perineal flap. This flap is extended to the ischium tuberositas bilaterally. These incisions provide an excellent exposure of the phallic structures and the whole perineum with the urogenital sinus.

Figure 55.1

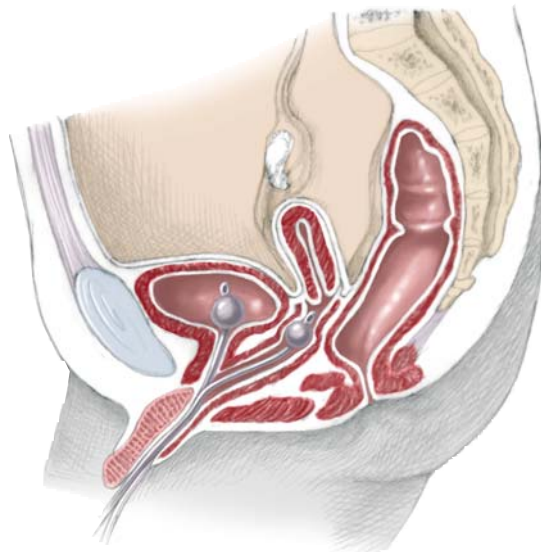


Figure 55.2

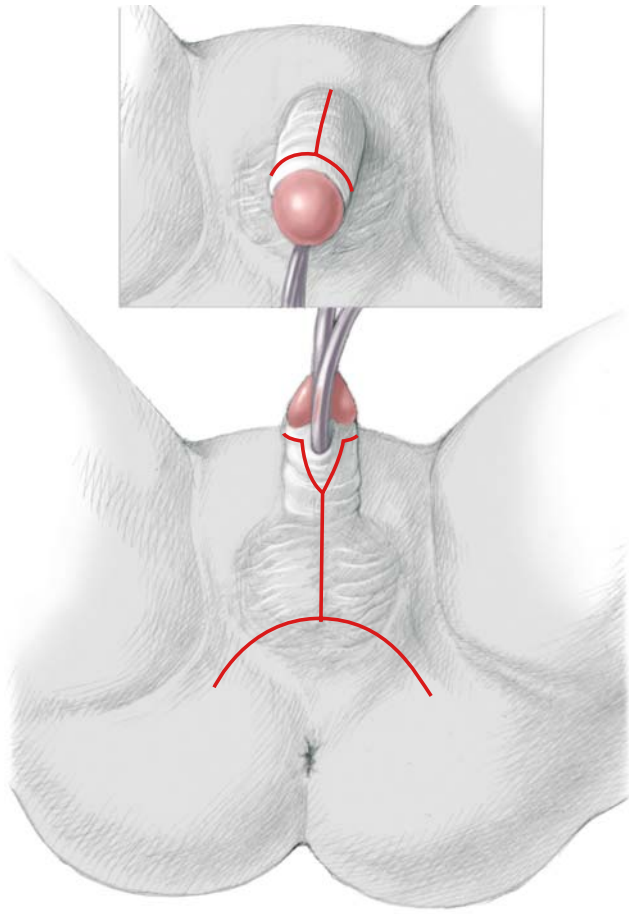


Figure 55.3a,b

The urogenital sinus is dissected from the corporal bodies of the phallus and detached completely. The dissection is continued using electro-coagulation with a needle shaped electrode between the urogenital sinus and the rectum, which is retracted dorsally. The plain of dissection is carried on laterally between the urogenital sinus and the crurae of the corpora cavernosa, and continued below the lower rami of the pubic bones until the whole urogenital si-

nus can be freely mobilized en-block and pulled out. The posterior vaginal wall is then exposed and brought to the perineum without tension. The continuous palpation of the balloon in the vagina enables accurate and safe dissection.

The two muco-cutaneous flaps made out of the phallic and preputial skin are completely dissected off the corpora cavernosa and pulled aside.

Figure 55.4

At this point the clitoroplasty is performed using the technique described by Kogan et al [3]: two suture ligatures are placed at the proximal ends of the previously exposed crurae of the corporal bodies. The incisions in Buck's fascia are at the ventro-lateral aspect of the phallus, in order to preserve the blood supply and the sensitivity of the glans of the clitoris. The Buck's fascia is dissected from the erectile tissue, which is again ligated just below the glans and then the whole erectile tissue is removed.

If the glans appears to be too bulky, it should be reduced by removing tissue centrally and leaving as much lateral tissue as possible, as this area is more sensitive. The glans is reconstructed with 6/0 sutures. Then the glans of the clitoris is placed under the pubic arch and sutured in place with two or three 4/0 absorbable sutures.

Figure 55.3a,b

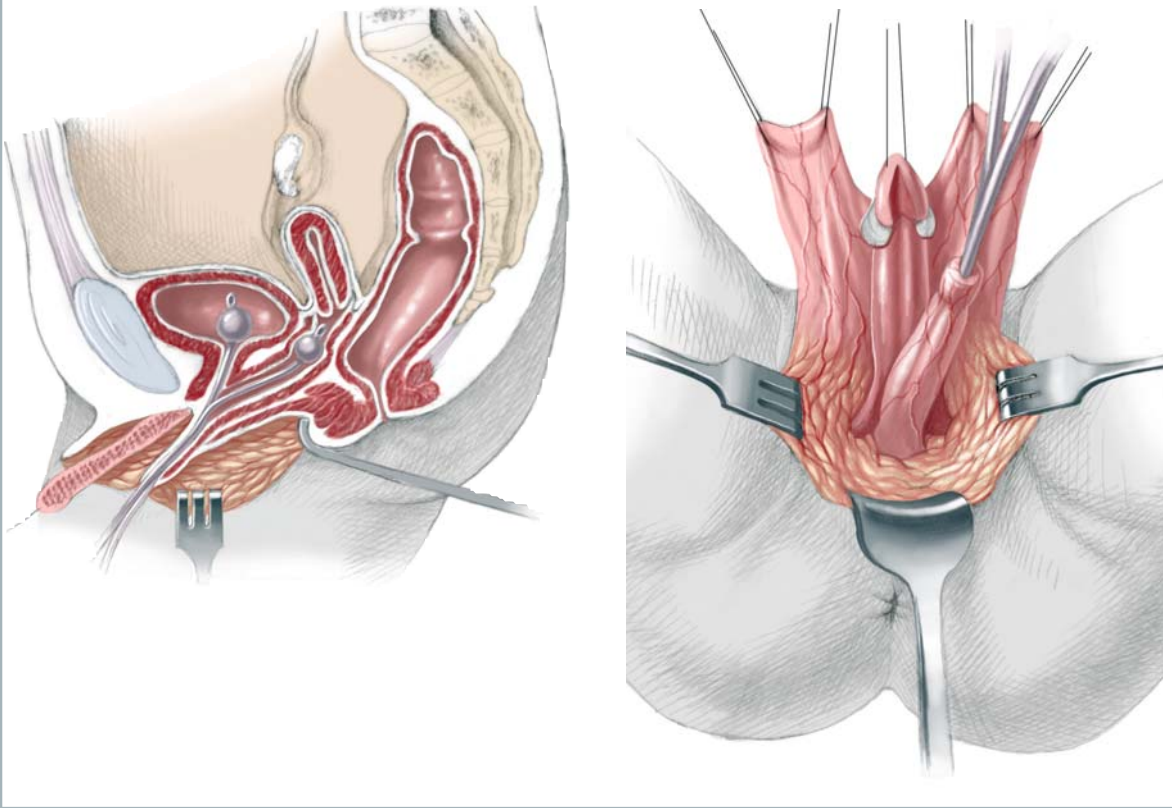


Figure 55.4

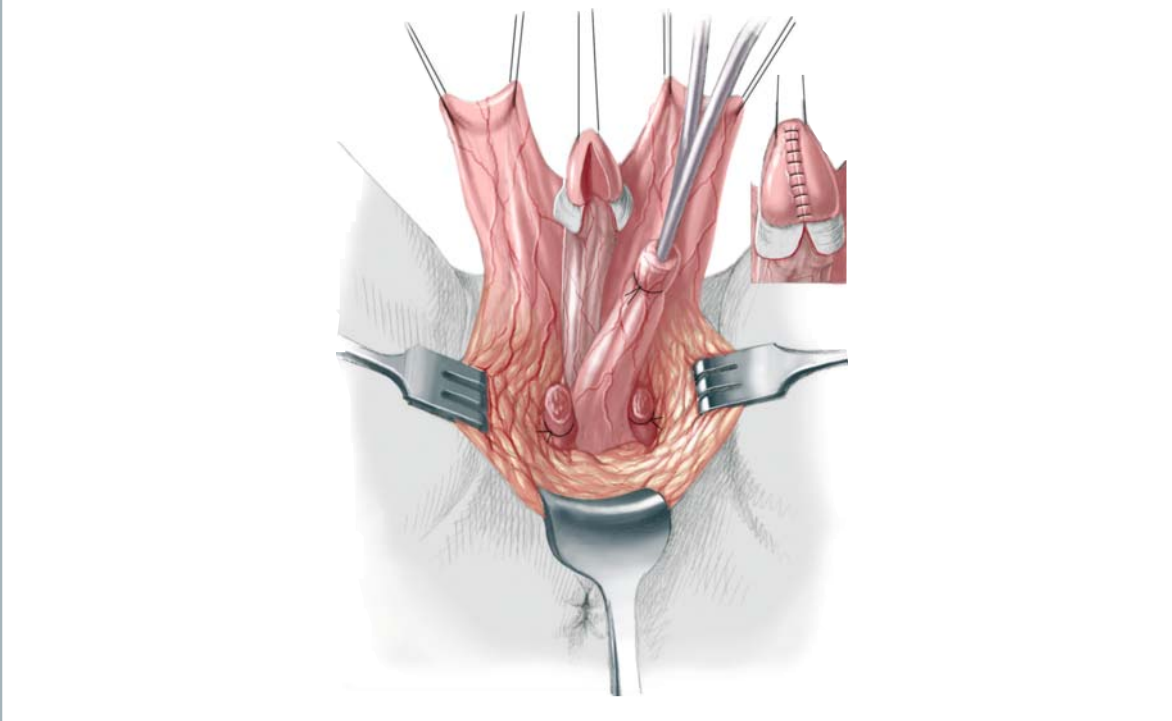


Figure 55.5a,b

The posterior aspect of the urogenital sinus is brought tension-free as close as possible to the perineum. The bulbo-cavernous muscles are divided in the midline and retracted laterally, thus exposing the

posterior vaginal wall. The vaginal wall is widely incised in its posterior aspect over the balloon and between traction and haemostatic sutures.

Figure 55.6

Once the posterior vaginal wall is opened, its communication to the urogenital sinus and the urethra can be seen. This communication is closed by interrupted 5/0 absorbable sutures from inside the vagina. The previously inserted Foley catheter in the bladder is protecting the urethra.

An adequate length of the urogenital sinus is preserved as a tube and sutured just below the clitoral glans to serve as urethra. The redundant part of the urogenital sinus is split in the midline in the dorsal aspect, creating a mucosal plate.

Figure 55.5a,b

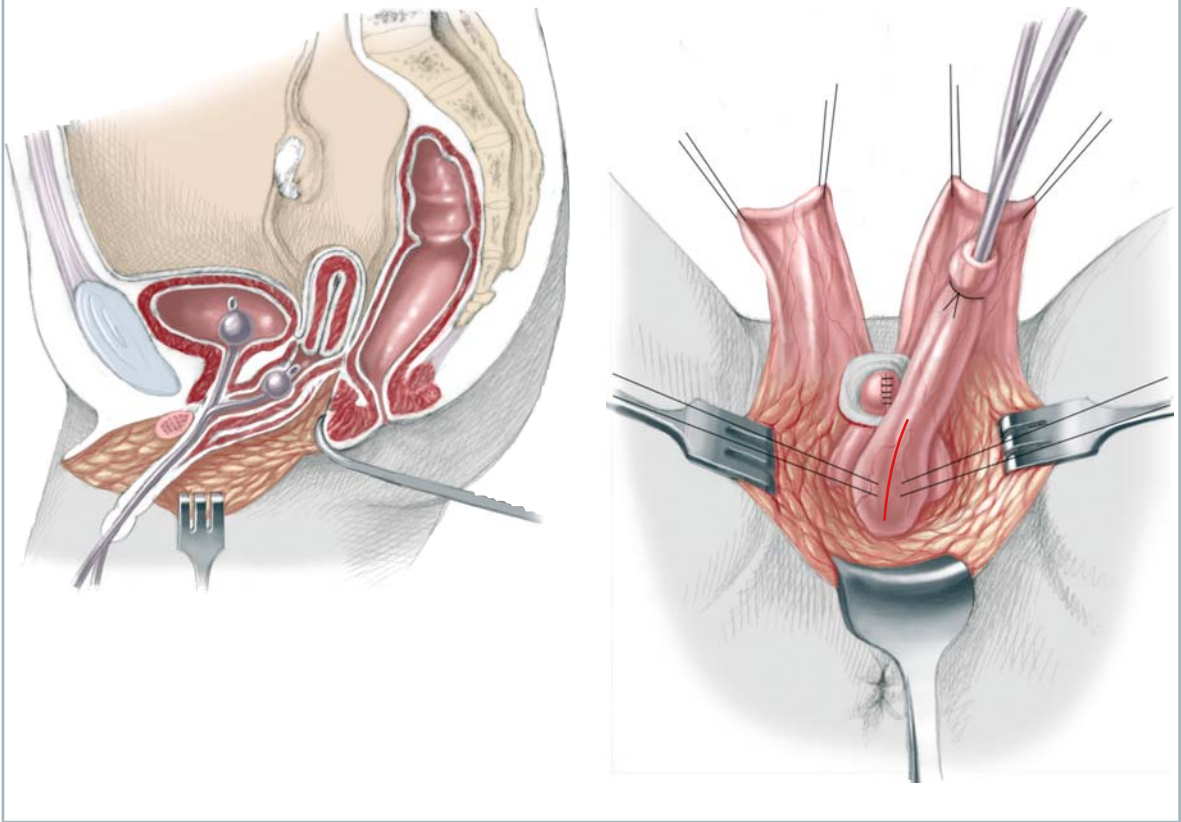


Figure 55.6

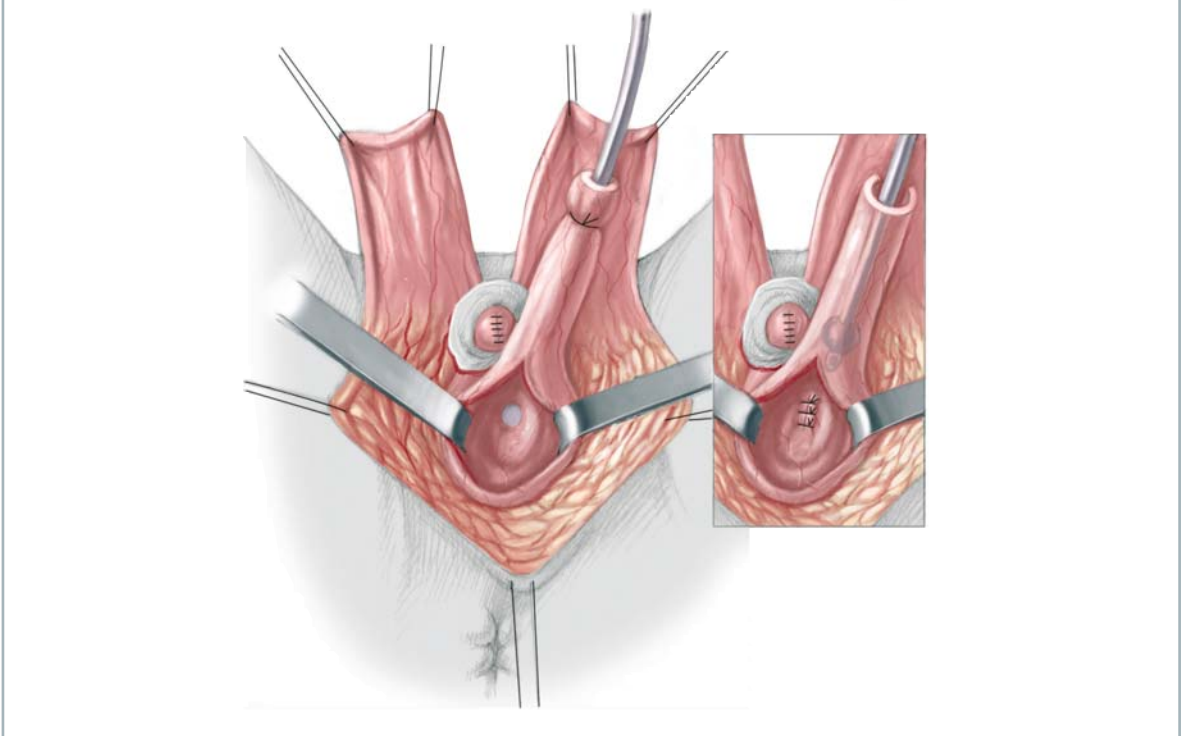


Figure 55.7a, b

The mucosal plate of the dorsally split urogenital sinus is sutured to the two lateral flaps of the phallic and preputial skin previously dissected off the phal-

lus. This will create a wide plate that is mucosal in its centre and its tip, while its lateral parts are made of phallic non-hairy soft and distendable skin.

Figure 55.7a

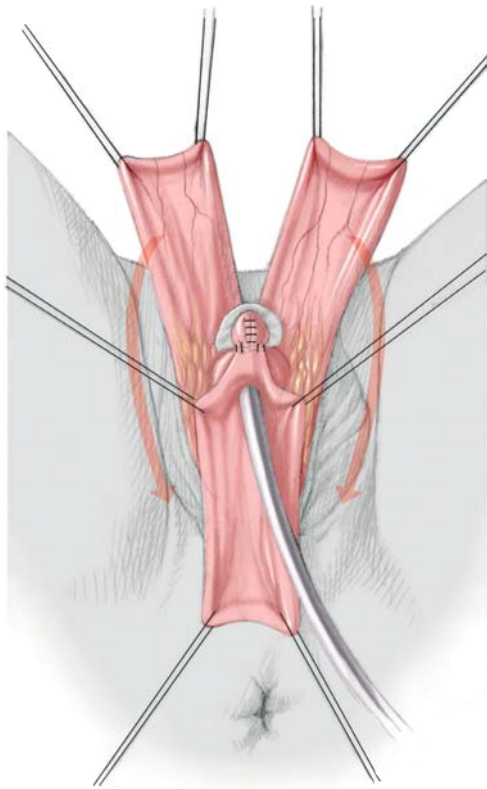


Figure 55.7b

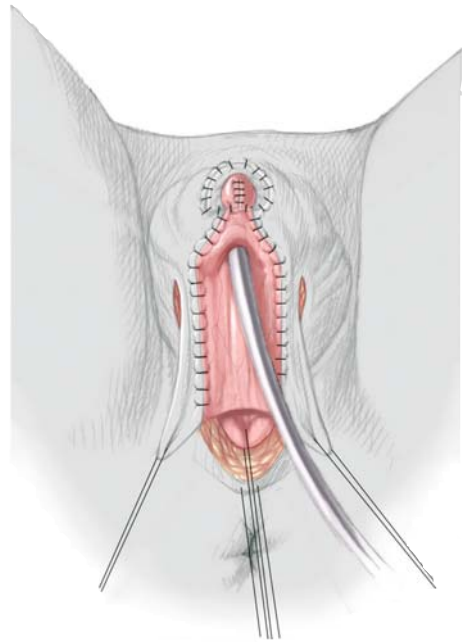


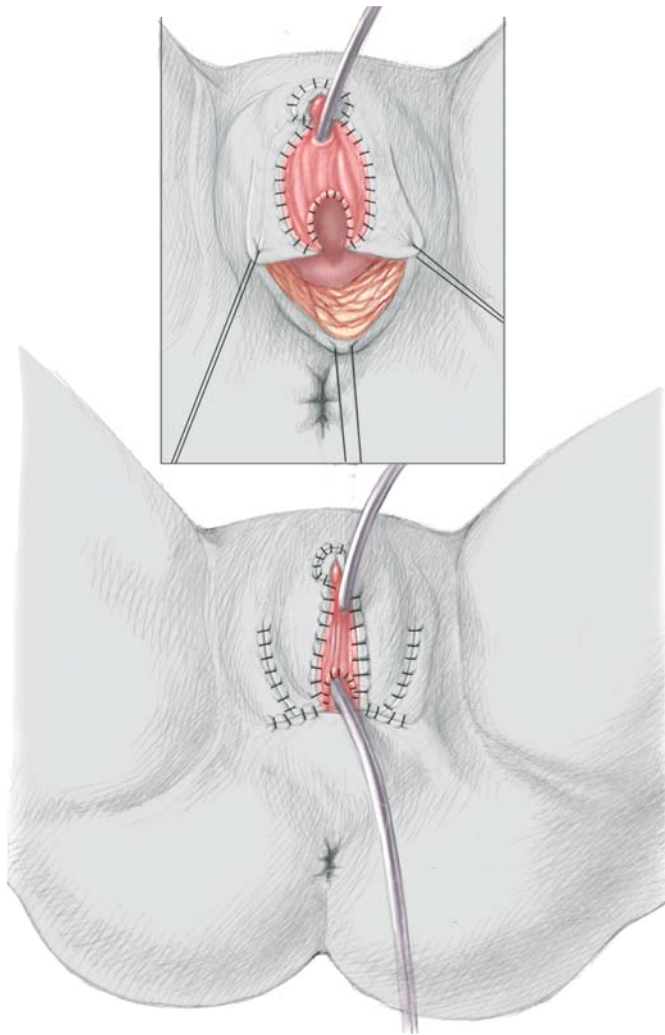
Figure 55.8

The muco-cutaneous plate is turned downwards, its mucosal base is sutured to the ventral vaginal wall and its lateral edges to the lateral vaginal wall, enabling a muco-mucosal anastomosis around almost 300° of the vaginal opening. The tip of the previously prepared inverted U-shaped perineal flap is sutured to the posterior dorsal corner of the vagina. The

phallic skin is sutured circumferentially, creating labia majora and labia minora.

A Xeroform packing is placed in the vagina and the wound is covered with a compression dressing. The compression and the vaginal tampon are removed after 48–72 h. The urethral catheter is left in place for 7 days.

Figure 55.8



CONCLUSION

Since 1991, 67 patients underwent one-stage feminizing genitoplasty using the above described technique. In two cases mild anterior rectal wall laceration was observed during the operation, which was sutured primarily without any further complications. Wound infection in the buttock area occurred in three cases, resulting in a hypertrophic scar in one case. One clitoris was totally lost due to inadequate blood supply. Two cases resulted in repeated clitoromegalia due to inadequate androgen suppression. The cosmetic results are very satisfactory. In the few girls who have already reached puberty, we observed a mucosal wide introitus and no evidence of fibrosis. None of our patients has so far experienced sexual relations and therefore we do not have any information regarding difficulties in intercourse, sexual satisfaction, fertility and the psychological aspects of intersexuality.

It is important to emphasize that the technique described is mainly suitable for the majority of the CAH cases with 21-Hydroxylase deficiency and with vaginal communication to the urogenital sinus at the pelvic floor or just below it (at the veru montanum). In the low vaginal insertion, a simple cutback is adequate or the use of a small perineal flap as described by Fortunoff et al. In the rare cases of very high vaginal insertion above the pelvic floor at the bladder neck, the perineal approach might be insufficient. Passerini-Glazel advocated the use of abdominal trans-vesical approach by dividing the bladder wall trans-trigonally. This technique was originally described by Monfort to reach the prostatic utricle. We believe, however, that in such rare complicated cases the posterior transanorectal approach advocated by Peña is the best choice. This technique is described in Chap. 4 of this volume by the master himself.

SELECTED BIBLIOGRAPHY

1. Farkas A, Chertin B, Hadas-Halpern I (2001) One-stage feminizing genitoplasty: 8 years of experience with 49 cases. *J Urol* 165:2341–2346
2. Fortunoff S, Lattimer JK, Edson M (1964) Vaginoplasty, technique for female pseudohermaphrodites. *Surg Gynecol Obstet* 118:545–547
3. Kogan SJ, Smey, P, Levitt SB (1983) Subtunical total reduction clitoroplasty, a safe modification of existing techniques. *J Urol* 130:746–748
4. Monfort G (1982) Transvesical approach to utricular cysts. *J Pediatr Surg* 17:406–408
5. Passerini-Glazel G (1989) A new one-stage procedure for clitorovaginoplasty in severely masculinized female pseudohermaphrodites. *J Urol* 142:565–568
6. Peña A (1997) Total urogenital sinus mobilization: an easier way to repair cloacas. *J Pediatr Surg* 32:263–268

Bladder Exstrophy and Epispadias

Dominic Frimberger, John P. Gearhart

INTRODUCTION

Bladder exstrophy and epispadias are rare and complex urogenital malformations predominantly occurring in males. The defect can be suspected during routine prenatal ultrasound; however, the definite diagnosis is made after examining the newborn at birth. Classical bladder exstrophy is characterized by an open abdominal wall, bladder and urethra and a wide diastases of the symphysis pubis, caused by a 30% bony deficit of the anterior pubic rami in combination with a 12° and 18° external rotation of the posterior and anterior aspect of the pelvis, respectively. While girls present with a bifid clitoris and a short vagina, there is a 50% shortening of the anterior corpora cavernosa and an upward deviation of the penis in males. Ureteral reflux in various degrees is seen in 100% of cases after closure. A pre-operative ultrasound evaluation of the otherwise usually unaffected upper tracts is mandatory to determine the presence of two normal kidneys. The magnitude of the defect and the complexity of the treatment require the immediate transfer of the affected child to a specialized centre. Only the multidisciplinary care of surgeons, anaesthesiologists, psychologists and nursing staff can guarantee the most favourable outcome for these otherwise healthy children.

Before Hugh Hampton Young performed the first recorded successful primary closure of a female exstrophy patient in 1942, bladder exstrophy was primarily treated by covering the defect with skin flaps. Modern exstrophy closure, based on the pioneering work of Jeffs [3] and Cendron [4], has been significantly modified in the last decade and is considered the standard of treatment today. The primary principles in surgical management are a secure, initial abdominal closure, the reconstruction of a functional and cosmetically satisfactory external genitalia and the achievement of urinary continence while preserving renal function. Although other forms of repair have been promoted, this approach provides the longest follow-up data and most favourable outcome in treating children with this complex malformation. The technique includes early bladder, posterior urethra and abdominal wall closure, usually with pelvic

osteotomy in the newborn period, subsequently followed by an early epispadias repair at 6 months to 1 year of age after local testosterone stimulation. Around age 4 to 5 years, a competent bladder neck is reconstructed along with bilateral ureteral reimplantation, when adequate bladder capacity is reached and the child is ready to participate in a postoperative voiding program.

Achieving urinary continence with a sufficient bladder capacity is strongly dependent on the initial successful bladder and posterior urethral closure. Therefore, in the first step of the reconstruction, the bladder exstrophy is converted into a complete epispadias with incontinence with a balanced posterior outlet resistance that preserves renal function, but stimulates bladder growth. In very selected cases newborn exstrophy closure can be combined with epispadias repair. This approach can also be performed in delayed primary closure and re-operative exstrophy repairs. However, this requires a good urethral plate and reasonable bladder template to be successful. Additionally pelvic osteotomies are performed if the patient is older than 72 h, for a symphyseal diastasis of more than 4 cm or if a tension-free closure cannot be achieved. In those cases, osteotomies are crucial to ensure a tension free approximation of the bladder, posterior urethral and abdominal wall preventing dehiscence or bladder prolaps. Furthermore, it places the urethra deep within the pelvic ring, enhances bladder outlet resistance and finally ensures alignment of the large pelvic floor muscles to support the bladder neck. The operations are performed in general anaesthesia with the patient in a supine position, even for the osteotomies. An epidural line is placed when possible to reduce the intraoperative amount of anaesthetic agents and for postoperative pain control. Care has to be taken to create a latex free environment in the operation room, since many children with bladder exstrophy are prone to latex allergies. Peri-operative broad-spectrum antibiotics are administered and continued throughout the first post-operative week.

■ **Combined Exstrophy and Epispadias Repair.** In very selected cases newborn exstrophy closure can be combined with epispadias repair. However, this approach requires good phallic length, a deep urethral groove and an adequate amount of penile skin. This technique should only be attempted by experienced exstrophy surgeons as the complications can be severe. The best applications of a combined exstrophy and epispadias repair are in the patient undergoing delayed primary or re-operative exstrophy closure. The pre-operative use of intramuscular testosterone in re-operative exstrophy patients will allow for improved vascularity and more penile skin for the reconstruction.

Figure 56.1, 56.2

■ **Combined bilateral transverse innominate and vertical iliac osteotomies.** With the patient in the supine position, the pelvis is exposed from the iliac wings inferiorly to the pectineal tubercle and posteriorly to the sacroiliac joint. The periosteum and sciatic notch are carefully elevated, and a Gigli saw is used to create a transverse innominate osteotomy, exiting anteriorly at a point halfway between the anterosuperior and the anteroinferior spines. In difference to the Salter osteotomy, a more cranial osteotomy is performed to facilitate placement of external fixator pins in the distal segment. To correct the posterior malrotation, the posterior ilium is incised by creating a closing wedge osteotomy vertically and just lateral to the sacroiliac joint. Note the intact proximal posterior iliac cortex, serving as a hinge when the pubic bones are brought together in the midline.

Two fixator pins are placed each, in the inferior segment and the wing of the superior ileum, respectively. After radiographs confirm the correct placement of the pins, the urological part of the procedure is performed. Afterwards, placing a suture between the two pubic rami concludes the pelvic closure. External fixators are applied and the child is placed in light horizontal Buck traction for four weeks to stabilize the pelvis and avoid ureteral and suprapubic tube displacement. In case of recurrence of the symphyseal diastasis, the fixator bars can be used to gradually approximate the pubic bones over several days. Once good callus formation is confirmed on pelvic radiographs around week 6, the pins are removed at the bedside under light sedation.

Figure 56.1

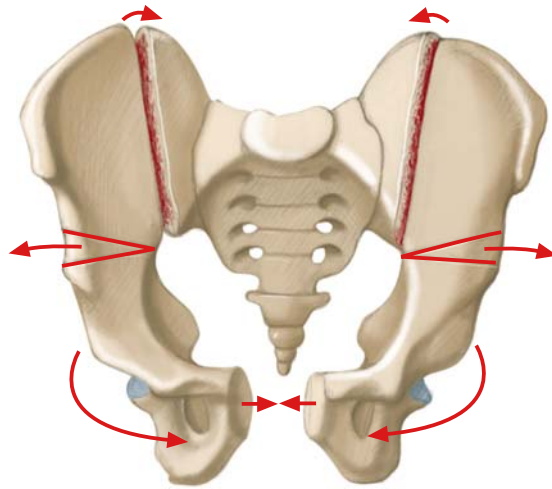


Figure 56.2

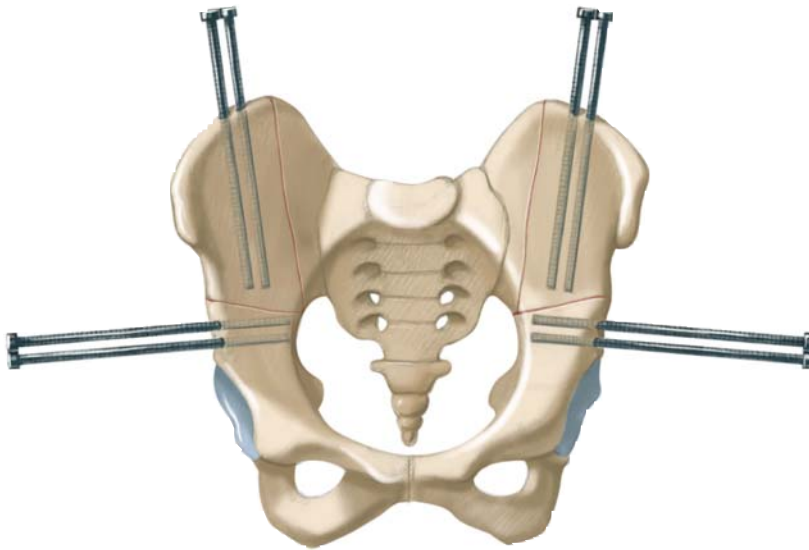


Figure 56.3

For bladder, posterior urethral and abdominal closure, anatomical outlay of the malformation before outlining the incision is important. The size of the bladder template is best evaluated by inverting the plate with sterile gloved fingers. With this manoeuvre, a previously unrecognized part of the bladder can be found behind the fascia in some cases with small bladder templates. To achieve proper retraction, a nylon suture is placed through the ventral glans.

The complete incision is outlined with a blue marking pen. The skin is incised using a no.15 blade above the umbilicus around the junction of the bladder and the paraexstrophy skin to the level of the urethral plate. The remainder of the incision is performed with electrocautery. For the prostatic and posterior urethral reconstruction, a 2-cm wide mucosal strip from the distal trigone to below the verumontanum out onto the base of the penis is outlined and incised. In females the incision is carried out down to the vaginal orifice and the clitoral halves are denuded for the complete reconstruction of the outer genitalia along with the bladder and posterior urethra. The skin incision leaves an inner mucosal line and outer skin rim for the closure of the bladder and skin, respectively.

Figure 56.4

The plane between the rectus fascia and the bladder is found and entered just above the umbilicus. The dome of the bladder is separated from the peritoneum and the retropubic space behind the bladder becomes developed. The attachments connecting the rectus sheath and muscle to the bladder are released sharply and the umbilical vessels are freed, transected and doubly ligated. Taking down the caudal rectus attachments and peritoneum from the dome leaves the cephalad part of the bladder completely mobilized, therefore allowing the bladder to be placed deeply into the pelvis, where it will begin to fold on itself.

Figure 56.5

At this point the urogenital diaphragm can be recognized connecting the pubic bone with the posterior urethra and bladder neck. Placing a skin hook in the pubic tubercles allows for lateral retraction, revealing the urogenital diaphragm completely. It is crucial to radically incise the diaphragm using electrocautery completely all the way down to the pelvic floor to prevent anterior placement of the vesicourethral unit after closure. Care is taken to release the fibrous band sharply at the subperiosteal level bilaterally. This manoeuvre cannot be emphasized enough since incomplete dissection of the diaphragm fibres will create anterior tension and often becomes the cause for failed closure.

By applying gentle traction on the glans caudally, the insertions of the corporal bodies on the lateral inferior aspect of the pubic bone can be visualized. Releasing the attachments of the suspensory ligaments to the corpora bilaterally at this level results in some penile lengthening by bringing the congenital shorter corpora further out of the pelvis.

Figure 56.6

The ureters are stented since swelling and the increased intravesical pressure can cause temporary obstruction. A Malecot catheter drains the bladder and all tubes are brought through the bladder wall and attached to the inside and outside of the bladder with 4/0 absorbable sutures. The mucosa and the muscle of the bladder and posterior urethra are closed with a running 3/0 absorbable suture in the midline anteriorly. The closure covers the ejaculatory duct and the proximal two-thirds of the posterior urethra. After urethral closure, a 12F–14F sound should easily be passable through the orifice into the bladder. The correct choice of bladder outlet resistance is of critical importance. Creating bladder outlet obstruction would ultimately lead to increased intravesical pressure and upper tract changes while on the other hand the outlet resistance has to be high enough to promote bladder adaptation and growth and prevent bladder prolapse. A second layer of interrupted stitches is placed and the posterior urethra and bladder neck are buttressed to the second layer of local tissue if possible. The urethra is sounded again to ensure the second layer did not add additional obstruction.

Figure 56.3

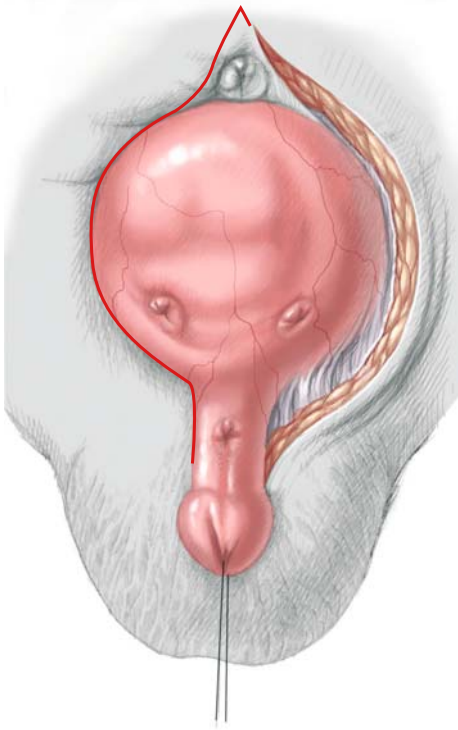


Figure 56.4

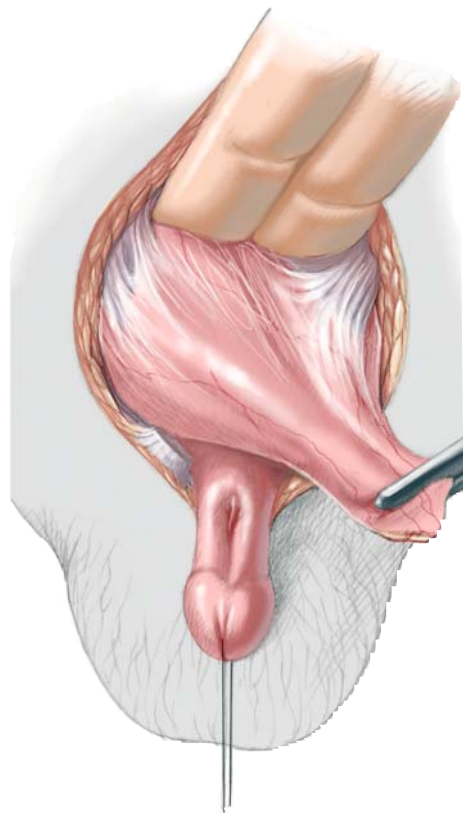

Figure 56.5

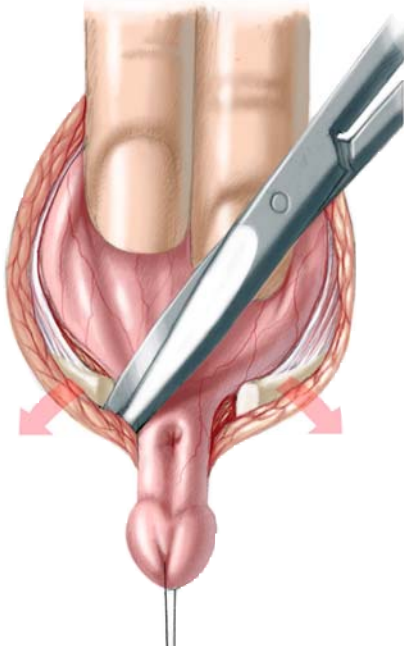


Figure 56.6

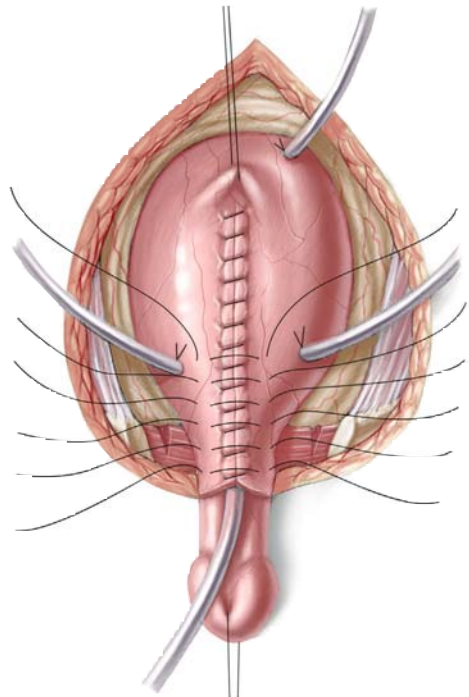


Figure 56.7

Following closure of the bladder the suprapubic tube and ureteral stents are exteriorized through the neoumbilicus, which is created by a V-shaped flap of abdominal skin, tacked down to the abdominal fascia in the correct anatomical position. The ureteral stents are left in place for 10 to 14 days and the suprapubic tube is removed 4 weeks post-operatively after calibrating the bladder outlet to warrant free drainage. Note that the urethra is not stented at the end of the operation to avoid pressure necrosis, infection and secretion accumulation with subsequent catheter blockage. The pelvis is approximated in the midline by gently applying pressure over the greater trochanters bilaterally. Horizontal mattress sutures using o-PDS (polydioxanone) are placed in the pubis.

It is important to tie the knot away from the neourethra to avoid material migration into the posterior urethra. A second stitch of o-PDS is used at the most caudal insertion of the rectus fascia onto the pubic bone for added security if it can be easily done and does not compromise the first stitch.

Figure 56.8

The modified Cantwell-Ransley epispadias repair is begun by placing a nylon suture through the ventral glans for traction. A circumcising incision is made and the ventral penile skin is taken down to the level of the scrotum to deglove the penis. Holding sutures are placed into the ventral prepuce. The ventral mesentery between the corpora is left intact for the blood supply to the urethral plate. The base of this mesentery is located where the corporal bodies diverge on the ventral aspect of the corpora.

Figure 56.7

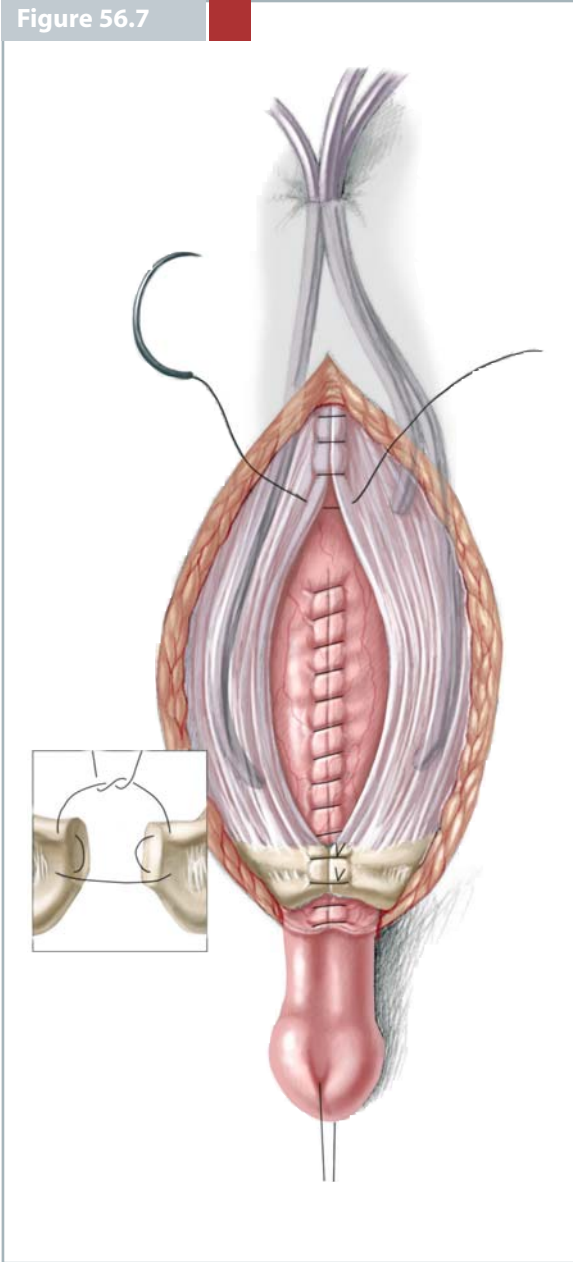


Figure 56.8

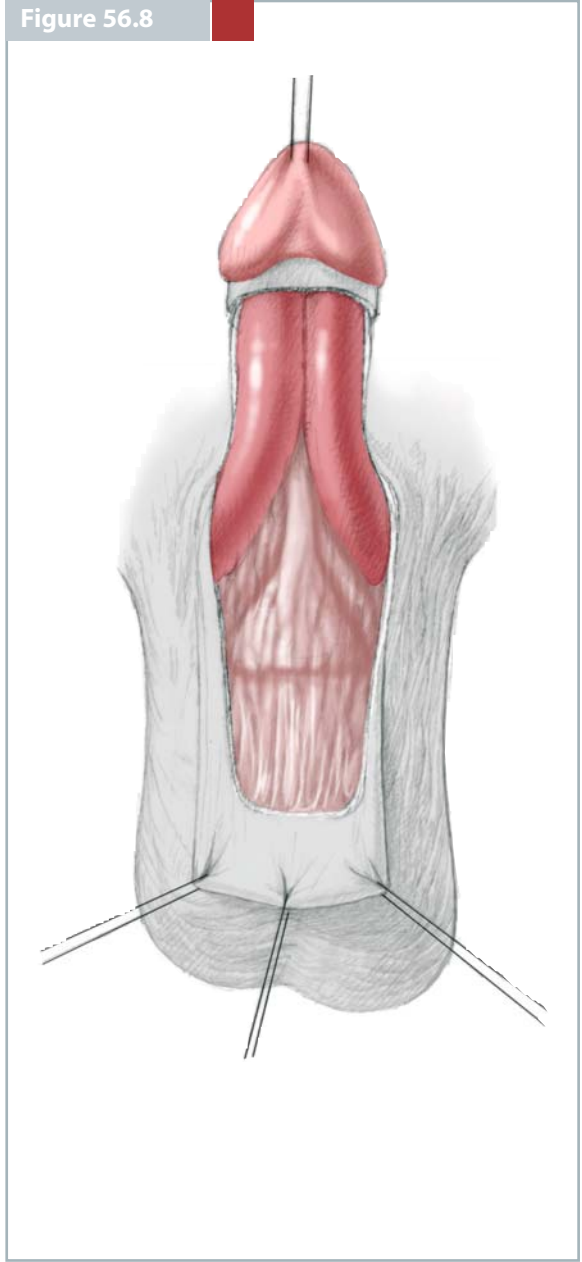


Figure 56.9

A deep vertical incision (IPGAM) in the distal urethral plate is performed and closed transversely with 6/0 polyglycolic sutures to flatten the distal urethra and advance it to the tip of the penis for later closure. On the dorsum of the penis an 18-mm wide urethral mucosal strip from the prostatic urethral meatus to the tip of the glans is outlined with a blue marking pen and incised with a no. 15 scalpel. Lateral skin flaps are mobilized and undermined.

Figure 56.10

The neurovascular bundles, situated between Buck's fascia and the corporal bodies can be visualized at the lateral aspects of the corpora. Thick glandular wings are developed sharply off the corpora and triangular mucosal areas are excised to bring denuded glans together at time of closure. At the dorsal base of the phallus a Z-incision is performed in the suprapubic area to release tension from old scar tissue of the initial closure. The suspensory ligament is exposed and divided to gain penile length.

Figure 56.11

The dissection of the urethral plate is continued from the ventral side. By strictly dissecting on the surface of Buck's fascia, the plane is followed in a circumferential fashion between the corpora spongiosum and cavernosa towards the dorsal side. The incisions from the dorsal and ventral side are joined followed by the dissection of the contra lateral side in the same way. Loops are passed around the corpora and the plane is extended proximally to the level of the prostate and distally to the junction of the glans with the corporal bodies. Care is taken to never leave the sur-

face of Buck's fascia to avoid injury of the corpora and neurovascular bundles, respectively. The urethral plate is now completely freed from the corporal bodies except for the distal most 1 cm attachment of the mucosal plate to the glans penis. This degree of mobilisation is necessary to rotate the corporal bodies over the urethra at the level of the corona. The urethral plate is now tubularized beginning at the level of the prostate over an 8F soft silicone stent with a running 6/0 polyglycolic suture.

Figure 56.9

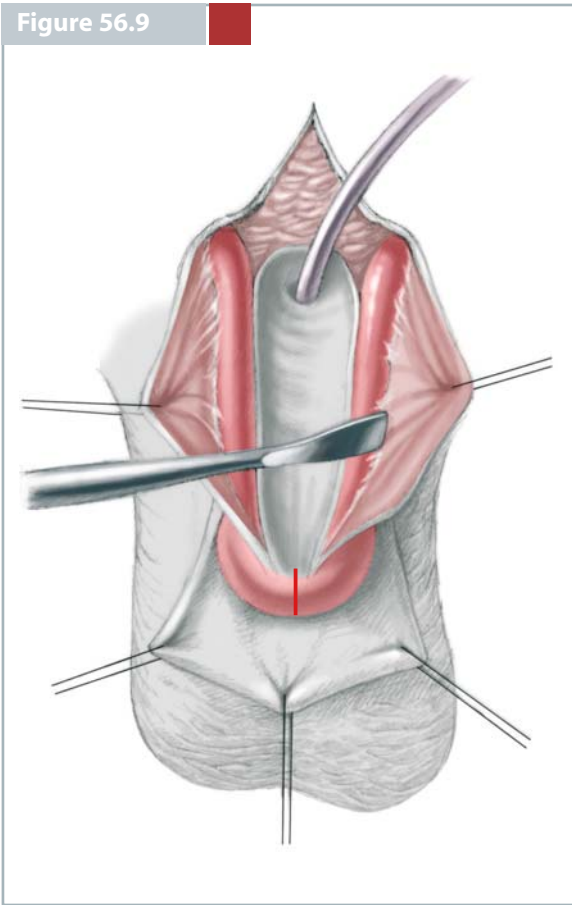


Figure 56.10

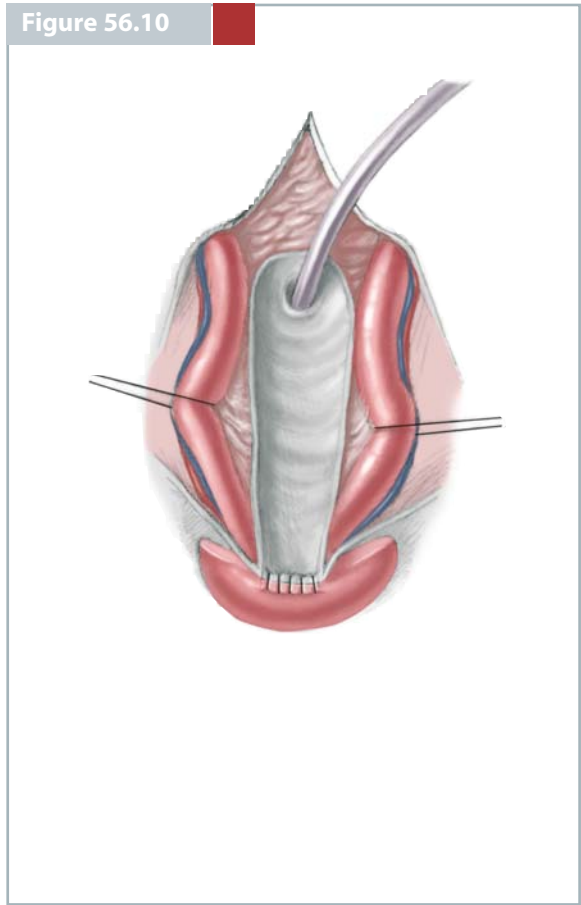


Figure 56.11

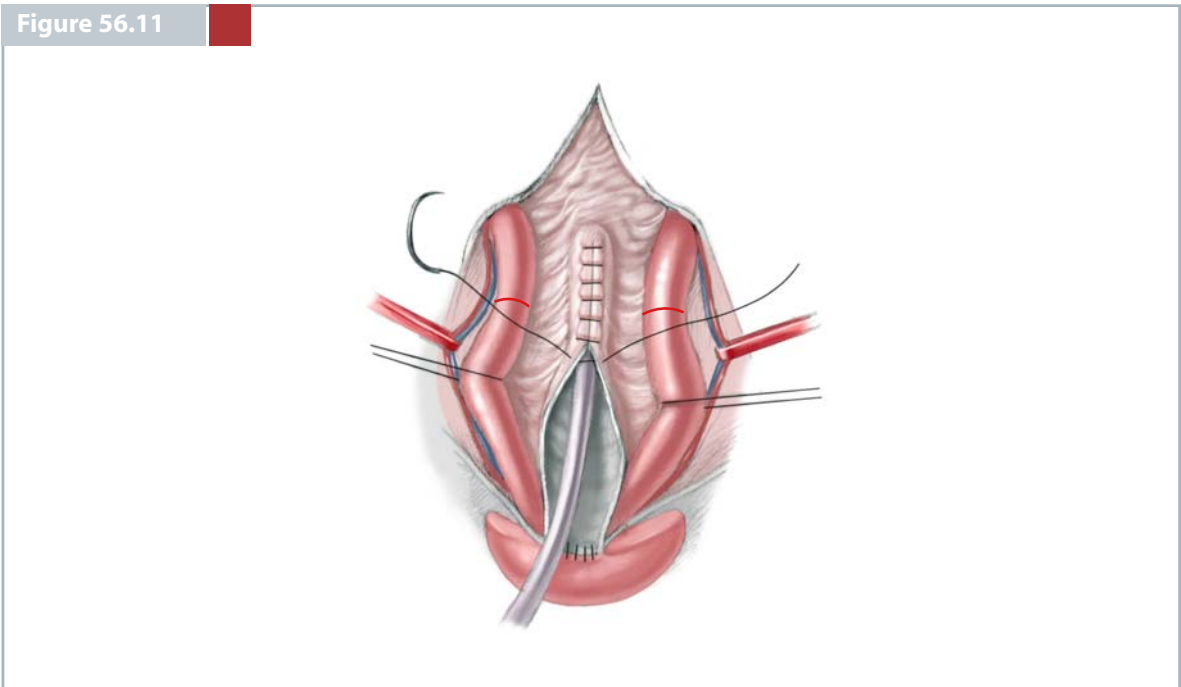


Figure 56.12, 56.13

If the rotating the corpora over the urethra alone does not straighten the penis satisfactory, corporal incisions at the point of maximum curvature is performed. To ascertain proper protection the neurovascular bundles in those cases, they become dissected free from the corporal bodies and secured with vessel

loops. The corpora can now be easily rotated over the neourethra.

If corporal incision took place, the diamond shaped defects are sutured to each other over the neourethra with two 5/0 polydioxanone running sutures.

Figure 56.14

If no incision was necessary, the corpora are rolled over and closed over the neourethra with interrupted 5/0 polydioxanone sutures. This manoeuvre deflects the penis downward and provides some increase in penile length. Additional sutures of 5/0 polyglycolic acid are placed between the corporal bodies to bury the urethra further, especially at the point where the urethra emerges between the corpora and at the level of the corona, respectively, to avoid fistula development.

Figure 56.15

The glans is now closed in two layers of interrupted sutures with 5/0 polyglycolic acid for the subcutaneous and 6/0 polyglycolic acid for the epithelial layer. The reconstructed phallus with the now ventrally displaced urethra and the corporal bodies with the neurovascular bundles running on the lateral sides to the reconstructed glans.

Figure 56.12

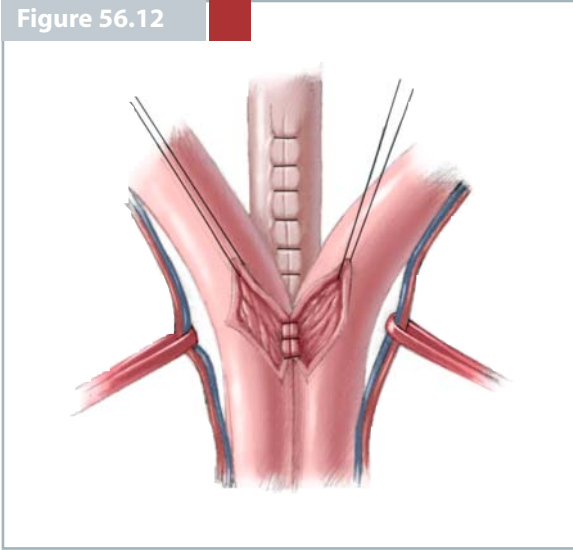


Figure 56.13

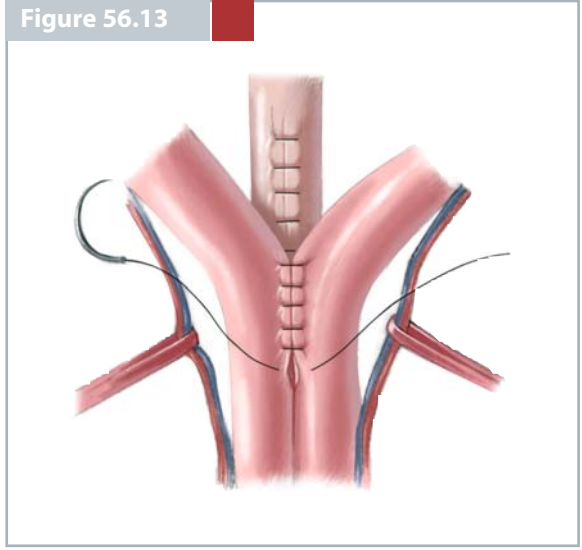


Figure 56.14

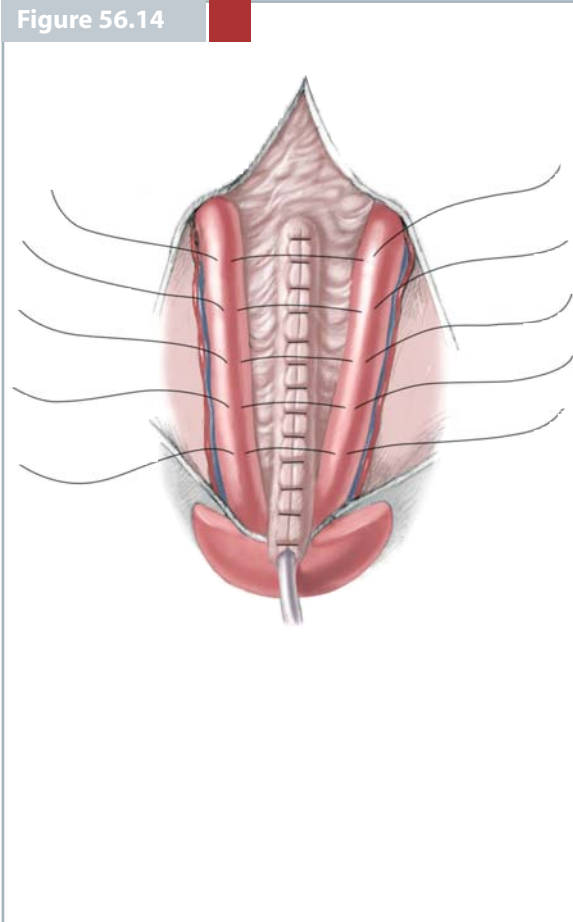


Figure 56.15

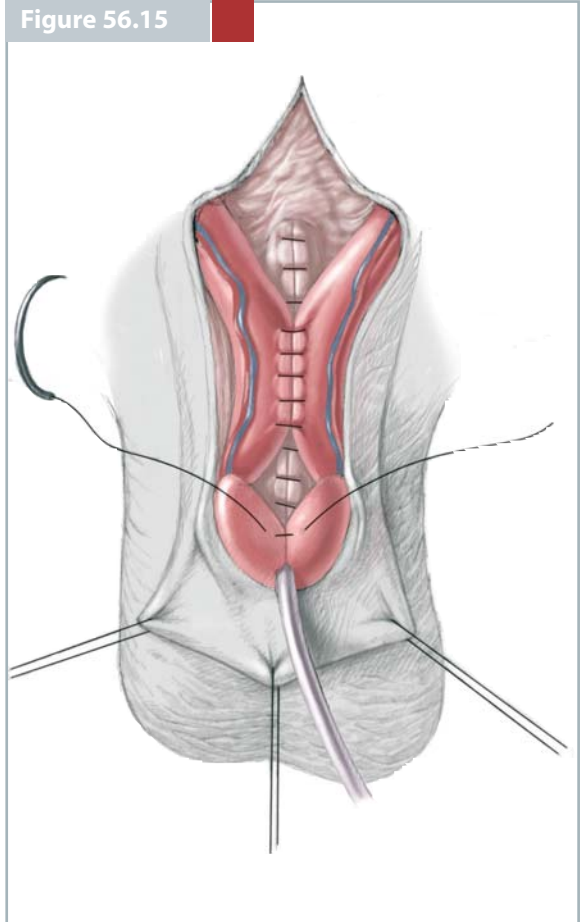


Figure 56.16

The mobilized ventral skin is brought up and sutured to the ventral edge of the corona. The dorsal side is covered with the skin flaps by bringing them together in the midline of the dorsal phallus with interrupted 5/0 or 6/0 polyglycolic acid sutures.

The urethral stent is secured at the tip of the gland with a nylon stitch and left in place for 10 to 12 days.

At the end of the operation the penis is covered with a plastic occlusive dressing, which will stay on until it falls off by itself. Postoperative pain and bladder spasm control has to be provided to keep the child comfortable and prevent urinary extravasation.

Figure 56.17

Before the operation the bladder capacity is measured by a gravity cystograms with the child in anaesthesia. A bladder capacity of 85 ml or more is necessary to achieve complete dryness after bladder neck reconstruction.

The abdomen is accessed through a Pfannenstil incision. The bladder is incised from the dome to the bladder neck with an additional vertical incision. This type of incision will narrow the bladder neck at time of midline closure, while enlarging the vertical

dimension of the bladder. A very radical dissection of the bladder, the bladderneck and posterior urethra is critical as well in the pelvis as behind the pubic bar. If the posterior urethra cannot be visualized, one should not hesitate to cut the intrasymphyseal bar to gain exposure and access. Enough mobility of the vesicourethral complex is necessary to create an adequate narrowing and tightening of the bladder neck to achieve postoperative continence. The symphysis is closed afterwards with o-PDS.

Figure 56.16

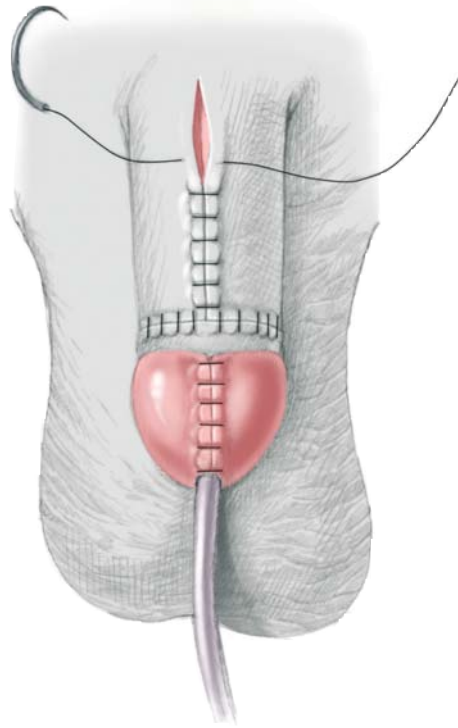


Figure 56.17

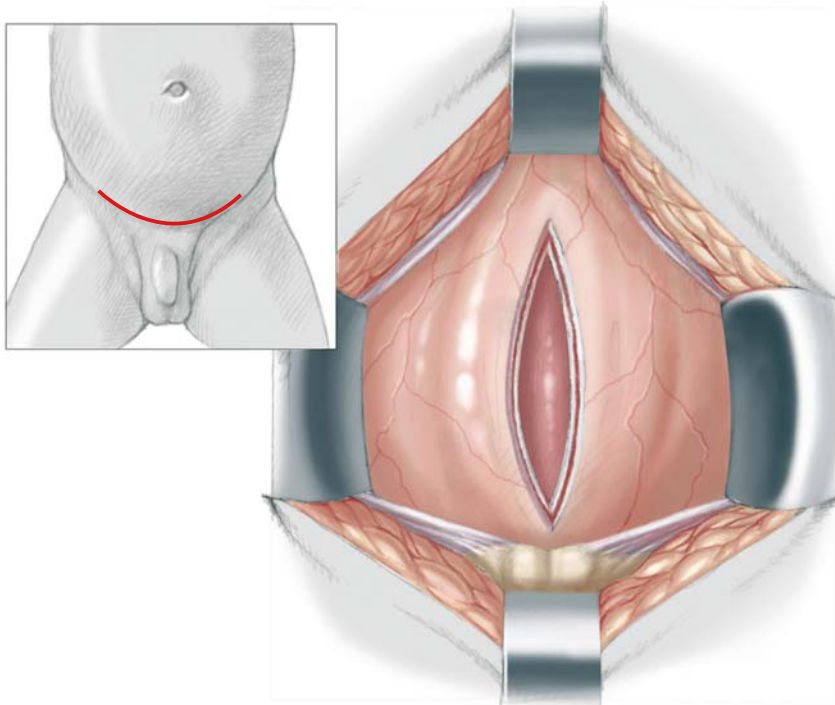


Figure 56.18

The ureters are reimplanted using standard Cohen's transtrigonal technique. If the ureteral hiatus is too close to the trigone, a cephalotrigonal reimplantation directs the ureters away from the trigone to ensure

proper distance between the reconstructed bladder neck and the reimplants preventing obstruction of the upper tracts. Ureteral stents are placed and brought through the bladder wall.

Figure 56.19

A posterior mucosal strip of 15–18 mm width and a length of 30 mm extending from the midtrigone to the prostate or posterior urethra is outlined with a blue marking pen and incised using a no. 15 blade. Note that the transverse incision is only at the level of the mucosa and does not include the muscle. Muscular incision at this level bears a high risk of denervation and ischaemia, leading to failure of the procedure.

Figure 56.20

The bladder muscle lateral to the mucosal strip is denuded of mucosa and covered in 1:200,000 adrenaline-soaked sponges to control bleeding for better visualization. The denuded lateral muscle triangles are tailored by multiple small incisions using electrocautery to allow the area of reconstruction to assume a more cephalic position.

Figure 56.18

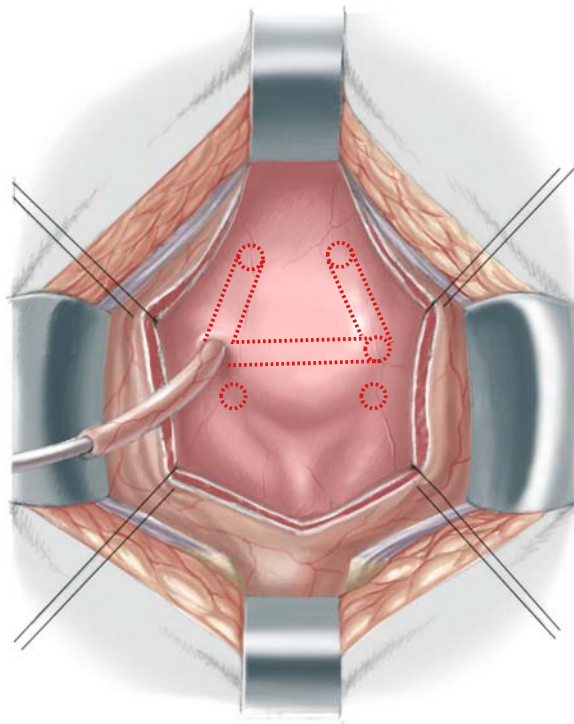


Figure 56.19

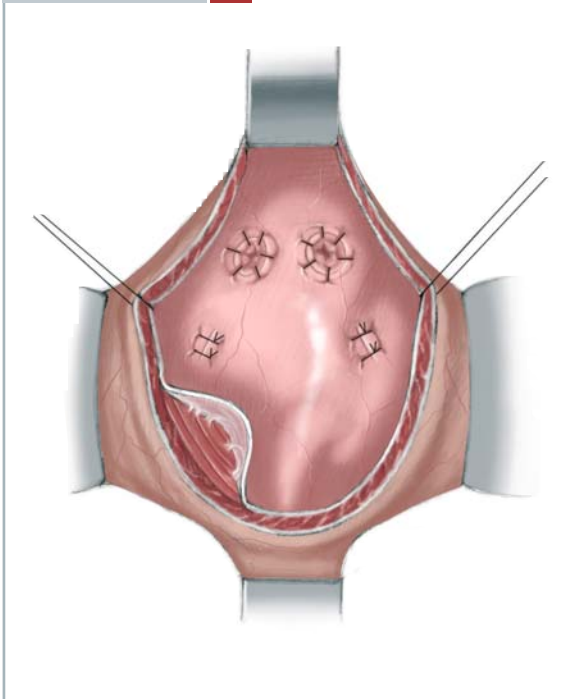


Figure 56.20

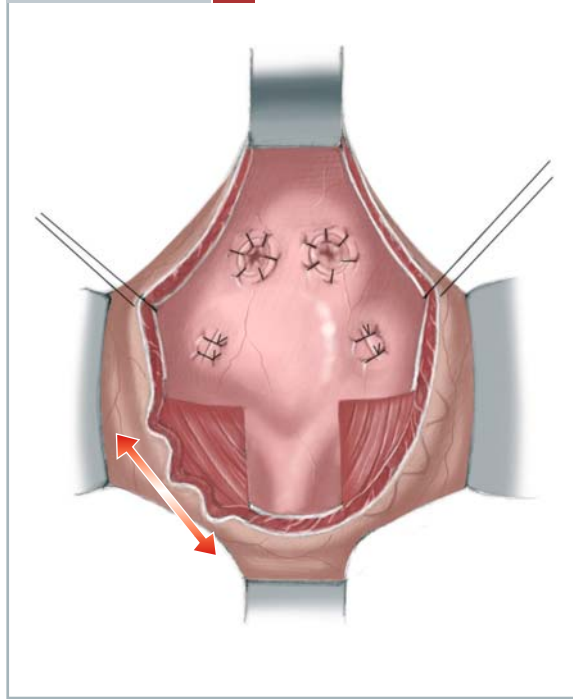


Figure 56.21

The previously outlined mucosal strip is tubularized over an 8F urethral stent using interrupted 4/0 polyglycolic acid sutures.

The denuded muscle flaps are overlapped tightly and sutured firmly in place with 3/0 polydioxanone sutures to reinforce the bladderneck. The result is a mucosa-lined tube inside a muscular funnel narrowing from the bladderneck towards the posterior ure-

thra. Three of the muscular sutures are left long and brought through the rectus fascia as suspension sutures.

The urethral stent is removed after the bladder neck reconstruction. A suprapubic tube is brought through the bladder and secured with 4/0 chromic sutures.

Figure 56.22

The bladder is closed in two layers and the tubes are brought through the skin and secured with a nylon stitch. The suspension sutures are elevated and tied on the rectus fascia increasing outlet resistance, estimated intra-operatively by water barometer. Note the

absence of urethral catheter. The ureteral stents are removed after 10–14 days. The suprapubic is clamped for the first time 3 weeks post-operatively and removed once the child empties the bladder without residual urine, confirmed by ultrasound.

Figure 56.21

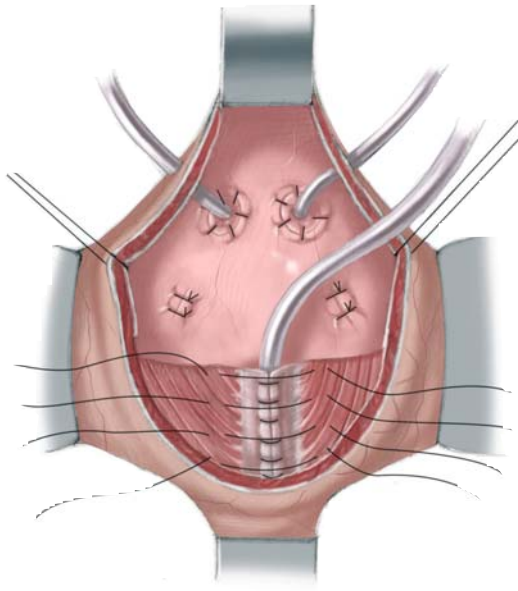
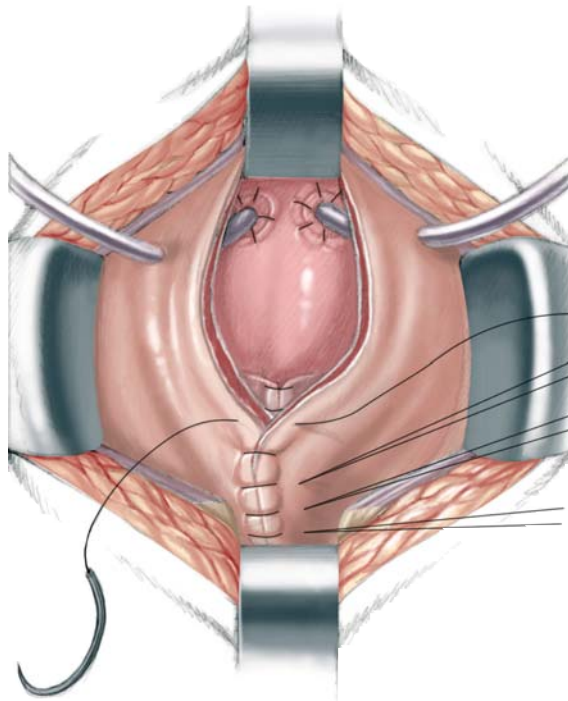


Figure 56.22



CONCLUSION

Successful initial bladder and posterior urethral closure is the most important factor for achieving urinary continence and sufficient bladder capacity. The original description of the described procedure has been significantly modified in the last decade, leading to a dramatic increase in success of the procedure. Several series since then have shown the success and applicability of our method for the treatment of bladder exstrophy [7,8]. However, strict criteria for the selection of patients who are suitable for his approach have been defined. The fragile mucosa as well as detrusor function is best preserved by closing the bladder in the newborn period. However, the size and the functional capacity of the detrusor muscle are important considerations for the outcome. Therefore, in the rare presence of a small, fibrotic bladder patch without elasticity or contractility the operation should be deferred until adequate growth of the bladder template took place. The risk of bladder neck failure is higher for the group with smaller bladder capacities under 85 cc. If sufficient size is not reached 4 to 6 months after birth, alternative options like creation of a colon conduit or uretersigmoidostomy has to be employed. Later in life, the former uri-

nary diversion can be converted into a continent catheterizable pouch bladder or augmented bladder if the template is still intact.

Out of our current database of 748 patients, 65 patients were isolated entirely treated at our institution who underwent initial modern staged functional closure show 77% to be continent day and night with 91% being socially dry. Continence is correctly defined as being dry for more than 3 h. Socially continent patients achieve that goal during the day, but have bed-wetting incidences during night-time.

The described approach for the functional closure of bladder exstrophy has developed over the last decades out of the experience and insight of committed researchers and surgeons in the field of the bladder exstrophy-epispadias complex. Pooling of experience in specialized centres is critical as surgeons, orthopedists, anaesthesiologists, psychiatrists, researchers, nurses, child life experts, social workers and the active exstrophy groups work together on a daily basis. The collaboration of these groups is the best basis to achieve the optimal outcome for each individual child born with the malformation.

SELECTED BIBLIOGRAPHY

1. Sponseller PD, Bisson LJ, Gearhart JP et al (1995) The anatomy of the pelvis in the exstrophy complex. *J Bone Joint Surg Am* 77:177-189
2. Silver RI, Partin AW, Epstein JJ, et al. (1997) Penile length in adulthood after bladder exstrophy reconstruction. *J Urol* 158:999
3. Jeffs RD, Charrios R, Mnay M, Juransz AR (1972) Primary closure of the exstrophied bladder. In: Scott R Jr, Gordon HL, Carlton CE, Beach PD (eds) *Current controversies in urologic management*. WB Saunders, Philadelphia, pp 135-143
4. Cendron J (1971) La reconstruction vesicale. *Ann Chir Infant* 12:371-381
5. Gearhart JP (2001) The bladder-epispadias-cloacal exstrophy complex. In: Gearhart JP, Rink RC, Mouriquand PDE (eds) *Pediatric urology*. WB Saunders, Philadelphia, pp 511-546
6. Gearhart JP (2001) Complete repair of bladder exstrophy in the newborn: complications and management. *J Urol* 165:243-246
7. Mollard P, Mouriquand PE, Buttin X (1994) Urinary continence after reconstruction of classic bladder exstrophy (73 cases). *Br J Urol* 73:298-302
8. McMahon DR, Kane MP, Husmann DA et al (1996) Vesical neck reconstruction in patients with the exstrophy-epispadias-complex. *J Urol* 155:1411-1413

INTRODUCTION

Cloacal exstrophy is the most severe anomaly in the spectrum of the extrophy-epispadias complex. It is extremely rare, occurring in approximately 1 in 200,000 to 400,000 live births, and males are affected twice as often as females.

With advance in prenatal diagnosis, more patients are now diagnosed on prenatal scans. The criteria include non-visualization of the bladder, a large mid-line infraumbilical anterior wall defect or cystic anterior wall structure (persistent cloacal membrane), omphalocele and lumbosacral anomalies. Seven less frequent or minor criteria namely lower extremity defects, renal anomalies, ascites, widened pubic arches, a narrow thorax, hydrocephalus and one umbilical artery have been described.

The exact embryology is still debated but the defect results from abnormal mesodermal migration during development of the lower abdominal wall and of the urogenital and anorectal canals.

Associated anomalies are common in the urinary tract, pelvic kidney and renal agenesis are seen in a third of all patients. Spinal dysraphism is present in about 67% of patients and is associated with a significant morbidity. Skeletal system anomalies of both the vertebral bodies and the lower limbs are commonly seen.

In girls duplication of the uterus and vagina are common. In the males the incidence of bilateral cryptorchidism is high but in some the testes have descended. These testes are normal on histology.

Exomphalos is seen in about 85% of patients and sometimes gastrointestinal (GI) tract abnormalities like malrotation, duplication and duodenal atresia may be present.

Short gut is seen in about 25–50% of all patients and, consequently, impaired growth is observed in a significant number of patients and appears to occur before any major reconstruction. Fifty percent of the infants in the Great Ormond Street Hospital series were below the 3rd centile for weight at 1 year of age.

Cloacal exstrophy should be managed in a specialist centre by a multidisciplinary team comprising a pediatric urologist, pediatric surgeon, neonatologist, pediatric neurosurgeon and a pediatric orthopedic surgeon with a special interest in the management of these complex anomalies. The role of the pediatric urology nurse specialist and a psychologist is invaluable in the long-term management of these patients.

The surgical repair includes reconstruction of the bladder and genitalia. Conservation of all bowel segments to minimize fluid and electrolyte losses and for further genito-urinary tract reconstruction. Soft tissue mobilization and/or osteotomies.

Transfer of the neonate to a specialist centre must be arranged. A cling-film dressing should be used to cover the exposed bladder plate and the hindgut. This minimizes fluid losses and reduces mucosal damage. The umbilical cord should be ligated with a nonabsorbable suture to prevent the umbilical clamp abrading the bladder plate or the hindgut.

Intravenous access should be obtained in the upper limbs. Routine pre-operative bloods including a karyotype should be drawn.

Renal and spinal tract ultrasounds are necessary to document any upper tract abnormalities and spinal cord tethering. A distal loopogram is recommended by some centres to assess colonic length.

Figure 57.1

Anatomically, the foreshortened hindgut or caecum is seen between the two hemibladders. The orifice of the terminal ileum, rudimentary hindgut and appendix are seen on the caecal surface. The ileum may be prolapsed. The pubic symphysis is widely separated and the hips are externally rotated and abducted. The phallus is separated into right and left halves with the adjacent labium or scrotal half. Superiorly there is an exomphalos containing small bowel and sometimes liver. There is a large intra-patient variation and a classification system has been proposed.

The size of the exomphalos and the hindgut plate largely determine the extent of the initial closure. The order of the repair is closure of the exomphalos followed by separation of the hemibladders from the hindgut plate and GI reconstruction and then bladder closure. The exomphalos closure is not always possible and a silo may be required in some cases.

Figure 57.2

Two 5F ureteric catheters are placed in the two ureteric orifices and secured with 5/0 absorbable sutures. Dissection commences first superiorly and the umbilical vessels are doubly ligated and divided. The extrophied section is separated from the skin and the adjacent hindgut with diathermy taking care to avoid the ureters, which can be felt medially once the stents are inserted. The two hemi-bladders are then separated from the exstrophied hindgut.

Once this is performed, the length of the available hindgut is measured and the exstrophied hindgut is tubularised to recreate the ileo-colonic valve. The terminal part of the colon is fashioned into a colostomy. The appendix, where possible, is preserved.

The two hemibladders are approximated and the bladder is closed according to standard principles applied for primary bladder exstrophy closure. The urethra is tubularized over an 8F catheter, either completely (in girls) or partially (in boys).

Figure 57.3

The abdominal wall is closed in layers with interrupted 3/0 absorbable sutures.

The pubic symphysis is approximated with a 0/0 suture. Osteotomies may be performed to assist clo-

sure. Skin closure with subcuticular 5/0 absorbable suture and the stents are brought out through the suture line.

Figure 57.1

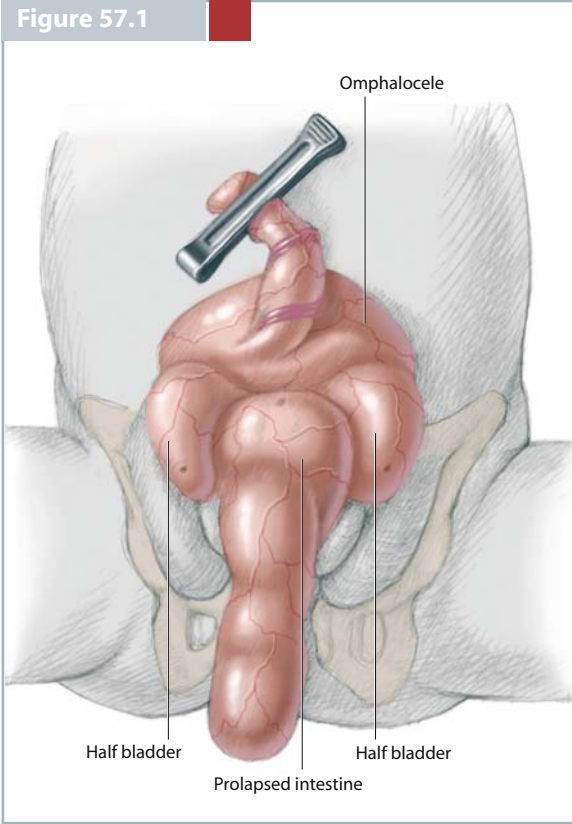


Figure 57.2

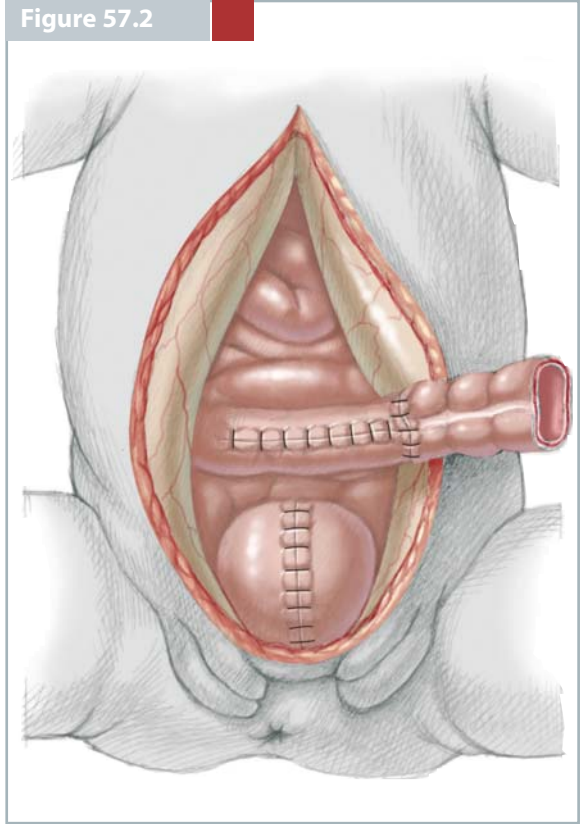
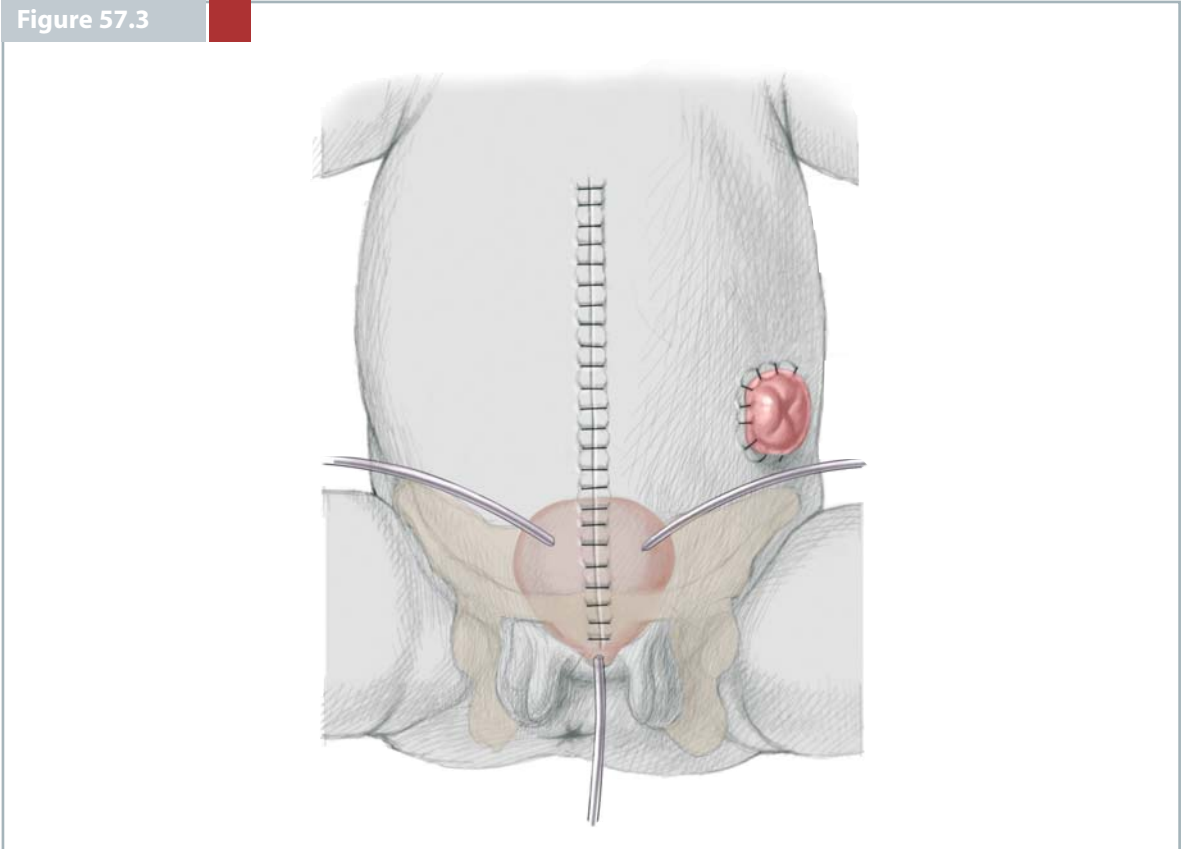


Figure 57.3



CONCLUSION

The majority of patients with cloacal exstrophy now survive with advances in perinatal management and surgical reconstruction. The emphasis has shifted from trying to achieve survival to providing a better quality of life to patients in the long-term.

The reconstruction of the urinary tract takes priority after the initial reconstruction. The timing varies with each individual patient. Initial continence rates were reported as about 5% in males and 10–15% in females.

Husmann reported in 1999 that even with staged reconstruction only 22% patients achieved continence. The presence of an associated neurological abnormality significantly affected the ability to achieve continence – 7% of those with neurological abnormality achieved continence compared to 40% of those without one. Those with low detrusor leak point pressure underwent bladder neck closure and Mitrofanoff channel construction. Overall continence was achieved in 48% of patients who underwent staged reconstruction, 22% after bladder neck reconstruction and 26% after a second procedure, including the Mitrofanoff principle with bladderneck closure. Noncontinent diversion was used to manage persistent incontinence in 22% of patients. However, 30% of them remained dependent on diapers.

He suggested that all patients have detailed neurological assessment; following this those with an intact spine should undergo staged reconstruction; those with an associated neurological abnormality should have a continent catheterizable stoma formed.

In the Great Ormond Street series, of the 19 patients reviewed, five patients had renal deterioration, two had pre-existing dysfunction, two deteriorated following bladder neck reconstruction and re-implant, and one patient deteriorated following bladderneck closure and re-implant. Bladderneck closure itself does not increase the risk for renal deterioration but close follow-up is mandatory following re-implantation to avoid renal deterioration.

A considerable proportion of patients have morbidity related to both GI tract and the spinal dysraphism and due attention should be paid to treat the bowel dysfunction. There was no difference in the growth velocity of patients who underwent terminal ileostomy compared with those who had terminal colostomy in the long-term follow-up though the former required more days in hospital and hyperalimentation usage during the first year of life. The hindgut has been used for terminal colostomy with anal pull-through if a solid stool can be produced. In a select group anterior sagittal anoproctoplasty may be used to achieve this. In a series of 25 patients reported by Peña over a 23-year period, eight patients had a PSARP and 17 an anterior sagittal ASARP.

Three were completely continent and four soiled occasionally. A total of 11 patients were continent with a bowel management program. Four were incontinent and were candidates for a bowel management programme, and two were incontinent and converted to an ileostomy. One patient was incontinent and refused a bowel management programme.

The decisions about gender reassignment are limited to the male patients with cloacal exstrophy and one is faced with the ultimate challenge of deciding whether those children who have XY chromosomes would fare better with abnormal or absent genitalia, or reconstruction in a reassigned gender. The testicular hormone has an important role in sexual differentiation of the mammalian brain and behaviour and no prenatal hormonal abnormality has been reported.

The experience at Great Ormond Street with cloacal exstrophy patients of XY chromosomes reassigned to the female gender has shown that they have female-type core gender identity but appear to demonstrate masculine childhood role behaviour-preference for toys like vehicles over dolls and an interest in athletic activity.

In male patients with cloacal exstrophy when conversion to a female gender is considered, reduction phalloplasty is not an issue as the penis is usually small. The real surgical issue is bilateral orchidectomy because if testes remain masculinization continues and if they are removed the potential for fertility is lost. No documentation of paternity exists. Infertility or subfertility could be multifactorial and result from cryptorchidism, retrograde ejaculation due to an incompetent bladderneck, dysfunctional bulbospongiosus muscle action, erectile dysfunction due to dissection of the corpora of the ischiopubic ramus, recurrent epididymo-orchitis, vasal or seminal tract injury during surgery. Myelodysplasia may also be a contributory factor.

In patients with cloacal exstrophy studied at Great Ormond Street, little difference was seen to exist in the quality of life between those raised as females, whether they were with an XY or XX karyotype. They appeared similar in social relationship with family and peers, and satisfaction with leisure and recreational activity. They disliked their colostomy and the need to perform catheterization but regarded the overall quality of life to be high.

Psychological well-being and stable gender identity are paramount when considering the quality of life for patients with cloacal exstrophy. Presently, there is insufficient information to make informed decision about optimal gender assignment in those with XY chromosomes. Until objective evidence becomes available, no firm approach could be advocated, and care needs to be individualized.

SELECTED BIBLIOGRAPHY

- Gearhart JB, Jeffs RD (1992) Exstrophy of the bladder, epispadias and other bladder anomalies. In: Walsh PC, Retik AB, Stamey TA, Vaughan ED (eds) *Campbell's urology*, 6th edn, vol 2. WB Saunders, Philadelphia, Chap 46, pp 1772–1815
- Groner JJ, Ziegler MM (2003) Cloacal exstrophy In: Puri P (ed) *Newborn surgery*. Arnold, London pp 629–636
- Husmann DA, Vandersteen DR, McLorie GA et al. (1999) Urinary continence after staged bladder reconstruction for cloacal exstrophy: the effect of coexisting neurological abnormalities on urinary continence. *J Urol* 161:1598
- Peña A (2000) New concepts in bowel reconstruction in cloacal exstrophy. *Dialogue Pediatr Urol* 23:3
- Schober JM, Carmichael PA, Hines M, Ransley PG (2002) The ultimate challenge of cloacal exstrophy. *J Urol* 167:300–304

Augmentation Cystoplasty and Appendicovesicostomy (Mitrofanoff Principle)

Boris Chertin

INTRODUCTION

There are two types of cystoplasty: augmentation cystoplasty where the bladder is enlarged, and substitution cystoplasty where the bladder is replaced. Augmentation cystoplasty is now commonly performed at most pediatric urological centres. The major goals of bladder augmentation are (1) to provide a compliant bladder reservoir, (2) to limit bladder contractility, and (3) to increase bladder capacity. Augmentation cystoplasty should allow the urinary tract to remain intact while preserving renal function and to provide urinary continence. There are different substrates most commonly utilized to augment the bladder. The most common is a segment of ileum. However, stomach, large bowel have been used. Ileum has been demonstrated to be the least contractile segment and therefore has become the tissue most commonly used for bladder augmentation. Sufficient augmentation should lead to effective bladder capacity. Nowadays, clean intermittent self-catheterization (CISC) has become a universal procedure assuring effective emptying of bladder after augmentation. However, in spite of the fact that CISC is simple and

easy to perform in mobile patients there are a relatively high number of failures in wheelchair patients. This is due to the difficulties in self-catheterization. To overcome those difficulties different techniques of continent diversion have been proposed. The technique of appendicovesicostomy, which is also well known as the Mitrofanoff principle has gained a wide popularity. The indications and detailed description of the different types of augmentation cystoplasty and continent diversion are outside scope of this chapter. Therefore, in this chapter we address the technical details of augmentation cystoplasty utilizing ileal patch (ileocystoplasty) and appendicovesicostomy.

Children are admitted to the hospital 2 days prior to the surgery. Clear fluid diet is started. The bowel preparation using GoLately is administered. The enema is performed at the surgery night. Parenteral antibiotics such as gentamycin, ampicillin and metronidazole are administered at the induction of anaesthetic.

Figure 58.1

The lower midline incision is made from pubis to umbilicus. Some surgeons do recommend a lower Pfannenstiel incision, but in our opinion this incision may limit exposure. In contrast, lower midline incision can be easily extended and allows access to entire abdomen. Following fascia incision, pyramidalis muscles and recti are exposed. Retropubic space is widely opened in order to expose the surgical field all

the way around the front and both lateral aspects of the bladder. The urachus is defined at the dome of the bladder, ligated and divided. The peritoneum is opened to expose the dome of the bladder with its peritoneal covering. Using traction suture at the urachus the plane cleavage along lateral bladder margin down to ureters and superior vesical pedicle on each side is performed (*dotted line*).

Figure 58.2

Following maximal bladder exposure, incision of the bladder wall is performed in either a circumferential or midline fashion. If the surgeon prefers circumferential incision, the bladder is exposed from the point of 2 cm from the ureteric orifice. In the case of midline bladder incision, the bladder is opened 1 cm from the bladderneck on the each side of bladder. We have used for years circumferential incision as shown

here, which gives us maximal exposure without jeopardizing ureters. Safe incision is achieved by starting on the bladder dome and opening the bladder using diathermy point down one side at a time. Use of the ureteric catheters is an option at the time of incision. The circumference of the bisected bladder is then measured utilizing tape or tubing in order to define the required length of the bowel segment.

Figure 58.1

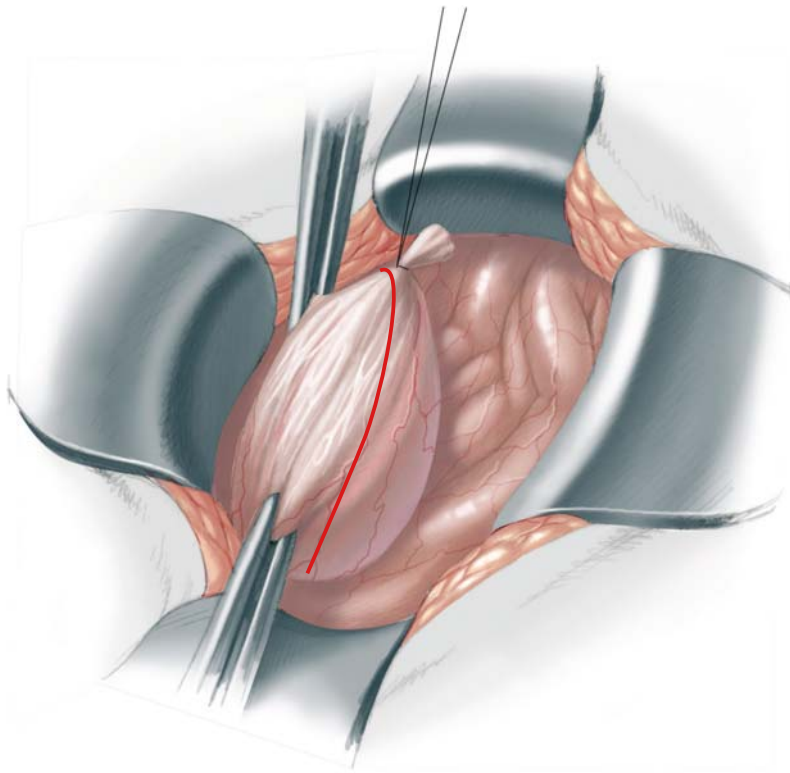


Figure 58.2

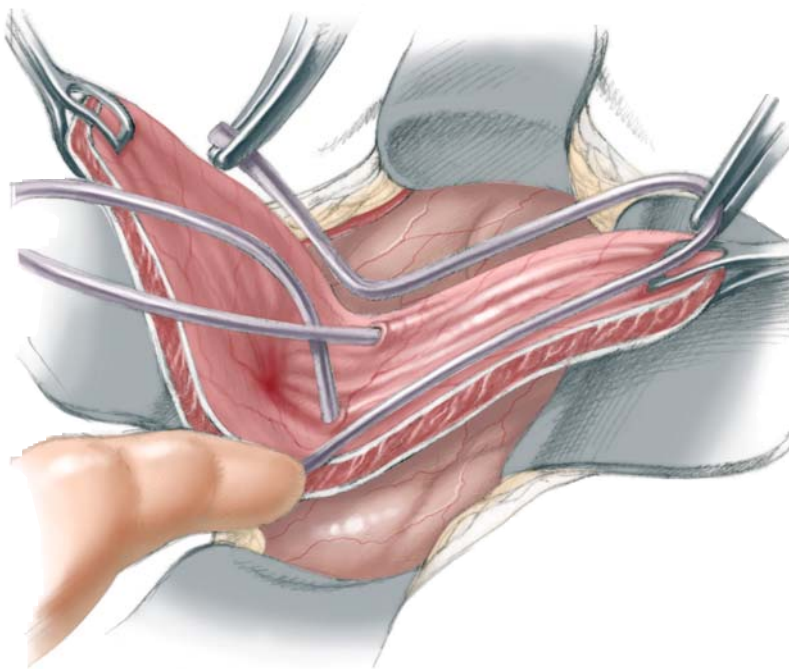


Figure 58.3

A convenient segment of the terminal ileum is isolated 15 cm proximal to the ileocecal valve. It should be equal in length to the measured maximal circumference of the bisected bladder and have a well defined

vascular pedicle supplying it. Two-layer ileoileostomy using GIA staplers or hand-sewn sutures is performed. The ileal segment is then opened on the anti-mesenteric aspect to produce a patch.

Figure 58.4

The ileal patch is inset into bisected bladder and sewn in place. In order to prevent overlap of the ileal edge and bladder edges because of the tendency of the bladder wall to contract during the procedure we halved and thereafter quartered the suture line with a

stay sutures. Ileal patch is anastomosed to the posterior bladder wall first using 3/0 absorbable continuous sutures locking stay sutures as they are encountered.

Figure 58.3

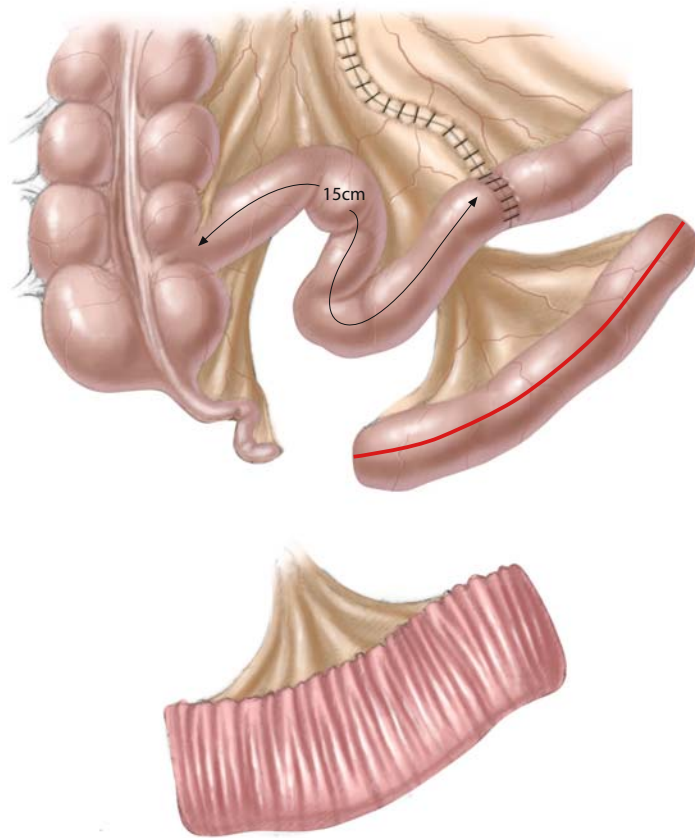


Figure 58.4

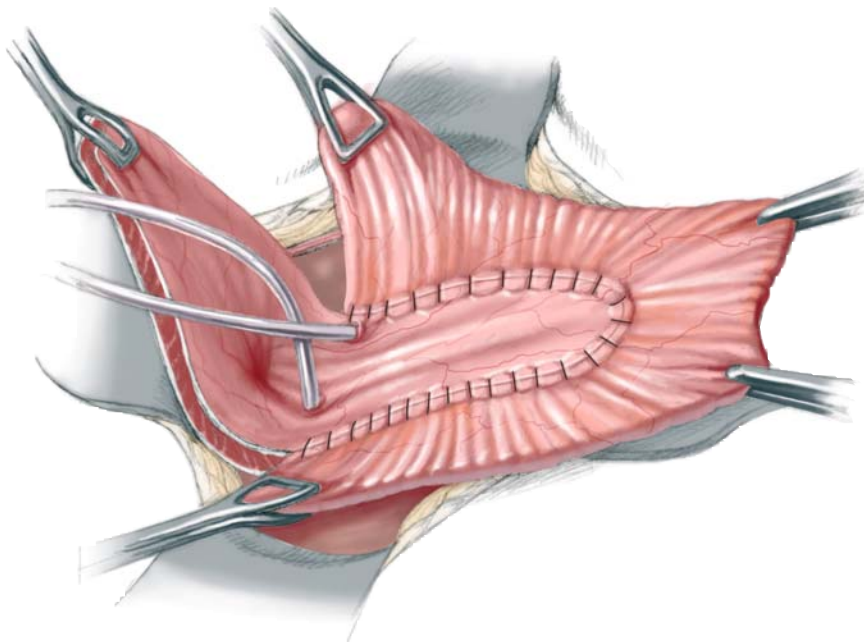


Figure 58.5

If a catheterizable Mitrofanoff procedure is to be performed it should be done at this time. The caecum and appendix are widely mobilized and appendix is isolated with its vascular pedicle and a small cuff of caecum. The caecum is closed.

Figure 58.6

The appendix is opened at the tip. The appendix is implanted in the bladder above the trigone in a transverse or oblique submucosal tunnel. The tunnel should be of at least 2.5–3.0 cm length with sufficient hiatus in detrusor in order not to squeeze on its blood supply.

Figure 58.5

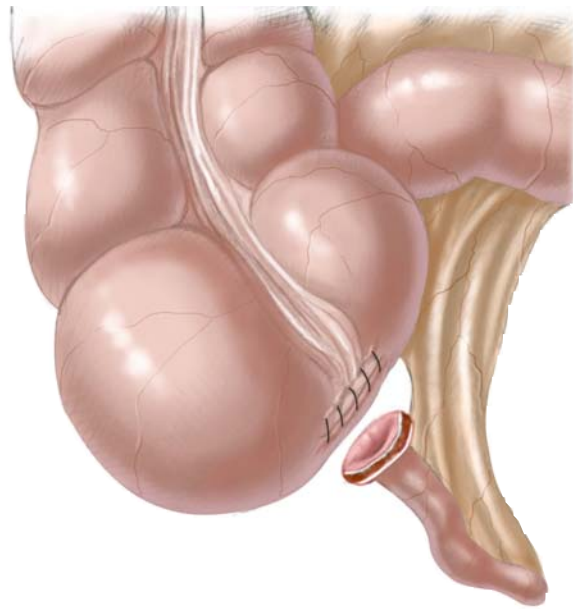


Figure 58.6

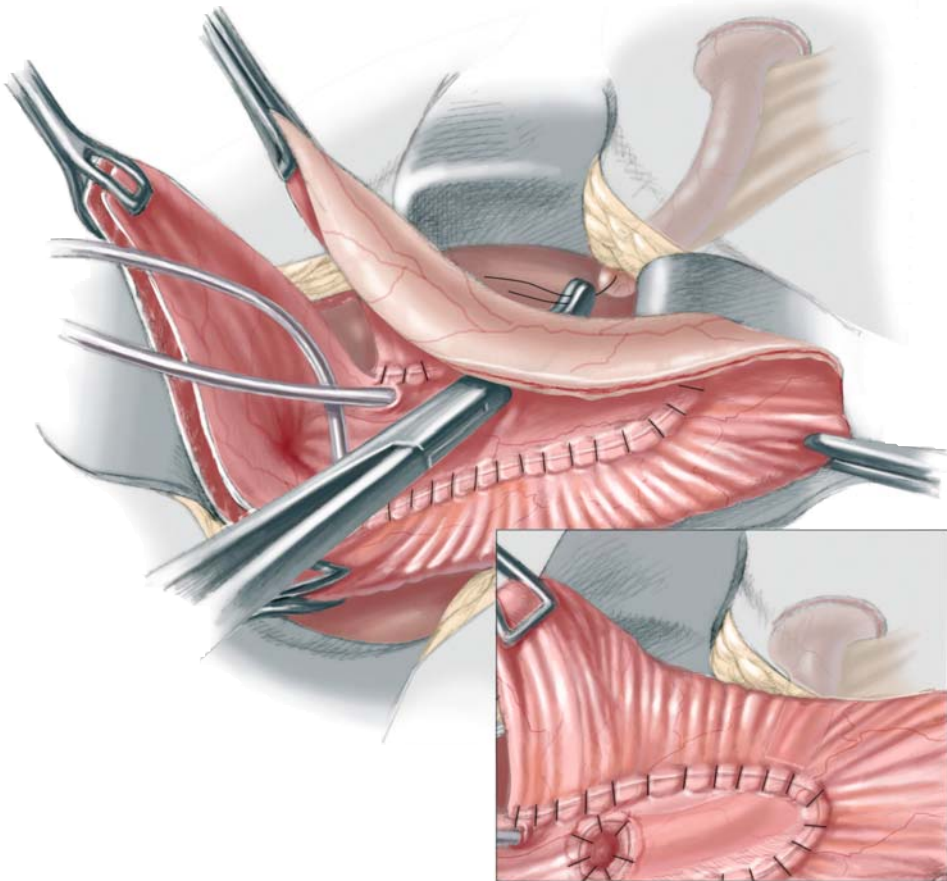


Figure 58.7

When appendicovesicostomy is completed, the ileal patch is flipped over and the procedure is repeated in order to seal the anterior bladder anastomosis. The anastomosis is performed as before at the posterior margin of the bladder. However, this time anastomosis is performed outside the bladder. At the end of

procedure a suprapubic catheter, which is big enough not to be obstructed by ileal mucus is left in the bladder. The catheter is brought out through the native bladder wall rather than through the suture line between the bladder and ileal patch. A wound drain is left into the retropubic space.

Figure 58.8

The base of the appendix is drawn to the skin through a large hole in the abdominal muscles, avoiding any kinking in its passage. At this stage the bladder is fastened to the abdominal muscle taking care to avoid strangulation of appendix and its pedicle. The site of the stoma on the skin is selected entirely for the patient's convenience. The umbilicus provides a good passage and best cosmetic result; however it is not an option in extrophy patients. With patients in wheelchairs, there is a tendency for the spine to be twisted with time causing progressive abdominal compression. In these patients the abdomen becomes hidden from the patient's field of vision. In these patients the stoma site close to the xiphisternum is the best option. The cutaneous end of appendix is spatulated and triangular 2–3 cm skin flap is sutured utilizing absorbable sutures into the spatulation, leaving a small portion of mucosa visible in or-

der to prevent any risk of delayed stenosis. If the conduit is short, the triangular skin flap is raised and rolled over the catheter to make a tube and latter is sutured to the spatulated end of the conduit to lengthen it. A 10F–12F Foley catheter is passed through the appendix and is left in bladder for least 2 weeks.

The wound drain is removed when it stops draining. The suprapubic catheter is clamped on about the eight postoperative day. When the suprapubic catheter is clamped the residual urine volume is checked out. Following satisfactory voiding, the catheter is removed after 24 h. In children being managed by intermittent catheterization we have kept urethral indwelling catheter for 48 h to ensure a complete healing of suprapubic site prior to commencement of the intermittent catheterizations.

Figure 58.7

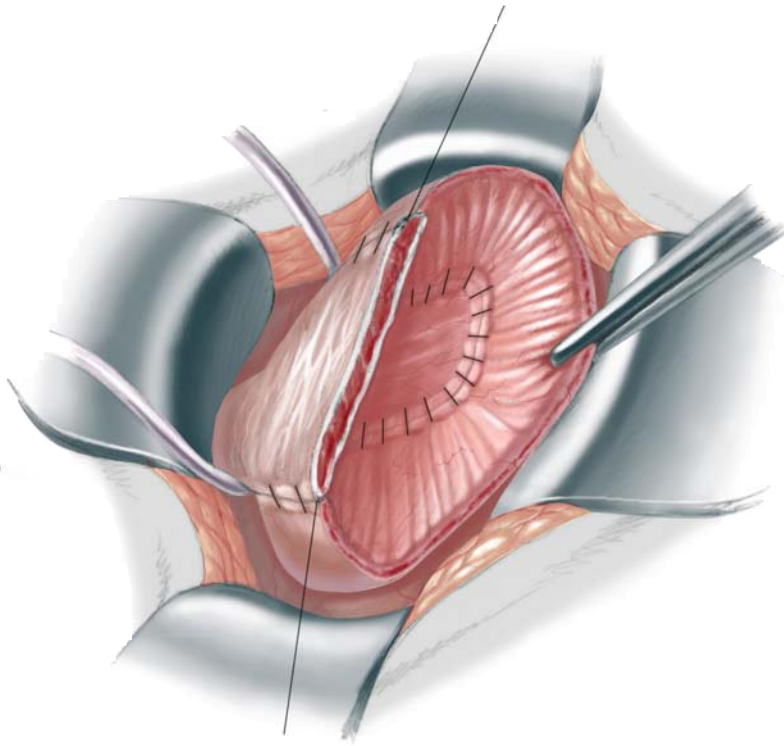
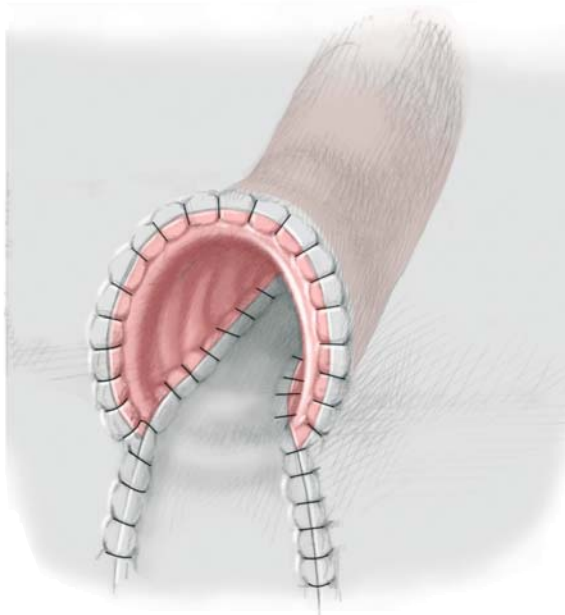


Figure 58.8



CONCLUSION

We have used augmentation cystoplasty utilizing ileal patch for years with a negligible complication rate and satisfactory results with respect to the bladder compliance and capacity in the long-term follow-up. None of our patients needed secondary augmentation due to increased contractile activity.

Even after ileal segment is isolated from the gastrointestinal tract it retains its absorbable and secretory properties. As a result of the electrolyte exchange hyperchloremic metabolic acidosis may de-

velop. The extent of the electrolyte exchange depends on the amount of intestinal surface area in contact with urine and the time that the urine remains in contact with the intestine. However, the patients with normal renal function prior to augmentation have adequate compensatory mechanisms and do not have significant problems with acute metabolic changes. Those patients who developed persistent severe metabolic changes have to be evaluated for insufficient bladder emptying.

SELECTED BIBLIOGRAPHY

- Mitrofanoff P (1980) Cystostomie continente trans-appendiculaire dans le traitement des vessies neurologiques. *Chir Pediatr* 21:297-305
- Duckett JW, Snyder HM III (1986) Use of the Mitrofanoff principle in urinary reconstruction. *Urol Clin North Am* 13:271-274
- Mundy AR, Noble JG (2002) Bladder augmentation and substitution cystoplasty. In: Frank JD, Gearhart JP, Snyder HM III (eds) *Operative pediatric urology*, 2nd edn, Churchill Livingstone, London, pp 49-68
- Mundy AR, Stephenson TP (1985) "Clam" ileocystoplasty for the treatment of refractory urge incontinence. *Br J Urol* 57:641-646
- Rink RC, Adams MC (1998) Augmentation cyctoplasty. In: Walsh PC, Retik AB, Vaughn ED et al (eds) *Cambell's urology*, 7th edn. WB Saunders, Philadelphia, pp 3167-3189

The ACE (Antegrade Continence Enema) Procedure

Padraig S. J. Malone

INTRODUCTION

Since its development in 1989, the ACE procedure has become widely accepted as a valuable addition to the therapeutic regimens available for treating intractable faecal incontinence associated with conditions such as myelomeningocele and anorectal malformations. Thousands of patients around the world have undergone ACE procedures with success rates in excess of 80% reported.

The original procedure described disconnecting the appendix from the caecum, amputating its tip, reversing it, re-implanting it into a submucosal tunnel on the anterior wall of the caecum to produce a continence mechanism, and the stoma was usually sited in the right iliac fossa. Since the original description numerous modifications have been proposed and introduced, so it is now incorrect to talk about the ACE procedure and it would be more accurate to use the term *ACE principle*.

In this chapter the author's current approach is described.

Because a failure rate of 20% exists, it is useful to perform an initial therapeutic trial of antegrade washouts, by minimally invasive means, before proceeding to the definitive procedure. A colonic catheter can be inserted percutaneously, under either radiological or colonoscopic control (as one would perform a percutaneous endoscopic gastrostomy, PEG), into any part of the large bowel and use it to administer the enemata. If constipation is the major problem the catheter is best placed in the distal descending colon but in the absence of constipation the caecum remains the best site. If the washouts are successful the patient has a choice: to keep the catheter, exchange it for a colonic button (identical to a gastrostomy button), or have a conduit constructed at open surgery. In the author's experience most patients will ultimately opt for a conduit, as there is a

tendency for leakage of flatus, and stool or washout fluid to occur around the side of the buttons. Using this approach it is also possible to test in which part of the colon the conduit will work best. Increasing numbers of conduits are now placed in the distal descending colon because the time taken to perform the washout is reduced.

In practical terms there are now two types of ACE, the original *caecal ACE* and the new *left colonic ACE*. For the caecal ACE, many surgeons now advocate simply amputating the tip of the appendix and bringing the open end on to the abdominal wall without constructing any continence mechanism. This is being increasingly performed laparoscopically. However, in the author's experience, if no continence mechanism is constructed, leakage of stool or washout fluid occurs in a significant number of cases and this approach is not recommended. The recommended technique for creating the continence mechanism has changed, however. It is no longer necessary to disconnect the appendix and the *in situ* technique will be described here. If the appendix is absent, required for a simultaneous Mitrofanoff procedure or if a left colonic ACE is being constructed, a tubularized small bowel tube using the Monti procedure is recommended and will be described. As the incision will depend on whether it is a caecal, left colonic or an ACE performed in combination with a bladder reconstruction no specific recommendations will be made. The surgeon can choose his or her own preferred approach.

It is recommended that patients receive broad-spectrum antibiotic prophylaxis and undergo a full-bowel preparation pre-operatively, as it is helpful to have the colon empty when the washouts are first commenced.

Figure 59.1, 59.2

The patient is placed supine on the operating table. The caecum is mobilized, the tip of the appendix is amputated and a stay suture is inserted in the open end to apply traction. A 10–12 Ch catheter is passed via the appendix into the caecum, to confirm that it is catheterizable. The stretched mesentery is inspected and fenestrated between the vessels. This allows the caecum to be wrapped around the appendix through the mesenteric windows, to produce the continence mechanism, without compromising the blood sup-

ply. Stay sutures are inserted into the caecum alongside the anterior taenia to keep it under tension whilst a submucosal tunnel is made. The serosa and muscle are initially incised using a diathermy and the trough is widened to expose the submucosa by spreading a mosquito artery forceps as one would perform a pyloromyotomy. It is important that this incision includes the base of the appendix as it allows this area to be buried in the caecum, reducing angulation and making catheterization easier.

Figure 59.3, 59.4

The appendix is folded along the length of the submucosal tunnel and the caecum is wrapped around it, as one would perform a Nissen fundoplication, to produce the continence mechanism. This is done using an absorbable 4/0 suture. The first suture is placed at the base of the appendix picking up the caecum–appendix–caecum to ensure that the appendix is firmly secured in the tunnel. This prevents movement and kinking and facilitates easy catheterization. Further sutures are progressively placed along the length of the appendix in a similar fashion, bringing the caecal wrap through the mesenteric windows

that were created earlier. The entire appendix is wrapped within the caecum until only a sufficient length is left to bring it out through the abdominal wall when the stoma is constructed. The antimesenteric end of the appendix is spatulated to allow a V-flap of skin to be inlaid during construction of the stoma to reduce the incidence of stomal stenosis. It is important to anchor the caecum to the posterior aspect of the anterior abdominal wall using absorbable sutures so it is not hanging on the appendix and at risk of torsion.

Figure 59.1

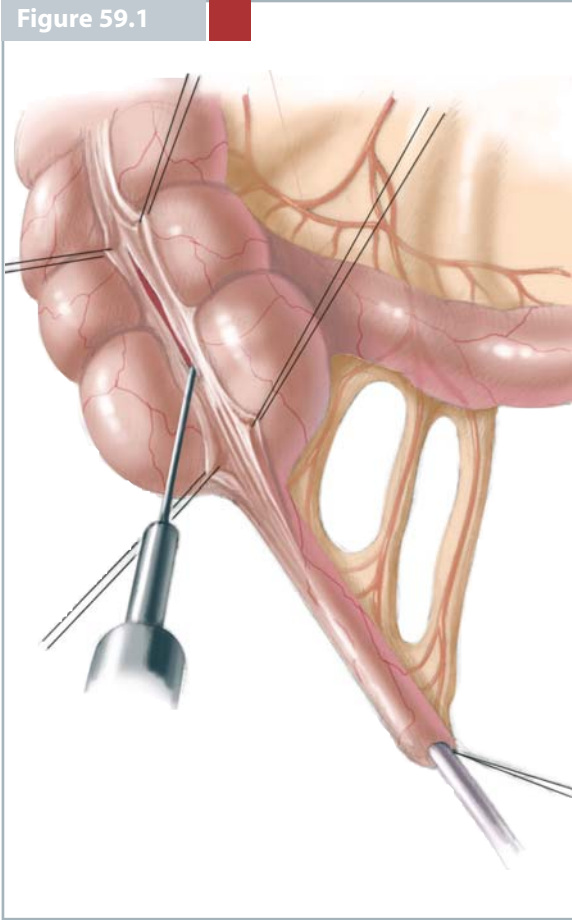


Figure 59.2

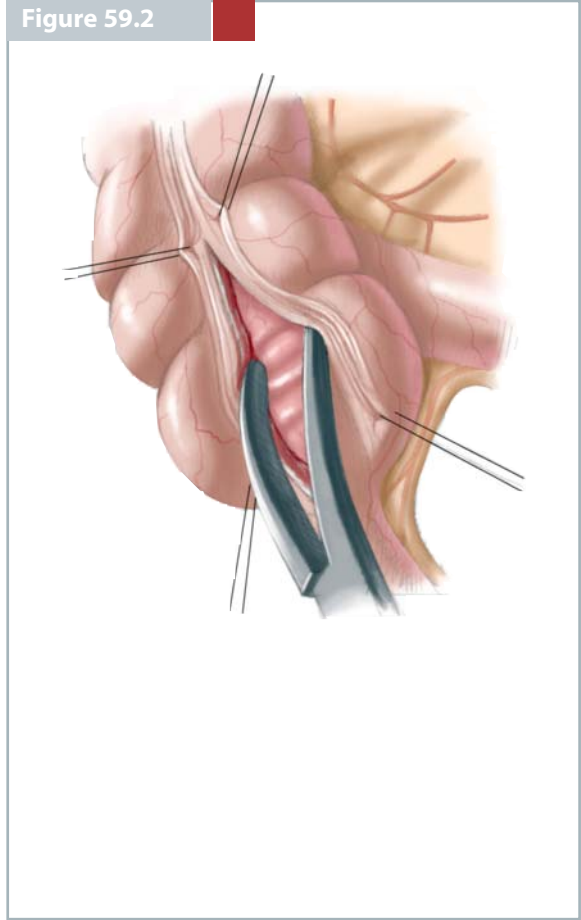


Figure 59.3

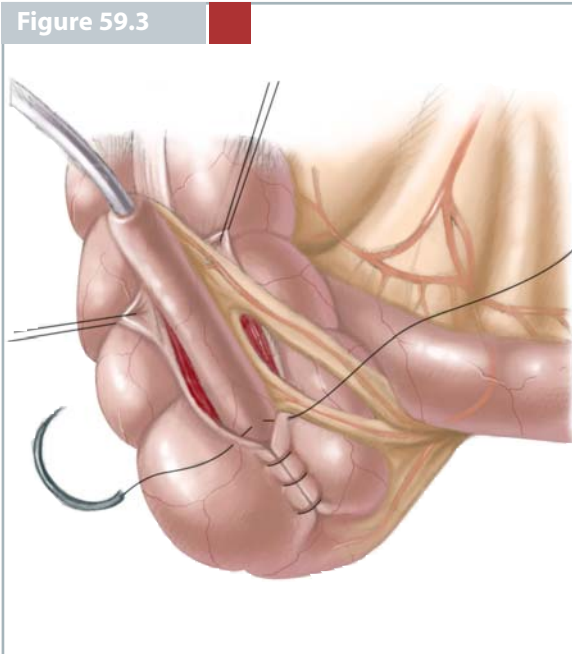


Figure 59.4

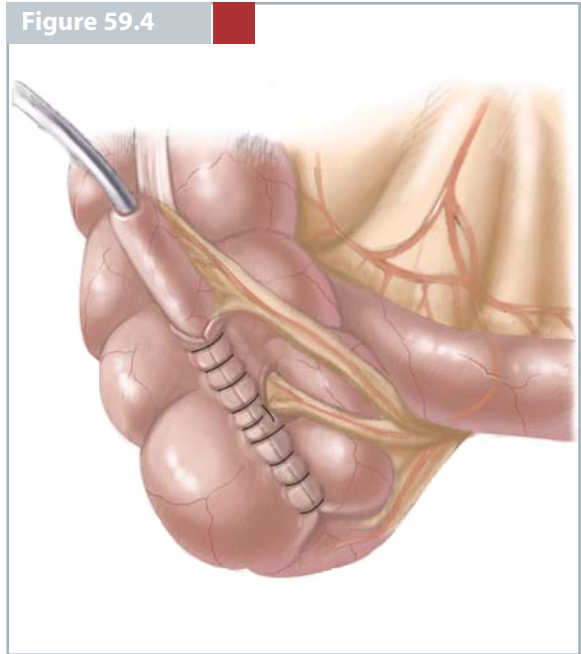


Figure 59.5, 59.6

The Monti ACE is required when the appendix is absent or required for a Mitrofanoff conduit or when a left colonic ACE is constructed. A 2-cm segment of ileum is isolated on its vascular pedicle. Straight non-crushing bowel clamps are applied to either end of the isolated segment and the bowel is then divided

using a knife. An end-to-end ileal anastomosis is performed using interrupted extramucosal 4/0 absorbable sutures and the mesenteric defect is closed. The bowel is detubularized by opening it along its anti-mesenteric border in the midline using scissors or diathermy.

Figure 59.7, 59.8

The Monti tube is constructed using a single layer of interrupted extra-mucosal 6/0 monofilament absorbable sutures over a 12 Ch catheter. Initially it is helpful to place stay sutures at either end and in the middle, in the region of the mesentery to keep the tube straight and under some tension. Care should be taken to ensure that the lumen of the conduit remains symmetrical throughout to avoid subsequent catheterisation difficulties. It is also helpful not to tu-

bularize the conduit all the way to the end where the stoma is to be constructed as this allows for a defect into which a V-flap of skin can be inserted in an attempt to reduce postoperative stomal stenosis.

Following completion of the conduit two segments are left at either side of the mesentery, one for insertion into the submucosal tunnel in the bowel and the other for bringing through the abdominal wall to the stoma.

Figure 59.5

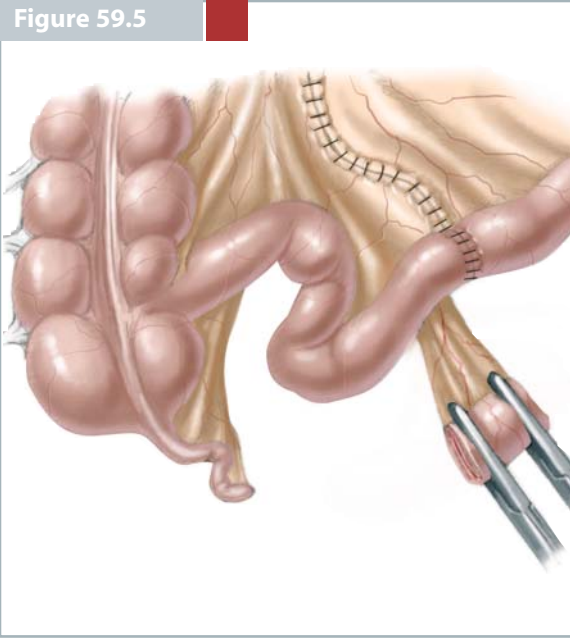


Figure 59.6

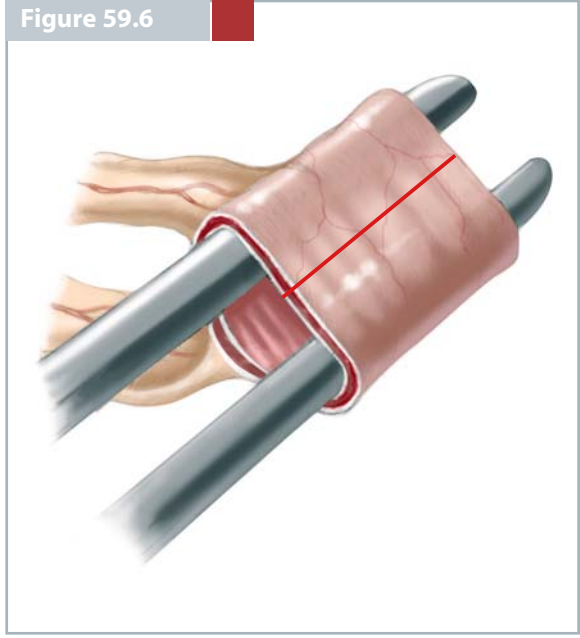


Figure 59.7

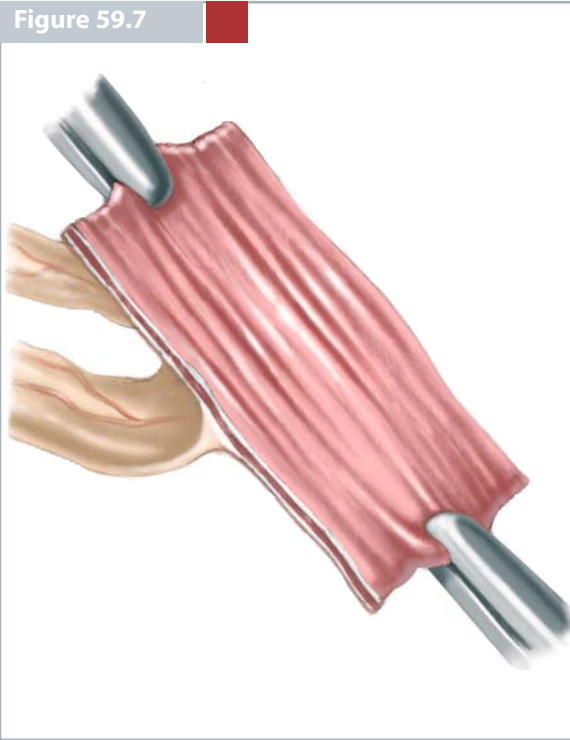


Figure 59.8

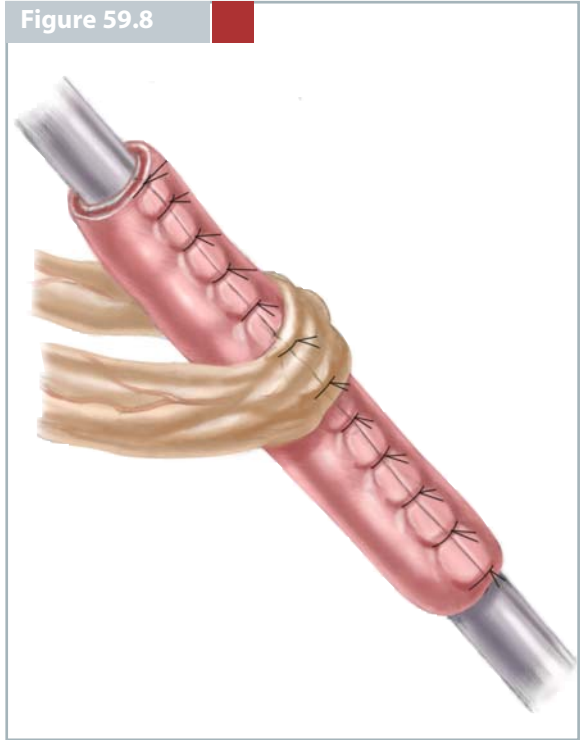


Figure 59.9, 59.10

The next step is to create the continence mechanism. At least four stay sutures are placed in the colon on either side of a suitably placed taenia. The seromuscular layer is divided using diathermy and the trough created is widened using mosquito artery forceps, until it is sufficiently wide to be able to close it over the Monti tube with no tension (*a*). The mucosa is opened at the end of this trough and the conduit is anastomosed to this, end-to-side fashion, using an absorbable suture (5/0). Following this anastomosis

it is important to check that the conduit remains easy to catheterize. The seromuscular layer is closed over the conduit using a 4/0 absorbable suture picking up each side of the colon and the conduit to ensure that it does not shift in the tunnel (*b*). It is vital to ensure that the vascular pedicle is not compromised during closure of the tunnel. The length of the conduit outside the tunnel should be just long enough to reach the skin of the abdominal wall.

Figure 59.11, 59.12

The stoma may be placed at any convenient place on the abdominal wall including the umbilicus. Irrespective of where the stoma is placed a V-flap of skin should be laid into the spatulated end of the conduit. In this chapter the more complex VQC stoma will be illustrated because studies have shown that it has a lower risk of developing stomal stenosis.

The skin flaps are initially marked. It is important to ensure that the centre of the V-flap directly over-

lies the fascial defect through which the conduit is brought. It is also important to ensure that the skin and abdominal wall are stretched at this stage using Kocker's forceps because if they are not the channel for the conduit may not be straight when the abdominal wound is closed. The Q- and V-flaps are then mobilized.

Figure 59.9

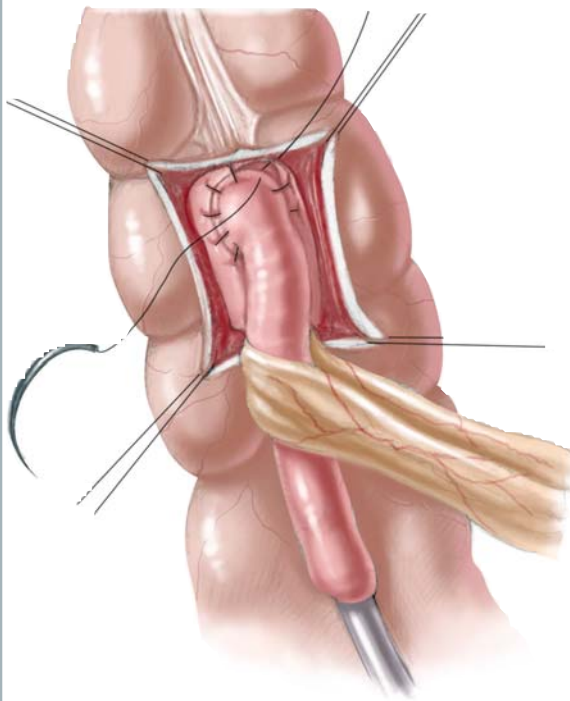


Figure 59.10

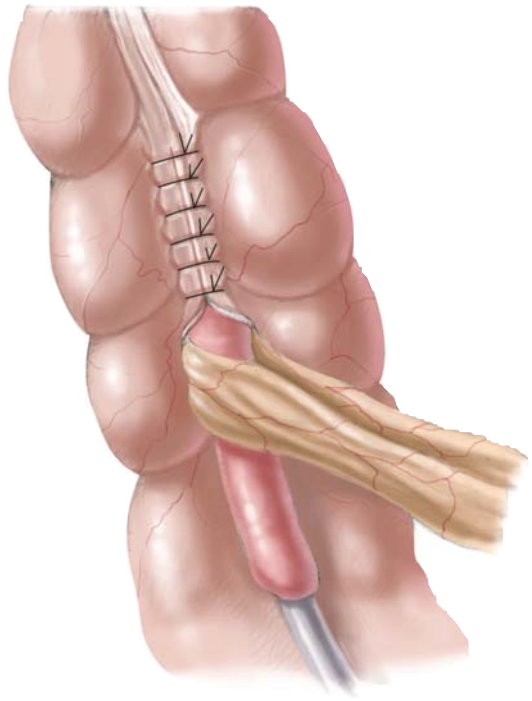


Figure 59.11

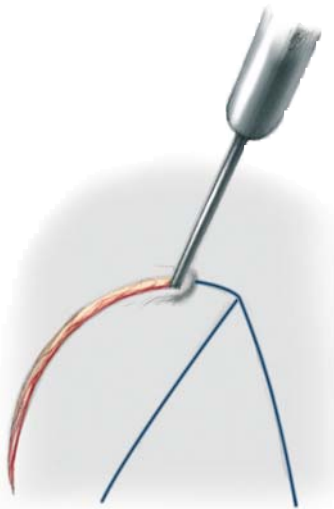


Figure 59.12

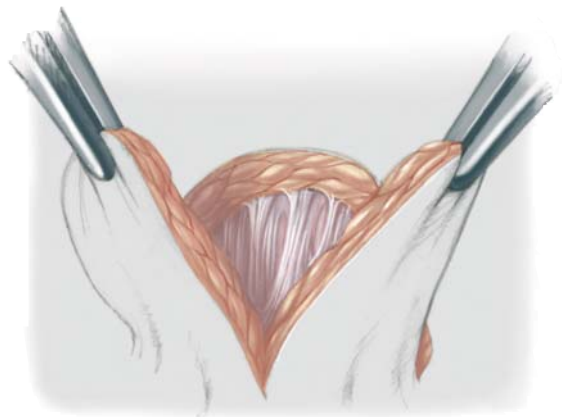


Figure 59.13, 59.14

The V-flap is sutured into the spatulated end of the conduit using an absorbable suture. The author favours interrupted 5/0 Maxon sutures as the needle is tapered, atraumatic and strong and goes through the skin easily; at the same time it does not damage and pull through the conduit. The knots are placed on the outside so they will not snag on the catheter as it is passed to test the conduit and stoma during its construction. It is vital to test the ease with which the conduit catheterizes after each separate step of its construction. The V-flap is sutured until there is

enough conduit left to anastomose the edge of the Q-flap to. The Q-flap is rolled over the anterior aspect of the conduit, anastomosing its inferior edge to the V-flap while its medial edge is anastomosed to the anterior margin of the conduit. This is best done with a 12–14 Ch catheter in place. The Q-flap is anastomosed to the whole of the anterior edge of the conduit and the superior defect between the Q and V-flaps is also closed with interrupted 5/0 absorbable sutures. This then leaves a C-shaped skin defect.

Figure 59.15

This defect is usually easy to close without tension by running a simple subcuticular 5/0 absorbable suture on a cutting needle. If there are abdominal scars following previous surgery it may be necessary to perform a relieving Z-plasty to facilitate tension-free closure.

The catheter is left in place for 4 weeks prior to the commencement of intermittent catheterisation but washouts can commence as soon as the patient has recovered from the post-operative ileus usually on day 5.

Figure 59.13

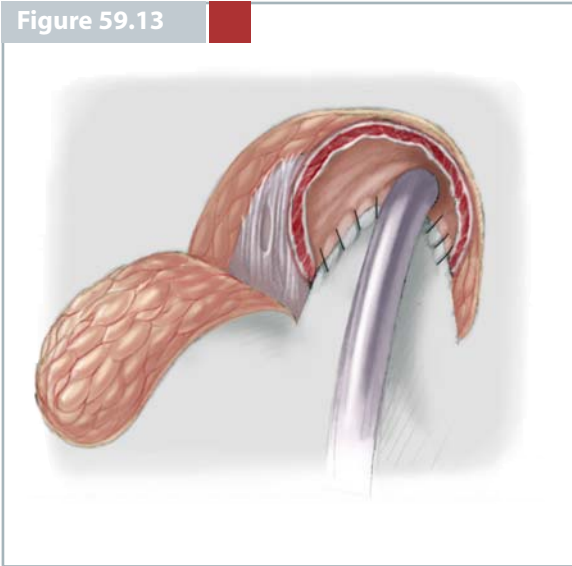


Figure 59.14

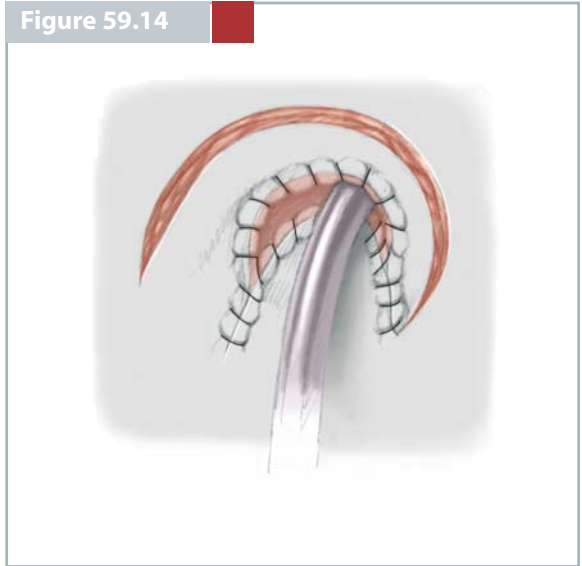
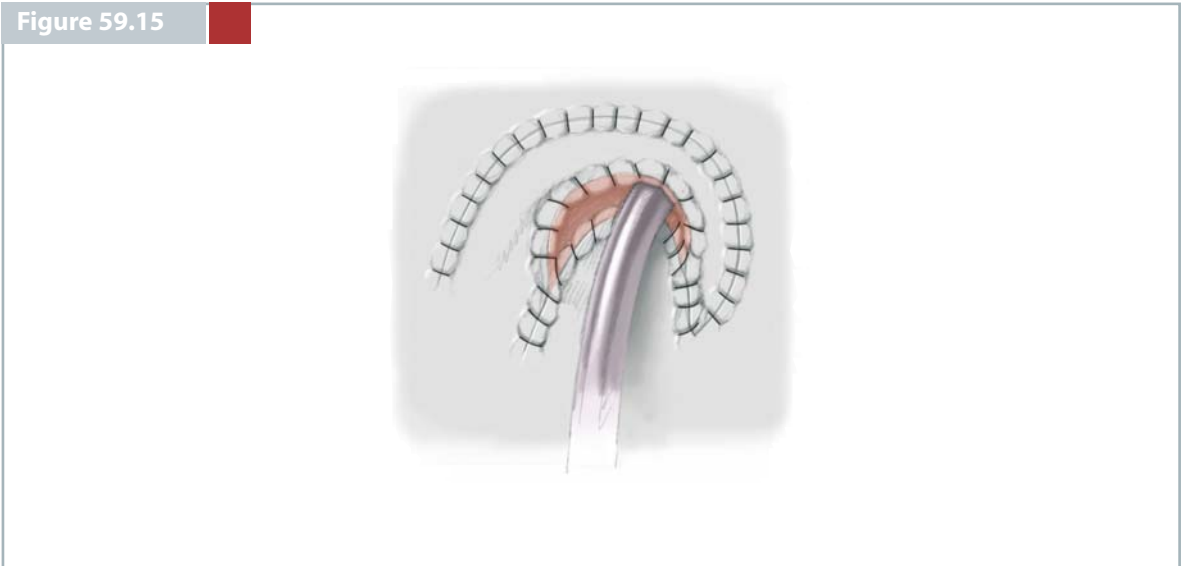


Figure 59.15



CONCLUSION

All conservative measures should be tried first before resorting to the ACE procedure. The underlying diagnosis is important as it influences the success rate. In the Southampton experience, patients with a neuropathic bowel or an anorectal malformation had a success rate of 73%, compared with 38% for patients with chronic idiopathic constipation. The age at operation is also important. In Southampton there was a 70% failure rate for patients under 5 years of age compared with 24% for those aged over 5 years. This difference was independent of the underlying diagnosis and probably reflected the inability of a child under 5 years of age to sit on a toilet for up to 1 h before emptying is complete.

Patient and caregiver motivation is vital in determining success. A lack of compliance with the washout regimen was a major contributory factor to failure in a number of series. Detailed pre-operative counselling and continued post-operative support, ideally provided by a nurse specialist, are essential to ensure adequate and continued motivation, without which the ACE is doomed to failure. It is an advantage to introduce the potential patient to a child and family with a functioning ACE prior to the surgical procedure. The initial therapeutic trial that has recently been introduced by the use of the percutaneously placed tube is a significant step forward as it enables the surgeon to test the family's motivation and their ability to cope with the regimen before proceeding to the definitive procedure. It also provides the opportunity of testing a number of washout regimens to see which one suits best.

The washout regimen is usually established by trial and error and it can take up to 6 months before a stable situation is reached. There are numerous different washout regimens in use around the world. In Southampton a phosphate enema is generally used. Initially 50 ml enema solution is diluted up to 100 ml with water and rapidly instilled and followed with approximately 500 ml water (in the original description saline was used but this is not necessary and it is

safe just to use tap water). The regimen is adjusted depending on the response; increasing/reducing the volume of phosphate and or water till a stable situation is reached. Care must be taken when using the phosphate as toxicity can occur if the enema is retained. Some units do not use a stimulant of any kind, simply relying on the washout using large volumes of water.

Several problems have been encountered during the establishment of the ACE. The most common is pain during the washout, which is reported in up to 60% of patients. This usually settles spontaneously during the first 3 months but can be helped by reducing the concentration of the phosphate, reducing the rate of the infusion or using an antispasmodic prior to the enema (Colofac, Solvary, UK). Despite regular washouts patients may still become constipated and this also produces pain and it should always be excluded. One of the other problems encountered is the time taken for the enema to pass and achieve a result and this has been a significant contributory factor to failure. The placement of the conduit in the distal descending colon has improved this situation considerably, with patients in whom the standard caecal ACE did not work achieving excellent results with the left colonic ACE.

The commonest operative complication encountered is stomal stenosis, which occurs in up to 30% of cases with half of these patients requiring revisional surgery. The VQC stoma described in this chapter has considerably reduced the incidence of stenosis. The site of the stoma and the type of conduit used makes no difference to the stenosis rate.

Despite all the problems associated with the ACE there is little doubt that it can achieve social continence and avoid a colostomy in patients with intractable incontinence, a situation that did not exist prior to the development of the ACE. It has also been shown to significantly improve patient's quality of life.

SELECTED BIBLIOGRAPHY

- Curry JL, Osborne A, Malone PSJ (1999) The MACE procedure: experience in the United Kingdom. *J Pediatr Surg* 34: 338–340
- Koyle MA, Malone PSJ (2001) The Malone antegrade continence enema (MACE). In: King LR, Belman AB, Kramer SA, (eds) *Clinical pediatric urology*, 4th edn. Martin Dunitz, London, Chap 18, pp 529–536
- McAndrew HF, Malone PSJ (2002) Continent catheterisable conduits. *BJU Int* 89: 86–89
- Shankar KR, Losty PD, Kenny SE, Booth JM, Turnock RR, Lamont GL, Rintala RJ, Lloyd DA (1998) Functional results following the antegrade continence enema procedure. *Br J Surg* 85: 980–982
- Wedderburn A, Lee RS, Denny A, Steinbrecher HA, Koyle MA, Malone PS (2001) Synchronous bladder reconstruction and ACE procedure. *J Urol* 163: 2392–2393