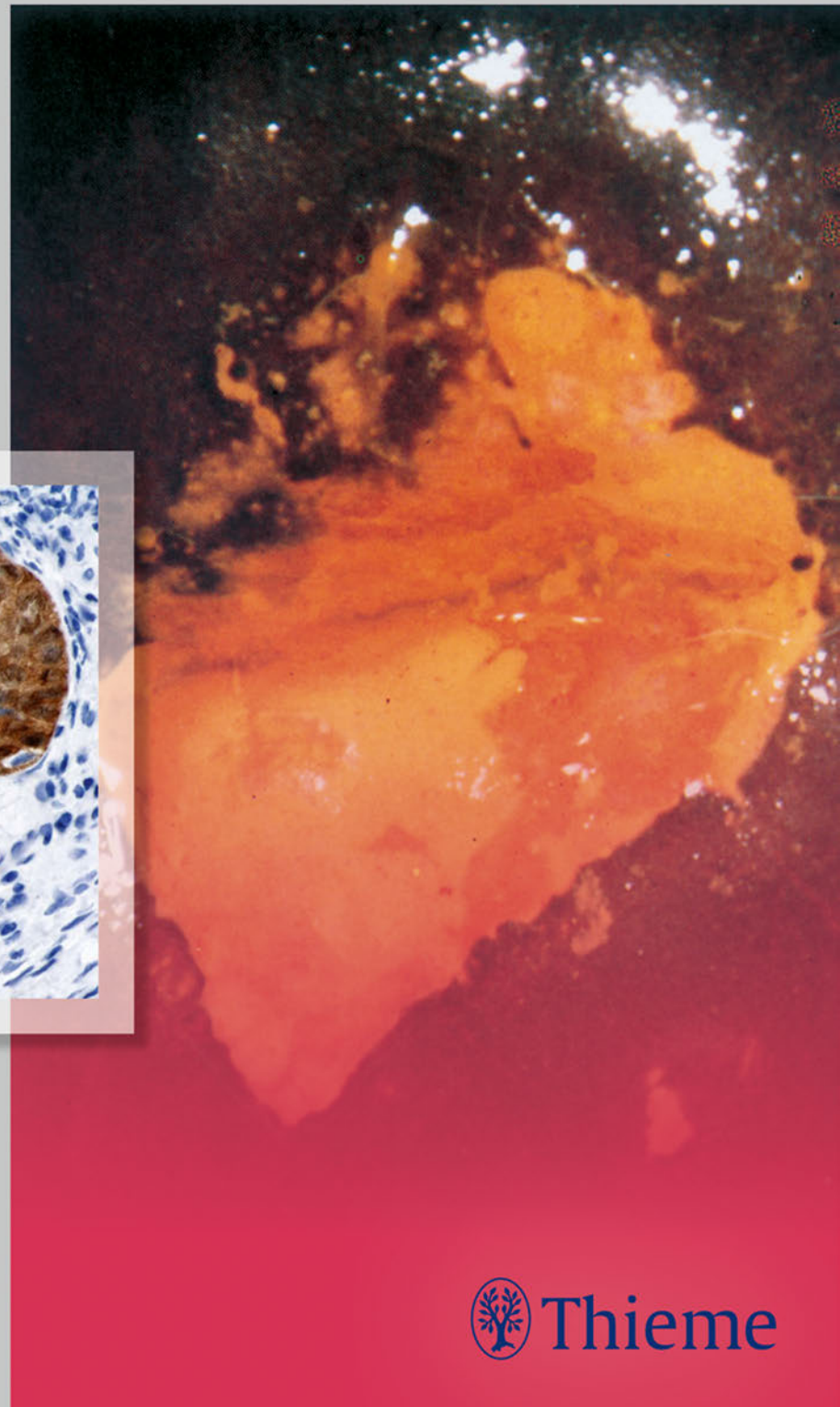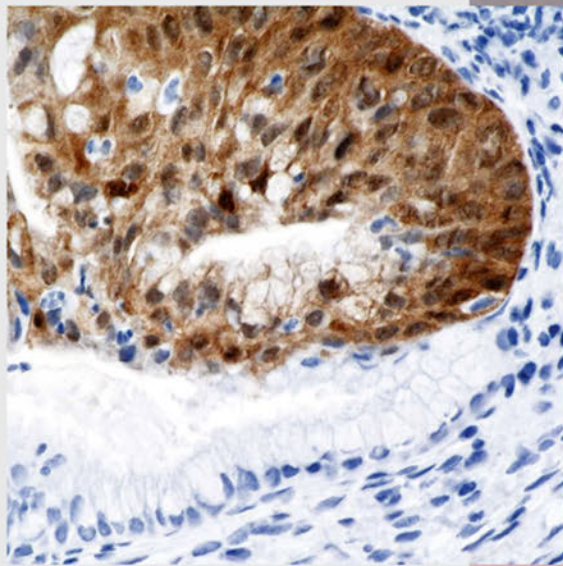


Burghardt's Colposcopy and Cervical Pathology

Textbook and Atlas

Frank Girardi
Olaf Reich
Karl Tamussino

4th Edition



Burghardt's Colposcopy and Cervical Pathology

Textbook and Atlas

4th Edition

Frank Girardi, MD

Department of Gynecology and Obstetrics
University of Graz
Graz, Austria

Olaf Reich, MD

Department of Gynecology and Obstetrics
University of Graz
Graz, Austria

Karl Tamussino, MD

Department of Gynecology and Obstetrics
University of Graz
Graz, Austria

Hellmuth Pickel, MD

Department of Gynecology and Obstetrics (formerly)
University of Graz
Graz, Austria

538 illustrations

Thieme

Stuttgart • New York • Delhi • Rio de Janeiro

Library of Congress Cataloging-in-Publication Data

Girardi, Frank, author.

Burghardt's colposcopy and cervical pathology : textbook and atlas / Frank Girardi, Olaf Reich, Karl Tamussino, Hellmuth Pickel. – 4th edition. p. ; cm.

Colposcopy and cervical pathology

Preceded by Colposcopy-cervical pathology / Erich Burghardt, Hellmuth Pickel, Frank Girardi ; translated by and with the collaboration of Andrew G. Östör and Karl Tamussino. 3rd rev. and enl. ed. 1998.

Includes bibliographical references and index.

ISBN 978-3-13-659904-4 (alk. paper) – ISBN 978-3-13-150471-5 (eISBN)

I. Reich, Olaf, author. II. Tamussino, K. (Karl), author. III. Pickel, Hellmuth, author. IV. Burghardt, E. (Erich). Kolposkopie, spezielle Zervixpatologie. English. Preceded by (work): V. Title. VI. Title: Colposcopy and cervical pathology.

[DNLM: 1. Cervix Uteri–pathology. 2. Cervix Uteri–pathology–Atlases. 3. Colposcopy–Atlases. 4. Colposcopy. WP 470]

RG107.5.C6

618.1'4075–dc23

2014019926

Translated by, and with the collaboration of:

Andrew G. Östör, MD

Karl Tamussino, MD

Important note: Medicine is an ever-changing science undergoing continual development. Research and clinical experience are continually expanding our knowledge, in particular our knowledge of proper treatment and drug therapy. Insofar as this book mentions any dosage or application, readers may rest assured that the authors, editors, and publishers have made every effort to ensure that such references are in accordance with **the state of knowledge at the time of production of the book.**

Nevertheless, this does not involve, imply, or express any guarantee or responsibility on the part of the publishers in respect to any dosage instructions and forms of applications stated in the book. **Every user is requested to examine carefully** the manufacturers' leaflets accompanying each drug and to check, if necessary in consultation with a physician or specialist, whether the dosage schedules mentioned therein or the contraindications stated by the manufacturers differ from the statements made in the present book. Such examination is particularly important with drugs that are either rarely used or have been newly released on the market. Every dosage schedule or every form of application used is entirely at the user's own risk and responsibility. The authors and publishers request every user to report to the publishers any discrepancies or inaccuracies noticed. If errors in this work are found after publication, errata will be posted at www.thieme.com on the product description page.

Some of the product names, patents, and registered designs referred to in this book are in fact registered trademarks or proprietary names even though specific reference to this fact is not always made in the text. Therefore, the appearance of a name without designation as proprietary is not to be construed as a representation by the publisher that it is in the public domain.

© 2015 Georg Thieme Verlag KG

Thieme Publishers Stuttgart

Rüdigerstrasse 14, 70469 Stuttgart, Germany

+49 [0]711 8931 421, customerservice@thieme.de

Thieme Publishers New York

333 Seventh Avenue, New York, NY 10001 USA,

1-800-782-3488, customerservice@thieme.com

Thieme Publishers Delhi

A-12, Second Floor, Sector -2, NOIDA -201301

Uttar Pradesh, India

+91 120 45 566 00, customerservice@thieme.in

Thieme Publishers Rio de Janeiro, Thieme Publicações Ltda.

Argentina Building 16th floor, Ala A, 228 Praia do Botafogo

Rio de Janeiro 22250-040 Brazil

+55 21 3736-3631

Cover design: Thieme Publishing Group

Typesetting by Thomson Digital, India

Printed in China by Everbest Printing Co.

5 4 3 2 1

ISBN 978-3-13-659904-4

Also available as an e-book:

eISBN 978-3-13-150471-5



This book, including all parts thereof, is legally protected by copyright. Any use, exploitation, or commercialization outside the narrow limits set by copyright legislation, without the publisher's consent, is illegal and liable to prosecution. This applies in particular to photostat reproduction, copying, mimeographing, preparation of microfilms, and electronic data processing and storage.

Contents

Preface to the Fourth Edition	ix
Preface to the First Edition	xi
Preface by the Translator to the First Edition	xiii
1 History of Colposcopy	2
2 Role of Colposcopy	6
2.1 Routine Colposcopy	6
2.2 Colposcopy to Evaluate an Abnormal Pap Smear ...	6
2.3 Colposcopy to Evaluate Patients Positive for HPV or Other Biomarkers	6
2.4 Colposcopy to Evaluate Abnormal Cytologic Findings during Pregnancy	6
2.5 Colposcopy to Evaluate Lesions before Treatment ..	6
2.6 Colposcopy in Screen-and-Treat Approaches in Resource-Poor Settings	6
3 Human Papillomaviruses and Cervical Cancer	10
3.1 Etiology of Cervical Cancer	10
3.2 Natural History of Cervical Cancer	10
3.2.1 Introduction	10
3.2.2 Phases of HPV Infection	12
Latent Phase	13
Permissive (Productive) Phase	13
Transforming Phase	14
3.3 Morphogenesis of Cervical Cancer	14
3.3.1 Morphogenesis of Squamous Cell Carcinoma in Metaplastic Epithelium	15
3.3.2 Morphogenesis of Squamous Cell Carcinoma in Original Squamous Epithelium	16
3.3.3 Morphogenesis of Adenocarcinoma	17
3.4 HPV Vaccines	17
4 Histology and Histopathology	24
4.1 Normal Findings; Reactive and Benign HPV-Related Changes	24
4.1.1 Normal Squamous Epithelium	24
4.1.2 Normal Columnar Epithelium and Ectopy	24
4.1.3 Metaplastic Squamous Epithelium and the Transformation Zone	24
Ectopy and the Last Gland	24
4.1.4 The Mechanism of Metaplasia and Transformation .	27
4.1.5 Vasculature of the Normal Cervix	27
4.1.6 Reactive Changes of Squamous and Columnar Epithelium	28
4.1.7 HPV-Infected Squamous Epithelium	29
4.1.8 Condylomatous Lesions	29
4.2 Premalignant Cervical Lesions	31
4.2.1 Histologic Terminology	31
Squamous Intraepithelial Lesions	31
4.2.2 A Brief History of the Terminology of Cervical Precursor Lesions	31
4.2.3 Glandular Intraepithelial Lesions (Adenocarcinoma in Situ)	32
4.2.4 Histology of Premalignant Cervical Lesions	32
Squamous Intraepithelial Lesions (SIL, CIN)	32
Atypical immature squamous metaplasia (AIM)	33
Adenocarcinoma in Situ	34
4.2.5 Biomarkers in Diagnosis of Cervical Precancer	34
HPV-DNA Testing	34
HPV E6/E7 mRNA Testing	35
HPV-DNA Genotyping	35
The L1 Capsid Protein	35
p16 ^{INK4a}	35
Other Potential Biomarkers	37
4.3 Invasive Cervical Cancer	38
4.3.1 Microinvasive Carcinoma	38
Early Stromal Invasion	38
4.3.2 Frank Invasive Cervical Cancer	41
Squamous Cell Carcinoma	42
Adenocarcinoma of the Cervix	44
Other Epithelial Tumors	46
4.4 Histology of Colposcopic Findings	46
4.4.1 Microscopic Versus Colposcopic Morphology	46
4.4.2 Topography and Extension of SIL (CIN)	46

Location of Dysplastic Epithelium with Respect to the Transformation Zone: the Last Gland	46	Acetowhite Epithelium (Thin, Dense)	53
Superficial Spread of SIL (CIN)	46	Inner Border Sign and Ridge Sign	53
Role of the Epithelium in Colposcopic Morphology	48	Erosion and Ulcer	53
4.4.3 Colposcopic Appearance of the Surface	49	Condylomatous Lesions	53
Sharp Epithelial Borders	50	4.4.4 Microinvasive Squamous Cell Carcinoma	56
Size and Extent of Dysplastic Epithelial Fields	50	4.4.5 Adenocarcinoma in situ and Microinvasive Adenocarcinoma	56
Leukoplakia (Keratosis)	50	4.4.6 Grossly Invasive Carcinoma	56
Mosaic and Punctation (Fine, Coarse)	50		
5 The Colposcope and the Colposcopic Examination	62		
5.1 Colposcopic Instruments	62	5.2.2 Chrobak's Probe	63
5.1.1 Specula	62	5.3 The Colposcopic Examination	63
5.1.2 Forceps	63	5.3.1 Application of Acetic Acid	64
5.1.3 Containers	63	5.3.2 Schiller (Iodine) Test	65
5.2 Biopsy Instruments	63		
5.2.1 Tenacula	63		
6 Teaching Colposcopy	72		
6.1 Understanding Colposcopic Findings	72		
7 Colposcopic Terminology	74		
8 Colposcopic Morphology	78		
8.1 Normal Colposcopic Appearances	78	8.3.4 Inflammatory Changes	114
8.1.1 Original Squamous Epithelium	78	8.3.5 Polyps	117
8.1.2 Atrophic Squamous Epithelium	78	8.3.6 Postconization Changes	120
8.1.3 Ectopy (Columnar Epithelium)	80	8.3.7 Changes Resulting from Prolapse	125
8.1.4 Transformation Zone	84	8.3.8 Endometriosis, Fistulas, Anatomic Anomalies	125
8.2 Abnormal Colposcopic Findings	90	8.4 Assessment of Colposcopic Findings	125
8.2.1 Acetowhite Epithelium	90	8.4.1 Benign Metaplastic Epithelium and Squamous Intraepithelial Neoplasia	127
8.2.2 Atypical Transformation Zone	94	8.5 Criteria for Differential Diagnosis	128
8.2.3 Mosaic	94	8.5.1 Sharp Borders	128
Fine Mosaic	94	8.5.2 Response to Acetic Acid (White Epithelium)	128
Coarse Mosaic	96	8.5.3 Surface Contour	129
8.2.4 Punctation	96	8.5.4 Cuffed Gland Openings	129
Fine Punctation	97	8.5.5 Blood Vessels	129
Coarse Punctation	98	8.5.6 Nonsuspicious Vascular Pattern	131
8.2.5 Leukoplakia (Keratosis)	98	8.5.7 Suspicious Vascular Pattern	131
8.2.6 Erosion, Ulcer	101	8.5.8 Atypical Vessels	131
8.2.7 Signs of Early Invasive Carcinoma	104	8.5.9 Surface Area (Size)	131
8.2.8 Invasive Carcinoma	107	8.6 Combinations of Abnormalities	131
8.2.9 Adenocarcinoma in Situ and Microinvasive Adenocarcinoma	110	8.6.1 Iodine Uptake	135
8.3 Miscellaneous Colposcopic Findings	110	8.6.2 Keratinization	135
8.3.1 Nonsuspicious Iodine-Yellow Area	110	8.6.3 Weighing Differential Diagnostic Criteria	137
8.3.2 Congenital Transformation Zone	110		
8.3.3 Condylomatous Lesions	112		

9	Colposcopy in Pregnancy	140		
9.1	Effects of Pregnancy on Colposcopic Findings	141	9.3	Suspicious Changes
9.1.1	Acetic Acid Test.....	141	9.4	The Puerperium
9.1.2	Schiller (Iodine) Test	141	9.5	Biopsy during Pregnancy
9.2	Benign Changes in Pregnancy	141		
10	Colposcopic–Histologic Correlation	154		
10.1	The Topography of Abnormal Colposcopic Findings	159		
11	Therapeutic Implications of Abnormal Colposcopic Findings	164		
11.1	Management of Benign Colposcopic Findings	164	11.2.3	Excisional Modalities: Loop Excision and Conization
11.1.1	Ectopy	164		Complete Excision.....
11.1.2	Normal Transformation Zone	164		Incomplete Excision
11.1.3	Metaplastic Epithelium with Leukoplakia, Punctation, or Mosaic	164		Repeat Conization.....
11.1.4	Condylomatous Lesions	164	11.2.4	Primary Hysterectomy
			11.2.5	Primary Medical Treatment of SIL
11.2	Treatment of Premalignant Cervical Lesions	164	11.3	Treatment of Microinvasive Carcinoma
11.2.1	Diagnostic Prerequisites	164	11.4	Follow-up after Treatment
11.2.2	Ablative Treatment of Squamous Intraepithelial Neoplasia (SIL).....	165		
12	Cervical Conization: Techniques and Histologic Processing of the Specimen	172		
12.1	Diagnostic Conization	172	12.3.4	Laser Cone Biopsy
12.2	Therapeutic Conization	172	12.3.5	Comparison of Loop Excision, Cold-Knife Conization, and Laser Cone Biopsy
12.3	Technique of Conization	172	12.4	Conization During Pregnancy
12.3.1	Loop Diathermy Excision	172	12.5	Histopathologic Processing of the Cone
12.3.2	Cold-Knife Conization.....	172		
12.3.3	Complications of Conization	173		
13	Colposcopy of the Vulva	182		
13.1	Histology of the Vulva	182	13.3.2	HPV-Independent Carcinogenesis
13.2	Diagnostic Methods for Evaluating Vulvar Lesions ..	183	13.4	Preinvasive Intraepithelial Lesions
13.2.1	History and Symptoms	183	13.4.1	Squamous Intraepithelial Lesions (SIL) and Differentiated-type Vulvar Intraepithelial Neoplasia (dVIN)
13.2.2	Inspection.....	183		Histologic Terminology and Classification
13.2.3	Palpation.....	183		Histology of SIL and dVIN
13.2.4	Toluidine Blue Test (Collins Test).....	183		Management of SIL and dVIN
13.2.5	Colposcopy of the Vulva	184		Surgical Therapy of SIL
13.2.6	Histologic Correlates of Colposcopic Findings	186		Medical Therapy of SIL
13.2.7	Biopsy	188		Therapeutic Vaccination
13.2.8	Exfoliative Cytology.....	188		Therapy of dVIN
13.2.9	HPV Testing	189	13.4.2	Paget Disease
13.3	Vulvar Carcinogenesis	189		Diagnosis
13.3.1	HPV–Dependent Carcinogenesis	189		Treatment.....

Contents

13.4.3	Intraepithelial Vulvar Melanocytic Lesions and Malignant Melanoma	199	13.5.2	Lichen Sclerosus	200
13.5	Non-Neoplastic	200	13.5.3	Lichen Planus	202
13.5.1	Epithelial Disorders of the Vulva	200	13.5.4	Psoriasis	204
			13.5.5	Lichen Simplex	204
			13.5.6	Vulvar Eczema	205
14	Colposcopy of the Vagina	208			
14.1	Histology	208	14.5	Histologic Terminology and Classification	211
14.2	Vaginal Carcinogenesis	208	14.6	Histomorphology of Vaginal SIL	211
14.3	Squamous Intraepithelial Lesions (SIL; formerly known as Vaginal Intraepithelial Neoplasia or VAIN)	208	14.7	Management of SIL	211
14.4	Diagnostic Methods for SIL	208	14.7.1	LSIL of the Vagina	211
14.4.1	History	208	14.7.2	HSIL of the Vagina	211
14.4.2	Colposcopy of the Vagina	208	14.7.3	Surgical Therapy	212
14.4.3	Cytology	210	14.7.4	Medical Therapy	212
14.4.4	Biopsy	210	14.7.5	Other Treatment Modalities	212
14.4.5	Biomarkers	210	14.8	Vaginal Melanoma	212
15	Colposcopy of the Perianal Region	216			
15.1	Anatomy and Histology	216	15.4.3	Biopsy	218
15.2	Anal Carcinogenesis	216	15.4.4	Biomarkers	218
15.3	Anal Intraepithelial Neoplasia	216	15.5	Histologic Terminology and Classification	218
15.4	Diagnostic Methods for AIN	217	15.6	Management of AIN	218
15.4.1	Colposcopy of the Anus (Anoscopy)	217	15.6.1	Surgical Therapy	218
15.4.2	Cytology	218	15.6.2	Medical Therapy	220
	Index	221			

Preface to the Fourth Edition

The 15 years between the publication of the third and fourth editions of this textbook and atlas have seen huge advances in our understanding of the pathogenesis of cervical neoplasia and specifically the role of human papillomavirus (HPV) infection. In 2008 Harald zur Hausen was awarded the Nobel Prize for Medicine for his work in elucidating the role of HPV in cervical cancer. The development and increasing application of HPV vaccines promises to further push back the scourge of cervical cancer, in developed countries and in the developing world. This understanding of the genesis of cervical neoplasia is leading to major changes in strategies for prevention, early detection, and treatment of this disease. The fourth edition of this textbook and atlas has been reworked accordingly.

Also, we have added new chapters on the vagina and the anus. This is in recognition of the common etiology of many of these lesions and of the fact that physicians should be alert to coexisting problems at sites in the vicinity.

This edition also incorporates the changes in colposcopic terminology agreed on at the 14th World Congress of the International Federation for Colposcopy and Cervical Pathology (IFCPC) in Rio de Janeiro in 2011 and the 2014 WHO *Classification of Tumours of Female Reproductive Organs*.

After Professor Erich Burghardt's death in 2006 we have incorporated his name into the title of the book. We are privileged to have worked with him and to build on his work. Our goal is to carry on his commitment to an atlas of the highest quality while incorporating the advances in the field and to provide a book that comprehensively addresses the fascinating dynamics of the cervix and the underlying histology and histopathology.

We thank Thieme Publishers and the Thieme Publishing Group for their ongoing support and commitment to the painstaking production of highest quality books and atlases.

We thank our families and particularly our spouses Ursula, Christine, Caroline, and Ulrike for their patience, understanding, and support.

*Frank Girardi, MD
Olaf Reich, MD
Karl Tamussino, MD
Hellmuth Pickel, MD*

*Graz, Austria
October 2014*

Preface to the First Edition

Routine colposcopy was instituted at the Graz Frauenklinik by my teacher Ernst Navratil in 1947. This date coincided with the introduction of cytologic diagnosis. In 1950, we acquired a modern surgical pathology laboratory devoted primarily to the study of early cervical cancer. Emphasis was placed on the examination of serial sections of ring biopsies and later of conization specimens. From the beginning of 1954 I had the opportunity to be at the forefront of these developments. Following a year of combined clinical and laboratory duties, I was appointed to the colposcopy outpatient clinic. Within two years I performed approximately 20,000 examinations. This experience was particularly valuable, as I also had the opportunity to interpret all the cytology smears and biopsies that I took. I also examined the serial sections from ring biopsies and conization specimens, not only for the first two years, but also for the following decades.

While accumulating knowledge and experience, I participated in the historic evolution of colposcopy, witnessing its hesitant beginning and later, especially during the last ten years, its story international course. The breakthrough was due, no doubt, to better international communication and exchange of ideas. Although textbooks as recently as 1960 have rejected colposcopy as "cumbersome and troublesome," its value is now undisputed. Controversies are centered merely on the indications for the colposcopic examination. While in Europe and South America colposcopy is accepted as an essential part of every gynecologic examination, in English-speaking countries its use is selective. This is due to the propagation of colposcopy not as a basic diagnostic modality, but as one which enables the taking of a directed target biopsy and consequently the avoidance of conization, a measure which is primarily cost-saving. During the last few years, colposcopy has found further application in the evaluation of vaginal adenosis and that of the seemingly more frequent condylomatous lesions. Colposcopy has thus become regarded as a special diagnostic tool; this was never intended. Typically, history repeated itself; as discussed later, some current concepts of morphogenesis of cervical carcinoma are mainly based on colposcopy, as envisaged by Hinselmann.

With colposcopy well established, every effort should be made to reinstate the method's original role and to reconcile it with the other means of diagnosis, in particular that of histology. This is the aim of this book. With the careful correlation of the colposcopic and histologic findings, it will be shown how easy it is to resolve seemingly difficult problems. The enormous scope for colposcopic research will also be demonstrated. The fact that cervical lesions

arise not only in histologically but also colposcopically recognizable and assessable fields with constant distributions leads us to discuss topics that are ignored or poorly discussed in the present colposcopic literature. It is hoped that in addition to its instructive value, this book will provide the stimulus for further study.

The future prospects for colposcopy have become clear during the last few years. Originally it was intended to devote a chapter to "functional colposcopy" to be written by Otto Baader. This undertaking was interrupted by the untimely death of this eminent colposcopist. He left, however, many photographs that he partly took with his unique equipment during a study leave at our clinic.

This book could not have been written without the assistance of my colleagues, all of whom I thank warmly. First of these is Dr. Hubert Schreithofer. He undertook the task of documenting colpophotographically every lesion on the cervix prior to conization, as well as a number of benign lesions. Most of the colpophotographs reproduced here have come from this collection. The fascinating job of correlating colposcopic and histologic findings in conization specimens was given to Dr. Wolf Dieter Schneeweiss. His schematic representation of the complex colposcopic and histologic findings is entirely original (Chapter 15). In the selection of the microphotographs, I had the valuable assistance of University Dozent Dr. Jürgen Hellmuth Pickel. And not the least, I would like to extend my special gratitude to the translator, Dr. Andrew Östör, who undertook this task with great expertise. He was confronted not only by the challenge of translating the German text into the best possible English, but also with the production of a text with scientific appeal to the English-speaking reader. It is thus more proper to refer to his as a collaborator, rather than merely a translator. Dr. Östör was also the first critical reader of the text. His observations and advice have also been incorporated into the German version. This collaboration between author and translator can only be regarded as unique.

Last but not least, my thanks go to all the staff of Georg Thieme Verlag, who are responsible for the realization of this book. They have troubled themselves to produce the best possible result.

*Erich Burghardt
Graz, Austria
January 1984*

Preface by the Translator to the First Edition

I entered the field of gynecologic pathology in 1973 when the English version of Burghardt's classic monograph "Early Histological Diagnosis of Cervical Cancer" (Thieme, Stuttgart and Saunders, Philadelphia 1973) was published. I first met Erich Burghardt in 1977 in Graz during a study tour and I spent several months in his department in 1979–1980. Our collaboration produced a recent article (Burghardt, E., A. G. Östör: Site and origin of squamous cervical cancer: a histomorphologic study, *Obstet. Gynec.*).

The idea of translating this book arose in October 1982 when Professor Burghardt was a guest lecturer in Sydney. It may be asked why, not being a professional translator, I undertook this arduous task. I believe this book makes a fundamental contribution to the practice of colposcopy and to its histopathologic basis. Colposcopy, introduced by Hinselmann some 50 years ago, has been largely ignored by English-speaking medical communities until recently. However, their new concepts have resulted in some unwarranted and unwelcome trends in the practice of colposcopy. This book will restore the balance.

It will be shown that the role of colposcopy is not to predict the histologic diagnosis, but to delineate the extent of the lesion on the cervix and to select the best area for biopsy. The colposcope cannot replace the microscope for two major reasons. First, invasion, or at least microinvasion, cannot always be excluded by cytology and colposcopy. And second, the same colposcopic picture may be produced by different histologic changes, each of which may have different biologic significance. This fact, however, will be appreciated only if one performs colposcopy in the Burghardt way *routinely* on all patients. Through such a routine, it soon becomes clear that the well-known patterns of punctation, mosaic, and keratosis are frequently expressions of a completely benign but specific epithelial change, characterized microscopically by hyperkeratosis, parakeratosis, acanthosis, and elongated stromal papillae, alone or in combination which in German is designated "abnormes Epithel." Because the strictly translated term "abnormal epithelium" does not distinguish between the benign and the premalignant, no equivalent term has found its way into the English colposcopic and pathologic literature, which dismiss it merely as "metaplastic." Furthermore, English-speaking colposcopists do not recognize the significance of this type of epithelium because selection of patients ensures that there is no opportunity to study colposcopically the cervixes of women with normal smears, in whom such epithelium is frequent.

Neither the term "abnormally differentiating epithelium" suggested in the aforementioned monograph (Burghardt 1973) nor the appellation "abnormally maturing epithelium" used in our article (Burghardt and Östör 1983) overcome the problem associated with the word "abnormal." The designation "acanthotic epithelium" employed in this book was proposed by Professor Richard Kempson of Stanford University, California, during an animated conversation between him, the author, and the translator. This

term is again not ideal, as acanthotic epithelium, while always acanthotic, frequently also shows parakeratosis or keratinization. However, it avoids premalignant connotation and is established in dermatology.

Acanthotic epithelium provides the key to the understanding of the discrepancy between colposcopic and histologic diagnosis, and obviates the hypothesis of premalignant colposcopic changes pre-dating those of histology (Stafl, A., R.F. Mattingly: Angiogenesis of cervical neoplasia. *Obstet. Gynec.*).

The importance of conization is also stressed. This procedure has attracted notoriety during the last two decades because of indiscriminate use and alleged complications. In English-speaking countries it has been largely superseded by so-called conservative, superficial ablative methods. It will be seen, however, that if carried out for the correct indications and by competent physicians, the complication rate is acceptable. Furthermore, only a cone biopsy (properly processed and examined) provides full assessment of all the histopathologic changes in the cervix. All other therapeutic measures destroy the tissues. The drawback of target biopsies as opposed to cone biopsy is that "'tis but a part we see, and not a whole" (Alexander Pope).


This book is the culmination of a lifetime devoted to the study of preinvasive and early invasive carcinoma of the cervix. Professor Burghardt has succeeded in bridging the ever-increasing gap between the laboratory and the bedside, having had rigorous training in all the disciplines required for this purpose: cytology, surgical pathology, colposcopy, and gynecology. It is little appreciated that it was he who first attributed diagnostic importance to aceto-white epithelium (Burghardt, E.: Über die atypische Umwandlungszone. *Geburtsh. u. Frauenheilk.*).

I am indebted to Dr. Ruth Davoren, cytopathologist at the Royal Women's Hospital, Melbourne, and Dr. Vernon Hollyock, the doyen of colposcopists in this city, both of whom have read the translation and made numerous valuable suggestions. My mother, Mrs. Magdalena Östör, has helped with the German language, and to her I am grateful. The final responsibility of course is mine, and I hope I have avoided the pitfalls epitomized by the French savant who compared translations with women: "Lorsqu'elles sont belles, elles ne sont pas fideles." My thanks, also, to Mrs. Kathleen Cassidy, whose expertise on the word processor made my task so much easier. Finally, I would like to express my gratitude to my wife Elizabeth and children Andrew, Jr., and Charlotte, who have kept their patience while I have often lost mine during the work's long gestation.

Andrew G. Östör
Melbourne, Australia

January 1984

Chapter 1
History of Colposcopy



1 History of Colposcopy

During much of the 20th century, cervical cancer was a scourge. In large parts of the world this remains the case, the disease often striking women younger than 40. In 1908, Friedrich Schauta in Vienna ended his monograph on radical vaginal hysterectomy for cervical cancer on the note that “the early detection of uterine cancer is the greatest challenge facing future generations of academic teachers and practicing physicians.”¹ In the same year, Howard Kelly in Baltimore wrote that “the only avenue open with certainty to progress today lies in the direction of discovering our cases of cancer at an earlier stage in the disease.”² Physicians battling this disease appreciated the importance of early detection, but did not know how to get there.

In 1924, a German gynecologist working on a chapter on uterine cancer for Veit and Stoeckel's *Handbook of Gynecology*³ was struck by the inadequacy of palpation and unaided visual examination for the early diagnosis of cervical cancer. Hans Hinselmann (1884-1959) thought this could be improved with magnification, a strong light source, and binocular vision. He built and described the first colposcope in 1925⁴ and coined the term “colposcopy.”⁵ At a time when 4-cm cervical cancers were considered early, the colposcope could visualize considerably smaller lesions, even in a grossly normal cervix. Hinselmann described the acetic acid test to evaluate columnar epithelium, the normal transformation zone, and atypical changes in the transformation zone. The acetic acid test was used in conjunction with the iodine test, described by Walter Schiller (1887-1960) in 1929.^{6,7,8} Hinselmann described punctation, leukoplakia, and diverse mosaic patterns. He called these colposcopic findings matrix areas and considered them potentially malignant. Later in the 20th century, Hinselmann was associated with the crimes of the Nazi regime when it emerged that specimens obtained without consent from inmates in Auschwitz were sent to his laboratory in Hamburg.^{9,10} We, the authors of this book, feel that Hinselmann's work in the development of colposcopy before the war needs to be acknowledged, but we have not cited later publications.

Colposcopy initially failed to gain wide recognition. Early instruments were cumbersome. Also, colposcopy consisting only of magnification, without application of acetic acid or iodine, was unsatisfactory. In addition, colposcopists repeatedly attempted to establish pseudohistologic nomenclatures for colposcopic findings, failing to appreciate that histologic nomenclature requires microscopic findings. This, at times, resulted in more confusion than clarity.⁷

Colposcopy was used first in Germany, Switzerland, and Austria (Anderes 1936, Wespi 1938, Mestwerdt 1939, Treite 1942) and South America.^{11, 12,13} In the early 1930s, Alfredo Jakob from Buenos Aires promoted its use in Argentina and Brazil (Jürgens 1933, Jakob 1939, Rieper 1941).

In the English-speaking world colposcopy was first studied in the early 1930s (Emmert 1931, Ries 1932)¹² but spread slowly. A barrier to the spread of colposcopy was the lack of easily reproducible teaching materials such as colpophotographs, which became available in the 1950s. Colpophotography was first described by Creer and Bruner et al in 1936 and Treite in 1941; Galloway published a small atlas in 1938.^{11,12} Satisfactory colpophotographs were facilitated by the advent of zoom lenses and electronic flash. In the following years Ganse, Schmitt, and

Menken contributed many improvements in colpophotography. In France, Bret and Coupez, in Scandinavia, Koller and Kolstad were protagonists.¹² Today, videocolposcopy can easily and vividly demonstrate and document colposcopic images.

Interest in colposcopy renewed in the 1950s in Austria (Navratil, Bajardi and Burghardt in Graz^{14,15,16,17}; Antoine¹⁸ in Vienna), Germany (Ganse, Limburg,¹⁹ Mestwerdt²⁰), Switzerland (Wespi,²¹ Held²²), France (Palmer, Funck- Brentano, De Watteville, Bret, Coupez), Italy (Cattaneo, De Palo), and Spain (Martinez de la Riva).

Colposcopy started in earnest in the United States in the 1960s. For a long time colposcopy in the United States was recognized only to clarify cytologic findings and encountered firm resistance because it was considered a technique that competed with cytology. Scheffey^{23,24} and Schmitt²⁵ were the first American authors to report on the technique. Adolf Štafl, a 1968 emigrant from Czechoslovakia, won an international reputation for cervicography, a kind of colpophotography.²⁶ Others who promoted colposcopy in the United States in the 1960s were Richart,²⁷ Burke,²⁸ Townsend,²⁹ Wilbanks,³⁰ and Scott.³¹ In Australia, colposcopy was introduced in the 1960s by Coppleson, Pixley,³² and Reid.³³ In the United Kingdom, colposcopy was promoted by Jordan³⁴ from Birmingham and Singer³⁵ from Oxford. In Scandinavia, Per Kolstad was a pioneer.³⁶

The International Federation for Cervical Pathology and Colposcopy (IFCPC) was founded at a meeting in Mar del Plata, Argentina, in 1972 through the initiative of the leading colposcopist in the country, Di Paola.¹³ The first president of the IFCPC was Erich Burghardt (1921–2006) from Graz, Austria.³⁷ The IFCPC, which now includes more than 30 national societies, strove to develop and maintain an internationally valid nomenclature for colposcopy and colposcopic findings.

The discipline of cytology, epitomized by the classic monograph of Papanicolaou and Traut,³⁸ revolutionized the early diagnosis of cervical cancer and thereby quashed interest in colposcopy. Cytology rapidly gained acceptance in the Anglo-Saxon world, where it was the only method for detecting early cervical cancer, as well as in Europe. Colposcopy was expected to be entirely replaced by cytology, which was simpler and more practical. That this did not happen is due to studies showing that the techniques should be used to complement one another. The names of Mestwerdt,²⁰ Limburg,¹⁹ Wespi,²¹ Navratil,^{14,15,16,17} and Held²² come to mind. These men championed colposcopy as a method that allowed direct observation of the site of developing cancer, something that cytology alone cannot do. Experience showed that high-quality cytology is the more accurate of the two methods. This is because about 15% of carcinomas develop exclusively in the endocervical canal, out of reach of the colposcope. Detailed studies, especially those from Graz between 1954 and 1960, showed that the best results were achieved by combining the two methods.^{14,15,16,17}

Today, colposcopy is used primarily to evaluate the diverse changes elicited by human papillomavirus (HPV) infection. Many of these changes, with the exception of simple condylomas, correspond to what used to be known as matrix areas.^{4,7}

Colposcopy succeeded because it closed a diagnostic loophole. Cytology detected an abnormality but not its location. Colposcopy can direct a biopsy to a suspicious area and reduce the

number of conizations. Today, in the era of HPV and molecular diagnostics, colposcopy continues to play a central role in the evaluation of women with lesions of the lower genital tract and in the worldwide fight against cervical cancer.

References

- [1] Schauta F. Die erweiterte Totalexstirpation des Uterus bei Kollumkarzinom [Extended vaginal extirpation of the uterus for cervical cancer]. Vienna: Josef Safar, 1908
- [2] Kelly H. Medical Gynecology. Appleton: New York, 1908
- [3] Hinselmann H. Die Ätiologie, Symptomatologie und Diagnostik des Uteruscarcinoms [Etiology, symptomatology, and diagnosis of uterine cancer] In: Veit J, Stoeckel W, eds. Handbuch der Gynäkologie [Handbook of Gynecology] Vol. 6/1 München: Bergmann, 1930
- [4] Hinselmann H. Verbesserung der Inspektionsmöglichkeiten von Vulva, Vagina und Portio. [Improved inspection of the vulva, vagina and portio] Munch Med Wochenschr 1925; 72: 1733
- [5] Hinselmann H. Einführung in die Kolposkopie [Introduction to Colposcopy]. Hamburg: Hartung, 1933
- [6] Schiller W. Jodpinselung und Abschabung des Portioepithels. [Iodine staining and scraping of the epithelium of the portio] Zbl Gynäkol 1929;53:1056–1064
- [7] Schiller W. Zur klinischen Frühdiagnose des Portiokarzinoms [On early clinical diagnosis of cervical cancer] Zbl Gynäkol 1928; 52: 1886–1892
- [8] Gruhn JG, Roth LM. History of gynecological pathology. V. Dr. Walter Schiller. Int J Gynecol Pathol 1998; 17: 380–386
- [9] Lifton RJ. The Nazi Doctors. New York: Basic Books, 1986
- [10] Lang H-J. Die Frauen von Block 10 – Medizinische Versuche in Auschwitz [The women from Block 10 – medical experiments in Auschwitz]. Hamburg: Hoffmann und Campe, 2011
- [11] Dexeus S, Carrera JM, Coupez F. Colposcopy. In: Friedman E.A.: Major problems in Obstetrics and Gynecology (Volume 10) Philadelphia: Saunders, 1977
- [12] Wespi HJ. 50 years colposcopy. A retrospective and a look ahead. Ann Ostet Gynecol Med Perinat 1988; 109: 319–350
- [13] Di Paola GR. History of the International Federation of Cervical Pathology and Colposcopy. Lecture at the XIII Congress of IFPCPC, Auckland, New Zealand 2008 (www.ifcpc.org)
- [14] Bajardi F, Burghardt E. Ergebnisse der Früherfassung des Collumcarcinoms mittels Cytologie und Kolposkopie an der Universitäts-Frauenklinik Graz 1954. [Results of early detection of cervical cancer at the University Women's Hospital Graz] Arch Gynakol 1956; 187: 621–637
- [15] Navratil E, Burghardt E, Bajardi F, Nash W. Simultaneous colposcopy and cytology used in screening for carcinoma of the cervix. Am J Obstet Gynecol 1958; 75: 1292–1297
- [16] Navratil E, Bajardi F, Burghardt E. Weitere Ergebnisse der Krebsfährtsuche an der Univ.-Frauenklinik Graz [Further results of cancer detection at the University Women's Hospital Graz] Wien Klin Wochenschr 1959; 71: 781–783
- [17] Navratil E. Colposcopy. In: Gray LA, ed. Dysplasia, carcinoma in situ and microinvasive carcinoma of the cervix uteri. Springfield: Thomas, 1964
- [18] Antoine T. Why colpomicroscopy? Wien Med Wochenschr 1962; 112: 530–531
- [19] Limburg H. Die Frühdiagnose des Uteruscarcinoms [Early diagnosis of uterine cancer]. Stuttgart: Thieme 1956
- [20] Mestwerdt G. Atlas der Kolposkopie [Atlas of colposcopy]. Jena: Fischer 1953
- [21] Wespi HJ. Early carcinoma of the uterine cervix: pathogenesis and detection. New York: Grune and Stratton, 1949
- [22] Held E, Schreiner WE, Oehler I. Bedeutung der Kolposkopie und Cytologie zur Erfassung des Genitalkarzinoms. [Role of colposcopy and cytology for the detection of genital cancer] Schweiz Med Wochenschr 1954; 84: 856–860
- [23] Scheffey LC, Lang WR, Tatarian G. An experimental program with colposcopy. Am J Obstet Gynecol 1955; 70: 876–888
- [24] Scheffey LC, Bolten KA, Lang WR. Colposcopy, aid in diagnosis of cervical cancer. Obstet Gynecol 1955; 5: 294–306
- [25] Schmitt A. Colposcopy detection of atypical and cancerous lesions of the cervix. Obstet Gynecol 1959; 13: 665–671
- [26] Staff A. Cervicography: a new method for cervical cancer detection. Am J Obstet Gynecol 1981; 139: 815–825
- [27] Richart RM. Colpomicroscopic studies of the distribution of dysplasia and carcinoma in situ on the exposed portion of the human uterine cervix. Cancer 1965; 18: 950–954
- [28] Burke L, Antonioli D, Knapp RC, Friedman EA. Vaginal adenosis. Correlation of colposcopic and pathologic findings. Obstet Gynecol 1974; 44: 257–264
- [29] Townsend DE, Ostergard DR, Mishell DR, Hirose FM. Abnormal Papanicolaou smears. Evaluation by colposcopy, biopsies, and endocervical curettage. Am J Obstet Gynecol 1970; 108: 429–434
- [30] Wilbanks GD, Richart RM. Postpartum cervix and its relation to cervical neoplasia. A colposcopic study. Cancer 1966; 19: 273–276
- [31] Scott JW, Brass P, Seckinger D. Colposcopy plus cytology. Results in 1,100 patients. Am J Obstet Gynecol 1969; 103: 925–929
- [32] Östör AG, Farrell LM, Chanen W. Ellis Charles Pixley: a pioneer of colposcopy. J Low Genit Tract Dis 2003; 7: 44–46
- [33] Reid BL, Singer A, Coppleson M. The process of cervical regeneration after electrocauterization. I. Histological and colposcopic study. Aust N Z J Obstet Gynaecol 1967; 7: 125–135
- [34] Jordan JA. The diagnosis and management of premalignant conditions of the cervix. Clin Obstet Gynaecol 1976; 3: 295–315
- [35] Singer A. The uterine cervix from adolescence to the menopause. Br J Obstet Gynaecol 1975; 82: 81–99
- [36] Kolstad P. Carcinoma of the cervix, Stage 0. Diagnosis and treatment. Am J Obstet Gynecol 1966; 96: 1098–1111
- [37] Pickel H, Winter R. XXI. Erich Burghardt. Int J Gynecol Pathol 2008; 27: 258–264
- [38] Papanicolaou GN, Traut HF. Diagnosis of uterine cancer by the vaginal smear. New York: Commonwealth Fund, 1943

Chapter 2

Role of Colposcopy

2.1 Routine Colposcopy	6
2.2 Colposcopy to Evaluate an Abnormal Pap Smear	6
2.3 Colposcopy to Evaluate Patients Positive for HPV or Other Biomarkers	6
2.4 Colposcopy to Evaluate Abnormal Cytologic Findings during Pregnancy	6
2.5 Colposcopy to Evaluate Lesions before Treatment	6
2.6 Colposcopy in Screen-and-Treat Approaches in Resource-Poor Settings	6

2 Role of Colposcopy

Colposcopy is a diagnostic procedure to visualize the epithelia of the lower genital tract with magnification and adequate illumination. Application of acetic acid and Lugol's iodine (Schiller test) are useful parts of the examination. The aim of colposcopy is to identify and plan the treatment of premalignant (intraepithelial) diseases of the cervix, vagina, vulva, and perianal region. Worldwide, colposcopy is performed in different settings and for different indications. Training programs were introduced to produce competent colposcopists.¹ Competency in colposcopy avoids overtreatment and promises better patient outcomes.² Colposcopy can be applied in a variety of contexts.

2.1 Routine Colposcopy

We believe colposcopic inspection of the cervix should be an integral part of the gynecologic examination. Lesions are better seen when magnified and optimally illuminated. This is true for inflammatory lesions, condylomas, and polyps as well as for pre-invasive and early invasive neoplastic lesions. With practice, the colposcopist can react quickly and accurately detect visible lesions. Many believe colposcopy should not be used as a screening method where the likelihood of finding cancer precursors is low,³ but it is easy to combine colposcopy with routine cytology. The diagnostic accuracy of cytology and colposcopy can then be checked by performing a biopsy of colposcopically suspect findings. We believe this practice is superior to colposcopy restricted to evaluating abnormal smears because it can detect lesions missed by cytology. In contrast to cytology, colposcopy can localize suspicious lesions. If cytology is positive but the ectocervix and the vagina are normal, an endocervical lesion can be predicted. In this way, cytology can select patients for biopsy. Also, it is possible to direct a smear for cytology under colposcopic guidance so that a colposcopic lesion can be scraped directly with an Ayre spatula, or the endocervical canal can be sampled when there are no lesions on the ectocervix. There is also no doubt that the quality of cytology can be improved by the simultaneous use of colposcopy. Lastly, routine colposcopy facilitates an appreciation of the dynamic processes that occur at the cervix in the different phases of life. It is instructive to follow up on given patient over years.

2.2 Colposcopy to Evaluate an Abnormal Pap Smear

In many countries, colposcopy is used primarily to evaluate women with an abnormal Pap smear. In this setting, the goal is to identify and localize lesions suspected on the basis of abnormal cytologic findings. In a meta-analysis, the sensitivity of colposcopy for the detection of high-grade squamous intraepithelial lesion (HSIL) was 96%, with a specificity of 48%.⁴ Colposcopy is no substitute for histologic evaluation,^{5,6,7} and a biopsy should be taken from the area of the most clinically severe abnormality of any lesion.^{8,9}

2.3 Colposcopy to Evaluate Patients Positive for HPV or Other Biomarkers

Testing for high-risk types of human papillomavirus (HPV) is more sensitive for the detection of HSIL than cytology.¹⁰ The association between infection with high-risk types of HPV and HSIL and cervical cancer is so strong that HPV testing has become an important part of the management of women with borderline cytologic abnormalities. Furthermore, the detection of HPV after treatment for HSIL is an accurate predictor of relapse, significantly more sensitive than repeated cytology (see Chapter 3).

The limitation of HPV testing is that women who test positive for high-risk (HR) HPV carry only a only small risk of underlying high-grade squamous intraepithelial lesions (H-SIL) or cancer. Dual staining for p16^{INK4a}/Ki-67 increases specificity and maintained sensitivity for the diagnosis of HSIL or adenocarcinoma in situ (AIS) compared with testing for HR-HPV.^{11,12,13,14} Most experts agree that women positive for both high-risk HPV and p16^{INK4a}/Ki-67 should be referred for colposcopy to verify or rule out a lesion.

Because there is a strong evidence base that HPV testing is advantageous in primary screening of women aged 30 years or older,¹⁰ HPV screening may come to supplant cytologic screening. If this comes to pass, we will likely see a large number of women positive for high-risk HPV referred for colposcopic evaluation of the cervix.

2.4 Colposcopy to Evaluate Abnormal Cytologic Findings during Pregnancy

Colposcopy is safe in pregnancy and is performed with the intention of ruling out invasive cancer (see Chapter 9). Cumulative data suggest that expectant treatment of pregnant women with an abnormal Pap smear (i.e., delaying treatment of preinvasive changes until after pregnancy) is safe.^{15,16,17}

2.5 Colposcopy to Evaluate Lesions before Treatment

Colposcopy is performed before treatment of presumed intraepithelial lesions to exclude overt invasive cancer and define the extent of disease. Also, colposcopy is helpful to plan the extent of conization and reduce the risk of overly aggressive excisions in young patients (see Chapter 11).

2.6 Colposcopy in Screen-and-Treat Approaches in Resource-Poor Settings

In developing countries with high rates of mortality from cervical cancer, new algorithms for cervical screening are being tested.

These algorithms include high-risk HPV testing with consecutive colposcopy of HPV-positive women and immediate treatment if a lesion is detected.¹⁸

References

- [1] www.ifcpc.org/en/education
- [2] Ulrich D, Tamussino K, Petru E, Haas J, Reich O. Conization of the uterine cervix: does the level of the gynecologist's training predict margin status? *Int J Gynecol Pathol* 2012; 31: 382–386
- [3] Kyrgiou M, Tsoumpou I, Vrekoussis T et al. The up-to-date evidence on colposcopy practice and treatment of cervical intraepithelial neoplasia: the Cochrane colposcopy & cervical cytopathology collaborative group (C5 group) approach. *Cancer Treat Rev* 2006; 32: 516–523
- [4] Mitchell MF, Schottenfeld D, Tortolero-Luna G, Cantor SB, Richards-Kortum R. Colposcopy for the diagnosis of squamous intraepithelial lesions: a meta-analysis. *Obstet Gynecol* 1998; 91: 626–631
- [5] Massad LS, Collins YC. Strength of correlations between colposcopic impression and biopsy histology. *Gynecol Oncol* 2003; 89: 424–428
- [6] Hopman EH, Voorhorst FJ, Kenemans P, Meyer CJ, Helmerhorst TJ. Observer agreement on interpreting colposcopic images of CIN. *Gynecol Oncol* 1995; 58: 206–209
- [7] Etherington IJ, Luesley DM, Shafi MI, Dunn J, Hiller L, Jordan JA. Observer variability among colposcopists from the West Midlands region. *Br J Obstet Gynaecol* 1997; 104: 1380–1384
- [8] Gage JC, Hanson VW, Abbey K et al. ASCUS LSIL Triage Study (ALTS) Group. Number of cervical biopsies and sensitivity of colposcopy. *Obstet Gynecol* 2006; 108: 264–272
- [9] Underwood M, Arbyn M, Parry-Smith W et al. Accuracy of colposcopy-directed punch biopsies: a systematic review and meta-analysis. *BJOG* 2012; 119: 1293–1301
- [10] Arbyn M, Ronco G, Anttila A et al. Evidence regarding human papillomavirus testing in secondary prevention of cervical cancer. *Vaccine* 2012; 30 Suppl 5: F88–F99
- [11] Singh M, Mockler D, Akalin A, Burke S, Shroyer A, Shroyer KR. Immunocytochemical colocalization of P16(INK4a) and Ki-67 predicts CIN2/3 and AIS/adenocarcinoma. *Cancer Cytopathol* 2012; 120: 26–34
- [12] Donà MG, Vocaturo A, Giuliani M et al. p16/Ki-67 dual staining in cervico-vaginal cytology: correlation with histology, human papillomavirus detection and genotyping in women undergoing colposcopy. *Gynecol Oncol* 2012; 126: 198–202
- [13] Wentzensen N, Schwartz L, Zuna RE et al. Performance of p16/Ki-67 immunostaining to detect cervical cancer precursors in a colposcopy referral population. *Clin Cancer Res* 2012; 18: 4154–4162
- [14] Petry KU, Schmidt D, Scherbring S et al. Triaging Pap cytology negative, HPV positive cervical cancer screening results with p16/Ki-67 dual-stained cytology. *Gynecol Oncol* 2011; 121: 505–509
- [15] Coppola A, Sorosky J, Casper R, Anderson B, Buller RE. The clinical course of cervical carcinoma in situ diagnosed during pregnancy. *Gynecol Oncol* 1997; 67: 162–165
- [16] Frega A, Scirpa P, Corosu R et al. Clinical management and follow-up of squamous intraepithelial cervical lesions during pregnancy and postpartum. *Anticancer Res* 2007; 27 4C: 2743–2746
- [17] Woodrow N, Permezel M, Butterfield L, Rome R, Tan J, Quinn M. Abnormal cervical cytology in pregnancy: experience of 811 cases. *Aust N Z J Obstet Gynaecol* 1998; 38: 161–165
- [18] Deodhar K, Sankaranarayanan R, Jayant K et al. Accuracy of concurrent visual and cytology screening in detecting cervical cancer precursors in rural India. *Int J Cancer* 2012; 131: E954–E962

Further Reading

- Bosgraaf RP, Mast PP, Struik-van der Zanden PH, Bulten J, Massuger LF, Bekkers RL. Overtreatment in a see-and-treat approach to cervical intraepithelial lesions. *Obstet Gynecol* 2013; 121: 1209–1216
- Cantor SB, Cárdenas-Turanzas M, Cox DD et al. Accuracy of colposcopy in the diagnostic setting compared with the screening setting. *Obstet Gynecol* 2008; 111: 7–14
- Freeman-Wang T, Walker P. Colposcopy in special circumstances: Pregnancy, immunocompromise, including HIV and transplants, adolescence and menopause. *Best Pract Res Clin Obstet Gynaecol* 2011; 25: 653–665
- Leeson SC, Alibegashvili T, Arbyn M et al. The future role for colposcopy in Europe. *J Low Genit Tract Dis* 2014; 18: 70–78
- Moss EL, Arbyn M, Dollery E et al. European Federation of Colposcopy quality standards Delphi consultation. *Eur J Obstet Gynecol Reprod Biol* 2013; 170: 255–258
- Tatti S, Bornstein J, Prendiville W. Colposcopy: a global perspective: introduction of the new IFCPC colposcopy terminology. *Obstet Gynecol Clin North Am* 2013; 40: 235–250

Chapter 3
**Human Papillomaviruses and
Cervical Cancer**

3.1 Etiology of Cervical Cancer	10
3.2 Natural History of Cervical Cancer	10
3.3 Morphogenesis of Cervical Cancer	14
3.4 HPV Vaccines	17



3 Human Papillomaviruses and Cervical Cancer

3.1 Etiology of Cervical Cancer

In 1976, Harald zur Hausen found the DNA of human papillomaviruses (HPVs) in cervical cancers and genital warts.¹ In 1983, investigators in zur Hausen's laboratory established HPV 16 as the leading candidate in the etiology of preinvasive and invasive cervical neoplasia.² Many types of HPV have now been identified and associated with cervical cancer. HPV types are widely classified into low-risk and high-risk groups according to their ability to promote malignant transformation. HPV types 16, 18, 31, 33, 35, 39, 45, 51, 52, 56, 58, 59, 68, 73, and 82 are now classified as high-risk (HR) types. In contrast, HPV 6, 11, 40, 42, 43, 44, 54, 61, 70, 72, and 81 are rarely found in cervical cancer and are considered low-risk types. HPV types 26, 53, and 66 are considered to be of uncertain risk.³

Papillomaviruses have evolved over millions of years. They are a large and highly diverse group of small (diameter about 55 nm), cubic DNA viruses that infect epithelial tissues. As parasites, they use species-specific animals and humans for replication. In humans, 120 cutaneous or mucosal PV types (HPVs) have been described, based on the isolation of complete viral genomes.⁴ HPVs have a simple structure and are built of only a few proteins. The small circular genomes of about 8,000 base pairs are organized into a set of six early genes (*E6*, *E7*, *E1*, *E2*, *E4*, *E5*). These genes are involved in viral gene expression and replication control. Two late genes (*L1* and *L2*) encode the major capsid proteins. A noncoding region contains the origin of DNA replication as well as positive and negative transcription control elements. A central assumption of cervical carcinogenesis is that two of the early genes (*E6* and *E7*) can transform cervical epithelium. In an organotypic keratinocyte culture system, HPV 18 *E6/E7* expression significantly altered the expression of more than 1,300 cellular genes.^{5,6}

All types of cervical epithelia are vulnerable to HPV infection. The development of cervical cancer and its precursor lesions requires persistent infection with high-risk HPV. Woodman et al⁷ defined persistent infection as detection of the same HPV type twice in an interval of at least 6 months. This applies to both squamous and glandular neoplasia.⁸ Different HPV types probably differ in their target cell specificity. HPV 16 infection results in predominantly squamous neoplasia, whereas HPV 18 and HPV 45 have a greater tendency to induce glandular neoplasia.⁹ In general, the distribution of different HPV types varies with the severity of a lesion: HPV 16 and 18 increase in prevalence from low- to high-grade lesions. HPV 16 and 18 are generally acknowledged to cause about 70% of cervical cancers. Together with HPV 31, 45, and cofactors (i.e., smoking, immunodeficiency, genetic predisposition, high parity, early first intercourse, number of sexual partners, long-standing oral contraception, drug abuse, poor nutrition), they are the prime risk factors for cervical cancer.¹⁰ A worldwide survey of more than 10,000 cases showed that women with HPV 16, HPV 18, or HPV 45-positive cervical cancer are on average 5 to 9 years younger at the time of diagnosis than patients with other HR-HPV types.⁹ In Europe, HPV 16 predominates in both high-grade squamous intraepithelial lesion (HSIL) and invasive cancer, whereas HPV 18 and 45 are

associated with a lower median age at development of invasive disease.¹¹

It has been estimated that worldwide about 300 million women are infected by HPVs,⁹ although the majority of genital HPV infections remain asymptomatic. Genital HPV infection is transmitted almost exclusively through sexual and genital skin-to-skin contact. Most women acquire cervical HPV infection within a few years of initiating sexual intercourse.¹² Coinfection with more than one HPV genotype is common, especially in young women.^{13,14} Most HPV infections clear as a result of cell-mediated immune response. About 90% of women with HPV infection become HPV-negative within 2 years. The peak rate of HPV infection is seen in women younger than 25 years of age with a decline that plateaus around 30 to 35 years. In some countries, there is a slight increase in women aged 50-plus years,¹² which is considered a consequence of decreasing immune function with age or of changing sexual habits.

3.2 Natural History of Cervical Cancer

3.2.1 Introduction

HPVs infect epithelial basal cells (reserve cells), which have a progenitor cell function (► Fig. 3.1). They are responsible for the regeneration of the epithelium. Subcolumnar reserve cells enable metaplasia from columnar to squamous epithelium. Generally, reserve cells are characterized by expression of the p53 homolog p63 and cytokeratin 17 and presumably originate during embryonic development.^{15,16} Distribution patterns and marker profiles show two subpopulations of cervical reserve cells, which may indicate that one group serves as the reserve cell population for both squamous and columnar epithelium and the other as reserve cells for columnar epithelium only.¹⁷

HPV infection probably occurs when minor trauma (e.g., sexual intercourse) exposes the basal cells (reserve cells) of metaplastic squamous epithelium in the cervical transformation zone or columnar epithelium to the virus.¹⁸ Initial contact of HPV with the epithelium appears to occur at the basal membrane and to be mediated by proteoglycans.¹⁹ Attachment leads to a conformational change of HPV, resulting in binding to an as yet unknown cellular receptor in basal cells.²⁰ Uptake of HPV into the basal cells appears to be mediated by endocytosis.²¹ Upon release from the particle, the circular viral genome is transported to the nucleus, where it resides as an extrachromosomal molecule. Wound healing with lateral extension of replicating basal keratinocytes may be supportive of the establishment of initial HPV infection. Infection of basal cells results in persistence of episomal HPV genomes at low copy numbers.²² It is unclear how often basal cells become infected with HPV. According to the most widely accepted model, expression of viral genes in individual infected basal cells leads to lateral extension of the initially HPV-infected cell clone^{23,24} (► Fig. 3.2 a,b).

The time from initial HPV infection to the development of HSIL varies widely. Generally, persisting infection with HPV 16, 18, or

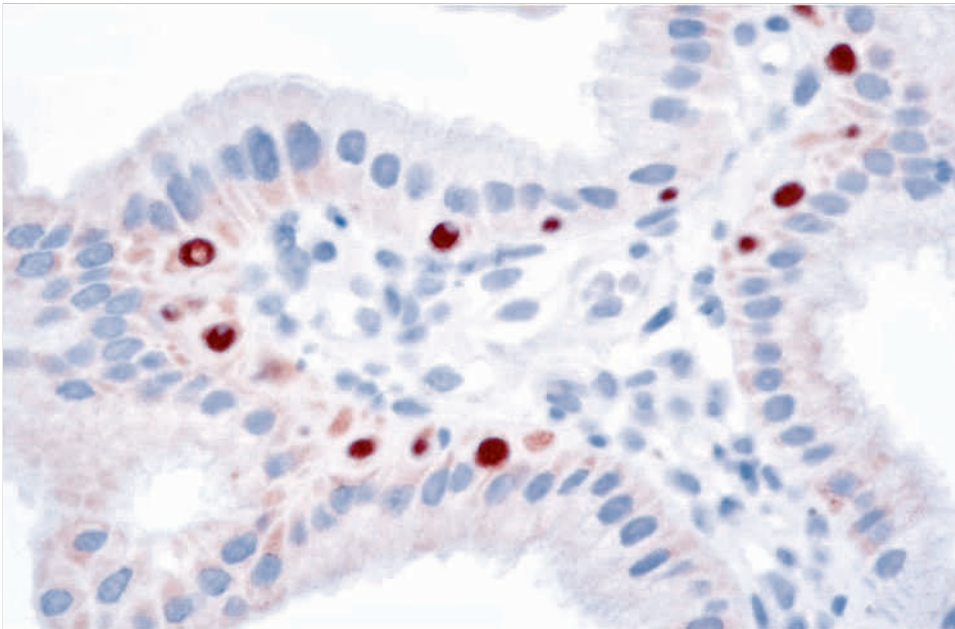


Fig. 3.1 Individual reserve cells in the basal layer of the columnar epithelium. The nuclei stain darkly for p63.

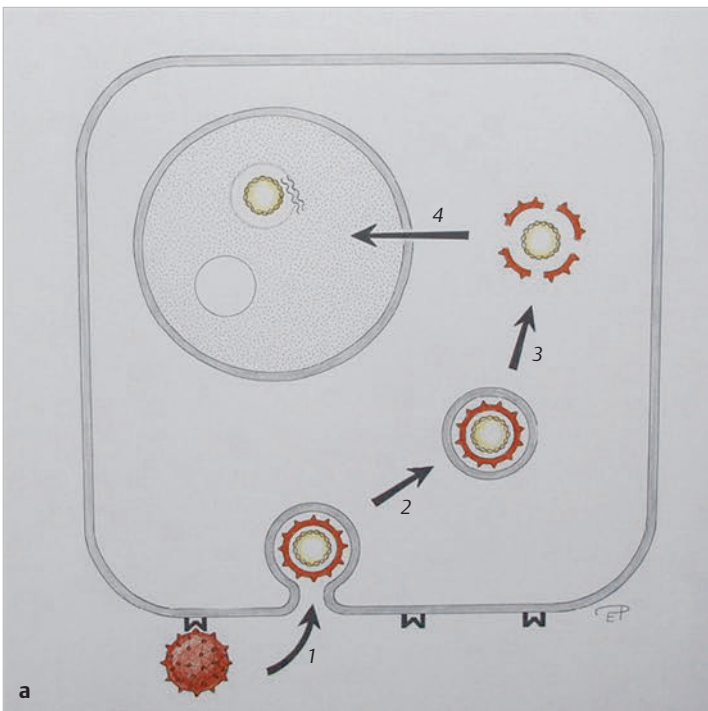
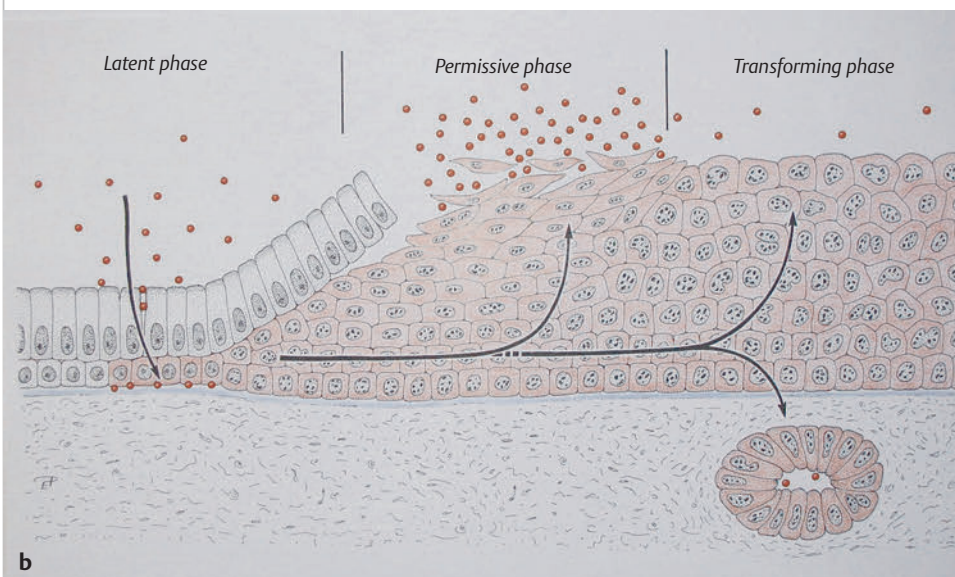


Fig. 3.2 a,b (a) HPV entry model: Uptake of HPV into the basal cells is mediated by endocytosis. Upon release from the particle, the circular viral genome is transported to the nucleus, where it resides as an extrachromosomal molecule.

(b) Schematic description of the three distinct phases of HPV infection at the cervix. Minor lacerations of the (columnar and/or squamous) epithelium permits contact of HPV with the cervical reserve (basal) cells. Upon viral uptake and transport to the nucleus, the HPV genome releases episomal in low copy numbers and without significant viral gene expression (latent phase)^{19,20,21} In some instances, low levels of viral gene expression occur and results in viral replication (permissive phase). Expression of early HPV genes is strictly limited to the basal cells. The late gene products permit packaging of the replicated viral genomes, and newly produced HPVs are released at the surface of the cervix. Morphologic effects are detectable as low-grade squamous intraepithelial lesions (LSIL). Particularly in the metaplastic epithelium of the transformation zone, viral gene expression may shift from the replication mode into the transforming mode with high-level expression of the early HPV genes E6 and E7 that trigger genomic instability of the host cell genome, which in turn permits aberrant mitosis and proliferation of atypical basaloid cells (transforming phase). Transforming infections cause HSIL and adenocarcinoma in situ (AIS).^{35,36,37,42,43,44,45,46,47}



45, entails a 20 to 30% risk for cervical intraepithelial neoplasia (CIN 3) over the next 5 years.^{25,26} However, some high-grade lesions, particularly with HPV 16 infection, develop quickly (i.e., 1 or 2 years after infection).^{27,28,29,30} Women with multiple HR HPV infections are at increased risk of high-grade lesions compared with women with single infections.¹⁴

Cervical cancer occurs rarely and late after exposure to HR HPV. The latency from initial HPV infection to invasive cancer is in the range of 8 years and more.^{31,32} HSIL correlates with a greater risk of progression to invasion than LSIL. Östör³³ reviewed the literature and compiled spontaneous regression in 57%, 43%, and 32% of cases of CIN 1, CIN 2, and CIN 3 lesions, respectively, and persistence in 32%, 35%, and 56%.

Only 1% of CIN 1 lesions and 5% of CIN 2 lesions, but more than 12% of CIN 3 lesions, progressed to invasive cervical cancer. In a retrospective cohort study by McCredie et al,³⁴ untreated CIN 3 had a 30% probability to become invasive over a 30-year period.

3.2.2 Phases of HPV Infection

HPV infections go through three distinct phases of viral gene expression: the latent phase, the permissive (productive) phase, and the transforming phase.²⁴ After intraepithelial neoplastic transformation, some HSIL and adenocarcinoma in situ (AIS) will progress to invasive cervical cancer (► Fig. 3.2).

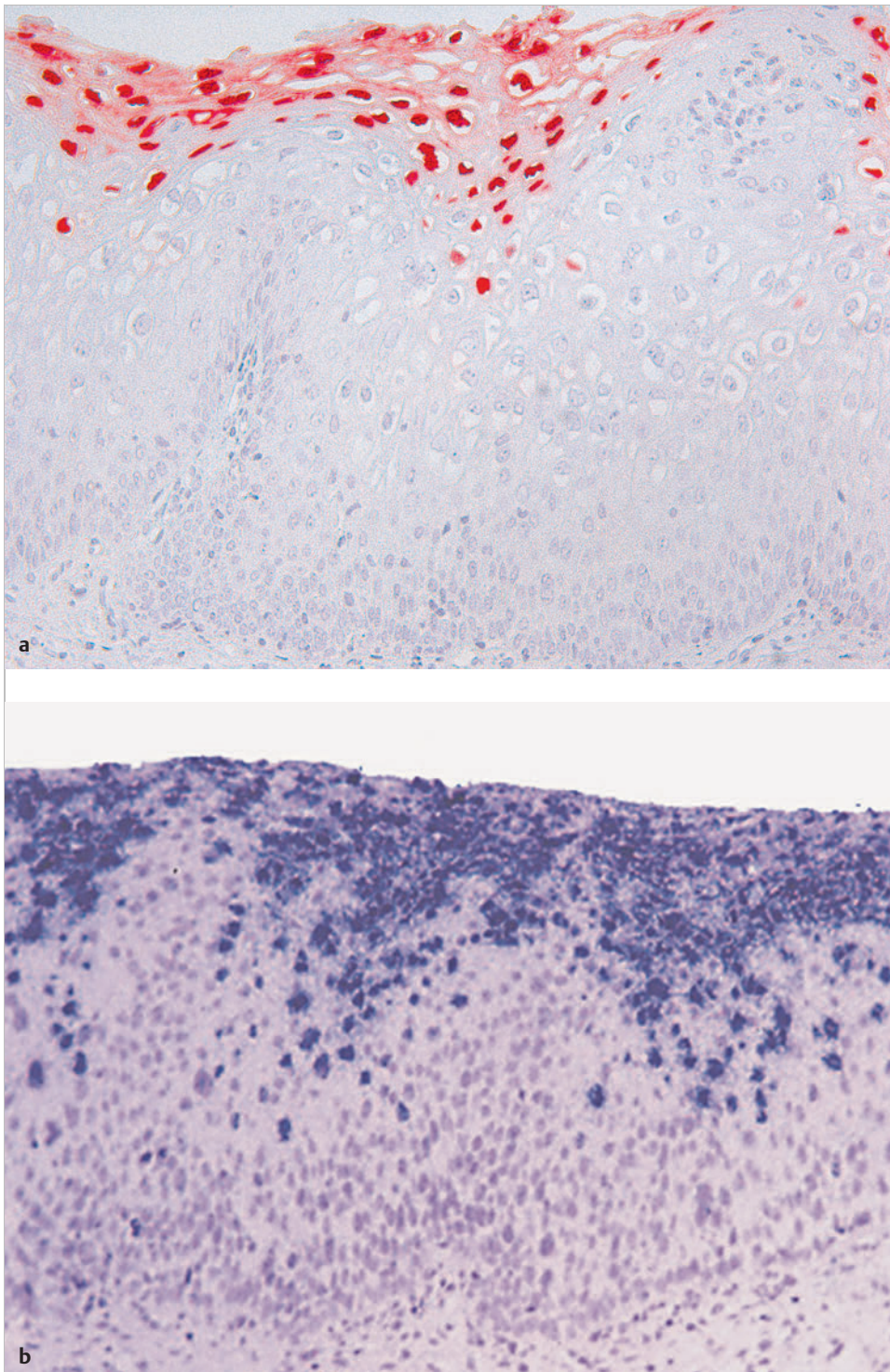


Fig. 3.3 a,b Permissive (productive) phase of HPV infection with viral replication during full squamous cell differentiation. The late gene products permit packaging of the replicated viral genomes, and the newly produced HPVs are released from the keratinocytes at the surface.^{36,37} (a) Staining for L1 shows HPV capsid protein (red) in superficial layers of the infected epithelium. (b) In situ hybridization shows newly produced HPVs (blue) (courtesy of S. Syrjänen).

Latent Phase

Latent infection is not associated with production of infectious particles, remains clinically inapparent, and triggers no histopathologic changes.^{20,23} Most HPV infections probably end this way, without initiation of major viral gene expression.

Permissive (Productive) Phase

The permissive (productive) phase of infection shows no signs of cellular transformation³⁵ and can be caused by either low-risk or high-risk HPV types. It occurs in squamous epithelium but not in columnar epithelium. Permissive (productive) HPV infection frequently results in characteristic morphologic changes within the infected cervical squamous epithelium (so-called virogenic cytopathic effects, referred to as koilocytosis) (► Fig. 3.2). Cells demonstrating the morphologic changes associated with a productive HPV infection corre-

spond to condylomas or CIN 1 when seen in histologic specimens or LSIL when seen in cytologic specimens.

In the permissive phase of infection, expression of the viral *E6* and *E7* genes is limited to the basal cells and is well controlled, apparently by the viral *E2* gene. If these basal cells start differentiating and progress upward to the intermediate cell layer, the cells lose their capacity to proliferate. If these cells reach the superficial layer HPV expression patterns shift to *E4* and the late genes *L1* and *L2*.³⁶ The late gene products permit packaging of the replicated viral genomes, and the newly produced HPVs are released from the keratinocytes at the surface of the infected epithelium (► Fig. 3.3a,b). HPV probably can replicate only with full squamous cell differentiation.³⁷ After a period of months, cytotoxic and helper T cells begin to detect viral antigens, particularly *E2* and *E6*, and can defeat the infection.^{38,39} Probably about 90% of productive infections become undetectable within 1–2 years, corresponding to spontaneous resolution of LSIL.^{40,41}

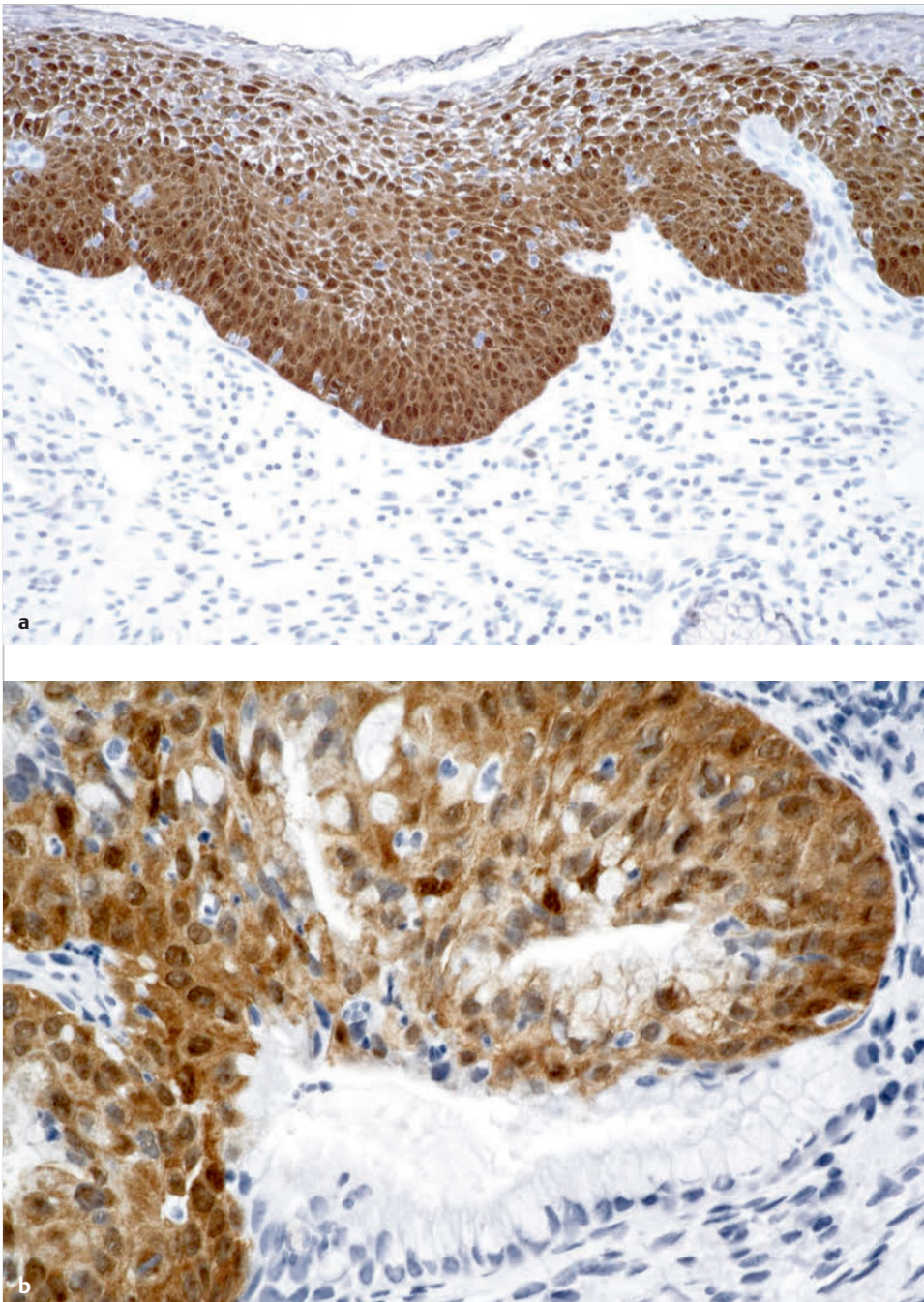


Fig. 3.4 a,b HSIL with diffuse overexpression of p16^{INK4a} in all cells of the proliferating compartment at the surface (**a**) and in a cervical crypt (**b**). In the transforming phase of HPV infection, the early viral genes *E6* and *E7* are strongly expressed and p16^{INK4a} is upregulated and overexpressed.

Transforming Phase

Transforming infections are almost always associated with HR HPV types and are characterized by a substantial shift of the viral gene expression profile, particularly in the basal cells.⁴² Transforming infections cause high-grade lesions. These lesions are referred to as CIN 2,3 in histology and HSIL in cytologic specimens. Koilocytic changes can be present, but they are usually less prominent than in lesions with permissive infection (► Fig. 3.2). The occasional LSIL due to infection with HPV 16 or 18 can show transforming infection and cause monoclonal proliferation.^{43,44}

In transforming infection, the viral *E6* and *E7* genes become strongly expressed, apparently by disruption of the E2-dependent negative feedback loop³⁷ (► Fig. 3.4a,b). Interaction of the E7 protein with the retinoblastoma gene product pRB1 results in inactivation of pRB and loss of cell-cycle control.⁴⁵ This disruption of normal cell-cycle regulation triggers abrogation of apoptosis, chromosomal instability, and a stepwise acquisition of multiple mutations and is thus the key event of the carcinogenetic progression.^{46,47} Alterations in the mitotic spindle apparatus cause genetic instability, which in turn permits aberrant mitotic events. These events can lead to changes in the number and structure of chromosomes.

The molecular events that initiate the transforming mode of HPV gene expression are not yet understood. One concept

suggests that integration of the HPV genome and disruption of the E2 open reading frame result in loss of the E2 function.⁴⁸ The transforming phase also appears to be linked to distinct shifts of the methylation pattern in the HPV genome.^{22,24}

Not all HSIL or AIS will progress to invasive cancer. It is unclear which molecular mechanisms initiate invasion. In many HSILs, HPV genomes are integrated into the host chromosome. More than one-half of HPV 16-positive cancers and most HPV 18-positive cancers contain integrated HPV genomes, suggesting that integration may contribute to malignant progression.⁴⁹ Most invasive cancers have loss of heterozygosity (LOH) at specific chromosomal loci, and many are aneuploid. This suggests that aneuploid intraepithelial lesions with LOH are at risk for progression to invasive carcinomas.^{49,50,51,52} It is also clear that for cancer to develop, HPV has to evade immune detection over a prolonged period for genetic abnormalities to accumulate. Cervical cancer patients have been reported to have a reduced or nonexistent T-cell response to antigens of the causal HPV type.²²

3.3 Morphogenesis of Cervical Cancer

There are probably two types of morphogenesis of squamous cell carcinoma; one occurs in metaplastic squamous

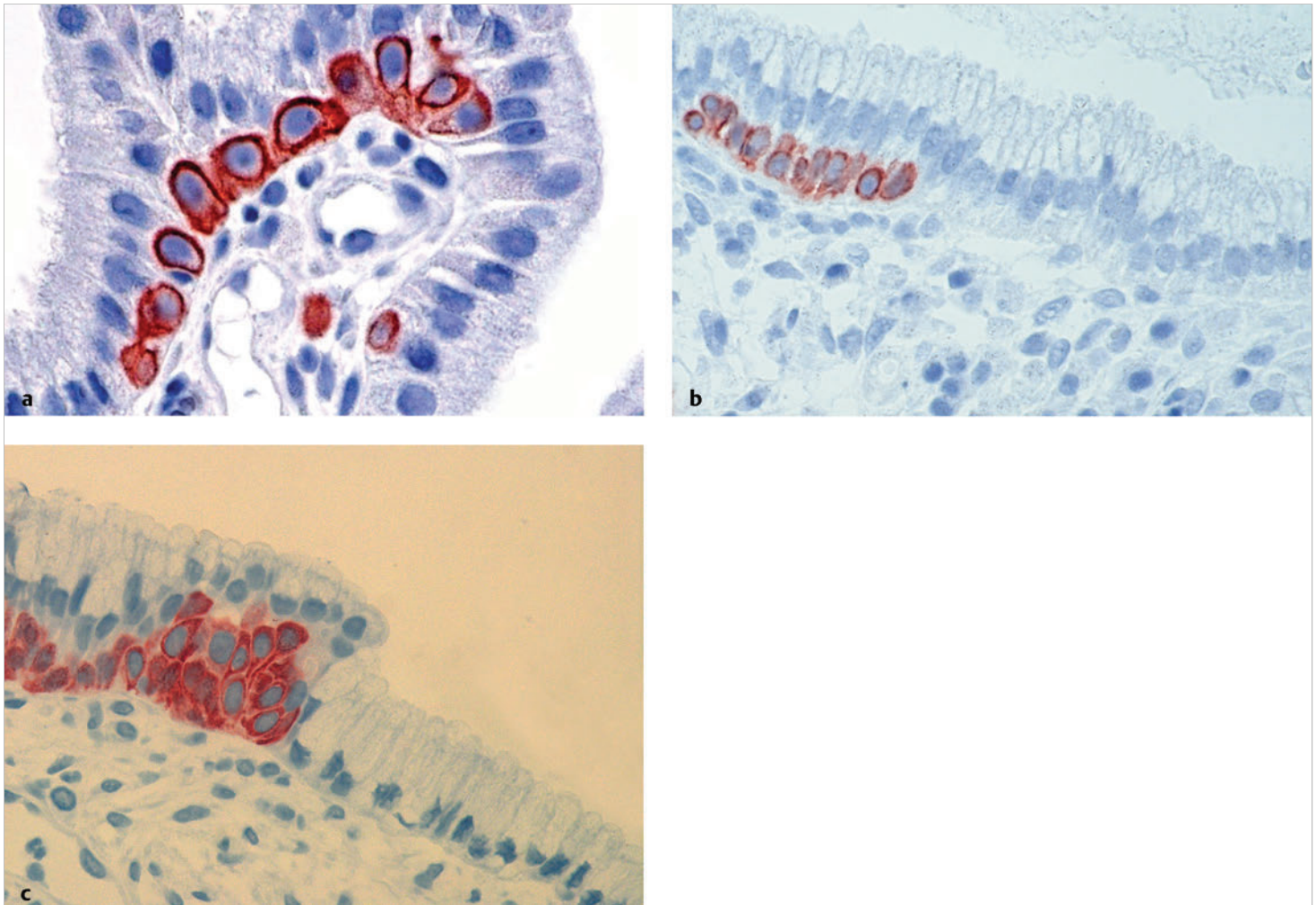


Fig. 3.5 a–c Rows of subcolumnar reserve cells as an early feature of squamous metaplasia of columnar epithelium (a,b). Note the well-defined fields and the beginning proliferation of subcolumnar reserve cells (c) (staining for cytokeratin 17).

epithelium (inside the transformation zone [TZ]) and the other in original squamous epithelium (outside the TZ). Recent studies on the fetal development of the uterine cervix show that original squamous epithelium of the cervix is of vaginal müllerian origin. In contrast, the columnar cervical epithelium is of uterine müllerian origin and includes columnar reserve cells with plasticity to transform into squamous epithelium.⁵³ A third type of morphogenesis leads to cervical adenocarcinoma.

3.3.1 Morphogenesis of Squamous Cell Carcinoma in Metaplastic Epithelium

Squamous cell carcinoma inside the TZ develops via SIL in uniform discrete fields of squamous epithelium of metaplastic origin. Metaplasia begins with the appearance of a row of subcolumnar reserve cells in a well-defined field (► Fig. 3.5a–c). The subsequently formed immature metaplastic squamous epithelium is then restricted to the same field (► Fig. 3.6a–d). Later, immature

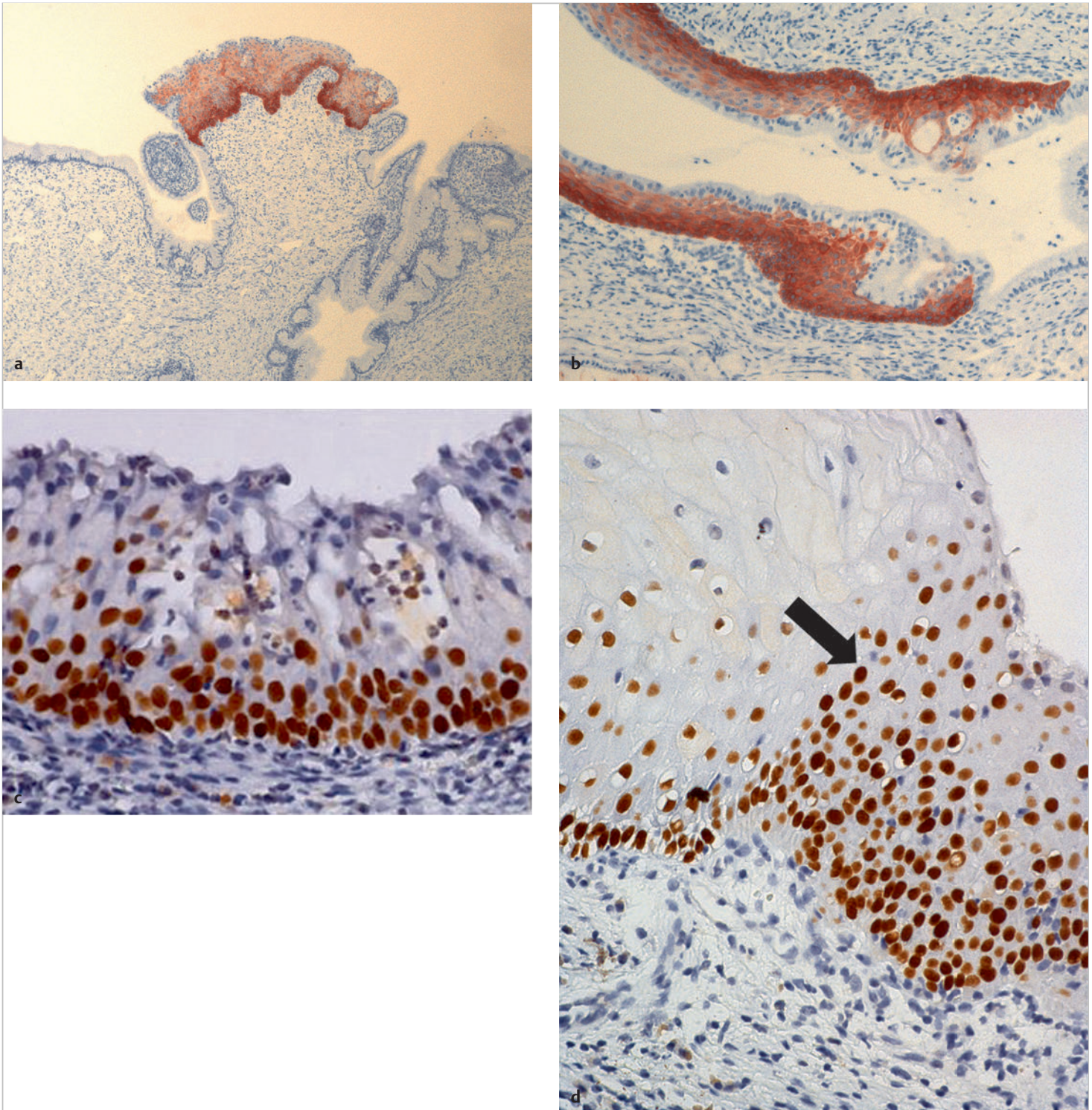


Fig. 3.6 a–d (a–c) Immature metaplastic squamous epithelium at the surface and the crypts. The structure already suggests squamous epithelium, but columnar cells are still present (a,b staining for cytokeratin 17). Note the proliferation of p63-positive subcolumnar reserve cells (c staining for p63). (d) Sharp border between newly formed metaplastic squamous epithelium on the right and adjacent mature squamous epithelium on the left (d staining for p63).

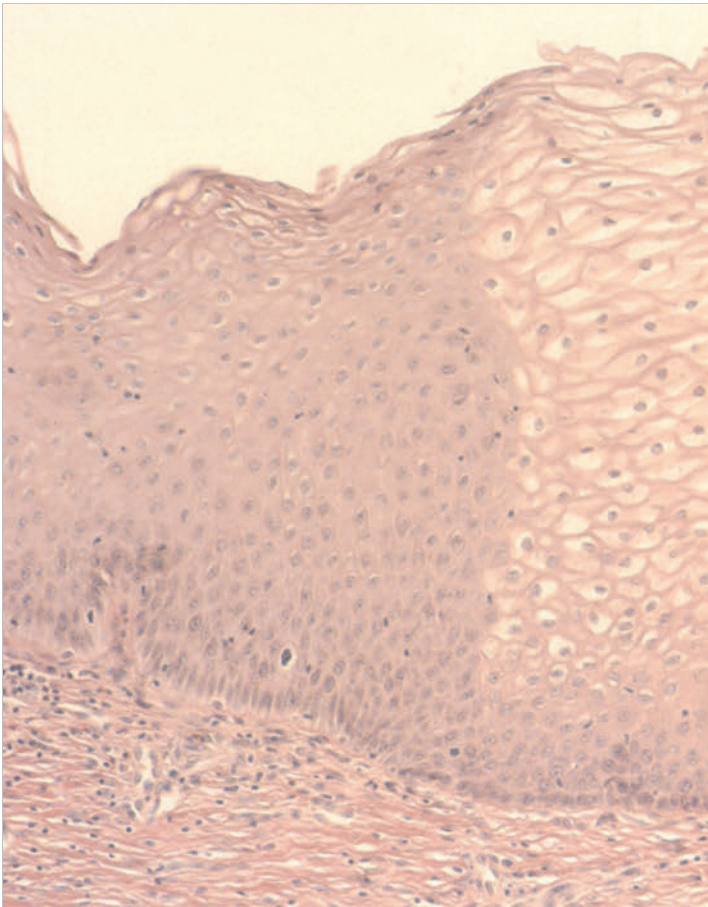


Fig. 3.7 Sharp border between mature metaplastic squamous epithelium on the left and normal squamous epithelium on the right hematoxylin and eosin.

metaplastic squamous epithelium can become mature (► Fig. 3.7). Different fields of (immature and mature) metaplastic squamous epithelium can arise on the same cervix, simultaneously, or at different times. If present, HPV infection usually does not affect the entire metaplastic epithelium. In permissive (productive) infections, virus replication is also limited to sharply defined fields (► Fig. 3.8).⁵⁴

HSIL can appear at the very beginning of the metaplastic process without LSIL. Atypical cells arise simultaneously from the base of whole fields of metaplastic epithelium, not from single cells in an initial focus (► Fig. 3.9a,b).^{54,55,56}

Squamous metaplasia and SIL frequently coexist in separate fields on the same cervix. Adjacent fields are separated by sharp borders. When caused by different HPV types, the appearance of SIL can differ from field to field, but the borders are also sharp (► Fig. 3.10).^{14,54,57} In these cases, the entire lesion is a mosaic of independent primary lesions.⁵⁴ Mostly metaplastic epithelium or LSIL lies distal to the HSIL fields that are normally located near the new squamocolumnar junction (SCJ). SIL remains within its original boundaries and does not enlarge by active surface spread. It grows, enlarges, and spreads by recruiting or apposing new fields of varying appearance.⁵⁴

The synchronous or metachronous development of SIL in various epithelial fields and its confluence play a central role in understanding the pathogenesis of cervical cancer because the likelihood of invasion increases with the surface area of a lesion, which is directly related to the total size. Invasion proceeds unifocally or multifocally from the base of larger lesions with a small nest of cells penetrating the stroma, so-called early stromal invasion.⁵⁸

3.3.2 Morphogenesis of Squamous Cell Carcinoma in Original Squamous Epithelium

A small percentage of SILs develop in original squamous epithelium of the cervix, outside the TZ. This is not due to active spread of SIL toward the vagina across the original SCJ. SIL outside the TZ develops separately and arises by proliferation of the basal and parabasal layers of the original squamous epithelium. It is believed that SIL outside the TZ is also derived from initial HPV-infected basal cells. This can result in a compact layer of atypical cells with increased mitoses. In original squamous epithelium the atypical layer of SIL is confined mostly to the lower quarter or third of the epithelium. Eventually SIL replaces the full thickness

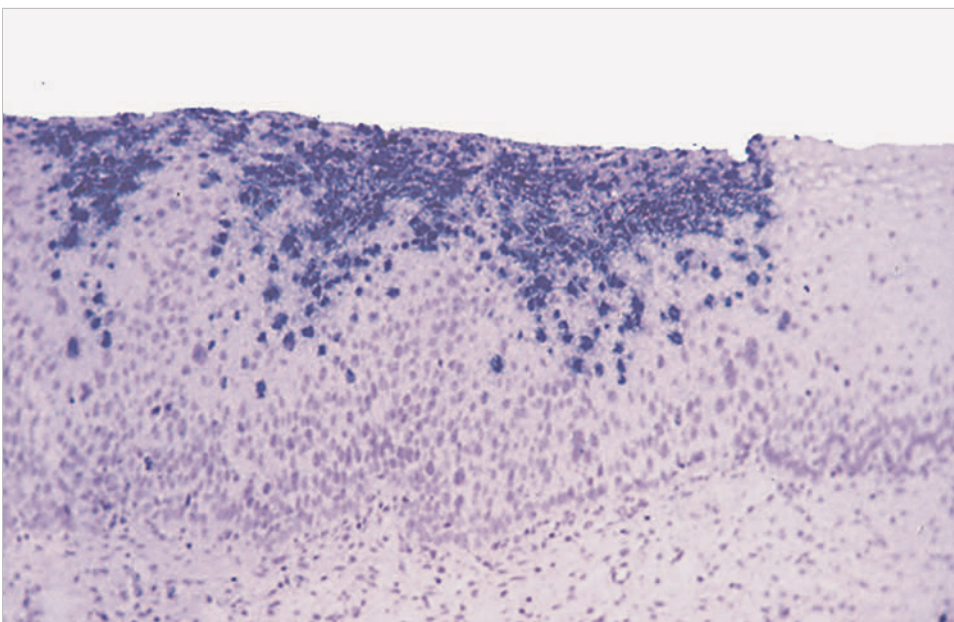


Fig. 3.8 Field of a permissive (productive) HPV infection of the squamous epithelium. Note the sharp border between the epithelium with viral replication on the left and the epithelium without HPV replication on the right (in situ hybridization) (courtesy of S. Syrjänen).

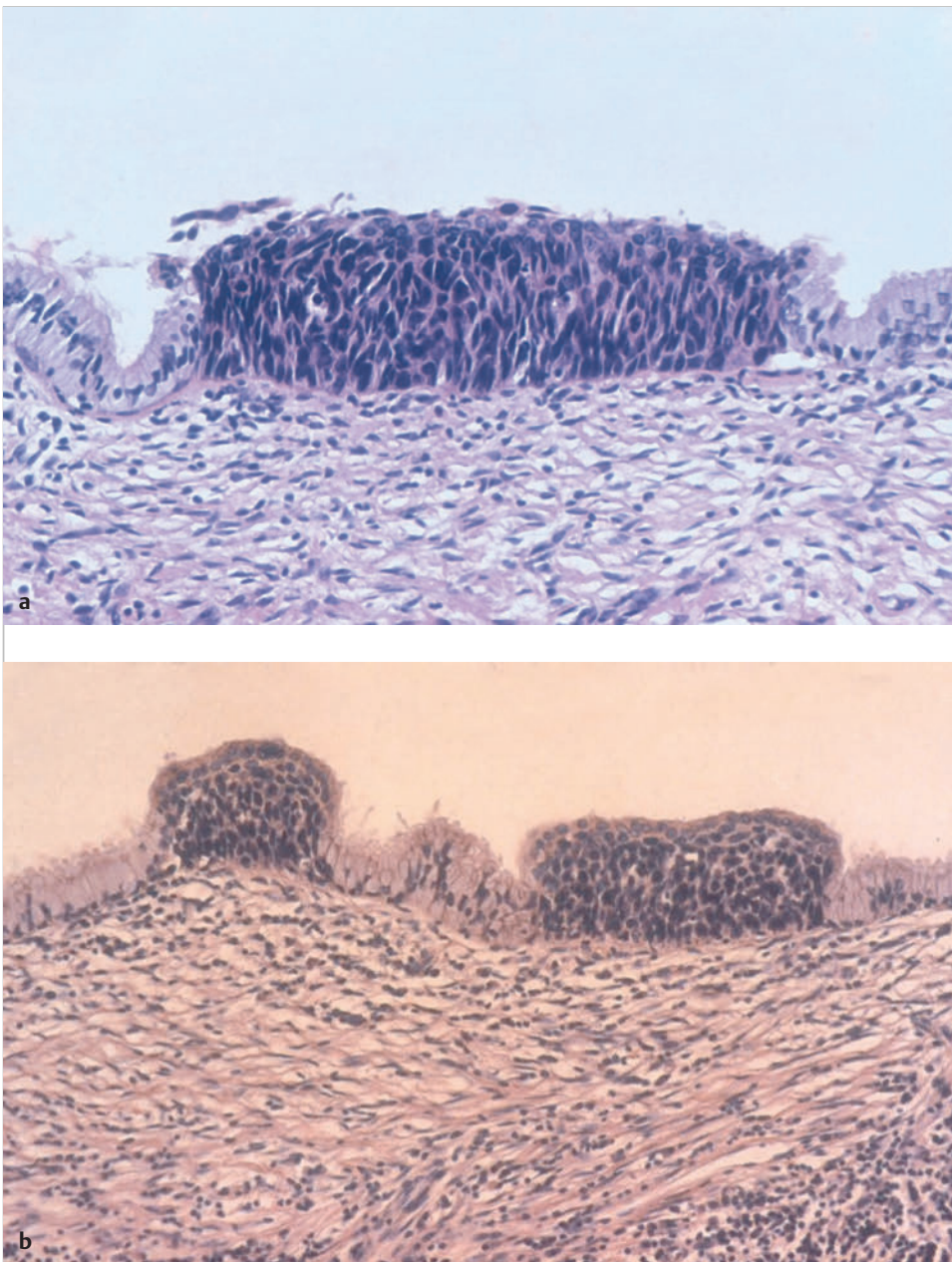


Fig. 3.9 High-grade squamous intraepithelial lesion at the beginning of the metaplastic process. **(a)** Atypical cells arise simultaneously from the base of a whole field of columnar epithelium, not from single cells in an initial focus. **(b)** Two small fields of severe dysplastic squamous epithelium that are still covered by columnar cells. There is no active spread of the epithelium beyond the borders of the fields hematoxylin and eosin.

of the epithelium, but original squamous epithelium is usually the matrix of CIN 1 and condylomas.⁵⁴

3.3.3 Morphogenesis of Adenocarcinoma

Adenocarcinoma of the cervix develops via adenocarcinoma in situ (AIS), which is defined as noninvasive but highly atypical columnar epithelium. There are no low-grade glandular lesions corresponding to LSIL. AISs most frequently arise at the TZ in fields, often in association with HSIL. As in SIL, the transition between the atypical and normal columnar epithelium is abrupt (► Fig. 3.11, ► Fig. 3.12). Active surface spread of these lesions does not exist. Surface spread occurs by apposition of new fields that have undergone neoplastic transformation. This is analogous to events in the squamous epithelium. Nevertheless, it is much more difficult to evaluate these processes in columnar epithelium because columnar epithelium forms more complex structures. Both the surface and the crypts can be involved by AIS. As in SIL, invasion of AIS proceeds from the base of the transformed epithelium, with a small nest of cells penetrating the stroma.⁵⁴

3.4 HPV Vaccines

The identification of HPV as the causative agent of cervical cancer soon prompted research into the development of vaccines. Prophylactic vaccines were based on virus-like particles (VLPs) produced by expressing L1, the major capsid protein of HPV, using recombinant DNA technology. The VLPs preserve and resemble the structure of the native virus and induce antibodies cross-reactive with infectious virus particles. Antibodies reach high serum titers, reach the vaginal fluid by transudation, and are released from the serum when lymph is liberated after wounding of the epithelium.⁵⁹ The protective effect is most likely mediated via serum levels of antibodies that bind to the HPV's shell (capsid) and prevent infection of host cells.⁶⁰

Two vaccines, one quadrivalent and one bivalent, were developed and entered into clinical trials in 2001 and 2004, respectively.⁶¹ The FUTURE studies^{62,63} evaluated the efficacy of a prophylactic quadrivalent vaccine in preventing anogenital diseases associated with HPV types 6, 11, 16, and 18. FUTURE 1 addressed the efficacy of the vaccine to prevent HPV infection and condylomas; FUTURE 2 looked at premalignant HPV lesions (CIN 2/3,

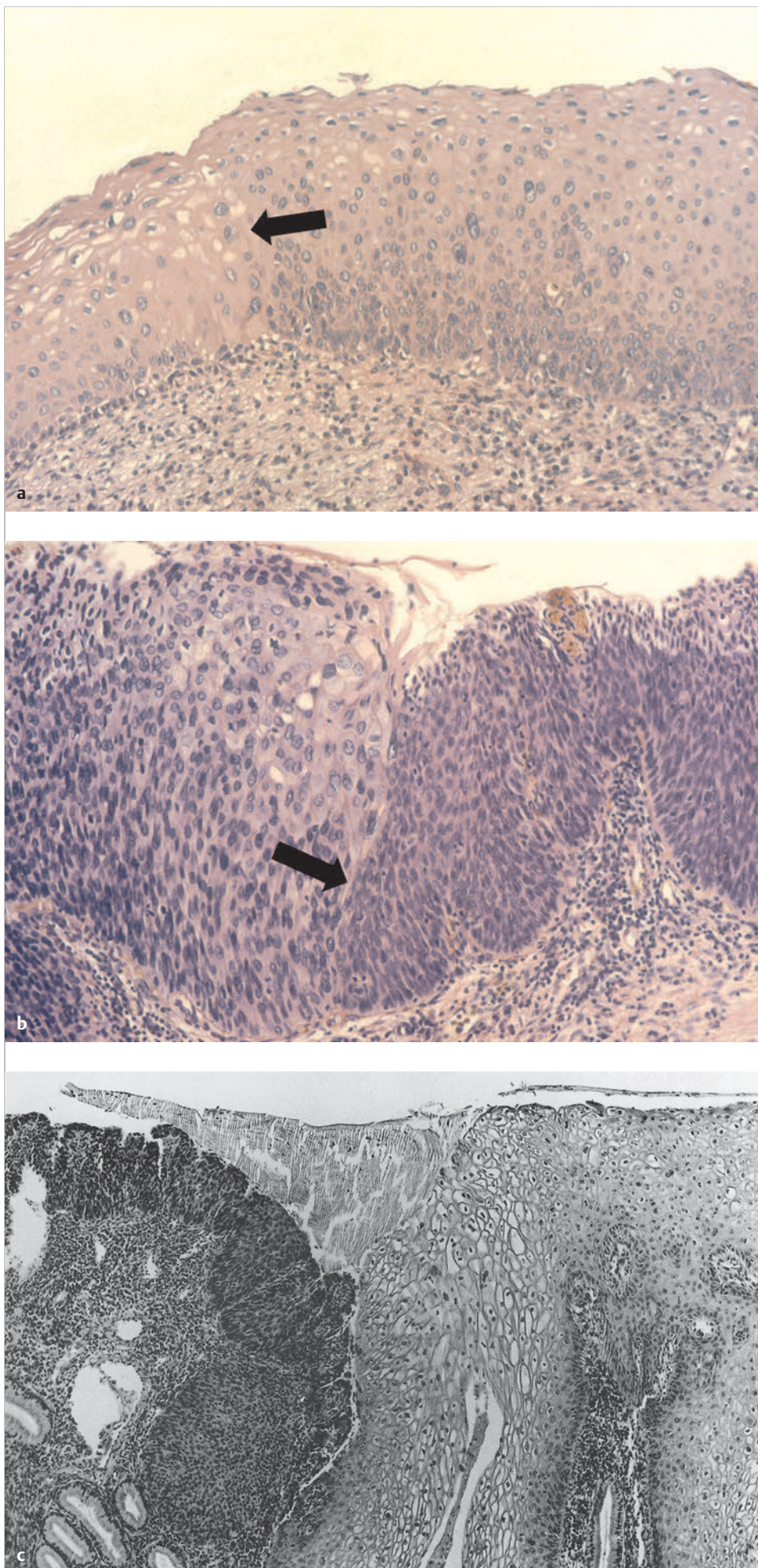


Fig. 3.10 a–c Different fields of SIL with sharp borders between them. (a) Border between squamous epithelium with permissive (productive) HPV infection (left) and slightly dysplastic squamous epithelium (CIN 1) (right). (b) Border between two fields of HSIL. The borders are indicated by arrows hematoxylin and eosin. (c) HSIL next to a typical condyloma with tall stromal papillae and marked koilocytosis.

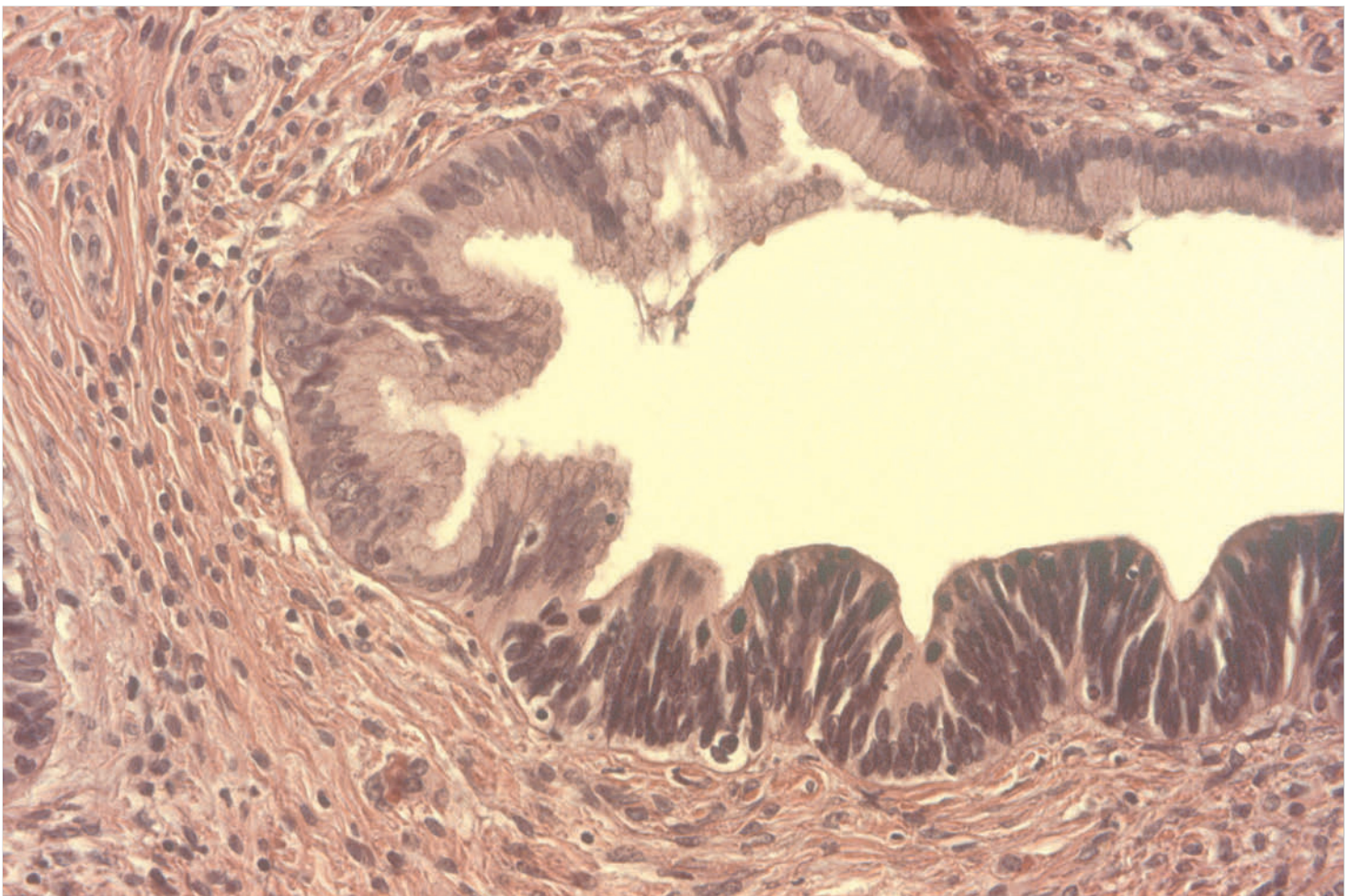


Fig. 3.11 Adenocarcinoma in situ. As in SIL, the border between atypical and normal columnar epithelium is abrupt (hematoxylin and eosin).

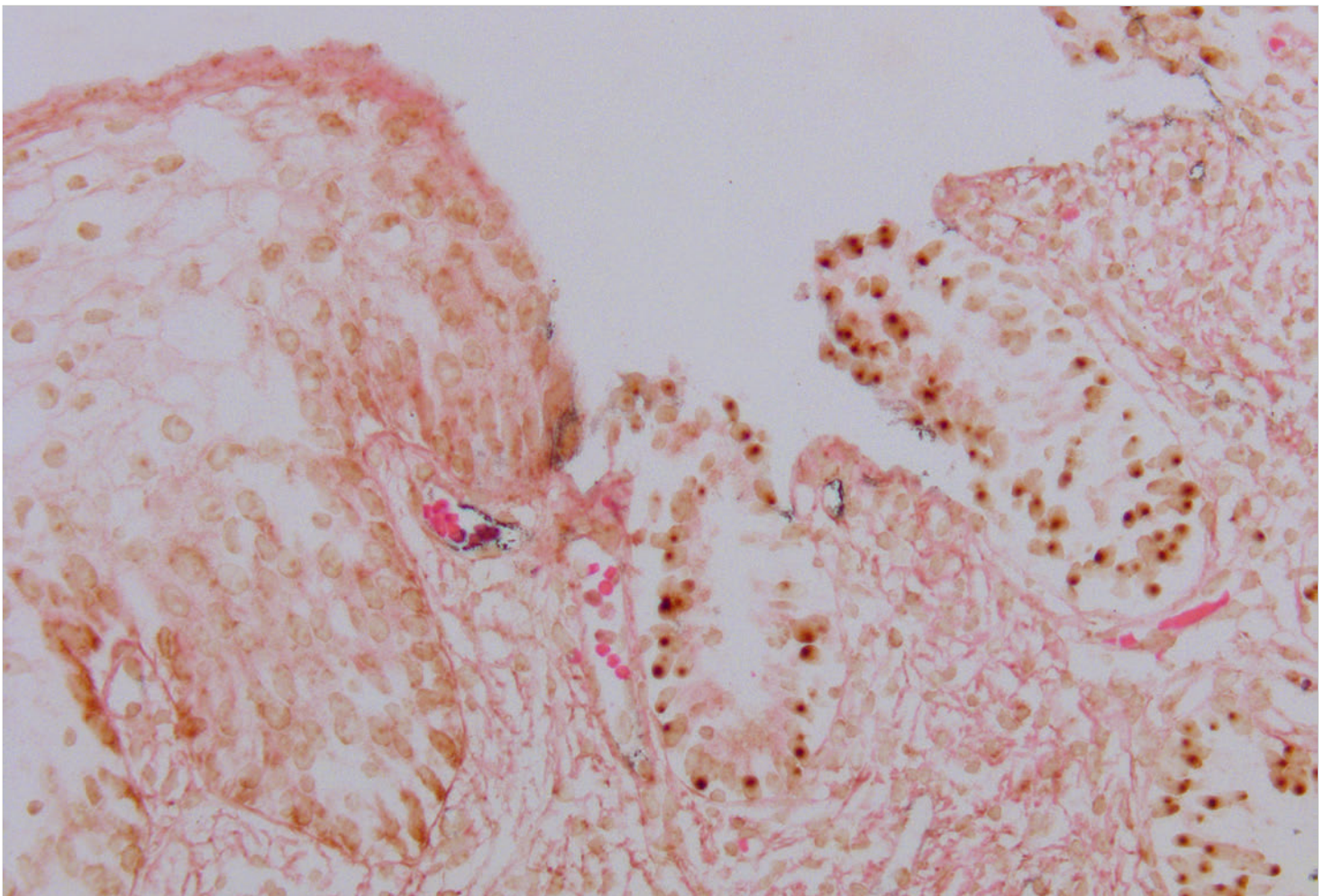


Fig. 3.12 Adenocarcinoma in situ near the squamocolumnar junction. Positive detection for HPV 18 in the neoplastic transformed columnar epithelium. The squamous epithelium is negative. Tyramine amplified in situ hybridization (courtesy S. Syrjänen).

VIN, and AIN). Initially a total of 5,455 women aged (16 to 24 years) received the vaccine or a placebo and were evaluated for the incidence of genital warts, vulvar or vaginal intraepithelial neoplasia (VIN/VAIN), or cancer and the incidence of CIN, AIS, or cancer associated with HPV type 6, 11, 16, or 18. In the primary analysis at 3 years of a per-protocol susceptible population of women who had no virologic evidence of HPV infection at baseline, vaccine efficacy for each of the coprimary endpoints was 100%, showing that the vaccine significantly reduced the incidence of HPV-associated anogenital diseases in young women. At 42 months' follow-up in the per-protocol susceptible population, the efficacy of the vaccine against lesions related to the HPV types in the vaccine was 96% for CIN 1, 100% for both VIN 1 and VAIN 1, and 99% for condylomata. In the FUTURE II study a total of 12,167 women were randomized and evaluated for CIN 2/3, AIS, or cervical cancer related to HPV 16/18. After 3 years' follow-up, vaccine efficacy for the prevention of the primary composite endpoint in the per-protocol susceptible population was 99%.^{62,63,64}

The PApilloma TRial against Cancer In young Adults (PATRICIA) included a total of 18,644 healthy women aged 15 to 25 years with no more than six lifetime sexual partners, irrespective of baseline HPV DNA status.⁶⁵ Women were randomly assigned to receive a bivalent HPV 16/18 vaccine or a control hepatitis A vaccine. The primary endpoint was vaccine efficacy against CIN 2+ associated with HPV 16/18 in women who were seronegative at baseline. After a mean follow-up of 35 months, vaccine efficacy against CIN 2+ associated with HPV 16/18 was 93% in the primary analysis and 98% in an analysis of probable causality to HPV type in lesions with multiple oncogenic types.⁶⁶ In the end-of-study analysis, vaccine efficacy was 93% against all CIN 3+ and 100% against CIN 3+ associated with HPV 16/18.⁶⁷

The quadrivalent vaccine (Gardasil, Merck & Co.) and the bivalent vaccine (Cervarix, GlaxoSmithKline Biologicals) were approved by the Food and Drug Administration in the United States in 2006 and 2009, respectively. HPV vaccines have been incorporated into vaccination programs and recommendations in many countries, and efforts are underway to make vaccination widely available in developing countries, where cervical cancer is a much larger public health problem.

The primary target population for HPV vaccination is adolescent girls before sexual debut. There is also substantial vaccine efficacy in a population approximating a general population of sexually active women, suggesting that catch-up vaccination will also provide benefit. Furthermore, women after surgical therapy of HPV-associated lesions (e.g., conization) after vaccination can continue to benefit from reduction in the risk of development recurrent lesions.⁶⁸ Both vaccines are generally less effective in immunocompromised individuals. Neither of the prophylactic vaccines has shown therapeutic activity.⁶¹

The landmark results of the PATRICIA and FUTURE studies very likely apply to the real world. In 2007 Australia became one of the first countries to implement a nationally funded program for vaccination of girls and young women with the quadrivalent vaccine. An audit of national surveillance data through 2011 showed large declines in the proportions of under 21-year-old and 21 to 30-year-old women diagnosed with genital warts in the vaccination period.^{64,69} Declines in the incidence of genital warts in heterosexual men also declined, probably as a result of herd immunity. These results indicate that the HPV vaccine has a

high efficacy outside the trial setting and strongly support their widespread implementation to prevent anogenital HPV infections and associated neoplasia.

References

- [1] Zur Hausen H. Condylomata acuminata and human genital cancer. *Cancer Res* 1976; 36: 794
- [2] Dürst M, Gissmann L, Ikenberg H, zur Hausen H. A papillomavirus DNA from a cervical carcinoma and its prevalence in cancer biopsy samples from different geographic regions. *Proc Natl Acad Sci U S A* 1983; 80: 3812–3815
- [3] Bosch FX, Qiao YL, Castellsaque X. The epidemiology of human papillomavirus infection and its association with cervical cancer. *Int J Gynaecol Obstet* 2006; 94 Suppl 1: 8–21
- [4] Bernard HU, Burk RD, Chen Z, van Doorslaer K, zur Hausen H, de Villiers EM. Classification of papillomaviruses (PVs) based on 189 PV types and proposal of taxonomic amendments. *Virology* 2010; 401: 70–79
- [5] Zur Hausen H. Papillomaviruses and cancer: from basic studies to clinical application. *Nat Rev Cancer* 2002; 2: 342–350
- [6] Garner-Hamrick PA, Fostel JM, Chien WM et al. Global effects of human papillomavirus type 18 E6/E7 in an organotypic keratinocyte culture system. *J Virol* 2004; 78: 9041–9050
- [7] Woodman CB, Collins SI, Young LS. The natural history of cervical HPV infection: unresolved issues. *Nat Rev Cancer* 2007; 7: 11–22
- [8] Schiffman M, Castle PE, Jeronimo J, Rodriguez AC, Wacholder S. Human papillomavirus and cervical cancer. *Lancet* 2007; 370: 890–907
- [9] De Sanjose S, Quint WG, Alemany L et al. Retrospective International Survey and HPV Time Trends Study Group. Human papillomavirus genotype attribution in invasive cervical cancer: a retrospective cross-sectional worldwide study. *Lancet Oncol* 2010; 11: 1048–1056
- [10] Muñoz N, Bosch FX, de Sanjosé S et al. International Agency for Research on Cancer Multicenter Cervical Cancer Study Group. Epidemiologic classification of human papillomavirus types associated with cervical cancer. *N Engl J Med* 2003; 348: 518–527
- [11] Tjalma WA, Fiander A, Reich O et al. HERACLES/SCALE Study Group. Differences in human papillomavirus type distribution in high-grade cervical intraepithelial neoplasia and invasive cervical cancer in Europe. *Int J Cancer* 2013; 132: 854–867
- [12] Moscicki AB, Schiffman M, Burchell A et al. Updating the natural history of human papillomavirus and anogenital cancers. *Vaccine* 2012; 30 Suppl 5: F24–F33
- [13] Vaccarella S, Franceschi S, Snijders PJ, Herrero R, Meijer CJ, Plummer M IARC HPV Prevalence Surveys Study Group. Concurrent infection with multiple human papillomavirus types: pooled analysis of the IARC HPV Prevalence Surveys. *Cancer Epidemiol Biomarkers Prev* 2010; 19: 503–510
- [14] Chaturvedi AK, Katki HA, Hildesheim A et al. CVT Group. Human papillomavirus infection with multiple types: pattern of coinfection and risk of cervical disease. *J Infect Dis* 2011; 203: 910–920
- [15] Ince TA, Cviko AP, Quade BJ et al. p63 coordinates anogenital modeling and epithelial cell differentiation in the developing female urogenital tract. *Am J Pathol* 2002; 161: 1111–1117
- [16] Troyanovsky SM, Guelstein VI, Tchipyshva TA, Krutovskikh VA, Bannikov GA. Patterns of expression of keratin 17 in human epithelia: dependency on cell position. *J Cell Sci* 1989; 93: 419–426
- [17] Martens JE, Smedts FM, Ploeger D et al. Distribution pattern and marker profile show two subpopulations of reserve cells in the endocervical canal. *Int J Gynecol Pathol* 2009; 28: 381–388
- [18] Frazer IH. Prevention of cervical cancer through papillomavirus vaccination. *Nat Rev Immunol* 2004; 4: 46–54
- [19] Selinka HC, Florin L, Patel HD et al. Inhibition of transfer to secondary receptors by heparan sulfate-binding drug or antibody induces noninfectious uptake of human papillomavirus. *J Virol* 2007; 81: 10970–10980
- [20] Kines RC, Thompson CD, Lowy DR, Schiller JT, Day PM. The initial steps leading to papillomavirus infection occur on the basement membrane prior to cell surface binding. *Proc Natl Acad Sci USA* 2009; 106: 20458–20463
- [21] Schiller JT, Day PM, Kines RC. Current understanding of the mechanism of HPV infection. *Gynecol Oncol* 2010; 118 Suppl: S12–S17
- [22] Doorbar J, Quint W, Banks L et al. The biology and life-cycle of human papillomaviruses. *Vaccine* 2012; 30 Suppl 5: F55–F70

- [23] Doorbar J. Papillomavirus life cycle organization and biomarker selection. *Dis Markers* 2007; 23: 297–313
- [24] Knebel Doeberitz Mv, Vinokurova S. Host factors in HPV-related carcinogenesis: cellular mechanisms controlling HPV infections. *Arch Med Res* 2009; 40: 435–442
- [25] Castle PE, Rodríguez AC, Burk RD et al. Proyecto Epidemiológico Guanacaste (PEG) Group. Short term persistence of human papillomavirus and risk of cervical precancer and cancer: population based cohort study. *BMJ* 2009; 339: b2569
- [26] Kjør SK, Frederiksen K, Munk C, Iftner T. Long-term absolute risk of cervical intraepithelial neoplasia grade 3 or worse following human papillomavirus infection: role of persistence. *J Natl Cancer Inst* 2010; 102: 1478–1488
- [27] Melnikow J, Nuovo J, Willan AR, Chan BK, Howell LP. Natural history of cervical squamous intraepithelial lesions: a meta-analysis. *Obstet Gynecol* 1998; 92: 727–735
- [28] Winer RL, Kiviat NB, Hughes JP et al. Development and duration of human papillomavirus lesions, after initial infection. *J Infect Dis* 2005; 191: 731–738
- [29] Mao C, Koutsky LA, Ault KA et al. Efficacy of human papillomavirus-16 vaccine to prevent cervical intraepithelial neoplasia: a randomized controlled trial. *Obstet Gynecol* 2006; 107: 18–27
- [30] Moscicki AB, Schiffman M, Kjaer S, Villa LL. Chapter 5: Updating the natural history of HPV and anogenital cancer. *Vaccine* 2006; 24 Suppl 3: 42–51
- [31] Kjaer SK, Høgdall E, Frederiksen K et al. The absolute risk of cervical abnormalities in high-risk human papillomavirus-positive, cytologically normal women over a 10-year period. *Cancer Res* 2006; 66: 10630–10636
- [32] Liebrich C, Brummer O, Von Wasielewski R et al. Primary cervical cancer truly negative for high-risk human papillomavirus is a rare but distinct entity that can affect virgins and young adolescents. *Eur J Gynaecol Oncol* 2009; 30: 45–48
- [33] Östör AG. Natural history of cervical intraepithelial neoplasia: a critical review. *Int J Gynecol Pathol* 1993; 12: 186–192
- [34] McCredie MR, Sharples KJ, Paul C et al. Natural history of cervical neoplasia and risk of invasive cancer in women with cervical intraepithelial neoplasia 3: a retrospective cohort study. *Lancet Oncol* 2008; 9: 425–434
- [35] Middleton K, Peh W, Southern S et al. Organization of human papillomavirus productive cycle during neoplastic progression provides a basis for selection of diagnostic markers. *J Virol* 2003; 77: 10186–10201
- [36] Wooldridge TR, Laimins LA. Regulation of human papillomavirus type 31 gene expression during the differentiation-dependent life cycle through histone modifications and transcription factor binding. *Virology* 2008; 374: 371–380
- [37] Thierry F. Transcriptional regulation of the papillomavirus oncogenes by cellular and viral transcription factors in cervical carcinoma. *Virology* 2009; 384: 375–379
- [38] Stanley MA. Immunobiology of papillomavirus infections. *J Reprod Immunol* 2001; 52: 45–59
- [39] Onda T, Carter JJ, Koutsky LA et al. Characterization of IgA response among women with incident HPV 16 infection. *Virology* 2003; 312: 213–221
- [40] Plummer M, Schiffman M, Castle PE, Maucort-Boulch D, Wheeler CM ALTS Group. A 2-year prospective study of human papillomavirus persistence among women with a cytological diagnosis of atypical squamous cells of undetermined significance or low-grade squamous intraepithelial lesion. *J Infect Dis* 2007; 195: 1582–1589
- [41] Rodríguez AC, Schiffman M, Herrero R et al. Proyecto Epidemiológico Guanacaste Group. Rapid clearance of human papillomavirus and implications for clinical focus on persistent infections. *J Natl Cancer Inst* 2008; 100: 513–517
- [42] Vinokurova S, von Knebel Doeberitz M. Differential methylation of the HPV 16 upstream regulatory region during epithelial differentiation and neoplastic transformation. *PLoS ONE* 2011; 6: e24451
- [43] Park TW, Richart RM, Sun XW, Wright TC. Association between human papillomavirus type and clonal status of cervical squamous intraepithelial lesions. *J Natl Cancer Inst* 1996; 88: 355–358
- [44] del Pino M, Garcia S, Fusté V et al. Value of p16(INK4a) as a marker of progression/regression in cervical intraepithelial neoplasia grade 1. *Am J Obstet Gynecol* 2009; 201: e1–e7
- [45] McLaughlin-Drubin ME, Münger K. Oncogenic activities of human papillomaviruses. *Virus Res* 2009; 143: 195–208
- [46] Zur Hausen H. Papillomaviruses causing cancer: evasion from host-cell control in early events in carcinogenesis. *J Natl Cancer Inst* 2000; 92: 690–698
- [47] Snijders PJ, Steenbergen RD, Heideman DA, Meijer CJ. HPV-mediated cervical carcinogenesis: concepts and clinical implications. *J Pathol* 2006; 208: 152–164
- [48] Kadaja M, Isok-Paas H, Laos T, Ustav E, Ustav M. Mechanism of genomic instability in cells infected with the high-risk human papillomaviruses. *PLoS Pathog* 2009; 5: e1000397
- [49] Moody CA, Laimins LA. Human papillomavirus oncoproteins: pathways to transformation. *Nat Rev Cancer* 2010; 10: 550–560
- [50] Chung TK, Cheung TH, Lo WK et al. Loss of heterozygosity at the short arm of chromosome 3 in microdissected cervical intraepithelial neoplasia. *Cancer Lett* 2000; 154: 189–194
- [51] Pieber D, Bauer M, Gücer F, Reich O, Pickel H, Pürstner P. Numerical chromosomal aberrations of chromosome 1 and 7 in dysplastic cervical smears. *Life Sci* 2000; 67: 671–678
- [52] Narayan G, Pulido HA, Koul S et al. Genetic analysis identifies putative tumor suppressor sites at 2q35-q36.1 and 2q36.3-q37.1 involved in cervical cancer progression. *Oncogene* 2003; 22: 3489–3499
- [53] Fritsch H, Hoermann R, Bitsche M et al. Development of epithelial and mesenchymal regionalization of the human utero-vaginal anlagen. *J Anat* 2013; 222: 462–472
- [54] Burghardt E. Early histological diagnosis of cervical cancer. Stuttgart: Thieme, 1973
- [55] Reich O, Pickel H, Regauer S. Why do human papillomavirus infections induce sharply demarcated lesions of the cervix? *J Low Genit Tract Dis* 2008; 12: 8–10
- [56] Reich O. The columnar epithelium hypothesis of cervical carcinogenesis. *Eur J Gynaecol Oncol* 2010; 31: 137–138
- [57] Agorastos T, Miliaras D, Lambropoulos AF et al. Detection and typing of human papillomavirus DNA in uterine cervixes with coexistent grade I and grade III intraepithelial neoplasia: biologic progression or independent lesions? *Eur J Obstet Gynecol Reprod Biol* 2005; 121: 99–103
- [58] Reich O, Pickel H. Multifocal stromal invasion in microinvasive squamous cell carcinoma of the cervix: how to measure and stage these lesions. *Int J Gynecol Pathol* 2002; 21: 416–417
- [59] Day PM, Kines RC, Thompson CD et al. In vivo mechanisms of vaccine-induced protection against HPV infection. *Cell Host Microbe* 2010; 8: 260–270
- [60] Stanley M, Lowy DR, Frazer I. Chapter 12: Prophylactic HPV vaccines: underlying mechanisms. *Vaccine* 2006; 24 Suppl 3: 106–113
- [61] Schiller JT, Castellsagué X, Garland SM. A review of clinical trials of human papillomavirus prophylactic vaccines. *Vaccine* 2012; 30 Suppl 5: F123–F138
- [62] Garland SM, Hernandez-Avila M, Wheeler CM et al. Females United to Unilaterally Reduce Endo/Ectocervical Disease (FUTURE) I Investigators. Quadrivalent vaccine against human papillomavirus to prevent anogenital diseases. *N Engl J Med* 2007; 356: 1928–1943
- [63] FUTURE II Study Group. Quadrivalent vaccine against human papillomavirus to prevent high-grade cervical lesions. *N Engl J Med* 2007; 356: 1915–1927
- [64] Ali H, Donovan B, Wand H et al. Genital warts in young Australians five years into national human papillomavirus vaccination programme: national surveillance data. *BMJ* 2013; 346: f2032
- [65] Paavonen J, Jenkins D, Bosch FX et al. HPV PATRICIA study group. Efficacy of a prophylactic adjuvanted bivalent L1 virus-like-particle vaccine against infection with human papillomavirus types 16 and 18 in young women: an interim analysis of a phase III double-blind, randomised controlled trial. *Lancet* 2007; 369: 2161–2170
- [66] Paavonen J, Naud P, Salmerón J et al. HPV PATRICIA Study Group. Efficacy of human papillomavirus (HPV)-16/18 AS04-adjuvanted vaccine against cervical infection and precancer caused by oncogenic HPV types (PATRICIA): final analysis of a double-blind, randomised study in young women. *Lancet* 2009; 374: 301–314
- [67] Lehtinen M, Paavonen J, Wheeler CM et al. HPV PATRICIA Study Group. Overall efficacy of HPV-16/18 AS04-adjuvanted vaccine against grade 3 or greater cervical intraepithelial neoplasia: 4-year end-of-study analysis of the randomised, double-blind PATRICIA trial. *Lancet Oncol* 2012; 13: 89–99
- [68] Joura EA, Garland SM, Paavonen J et al. Effect of the HPV quadrivalent vaccine in a subgroup of women with cervical and vulvar disease: retrospective pooled analysis of trial data. *BMJ* 2012; 344: e1401
- [69] Muñoz N, Kjaer SK, Sigurdsson K et al. Impact of human papillomavirus (HPV)-6/11/16/18 vaccine on all HPV-associated genital diseases in young women. *J Natl Cancer Inst* 2010; 102: 325–339

Further Reading

- Herfs M, Yamamoto Y, Laury A et al. A discrete population of squamocolumnar junction cells implicated in the pathogenesis of cervical cancer. *Proc Natl Acad Sci U S A* 2012; 109: 10516–10521
- Holl A, Nowakowski AM, Powell N et al. Human papillomavirus prevalence and type distribution in cervical glandular neoplasias: results from a European multinational epidemiological study. *Int J Cancer* 2014 (in press)
- Ojesina AI, Lichtenstein L, Freeman SS et al. Landscape of genomic alterations in cervical carcinomas. *Nature* 2014; 506: 371–375
- Ronco G, Dillner J, Elfström KM et al. International HPV screening working group. Efficacy of HPV-based screening for prevention of invasive cervical cancer: follow-up of four European randomised controlled trials. *Lancet* 2014; 383: 524–532
- Schiffman M, Solomon D. Cervical-cancer screening with human papillomavirus and cytologic cotesting. *N Engl J Med* 2013; 369: 2324–2331
- Thomas LK, Bermejo JL, Vinokurova S et al. Chromosomal gains and losses in human papillomavirus-associated neoplasia of the lower genital tract - a systematic review and meta-analysis. *Eur J Cancer* 2014; 50: 85–98

Chapter 4

Histology and Histopathology

4.1 Normal Findings; Reactive and Benign HPV-Related Changes	24
4.2 Premalignant Cervical Lesions	31
4.3 Invasive Cervical Cancer	38
4.4 Histology of Colposcopic Findings	46



4 Histology and Histopathology

4.1 Normal Findings; Reactive and Benign HPV-Related Changes

4.1.1 Normal Squamous Epithelium

The normal squamous epithelium of the cervix and vagina is stratified, contains glycogen, and is arranged in layers (► Fig. 4.1a). A single row of basal cells supports a band of prickle cells followed by a thick layer of large polygonal cells. The surface is covered by a thin layer of squamous cells. Normal squamous epithelium is non-keratinized. Short stromal papillae extend into the epithelium at regular intervals. The epithelial-stromal junction is straight. During the reproductive years, the epithelium is high and well differentiated (► Fig. 4.1a). In childhood and in old age, without the influence of estrogen, the squamous epithelium is low and consists of only few layers of small epithelial cells (► Fig. 4.1b).

4.1.2 Normal Columnar Epithelium and Ectopy

The normal columnar epithelium of the endocervical mucosa consists of a single layer of tall mucin-secreting cells with basal nuclei (► Fig. 4.2). Its junction with the original squamous epithelium is near the external os. Columnar epithelium covers the endocervical mucosa and lines the so-called cervical glands. These are not true glands but invaginations of the mucosa.¹ The surface of the mucosa in the canal is gently undulating, and parts of it can be smooth. If the original squamocolumnar junction is situated on the ectocervix, the surface of the resulting ectopy is markedly papillary. The characteristic steplike appearance of the squamocolumnar junction is due to the difference in the heights of the two epithelia. Where the endocervical mucosa merges with the isthmic mucosa, endometrial-type glands intermingle with endocervical glands.

The original squamocolumnar junction is usually located at the external os. *Ectopy* refers to columnar epithelium on the external os, with the squamocolumnar junction situated on the ectocervix. With ectopy the surface columnar epithelium with glands and supporting stroma is on the external os. It is not always possible to see the original squamocolumnar junction on the surface of the ectocervix; its true position is permanently marked histologically by the *last gland* (see section Ectopy and the Last Gland).

The surface of ectopy is usually highly papillary (► Fig. 4.2). The stroma usually contains a light inflammatory infiltrate; occasionally this is dense and associated with a prominent capillary network. In rare cases, the columnar epithelium extends all the way to the vaginal fornix. The term *vaginal adenosis* refers to the rare finding of islands of columnar epithelium in the fornices or elsewhere in the vaginal epithelium (see Chapter 14).

4.1.3 Metaplastic Squamous Epithelium and the Transformation Zone

Metaplasia of squamous epithelium denotes the gradual transformation of columnar epithelium into squamous epithelium. The

transformation zone (TZ) is where squamous metaplasia occurs (► Fig. 4.3). It extends from the original nonkeratinizing squamous epithelium of the ectocervix to the mucin-producing columnar epithelium of the endocervix. Transformation can involve the columnar epithelium in the endocervical canal.

Metaplasia (i.e., the replacement of columnar epithelium by squamous epithelium) is preceded by the appearance of so-called subcolumnar reserve cells under the columnar epithelium (► Fig. 3.5). The squamous epithelium, which results from the replication of these reserve cells, eventually sloughs the pre-existent columnar epithelium (► Fig. 3.5, ► Fig. 3.6).

The origin of the subcolumnar reserve cells is poorly understood.^{2,3} They are believed to be pluripotent cells native to the endocervical mucosa and to be responsible for both the ongoing regeneration of columnar cells and the initiation of the metaplastic process. In normal columnar mucosa individual reserve cells lie in the basal layer of the epithelium (► Fig. 3.5). When metaplasia occurs, they form neat rows in well-defined segments of the mucosa in discrete fields (► Fig. 3.6). One or several of these fields can be present at the same time, either isolated or closely joined together, like patchwork. In the latter case it is possible to observe the stages of maturation of the metaplastic epithelium. Subcolumnar reserve cells are probably of epithelial (not stromal) origin, although this is not entirely clear.⁴

Because the reserve cells appear in well-defined rows and fields, the squamous epithelium resulting from squamous metaplasia also has sharp, well-defined borders (see Chapter 2). Distinct epithelial borders imply true epithelial transformation rather than reactive changes due to inflammation or regeneration.

Transformation usually begins at the squamocolumnar junction (SCJ) (► Fig. 4.3). Less commonly, it begins amid columnar epithelium near the junction. The epithelium that appears first is thin, multicellular and lacks stratification. The histologic appearance resembles the various stages of regenerating epithelium (► Fig. 4.3). The epithelium gradually becomes thicker (► Fig. 4.4) and stratified and finally is scarcely distinguishable from normal glycogen-containing squamous epithelium. Only the underlying columnar mucosa indicates its true origin.

Ectopy and the Last Gland

Ideally, the SCJ lies at the external os. Ectopy is present when the SCJ lies outside the external os. The columnar epithelium of ectopy is often replaced by metaplastic squamous epithelium that is continuous with and at first glance indistinguishable from the original squamous epithelium. The SCJ is thus shifted proximally to some distance away from the so-called last gland, resulting in what Pixley called the new SCJ⁵ (► Fig. 4.4).

The concept of the *last gland* was introduced by Hamperl et al^{6,7} in studies of epithelial shifts. These investigators noticed that the endocervical mucosa often extended onto the ectocervix as ectopy during reproductive life, but retracted back into the canal in postmenopausal women. The distal extent of the former ectopy is marked morphologically by the last gland (► Fig. 4.5). The last gland is also the focal point for the distribution of the stromal connective tissue and blood vessels of the outer area of

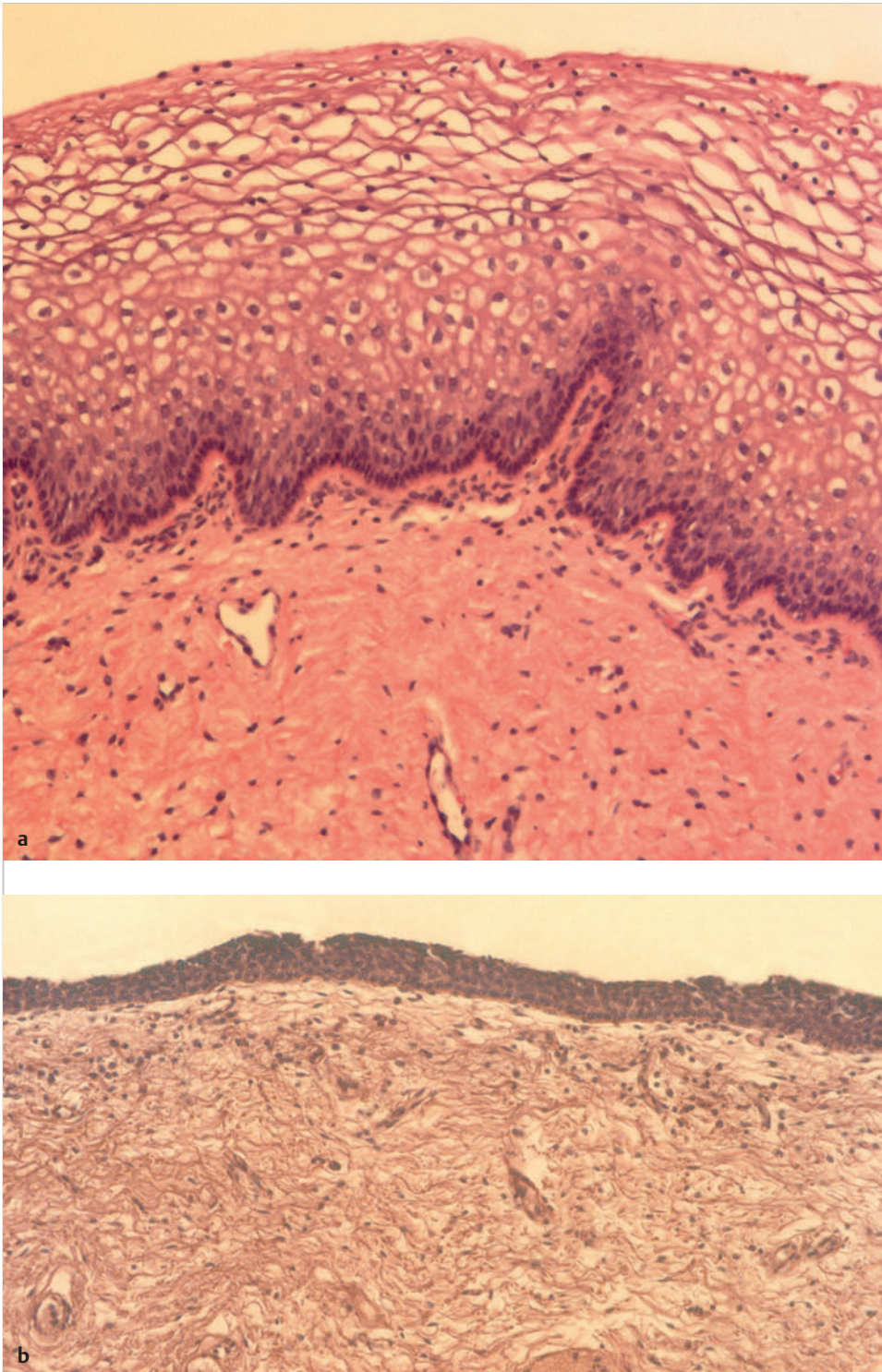


Fig. 4.1 a,b Normal squamous epithelium. **(a)** Almost the whole thickness of the epithelium is taken up by cells with clear cytoplasm containing glycogen. Note the prominent single-layered basal row and the short stromal papillae. **(b)** Atrophy. The squamous epithelium is low and consists of only a few layers of small epithelial cells.

the cervix. These structures accompany any change in the location of the last gland and serve as permanent markers of its position from intrauterine life to the postmenopause. The last gland is important because its position is constant. It is a landmark separating endocervical mucosa (columnar epithelium) proximally from original squamous epithelium distally.

The concept of the last gland is supported by recent studies of the fetal development of the uterine cervix. These show that the original squamous epithelium of the cervix up to the last gland is of *vaginal* müllerian origin. In contrast, the columnar cervical epithelium is of *uterine* müllerian origin and includes columnar reserve cells with the plasticity to transform into squamous epithelium. In late fetal life, cervical glands migrate from the

epithelial surface of the cervical canal into the underlying stroma. They spread caudally toward the cervical office. The SCJ is clearly detectable from week 24 onward and is situated within the cervical canal during all stages of fetal life. In the newborn, this border tends toward the vagina (► Fig. 4.5).⁸

During reproductive life, there are three types of epithelium on the cervix: the original squamous epithelium, the squamous epithelium of metaplastic origin (► Fig. 4.3), and the columnar epithelium. The metaplastic epithelium corresponds to the transformation zone (TZ) seen at colposcopy. The TZ is situated between the original SCJ, marked by the last gland, and the new SCJ (► Fig. 4.4, ► Fig. 4.5).⁵ Accordingly, squamous epithelium proximal to the last gland arises via squamous metaplasia.⁹

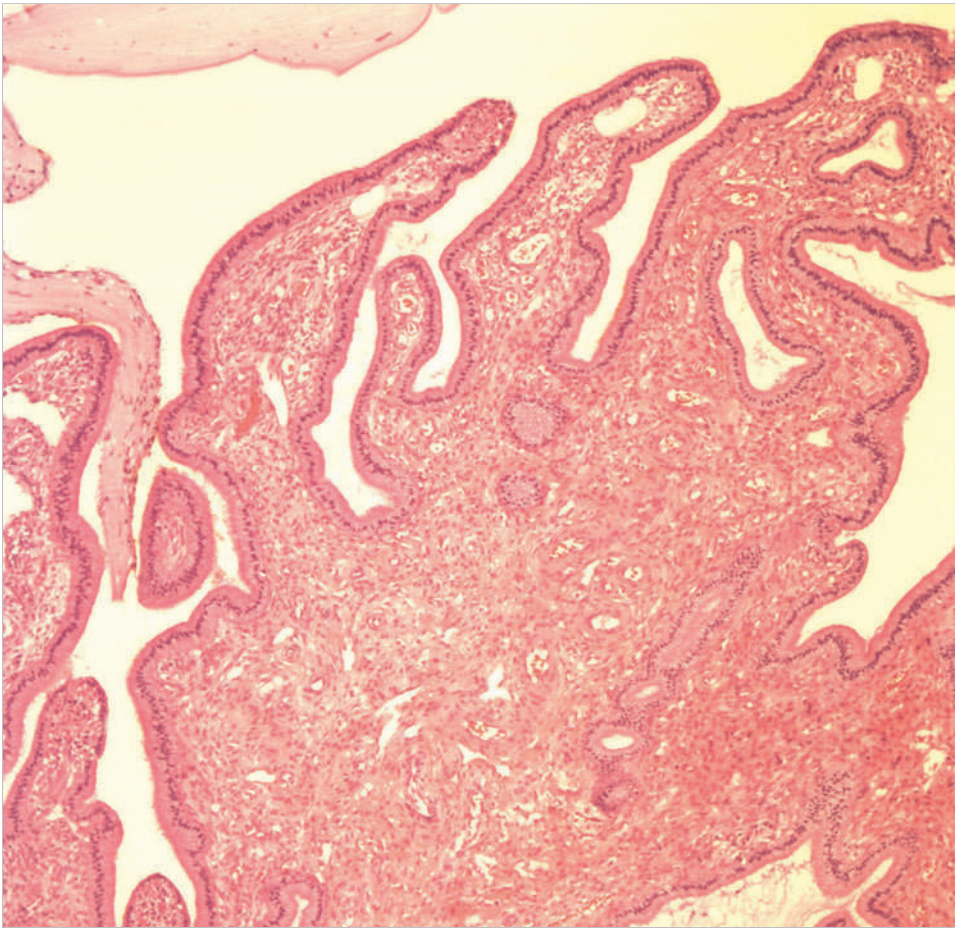


Fig. 4.2 Normal columnar epithelium is single-layered and consists of tall mucin-secreting cells with basal nuclei. Note the papillary configuration in the area of an ectopy.

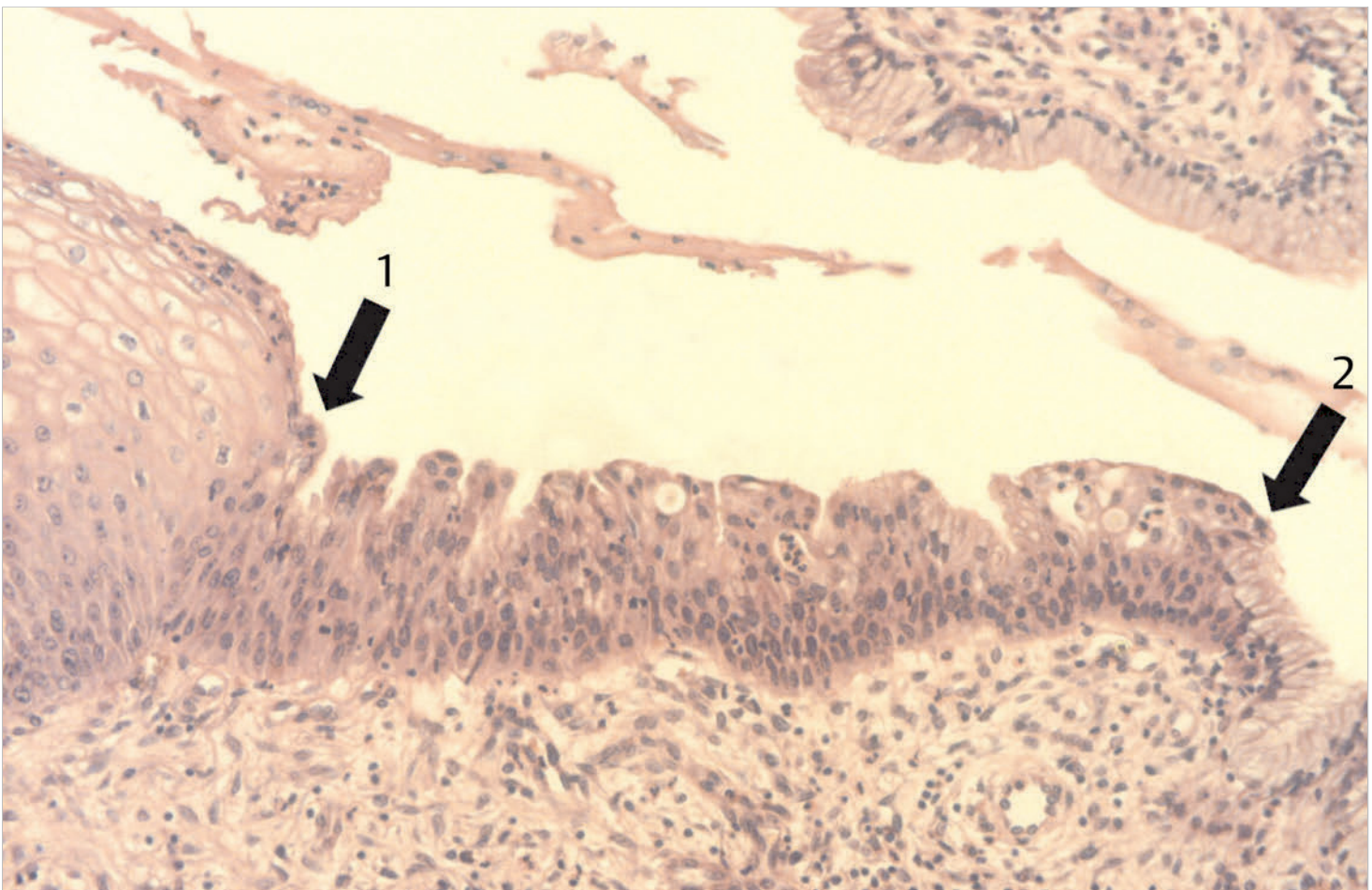


Fig. 4.3 Immature metaplastic squamous epithelium within a small transformation zone (TZ). The TZ extends from the original nonkeratinizing squamous epithelium of the ectocervix (left) to the columnar epithelium of the endocervix (right). Note the original squamocolumnar junction (arrow 1) and the new squamocolumnar junction (arrow 2). The young metaplastic epithelium is thin and contains only little glycogen.

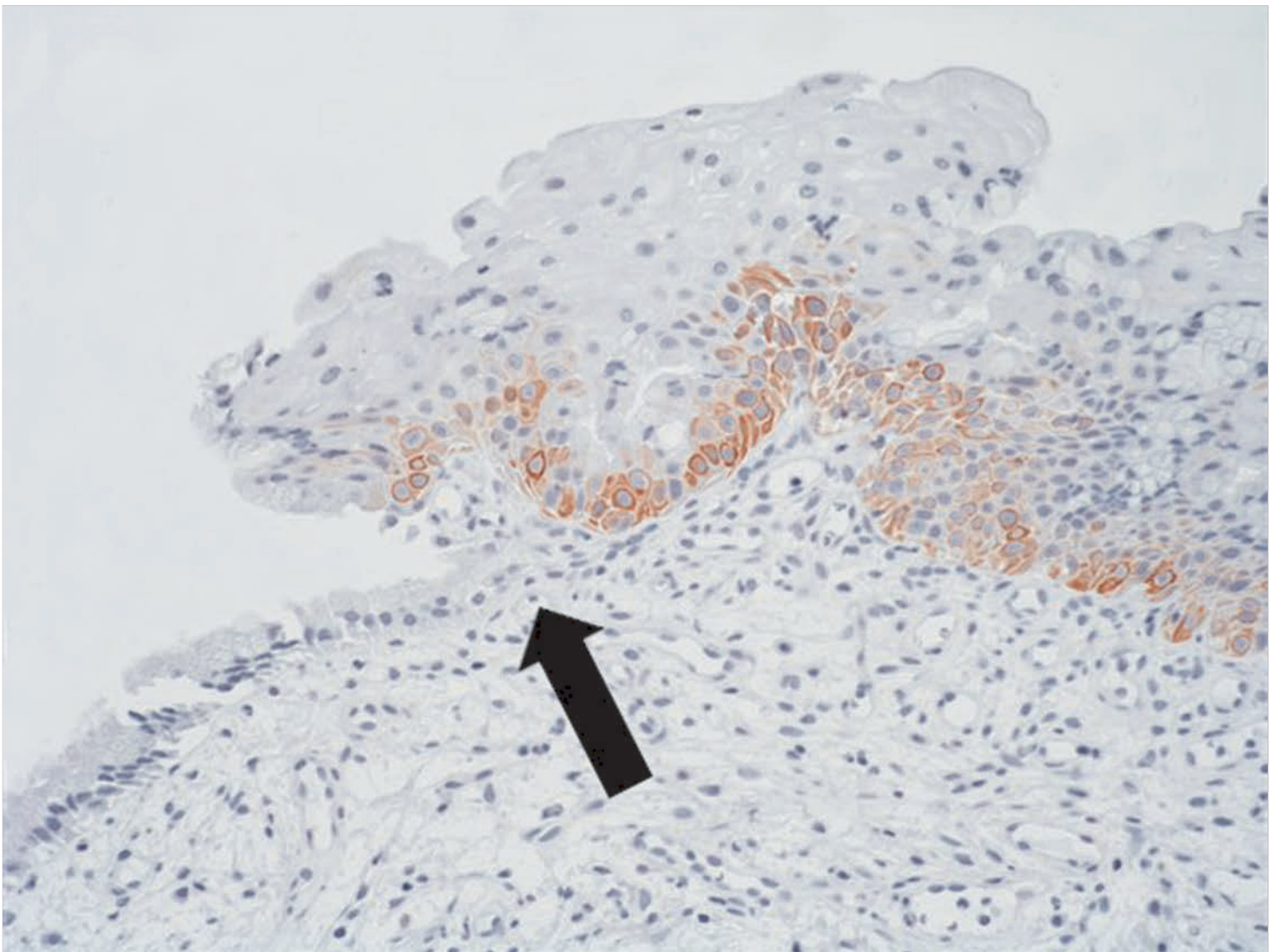


Fig. 4.4 Mature metaplastic squamous epithelium within a transformation zone becomes thicker and stratified and contains glycogen. Note the new squamocolumnar junction (*arrow*) (staining for cytokeratin 17).

4.1.4 The Mechanism of Metaplasia and Transformation

At the cervix the term *transformation* refers to squamous metaplasia (i.e., the transformation of columnar epithelium to squamous epithelium). Other metaplastic changes of the columnar epithelium of the cervix include tubal metaplasia, tuboendometrioid metaplasia, and transitional cell metaplasia.

Metaplasia is based on the reprogramming of stem cells (reserve cells) to alter their differentiation.¹⁰ Results from developmental biology show that the activity of a few critical genes determines different developmental choices. These critical genes are activated first during embryonic development. If the expression of these genes subsequently changes, tissue differentiation changes direction and a different phenotype results.¹⁰ Factors that induce this process of squamous metaplasia (transformation) at the uterine cervix include pH changes, hormonal changes, mechanical irritation, and chronic inflammation; HPV plays no causal role here.

4.1.5 Vasculature of the Normal Cervix

Microscopically, the original squamous epithelium has two types of blood vessels, referred to as network and hairpin capillaries. Network vessels form a vascular plexus that lies in the submucosal stroma beneath the basement membrane. The network vessels are most prominent when they become hyperemic and dilated during pregnancy or infections. Hairpin capillaries extend toward the epithelial surface in the connective tissue papillae. They have both afferent (arterial) and efferent (venous) branches. They are closely spaced and uniformly distributed.

Vessels underlying the metaplastic epithelium (inside the TZ) vary depending on the degree of maturation. Immature metaplasia shows long parallel vessels that are oriented radially to the external os. Treelike branched vessels can overlie nabothian cysts. In addition, the TZ also has network and hairpin capillaries similar to original squamous epithelium.

The columnar epithelium contains afferent and efferent loops of terminal vessels that extend toward the surface in the lamina propria of each of the endocervical villi.^{11,12}

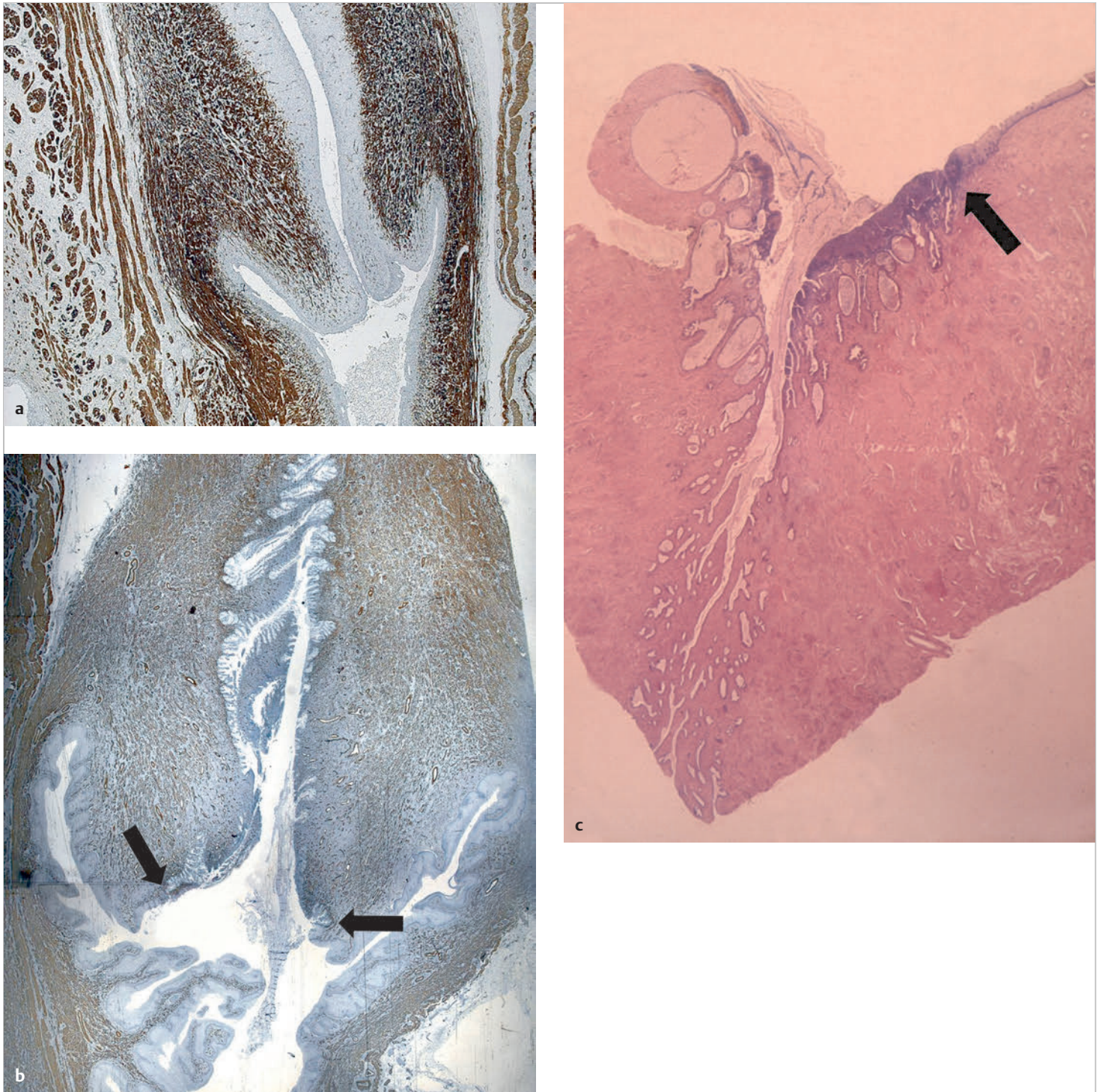


Fig. 4.5 Development of the uterine cervix. **(a)** Cervix in early fetal life without cervical glands. **(b)** In late fetal life, cervical glands migrate from the epithelial surface of the cervical canal into the underlying stroma. The squamocolumnar junction is clearly detectable from week 24 onward (*arrow*). **(c)** After menarche, the last gland is defined as the distal extent of a former ectopy. It is a lifelong anatomical landmark. Lesions proximal to the last gland are inside the transformation zone (TZ), whereas lesions distal to the last gland are outside the TZ. Note the abrupt junction of a high-grade squamous intraepithelial lesion (inside the TZ) with the original squamous epithelium at the last gland (*arrow*) in a cone specimen (**a** and **b** courtesy of H. Fritsch, Innsbruck).

4.1.6 Reactive Changes of Squamous and Columnar Epithelium

With inflammation, chronic irritation, regeneration (repair), and after radiation, the squamous and columnar epithelia undergo reactive changes characterized by epithelial disorganization (► Fig. 4.6).¹³ When reparative changes develop in mature squamous epithelium, there is usually basal cell hyperplasia that involves the lower one-third of the epithelium. Intermediate and superficial epithelial cells show maturation. These cells often

develop perinuclear halos and some degree of nuclear enlargement. Mitotic figures are normal and are confined to the basal and parabasal layers. When reparative changes develop in immature metaplastic epithelium, the nuclei of the metaplastic epithelium become hyperchromatic and enlarged. The epithelium is often acanthotic and infiltrated with inflammatory cells. When reparative changes affect columnar epithelium, the morphologic alterations include nuclear enlargement and hyperchromasia with irregularity of nuclear size and shape. Cytoplasmatic eosinophilia and loss of mucinous droplets can also occur.

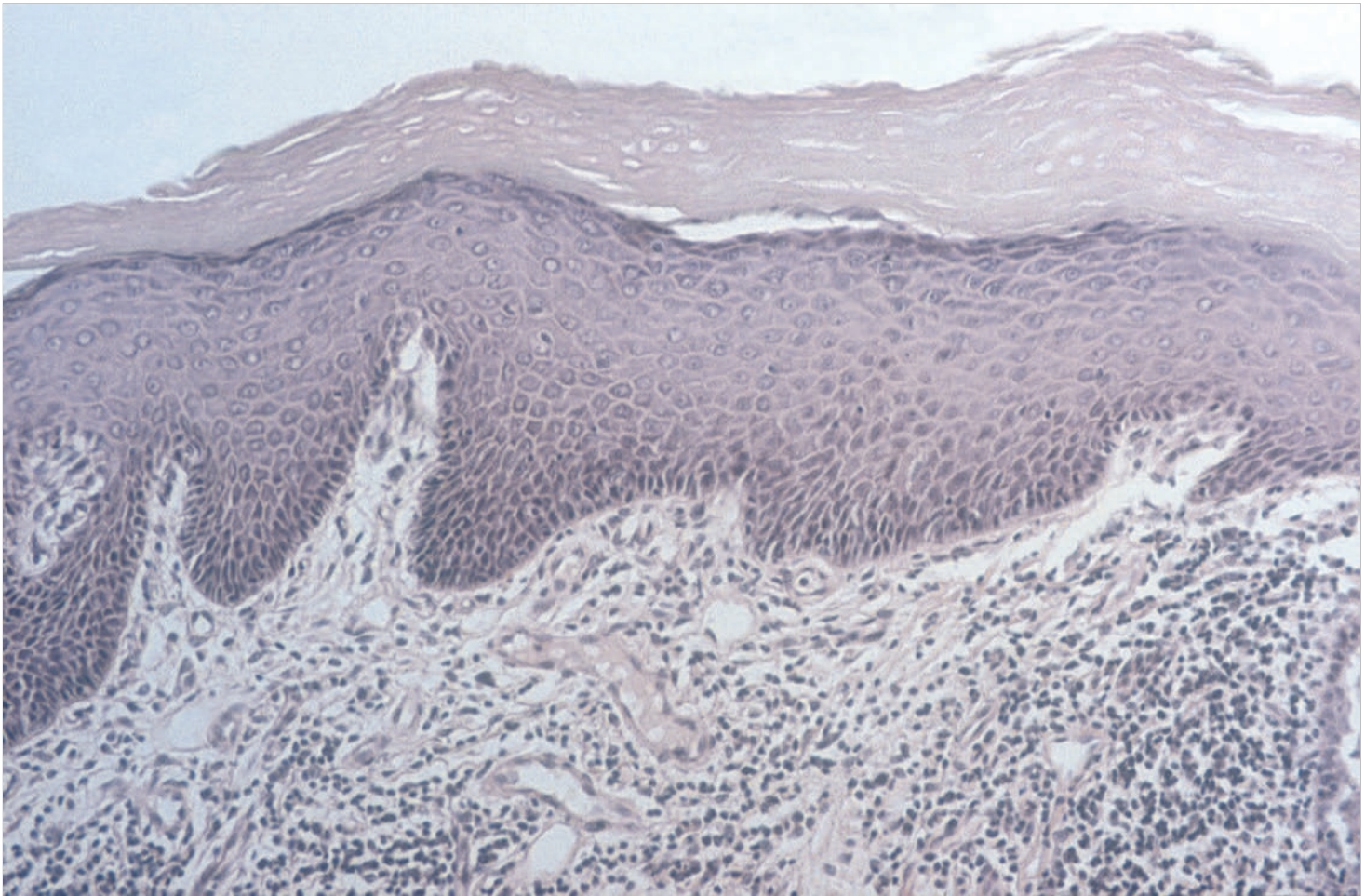


Fig. 4.6 Reactive changes in the form of acanthosis, hyperkeratosis, basal hyperplasia, and an inflammatory stromal infiltrate in the squamous epithelium.

Chronic local irritation (from a pessary, for instance) can induce parakeratosis and hyperkeratosis. However, parakeratosis and hyperkeratosis can occur without a clear inducing factor.

Radiation can cause acute and chronic morphologic changes in both the squamous and glandular epithelium. The squamous epithelium often shows nuclear enlargement with multinucleation and vacuolation of cytoplasm. In glandular epithelium, radiation can induce cellular enlargement, a loss of polarity of nuclei, and multinucleation.¹⁴

All these changes can be confused with high-grade squamous intraepithelial lesion (HSIL) or adenocarcinoma in situ (AIS). However, reactive atypia in both squamous and endocervical cells stains negatively for p16^{INK4a}.

4.1.7 HPV-Infected Squamous Epithelium

In contrast to latent infection, a productive HPV infection results in characteristic morphologic changes in the squamous cervical epithelium (► Fig. 4.7). Squamous epithelial cells with multinucleation, nuclear enlargement and hyperchromasia, irregular nuclear outlines, and perinuclear halos are referred to as *koilocytes*. Koilocytosis is the first morphologic cellular change induced by HPV infection.

4.1.8 Condylomatous Lesions

Most condylomatous lesions are fibroepithelial proliferations caused by the low-risk HPV types 6 and 11. After the infection, the virus replicates unless it is controlled by an immunologic response or medical management. The lesions produce a large number of virions that infect adjacent tissue. There are five different histologic types of condylomas: papillary, spiked, flat, inverted, and atypical.^{15,16,17}

Papillary condylomas (► Fig. 4.8) show a highly papillary architecture, with excrescences of thickened epithelium supported by a scaffold of elongated and delicate stromal stalks rich in blood vessels. The blood vessels are best seen in tangentially cut sections. The surface of papillary condylomas often shows a variable degree of keratinization. The epithelial makeup is squamous. A distinct basal layer is covered by a thick layer of prickle cells that in turn is covered by a zone of cells with clear cytoplasm, reminiscent of normal cervical squamous epithelium. The similarity to the “empty” normal glycogen-containing cells is due to perinuclear halos offset by the rather dense cytoplasm. These cells are often binucleated or multinucleated and are referred to as *koilocytes*.^{18,19} They are characteristic of viral condylomas and can show marked nuclear abnormalities. Koilocyte-like cells without nuclear enlargement or hyperchromasia are found in inflammation.

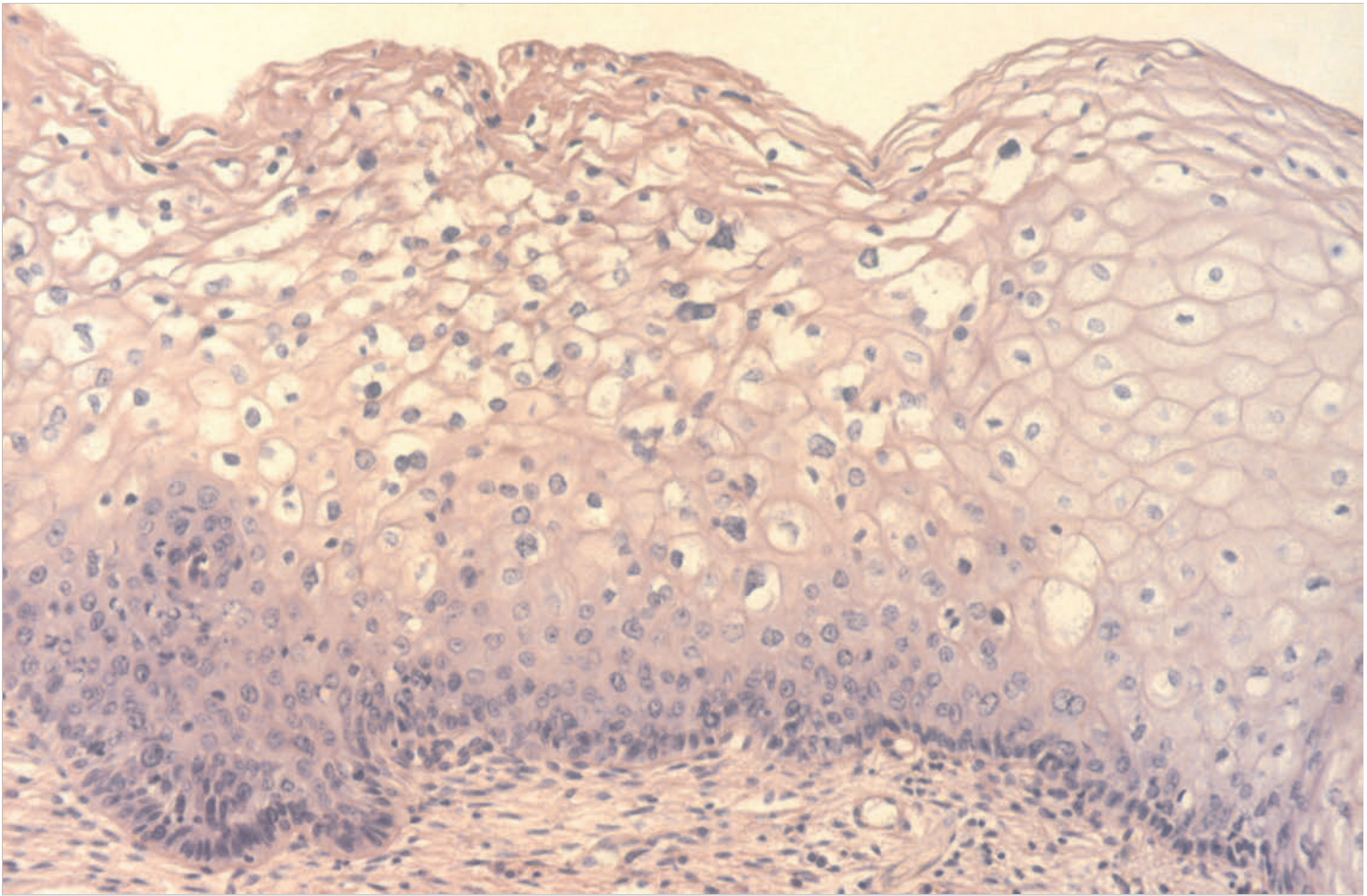


Fig. 4.7 HPV-infected squamous epithelium (permissive infection) with multinucleation, nuclear enlargement and hyperchromasia, irregular nuclear outlines, and perinuclear halos in the upper layers. Corresponds to LSIL.

Spiked condylomas show elongated and slender stromal papillae pushing upward and indenting the thickened epithelium to produce small undulations or fully developed spikes. The epithelial architecture is similar to that of papillary condylomas. Cells showing koilocytosis predominate in the superficial layers and are also found in the intermediate zone. The surface shows parakeratosis, with retention of pyknotic nuclei in the keratin.

Flat condylomas (► Fig. 4.9) are histologically and colposcopically very similar to low-grade squamous intraepithelial lesion (LSIL), and some pathologists and colposcopists believe these lesions are identical. Koilocytes, with perinuclear halos, nuclear pleomorphism, and dense cytoplasm, are found in the middle and superficial layers of the epithelium and are accompanied by cells with mild atypia. Pronounced atypia and atypical mitoses are lacking, and some of the cells can contain glycogen. As in other condylomas, the stromal papillae are elongated. The frequent occurrence of warty lesions outside the glandular field, in original squamous epithelium, provides good evidence that lesions with papillary contours do not necessarily arise in the undulating matrix of the endocervical mucosa. Histologically, the epithelium appears normal at first glance, but closer examination reveals tall stromal papillae or an undulating surface. The normal honeycomb arrangement of the epithelium is disturbed, but the cells contain glycogen. The spikes over the papillae can show keratinization. Meisels et al^{15,16,17,20} have described a variant of

flat condyloma designated as *condylomatous cervicitis and vaginitis*, a diffuse lesion resembling inflammation with poorly defined margins.

Inverted condylomas (► Fig. 4.10) also have excrescences, which can be distinctly keratinized. Characteristically, portions of the endocervical crypts, especially those of an ectopy, are involved. Such cases appear to be due to infection of metaplastic squamous epithelium.

Atypical condylomas (► Fig. 4.11) are characterized by the presence of atypical koilocytes with large hyperchromatic, smudged, and often bizarre nuclei. Atypical condyloma can therefore be misdiagnosed on cytologic smear as HSIL or even invasive squamous cell carcinoma.¹⁷ However, they typically show only minimal basal or parabasal cell atypia and orderly maturation. In contrast, warty subtypes of HSIL of the cervix, vagina, and anus and usual-type VIN exhibit nuclear pleomorphism and atypical mitosis, also in the suprabasal layers of epithelium.¹⁷

At the cervix, condylomatous lesions can arise in the metaplastic squamous epithelium of the TZ or in the original squamous epithelium. Flat condylomas, like dysplastic epithelia, develop in clearly defined fields. The border between an exophytic condyloma and normal squamous epithelium is sharp; gradual transitions are not seen. This observation supports the development of epithelial lesions in areas whose boundaries are set by foregoing squamous metaplasia.

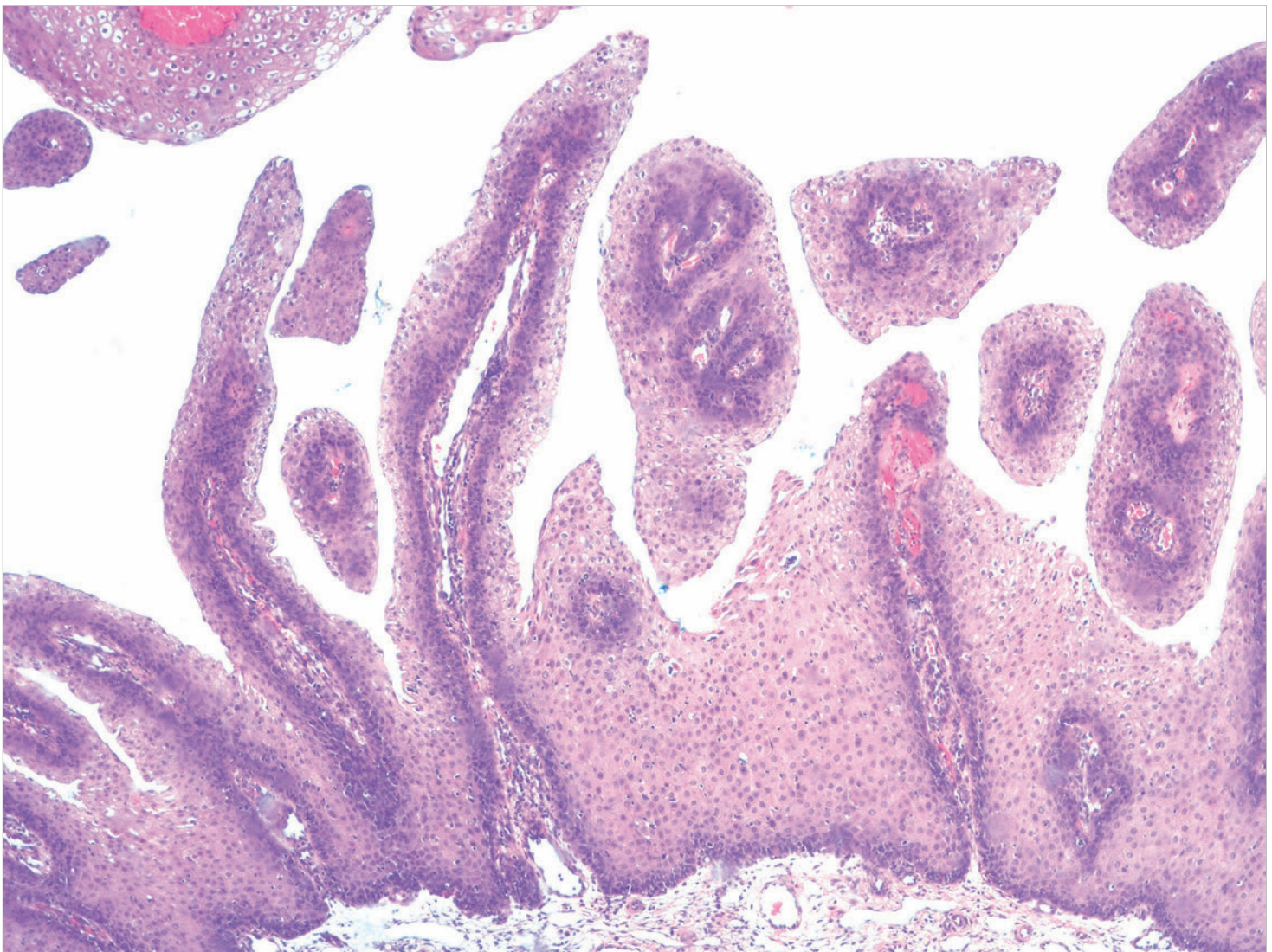


Fig. 4.8 Papillary condyloma. The normal architecture of the squamous epithelium is disturbed. The stromal stalks contain prominent blood vessels.

4.2 Premalignant Cervical Lesions

4.2.1 Histologic Terminology

Squamous Intraepithelial Lesions

The nomenclature of dysplastic forms of squamous cervical epithelium is in flux (► Table 4.1). The terms *dysplasia* and *carcinoma in situ* (CIS) are being phased out. The two-tiered system of LSIL and HSIL is more biologically relevant and reproducible than the previous three-tiered CIN terminology and is therefore recommended in the 2014 World Health Organization (WHO) system (WHO 2014).^{13,21}

4.2.2 A Brief History of the Terminology of Cervical Precursor Lesions

The term *carcinoma in situ* was coined by Broders in 1932.²² This concept built on detailed studies of noninvasive precursor lesions of cervical cancer by Schauenstein, Schottlaender, and Kermauner in the early 1900s.^{23,24} Reagan coined the term *dysplasia* in 1953.²⁵ Dysplasia came to mean all disturbances of differentiation

Table 4.1 Terminologies for squamous cervical precursor lesions.

Older classification	WHO classification (2003)	WHO classification (2014)
Mild dysplasia	CIN 1	Low-grade squamous intraepithelial lesion (LSIL)
Moderate dysplasia Severe dysplasia/ carcinoma in situ	CIN 2 CIN 3	High-grade squamous intraepithelial lesion (HSIL)

of the squamous epithelium of lesser degree than CIS. In 1963 Koss et al²⁶ posited that all precancerous intraepithelial anomalies of the cervix, regardless of their morphologic appearance, are capable of progression to invasive cancer, albeit less frequently for mild dysplasia than for severe dysplasia. In 1968 Richart²⁷ coined the three-tiered term *cervical intraepithelial neoplasia* (CIN) for the histologic continuum of dysplasia and carcinoma in situ. CIN 1, 2, and 3 indicated mild, moderate, and severe dysplasia, respectively. CIN 3 (severe dysplasia) was equated with CIS.

In 1990 Richart²⁸ transferred the cytologic concept of low-grade and high-grade neoplasia to the histologic classification of

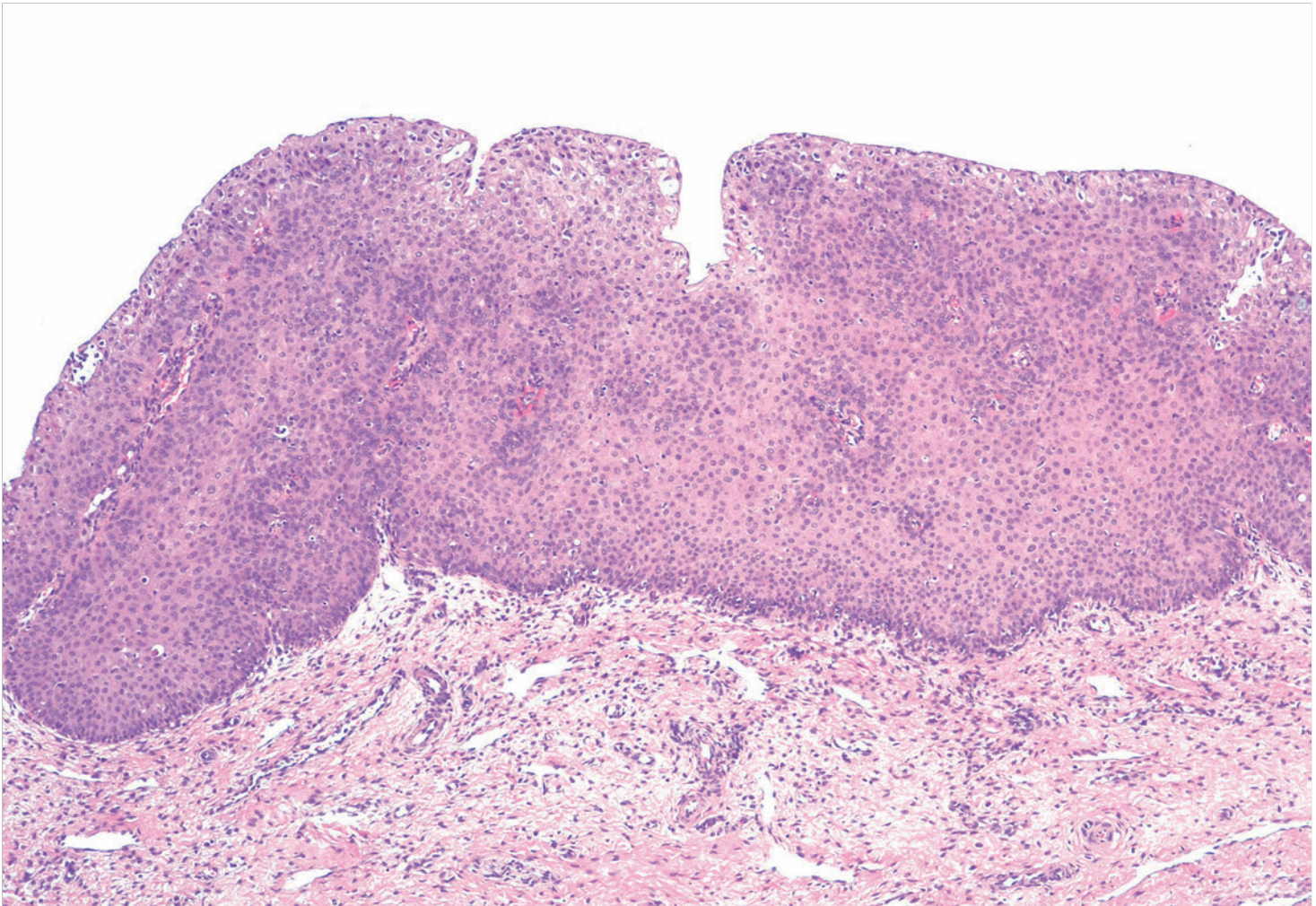


Fig. 4.9 Flat condyloma. The prominent epithelial pegs are separated by tall stromal papillae. Corresponds to LSIL.

early cervical neoplasia. This was done at a workshop in Bethesda, Maryland, sponsored by the National Institutes of Health. The histologic nomenclature defined two grades of disease: LSIL, consisting of koilocytotic atypia and CIN 1, and HSIL, consisting of CIN 2 and CIN 3. LSIL is usually self-limited and resolves spontaneously (“low SIL is no SIL”), whereas HSIL is considered a true precursor of invasive cancer. The Bethesda terminology was evaluated and updated in 2001.²⁹ The Bethesda terminology has also been applied to vulvar, vaginal, and anal intraepithelial neoplasia (see Chapter 7). In 2014, the WHO also moved to a two-tiered system (WHO 2014).

4.2.3 Glandular Intraepithelial Lesions (Adenocarcinoma in Situ)

AIS is the noninvasive precursor of invasive adenocarcinoma.³⁰ In 1952 Hepler³¹ described highly atypical neoplastic glandular cells as precursor lesions of invasive cervical adenocarcinoma, and Friedell introduced the term AIS in 1953.³² At least 50% of AIS are mixed lesions, with associated SIL.¹³ By analogy to the SIL concept, nomenclatures indicating a lesser degree of abnormality than AIS have been proposed (i.e., *endocervical dysplasia*,³³ *cervical intraepithelial glandular neoplasia*³⁴). However, glandular

epithelium does not support productive HPV infection, so there is no comparable low-grade lesion in glandular epithelium, and these terms should not be used.

4.2.4 Histology of Premalignant Cervical Lesions

Squamous Intraepithelial Lesions (SIL, CIN)

Dysplastic epithelium is characterized by the proliferation of atypical cells. There is variation in the size and shape of the cells and their nuclei, which are enlarged and hyperchromatic. Mitoses, including abnormal forms, are increased. The epithelial architecture is disturbed, with loss of polarity of the cells. The surface often shows parakeratosis or keratinization. Stratification can be completely lost, and the full thickness of the epithelium is made up of a uniform population of atypical cells. The stromal papillae are often tall, and the rete pegs bulky. Occasionally these features can be lacking. As with metaplastic squamous epithelium, the border between dysplastic and normal epithelium is sharp. It is not uncommon for several different types of dysplastic epithelium to coexist on the same cervix; the borders between them are consistently clear and sharp (► Fig. 3.10).

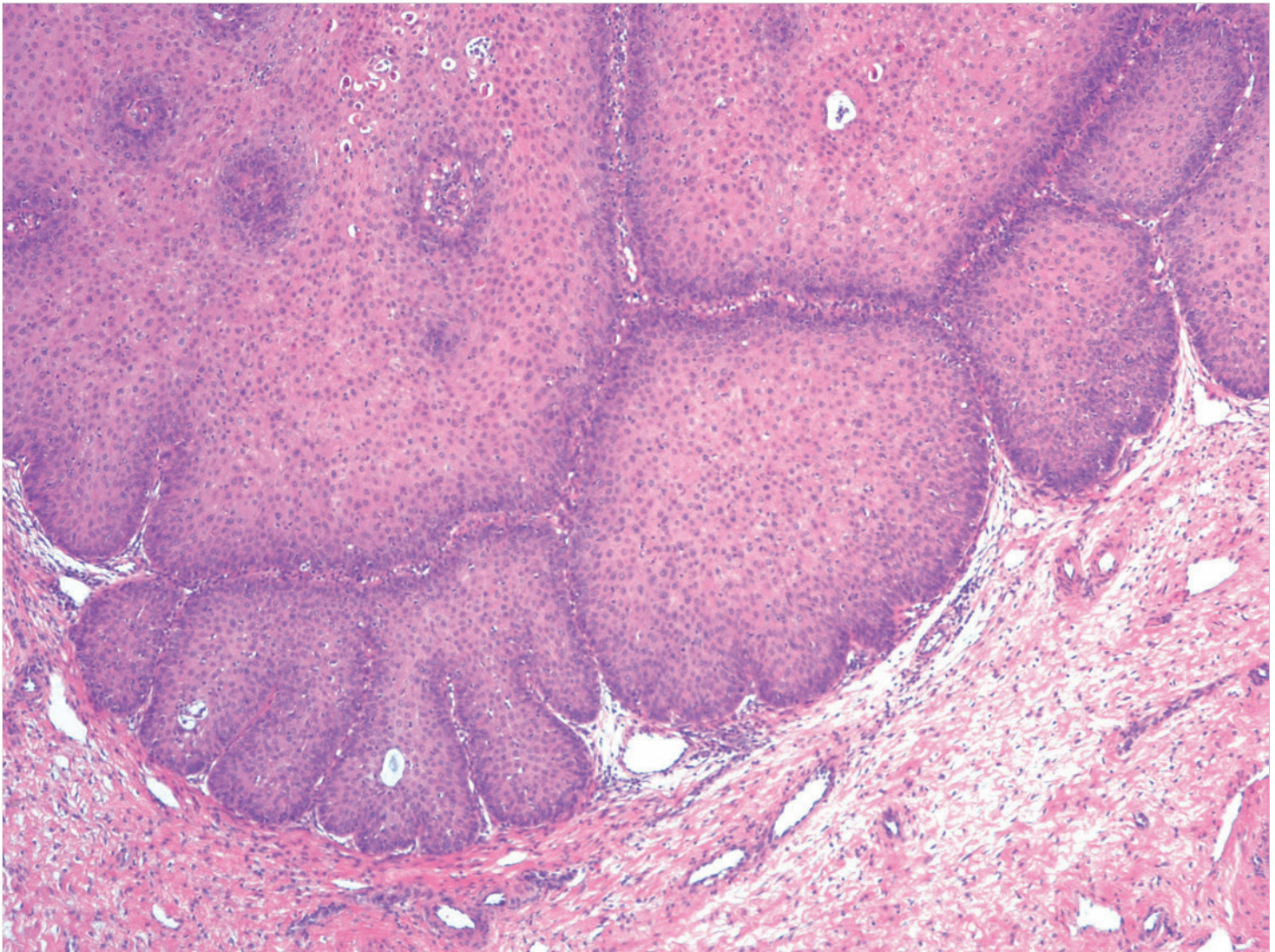


Fig. 4.10 Inverted condyloma. The lesion involves both the surface and the endocervical crypts. Corresponds to LSIL.

The *grade* of CIN is based on the degree of cellular atypia and disturbance of epithelial architecture.³⁵

- CIN 1 (LSIL): Maturation is present in the upper two-thirds of the epithelium. The superficial cells contain variable but usually mild atypia, which can include viral koilocytosis. Nuclear abnormalities are present throughout but are mild. Mitotic figures are present in the basal third and are not numerous; abnormal forms are rare (► Fig. 4.12). LSIL now also includes flat condylomas (WHO 2014).
- CIN 2 (HSIL): Maturation is present in the upper third and nuclear atypia in both the middle and lower thirds of the epithelium. Mitotic figures are generally confined to the basal two-thirds of the epithelium. Abnormal mitotic figures can be seen (► Fig. 4.13a).
- CIN 3 (HSIL): Normal maturation is absent or confined to the superficial third of the epithelium. Nuclear abnormalities are marked through most of or the full thickness of the epithelium. Mitotic figures are numerous and found at all levels of the epithelium. Abnormal mitoses are frequent (► Fig. 4.13b). Koilocytes are not seen. CIS can show a complete loss of stratification.

Atypical immature squamous metaplasia (AIM)

The term *atypical immature squamous metaplasia* (AIM) was introduced in 1983 to describe lesions featuring a uniform intraepithelial full-thickness basal cell proliferation with a high nuclear density in the absence of maturation but without sufficient criteria for a diagnosis of HSIL³⁶ (► Fig. 4.14). Nonpapillary atypical immature squamous proliferations with cytologic atypia sufficient for a diagnosis of HSIL and some metaplastic features have been called *eosinophilic dysplasia*.³⁷ Other nonpapillary atypical immature squamous proliferations that contain both metaplastic features and cytologic atypia and defy precise classification have been called *atypical immature metaplastic-like proliferation of the cervix*.³⁸

The diagnosis AIM has poor intraobserver and interobserver reproducibility on hematoxylin and eosin (HE)-stained sections. Although AIM is a helpful histologic description, the term should not be used as a diagnosis. Immunohistochemistry for p16^{INK4a} is able to distinguish between immature squamous metaplasia that should be followed up and HSIL that should be treated (► Fig. 4.14).³⁹

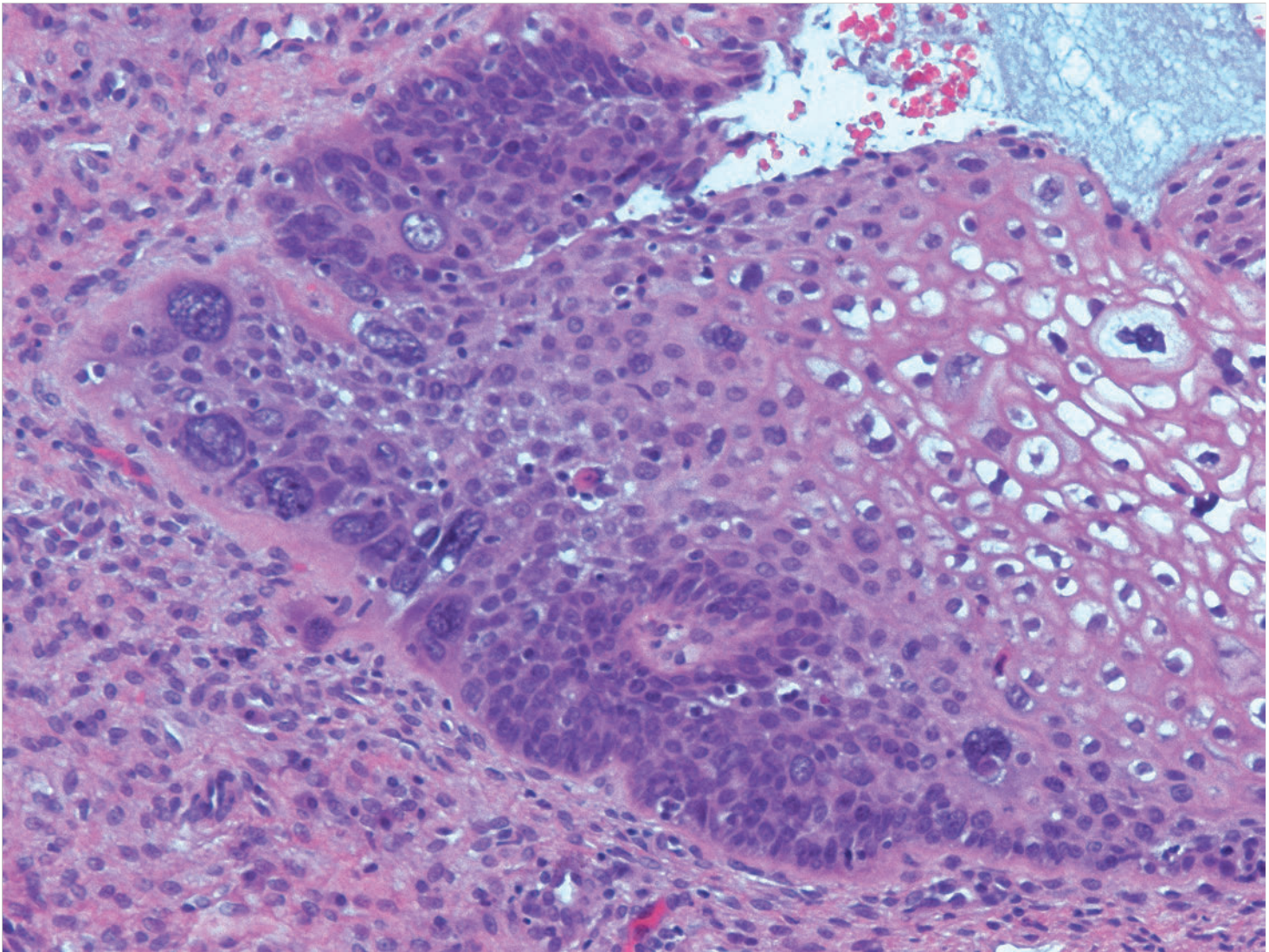


Fig. 4.11 Atypical condyloma. The lesion shows atypical koilocytes with large hyperchromatic, smudged, and bizarre nuclei in the basal layers. Corresponds to LSIL.

Adenocarcinoma in Situ

AIS is defined as noninvasive but highly atypical columnar epithelium of the cervix.^{2,9,30,40} It involves both the surface and the crypts (► Fig. 4.15). The transition between dysplastic and normal columnar epithelium is abrupt (► Fig. 3.11).

Endocervical AIS is the most common type (► Fig. 4.15). The atypical cells have elongated, cigar-shaped, hyperchromatic nuclei with coarse granular or clumped chromatin and are located at various levels within the cells so that the epithelium can imitate stratification. Mitoses, including abnormal forms, are common and characteristically found in the scanty cytoplasmic layer above the compact, dense nuclear layer (► Fig. 4.16). The amount of cytoplasm is reduced, and there is only minimal intracellular mucin.

The intestinal type of AIS has features of intestinal mucosa with goblet cells and sometimes Paneth cells⁴¹ (► Fig. 4.17).

Additional forms of AIS include clear cell type, endometrioid type, and adenosquamous type.

During pregnancy, the Arias–Stella reaction can occasionally be mistaken for clear cell AIS.¹³ The Arias–Stella reaction refers to cells within the affected glands with markedly enlarged, irregular, and hyperchromatic nuclei that can project into the glandular lumen in a hobnail pattern but lack mitotic activity. Further challenges in the differential diagnosis of AIS include inflammatory,

hyperplastic, and metaplastic changes as well as endometriosis. Because AIS is positive for p16^{INK4a} in most cases, immunohistochemical staining for p16^{INK4a} can be helpful¹³ (► Fig. 4.18).

4.2.5 Biomarkers in Diagnosis of Cervical Precancer

Research on biomarkers has the goal of identifying key events in the process of carcinogenesis, objectifying the cytologic and histologic diagnosis, and predicting the prognosis of the condition. It is hypothesized that there must be a “point of no return” in cervical pathogenesis on the way to malignancy. The ideal biomarker would clearly identify whether this point has been reached or passed.⁴²

HPV-DNA Testing

HPV-DNA testing detects latent, productive, or transforming HPV infections. Accordingly, HPV-DNA testing is more sensitive for the detection of HSIL than cytology. HPV testing is used in the clinical treatment of women with borderline cytologic abnormalities and as an adjunct to cytologic screening in women 30 years and older. The negative predictive value of the combination of negative cytology and negative HPV status approaches 99%. This has enormous implications for screening strategies.^{43,44,45}

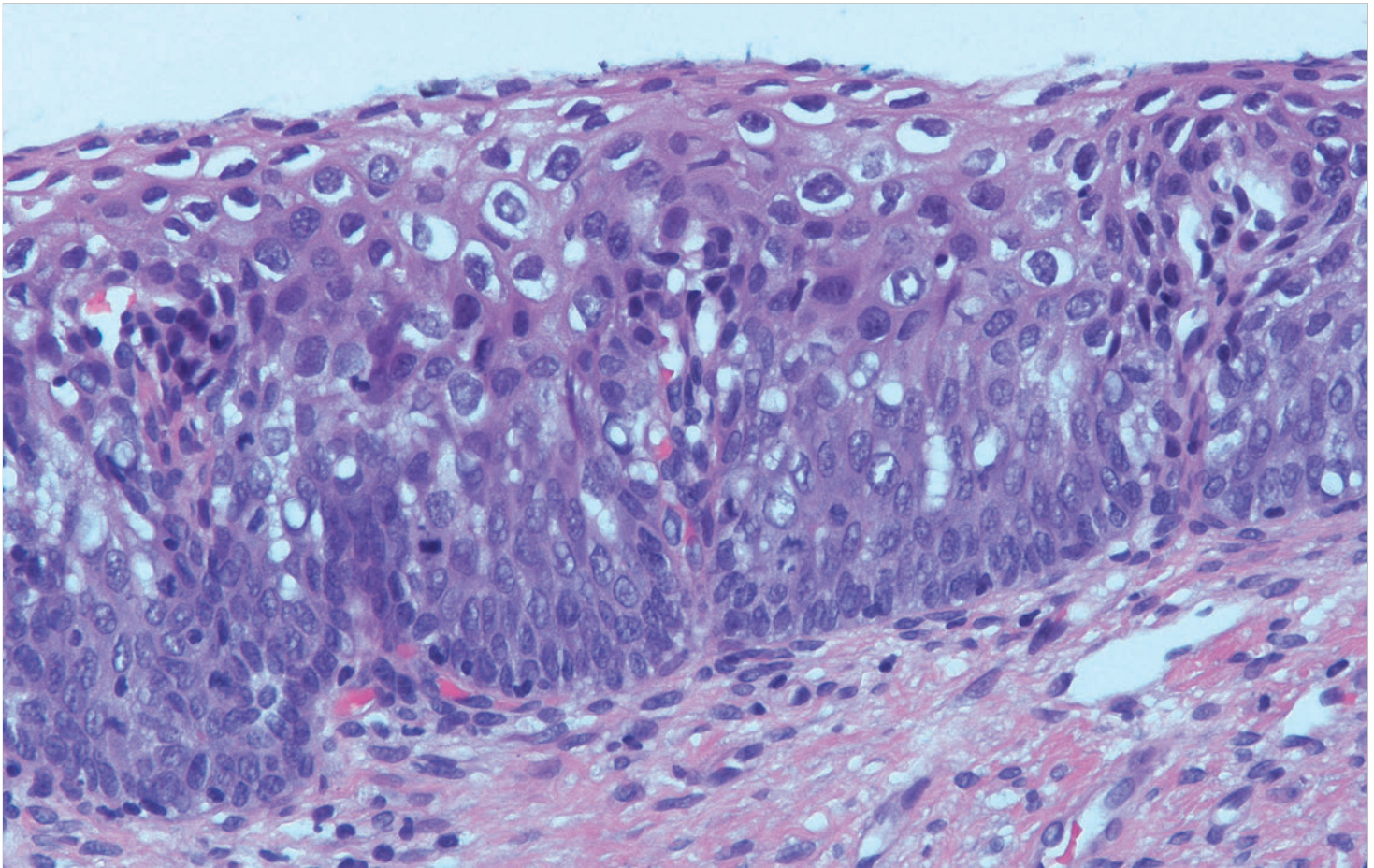


Fig. 4.12 LSIL (CIN 1) with only mild increases in cellularity, atypia, and mitoses, best seen in the basal layers. There is little disturbance of polarity.

In the follow-up of patients treated for HSIL, HPV-DNA status is a more accurate predictor of relapse than repeated cytology.⁴⁵

HPV E6/E7 mRNA Testing

E6/E7 mRNA is an indirect marker of viral oncogene expression.⁴⁶ The genes *E6/E7* are required in permissive (productive) HPV infection and are strongly expressed in the transforming phase. Therefore, HPV E6/E7 mRNA testing may serve as a specific discriminator between transient SIL and potentially progressive SIL. Recent clinical studies compare the sensitivity and specificity of HPV-DNA and HPV-mRNA testing (in different settings).

HPV-DNA Genotyping

Because HPV 16 and HPV 18 are associated with a significantly increased risk for the development of HSIL, genotyping with regard to these two high-risk types has been studied for screening for high-grade disease.^{47,48,49,50} According to Khan et al,⁴⁷ the risk for CIN 3+ is 0.8% in women negative for HPV, 17% in women with HPV 16, 13.6% for women with HPV 18, and only 3% for women positive for other HPV types.

The limitation of high-risk HPV testing and typing is that women older than 29 years with negative cytology who are positive for high-risk HPV have only a 7 to 10% risk of underlying HSIL+.^{48,49}

The L1 Capsid Protein

L1, the major capsid protein, is one of eight known HPV-specific proteins (E1, E2, E4, E5, E6, E7, L1, and L2). During the permissive

(productive) phase of the viral life cycle, the L1 capsid protein (together with L2, the minor capsid protein) is produced in the cytoplasm and translocated into the nucleus.⁵¹ This is reflected immunochemically by strong nuclear staining (► Fig. 3.3a, ► Fig. 4.19).

L1 is a major target of the immune response.⁵² More severe SIL gradually loses the capacity to differentiate, and increasingly fails to express L1. Lesions with L1 expression in biopsy or cytology samples are more likely to regress than L1-negative lesions.^{53,54, 55,56} Therefore, the detection of L1 may serve as a marker for SIL with a potential to regress. Some SIL, however, still retains the potential to replicate the virus while already displaying the transforming phase of the HPV infection. Such lesions are positive for both L1 and p16^{INK4a} (► Fig. 4.20).^{57,58}

p16^{INK4a}

Overexpression of the cell-cycle regulatory protein p16^{INK4a}, a cyclin-dependent kinase inhibitor, is associated with transforming HPV infections. Its overexpression results from functional inactivation of the retinoblastoma protein (pRb) cell-cycle pathway by high-risk HPV E7 oncoprotein.⁵⁹ The inactivation of pRb is a key molecular event in HPV-mediated molecular carcinogenesis. Therefore, p16^{INK4a} overexpression is highly sensitive and highly specific for HSIL and AIS (► Fig. 3.4, ► Fig. 4.18).

Additional staining of HE slides for p16^{INK4a} has been shown to improve the accuracy of diagnosing HSIL and AIS in cervical biopsies.^{60,61,62} Interobserver agreement was also improved. p16^{INK4a} is therefore being used increasingly in routine diagnostic pathology to confirm HSIL and AIS.⁴³

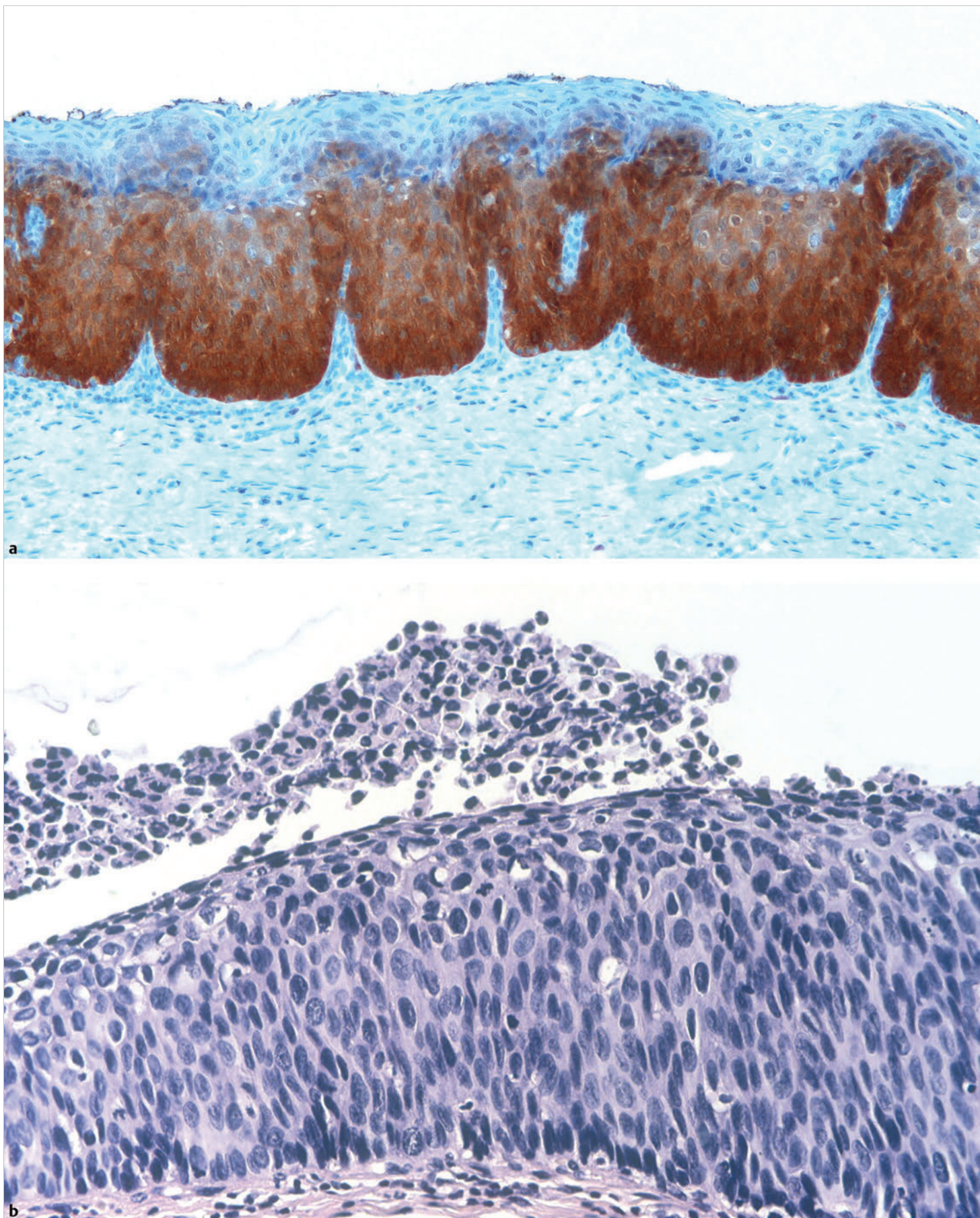


Fig. 4.13 HSIL. (a) CIN 2: Atypia is limited to the basal half of the epithelium, whereas the superficial half is normal. Immunohistochemistry for p16^{INK4a}. (b) CIN 3 with numerous mitoses extending to the upper third of the epithelium and atypical basaloid cells extending almost to the surface.

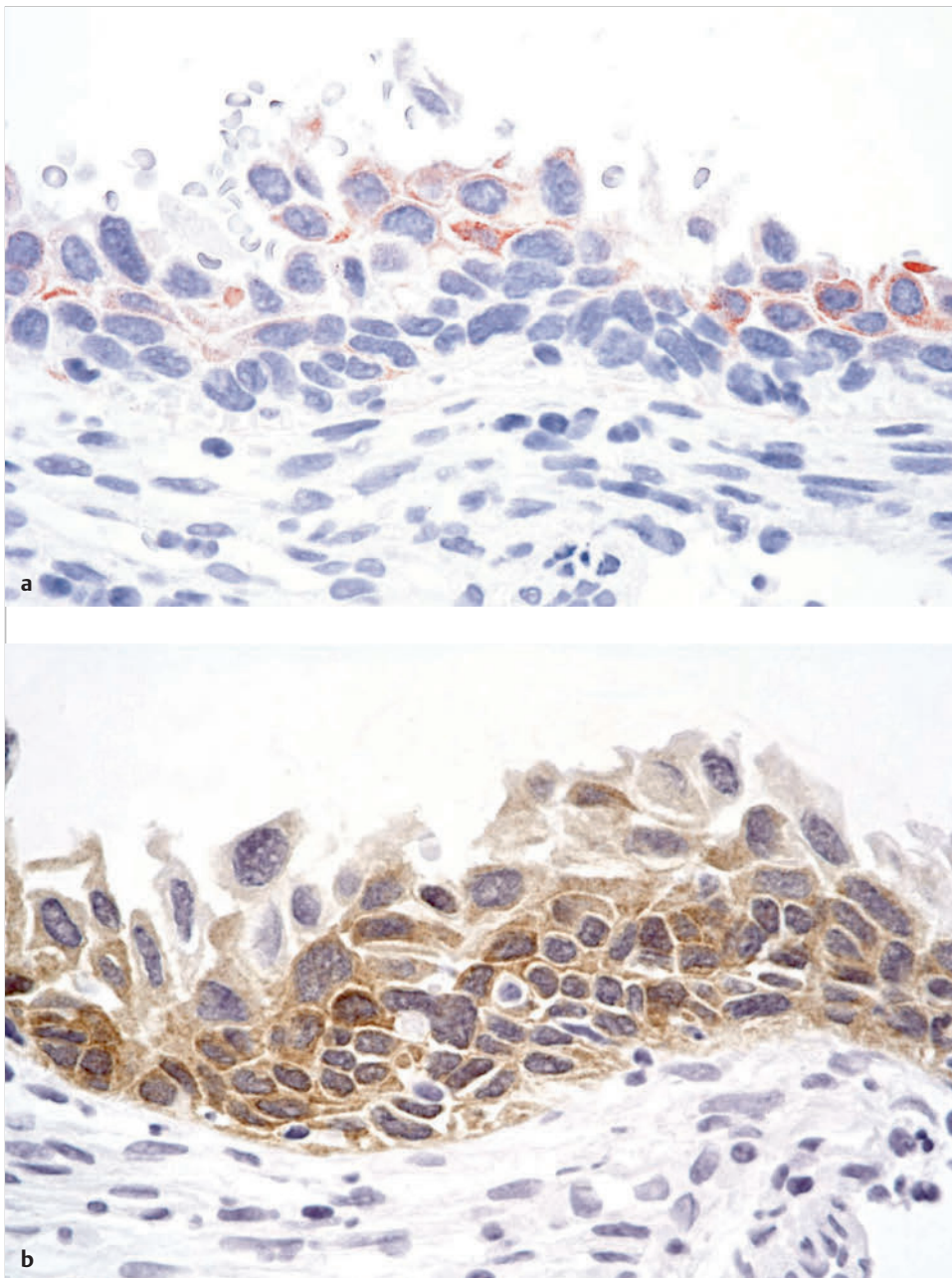


Fig. 4.14 Atypical immature squamous metaplasia.³⁹ (a) Note the atypical immature squamous proliferations with nuclear atypia in a flat lesion (staining for cytokeratin 17). (b) Immunohistochemistry for p16^{INK4a} can distinguish between immature squamous metaplasia and HSIL (from reference 39).

Diffuse p16^{INK4a} staining has prognostic value in LSIL. In a prospective clinical study, CIN 1 lesions negative for p16^{INK4a} persisted or regressed, whereas CIN 1 lesions with a positive diffuse staining pattern showed an increased risk for progression to HSIL.⁶³

The overexpression of p16^{INK4a} has been also been studied in cervical cytology specimens, particularly in the triage of equivocal or mildly abnormal Pap cytology. In a large controlled study of ASC-US (atypical squamous cells of undetermined significance) or LSIL, the sensitivity of p16^{INK4a} cytology for the detection of HSIL was similar to that of HPV testing, but specificity was higher.⁶⁴ A second-generation approach combines staining for p16^{INK4a} and the proliferation marker Ki-67 in a single test. Dual staining for p16^{INK4a} and Ki-67 has shown promise in clinical studies for

screening, for the triage of ASC-US or LSIL Pap cytology results, and for the triage of positive HPV test results (► Fig. 4.21).^{43,65,66}

Other Potential Biomarkers

Methylation of HPV 16 E2 binding sites is frequent in squamous cell cancers, indicating that it is a rather late event in carcinogenesis. Methylation of E2 binding sites, which is most frequent in HSIL lesions, is proportional to the severity of the lesion.⁶⁷ Methylation markers such as CADM 1 and MAL may therefore have diagnostic potential.^{43,68} Cytokeratin 3 is reported to be able to discriminate CIN 2 from CIN 3 in cervical biopsies.⁶⁹ Proteins expressed in cells with aberrant S-phases can also be used to detect dysplastic cervical lesions.^{43,70}

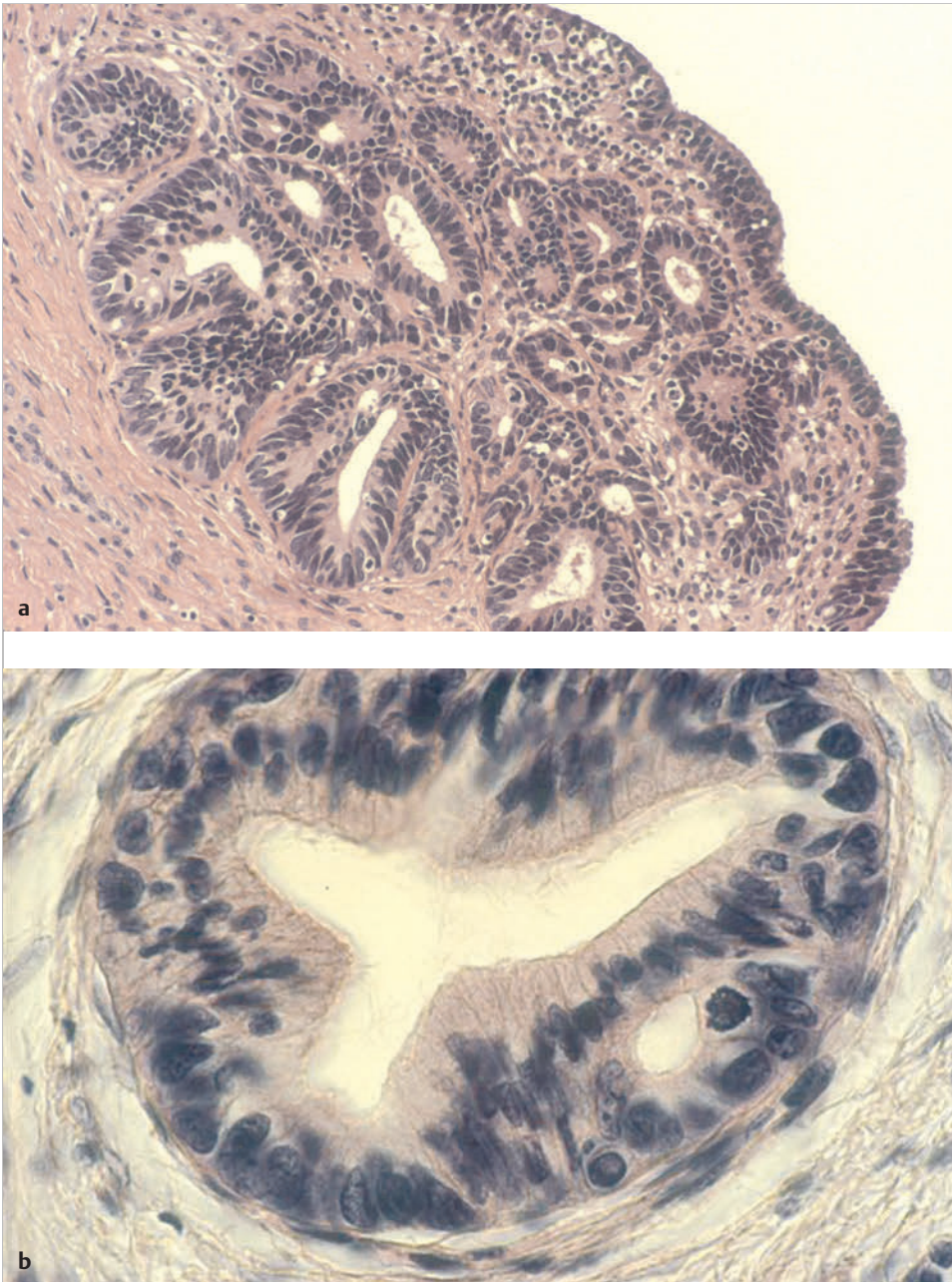


Fig. 4.15 a,b Adenocarcinoma in situ, endocervical type. The lesion involves both the surface and the crypts. The atypical cells have elongated, cigar-shaped, hyperchromatic nuclei with coarse granular or clumped chromatin. The amount of cytoplasm is reduced, and there is only minimal intracellular mucin.

4.3 Invasive Cervical Cancer

The spectrum of invasive cervical cancer ranges from microscopic lesions to macroscopic, clinically frank, invasive lesions measuring several centimeters. Cervical cancer is widely staged according to the system developed by the International Federation of Gynecology and Obstetrics (FIGO),⁷¹ which is based mainly on clinical findings and measurements (as opposed to imaging results).

4.3.1 Microinvasive Carcinoma

Microinvasive cancers (MICs) of the uterine cervix are mostly intraepithelial lesions that have breached the basal membrane and begun to invade the underlying cervical stroma. The current (2009) FIGO definition⁷¹ applies to both squamous cell carcinoma and adenocarcinoma and stipulates measurement in two dimensions:

- **FIGO stage IA1** encompasses stromal invasion with a depth ≤ 3.0 mm and a horizontal extension ≤ 7 mm.

- **FIGO stage IA2** encompasses stromal invasion with a depth of > 3.0 mm and ≤ 5.0 mm, and a horizontal extension ≤ 7.0 mm.
- Larger lesions, although they cannot be identified clinically, are staged as **FIGO stage IB1**.

Because MIC cannot be seen in most instances on colposcopy, the diagnosis requires histologic examination of step-serial sections of an excisional specimen that includes the entire lesion.

Burghardt et al⁹ divided the natural history of MIC into three phases (► Fig. 4.22). The first is between the appearance of intraepithelial neoplasia and the first invasive breakthrough into the cervical stroma (early stromal invasion); the second phase is between this first breach and the formation of recognizable invasive buds; and the third phase ends when the lesion forms a measurable tumor that has attained the ability to metastasize.

Early Stromal Invasion

Histologic invasion of squamous cell carcinoma begins as *early stromal invasion*. The term denotes the first invasive protrusions of HSIL into the stroma and is a histologic entity. The term was

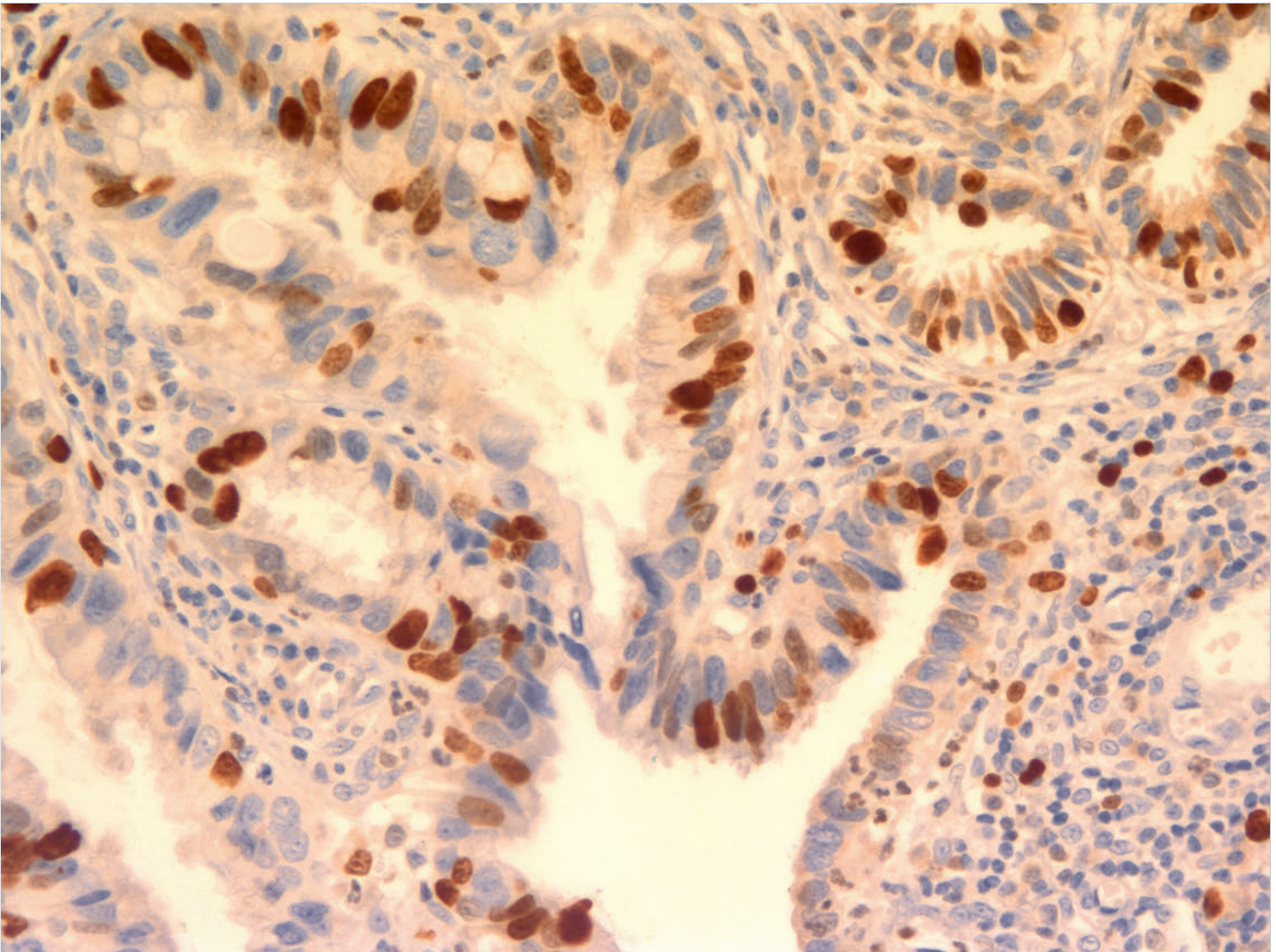


Fig. 4.16 Adenocarcinoma in situ, endocervical type. Note the high growth fraction of the neoplastic transformed glandular epithelium (staining for Ki-67).

included in the 1985 FIGO classification,⁷² which distinguished *early stromal invasion* from the considerably larger *microinvasive carcinoma*, but was dropped from the 1995 and subsequent versions of the staging system.⁷³ We consider the diagnosis of early stromal invasion of considerable practical relevance, because lymph node metastases are exceedingly rare.^{74,75,76}

The histologic criteria for early stromal invasion are round, club-shaped, or finger-like projections extending from the base of a field of HSIL into the underlying stroma (► Fig. 4.22a),^{9,77,78,79} The invasive tongues differ distinctly from the parent epithelium in that the invasive cells are enlarged, with bigger and paler nuclei and abundant eosinophilic cytoplasm, giving the impression of greater differentiation. The stroma surrounding the invasive buds is not normal (desmoplastic stromal reaction). It is edematous and infiltrated to a greater or lesser extent by round cells, usually lymphocytes (► Fig. 4.23). Epithelial buds surrounded by normal stroma without an inflammatory infiltrate should not be mistaken for early invasion. Immunohistochemistry is of little value for diagnosing early invasion because small basement membrane ruptures as visualized by staining for laminin and type IV collagen are common in normal cervical epithelium and in SIL without early invasion, especially in areas with inflammatory infiltrates.¹³

Approximately 12% of cases of early stromal invasion have more than one invasive focus.⁸⁰ Subsequently these individual buds can coalesce to form a single focus of tumor. Some have suggested that lesions characterized by confluence of multiple foci have a worse prognosis than those with a single invasive focus.

About half the foci of early stromal invasion originate from HSIL deep in cervical glands and without connection to the surface epithelium. Only 33% of early stromal invasion occurs on the ectocervix, in connection with the surface epithelium of the TZ, and about 18% of cases develop in the endocervical canal.⁸⁰

Microinvasive Tumor

A microinvasive carcinoma is a small invasive tumor with invasive buds that have begun to branch out and form a measurable tumor (► Fig. 4.22c). Since 1995, FIGO stipulates measurement of the lesion in two dimensions, depth and width. The *depth* of invasion is defined as the distance of the deepest focus of tumor from the epithelial–stromal junction of the adjacent dysplastic epithelium (surface or crypt). If the origin of the invasive focus cannot be seen, the depth of invasion is measured from the basal lamina of the surface epithelium to the deepest focus of invasion.⁸¹

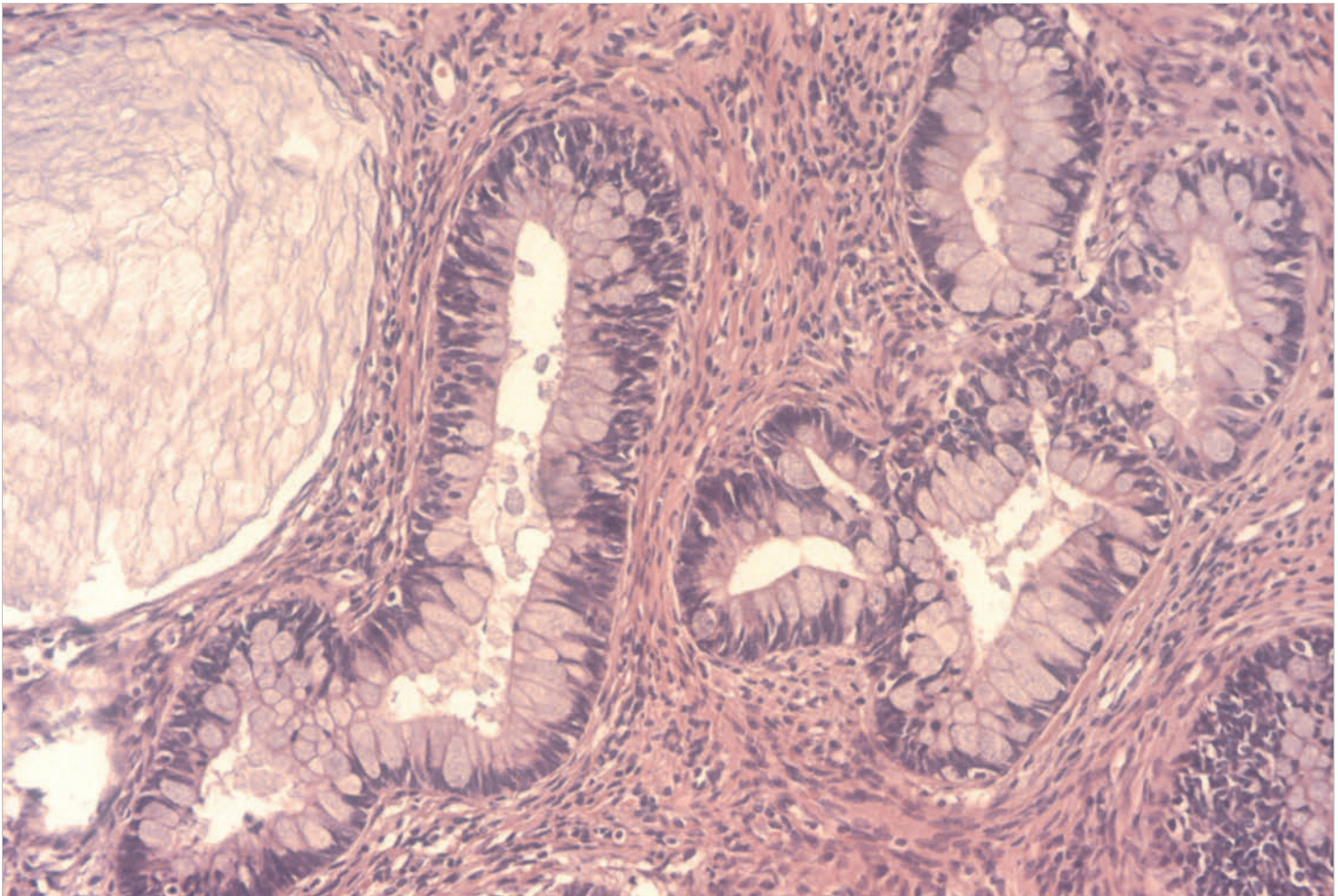


Fig. 4.17 Adenocarcinoma in situ, intestinal type. The lesion has features of intestinal mucosa (goblet cells).

The 2009 FIGO definition⁸² does not specify how to measure horizontal spread; this is straightforward for unifocal lesions, but not so if a lesion has multiple invasive foci. Multiple foci can be close together or far apart.⁸³ We and others suggest measuring lateral extension of microinvasion between the two farthest points where invasion is identified.^{13,84}

Width was added to the FIGO definition because a lesion with 4- to 5-mm invasion can measure up to 22 mm in width⁸⁵ and because width can be relevant to the prognosis.^{86,87,88,89} Tan et al⁹⁰ reported a lesion with less than 5 mm invasion but superficial spread into the endometrial cavity.

Burghardt et al^{9,76,91} repeatedly suggested that the volume of invasive tumor is the most reliable prognostic factor in MIC and that there is no risk of metastatic spread for tumors less than 500 mm³ in volume, provided that no lymphovascular invasion (LVSI) is seen. The volume of a microinvasive tumor can be estimated by assuming that the third (unmeasured) dimension does not exceed the greater of the other two diameters by more than 50%. In step-serial sections of a cone specimen with a unifocal invasive lesion, tumor size can be measured in two dimensions in the section that shows the largest area, and the third dimension can be calculated by counting the number of sections (which is time-consuming). The present FIGO classification does not address volume, and few groups have tested Burghardt's hypothesis.⁹²

Lymphovascular Space Invasion

Roche and Norris⁹³ defined lymphatic space invasion as endothelial-lined spaces containing tumor cells that are contiguous with the stroma (► Fig. 4.22d). In general, the histologic detection of lymphatic space invasion is of consequence since invasive cervical cancer typically spreads lymphatically.

In view of the difficulties in distinguishing small blood vessels and capillaries from lymphatic channels, the term *lymphovascular space invasion* (LVSI) is often used for all types of vascular channels. Interobserver variation in the diagnosis of LVSI is high and identification of LVSI can be difficult. Spaces around tumor nests can be caused by tissue retraction and/or mechanical artefacts as well as the implantation of surface epithelium, which can lead to a false diagnosis of LVSI. Also, the incidence of LVSI is directly proportional to the number of sections taken. Monoclonal antibodies against lymphatic epithelium can be helpful in distinguishing between LVSI and artefacts.¹³

Microinvasive Adenocarcinoma

Microinvasive adenocarcinoma of the uterine cervix is a small glandular tumor in which the extent of stromal invasion is minimal and the risk of lymph node metastases is negligible (► Fig. 4.24). Histologically it is difficult to determine where AIS

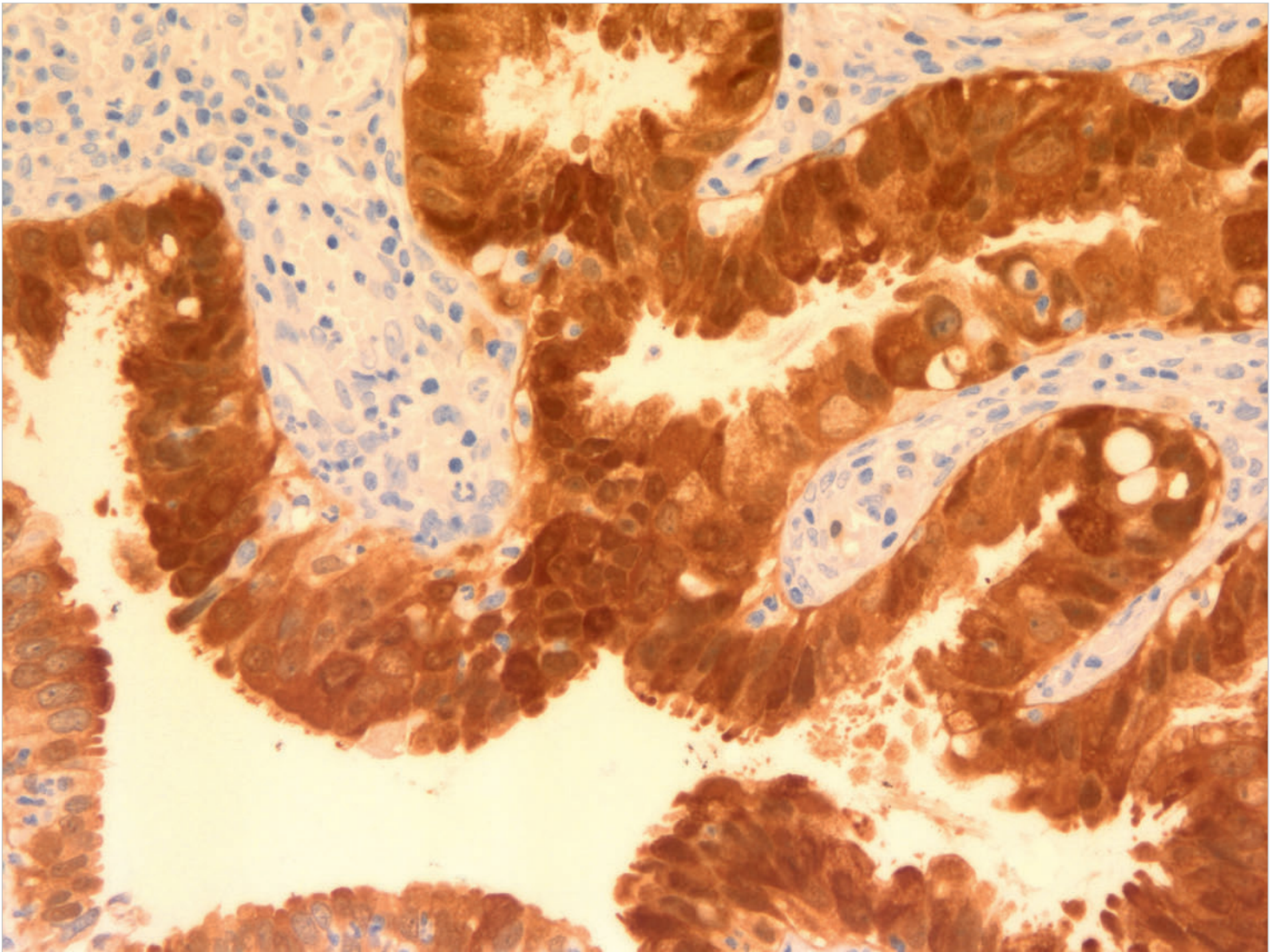


Fig. 4.18 Adenocarcinoma in situ. The lesion stains positive for p16^{INK4a}, thus distinguishing it from a reactive glandular lesion.

stops and early invasion begins.^{2,9,30} The well-established criteria for microinvasive squamous carcinoma do not apply. The often bizarre ramifications of the atypical glands can mimic invasion. Nevertheless, if the stroma investing the glandular protrusions is completely normal, it is unlikely that microinvasion has begun. The depth of penetration of the glands into the stroma is an indirect criterion: it should not exceed the normal depths of the crypts in the stroma (about 6 to 8 mm). Atypical glands more than 6 to 8 mm under the basement membrane are suspicious for invasion.¹³

Close proximity of glands and blood vessels can be a sign of microinvasion.⁹⁴ LVSI and a desmoplastic reaction of the stroma can help confirm the diagnosis. Like its squamous counterpart, microinvasive adenocarcinoma requires examination of the entire lesion on the basis of step-serial sections.

Once invasion or microinvasion is established, the depth and width of invasion are measured. The depth of invasion is measured on the slide with deepest invasion from overlying the in situ carcinoma or, when there is no in situ component, from the surface. The width is the greatest diameter of the neoplasm measured parallel to the surface.³⁵

4.3.2 Frank Invasive Cervical Cancer

Frank invasive cervical cancers (also called clinical cancers) show several growth patterns. They can be *exophytic*, *endophytic*, or a combination of the two (► Fig. 4.25a–e). Tumors confined to the endocervical canal are of particular diagnostic importance. *Exophytic carcinomas* are often not deeply invasive (► Fig. 4.25a,b). Their bulk grows into the vaginal lumen and caps the cervix like a mushroom. Such tumors are classically soft, friable, and subject to contact bleeding.

Endophytic carcinomas (► Fig. 4.25c) extensively infiltrate the stroma without much surface growth. If they are not excessively large, there is little change in the size or shape of the cervix. Histology shows a flat ulcer surrounded by normal or abnormal squamous epithelium. If some of the tumor is still covered by epithelium, the eroded area masks its true size. The surface of an endophytic tumor can be rough, papillary, granular, and ulcerated. The surfaces of *partly endophytic*, *partly exophytic* tumors (► Fig. 4.25d,e) are usually ulcerated. In spite of their exophytic component, they can deeply infiltrate the underlying stroma. A purely *endocervical tumor* cannot be seen on inspection; it distorts and enlarges the cervix according to its size.

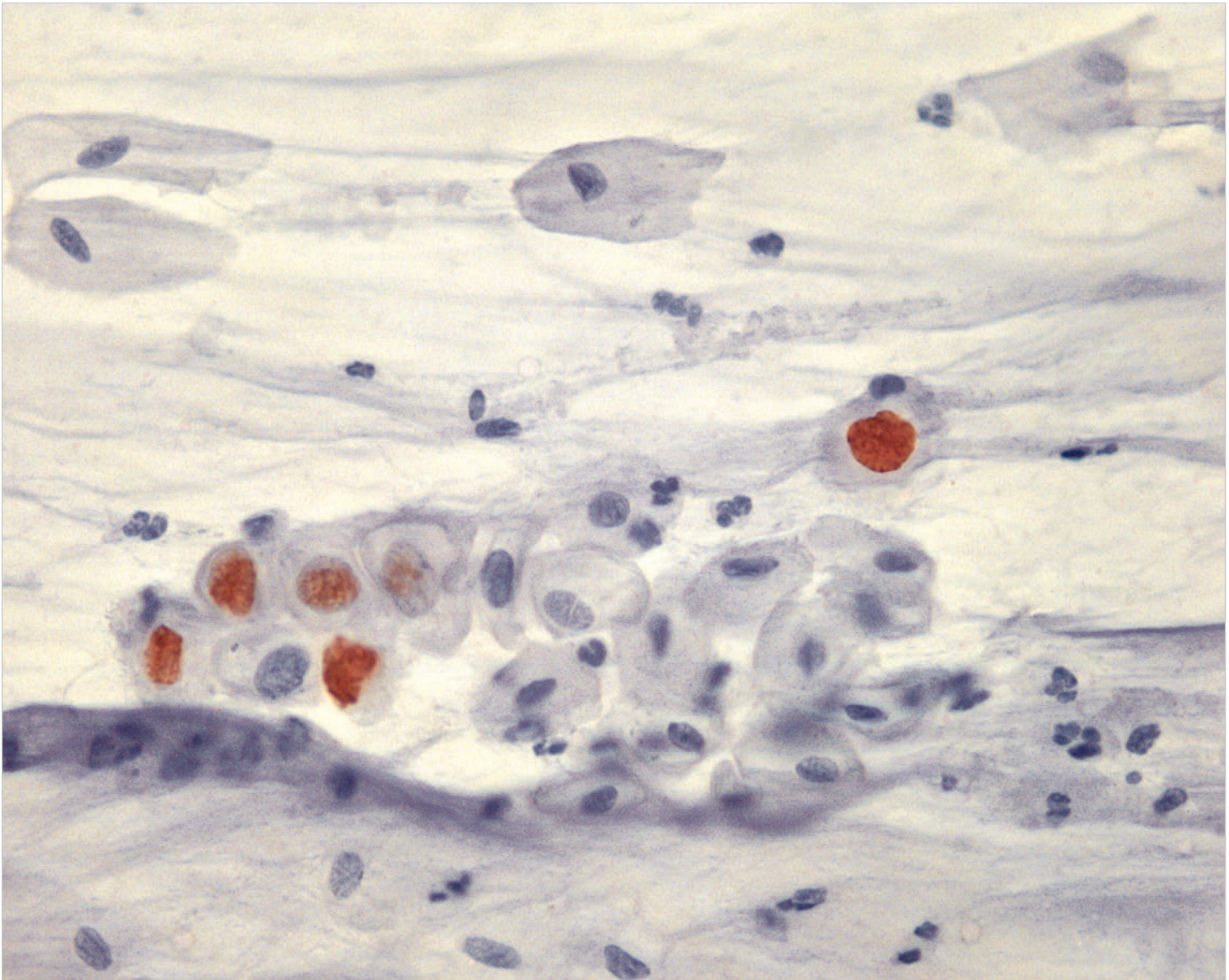


Fig. 4.19 Pap smear with L1-positive LSIL. Note the strong nuclear staining of atypical superficial squamous cells.

Microscopically, the WHO³⁵ recognizes three histologic categories of invasive cervical carcinoma: squamous cell carcinoma, adenocarcinoma, and “other epithelial tumors,” including adenosquamous carcinoma, adenoid basal cell carcinoma, neuroendocrine tumors, and undifferentiated carcinomas.

Squamous Cell Carcinoma

Most (about 80%) invasive cervical cancers are squamous cell lesions. Depending on their ability to undergo keratinization, squamous cell carcinomas can be divided into two groups: *keratinizing* and *nonkeratinizing*. The defining feature of keratinizing carcinomas is the presence of keratin pearls. Nonkeratinizing forms can show individual cell keratinization, but not keratin pearls.

Histologic grading divides squamous cell carcinomas into three groups: well differentiated (grade 1), moderately differentiated (grade 2), and poorly differentiated (grade 3).

In well-differentiated forms (grade 1), tumor cells can show marked cellular and nuclear atypia but are unmistakably squamous. Tumor cells show large, irregular, and hyperchromatic nuclei and abundant eosinophilic cytoplasm. They are tightly packed but have well-developed cellular borders and intercellular bridges. Typically, keratin pearls can be seen. Individual cell keratinization (dyskeratosis) may also be present.

In moderately differentiated (grade 2) tumors, the neoplastic cells are more pleomorphic. The cytoplasm is less abundant. The cellular borders and intercellular bridges appear indistinct. Keratin pearls are rare. Mitotic figures are more numerous than in grade 1 lesions.

Grade 3 tumors contain pleomorphic tumor cells with giant, bizarre nuclei and abnormal mitotic figures. Signs of keratinization are rare and may be difficult to find. Spindle-shaped configuration may also be present. Immunohistochemical staining for cytokeratins and epithelial membrane antigen (EMA) can help demonstrate the epithelial origin of the lesion.

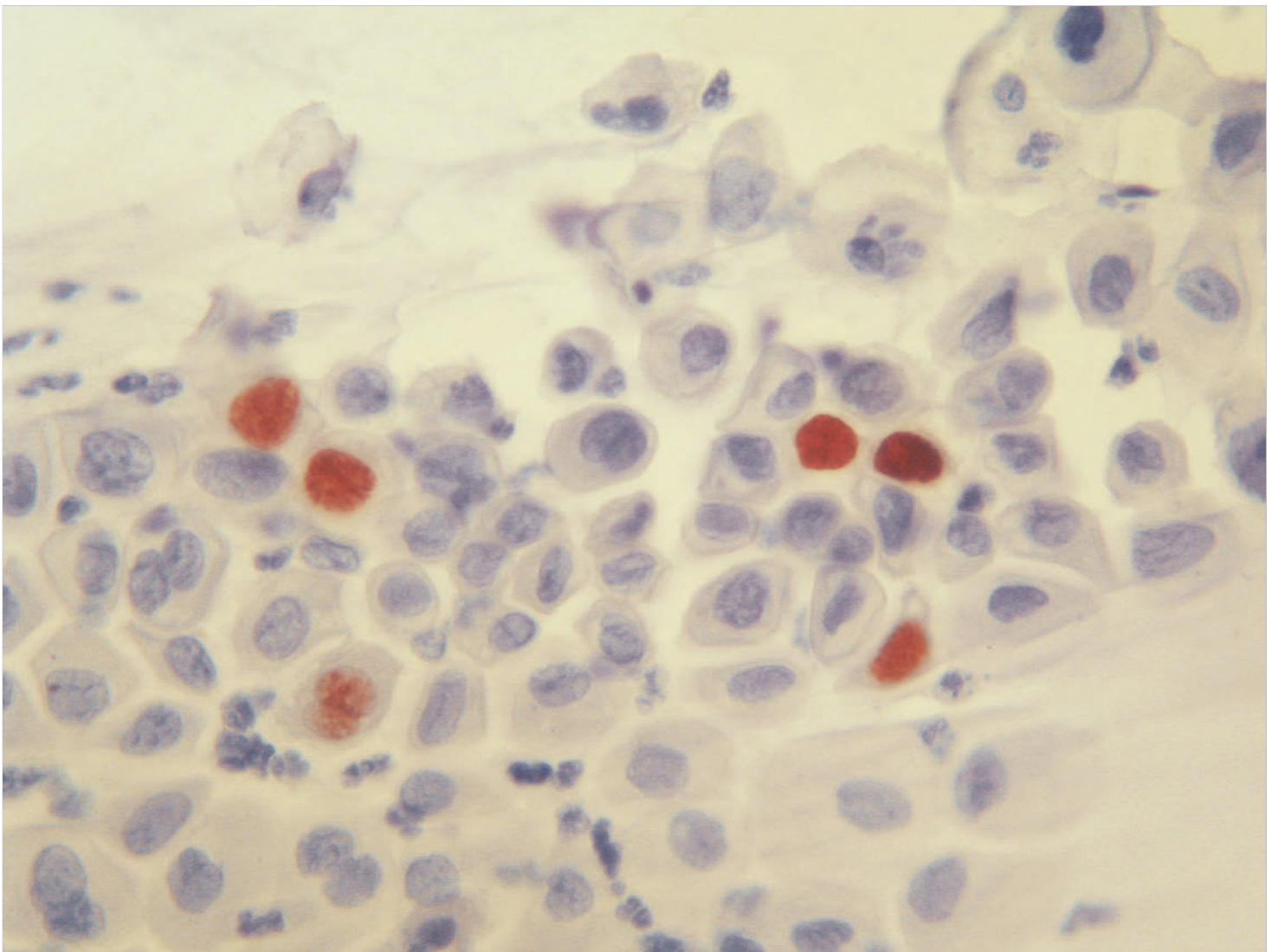


Fig. 4.20 Pap smear with L1-positive HSIL. Note the strong L1-positive atypical parabasal cells.

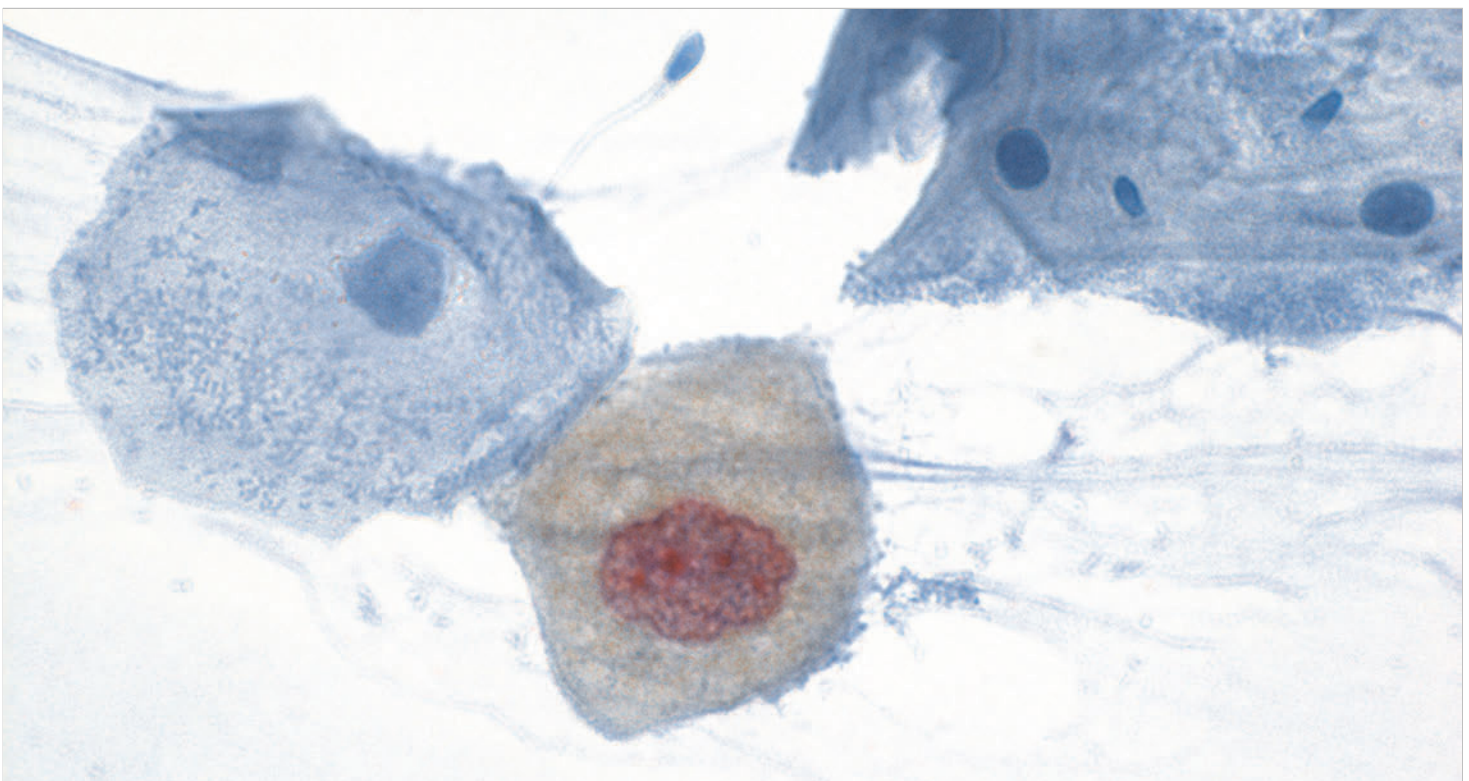


Fig. 4.21 Pap smear with dual staining for p16 and Ki-67. p16 is identified in the cytoplasm by the brown staining, Ki-67 is identified by the red staining of the nuclei in the same cells.

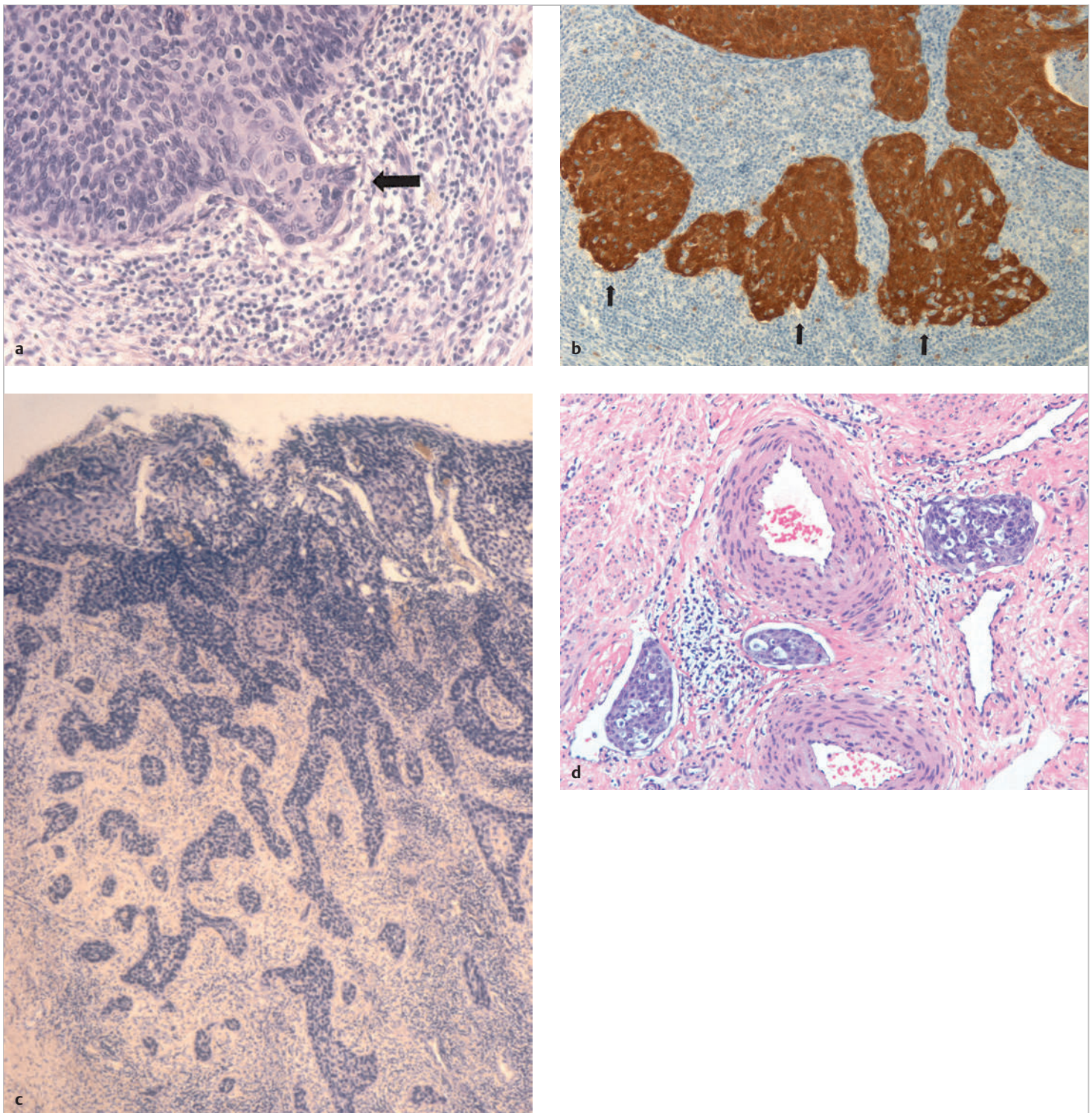


Fig. 4.22 Microinvasive squamous cell carcinomas. The natural history of these lesions can be divided into three phases: (a) Between the appearance of intraepithelial neoplasia and the first invasive breakthrough into the cervical stroma (early stromal invasion) (arrow); (b) between this first breach and the formation of invasive buds (arrows); and (c) until the invasive buds form a measurable tumor that has attained the ability to metastasize. (d) The figure show lymphovascular space invasion of the cervical stroma.

Lymphoepitheloma-like carcinoma,⁹⁵ verrucous carcinoma, and warty (condylomatous) carcinoma are rare variants of squamous cell carcinoma. These tumors are reported to have a better prognosis than typical squamous cell carcinoma.¹³

Adenocarcinoma of the Cervix

Cervical adenocarcinoma displays a wide variety of morphologic patterns. Because these cell types and patterns are frequently mixed, the histologic classification is based on the predominant cell type.¹³

Mucinous adenocarcinoma, of which there are five variants (endocervical, intestinal, signet-ring cell, minimal deviation, and villoglandular) is the most frequent type of adenocarcinoma (about 75%). It is defined as an adenocarcinoma in which the tumor cells contain intracytoplasmic mucin.³⁵

The well or moderately differentiated *endocervical variants* retain their resemblance to normal columnar cervical epithelium. The cells are tall and contain abundant cytoplasm. The glands lie back to back, with virtually no stroma between them. Mitoses are numerous and situated mostly near the luminal surface.

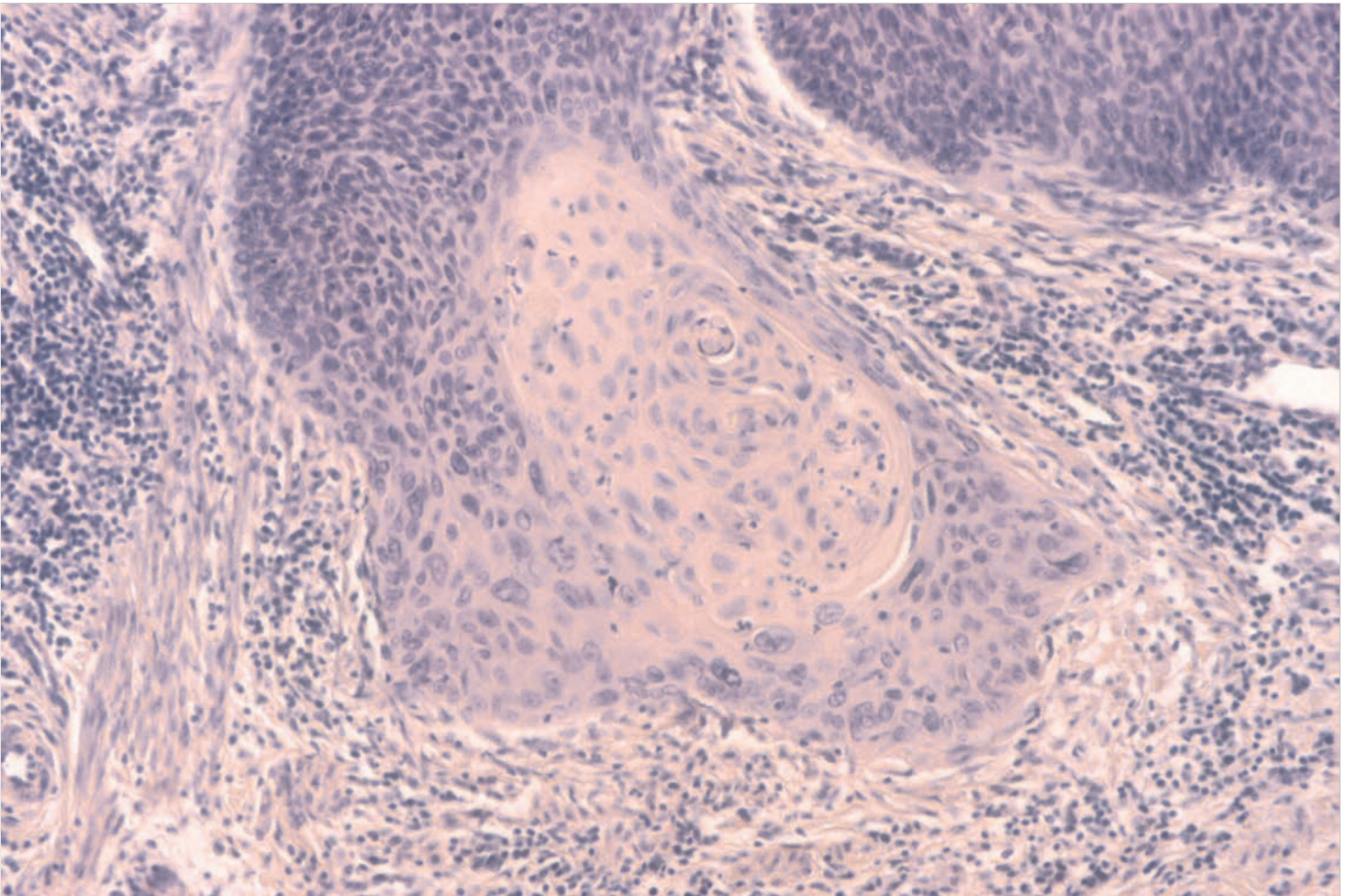


Fig. 4.23 Early stromal invasion. The invasive tongue differs distinctly from the parent epithelium in that the invasive cells are enlarged, with bigger and paler nuclei and abundant eosinophilic cytoplasm, giving the impression of greater differentiation. The stroma surrounding the invasive buds is desmoplastic and infiltrated by lymphocytes.

In the poorly differentiated endocervical variant, solid strands of tumor cells predominate with pseudorosette formation or palisading of nuclei. Intracytoplasmic mucin is rare, but monocellular accumulation of mucin may be found.

Intestinal variants resemble adenocarcinoma of the colon. The cancers contain goblet cells and occasionally argentaffin and Paneth cells.

The *minimal deviation* variant is extremely well differentiated. The diagnosis cannot be made in a small biopsy specimen. The characteristic microscopic feature is the presence of cytologically widely normal but architecturally atypical cervical glands that vary in size, shape, and location and show depth invasion. Vascular and perineural lymphatic involvement is frequent. This type may be associated with Peutz–Jeghers syndrome and with a second primary ovarian mucinous adenocarcinoma.⁹⁶

The *villoglandular variant* generally occurs in young women. These tumors are well differentiated and have a frondlike pattern resembling villoglandular adenoma of the colon. One or several layers of columnar cells, some of which contain mucin, line the papillae and glands. The invasive portion is composed of elongated branching glands separated by fibrous stroma.

Endometrioid adenocarcinoma has a histologic structure identical to that of the endometrial-type adenocarcinoma arising from the corpus mucosa.

Clear cell adenocarcinoma is composed mainly of clear or hobnail cells arranged in a solid, tubulocystic, or papillary pattern. It closely resembles the clear cell carcinoma of ovarian, endometrial, or vaginal origin.^{13,97}

Serous adenocarcinoma is histologically similar to serous adenocarcinoma of the ovaries and endometrium. It also may contain psammoma bodies.

Mesonephric adenocarcinoma originates from remnants of the mesonephric duct in the lateral wall of the cervix. Hence it is located deeper in the cervical wall than other types of adenocarcinoma. The histology shows characteristic small tubular glands lined by mucin-free cuboidal epithelium containing eosinophilic hyaline secretion in their lumens.

Cervical adenocarcinomas have to be distinguished from adenocarcinoma of the uterine corpus. In most types, immunohistochemistry and HPV testing can be useful to identify the site of origin. Cervical adenocarcinomas usually are positive for carcinoembryonic antigen high-risk HPV, and p16^{INK4a} but negative for estrogen receptors and vimentin.^{98,99} With the aid of HPV testing, some cervical adenocarcinomas that may have been previously diagnosed as endometrial carcinomas are now being correctly assigned as cervical adenocarcinomas. However, a small subset of cervical adenocarcinomas test as HPV negative including uncommon subtypes.¹⁰⁰

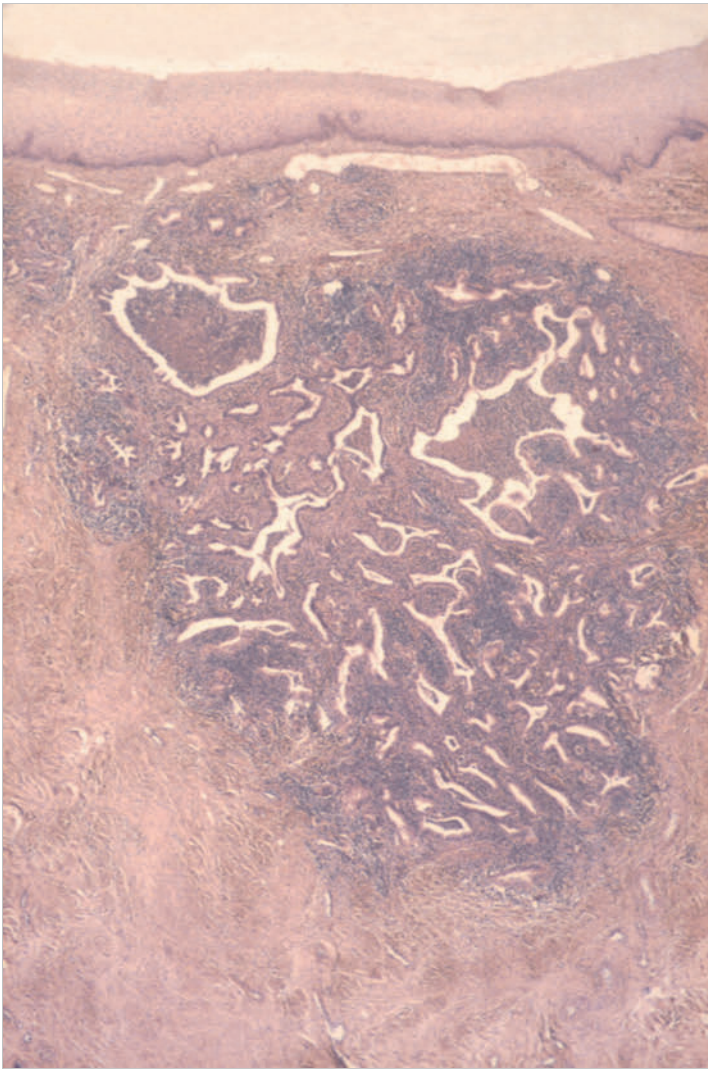


Fig. 4.24 Microinvasive adenocarcinoma. The neoplastic glands, and the stromal reaction to them, form an invasive tumor with 4-mm depth of invasion and 3-mm lateral spread. Normal cervical glands are present just under the surface.

Other Epithelial Tumors

The group of “other epithelial tumors” contains *neuroendocrine small cell carcinoma*. Small cell carcinoma of the cervix is cytologically and histologically identical to its counterpart at other sites, such as the lung.^{13,101} Its biological behavior is highly aggressive. The prognosis is worse than of stage-comparable poorly differentiated squamous cell carcinomas and adenocarcinomas (► Fig. 4.25b).

4.4 Histology of Colposcopic Findings

4.4.1 Microscopic Versus Colposcopic Morphology

The colposcopic image results from the reciprocal relationship between the epithelium and the stroma. The epithelium is a filter

through which both the incident and reflected light must pass. The epithelium itself is colorless, whereas the stroma is red because it contains blood vessels. With the colposcope, the redness of the stroma is visible through the epithelium. The nature and intensity of the color depend on the thickness and architecture of the epithelium and on the nature of the stroma.

Colposcopic lesions are clearly demarcated from their normal surroundings and from each other. It is important to appreciate that practically all colposcopically suspicious lesions have sharp, distinct borders.

4.4.2 Topography and Extension of SIL (CIN)

Location of Dysplastic Epithelium with Respect to the Transformation Zone: the Last Gland

Histologic studies of conization specimens show that SIL almost always ends at the last gland (► Fig. 4.5, ► Fig. 4.26). This applies both to lesions arising in the TZ and to those arising in original squamous epithelium. Our own study of 152 conization specimens showed that SIL was located exclusively on one or the other side of the last gland in 97% of cases. In 81%, the columnar epithelium was involved, and in 33% the lesions ended at the last gland. In 16% of cases, dysplastic epithelium was situated distal to the last gland, and in 13% the proximal portion ended at the last gland. Thus, the last gland frequently (46%) represented either the distal or proximal border of SIL. Only in 3% of cases did dysplastic epithelium extend beyond the last gland.⁹¹

The more distal (beyond the last gland, on the ectocervix and outside the TZ) the location of SIL, the better its differentiation. In contrast, HSIL is mostly located in the gland field proximal to the last gland, that is, inside the TZ, and is often situated high in the endocervical canal, where LSIL is uncommon.

The location of a lesion with regard to the TZ was reintroduced into the 2012 International Federation for Cervical Pathology and Colposcopy (IFCPC) colposcopic terminology,¹⁰² after having been omitted in 2002. It is an independent predictor of HSIL or invasive carcinoma¹⁰¹.

Superficial Spread of SIL (CIN)

HSILs frequently involve not only the surface of the cervix but also the endocervical glands, whether as part of an ectopy or within the endocervical canal (inside the TZ). This involvement can be focal or extend to most of the gland field (► Fig. 4.27). Endocervical crypts can be completely occupied by SIL, resulting in solid epithelial buds lying within the stroma, or only partially affected, with intact segments of columnar epithelium. When SILs involve endocervical crypts, the borders between them are still sharp. Occasionally, squamous metaplasia can be seen isolated within crypts.

SIL in endocervical glands is due to squamous metaplasia, not active spread.^{9,103,104} The earlier idea (based on Robert Meyer’s

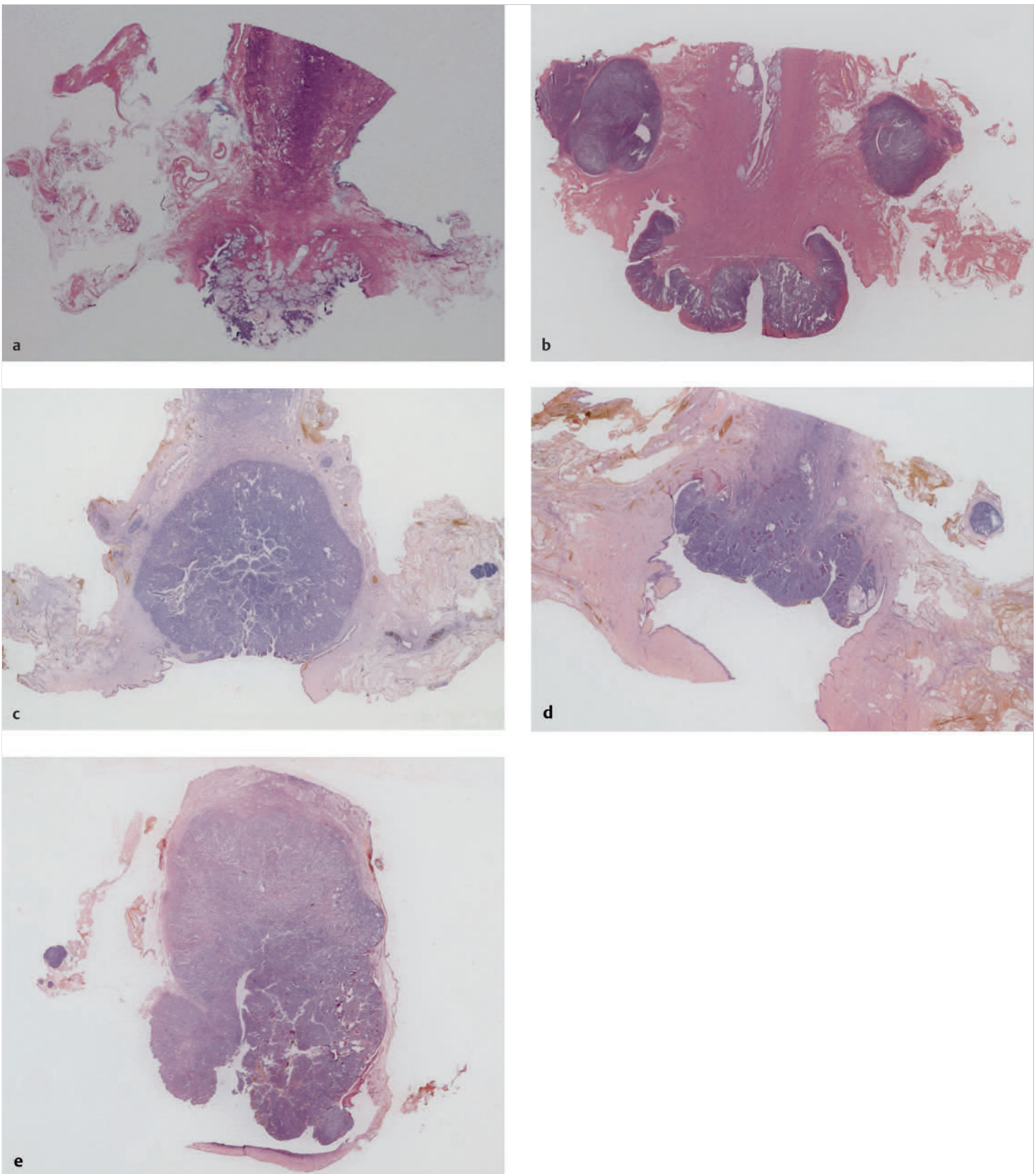


Fig. 4.25 Grossly invasive cervical cancers: giant sections. (a) Entirely exophytic mucinous adenocarcinoma; (b) neuroendocrine small cell carcinoma with typical exophytic growth and large lymph node metastases in both parametria; (c) entirely endophytic squamous cell carcinoma (the vaginal portion is ulcerated); (d,e) partly exophytic and partly endophytic squamous cell carcinoma. Note a lymph node metastasis in the left parametrium in (d).

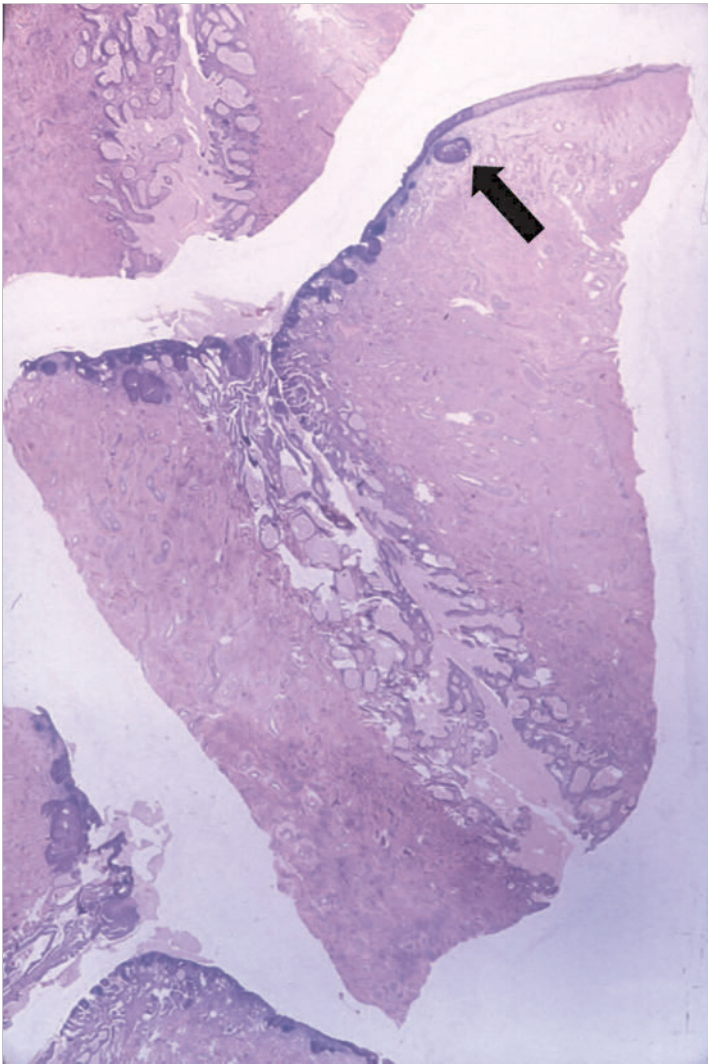


Fig. 4.26 Cone specimen showing the topographic relationship between the last gland and cervical intraepithelial neoplasia (squamous intraepithelial lesion [SIL]). Note a high-grade squamous intraepithelial lesion located in the gland field proximal to the last gland (*arrow*) (i.e., inside the transformation zone). The last gland indicates the distal or proximal border of SIL in the large majority of cases; dysplastic epithelium of uniform appearance exists on both sides of the last gland in continuity in less than 5% of cases.

theory of healing of erosions^{105,106}) of active downgrowth of surface epithelium into the crypts is inaccurate.

SIL in original squamous epithelium (outside the TZ) also occurs in well-defined fields.

Role of the Epithelium in Colposcopic Morphology

During the reproductive years, the *original glycogen-containing squamous epithelium* is thick and multilayered and acts as an optical filter over the underlying stroma (► Fig. 4.1a). A surface covered by normal squamous epithelium appears *pink to reddish* (► Fig. 8.1). Before puberty and after menopause, in the absence of estrogen, the squamous epithelium is thinner and does not contain glycogen (► Fig. 4.1b). The stromal blood supply is reduced and the colposcopic appearance is pale red (► Fig. 8.6a).

Columnar epithelium is thin, contains mucin, and is therefore highly transparent (► Fig. 4.2). Hence, areas of the cervix covered by columnar epithelium look bright red (► Fig. 8.2a).

The thickness of *metaplastic squamous epithelium* in the normal TZ varies according to its stage of development, but it is thinner than normal squamous epithelium and devoid of glycogen. Consequently, it is relatively transparent and appears bright red (► Fig. 4.3, ► Fig. 8.17a).

Dysplastic squamous epithelium (SIL, CIN) is thinner than normal epithelium, contains little or no glycogen, and, most importantly, is more cellular with a higher nuclear content (► Fig. 4.12, ► Fig. 4.13). It appears red admixed with a dirty gray or whitish discoloration (► Fig. 8.29, ► Fig. 8.30).

Regenerating squamous epithelium (repair) is usually somewhat thinner than normal squamous epithelium. It is composed almost entirely of prickle cells, which do not contain glycogen and always shows some degree of parakeratosis or keratosis or both. Accordingly, regenerating squamous epithelium is optically more dense than normal squamous epithelium. Colposcopically it appears pale red (► Fig. 8.65) or gray to grayish white (► Fig. 8.55), depending on the degree of keratinization.

Both metaplastic and dysplastic squamous epithelia as well as cases with local chronic irritation can show distinct keratinization

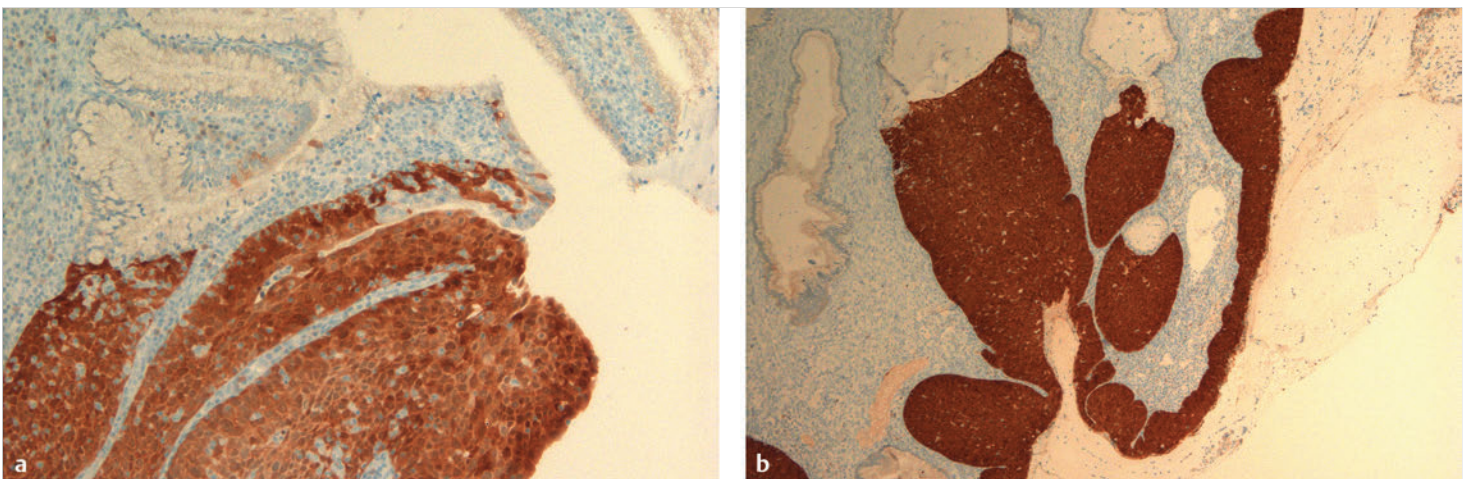


Fig. 4.27 Involvement of glands by HSIL. (a) The dysplastic epithelium is clearly demarcated from the normal glandular epithelium. (b) HSIL is seen both on the surface and at the gland opening. Immunohistochemistry for p16^{INK4a}.

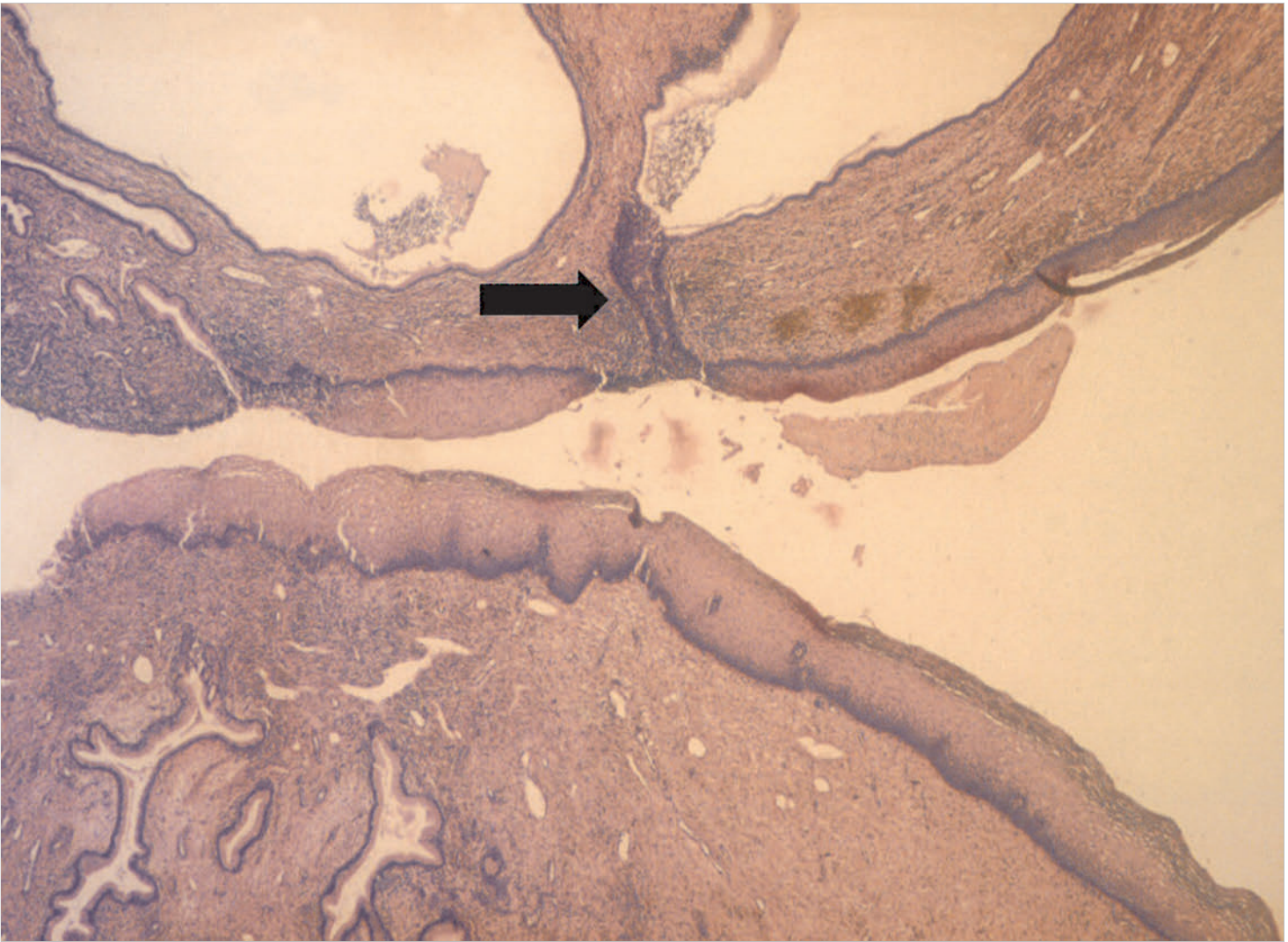


Fig. 4.28 Involvement of a gland by squamous metaplasia. Note the two nabothian follicles. Such retention cysts develop under the surface when the outlets of crypts are occluded by squamous metaplasia (*arrow*).

(► Fig. 4.6), which appears colposcopically as keratosis (leukoplakia). The keratotic layer is opaque, white, and grainy and obfuscates the underlying epithelium (► Fig. 8.53).

In areas of *erosion* of the epithelium, the stroma is exposed and appears rough, red, and raw (► Fig. 8.46).

The colposcopic picture also depends on the composition of the stroma. Normal stroma is red because of its vasculature. When the stroma is inflamed, the redness is muted to a gray-white or yellow, depending on the degree of inflammatory infiltrate.

4.4.3 Colposcopic Appearance of the Surface

The colposcopic appearance of the surface of the cervix is determined by the surface contour of the cervix, the planes between different epithelia, and the thickness of the epithelium. The *surface of the cervix* is smooth or papillary; in the latter case, the mucosa shows grapelike villi. This appearance is most pronounced with ectopy (► Fig. 8.10). The papillae are usually covered by columnar epithelium (► Fig. 4.2).

Differences in epithelial planes are most pronounced between normal squamous and columnar epithelium, especially in an ectopy. Because the epithelial–stromal interface is normally at the same level, the junction between the thick stratified squamous

epithelium and the thin, single-layered columnar epithelium is steplike (► Fig. 8.18) and most pronounced in ectopy with no TZ (► Fig. 8.13). The effect of variation in thickness of the squamous epithelium is most marked when the stromal papillae are elongated. The thin epithelial covering of the papillae allows the rich capillary network to shine through, whereas the thick rete pegs between them are less translucent.

The resulting colposcopic picture depends on the spatial arrangement of the stromal papillae. The papillae can form *columns*; the capillaries then shine through the attenuated epithelium covering the tips and give rise to red dots referred to colposcopically as *punctuation* (► Fig. 4.30, ► Fig. 8.52). Alternatively, an arborizing network of stromal ridges subdivides the surface epithelium into discrete fields, producing a colposcopic *mosaic* pattern (► Fig. 4.31, ► Fig. 8.41).

Gland openings. The replacement of columnar epithelium by metaplastic squamous epithelium takes place mostly on the exposed surfaces. The margins of the squamous epithelium reach to the gland openings, leaving the recesses of the glands or crypts and their openings intact. If metaplasia extends into the glands, the gland openings are lined by squamous epithelium (► Fig. 4.28). The circular gland openings are easily seen colposcopically (► Fig. 8.28a). The characteristic white rings around them are due to the tangential view of the wedge-shaped

squamous epithelium. The presence of gland openings can be the only indication that the squamous epithelium is metaplastic, not original. Cuffed gland openings in HSIL are more prominent and above the surface than the gland openings seen in the normal TZ.

Nabothian follicles are retention cysts that develop under the surface when the outlets of crypts are occluded by squamous metaplasia. The buried columnar epithelium continues to secrete mucus, which fills and distends the gland. Nabothian follicles can measure up to a centimeter in diameter and sometimes more. The cysts buckle the overlying squamous epithelium, which becomes attenuated. A network of vessels characteristically courses over the surface of nabothian follicles (► Fig. 8.132). The entrapped mucus gives the cyst an ivory-yellow tinge. The latter feature allows recognition of a deeper cyst, even when the surface is flat.

The columnar epithelium lining crypts can also undergo metaplasia. The impression of active downgrowth of squamous epithelium is misleading. The columnar epithelium can be either partly or completely replaced by squamous metaplasia. In the latter case there are more or less well-defined squamous pearls beneath the surface, which can be visible colposcopically. If numerous, this can result in a mosaic appearance (► Fig. 8.42). The prominent network of the capillary-rich stromal ridges associated with true mosaic, however, is absent (see section Mosaic and Punctuation (Fine, Coarse)).

Sharp Epithelial Borders

Squamous metaplasia, SIL, and AIS develop in well-defined fields with sharp borders. These distinct borders are a classic colposcopic feature, especially with suspicious findings. These margins, as well as those between different pathologic epithelia, can be accentuated by applying iodine (► Fig. 10.3) or acetic acid (► Fig. 10.2). The sharp borders between different epithelial fields are easily seen colposcopically and histologically (► Fig. 10.1, ► Fig. 10.2, ► Fig. 10.3, ► Fig. 10.4). Borders between metaplastic and original squamous epithelium are also sharp. Because squamous metaplasia arises in discrete fields, sharp borders also exist between different pathologic epithelia (see Chapter 10).

Different normal and pathologic epithelia frequently can coexist on the same cervix (► Fig. 3.10). Different fields of squamous metaplasia can arise simultaneously or at different times (► Fig. 3.6). Both the gland field and the original squamous epithelium can be involved (► Fig. 4.7). In 657 conization specimens, 46% contained two different types of SIL and 30% contained three. When different epithelia adjoin one another, they are well demarcated by sharp borders that are often perpendicular. Occasionally the junctions are less distinct, irregular, or wavy.^{9,107} Abrupt borders are clearly seen between normal or atypical metaplastic and original squamous epithelium and are especially pronounced when the different epithelia are thick. The more highly differentiated epithelium lies distal to the less differentiated (see also section 4.4.2).

Although sharp borders also occur in metaplastic and dysplastic epithelium, this classic colposcopic feature is placed in the major changes (grade 2) category of abnormal colposcopic findings in the 2011 terminology.¹⁰²

Size and Extent of Dysplastic Epithelial Fields

For the interpretation of colposcopic findings, it is important to appreciate that the likelihood of invasion increases with the surface area of a lesion. We have also found that incomplete excision at conization was most common with HSIL with microinvasive cervical cancer (FIGO IA1). This can be because HSIL with the potential to become invasive is usually large; HSIL with a small surface area is almost always noninvasive. Enlargement of lesions is due to recruitment and apposition of new fields (► Fig. 3.10). Accordingly, the size of SIL as a percentage of the cervix, and the number of quadrants a lesion covers were incorporated into the 2011 IFCPC colposcopic terminology¹⁰² (see Chapter 7).

Leukoplakia (Keratoses)

Leukoplakia is defined as a white change present before the application of acetic acid. It can preclude adequate visualization of the underlying TZ. The histologic hallmark of leukoplakia is keratinization of the surface (► Fig. 4.29) in the form of *parakeratosis* or *hyperkeratosis*. Parakeratosis implies retention of pyknotic nuclei in the horny layer. Hyperkeratosis, as seen in the epidermis, is characterized by cornification without nuclei. The degree of keratinization does not depend on the type of underlying epithelium. In the same type of epithelium, the appearance can range from mild parakeratosis to full cornification.

Keratoses can be produced by normal (original or metaplastic) epithelium (► Fig. 4.28), regenerating epithelium, dysplastic epithelium (SIL), and invasive carcinoma. Parakeratosis or hyperkeratosis can occur with all epithelial types, without differences in structure or thickness of the keratotic layers. It is impossible to assess the nature of the underlying epithelium from the type of cornification; this requires biopsy.

What is important is the company that keratosis keeps. Keratosis from metaplastic or regenerating epithelium requires neither treatment nor careful follow-up. On the other hand, extensive leukoplakia can vary histologically at different sites, and benign epithelium can coexist with dysplastic epithelium in the same lesion (► Fig. 10.2, ► Fig. 10.3, ► Fig. 10.4, ► Fig. 10.5). A small biopsy from a large lesion can therefore be nonrepresentative and misleading. Finally, keratosis can mask a *keratinizing invasive carcinoma* (► Fig. 8.72).

Leukoplakia was considered a major lesion in early IFCPC terminologies but was downgraded to a miscellaneous finding in 2002; but since leukoplakia was shown to have a 25% independent predictive value for HSIL,¹⁰² the term was returned to the nonspecific category of abnormal colposcopic findings in the 2011 terminology¹⁰² (see Chapter 7).

Mosaic and Punctuation (Fine, Coarse)

The colposcopic patterns of mosaic and punctuation result from architectural features of the squamous epithelium. It reflects either a normal pattern or a modification of preexisting normal vascular architecture of the squamous epithelium of the cervix. These epithelial changes develop in clearly circumscribed fields *pari passu* with changes in the accompanying stroma and blood vessels and can be found in original and metaplastic squamous epithelium as well as in SIL.

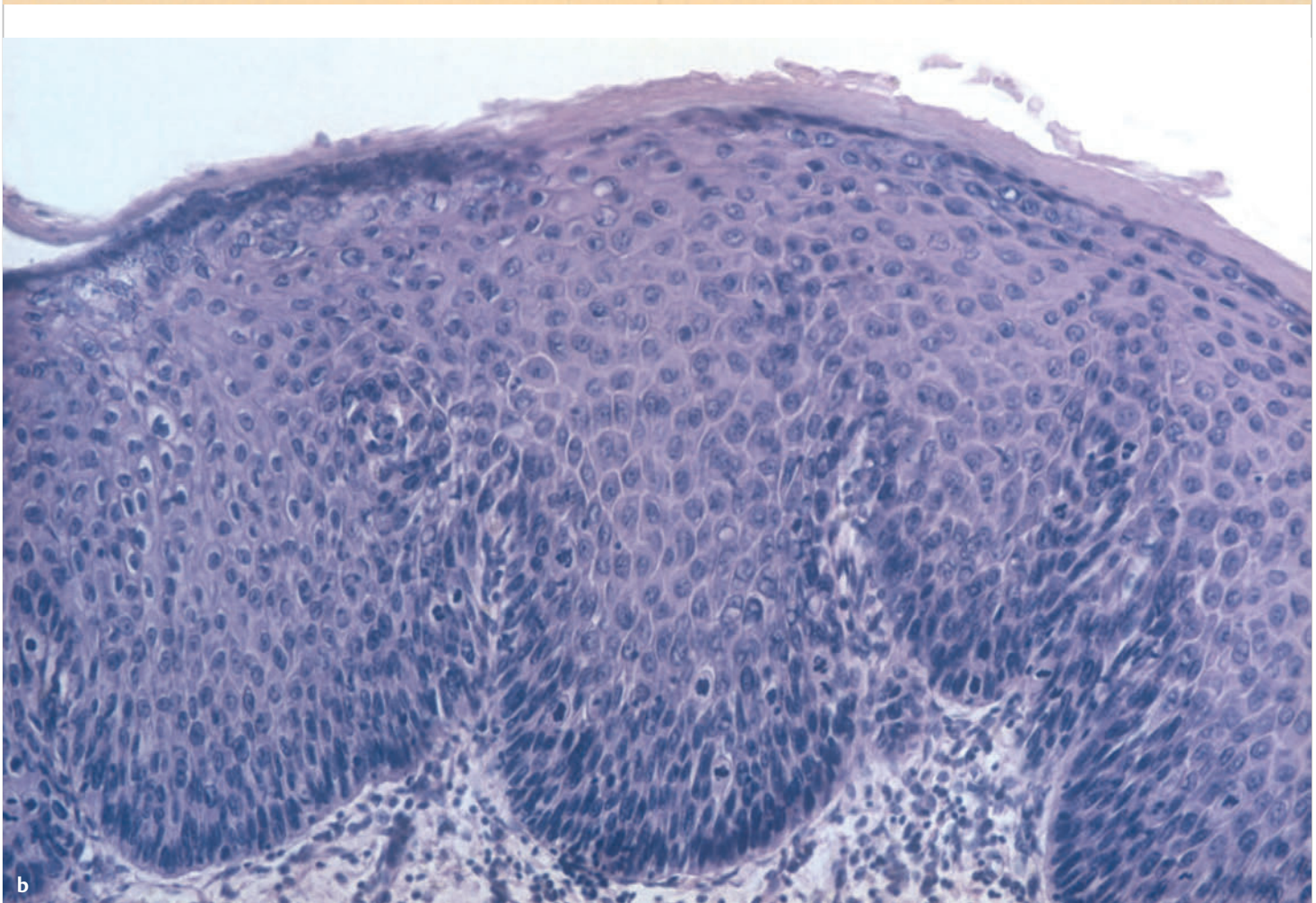
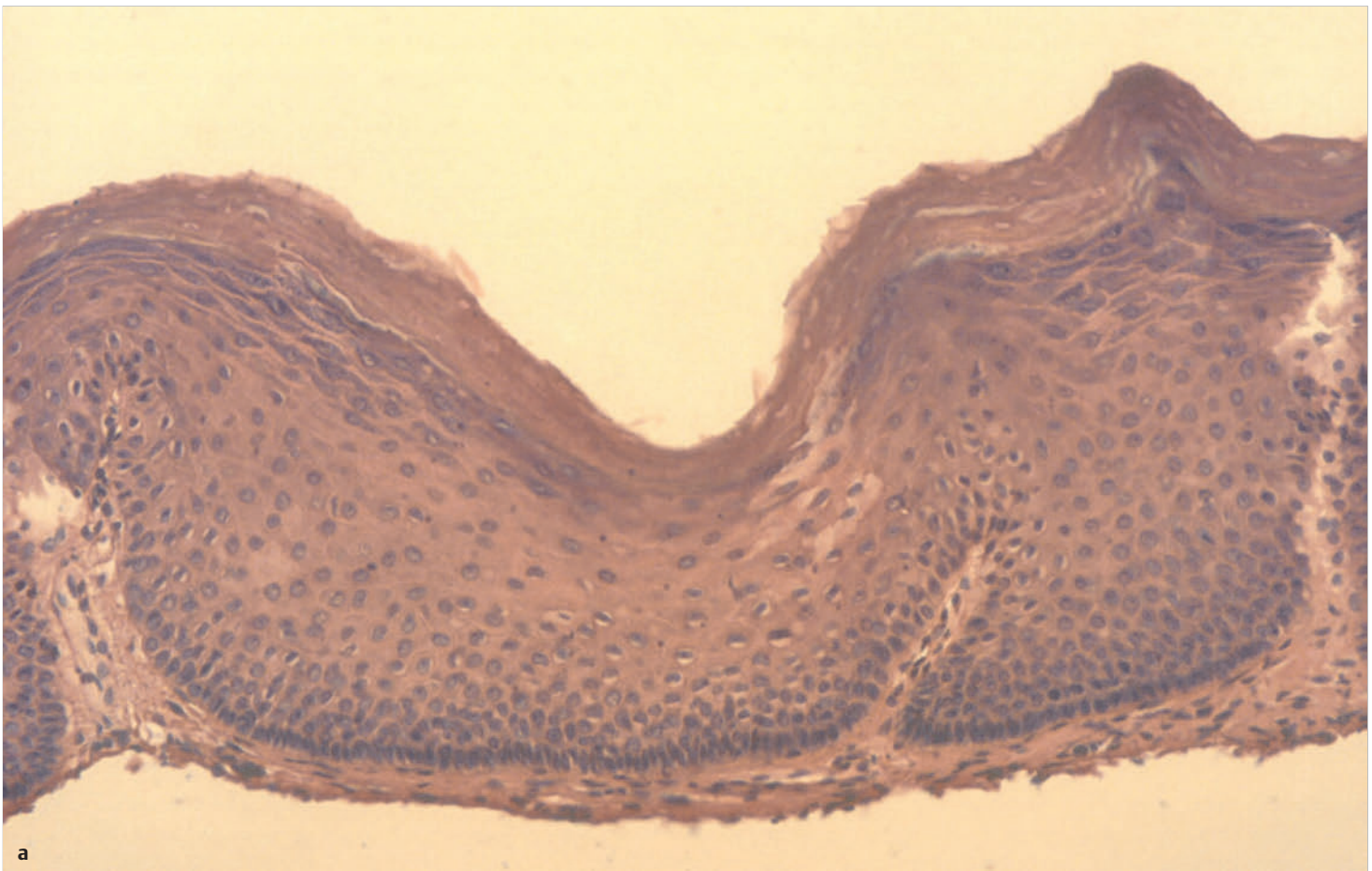


Fig. 4.29 Keratosis (leukoplakia) with keratinization of the epithelial surface. (a) Keratosis produced by unsuspecting epithelium. (b) Keratosis produced by dysplastic epithelium (LSIL).

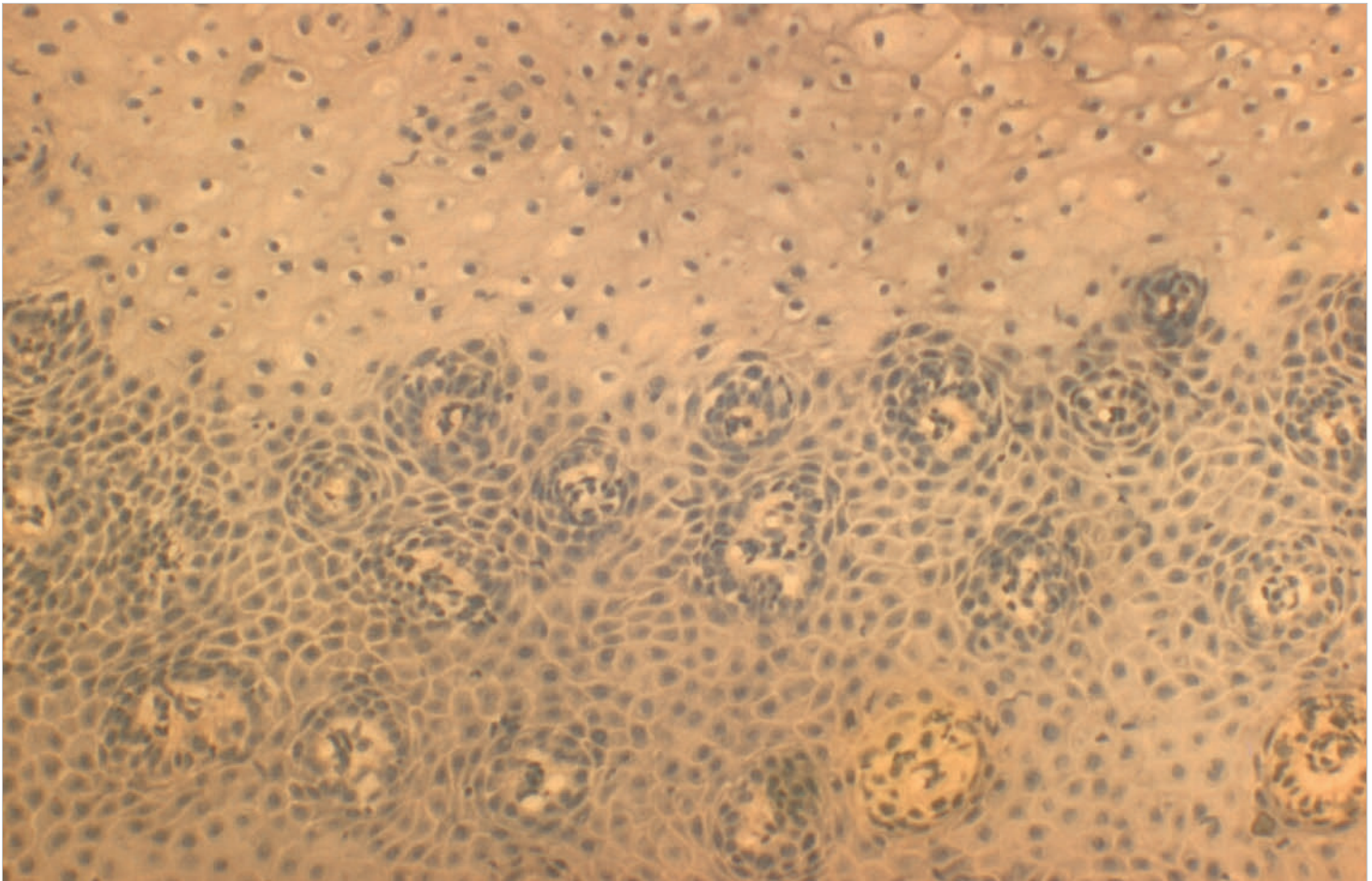


Fig. 4.30 Punctuation with terminal capillaries within stromal papillae of benign squamous epithelium. The capillaries run perpendicularly toward the epithelial surface.

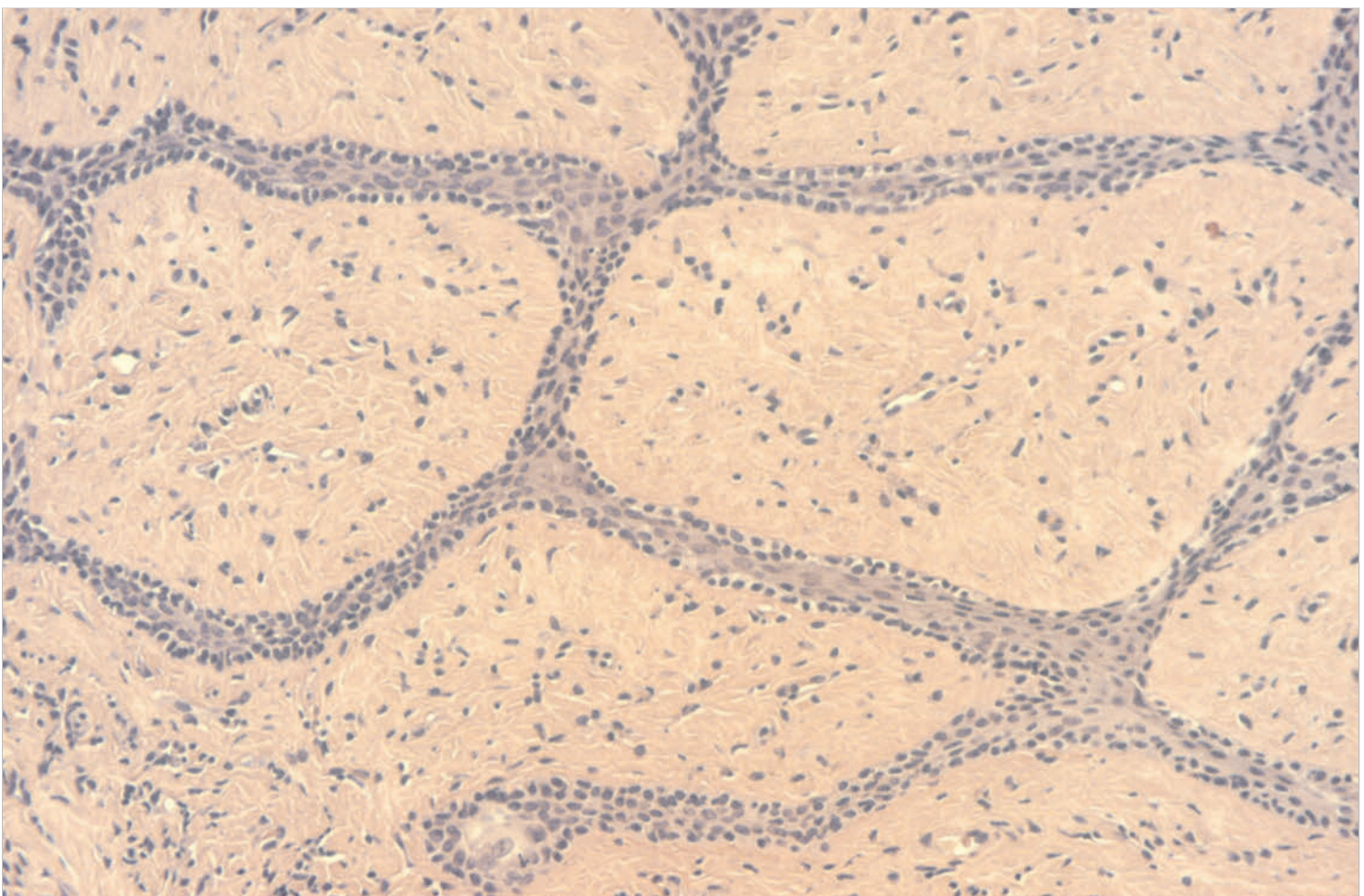


Fig. 4.31 Mosaic with capillaries in stromal papillae arranged parallel to the epithelial surface. The capillaries form a basket-like structure around pegs of epithelium.

It is important to appreciate that mosaic and punctation can be seen in biologically entirely different epithelia. Immature metaplastic epithelium or LSIL can display extensive budding and branching, the epithelial pegs interdigitating with quite slender stromal papillae. The interpapillary distance varies but is usually not excessive. In contrast, the epithelial pegs of HSIL are heftier and irregular, the stromal papillae are more robust, and the interpapillary distance is greater.

Punctation and mosaic are produced by isolated stromal papillae and interlacing stromal ridges, respectively. The term *punctation* refers to single looped terminal capillaries within stromal papillae of (benign or dysplastic) squamous epithelium running perpendicularly or obliquely toward the epithelial surface (► Fig. 4.30). The term *mosaic* refers to a vascular pattern produced when capillaries in stromal papillae are arranged parallel to the epithelial surface and form a basket-like structure around blocks or pegs of (benign or dysplastic) squamous epithelium (► Fig. 4.31).

Colposcopically, the blood vessels shine through the overlying attenuated epithelium (► Fig. 8.41). Only rarely does the epithelium with punctation or mosaic contain glycogen. In such cases, the epithelial segments between the red dots or lines will stain with iodine (► Fig. 8.97, ► Fig. 8.98). In keratosis (leukoplakia) a blanket of keratin can mask underlying punctation or mosaic. When Hinselmann removed the keratin layer from an area of leukoplakia, the predominant pattern he uncovered was punctation. Hinselmann was the first to describe mosaic and punctation and equated them with what he called the *matrix area of cancer*.¹⁰⁸

Mosaic and punctation are more common outside the TZ than within it.¹⁰⁹ Histologically, mosaic and punctation outside the TZ corresponded to benign epithelium in 70% and to SIL (CIN) in 30% of cases. In contrast, mosaic and punctation within the TZ corresponded to benign epithelium in 20% and to SIL (CIN) in 80% of cases, respectively.¹⁰⁹

In the current (2011) colposcopic terminology,¹⁰² punctation and mosaic is subdivided into *fine punctation* and *fine mosaic* or *coarse punctation* and *coarse mosaic*, depending on the vessel caliber and intercapillary spacing. In general, the finer the punctation or the mosaic, the more likely the lesion is to be LSIL or squamous metaplasia. Fine punctation and fine mosaic reflect a comparatively uniform vascular architecture typically seen in benign changes or LSIL. The coarser the punctation and the coarser, wider, and more irregular the mosaic, the more likely the lesion is to be HSIL. Coarse punctation and coarse mosaic result when expanding epithelial blocks of HSIL evoke lateral displacement of capillaries that are dilated and irregular in caliber because of venous occlusion.

Acetowhite Epithelium (Thin, Dense)

Acetic acid causes both metaplastic and dysplastic squamous epithelium to swell and change color. Particularly, immature metaplastic epithelium and dysplastic epithelium with an increased nuclear-to-cytoplasmic ratio and reduced intercellular junctions appear acetowhite.

How quickly acetic acid effects appear and disappear vary with different types of lesions. Metaplastic epithelium is not as acetowhite as dysplastic epithelium (thin acetowhite epithelium).

In several studies, dense acetowhite epithelium had a good correlation with HSIL¹¹⁰ (► Fig. 8.52). When dysplastic epithelium involves both the surface and the outer portion of an endocervical gland (crypt), it often produces a rim around the gland opening which, after the application of acetic acid appears colposcopically as a white cuff (so-called cuffed gland openings). This is less pronounced with metaplastic epithelium. Generally, the denser the acetowhite change, the more quickly it becomes apparent, the longer it persists, and the more severe the lesion.

Inner Border Sign and Ridge Sign

An opaque white protuberance at the area of the TZ after acetic acid (*ridge sign*) or a sharp acetowhite demarcation within a less opaque acetowhite area (*inner border sign*) is associated with the presence of HSIL¹¹¹ (► Fig. 8.142, ► Fig. 10.4). The inclusion of these two findings in the 2011 IFCPC colposcopic terminology¹⁰² is due to their validity as markers of HSIL. The inner border sign is a sharp acetowhite demarcation within a less opaque acetowhite area.¹¹² Histologically it reflects the fact that different fields of normal and pathologic epithelia frequently coexist on the same cervix and that abrupt borders are clearly seen between fields of metaplastic and high-grade dysplastic squamous epithelium.

The ridge sign is an opaque white protuberance inside the TZ after the application of acetic acid.¹¹² It reflects the fact that HSIL is usually located in a sharply demarcated field proximal to the last gland. Histology itself shows no further specific findings.

Erosion and Ulcer

An *erosion* is an area of denuded epithelium, whereas an *ulcer* extends into the subepithelial stroma (► Fig. 4.32). An erosion can be caused by trauma and can be an indication that the surface epithelium is vulnerable and possibly dysplastic. Traumatic erosions occur easily in nonestrogenized, atrophic squamous epithelium or in the columnar epithelium of ectopy. They are difficult to study histologically because they heal quickly. The epithelial defect is poorly circumscribed and its margins irregular. With acute lesions there is little alteration of the stroma. The surface can be covered by a fibrinous exudate.

Erosion within a colposcopic lesion: Erosions can appear spontaneously. Dysplastic epithelium is more friable and shows less intercellular cohesion than normal or atrophic epithelium. Detachment can occur, which accounts for the ease with which the cells are exfoliated, and for the potential for cytologic examination. Whole epithelial segments or fields can be lost. Early on, HSIL may show rolled, peeling edges.¹¹³ The fracture sites, seen at epithelial junctions, also show that epithelia do not merge with each other and that their borders are real. The stroma underlying an epithelial detachment shows reactive changes. The surface of an erosion is usually flat, although covered by fibrin. Even if the epithelium around the erosion is normal, the denuded epithelium may have been dysplastic.

Condylomatous Lesions

The colposcopic appearance of condylomatous lesions depends on their surface. It is easy to see how the typical finger-like



Fig. 4.32 Erosion and ulcer. (a) Erosion caused by trauma with denudation of epithelium. The subepithelial stroma is intact. (b) Small ulcer resulting from a microinvasive squamous cell carcinoma. The lesion extends into the subepithelial stroma.

processes of papillary growths are determined by the histologic architecture (► Fig. 4.8). Similarly, the epithelial excrescences of spiked condylomas account for the more or less tightly packed spikes. Keratinization gives the surface a homogeneous, pearly finish, which can mask further structural details.

The markedly elongated stromal ridges or papillae are also important determinants of the colposcopic appearance. Each contains a blood vessel or several vessels of varying caliber. Unless obscured by keratosis, these are easily visible.

Flat condylomas can appear colposcopically as punctuation or mosaic, depending on whether the supporting stroma forms papillae or ridges. Because of the thickness of the epithelium and the height of the stromal papillae, the surface of these lesions is coarser than that of lesions resulting from dysplastic epithelia (► Fig. 8.129).

Colposcopy cannot distinguish between flat condyloma and LSIL.^{74,75} It cannot be assumed that lesions outside the TZ are condylomas and not HSIL.

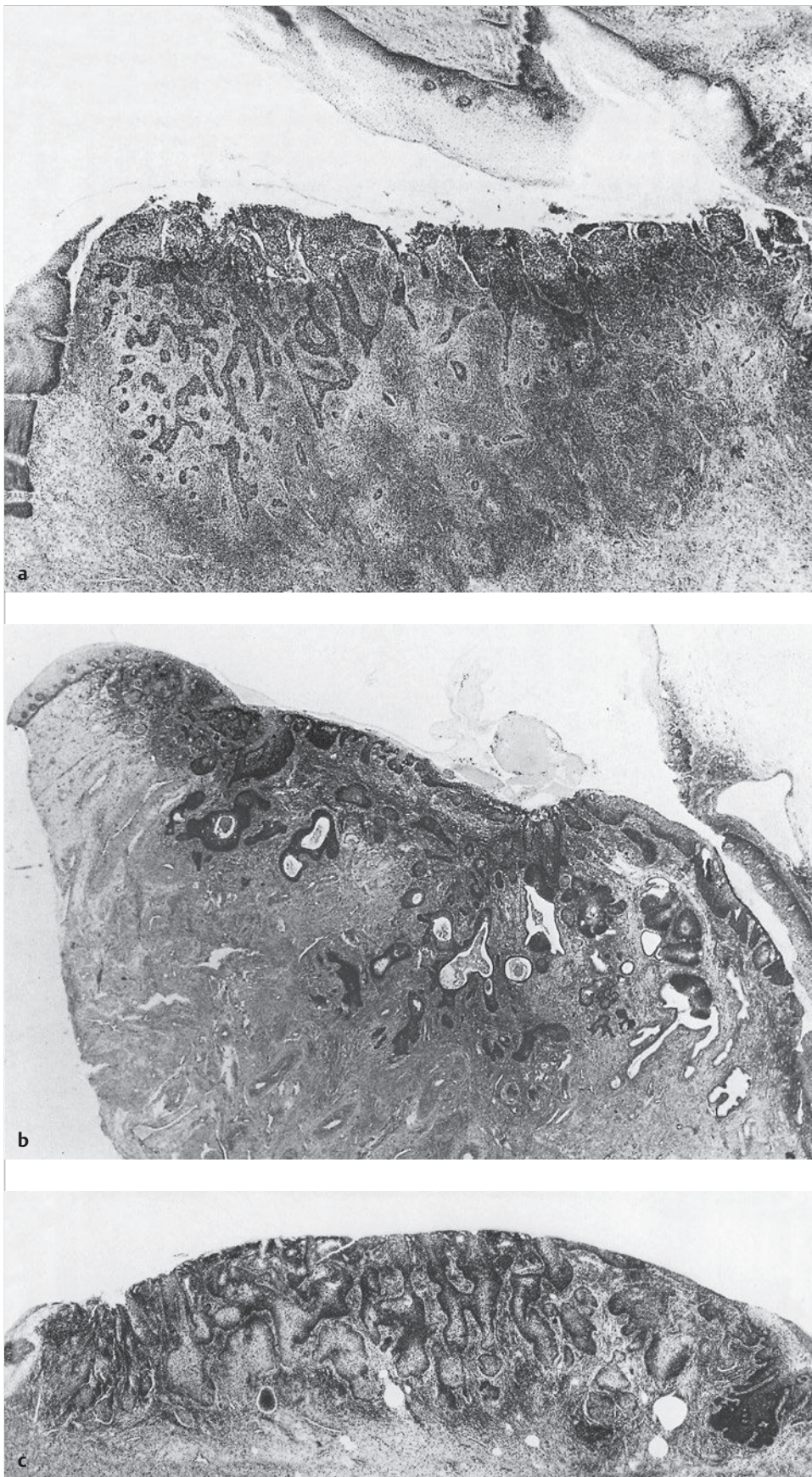


Fig. 4.33 Microcarcinomas of the cervix. (a) The surface of the cervix is ulcerated, and there is a marked stromal reaction around the tumor. Superficial spread 5 mm; maximum depth 2 mm. (b) Microinvasive squamous cell carcinoma (4 × 7 mm) with a distinct inflammatory response. (c) Small stage IB tumor 9 mm wide with 3 mm depth of invasion.

Although supported by tall stromal papillae, the slightly altered glycogen-containing epithelium of *condylomatous cervicitis and vaginitis* is diffuse and poorly circumscribed; colposcopically the poorly keratinized papillary spikes give rise to a white stippling (► Fig. 8.99, ► Fig. 8.100).

In contrast to metaplastic or dysplastic epithelium, which can also be characterized by prominent stromal papillae, condylomatous lesions usually contain a certain amount of glycogen. This can lead to an image that is rarely mentioned in the colposcopic literature: an *iodine-positive mosaic* (► Fig. 8.97, ► Fig. 8.98).

Patchy iodine uptake is more common with flat condylomas than with papillary lesions.

4.4.4 Microinvasive Squamous Cell Carcinoma

The colposcopic appearances of microinvasive carcinomas reflect the progression from early stromal invasion (ESI) to microinvasive tumor. The latter is a number of orders of magnitude larger than the former.

ESI arises from HSIL (CIN 3). The invasive foci form typical round, club-shaped, or finger-like buds extending from the base of the epithelium (► Fig. 4.22a). The invasive buds usually measure only a fraction of a millimeter. ESI does not have a typical colposcopic pattern, and the tiny invasive buds are not visible at colposcopy. However, the larger the surface area of an atypical colposcopic lesion, the greater the chance that there is early invasion.

Microinvasive tumors (microcarcinomas) are small, measurable tumors that can be several millimeters in size (► Fig. 4.22b,c, ► Fig. 4.33). Microinvasive tumors form circumscribed foci, usually just beneath an superficial epithelium on the ectocervix or in the cervical canal. Occasionally the surface is ulcerated (► Fig. 4.32b, ► Fig. 4.33). Typical stromal changes are consistently present and confined to the immediate vicinity of the tumor (► Fig. 4.33a). The stroma is edematous and infiltrated by round cells, as in ESI. The blood vessels are more numerous and larger. These are the features most likely to produce colposcopic signs of a microinvasive tumor.

Not all microinvasive tumors of the cervix are amenable to colposcopic detection. Ectocervical lesions in connection with the surface epithelium are well accessible to colposcopy (► Fig. 4.33a, b), but endocervical lesions above the external os are out of range of the colposcope. Also, microinvasive tumors originating from a gland deep in the stroma can lie several millimeters under the surface of the epithelium.⁷⁸ Such lesions can elude colposcopic detection until they establish a relationship to the surface of the ectocervix (by which time they are often stage IB1 lesions).

4.4.5 Adenocarcinoma in situ and Microinvasive Adenocarcinoma

AIS and microinvasive adenocarcinomas are much rarer than their squamous counterparts. They are often focal and often produce only minor alterations of the surface contour of the cervix and are thus often undetectable or easily overlooked by colposcopy. However, many AIS and invasive adenocarcinomas coexist with a squamous lesion that is topographically separate and distinct from the AIS.¹¹⁴ Lesions overlying columnar epithelium not contiguous with the SCJ, lesions with large gland openings and papillary lesions, and lesions exhibiting epithelial budding are suspicious for AIS (► Fig. 4.24).¹¹⁴

Most AIS occur within the TZ. Dense acetowhite changes within columnar epithelium can indicate glandular disease. Most microinvasive adenocarcinomas are located deep in the gland field or in the distal endocervical canal. Therefore, most cases are detected indirectly via coexistent squamous lesions of the ectocervix.

4.4.6 Grossly Invasive Carcinoma

It is not possible to distinguish colposcopically between cervical squamous cell carcinoma and adenocarcinoma. In spite of the various histologic growth patterns of invasive tumors, their colposcopic appearance is quite similar. The surfaces of both the exophytic and endophytic types are irregular, fissured, and papillary.

Endophytic carcinomas are noteworthy because they cause ulceration but little distortion of the cervix (► Fig. 4.25d). Such lesions can be overlooked. Flat ulcers should always be probed with a sound (Chrobak's test, see Chapter 5, section 5.2.2) because cancerous tissue is easy to penetrate, whereas normal tissue and papillomas offer an elastic resistance. This does not apply to the rare cancers with stromal fibrous hyperactivity (scirrhous carcinomas), which are difficult to diagnose and can be confirmed only by conization.

Purely endocervical tumors can be impossible to detect by colposcopy, particularly if small (► Fig. 4.34). Deep-seated carcinomas can sometimes be visualized if the canal is patulous or by opening the canal with an endocervical speculum. Tumors that escape clinical and colposcopic detection are called *occult carcinomas* (the term has also been used for microcarcinomas⁹ but should be reserved for larger cancers that cannot be diagnosed clinically or colposcopically). Typically, such tumors are detected by conization performed to evaluate dysplastic epithelium seen on the surface or in the canal.

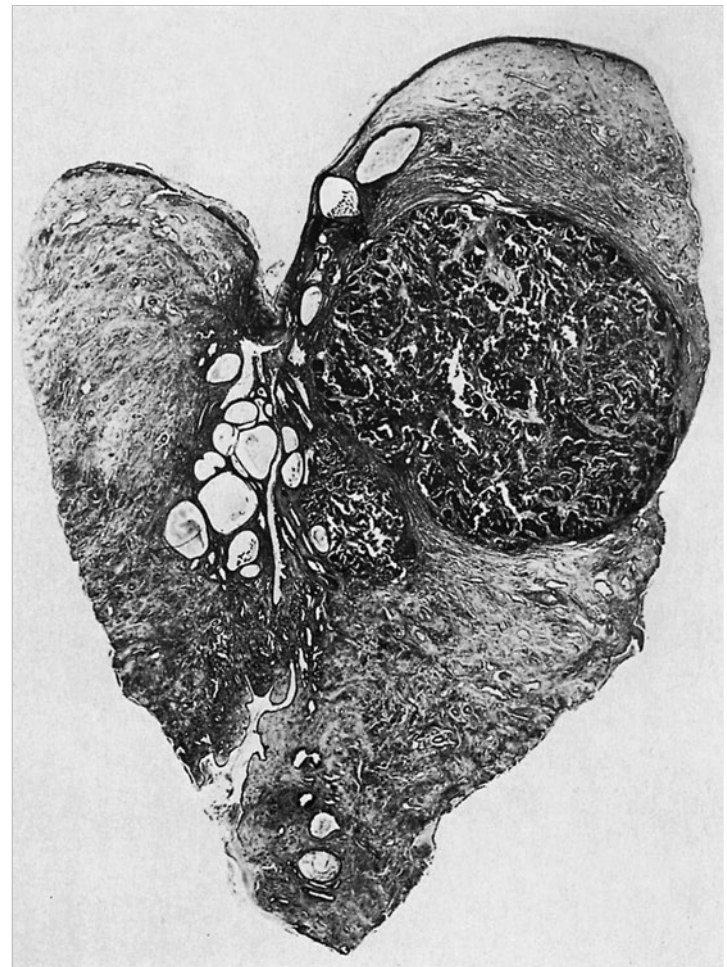


Fig. 4.34 Small endocervical carcinoma. The conization specimen contains two tumors under the surface epithelium. Note that the contour of the cervix is undisturbed.

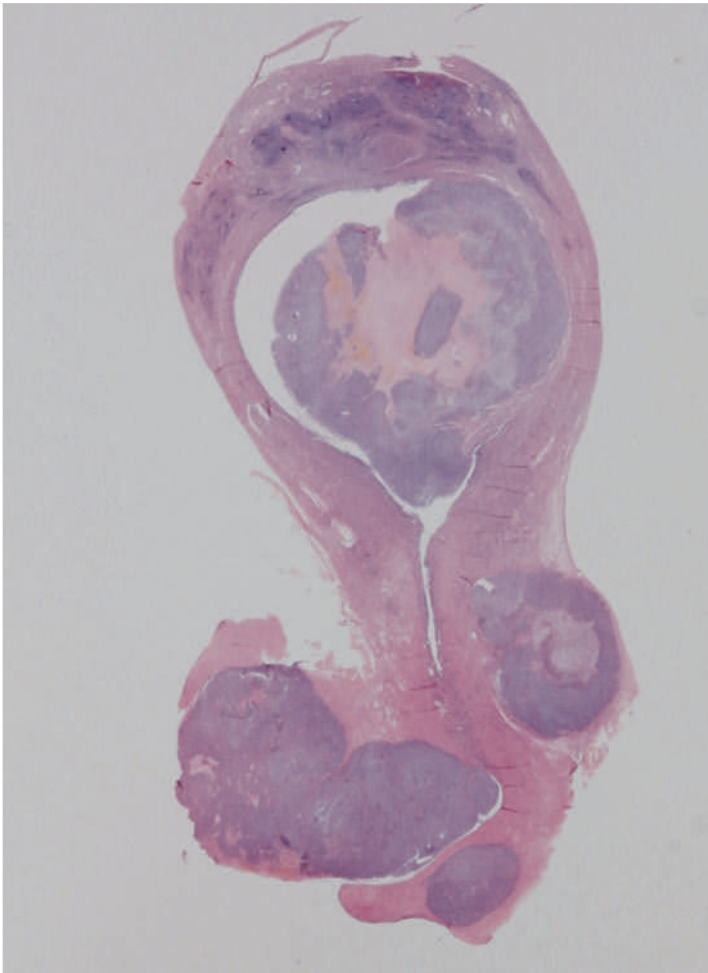


Fig. 4.35 Giant section showing a multifocal leiomyosarcoma involving the corpus, isthmus, and cervix. Note the ulceration of the anterior lip of the cervix.

Involvement of the cervix by malignant mesenchymal tumors of the uterus is rare (► Fig. 4.35). Macroscopic appearance does not differ significantly from that of carcinomas. Only primary malignant melanoma of the cervix is pigmented in most cases.

References

- [1] Fluhmann CF. *The Cervix Uteri and its Diseases*. Philadelphia: Saunders, 1961
- [2] Burghardt E. Pathology of early invasive squamous and glandular carcinoma of the cervix (FIGO stage Ia). In: Coppleson M, ed. *Gynecologic Oncology*. 2nd ed. Edinburgh: Churchill Livingstone, 1992
- [3] Burghardt E, Holzer E. Diagnosis and treatment of microinvasive carcinoma of the cervix uteri. *Obstet Gynecol* 1977; 49: 641–653
- [4] Burghardt E, Östör AG. Site of origin and growth pattern of cervical cancer: a histomorphological study. *Obstet Gynecol* 1973; 62: 117–127
- [5] Pixley E. Morphology of the fetal and prepubertal cervicovaginal epithelium. In: Jordan JA, Singer A, eds. *The Cervix*. Philadelphia: Saunders, 1976
- [6] Hamperl H, Kaufmann C, Ober KG, Schneppenheim P. Die Erosion der Portio; die Entstehung der Pseudoerosion, das Ektropion und die Plattenepithelüberhäutung der Cervixdrüsen auf der Portiooberfläche [Erosion of the portio; formation of pseudoerosion, ectropion and pavement cell epithelialization of the cervical glands on the surface of the portio]. *Virchows Arch* 1958; 331: 51–71
- [7] Ober KG, Schneppenheim P, Hamperl H, Kaufmann C. Die Epithelgrenzen im Bereiche des Isthmus uteri [Epithelial borders in the area of the isthmus uteri]. *Arch Gynäkol* 1958; 190: 346–383
- [8] Fritsch H, Richter E, Adam N. Molecular characteristics and alterations during early development of the human vagina. *J Anat* 2012; 220: 363–371
- [9] Burghardt E. *Early Histological Diagnosis of Cervical Cancer*. Stuttgart: Thieme, 1973
- [10] Slack JMW. Metaplasia and somatic cell reprogramming. *J Pathol* 2009; 217: 161–168
- [11] Wright CV, Lickrish GM, Shier RM. *Basic and Advanced Colposcopy*. Komoka, Ontario: Biomedical Communications, 1995
- [12] Ferris GD, Cox JT, O'Connor DM, et al. *Modern Colposcopy, Textbook and Atlas*. Dubuque, IA: Kendall/Hunt, 2004
- [13] Kurman RJ, Ellenson LH, Ronnett BM. *Blaustein's Pathology of the Female Genital Tract*. New York: Springer, 2011
- [14] Lesack D, Wahab I, Gilks CB. Radiation-induced atypia of endocervical epithelium: a histological, immunohistochemical and cytometric study. *Int J Gynecol Pathol* 1996; 15: 242–247
- [15] Meisels A, Fortin R, Roy M. Condylomatous lesions of the cervix. II. Cytologic, colposcopic and histopathologic study. *Acta Cytol* 1977; 21: 379–390
- [16] Meisels A, Roy M, Fortier M et al. Condylomatous lesions of the cervix: morphologic and colposcopic diagnosis. *Am J Diagn Gynecol Obstet* 1979; 1: 109–116
- [17] Meisels A, Roy M, Fortier M et al. Human papillomavirus infection of the cervix: the atypical condyloma. *Acta Cytol* 1981; 25: 7–16
- [18] De Girolami E. Perinuclear halo versus koilocytotic atypia. *Obstet Gynecol* 1967; 29: 479–487
- [19] Koss LG. Carcinogenesis in the uterine cervix and human papillomavirus infection. In: Syrjänen K, Gissmann L, Koss LG, eds. *Papillomaviruses and Human Disease*. Berlin: Springer, 1987
- [20] Meisels A, Morin C, Casas-Cordero M. Lesions of the uterine cervix associated with papillomavirus, and their clinical consequences. In: Koss LG, Coleman DV, eds. *Advances in Clinical Cytology*. New York: Masson, 1984
- [21] Wright TC, Cox JT, Massad LS, Carlson J, Twigg LB, Wilkinson EJ American Society for Colposcopy and Cervical Pathology. 2001 consensus guidelines for the management of women with cervical intraepithelial neoplasia. *Am J Obstet Gynecol* 2003; 189: 295–304
- [22] Broders AC. Carcinoma in situ contrasted with benign penetrating epithelium. *JAMA* 1932; 99: 1670–1674
- [23] Schauenstein W. Histologische Untersuchungen über atypisches Plattenepithel an der Portio und an der Innenfläche der Cervix uteri. [Histologic studies of atypical squamous epithelium at the portio and the inner surface of the uterine cervix]. *Arch Gynecol* 1908; 85: 567–616
- [24] Pickel H, Reich O. History of gynecological pathology XIX. Walther Schauenstein: an early austrian pioneer of cervical pathology with comments on his successors. *Int J Gynecol Pathol* 2006; 25: 195–198
- [25] Reagan JW, Seidemann IL, Saracusa Y. The cellular morphology of carcinoma in situ and dysplasia or atypical hyperplasia of the uterine cervix. *Cancer* 1953; 6: 224–234
- [26] Koss LG, Stewart FW, Foote FW, Jordan MJ, Bader GM, Day E. Some histological aspects of behavior of epidermoid carcinoma in situ and related lesions of the uterine cervix. A long-term prospective study. *Cancer* 1963; 16: 1160–1211
- [27] Richart RM. Natural history of cervical intraepithelial neoplasia. *Clin Obstet Gynecol* 1967; 10: 748–784
- [28] Richart RM. A modified terminology for cervical intraepithelial neoplasia. *Obstet Gynecol* 1990; 75: 131–133
- [29] Solomon D, Davey D, Kurman R. et al Forum Group Members Bethesda 2001 Workshop The 2001 Bethesda System: terminology for reporting results of cervical cytology. *JAMA* 2002; 287: 2114–2119
- [30] Burghardt E. Das Adenocarcinoma in situ der Cervix [Adenocarcinoma in situ of the cervix]. *Arch Gynäkol* 1966; 203: 57–74
- [31] Hepler TK, Dockerty MB, Randall LM. Primary adenocarcinoma of the cervix. *Am J Obstet Gynecol* 1952; 63: 800–808
- [32] Friedell GH, McKAY DG. Adenocarcinoma in situ of the endocervix. *Cancer* 1953; 6: 887–897
- [33] Bousfield L, Pacey F, Young Q, Krumins I, Osborn R. Expanded cytologic criteria for the diagnosis of adenocarcinoma in situ of the cervix and related lesions. *Acta Cytol* 1980; 24: 283–296
- [34] Gloor E, Hurlimann J. Cervical intraepithelial glandular neoplasia (adenocarcinoma in situ and glandular dysplasia). A correlative study of 23 cases with histologic grading, histochemical analysis of mucins, and immunohistochemical determination of the affinity for four lectins. *Cancer* 1986; 58: 1272–1280
- [35] Tavassoli FA, Devilee P. *World Health Organization Classification of Tumours: Tumours of the Breast and Female Genital Organs*. Lyon: IARC Press, 2003

- [36] Crum CP, Egawa K, Fu YS et al. Atypical immature metaplasia (AIM). A subset of human papilloma virus infection of the cervix. *Cancer* 1983; 51: 2214–2219
- [37] Ma L, Fisk JM, Zhang RR, Ulukus EC, Crum CP, Zheng W. Eosinophilic dysplasia of the cervix: a newly recognized variant of cervical squamous intraepithelial neoplasia. *Am J Surg Pathol* 2004; 28: 1474–1484
- [38] Geng L, Connolly DC, Isacson C, Ronnett BM, Cho KR. Atypical immature metaplasia (AIM) of the cervix: is it related to high-grade squamous intraepithelial lesion (HSIL)? *Hum Pathol* 1999; 30: 345–351
- [39] Regauer S, Reich O. CK17 and p16 expression patterns distinguish (atypical) immature squamous metaplasia from high-grade cervical intraepithelial neoplasia (CIN III). *Histopathology* 2007; 50: 629–635
- [40] Pickel H. Die Lokalisation des Adenocarcinoma in situ der Cervix uteri [On the localisation of the adenocarcinoma in situ of the cervix uteri (author's transl)]. *Arch Gynäkol* 1978; 225: 247–254
- [41] Östör AG, Pagano R, Davoren RAM, Fortune DW, Chanen W, Rome R. Adenocarcinoma in situ of the cervix. *Int J Gynecol Pathol* 1984; 3: 179–190
- [42] Koskimaa HM, Kurvinen K, Costa S, Syrjänen K, Syrjänen S. Molecular markers implicating early malignant events in cervical carcinogenesis. *Cancer Epidemiol Biomarkers Prev* 2010; 19: 2003–2012
- [43] Cuzick J, Bergeron C, von Knebel Doeberitz M et al. New technologies and procedures for cervical cancer screening. *Vaccine* 2012; 30 Suppl 5: F107–F116
- [44] Wright TC, Schiffman M, Solomon D et al. Interim guidance for the use of human papillomavirus DNA testing as an adjunct to cervical cytology for screening. *Obstet Gynecol* 2004; 103: 304–309
- [45] Paraskevaides E, Arbyn M, Sotiropoulos A et al. The role of HPV DNA testing in the follow-up period after treatment for CIN: a systematic review of the literature. *Cancer Treat Rev* 2004; 30: 205–211
- [46] Getman D, Aiyer A, Dockter J, Giachetti C, Zhang F, Ginocchio CC. Efficiency of the APTIMA HPV Assay for detection of HPV RNA and DNA targets. *J Clin Virol* 2009; 45 Suppl 1: S49–S54
- [47] Khan MJ, Castle PE, Lorincz AT et al. The elevated 10-year risk of cervical pre-cancer and cancer in women with human papillomavirus (HPV) type 16 or 18 and the possible utility of type-specific HPV testing in clinical practice. *J Natl Cancer Inst* 2005; 97: 1072–1079
- [48] Petry KU, Menton S, Menton M et al. Inclusion of HPV testing in routine cervical cancer screening for women above 29 years in Germany: results for 8466 patients. *Br J Cancer* 2003; 88: 1570–1577
- [49] Stoler MH, Wright TC, Sharma A, Apple R, Gutekunst K, Wright TL ATHENA (Addressing The Need for Advanced HPV Diagnostics) HPV Study Group. High-risk human papillomavirus testing in women with ASC-US cytology: results from the ATHENA HPV study. *Am J Clin Pathol* 2011; 135: 468–475
- [50] Rijkaart DC, Berkhof J, Rozendaal L et al. Human papillomavirus testing for the detection of high-grade cervical intraepithelial neoplasia and cancer: final results of the POBASCAM randomised controlled trial. *Lancet Oncol* 2012; 13: 78–88
- [51] Zur Hausen H. Papillomaviruses and cancer: from basic studies to clinical application. *Nat Rev Cancer* 2002; 2: 342–350
- [52] Stanley M. Immune responses to human papillomavirus. *Vaccine* 2006; 24 Suppl 1: S16–S22
- [53] Hilfrich R, Hariri J. Prognostic relevance of human papillomavirus L1 capsid protein detection within mild and moderate dysplastic lesions of the cervix uteri in combination with p16 biomarker. *Anal Quant Cytol Histol* 2008; 30: 78–82
- [54] Griesser H, Sander H, Walczak C, Hilfrich RA. HPV vaccine protein L1 predicts disease outcome of high-risk HPV+ early squamous dysplastic lesions. *Am J Clin Pathol* 2009; 132: 840–845
- [55] Choi YS, Kang WD, Kim SM et al. Human papillomavirus L1 capsid protein and human papillomavirus type 16 as prognostic markers in cervical intraepithelial neoplasia 1. *Int J Gynecol Cancer* 2010; 20: 288–293
- [56] Lee SJ, Lee AW, Kim TJ et al. Correlation between immunocytochemistry of human papilloma virus L1 capsid protein and behavior of low-grade cervical cytology in Korean women. *J Obstet Gynaecol Res* 2011; 37: 1222–1228
- [57] Negri G, Bellisano G, Zannoni GF et al. p16 ink4a and HPV L1 immunohistochemistry is helpful for estimating the behavior of low-grade dysplastic lesions of the cervix uteri. *Am J Surg Pathol* 2008; 32: 1715–1720
- [58] Yoshida T, Sano T, Kanuma T et al. Immunochemical analysis of HPV L1 capsid protein and p16 protein in liquid-based cytology samples from uterine cervical lesions. *Cancer* 2008; 114: 83–88
- [59] Knebel Doeberitz Mv, Vinokurova S. Host factors in HPV-related carcinogenesis: cellular mechanisms controlling HPV infections. *Arch Med Res* 2009; 40: 435–442
- [60] Bergeron C, Ordi J, Schmidt D, Trunk MJ, Keller T, Ridder R. European CINtec Histology Study Group Conjunctive p16INK4a testing significantly increases accuracy in diagnosing high-grade cervical intraepithelial neoplasia. *Am J Clin Pathol* 2010; 133: 395–406
- [61] Dijkstra MG, Heideman DA, de Roy SC et al. p16(INK4a) immunostaining as an alternative to histology review for reliable grading of cervical intraepithelial lesions. *J Clin Pathol* 2010; 63: 972–977
- [62] Galgano MT, Castle PE, Atkins KA, Brix WK, Nassau SR, Stoler MH. Using biomarkers as objective standards in the diagnosis of cervical biopsies. *Am J Surg Pathol* 2010; 34: 1077–1087
- [63] Del Pino M, Garcia S, Fusté V et al. Value of p16(INK4a) as a marker of progression/regression in cervical intraepithelial neoplasia grade 1. *Am J Obstet Gynecol* 2009; 201: e1–e7
- [64] Denton KJ, Bergeron C, Klement P, Trunk MJ, Keller T, Ridder R. European CINtec Cytology Study Group The sensitivity and specificity of p16(INK4a) cytology vs HPV testing for detecting high-grade cervical disease in the triage of ASC-US and LSIL Pap cytology results. *Am J Clin Pathol* 2010; 134: 12–21
- [65] Schmidt D, Bergeron C, Denton KJ, Ridder R. European CINtec Cytology Study Group p16/ki-67 dual-stain cytology in the triage of ASCUS and LSIL Papanicolaou cytology: results from the European equivocal or mildly abnormal Papanicolaou cytology study. *Cancer Cytopathol* 2011; 119: 158–166
- [66] Petry KU, Schmidt D, Scherbring S et al. Triage Pap cytology negative, HPV positive cervical cancer screening results with p16/Ki-67 Dual-stained cytology. *Gynecol Oncol* 2011; 121: 505–509
- [67] Snellenberg S, Schütze DM, Claassen-Kramer D, Meijer CJ, Steenbergen RD. Methylation status of the E2 binding sites of HPV16 in cervical lesions determined with the Luminex® xMAP™ system. *Virology* 2012; 422: 357–365
- [68] Overmeer RM, Henken FE, Bierkens M et al. Repression of MAL tumour suppressor activity by promoter methylation during cervical carcinogenesis. *J Pathol* 2009; 219: 327–336
- [69] Uleberg KE, Munk AC, Brede C et al. Discrimination of grade 2 and 3 cervical intraepithelial neoplasia by means of analysis of water soluble proteins recovered from cervical biopsies. *Proteome Sci* 2011; 9: 36
- [70] Walts AE, Bose S. p16, Ki-67, and BD ProExC immunostaining: a practical approach for diagnosis of cervical intraepithelial neoplasia. *Hum Pathol* 2009; 40: 957–964
- [71] Pecorelli S, Zigliani L, Odicino F. Revised FIGO staging for carcinoma of the cervix. *Int J Gynaecol Obstet* 2009; 105: 107–108
- [72] The oncology committee of the International Federation of Gynecology and Obstetrics. FIGO news changes of the 1985 FIGO report on the result of treatment in gynecological cancer. *Int J Gynaecol Obstet* 1987; 25: 87–88
- [73] Creasman WT. New gynecologic cancer staging. *Gynecol Oncol* 1995; 58: 157–158
- [74] Burghardt E, Pickel H. Local spread and lymph node involvement in cervical cancer. *Obstet Gynecol* 1978; 52: 138–145
- [75] Burghardt E, Östör A, Fox H. The new FIGO definition of cervical cancer stage IA: a critique. *Gynecol Oncol* 1997; 65: 1–5
- [76] Burghardt E, Girardi F, Lahousen M, Pickel H, Tamussino K. Microinvasive carcinoma of the uterine cervix (International Federation of Gynecology and Obstetrics Stage IA). *Cancer* 1991; 67: 1037–1045
- [77] Bajardi F, Burghardt E. Ergebnisse von histologischen Serienschchnittuntersuchungen beim Carcinoma colli O [Results of histological serial section examinations]. *Arch Gynäkol* 1957; 189: 392–403
- [78] Fennell RH. Carcinoma in situ of the cervix with early invasive changes. *Cancer* 1955; 8: 302–309
- [79] Stoddard LD, Erickson CC, Howard HL. Further studies on the histogenesis of intraepithelial carcinoma and early invasive carcinoma of the cervix uteri. *Am J Pathol* 1950; 26: 679
- [80] Reich O, Pickel H, Tamussino K, Winter R. Microinvasive carcinoma of the cervix: site of first focus of invasion. *Obstet Gynecol* 2001; 97: 890–892
- [81] Pecorelli S, Zigliani L, Odicino F. Revised FIGO staging for carcinoma of the cervix. *Int J Gynaecol Obstet* 2009; 105: 107–108
- [82] Benedet JL, Bender H, Jones H, Ngan HY, Pecorelli S FIGO Committee on Gynecologic Oncology. FIGO staging classifications and clinical practice guidelines in the management of gynecologic cancers. *Int J Gynaecol Obstet* 2000; 70: 209–262

- [83] Singer A, Monaghan JM. Lower Genital Tract Precancer, Colposcopy Pathology and Treatment. Oxford: Blackwell Science, 2000
- [84] Reich O, Pickel H. Multifocal stromal invasion in microinvasive squamous cell carcinoma of the cervix: how to measure and stage these lesions. *Int J Gynecol Pathol* 2002; 21: 416–417
- [85] Simon NL, Gore H, Shingleton HM, Soong SJ, Orr JW, Hatch KD. Study of superficially invasive carcinoma of the cervix. *Obstet Gynecol* 1986; 68: 19–24
- [86] Lohe KJ. Early squamous cell carcinoma of the uterine cervix. I. Definition and histology. *Gynecol Oncol* 1978; 6: 10–30
- [87] Sedlis A, Sall S, Tsukada Y et al. Microinvasive carcinoma of the uterine cervix: a clinical-pathologic study. *Am J Obstet Gynecol* 1979; 133: 64–74
- [88] Benedet JL, Anderson GH. Stage IA carcinoma of the cervix revisited. *Obstet Gynecol* 1996; 87: 1052–1059
- [89] Sedlis A, Sall S, Tsukada Y et al. Microinvasive carcinoma of the uterine cervix: a clinical-pathologic study. *Am J Obstet Gynecol* 1979; 133: 64–74
- [90] Tan GC, Isa MR, Ng SP, Jamil YM. Unusual form of superficial spreading microinvasive squamous cell carcinoma of uterine cervix involving the endometrium of uterus. *J Obstet Gynaecol Res* 2004; 30: 363–367
- [91] Burghardt E. Gibt es ein Flächenwachstum des intraepithelialen Carcinoms an der Cervix [Does a spread of the intraepithelial carcinoma of the cervix exist? (author's transl)]. *Arch Gynäkol* 1973; 215: 1–16
- [92] Ostör AG. Studies on 200 cases of early squamous cell carcinoma of the cervix. *Int J Gynecol Pathol* 1993; 12: 193–207
- [93] Roche WD, Norris HJ. Microinvasive carcinoma of the cervix. The significance of lymphatic invasion and confluent patterns of stromal growth. *Cancer* 1975; 36: 180–186
- [94] Wheeler DT, Kurman RJ. The relationship of glands to thick-wall blood vessels as a marker of invasion in endocervical adenocarcinoma. *Int J Gynecol Pathol* 2005; 24: 125–130
- [95] Reich O, Pickel H, Pürstner P. Exfoliative cytology of a lymphoepithelioma-like carcinoma in a cervical smear. A case report. *Acta Cytol* 1999; 43: 285–288
- [96] Young RH, Welch WR, Dickersin GR, Scully RE. Ovarian sex cord tumor with annular tubules: review of 74 cases including 27 with Peutz-Jeghers syndrome and four with adenoma malignum of the cervix. *Cancer* 1982; 50: 1384–1402
- [97] Reich O, Tamussino K, Lahousen M, Pickel H, Haas J, Winter R. Clear cell carcinoma of the uterine cervix: pathology and prognosis in surgically treated stage IB–IIB disease in women not exposed in utero to diethylstilbestrol. *Gynecol Oncol* 2000; 76: 331–335
- [98] Alkushi A, Irving J, Hsu F et al. Immunoprofile of cervical and endometrial adenocarcinomas using a tissue microarray. *Virchows Arch* 2003; 442: 271–277
- [99] Kong CS, Beck AH, Longacre TA. A panel of 3 markers including p16, ProExC, or HPV ISH is optimal for distinguishing between primary endometrial and endocervical adenocarcinomas. *Am J Surg Pathol* 2010; 34: 915–926
- [100] Park KJ, Kiyokawa T, Soslow RA et al. Unusual endocervical adenocarcinomas: an immunohistochemical analysis with molecular detection of human papillomavirus. *Am J Surg Pathol* 2011; 35: 633–646
- [101] Reich O, Pickel H, Pürstner P. Exfoliative cytology of invasive neuroendocrine small cell carcinoma in a cervical cytologic smear. A case report. *Acta Cytol* 1996; 40: 980–984
- [102] Bornstein J, Bentley J, Bösze P et al. 2011 colposcopic terminology of the international Federation for Cervical Pathology and Colposcopy. *Obstet Gynecol* 2012; 120: 166–172
- [103] Fennell RH. Carcinoma in situ of the uterine cervix; a report of 118 cases. *Cancer* 1956; 9: 374–384
- [104] Thornton WN, Fox CH, Smith DE. The relationship of the squamocolumnar junction and the endocervical glands to the site of origin of carcinoma of the cervix. *Am J Obstet Gynecol* 1959; 78: 1060–1073
- [105] Meyer R. Die Epithelentwicklung der Cervix und Portio vaginalis uteri und die Pseudoerosio congenita [The development of the epithelium of the cervix and porti vaginalis uteri and pseudoerosio congenita]. *Arch Gynäkol* 1910; 91: 579–598
- [106] Meyer R. Die Erosion und Pseudoerosion des Erwachsenen [Erosion and pseudoerosion in the adult]. *Arch Gynäkol* 1910; 91: 658–691
- [107] Bajardi F. Über Wachstumsbeschränkungen des Collumcarcinoms in seinem invasiven und auch präinvasiven Stadium [On limitation of the growth of cervix carcinoma in its invasive and also its preinvasive stage, with a contribution on the formation of pathological uterine cervix epithelium]. *Arch Gynäkol* 1962; 197: 407–454
- [108] Hinselmann H. Einführung in die Kolposkopie [Introduction to Colposcopy]. Hamburg: Hartung 1933
- [109] Girardi F. The topography of abnormal colposcopy findings. *Cervix Lower Female Genit Tract* 1993; 11: 45–52
- [110] Strander B, Ellström-Andersson A, Franzén S, Milsom I, Rådborg T. The performance of a new scoring system for colposcopy in detecting high-grade dysplasia in the uterine cervix. *Acta Obstet Gynecol Scand* 2005; 84: 1013–1017
- [111] Scheungraber C, Koenig U, Fechtel B, Kuehne-Heid R, Duerst M, Schneider A. The colposcopic feature ridge sign is associated with the presence of cervical intraepithelial neoplasia 2/3 and human papillomavirus 16 in young women. *J Low Genit Tract Dis* 2009; 13: 13–16
- [112] Scheungraber C, Glutig K, Fechtel B, Kuehne-Heid R, Duerst M, Schneider A. Inner border—a specific and significant colposcopic sign for moderate or severe dysplasia (cervical intraepithelial neoplasia 2 or 3). *J Low Genit Tract Dis* 2009; 13: 1–4
- [113] Reid R, Scalzi P. Genital warts and cervical cancer. VII. An improved colposcopic index for differentiating benign papillomaviral infections from high-grade cervical intraepithelial neoplasia. *Am J Obstet Gynecol* 1985; 153: 611–618
- [114] Wright VC. Colposcopy of adenocarcinoma in situ and adenocarcinoma of the uterine cervix: differentiation from other cervical lesions. *J Low Genit Tract Dis* 1999; 3: 83–97

Further Reading

- Berjeron C, Ronco G, Reuschenbach M, et al. The clinical impact of using p16INK4a immunochemistry in cervical histopathology and cytology: An update of recent developments. *Int J Cancer* 2014 (online May 12 2014)
- Diaz De Vivar A, Roma AA, Park KJ et al. Invasive endocervical adenocarcinoma: Proposal for a new pattern-based classification system with significant clinical implications: A multi-international study. *Int J Gynecol Pathol* 2013; 32: 592–601
- Dijkstra MG, Snijders PJ, Arbyn M, et al. Cervical cancer screening: on the way to a shift from cytology to full molecular screening. *Ann Oncol*. 2014;25:927-935
- Hammes LS, Naud P, Passos EP et al. Value of the International Federation for Cervical Pathology and Colposcopy (IFCPC) Terminology in predicting cervical disease. *J Low Genit Tract Dis* 2007; 11: 158–165
- Hesselink AT, Heideman DA, Steenbergen RD, et al. Methylation marker analysis of self-sampled cervico-vaginal lavage specimens to triage high-risk HPV-positive women for colposcopy. *Int J Cancer* 2014 Jan 13, online.
- McCluggage WG. Premalignant lesions of the lower female genital tract: cervix, vagina and vulva. *Pathology* 2013; 45: 214–228
- McCluggage WG. New developments in endocervical glandular lesions. *Histopathology* 2013; 62: 138–160
- Negri G, Bellisano G, Carico E et al. Usefulness of p16ink4a, ProEX C, and Ki-67 for the diagnosis of glandular dysplasia and adenocarcinoma of the cervix uteri. *Int J Gynecol Pathol* 2011; 30: 407–413
- Ronco G, Dillner J, Elfström KM et al. Efficacy of HPV-based screening for prevention of invasive cervical cancer: follow-up of four European randomised controlled trials. *Lancet* 2014; 383: 524–532
- Reich O, Fritsch H. The developmental origin of cervical and vaginal epithelium and their clinical consequences - A systematic review. *J Lower Genit Tract Dis* 2014 in press
- World Health Organization Classification of Tumours of the Female Reproductive Organs. 4th edition. Kurman JR, Carcangiu ML, Herrington CS, Young RH (eds). IARC press, Lyon 2014

Chapter 5

The Colposcope and the Colposcopic Examination

5.1 Colposcopic Instruments	62
5.2 Biopsy Instruments	63
5.3 The Colposcopic Examination	63



5 The Colposcope and the Colposcopic Examination

For the first colposcopic examination, Hinselmann used Leitz lenses on top of a pile of books.¹ The light source was a lamp normally used for gynecologic exams positioned above the physician's head to illuminate the cervix. The first colposcope was a fixed binocular instrument mounted on a tripod and equipped with a light source and a mirror to center the light (► Fig. 5.1).

Modern colposcopes permit magnification between $\times 6$ and $\times 40$. Enlargement $\times 10$ is most suitable for routine use. Higher magnifications reveal minor features but are not necessary for accurate diagnosis. The colposcope can be equipped with a green filter to filter out red and thereby enhance the vascular appearance of the vessels by making them look darker.

A colposcope can be mounted in different ways. For routine use, a swivel arm attached to the examination chair is very practical (► Fig. 5.2). It can be easily adjusted by hand, both vertically and horizontally. A colposcope on a mobile stand is independent of the examination table (► Fig. 5.3). It can be fitted with a swivel arm and, with the wheels locked, can be used in the same way as a scope mounted on the examination table. Colposcopes mounted on the wall or ceiling are easy to handle because of their mobility. The head of the colposcope can be tilted up, down, and sideways. There is usually no need for the fine adjustment, as a sharp focus can be achieved just as easily by positioning the scope at the working distance of 20–24 cm.

Photographic and video equipment are important accessories. For teaching, a camera and video equipment are mandatory.³ Video colposcopy can improve patient satisfaction.² New technologies are likely to improve the colposcopic detection of precancerous lesions.^{4,5,6,7}

5.1 Colposcopic Instruments

Colposcopy requires few instruments. In addition to the colposcope, one needs a duck-billed speculum or Breisky-type retractors, anatomic forceps and swabs, dilute acetic acid and iodine, and biopsy instruments (► Fig. 5.4). Some investigators use an endocervical speculum to improve access to the cervical canal (► Fig. 5.4).

5.1.1 Specula

A duckbill speculum (► Fig. 5.4) usually provides adequate exposure of the cervix and can be manipulated by the examiner without assistance. Duckbill specula are available in various sizes. On occasion, vaginal (Breisky) retractors (► Fig. 5.4) are helpful, particularly to evaluate lesions involving the fornix and vagina. A disadvantage of the Breisky speculum is that the anterior blade needs to be held by an assistant.

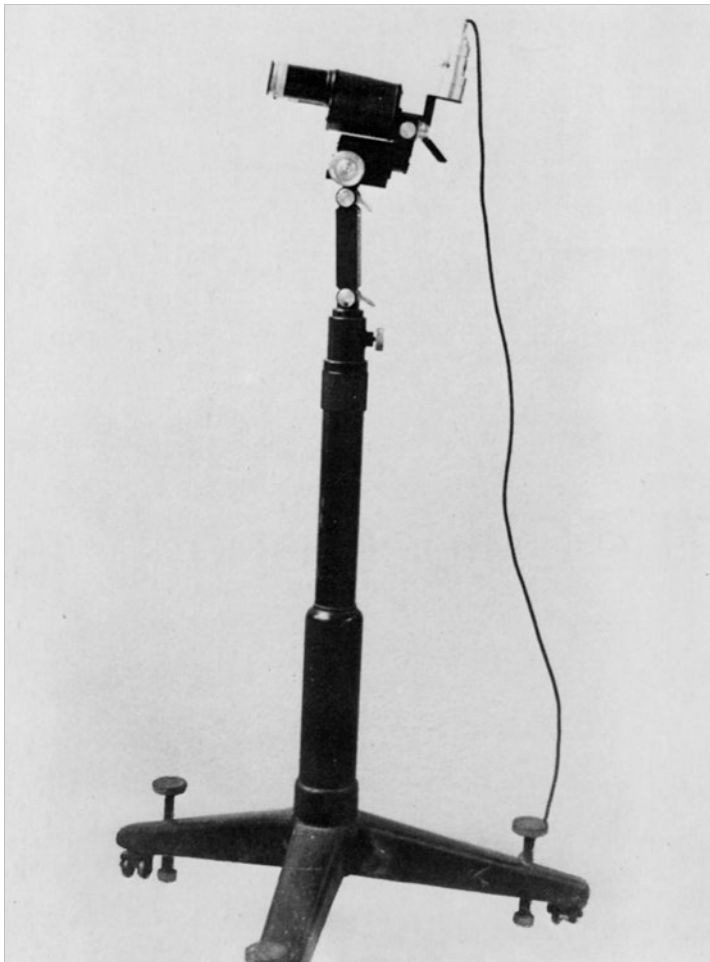


Fig. 5.1 The first colposcope with a fixed mount. This model was designed by Hinselmann and built by Leitz.



Fig. 5.2 Chair-mounted colposcope (Carl Zeiss, Oberkochen, Germany).

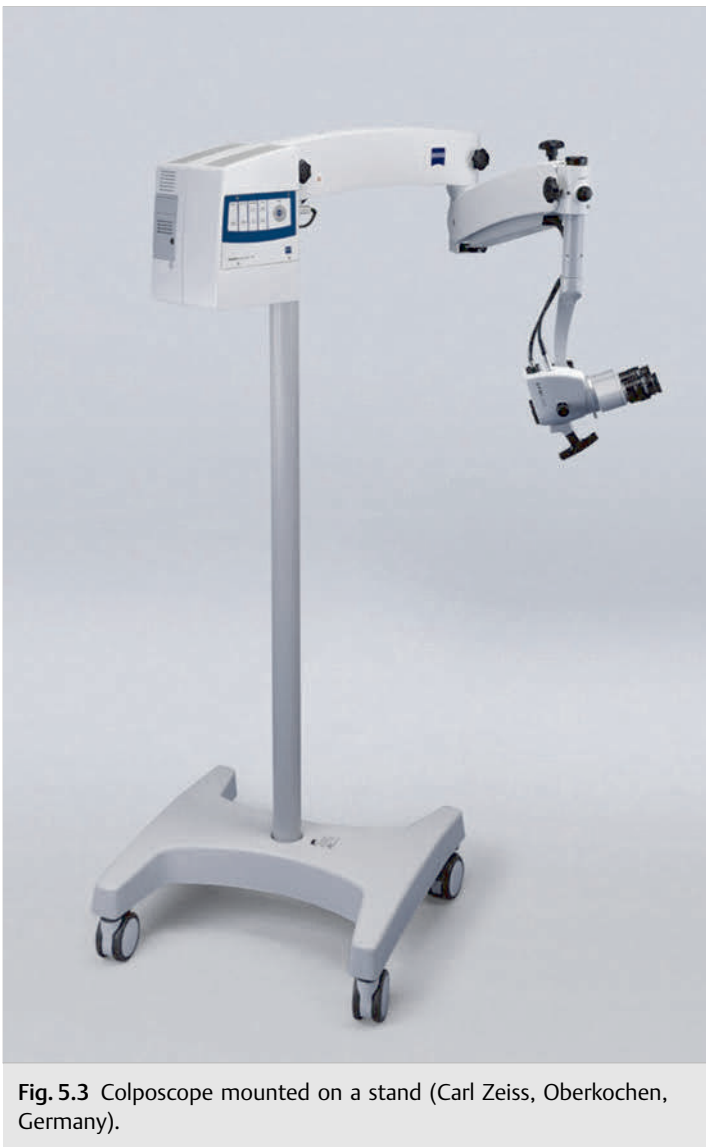

Fig. 5.3 Colposcope mounted on a stand (Carl Zeiss, Oberkochen, Germany).

5.1.2 Forceps

Anatomic forceps at least 20 cm long are needed to handle swabs (► Fig. 5.4). They are more practical than tenacula. Sometimes forceps can be used to improve access to the cervical canal, for example, to evaluate the squamocolumnar junction (SCJ) and define the type of transformation zone.

5.1.3 Containers

Swabs are placed in a bowl from which they can be easily retrieved with forceps. For the acetic acid test (► Fig. 5.4), swabs are soaked in 3% acetic acid and handled with forceps. Iodine (Lugol's solution) is put into test tubes, which are placed in a rack. Tampons, which can be removed by the patient later. (► Fig. 5.13), are available.

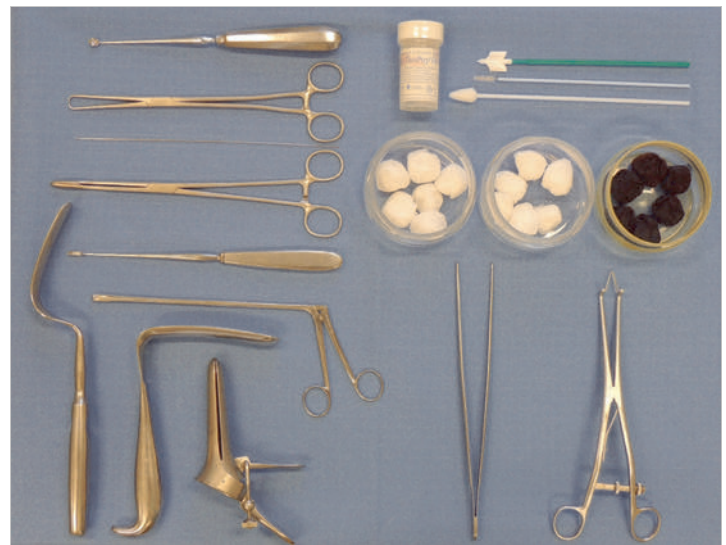

Fig. 5.4 Instruments for colposcopy (clockwise from lower left): Breisky specula, biopsy forceps, curet, oval forceps, Chrobak's probe, tenacula, sharp curet, ThinPrep container, three cytobrushes, swabs for acetic acid and iodine, cervical dilator according to Cogan, and anatomical forceps.

5.2 Biopsy Instruments

There are several types of biopsy instruments (► Fig. 5.4). They are usually scissor-shaped and measure between 20 and 25 cm. Sharp curets of various sizes are needed for scraping the endocervical canal and to obtain material from clinically invasive cancers. To curet a narrow endocervical canal, instruments with fine, sharp grooves are more practical than spoon-shaped ones.

5.2.1 Tenacula

To prevent slipping of the biopsy punch and obtain an accurately directed biopsy, fixation of the cervix is sometimes helpful. This can be done easily and painlessly with a single-toothed tenaculum (► Fig. 5.4). Cervical polyps can be avulsed with polyp forceps (► Fig. 5.4).

5.2.2 Chrobak's Probe

Chrobak's probe (► Fig. 5.5) is a thin steel sound with a bulbous head that is useful to distinguish between carcinomas and papillomas or flat ectocervical ulcers (see Chapter 4). When investigating normal tissue or benign tumors, the probe encounters an elastic resistance; in contrast, malignant tissue feels soft, like warm butter.

5.3 The Colposcopic Examination

The colposcopic examination begins with an explanation for the patient. The vulva and perianal region is inspected (see



Fig. 5.5 Chrobak's probe.

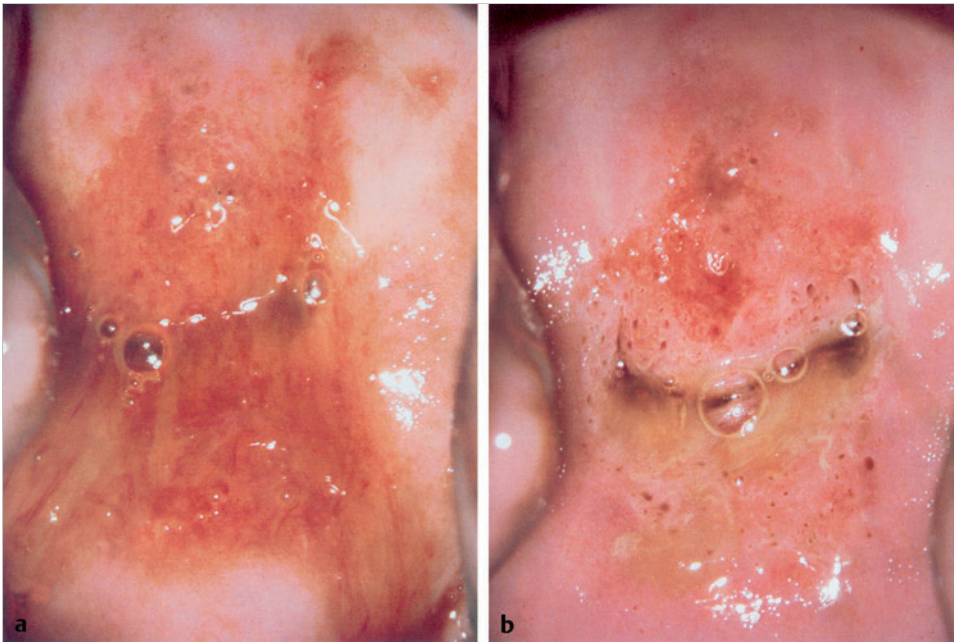


Fig. 5.6 (a) Normal transformation zone before application of acetic acid. The fine details are clouded by mucous. (b) Removal of the mucous with 3% acetic acid reveals numerous gland openings.

Chapter 13). An appropriate duck-billed speculum is inserted; lubrication of the speculum can be helpful. Secretions and signs of inflammation in the vagina are noted, if present (see Chapter 14). The cervix is visualized and dry swabbed to remove mucous. The cervix, particularly the vessels, is inspected colposcopically in the native state. A smear for cervical cytology (Pap smear) is obtained with an Ayre's spatula, cervical brush, or cotton-tipped swab. If indicated, material for HPV testing is obtained with an appropriate brush. If liquid-based cytology is used, only one sample of material is obtained with an appropriate brush and transferred to the container; cytology, HPV testing, and other molecular tests are done from the liquid suspension.

On occasion, the cervix can be difficult to expose adequately. This can be the case in obese women, patients with a narrow vagina or vaginal stenosis, or patients with pelvic tumors or a fibroid uterus distorting the anatomy. In these (rare) cases we obtain a smear without visualizing the cervix proper.

The acetic acid test and the iodine test (Schiller test), which we consider integral parts of the colposcopic examination, are next.

At the end of the colposcopic examination we make a decision whether and where to biopsy. It is our practice to biopsy a major lesion noted at colposcopy without awaiting the results of cytology or HPV testing.

5.3.1 Application of Acetic Acid

Application of 3% acetic acid plays a decisive role in colposcopic diagnostics. No colposcopic examination is complete without it.

After removing vaginal secretions with dry swabs, the cervical epithelium is often still masked by a film of mucus, especially in the presence of ectopy. Cleansing the cervix of mucous with acetic acid enhances the colposcopic features. This applies especially to the grapelike structure of columnar epithelium in ectopy. However, all epithelial lesions become more distinct with acetic acid, the color changes are accentuated, and the various structures become more easily distinguishable from one another (► Fig. 5.6).

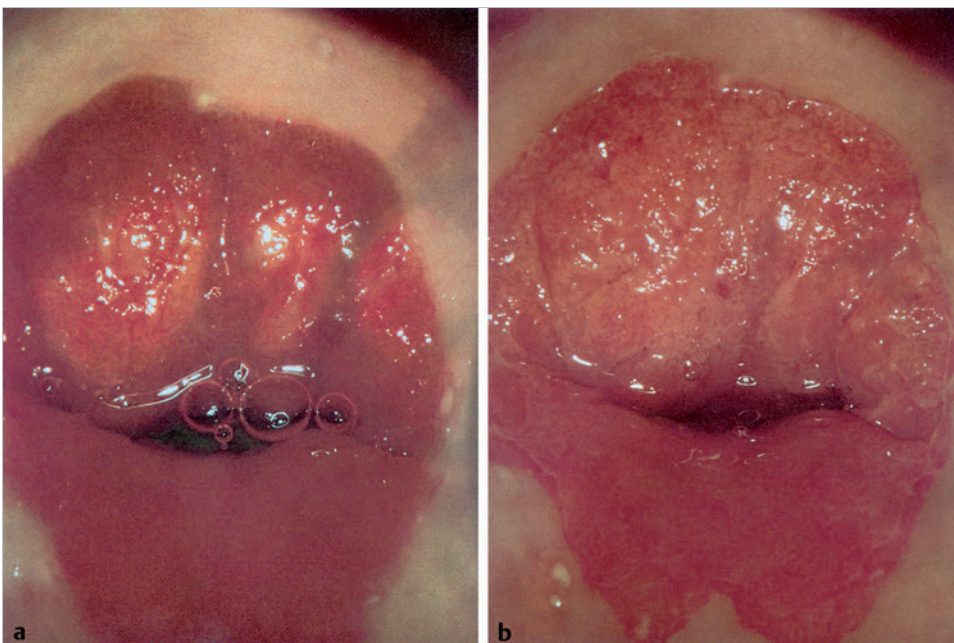


Fig. 5.7 (a) Large intensely red area around external os. The border to the normal squamous epithelium is abrupt. (b) Application of 3% acetic acid evokes the grape-like structure of the mucosa covered by columnar epithelium. Note the blanching of the previously intensely red area caused by the swelling of the columnar epithelium. Individual gland openings in the adjacent squamous epithelium on the posterior lip indicate that transformation has occurred.

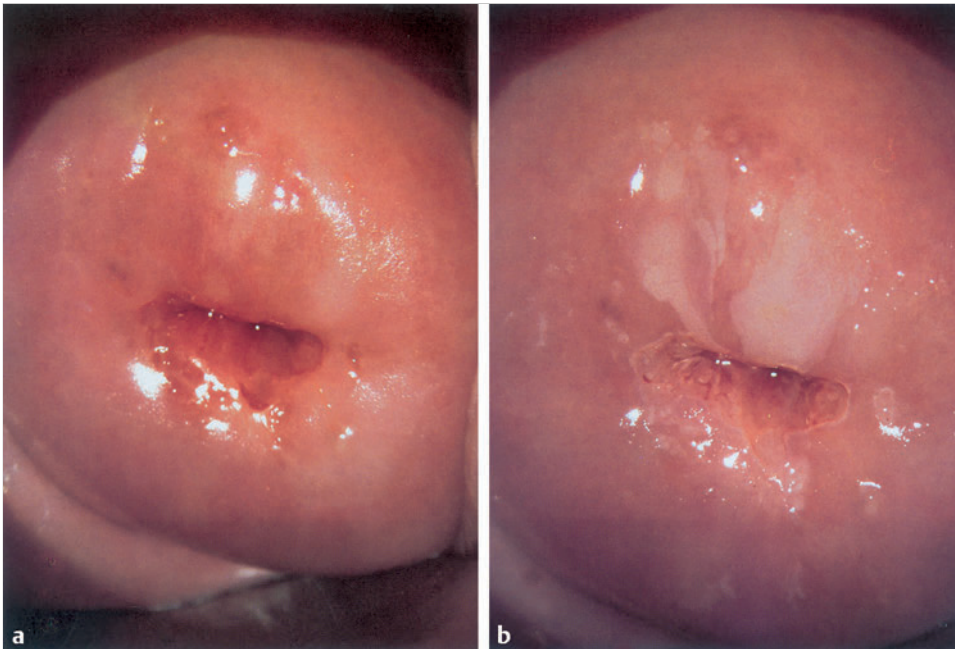


Fig. 5.8 (a) A distinct red area on the anterior lip of the external os. On the posterior lip there is a small intensely red area. (b) Application of 3% acetic acid reveals a number of sharply demarcated white areas on the anterior lip. There are some cuffed gland openings near the white areas. Histology showed HSIL (CIN 2). The area on the posterior lip is columnar epithelium with a narrow transformation zone at its edge.

Ectopy shows a dramatic change of color after application of acetic acid. The intense dark red ectopic columnar epithelium becomes paler and displays shades of pink to white. At the same time, the grapelike structures become more pronounced because of swelling and enlargement of the villi (► Fig. 5.7).

Similar changes can be seen in altered epithelia. The epithelial swelling caused by acetic acid turns atypical epithelium white and accentuates its surface contour (► Fig. 5.8). The patterns of mosaic and punctuation also become more distinct, and the red partitions and fine petechiae stand out against the white epithelium (► Fig. 5.9).

Because the effect on pathologic epithelium is not as rapid as on ectopic columnar epithelium, the white epithelium that appears after application of acetic acid should not be confused with leukoplakia.

5.3.2 Schiller (Iodine) Test

Application of iodine quickly produces intense staining of glycogen-containing epithelium. (► Table 5.1) This makes it an

important diagnostic aid for assessing colposcopic findings. Lugol's iodine solution was first used in clinical diagnosis by Walter Schiller in 1929,^{8, 9,10,11} hence the term Schiller test. While some colposcopists do not use iodine, we find it very useful for the evaluation of colposcopic morphology. We pay particular attention to how acetowhite epithelium reacts with the Lugol's solution.

The 1% iodine solution consists of 2 g iodine and 4 g potassium iodide dissolved in 200 ml distilled water.

The Schiller test depends on the interaction between iodine and glycogen. The glycogen-containing vaginal epithelium of women of reproductive age quickly takes up iodine to produce an intense mahogany brown. Glycogen-free epithelium stains yellow (not brown) with iodine (► Fig. 5.10). Such an area is referred to as iodine-yellow (sometimes—and in our opinion incorrectly—to as iodine negative).

Iodine solution stains normal glycogen-containing squamous epithelium uniformly deep brown. Such epithelium is found during the reproductive period and reflects the influence of estrogens (► Fig. 5.11).

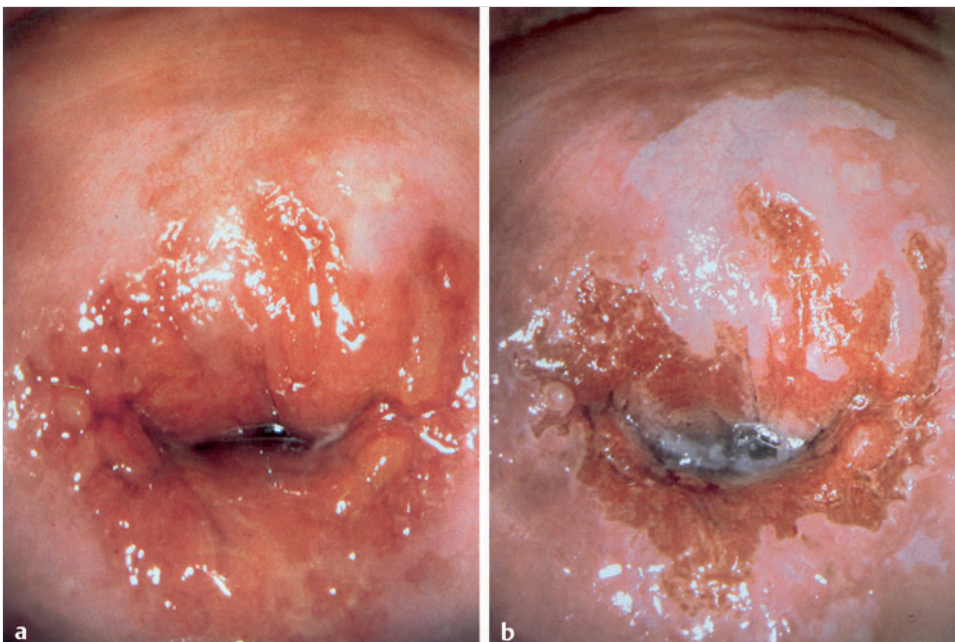


Fig. 5.9 (a) Before application of acetic acid the transformation zone is inconspicuous. The experienced colposcopist will detect an early lesion at 12 o'clock outside the transformation zone. (b) The white color and mosaic pattern of HSIL (CIN 3) are due to cellular edema caused by acetic acid.

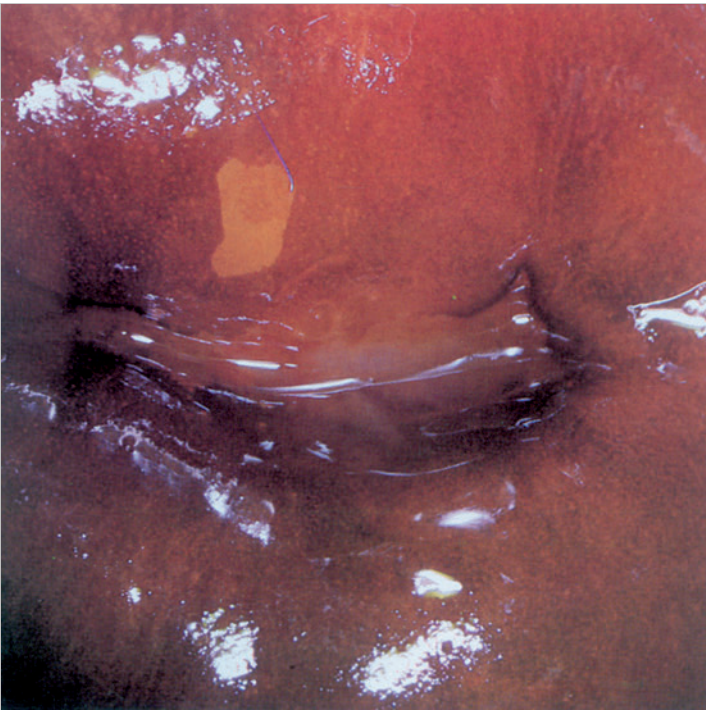

Fig. 5.10 Original squamous epithelium displays uniform mahogany staining with iodine. Note a sharply demarcated iodine-yellow area at the 11 o'clock position.

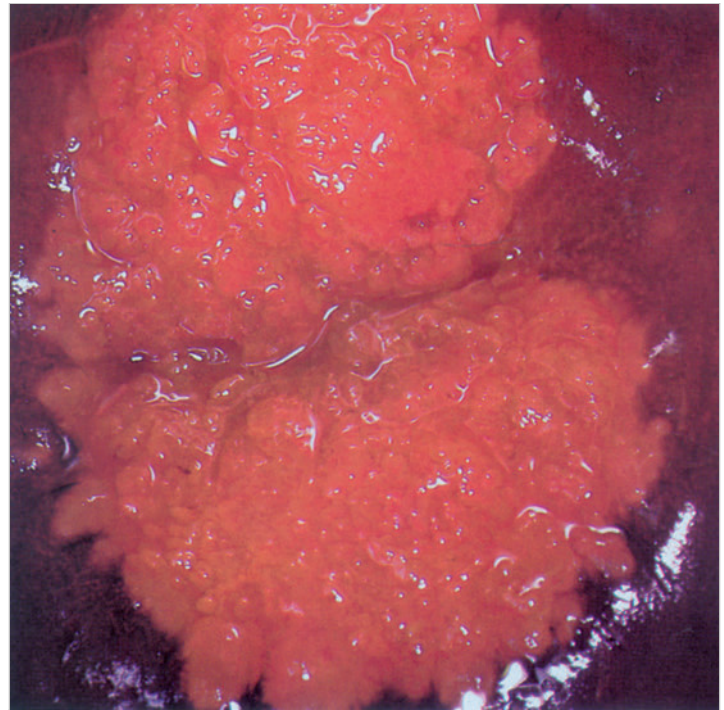


Fig. 5.11 The columnar epithelium of an ectopy does not stain with iodine (iodine negative). It shows only a slight discoloration due to the thin film of solution veiling it. The original epithelium stains characteristically deep brown.

Columnar epithelium does not stain with iodine (► Fig. 5.11) nor does thin regenerating epithelium, seen during the early stages of squamous metaplasia (► Fig. 5.12). Failure to stain with iodine is useful to assess inflammatory lesions, which, because of their increased vascularity and capillary dilatation, can mimic punctation. Inflammation is associated with indistinct margins and failure to react strongly with iodine (► Fig. 5.13).

Dysplastic epithelium stains with iodine as described below, even when still thin. This is an important difference between the normal transformation zone and the acetowhite epithelium. A colposcopic lesion, as well as the whole length of the vagina, can display all shades between tan and the chestnut brown of normal squamous epithelium (► Fig. 5.14).

Designation	Staining	Underlying histology
Iodine positive	Deep brown (mahogany)	Mature glycogen-containing squamous epithelium
Iodine negative	None	Columnar epithelium Immature metaplastic epithelium Inflammation
Weak staining	Lighter shades of brown	Waning estrogen effect (menopause) Transformation zone during metaplasia
Iodine-yellow	Characteristic canary yellow to ochre	HSIL (CIN 2, CIN 3)
Nonsuspicious iodine-yellow area	Yellow	Metaplastic squamous epithelium LSIL (CIN1)
Iodine positive mosaic or punctation	Brown, brownish, speckled brown	Condylomatous colpitiss, condylomatous lesions

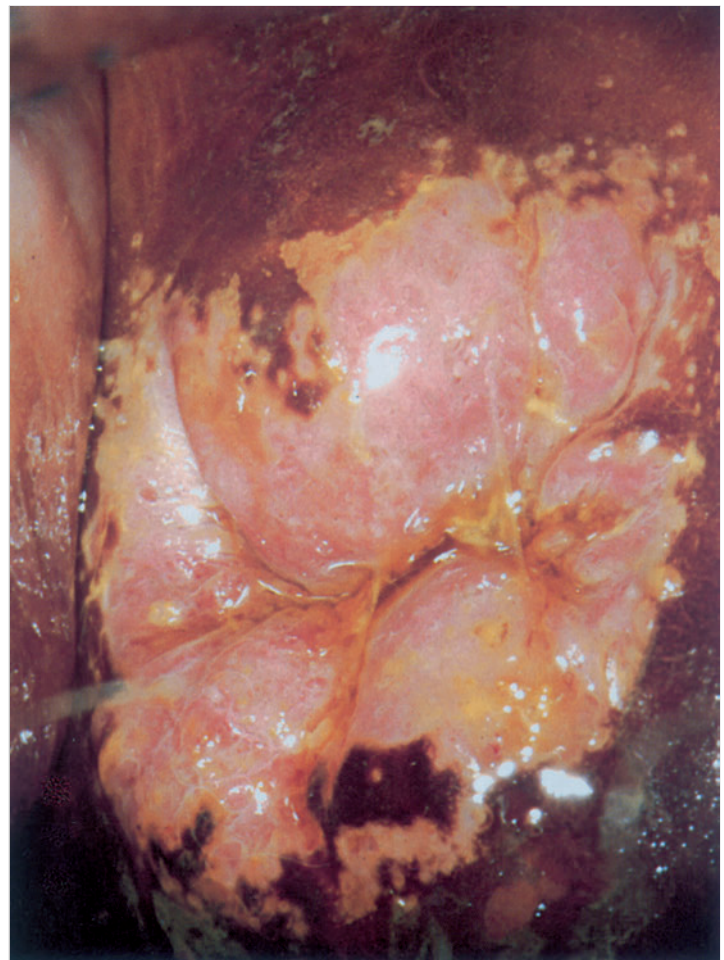


Fig. 5.12 The normal transformation zone does not stain with iodine. Note the contrast with the mahogany color of the original squamous epithelium.

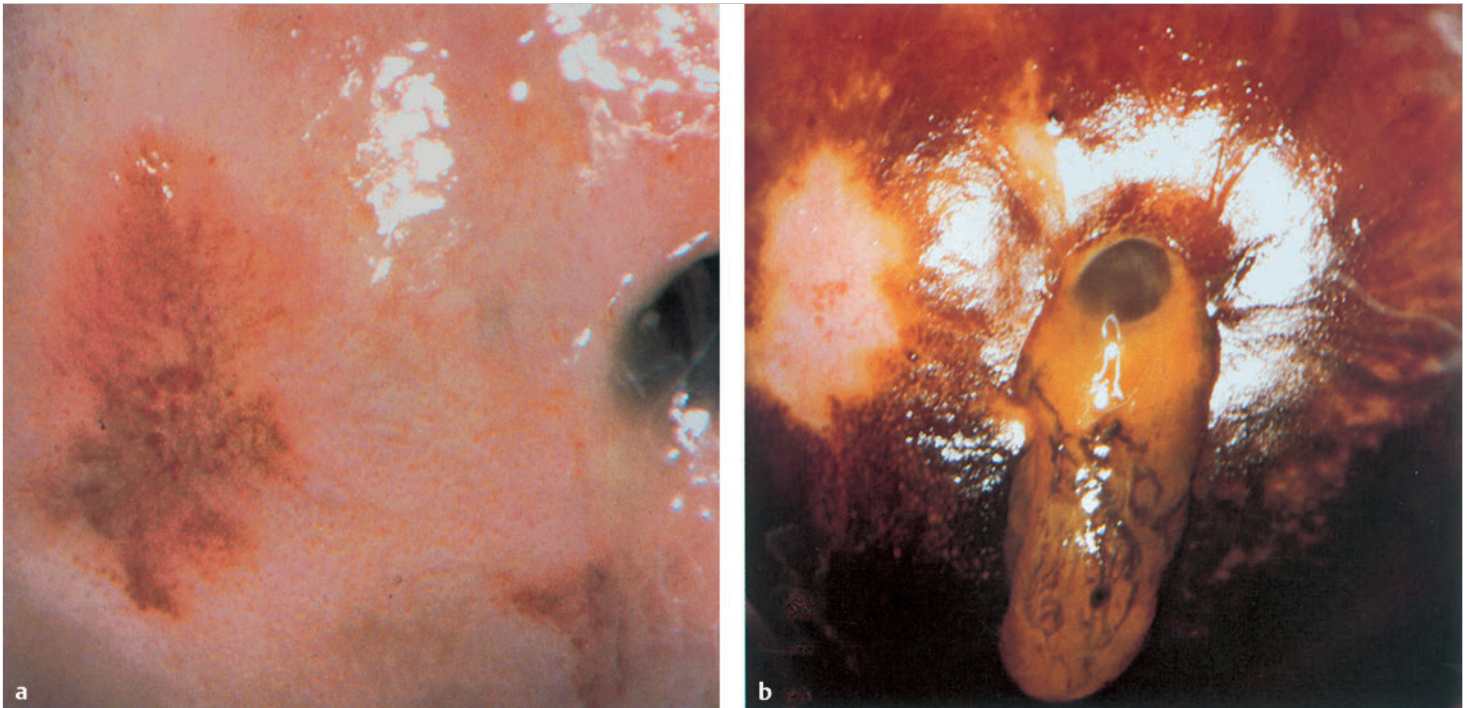


Fig. 5.13 (a) Red, inflamed area lateral to the external os. (b) This area does not stain with iodine and is poorly demarcated from the adjacent deep brown original epithelium.

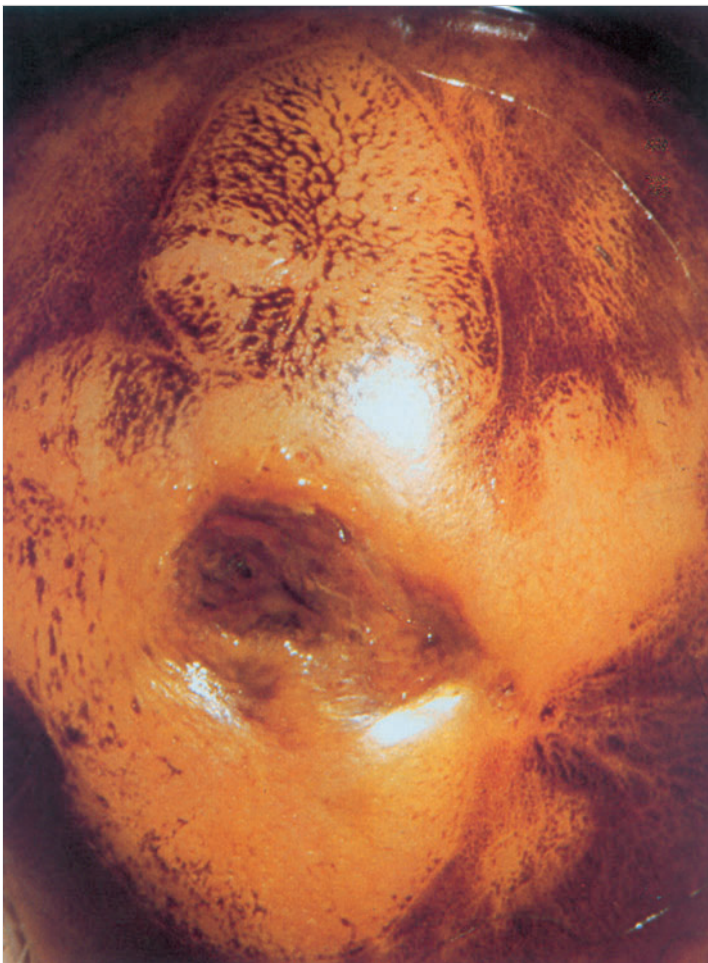


Fig. 5.14 This transformation zone has a stippled appearance with iodine reflecting the various stages of development of the metaplastic epithelium.

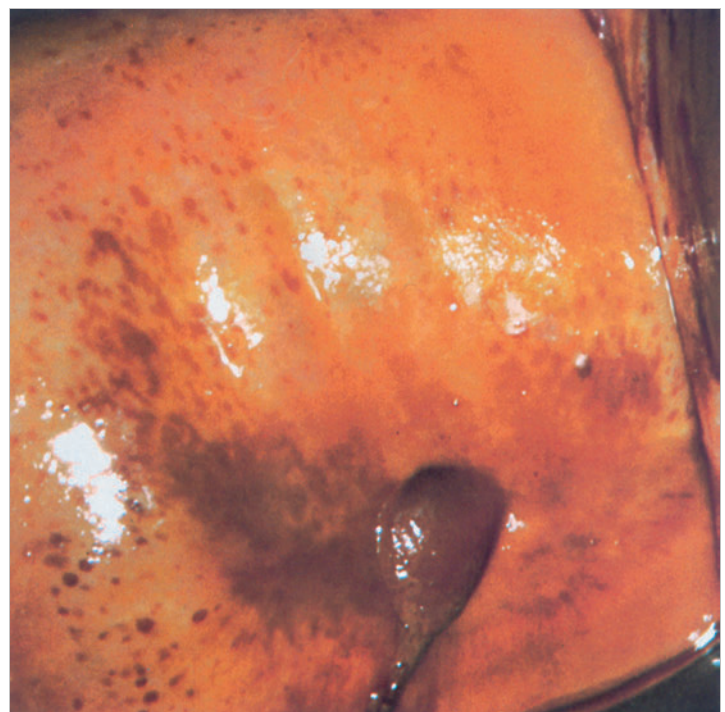


Fig. 5.15 Yellowish light brown of atrophic epithelium after application of iodine. At least some of the dark spots are due to subepithelial hemorrhages.

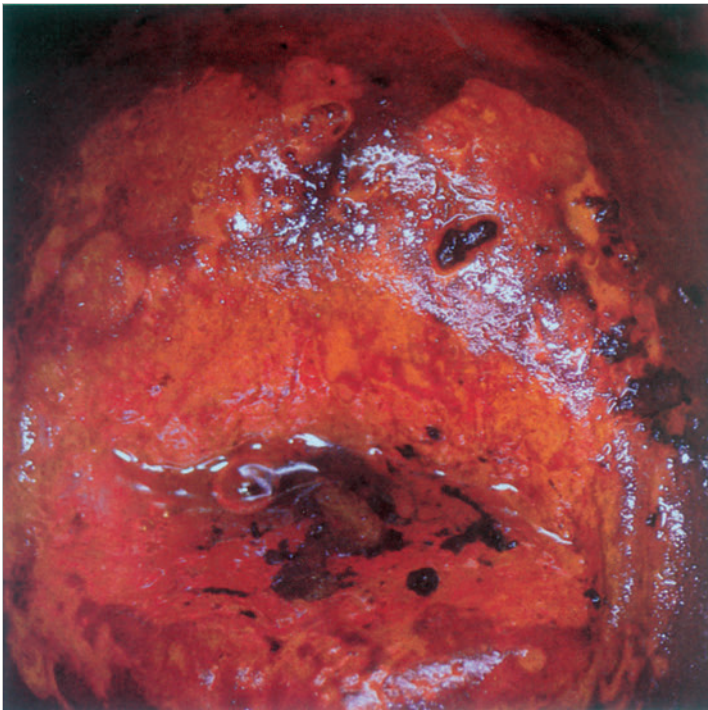


Fig. 5.16 When transformation is more advanced, various shades of brown may appear, according to the maturity of the metaplastic epithelium.

The vagina can have a stippled brown appearance, especially after menopause, when the effect of estrogen wanes. The post-menopausal cervix and vagina stain light brown to yellow (► Fig. 5.15, ► Fig. 8.7).

The various shades of brown of the normal transformation zone depend on the maturity (i.e., the glycogen content) of the

squamous epithelium (► Fig. 5.16). The squamous epithelium in the fully developed transformation zone stains mahogany brown. The transformation zone in such cases can be recognized only by the gland openings and the retention cysts (► Fig. 5.17). The deep brown color distinguishes it from the acetowhite epithelium, as metaplastic and dysplastic epithelia are almost always glycogen-free.

Iodine solution typically reacts with SIL to produce a characteristic ochre yellow (► Fig. 5.17, ► Fig. 5.18, ► Fig. 5.19, ► Fig. 5.20, ► Fig. 5.21). In some cases, only portions of the transformation zone stain yellow (► Fig. 5.21). Such areas should be regarded with suspicion, should be carefully searched for, and should be considered for biopsy.

The colposcopist who uses the Schiller test routinely often will see well-demarcated areas with a characteristic canary yellow color that otherwise escape colposcopic detection. Such an area, which is otherwise inconspicuous, is referred to as a non-suspicious iodine-yellow area, and is usually due to metaplastic squamous epithelium (► Fig. 5.10). If the exact location of a non-suspicious iodine-yellow area has been noted, colposcopic examination after the effect of iodine has subsided can detect a subtle color difference between this area and normal squamous epithelium (► Fig. 8.84).

Not only the nuances of color, but also the borders between normal and altered epithelia can be viewed to advantage with the help of iodine. The epithelial borders within colposcopic lesions also become distinct (► Fig. 5.9; see also ► Fig. 8.142 and ► Fig. 10.3). There is no better way to demonstrate the sharpness and clarity of epithelial borders. This is of great diagnostic import, as poorly circumscribed colposcopic areas are hardly ever significant (► Fig. 5.11, ► Fig. 5.12, ► Fig. 5.13, ► Fig. 5.14, ► Fig. 5.16).

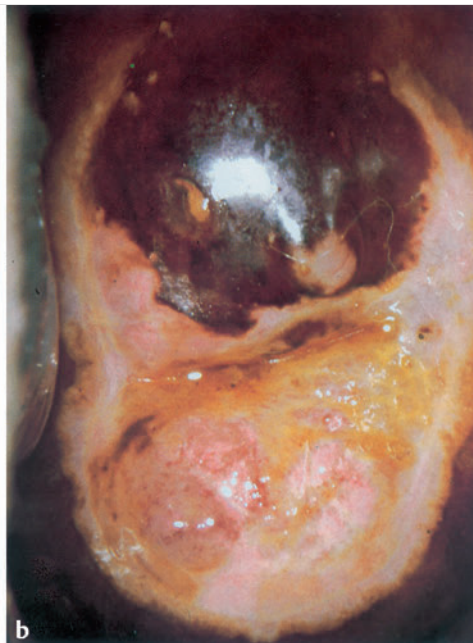
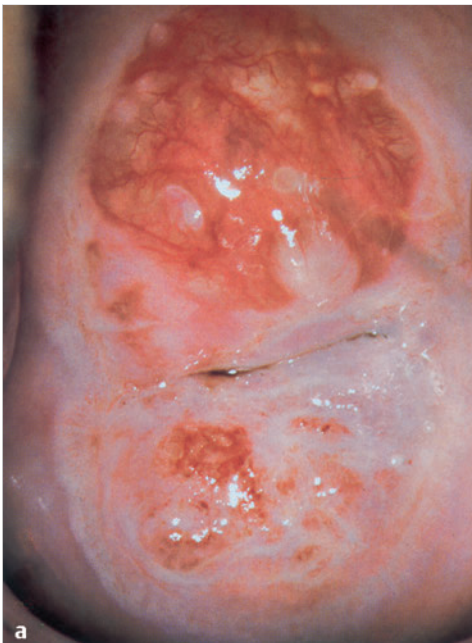

Fig. 5.17 (a) Very different appearance of the transformation zones anteriorly and posteriorly. On the anterior lip, the squamous epithelium is attenuated over retention (nabothian) cysts, and blood vessels coarse over their surfaces. The posterior lip shows acetowhite epithelium and gland openings. **(b)** Surprising reaction with iodine. The epithelium covering the retention cysts is fully mature and contains glycogen. The area on the posterior lip, which stains partly or not at all with iodine, corresponded to HSIL (CIN 3) histologically.

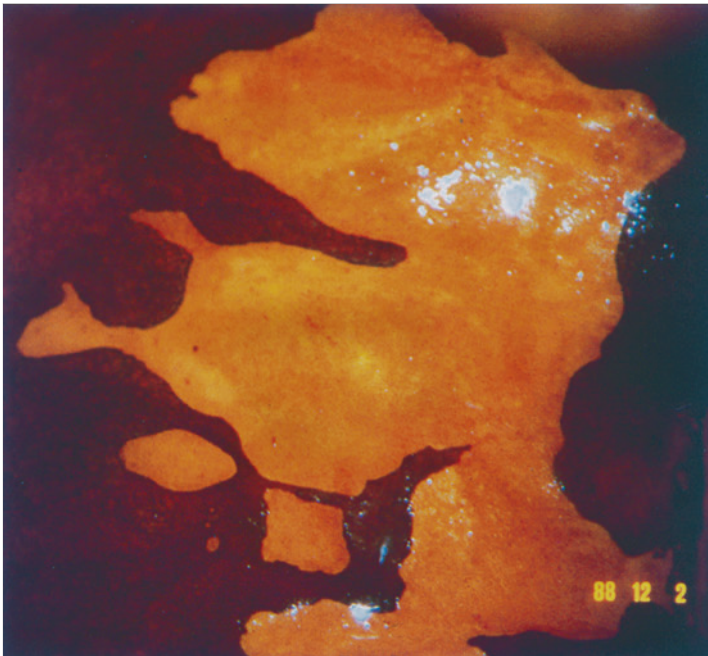


Fig. 5.18 Nonsuspicious iodine-yellow area. The lesion is sharply demarcated and in the same plane as its surroundings. Histology showed metaplastic squamous epithelium.

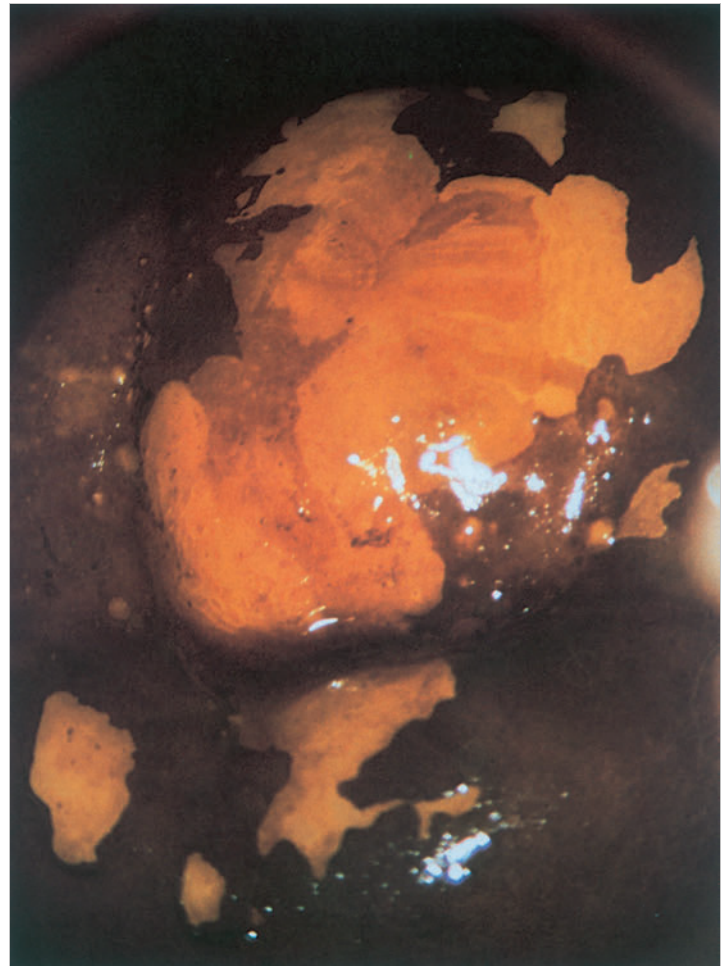


Fig. 5.19 Nonsuspicious iodine-yellow area with different color tones, from yellow to brown, corresponding to sharply demarcated epithelial fields. Histology showed metaplastic squamous epithelium.

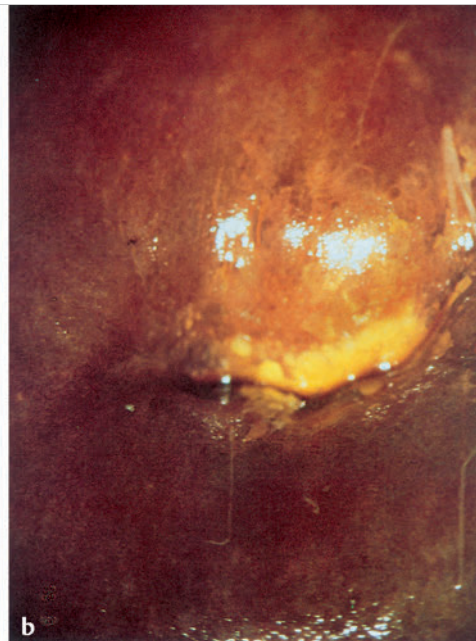
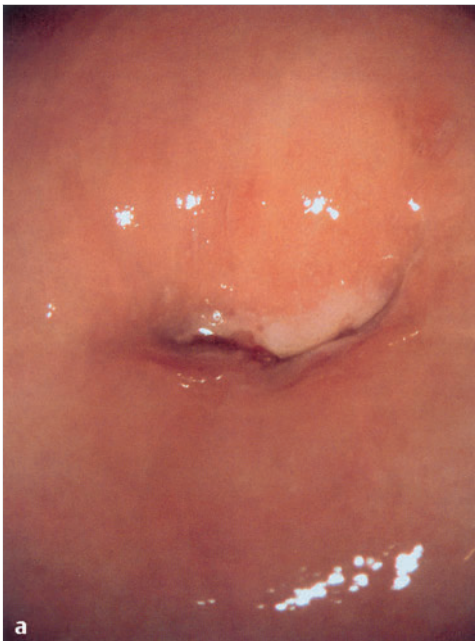

Fig. 5.20 (a) Application of 3% acetic acid reveals a small, easily missed white area on the anterior external os. (b) After application of iodine the area on the external os appears bright yellow. Histology showed HSIL (CIN 2) in the cervical canal.

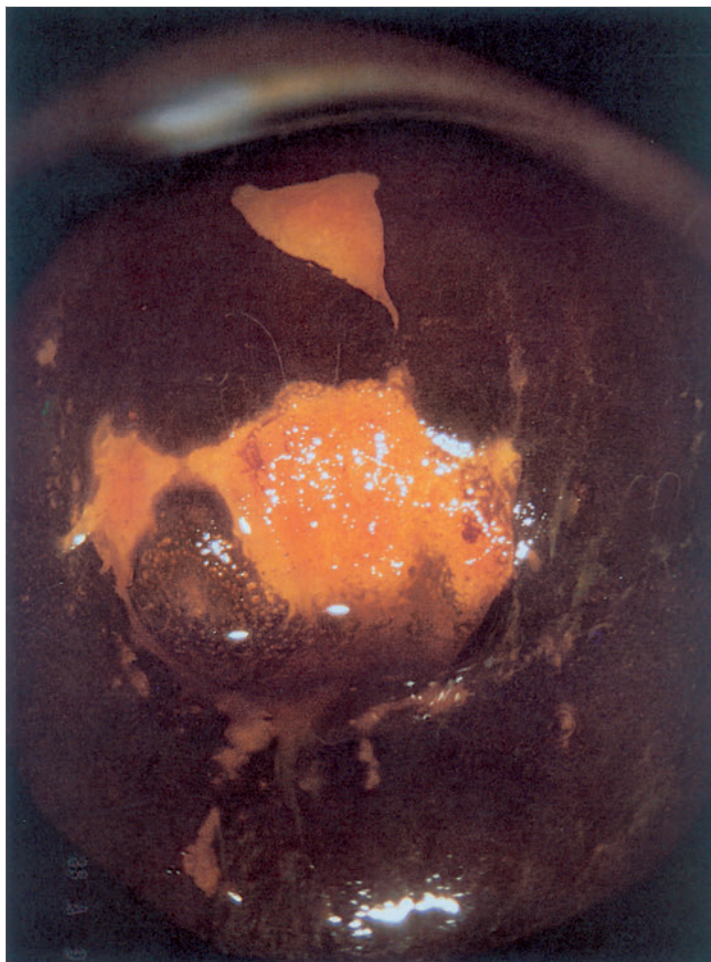


Fig. 5.21 Patchy uptake of iodine by a partially atypical transformation zone. Histology showed HSIL (CIN 3). On the left, within the transformation zone, there is a small condylomatous area with iodine-positive punctation. At 12 o'clock there is an isolated nonsuspicious iodine-yellow area.

References

- [1] Hinselmann H. Die Ätiologie, Symptomatologie und Diagnostik des Uteruskarzinoms. In: Veit J, Stoeckel W, eds. *Handbuch der Gynäkologie*. Vol 6:1. Munich: Bergmann, 1930:854
- [2] European Federation for Colposcopy and Pathology of the Lower Genital Tract. www.e-f-c.org (accessed 28 November 2012)
- [3] Greimel ER, Gappmayer-Löcker E, Girardi FL, Huber HP. Increasing women's knowledge and satisfaction with cervical cancer screening. *J Psychosom Obstet Gynaecol* 1997; 18: 273–279
- [4] Soutter WP, Diakomanolis E, Lyons D et al. Dynamic spectral imaging: improving colposcopy. *Clin Cancer Res* 2009;15:1814–1820
- [5] Park SY, Follen M, Milbourne A et al. Automated image analysis of digital colposcopy for the detection of cervical neoplasia. *J Biomed Optics* 2008;13:1–10
- [6] Balasubramani L, Brown BH, Healey J, tidy JA. The detection of cervical intraepithelial neoplasia by electronical impedance spectroscopy: the effects of acetic acid and tissue homogeneity. *Gynecol Oncol* 2009;115:267–271
- [7] Alvarez RD, Wright TC. Effective cervical neoplasia detection with a novel optical detection system: a randomized trial. *Gynecol Oncol* 2007;104:281–289
- [8] Schiller W. Early diagnosis of carcinoma of the cervix. *Surg Gynecol Obstet* 1933;56:210
- [9] Schiller W. Early diagnosis of carcinoma of the portio uteri. *Am J Surg* 1934;26:269
- [10] Schiller W. Pathology of the cervix. *Am J Obstet Gynecol* 1937;34:430.
- [11] Schiller W. Leukoplakia, leukokeratosis, and carcinoma of the cervix. *Am J Obstet Gynecol* 1938;35:17

Chapter 6

Teaching Colposcopy

6.1 Understanding Colposcopic Findings 72



6 Teaching Colposcopy

The colposcope is a simple instrument, the handling of which should pose no difficulties, even for beginners. The eyepieces are adjusted individually. The instrument is focused by moving the swivel arm to the working distance for the particular scope. It is usually unnecessary to use the fine focus. Magnification $\times 10$ is quite adequate for routine work. Higher magnification is needed only to study details. Smaller enlargements can be used for panoramic photographs. Colpophotography is simple and produces high-quality pictures. The cervix has to be exposed well and the camera focused correctly. Video systems are very helpful for teaching purposes and to demonstrate the dynamics of changes after application of acetic acid. The European Federation for Colposcopy and Pathology of the Lower Genital Tract has proposed standards for colposcopy training [<http://www.e-f-c.org/pages/education/minimum-standards-for-colposcopy-training.php?lang=DE>]. The International Federation for Cervical Pathology and Colposcopy provides useful information online [<http://www.ifcpc.org/>].

6.1 Understanding Colposcopic Findings

Basic knowledge of colposcopic theory and an appreciation of cervical pathology are essential. Only by correlating colposcopic and histologic changes can the colposcopic findings be interpreted correctly (see Chapters 4 and 15). Once a working knowledge of colposcopic findings has been acquired from a textbook, atlas, or teaching slides, it is helpful to work with an experienced colposcopist who can demonstrate and explain findings step by step. Obtaining a biopsy should be demonstrated and then practiced. All of this can be done with video equipment. Video monitoring also lets the patient follow the examination. A randomized trial showed that videocolposcopy increased patient satisfaction with preventive health care.¹ Video applications for teaching and documentation will undoubtedly increase as the technology advances. Courses where individual problems can be discussed with the faculty are available at entry and advanced levels.

Improvement takes practice. The time it takes to improve and the degree of competence attained also depend on how the colposcope is integrated into practice. We use the colposcope at every gynecologic examination. By working this way, the practitioner will get into the routine of using the colposcope at every speculum examination and will not find the approach costly or unnecessarily time-consuming. It expedites the appreciation of benign findings in women of all ages, and familiarity with benign findings makes one more alert to those that are no longer benign. It is logical to start with the study of ectopy and continue with the protean manifestations of the transformation zone. We believe this approach fosters an understanding of the dynamics of the events at the cervix, which, if they take a wrong turn, can lead to atypia and neoplasia.

Certain colposcopic findings are easy to categorize either as benign or as highly suspicious, but in between there is a wide spectrum of appearances that are difficult to appraise (see Chapter 14). The same applies to cytology. The degree of uncertainty depends on the experience of the examiner. Obtaining a biopsy of doubtful findings is part of the learning process and avoids serious mistakes. By correlating the colposcopic appearance with the histologic findings, the practitioner will gain confidence and the number of biopsies will decrease. The chance of missing a significant finding is considerably reduced by concomitant cytology.

Reference

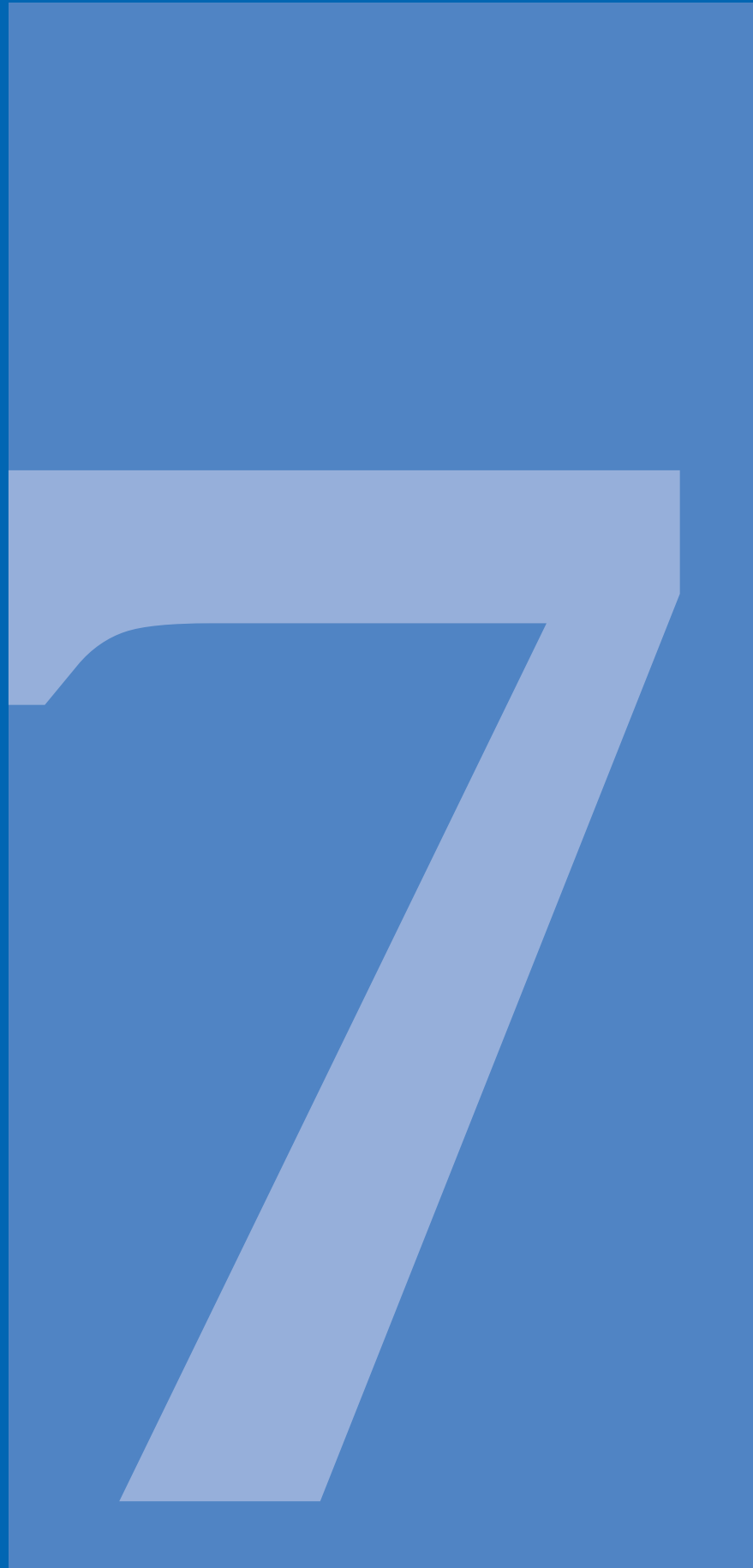- [1] Greimel ER, Gappmayer-Löcker E, Girardi FL, Huber HP. Increasing women's knowledge and satisfaction with cervical cancer screening. *J Psychosom Obstet Gynaecol* 1997; 18: 273–279

Further Reading

- European Federation for Colposcopy and Pathology of the Lower Genital Tract. www.e-f-c.org (accessed 28 November 2012)
- International Federation for Cervical Pathology and Colposcopy (IFCPC). www.ifcpc.org (accessed 28 November 2012)

Chapter 7

Colposcopic Terminology



7 Colposcopic Terminology

After Hinselmann's initial descriptions,¹ a variety of colposcopic nomenclatures developed in different countries. The first uniform international terminology was agreed upon by the International Federation for Cervical Pathology and Colposcopy (IFCPC) in Graz, Austria, in 1975.² Substantial changes were made at the meetings in Rome, Italy, in 1990³ and Barcelona, Spain, in 2002.⁴ A detailed history of colposcopic terminologies is provided elsewhere.⁵

The latest version of the international terminology, which is used in this book, was formulated by the IFCPC with the Interna-

tional Society for the Study of Vulvar Disease (ISSVD) in Rio de Janeiro, Brazil, in 2011. This current version provides a comprehensive terminology for the entire lower genital tract and thus includes vulvar, vaginal, and anal disease as well as cervical findings.^{6,7} It also specifies terminology for different excision techniques and excision specimen dimensions (► Table 7.1, ► Table 7.2, ► Table 7.3, ► Table 7.4, ► Table 7.5).

Table 7.1 2011 International Federation for Cervical Pathology and Colposcopy colposcopic terminology of the cervix⁷

General assessment		<ul style="list-style-type: none"> • Adequate/inadequate for the reason (e.g., cervix obscured by inflammation, bleeding, scar) • SCJ visibility: completely visible, partially visible, not visible • TZ types 1, 2, 3 	
Normal colposcopic findings		Original squamous epithelium: <ul style="list-style-type: none"> • Mature • Atrophic Columnar epithelium <ul style="list-style-type: none"> • Ectopy Metaplastic squamous epithelium <ul style="list-style-type: none"> • Nabothian cysts • Crypt (gland) openings Deciduosus in pregnancy	
Abnormal colposcopic findings	General principles	Location of the lesion: <ul style="list-style-type: none"> • Inside or outside the TZ • By clock position Size of the lesion: <ul style="list-style-type: none"> • Number of cervical quadrants the lesion covers • Size as percentage of cervix 	
	Grade 1 (minor)	Thin acetowhite epithelium Irregular, geographic border	Fine mosaic, Fine punctation
	Grade 2 (major)	Dense acetowhite epithelium, rapid appearance of acetowhitening, cuffed crypt (gland) openings	Coarse mosaic, coarse punctation, sharp border, inner border sign, ridge sign
	Nonspecific	Leukoplakia (keratosis, hyperkeratosis), erosion, Lugol's staining (Schiller's test): stained/nonstained	
Suspicious for invasion		Atypical vessels Additional signs: Fragile vessels, irregular surface, exophytic lesion, necrosis, ulceration (necrotic), tumor/gross neoplasm	
Miscellaneous findings		Congenital TZ, condyloma, polyp (ectocervical/ endocervical), inflammation	Stenosis, congenital anomaly, post-treatment consequence, endometriosis

Abbreviations: SCJ, squamocolumnar junction; TZ, transformation zone.

Table 7.2 International Federation for Cervical Pathology and Colposcopy definitions of excision types and dimensions of cone specimens⁷

Excision treatment types	
Type 1	Resection of a completely ectocervical or type 1 TZ
Type 2	Resection of a type 2 TZ (small amount of endocervical epithelium visible with a colposcope)
Type 3	Resection of a type 3 TZ (longer and larger amount of tissue than type 1 or type 2 excisions, with a significant amount of endocervical epithelium)
Excision specimen dimensions	Length: distance from the distal or external margin to the proximal or internal margin Thickness: distance from the stromal margin to the surface of the excised specimen Circumference (optional): perimeter of the excised specimen

Abbreviation: TZ, transformation zone.

Table 7.3 2011 International Federation for Cervical Pathology and Colposcopy clinical/colposcopic terminology of the vagina⁷

General assessment	Adequate/inadequate for the reason (e.g. inflammation, bleeding, scar)	
Normal colposcopic findings	Squamous epithelium: • Mature • Atrophic	
Abnormal colposcopic findings	General principles	Upper 1/3 /lower 2/3, anterior/posterior/lateral (right or left),
	Grade 1 (minor)	Thin acetowhite epithelium, fine punctation fine mosaic
	Grade 2 (major)	Dense acetowhite epithelium, coarse punctation coarse mosaic
	Suspicious for invasion	Atypical vessels Additional signs: Fragile vessels, Irregular surface, exophytic lesion, necrosis, ulceration (necrotic), tumor/gross neoplasm
	Nonspecific	Columnar epithelium (adenosis); Lesion staining by Lugol's solution (Schiller's test): stained/nonstained, leukoplakia
Miscellaneous findings		Erosion (traumatic), condyloma, polyp, cyst, endometriosis, inflammation, vaginal stenosis, congenital transformation zone

Table 7.4 2011 International Federation for Cervical Pathology and Colposcopy clinical/colposcopic terminology of the vulva (including the anus)⁶

Section	Pattern	
Basic definitions	Various structures: Urethra, Skene duct openings, clitoris, prepuce, frenulum, mons pubis, labia minora, labia majora, interlabial sulci, vestibule, vestibular duct openings, Bartholin duct openings, hymen, fourchette, perineum, anus, anal SCJ (dentate line)	Composition: Squamous epithelium: hairy/nonhairy, mucosa
Normal findings		Micropapillomatosis, sebaceous glands (Fordyce spots), vestibular redness
Abnormal findings	General principles: Size in centimeters, location	Lesion type: Macule, patch, papule, plaque nodule, cyst, vesicle, bulla, pustule Lesion color: Skin-colored, red, white, dark Secondary morphology: Eczema, lichenification, excoriation, purpura, scarring, ulcer, erosion, fissure, wart
	Abnormal colposcopic or other magnification findings	Acetowhite epithelium, punctation, atypic vessels, surface irregularities, abnormal anal SCJ (note location about dentate line)
Suspicion of malignancy	With or without white, gray, red or brown discoloration	Gross neoplasm, ulceration, necrosis, bleeding, exophytic lesion, hyperkeratosis
Miscellaneous findings		Trauma, malformation

Abbreviation: SCJ, squamocolumnar junction.

Table 7.5 Definitions of primary lesion types of the vulva⁶

Term	Definition
Macule	Small (<1.5 cm) area of color change; no elevation and no substance of palpation
Patch	Large (>1.5 cm) area of color change; no elevation and no substance of palpation
Papule	Small (<1.5 cm) elevated and palpable lesion
Plaque	Large (>1.5 cm) elevated, palpable, and flat-topped lesion
Nodule	Large (>1.5 cm) often hemispherical or poorly marginated; may be located on the surface, within or below the skin; nodules may be cystic or solid
Vesicle	Small (<1.5 cm) fluid-filled blister; the fluid is clear (blister: a compartmentalized, fluid-filled elevation of the skin or mucosa)
Bulla	A large (>1.5 cm) fluid-filled blister; the fluid is clear
Pustule	Pus-filled blister; the fluid is white or yellow

References

- [1] Hinselmann H. Einführung in die Kolposkopie [Introduction to Colposcopy]. Hamburg: Hartung, 1933
- [2] Stafil A. Report of the Committee on Terminology. New nomenclature for colposcopy. Report of the committee on terminology. *Obstet Gynecol* 1976; 48: 123–124
- [3] Stafil A, Wilbanks GD. Report of the Nomenclature Committee of the International Federation of Cervical Pathology and Colposcopy. An international terminology of colposcopy. Report of the Nomenclature Committee of the International Federation of Cervical Pathology and Colposcopy. *Obstet Gynecol* 1991; 77: 313–314
- [4] Walker PG, Dexeus S, De Palo G et al. Nomenclature Committee of the International Federation for Cervical Pathology and Colposcopy. International terminology of colposcopy: an updated report from the International Federation for Cervical Pathology and Colposcopy. *Obstet Gynecol* 2003; 101: 175–177
- [5] Di Paola G. History of the International Federation of Cervical Pathology and Colposcopy (2008). http://www.ifcpc.org/About_IFCPC/index.asp
- [6] Bornstein J, Sideri M, Tatti S, Walker P, Prendiville W, Haefner HK. Nomenclature Committee of International Federation for Cervical Pathology and Colposcopy. 2011 Terminology of the vulva of the International Federation for Cervical Pathology and Colposcopy. *J Low Genit Tract Dis* 2012; 16: 290–295
- [7] Bornstein J, Bentley J, Bösze P et al. 2011 colposcopic terminology of the International Federation for Cervical Pathology and Colposcopy. *Obstet Gynecol* 2012; 120: 166–172

Chapter 8

Colposcopic Morphology

8.1 Normal Colposcopic Appearances	78
8.2 Abnormal Colposcopic Findings	90
8.3 Miscellaneous Colposcopic Findings	110
8.4 Assessment of Colposcopic Findings	125
8.5 Criteria for Differential Diagnosis	128
8.6 Combinations of Abnormalities	131



8 Colposcopic Morphology

It is important to appreciate that very similar colposcopic appearance can be produced by different biologic processes. Understanding this requires knowledge of the underlying histology. The relationship between cervical histology and pathology and colposcopic diagnosis is fundamental and reciprocal.

8.1 Normal Colposcopic Appearances

8.1.1 Original Squamous Epithelium

Like other normal superficial squamous epithelia, the native, original squamous epithelium of the uterine cervix is smooth and uninterrupted by gland openings (► Fig. 8.1). This sets it apart from normal squamous epithelium that has arisen through metaplasia. More detailed observation of a surface covered by epithelium of metaplastic origin shows gland (crypt) openings and retention cysts, which indicate that the area was originally occupied by columnar epithelium (► Fig. 8.2, ► Fig. 8.3a–c). The original squamous epithelium during the reproductive period displays a reddish color that can vary from pale to intense pink during the

various phases of the menstrual cycle. It stains deep brown with iodine, reflecting its glycogen content (► Fig. 8.3c).

The so-called portio rugata is seen especially during adolescence.¹ The cervix is dome-shaped, with a dimple-like os but can expand distally to resemble a mushroom (► Fig. 8.4). Sometimes the surface looks like a cockscomb (► Fig. 8.5a,b). This is probably an incidental finding without clinical relevance.

8.1.2 Atrophic Squamous Epithelium

After menopause, in the absence of estrogen, the squamous epithelium becomes thin and devoid of glycogen and the stromal blood supply diminishes. These changes result in a pale epithelium that can show a fine network of capillaries (► Fig. 8.6a). The epithelial thinning and loss of glycogen are patchy, resulting in a stippled appearance with iodine because of its irregular uptake (► Fig. 8.6b). In older women, the epithelium assumes a uniform light brown to yellow color as a result of complete loss of glycogen (► Fig. 8.7). The thin epithelial covering is fragile and makes the terminal vessels vulnerable to minor trauma, which can result in erosions and subepithelial hemorrhages (► Fig. 8.8).

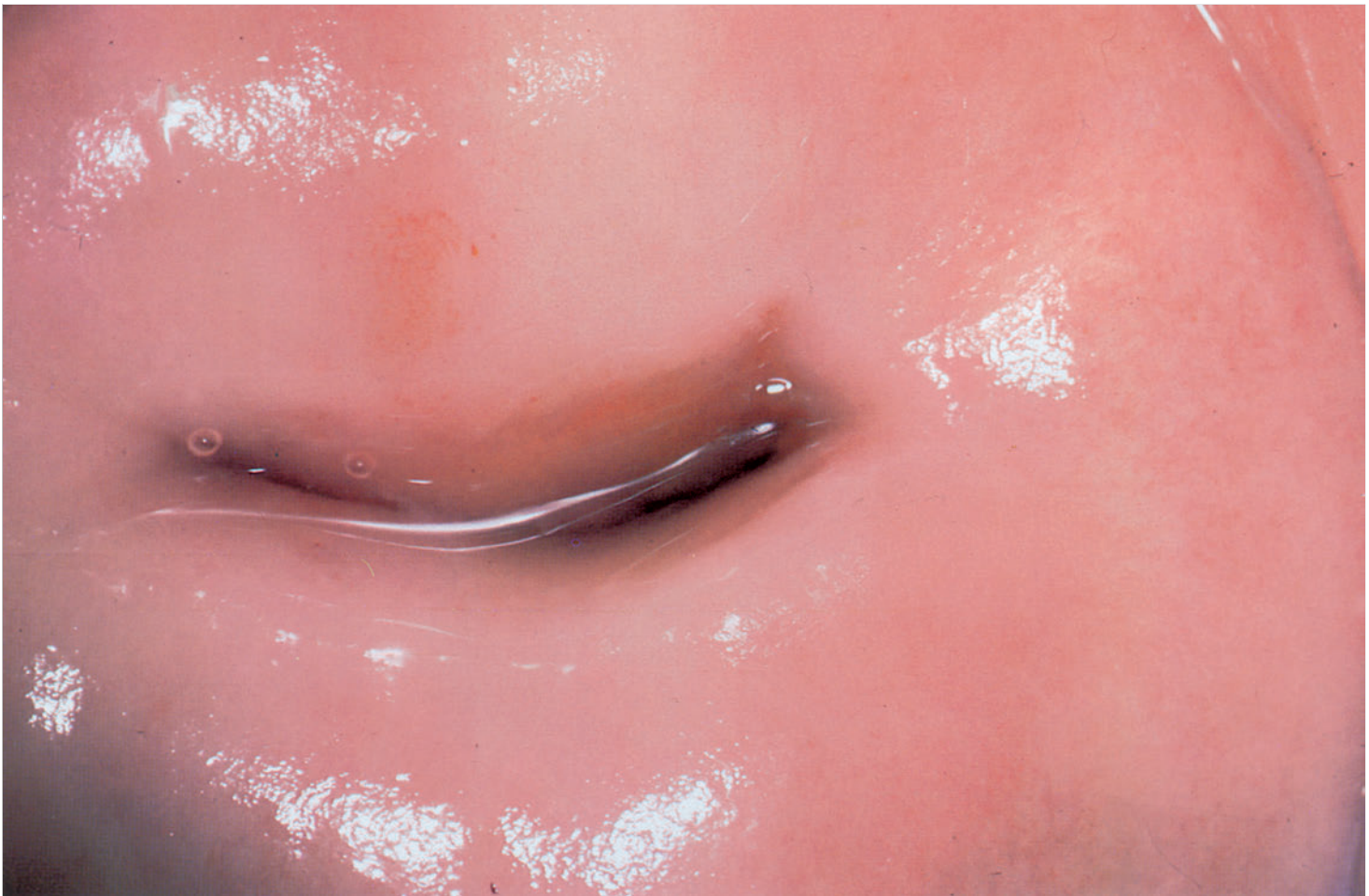

Fig. 8.1 Original squamous epithelium in a woman of reproductive age. The surface is completely smooth and displays a fresh reddish color.

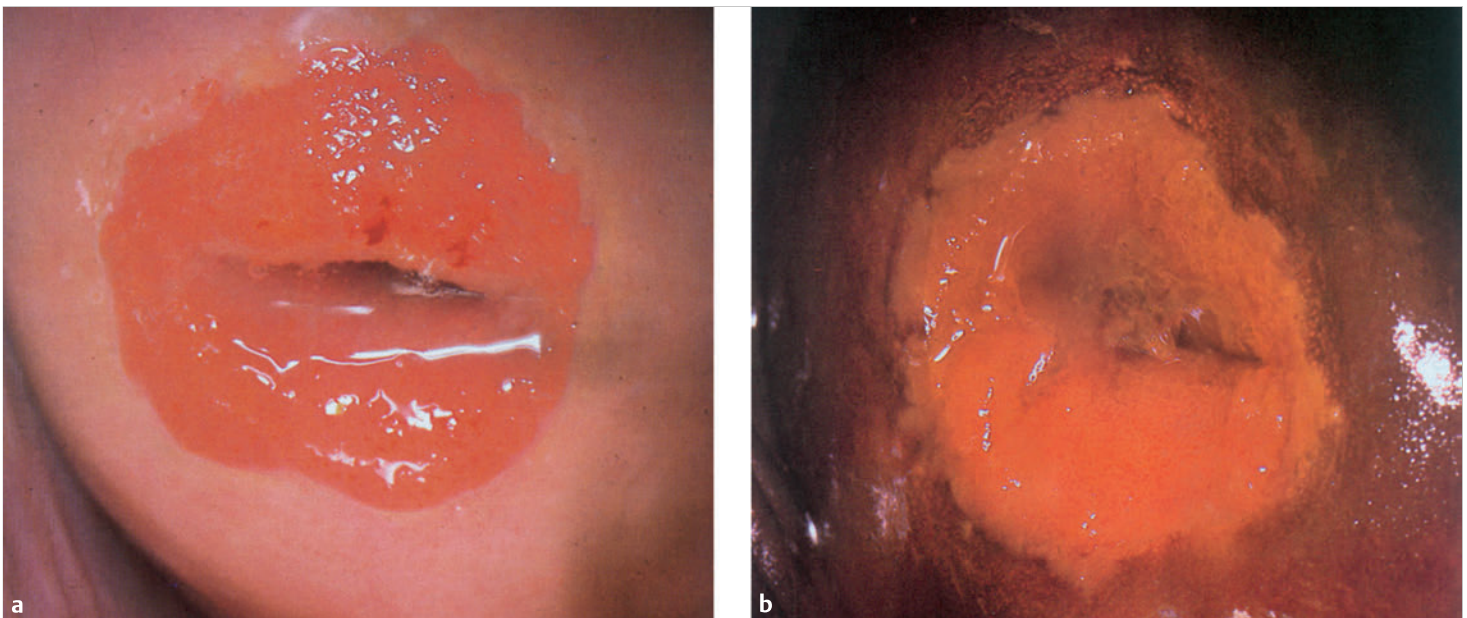


Fig. 8.2 (a) Ectopy before application of acetic acid. The gland openings at the 10 o'clock position indicate earlier transformation. (b) After application of iodine. The columnar epithelium does not stain; it is merely discolored by the thin film covering it. The demarcation from the deep brown original squamous epithelium is indistinct.

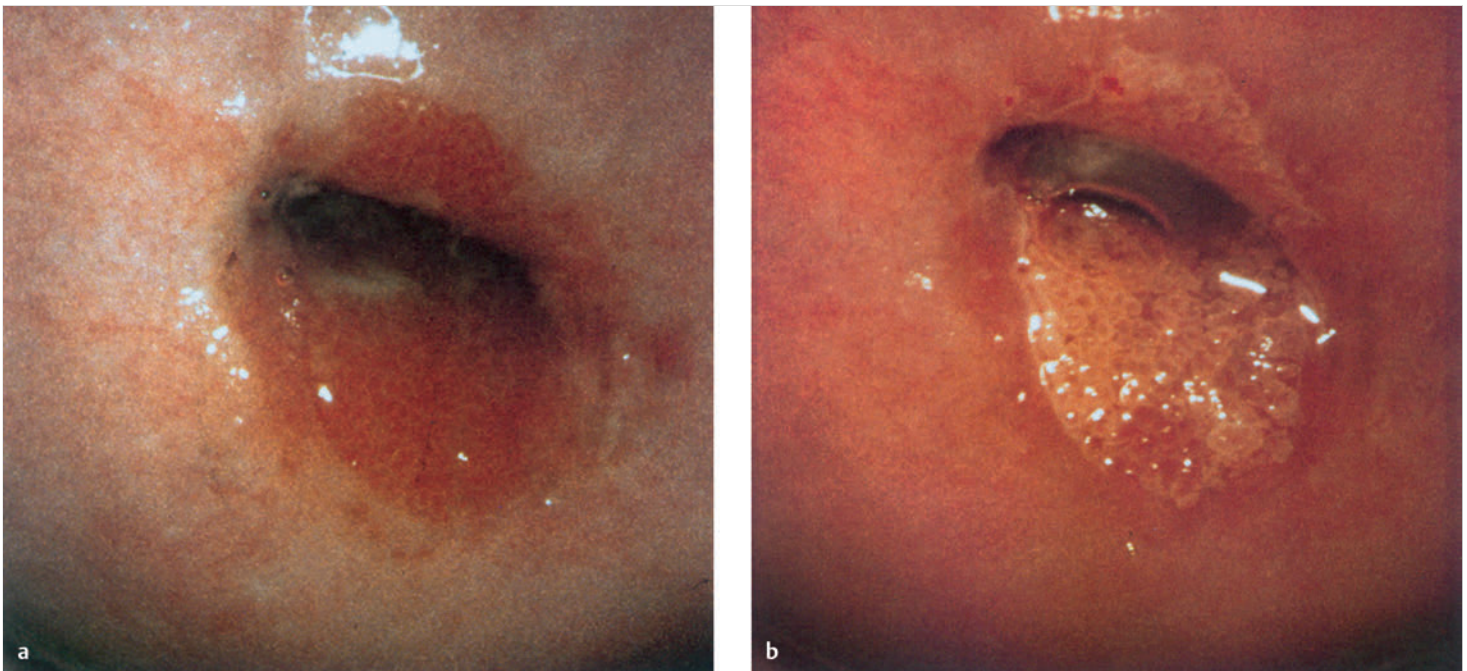


Fig. 8.3 Small red area on the anterior and posterior lip of the external os. (a) Before application of acetic acid. (b) After application of 3% acetic acid. (c) After application of iodine. The columnar epithelium does not stain. The transformation zone at the margins is identifiable by the incomplete staining of the new squamous cell epithelium.

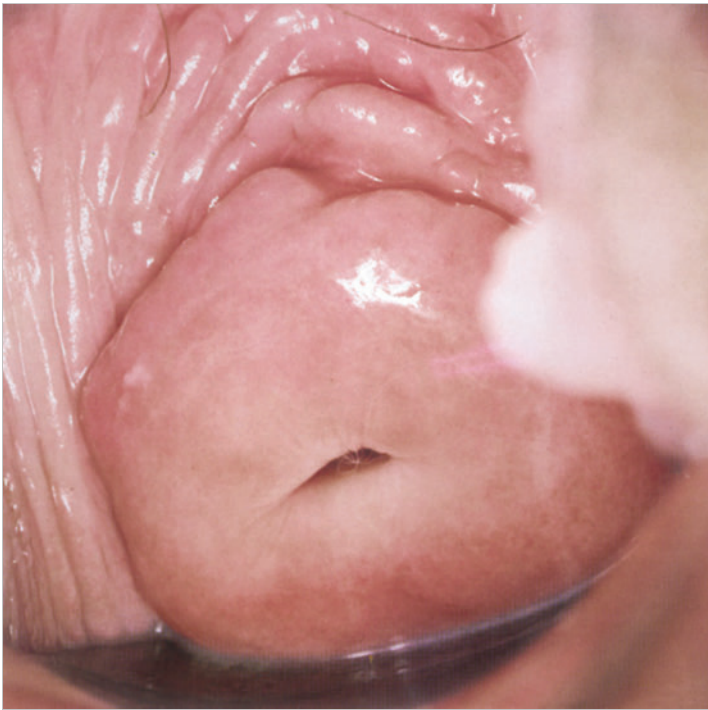

Fig. 8.4 The portio rugata in a 29-year-old woman. Squamocolumnar junction not visible (type III transformation zone) (Courtesy of O. Baader)

8.1.3 Ectopy (Columnar Epithelium)

Ideally the original squamocolumnar junction (SCJ) is situated at the external os. Depending on the size, shape, and patulousness of the external os, varying portions of the canal may be visible. In patulous cervixes, the architecture of endocervical mucosa can be seen clearly (► Fig. 8.9).

In adolescents and young women, the columnar epithelium is frequently situated on the ectocervix at some distance from the external os. This is referred to as *ectopy*. In cases of marked eversion of the endocervical mucosa, its rugose architecture becomes evident (► Fig. 8.10, ► Fig. 8.11, and ► Fig. 8.12a,b).

Ectopy appears classically as a “red patch” (► Fig. 8.2a). Grossly it may look suspicious to the inexperienced examiner. More detailed colposcopic examination shows its unique papillary architecture, which identifies its real nature. Ectopy does not stain with iodine (► Fig. 8.2b).

Ectopy is usually covered by mucus secreted by the columnar epithelium. Acetic acid helps to remove the mucus (see Chapter 5), revealing the distinctive papillary structure. Acetic acid also causes the tissue to swell, throwing the mucosal architecture

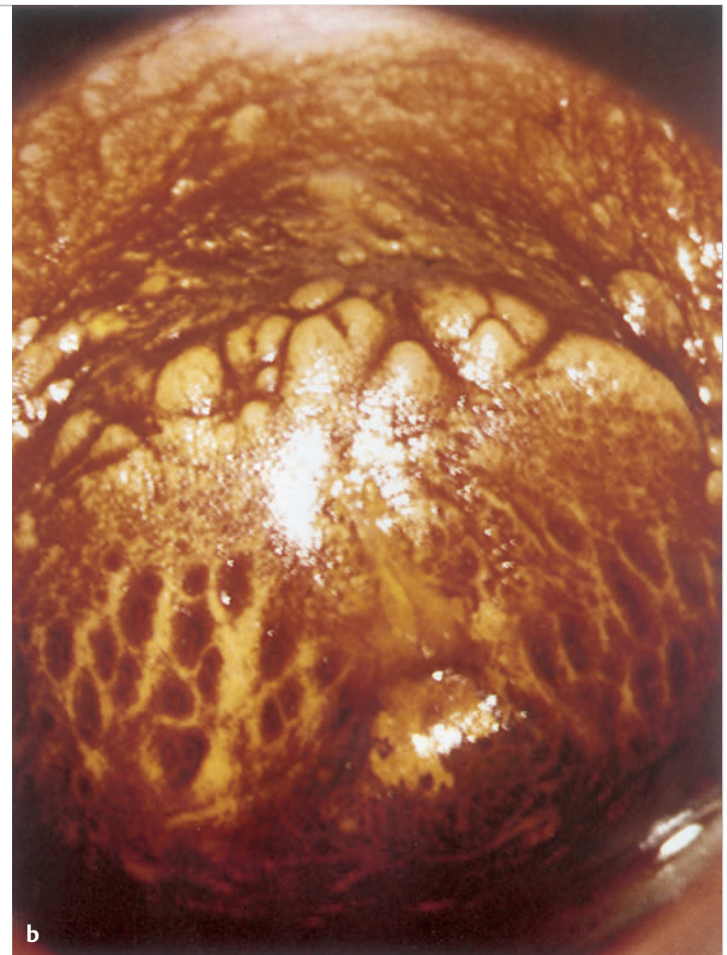
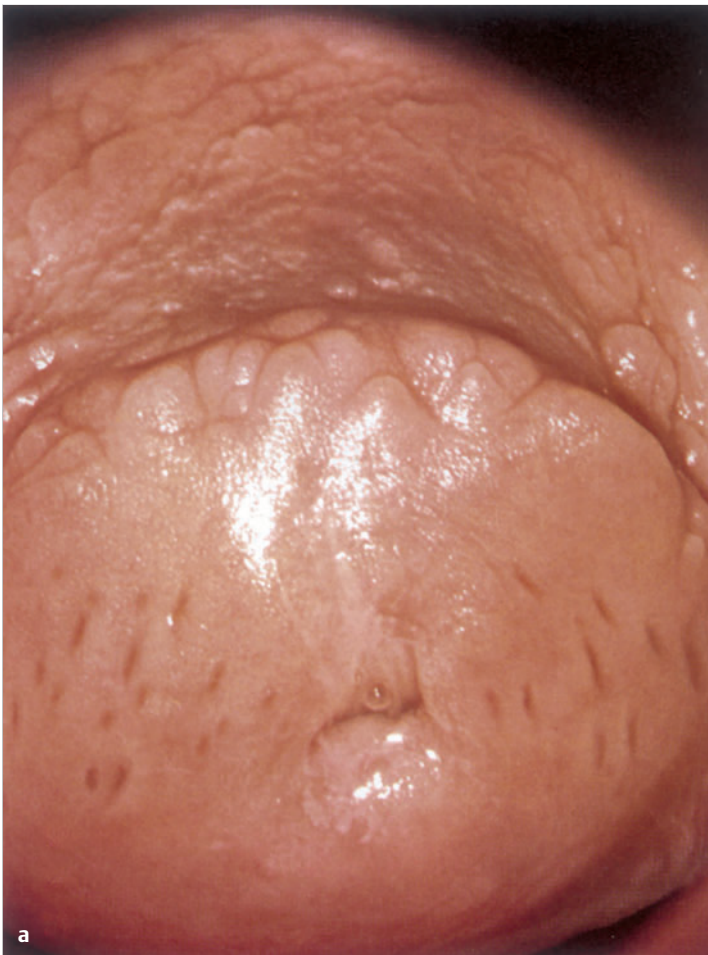


Fig. 8.5 (a) Original squamous epithelium. Cockscomb-like lesion on the anterior lip and fornix in a 17-year-old girl. The polypoid contour around the external os is suggested only by the shallow notches. **(b)** Surprising stippling effect of iodine. Only the posterior lip shows typical uniform mahogany-brown staining. (Courtesy of O. Baader)

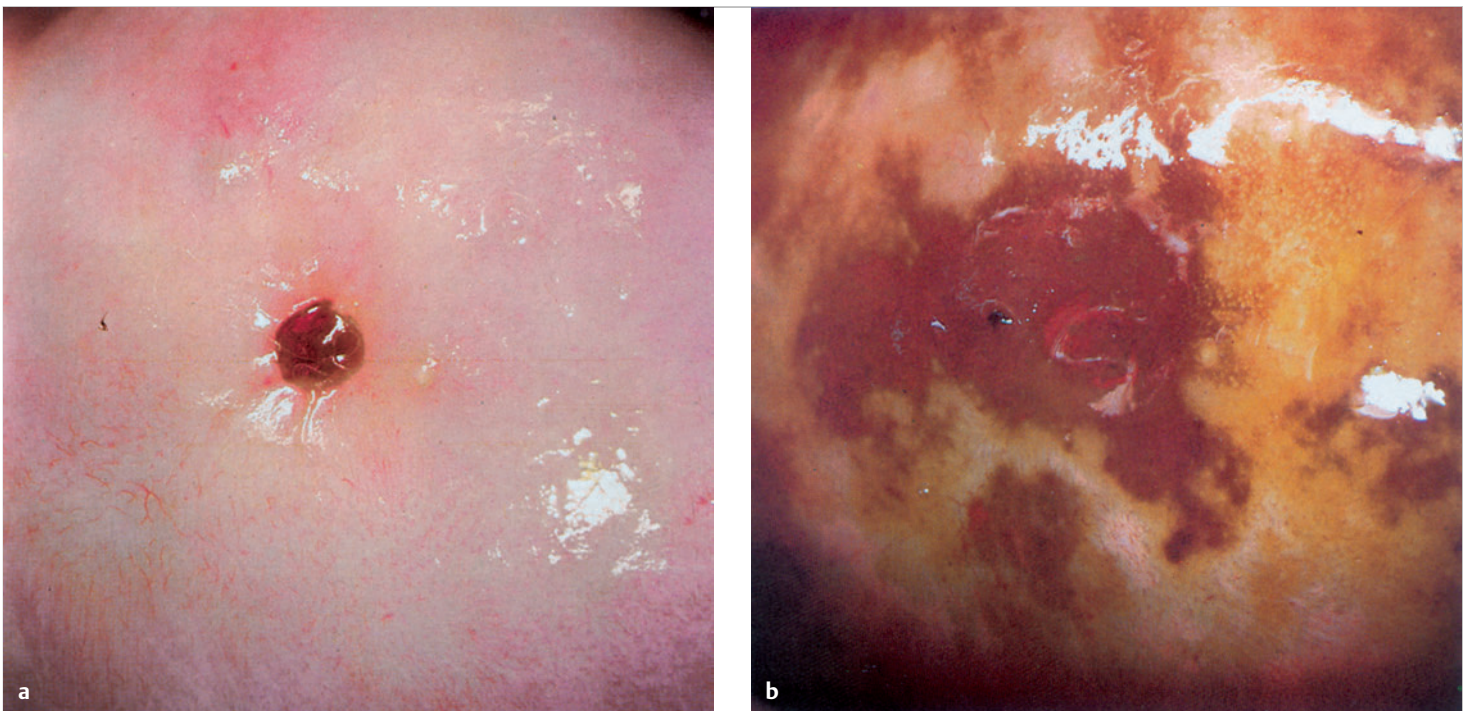


Fig. 8.6 (a) Atrophic squamous epithelium in a postmenopausal woman. Fine blood vessels shine through the thin epithelium, which appears pale pink to yellowish. (b) The same cervix after application of iodine. The characteristic stippled appearance is due to focal glycogen retention.

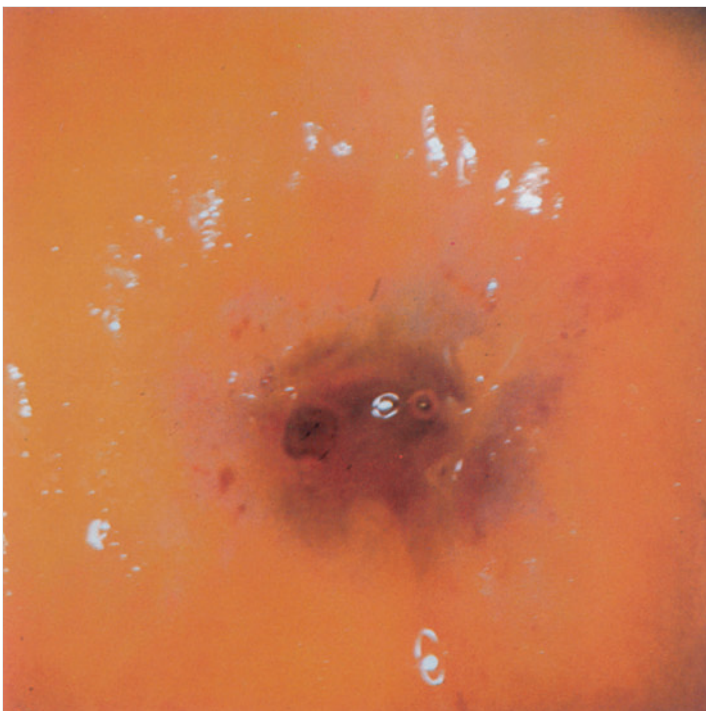


Fig. 8.7 The loss of glycogen is uniform in the atrophic epithelium of an older woman, resulting in homogeneous yellow staining with iodine.

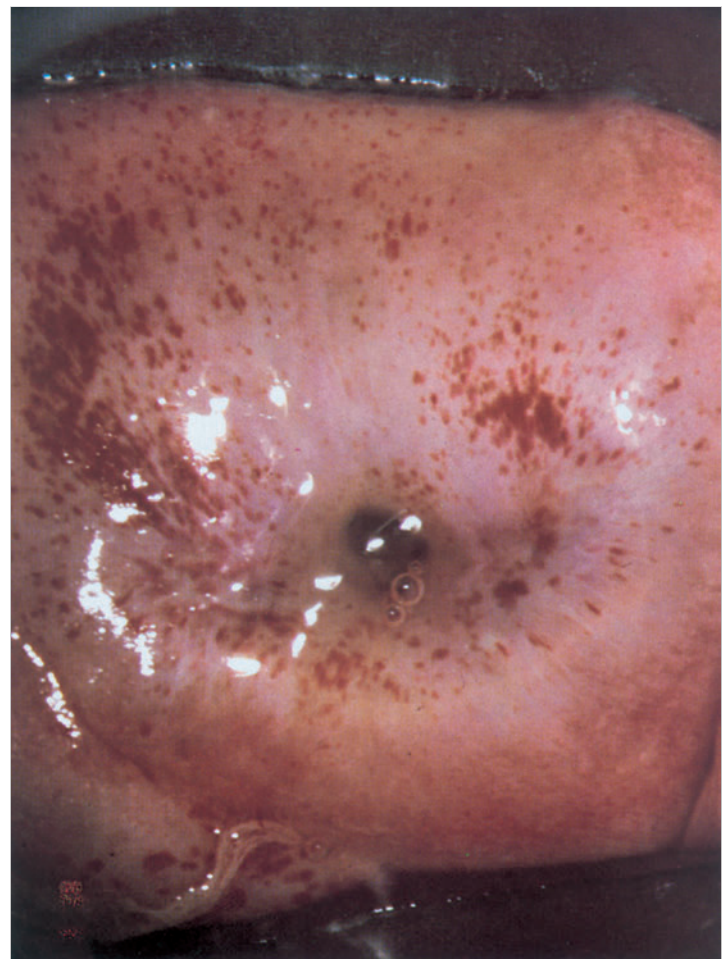


Fig. 8.8 With advancing age, the squamous epithelium becomes fragile. Subepithelial hemorrhages may appear during vaginal examination. Note the fine vessels that run toward the os.

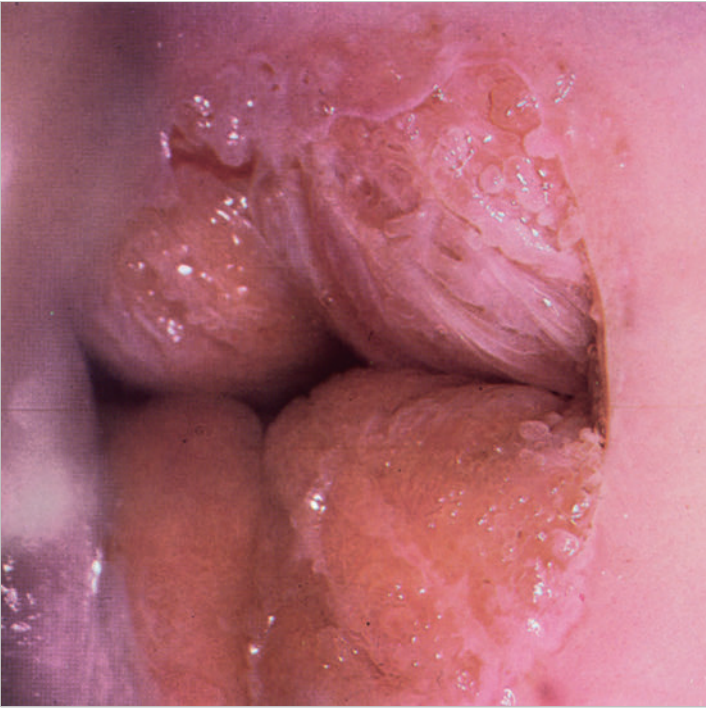

Fig. 8.9 The original squamocolumnar junction of this gaping cervix is most distinct. The anterior lip displays a thin rim of transformation zone. The rugose structure of the endocervical mucosa is clearly seen.

into sharp relief and giving the papillae a grapelike appearance. The intense red of the red patch changes to pink or whitish (► Fig. 8.3, ► Fig. 8.13).

The SCJ is usually sharp and steplike (► Fig. 8.2, ► Fig. 8.9, ► Fig. 8.13). Careful inspection often reveals a slender, white margin and gland openings, which indicates the initiation of transformation (► Fig. 8.11, ► Fig. 8.3, ► Fig. 8.14). It is important to pay close attention to the margins of ectopy so as not to overlook significant colposcopic lesions.

Ectopic columnar epithelium is less resilient and more vulnerable to trauma than squamous epithelium. It is subject to contact bleeding at speculum examination (contact bleeding should also make the examiner consider the possibility of cancer). Although neoplastic papillary fronds tend to be coarse and irregular, they can be mistaken for benign changes.

The influence of exogenous and endogenous sex steroids on the transformation of the columnar epithelium has been studied longitudinally.^{2,3,4,5} (► Fig. 8.15a–d). Estrogen-containing oral contraceptives appear to have a positive and enhancing effect on ectopy, and women who discontinue contraceptives show transformation in a relatively brief time (► Fig. 8.16a,b).⁵

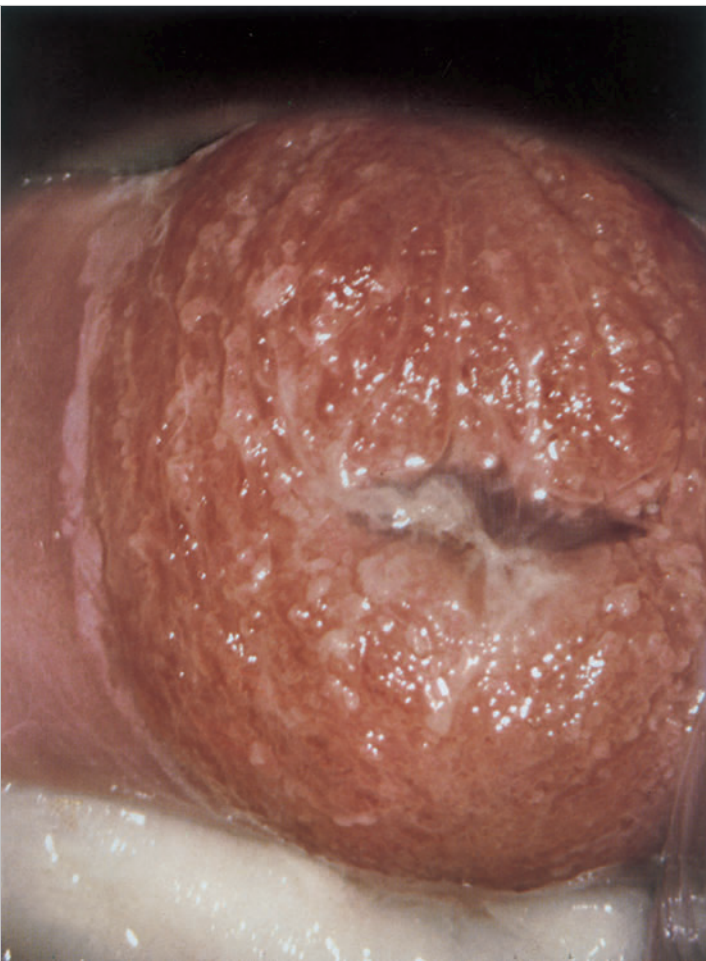


Fig. 8.10 Eversion of the endocervical mucosa (ectopy), with its rugose architecture thrown into sharp relief.

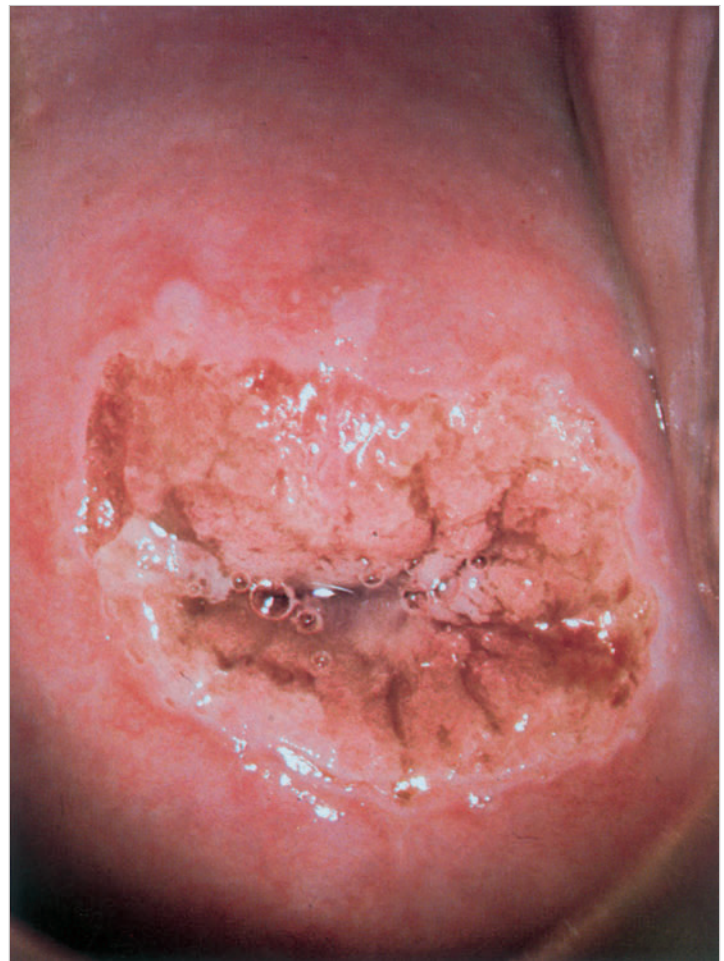

Fig. 8.11 Apparent eversion (ectopy) of a cervix with a patulous os resulting from wide separation of the speculum. A thin rim of transformation zone is visible near the junction with the original squamous epithelium.

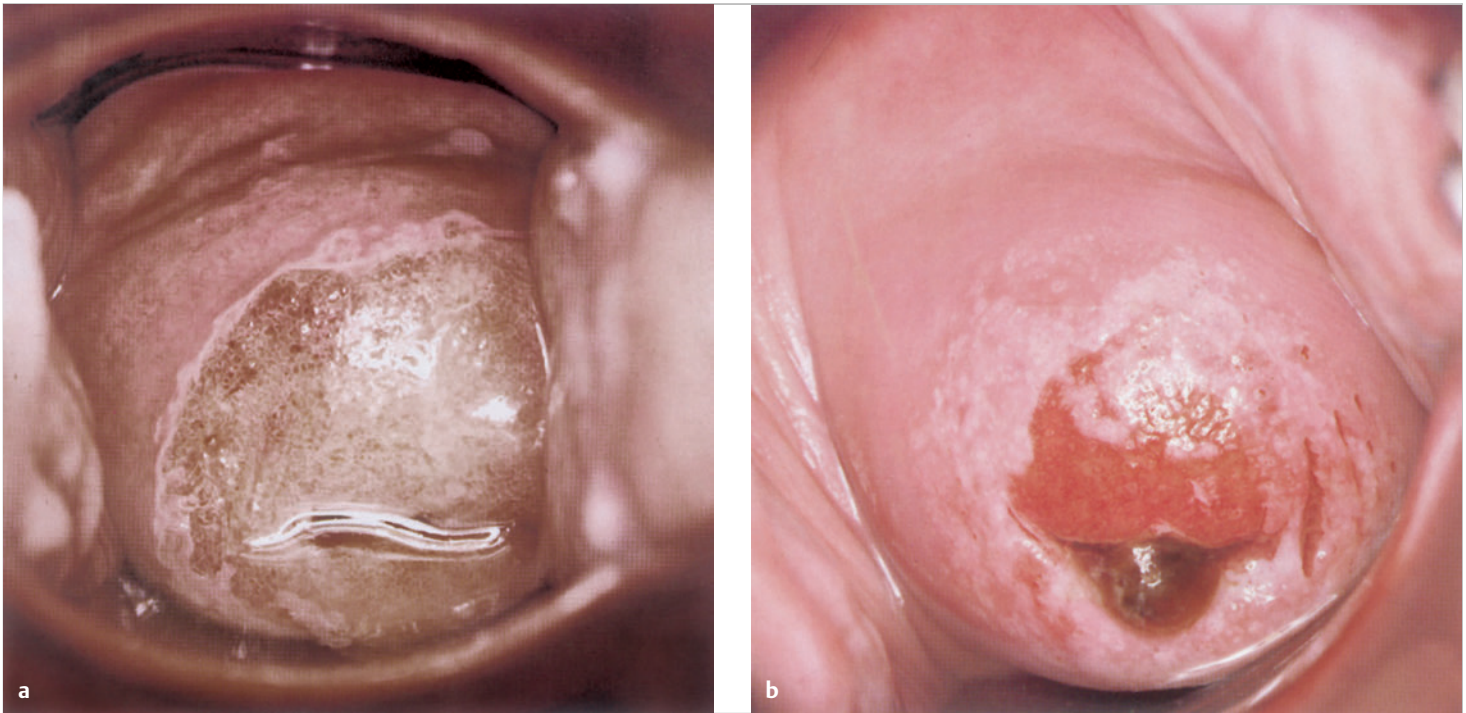


Fig. 8.12 (a) Ectopy with a thin rim of transformation zone (TZ) in a 14-year-old. (b) After 2 years, the transformation is more advanced. Squamocolumnar junction fully visible (type 1 TZ). (Courtesy of O. Baader.)

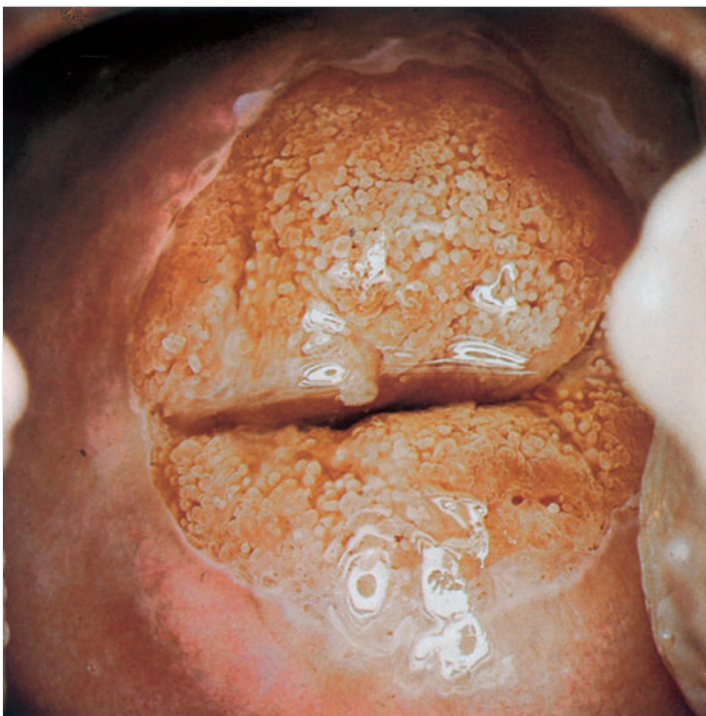


Fig. 8.13 Typical appearance of ectopy after application of acetic acid. The grapelike structure is unmistakable. Note the whitish rim of transformation zone at the periphery.

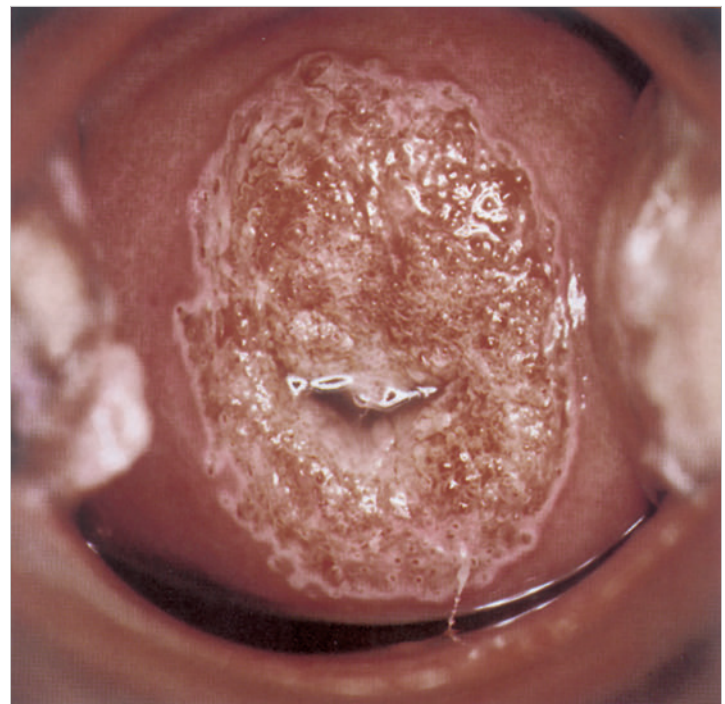


Fig. 8.14 Ectopy with a slim margin of transformation at the periphery in a 29-year-old nullipara (type 1 transformation zone). (Courtesy of O. Baader)

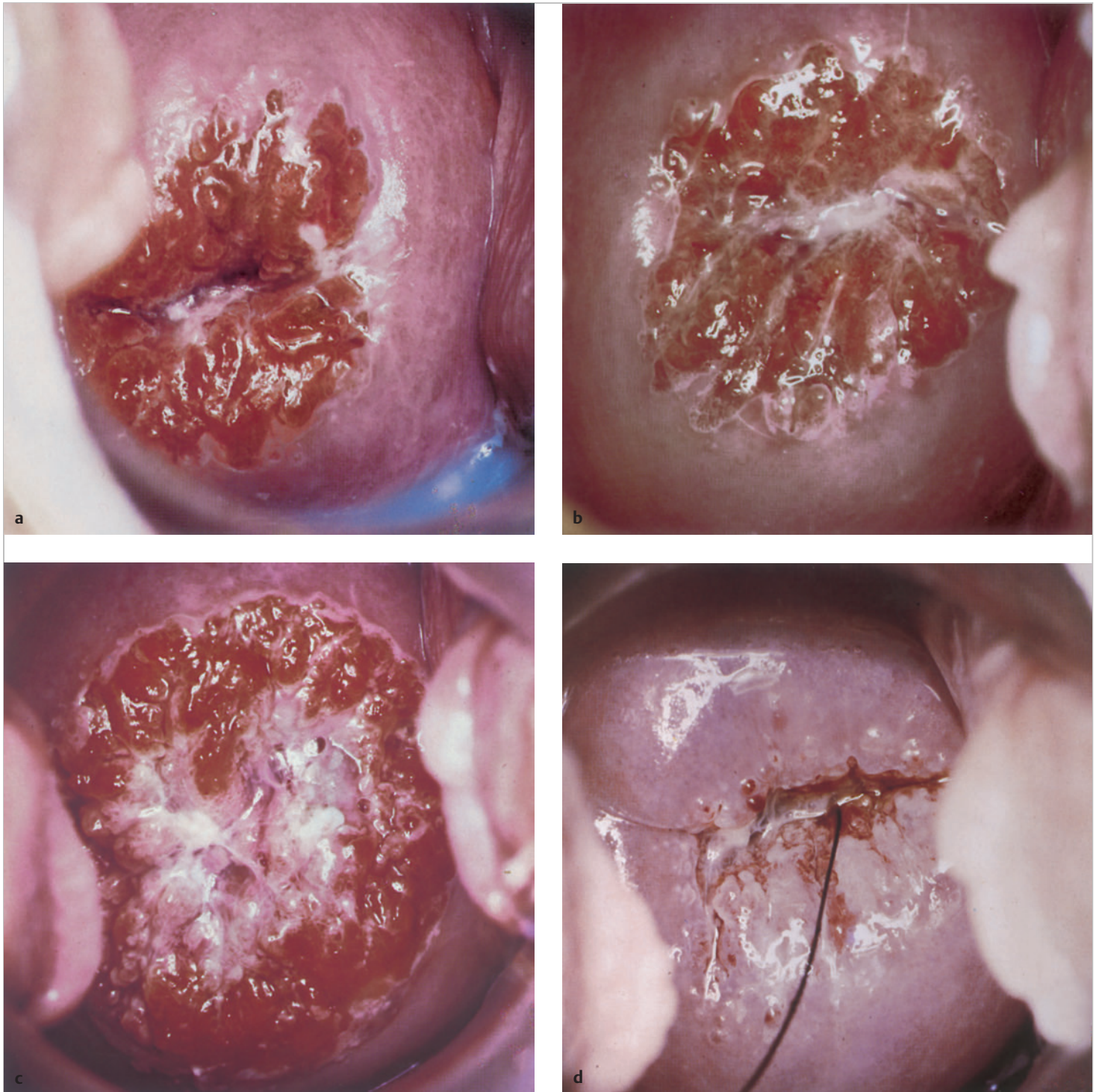


Fig. 8.15 Longitudinal follow-up of a 20-year-old woman beginning oral contraception (OC). (a) Before starting OC there is ectopy with a slim margin of transformation (type 1 transformation zone [TZ]). (b) After several months of OC, the ectopy has assumed a strongly coarse papillary appearance. (c) At this point the woman has resumed OC after a vaginal delivery. The ectopy is again apparent. (d) The woman received an intrauterine contraceptive device 9 months later and discontinued OC. Three months later the ectopy has been rapidly transformed (type 1 TZ). (Courtesy of O. Baader)

8.1.4 Transformation Zone

The transformation zone (TZ) can appear as a nonspecific red area. Sometimes there is a fine vascular pattern (► Fig. 8.17a). Application of acetic acid turns the previously red epithelium grayish white. Within the TZ are openings of cervical glands (crypts) and small islands of residual columnar epithelium. The demarcation from the original squamous epithelium is indistinct (► Fig. 8.17b).

The process of transformation characteristically begins at the SCJ. The flat epithelial margin around the periphery of an ectopy can be distinguished from the original squamous as well as columnar epithelium by its variable color and by the presence of gland openings (► Fig. 8.2, ► Fig. 8.6, ► Fig. 8.18, ► Fig. 8.19, ► Fig. 8.20).

Pari passu with peripheral transformation of an ectopy, the surface contour of its central portion undergoes changes. The papillae become coarse and fused, resulting in only slight

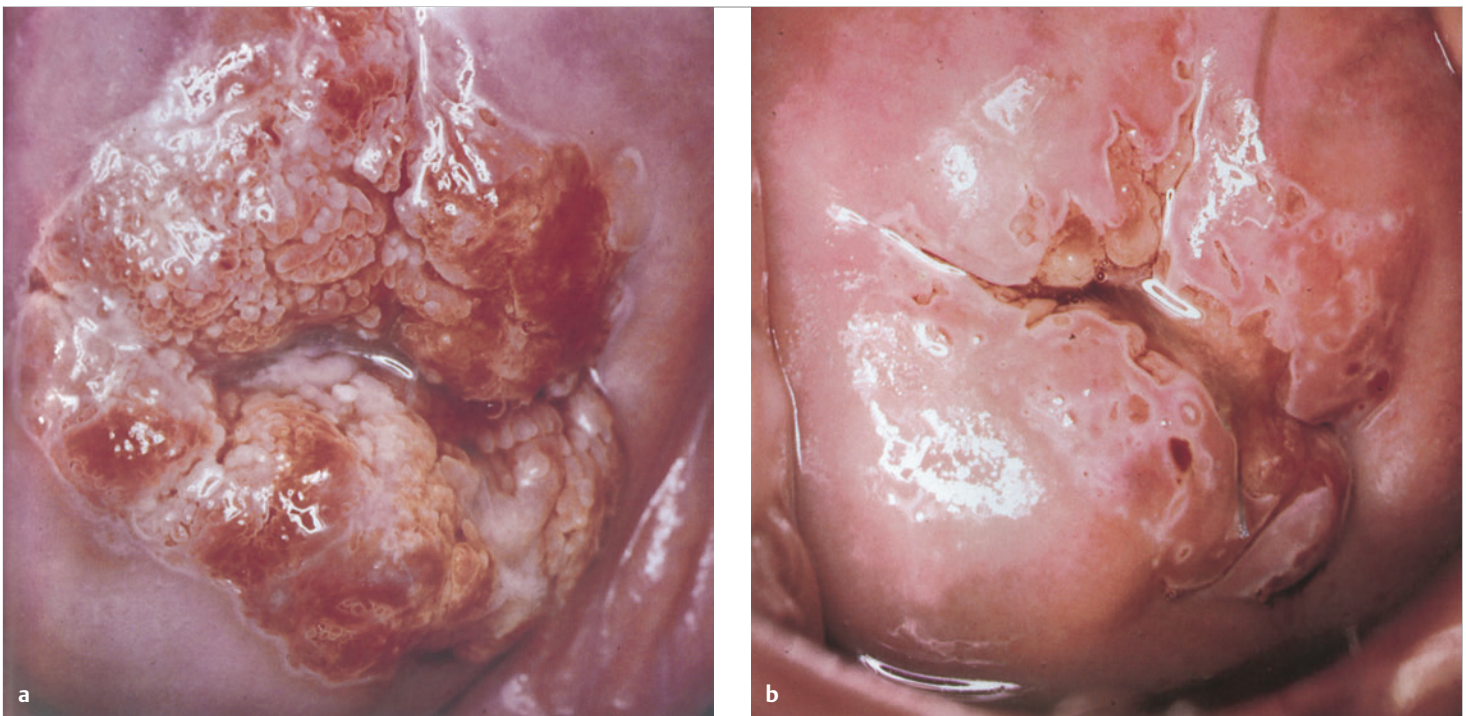


Fig. 8.16 Transformation of marked ectopy with discontinuation of oral contraception (OC). **(a)** Marked ectopy with coarse papillae in a woman with 4 years of OC. **(b)** Only 1 year after discontinued OC (and intrauterine device insertion), there is advanced transformation of the ectopy (type 1 TZ). (Courtesy of O. Baader)

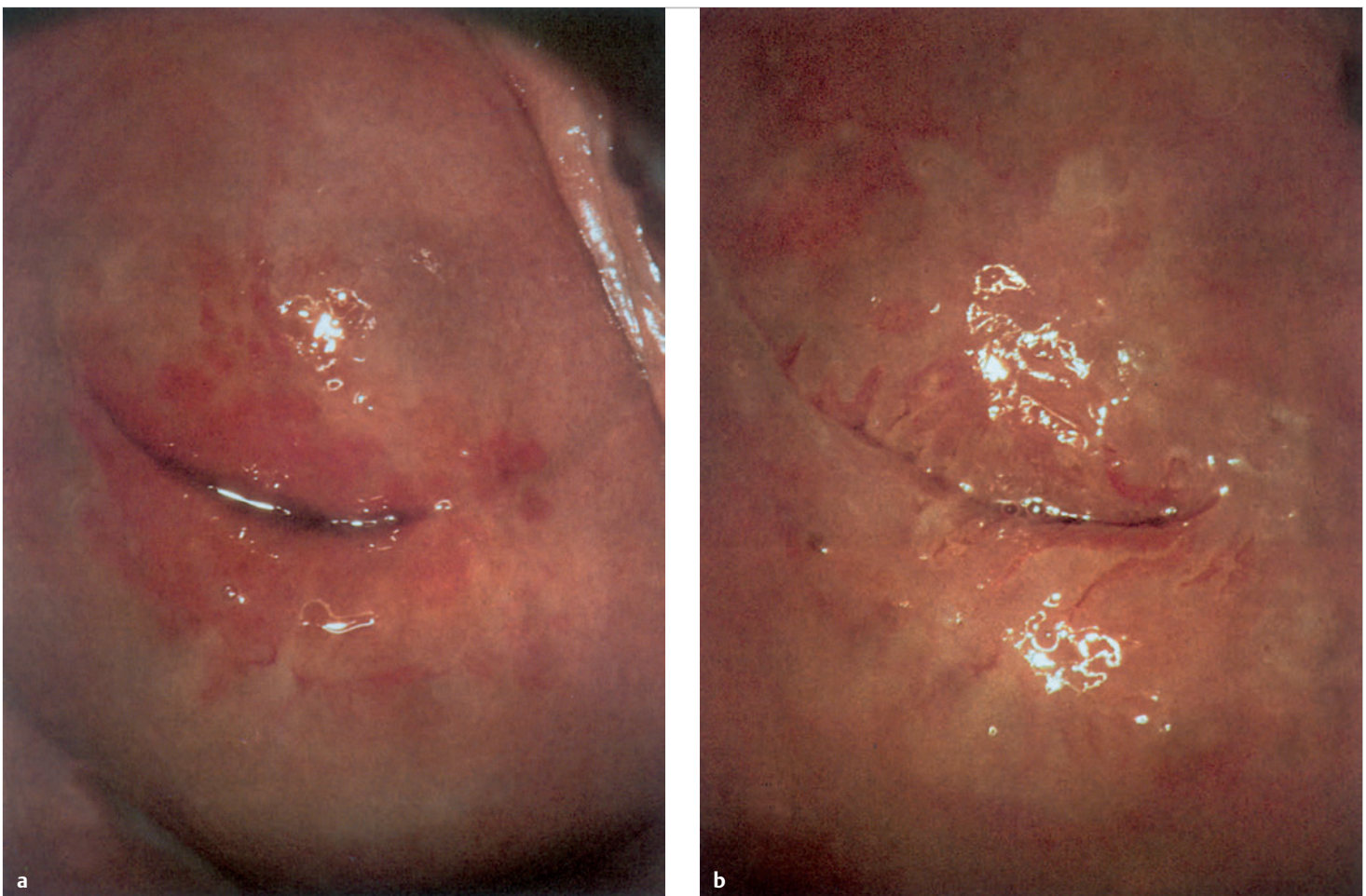


Fig. 8.17 **(a)** Transformation zone (TZ) before the application of acetic acid. There are small, unremarkable vessels at the edge of the reddish area on the posterior lip of the cervix. **(b)** After application of acetic acid, the previously reddish epithelium is grayish white. Gland openings and small islands of residual columnar epithelium are signs of the TZ.

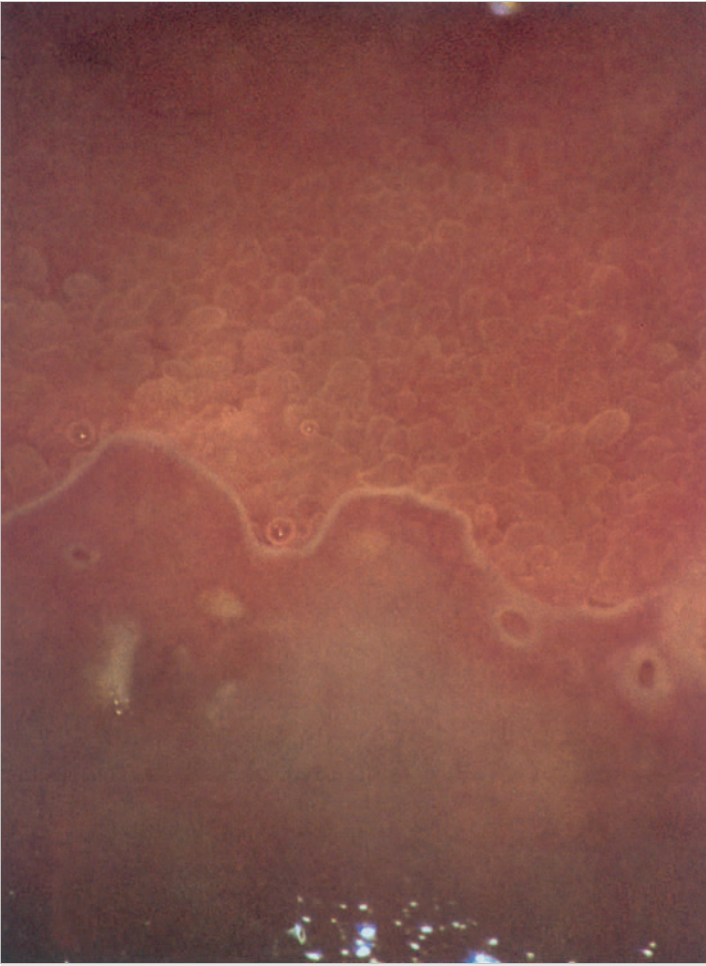


Fig. 8.18 Steplike border between the grapelike structure of the glandular epithelium (ectopy) and the squamous epithelium of the transformation zone. Note the gland openings at the periphery of the squamous epithelium, indicating completed transformation at the edge of the previously larger ectopic area.

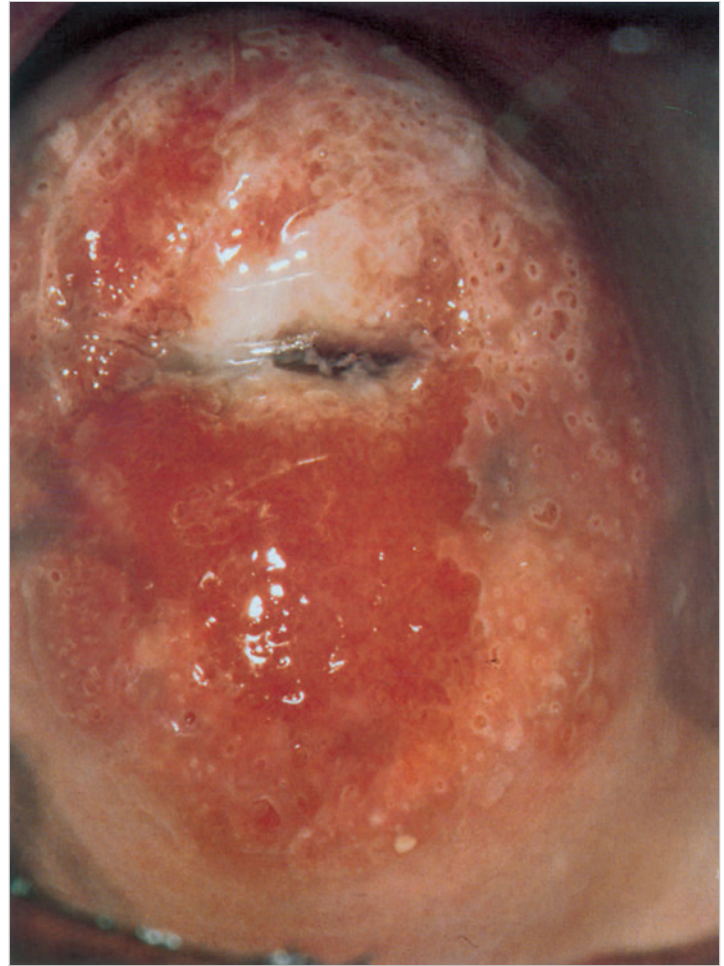

Fig. 8.19 Transformation zone. Here, too, the process begins peripherally and spreads toward the center in an irregular manner. Note the smooth surface in spite of the incomplete transformation. There are numerous gland openings.

fissuring of the surface. These changes signify the initiation of squamous metaplasia. Fields of metaplastic epithelium within a TZ may vary widely in their maturation, easily verifiable by application of iodine (the Schiller test), which is a sensitive indicator of epithelial maturity (► Fig. 8.20b).

The topographic progression of transformation can be haphazard, and its stage of development can vary markedly from one part of the periphery to another. Islands of squamous epithelium can appear in a sea of columnar epithelium; these must have arisen by metaplasia (► Fig. 8.15a–d, ► Fig. 8.16a,b, ► Fig. 8.19). The metaplastic epithelium can form tongues or finger-like processes that interdigitate with intact columnar epithelium (► Fig. 8.21). Even when most of an ectopy is fully transformed, small islands of columnar epithelium can remain; this appearance is referred to as *TZ with ectopic residuals* (► Fig. 8.22). Longi-

tudinal study of the TZ over years is particularly informative (► Fig. 8.15, ► Fig. 8.16).

The transformation of an ectopy from columnar to squamous epithelium does not always proceed to completion. Areas of the newly formed squamous epithelium can be fully mature, whereas other parts of an ectopy can remain columnar for long periods (► Fig. 8.23). The new SCJ is again situated at the external os. Squamous epithelium of metaplastic origin can be distinguished from original squamous epithelium by the presence of gland openings, more prominent vessels (► Fig. 8.24), or retention cysts (► Fig. 8.25). Undulations from numerous retention cysts (nabothian follicles), with long vessels coursing over their surface, are also characteristic (► Fig. 8.26). The vasculature in such cases is so typical that the presence of deep-seated and otherwise invisible cysts can be easily inferred (► Fig. 8.132, ► Fig. 8.133).

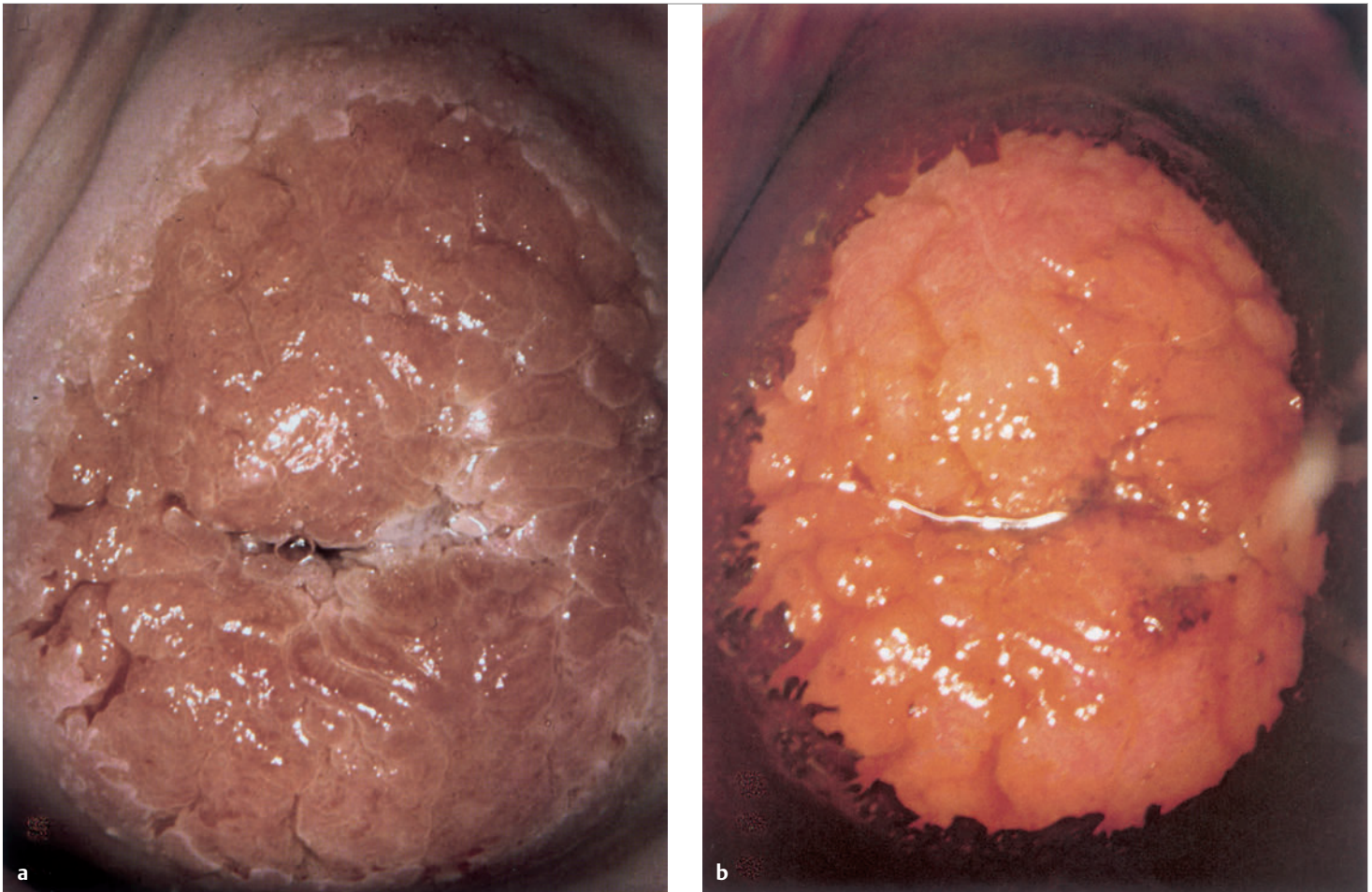


Fig. 8.20 (a) Transformation zone. Centrally, within this ectopy, the villi become plumper and fuse to eventually form a flat surface. (b) The same patient after application of iodine. The transformed epithelium is mature and contains glycogen. Gland openings are well displayed. The central part does not take up iodine, which merely covers it like a veil.

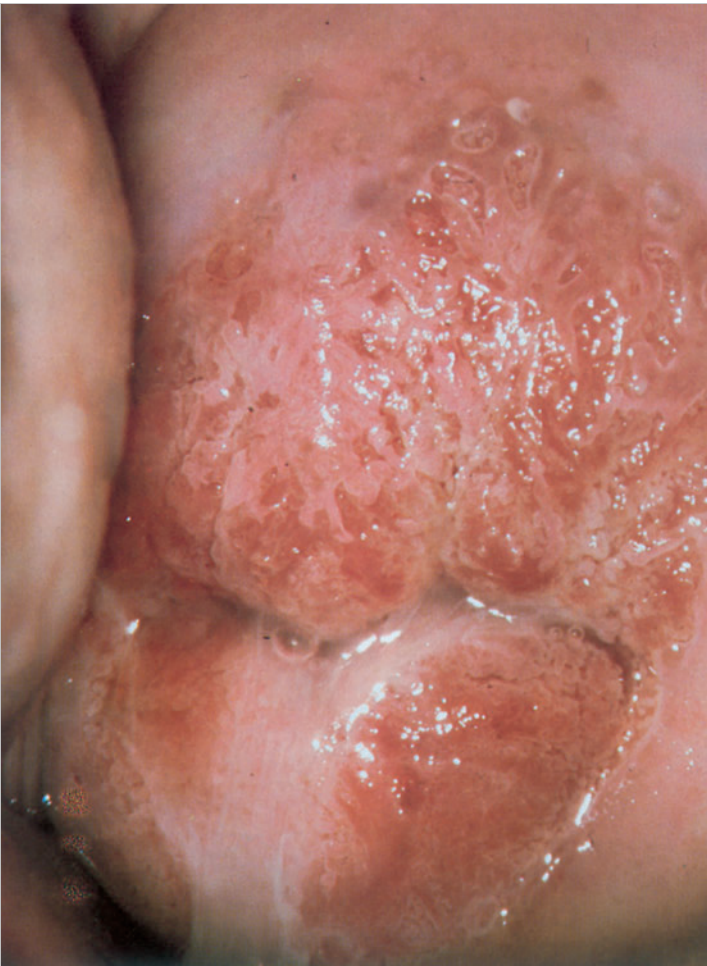


Fig. 8.21 Finger-like processes of metaplastic epithelium extend centrally from the periphery and interdigitate with islands of columnar epithelium. The transformation involves only the anterior lip.

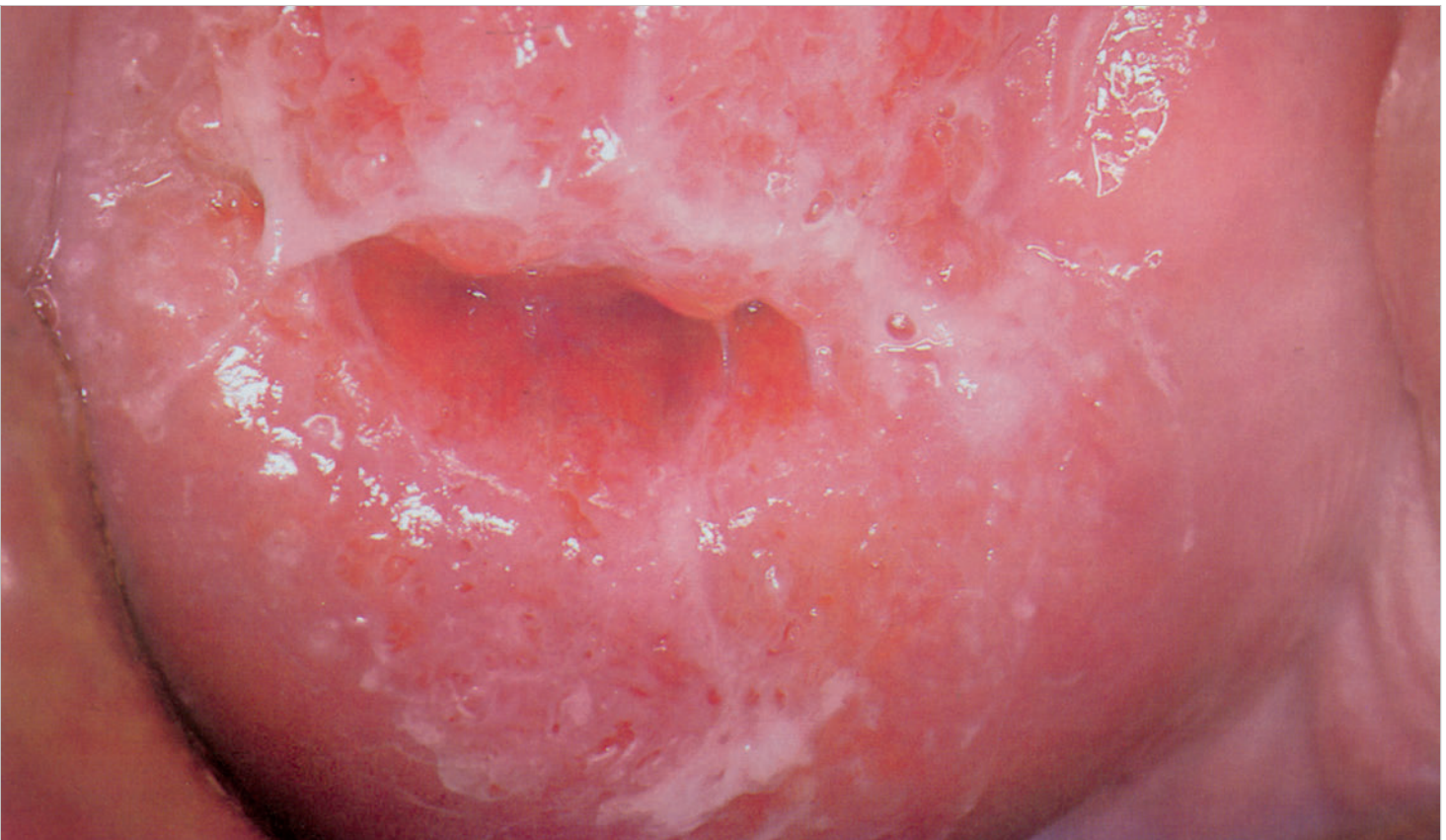

Fig. 8.22 Transformation zone with residual islands of grapelike columnar epithelium on the anterior lip.

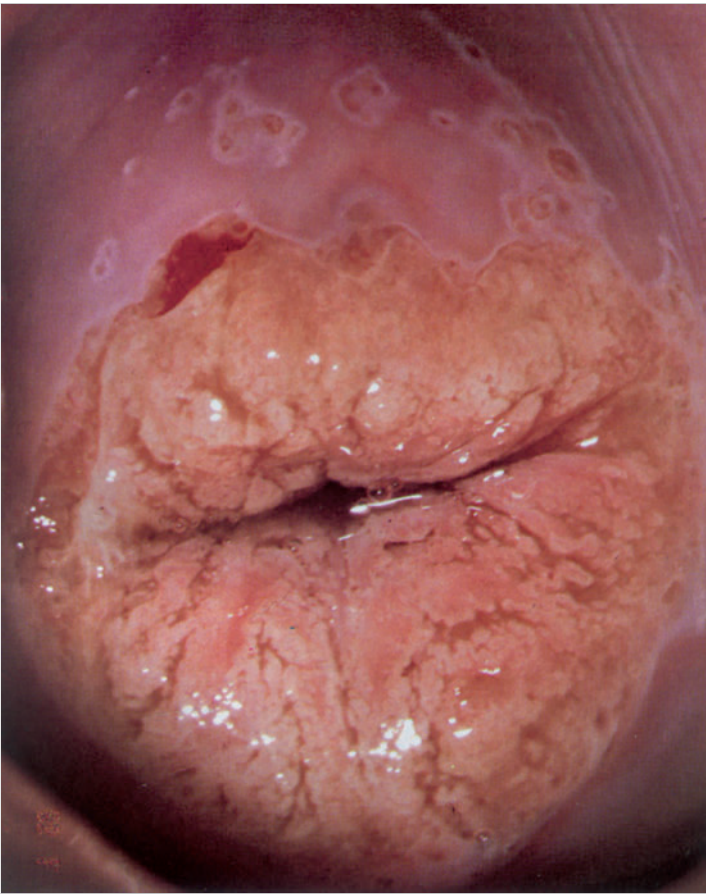

Fig. 8.23 Partial transformation. The transformation zone on the anterior lip takes up only a small portion of the ectopy, which is largely unchanged, apart from enlargement and fusion of its papillae.

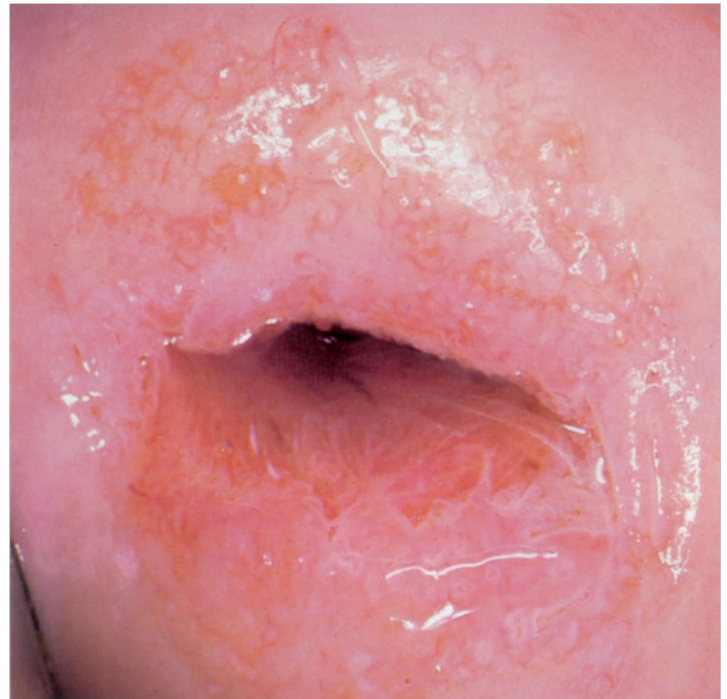

Fig. 8.24 Well-established transformation zone. Although the color of the new squamous epithelium is hardly distinguishable from that of the original, the border of the transformation is marked by fine blood vessels. The new squamocolumnar junction is abrupt.

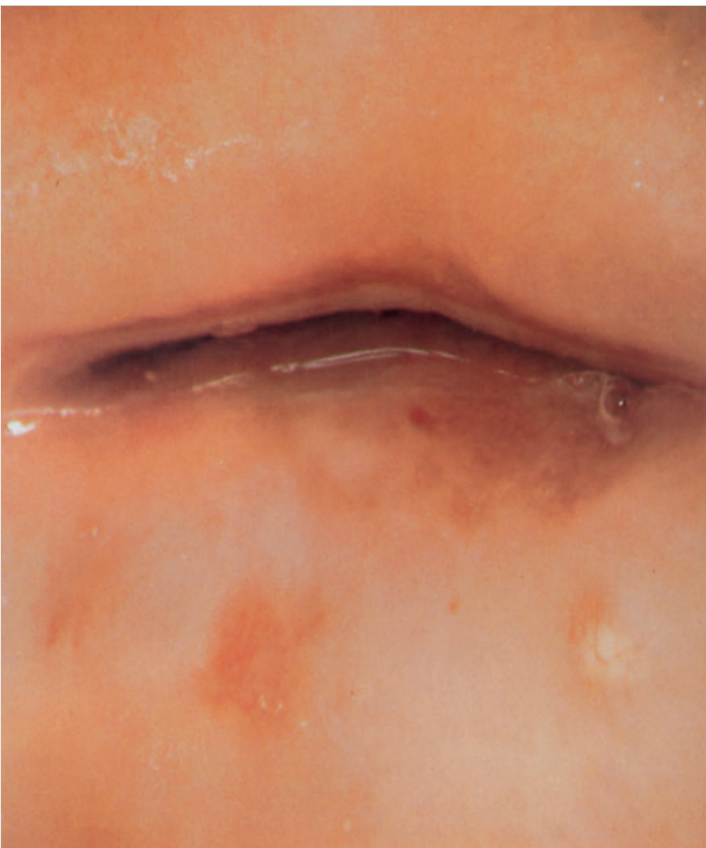

Fig. 8.25 Nabothian follicles covered by smooth squamous epithelium. They are the only indicators of earlier transformation. Blood vessels characteristically run over the surface of the retention cyst on the right.

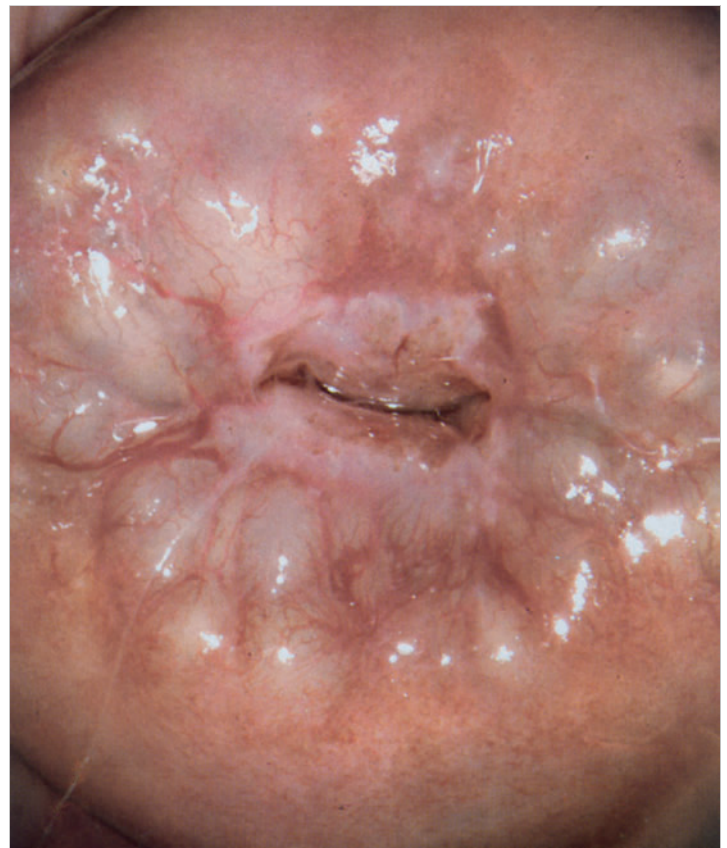

Fig. 8.26 Nabothian follicles in an established transformation zone. The long, regularly branching blood vessels that shine through the attenuated epithelium are typical.

8.2 Abnormal Colposcopic Findings

8.2.1 Acetowhite Epithelium

The 2011 International Federation for Cervical Pathology and Colposcopy nomenclature distinguishes between *thin* and *dense* acetowhite epithelium, the former being a minor change and the latter a major change.⁶ Rapid appearance of acetowhitening is also considered a major change. Acetowhite epithelium does not show mosaic, punctation, or leukoplakia. It does usually contain gland openings and even retention cysts. It usually corresponds to the normal TZ but differs from it in several important aspects. It is characterized by the hallmarks of transformation (e.g., gland openings, retention cysts, residual islands of columnar epithelium) but differs from normal in one or more of the following features⁷:

- A dull to yellow-red color before application of acetic acid
- A more pronounced color change from red to white with acetic acid application
- Cuffed gland openings
- A richer vascularity with occasional atypical vessels
- A characteristic canary yellow tinge after application of iodine, with at least part of its circumference being sharply demarcated

These criteria do not always signify the development of atypical epithelium. Transformation can also result in a metaplastic

epithelium with only slight keratinization and no elongated stromal papillae and thus will not appear colposcopically as keratosis, punctation, or mosaic. Compared with original squamous epithelium, metaplastic epithelium undergoes a more distinct color change with acetic acid, and its junction with original squamous epithelium is sharply defined (► Fig. 8.27). In spite of these differences, it is not always possible to distinguish colposcopically between metaplastic epithelium and squamous intraepithelial lesion (SIL). Even the whitish epithelium of high-grade SIL (HSIL) may be only discrete (thin acetowhite epithelium) so that it can be difficult to distinguish from a normal TZ (► Fig. 8.28).

There may be subtle hints of the presence of white epithelium before application of acetic acid. Any shade of red other than the fresh red of the normal TZ should be viewed with suspicion. Grayish red tones, which give the TZ an opaque appearance, and yellow shades, which are probably due to marked inflammatory infiltration of the stroma (► Fig. 8.29, ► Fig. 8.30a), are particularly worrisome. In such cases, acetic acid usually induces a distinct white color change and reveals sharp borders (► Fig. 8.29b, ► Fig. 8.30b). A rich vascular bed suggests unusual transformation but is not pathognomonic of epithelial atypia (► Fig. 8.31).

The best diagnostic criterion is the acetic acid test. The more marked and the more rapid the color change and the greater the swelling, the greater the likelihood of epithelial atypia (dense acetowhite epithelium; ► Fig. 8.30b, ► Fig. 8.32, ► Fig. 8.33). However, the spectrum of color changes is wide (► Fig. 8.34, ► Fig. 8.35a).

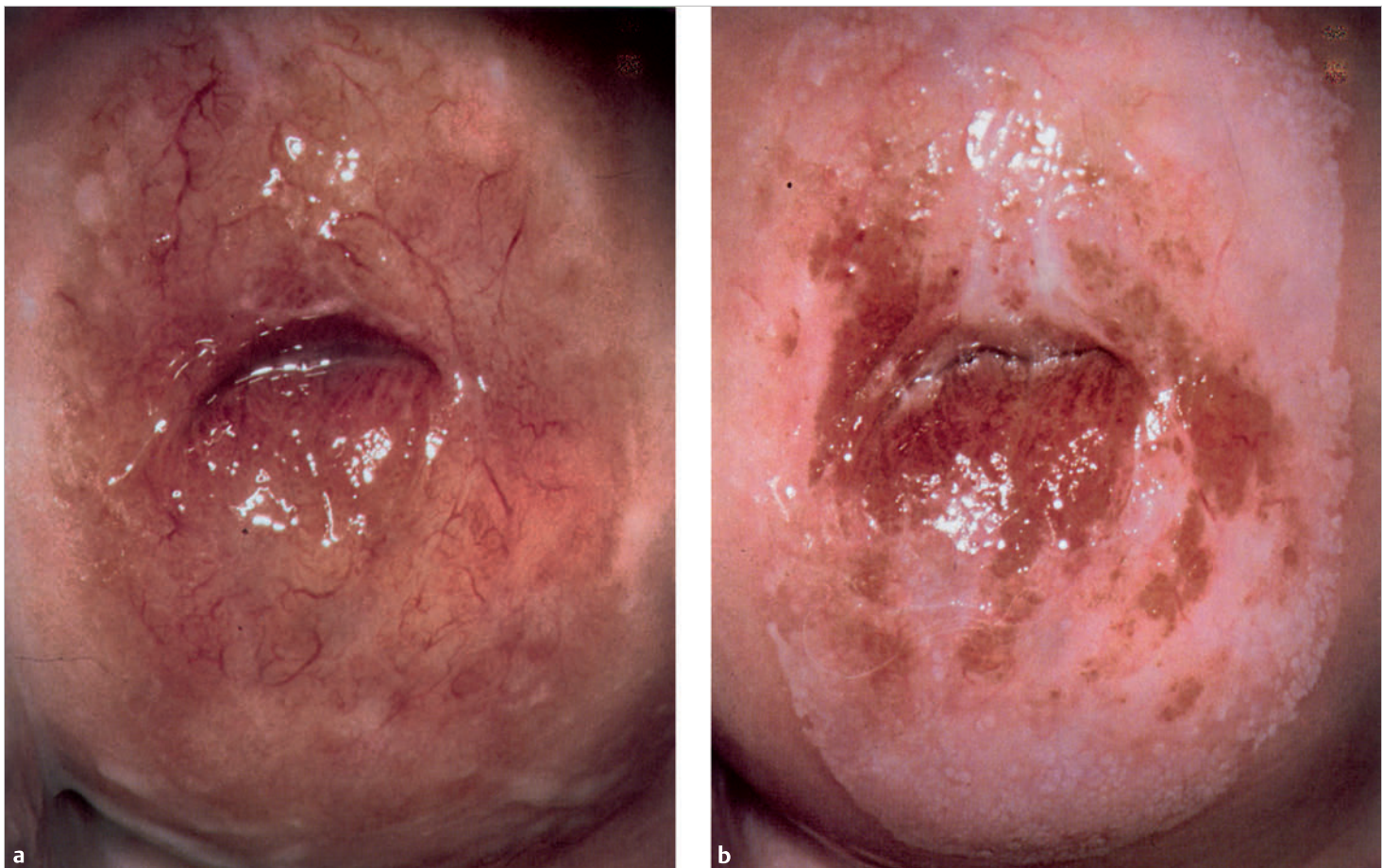


Fig. 8.27 (a) Regularly branching blood vessels in a reddish yellow, colposcopically abnormal lesion before application of acetic acid. (b) Acetic acid suppresses the vascular pattern but brings out a sharply demarcated fine mosaic with a distinct change in color tone. Histology showed metaplastic epithelium.

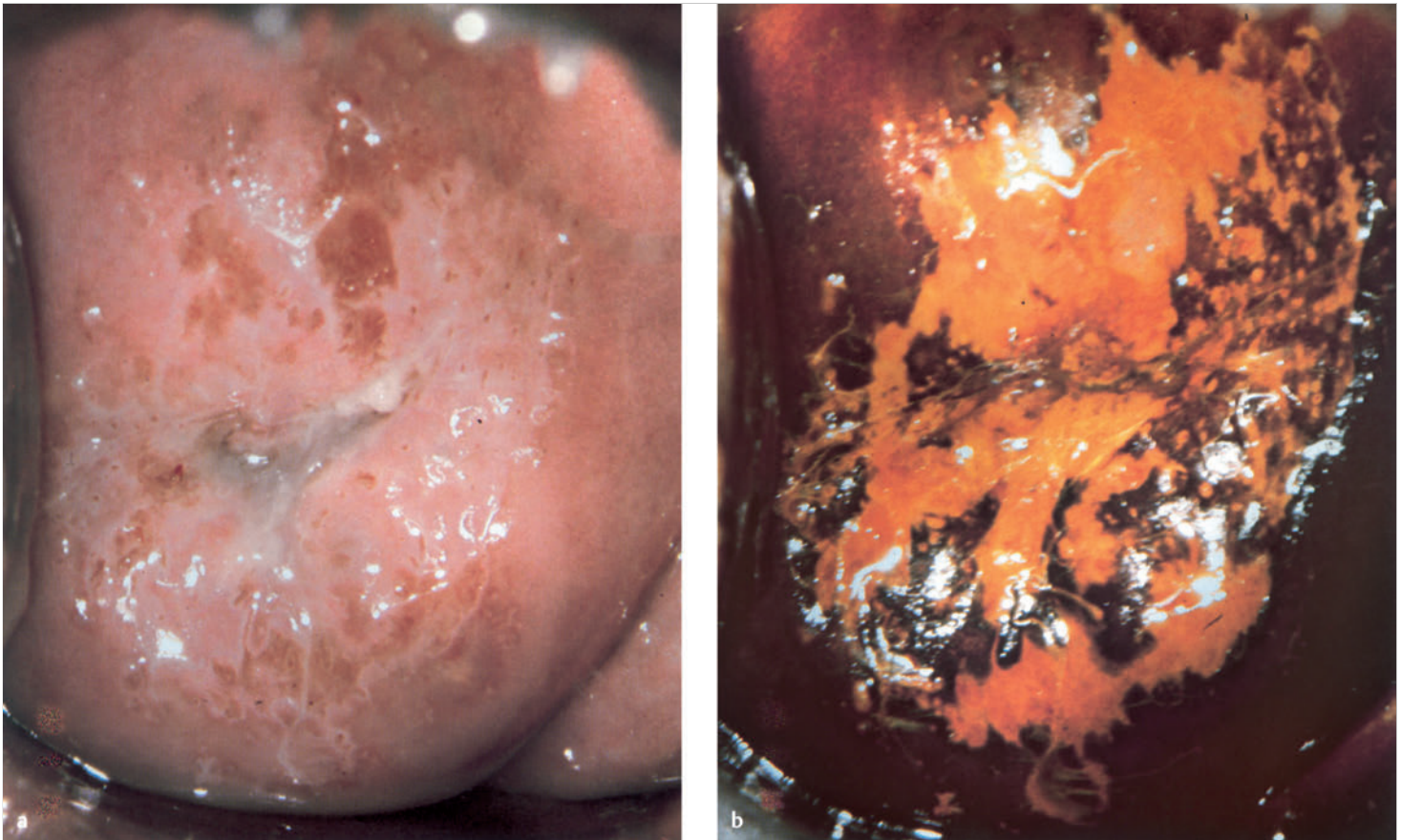


Fig. 8.28 (a) Characteristic appearance of thin acetowhite epithelium, distinguished from the normal transformation zone only by numerous cuffed gland openings. Histology showed low-grade squamous intraepithelial lesion (LSIL) (CIN 1). (b) Application of iodine (Schiller test) reveals a variegated appearance resulting from the admixture of LSIL and fully mature brown squamous epithelium.

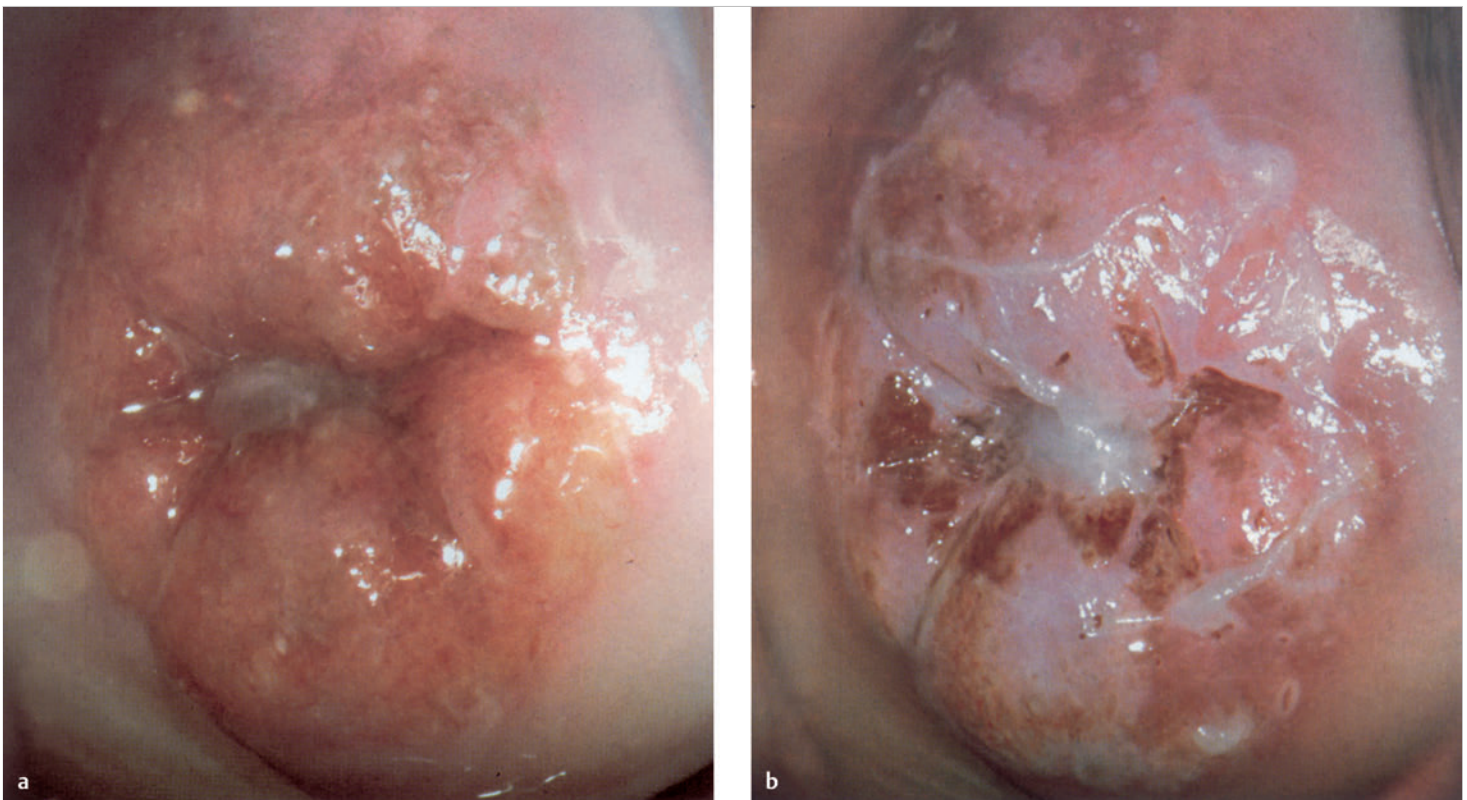


Fig. 8.29 (a) Before application of acetic acid, the white epithelium shows indistinct red tones. Several nabothian follicles shine through the reddish surface. (b) The white change is produced by acetic acid. Some gland openings are cuffed. The lesion between the 11-o'clock and 12-o'clock positions is due to glandular involvement. Histology showed LSIL (CIN 1).

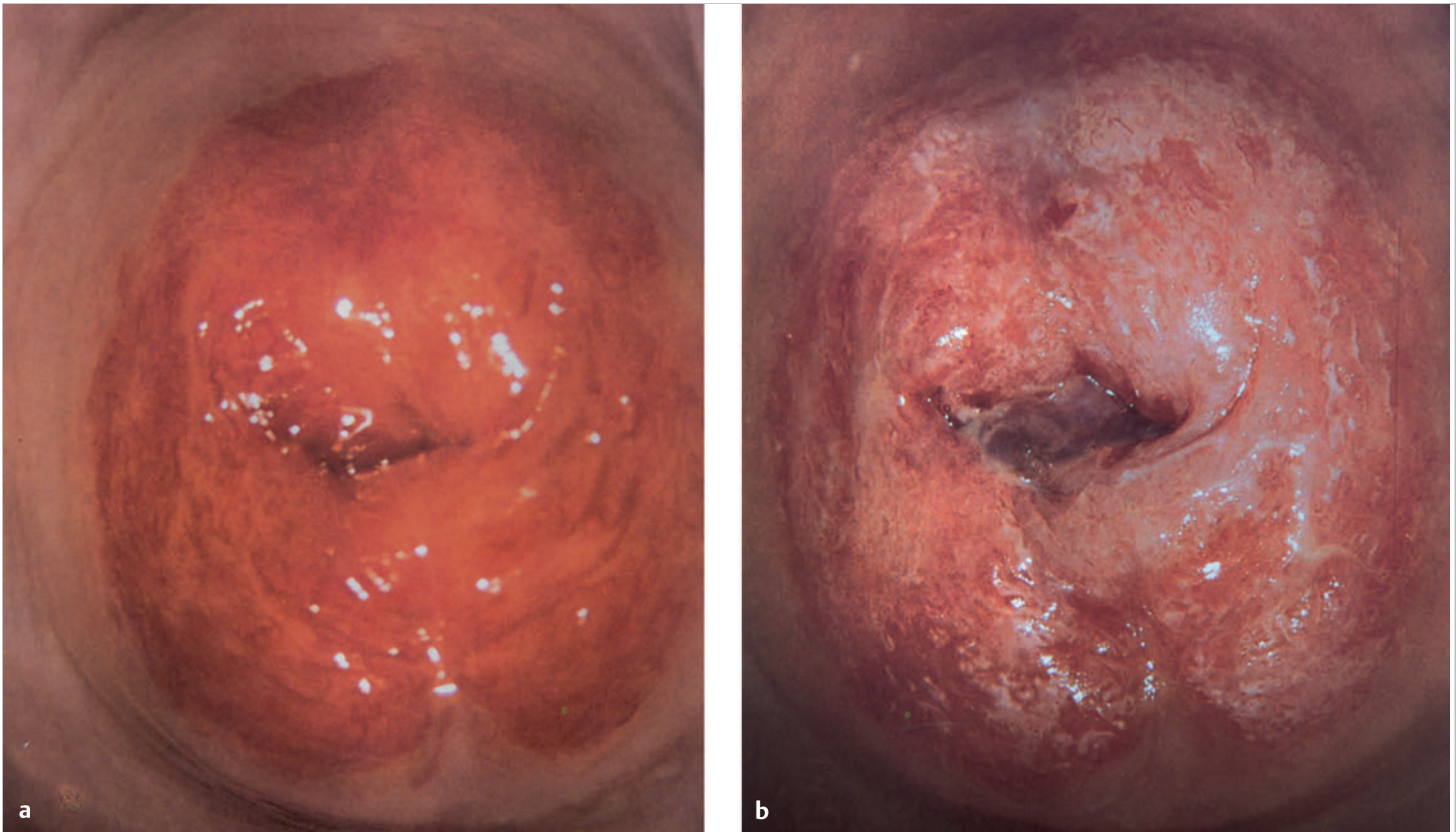


Fig. 8.30 (a) Angry red transformation zone, sharply demarcated from the original squamous epithelium. (b) Patchy appearance after application of acetic acid. Between the coarse and irregular white patches there are reddish areas with cuffed gland openings and solid epithelial pegs in the glands. Histology showed HSIL (CIN 3).

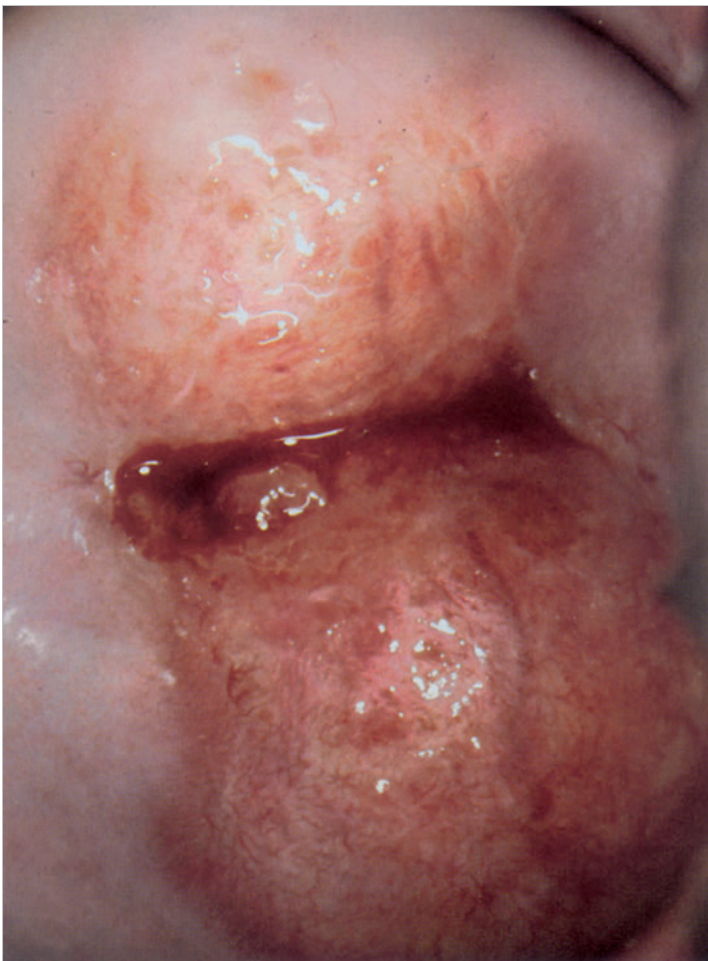


Fig. 8.31 Transformation zone with suspicious vessels on the posterior lip. Histology showed HSIL (CIN 3).

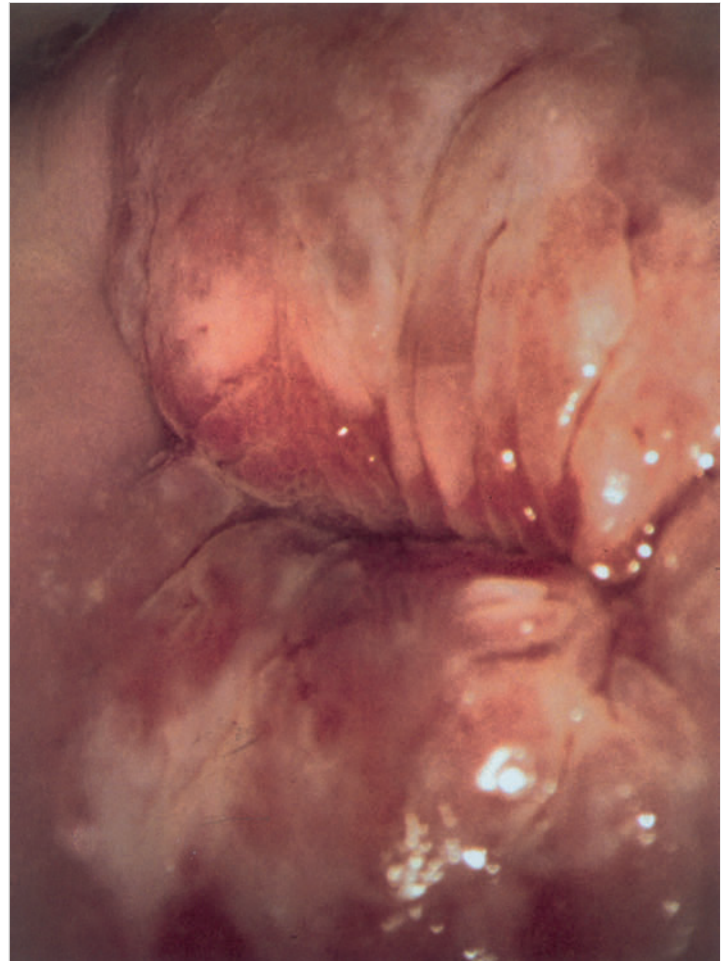

Fig. 8.32 Dense acetowhite epithelium after application of acetic acid. There are only isolated gland openings. Histology showed HSIL (CIN 3).

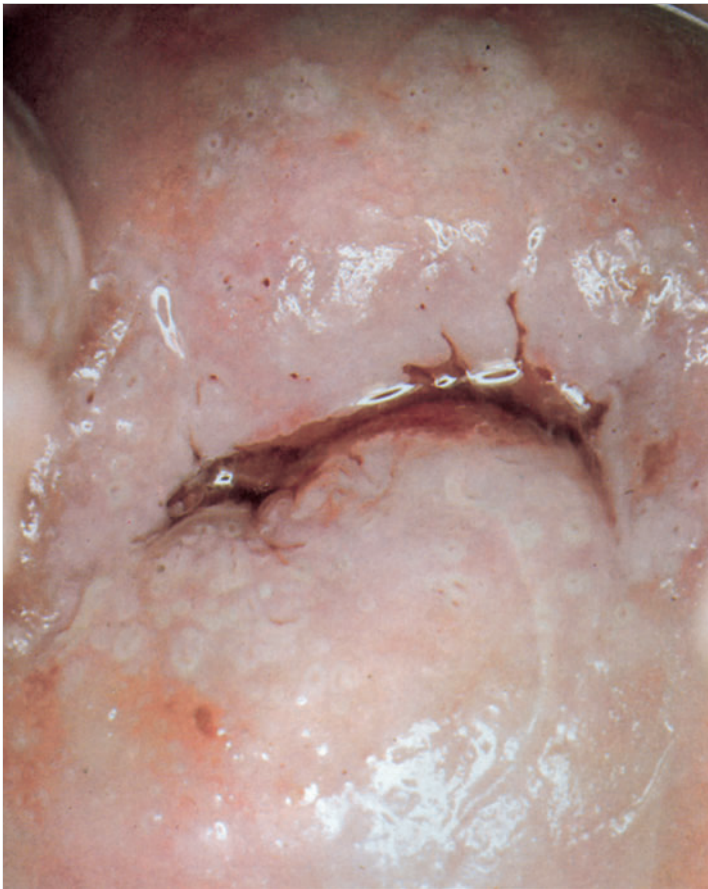

Fig. 8.33 Dense acetowhite epithelium with numerous cuffed gland openings. Histology showed HSIL (CIN 3).

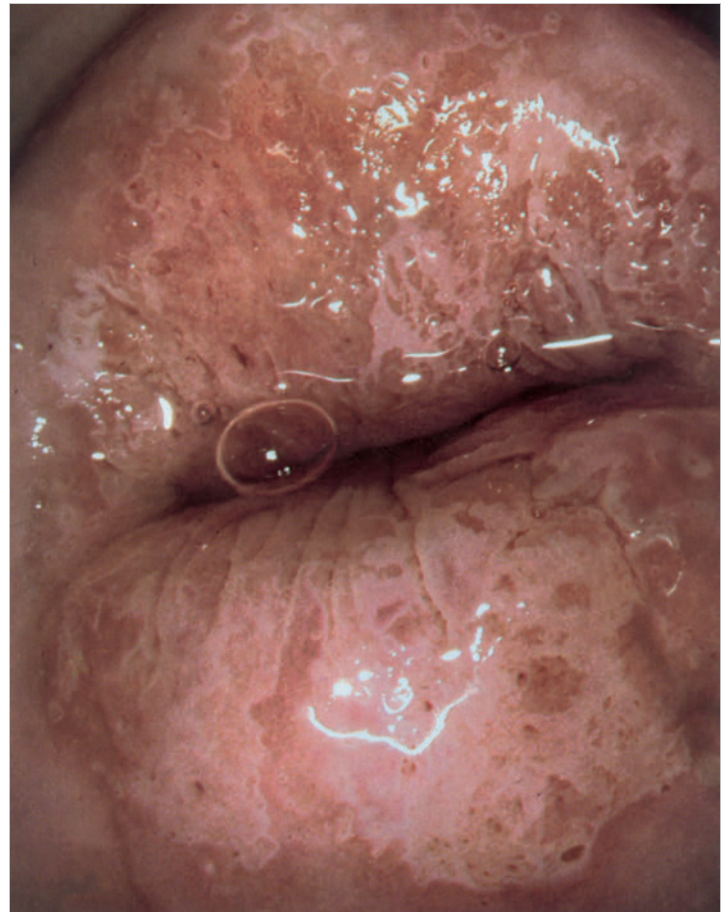

Fig. 8.34 Dense acetowhite epithelium on the posterior lip and on the anterior lip between 12 o'clock and 3 o'clock and between 9 o'clock and 10 o'clock. Histologically the acetowhite epithelium was HSIL (CIN 3), whereas the pale pink area on the anterior lip was metaplastic epithelium.

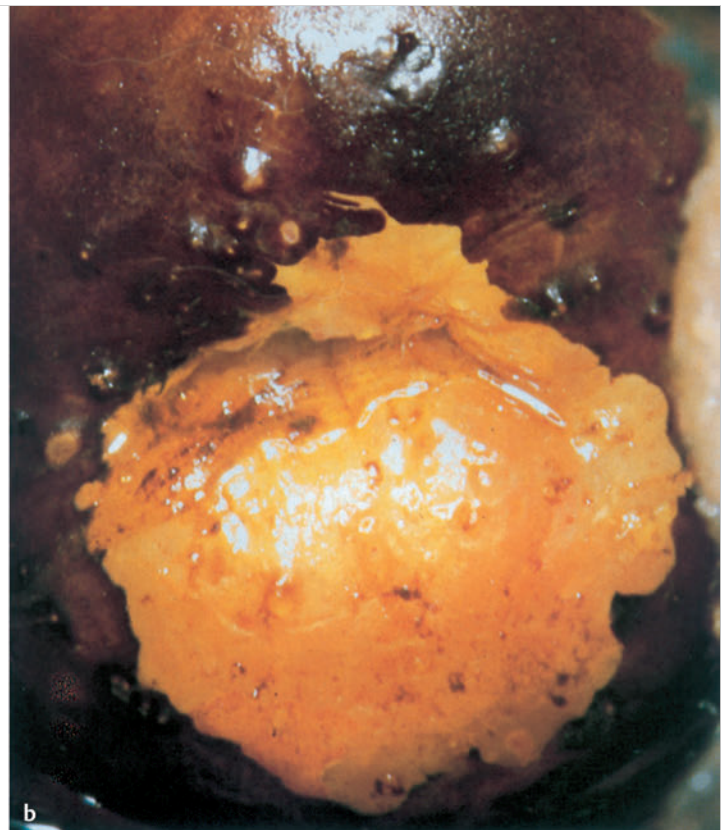
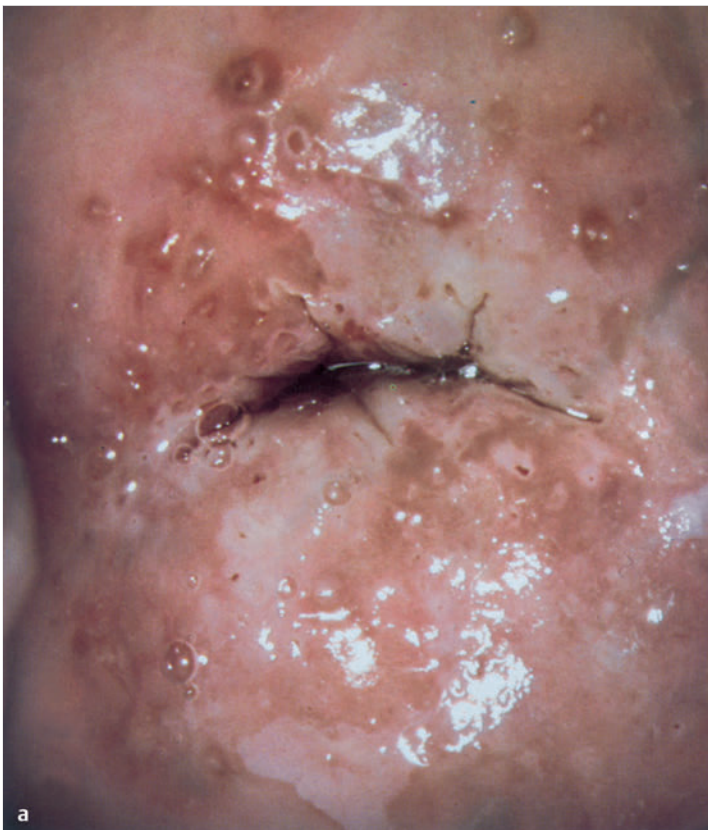
Fig. 8.35 (a) Dense acetowhite epithelium involving the entire posterior lip as well as the external os between 11 o'clock and 1 o'clock. Note the whitenss of the epithelium and the gland openings, some of which are cuffed. Histology showed HSIL (CIN 3). (b) After iodine staining, the pathologic epithelium clearly stands out against the fully mature squamous epithelium in the transformation zone.

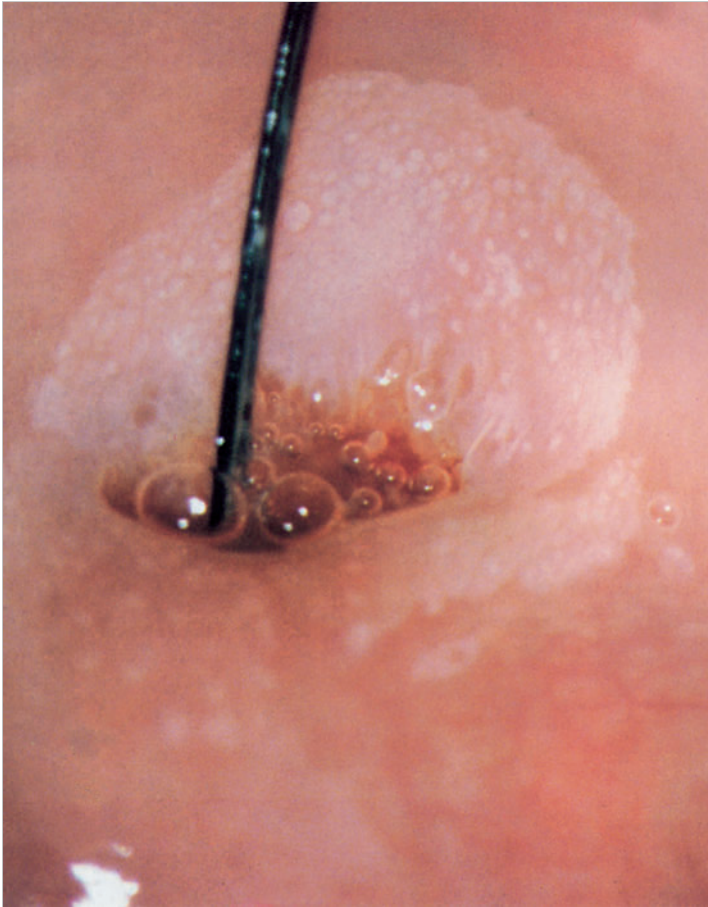


Fig. 8.36 Fine mosaic, mainly on the anterior lip of the external os, after application of acetic acid. Histology showed metaplastic epithelium. The string of an intrauterine device is visible.

8.2.2 Atypical Transformation Zone

The term *atypical transformation zone* was previously used as an umbrella designation for practically all abnormal colposcopic appearances such as leukoplakia, punctuation, and mosaic, as these also occur outside the TZ. The term is no longer part of the official nomenclature.

8.2.3 Mosaic

The term *mosaic* refers to a colposcopic pattern of cobblestone-like tiles with capillaries forming the borders of the individual tiles. As with punctuation, the appearances of mosaic are determined by epithelial changes, which allow distinction between *fine mosaic* (minor change) and *coarse mosaic* (major change).

Fine Mosaic

Fine mosaic, like fine punctuation, occurs in sharply demarcated areas in the plane of the superficial epithelium. The appearance of such an area before application of acetic acid can be non-specific and can remind one of a relatively vascular TZ, which, however, is usually devoid of gland openings or cysts (► Fig. 8.27, ► Fig. 8.36, ► Fig. 8.37, ► Fig. 8.38, ► Fig. 8.39, ► Fig. 8.40, ► Fig. 8.41, ► Fig. 8.42). A distinct color change to gray-white occurs with acetic acid application, and the margins become sharp. The blood vessels become less conspicuous (► Fig. 8.27b). The whole area remains in the same plane as before. The mosaic pattern is delineated by the fine network of pale red lines. Such

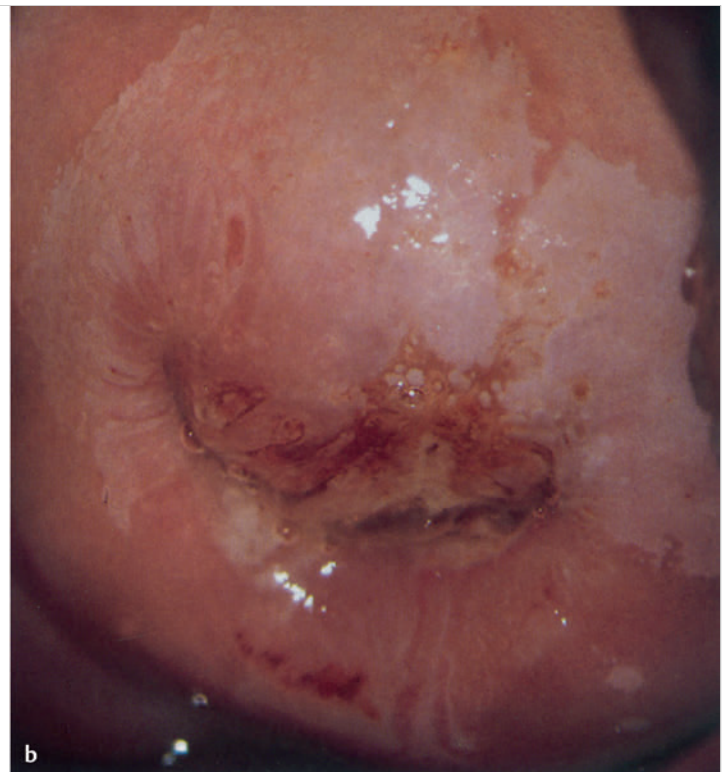
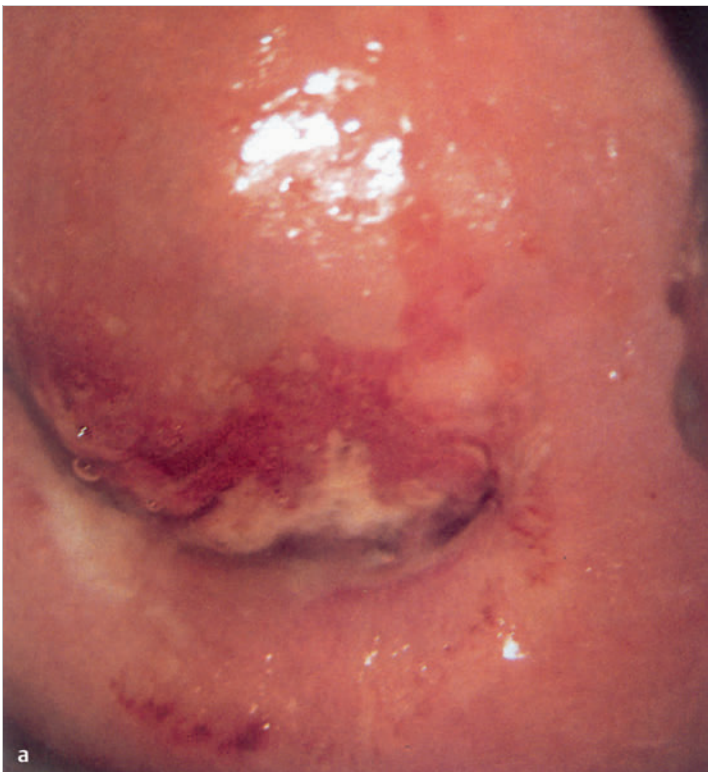

Fig. 8.37 (a) Indistinct lesion outside an intensely red area around the external os. Close examination shows increased vascularity on the posterior lip at the edge of the area. (b) Application of acetic acid shows an unexpectedly large, fine mosaic, mainly on the anterior lip. The whitish points in the narrow transformation zone are glands filled by squamous epithelium. Histology showed metaplastic epithelium.

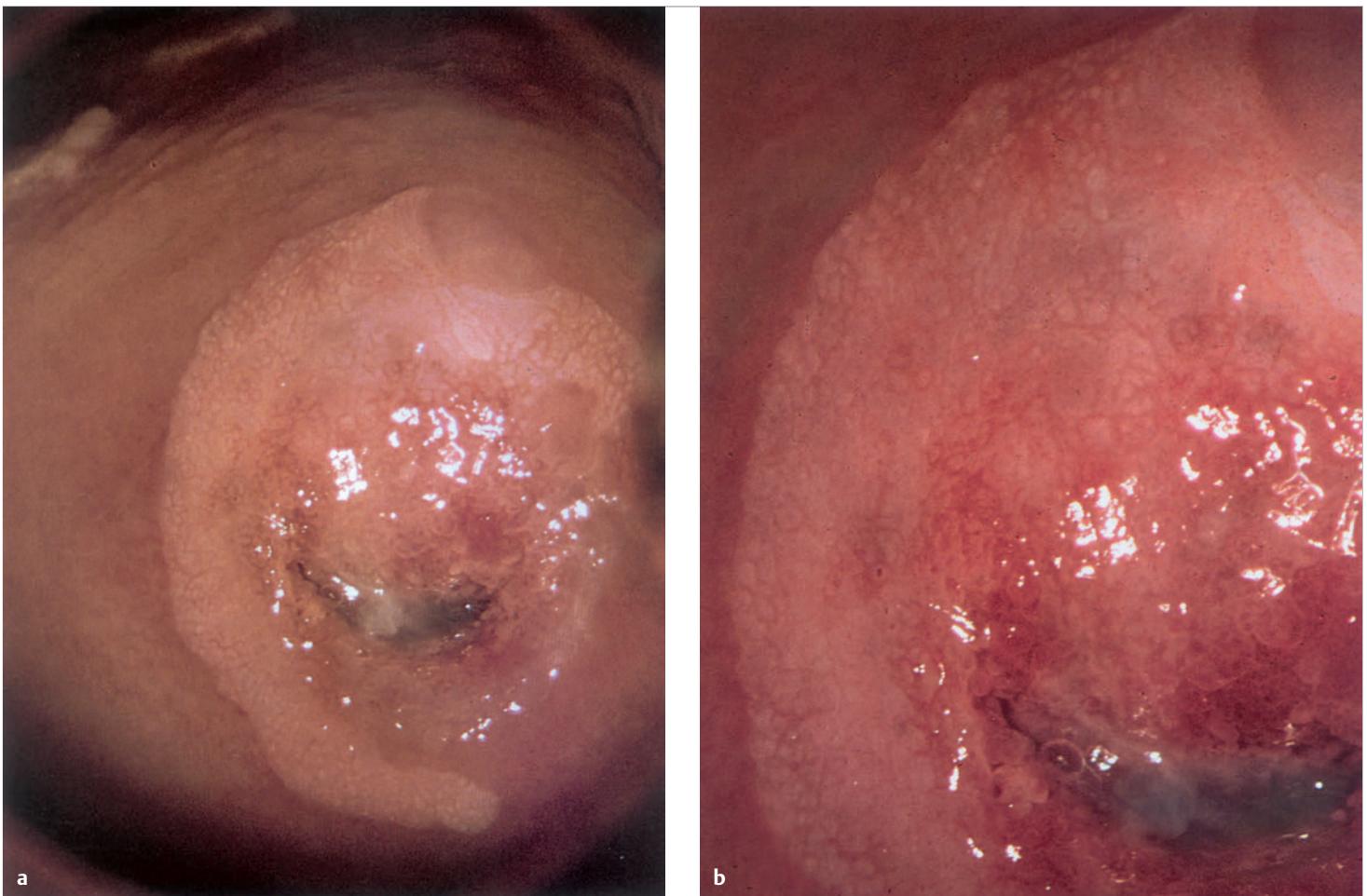


Fig. 8.38 (a) Transformation zone surrounded by a semicircular area that turns whitish after the application of acetic acid and shows a fine mosaic. (b) Higher magnification shows that the mosaic is coarser and more irregular than in ► Fig. 8.27, ► Fig. 8.36, and ► Fig. 8.37. Histology showed LSIL (CIN 1).

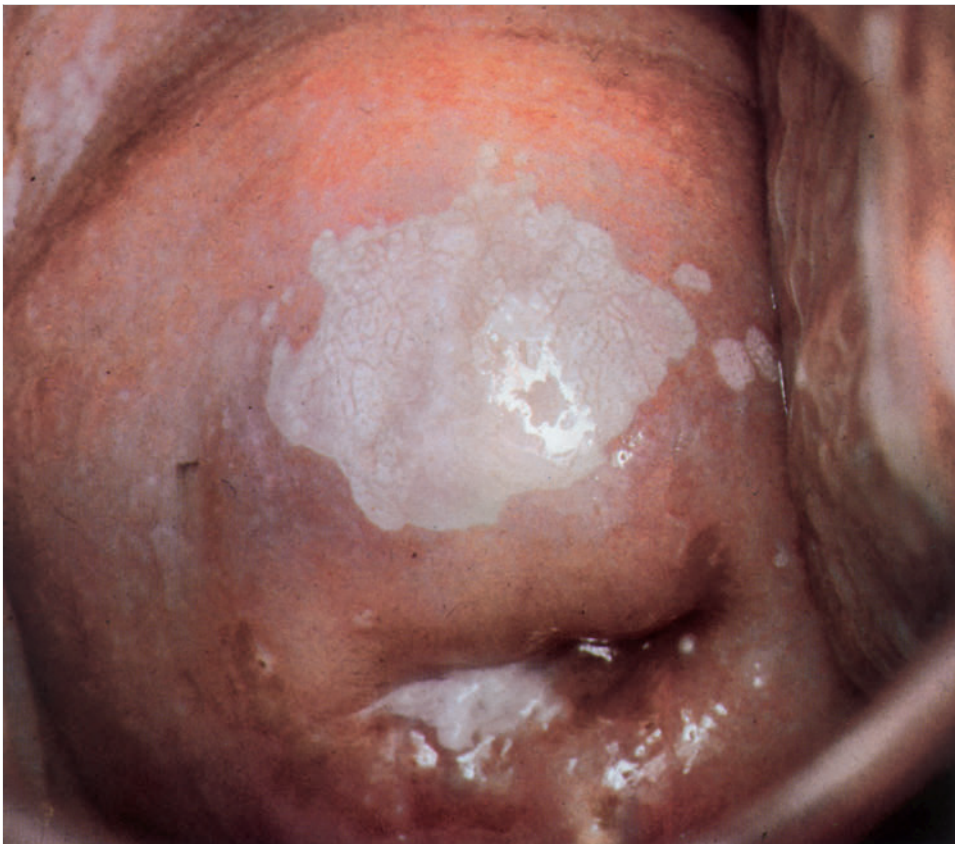


Fig. 8.39 Fine to coarse mosaic outside the transformation zone involving original squamous epithelium. Histology showed HSIL (CIN 2).

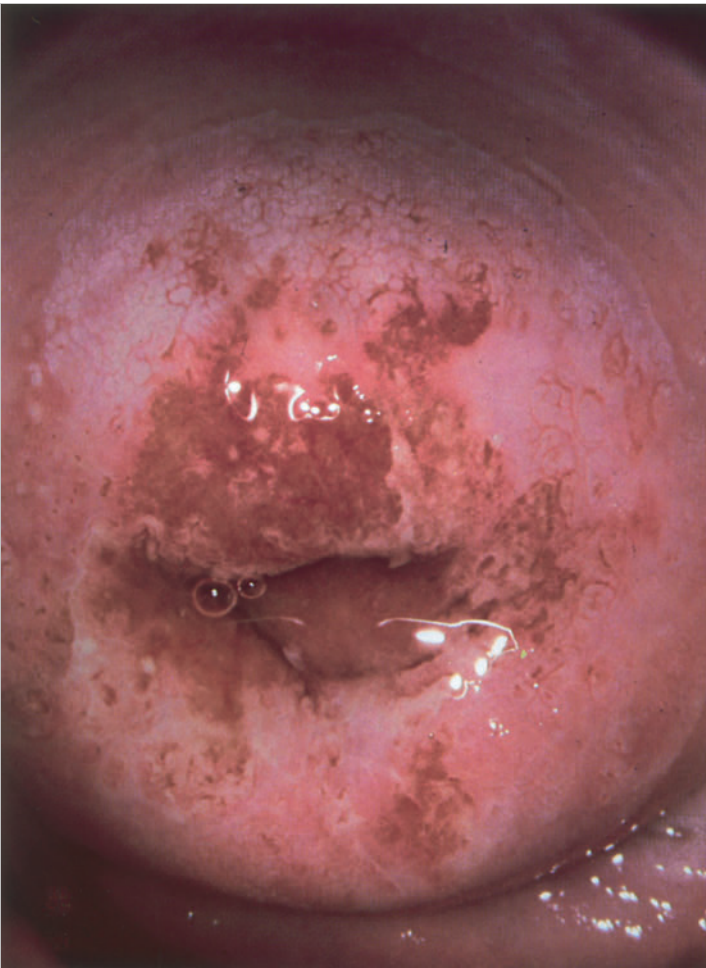

Fig. 8.40 Coarse mosaic around the os. Histology showed HSIL (CIN 3).

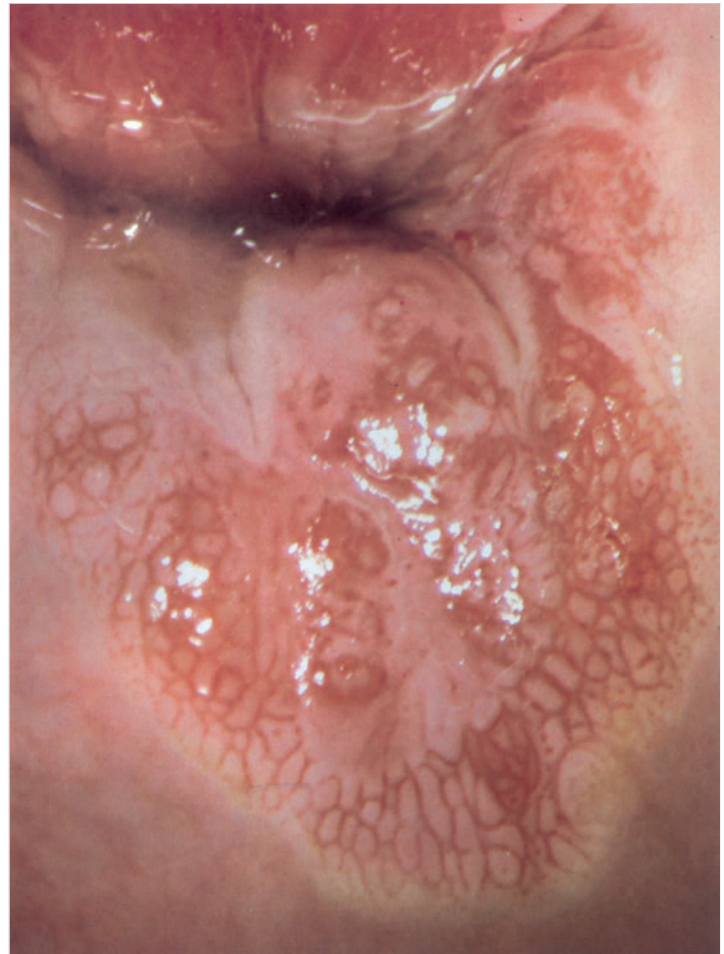

Fig. 8.41 Coarse mosaic intermingling with coarse punctuation on the posterior lip. The border to the acetowhite epithelium is sharp. The latter returned HSIL (CIN 3) and the former dysplastic epithelium HSIL (CIN 2).

an area may not display the mosaic pattern throughout its entirety; in places, the surface may be uniform and flat because the epithelium is not supported by elongated stromal papillae.

It can be difficult to classify mosaic as fine or coarse (► Fig. 8.39, ► Fig. 8.42). Intermediate forms are mostly caused by low-grade squamous intraepithelial lesion (LSIL), which may also produce various forms of punctuation, depending on the degree of atypia and epithelial architecture.

Coarse Mosaic

Coarse mosaic is characterized by greater irregularity of the mosaic pattern. The network of fissures is more pronounced and intensely red. The furrows are more widely spaced, and the epithelial cobbles between them are bigger and more variable in shape than in the fine form (► Fig. 8.38, ► Fig. 8.39, ► Fig. 8.40, ► Fig. 8.41). The swelling from acetic acid makes the structures stand out (► Fig. 8.41); the peak effect may take a minute to develop. The metamorphosis can be observed through the colposcope as the coarse structure of the mosaic and punctuation gradually appears. In contrast, the effect of acetic acid on fine mosaic is immediate.

Gland openings and nabothian follicles are usually not found within areas of punctuation or mosaic. Like leukoplakia, mosaic and punctuation can also be found outside the TZ, in original squamous epithelium (► Fig. 8.43, ► Fig. 8.44, ► Fig. 8.39; see also ► Fig. 8.52). This is fundamental to the understanding of

the morphogenesis of punctuation and mosaic and epithelial atypia.

Punctuation and mosaic occur in isolated fields (► Fig. 8.39, ► Fig. 8.43, ► Fig. 8.44, ► Fig. 8.45) and can coexist with other lesions (see ► Fig. 10.1, ► Fig. 10.2). In the latter case, the more peripherally located lesions usually represent lower-grade lesions (LSIL, CIN 1) or merely metaplastic epithelium, which was confirmed by topographic studies showing that mosaic and punctuation occur more commonly outside than inside the TZ (84% vs. 16%). Histologically, mosaic and punctuation outside the TZ corresponded to benign metaplastic epithelium in 70% and to CIN in only 30% of treated cases; within the TZ the respective rates were 20% and 80%.⁸ Thus, mosaic and punctuation within the TZ are more likely to represent CIN than are the same lesions outside the TZ.

8.2.4 Punctuation

Punctuation is a colposcopic finding caused by capillary loops near to and visible through the epithelial surface as dots in a stippled pattern. Usually punctuation is imprinted on a uniform surface that is undisturbed by either gland openings or nabothian follicles or by any other signs of a TZ. The degree of punctuation depends on the type of underlying epithelial abnormality. The type of punctuation, as well as of mosaic, is important at colposcopic evaluation. The colposcopist should be aware that similar colposcopic appearances can be due to either benign

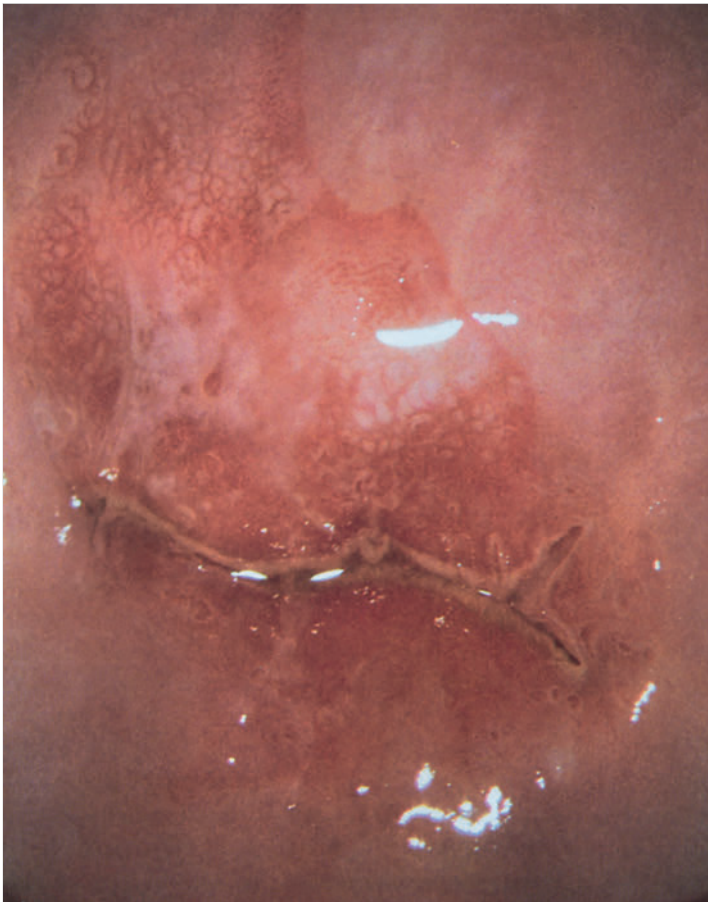

Fig. 8.42 Fine to coarse mosaic intermingling with fine punctuation at the edge of acetowhite epithelium with cuffed gland openings and solid white points. The points correspond to HSIL (CIN 3).

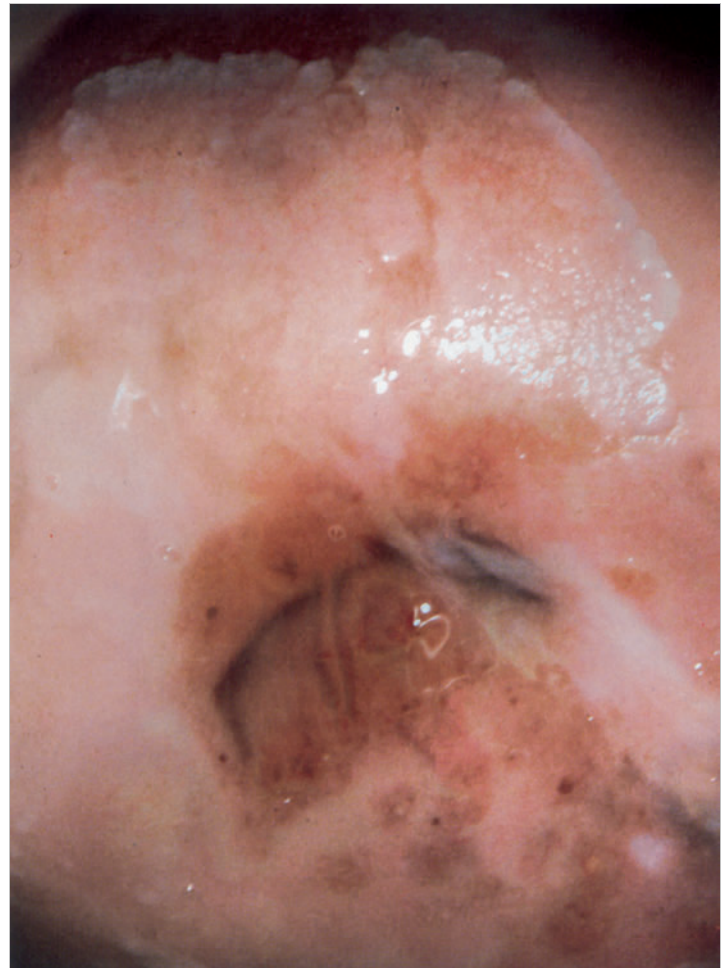

Fig. 8.43 Leukoplakia outside the transformation zone, on the anterior lip of the cervix. Histology showed metaplastic epithelium.

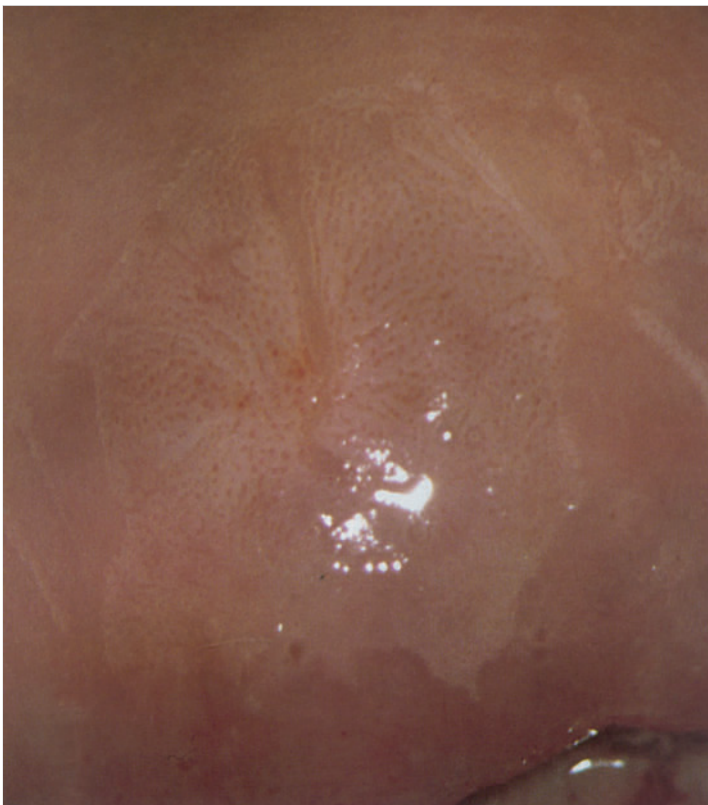


Fig. 8.44 Slightly prominent punctuation. The entire sharply demarcated area apparently lies within unaltered squamous epithelium. Histology showed HSIL (CIN 3).

metaplastic epithelium or atypical epithelium, which differ only in arrangement and degree of expression.

Two types of punctuation are of diagnostic importance: *fine punctuation* (minor change) and *coarse punctuation* (major change). There are good diagnostic criteria to distinguish between the two types, but it is not always possible to categorize a given case as one or the other. Such appearances should always be regarded with suspicion: biopsy should be carried out, or cytology should be repeated.

Fine Punctuation

Fine punctuation characteristically imparts delicate stippling to an otherwise circumscribed grayish white to reddish area (► Fig. 8.45). When the epithelium is keratinized, the dots may appear white, but they are usually red and remain in the same plane as the surface epithelium, even after the application of acetic acid. The “dots” of fine punctuation are close together (► Fig. 8.46). Fine punctuation is often combined with equally fine mosaic. Fine focal punctuation may be due to inflammation, in which case the margins of the inflamed area appear indistinct after application of iodine (see ► Fig. 8.47 and ► Fig. 8.48b). Fine punctuation can also be associated with LSIL (caused by human papillomavirus [HPV] infection). With the Schiller iodine test, the punctations become yellow to ochre, whereas the adjacent epithelium, as a result of the koilocytes, stains brown. This is known as iodine-positive punctuation (► Fig. 8.45b).

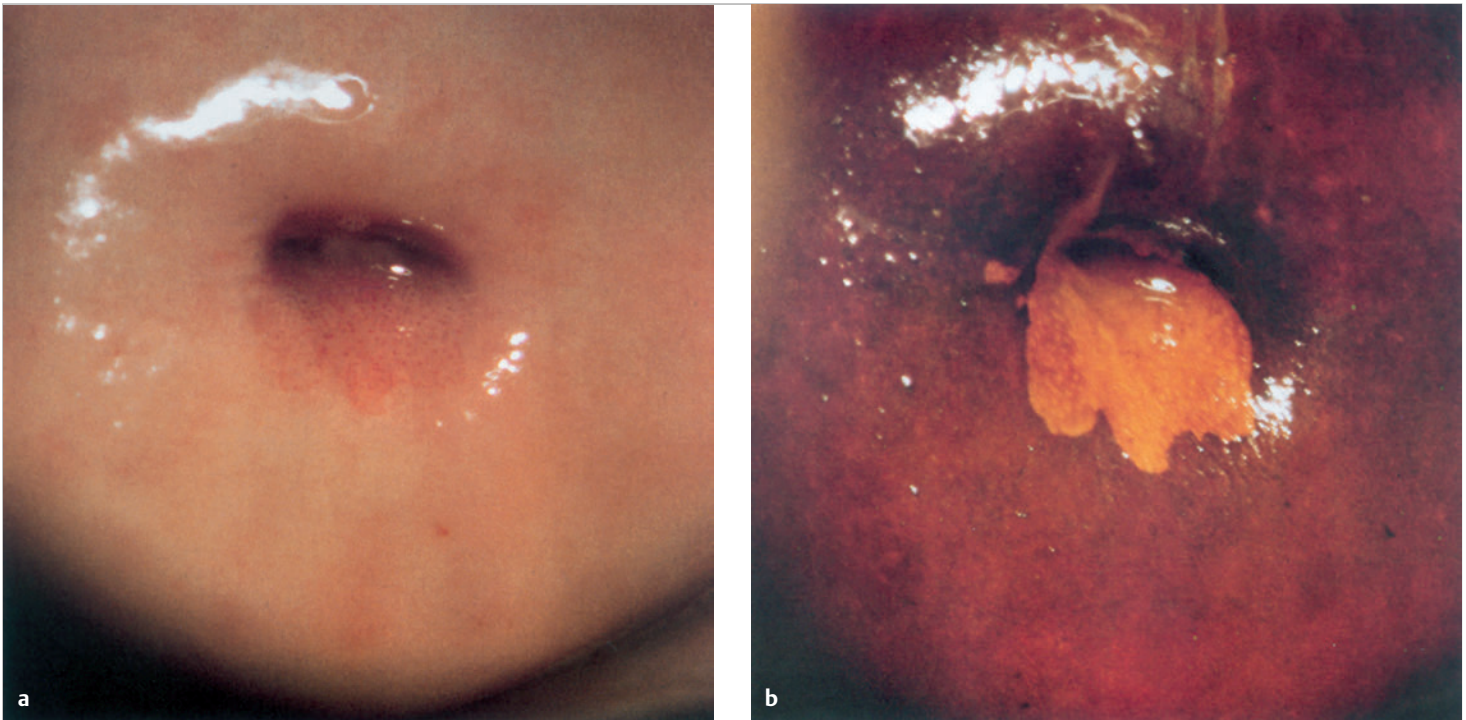


Fig. 8.45 (a) A fine punctuation on the posterior lip of the cervix extends into the cervical canal. The squamocolumnar junction is not visible (type 3). (b) After application of iodine, the epithelium is stained brown. This so-called iodine-positive punctuation is a sign of human papillomavirus infection. Histology showed LSIL (CIN 1) with koilocytosis.

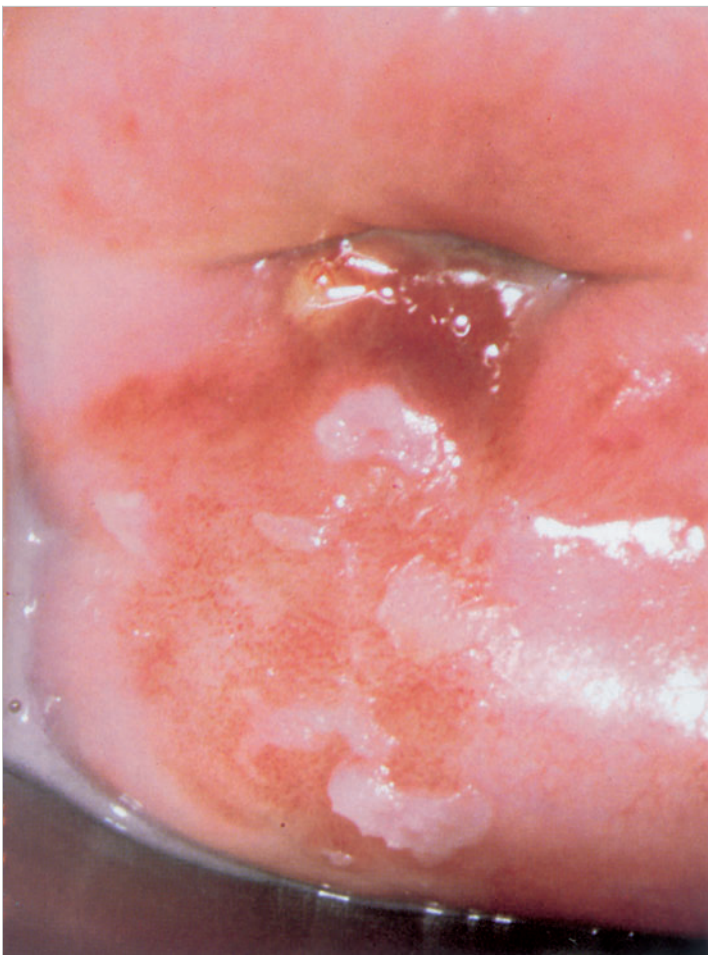


Fig. 8.46 Leukoplakia. Punctuation appears where the keratin layer has been peeled off. Histology showed keratinizing metaplastic epithelium.

Coarse Punctuation

Coarse punctuation usually indicates HSIL. The petechiae are more pronounced, bigger, and widely separated (► Fig. 8.44, ► Fig. 8.49, ► Fig. 8.50, ► Fig. 8.51). In extreme cases, punctuation resembles papillae (► Fig. 8.52). With higher magnification, corkscrew capillaries can be seen in the papillae. After application of acetic acid, coarse punctuation stands out from the plane of the surrounding surface epithelium (► Fig. 8.49a,b). Coarse punctuation may be combined with coarse mosaic. The two patterns may overlap, with intermingling of dots and fissures (► Fig. 8.50).

8.2.5 Leukoplakia (Keratoses)

Leukoplakia (keratoses) can usually be seen with the naked eye (► Fig. 8.53, ► Fig. 8.54a,b), but sometimes the colposcope is necessary (► Fig. 8.55). Histologically leukoplakia corresponds to parakeratosis or true keratinization (► Fig. 4.6), which cannot be distinguished colposcopically. A colposcopically delicate white patch, however, usually corresponds to parakeratosis, whereas hyperkeratosis usually produces a thick, rough-surfaced plaque. Fine leukoplakias are well circumscribed (► Fig. 8.55), their surface either flat or finely pitted. When keratinization is marked, the margins become obscured by the overlapping horny layer. The surface may be smooth but is more commonly pitted and may even have a mosaic appearance. Partial shedding or removal of the keratin can result in a plaquelike appearance, referred to as *plaquelike* or *thick leukoplakia*.

If the keratin layer is completely wiped away, the underlying epithelium can display a pattern, often punctuation (► Fig. 8.46). Leukoplakia can be found within or outside the TZ, in the latter case arising from original squamous epithelium.

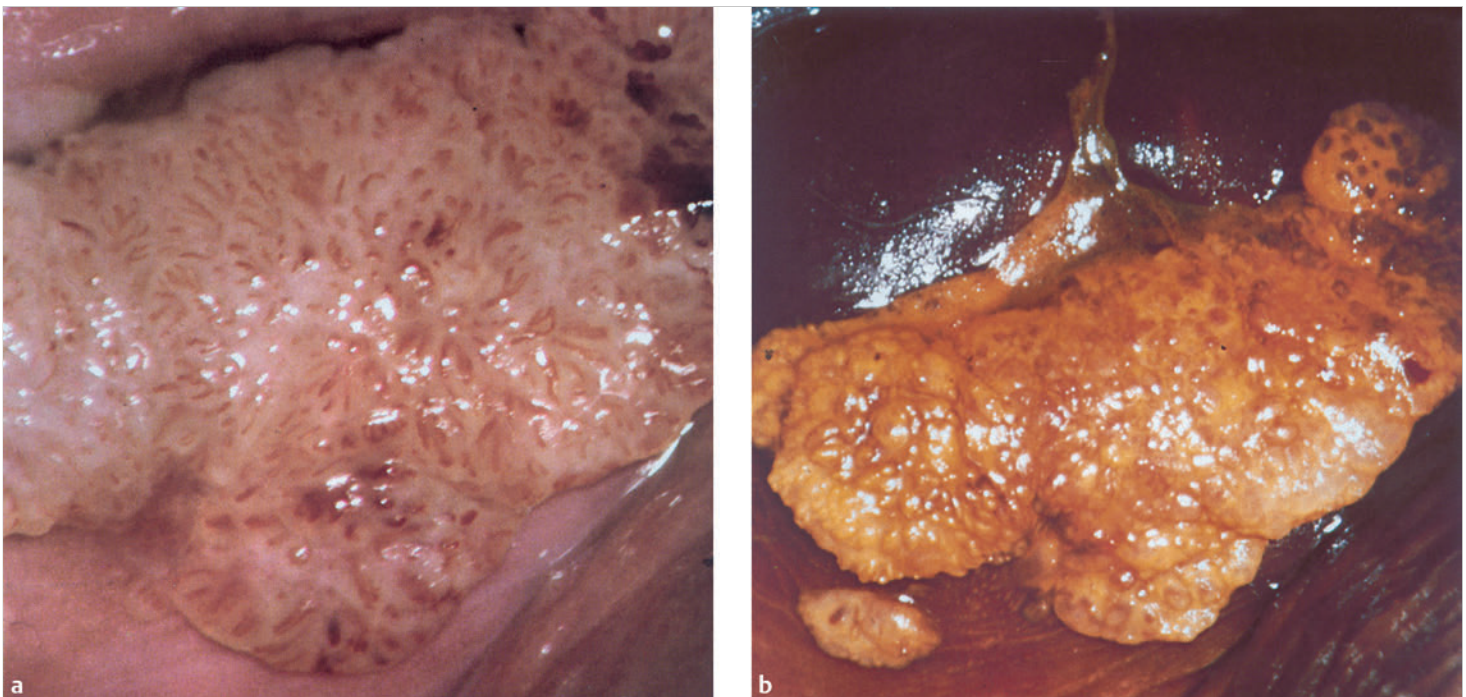


Fig. 8.47 (a) On higher magnification, the vessels within the papillae resemble commas and antlers. Their coarseness gives the impression of atypia. (b) Condyloma. The brownish color after application of iodine indicates glycogen-containing patches within the condyloma and correlates well with the histologic picture.

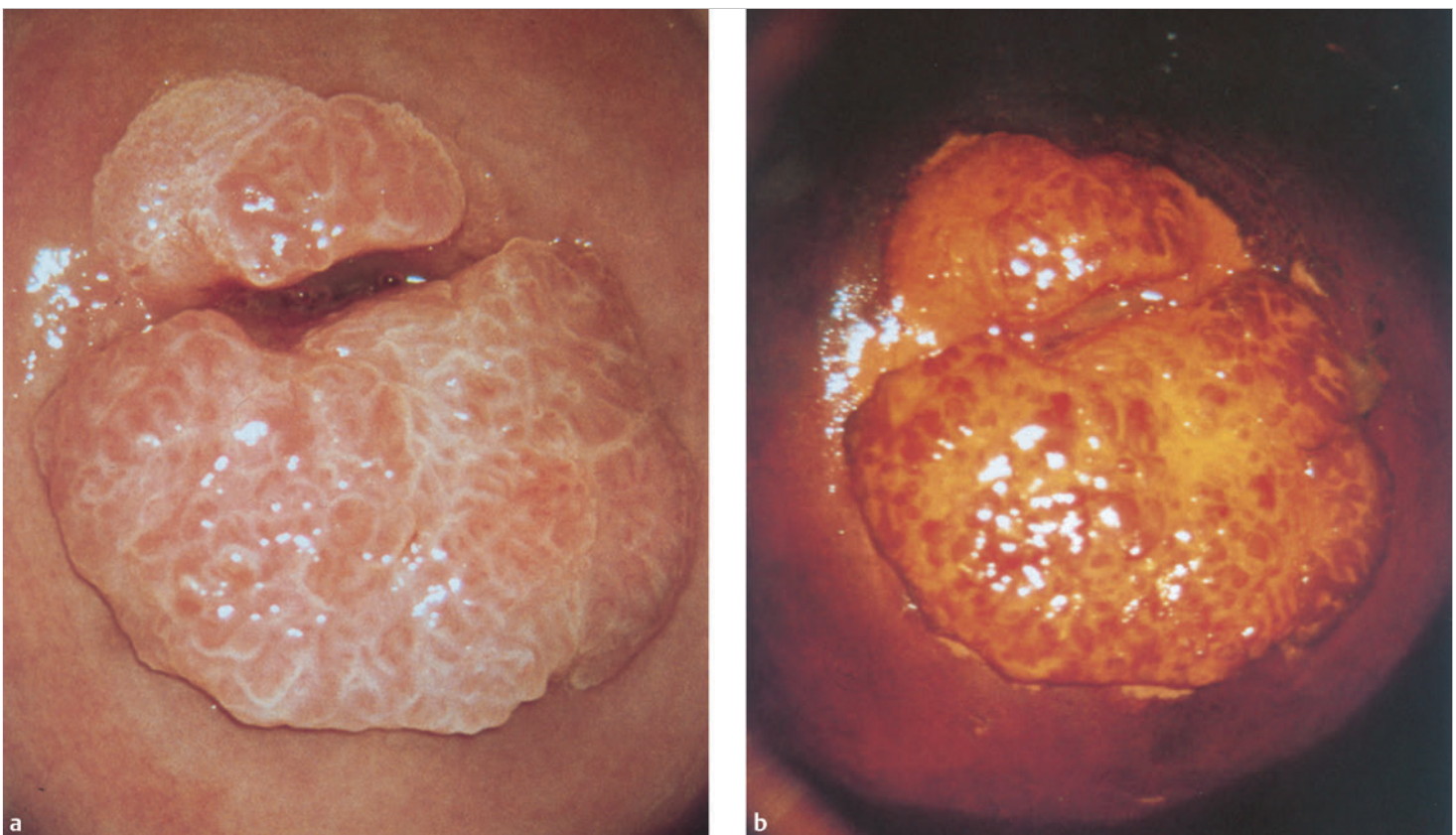


Fig. 8.48 (a) Exophytic condylomatous lesion after application of 3% acetic acid. (b) After application of iodine, the surface shows the patchy brown staining typical of condylomas and an other epithelium.

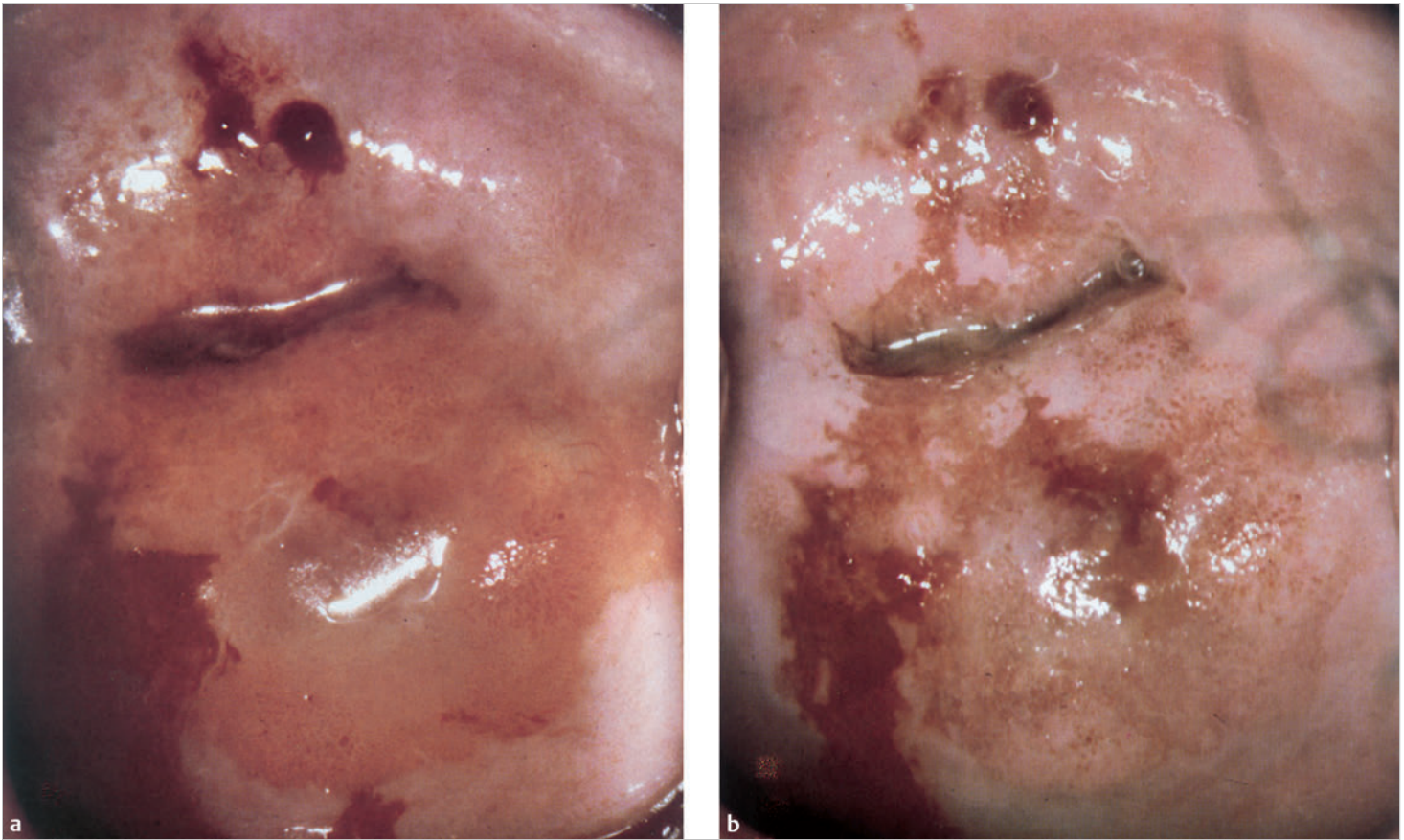


Fig. 8.49 (a) Atypical yellowish-reddish area showing focal coarse punctation. (b) After application of acetic acid, the area of punctation swells, stands out from the surface, and becomes white. Histology showed HSIL (CIN 3). There is an island of fully mature squamous epithelium in the transformation zone on the anterior lip.

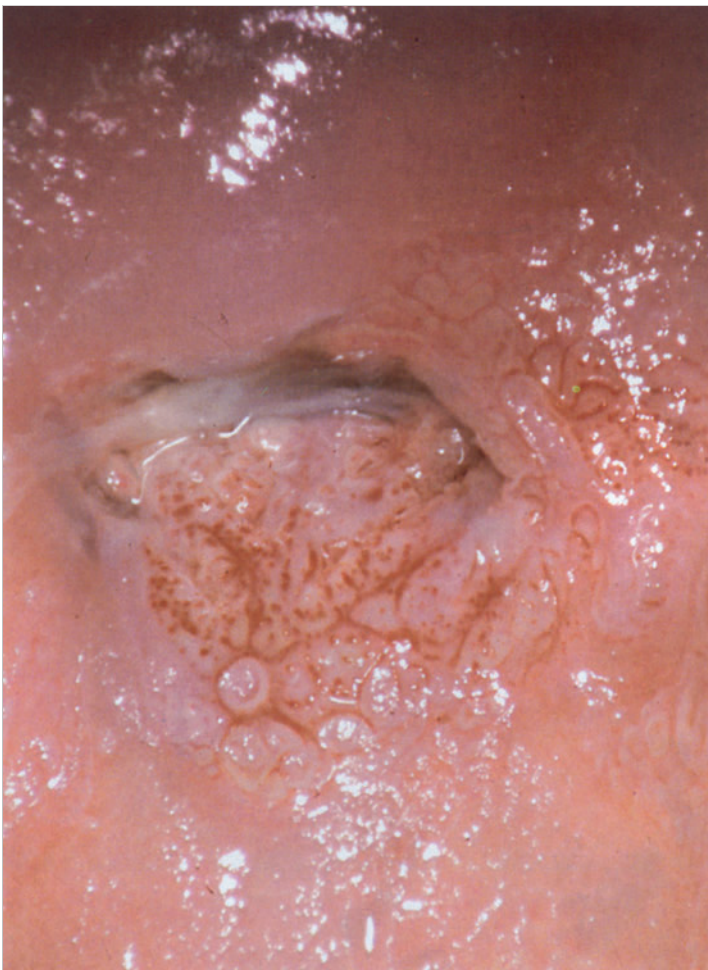

Fig. 8.50 Combination of coarse punctation and coarse mosaic. Histology showed HSIL (CIN 3).

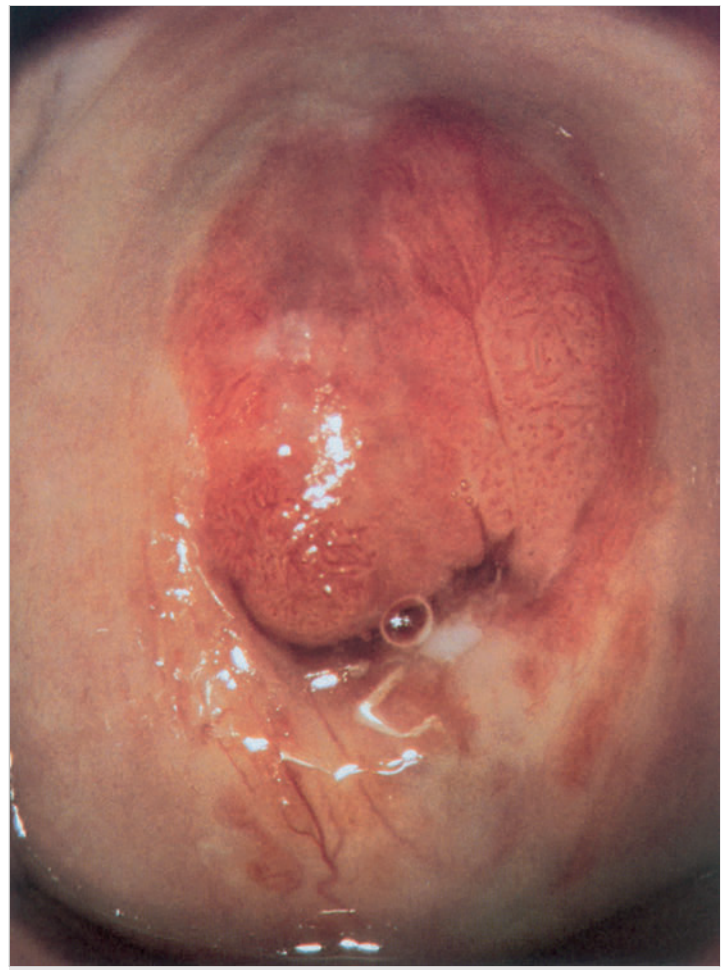


Fig. 8.51 Coarse, irregular punctation before the application of acetic acid. Histology showed HSIL (CIN 2). On the posterior lip there is a regular vascular pattern in a mature transformation zone.

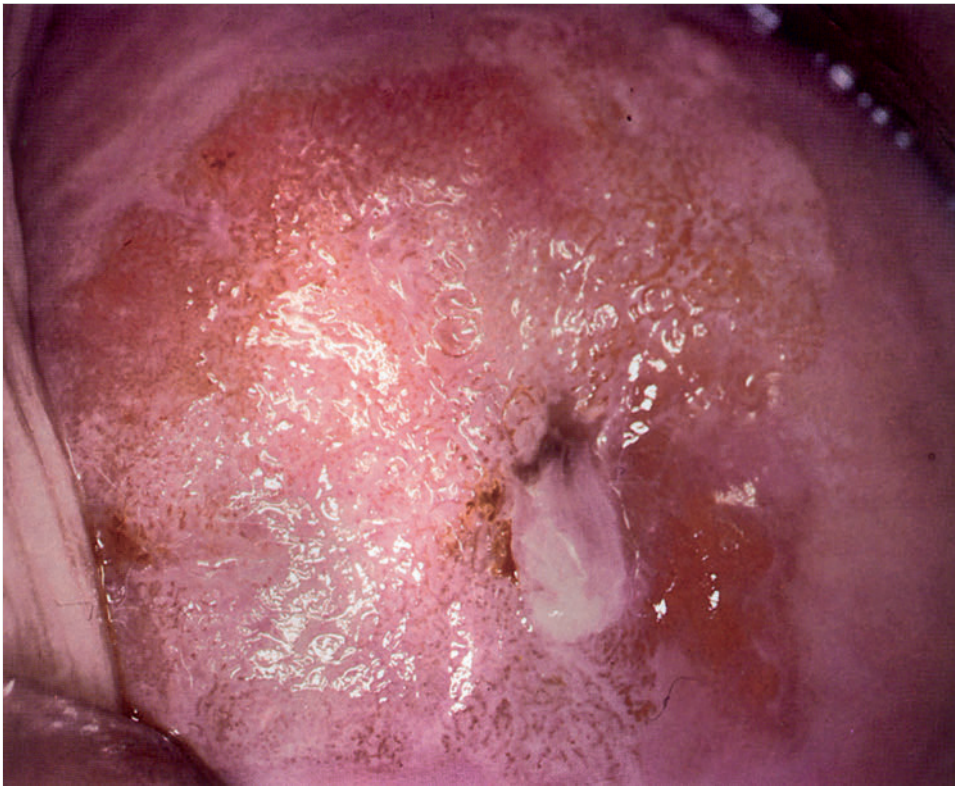

Fig. 8.52 Coarse punctation. Note the papillary appearance. Histology showed HSIL with early stromal invasion (FIGO stage IA1).

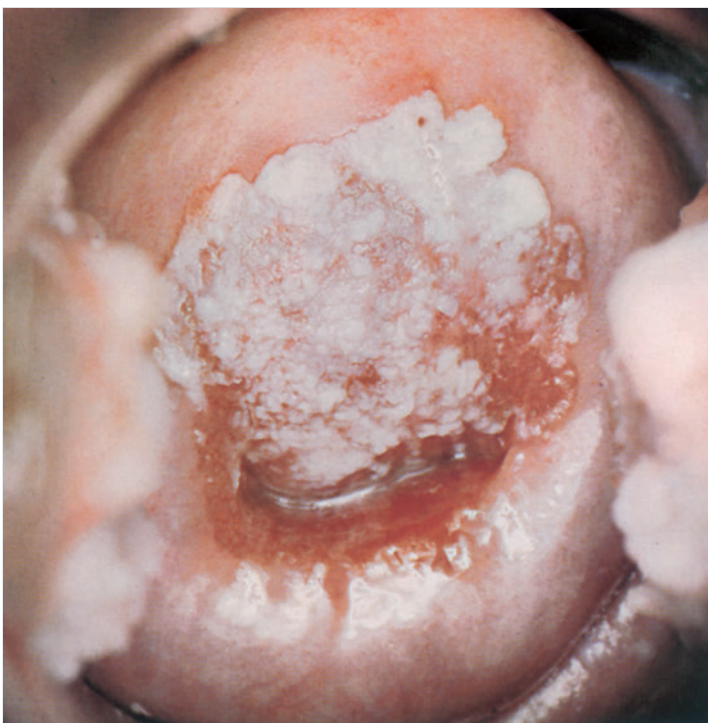


Fig. 8.53 Coarse plaque of keratosis with a partly fissured surface. Histology showed HSIL (CIN 3).

It is important to appreciate that the type of epithelium underlying leukoplakia cannot be predicted colposcopically. The epithelium may be of metaplastic origin, especially when the leukoplakia is fine. When cornification is more pronounced, the underlying epithelium may show the features of HSIL (CIN 3), early stromal invasion (► Fig. 8.54), even deeper invasion, or only benign acanthosis (► Fig. 8.43). Even iodine staining (Schiller test) cannot provide further diagnostic clues (► Fig. 8.54b). Moderate-sized leukoplakias typically stain canary yellow with iodine, which also enhances their sharp demarcation.

Leukoplakias usually should be evaluated with biopsy. Neither the surface contour nor the location of leukoplakia with regard to the TZ can predict whether the underlying epithelium is benign or neoplastic. Cytology is not diagnostic because the smear contains largely cornified material and nothing representative from an underlying lesion. Topographic studies have shown that leukoplakia is usually found outside the TZ and that it corresponds histologically to benign metaplastic epithelium in 62% of cases and to SIL in 38%.⁸

8.2.6 Erosion, Ulcer

Erosions are superficial epithelial defects; deeper defects, with exposure of the stroma, are called *ulcers*. Erosions and ulcerations are not normal during the reproductive years but can be iatrogenic artifacts during examination in the atrophic postmenopausal epithelium, particularly when obtaining the smear. Atypical epithelium is particularly vulnerable as it lacks cohesiveness, being more loosely structured than normal squamous epithelium. This accounts for the exfoliation of cells detected in smears as well as the swelling induced by acetic acid. The epithelium is also less firmly attached to the underlying stroma, from which it may detach easily to produce an erosion.

Ulcers are less easy to see when they occur within a colposcopically evident lesion (► Fig. 8.56). They are seen better with iodine because the exposed stroma does not stain (► Fig. 8.55b). An ulcer can be recognized by its intense red color, granular floor, and punched-out margin (► Fig. 8.57, ► Fig. 8.58). It is important not to miss larger ulcers that result from detachment of whole epithelial fields (► Fig. 8.58). Careful examination of the edges of such defects will reveal residual epithelium, which differs from surrounding normal epithelium in its color and acetic acid reaction. Biopsy should be performed on such epithelial rims.

Endophytic carcinomas (► Fig. 8.59) can masquerade as erosions or flat ulcers, so flat ulcers should be probed with a Chrobak's sound (► Fig. 5.5). Stroma infiltrated by tumor offers no

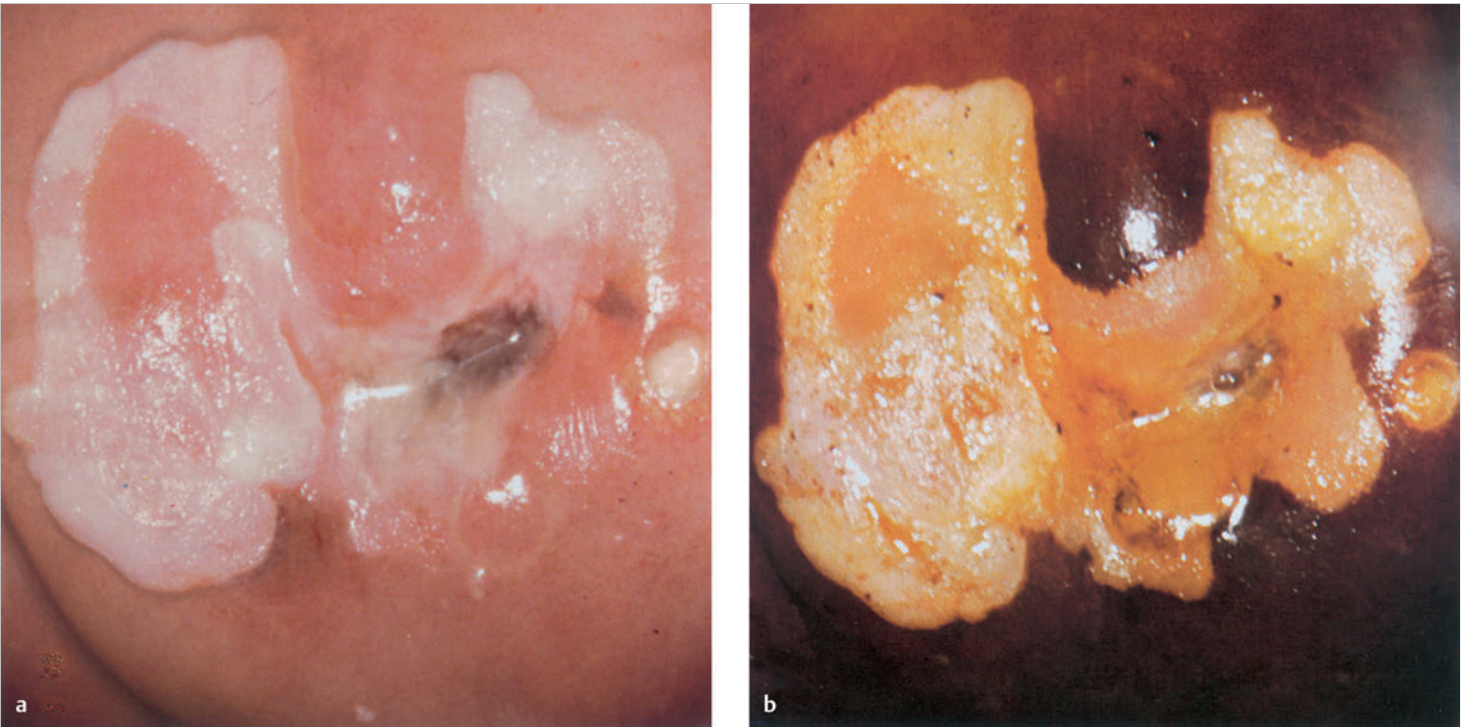


Fig. 8.54 (a) Pronounced leukoplakia displayed by most of a well-circumscribed lesion. Note the sharp border close to the external os at 11 o'clock. Conization showed HSIL with early stromal invasion (FIGO stage IA1). (b) After application of iodine, the border seen in (a) is accentuated. The leukoplakia is outside the transformation zone. A plaquelike arrangement of the keratin is suggested.

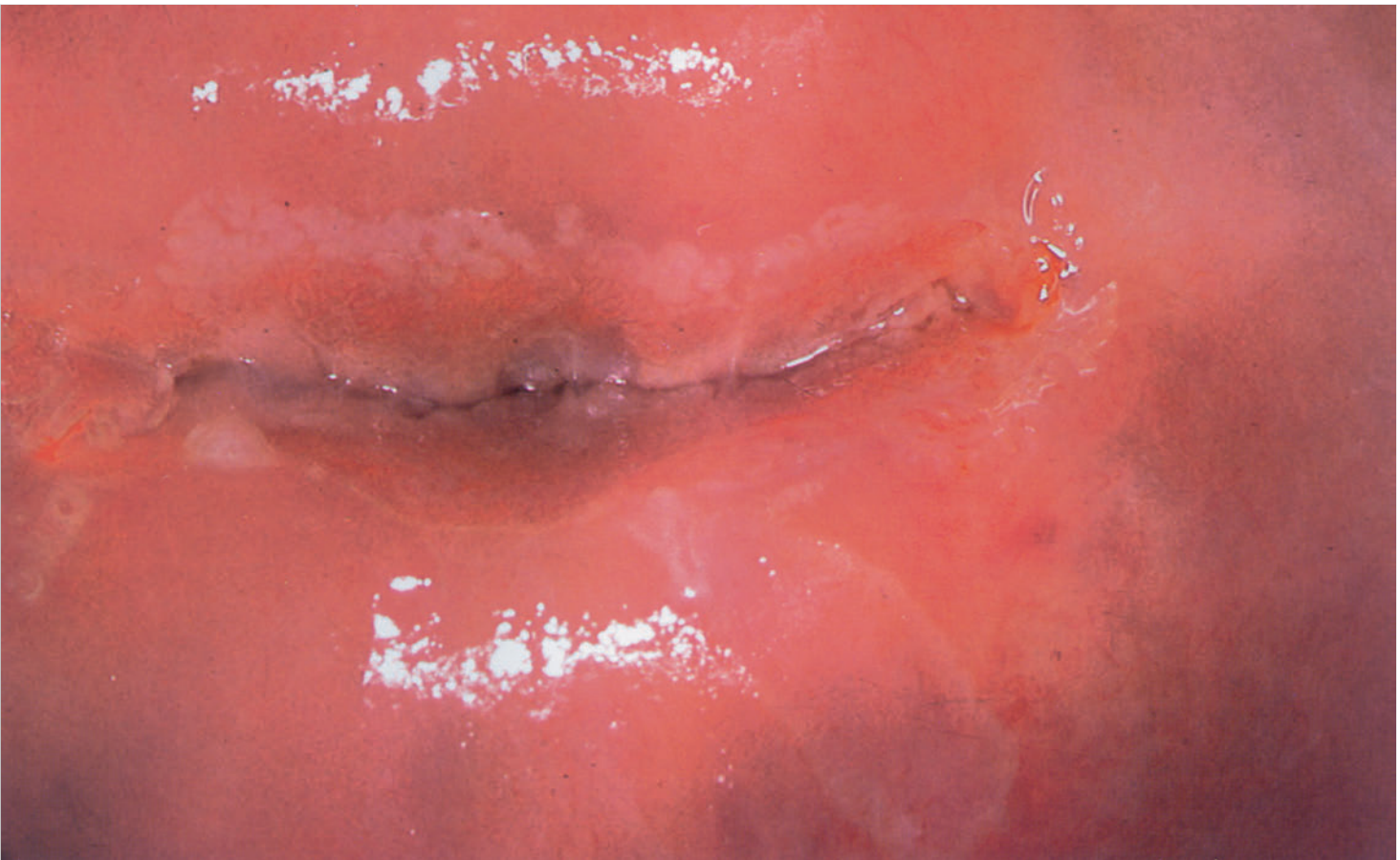


Fig. 8.55 Sharply demarcated but only slightly keratotic area on the posterior lip of the cervix. Histology showed metaplastic epithelium with parakeratosis. Note the thin seam of transformation zone on the anterior lip.

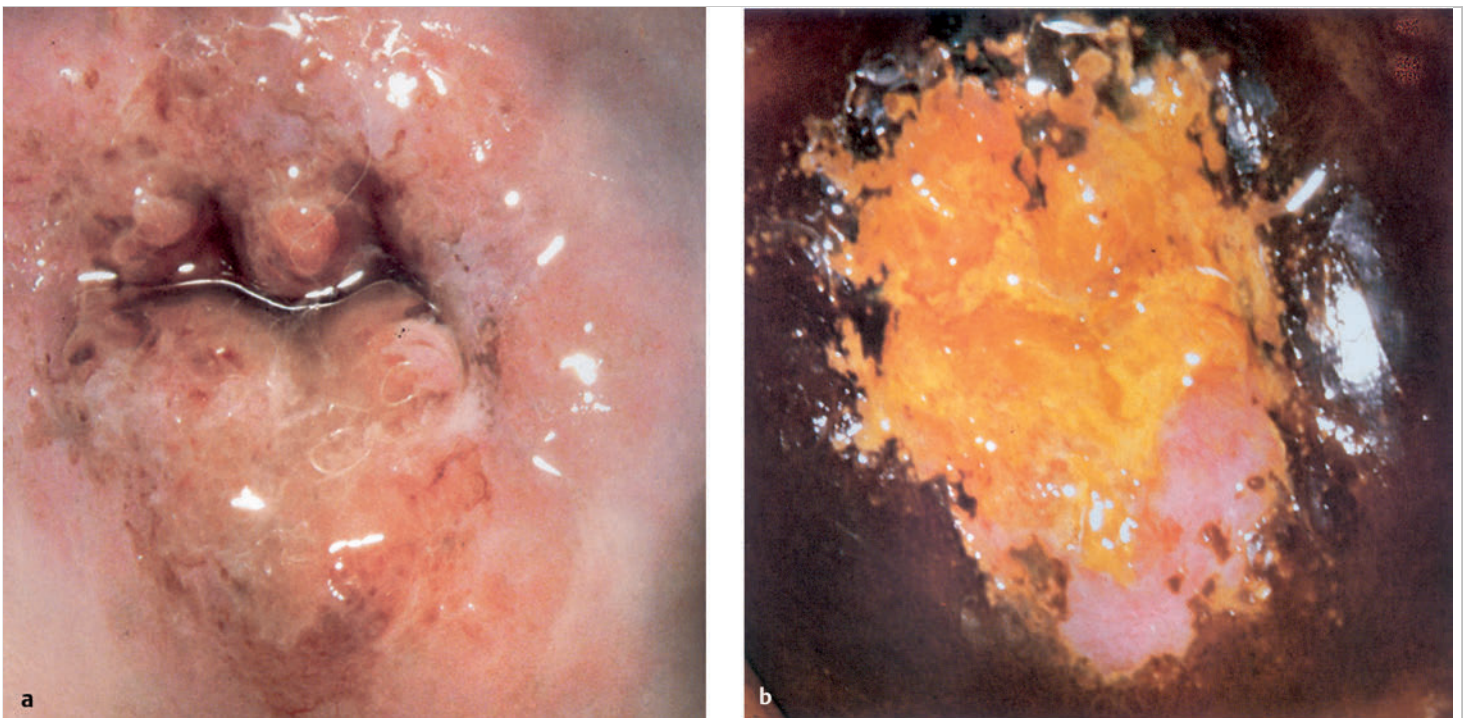


Fig. 8.56 (a) True erosion at the outskirts of an acetowhite epithelium. The steplike edge, with pathologic as well as normal squamous epithelium, is well shown in places. Biopsy of the whitish epithelium showed HSIL (CIN 2). (b) After application of iodine, the pathologic epithelium is typically iodine-yellow, whereas the erosion does not stain at all.

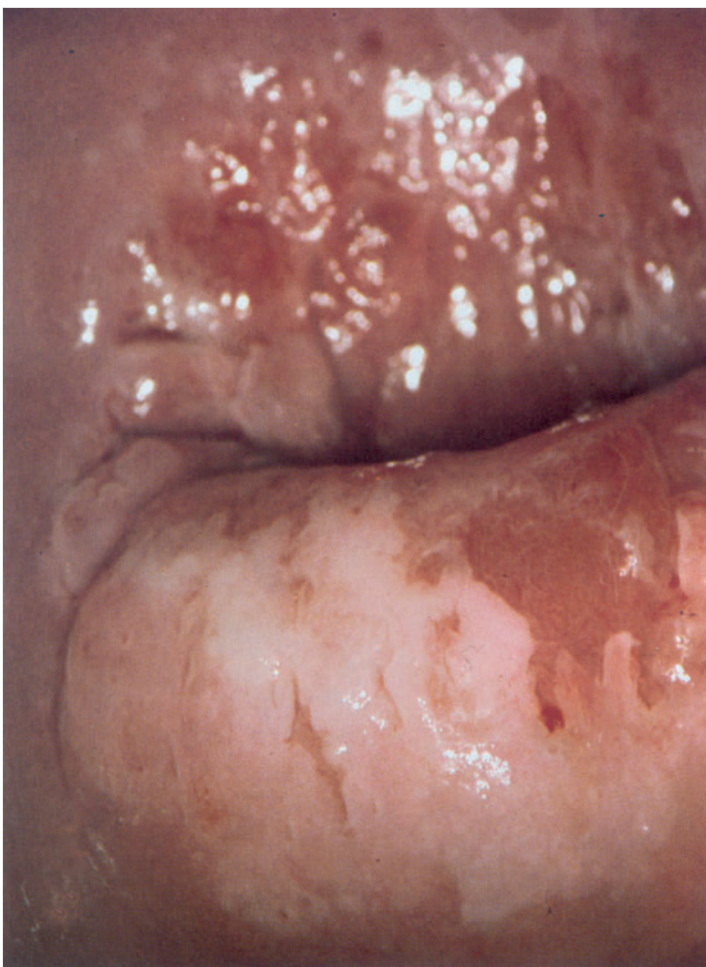

Fig. 8.57 Typical erosion in white epithelium. Epithelial denudation reveals the intensely red stroma. Histology of the whitish epithelium showed HSIL (CIN 3).

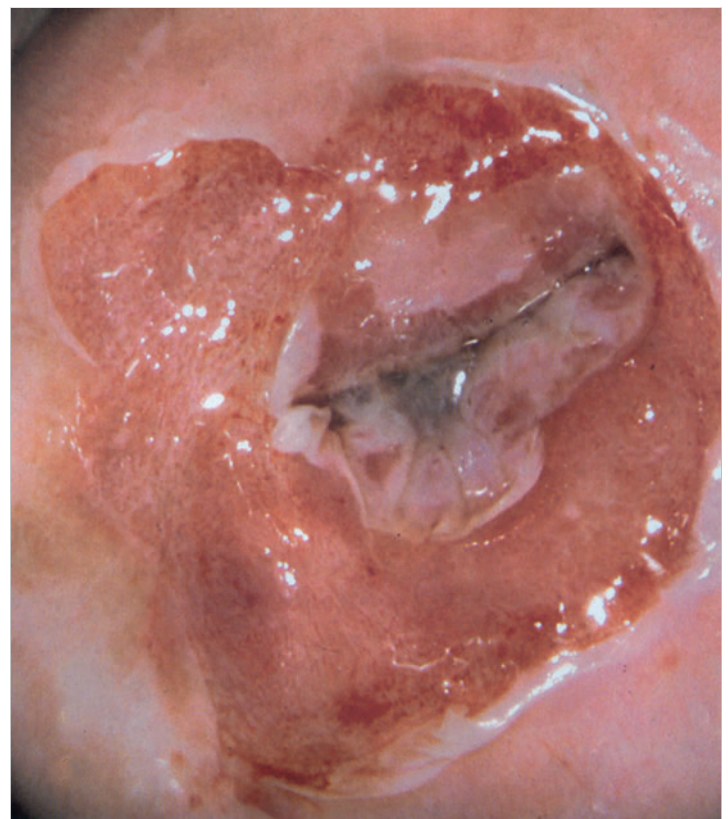

Fig. 8.58 Extensive erosion. Islands of HSIL (CIN 3) remain both toward the endocervical canal and bordering the peripheral, normal squamous epithelium. The texture of the stroma is exposed

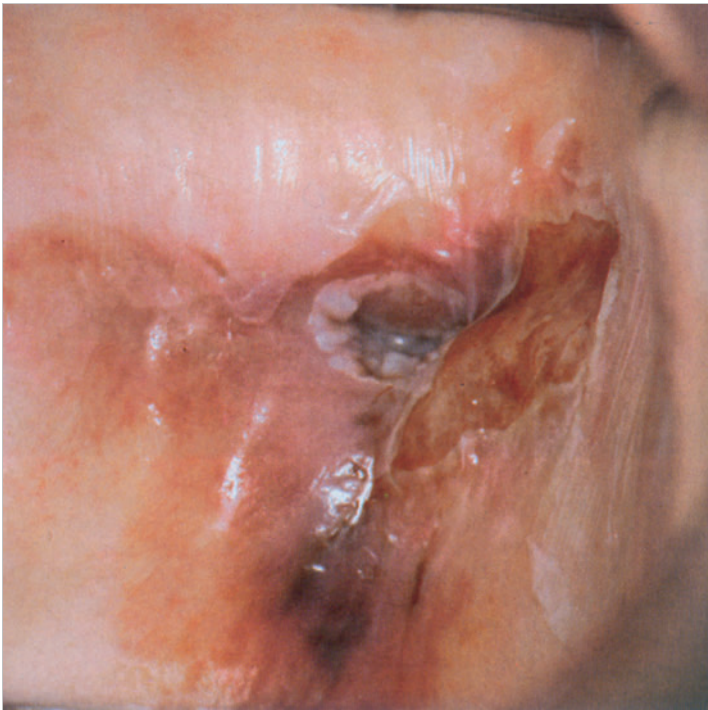


Fig. 8.59 Flat ulcer to the left of the external os. Its floor is uneven and yellowish to dark red. Histology showed squamous cell carcinoma (FIGO stage IB).

resistance; the sound advances as into warm butter. With normal tissues, the probe encounters firm elastic resistance.

8.2.7 Signs of Early Invasive Carcinoma

Colposcopic detection of small invasive lesions depends on how big and where the lesions are. Foci of early stromal invasion (ESI), which reach only a fraction of a millimeter into the cervical stroma, cannot be seen with the colposcope. Also, such foci arise more often from glands involved by SIL than from atypical surface epithelium (see Chapter 4). In the latter case, the colposcopic appearance is that of the parent epithelium.

The colposcopic signs of ESI are indirect. The likelihood of ESI increases with the surface extent of a lesion. Also, ESI is more common when simultaneously there are different types of epithelia. Some cases show all these features. Increased vascularity also suggests invasion (► Fig. 8.60, ► Fig. 8.61).

Although the likelihood of ESI increases with the size of a lesion, quite small or poorly vascularized lesions can be invasive. Some cases of ESI have surprisingly few colposcopic changes (► Fig. 8.62, ► Fig. 8.63, ► Fig. 8.64).

Similarly, colposcopic detection of *microinvasive carcinomas* depends on their size and location. If a microinvasive carcinoma

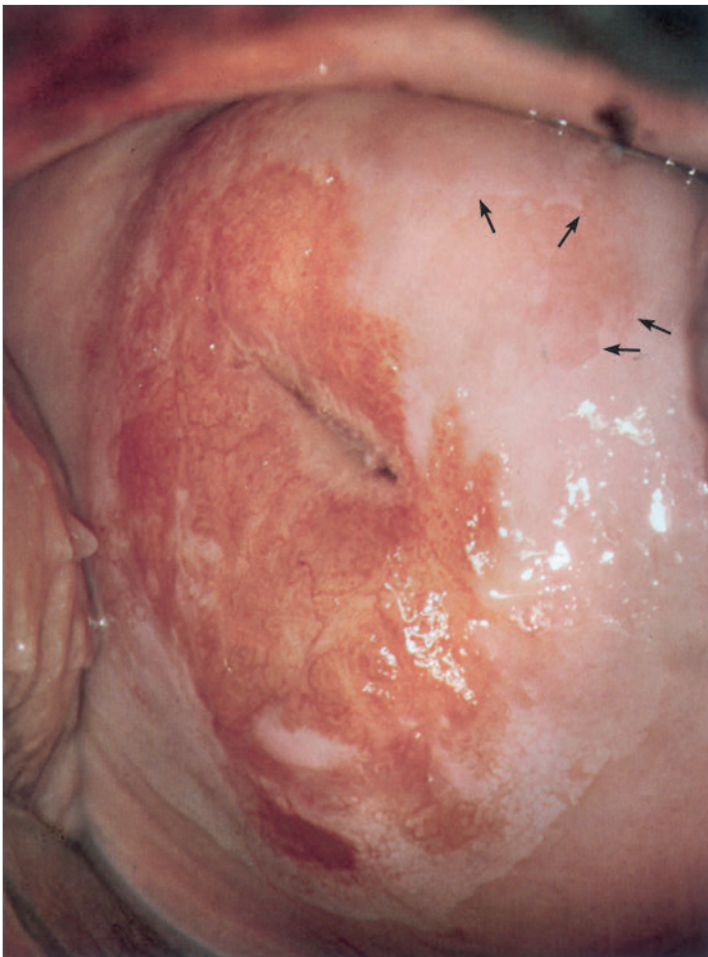


Fig. 8.60 Markedly vascular transformation zone. At the periphery, between 4 o'clock and 6 o'clock, there is a moderately coarse mosaic as well as clearly delineated mild keratosis. Conization and histology showed early stromal invasion (FIGO stage IA1) of a squamous lesion and metaplastic epithelium at the white plaques.

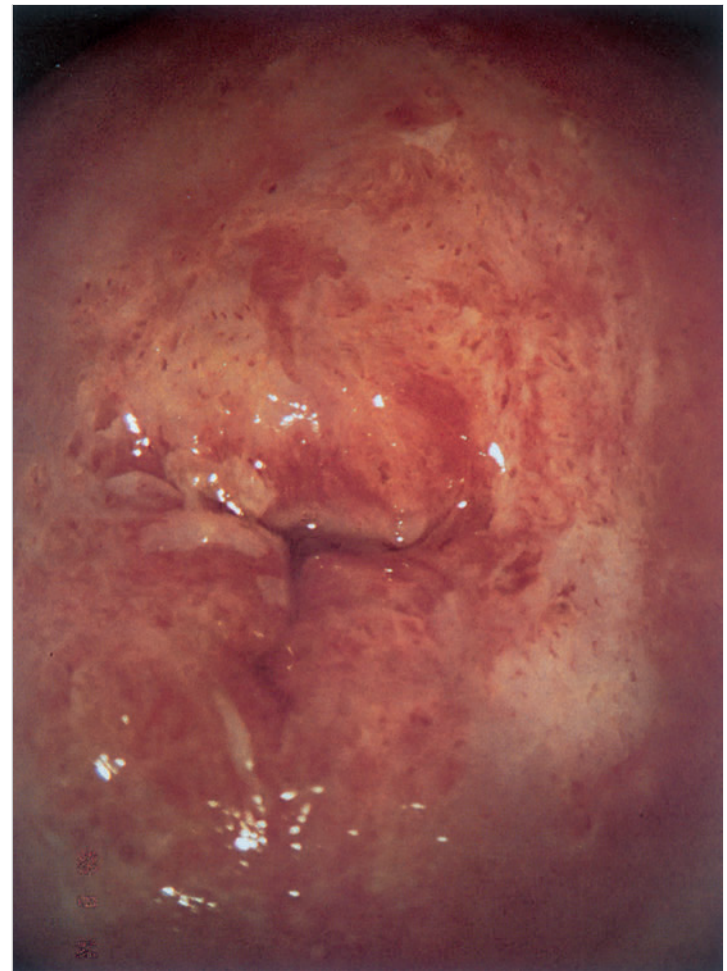

Fig. 8.61 Dense acetowhite epithelium with a strikingly coarse surface. There are irregularly located, comma-shaped vessels in the entire area. The conization specimen showed HSIL (CIN 2/3) and early stromal invasion (1A1 FIGO).

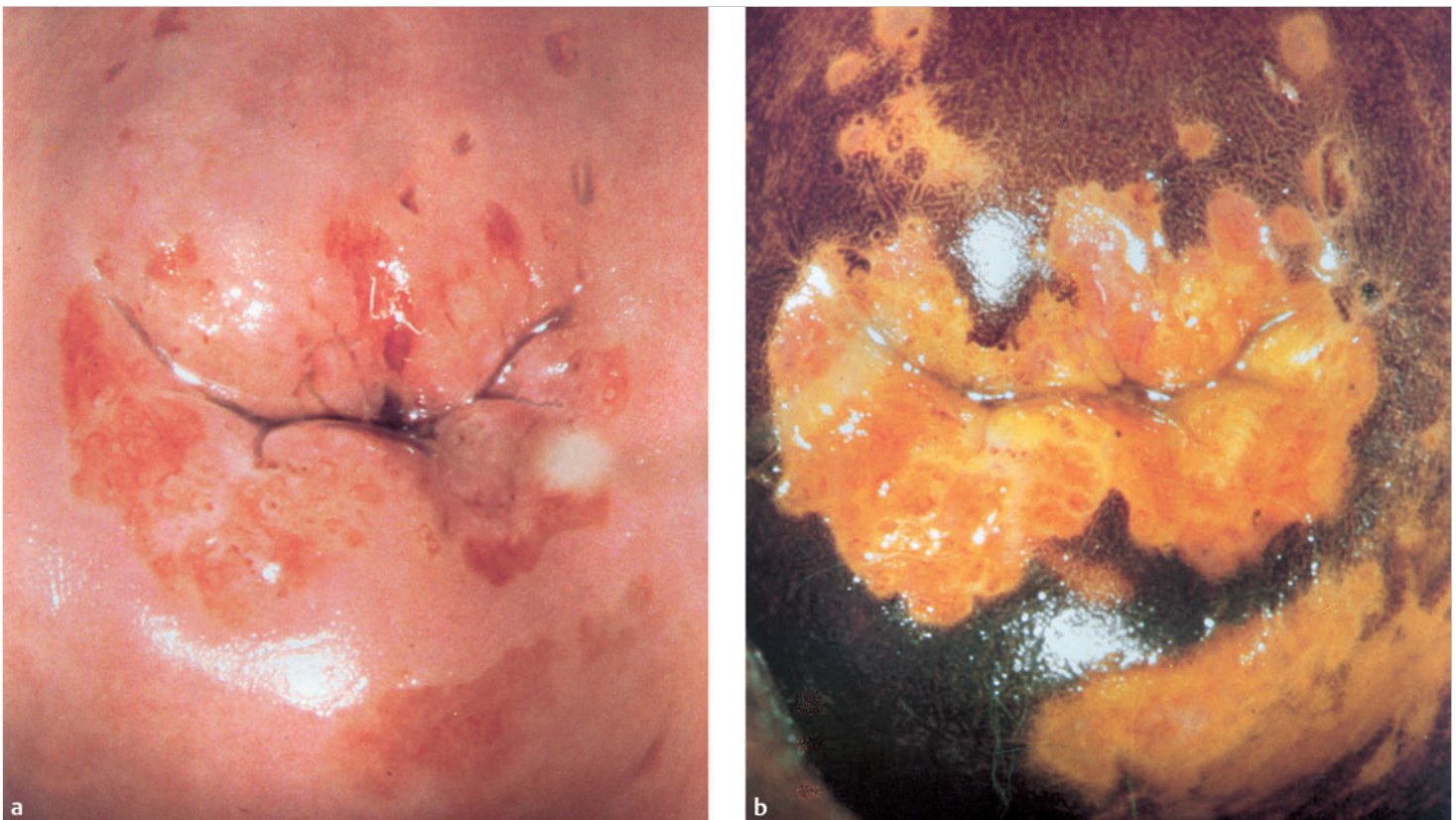


Fig. 8.62 (a) Acetowhite epithelium that merges imperceptibly with the periphery. Note the separate poorly circumscribed reddish area on the posterior lip. (b) The iodine-yellow area around the external os was HSIL (CIN 3) with early stromal invasion (1A1 FIGO). The isolated area on the posterior lip was inflammatory. The speckled brown lesion on the anterior lip is condylomatous colpititis (► Fig. 8.103).

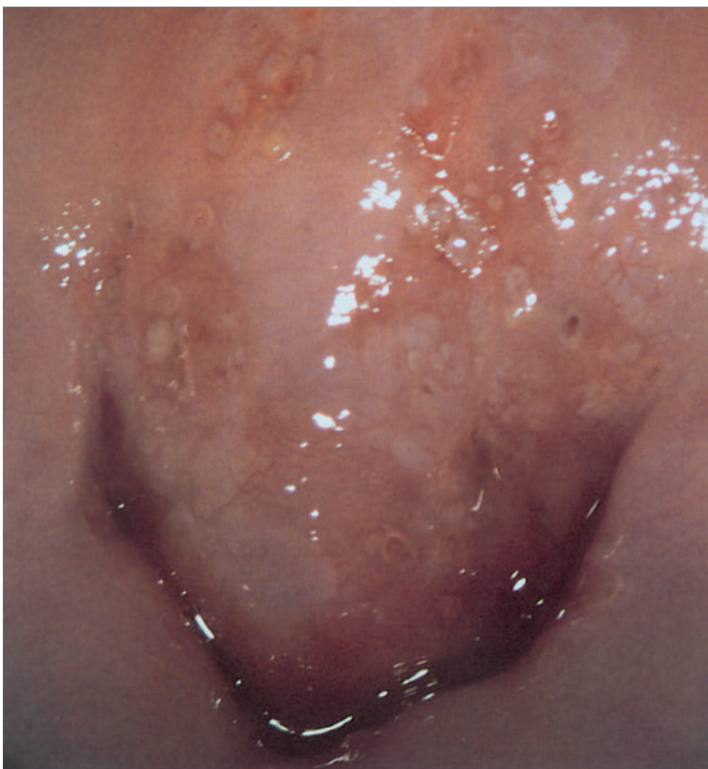

Fig. 8.63 Acetowhite epithelium with cuffed gland openings after application of acetic acid. The conization specimen showed HSIL (CIN 3) with early stromal invasion (FIGO stage 1A1).

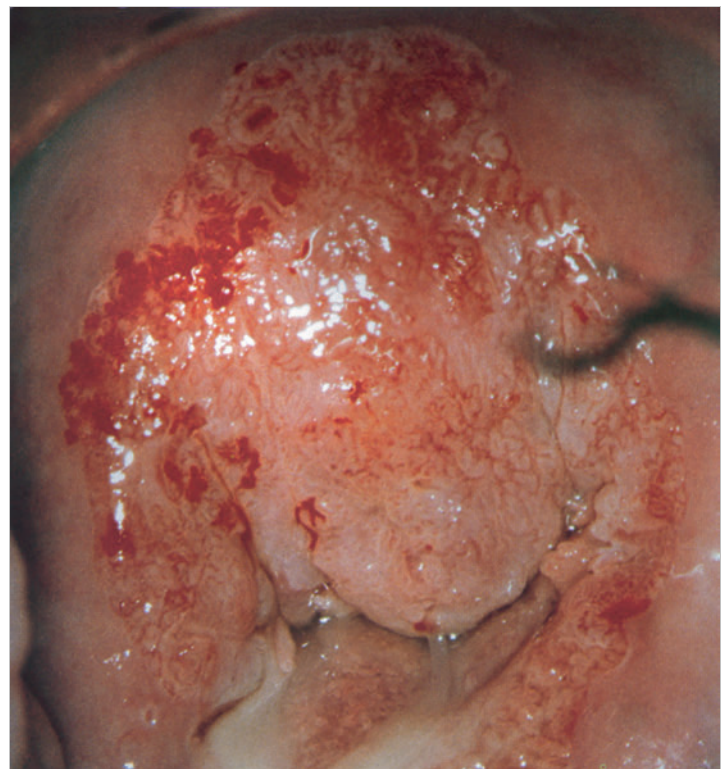


Fig. 8.64 Acetowhite epithelium and coarse mosaic after application of 3% acetic acid. Note the friability of the extensive lesion. Histology showed HSIL (CIN 3) with early stromal invasion (FIGO stage 1A1).

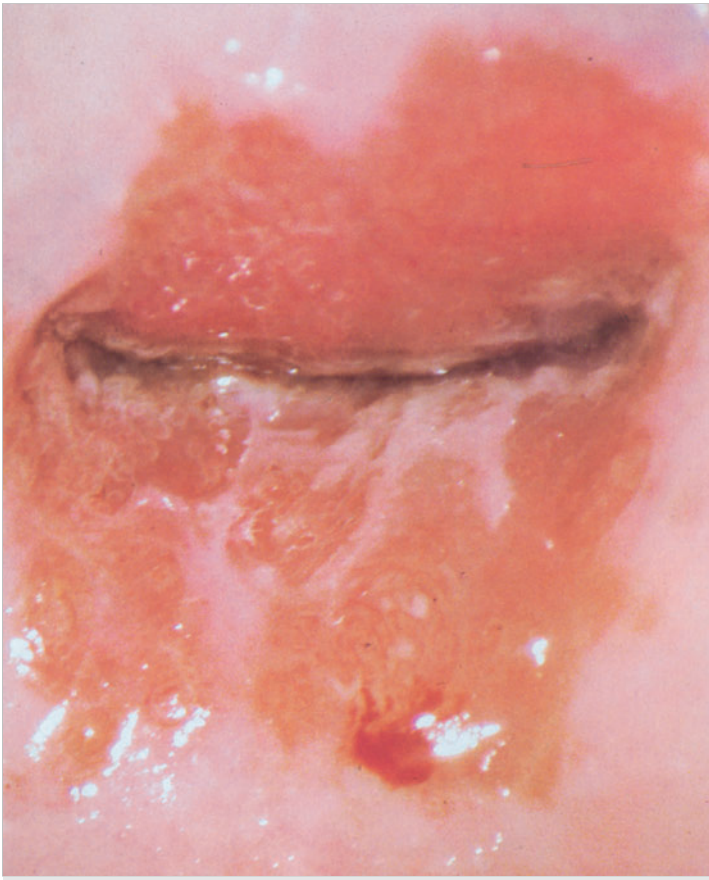

Fig. 8.65 White epithelium before acetic acid application harboring a FIGO stage IA2 microinvasive squamous cell carcinoma just above the bleeding point. Note the irregularly branching vessels. The neighboring reddish areas corresponded to HSIL (CIN 3). True erosion and regenerating epithelium can be seen in the vicinity of the external os on the posterior lip and regenerating epithelium on the anterior lip.

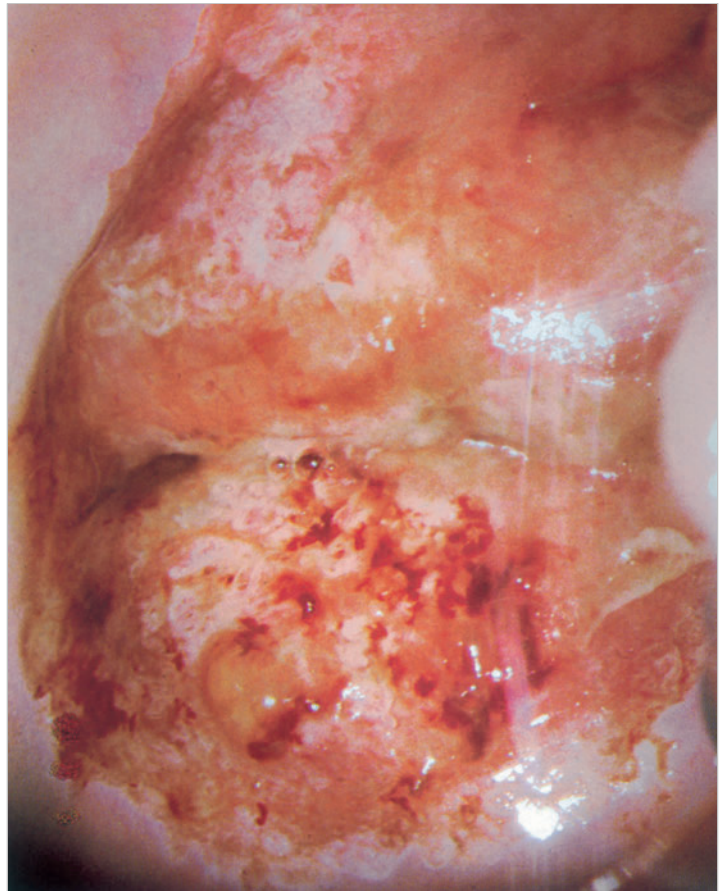

Fig. 8.66 Large area of white epithelium before application of acetic acid. The surface of the posterior lip is bulging because of the presence of a small FIGO stage IB1 carcinoma. Note the extravasation of blood where the vessels are atypical.

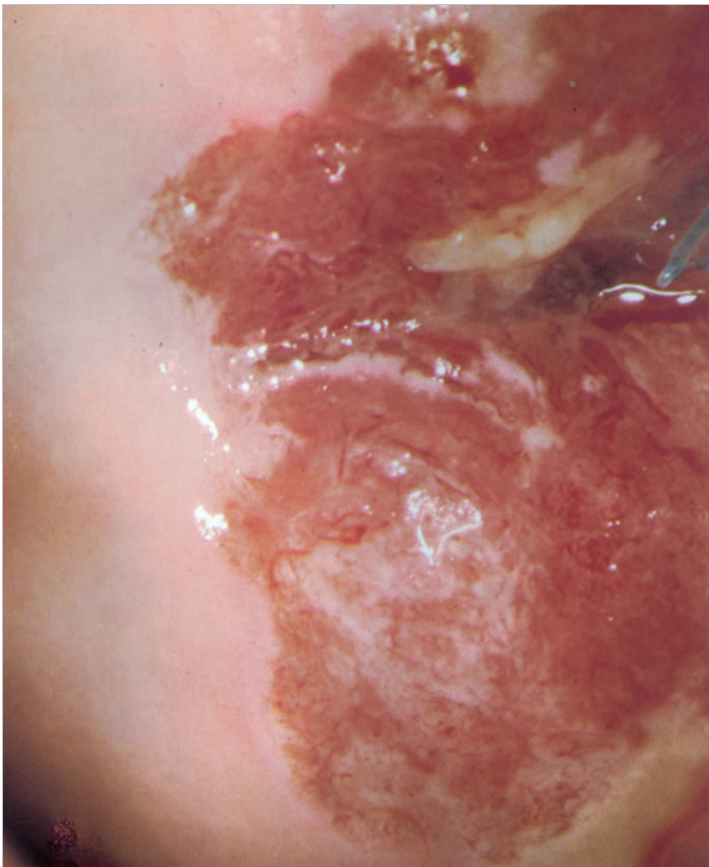


Fig. 8.67 Stage IA2 microinvasive carcinoma (squamous cell) producing a small bulge on the posterior lip. Atypical vessels course over the white surface.

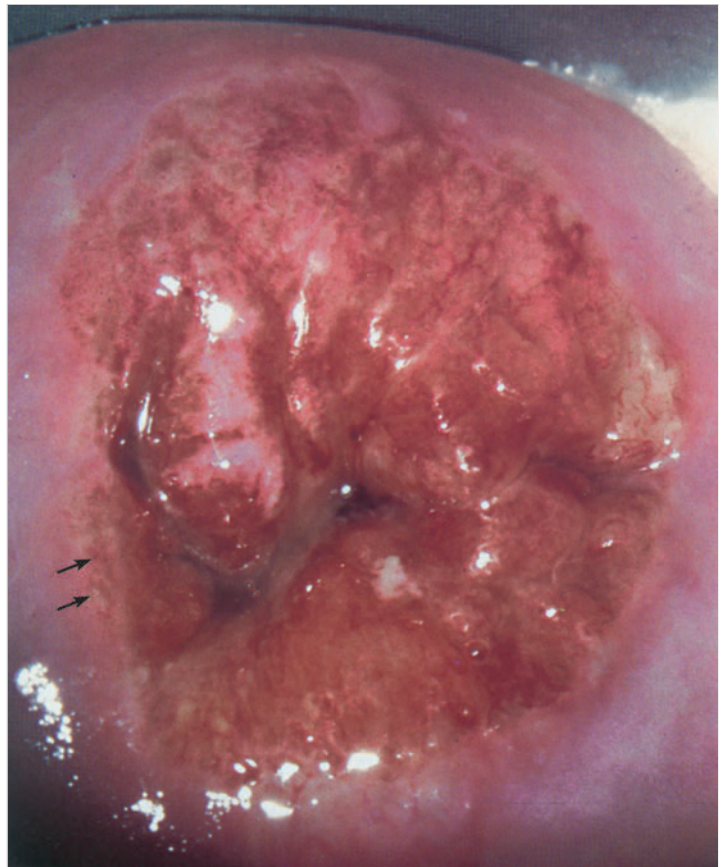


Fig. 8.68 Vascular transformation zone showing focal hemorrhages. The microinvasive carcinoma (1A2 FIGO) occupying the left lateral recess of the external os is easily overlooked.

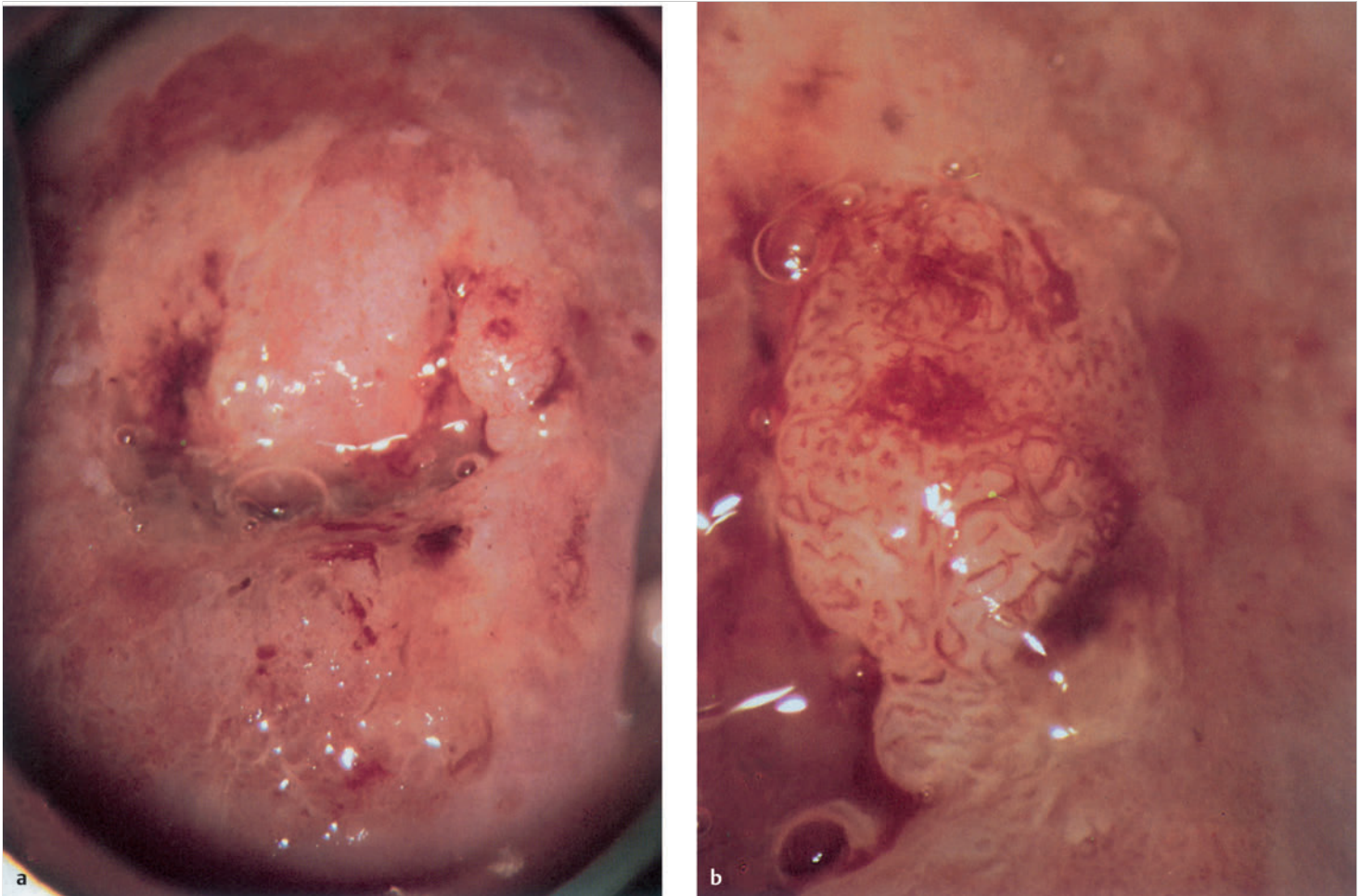


Fig. 8.69 (a) Acetowhite epithelium with a coarse surface. The effect of acetic acid is especially marked on the anterior lip: white epithelium with a small polypoid lesion in the left corner of the external os. (b) At high magnification, the tumor shows numerous atypical vessels. The polypoid structure is a small, exophytic stage IB1 carcinoma (squamous cell).

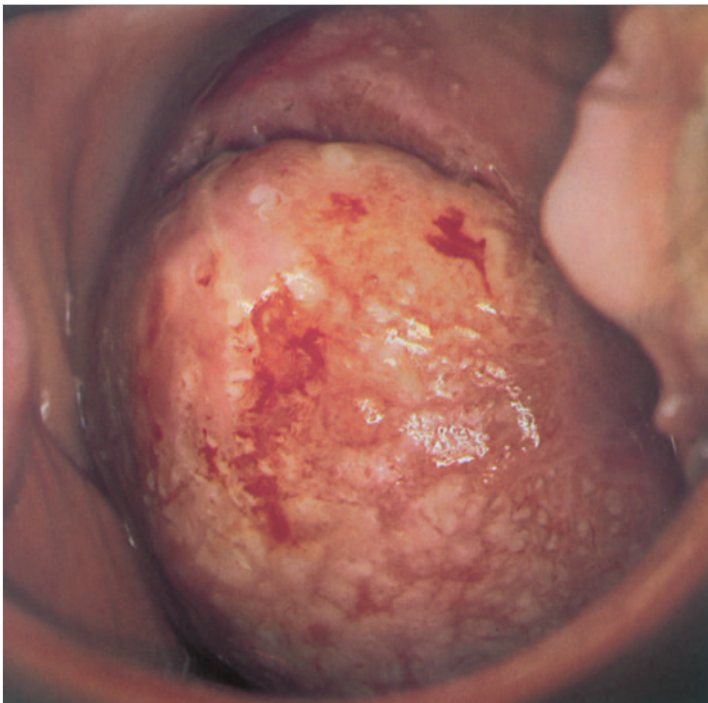

Fig. 8.70 Exophytic stage IB1 squamous cell carcinoma on the posterior lip. The tip is ulcerated.

is entirely within the cervical canal, the ectocervix will show no clue. Ectocervical lesions characterized by focal collections of atypical vessels are highly suspicious for microinvasion. Atypical vessels are invariably restricted to the invasive focus (► Fig. 8.65, ► Fig. 8.66, ► Fig. 8.67, ► Fig. 8.68). The vessels are often drawn out, have an irregular course, and are prone to bleed.

Somewhat larger cervical cancers can produce a slight bump on the surface that gives away their location (► Fig. 8.66, ► Fig. 8.67), or they can form a confined polypoid lesion (► Fig. 8.69a,b). The diagnosis of an invasive lesion arising within an already vascular TZ is difficult, if not impossible. Hints of invasion in such cases may be sought only retrospectively by carefully correlating the colposcopic findings with the histology of the conization specimen (► Fig. 8.68).

8.2.8 Invasive Carcinoma

Invasive carcinomas on the ectocervix can be seen with the naked eye. Tumors located entirely within the cervical canal can be seen better with the colposcope, but only if the os is somewhat gaping. In all other cases, colposcopy merely confirms the gross findings. The degree of distortion of the ectocervical contour depends on the growth pattern of the tumor. Exophytic lesions protrude into the vagina as fungating tumors of varying size (► Fig. 8.70, ► Fig. 8.71, ► Fig. 8.76). In contrast, purely endophytic neoplasms present merely as red or white eroded areas, the true nature of

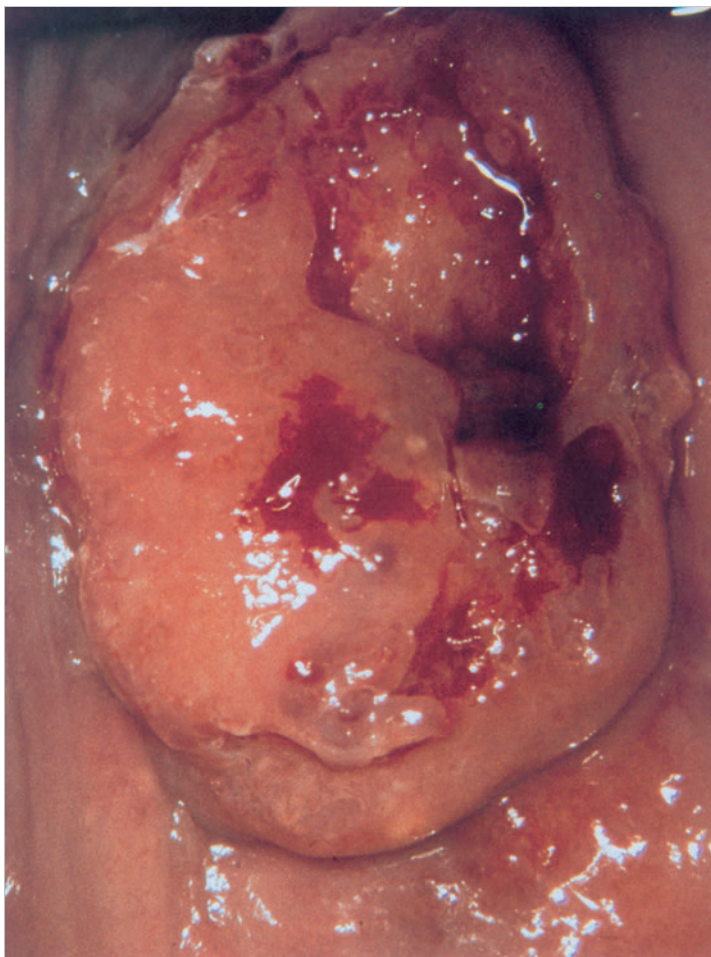

Fig. 8.71 Exophytic FIGO stage IB1 cervical carcinoma measuring 4×3 cm.

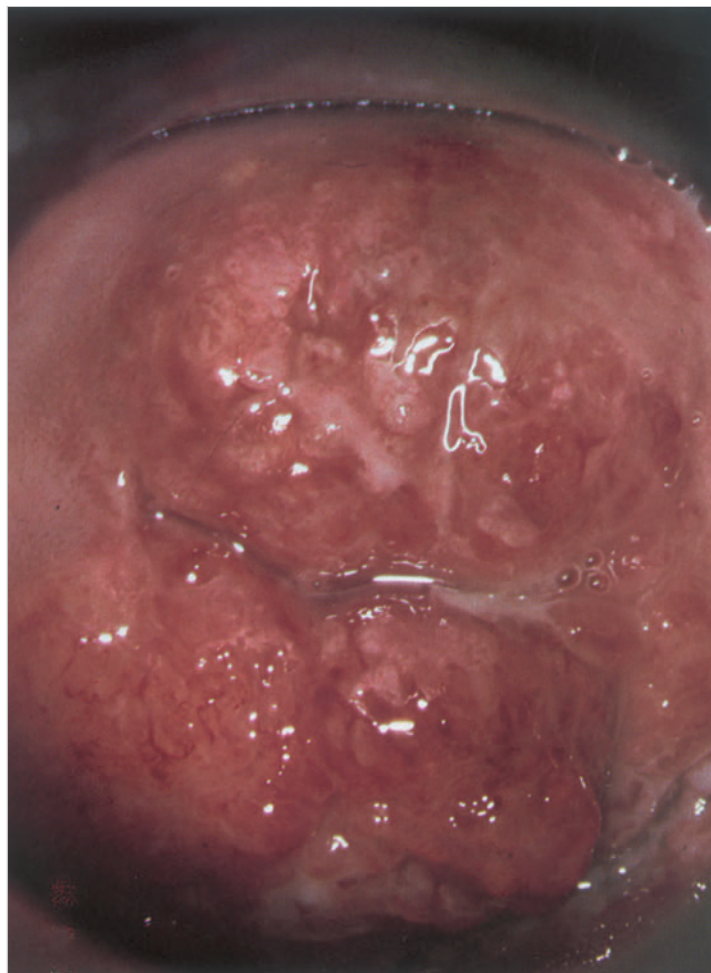


Fig. 8.73 This endophytic FIGO stage IB1 squamous cell carcinoma could be mistaken for white epithelium. The markedly atypical blood vessels on the posterior lip are associated invasive carcinomas.

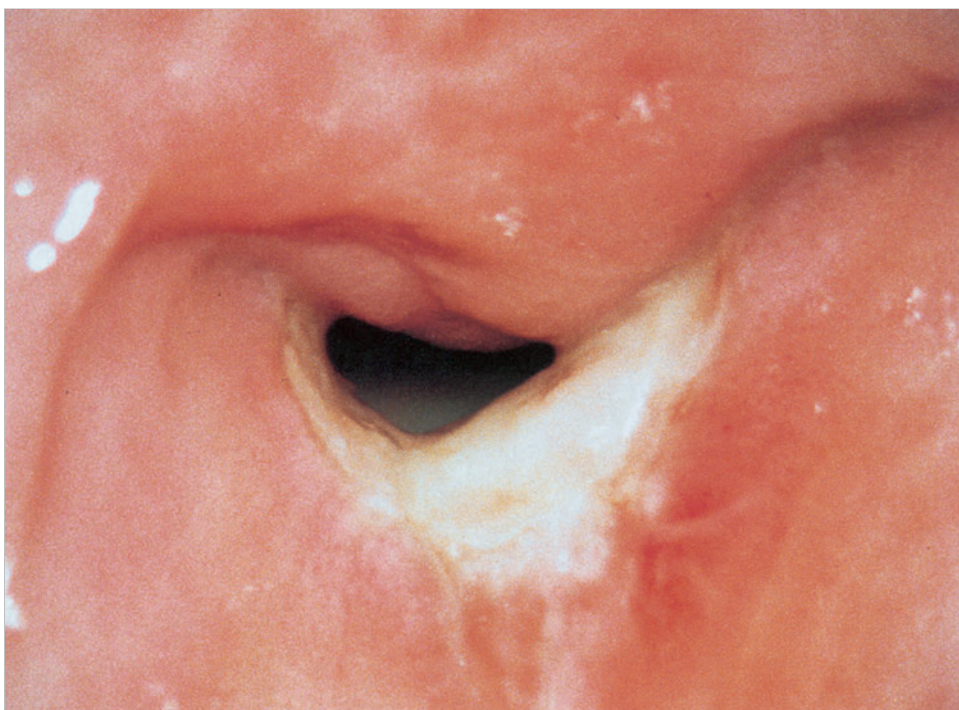

Fig. 8.72 Endophytic stage IB2 squamous carcinoma. Colposcopy shows a patulous external os and leukoplakia on the posterior lip of the cervix.

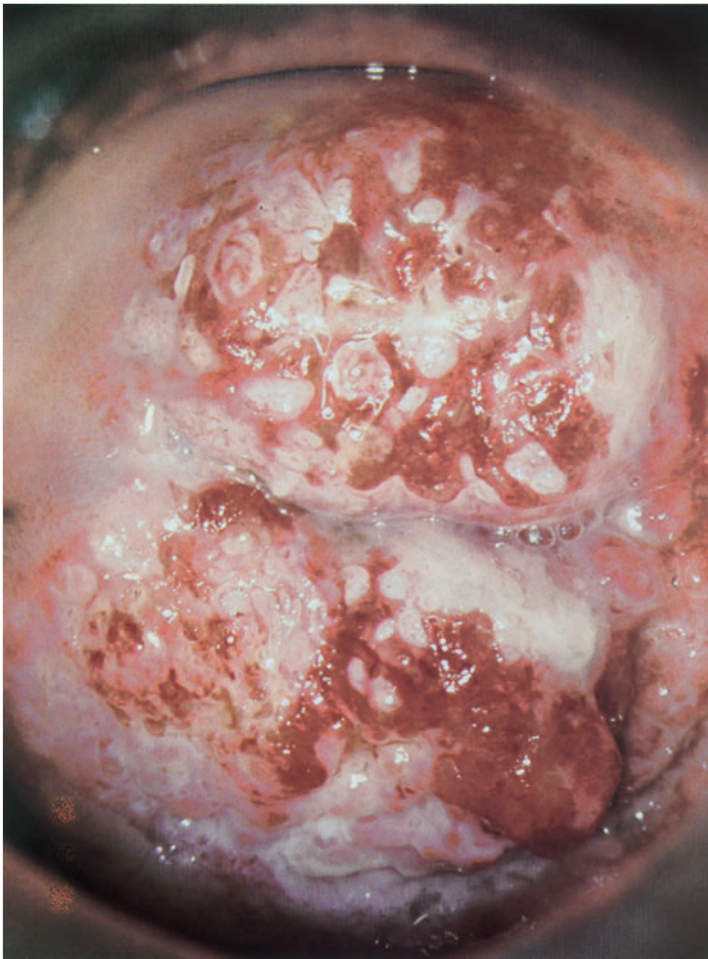

Fig. 8.74 Endophytic FIGO stage IB1 squamous cell carcinoma with marked hyperkeratosis.

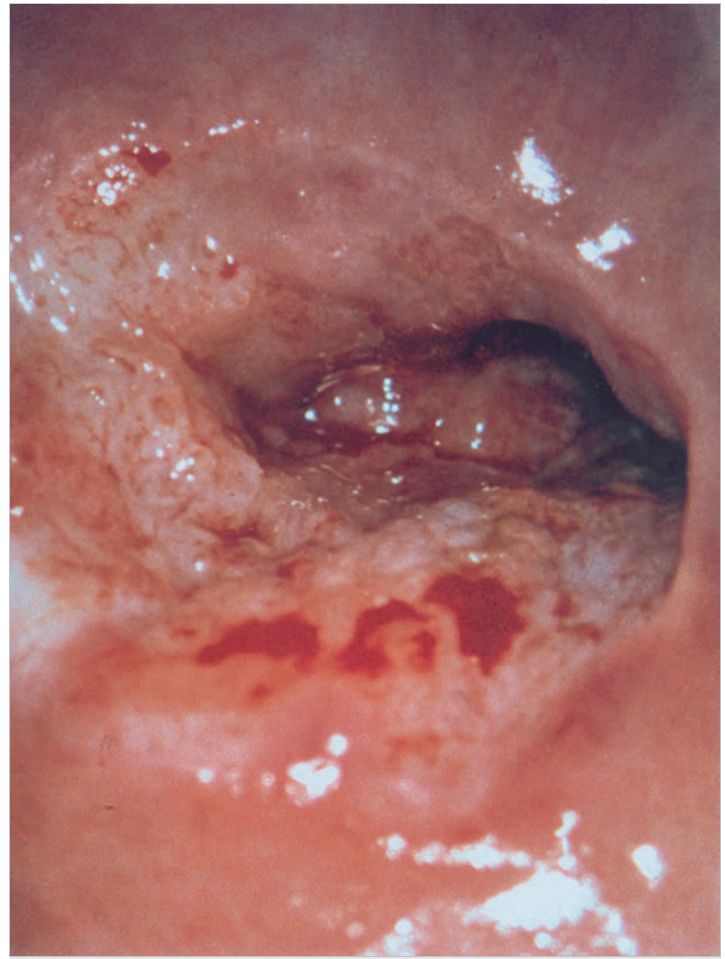


Fig. 8.75 FIGO stage IB1 squamous cell carcinoma after application of 3% acetic acid. The vessels are atypical and friable, and the surface is irregular.

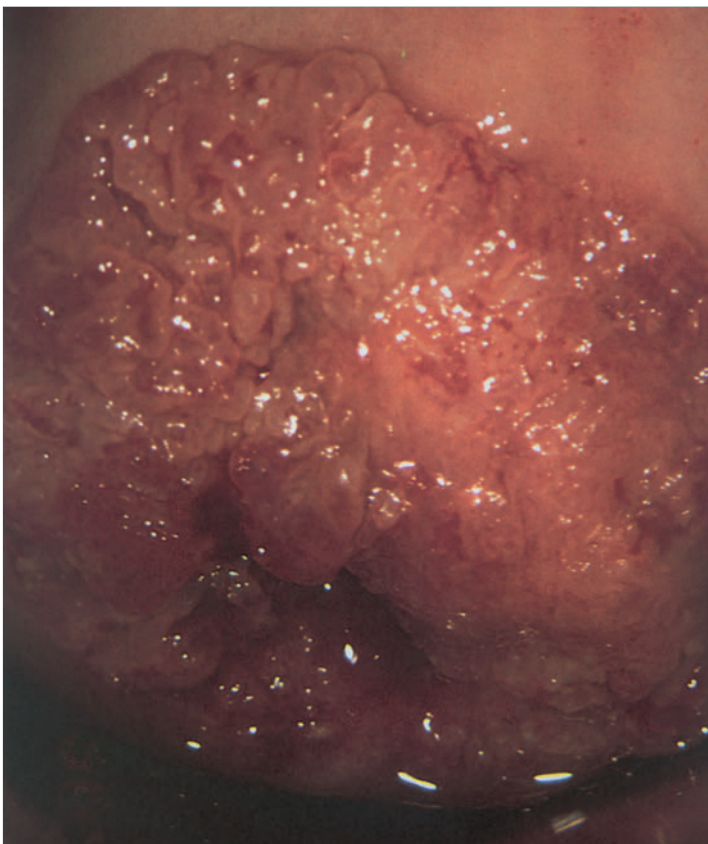


Fig. 8.76 Exophytic, papillary verrucous carcinoma around the external os (FIGO stage IB1).

which can be recognized only by their papillary surface and atypical vessels (► Fig. 8.75). Flat endophytic carcinomas with ulcerated surfaces can be difficult to diagnose both with the naked eye and with the colposcope (► Fig. 8.72). In such cases, palpation and probing with a Chrobak's sound (► Fig. 5.5) are of value. Most invasive carcinomas are partly exophytic and partly endophytic, and their diagnosis should pose no difficulty. Most carcinomas surround the external os (► Fig. 8.71, ► Fig. 8.78). Less often, one or only part of one lip is involved (► Fig. 8.73, ► Fig. 8.80).

The surface of invasive tumors is usually irregularly fissured (► Fig. 8.79) like a cauliflower. If the papillae are somewhat finer and more regular, they can be confused with ectopy. The degree of ulceration and tissue destruction is greater in more advanced cancers. Occasionally, tumors present as smooth sessile polyps (► Fig. 8.80), to be distinguished from benign polyps by their vasculature and by use of Chrobak's sound (► Fig. 5.5).

An endophytic tumor with a keratotic surface can pose a further diagnostic challenge (► Fig. 8.74). Performing biopsies of keratotic lesions will avoid missing lesions hidden by keratin.

Invasive cancers afford an excellent opportunity to study all kinds of atypical vessels (► Fig. 8.69, ► Fig. 8.141). This should be done after the cervix is cleansed with a dry swab and before applying acetic acid, which makes the vessels blanch (► Fig. 8.77a,b). Invasive lesions also become more prominent and whitish with acetic acid (► Fig. 8.77). After acetic acid, the criteria for the evaluation of atypical epithelia can be applied to preinvasive lesions, which frequently surround an invasive tumor (► Fig. 8.79).

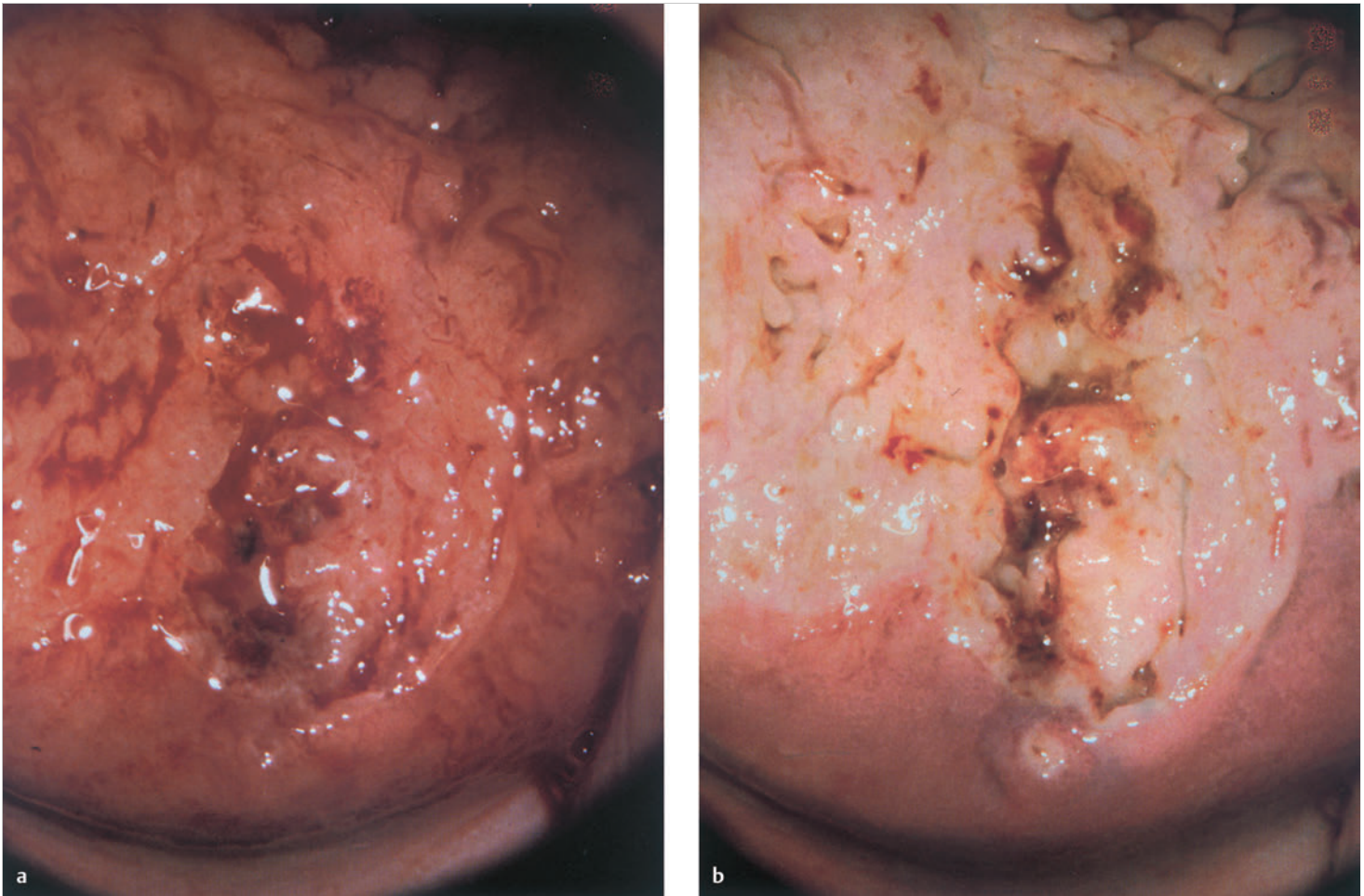


Fig. 8.77 (a) An exophytic FIGO stage IB1 squamous cell carcinoma with a variety of atypical blood vessels. (b) Application of acetic acid suppresses the vascular pattern and turns the background white.

8.2.9 Adenocarcinoma in Situ and Microinvasive Adenocarcinoma

There are no colposcopic images that are pathognomonic for the presence of an adenocarcinoma in situ (AIS) or a microinvasive adenocarcinoma. However, surface patterns indicative of AIS are lesions overlying columnar epithelium not contiguous with the squamocolumnar border, lesions with large gland openings, papillary lesions showing epithelial budding, and variegated red and white lesions.⁹ Because these lesions usually occur with SIL, one finds the colposcopic changes suggesting SIL (► Fig. 8.81, ► Fig. 8.82). Furthermore, AIS is usually located in glands or crypts; when on the surface, it is friable and often eroded (► Fig. 8.81, ► Fig. 8.83). The somewhat larger microinvasive adenocarcinoma can occasionally be seen with the colposcope but cannot reliably be distinguished from its squamous cell counterpart (► Fig. 8.83).

8.3 Miscellaneous Colposcopic Findings

8.3.1 Nonsuspicious Iodine-Yellow Area

Regular use of the Schiller (iodine) test frequently shows sharply circumscribed iodine-yellow areas that are otherwise either not

visible or overlooked. Such areas are especially striking if the cervix at first sight appears completely normal (► Fig. 8.84a). If the patient can be re-examined after the iodine reaction has abated, the previously iodine-yellow area will appear grayish and sharply demarcated.

Besides such unsuspected and isolated foci, iodine-yellow areas are also found in combination with other colposcopic lesions; the latter are therefore really bigger and have different outlines from first suspected (► Fig. 8.85b).

Colposcopically nonsuspicious iodine-yellow areas are usually caused by benign metaplastic epithelium. The risk of intraepithelial neoplasia is low.

Transformation that has resulted in metaplastic squamous epithelium with colposcopic findings of a nonsuspicious iodine-yellow area will not undergo further change (► Fig. 8.86a–c).

8.3.2 Congenital Transformation Zone

The congenital TZ is a colposcopic finding of a large iodine-yellow area extending into the anterior or posterior fornix (► Fig. 8.87). This is a relatively common finding (4%), and the colposcopist should be thoroughly familiar with its appearance.¹⁰ The origin of this finding is unclear. It appears to be a variant of müllerian epithelial differentiation.^{11,12}

The epithelium is nonglycogenated and is faintly acetowhite; usually the degree of acetowhiteness is very minor and may be difficult to see. It can be recognized clearly after the application

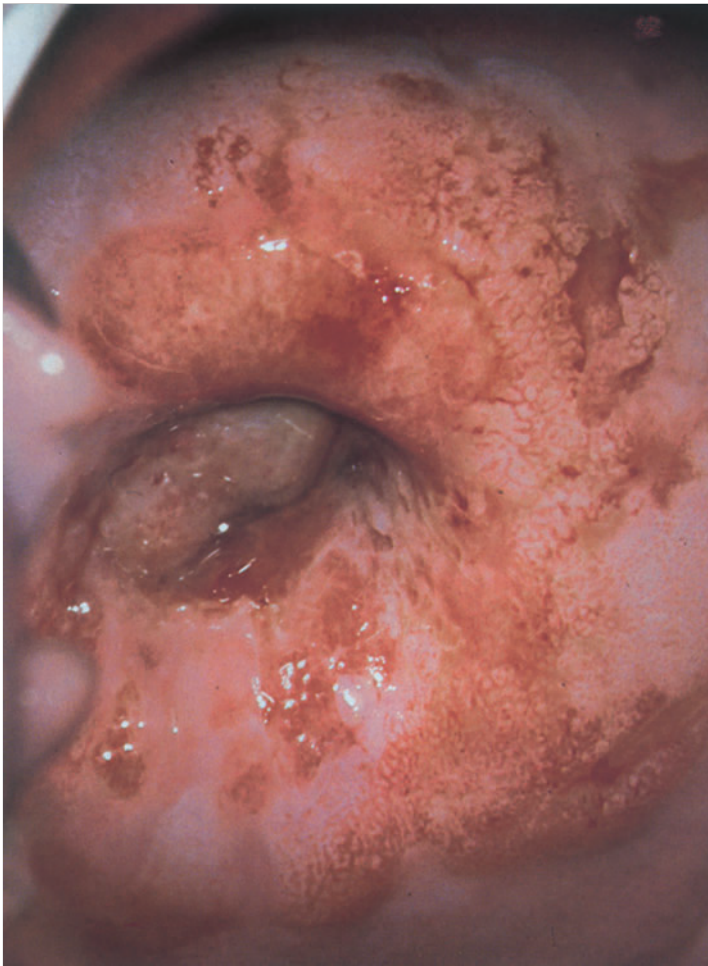


Fig. 8.78 Margin of HSIL (CIN 3) around a FIGO stage IB1 squamous cell carcinoma situated predominantly in the canal. Note the flat ulcer on the anterior lip surrounded by a coarse mosaic.

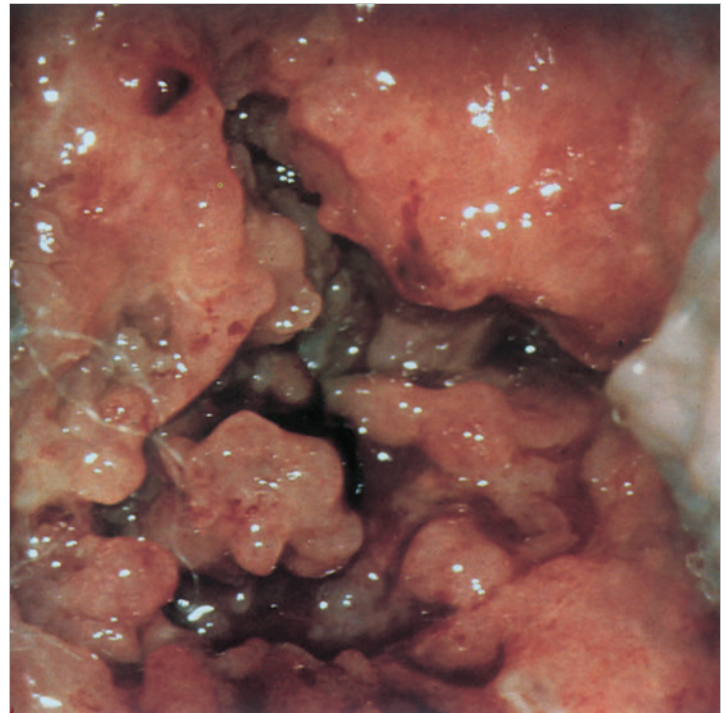

Fig. 8.79 Deeply fissured and coarsely papillary FIGO stage IIB squamous cell carcinoma. The vascular pattern is not pronounced.

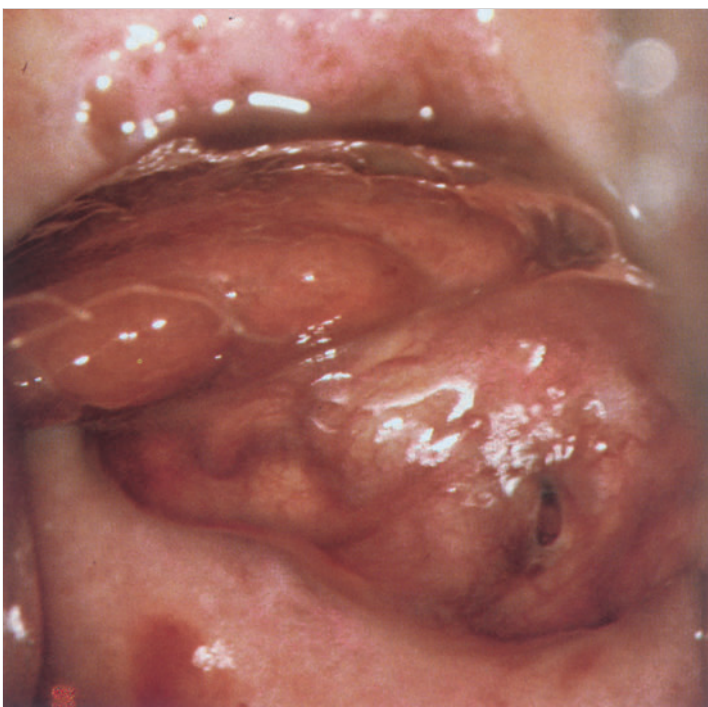


Fig. 8.80 Polypoid FIGO stage IB1 squamous cell carcinoma, which could be mistaken for a large benign cervical polyp. The color and blood supply of the polyp lower down resemble a nabothian follicle.

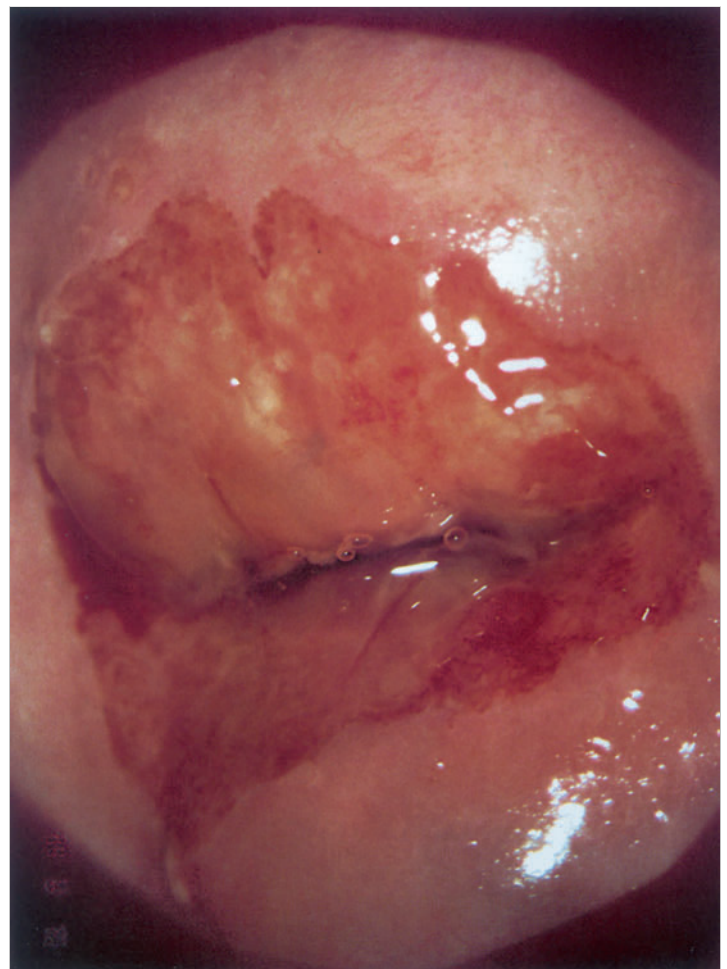


Fig. 8.81 White epithelium and a suspicious vascular pattern. The conization specimen showed LSIL (CIN 1) and HSIL (CIN 3) as well as an adenocarcinoma in situ (AIS) on the ectocervix. The latter was present both in glands and in the superficial columnar epithelium.

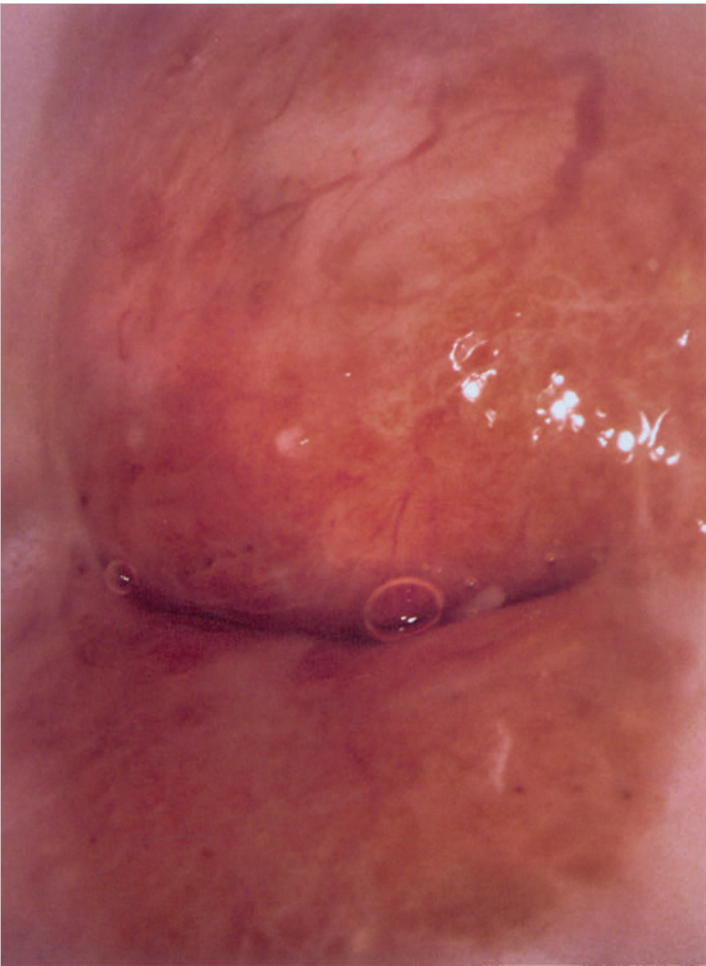

Fig. 8.82 White epithelium with a few gland openings. Histology showed HSIL (CIN 2) on the ectocervix and an adenocarcinoma in situ (AIS) in the lower part of the cervical canal.

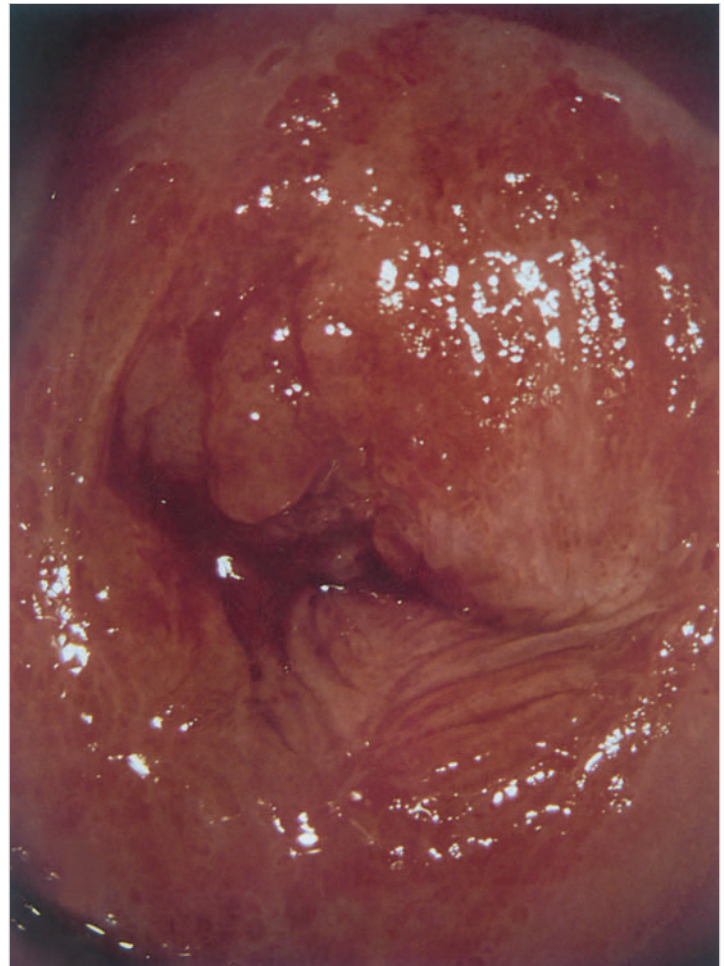


Fig. 8.83 Large, partly eroded transformation zone. The rugae of the everted cervical mucosa are still visible. Histology of the whitish areas showed HSIL (CIN 2) and, on the left side of the cervical os, a 10 × 3-mm adenocarcinoma (FIGO stage IB1).

of Schiller's iodine. It has histologic features in common with squamous metaplasia.

A congenital TZ does not require biopsy or treatment.

8.3.3 Condylomatous Lesions

Colposcopy is important for the recognition of flat condylomatous lesions on the cervix. Such changes closely mimic suspicious findings^{13,14,15} but are benign and can be reversible (see section 4.1.8). Condylomatous lesions (► Fig. 8.47, ► Fig. 8.48, ► Fig. 8.88, ► Fig. 8.89, ► Fig. 8.90, ► Fig. 8.91, ► Fig. 8.92, ► Fig. 8.93, ► Fig. 8.94, ► Fig. 8.95, ► Fig. 8.96, ► Fig. 8.97, ► Fig. 8.98) can coexist with SIL.

Condylomata acuminata are usually straightforward to diagnose colposcopically. However, an isolated condyloma in the region of the external os can be mistaken for an exophytic carcinoma (► Fig. 8.88). Chrobak's probe can be a useful diagnostic aid (see Chapter 5). The surface of condylomatous lesions is classically papillary (► Fig. 8.88, ► Fig. 8.89, ► Fig. 8.90, ► Fig. 8.94a,b, ► Fig. 8.95). The structural details, however, can be concealed by keratin, resulting in a smooth, shiny, mother-of-pearl-like surface (► Fig. 8.91, ► Fig. 8.92). Not uncommonly, the papillae are fine and finger-like (► Fig. 8.96). The color of condylomas varies according to the degree of keratinization and ranges from white and grayish red to intense red.

Condylomas are often multiple (► Fig. 8.88, ► Fig. 8.94) and vary in size, providing a good opportunity to study their development. Exophytic condylomas can intermingle with flat lesions (► Fig. 8.94). Higher magnification reveals the presence of blood vessels within the papillae of condylomas. The vessels can be comma, corkscrew, or staghorn in shape and can appear suspicious because of their relatively large caliber (► Fig. 8.47a,b). Flat and smooth lesions tend to have a distinctive pearly surface as a result of hyperkeratosis (► Fig. 8.92, ► Fig. 8.94). No criteria have been described to distinguish colposcopically between typical and atypical condylomas. However, the latter may have a coarser structure producing coarse punctation or mosaic by analogy with SIL (CIN) and metaplastic epithelium.

Application of iodine (Schiller test) shows that condylomatous cells still contain some glycogen. A stippled, variegated appearance can be produced by focal keratinization (► Fig. 8.93b, ► Fig. 8.47b, ► Fig. 8.48a,b). Occasionally, glycogen storage by condylomatous epithelium produces the unusual colposcopic appearance of *iodine-positive mosaic or punctation* (► Fig. 8.97a,b). It is unclear whether this picture is typical of condylomas, but at any rate, such mosaics are caused by glycogen-containing epithelium associated with tall stromal papillae. Histologically, the epithelium in such cases shows features suggestive of flat condylomas. An iodine-positive mosaic pattern can be produced by colposcopic lesions that, before the Schiller

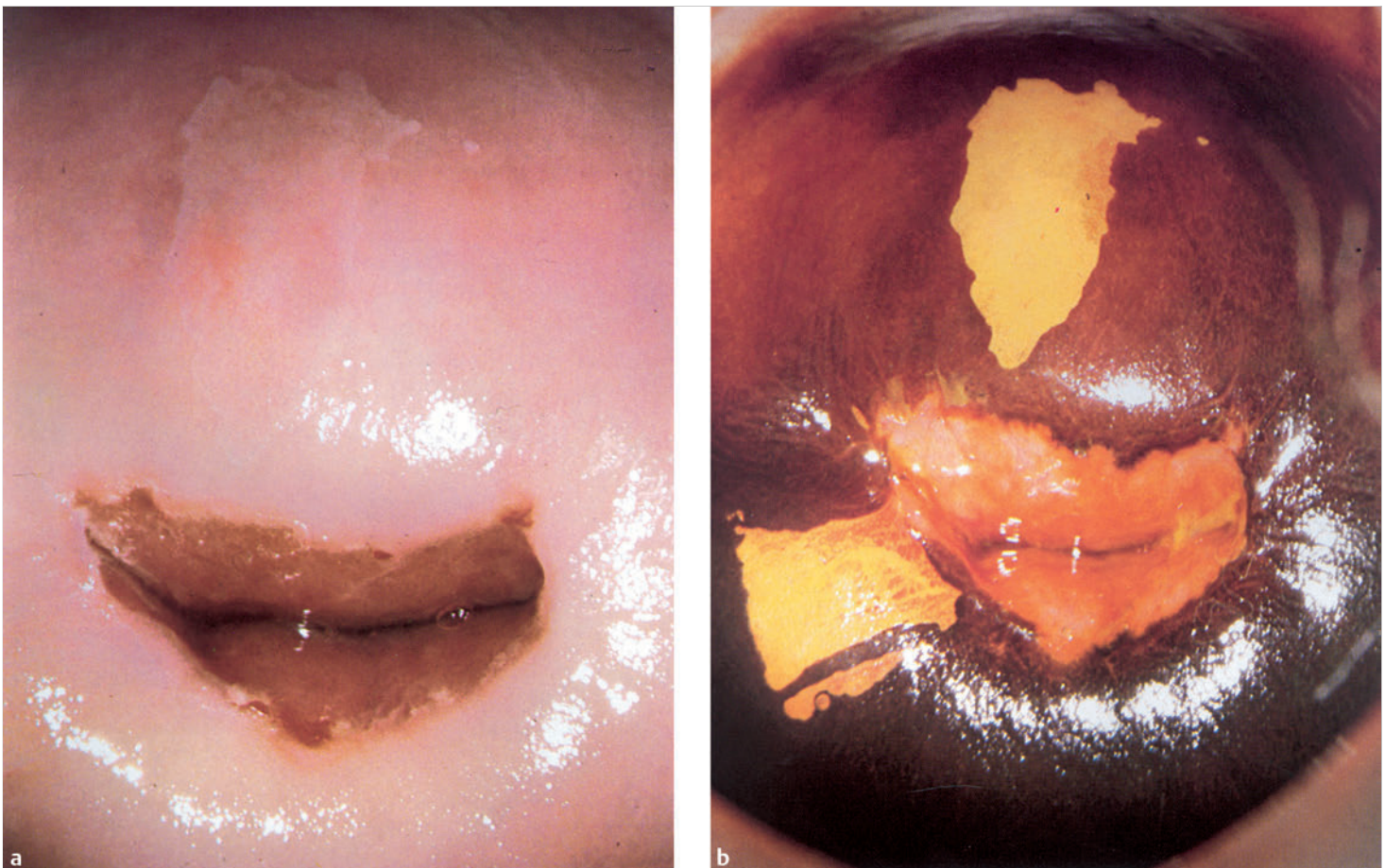


Fig. 8.84 (a) Only nuances in color suggest a lesion arising in original squamous epithelium. Such a lesion can be easily overlooked at routine colposcopy. (b) After application of iodine, the bright yellow area stands out. There is also a second yellow lesion, hardly recognizable in (a). Histology showed metaplastic epithelium.

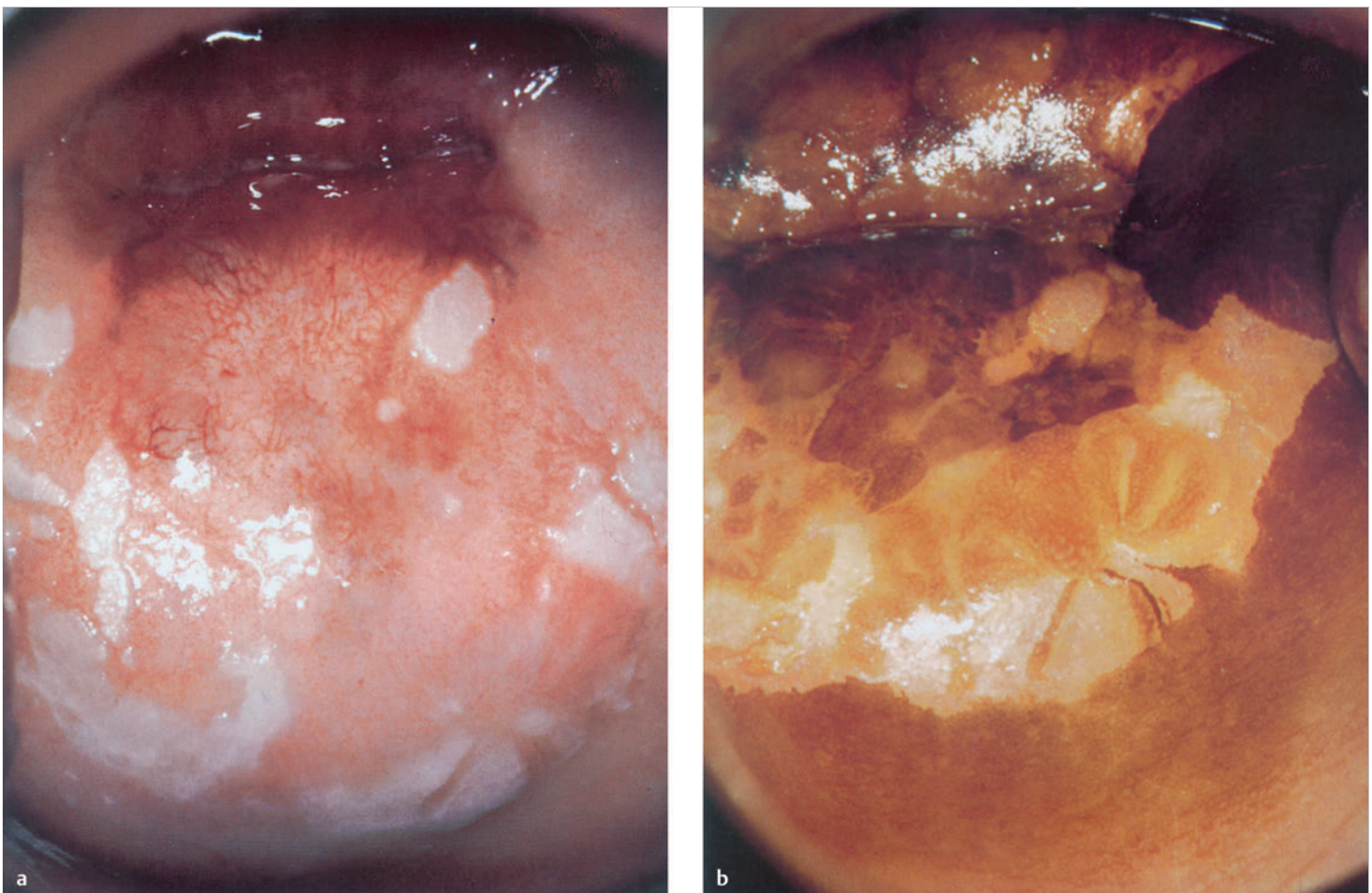


Fig. 8.85 (a) Keratosis in a vascular transformation zone. (b) The vascular epithelium stains strongly with iodine; the presence of the clearly circumscribed iodine-yellow areas was not suspected. Histology showed HSIL (CIN 3).

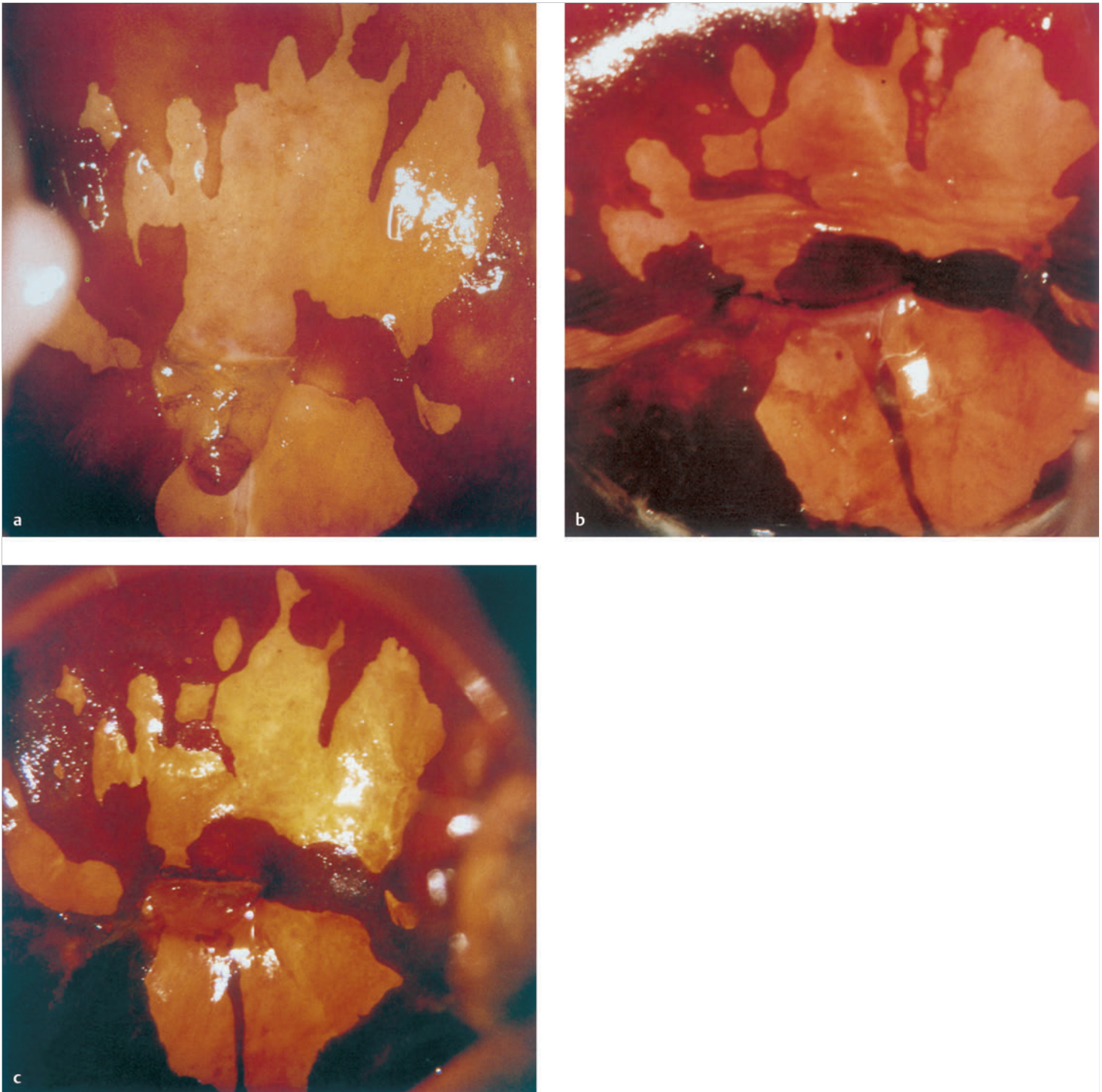


Fig. 8.86 Bizarrely shaped nonsuspicious iodine-yellow areas. The contours remained unchanged over a 5-year period.

test, appear nonspecific apart from their pearly surface. The result of the Schiller test in such cases is all the more surprising (► Fig. 8.98a,b).

Experienced colposcopists will have come across an essentially normal cervix and vagina, the surfaces of which are evenly studded with numerous white dots (► Fig. 8.99, ► Fig. 8.100). These correspond to the tips of elongated stromal papillae that perforate a rather irregular-structured yet glycogen-containing epithelium and is due to HPV infection. Meisels et al¹³ called this *condylomatous vaginitis*.

8.3.4 Inflammatory Changes

Diffuse inflammation of the vagina has a nonspecific colposcopic appearance. The appearance of focal lesions is of some significance because of their patchy inflammatory infiltration of the stroma accompanied by dilated capillaries. Diagnostic difficulties arise when such foci become bigger and indiscriminately arranged.

Trichomonal infection produces a typical frothy discharge. Removal of the secretions may reveal numerous red spots covering the cervix (► Fig. 8.101a). The inflammatory foci vary in

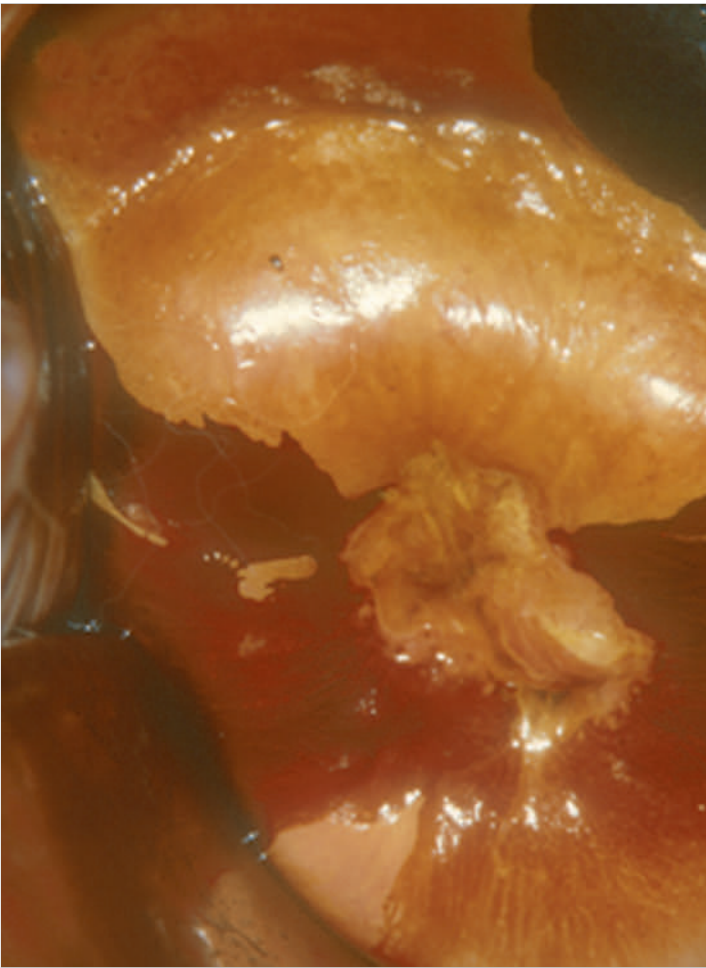


Fig. 8.87 Congenital transformation zone after the application of iodine.

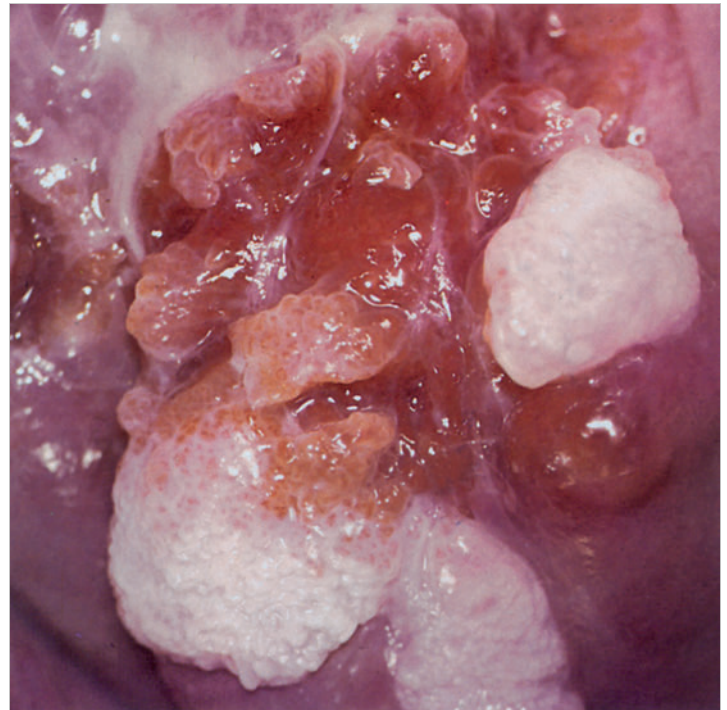

Fig. 8.88 Multiple condylomas around the external os. Only the tips of the large condylomas show advanced keratinization.

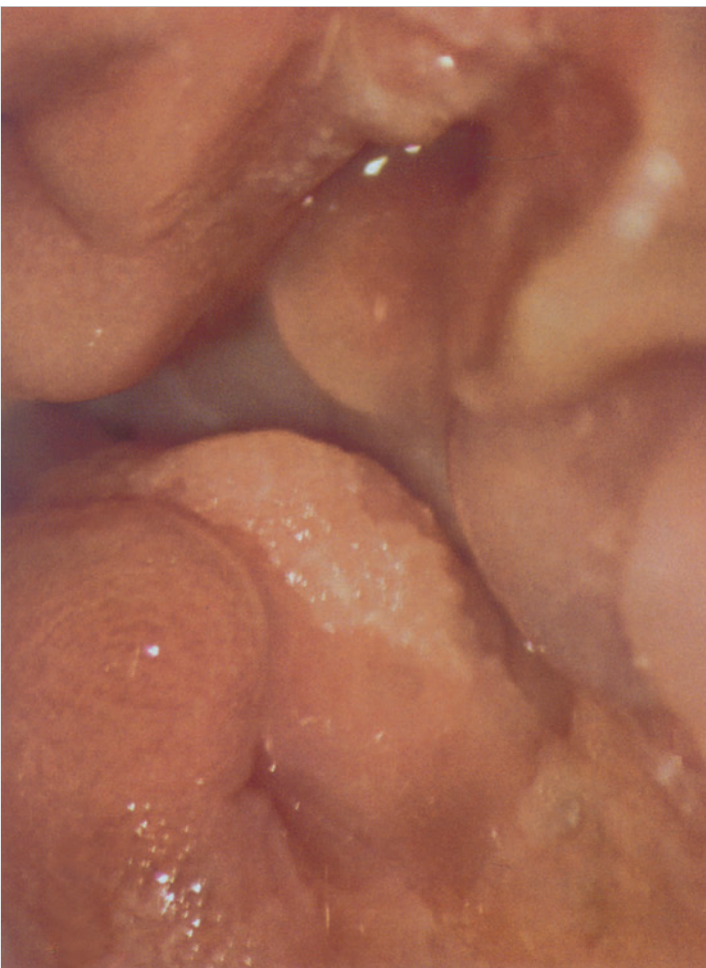

Fig. 8.89 Lacerated external os. Note the slightly elevated, fine papillary condyloma in a crease, not easily visible to the naked eye.

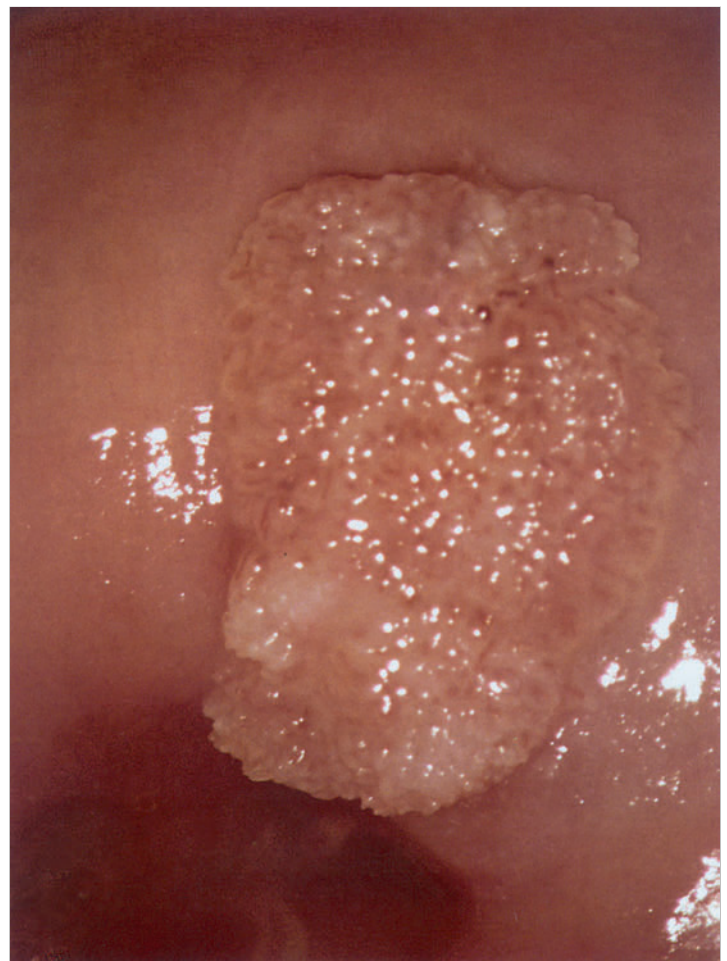

Fig. 8.90 Fine papillary, HPV 16–positive condyloma as an isolated lesion on the anterior lip of the cervix close to the external os. Histology showed a condyloma without atypia.

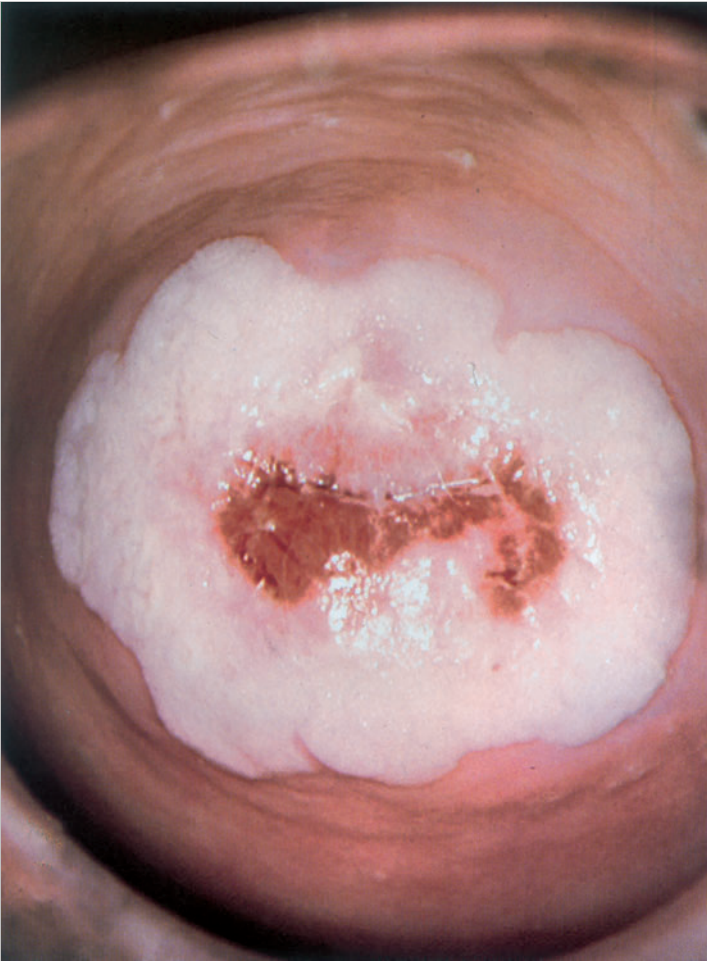

Fig. 8.91 Condyloma with marked keratinization. The keratin layer is so thick that a fissured surface is retained only focally, on the left side.

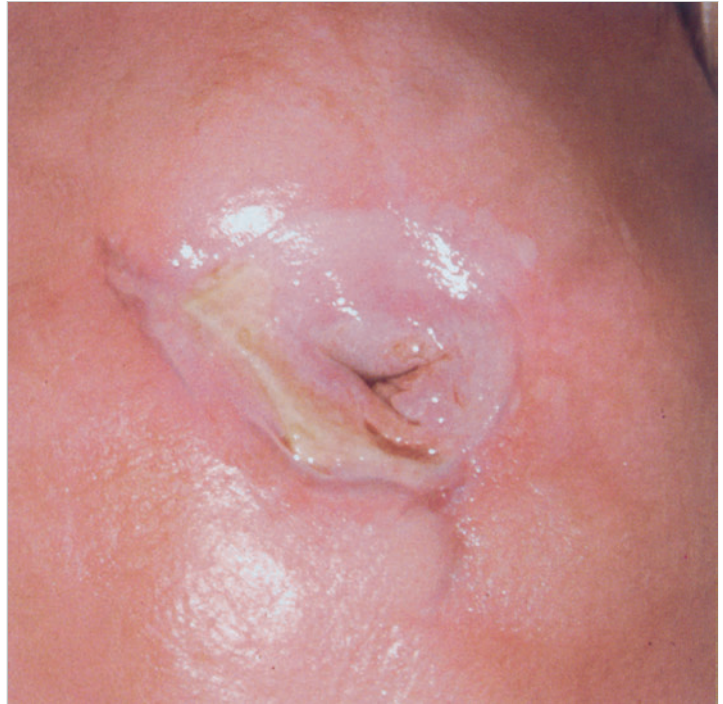


Fig. 8.92 Markedly keratinized flat condyloma surrounding the external os. Note the characteristic pearly, flat surface.

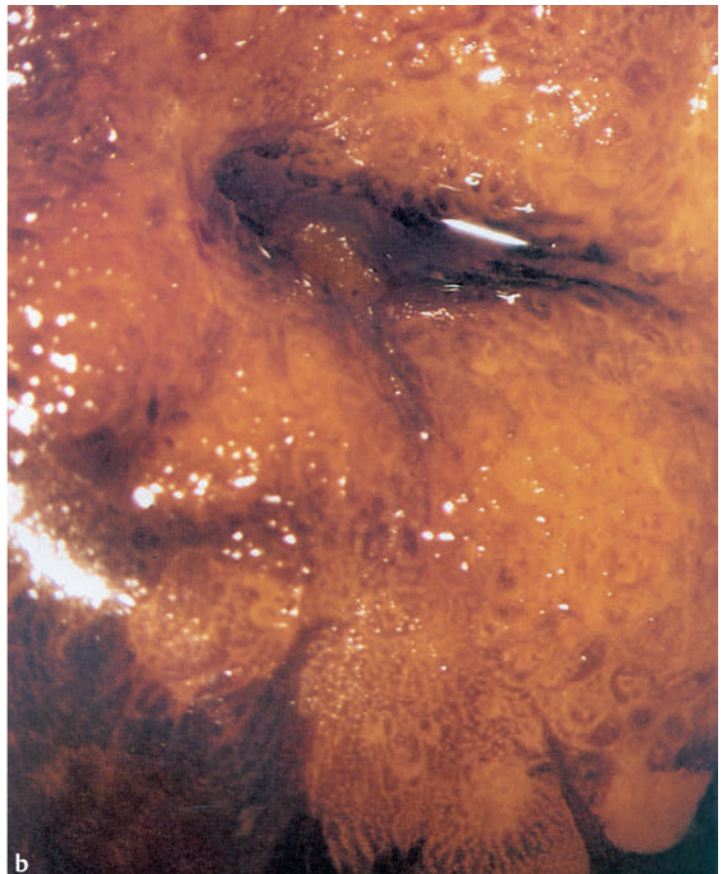
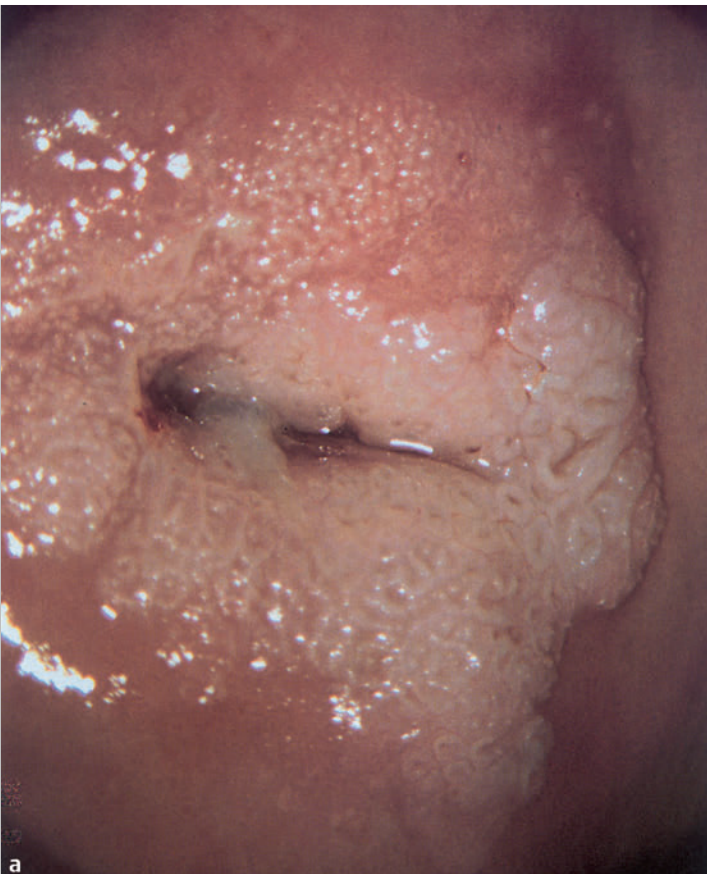


Fig. 8.93 (a) Flat to distinctly elevated condylomas around the external os and in the lower cervical canal. (Same patient as in ► Fig. 8.84, 6 months later.) (b) Iodine (Schiller test) shows the typical patchy brown areas indicating glycogen storage in the condylomas. Histology showed LSIL (CIN 1) with koilocytosis.

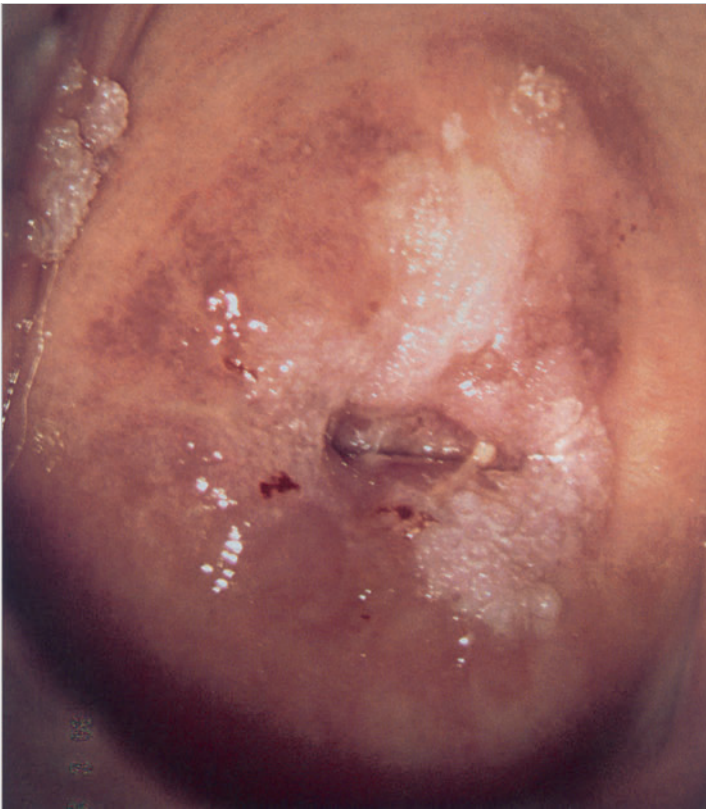


Fig. 8.94 Flat condylomas around the external os in an HIV-positive patient. Most of their surface is finely granular; some areas are smooth. Small condylomatous lesions dot the cervix and the vagina (HPV 16–positive).

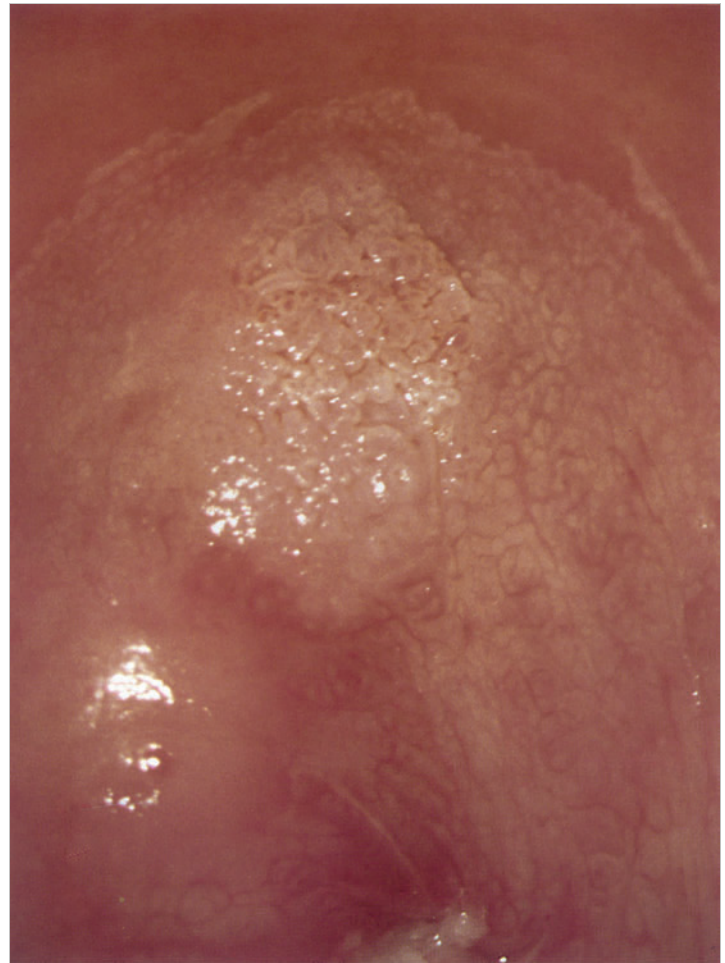


Fig. 8.95 Flat, fine papillary condylomatous excrescences within a mosaic. The mosaic is HPV 16–positive; histology showed LSIL (CIN 1).

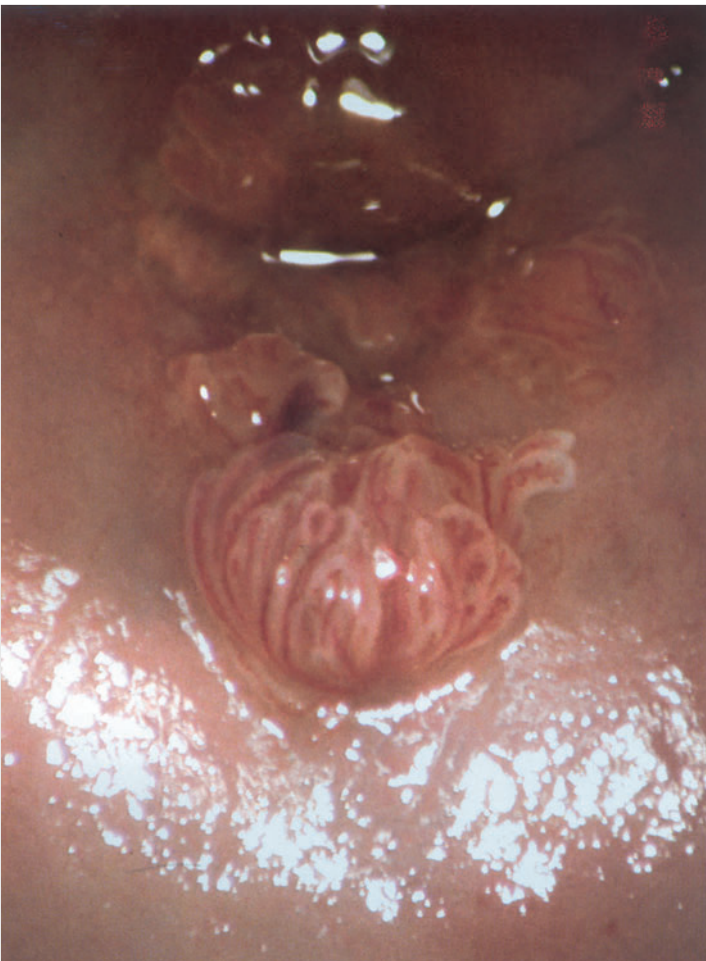

Fig. 8.96 Condyloma characterized by finger-like processes with little keratinization.

shape and in distribution. After application of acetic acid, the previously red areas turn whitish, the squamous epithelium being already loosened by the inflammation (► Fig. 8.101b). The damaged epithelium can release its glycogen, with consequent failure to stain with iodine. Iodine typically imparts a leopard-skin appearance to inflammatory lesions (► Fig. 8.102) and confirms the poor circumscription of larger lesions that might otherwise be mistaken for more serious abnormalities.

Colpitis macularis (strawberry cervix) has a unique colposcopic appearance, characterized by uniformly arranged red spots a few millimeters in size. It is usually due to *Trichomonas vaginalis* (► Fig. 8.103a). The inflamed area is always iodine-negative, and its margin is indistinct (► Fig. 8.103b). In severe cases, the vagina is also involved.

8.3.5 Polyps

Polyps are easily seen colposcopically, even if they are situated farther up in the endocervical canal. The aim of colposcopy is to detect them and evaluate their surface for signs of atypia. High polyps can be composed of columnar epithelium only, in which case the typical grapelike appearance will be seen. More often, the polyp is covered by smooth squamous epithelium (► Fig. 8.104, ► Fig. 8.105, ► Fig. 8.106, ► Fig. 8.107, ► Fig. 8.108, ► Fig. 8.109a,b). If the maturation of such histogenetically metaplastic squamous epithelium is irregular, then the various fields are clearly demarcated from each other (► Fig. 8.105,

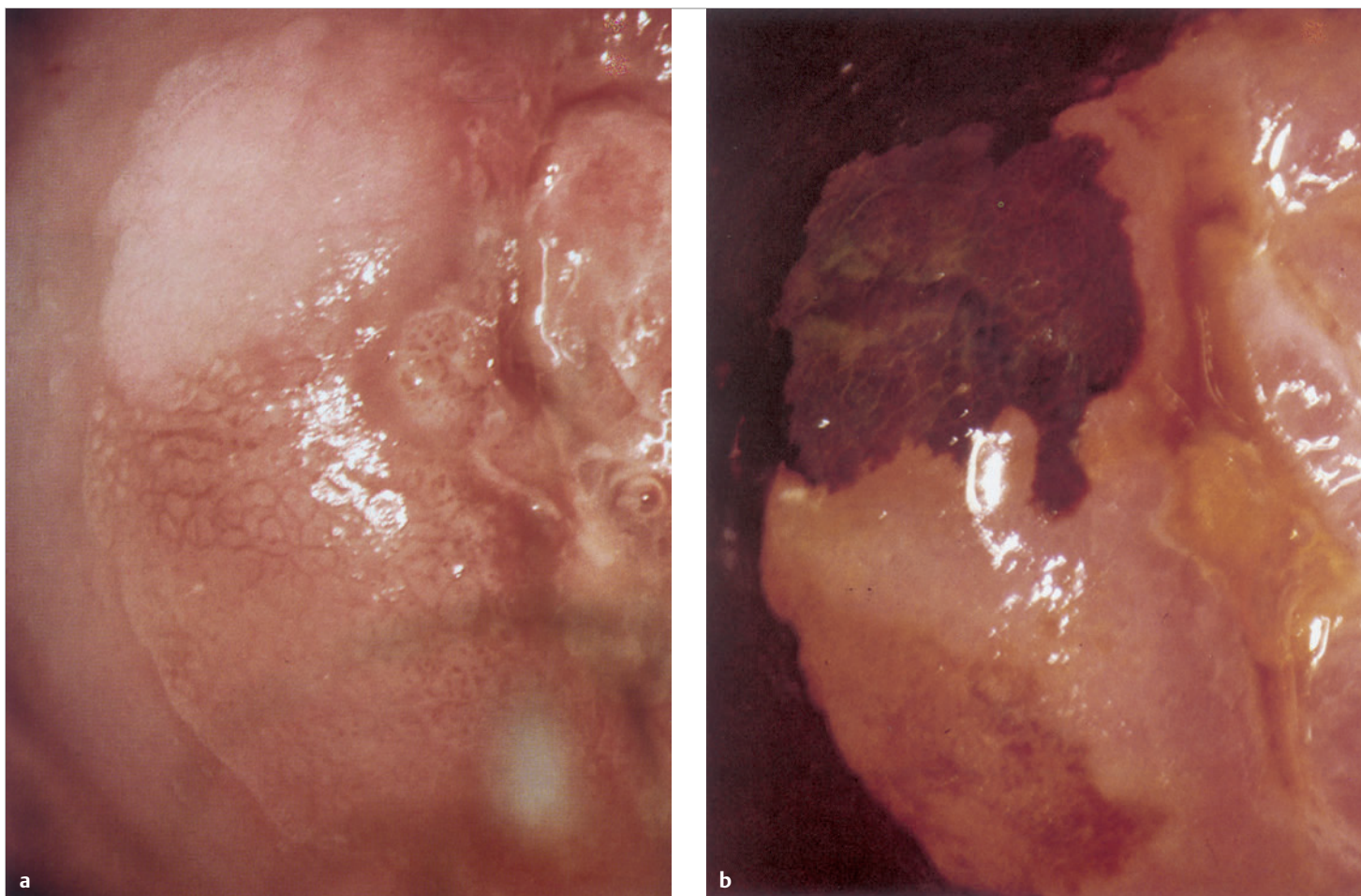


Fig. 8.97 (a) A shiny mother-of-pearl surface of a lesion also showing fine mosaic and punctation. Histologically, the white area corresponded to a flat condyloma, the mosaic showed LSIL (CIN 1). (b) After iodine (Schiller test), the previously white lesion displays an iodine-positive mosaic. Histology showed flat condyloma. The mosaic and punctation, clearly visible before the Schiller test, stain poorly. Less structured areas are light brown.

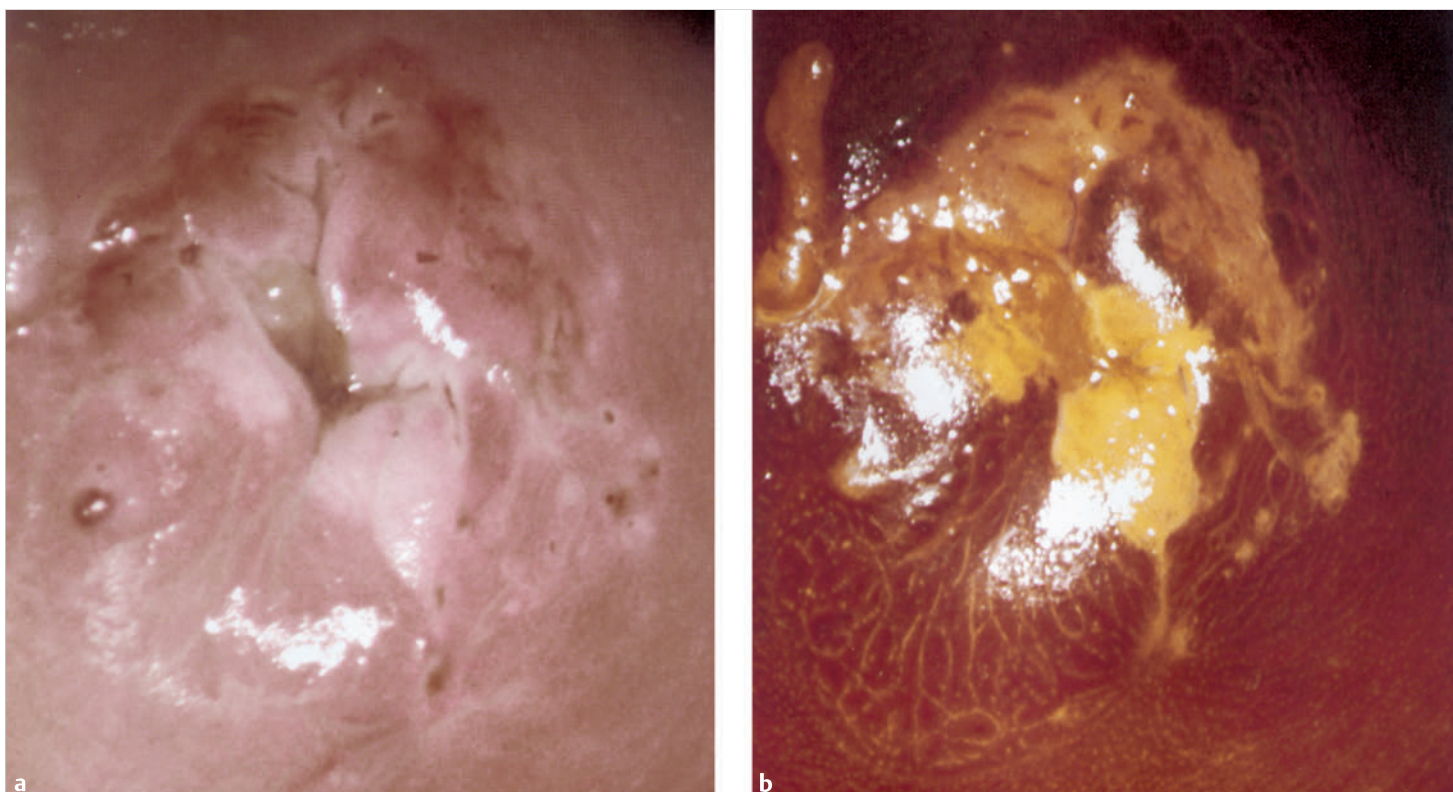


Fig. 8.98 (a) Shiny pearly lesion around the external os. The white epithelium was HSIL with koilocytosis. (b) The Schiller test shows the other lesion and, beneath it, a fine iodine-positive mosaic.

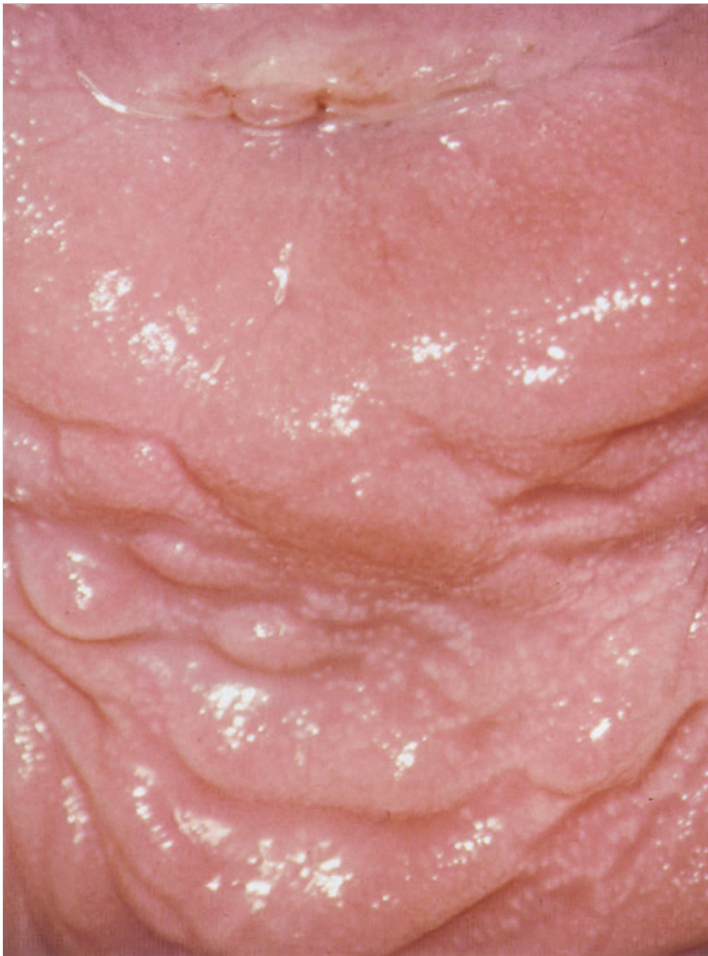


Fig. 8.99 Condylomatous colpitis. The cervix and the vagina show numerous white spots.

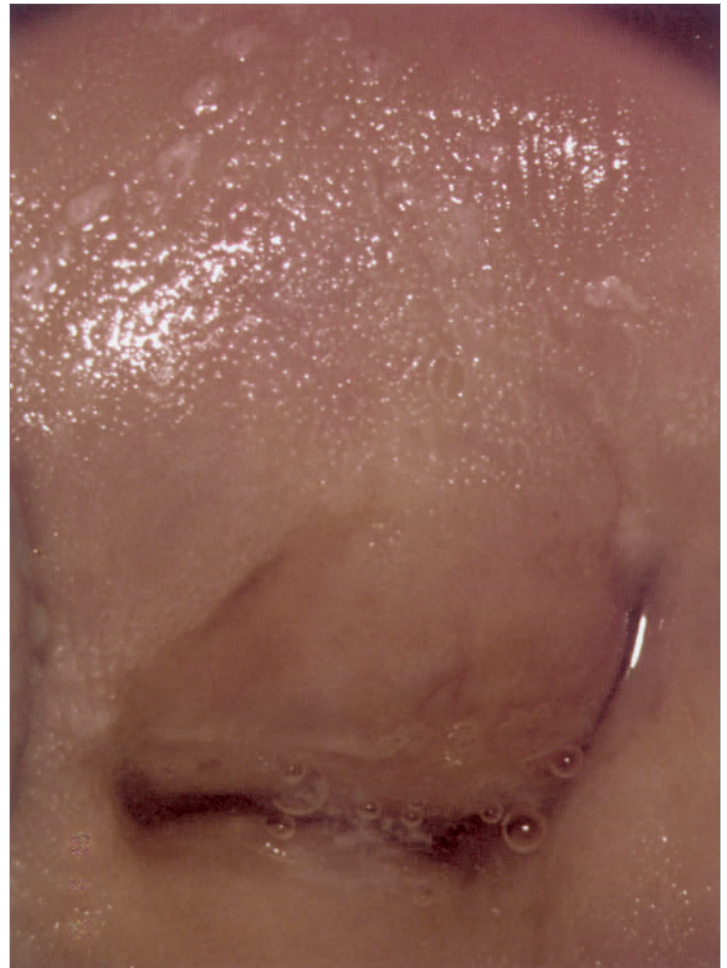


Fig. 8.100 Condylomatous vaginitis. There are circumscribed, slightly elevated condylomas within the granular area.

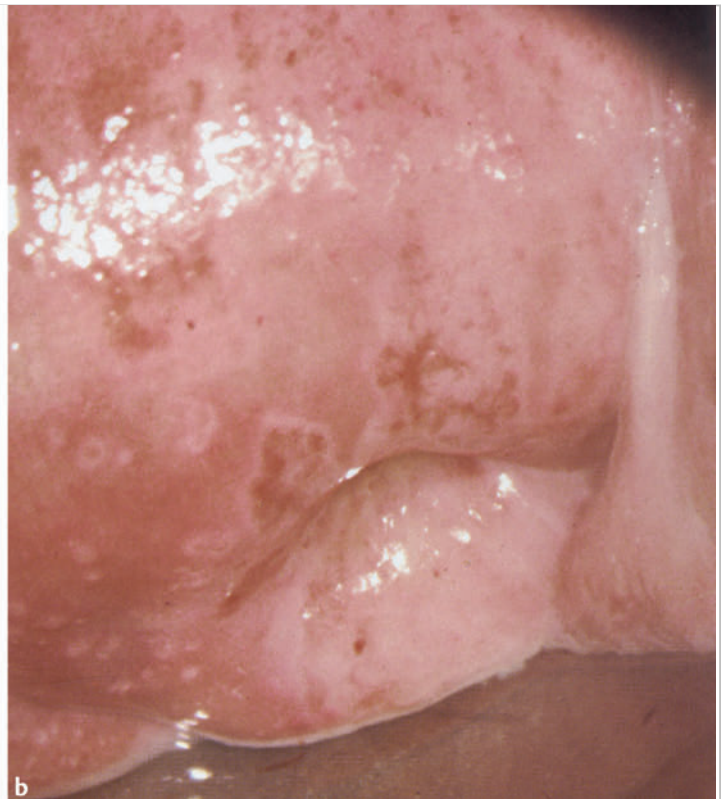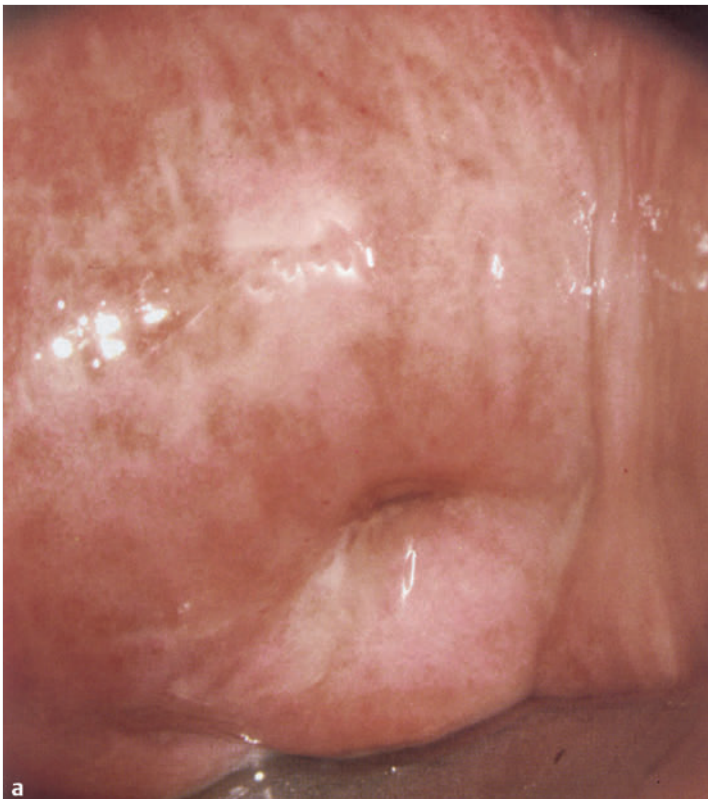


Fig. 8.101 (a) Irregular reddish stippling of the cervix from trichomonal infection. (b) The inflamed area becomes somewhat white to some extent after application of acetic acid; its margins are indistinct.

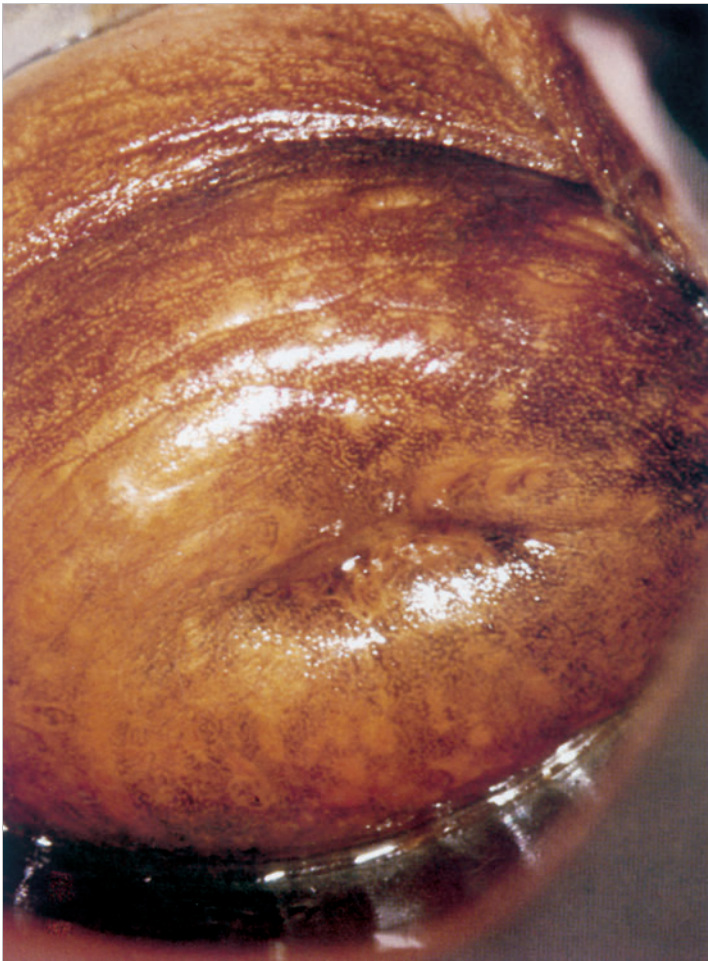


Fig. 8.102 The vague margins of the inflamed areas are well seen after application of iodine (Schiller test).

► Fig. 8.106a,b). Rarely, the squamous epithelium is atypical; in such cases, the colposcopic changes conform to those that occur elsewhere on the cervix. Polyps can be single or multiple and can arise from ectopies, from TZs (► Fig. 8.104, ► Fig. 8.106a,b, ► Fig. 8.107) or from otherwise unremarkable cervixes (► Fig. 8.108, ► Fig. 8.109a,b). On occasion, endometrial cancer can present as a bleeding polypoid mass protruding from the cervix (► Fig. 8.110). A myoma in the statu nascendi is shown in ► Fig. 8.111.

8.3.6 Postconization Changes

After conization the cervix is usually smooth and covered by normal squamous epithelium. The SCJ is again situated at the external os. Occasionally the scar after conization clearly stands out from the residual cervix (► Fig. 8.112a) and can be mistaken for some other abnormality. But with iodine (Schiller test), the area in question stains brown like the rest of the cervix (► Fig. 8.112b), and any nuance in color is due to scar tissue under the epithelium. This is a good example of how the stroma can influence the colposcopic appearance. Six weeks after conization, scarring can be extensive (► Fig. 8.113).

The changes after loop conization are the same after cold-knife procedures. With correct technique the entire SCJ is usually visible, which is helpful for follow-up colposcopy (► Fig. 8.114, ► Fig. 8.115). Laser vaporization techniques give excellent cosmetic results (► Fig. 12.9b).

Residual lesions from incomplete excision by conization can be detected at follow-up colposcopy in the region of the reconstituted external os (► Fig. 8.116). Sturmdorf sutures for hemostasis

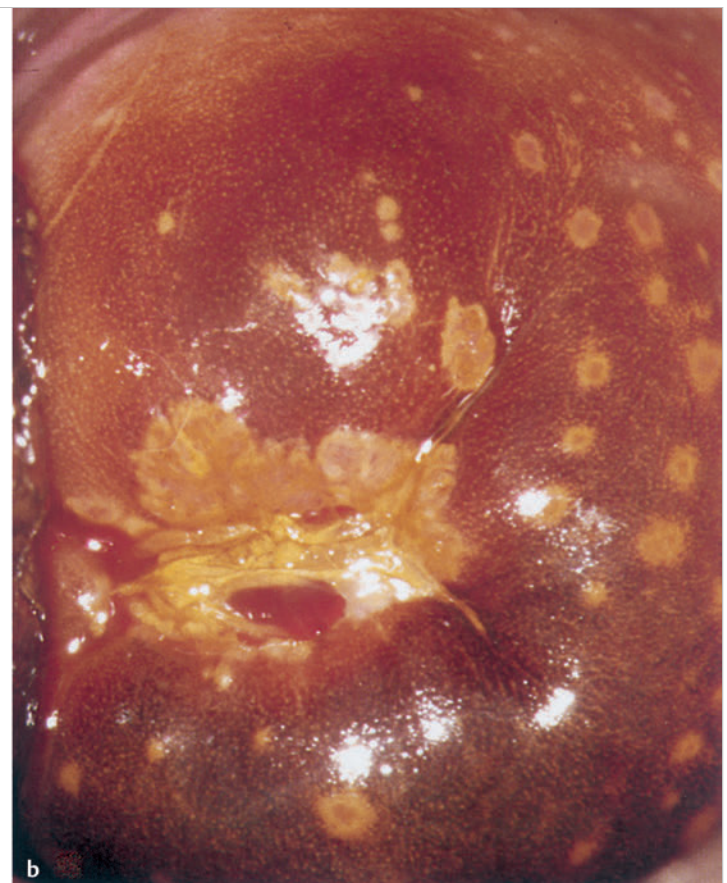
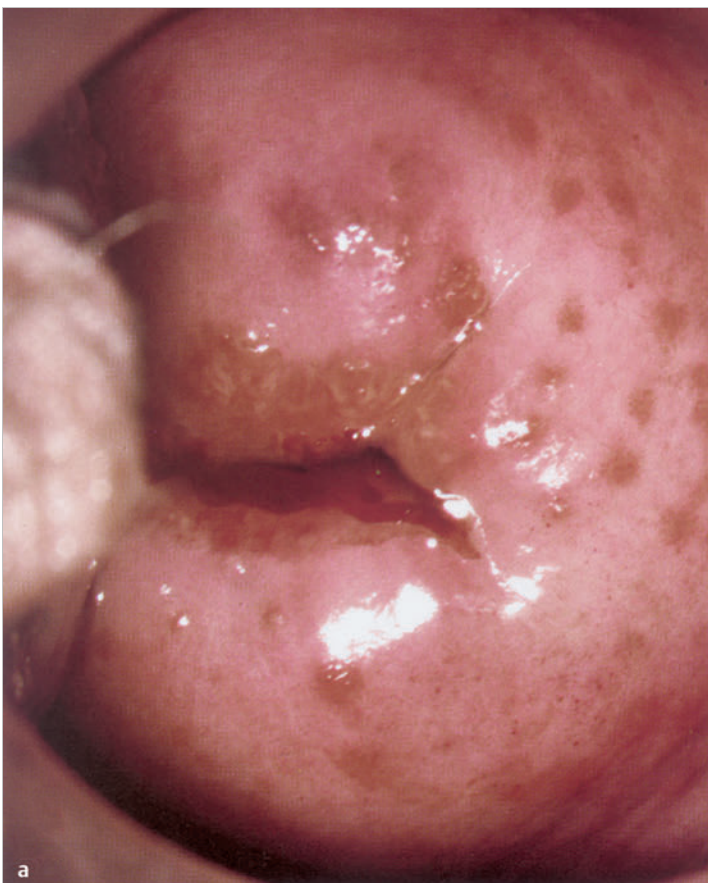

Fig. 8.103 (a) Colpitis macularis (strawberry cervix). Numerous round spots on the cervix and vagina are due to focal round cell infiltration. **(b)** After the Schiller test, the inflamed areas are poorly demarcated and are separated by fields showing so-called condylomatous colpititis.

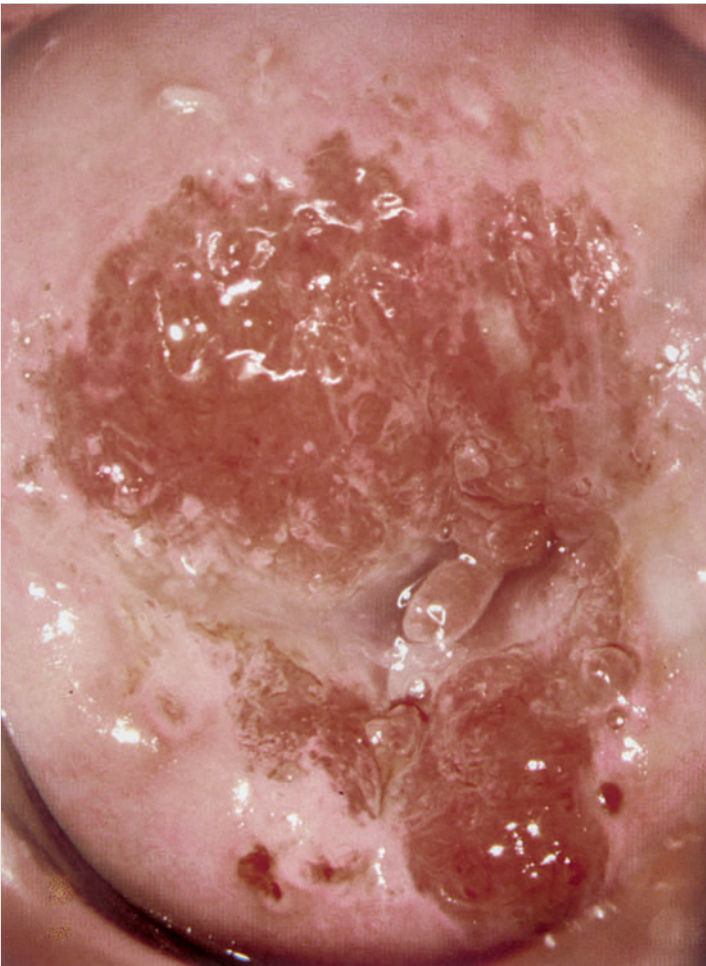

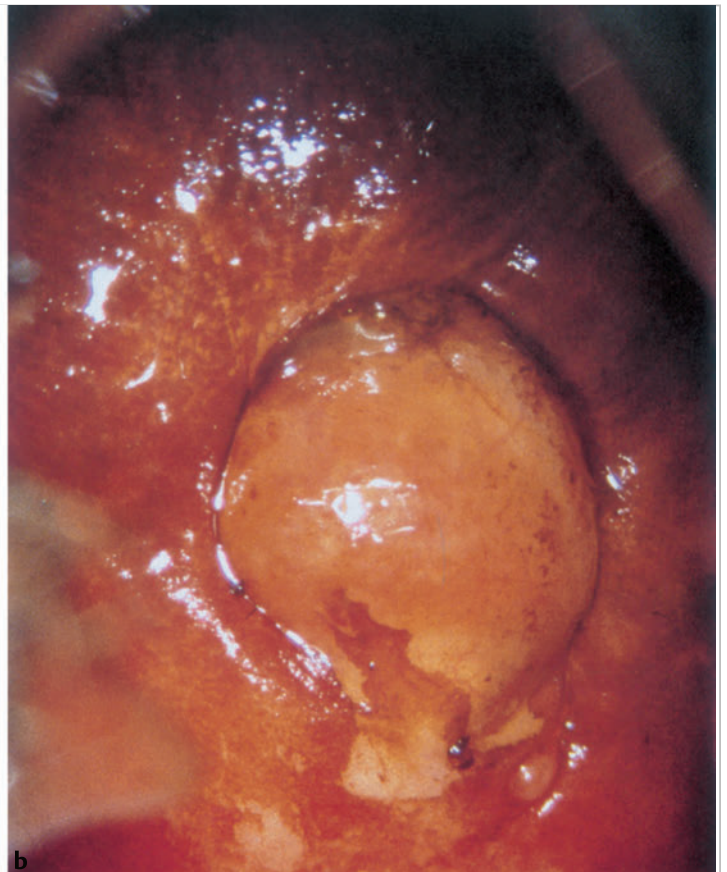
Fig. 8.104 Cervical polyp in the transformation zone. The polyp is covered by metaplastic squamous epithelium.

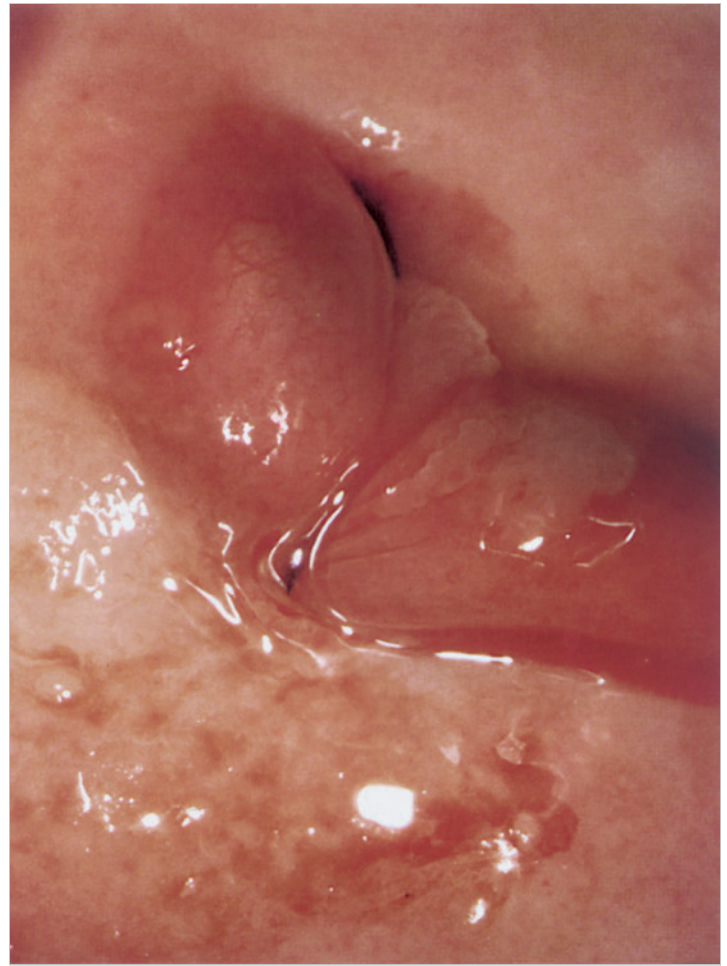
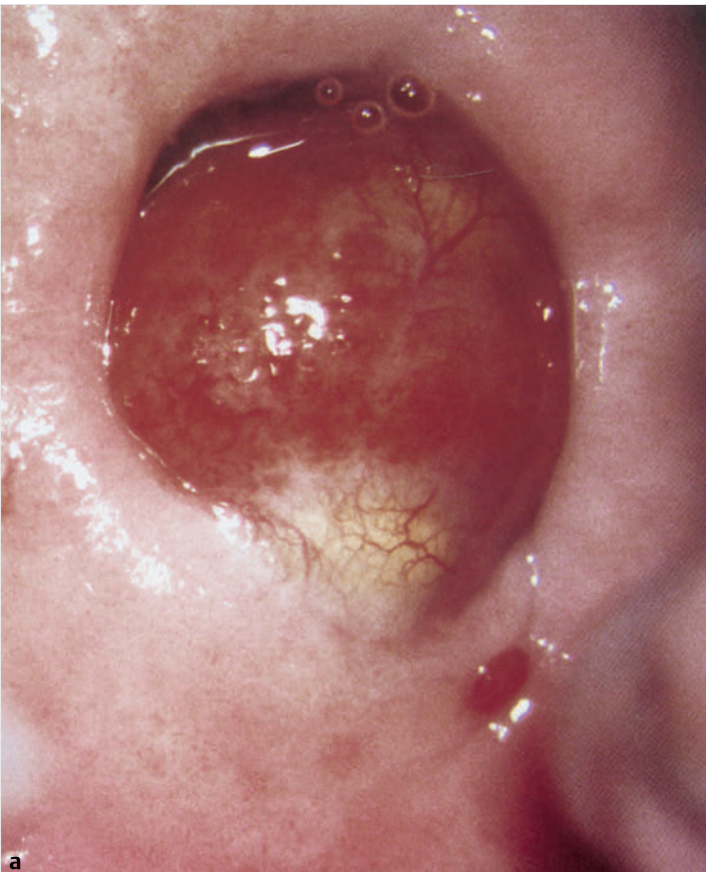
Fig. 8.105 Endocervical polyps that have undergone metaplasia. A nabothian follicle has developed within one of the polyps. The lowermost polyp shows that the metaplastic process developed in separate, well-defined fields.



a



b

Fig. 8.106 (a) Broad-based polypoid structure corresponding to a nabothian follicle. (b) After application of iodine, the cervix stains brown and the nabothian follicle stains yellow.

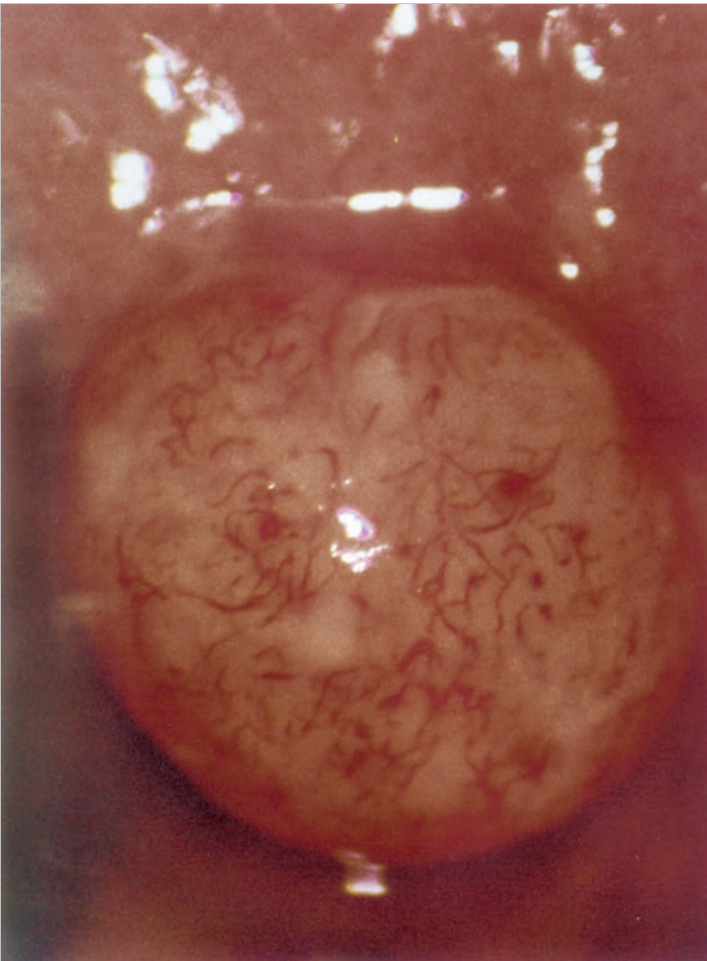

Fig. 8.107 Nabothian follicle with delicate nonsuspicious vessels on its surface.

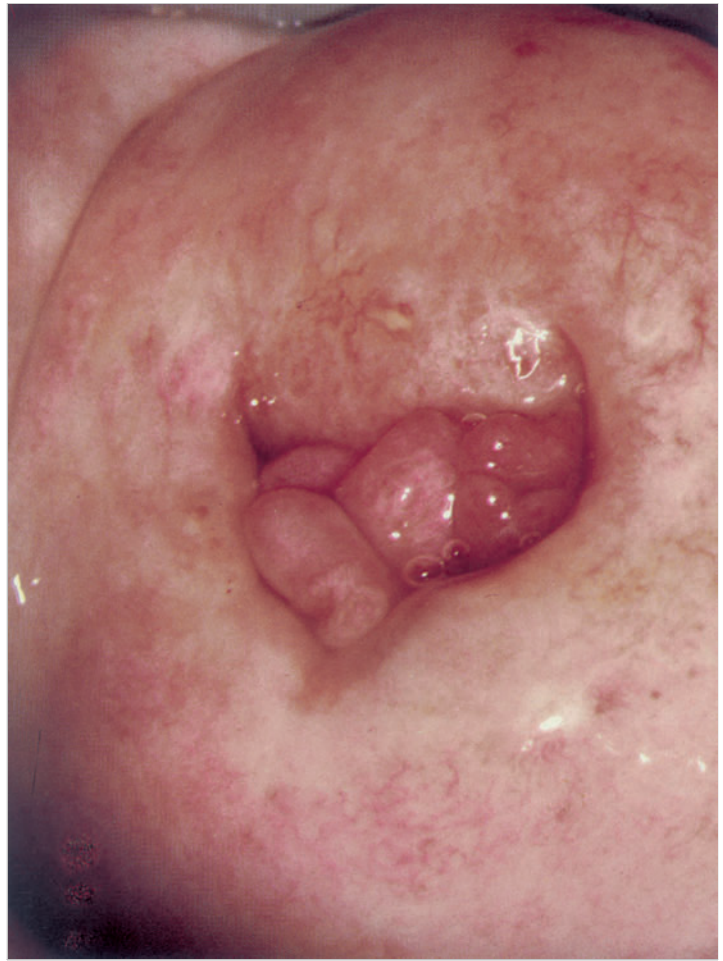

Fig. 8.108 Multiple polyps arising from an atrophic cervix. The metaplastic epithelium covering the polyps also arose in separate fields.

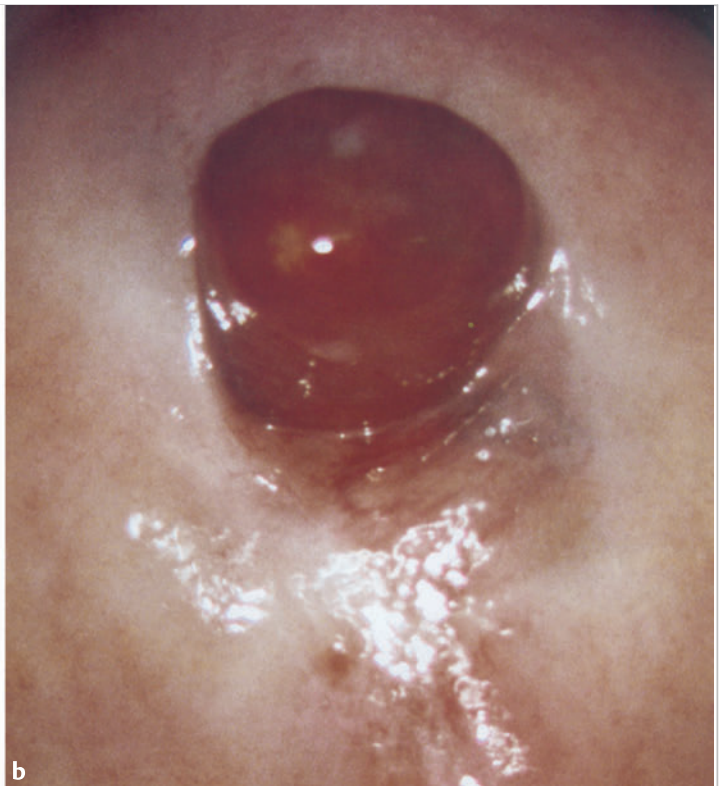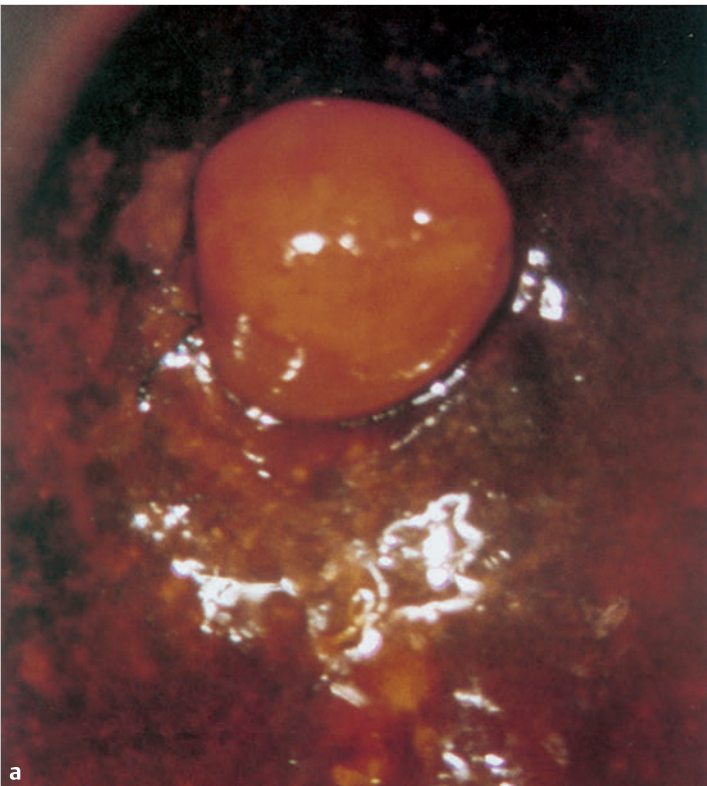


Fig. 8.109 (a) Polyp protruding from the external os. The surface is smooth and the origin unclear. (b) After application of iodine (Schiller test), the cervix stains brown and the polyp stains yellow. Histology showed a cervical mucosal polyp with metaplastic epithelium.

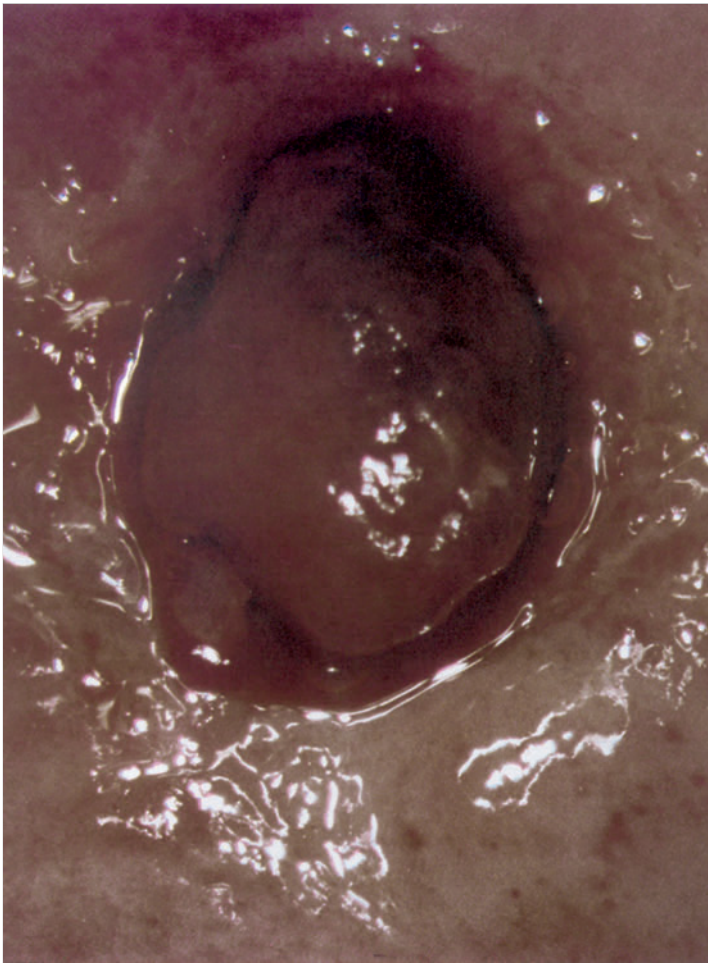

Fig. 8.110 Bleeding polyp protruding out of the cervical canal. The surface of the cervix shows signs of atrophy. Histology showed G1 endometrial carcinoma.

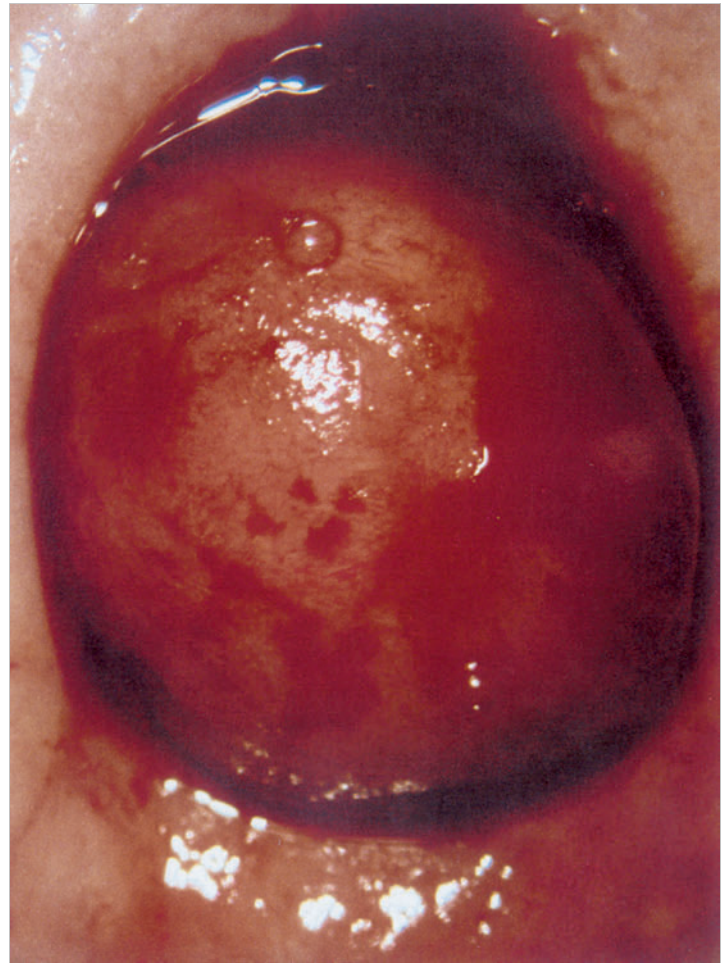

Fig. 8.111 Myoma in statu nascendi.

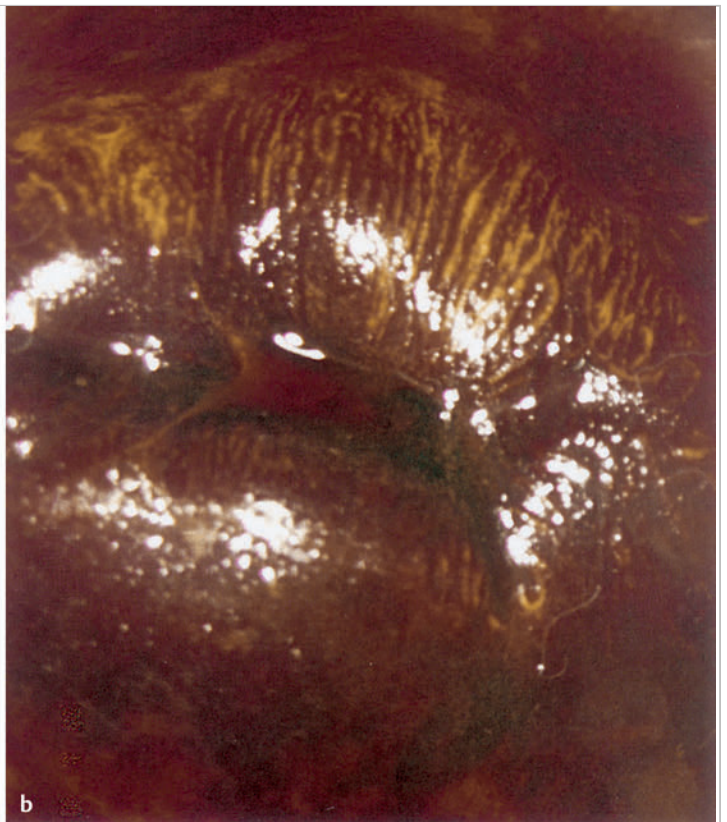
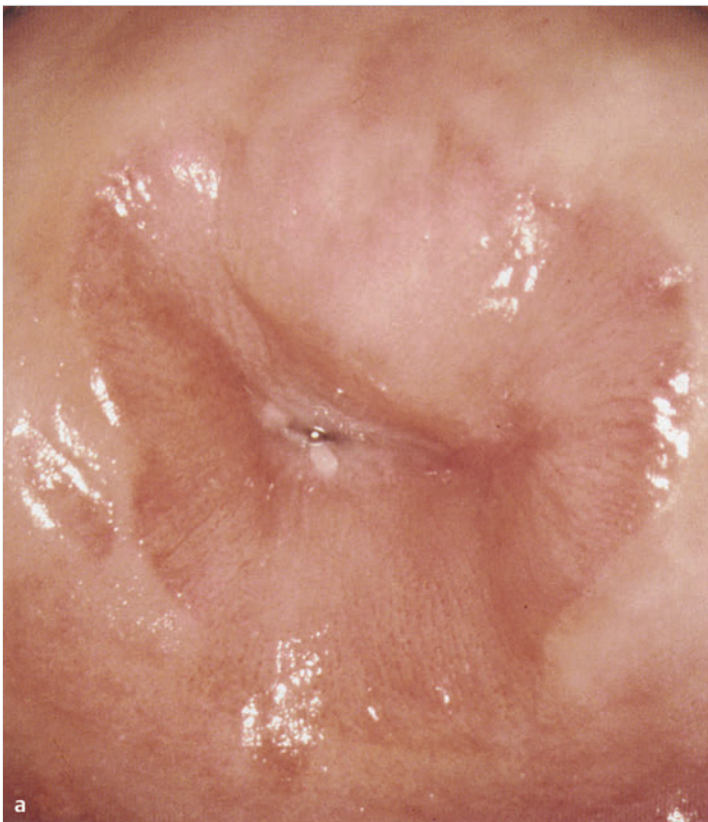

Fig. 8.112 (a) Cervix 1 year after conization. The excision site shows scarring and fine vasculature. (b) Iodine staining shows the uniform nature of the epithelium. The light yellow streaks correspond to scars.

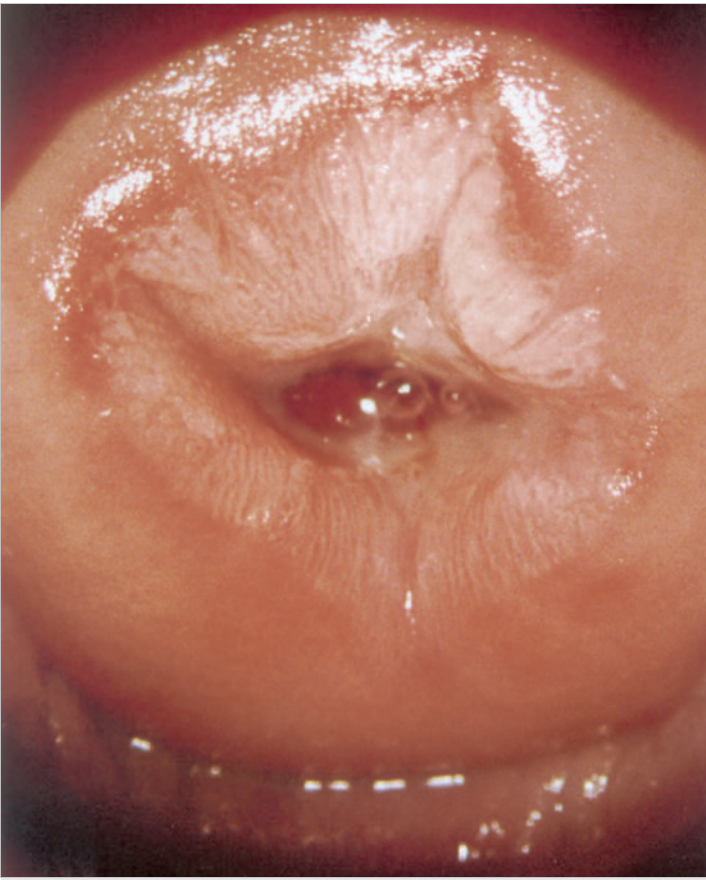


Fig. 8.113 Cervix 6 weeks after cold-knife conization. Scarring is clearly apparent. There is a small polyp in the cervical canal, and the squamocolumnar junction is visible in its entirety.

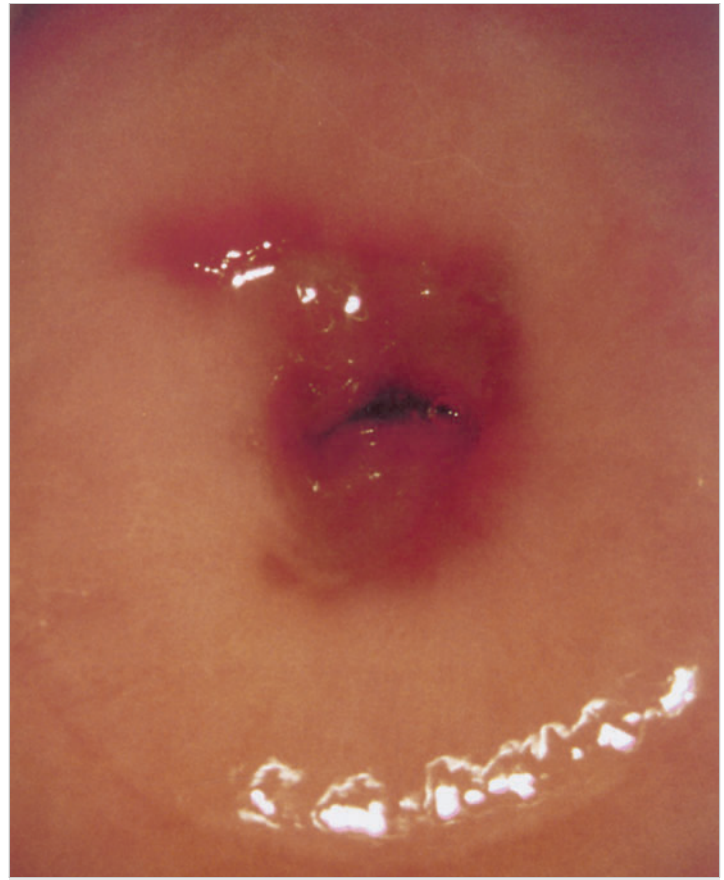

Fig. 8.114 Cervix 6 weeks after loop excision. A small scar can be seen. The squamocolumnar junction is visible in its entirety.

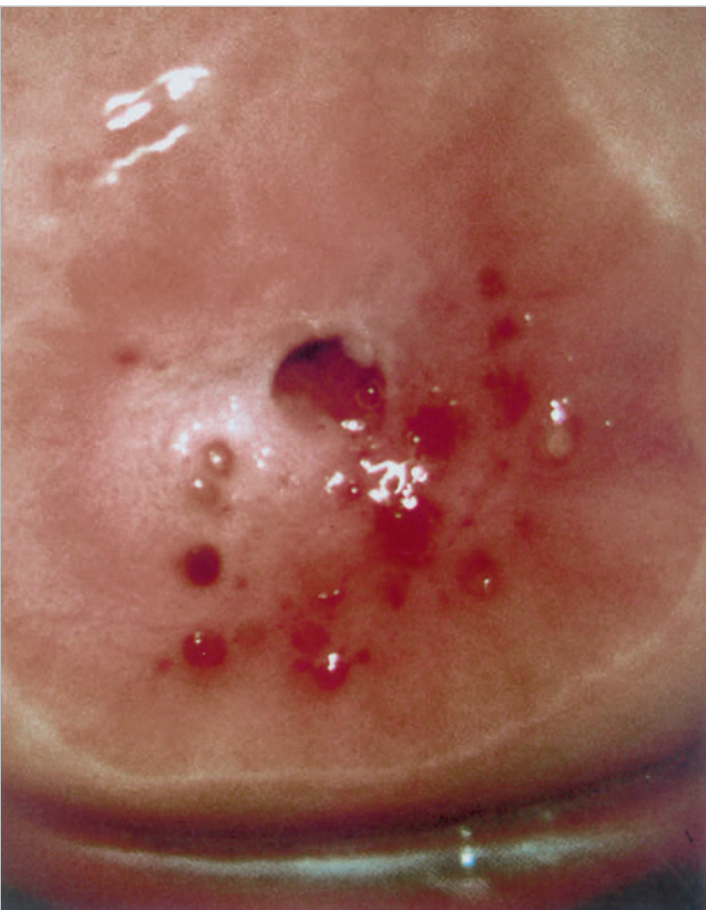

Fig. 8.115 Cervix 6 weeks after loop excision. There is slight scarring on the external os with somewhat increased scarring between 3 and 7 o'clock. Cervical glands with nonsuspicious vessels.

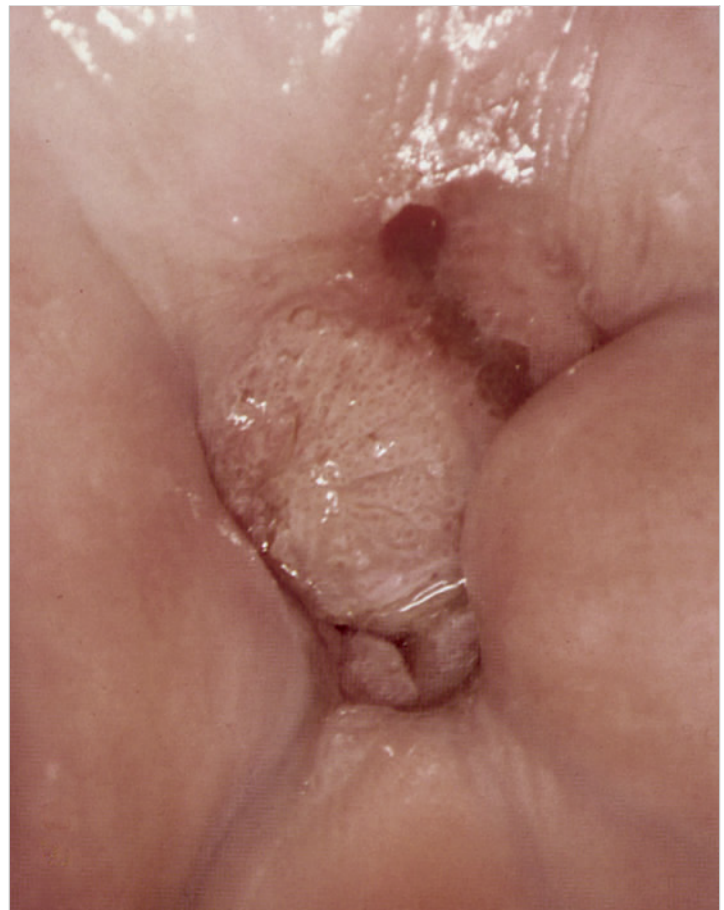

Fig. 8.116 The cervix after incomplete excision of HSIL (CIN 3) by conization. Note in the scar tissue an area of coarse punctation from residual dysplastic epithelium.

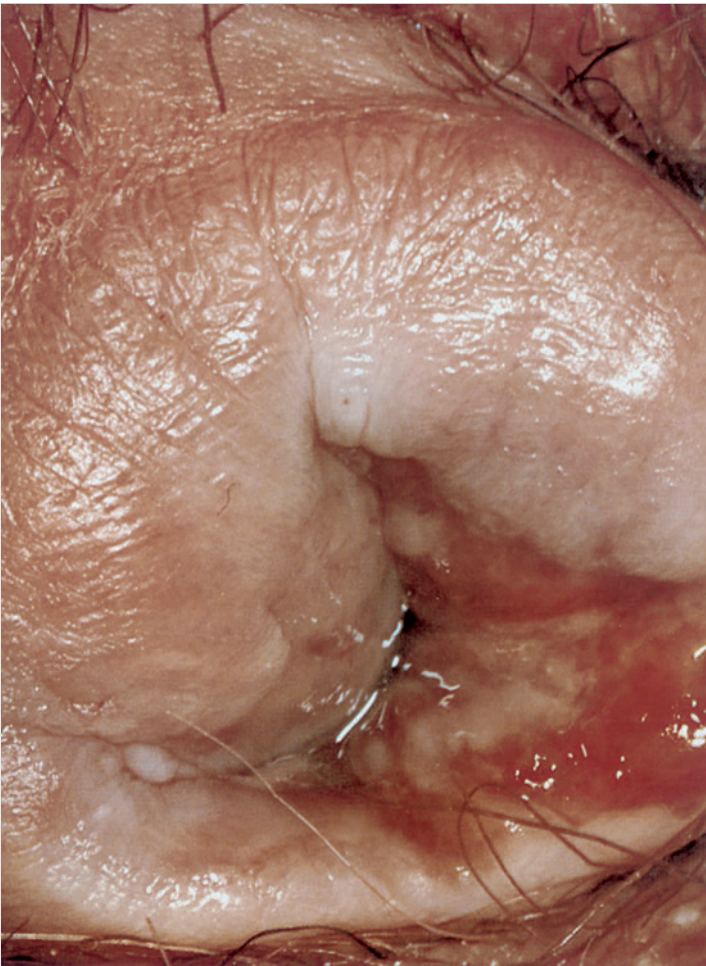


Fig. 8.117 Keratinization of uterovaginal prolapse. The ectocervical epithelium assumes the character of wrinkled skin.

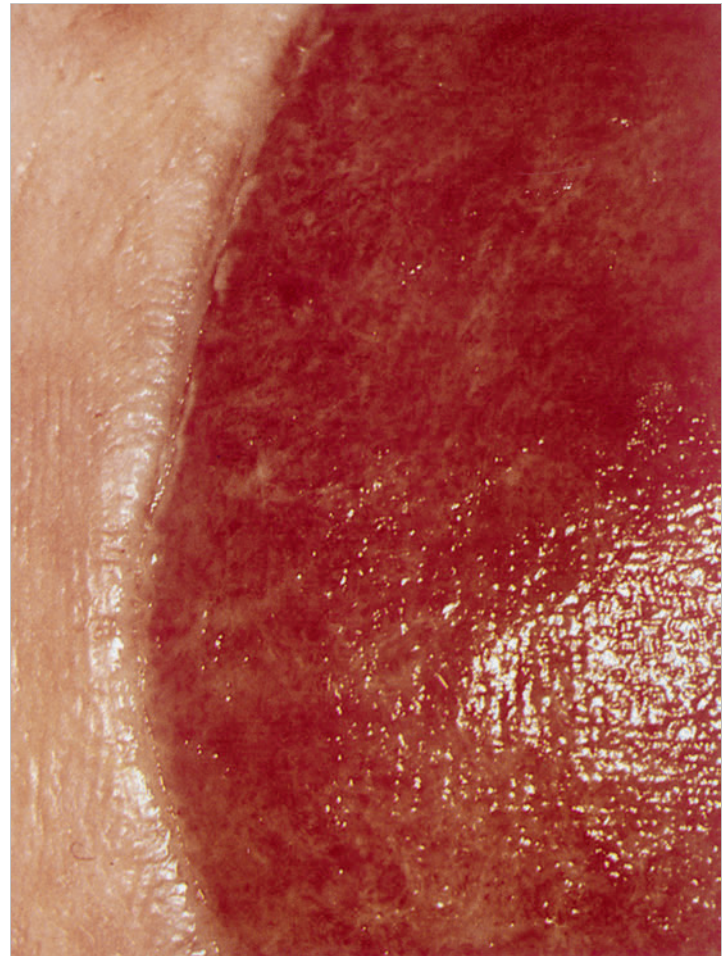


Fig. 8.118 Ulcer associated with uterovaginal prolapse. Note the typically flat floor and punched-out margin.

after conization are obsolete, not only because they produce a poor cosmetic result (► Fig. 12.7).

8.3.7 Changes Resulting from Prolapse

Prolapse results in exteriorization of the squamous epithelium of the cervix and portions of the vagina. The glycogen-containing squamous epithelium changes and becomes skinlike. Histology shows acanthosis and hyperkeratosis. This process proves that, according to demand, the nonkeratinized glycogen-containing epithelium can become like the epidermis, so-called *epidermization*. Colposcopically, we encounter far more often the *regenerative form* of metaplastic epithelium that arises from metaplasia in clearly defined fields and is of great colposcopic significance. The important difference between the reactive and regenerative types is the reversible nature of the former: after the stimulus ceases (i.e., after reduction of the prolapse), the epithelium resumes its original form. In contrast, the well-circumscribed regenerative type of metaplastic epithelium retains its position and contour. The regenerative type of metaplastic epithelium therefore is abnormal and in this respect resembles chronic dermatoses.

The colposcopic appearance of the epidermized cervix is reminiscent of skin both in color and in its wrinkled surface contour (► Fig. 8.117). It is obvious even with the naked eye that this type of epithelium is tougher. A well-recognized complication of pro-

lapse is ulceration of the extruded portion of the cervix or vagina. These ulcers are punched out, their floor is flat and usually very red (► Fig. 8.118), but it can be dirty gray if superinfected. Ulcers caused by prolapse are not to be confused with cervical cancer coexisting with uterovaginal procidentia (► Fig. 8.119).

8.3.8 Endometriosis, Fistulas, Anatomic Anomalies

Endometriosis of the cervix is uncommon (► Fig. 8.120). The posterior vaginal fornix is involved most frequently (► Fig. 8.121). Endometriotic foci appear as bluish spots shimmering through the epithelium and are best seen before menstruation; they can disappear altogether during the proliferative phase of the cycle. Fistulas can occasionally develop in patients after surgery or radiation therapy of the lower genital tract.

Fistulas (► Fig. 8.122), and anatomic anomalies such as septae (► Fig. 8.123) can on occasion be documented at colposcopy.

8.4 Assessment of Colposcopic Findings

Colposcopists want to predict the histology underlying colposcopic findings. This is straightforward as far as original squamous epithelium, ectopy, or normal TZ are concerned. The task becomes more difficult when colposcopic findings are abnormal

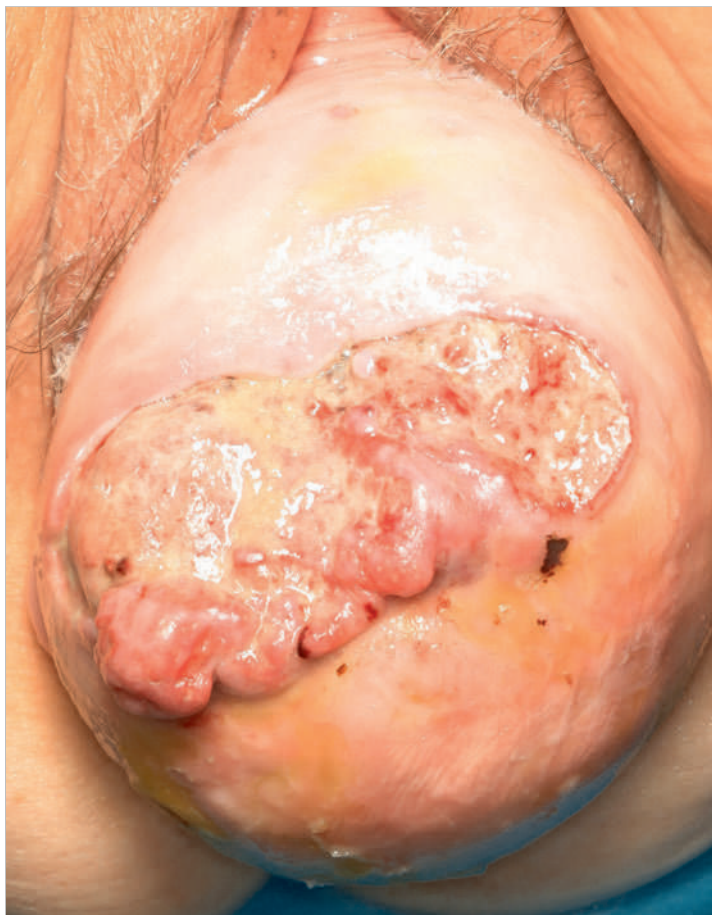

Fig. 8.119 Large cervical cancer in a patient with uterovaginal procidentia.

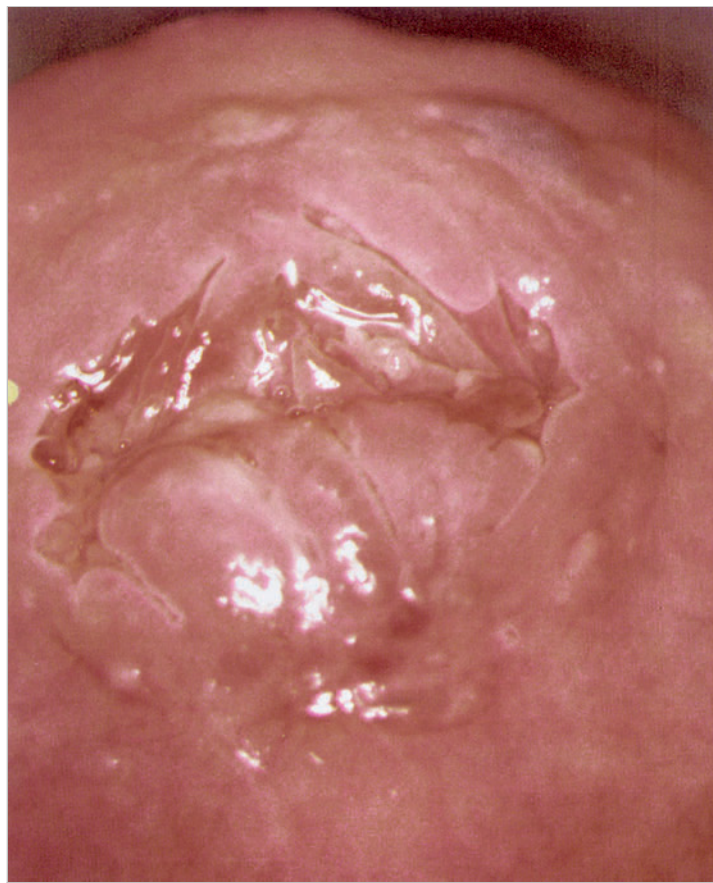

Fig. 8.120 Small bluish focus of endometriosis on the anterior lip at 2 o'clock of a transformation zone with still recognizable rugae of the ectropion.

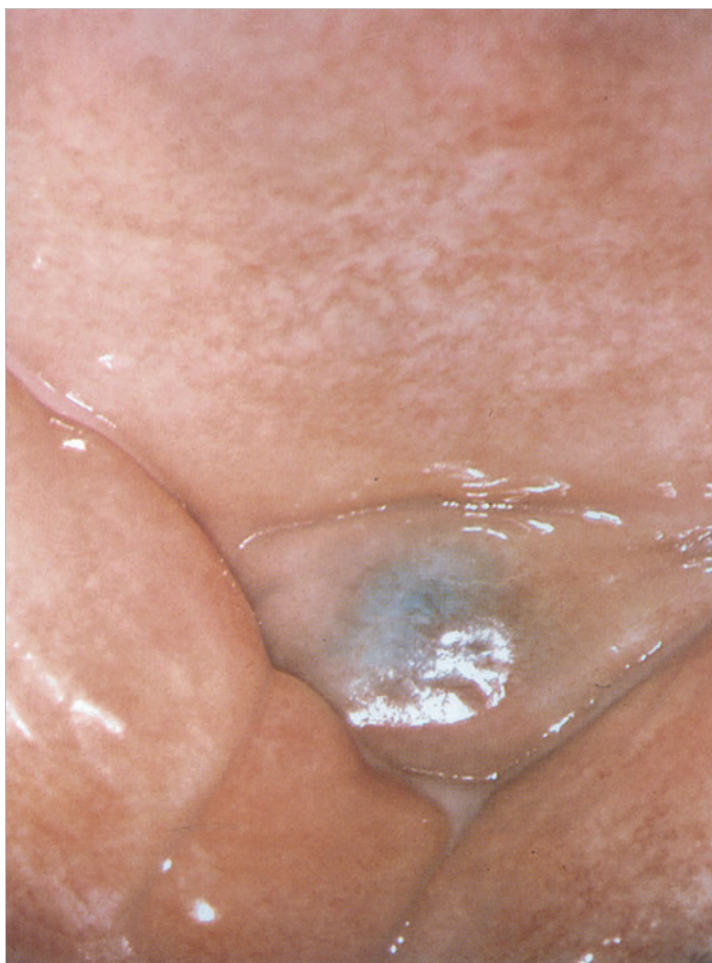

Fig. 8.121 Bluish endometriotic deposit in the posterior fornix of a 38-year-old woman on day 24 of the menstrual cycle.

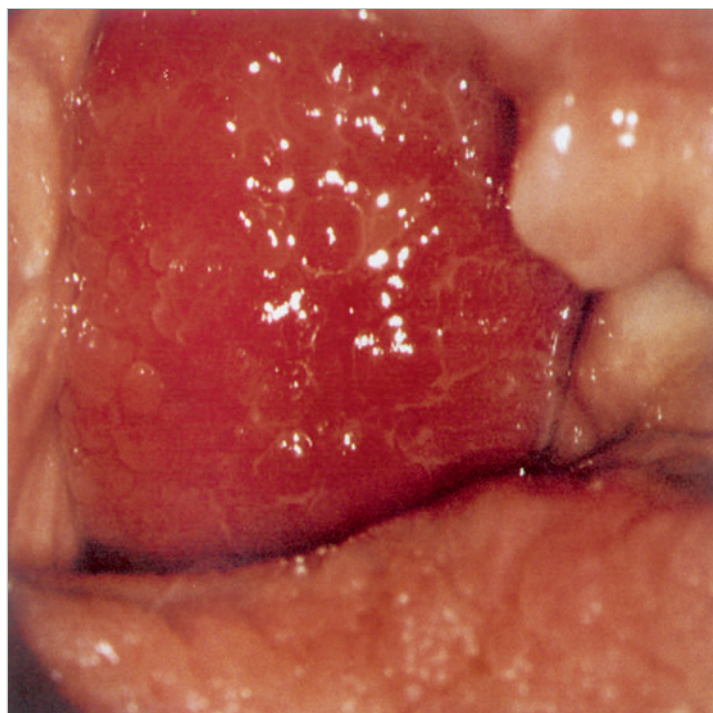


Fig. 8.122 Vesicovaginal fistula after primary radiation treatment for carcinoma of the cervix. The bladder mucosa is red and grapelike without the application of acetic acid.

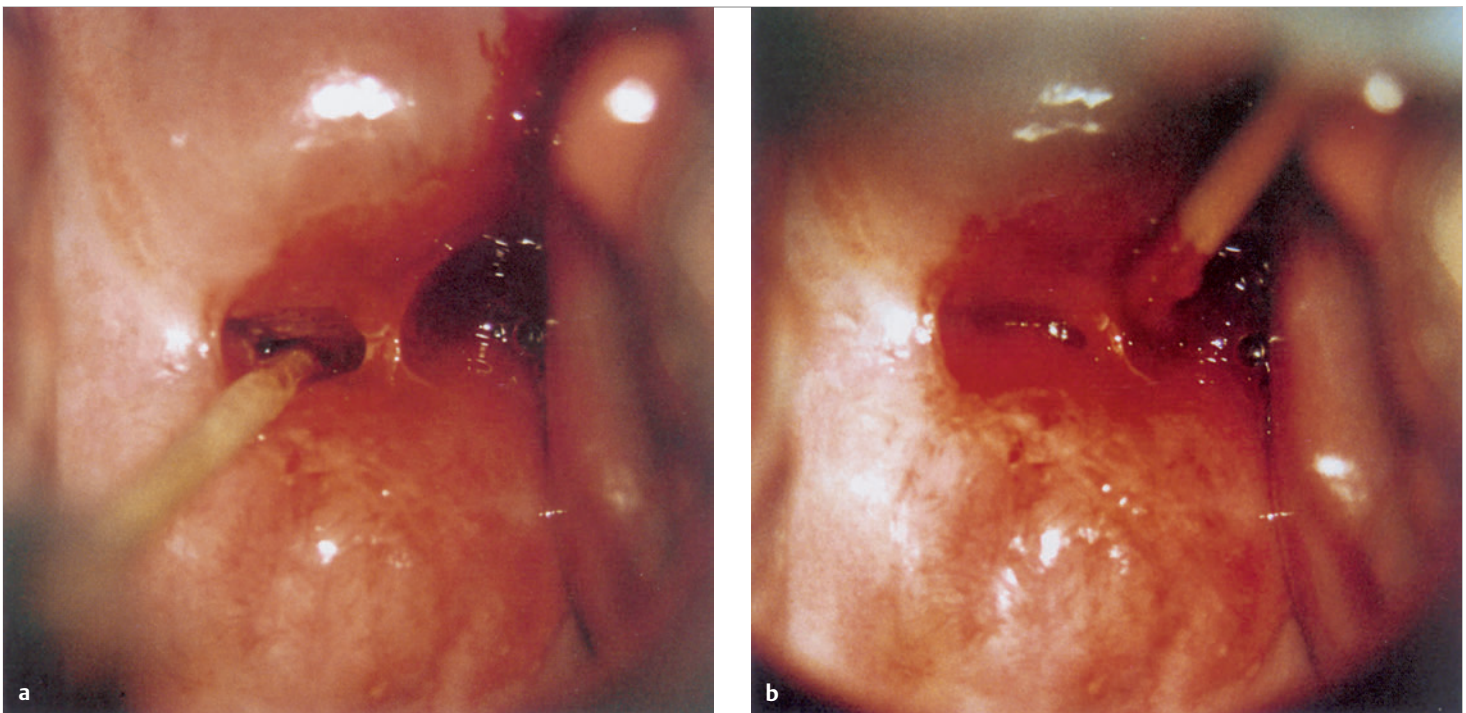


Fig. 8.123 Transformation zone in a cervix divided by a septum. The probe is in the left (a) and right (b) part of the cervical canal.

and the question arises whether they are benign or neoplastic. It is challenging when normal and abnormal colposcopic findings differ only in subtle features.

It is important to appreciate that no colposcopic findings are pathognomonic of malignancy. In practice, the colposcopist must distinguish between two patterns: *nonsuspicious findings* and *suspicious findings*. With experience, the colposcopist will succeed increasingly in distinguishing between the two, thereby reducing the number of biopsies. *Suspicious findings* are not synonymous with *abnormal findings* because the latter are not always due to premalignant lesions.

8.4.1 Benign Metaplastic Epithelium and Squamous Intraepithelial Neoplasia

Variations in the interpretation of colposcopic findings are due to the fact that colposcopy is often carried out only to evaluate patients with abnormal smears. Patient selection thus ensures that in most cases abnormal colposcopic findings correspond to histologically atypical epithelia. Those who use colposcopy routinely take a different view. They appreciate that the histologic counterparts of leukoplakia, punctation, mosaic, or acetowhite epithelium are more often due to metaplastic than to dysplastic epithelia.

► Table 8.1 shows the frequency of SIL or ESI in cone biopsies obtained from patients with colposcopically suspicious lesions.^{8, 16} The rate of SIL or microinvasion was 38% in cases of leukoplakia, 30% in cases of mosaic and punctation outside the TZ, and 80% in cases of mosaic and punctation inside the TZ. Histologic

evaluation of white epithelium revealed an 80% rate of SIL or microinvasion compared with a mere 6% in colposcopically nonsuspicious iodine-yellow areas.

Metaplastic epithelium is a great imitator. It arises in the TZ. The metaplastic process can result in normal, mature squamous epithelium; immature, metaplastic epithelium; or SIL. Like the epidermis, metaplastic epithelium is composed mostly of prickle cells and shows at least parakeratosis (see Chapter 4). It is important for colposcopic diagnosis because metaplastic epithelium can develop in clearly demarcated fields. Normal glycogen-containing epithelium can also change to diffusely keratinizing metaplastic epithelium, as in prolapse.

If the metaplastic epithelium is focal, the individual fields have sharp borders. The surface usually shows parakeratosis or hyperkeratosis. Also, metaplastic epithelium is often peg-forming, being subdivided by tall stromal papillae. The pegs can appear as isolated columns or be arranged in interlacing netlike ridges.

Metaplastic epithelium can therefore appear in the TZ as leukoplakia, punctation, mosaic, or even acetowhite epithelium.

Table 8.1 Colposcopic findings and corresponding histology in 118 patients with SIL (CIN) who underwent conization.

Colposcopic findings	HSIL (CIN 2/3) or microinvasion	LSIL (CIN 1)
Nonsuspicious iodine-yellow area	0%	6%
Mosaic or punctation inside the TZ	76%	4%
Mosaic or punctation outside the TZ	20%	9%
Acetowhite epithelium	76%	4%
Leukoplakia	30%	8%

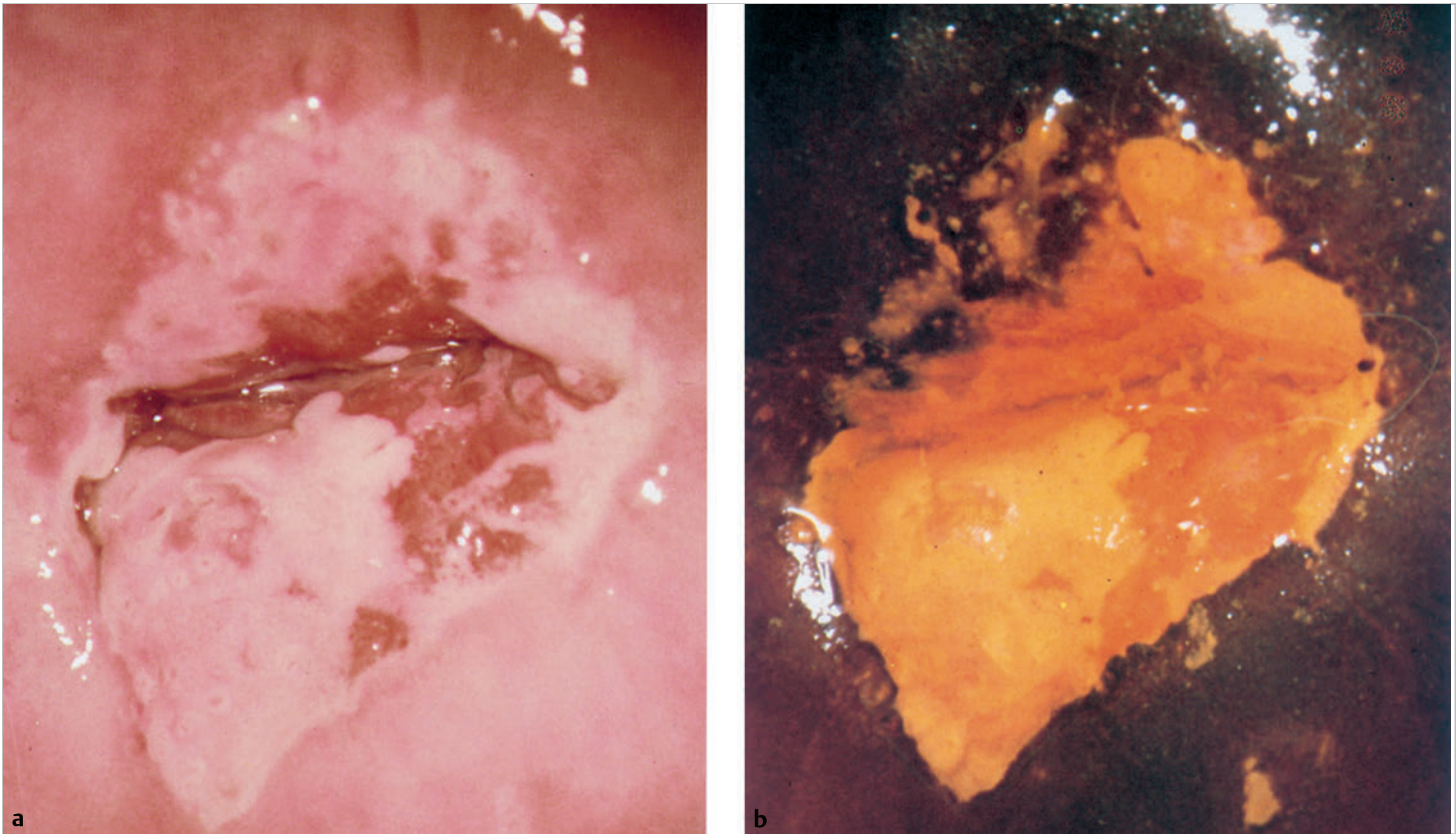


Fig. 8.124 (a) Dense acetowhite epithelium after application of 3% acetic acid. Note the uniform appearance and the cuffed gland openings. (b) Application of iodine reveals that the typically yellowish discoloration is focal and the sharp border segmental. Between the 9 o'clock and 12 o'clock positions, the margin is quite indistinct. The iodine-yellow area returned HSIL (CIN 3).

8.5 Criteria for Differential Diagnosis

The differential diagnosis of colposcopic findings is based on a number of features:

- Sharp borders
- Response to acetic acid (white epithelium)
- Surface contour
- Appearance of gland openings
- Appearance of blood vessels
- Surface area (size)
- Combinations of abnormalities
- Iodine uptake
- Keratinization

8.5.1 Sharp Borders

Sharp borders are among the most important colposcopic findings but often underappreciated in the colposcopic and pathology literature. Almost all colposcopically significant lesions have sharp borders. Such borders are also found within large lesions, especially after the application of iodine (Schiller test).

Any sharply circumscribed epithelium has developed via transformation. Reactive changes, such as those induced by inflammation, are usually diffuse. Sharp borders are often recognizable by native colposcopy. In any case, they become distinct after application of acetic acid iodine (► Fig. 8.124). In contrast to punctation

and mosaic, which are always sharply circumscribed, punctation from inflammation and mosaic simulated by chance arrangement of blood vessels have indistinct margins. In most cases, the criterion of sharp borders alone enables one to distinguish between significant and nonspecific colposcopic lesions. This feature, however, cannot be used to differentiate between metaplastic epithelia and SIL because both have sharp borders.

8.5.2 Response to Acetic Acid (White Epithelium)

Application of acetic acid clarifies the colposcopic appearance by removing mucus. Acetic acid also induces swelling of SIL because of its poor intercellular cohesiveness. At the same time, the color of the epithelium changes from red to white. If, in addition, the lesion shows punctation or mosaic, the white epithelial fields project above the surface. Vascular structures remain red and consequently become better contrasted. The atypical TZ remains unstructured except for the gland openings and thus displays a white surface (► Fig. 8.33). This feature is called “white epithelium” if neither mosaic nor punctation is present. The cohesiveness of the epithelium is directly proportional to its differentiation, the effect of acetic acid being maximal on undifferentiated epithelium. Thus, its effect on mildly dysplastic epithelium is considerably less than on HSIL (► Fig. 8.125, ► Fig. 8.126). Condylomata, especially flat ones, show a characteristic shiny white mother-of-pearl hue (► Fig. 8.91, ► Fig. 8.93a).

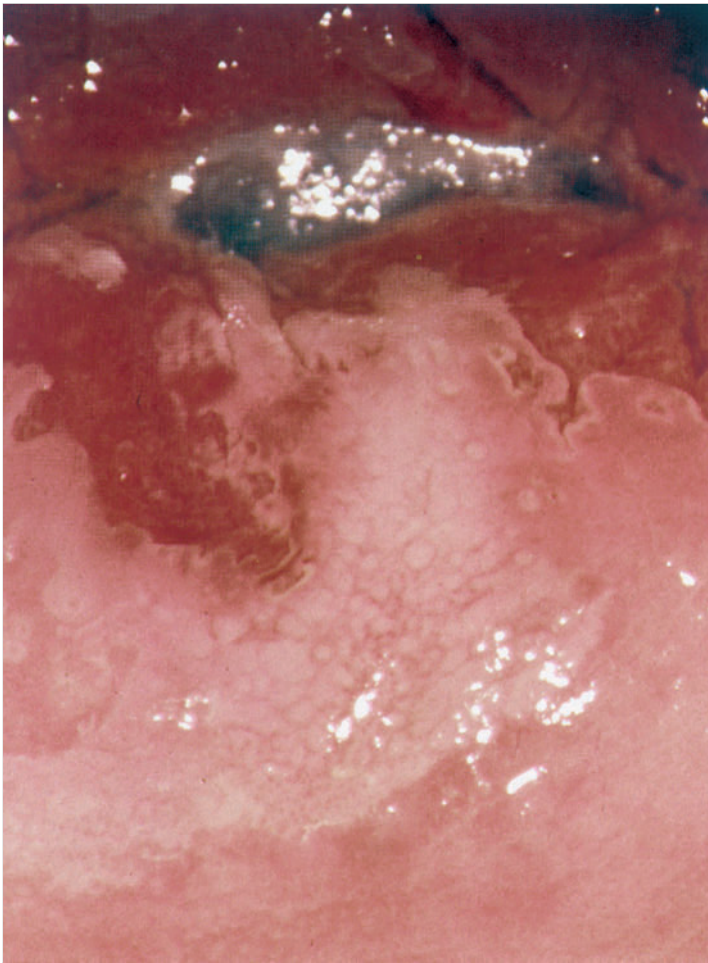


Fig. 8.125 Moderately coarse mosaic with mild accentuation of the surface contour following application of acetic acid. Histology showed HSIL (CIN 2).

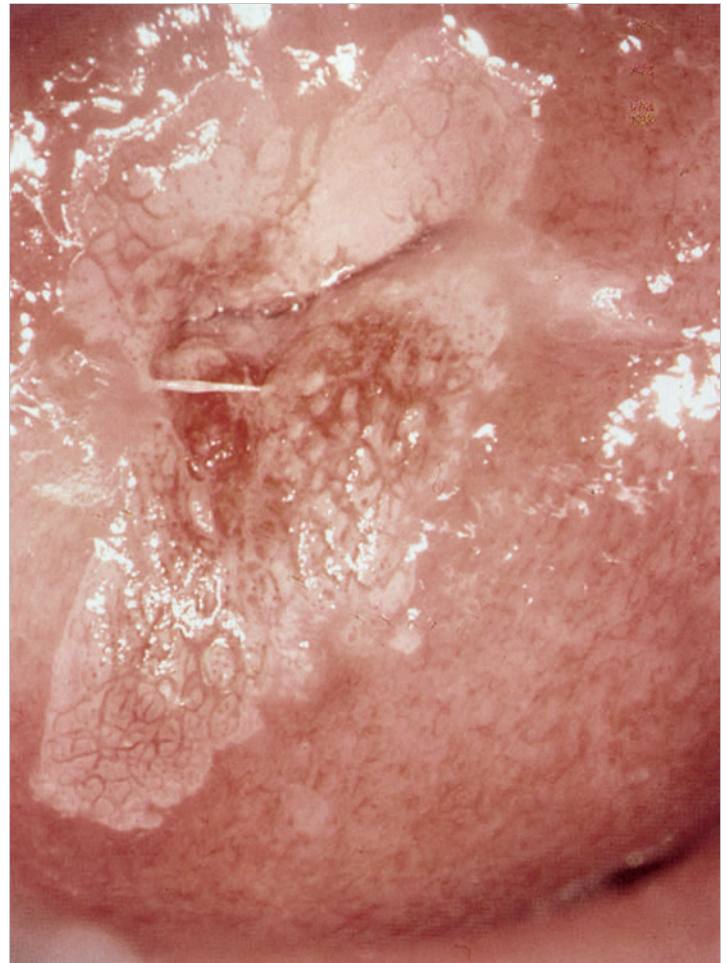


Fig. 8.126 Coarse mosaic with marked swelling and elevation of the epithelium after application of acetic acid. Histology showed HSIL (CIN 3).

8.5.3 Surface Contour

Punctuation and mosaic produced by metaplastic epithelium resemble a delicate sketch, the dots being small and the lines fine. The distance between the spots is not excessive, and the epithelial fields between the lines are small and regular. These features become more distinct after application of acetic acid (► Fig. 8.127) but do not project from the surface. Punctuation produced by SIL can appear in marked cases (HSIL) as *elevated papillae* (► Fig. 8.128) and the lines of mosaic as *coarse ridges* (► Fig. 8.126). In contrast to metaplastic epithelium, the dots (or papillae) of SIL are more widely separated; similarly, the epithelial cobbles of a mosaic are larger. After application of acetic acid, these structures become more prominent and raised above the surface. In clear-cut cases, it is easy to differentiate between fine and coarse mosaics and punctations. There is a spectrum of appearances between the two extremes, the proper categorization of which depends on the evaluation of the remaining criteria.

Flat condylomas, which are essentially benign, can show coarse patterns of punctuation and mosaic with an irregular surface configuration (► Fig. 8.129). Their pearly surface can distinguish them from HSIL, the surfaces of which are characteristically opaque. Because flat condylomas frequently coexist with papillary or spiked condylomas, the presence of one or more spikes on or near the lesion is a useful diagnostic feature.

8.5.4 Cuffed Gland Openings

The presence of gland openings is a characteristic feature of the TZ. They are visible proof that columnar epithelium has been replaced by squamous epithelium. The metaplasia is often restricted to the rims of the gland outlets, leaving the mouths open. The metaplasia can also involve the glandular crypts, so that the gland openings will be completely lined by squamous epithelium (► Fig. 4.27). Colposcopically, such events are evidenced by the development of white cuffs after application of acetic acid (► Fig. 8.19). The cuff will be wider and more pronounced after acetic acid (► Fig. 8.33) in HSIL compared with normal or metaplastic epithelium (► Fig. 8.19, ► Fig. 8.23). Such an appearance is referred to as a “cuffed gland opening.”

8.5.5 Blood Vessels

Over the years, a great deal of importance has been attached to the vascular pattern.^{17,18,19,20} The nature of the blood vessels is an important diagnostic feature. During the reproductive years, the vasculature is not always visible under the well-developed squamous epithelium. The vascular pattern is enhanced by inflammation and by the attenuation of the covering epithelium and is a prominent feature of well-circumscribed epithelial lesions.

The blood vessels are best inspected at the beginning of the colposcopic examination. Acetic acid can suppress the vasculature to

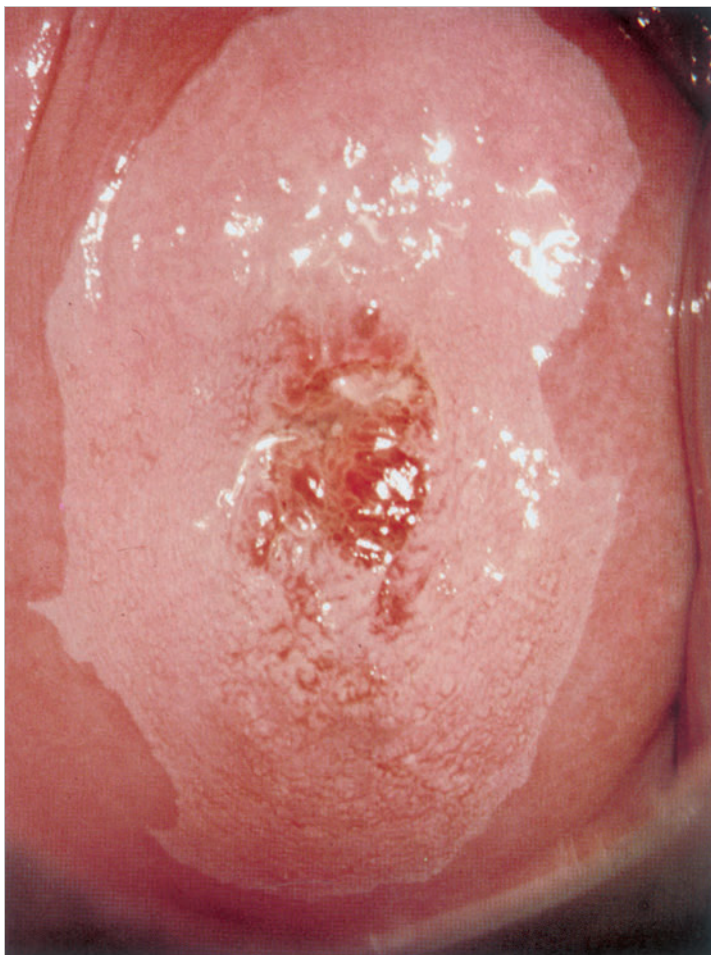

Fig. 8.127 Fairly fine mosaic. The sharply circumscribed acetowhite epithelium remains in the same plane as its surroundings. Histology showed metaplastic epithelium.

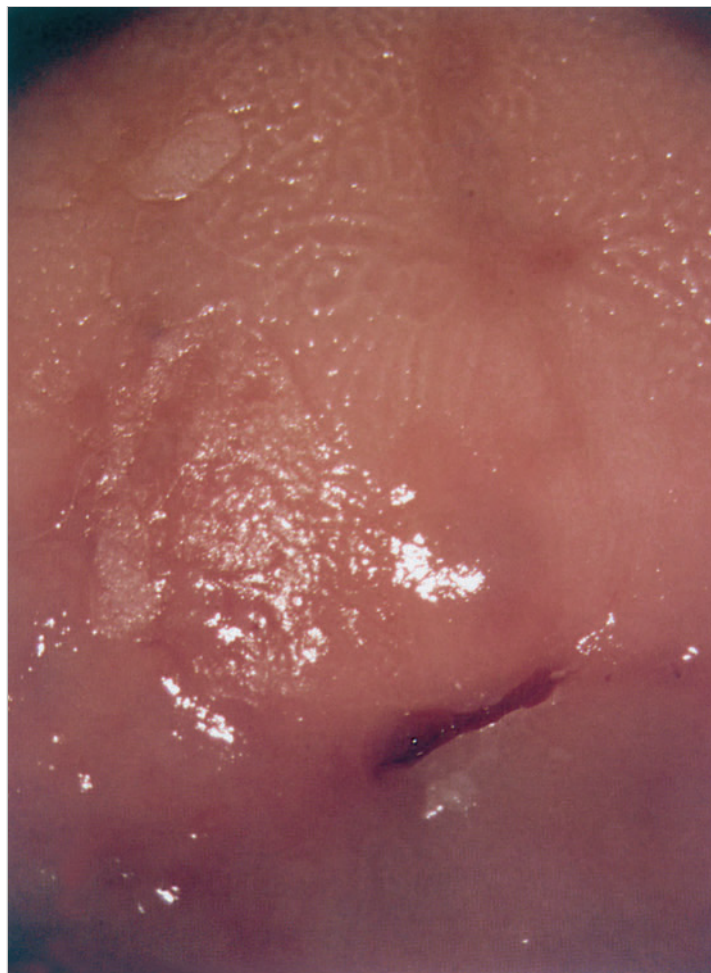


Fig. 8.129 Numerous flat condylomas with gyrate surfaces. In between, there are small, markedly cornified areas.

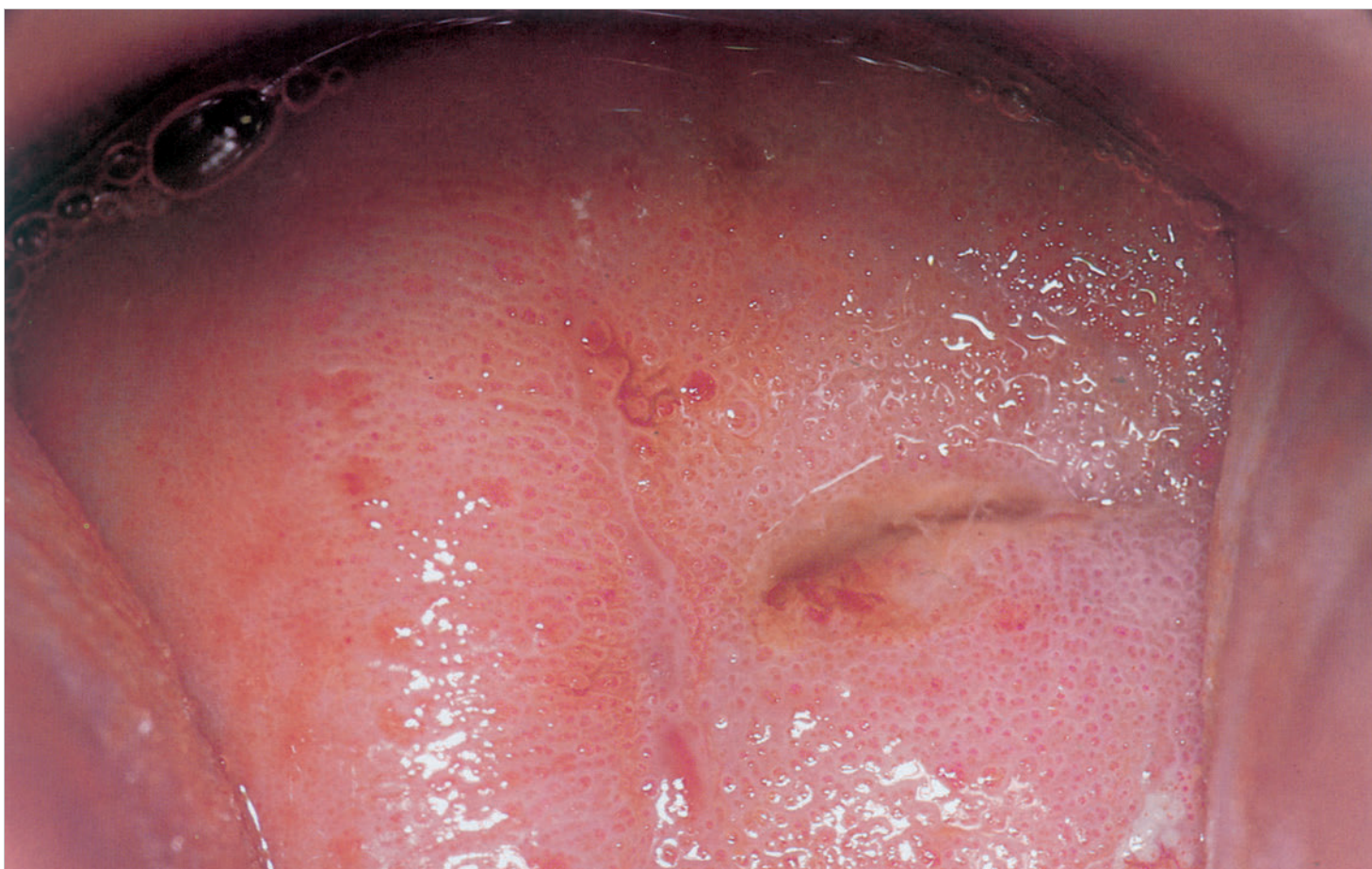


Fig. 8.128 Pronounced papillary punctation. Histology showed HSIL (CIN 3) with early stromal invasion (FIGO stage IA1).

the point that it almost disappears (► Fig. 8.27). A green filter, which screens out red and makes the vessels appear dark, can enhance the vascular appearance. Like others,^{21,22} we distinguish between various vascular patterns.

8.5.6 Nonsuspicious Vascular Pattern

The course and branching of the vessels are regular, with gradual reduction in caliber. The distance between the regular terminal capillary loops, the so-called *intercapillary distance*, is normal (► Fig. 8.130a–f). The distribution of these vessels is usually diffuse, and they do not appear in lesions that are clearly circumscribed. Nonsuspicious vessels are characteristic of diffuse inflammation, when the cervix assumes a stippled appearance. On higher magnification, the capillary loops are hairpin or, when not seen in their entirety, comma-shaped.

Diagnostic difficulties can arise if the inflammatory foci are not regularly dispersed, as in colpitis macularis, but vary in size and distribution (► Fig. 8.101). The blood vessels in such lesions can be particularly clearly etched out and can be fork-shaped or antler-shaped; the intercapillary distance, however, remains normal. The appearances can mimic punctation. These lesions are always poorly circumscribed, a feature seen especially well after application of iodine.

The neat, finely knit meshwork of blood vessels of atrophic, postmenopausal squamous epithelium can be distinctive (► Fig. 8.131).

The individual vessels of the vascular network of the normal TZ tend to be long and regularly arborizing, with no abrupt change in direction or in caliber. The vessels decrease in caliber as they branch out. Nabothian follicles show normal vascular patterns. The long blood vessels that traverse these yellowish structures are relatively large and show regular branching and gradual loss of caliber (► Fig. 8.132). They are so characteristic that the presence of deep-seated and otherwise invisible nabothian follicles can be inferred (► Fig. 8.133).

8.5.7 Suspicious Vascular Pattern

The first hint of atypia is the presence of blood vessels in sharply circumscribed areas (especially with iodine) (► Fig. 8.130g,h). The blood vessels in punctation are fine to coarse and hairpin, comma, or tortuous (corkscrew) in shape, but still regularly arranged. Within this pattern, the appearances show wide variation. The capillary loops in punctation resulting from metaplastic epithelium are delicate and regular, with no increase in the intercapillary distance (► Fig. 8.133). The tortuous corkscrew and comma-shaped vessels associated with SIL are coarser, show haphazard branching, and vary in caliber; the intercapillary distance is increased (► Fig. 8.134, ► Fig. 8.135, ► Fig. 8.136).

A similar range of appearances is seen in the various expressions of mosaic. The delicate mosaic pattern associated with metaplastic epithelium is produced by small, evenly distributed epithelial fields subdivided by thin red ridges (► Fig. 8.127). In coarse mosaic, the dividing lines are more definite, the resulting fields larger and more irregular (► Fig. 8.126).

Even relatively regular and more or less parallel vessels can appear suspicious when they are wider (compare ► Fig. 8.131, ► Fig. 8.137) and show an abrupt change in caliber (► Fig. 8.134).

The vascular pattern can on occasion mimic a mosaic. Closer inspection, however, shows that the vessels in these circumstances display treelike branching and uniform reduction in caliber and appear in poorly circumscribed areas (► Fig. 8.130f).

8.5.8 Atypical Vessels

The 2011 colposcopic terminology includes atypical vessels as a separate diagnostic entity. Atypical vessels show a completely irregular and haphazard disposition, great variation in caliber, and abrupt changes in direction, often forming acute angles (► Fig. 8.130i–k). The intercapillary distance is increased and tends to be variable (► Fig. 8.138). Highly atypical vessels are characteristic of invasive carcinomas (► Fig. 8.69b, ► Fig. 8.139, ► Fig. 8.140). When flattish lesions display focal collections of such vessels, microinvasion should be suspected (► Fig. 8.141).

8.5.9 Surface Area (Size)

Morphometric studies of conization specimens have shown that the surface extent of SIL increases with the severity of the lesion.²³ Thus, lesions caused by ESI are larger than those from HSIL, which in turn are larger than those from LSIL. This does not mean that fields of HSIL are larger than those of LSIL per se but that the former are more likely to be combined with the latter so that the total area is larger. The marked increase in the surface extent of early invasive lesions is also due to coalescence of fields of LSIL and HSIL. There is a direct relationship between size and likelihood of invasion.

The same conclusions apply to colposcopic lesions. Colposcopically suspicious but small lesions are frequently not of histologic significance, whereas colposcopically highly suspicious lesions are consistently extensive. Small lesions are more likely to be LSIL than HSIL or invasive carcinoma. This does not contradict the principles of evaluation of intraepithelial lesions as detailed in Chapter 3. On the contrary, the coexistence of different epithelia shows that invasive potential is acquired by their coalescence and not by progression of one type to another.

These statements do not apply to metaplastic epithelium, which can involve only small areas or cover the whole cervix and even parts of the vagina (congenital TZ). Consequently, size alone is not a diagnostic criterion; size should be considered only in concert with other criteria. If the latter point to atypia, large size should further raise the index of suspicion. This has been accounted for in the 2011 nomenclature (see Chapter 7) with the inclusion of the size of the lesion (expressed as the number of cervical quadrants or percentage of the cervix covered).⁶

8.6 Combinations of Abnormalities

► Table 8.1 (section 8.4.1) lists the rate of SIL or microinvasion in cone biopsies according to types of abnormal colposcopic findings. The rate of SIL or microinvasion is less than 50% for all types of individual findings; but if the patterns of leukoplakia, mosaic, and punctation are combined, the chance of finding SIL or microinvasion rises to 80%. These facts are entirely

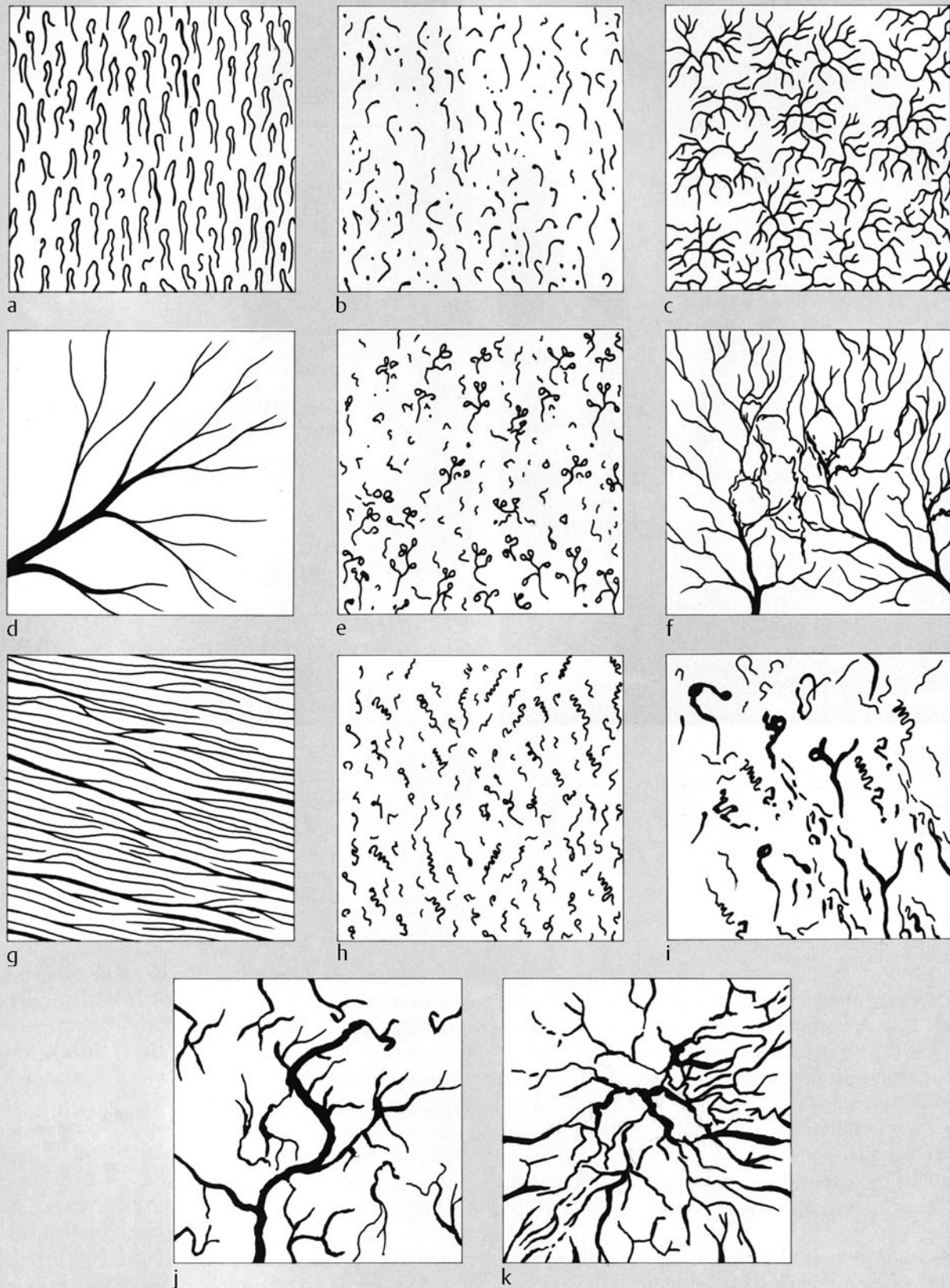


Fig. 8.130 Normal and atypical vascular patterns on the cervix. (a) Hairpin-shaped capillary loops. (b) Comma-shaped capillaries. (c) Blood vessels with regular branching. (d) Long, regularly branching vascular tree, with gradual decrease in caliber. (e) Staghorn-like vessels, seen especially in inflammation. (f) Regular vascular network, simulating mosaic. (g) Long parallel-coursing blood vessels, with some variation in caliber. (h) Irregular corkscrew vessels that vary only slightly in caliber. (i) Bizarre, tortuous, atypical vessels, with marked variation in caliber. (j) Atypical blood vessels with gross variation in caliber and arrangement and abrupt changes in direction. (k) Irregular vessels with great fluctuation in caliber.

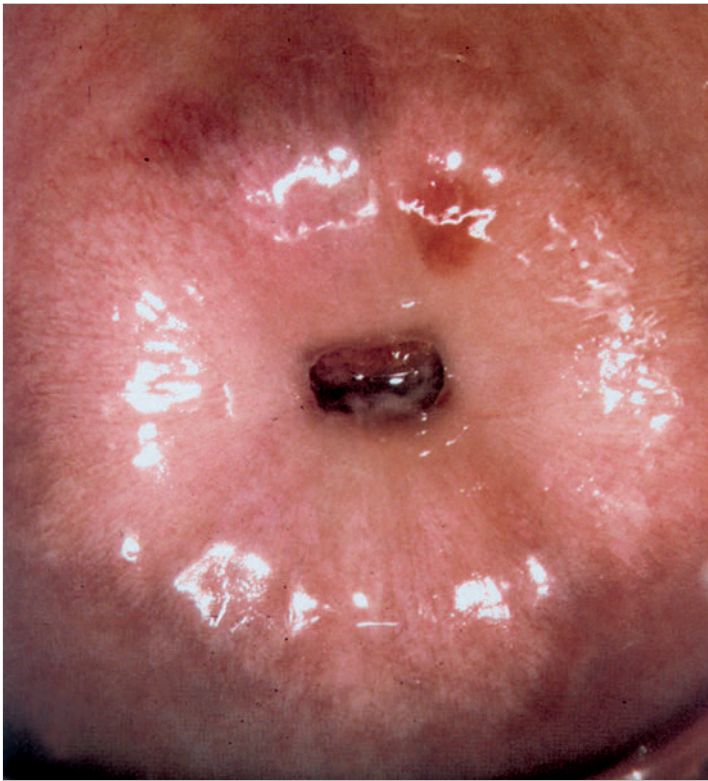

Fig. 8.131 Thin, atrophic squamous epithelium allows the fine radial network of blood vessels to shine through; the vascular pattern is not suspicious (compare with ► Fig. 8.12).

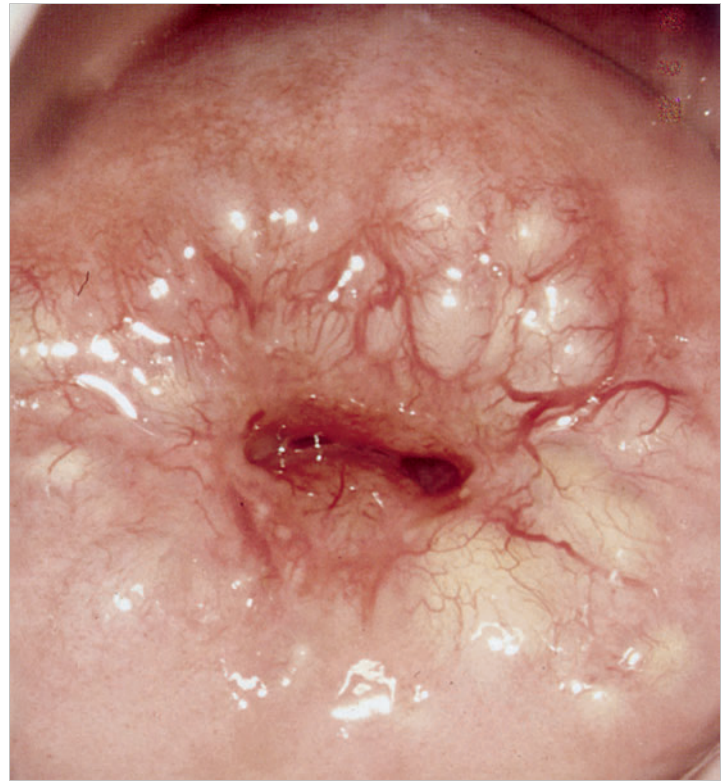

Fig. 8.132 Typical vascular tree over a nabothian follicle. Note the regular branching.

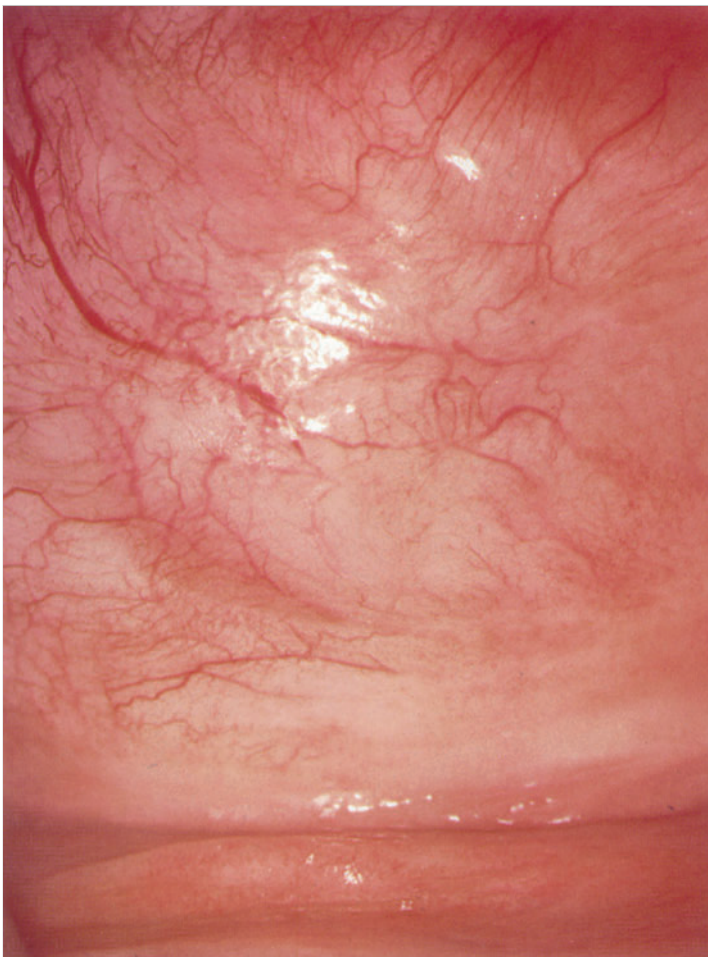


Fig. 8.133 Long, regularly branching blood vessels over the surface of a deep nabothian follicle. Note the gradual decrease in caliber.

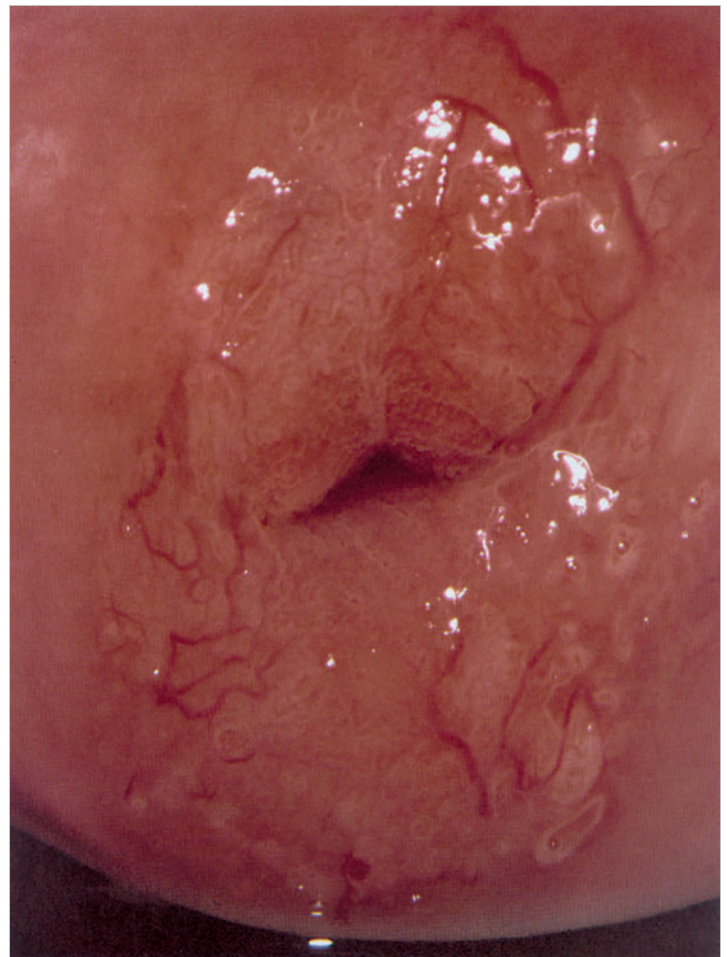

Fig. 8.134 Long, suspicious vessels in white epithelium. The caliber of the vessels varies slightly, and there are some abrupt changes in direction. Histology showed LSIL (CIN 1) with koilocytosis.

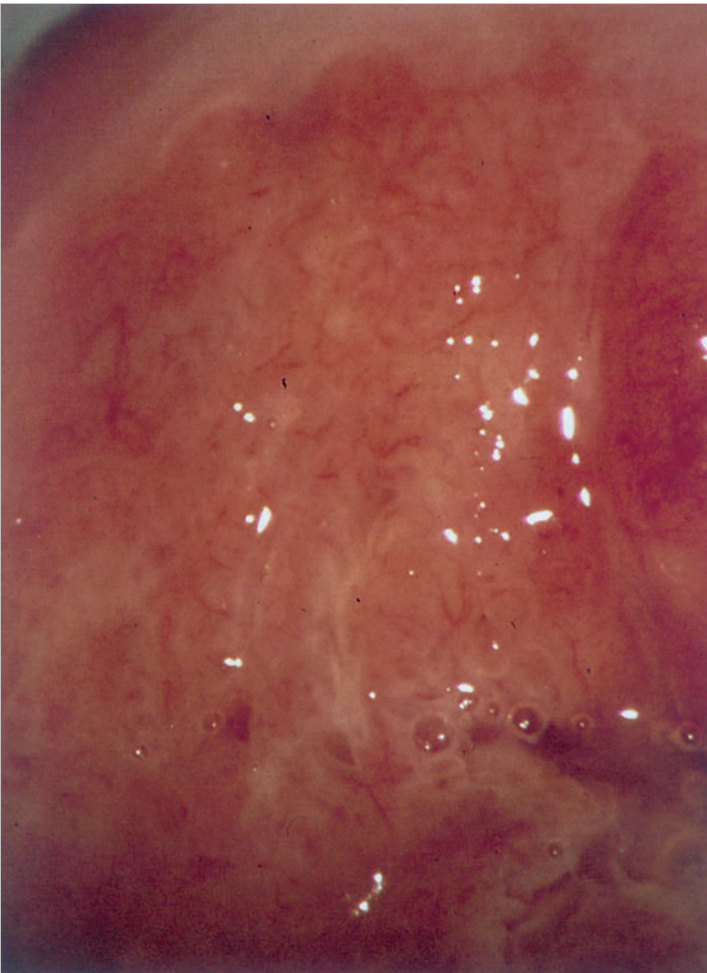


Fig. 8.135 Suspicious vessels in a white epithelium. Histology showed HSIL (CIN 3).

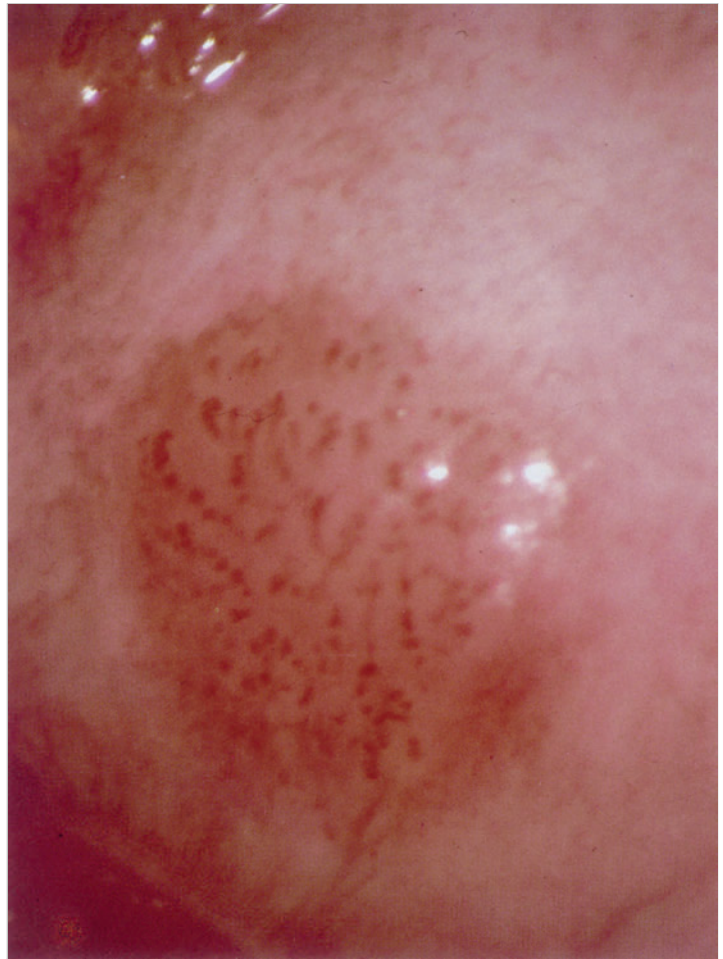

Fig. 8.136 Atypical vessels. The coarse, tortuous, comma-shaped, and corkscrew-shaped vessels vary distinctly in caliber. The intercapillary distance is markedly increased. Histology showed HSIL with early stromal invasion (FIGO stage 1A1).

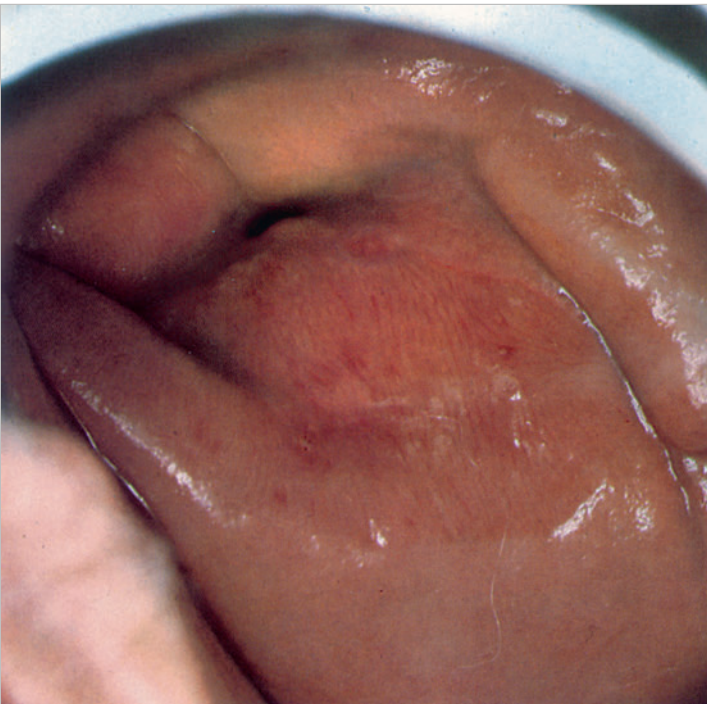


Fig. 8.137 Coarse parallel vessels showing great variation in caliber, skirting an invasive squamous cell carcinoma.

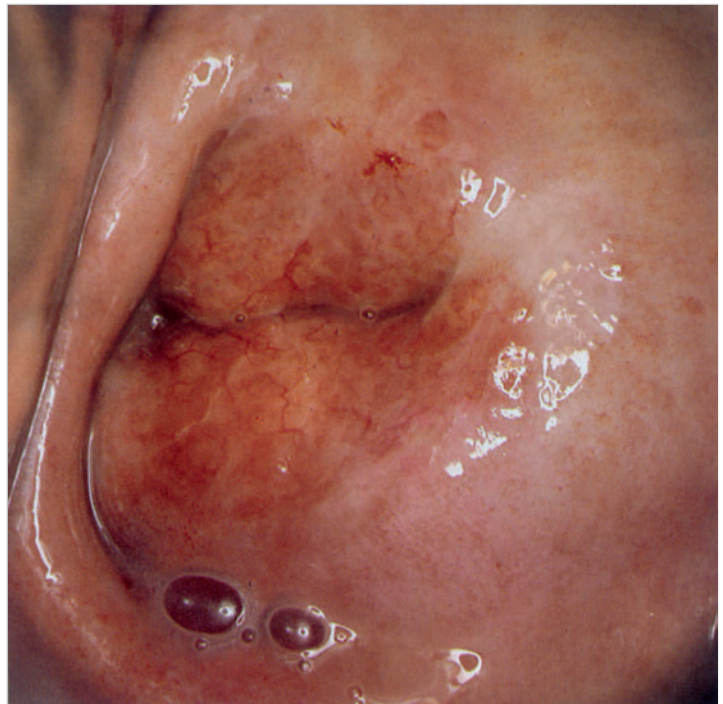

Fig. 8.138 Atypical vessels showing large variation in width and abrupt changes in direction at the margin of a squamous cell carcinoma in the canal.

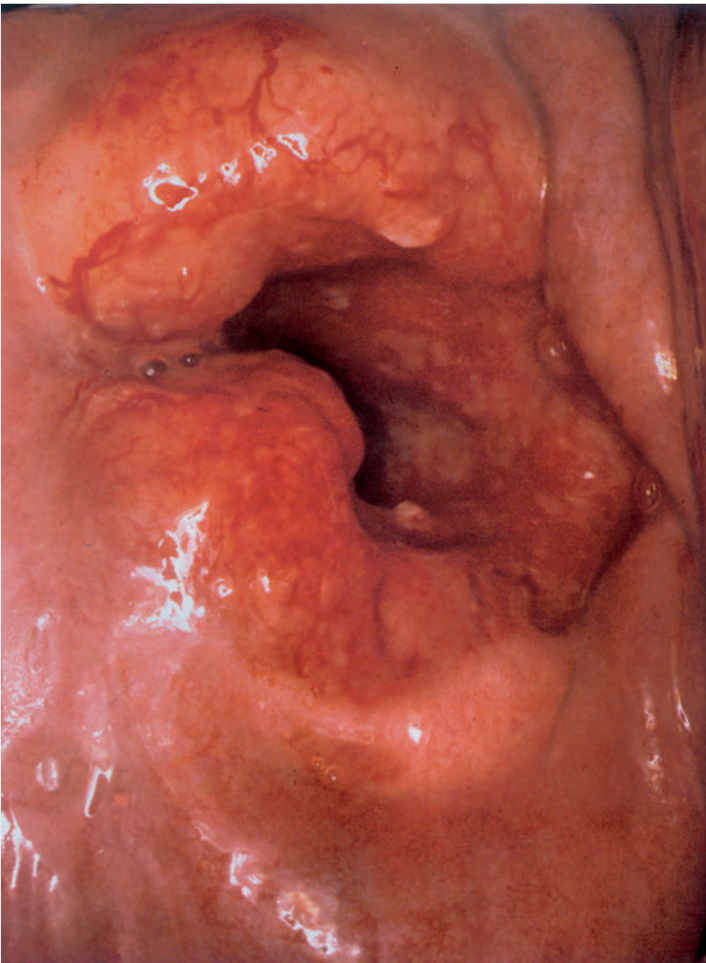


Fig. 8.139 Highly atypical vessels on the anterior lip in a partly exophytic and partly endophytic squamous cell carcinoma. Note the complete irregularity and large variations in width.

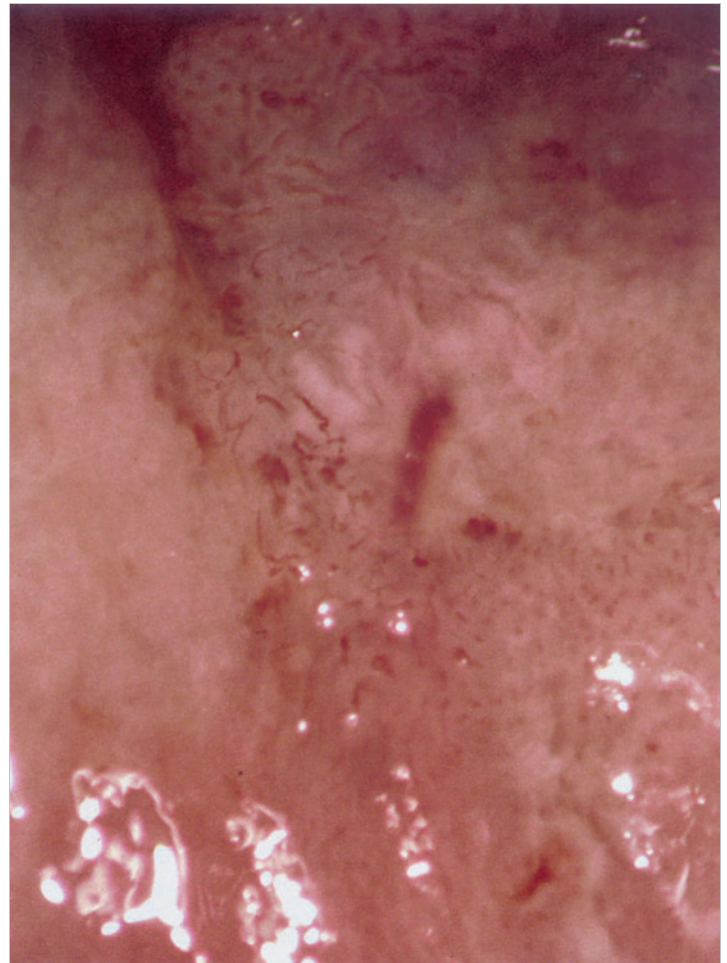

Fig. 8.140 A great variety of atypical vessels in an invasive squamous cell carcinoma.

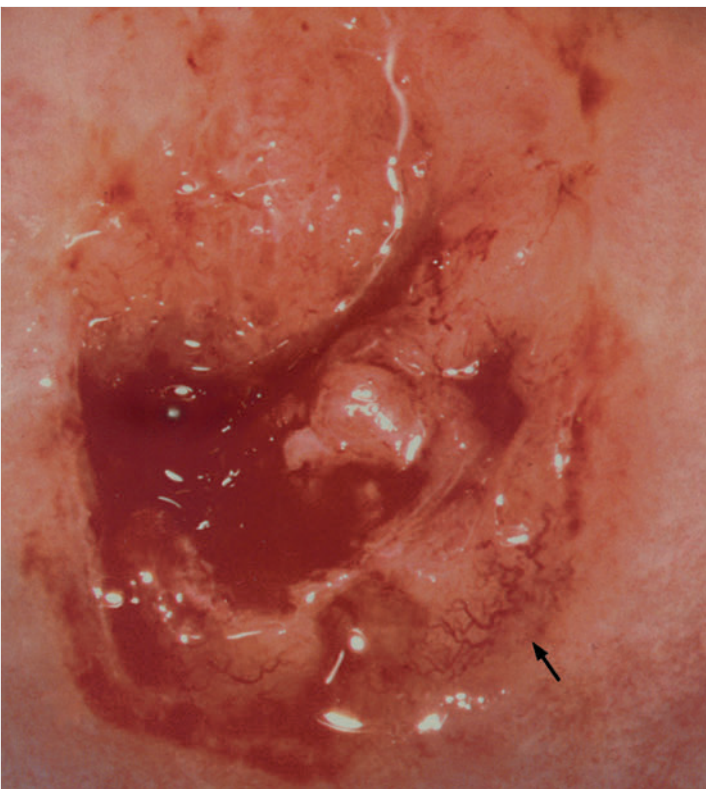


Fig. 8.141 Focal collection of atypical vessels over the surface of a microcarcinoma on the posterior lip (*arrow*).

consistent with the observation that significant lesions are a patchwork of several epithelial types, including those showing various degrees of atypia (► Fig. 10.1, ► Fig. 10.2, ► Fig. 10.3, ► Fig. 10.4).⁸

8.6.1 Iodine Uptake

Colposcopic findings differ markedly in the intensity of staining with iodine (Lugol's solution; Schiller test). Also, iodine staining enhances colposcopic borders. Brownish or brown staining from glycogen decreases the risk of SIL or invasive disease (► Fig. 8.142a,b). An area that does not take up iodine at all can contain columnar epithelium or thin, regenerating, nonspecific epithelium. Well-developed metaplastic epithelium characteristically stains uniformly canary yellow and remains flat (► Fig. 8.143). SIL also stains canary yellow, but it becomes mottled, and its surface is not so smooth. In cases of punctuation and mosaic, the surface contour remains more clearly visible when the epithelium is dysplastic and not metaplastic, as the latter is essentially flat. The same applies when the Schiller test is used.

8.6.2 Keratinization

Keratinization is not a particularly useful diagnostic criterion. All grades of keratinization, from mild parakeratosis to pronounced hyperkeratosis, both of which appear colposcopically as

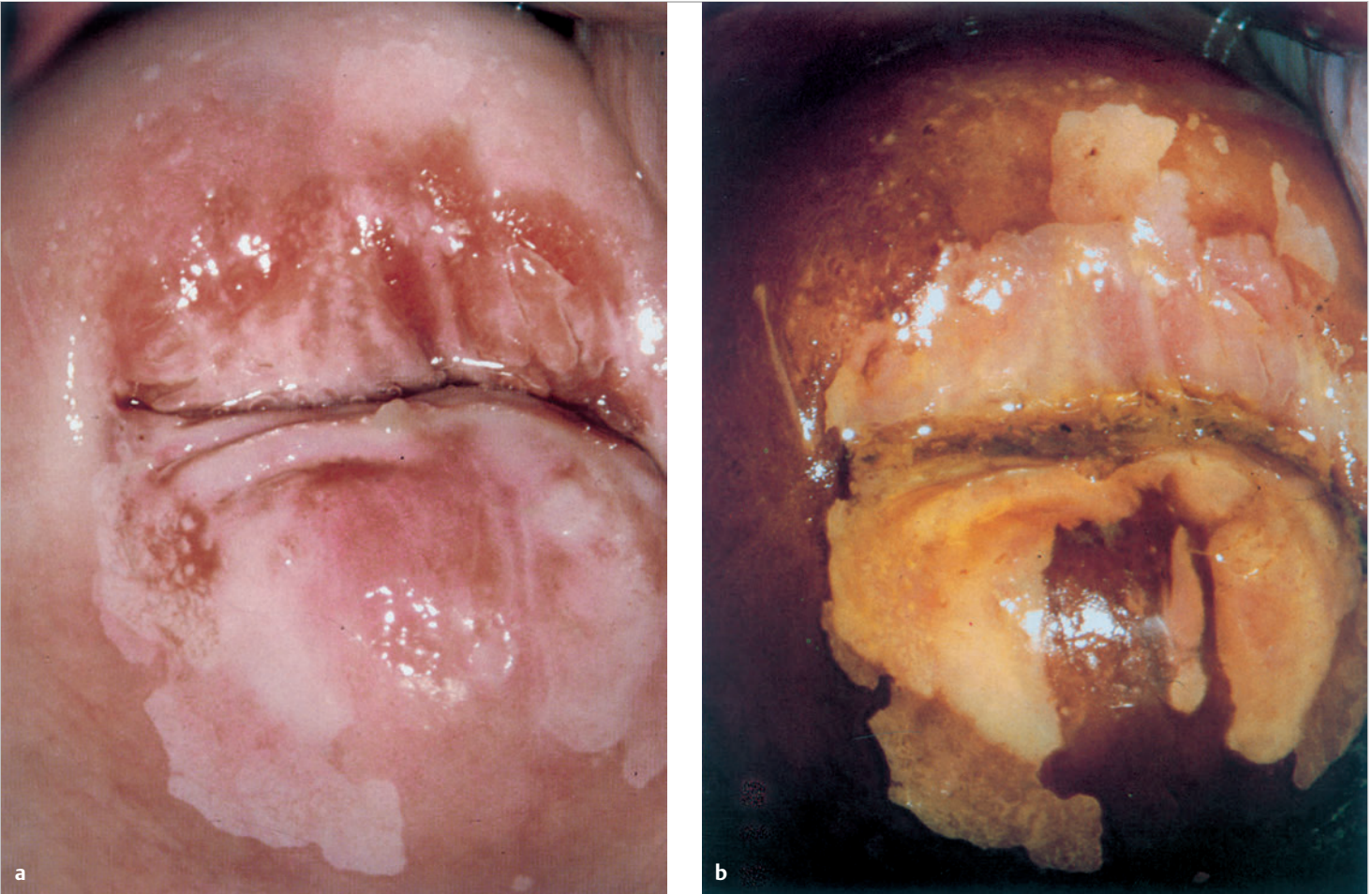

Fig. 8.142 (a) Acetic acid reveals a raised lesion with a variegated appearance between 6 o'clock and 8 o'clock (so-called ridge sign). Between 3 o'clock and 6 o'clock are two distinct fields of acetowhite epithelium (so-called inner border sign). Note the moderately coarse mosaic between 8 o'clock and 9 o'clock. (b) Iodine staining allows a more detailed analysis of an already complex colposcopic picture. The area seen in (a), now brownish, is probably a flat condyloma. The brown area on the posterior lip represents fully mature transformed squamous epithelium. The equally well-demarcated iodine-yellow area at 12 o'clock is due to metaplastic epithelium. The remaining yellow patches are HSIL (CIN 3).

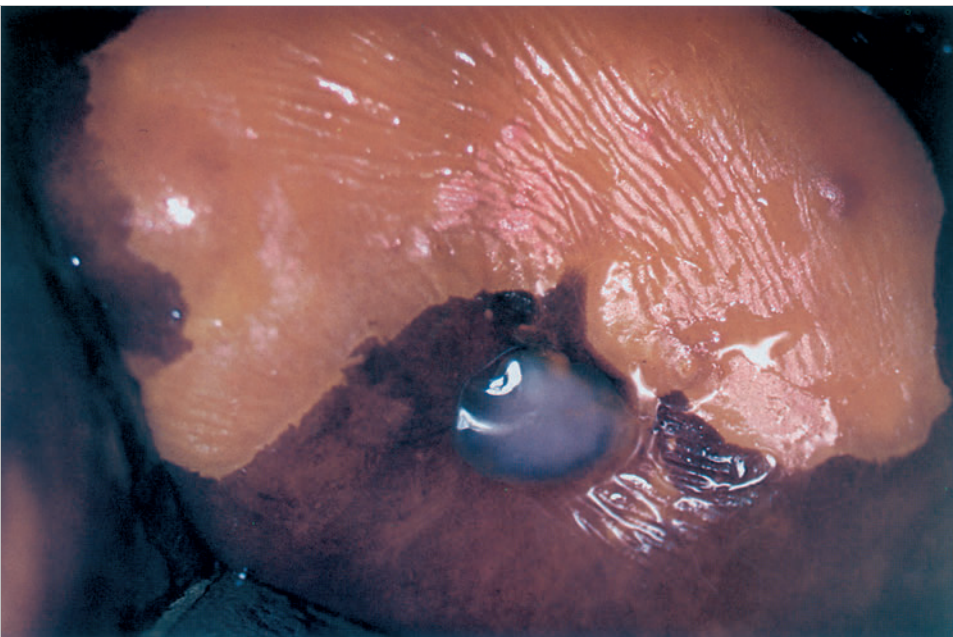


Fig. 8.143 Sharply circumscribed, smooth, iodine-yellow lesion from metaplastic squamous epithelium.

leukoplakia, can be seen with both metaplastic epithelium and SIL. However, a mild degree of keratinization often corresponds to metaplastic epithelium, whereas flaky keratin suggests atypia.

The keratin layer obscures not only the surface contour but also the margins, and inhibits the effect of acetic acid. There is poor uptake of iodine resulting in a light yellow color. If the keratin layer can be peeled off, features of diagnostic importance may emerge. All cases of leukoplakia should be evaluated by biopsy.

8.6.3 Weighing Differential Diagnostic Criteria

The diagnostic features described in this chapter can be expressed to varying degrees and can be found singly or in combination. The more distinct a feature is and the greater the variety of features seen in combination, the higher the index of suspicion. Lesions should be viewed with a degree of suspicion by beginners, who should evaluate their findings by biopsy as part of the learning process. Quality can also be improved by repeating the smear if it was initially negative. With increasing practice, the colposcopist will be able to distinguish between benign and suspicious findings with some confidence. However, colposcopy cannot reliably distinguish between various forms of intraepithelial neoplasia.

References

- [1] Graham J, Graham R, Hirabayashi K. Reversible "cancer" and the contraceptive pill. Report of a case. *Obstet Gynecol* 1968; 31: 190–192
- [2] Baader O. Hormonell bedingte kolposkopische Befunde [Colposcopic findings due to hormonal changes]. *Arch Gynakol* 1981; 232: 17
- [3] Baader O. Comparative and long-term colposcopic observation. In: Burghardt E, Holzer E, Jordan JA. *Cervical pathology and colposcopy*. Stuttgart: Thieme, 1978
- [4] Saunders N, Anderson D, Gilbert L, Sharp F. Unsatisfactory colposcopy and the response to orally administered oestrogen: a randomized double blind placebo controlled trial. *Br J Obstet Gynaecol* 1990; 97: 731–733
- [5] Critchlow CW, Wölnner-Hanssen P, Eschenbach DA et al. Determinants of cervical ectopia and of cervicitis: age, oral contraception, specific cervical infection, smoking, and douching. *Am J Obstet Gynecol* 1995; 173: 534–543
- [6] Bornstein J, Bentley J, Bösze P et al. 2011 colposcopic terminology of the International Federation for Cervical Pathology and Colposcopy. *Obstet Gynecol* 2012; 120: 166–172
- [7] Burghardt E. Über die atypische Umwandlungszone [On the atypical transformation zone]. *Geburtshilfe Frauenheilkd* 1959; 19: 676
- [8] Girardi F. The topography of abnormal colposcopy findings. *Cervix Low Female Genit Tract* 1993; 11: 45–52
- [9] Wright VC. Colposcopy of adenocarcinoma in situ and adenocarcinoma of the uterine cervix: differentiation from other cervical lesion. *J Low Genit Tract Dis* 1999; 3: 83–97
- [10] Jordan JA. Colposcopy of the normal transformation zone. *Obstet Gynecol Clin North Am* 1993; 20: 69–81
- [11] Fritsch H, Hoermann R, Bitsche M et al. Development of epithelial and mesenchymal regionalization of the human fetal utero-vaginal Anlagen. *J Anat* 2013
- [12] Martens JE, Smedts F, van Muyden RC et al. Reserve cells in human uterine cervical epithelium are derived from müllerian epithelium at midgestational age. *Int J Gynecol Pathol* 2007; 26: 463–468
- [13] Meisels A, Fortin R, Roy M. Condylomatous lesions of the cervix. II. Cytologic, colposcopic and histopathologic study. *Acta Cytol* 1977; 21: 379–390
- [14] Meisels A, Roy M, Fortier M et al. Human papillomavirus infection of the cervix: the atypical condyloma. *Acta Cytol* 1981; 25: 7–16
- [15] Reid R, Stanhope CR, Herschman BR, Crum CP, Agronow SJ. Genital warts and cervical cancer. IV. A colposcopic index for differentiating subclinical papillomaviral infection from cervical intraepithelial neoplasia. *Am J Obstet Gynecol* 1984; 149: 815–823
- [16] Navratil E. Colposcopy. In: Gray LA, ed. *Dysplasia, carcinoma in situ and microinvasive carcinoma of the cervix uteri*. Springfield, IL: Thomas, 1964
- [17] Ganse R. Atypische Gefässentwicklung beim Portiokarzinom [Atypical vascularization in cervical carcinoma.]. *Zentralbl Gynakol* 1952; 74: 749–752
- [18] Ganse R. Die atypische Gefässneubildung bei Karzinom [Atypical revascularization in carcinoma.]. *Zentralbl Gynakol* 1957; 79: 519–524
- [19] Koller O. *The vascular pattern of the uterine cervix*. Oslo: Universitetsforlaget, 1963
- [20] Madej J. Die Bedeutung der Gefässveränderungen bei der kolposkopischen Diagnostik der Vor- und Frühstadien des Zervixkarzinoms [Significance of vascular changes in the colposcopic diagnosis of precancerous and early stages of cervical cancer] *Geburtshilfe Frauenheilkd* 1983; 43: 606–610
- [21] Mateu-Aragonés JM. *Atlas de colposcopia*. Barcelona: JIMS, 1973
- [22] Kolstad P, Stafil A. *Atlas of colposcopy*. Oslo: Universitetsforlaget, 1982
- [23] Holzer E, Pickel H. Die Ausdehnung des atypischen Plattenepithels an der Zervix [The extent of the atypical squamous epithelium of the cervix uteri]. *Arch Geschwulstforsch* 1975; 45: 79–91

Chapter 9

Colposcopy in Pregnancy

9.1 Effects of Pregnancy on Colposcopic Findings	141
9.2 Benign Changes in Pregnancy	141
9.3 Suspicious Changes	143
9.4 The Puerperium	143
9.5 Biopsy during Pregnancy	145



9 Colposcopy in Pregnancy

A gynecologic examination is indicated in early pregnancy if the patient has not recently had one. This should include a Pap smear and, we believe, colposcopy. The scenario of cervical cancers diagnosed in pregnancy (usually in women without standard gynecologic care) has become uncommon.

The most prominent colposcopic finding seen in pregnancy is the increase in size and number of the blood vessels, leading to hyperemia of the cervix.¹ The stroma is softened and edematous, and the cervix becomes enlarged. The endocervical mucosa is hyperplastic. Proliferation of the columnar cells leads to enlargement and ramification of the glandular crypts, with formation of numerous secondary clefts and tunnels.^{2,3} The endocervical mucosa becomes velvety as a result of deeper extension into the stroma. The end result is a honeycomb appearance of the gland field.

Another characteristic change in pregnancy is a decidual reaction of the stroma. This can be limited and focal or quite extensive and can on occasion produce polypoid lesions referred to as *decidual polyps* (► Fig. 9.1, ► Fig. 9.2, ► Fig. 9.3).

An ectocervix completely covered by squamous epithelium will not change much during the course of the pregnancy. However, occasionally a pregnant woman can develop ectopy, or a pre-existing ectopy can increase in size as a result of the increased

volume of the cervix. (Outside pregnancy ectopy does not develop *de novo*.) It is also possible to produce pseudoectopy during the later stages of pregnancy by everting the cervical lips during speculum examination.

The cervical mucus undergoes characteristic changes during pregnancy, becoming viscous and cloudy, whitish or yellowish, and containing threads or particles (► Fig. 9.4, ► Fig. 9.5). The mucus can be more difficult to remove with acetic acid than in the nonpregnant patient.

Apart from lesions such as decidual polyps (► Fig. 9.1), there are no colposcopic findings specific for pregnancy. The changes occurring during pregnancy are the same as those described in Chapter 3 and Chapter 4. The same applies to reactive changes, inflammation, and infections.

In the past, there has been lively debate as to whether squamous intraepithelial lesion (SIL; also known as cervical intraepithelial neoplasia [CIN]) can develop during pregnancy and regress after the puerperium.^{4,5} Of course, low-grade squamous intraepithelial lesion (LSIL) can regress independently of pregnancy. In contrast, a number of studies have shown that high-grade squamous intraepithelial lesion (HSIL; CIN 3) detected during pregnancy does not regress postpartum.^{6,7,8,9,10} Systematic examination of the cervixes of women in early pregnancy has even shown a surprisingly high incidence of persisting HSIL (CIN 3).¹⁰ These results are of interest from the epidemiologic point of view and underline the importance of standard gynecologic care during pregnancy.¹¹

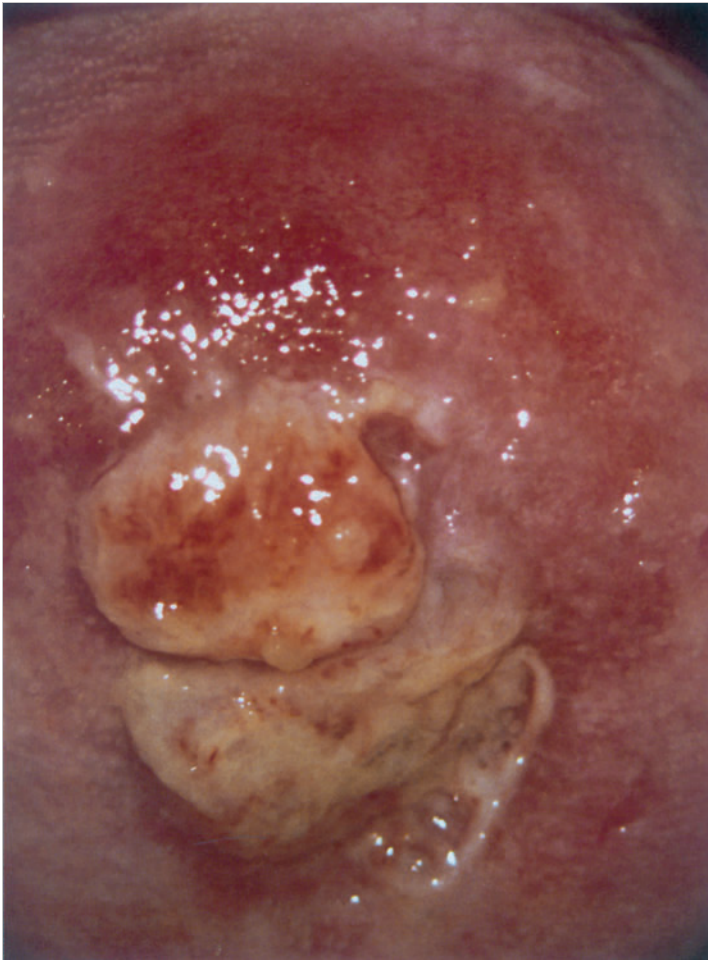


Fig. 9.1 Gravida 3, 20 weeks' gestation. Deciduosis. Grayish, solid formation at the external os. The formation is covered by fibrin, not epithelium. Histology showed a decidual reaction of the stroma.

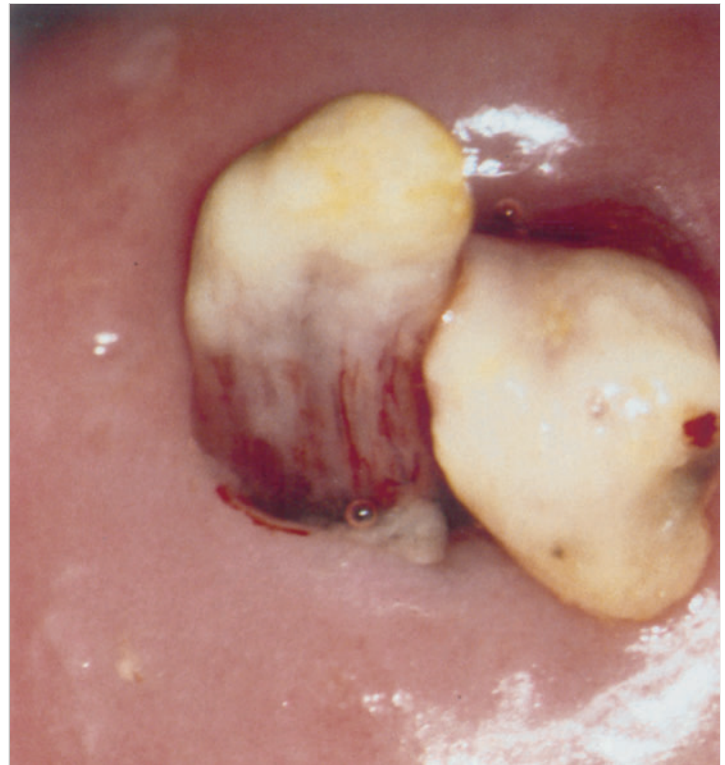

Fig. 9.2 Gravida 2, 8 weeks' gestation. Two decidual polyps in the cervical canal. Their surface is covered with fibrin, which obscures the epithelium. Note the vascular pattern, which is typical for decidual polyps.

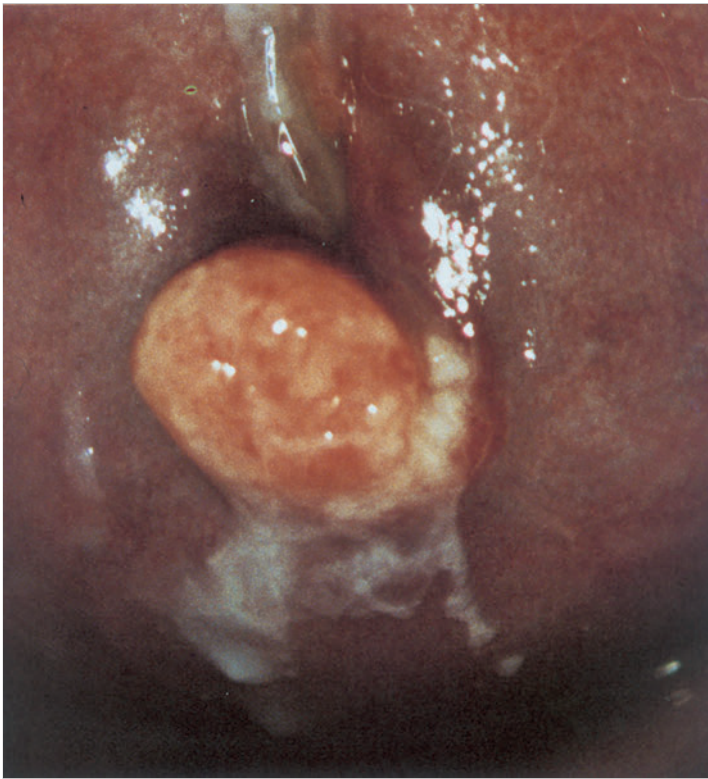

Fig. 9.3 Gravida 2, 16 weeks' gestation, decidua polyp in the cervical canal. The cervix is livid.

9.1 Effects of Pregnancy on Colposcopic Findings

Lividity of the cervicovaginal mucosa was a clinical sign of pregnancy long before ultrasound and immunologic tests were developed. Lividity is due to the increased vascularity of the pelvic organs, especially the venous plexuses. Marked fluid retention gives the cervix a soft consistency, and it becomes softer as the pregnancy advances. Increased fragility and a tendency toward contact bleeding are observed with introduction of the speculum, especially when taking a smear or biopsy.

The lividity and softness bring about background changes in the colposcopic appearance. In contrast to the nonpregnant state, these are coarse and may give even benign changes a suspicious and alarming aspect (► Fig. 9.5, ► Fig. 9.6, ► Fig. 9.7, ► Fig. 9.8, ► Fig. 9.9). This applies especially to the response to acetic acid.

9.1.1 Acetic Acid Test

The effect of acetic acid is more pronounced during pregnancy, so that whitening even of benign lesions can appear suspicious (► Fig. 9.5b, ► Fig. 9.7, ► Fig. 9.9b). Thus, the response to acetic acid can be difficult to interpret during pregnancy. See also Chapter 5.

9.1.2 Schiller (Iodine) Test

The Schiller test is affected by pregnancy only to the extent that the cervicovaginal squamous epithelium turns a more intense brownish black with iodine (► Fig. 9.6b, ► Fig. 9.10, ► Fig. 9.11b). The Schiller test is particularly useful when an area that turns white after acetic acid displays a speckled, but not uniform, brown appearance with iodine (► Fig. 9.9c). Such a finding

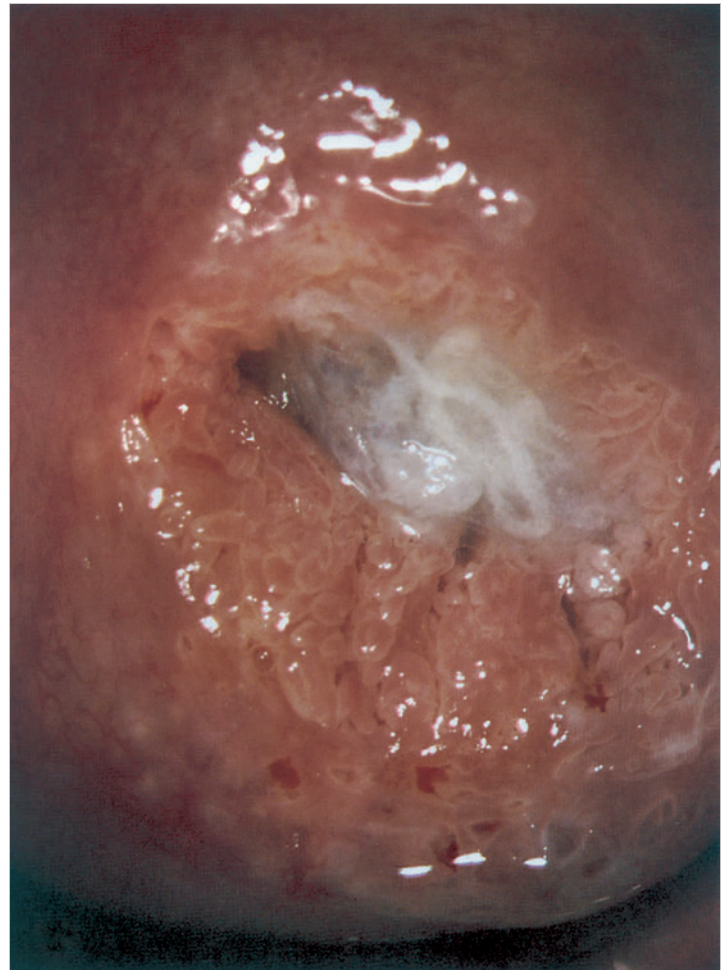

Fig. 9.4 Gravida 3, 17 weeks' gestation. Ectopy with a coarsened texture and deep longitudinal folds. On the posterior lip, transformation is complete, with gland openings and small nabothian cysts shining through. Livid coloration of the entire cervical mucosa. In the os, there is viscous mucus with whitish threads and granules typical of pregnancy.

suggests a condylomatous lesion rather than atypia. See also Chapter 5.

Postpartum, especially in breastfeeding mothers, colposcopy can show areas on the cervix and vagina that do not stain with iodine. This epithelium is glycogen-free as a result of postpartum atrophy (► Fig. 9.12b). After cessation of breastfeeding, conditions revert to normal, with the usual uniform staining of the vagina and cervix.

9.2 Benign Changes in Pregnancy

At the beginning of pregnancy, the cervix is largely unchanged (► Fig. 9.13) and shows the coarse, grapelike appearance of ectopy. The longitudinal folds of the cervical mucosa are particularly distinctive (► Fig. 9.4). Such appearances can be elicited merely by everting the endocervical canal with the speculum. The coarsening of the surface contour of the transformation zone (TZ) can occur early in pregnancy (► Fig. 9.6a). The Schiller test can bring out other diagnostic features, including islands of mature, glycogen-rich epithelium. The indistinct border between the TZ and the surrounding iodine-positive cervix is also suggestive of a benign lesion (► Fig. 9.6b). After acetic acid is applied, a normal TZ often turns more intensely acetowhite than usual, with more prominent gland openings (► Fig. 9.7, ► Fig. 9.14).

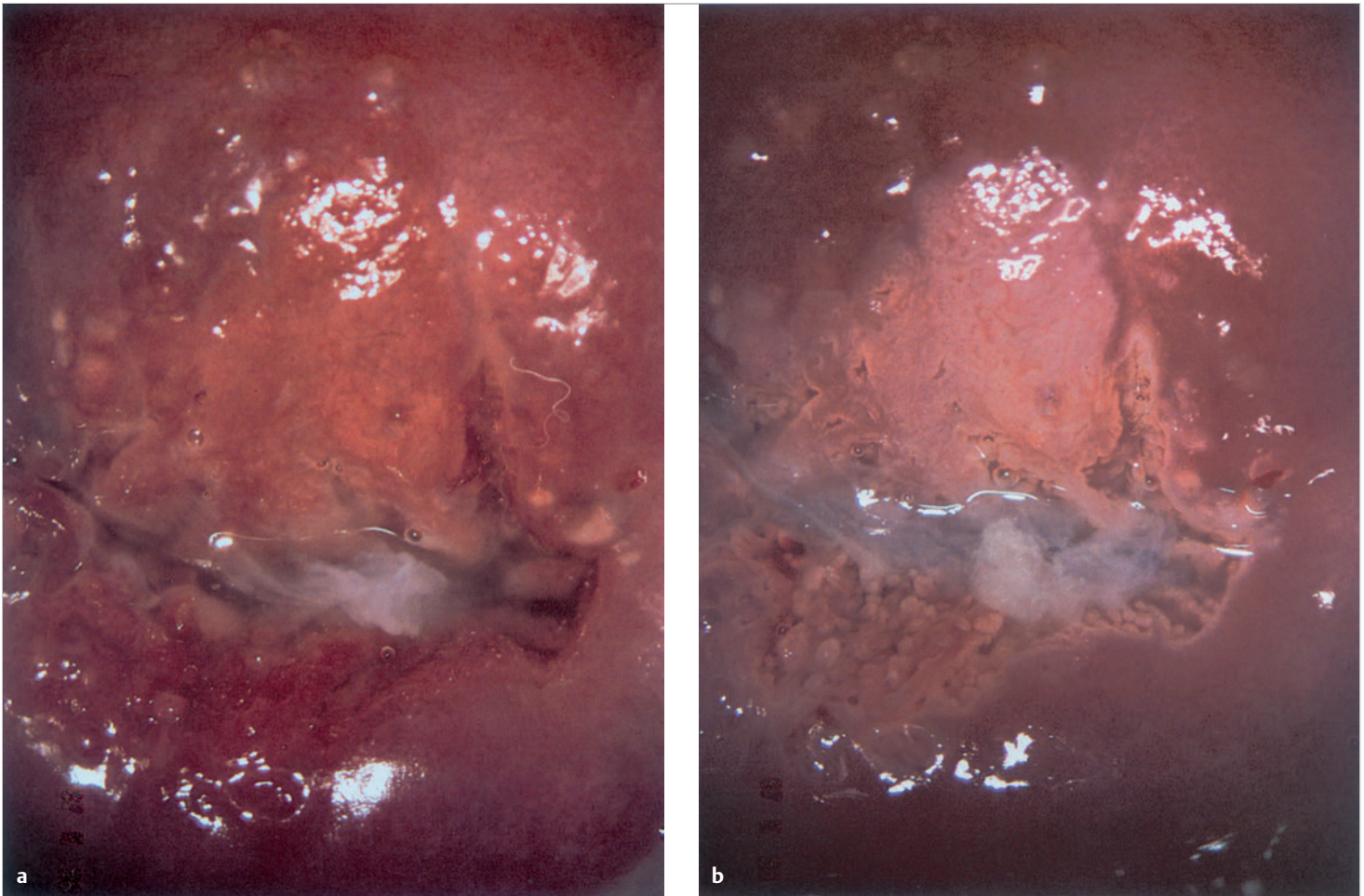


Fig. 9.5 (a) Gravida 2, 18 weeks' gestation. There is a clearly circumscribed, almost unstructured area within an otherwise unremarkable transformation zone on the anterior lip. (b) After application of acetic acid, a few gland openings and a fine mosaic appear within the area described. Histology showed metaplastic epithelium.

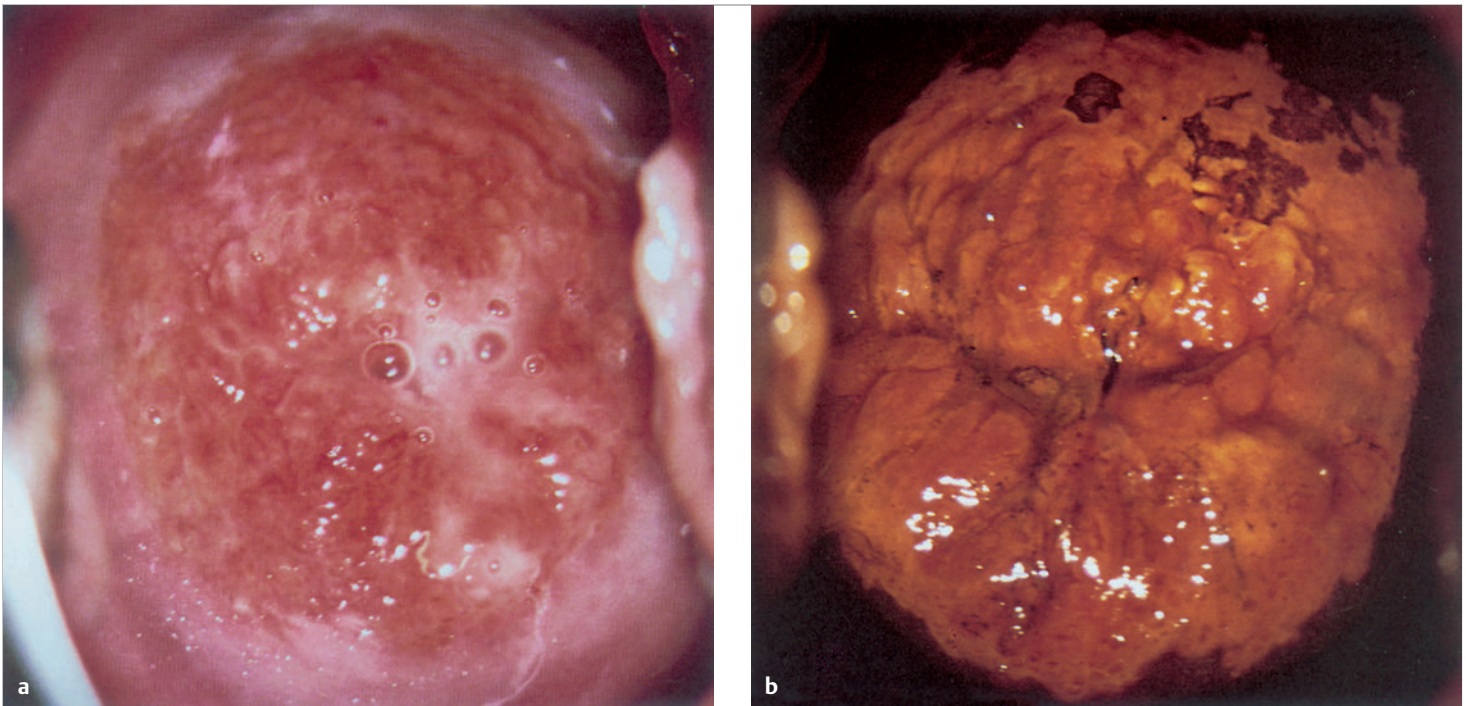


Fig. 9.6 (a) Gravida 2, 11 weeks' gestation. Preexistent transformation zone (TZ) with a slightly coarse surface and increased vascularity. Slightly livid coloration of the original cervical epithelium. (b) After application of iodine (Schiller test), the squamous epithelium is stained dark brown. Within the TZ, there are islands of a mature, glycogen-containing metaplastic epithelium.

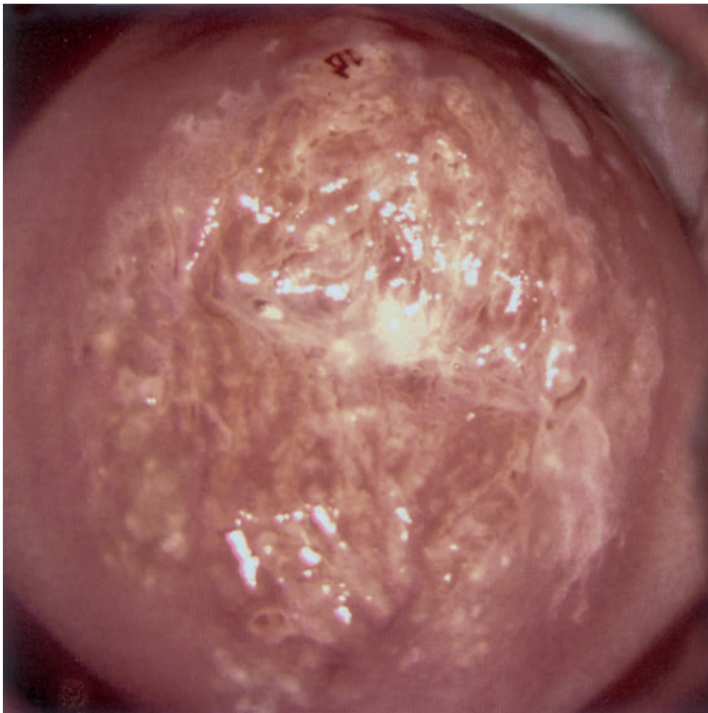


Fig. 9.7 Gravida 1, 8 weeks' gestation. Transformation zone, with a whitish reaction to acetic acid. Cuffed gland openings. Flat condylomas between 12 o'clock and 2 o'clock.

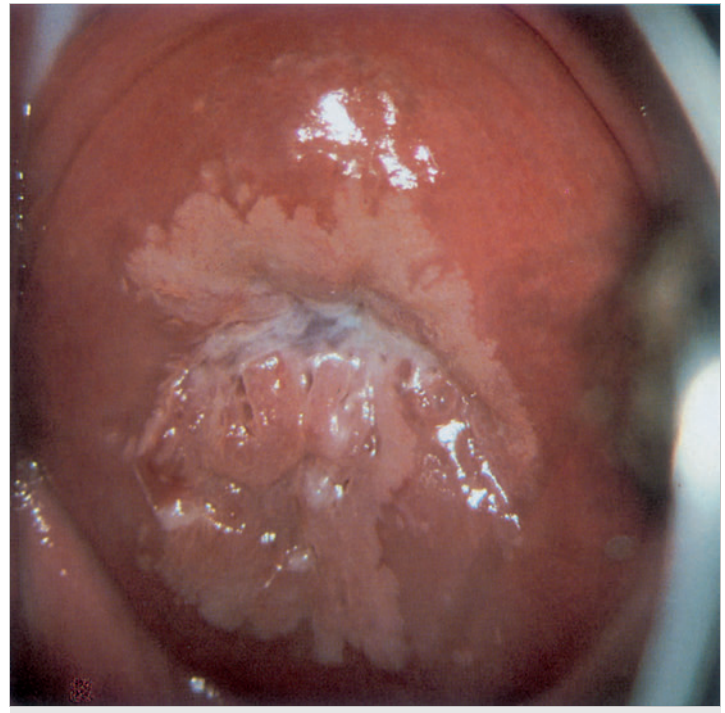


Fig. 9.8 Gravida 1 at 11 weeks' gestation. After acetic acid, a white area with fine mosaic and punctation appears on the anterior and posterior lip inside the transformation zone. The border with the slightly livid original epithelium is sharp. Histology showed metaplastic epithelium.

When transformation is complete, one can see retention cysts and gland openings shining through the lucid epithelium (► Fig. 9.4).

Clearly delineated areas within a normal TZ can appear suspicious, especially when they display an intense and prompt reaction to acetic acid (► Fig. 9.5a,b). In pregnancy, this applies especially to metaplastic epithelium, which can also be clearly demarcated from original squamous epithelium and can show mosaic, punctation, or both (► Fig. 9.8). In such cases, the small size and regular appearance of the mosaic, or delicate and regular punctation, provide helpful diagnostic hints. In the case of some coarser-looking lesions, and certain combinations of changes, it may be difficult or impossible to make an exact colposcopic diagnosis (► Fig. 9.9a–c).

The decidual reaction can barely be seen colposcopically, as it manifests itself in the deeper cervical stroma. Decidual polyps, however, are easily distinguished from conventional endocervical polyps. The latter often are covered by smooth, pink metaplastic squamous epithelium (► Fig. 8.108) or display the typical grape-like pattern of columnar epithelium, whereas decidual polyps are yellowish and not covered by epithelium (► Fig. 9.1, ► Fig. 9.2, ► Fig. 9.3).

Condylomatous lesions are relatively common in pregnancy. Except for a certain softness, they are similar to those in the non-pregnant patient (► Fig. 9.15). Inflammatory lesions look the same as they do outside pregnancy. Because the normal squamous epithelium has a deeper brown color, they stand out strongly after iodine (► Fig. 9.10; see also ► Fig. 8.103b).

9.3 Suspicious Changes

Colposcopic findings corresponding to SIL (CIN) are rather uniform in pregnancy. The distinction between LSIL and metaplastic

epithelium is difficult (► Fig. 9.5, ► Fig. 9.8, ► Fig. 9.9, ► Fig. 9.16). An irregular, coarser appearance of mosaic, for example, suggests HSIL (as it does outside of pregnancy). Lesions can occur just outside the TZ (► Fig. 9.11, ► Fig. 9.17). Lividity can give an abnormal colposcopic finding a particular hue (► Fig. 9.18), which can be overlooked or interpreted as harmless. In other cases, one may find an abnormal appearance with strong white coloration of the sharply circumscribed TZ (► Fig. 9.19). Bright red lesions are particularly striking, are always suspicious, and, in cases of HSIL, also respond characteristically to acetic acid (► Fig. 9.20a,b).

Condylomas can lose their typical pearly-white appearance (► Fig. 8.98) during pregnancy. They can assume a dark red undertone, which makes them difficult to recognize as condylomas (► Fig. 9.21a). An important diagnostic aid in such cases is the application of iodine (Schiller test), which elicits a distinctive brown staining, with sparing of small clear patches producing a speckled appearance (► Fig. 9.21b). This appearance corresponds to the iodine-positive mosaic in ► Fig. 8.98b. During the course of the pregnancy, it can become coarser, more livid, and more succulent (► Fig. 9.21c,d). After the puerperium, one can often observe the regression of condylomas (► Fig. 9.21e), which merely displays islands of brown-staining epithelium at the periphery (► Fig. 9.21f).

9.4 The Puerperium

Lesions established during pregnancy remain essentially unchanged during the puerperium but lose the characteristic features of pregnancy (► Fig. 9.12a, ► Fig. 9.21a–f). The Schiller test can reveal surprising findings: parts of the cervix and varying lengths of the corrugated surface of the vagina remain unstained (i.e., glycogen-free) (► Fig. 9.12a,b), particularly in breastfeeding women. The appearances are probably caused by the

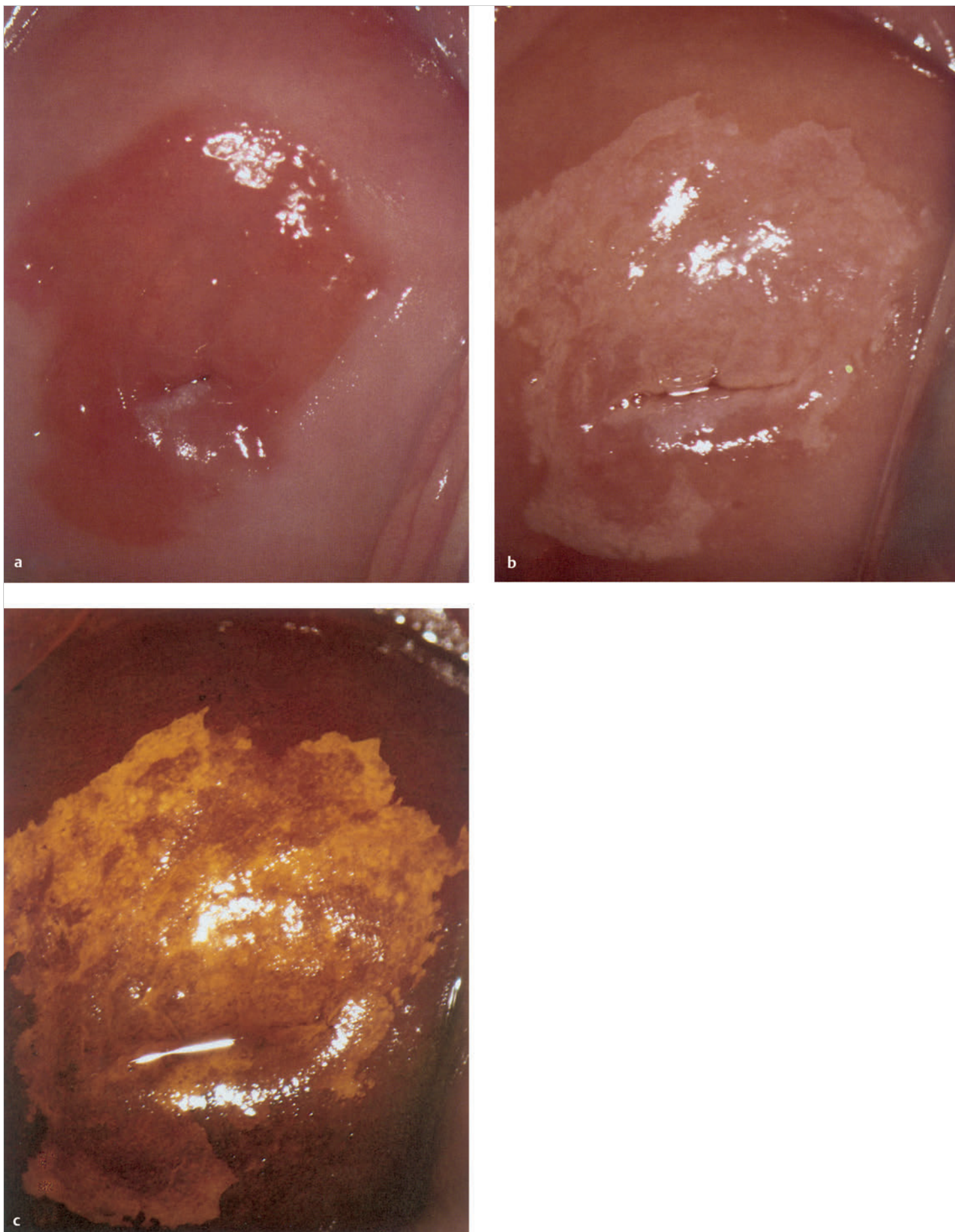


Fig. 9.9 (a) Gravida 1, 11 weeks' gestation. Shiny red area within the livid squamous epithelium. (b) After acetic acid, the entire area turns white, but without swelling. There are small areas of fine mosaic. An isolated field can be delineated between the 11 o'clock and 12 o'clock positions. (c) After application of iodine, there is a patchy, partly brown staining of the previously completely white area. Histology showed metaplastic epithelium.

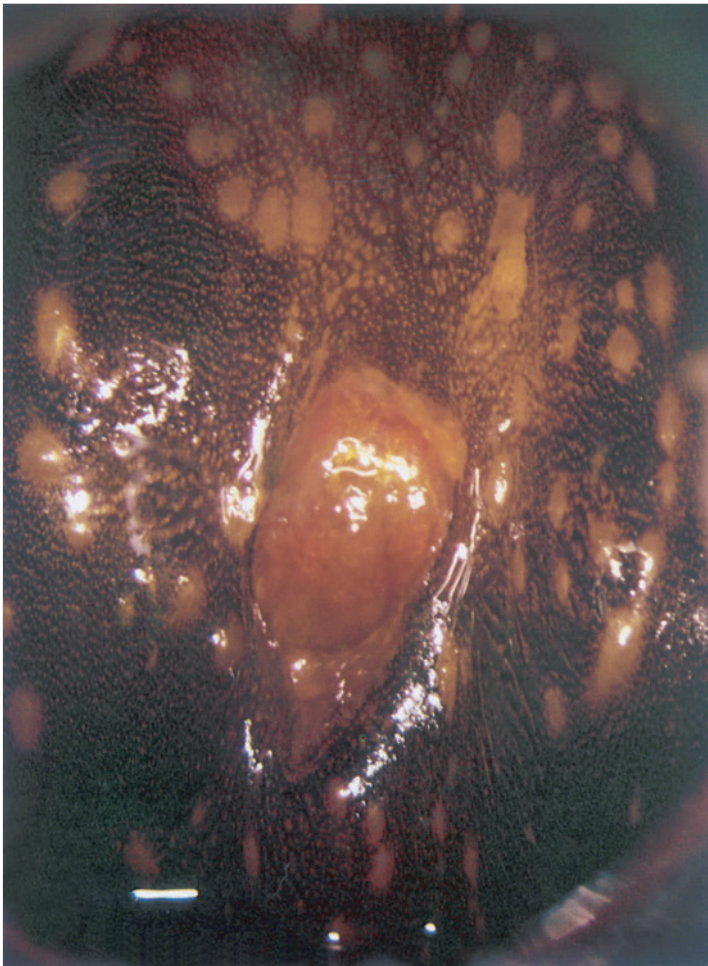


Fig. 9.10 Gravida 8, 20 weeks' gestation. Cervix after conization. The external os is slitlike; the mucosa on the anterior lip is slightly everted. The plaques of macular colpitosis are distinct from the dark brown cervical squamous epithelium.

hypoestrogenemic state induced by lactation and revert to normal after cessation of lactation.

9.5 Biopsy during Pregnancy

Colposcopy in pregnancy is used to rule out invasive cervical cancer. It is quite possible to perform a punch biopsy of the cervix during pregnancy (► Fig. 5.14). Bleeding can be controlled with a tampon (► Fig. 5.13), which should be left in for a few hours. Careful endocervical curettage can also be performed when indicated; naturally, this should not reach the upper confines of the endocervical canal, where lesions are rare during pregnancy.

Conization during pregnancy is discussed in section 12.4.

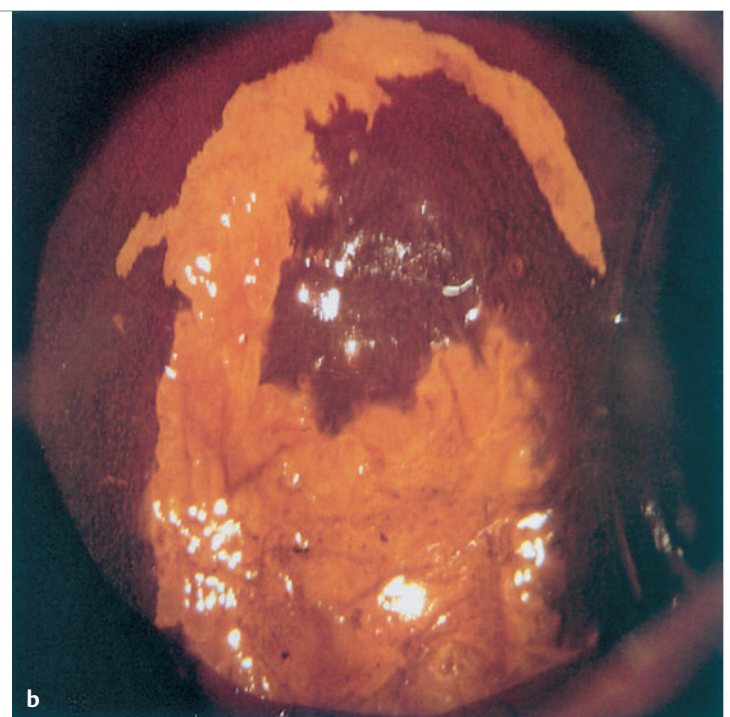
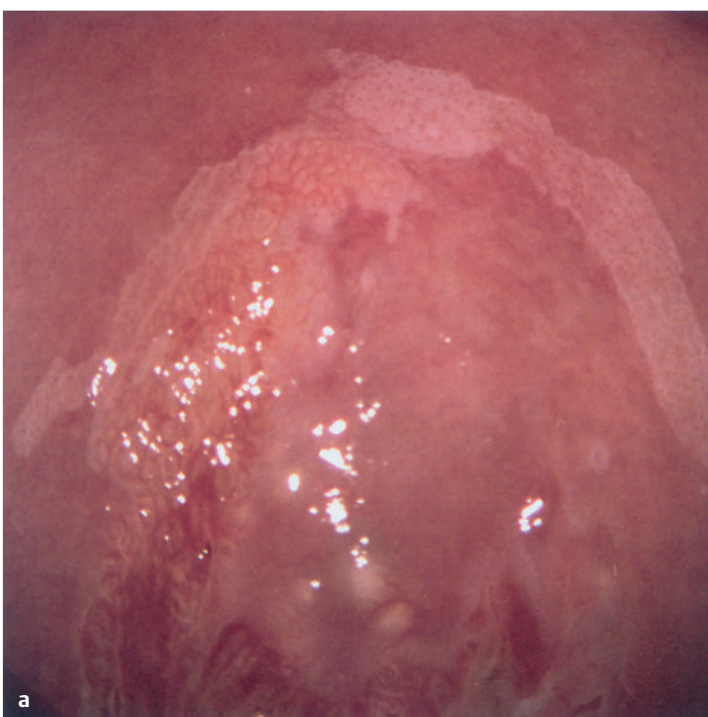

Fig. 9.11 (a) Gravida 2. A livid transformation zone (TZ) on the anterior lip, with mature metaplastic squamous epithelium and retention cysts shining through. The TZ is semicircularly surrounded by a narrow band of fairly coarse, irregular mosaic. Histology showed HSIL (CIN 2). (b) At a lower magnification, and after application of iodine (Schiller test), the narrow band with the mosaic is sharply demarcated. The epithelium in the completed TZ on the anterior lip is stained dark brown. On the posterior lip, there is an early TZ with a diffuse border.

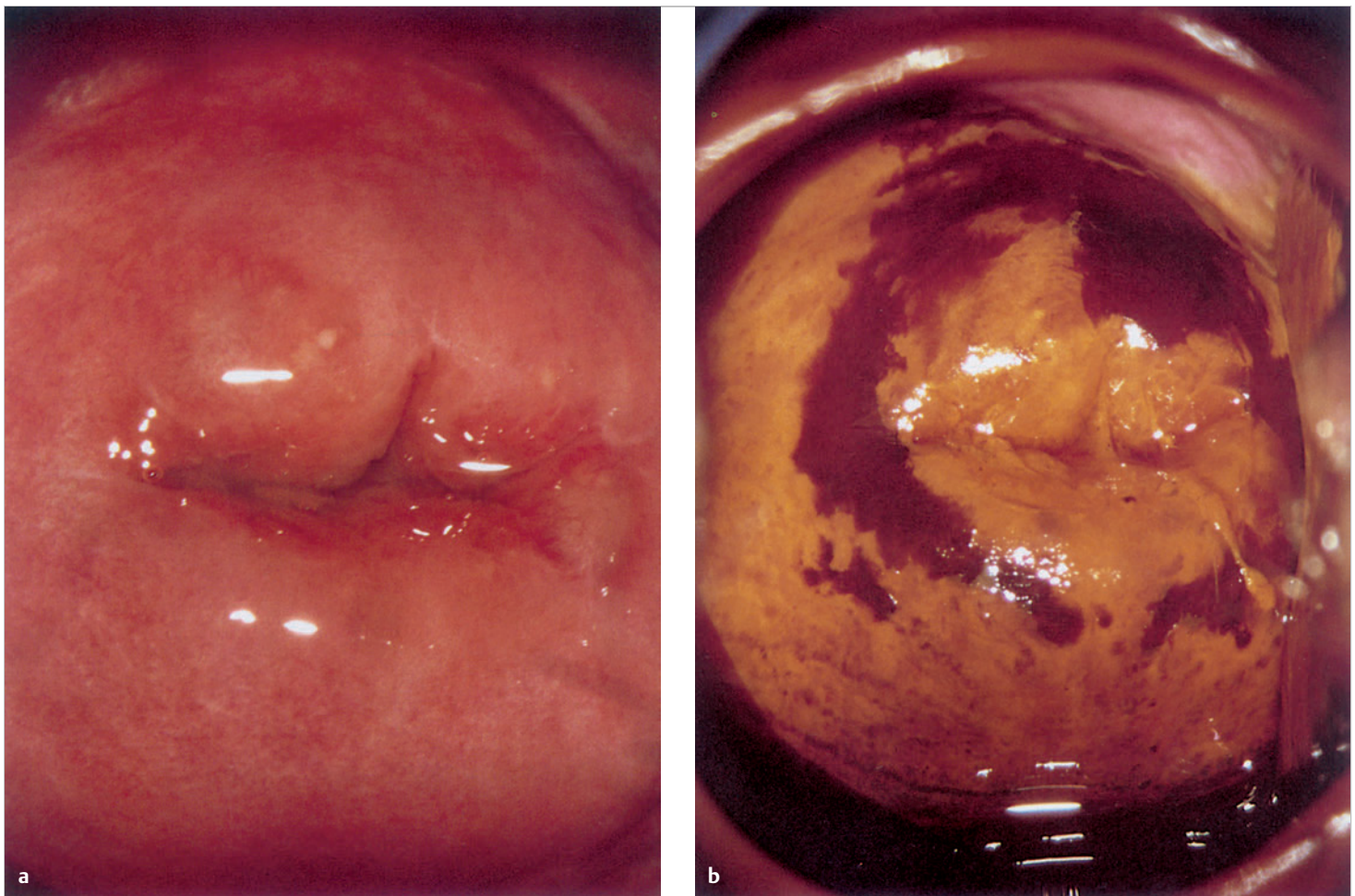


Fig.9.12 (a) Four weeks after delivery. The cervix is still slightly red and edematous, with a narrow transformation zone. (b) After the Schiller test, surprisingly large areas of the cervix and vagina are not stained (i.e., glycogen-free). Islands of brown staining appear within these areas.

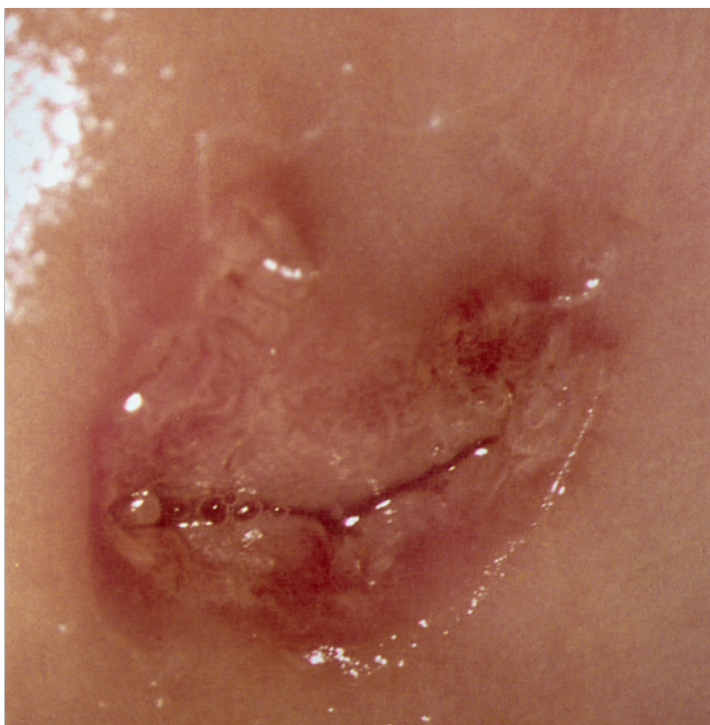

Fig.9.13 Gravida 5, 10 weeks' gestation. Narrow transformation zone, slight lividity.

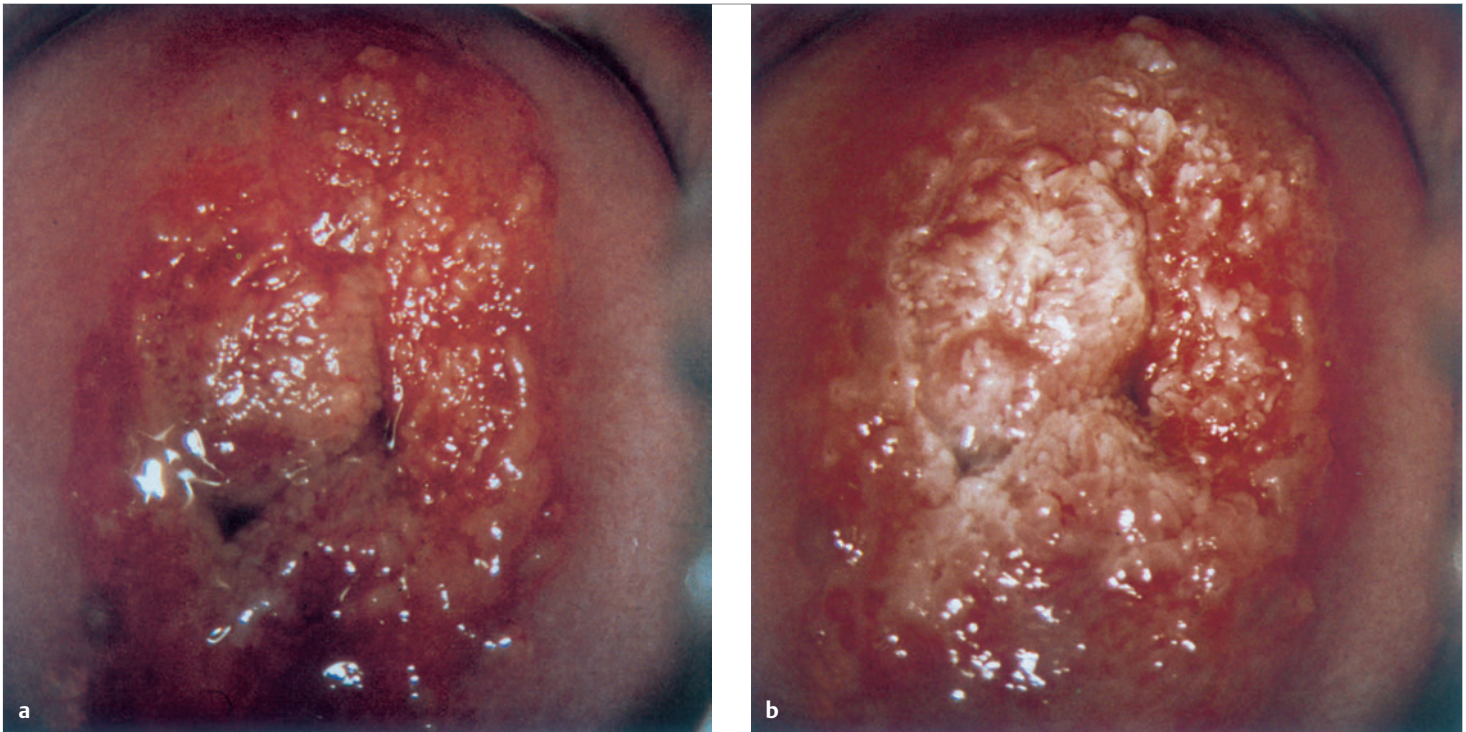


Fig. 9.14 (a) Gravida 2, 13 weeks' gestation. Ectopy and transformation zone (TZ) with elevated decidual foci on the posterior lip of the cervix. (b) After application of 3% acetic acid, the columnar epithelium swells markedly but the TZ and the decidual foci remain largely unchanged.

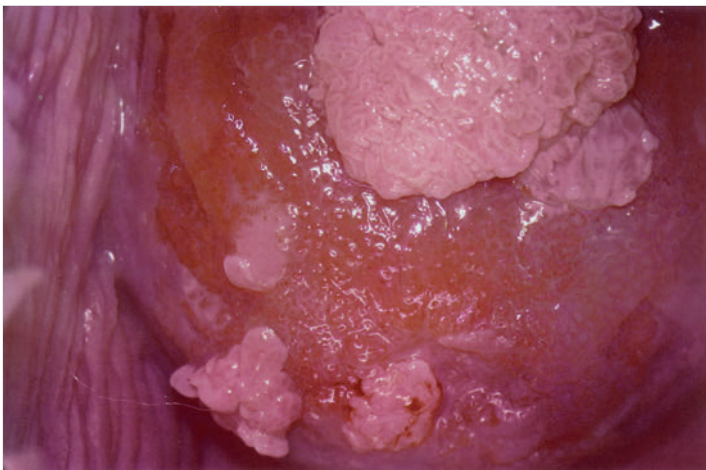

Fig. 9.15 Thirty weeks' gestation. Papillary condylomas, around the external os. The vagina and cervix are highly congested. Within this lesion, and at its edge are condylomatous excrescences that have also assumed a deep red color.

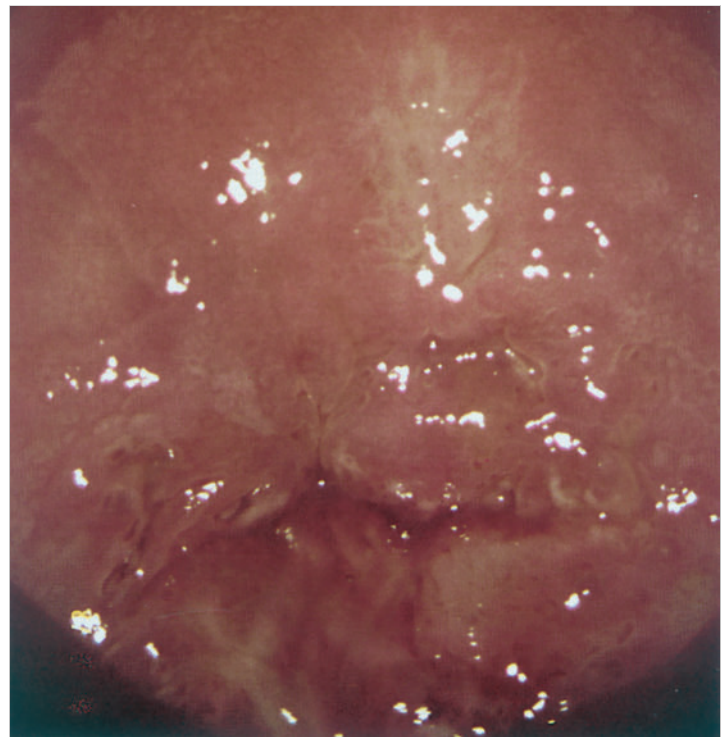

Fig. 9.16 Gravida 1, 20 weeks' gestation. Acetic acid has been applied. Outside the transformation zone, on the anterior lip of the external os, there is a fairly fine mosaic, sharply demarcated from its surroundings. Histology showed LSIL (CIN 1).

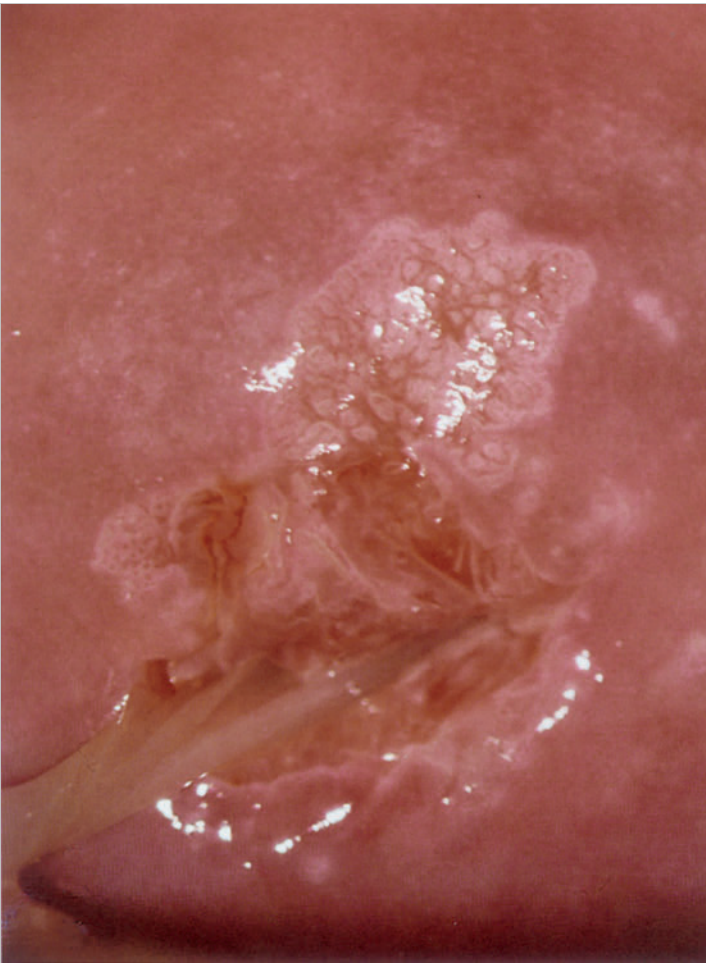

Fig. 9.17 Gravida 1, 16 weeks' gestation. After application of acetic acid, an irregular, coarse mosaic appears at the edge of the ectopy and outside the transformation zone. Histology showed HSIL (CIN 2).

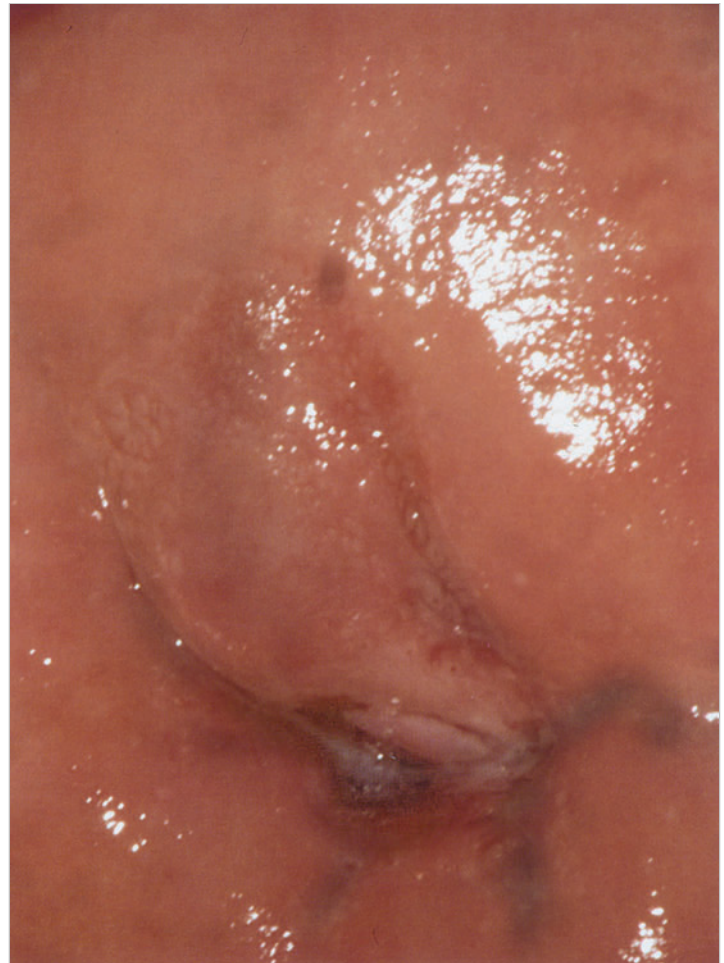


Fig. 9.18 Gravida 2, 10 weeks' gestation. After application of acetic acid, a deeply livid tongue-like area appears on the posterior lip. Within this area are only isolated gland openings; at its edge, there is a narrow band with coarse mosaic. Histology showed HSIL (CIN 2).

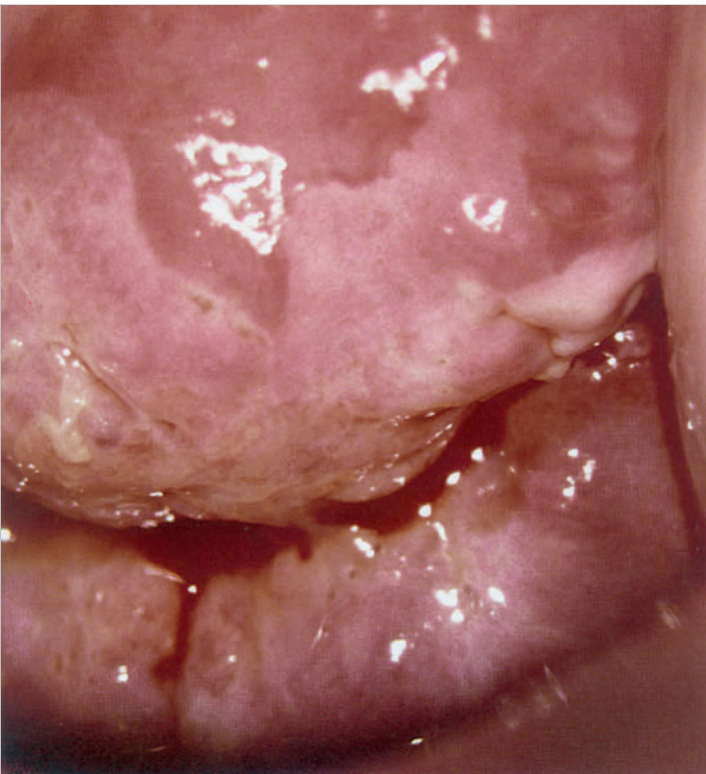

Fig. 9.19 Gravida 4, 40 weeks' gestation. The transformation zone with isolated gland openings is stained intensely white by acetic acid and is sharply demarcated. Ridge sign at 4 o'clock. Histology showed HSIL (CIN 3), which was followed closely over the pregnancy. The bleeding resulted from a smear taken with an Ayre's spatula.

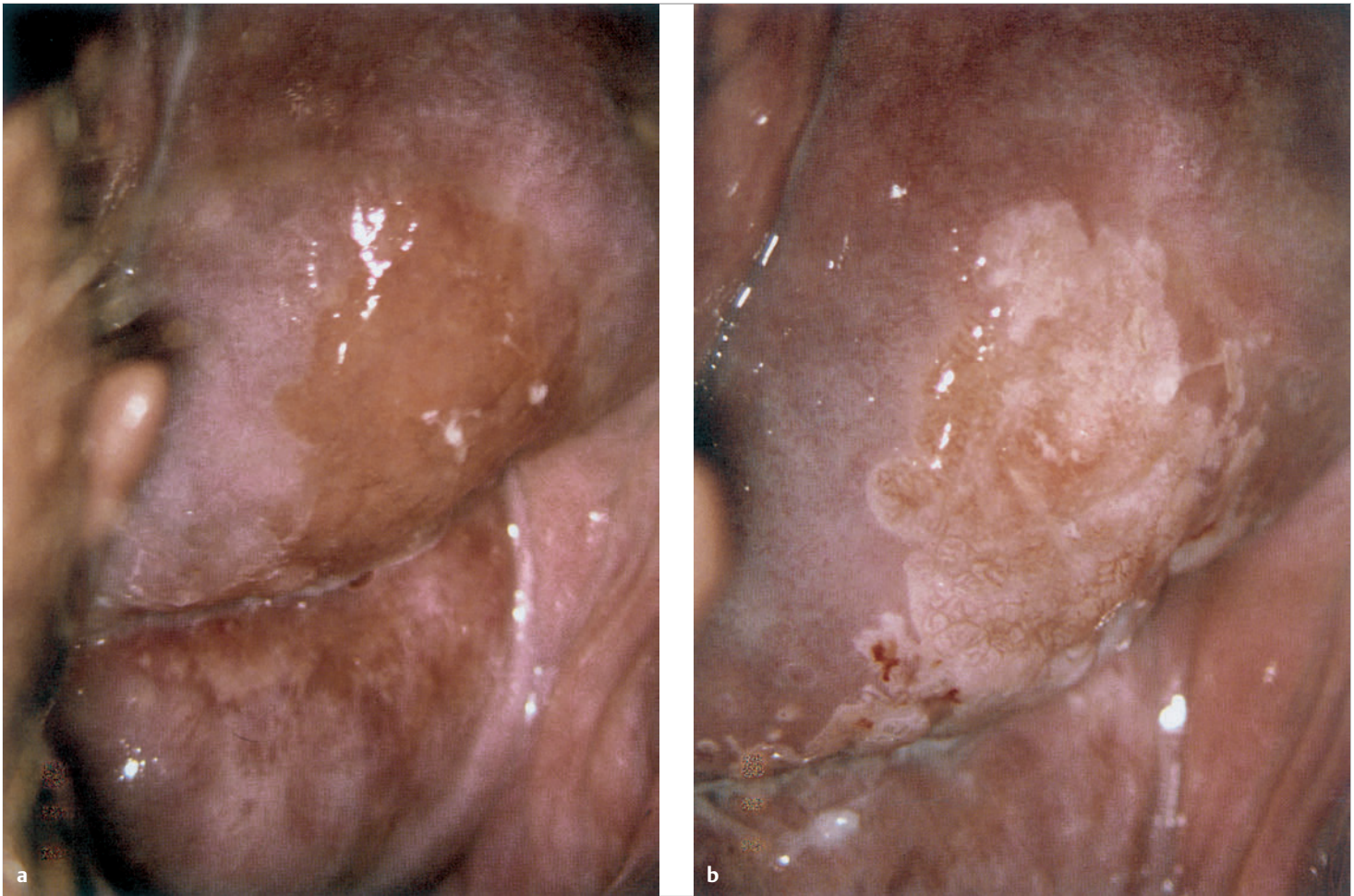


Fig. 9.20 (a) Gravida 7, 29 weeks' gestation. Within the livid and succulent epithelium, there is a sharply demarcated red area without any recognizable surface structure. (b) After application of acetic acid, the area swells, and a coarse mosaic appears. Histology showed HSIL (CIN 3).

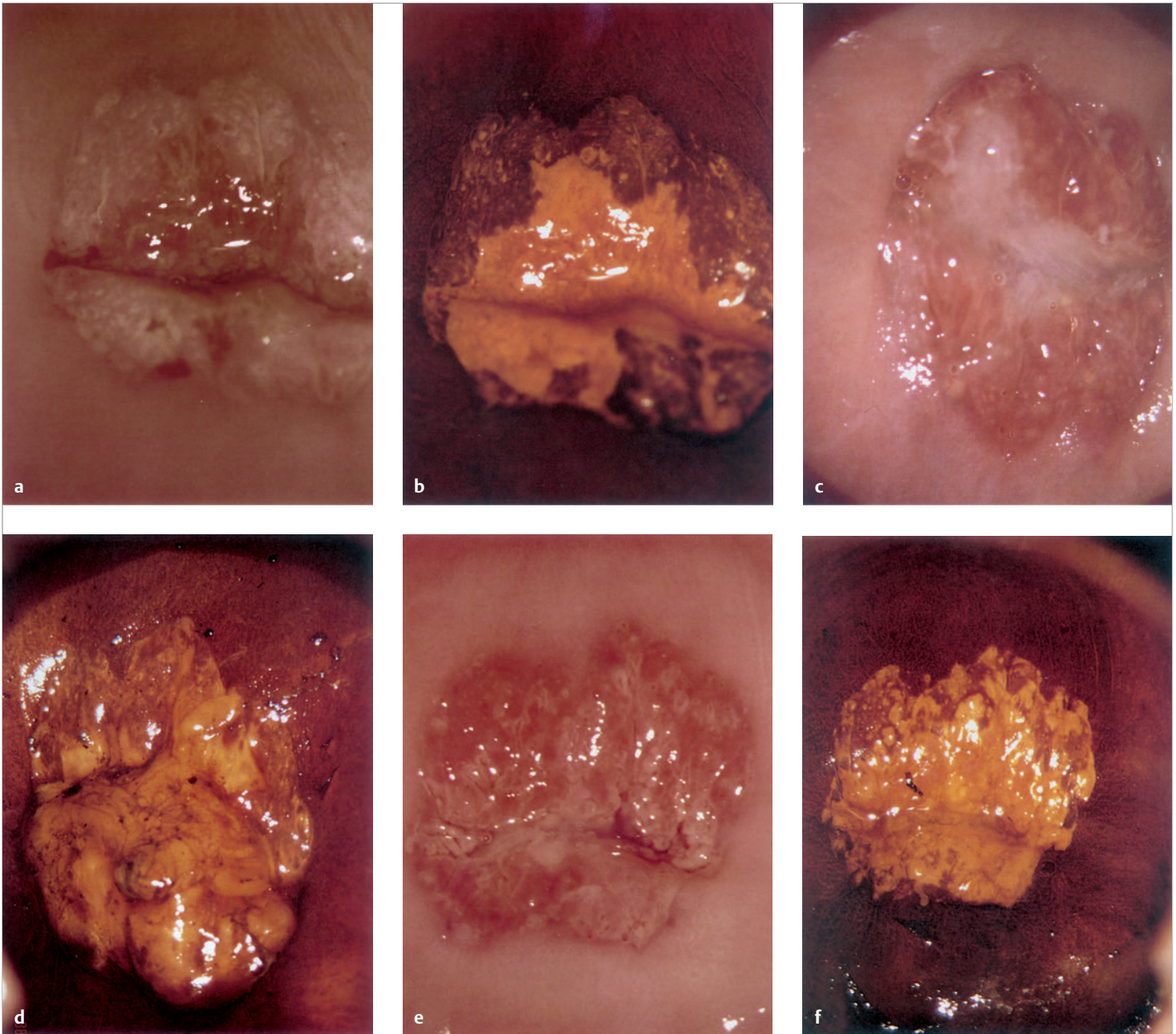


Fig. 9.21 (a) Gravida 2, 8 weeks' gestation. At the edge of an ectopy undergoing transformation, there is white-to-livid epithelium with cervical gland openings and white dots. The dots correspond to crypt involvement of squamous epithelium. Histology showed HSIL (CIN 2) with koilocytosis. (b) Brown staining after application of iodine confirms a flat condyloma (LSIL). The small, light spots could be called iodine-positive punctation. (c) By 24 weeks' gestation, the lesion has become coarser and succulent. (d) With the Schiller test, the staining of the epithelium on the anterior lip is unchanged. Mucus prevents staining of the posterior lip. (e) Six weeks after delivery, the transformation zone (TZ) appears normal and bright red. The lesion has become smaller. Histology showed metaplastic squamous epithelium. (f) Application of iodine produces only patchy staining at the edge of the TZ.

References

- [1] Stieve H. Der Halsteil der menschlichen Gebärmutter, seine Veränderungen während der Schwangerschaft, der Geburt und des Wochenbettes und ihre Bedeutung. [The cervical portion of the human uterus, its changes during pregnancy, delivery and the puerperium.] *Z Mikrosk Anat Forsch* 1927; 11: 291
- [2] Fluhmann CF. The cervix uteri and its disease. Philadelphia: Saunders, 1961.
- [3] Freeman - Wang T., Walker P. Colposcopy in Special Circumstances: Pregnancy, Immunocompromise, Adolescence and Menopause. *Best Pract Res Clin Obstet Gynecol* 2011; 25:653–665
- [4] Epperson JWW, Hellman LM, Galvin GA, Busby T. The morphological changes in the cervix during pregnancy, including intraepithelial carcinoma. *Am J Obstet Gynecol* 1951; 61: 50–61
- [5] Nesbitt REL, Hellman LM. The histopathology and cytology of the cervix in pregnancy. *Surg Gynecol Obstet* 1952; 94: 10–20
- [6] Greene RR, Peckham BM. Preinvasive cancer of the cervix and pregnancy. *Am J Obstet Gynecol* 1958; 75: 551–561, discussion 561–564
- [7] Hamperl H, Kaufmann C, Ober KG. Histologische Untersuchungen an der Cervix schwangerer Frauen; die Erosion und das Carcinoma in situ [Histological examination of the cervix of pregnant women; erosion and carcinoma in situ]. *Arch Gynakol* 1954; 184: 181–280
- [8] Fitzgerald PJ, Marsh M. Carcinoma in situ of the human uterine cervix in pregnancy; prevalence and postpregnancy persistence. *Cancer* 1956; 9: 1195–1207
- [9] Moore DB, Gusberg SB. Cancer precursors in pregnancy. *Obstet Gynecol* 1959; 13: 530–538
- [10] Ahdoot D, Van Nostrand KM, Nguyen NJ et al. The effect of route of delivery on regression of abnormal cervical cytologic findings in the postpartum period. *Am J Obstet Gynecol* 1998; 178: 1116–1120
- [11] Morice P, Uzan C, Gouy S, Verschraegen C, Haie-Meder C. Gynaecological cancers in pregnancy. *Lancet* 2012; 379: 558–569

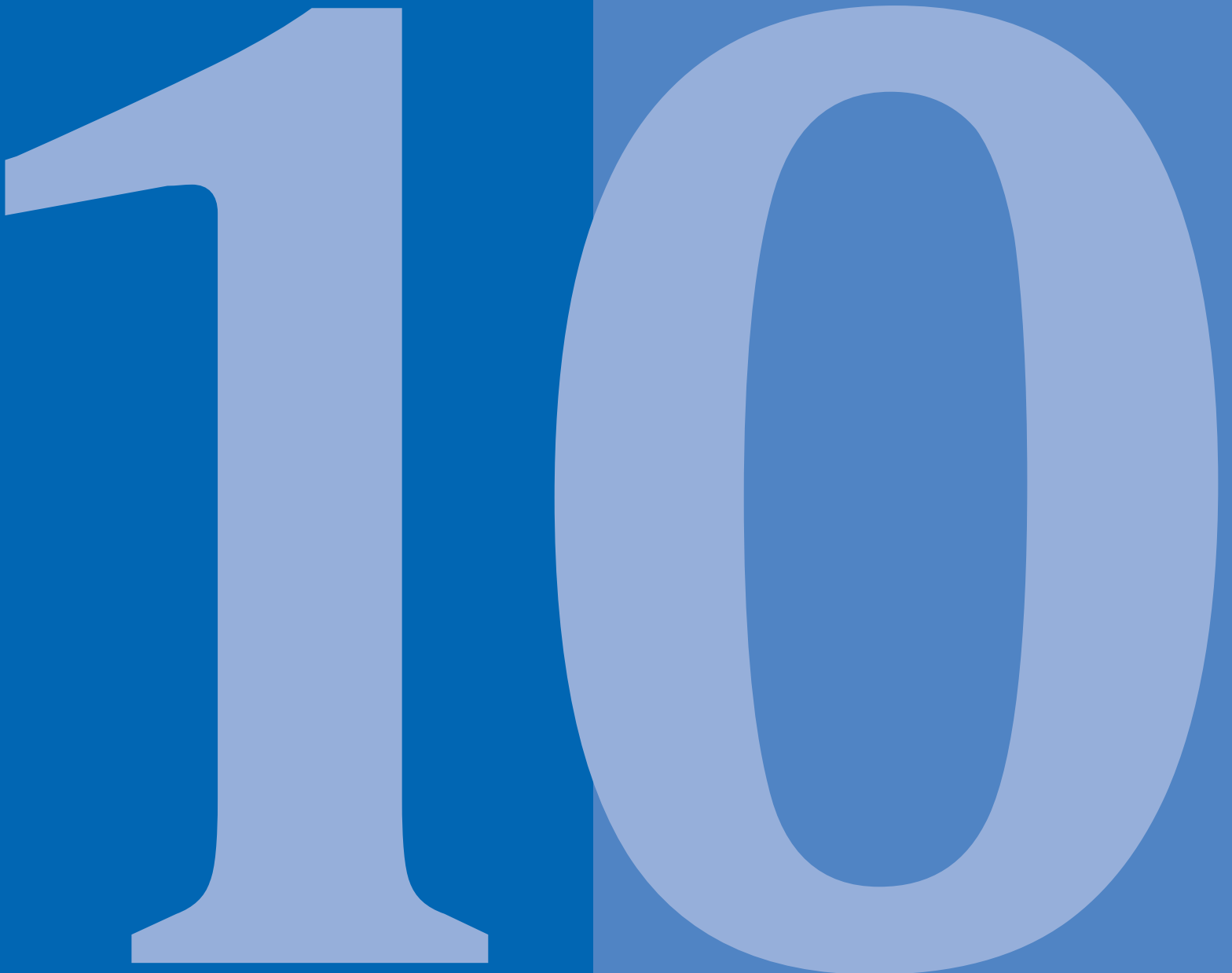Further Reading

- Fader AN, Alward EK, Niederhauser A et al. Cervical dysplasia in pregnancy: a multi-institutional evaluation. *Am J Obstet Gynecol* 2010; 203: e1–e6
- Fleury AC, Birsner ML, Fader AN. Management of the abnormal Papanicolaou smear and colposcopy in pregnancy: an evidenced-based review. *Minerva Ginecol* 2012; 64: 137–148
- Hunter MI, Monk BJ, Tewari KS. Cervical neoplasia in pregnancy. Part 1: screening and management of preinvasive disease. *Am J Obstet Gynecol* 2008; 199: 3–9
- Stonehocker J. Cervical cancer screening in pregnancy. *Obstet Gynecol Clin North Am* 2013; 40: 269–282
- Morice P, Uzan C, Gouy S, Verschraegen C, Haie-Meder C. Gynaecological cancers in pregnancy. *Lancet* 2012; 379: 558–569
- Trutnovsky G, Kolovetsiou-Kreiner V, Reich O. P16/Ki-67 dual stained cytology testing may predict postpartum outcome in patients with abnormal Papanicolaou cytology during pregnancy. *Acta Cytol* 2014
- Wetta LA, Matthews KS, Kemper ML et al. The management of cervical intraepithelial neoplasia during pregnancy: is colposcopy necessary? *J Low Genit Tract Dis* 2009; 13: 182–185

Chapter 10
**Colposcopic–Histologic
Correlation**

**10.1 The Topography of Abnormal
Colposcopic Findings**

159



10 Colposcopic–Histologic Correlation

Colposcopy is an attempt to predict underlying histology from colposcopic findings. Each colposcopic finding should have an exact histologic counterpart, but such correlations can never be achieved fully and should not be attempted during routine colposcopy. In daily practice, the goal is to distinguish between normal, abnormal, and suspicious findings.

Precise correlations between colposcopic and histologic findings require guided biopsies,¹ but analyzing complex colposcopic findings with numerous biopsies is neither feasible nor fair to the

patient. Colposcopic–histologic correlations require good colposcopic photographs and meticulous histology of conization specimens with serial sections (► Fig. 10.1). We have carried out numerous such studies. Many of the legends to the colposcopic photographs in this book highlight details revealed by comparing colposcopic and histologic findings in conization specimens. To illustrate the kind of information that can be obtained by this kind of analysis, this chapter shows cases with multiple abnormal findings. A few of the figures also show changes outside the transformation zone

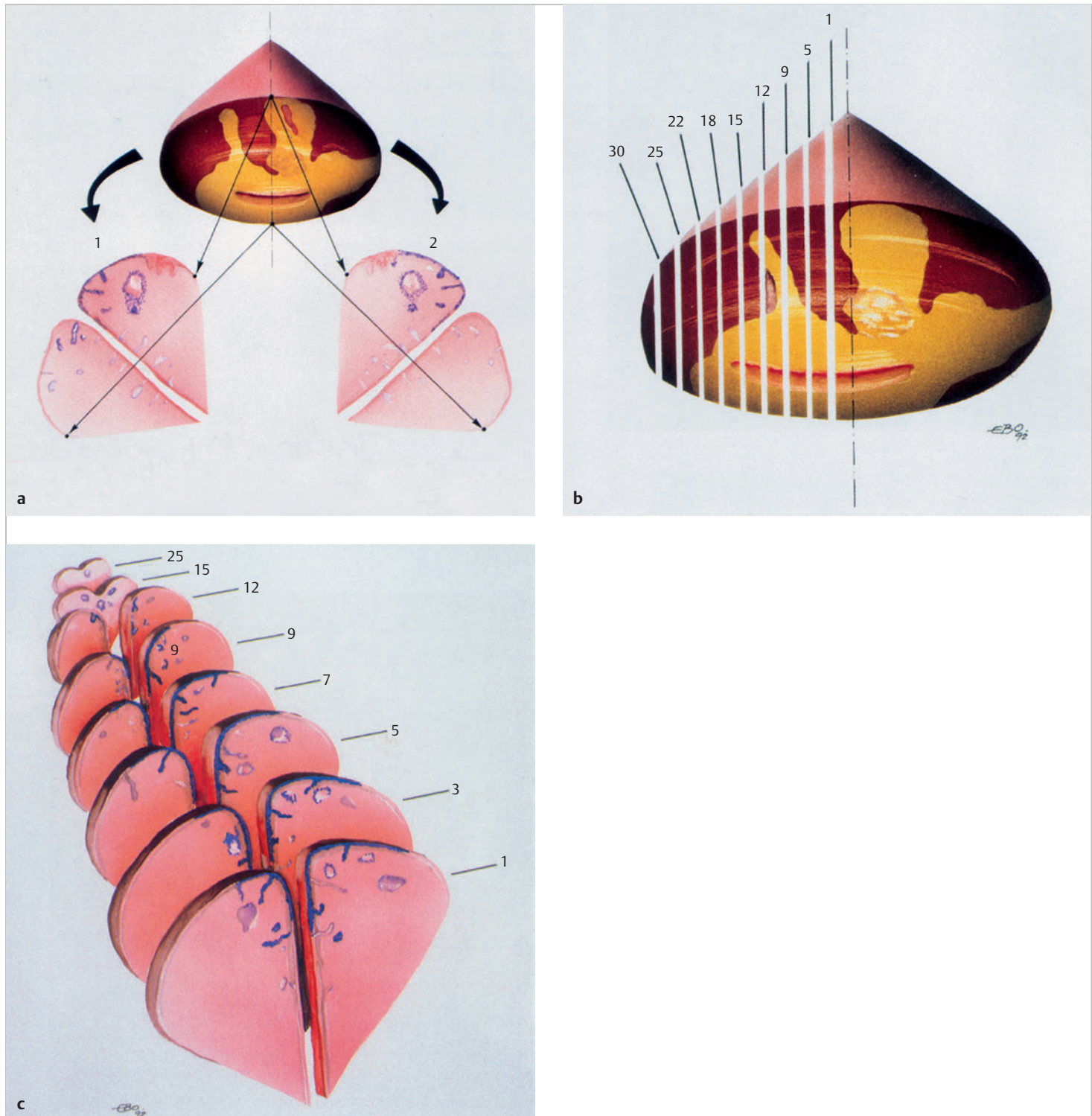


Fig. 10.1 Schematic representation of the histologic processing of a conization specimen. The cone is divided in half in the sagittal plane (a) and processed as step serial sections at 400- μ m intervals (b, 1–30). The gland field is reconstructed by connecting the positions of the last glands (c, 1–25). The epithelial lesions and the borders between them are then related to the colposcopic findings.

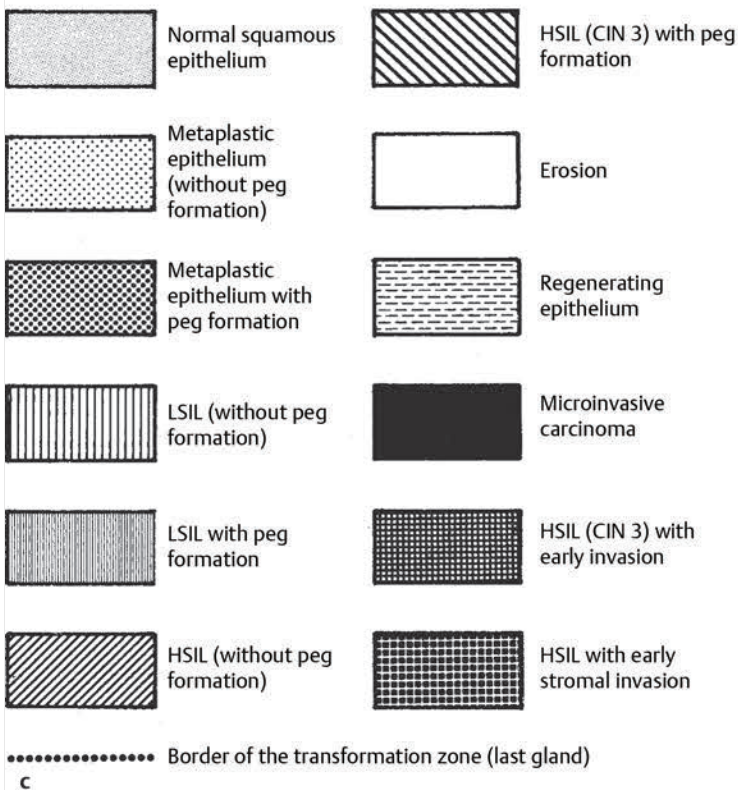
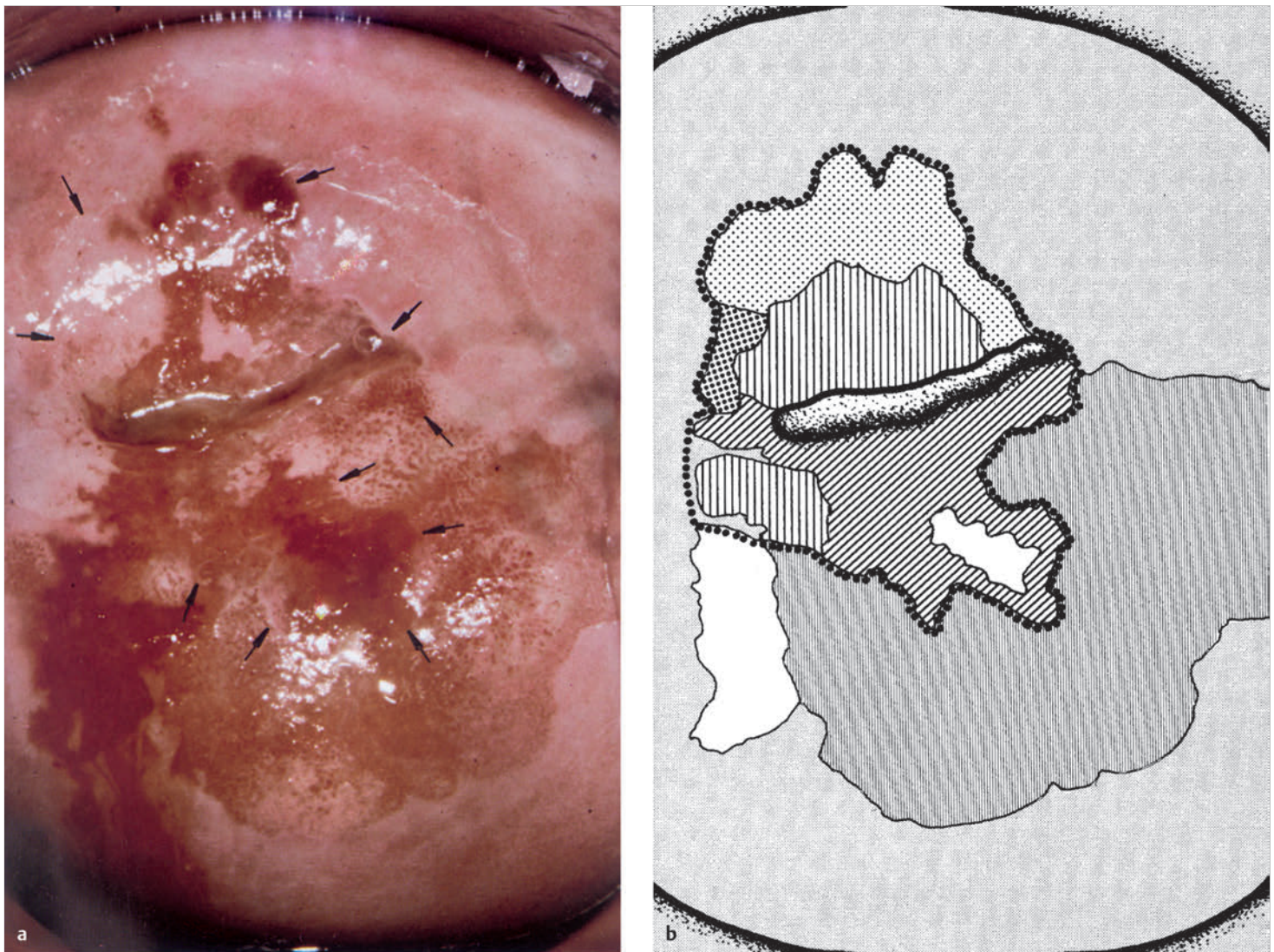


Fig. 10.2 Correlation of the colposcopic picture with the histologic findings in step serial sections of the corresponding conization specimen. The arrows point to borders between colposcopic lesions.

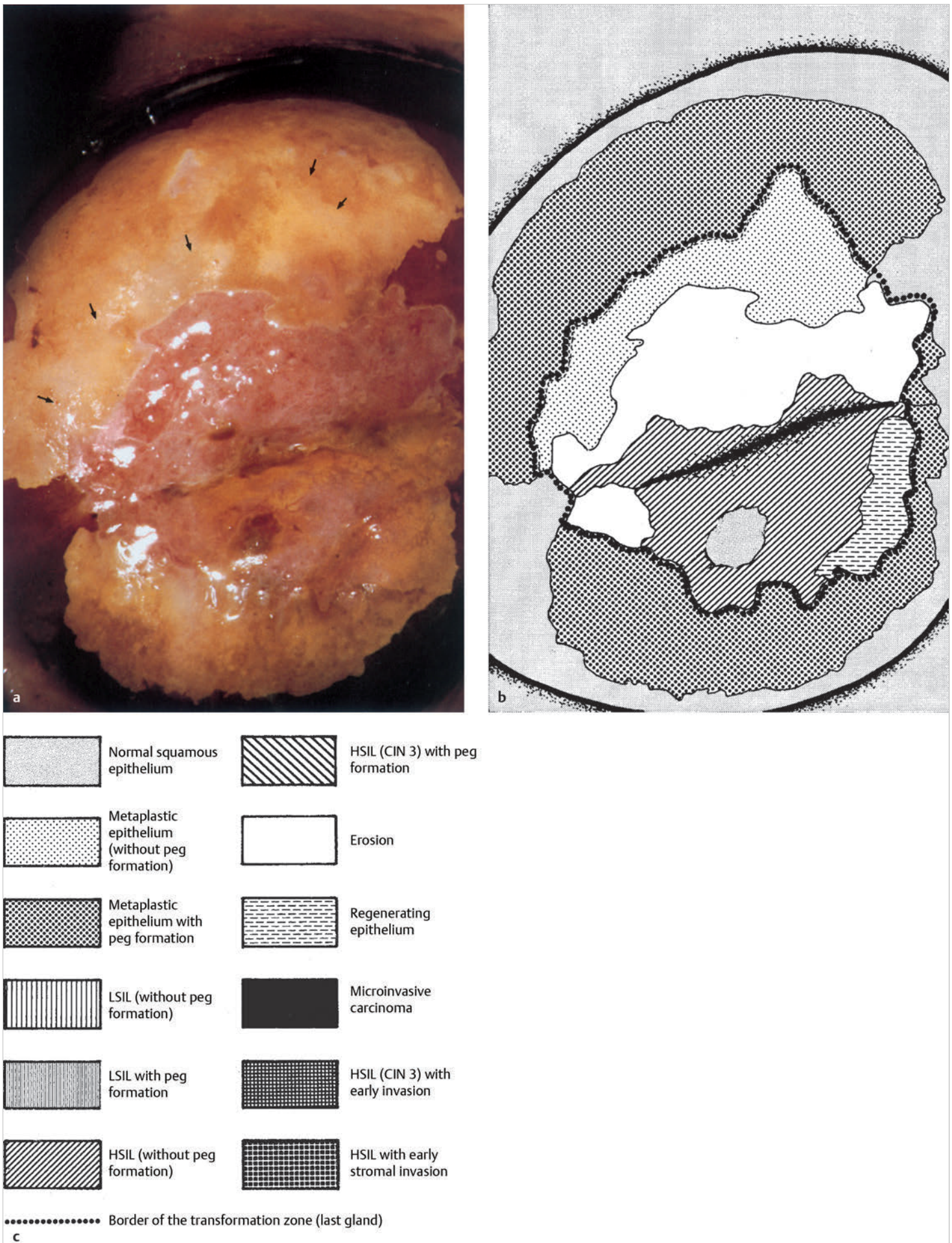


Fig. 10.3 Correlation of the colposcopic picture following application of iodine (Schiller test) with the histologic findings in step serial sections of the corresponding conization specimen. The arrows point to discrete borders between colposcopic lesions.

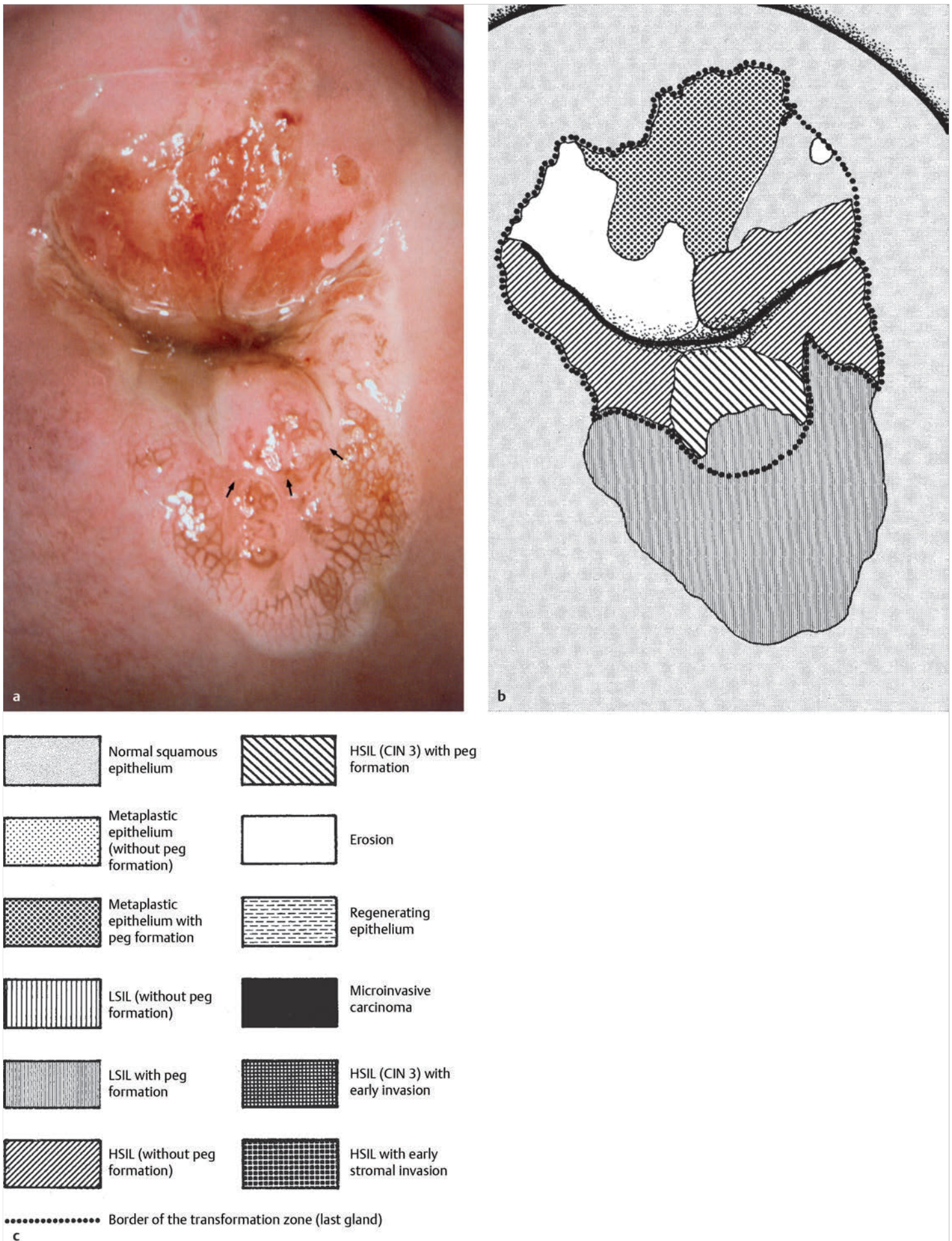


Fig. 10.4 Correlation of the colposcopic picture with the histologic findings in step serial sections of the corresponding conization specimen. The arrows point to discrete borders between colposcopic lesions. There is dysplasia on both sides of the last gland.

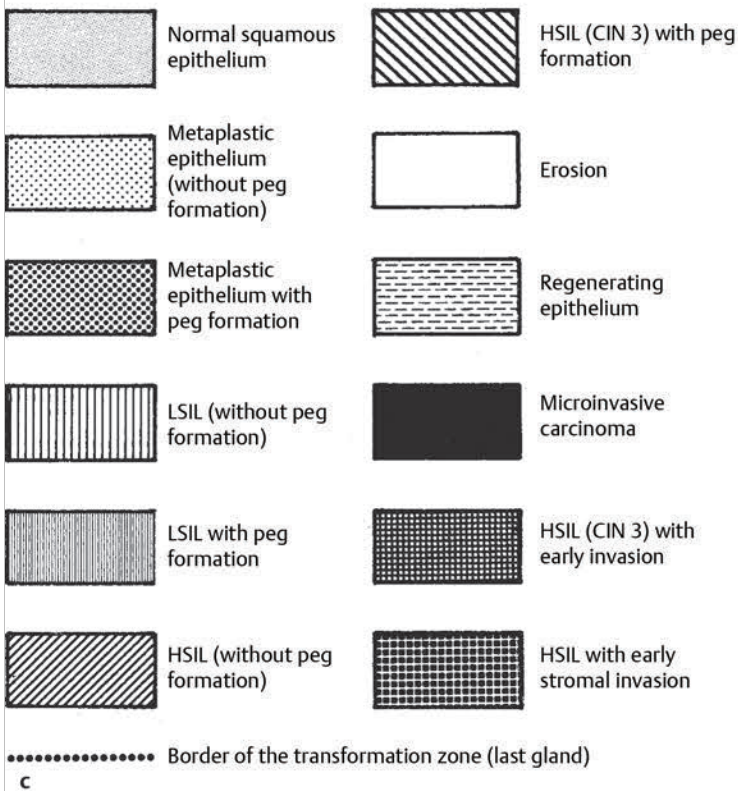
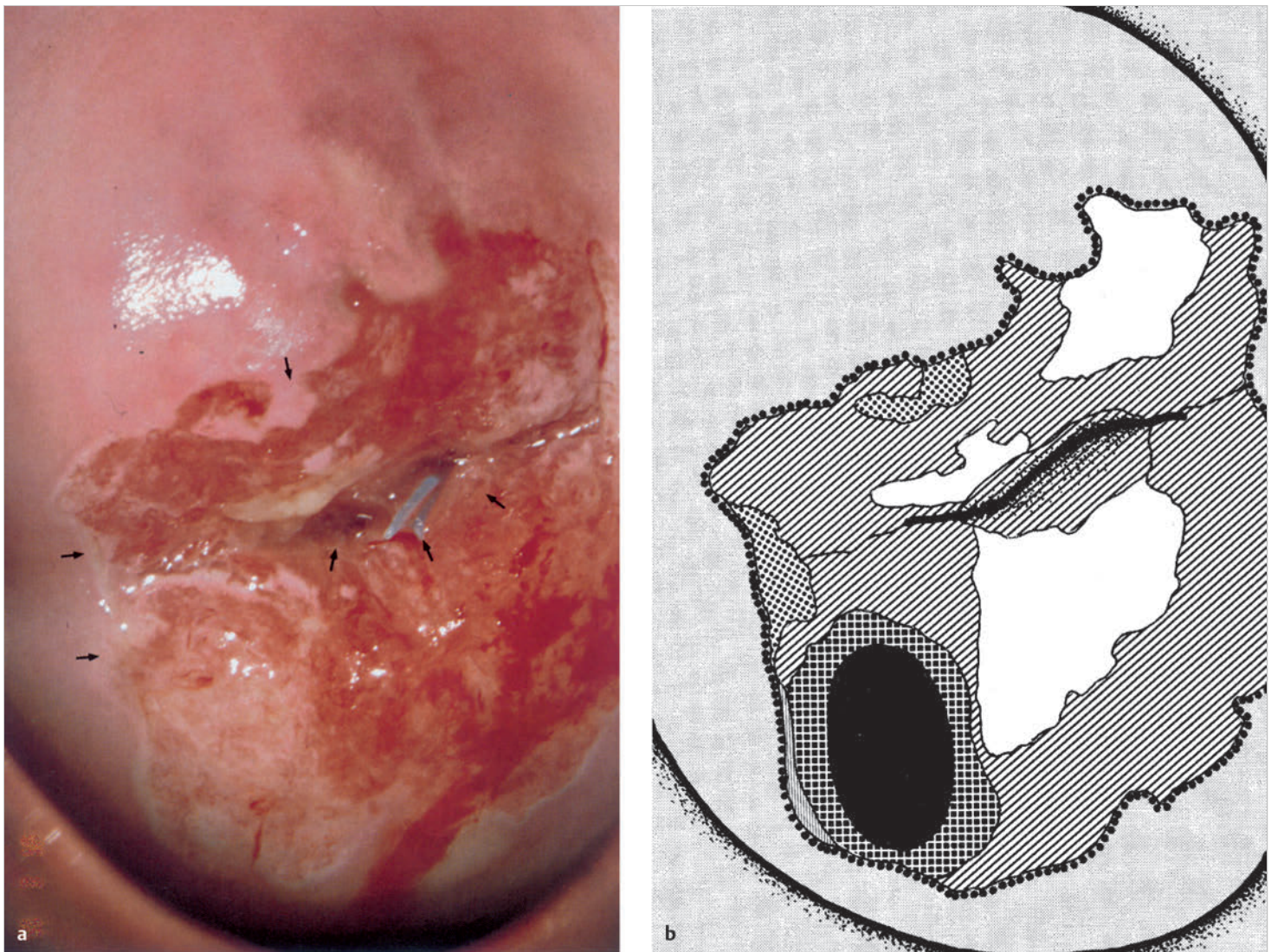


Fig. 10.5 Correlation of the colposcopic picture with the histologic findings in step serial sections of the corresponding conization specimen. The arrows point to discrete borders between colposcopic lesions.

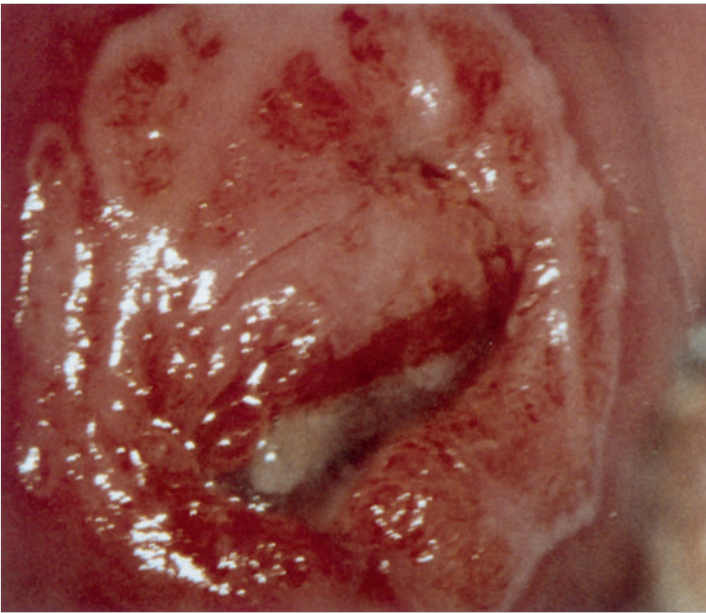

Fig. 10.6 Acetowhite epithelium. Histology showed HSIL (CIN 3).

(TZ), i.e., outside the gland field. The heavily dotted lines in the figures mark the borders of the gland field (i.e., the position of the last gland) (see Chapter 4, section 4.1.3.1).

Borders within colposcopic lesions are not always easy to recognize, particularly in photographs. Nevertheless, borders become surprisingly distinct with careful scrutiny and using sketches made from colpophotographs.

First, it becomes obvious that all uniform epithelia arise in clearly circumscribed fields. Secondly, more-differentiated lesions are found distal (toward the vagina) to less-differentiated lesions. Thus, high-grade squamous intraepithelial lesion (HSIL; cervical intraepithelial neoplasia [CIN] 2/3) lies above (i.e., further toward the cervical canal) than low-grade squamous intraepithelial lesion (LSIL, or CIN 1). Metaplastic squamous epithelium is located most distally (► Fig. 10.2, ► Fig. 10.3, ► Fig. 10.4). All kinds of epithelia are found proximal to the last gland, but they follow these rules (► Fig. 10.2, ► Fig. 10.3, ► Fig. 10.4, ► Fig. 10.5). LSIL (CIN 1) is found on either side of the last gland, and often begins or ends here. Thus, colposcopy illustrates the importance of the histologic concept of the last gland.

To complete the picture, ► Fig. 10.4 shows the rare exception. There is a large area of HSIL (CIN 2) on both sides of the last gland on the posterior lip of the cervical os. The lesion is uniform and

continuous. If the corresponding colpophotograph is studied carefully, the somewhat coarse mosaic is seen to consist of two clearly distinct fields. In this case the two epithelia, which can hardly be distinguished from one another histologically, have arisen quite independently on either side of the last gland. The border of the gland field at 2 o'clock is covered by normal squamous epithelium that must have arisen in the glandular field by metaplasia.

► Fig. 10.5 is instructive because it clearly shows a focus of invasive squamous cell carcinoma without striking diagnostic features.

Cervical cancer has often been thought to arise only in the TZ, but there is now convincing histologic evidence that SIL (CIN) can arise outside the TZ, in the original squamous epithelium. Even uniform lesions can occur simultaneously both inside and outside the gland field. Although the combination of different colposcopic findings is well known, it is little appreciated that their sharp borders can be seen colposcopically. Naturally, there are lesions that arise completely outside the TZ, some exclusively from original squamous epithelium (► Fig. 8.38, ► Fig. 8.39, ► Fig. 8.43, ► Fig. 8.84). Ectopic cervical mucosa will usually be replaced by squamous epithelium via metaplasia, but the glands beneath the new squamous epithelium remain, as is the case in so-called vaginal adenosis.² For the same reason, the argument that the last gland is not really the last because other glands have disappeared is not valid. If this were so, the position of the last gland would be at random. The unique topographic relationship of the last gland to epithelial abnormalities, both histologically (See section 4.4.2, ► Fig. 4.26), and colposcopically (► Fig. 10.2, ► Fig. 10.5) is strong proof of the validity of the concept of the last gland.³

10.1 The Topography of Abnormal Colposcopic Findings

In 1990 the colposcopic terminology of the International Federation for Cervical Pathology and Colposcopy (IFCPC) took into account that abnormal colposcopic findings can be located inside or outside the TZ, or both (see Chapter 7, ► Table 7.1).⁴ The current (2011) terminology has kept this topographic distinction for abnormal colposcopic findings.⁵

We have studied the location of abnormal colposcopic findings and the underlying histology in a series of 118 conization

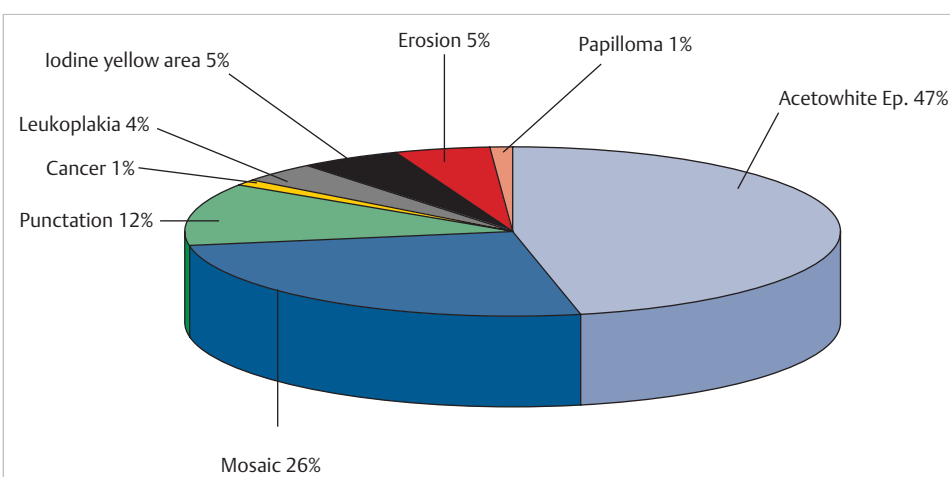


Fig. 10.7 Distribution of abnormal colposcopy findings in 118 conization specimens.

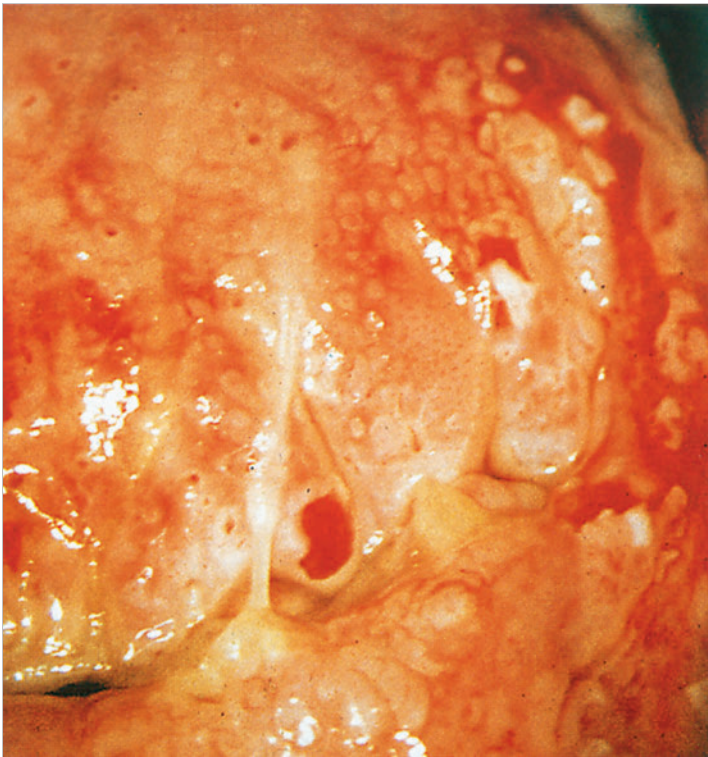


Fig. 10.8 Mosaic, punctation, and acetowhite epithelium within the transformation zone; histology showed HSIL (CIN 3).

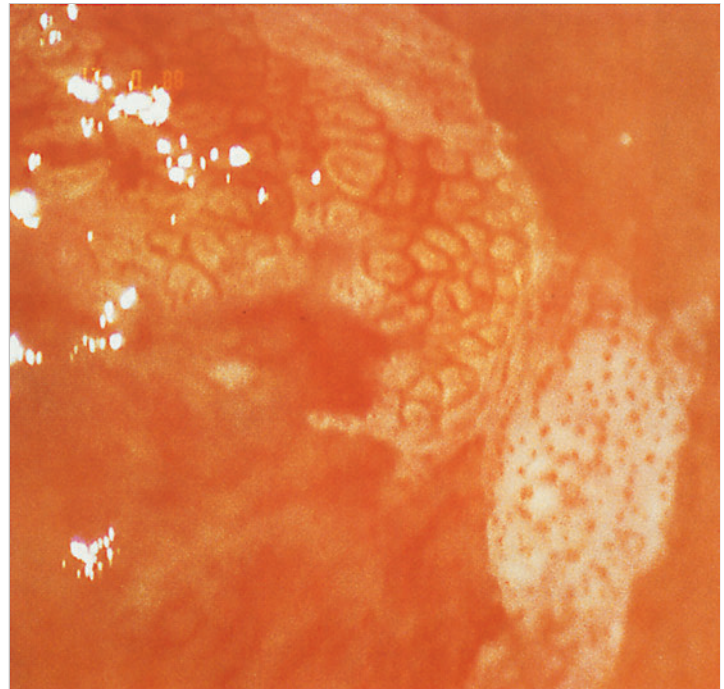


Fig. 10.9 Mosaic and punctation entirely outside the transformation zone; histology showed HSIL (CIN 2).

specimens of patients with cervical dysplasia.⁶ In this series, 47% of cases showed acetowhite epithelium (► Fig. 10.6), 38% mosaic and punctation, 4% leukoplakia, and 11% other findings (► Fig. 10.7). In 85 patients the colposcopic lesions were located both within and outside the TZ, in 31 the lesions were located entirely within the TZ, and in only two the lesions were entirely outside the TZ. The distribution of colposcopic and histologic

correlates is shown in ► Fig. 10.8, ► Fig. 10.9, ► Fig. 10.10, ► Fig. 10.11, ► Fig. 10.12, and ► Fig. 10.13. The analyses showed that abnormal colposcopic findings within the TZ are more likely to correspond to SIL than lesions outside the TZ. Similar findings have been reported by Hammes et al. (2007).⁷

Thus, mosaics and punctations within the TZ (► Fig. 10.12) differ from those outside the TZ (► Fig. 10.13) in their morphogenesis and in their risk of malignancy.

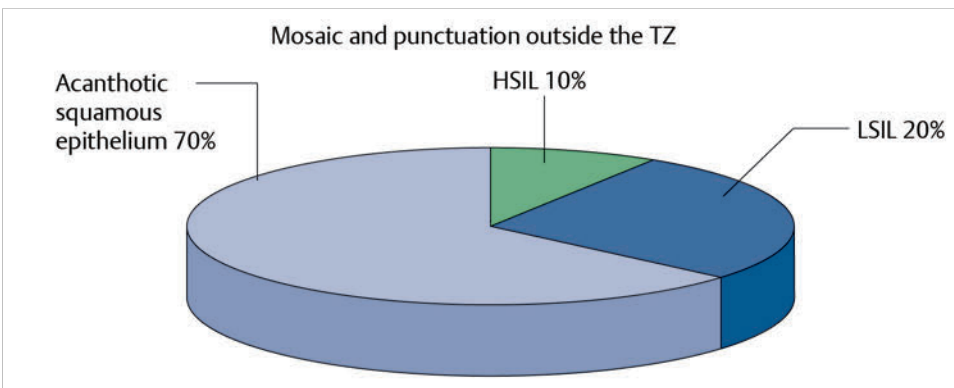


Fig. 10.10 Histologic correlates of mosaics and punctations outside the transformation zone (98 lesions in 87 cases).

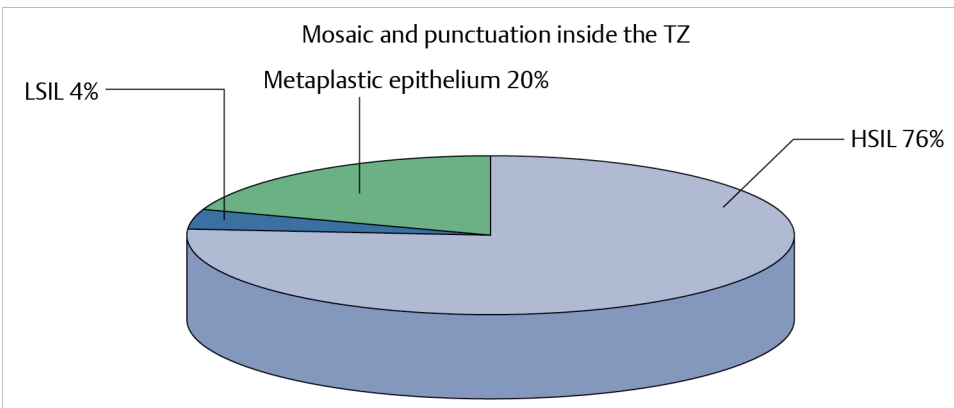


Fig. 10.11 Histologic correlates of mosaics and punctations inside the transformation zone (25 lesions in 116 cases).

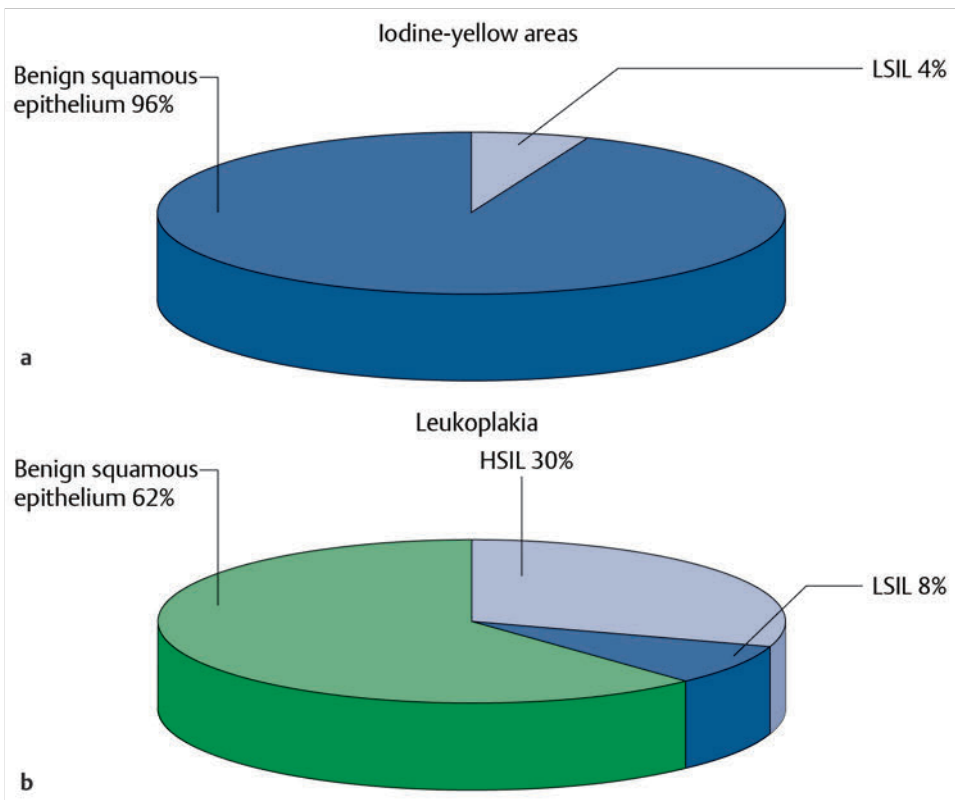


Fig. 10.12 Histologic correlates of iodine-yellow areas and leukoplakias in 87 cases.

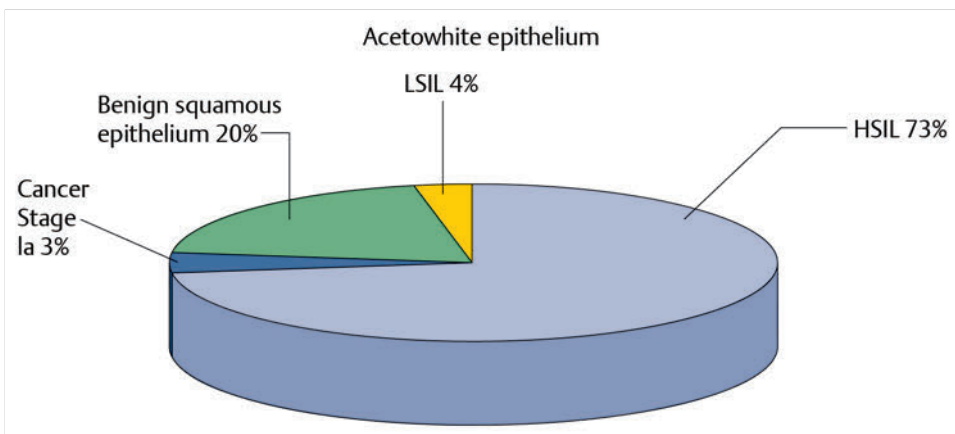


Fig. 10.13 Histologic correlates of acetowhite epithelium (152 lesions in 118 cases).



References

- [1] Bajardi F. Kolposkopische Befunde und ihre histologischen Korrelate [Colposcopic findings and their histologic correlates] *Geburtshilfe Frauenheilkd* 1984; 44: 84–86
- [2] Burghardt E, Ostör AG. Site and origin of squamous cervical cancer: a histomorphologic study. *Obstet Gynecol* 1983; 62: 117–127
- [3] Burghardt E. The importance of the last cervical gland in the natural history of cervical neoplasia. *Obstet Gynecol Surv* 1979; 34: 862–866
- [4] Stafil A, Wilbanks GD. An international terminology of colposcopy. Report of the Nomenclature Committee of the International Federation of Cervical Pathology and Colposcopy. *Obstet Gynecol* 1991; 77: 313–314
- [5] Bornstein J, Bentley J, Bösze P et al. 2011 colposcopic terminology of the International Federation for Cervical Pathology and Colposcopy. *Obstet Gynecol* 2012; 120: 166–172
- [6] Girardi F. The topography of abnormal colposcopy findings. *Cervix Low Female Genital Tract* 1993; 11: 45–52
- [7] Hammes LS, Naud P, Passos EP et al. Value of the International Federation for Cervical Pathology and Colposcopy (IFCPC) Terminology in predicting cervical disease. *J Low Genit Tract Dis* 2007; 11: 158–165

Chapter 11

Therapeutic Implications of Abnormal Colposcopic Findings

11.1 Management of Benign Colposcopic Findings	164
11.2 Treatment of Premalignant Cervical Lesions	164
11.3 Treatment of Microinvasive Carcinoma	167
11.4 Follow-up after Treatment	168



11 Therapeutic Implications of Abnormal Colposcopic Findings

Abnormal or suspicious colposcopic findings should be evaluated by biopsy under direct colposcopic guidance (see Chapter 5). It is important that treatment is based on a histologic diagnosis, not on a colposcopic finding or a cytologic result. Cytology shows only whether epithelial atypia is present, and cytology imprecisely predicts histology. HPV testing is a useful adjunct.

11.1 Management of Benign Colposcopic Findings

11.1.1 Ectopy

A large ectopy can produce symptoms, such as mucous discharge and postcoital contact bleeding. Symptomatic ectopy can be treated, particularly in women who have completed their families. In young women in whom ectopy is unusually large due to oral contraceptives, an alternate form of contraception can be considered. Ectopy can be ablated or removed with shallow excision, diathermy, cryosurgery, or laser treatment. With any method, the end result should be re-epithelialization with normal glycogen-containing squamous epithelium. In favorable cases, the squamocolumnar junction (SCJ) will lie at the external os. Before treatment, care must be taken to rule out squamous intraepithelial lesions (SIL) or invasive disease by using cytology, histology, or both.

11.1.2 Normal Transformation Zone

The transformation zone (TZ) per se is a normal finding and does not require treatment.

11.1.3 Metaplastic Epithelium with Leukoplakia, Punctation, or Mosaic

Leukoplakia, punctation, and mosaic should be evaluated with human papillomavirus (HPV) testing and cytology and occasional biopsy. If the findings are normal, the patient and the physician can be reassured. These patients do not need treatment or more intensive follow-up. Colposcopic findings resulting from metaplastic epithelium tend to be stable, as long-term follow-up studies show little change in the contours or cytologic makeup (see Chapter 8).

11.1.4 Condylomatous Lesions

A number of medical and ablative options are available to treat condylomas. We prefer laser ablation.^{1,2} With a laser, lesions of the cervix, vagina, and vulva can be vaporized under direct colposcopic guidance. Papillary and spiked condylomas can be surgically ablated. Papillary lesions, and extensive flat ones, can be removed with a diathermy loop with the current set low enough that the underlying tissue is not damaged. Flat condylomas near papillary lesions can also be removed with a diathermy loop or cauterized after biopsy. Diathermy of the base of the lesion is

important to help prevent recurrences due to residual infected tissue.

Cryosurgery can also be used. Spiked condylomas adjacent to lesions treated with cryosurgery have been observed to regress spontaneously, presumably due to an immune response induced by the freezing.³

In patients with flat condylomas, invasive carcinoma should be ruled out with biopsy. All the methods described herein can be considered. If the surface of the lesion is particularly coarse, then it can have an endophytic component, and the depth of treatment should be increased to help prevent recurrence. If the biopsy shows atypia, the lesion should be treated as intraepithelial neoplasia (discussed in section 11.2).

Medical options for the treatment of condylomas include imiquimod and podophyllotoxin. Because of the risk of recurrence, these substances are also used for the adjuvant treatment after surgical ablation. Interferon- α hydrogel⁴ or 5-fluorouracil are seldom used.^{5,6}

11.2 Treatment of Premalignant Cervical Lesions

Low-grade squamous intraepithelial lesion (LSIL, CIN 1) can and should be managed with short-term follow-up because such lesions can regress, especially if poorly demarcated colposcopically. A well-defined lesion persisting for about 1 to 2 years should be treated as a high-grade lesion. The aim of treatment is to remove or destroy the atypical epithelium in its entirety. Definitive treatment should be based on a precise definition of the lesion.

The following are diagnostic considerations in SIL (CIN):

- Histologic appearance
- Extent of superficial spread, including extension into the endocervical canal
- Depth of involvement of cervical glands (crypts)
- Exclusion of invasion

Recent studies have addressed medical treatment for CIN (SIL).⁷

11.2.1 Diagnostic Prerequisites

None of the first-line diagnostic methods (cytology, colposcopy, even guided biopsy) can be relied on absolutely for an accurate diagnosis of SIL (► Table 11.1; see also Chapter 10). Colposcopy can evaluate only the extent of the lesion on the surface, and only when the lesions are limited to the ectocervix. The endocervical speculum (► Fig. 5.8) can visualize the lower portion of the canal, but lesions higher in the canal are out of reach of the colposcope. The colposcopic criteria for evaluating epithelia (see Chapter 8) are not sufficiently accurate for decisions regarding treatment. Also, microinvasive carcinomas can be diagnosed colposcopically only when they have reached a certain size and are located on the ectocervix and not too far under the surface.

Table 11.1 Morphologic methods for evaluating cervical intraepithelial neoplasia

	Cytology	Colposcopy	Guided biopsy	Endocervical curettage	Conization
Histology	+	-	++	++	+++
Surface extent	-	+	+	+	+++
Glandular involvement	-	+	+	+	+++
Exclusion of invasion	-	-	+	+	+++

The diagnostic accuracy of colposcopically guided biopsies depends entirely on the sites from which they are taken, which in turn is determined by the colposcopic impression. Biopsy cannot always detect glandular involvement or invasion. Endocervical curettage shows only extension of SIL (CIN) into the cervical canal. It is not always possible to establish or rule out invasion or to determine the extent of glandular involvement and the depth of the crypts in the fragmented specimens obtained using biopsy techniques.

A definitive diagnosis of high-grade squamous intraepithelial lesion (HSIL) requires complete excision of the abnormal area by conization (diathermy loop or cold knife) and rigorous histologic examination. Some guidelines consider adolescents and young women a special population to be considered for conservative management of HSIL.⁸

11.2.2 Ablative Treatment of Squamous Intraepithelial Neoplasia (SIL)

Ablative modalities performed in the office are attractive for patients, physicians, and payers, but they have to be used with an appreciation of their limitations and an understanding of cervical pathology. Colposcopy was widely used in the ablative treatment of SIL (CIN) in the hope that the lesions could be accurately destroyed with electrocoagulation diathermy, cryosurgery, or laser ablation.^{9,10,11,12,13} The idea was to reduce the number of cold-knife conizations, many of which had been performed without proper indications. Certainly, total destruction of the abnormal epithelium should achieve cure. If this result could be guaranteed, any ablative modality could be used; but the crux of the matter is that it is not possible to be sure that all abnormal epithelium has truly been destroyed.

Only lesions that are predominantly ectocervical and for which the entire SCJ is visible are suitable for superficial ablative treatment.^{14,15,16,17} Lesions reaching farther up into the cervical canal cannot be reached with certainty. There is also a risk that dysplastic epithelium can persist in deep glands. In a study of 3,343 conization specimens, glands holding intraepithelial neoplasia reached a maximum of 5.2 mm under the surface whereas normal glands reached a maximum depth of 7.8 mm.¹⁸ However, we have found glands at a depth of 10 mm and in unexpected places (► Fig. 11.1), out of the range of superficial ablative methods. Finally, microinvasive carcinomas can arise from the base of crypts, with no connection to any atypical epithelium on the surface.¹⁹ Such invasive tumors can extend deeper than 5 mm into the stroma and can also arise in unexpected places (► Fig. 11.2).

The likelihood of deep extension and invasion is related to the extension of the lesion on the surface. In general, only large lesions are invasive. Deep extension in glands is less likely with low-grade lesions than with HSIL because HSIL develops more often from squamous metaplasia within the gland field and its

crypts. Glandular involvement is impossible in regions of the original squamous epithelium.

Ablative modalities should be used only if the following criteria are met:

- The lesion is limited to LSIL
- The lesion is small
- The surface of the lesion is smooth
- The lesion is located purely on the ectocervix
- The entire SCJ is visible

We have calculated the proportion of cases of SIL that fulfill the preceding criteria in a series of 119 conization specimens (► Table 11.2). Even including HSIL, only six cases (5%) met all the criteria. If we add a further 44 cases (37%) in which SIL extended into the lower portion of the canal and the SCJ may have been visible, the rate is 42%. Other authors have postulated even more restrictive criteria for ablative modalities.^{14,15}

It is a misconception that regular follow-up after conservative treatment of SIL will detect any persistent or recurrent abnormality eventually. Of concern is persistence of SIL in glands or a deep microinvasive carcinoma with no connection to the surface of the

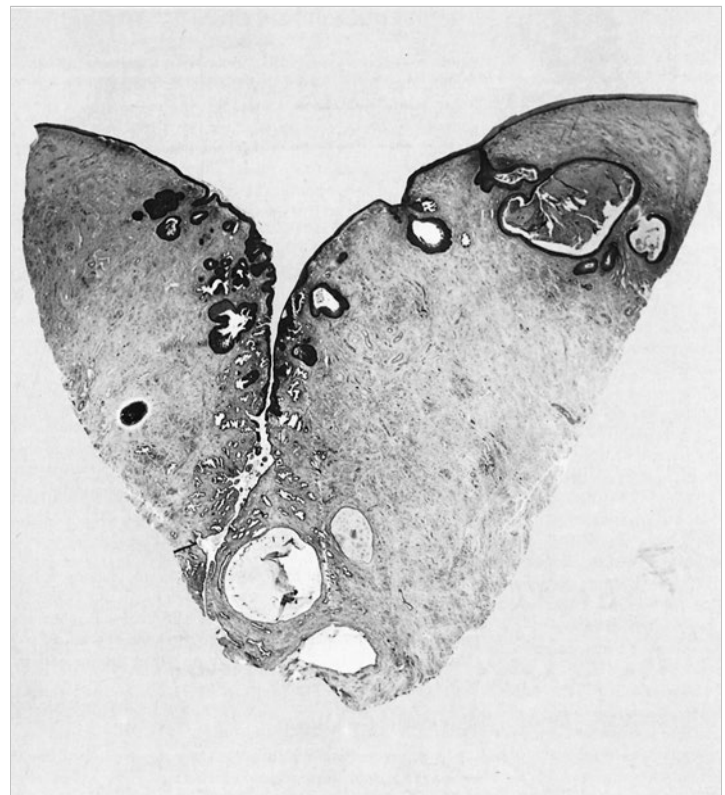


Fig. 11.1 Conization specimen. The surface of both lips of the cervix is covered by HSIL (CIN 3). Note the abrupt change at the junction with normal squamous epithelium. The HSIL involves glands and extends into the lower portion of the canal. On the right there is extensive involvement of glands, which extend 10 mm under the surface. Such a lesion cannot be detected or suspected colposcopically.

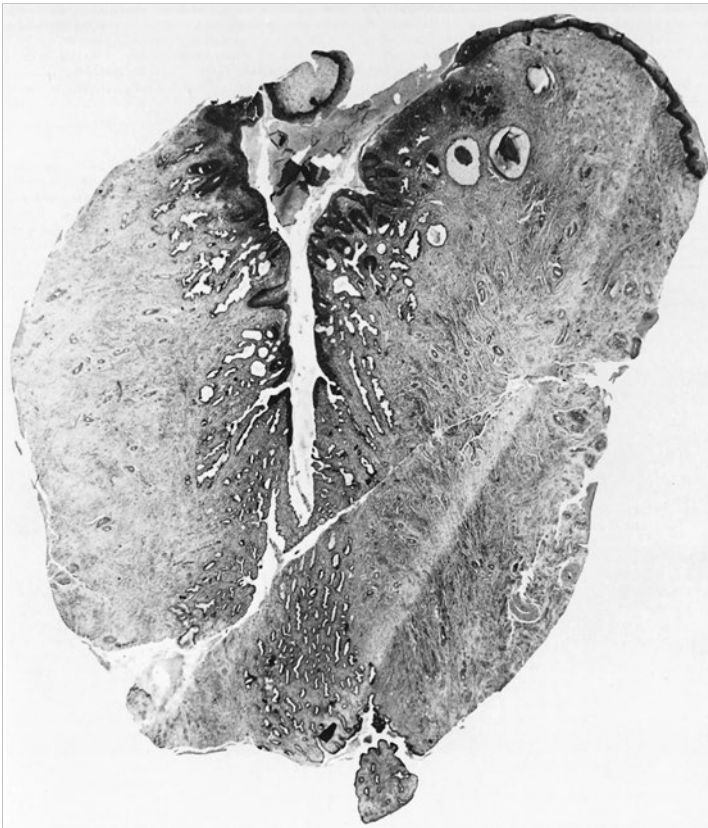


Fig. 11.2 Conization specimen. The right lip harbors a microinvasive carcinoma 2 mm in diameter. The surface and the glands show HSIL (CIN 3). The CIN on the left extends to the margin.

remodeled cervix. Neither cytology nor colposcopy is appropriate for these contingencies, and these lesions will become manifest only when invasive disease breaks through the surface of the cervix.²⁰

Recurrence after superficial ablative therapy and three negative follow-up examinations is rare,²¹ but residual, mostly preinvasive, disease after conservative treatment is not infrequent,^{9,22,23,24,25} and retreatment is required. For this reason, cryosurgery is no longer considered appropriate for treating HSIL.²⁶ It has also been shown that the recurrence rate is inversely proportional to the depth of destruction. The amount of tissue damage required is comparable to that obtained with adequate excision,²⁴ but conservative methods destroy the tissue and eliminate the possibility of examining the histology.

Invasive carcinoma and death of disease after conservative treatment of SIL have been reported.^{20,25,26,27} In expert hands, the results of superficial ablative methods are excellent; however, one experienced group has reported a collected series of nine

invasive recurrences after laser ablation with one death. Four patients who developed an invasive tumor had been treated for CIN 3 according to the initial histology report.²⁸

Finally, ablative treatment modalities have lost ground to loop excisional procedures, which are also performed on an outpatient basis and provide a good specimen for pathology.

11.2.3 Excisional Modalities: Loop Excision and Conization

Conization, whether with diathermy or a scalpel, is frequently a therapeutic as well as a diagnostic procedure. Further treatment depends on the quality of the histologic examination and on whether the lesion has been removed completely. Poor techniques have led to unnecessary complications. Treatment of patients after conization depends on the nature of the lesion in the cone and on the status of the margins of the cone.^{29,30}

Complete Excision

If the lesion is purely intraepithelial or early invasive with virtually no metastatic potential, nothing further apart from careful follow-up need be done. We have reported on a series of 4,417 patients with long-term follow-up after cold-knife conization for HSIL with clear margins. More than 99% of patients were free of disease with a mean follow-up of 18 years.³¹ Higher rates of recurrence reported by some groups may be due to different surgical techniques or inadequate histology, resulting in uncertainty as to the completeness of the excision.³² HPV testing is increasingly being used in the follow-up of patients after conization.

Incomplete Excision

Excision is incomplete if the margins pass through at least LSIL, but this does not necessarily mean that major lesions have remained in the residual cervix. Coagulation of the wound surface after excisional procedures probably ablates residual intraepithelial neoplasia, the margin of excision can pass very close to the edge of a lesion, and small portions of residual atypical epithelium can be sloughed during the healing process.

Further management depends on a number of factors:

- Which margins are not clear (endocervical, ectocervical, or stromal)?
- How far from the margins of the lesion are the invasive foci?
- What is the patient's HPV status at follow-up?
- Is preservation of the uterus desired?

Cases in which the ectocervical margin is not clear are easiest to manage. In these patients, a persistent abnormality can be detected reliably by colposcopy and cytology (► Fig. 8.113, ► Fig. 8.114, ► Fig. 8.116). In contrast, conservative management is more difficult if the apex of the cone is involved. In this setting, follow-up cytology should be complemented by endocervical curettage. The most difficult cases are those in which the stromal interface is concerned, with the margins running close to or through dysplastic epithelium in endocervical crypts (► Fig. 11.1, ► Fig. 11.3). As with destructive methods, malignant epithelium can be buried in residual crypts after healing and re-epithelialization of the surface. Such cases can be detected with cytology and colposcopy only when they have

Table 11.2 Location of SIL (CIN) according to age (119 patients undergoing conization)

	Age < 25 years	Age 26–40 years
Ectocervical only (type 1 TZ)	5 (14%)	1(1%)
Ectocervical and visible portion of the canal (type 2 TZ)	11 (31%)	33 (40%)
Upper portion of the endocervical canal (type 3 TZ)	20 (56%)	49 (59%)
Total	36 (100%)	83 (100%)

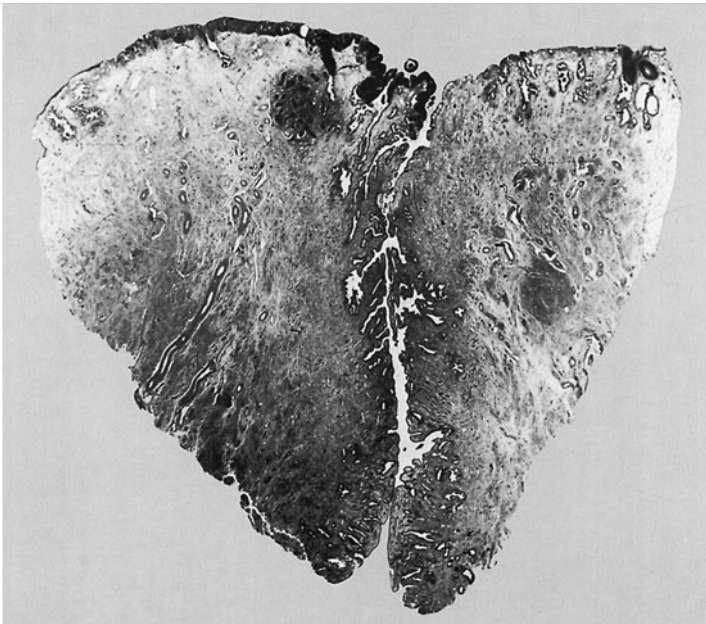


Fig. 11.3 Conization specimen. The left lip contains a microinvasive carcinoma, which shows no connection with the surface epithelium. It measures 3 mm in diameter, and reaches 6 mm in depth. This lesion can be seen with the naked eye in histologic sections. The surface and some crypts show carcinoma in situ (CIN 3, HSIL), extending beyond the external os on the left.

become invasive and broken through the surface. This also applies to invasive nests close to the resection margins; similar foci can remain in the residual cervix.

Preservation of the uterus must be weighed against the risks. The risk of expectant therapy for patients with incompletely excised superficial lesions is not high, provided regular follow-up is ensured. We have reported on a series of 390 patients with positive margins after cold-knife conization for HSIL. After a mean of 19 years, 78% of patients remained free of disease and 22% had persisting or recurrent CIN 3.³³

Repeat Conization

Residual lesions after conization can be removed completely with repeat conization, provided there is still sufficient cervical tissue. The technique is the same as for primary conization.

11.2.4 Primary Hysterectomy

The considerations that apply to ablative methods also apply to hysterectomy as the initial treatment of SIL (CIN). Specifically, invasive disease must not be overlooked. Mortality from cervical

cancer after primary hysterectomy for presumed intraepithelial neoplasia can be explained only by inadequate diagnosis before the operation. However, not infrequently, patients with SIL have other indications for hysterectomy (e.g., abnormal bleeding, symptomatic fibroids).

Primary hysterectomy should be based on firm indications. The vaginal approach appears indicated because the cervix can be circumcised under direct vision after iodine staining (Schiller test) for precise delineation of the SIL. Recurrence rates appear lower after vaginal than after abdominal hysterectomy.

11.2.5 Primary Medical Treatment of SIL

Grimm et al reported a randomized trial of local imiquimod for the treatment of HSIL.⁷ This appears a promising option, particularly for younger women with fertility concerns and easily visible lesions on the ectocervix. Other authors have looked at oral diindolylmethane and cyclooxygenase-2 for the treatment of SIL.^{34,35}

11.3 Treatment of Microinvasive Carcinoma

The treatment of microinvasive carcinoma (FIGO stage IA) has been as controversial as its definition, for both squamous cell and glandular lesions. Overall, in recent decades, the trend has clearly been toward less radical surgery for patients with microinvasive disease. Most patients can probably be treated with conization alone provided that margins are clear.³⁶ Controversy persists particularly as to the indications for lymphadenectomy and resection of parametrial tissue. The difficulty lies in selecting patients who need more extensive surgery (i.e., lymphadenectomy, parametrial resection).

Lymphatic space involvement and poor differentiation (confluent growth pattern) appear to be risk factors for recurrence,³⁷ but considering how common these perceived risk factors are in patients free of recurrence, it is clear that their specificity is low. This supports the view that radical treatment of microinvasive carcinoma is almost always overtreatment, as Kolstad was one of the first to point out.³⁸

Less than 2% of such patients have died of carcinoma (► Table 11.3).³⁹ Clearly, treatment needs to be individualized. Lymphadenectomy is indicated for patients with extensive vascular space involvement and a poorly differentiated lesion, but removal of parametrial tissue appears unnecessary.^{40,41,42,43,44}

Table 11.3 Pelvic lymph node metastases and recurrence in FIGO stage IA2 cervical cancer (with or without lymphatic space involvement)³⁹

Authors	Reference	No. of patients	Pelvic node metastasis	Invasive recurrence	Dead of disease
Östör et al. 1994		91	0	3	2
Creasman et al. 1998	43	51	0	0	0
Gadducci et al. 2003	44	23	0	3	-
Lee et al. 2006	42	28	1	0	0
Smrkolj et al. 2012	40	89	0	0	0
Reich et al. 2014	39	25	1	2	1
Total		307	2 (0.6%)	8 (2.6%)	3 (1.0%)

Abbreviation: FIGO, International Federation of Gynecology and Obstetrics

11.4 Follow-up after Treatment

Follow-up after treatment consists of colposcopy, cytology, and HPV-testing. In women who test negative at 6 and 24 months post-treatment, the risk of disease seems to be similar to that of the general population. Recurrences after treatment are higher for older than for younger women. The lower recurrence rates in younger women suggests that age-specific immunity may also contribute to the cure of cervical precancer. However, large epidemiological studies report that the risk of developing or dying from invasive cervical or vaginal cancer in women with a history of treatment for CIN 3 is two to three times higher than in the general population. This makes clear that women who have been treated for HSIL or AIS require careful surveillance.

References

- [1] Baggish MS. Complications associated with carbon dioxide laser surgery in gynecology. *Am J Obstet Gynecol* 1981; 139: 568–574
- [2] Gross G, Roussaki A, Schöpf E, De Villiers EM, Papendick U. Successful treatment of condylomata acuminata and bowenoid papulosis with subcutaneous injections of low-dose recombinant interferon-alpha. *Arch Dermatol* 1986; 122: 749–750
- [3] Benedet JL, Miller DM, Nickerson KG. Results of conservative management of cervical intraepithelial neoplasia. *Obstet Gynecol* 1992; 79: 105–110
- [4] Vesterinen E, Meyer B, Puroola E, Cantell K. Treatment of vaginal flat condyloma with interferon cream. *Lancet* 1984; 21: 157
- [5] Batista CS, Atallah AN, Saconato H, da Silva EMK. 5-FU for genital warts in non-immunocompromised individuals. *Cochrane Database Syst Rev* 2010; CD006562
- [6] Fisher AA. Severe systemic and local reactions to topical podophyllum resin. *Cutis* 1981; 28: 233–266
- [7] Grimm Ch, Polteraer St, Natter C et al. Treatment of cervical intraepithelial neoplasia with topical imiquimod: a randomized controlled trial. *Obstet Gynecol* 2012; 120: 152–159
- [8] Wright TC, Massad LS, Dunton CJ, Spitzer M, Wilkinson EJ, Solomon D. 2006 American Society for Colposcopy and Cervical Pathology-sponsored Consensus Conference. 2006 consensus guidelines for the management of women with cervical intraepithelial neoplasia or adenocarcinoma in situ. *J Low Genit Tract Dis* 2007; 11: 223–239
- [9] Chanen W, Hollyock VE. Colposcopy and the conservative management of cervical dysplasia and carcinoma in situ. *Obstet Gynecol* 1974; 43: 527–534
- [10] Kaufman RH, Conner JS. Cryosurgical treatment of cervical dysplasia. *Am J Obstet Gynecol* 1971; 109: 1167–1174
- [11] Kaufmann RH, Irwin JF. The cryosurgical therapy of cervical intraepithelial neoplasia. III. Continuing follow-up. *Am J Obstet Gynecol* 1978; 131: 381
- [12] Richart RM, Sciarra JJ. Treatment of cervical dysplasia by outpatient electrocauterization. *Am J Obstet Gynecol* 1968; 101: 200–205
- [13] Volante R, Pasero L, Saraceno L, Magurano M, Ribaldone R. Carbon dioxide laser surgery in colposcopy for cervicovaginal intraepithelial neoplasia treatment. 10 years experience and failure analysis. *Eur J Gynaecol Oncol* 1992; 13 Suppl: 78–81
- [14] Jordan JA. CO2 laser therapy. In: Coppleson M, ed. *Gynecologic oncology*, vol 2. Edinburgh: Churchill Livingstone, 1981:817
- [15] Jordan JA, Mylotte J. Treatment of CIN by destruction: laser. In: Jordan JA, Sharp F, Singer A, eds. *Pre-clinical neoplasia of the cervix*. London: Royal College of Obstetricians and Gynaecologists, 1982:205
- [16] Staffl A, Wilkinson EJ, Mattingly RF. Laser treatment of cervical and vaginal neoplasia. *Am J Obstet Gynecol* 1977; 128: 128–136
- [17] Townsend DE. Cryosurgery. In: Coppleson M, ed. *Gynecologic oncology*, vol. 2. Edinburgh: Churchill Livingstone, 1981:809
- [18] Anderson MC, Hartley RB. Cervical crypt involvement by intraepithelial neoplasia. *Obstet Gynecol* 1980; 55: 546–550
- [19] Reich O, Pickel H, Tamussino K, Winter R. Microinvasive carcinoma of the cervix: site of first focus of invasion. *Obstet Gynecol* 2001; 97: 890–892
- [20] Kranzfelder D, Mestwerdt W. Kollumkarzinom 3 Jahre nach kryochirurgischer Behandlung der Portio vaginalis uteri [Invasive squamous cell carcinoma of the uterine cervix three years after cryosurgical treatment of a benign ectopy]. *Geburtshilfe Frauenheilkd* 1978; 38: 289–291
- [21] Richart RM, Townsend DE, Crisp W et al. An analysis of “long-term” follow-up results in patients with cervical intraepithelial neoplasia treated by cryotherapy. *Am J Obstet Gynecol* 1980; 137: 823–826
- [22] Charles EH, Savage EW, Hacker N, Jones NC. Cryosurgical treatment of cervical intraepithelial neoplasia. *Gynecol Oncol* 1981; 12: 83–88
- [23] Walton LA, Edelman DA, Fowler WC, Photopoulos GJ. Cryosurgery for the treatment of cervical intraepithelial neoplasia during the reproductive years. *Obstet Gynecol* 1980; 55: 353–357
- [24] Masterson BJ, Krantz KE, Calkins JW, Magrina JF, Carter RP. The carbon dioxide laser in cervical intraepithelial neoplasia: a five-year experience in treating 230 patients. *Am J Obstet Gynecol* 1981; 139: 565–567
- [25] Townsend DE, Richart RM, Marks E, Nielsen J. Invasive cancer following outpatient evaluation and therapy for cervical disease. *Obstet Gynecol* 1981; 57: 145–149
- [26] Ostergard DR. Cryosurgical treatment of cervical intraepithelial neoplasia. *Obstet Gynecol* 1980; 56: 231–233
- [27] Sevin BU, Ford JH, Girtanner RD et al. Invasive cancer of the cervix after cryosurgery. Pitfalls of conservative management. *Obstet Gynecol* 1979; 53: 465–471
- [28] Ali SW, Evans AS, Monaghan JM. Results of CO2 laser cylinder vaporization of cervical intraepithelial disease in 1234 patients. An analysis of failures. *Br J Obstet Gynaecol* 1986; 93: 75–78
- [29] Martin-Hirsch PP, Paraskevaidis E, Bryant A, Dickinson HO. Surgery for cervical intraepithelial neoplasia. *Cochrane Database Syst Rev* 2013; 12: CD001318
- [30] Wright TC, Massad LS, Dunton CJ, Spitzer M, Wilkinson EJ, Solomon D 2006 American Society for Colposcopy and Cervical Pathology-sponsored Consensus Conference. 2006 consensus guidelines for the management of women with cervical intraepithelial neoplasia or adenocarcinoma in situ. *J Low Genit Tract Dis* 2007; 11: 223–239
- [31] Reich O, Pickel H, Lahousen M, Tamussino K, Winter R. Cervical intraepithelial neoplasia III: long-term outcome after cold-knife conization with clear margins. *Obstet Gynecol* 2001; 97: 428–430
- [32] Melnikow J, McGahan C, Sawaya GF, Ehlen T, Coldman A. Cervical intraepithelial neoplasia outcomes after treatment: long-term follow-up from the British Columbia Cohort Study. *J Natl Cancer Inst* 2009; 101: 721–728
- [33] Reich O, Lahousen M, Pickel H, Tamussino K, Winter R. Cervical intraepithelial neoplasia III: long-term follow-up after cold-knife conization with involved margins. *Obstet Gynecol* 2002; 99: 193–196
- [34] Young JL, Jazaeri AA, Darus CJ, Modesitt SC. Cyclooxygenase-2 in cervical neoplasia: a review. *Gynecol Oncol* 2008; 109: 140–145
- [35] Del Priore G, Gudipudi DK, Montemarano N, Restivo AM, Malanowska-Stega J, Arslan AA. Oral diindolylmethane (DIM): pilot evaluation of a nonsurgical treatment for cervical dysplasia. *Gynecol Oncol* 2010; 116: 464–467
- [36] Girardi F, Burghardt E, Pickel H. Small FIGO stage IB cervical cancer. *Gynecol Oncol* 1994; 55: 427–432
- [37] Burghardt E, Girardi F, Lahousen M, Pickel H, Tamussino K. Microinvasive carcinoma of the uterine cervix (International Federation of Gynecology and Obstetrics stage IA). *Cancer* 1991; 67: 1037–1045
- [38] Kolstad P. Follow-up study of 232 patients with stage Ia1 and 411 patients with stage Ia2 squamous cell carcinoma of the cervix (microinvasive carcinoma). *Gynecol Oncol* 1989; 33: 265–272
- [39] Reich et al. unpublished data
- [40] Smrkolj S, Pogačnik RK, Slabe N, Rakar S. Clinical outcome of patients with FIGO stage IA2 squamous cell carcinoma of the uterine cervix. *Gynecol Oncol* 2012; 124: 68–71
- [41] Östör AG. Pandora's box or Ariadne's thread? Definition and prognostic significance of microinvasion of the uterine cervix. Squamous lesions. *Pathol Annu* 1995; 30: 103–136
- [42] Lee KBM, Lee JM, Park CY, Lee KB, Cho HY, Ha SY. Lymph node metastasis and lymph vascular space invasion in microinvasive squamous cell carcinoma of the uterine cervix. *Int J Gynecol Cancer* 2006; 16: 1184–1187
- [43] Creasman WT, Zaino RJ, Major FJ, DiSaia PJ, Hatch KD, Homesley HD. Early invasive carcinoma of the cervix (3 to 5 mm invasion): risk factors and prognosis. A Gynecologic Oncology Group study. *Am J Obstet Gynecol* 1998; 178: 62–65
- [44] Gadducci A, Sartori E, Maggino T et al. The clinical outcome of patients with stage Ia1 and Ia2 squamous cell carcinoma of the uterine cervix: a Cooperation Task Force (CTF) study. *Eur J Gynaecol Oncol* 2003; 24: 513–516

- [45] Flannelly G, Bolger B, Fawzi H, De Lopes AB, Monaghan JM. Follow up after LLETZ: could schedules be modified according to risk of recurrence? *BJOG* 2001; 108: 1025–1030
- [46] Ang C, Mukhopadhyay A, Burnley C et al. Histological recurrence and depth of loop treatment of the cervix in women of reproductive age: incomplete excision versus adverse pregnancy outcome. *BJOG* 2011; 118: 685–692
- [47] Strander B, Hällgren J, Sparén P. Effect of ageing on cervical or vaginal cancer in Swedish women previously treated for cervical intraepithelial neoplasia grade 3: population based cohort study of long term incidence and mortality. *BMJ* 2014; 348: f7361
- Cruikshank ME, Sharp L, Chambers G, Smart L, Murray G. Persistent infection with human papillomavirus following the successful treatment of high grade cervical intraepithelial neoplasia. *BJOG* 2002; 109: 579–581
- Ghaem-Maghani S, Sagi S, Majeed G, Soutter WP. Incomplete excision of cervical intraepithelial neoplasia and risk of treatment failure: a meta-analysis. *Lancet Oncol* 2007; 8: 985–993
- Kocken M, Helmerhorst TJ, Berkhof J et al. Risk of recurrent high-grade cervical intraepithelial neoplasia after successful treatment: a long-term multi-cohort study. *Lancet Oncol* 2011; 12: 441–450
- Manchanda R, Baldwin P, Crawford R et al. Effect of margin status on cervical intraepithelial neoplasia recurrence following LLETZ in women over 50 years. *BJOG* 2008; 115: 1238–1242
- Rapiti E, Usel M, Neyroud-Caspar I et al. Omission of excisional therapy is associated with an increased risk of invasive cervical cancer after cervical intraepithelial neoplasia III. *Eur J Cancer* 2012; 48: 845–852
- Soutter WP, Sasieni P, Panoskaltis T. Long-term risk of invasive cervical cancer after treatment of squamous cervical intraepithelial neoplasia. *Int J Cancer* 2006; 118: 2048–2055

Further Reading

- Arbyn M, Ronco G, Anttila A et al. Evidence regarding HPV testing in secondary prevention of cervical cancer. *Vaccine* 2012; 30 suppl 5: F88–F99
- Arbyn M, Kyrgiou M, Gondry J, Petry KU, Paraskevaidis E. Long term outcomes for women treated for cervical precancer. *BMJ* 2014; 348: f7700
- Chan BKS, Melnikow J, Slee CA, Arellanes R, Sawaya GF. Posttreatment human papillomavirus testing for recurrent cervical intraepithelial neoplasia: a systematic review. *Am J Obstet Gynecol* 2009; 200: e1–e9

Chapter 12

Cervical Conization: Techniques and Histologic Processing of the Specimen

12.1 Diagnostic Conization	172
12.2 Therapeutic Conization	172
12.3 Technique of Conization	172
12.4 Conization During Pregnancy	175
12.5 Histopathologic Processing of the Cone	175



12 Cervical Conization: Techniques and Histologic Processing of the Specimen

Conization (also known as cone biopsy) is a surgical procedure to excise the area of the transformation zone (TZ) of the uterine cervix. By removing intraepithelial neoplasia, conization is a diagnostic and frequently a therapeutic procedure. For years, conization was performed with a scalpel (cold-knife conization) and yielded a cone-shaped specimen (hence the origin of the term). Today conization is most frequently performed with diathermy loops, which obtain smaller volumes of tissue (scoops rather than cones) and are thus associated with fewer complications in subsequent pregnancies.^{1,2,3,4,5,6,7,8,9} Conization can also be done with a laser, but this requires special equipment and removes a cylinder rather than a cone of tissue,^{1,2,10} thereby removing more of the cervical stroma than necessary. The relative incidence of cervical incompetence in subsequent pregnancies after the different procedures favors diathermy-loop excisions.^{6,11}

12.1 Diagnostic Conization

Conization provides a definitive diagnosis of cervical precancer, provided the lesion has been excised completely. Conization is planned according to the shape of the cervix and the topographic distribution of the epithelial abnormalities.¹²

The following are the indications for conization:

- HSIL (CIN 3) and adenocarcinoma in situ (AIS). These lesions are unlikely to regress and are precursors of invasive cervical cancer
- Persistent LSIL (CIN 1) and persistent CIN 2 based on colposcopically guided biopsies; this is often associated with HSIL¹³
- Recurrent high-grade intraepithelial lesions (HSIL) on cervical cytology (even if biopsies are negative)¹⁴
- Suspected microinvasive disease. The extent of the invasive component is important for planning further management.

12.2 Therapeutic Conization

Conization is frequently a definitive therapeutic intervention as well as a diagnostic procedure. Decisions about whether conization alone is sufficient treatment for a given lesion require precise histology of the surgical specimen.^{12,15} The status of the margins—that is, whether the lesion has been excised completely—and whether there is any invasion is important. These issues are discussed in detail in Chapter 11.

12.3 Technique of Conization

Conization should be done with a thorough knowledge of the possible location and significance of cervical lesions. A good standardized technique permits highly accurate diagnosis of cervical epithelial abnormalities.¹² The goal is to remove the lesion in an intact specimen that the pathologist can conveniently process.

The size and quality of the surgical specimen are crucial. All too often pathologists have to work with cones that are too small, morcellated, or difficult to orient. Excision of a cone can be technically difficult because the consistency of the tissue to be removed can vary and because of intraoperative bleeding. Such

bleeding can be largely prevented by infiltrating the cervix with a vasoconstrictive agent (dilute norepinephrine). Normal saline can be used without vasoconstrictive additives but does nothing for a surgical field.

12.3.1 Loop Diathermy Excision

Diathermy involves cutting with electrical current. The technique requires local or general anesthesia (we prefer the latter). The equipment consists of a thin stainless steel wire loop, available in a range of sizes, attached to a standard cautery handpiece. A variety of combined cutting and coagulation devices are available.^{2,12,16} Pure cutting current should be used for excising the specimen so as to limit thermal artifacts that can obscure the margins of the cone at histology.

The excised cone can be broad and shallow or narrow and high, as required by the location and size of the lesion. Shallow loop excision is appropriate if the lesion is confined colposcopically to the ectocervix or the lower part of the cervical canal (type 1 TZ) (► Fig. 12.1a). If the lesion extends up the canal out of range of the colposcope (type 2 or 3 TZ), about two-thirds of the canal should be excised (► Fig. 12.1b).

Our technique is as follows.^{12,17} The cervix is grasped with single-toothed tenacula at the 3 o'clock and 9 o'clock positions outside the area of interest and is put under some traction (► Fig. 12.2a). The cervix is infiltrated with a dilute vasoconstrictor. Iodine is applied to delineate the extent of the lesion. An appropriate loop is selected to remove the lesion with a small margin of normal (iodine-stained) tissue.

The loop is placed gently over the lesion with just enough pressure to bend the wire slightly. Cutting current is applied, and after a brief moment the loop enters the cervical epithelium. It is essential to pull rather than push the loop through the cervix (► Fig. 12.2a,b). If the loop is dragged, a shallow cut is made. The loop leaves a pale defect in the cervix, with a small amount of bleeding from the edge of the mucosa (► Fig. 12.2c). We place a suture in the specimen at 12 o'clock to orient the specimen for the pathologist.

In selected cases (i.e., large lesions with both an ectocervical and endocervical component), one can initially remove a wide but shallow specimen (ectocervically) and then a narrower, second specimen from the endocervical canal (sometimes called *cowboy hat conization*).

The loop electrode is now exchanged for a ball electrode, and the cut surface of the cervix is coagulated. Alternatively, this can be done with an argon beam coagulator. It is usually unnecessary to pack the vagina afterward.

12.3.2 Cold-Knife Conization

Cold-knife conization, once the standard, is now performed for selected indications such as AIS, reconization, lesions with an extensive endocervical component, and if fertility is not a primary consideration. An advantage is that there are no thermal artifacts to obscure the status of the margins.

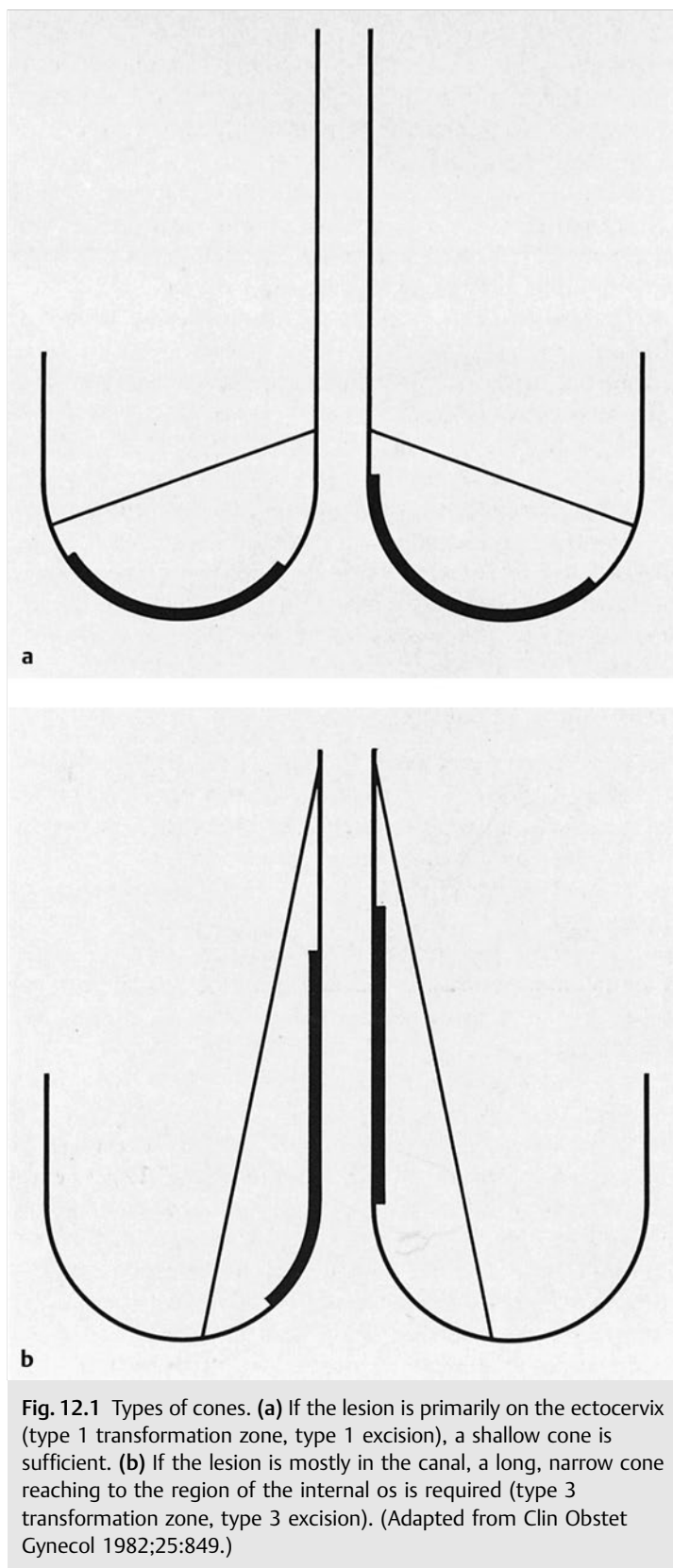


Fig. 12.1 Types of cones. (a) If the lesion is primarily on the ectocervix (type 1 transformation zone, type 1 excision), a shallow cone is sufficient. (b) If the lesion is mostly in the canal, a long, narrow cone reaching to the region of the internal os is required (type 3 transformation zone, type 3 excision). (Adapted from *Clin Obstet Gynecol* 1982;25:849.)

The cervix is infiltrated with a medium-gauge needle at four to six sites outside any lesions (► Fig. 12.3a). According to the size of the cervix, up to 40 mL of diluted vasoconstrictor is injected, enough to produce ballooning and blanching of the entire cervix (► Fig. 12.3b). Next, Lugol's iodine solution is applied generously to delineate the margins of the abnormal tissue (which appears yellow) (► Fig. 12.3c).

A circumferential incision is made to define the base of the cone. Ideally, it should be outside any visible lesion. Rarely, if the lesion is large, one has to cut closer to the margins, or even

through an iodine-yellow area. This should be noted in the surgical report, and the pathologist should be informed accordingly. Lesions extending to the vaginal fornix or even to the upper portions of the vagina beyond the margin of the cone should be evaluated with multiple biopsies.

As the incision is carried deeper, the previously injected tissue appears white and does not bleed. The soft, edematous tissue allows smooth and even excision. The cut is then angled toward the canal to achieve the intended height of the cone. The incision should be wide enough that the canal is not inadvertently entered and the cone opened. As the excision approaches the edge of the cone, the cut surface of the specimen can be grasped with a tenaculum to pull the apex into view (► Fig. 12.3d). The apex is then severed and the specimen removed. The specimen is marked with a suture at 12 o'clock.

The cut edge of the wound is white, but there may be several bleeding points (► Fig. 12.3e). The entire wound surface is then electrocoagulated, with particular attention to the bleeding points. This controls the bleeding and contracts the area of the wound as the infiltrated solution is vaporized (► Fig. 12.3f). Packing is usually not necessary, and there is no need for sutures. In particular, so-called Sturmdorf sutures, which cause scarring, distortion, and stenosis of the cervix, are obsolete. The cervix heals and reconstitutes itself best in the absence of sutures. About 6 weeks after conization, the cervix often looks nulliparous (► Fig. 12.4), with any shortening detectable only by palpation or ultrasound.

12.3.3 Complications of Conization

The most common complication is postoperative bleeding, which classically occurs between postoperative days 8 and 10.^{12,18} The incidence of postoperative bleeding is between 3% and 23%^{17,18,19, 20,21,22} (► Table 12.1) and may be reduced by infiltrating the cervix with a diluted vasoconstrictive agent before conization and by coagulating the cut surface. Excessive bleeding during or immediately after the procedure is usually due to poor technique. Neither Sturmdorf sutures¹⁸ nor ligation of the descending branch of the uterine artery^{18,21} seems to reduce the incidence of postoperative bleeding.¹⁹ The treatment of bleeding complications at our department is shown in ► Table 12.2. Infectious complications are rare (► Table 12.1) and can be limited by treating vaginal infections before surgery.

Approximately 6 weeks after conization, the cervix is scarred (► Fig. 12.5). Any shortening is detected by palpation or ultrasound. The bulk of the literature indicates an increased rate of prematurity after conization, more so with knife conization.^{6,7,8} There is no evidence to support prophylactic cerclage.

12.3.4 Laser Cone Biopsy

The cervix is stained with iodine as described already herein. The carbon dioxide laser is used in the cutting mode focused to the smallest spot size. The lesion is circumscribed under colposcopic guidance with a small margin. The incision is carried deeper vertically as far as necessary for the estimated intracervical extent of the lesion. Bleeding is minimal, as the blood vessels are rapidly cut across and retracted. To reduce damage to the specimen and facilitate cutting, the block is drawn away from the beam with fine forceps. The base of the circumscribed cylinder is then cut with

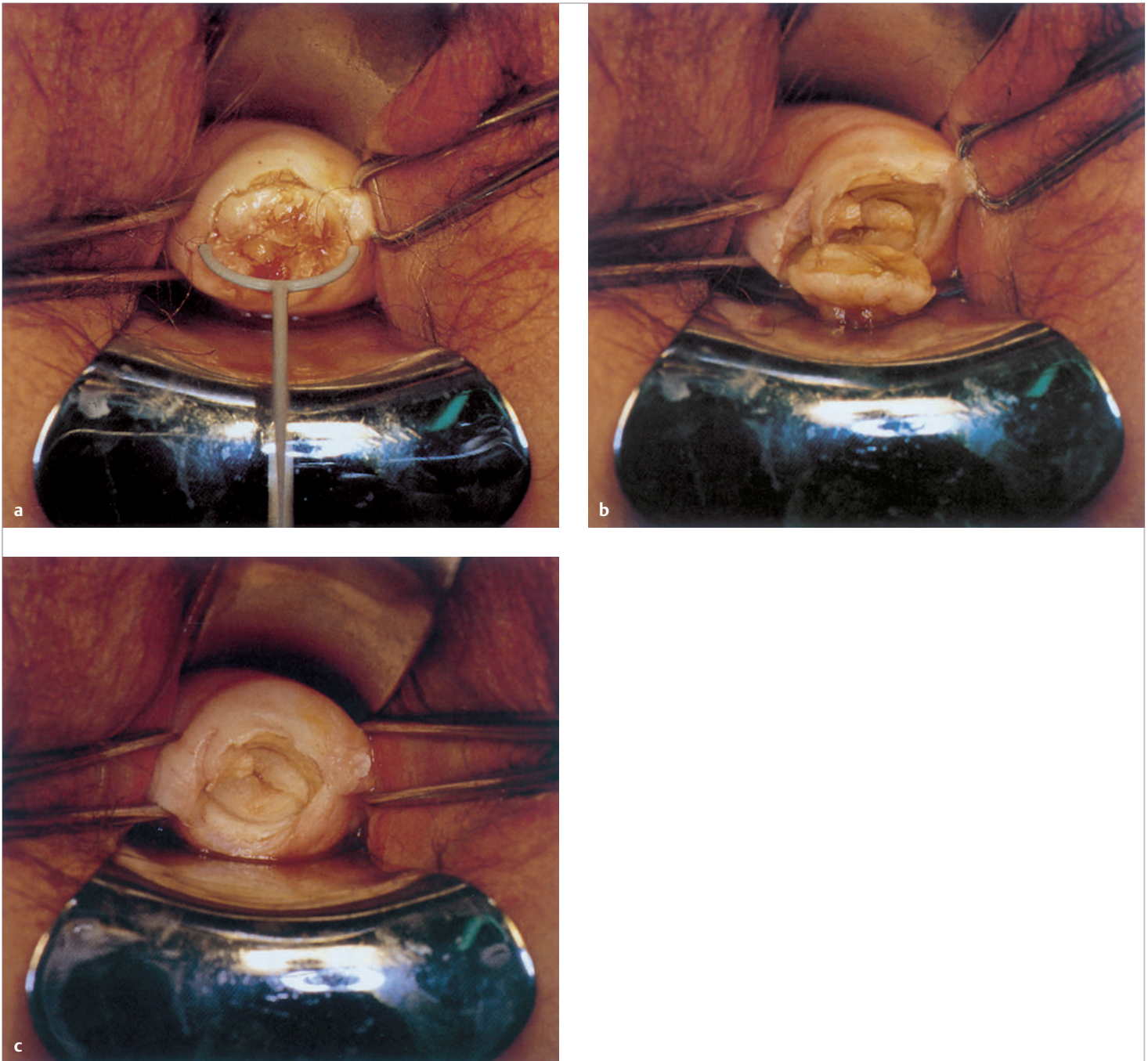


Fig. 12.2 (a) Loop diathermy excision. The cervix is grasped with single-toothed tenacula at 3 o'clock and 9 o'clock, infiltrated with about 30 mL of a diluted vasoconstrictor, and stained with iodine. The loop is chosen so that the tissue can be removed with a clear margin in one pull through the cervix. (b) The specimen comes to rest on the posterior speculum. It is marked with a suture at 12 o'clock and sent for pathology. (c) The wound surface is dry immediately after excision. It is coagulated with diathermy; the vagina is not packed.

a knife or with the laser by manipulating the block with a tenaculum. A dry cylindrical defect should remain at the end of the procedure, showing the white deep stromal tissue of the cervix with a few flecks of carbon on the surface.¹⁰

12.3.5 Comparison of Loop Excision, Cold-Knife Conization, and Laser Cone Biopsy

In a randomized study, loop excision removed less healthy tissue than cold-knife conization without reducing the chance of complete excision.²³ Although the average width of the lesions did not differ, the specimens obtained with the latter procedure were smaller and contained less of the cervical canal. Postoperative

bleeding was not more frequent. This confirms findings that complications increase with the size of the cone.²¹

If there is an association between the amount of cervical tissue removed at conization and the rate of cervical incompetence during subsequent pregnancies, then loop excision is preferable for patients who desire future pregnancies.^{5,6}

Loop excision is technically easier and less time-consuming but sometimes induces electrocautery artifacts so that histologic evaluation of the margins is difficult. Laser conization is relatively costly and time-consuming and alters the tissue significantly.^{2,3, 16,23}

The cosmetic result after healing of the defect after laser ablation is excellent (► Fig. 12.6a,b). Sturmdorf sutures, which produce scarring and deformation that make follow-up difficult, are obsolete (► Fig. 12.7).

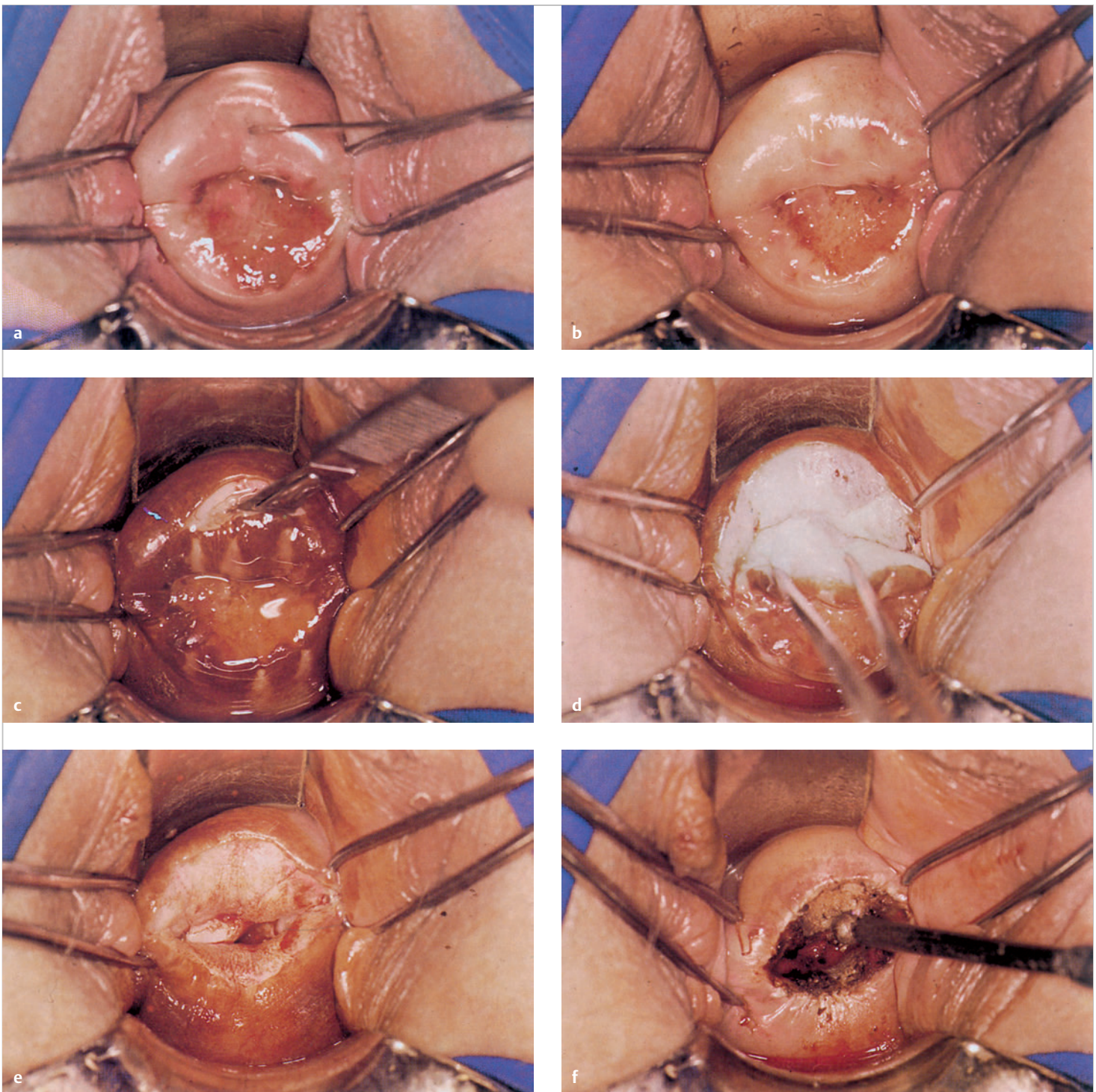


Fig. 12.3 Cold-knife conization. (a) The needle is inserted outside the lesion. (b) After injection of a vasoconstrictive agent at several points, the entire ectocervix shows ballooning and blanching. (c) The excision is begun after application of Lugol's iodine. The injected tissue is white. The injection sites are indicated by the apices of the clear triangles, which are due to seepage of the injected solution and consequent dilution of Lugol's iodine. (d) After the base of the cone, which is still attached at its tip, is excised, the cone is grasped with a tenaculum placed peripheral to the epithelial surface. The tissue is quite bloodless. (e) After removal of the cone, several bleeding points appear. (f) The surface of the wound is electrocoagulated. The cervix contracts as the injected solution evaporates; the wound surface is thus reduced.

12.4 Conization During Pregnancy

In historical experience at our institution, there was no real difference between cold-knife conization during pregnancy before 20 weeks' gestation and conization in nonpregnant women.^{17,22, 24} Because cervical lesions are usually located on the ectocervix during pregnancy, a shallow cone usually suffices. With loop excisions, a rate of positive margins of 57% has been reported.²⁵ In the past, some authors had no problems doing conization

including cold-knife procedures during pregnancy, but today most are reluctant to perform conization in pregnant patients.²⁶

12.5 Histopathologic Processing of the Cone

Histopathology of conization specimens assesses the nature of the epithelial abnormality and determines whether it has been

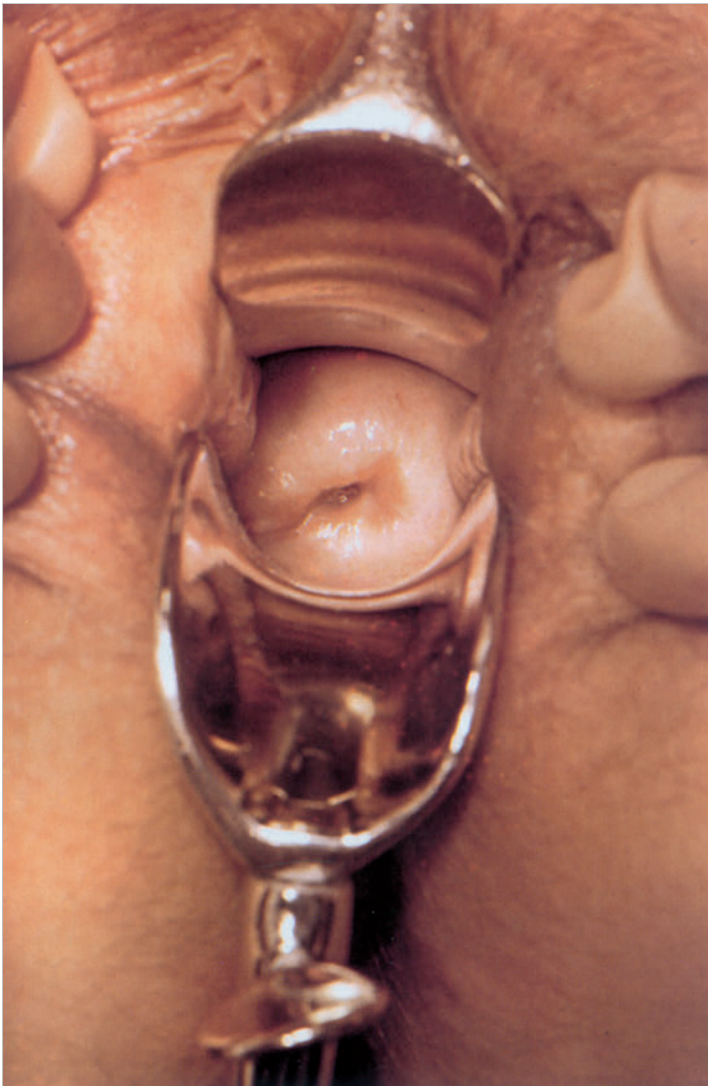

Fig. 12.4 The cervix 2 months after conization. The external os resembles that of a nullipara.

Table 12.1 Complications of cold-knife conization in 5,234 patients (Graz, 1958–1984)

Complication	No. of cases
Perforation	3 (0.005%)
Hemorrhage	329 (6.3%)
Transfusion	56 (1.0%)
Infection	12 (0.2%)
Cervical stenosis	38 (0.7%)

Table 12.2 Treatment of bleeding complications (Graz, 1981–1984)

Type of treatment	No. of cases
Expectant	13 (24%)
Packing, tamponade	25 (45%)
Diathermy coagulation	7 (13%)
Suture	10 (18%)

removed completely. Firm answers require detailed histologic assessment. It is unwise for a pathologist to comment on the margins of a cone if only single sections are examined from blocks 2 to 3 mm thick. Margins reported as clear under these circumstances may explain the relatively high number of recurrences after conization, which may actually represent persisting (rather than recurrent) disease.^{2,15}

The accuracy of histologic diagnosis depends on the handling of the specimen, the plane of sectioning, and the number of sections.³ Optimal fixation is essential. The fixed specimen can be processed in various ways. One technique involves dividing the specimen with 8 to 12 radial incisions (► Fig. 12.8a). However, if the individual sector is preserved in sequential sections, one obtains slides oriented in unfavorable planes. Although there are a lot of slides, the overall overview is poor and of limited

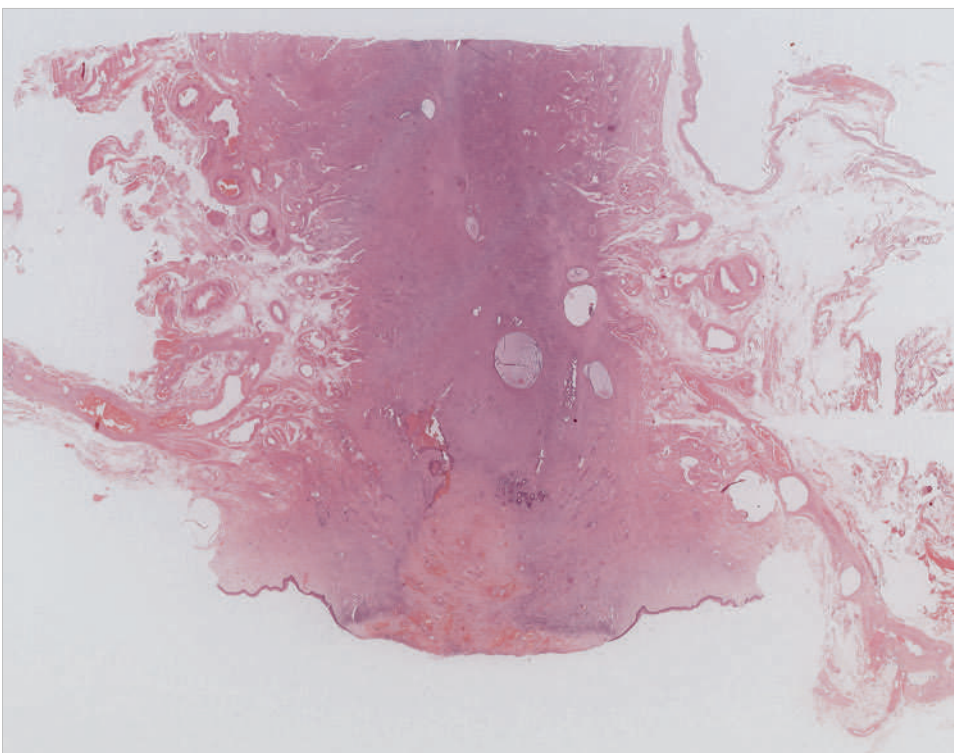


Fig. 12.5 Sagittal giant section through the cervix and the adjacent parametria 2 months after conization. Note the wedge-shaped scar tissue at the former site of conization.

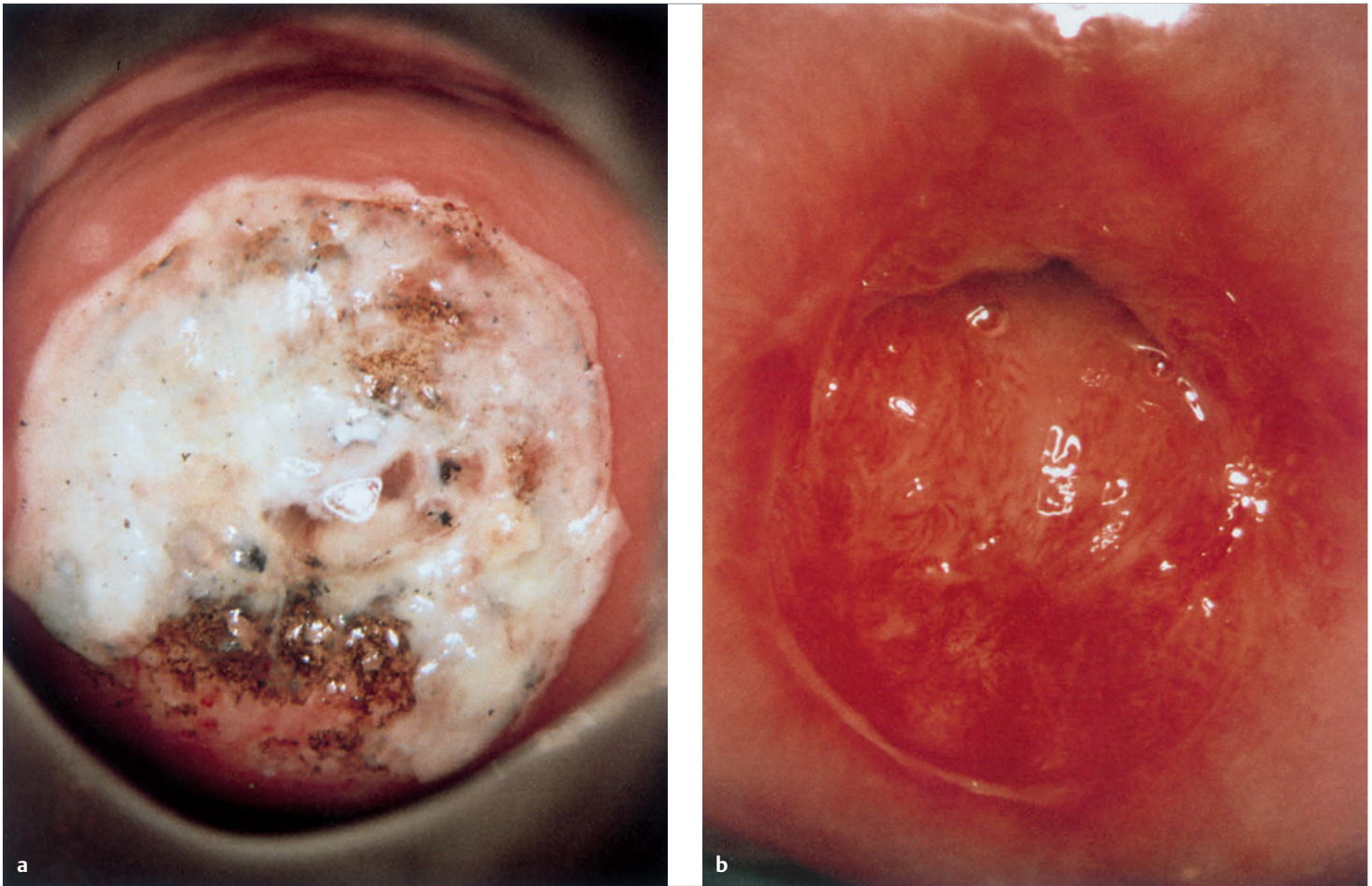


Fig. 12.6 (a) Ten days after laser vaporization of low-grade squamous intraepithelial lesion (LSIL), the ablation site is covered with fibrin and mucus and there is some residual carbonization posteriorly. (b) At 6 weeks ascending healing from the cervix has led to shiny pink epithelium with slight residual scarring at the periphery.

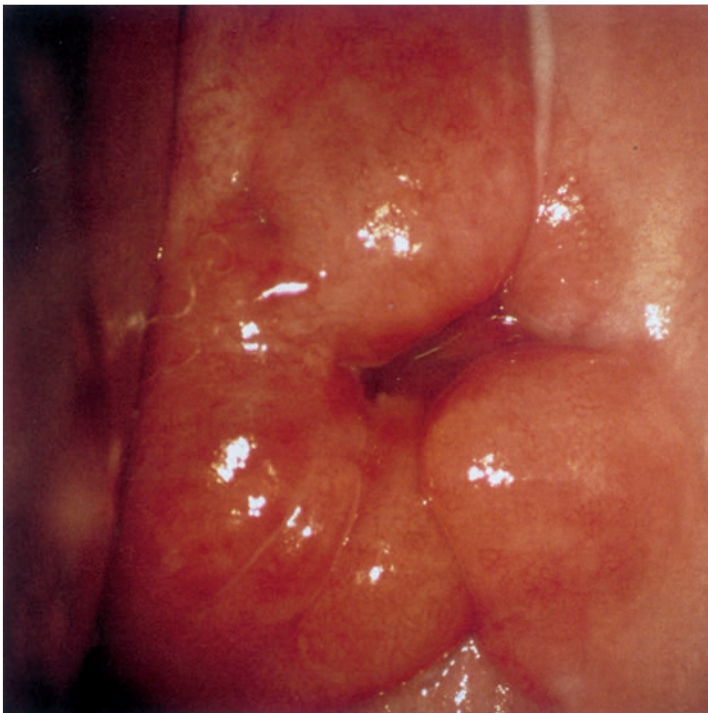

Fig. 12.7 Three months after cold-knife conization with Sturmdorf sutures for hemostasis. The cosmetic result is poor and extensive scarring obscures the squamocolumnar junction, thus making follow-up more difficult.

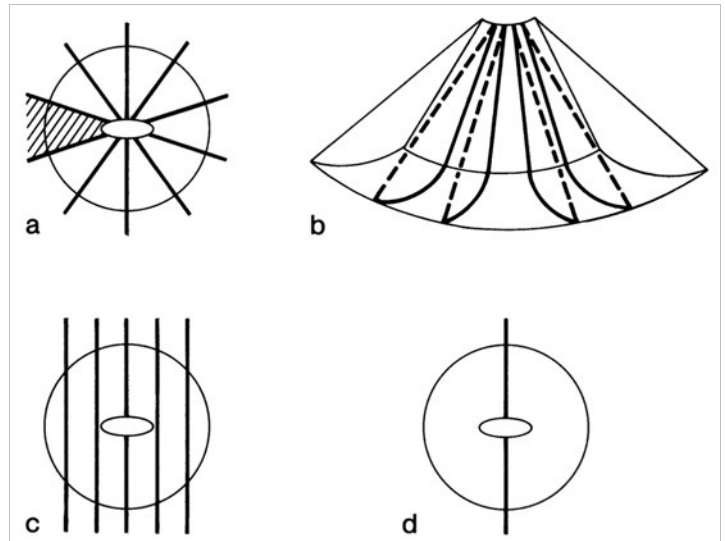


Fig. 12.8 Sectioning of the conization specimen. (a) Radial cuts. In one of the sectors, we show how the method by which it is processed must ultimately lead to unsuitable sections. (b) Sectioning of the conization specimen that has been opened and rolled up. The result of this approach is similar to that in (a). (c) Series of sagittal cuts. The resulting blocks can be cut from either side. (d) Median sagittal cut. Both blocks are evaluated from the cut surface laterally.

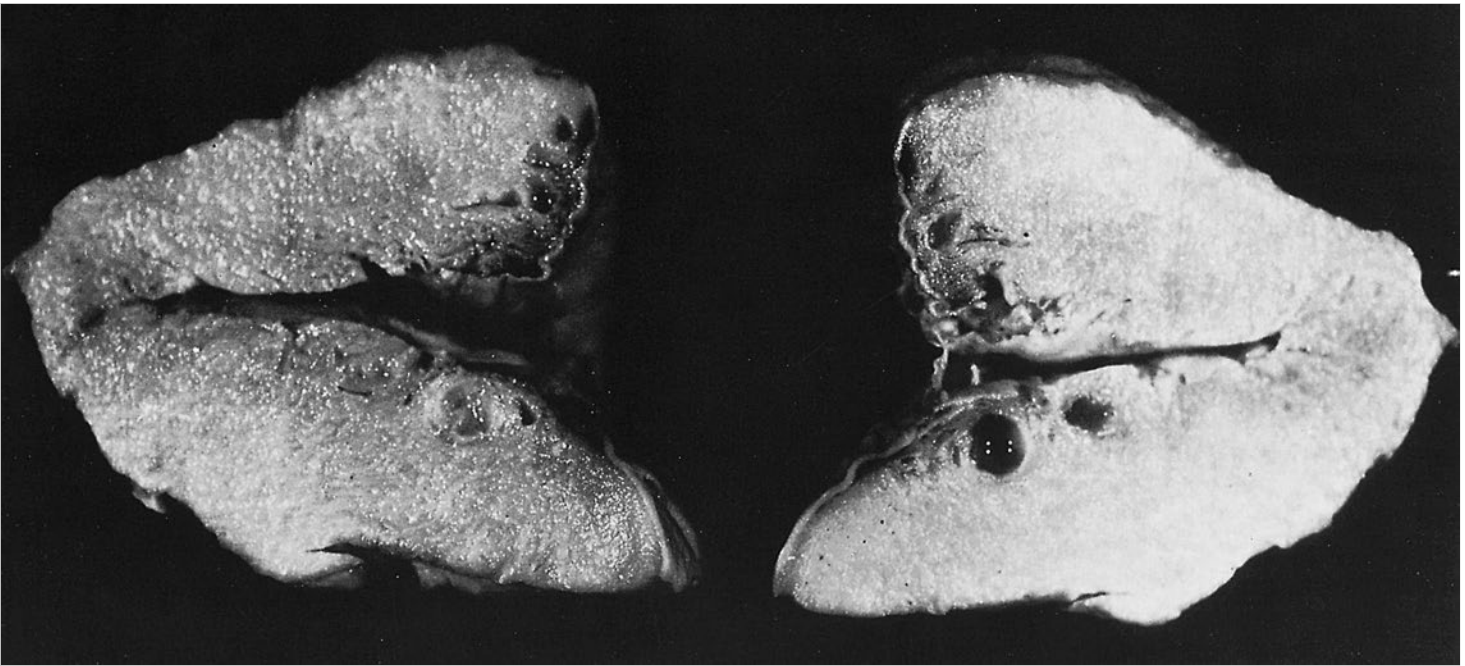

Fig. 12.9 The fixed cone from a patient with adenocarcinoma in situ is bisected. Each half is embedded in toto and serially sectioned.

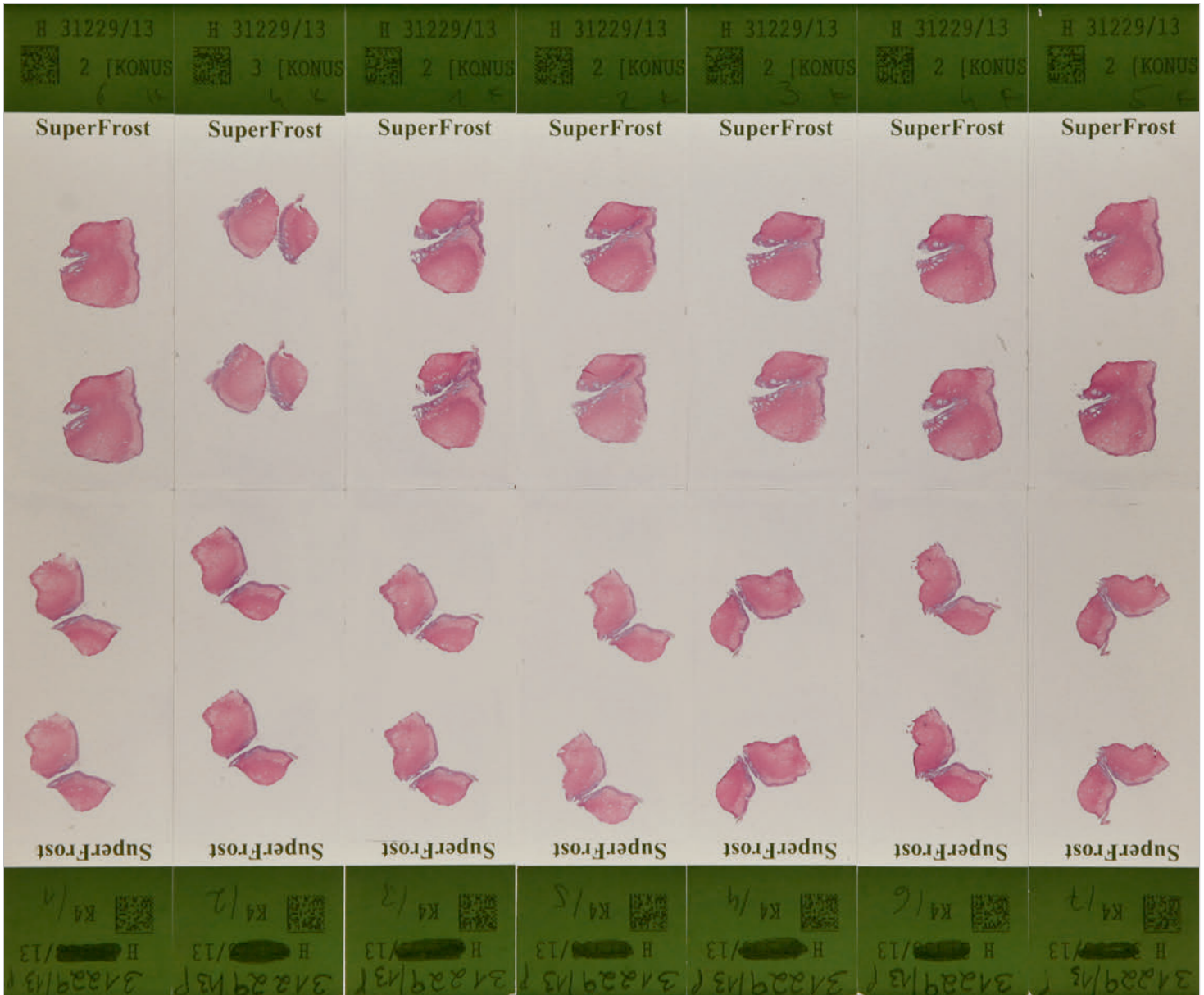

Fig. 12.10 Serial sections form a conization specimen; detail.

diagnostic value. Opening the cone parallel to the canal and sectioning the spread-out specimen into several blocks (► Fig. 12.8b) produce somewhat better overview sections.

In our experience the best results are obtained by cutting the fixated specimen sagittally (► Fig. 12.8c). We bisect the cone with a median cut (► Fig. 12.8d) and then embed the halves in toto (► Fig. 12.9). The two blocks are then serially sectioned at intervals of 200 to 300 µm until the endocervical canal has disappeared. If the lesions are still present, the two remaining blocks can be cut further. With this technique, 60 to 80 sections are obtained per cone. The result is a panoramic overview of all lesions and the topography of the cervix (► Fig. 12.10). This applies particularly to microinvasive lesions and AIS, which require precise histology to determine the dimensions and margin status.

References

- [1] Crompton AC, Johnson N. Which is more painful? A randomized trial comparing loop with laser excision of the cervical transformation zone. *Gynecol Oncol* 1994; 52: 392–394
- [2] Mathevet P, Dargent D, Roy M, Beau G. A randomized prospective study comparing three techniques of conization: cold knife, laser, and LEEP. *Gynecol Oncol* 1994; 54: 175–179
- [3] Messing MJ, Otken L, King LA, Gallup DG. Large loop excision of the transformation zone (LLETZ): a pathologic evaluation. *Gynecol Oncol* 1994; 52: 207–211
- [4] Prendiville W, Cullimore J, Norman S. Large loop excision of the transformation zone (LLETZ). A new method of management for women with cervical intraepithelial neoplasia. *Br J Obstet Gynaecol* 1989; 96: 1054–1060
- [5] Noehr B, Jensen A, Frederiksen K, Tabor A, Kjaer SK. Depth of cervical cone removed by loop electrosurgical excision procedure and subsequent risk of spontaneous preterm delivery. *Obstet Gynecol* 2009; 114: 1232–1238
- [6] Arbyn M, Kyrgiou M, Simoons C et al. Perinatal mortality and other severe adverse pregnancy outcomes associated with treatment of cervical intraepithelial neoplasia: meta-analysis. *BMJ* 2008; 337: a1284
- [7] Bevis KS, Biggio JR. Cervical conization and the risk of preterm delivery. *Am J Obstet Gynecol* 2011; 205: 19–27
- [8] Klaritsch P, Reich O, Giuliani A, Tamussino K, Haas J, Winter R. Delivery outcome after cold-knife conization of the uterine cervix. *Gynecol Oncol* 2006; 103: 604–607
- [9] Martin-Hirsch PP, Paraskevaidis E, Bryant A, Dickinson HO, Keep SL. Surgery for cervical intraepithelial neoplasia. *Cochrane Database Syst Rev* 2010: CD001318
- [10] Wright VC, Davies E, Riopelle MA. Laser cylindrical excision to replace conization. *Am J Obstet Gynecol* 1984; 150: 704–709
- [11] Werner CL, Lo JY, Heffernan T, Griffith WF, McIntire DD, Leveno KJ. Loop electrosurgical excision procedure and risk of preterm birth. *Obstet Gynecol* 2010; 115: 605–608
- [12] Burghardt E, Monaghan JM. Surgical treatment of CIN. In: Burghardt E, Webb MJ, Monaghan JM, Kindermann G, eds. *Surgical Gynecologic Oncology*. Stuttgart: Thieme, 1993:259–74
- [13] Reich O, Regauer S. Initial diagnosis of CIN 2—should patients be managed expectatively? *Am J Obstet Gynecol* 2012; 206: e11–, author reply e11–e12
- [14] Ulrich D, Tamussino K, Reich O. Should patients with cytologic high-grade intraepithelial lesions of the cervix be treated without colposcopic-guided biopsy? (letter) *Am J Obstet Gynecol* 2011; 205: e8–e9, author reply e9
- [15] Burghardt E. *Early histological diagnosis of cervical cancer*. Philadelphia: Saunders, 1973
- [16] Naumann RW, Bell MC, Alvarez RD et al. LLETZ is an acceptable alternative to diagnostic cold-knife conization. *Gynecol Oncol* 1994; 55: 224–228
- [17] Scott JW, Welch WB, Blake TF. Bloodless technique of cold knife conization (ring biopsy). *Am J Obstet Gynecol* 1960; 79: 62–66
- [18] Jones HW, Buller RE. The treatment of cervical intraepithelial neoplasia by cone biopsy. *Am J Obstet Gynecol* 1980; 137: 882–886
- [19] Ahlgren M, Ingemarsson I, Lindberg LG, Nordqvist RB. Conization as treatment of carcinoma in situ of the uterine cervix. *Obstet Gynecol* 1975; 46: 135–139
- [20] Bjerre B, Eliasson G, Linell F, Söderberg H, Sjöberg NO. Conization as only treatment of carcinoma in situ of the uterine cervix. *Am J Obstet Gynecol* 1976; 125: 143–152
- [21] Rubio CA, Thomassen P, Kock Y. Influence of the size of cone specimens on postoperative hemorrhage. *Am J Obstet Gynecol* 1975; 122: 939–944
- [22] Sprang ML, Isaacs JH, Boraca CT. Management of carcinoma in situ of the cervix. *Am J Obstet Gynecol* 1977; 129: 47–50
- [23] Girardi F, Heydarfadai M, Koroschetz F, Pickel H, Winter R. Cold-knife conization versus loop excision: histopathologic and clinical results of a randomized trial. *Gynecol Oncol* 1994; 55: 368–370
- [24] van Nagell JR, Parker JC, Hicks LP, Conrad R, England G. Diagnostic and therapeutic efficacy of cervical conization. *Am J Obstet Gynecol* 1976; 124: 134–139
- [25] Robinson WR, Webb S, Tirpack J, Degefu S, O'Quinn AG. Management of cervical intraepithelial neoplasia during pregnancy with LOOP excision. *Gynecol Oncol* 1997; 64: 153–155
- [26] Morice P, Uzan C, Gouy S, Verschraegen C, Haie-Meder C. Gynaecological cancers in pregnancy. *Lancet* 2012; 379: 558–569

Chapter 13

Colposcopy of the Vulva

13.1 Histology of the Vulva	182
13.2 Diagnostic Methods for Evaluating Vulvar Lesions	183
13.3 Vulvar Carcinogenesis	189
13.4 Preinvasive Intraepithelial Lesions	191
13.5 Non-Neoplastic	200



13 Colposcopy of the Vulva

13.1 Histology of the Vulva

The vulva is covered by three types of squamous epithelium:

- **Keratinized skin** with hair follicles, sebaceous glands, and apocrine and eccrine sweat glands. This type of skin covers the mons pubis and the labia majora.
- **Modified mucosa** with sebaceous glands but no hair follicles or sweat glands; no cornification on the interlabial sulci covers the outer aspect of the labia minora and the clitoris.
- **Glycogen-containing mucosa** without sebaceous or sweat glands, hair, or cornification covers the inner aspect of the labia minora and the introitus (► Fig. 13.1).

The transition between the keratinized and nonkeratinized epithelia (Hart's line) is sometimes visible to the naked eye and always visible microscopically.¹ Hart's line is best seen at the posterior fourchette, and it marks the peripheral border of the vaginal vestibulum. The vaginal vestibulum comprises the outer aspect of the hymen, which separates the vestibule from the vagina, the frenulum clitoridis, the inner aspect of the labia minora, the vaginal introitus, and the external urethral orifice.

The epidermis is a stratified squamous epithelium composed of distinct layers. In a vertical section, the epidermis has an undulating appearance caused by the malpighian rete. The deepest layer, resting on the basement membrane, is the basal cell layer (germinative layer, stratum germinativum) from which the epithelium

regenerates. The basal cells are undifferentiated and pluripotent. The basal layer also contains melanocytes, which are highly differentiated. The spinous cell layer (stratum spinosum) is the layer most variable in thickness. The next layer, the granular layer (stratum granulosum), is followed by the horny layer (stratum corneum), which also varies in thickness.

A variant of normal is the so-called *micropapillomatosis*.² These are prominent, 1- to 3-mm vestibular papillae³ (► Fig. 13.2) are a common finding in premenopausal women and not to be confused with condylomas. Micropapillomatosis can also be found at the inner aspect of the labia minora and at the external edges of the vestibule.

The glycogen-containing mucosa of the introitus and the vagina has the same appearance as the cervical epithelium and is very sensitive to hormonal influences. With lack of estrogen in childhood and after menopause, this layer is thin. With exposure to estrogen, the mucosa gains its characteristic multilayered appearance. Apart from the basal cell layer, which does not contain melanocytes, the next cell layers are generally uniform. All contain glycogen in the cytoplasm, which gives it a honeycomb appearance in hematoxylin–eosin sections. Apart from the basal cell layer, one can distinguish only an intermediate and a superficial cell layer.

The vulva can be affected nonspecifically by dermatologic conditions and by specific conditions. The vulva is an epithelial high-risk area with a predisposition to multifocal and recurrent malignant transformation.

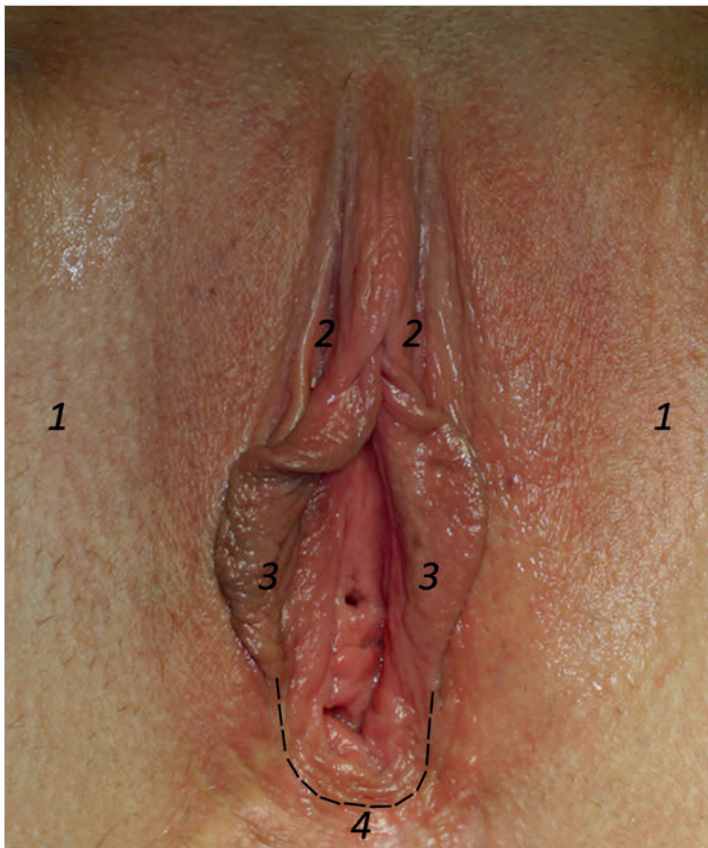

Fig. 13.1 Three types of vulvar squamous epithelium: 1, keratinized skin; 2, modified mucosa; and 3, glycogen-containing mucosa. Hart's line (4) is the border between the keratinized and nonkeratinized epithelia.

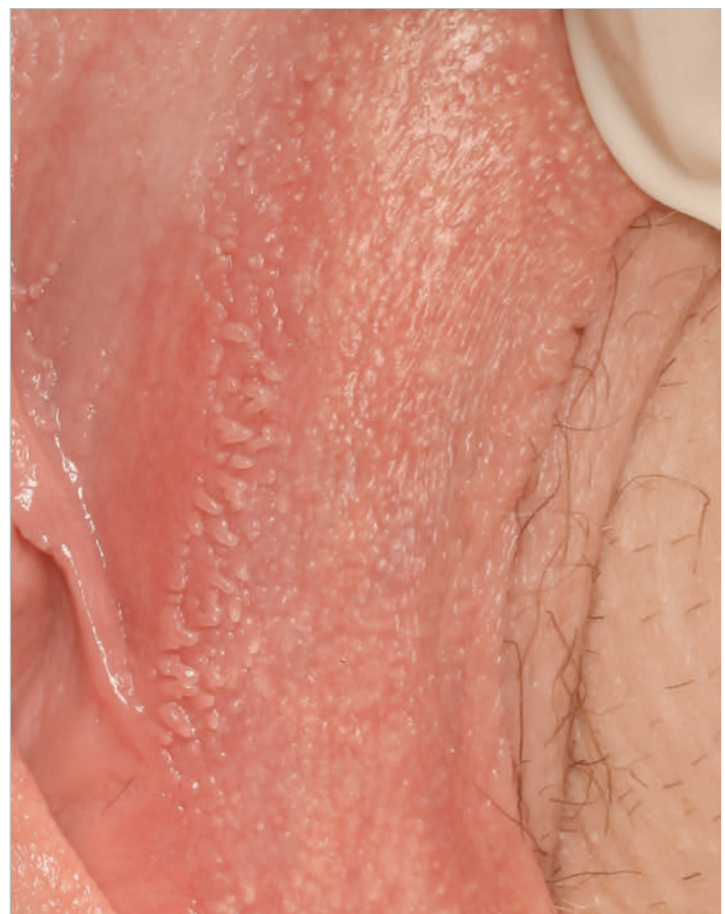


Fig. 13.2 Micropapillomatosis at the inner aspect of the labia minora.

13.2 Diagnostic Methods for Evaluating Vulvar Lesions

The diagnosis of vulvar disorders is based on the clinical history, inspection, palpation, colposcopy, histology, and, in some instances, confirmation with laboratory evaluation, including biomarkers.

13.2.1 History and Symptoms

In younger patients, the history is often brief and related to an acute condition. Older patients frequently have chronic lesions, and sometimes there is a marked discrepancy between the subjective complaints and the objective findings. Characteristic symptoms of vulvar lesions are itching (pruritus), soreness, burning sensations, paresthesias, and pain, including dyspareunia. The relevant surgical, medical (diabetes), and psychiatric history should be elicited. Medications, estrogen replacement, allergies, incontinence, and prior vaginitis and sexually transmitted diseases are of interest.

13.2.2 Inspection

Diseases of the vulva vary and overlap in appearance. Some patients have multiple conditions. Biopsy and histopathology are required for most diagnoses. Vulvar lesions that do not resolve within weeks of medical management have to be

watched closely to detect progression. Photographic documentation is very helpful.

13.2.3 Palpation

Many vulvar conditions are normal to palpation. However, even small invasive carcinomas show a tougher consistency around their base than the surrounding tissue. Small invasive foci may, on occasion, be suspected in large areas of abnormal findings by palpation alone. When these lesions grow, they are no longer at the level of the surrounding tissue and become less mobile against the dermis. The surface of vulvar conditions can also be smooth or rough on palpation; a rough surface is often due to either crust or scale.

13.2.4 Toluidine Blue Test (Collins Test)

This technique, now rarely used, consists of 1% toluidine blue dye applied to the vulva for 2–3 minutes and then washed off with 1% acetic acid. This method is a native stain for cell nuclei, which can be increased in neoplastic lesions or exposed in ulcers. Thus, a positive test result is unspecific (► Fig. 13.3), whereas a negative result makes a malignant lesion unlikely. The toluidine blue test can also be used during surgery to plan the margins of the excision. However, the test has become almost obsolete with the increased use of colposcopy with acetic acid. Colposcopy

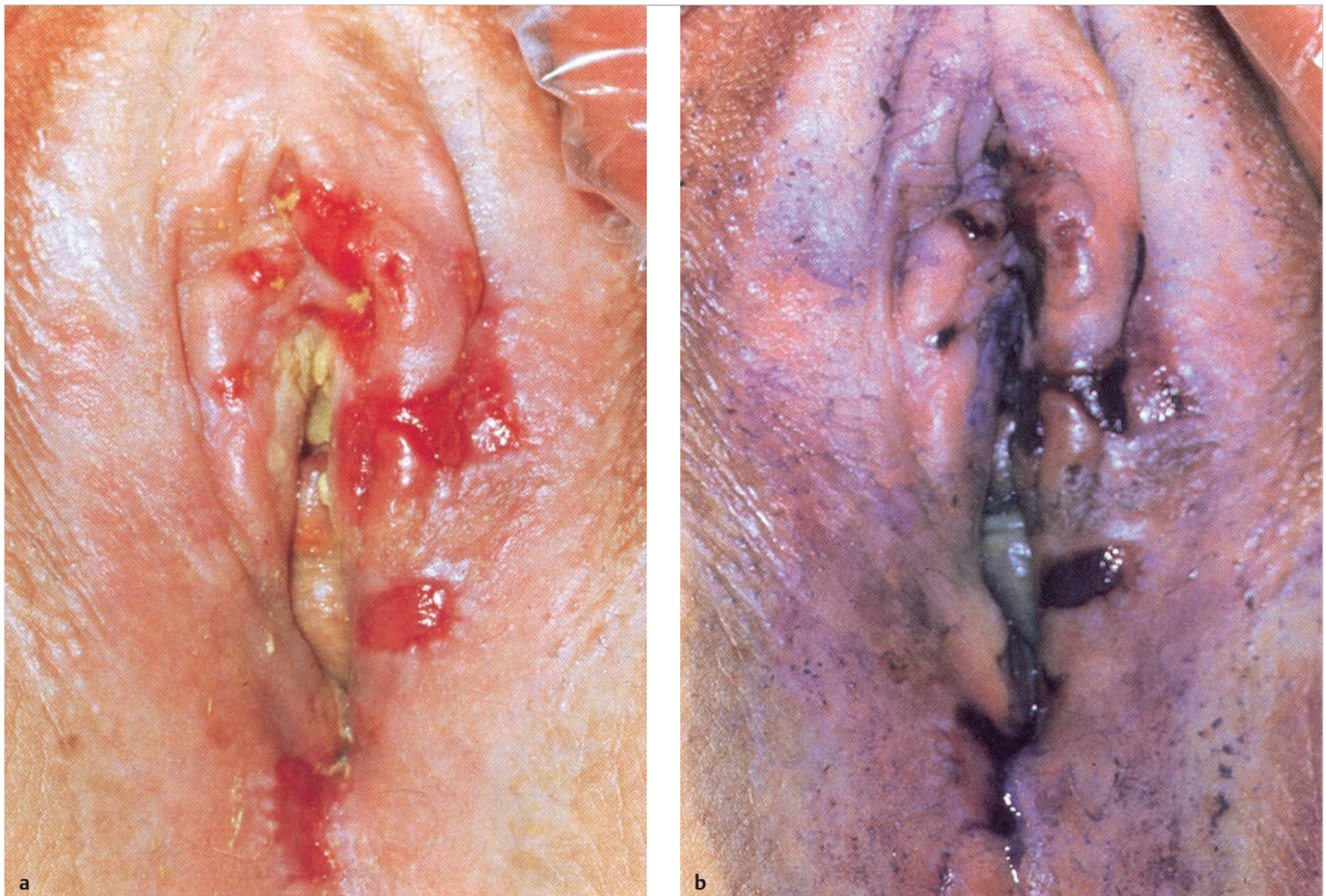


Fig. 13.3 Collins test. (a) Multicentric erosions in a patient with lichen sclerosus. (b) Positive toluidine blue staining of the erosions. The test is unspecific because staining is seen with both dysplastic and neoplastic lesions as well as benign injuries, erosions, and ulcers.

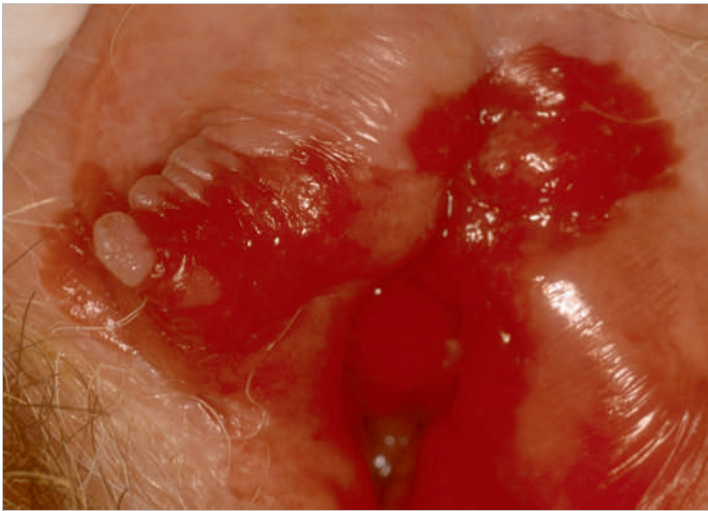

Fig. 13.4 Erythroplakia in a patient with HSIL.

(vulvoscopy) provides much more detail, particularly for papillary lesions and the typical findings of punctations and mosaics. Toluidine blue is sometimes applied for forensic purposes to demonstrate injuries.

13.2.5 Colposcopy of the Vulva

Magnification of the vulvar skin with or without the application of acetic acid permits more precise evaluation and earlier detection of vulvar lesions than inspection with the naked eye. In contrast to colposcopy of the cervix, low magnification usually suffices.

Color can be described as red (erythroplakia), white (leukoplakia), or pigmented (melanotic). Skin-colored lesions are those that match the color of the surrounding normal skin. In the

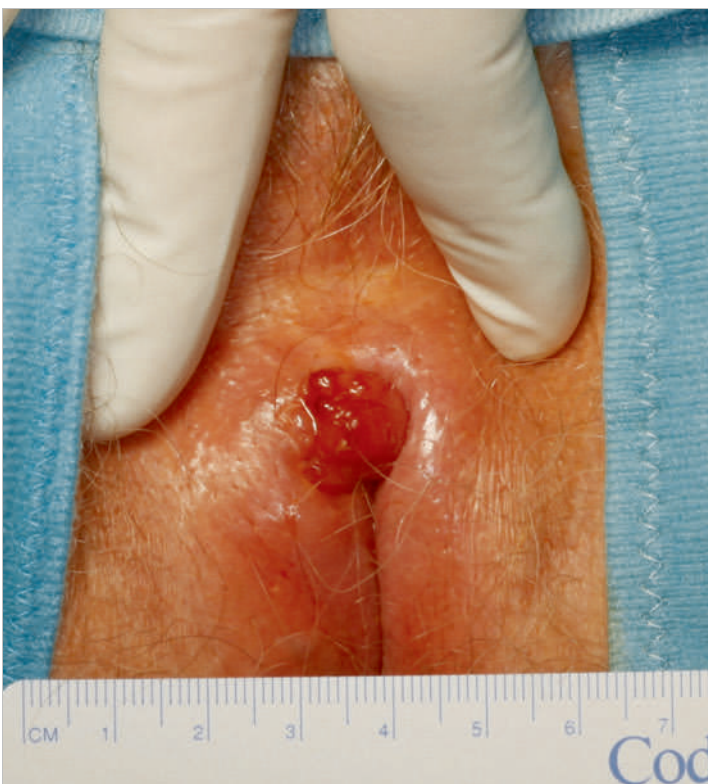

Fig. 13.5 Erythroplakia in a patient with small HPV-associated invasive vulvar cancer.

mucosal portion of the vulva, skin-colored lesions will be pink or red. Evaluation of color does not require colposcopy.

Redness (*erythroplakia*) can be due to acute or chronic inflammation, squamous intraepithelial lesions (SIL), differentiated-type vulvar intraepithelial neoplasia (dVIN), or invasive neoplasia. Erythroplakia can be circumscribed or diffuse (► Fig. 13.4 and ► Fig. 13.5).

Leukoplakia is a general descriptive term for whitish lesions before application of acetic acid. It is caused by thickening of the superficial keratinized epithelial layers. Whiteness can be caused by dermatoses such as lichen sclerosus or lichen planus with decreased blood supply and hyperkeratosis as well as with malignant and premalignant conditions (► Fig. 13.6, ► Fig. 13.7, ► Fig. 13.8).

Dark (melanotic) lesions: Apart from the lesions of malignant melanoma and its precursors, about 30% of all high-grade SIL (HSIL) are associated with irregular hyperpigmentation (► Fig. 13.9).

Colposcopy of the vulva is used for the following:

- To define the extent of lesions
- To direct biopsies to the area of the most clinically severe abnormality
- To exclude overt invasive cancer
- To direct treatment by visualizing anatomic landmarks

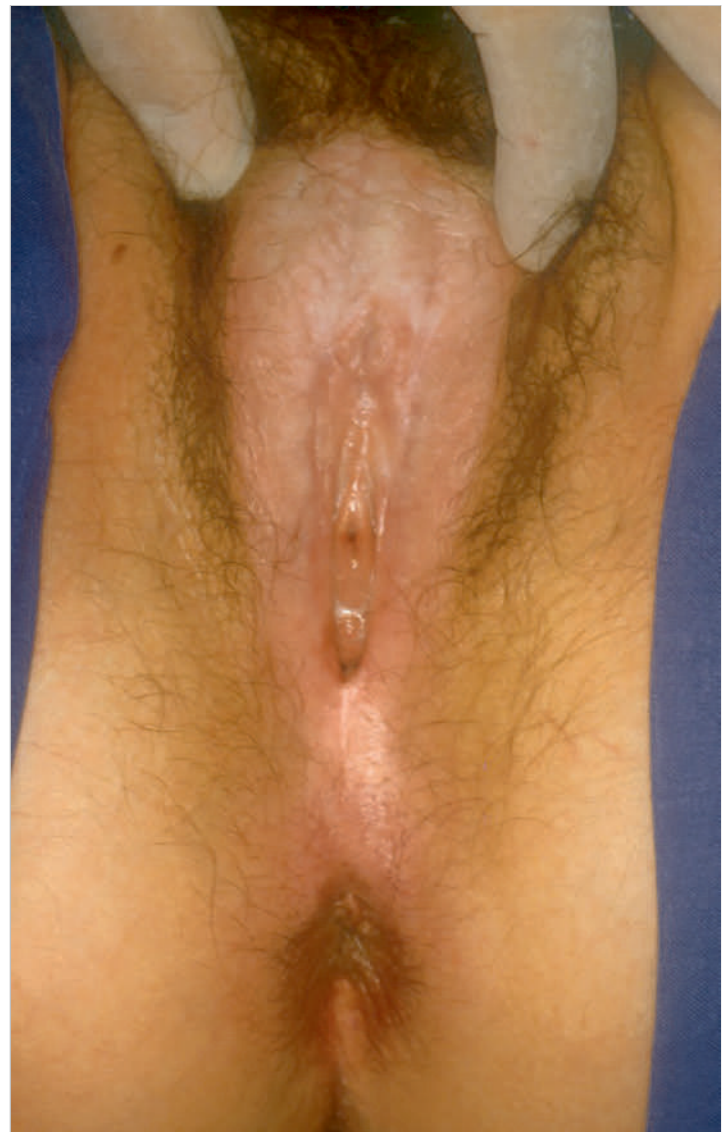

Fig. 13.6 Leukoplakia in a patient with advanced lichen sclerosus.

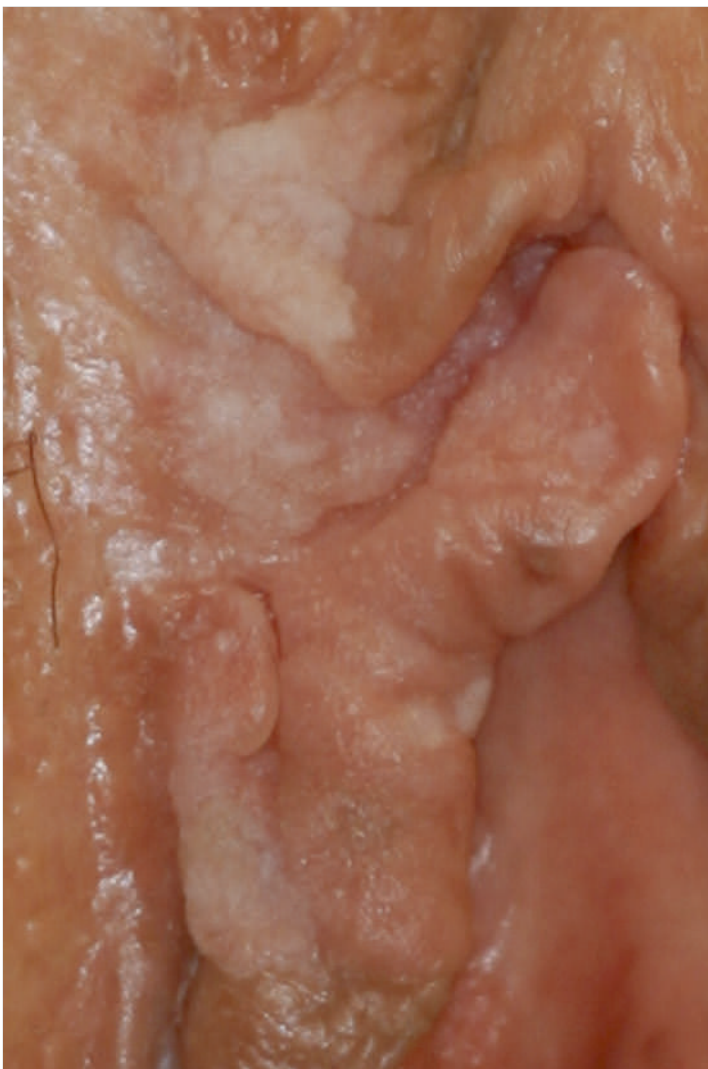

Fig. 13.7 Leukoplakia in a patient with multicentric HSIL.

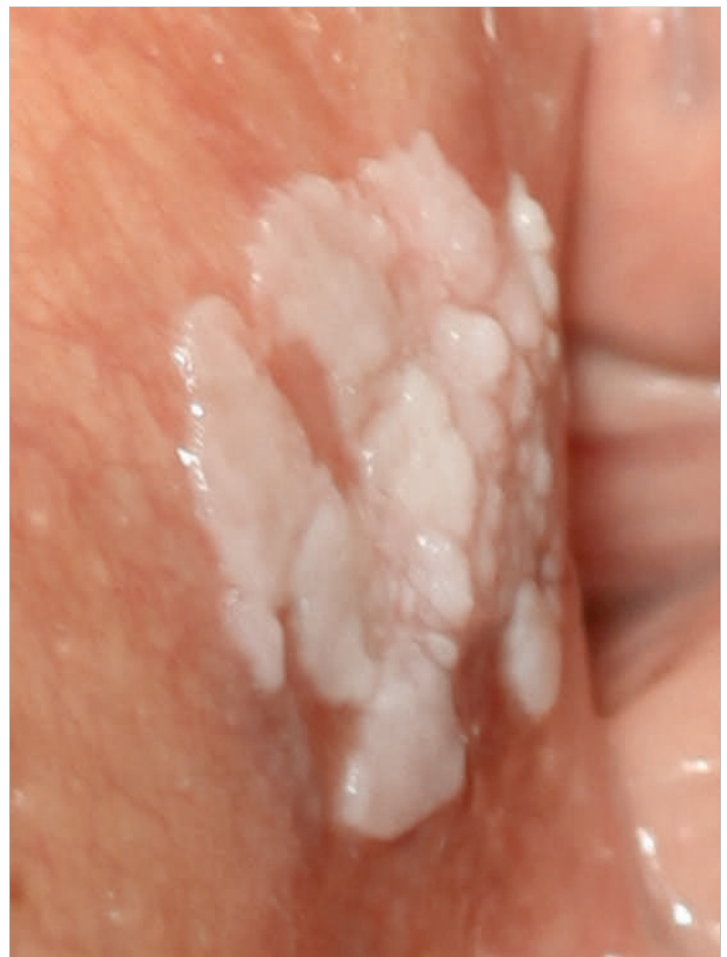

Fig. 13.8 Leukoplakia, well circumscribed, at the introitus vaginae. Histology shows HSIL.

The 2011 IFCPC Clinical/Colposcopic Terminology of the Vulva² distinguishes normal findings, abnormal findings, miscellaneous findings, findings suspicious for malignancy, and abnormal colposcopic (magnification) findings. *Sharp borders* are also important. *Mosaic* is not included in the new terminology, although it can be detected in vulvar lesions. The vulvar terminology does not distinguish between minor and major abnormal colposcopic findings, as it does for the cervix and vagina.

Acetowhite epithelium. In contrast to the cervix, where acetic acid is an integral part of the examination, on the vulva, acetic acid is applied only when morphological manifestation of HPV infection (SIL) or early invasive disease linked to high-risk HPV is suspected. Application of 3–5% acetic acid requires 2–3 minutes for lesions to become apparent.

It is important to carefully inspect the vulva before acetic acid is applied in order to outline preexisting areas of leukoplakia. Diffuse and flat acetowhite epithelium can represent a normal finding that is most likely due to increased cell turnover secondary to mechanical stimuli or inflammatory conditions of the vulva. Flat acetowhite epithelium therefore should be considered non-specific. In contrast, acetowhite epithelium from HSIL is more likely to be raised and sharply demarcated. The results after application of acetic acid are interpreted in combination with other signs such as punctuation, mosaic, sharp borders, elevated lesions, and atypical vessels (► Fig. 13.10).^{4,5}

Punctuation and mosaic. Acetowhite epithelium, erythroplakia, and leukoplakia can show *mosaics* and *punctations* when studied

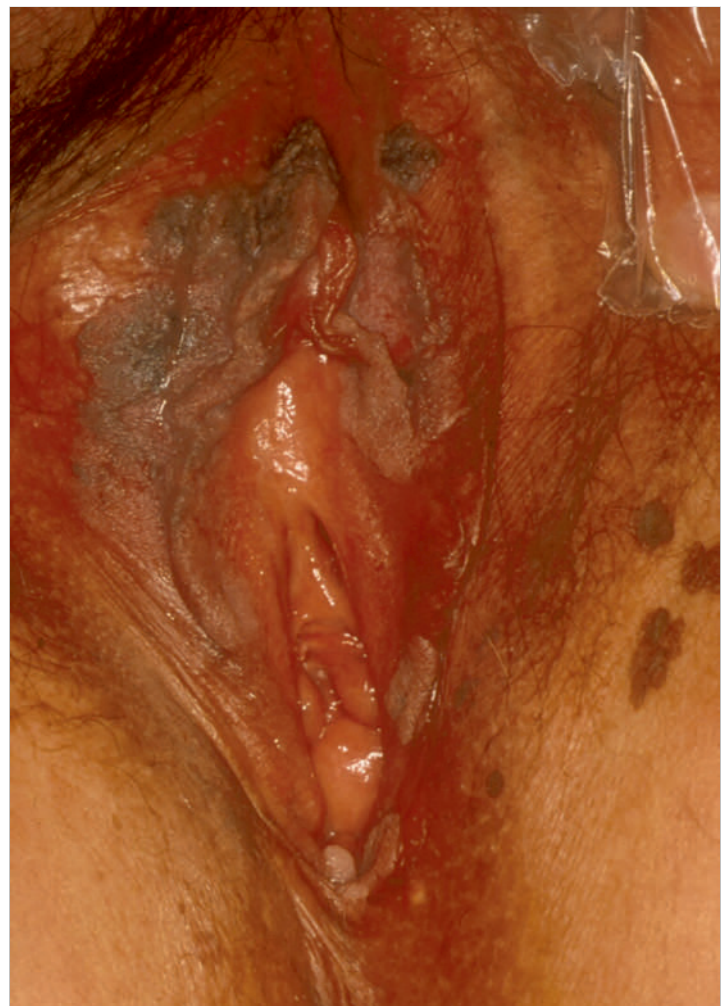

Fig. 13.9 Irregular hyperpigmentation in a patient with multicentric HSIL.

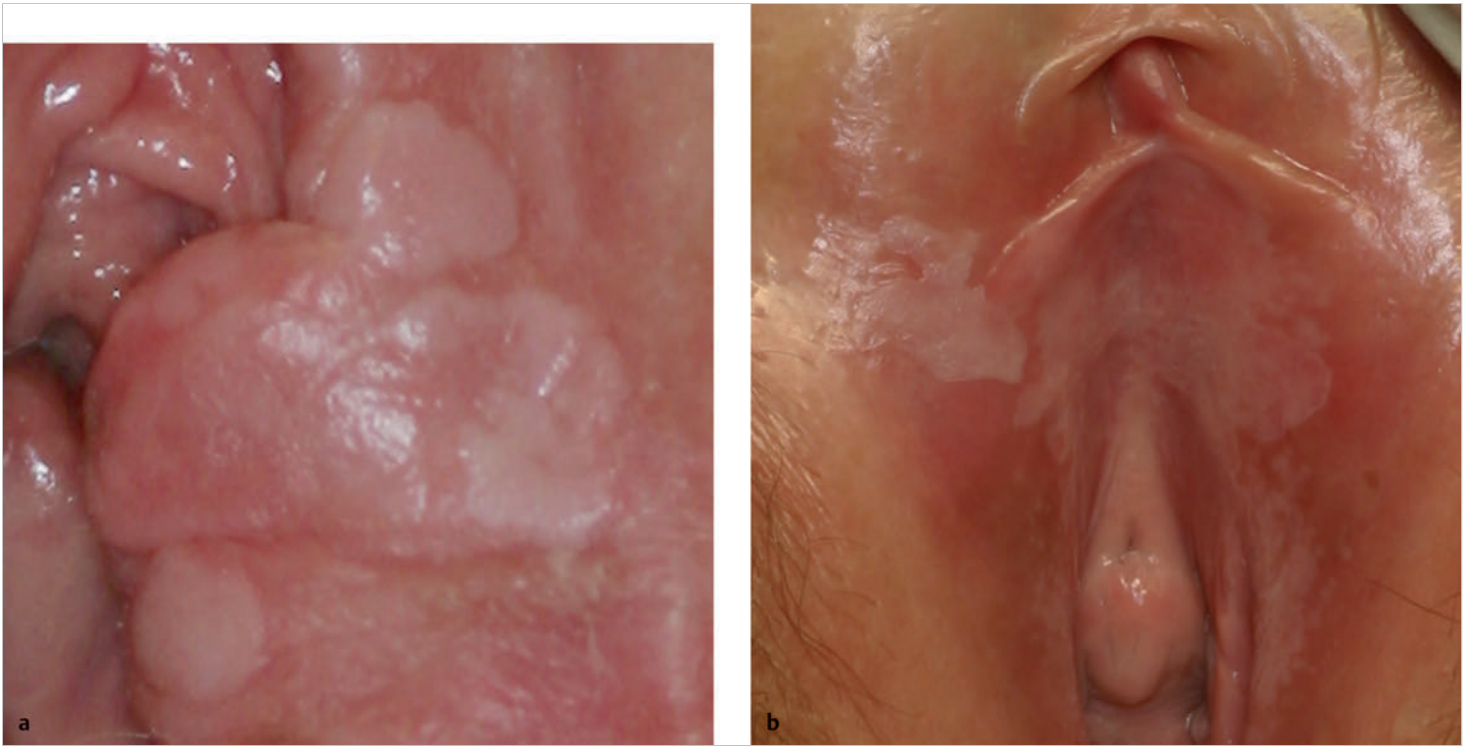


Fig. 13.10 Acetowhite epithelium (a) raised in a patient with HSIL (b) sharply demarcated, histology showed HSIL.

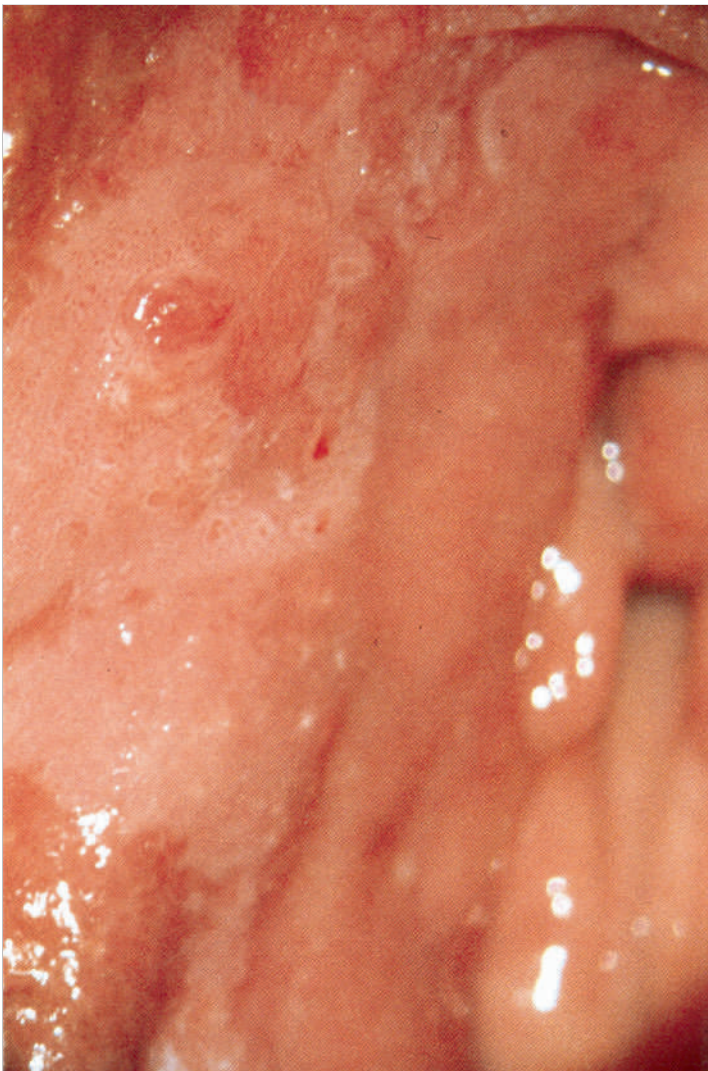

Fig. 13.11 Acetowhite epithelium with marked punctation and a slight mosaic in a patient with HSIL.

with the colposcope. They are more common in the nonkeratinizing, glycogen-containing squamous epithelium of the introitus than in the remaining vulva (► Fig. 13.11, ► Fig. 13.12, ► Fig. 13.13, ► Fig. 13.14).

Sharp borders. Border zones (margination) represent the transition from normal skin to lesional skin. A sharply marginated lesion has an abrupt transition; a poorly marginated lesion has a more gradual transition. HSIL are often sharply demarcated from their surrounding normal epithelium, as are different types of abnormal epithelia among themselves (► Fig. 13.15). The larger the difference in the differentiation of areas of adjoining HSIL, the clearer the border between them. In contrast, inflammation affects the stroma more than the epithelium and its borders are much less defined. Sharp demarcation is seen with carcinomas of all sizes (► Fig. 13.16).

Surface irregularities. Leukoplakia with a rough and irregular surface are suspicious for dVIN (see 13.3.2).

Atypical vessels. As at other locations, atypical vessels are suggestive of invasive lesions (► Fig. 13.17).

The 2011 IFCPC terminology for the vulva distinguishes primary lesion types (► Table 7.5) and secondary presentations (► Table 13.1).² These lesions can be evaluated with the naked eye, a magnifying glass or a colposcope with low magnification.

13.2.6 Histologic Correlates of Colposcopic Findings

Acetowhite epithelium. Sharply demarcated and raised acetowhite epithelium generally corresponds to HSIL, whereas dVIN generally does not react to acetic acid.

Leukoplakia and erythroplakia. SIL and dVIN can cause marked hyper/parakeratosis visible as leukoplakia or inflammation

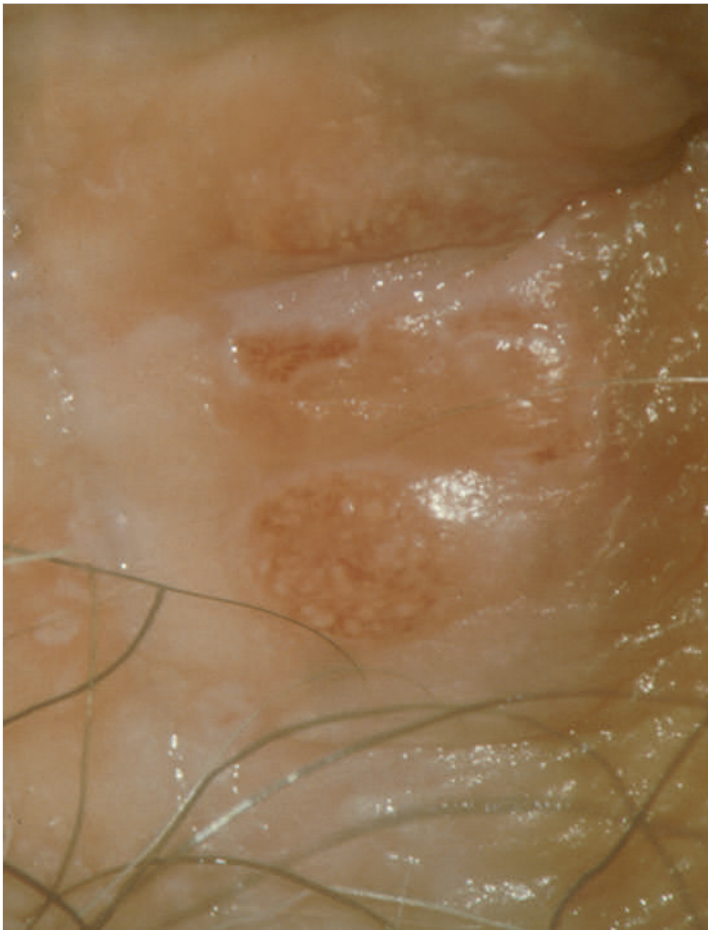


Fig. 13.12 Coarse mosaic with sharp borders surrounded by acetowhite epithelium in a patient with FIGO I HPV 16 positive vulvar squamous cell carcinoma.

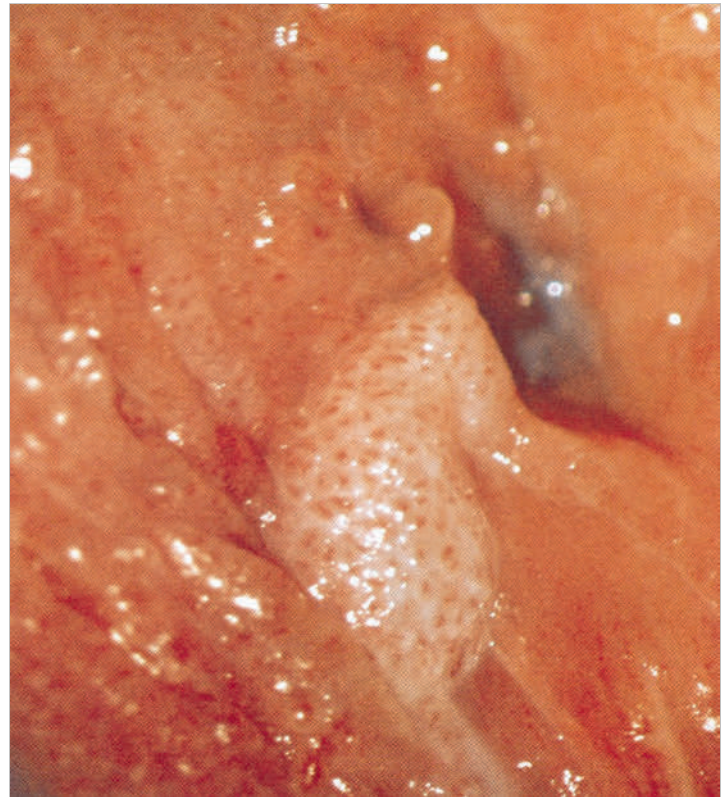


Fig. 13.13 Coarse punctuation in an elevated acetowhite epithelium. Histology shows HSIL.

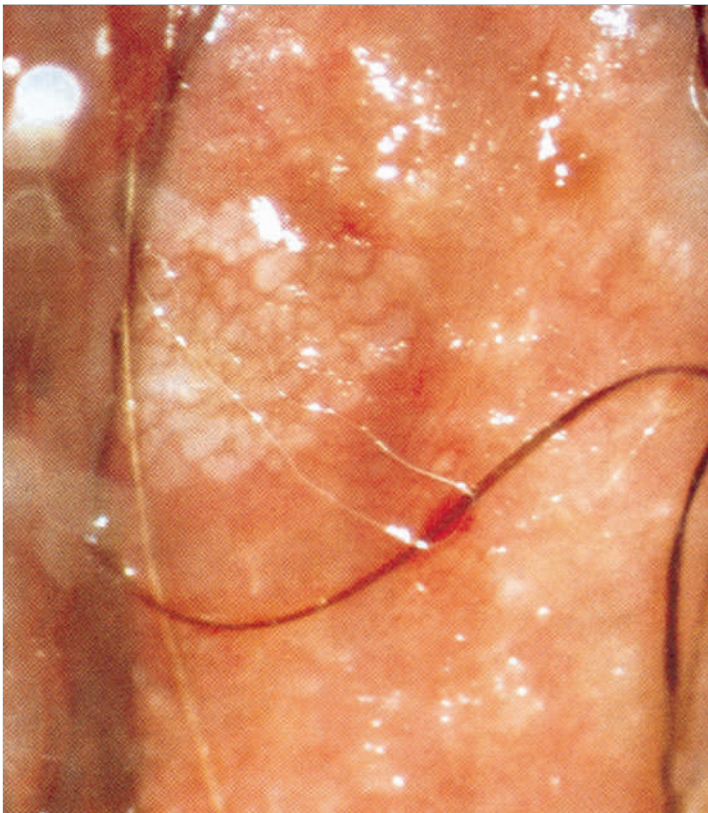

Fig. 13.14 Coarse mosaic in a lesion with leukoplakia. Histology shows HSIL.

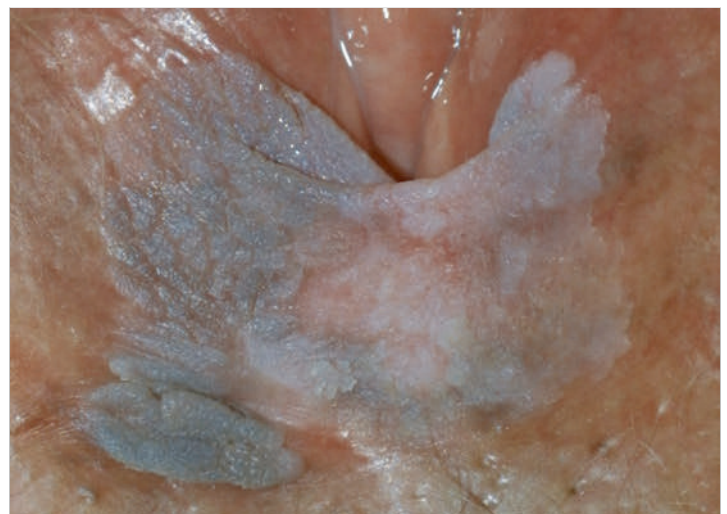

Fig. 13.15 Sharp borders in a slightly pigmented lesion with rough leukoplakia and surface irregularities. Histology showed HSIL.

and hypervascularization visible as erythroplakia. There are also erythroplakic areas in atrophic glycogen-containing squamous epithelium.

Punctuation and mosaic. Punctations and mosaics in non-malignant lesions correspond to thin epithelial ridges and wide stromal papillae. In premalignant and malignant lesions, the stromal papillae are much narrower and the epithelial ridges plumper and more irregular. In vertical sections, the differences between normal and atypical squamous epithelium are even more apparent. Papillae and papillary ridges of considerable

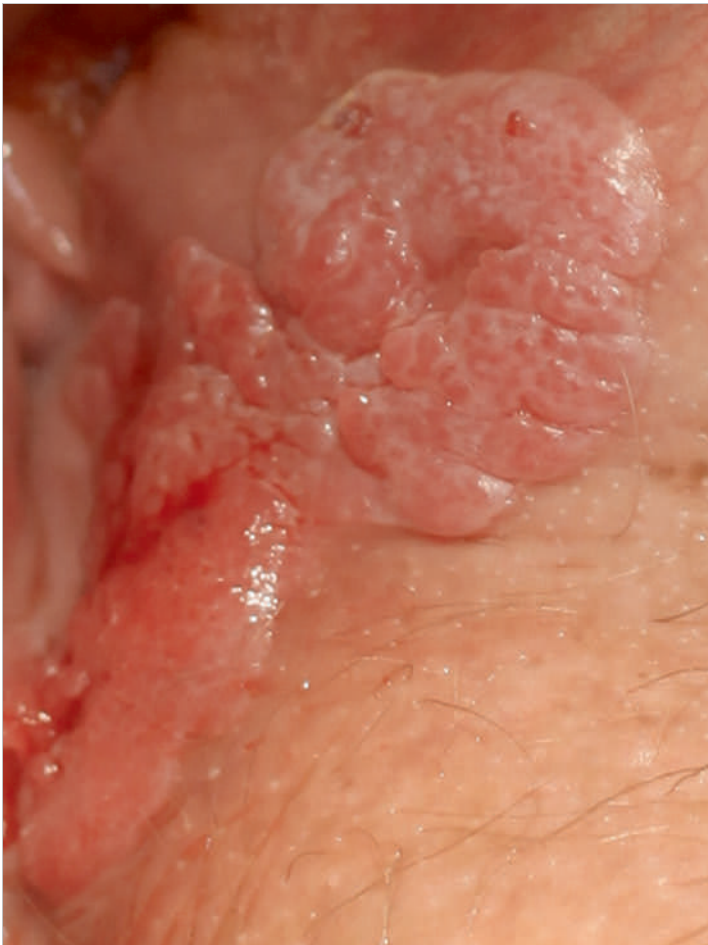

Fig. 13.16 Sharp borders of a FIGO stage I HPV 16 positive squamous cell vulvar cancer.

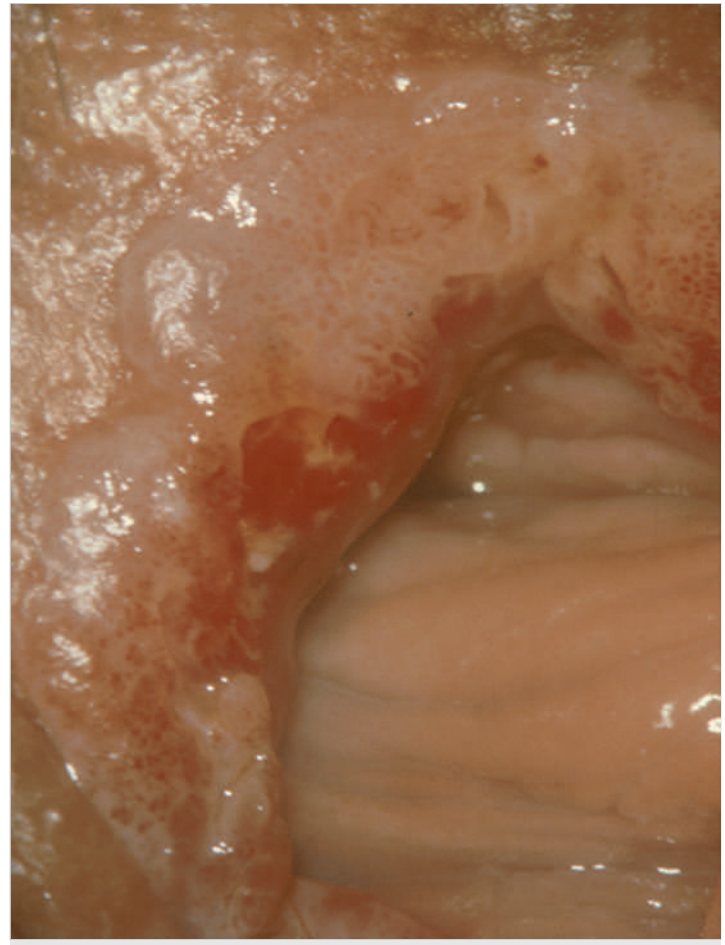


Fig. 13.17 Fragile atypical vessels in an exophytic, well-demarcated FIGO stage II squamous cell vulvar cancer.

height can be seen in hyperplastic epidermis as well as in all types of SIL. High and thin stromal papillae in papillary low-grade SIL (LSIL) are especially well seen. Papillomatous HGSIL often show marked but irregular stromal papillae.

Table 13.1 Secondary morphology presentation²

Type of lesion	Comment
Eczema	A group of inflammatory diseases that are clinically characterized by the presence of itchy, poorly marginated red plaques with minor evidence of microvesiculation and/or, more frequently, subsequent surface disruption
Lichenification	Thickening of the tissue and increased prominence of skin markings. Scale may or may not be detectable in vulvar lichenification. Lichenification may be bright-red, dusky-red, white, or skin-colored
Excoriation	Surface disruption occurring as a result of the “itch-scratch cycle”
Erosion	A shallow defect in the skin surface; absence of some, or all, of the epidermis down to the basement membrane; the dermis is intact
Fissure	A thin, linear erosion of the skin surface
Ulcer	Deeper defect; absence of the epidermis and some, or all, of the dermis

13.2.7 Biopsy

Biopsy should be performed on all suspicious lesions of the vulva, including white, gray, red, pigmented, or raised lesions and all conditions that do not resolve promptly with medical treatment. If the lesion is uniform, a single biopsy suffices. If the lesion is multifaceted, two or more biopsies should be obtained. In ulcerative lesions, a biopsy at the periphery can avoid non-representative necrosis.

Biopsies can be performed quickly and simply with local anesthesia (lidocaine with or without adrenaline or topical lidocaine cream) on an outpatient basis using just a few instruments (► Fig. 13.18). The hands of the patient can help expose the lesion. A 5-mm punch biopsy perpendicular to the surface is ideal. The defect on occasion requires a fine resorbable suture for hemostasis. Ideally, anticoagulants are discontinued before biopsy.

13.2.8 Exfoliative Cytology

Cytology has poor sensitivity and specificity for the detection of SIL. Liquid-based cytology may provide better results than conventional cytology, especially at the mucosal side of the vulva. Cytology is inadequate in the detection of dVIN, Paget disease, and melanoma in situ.

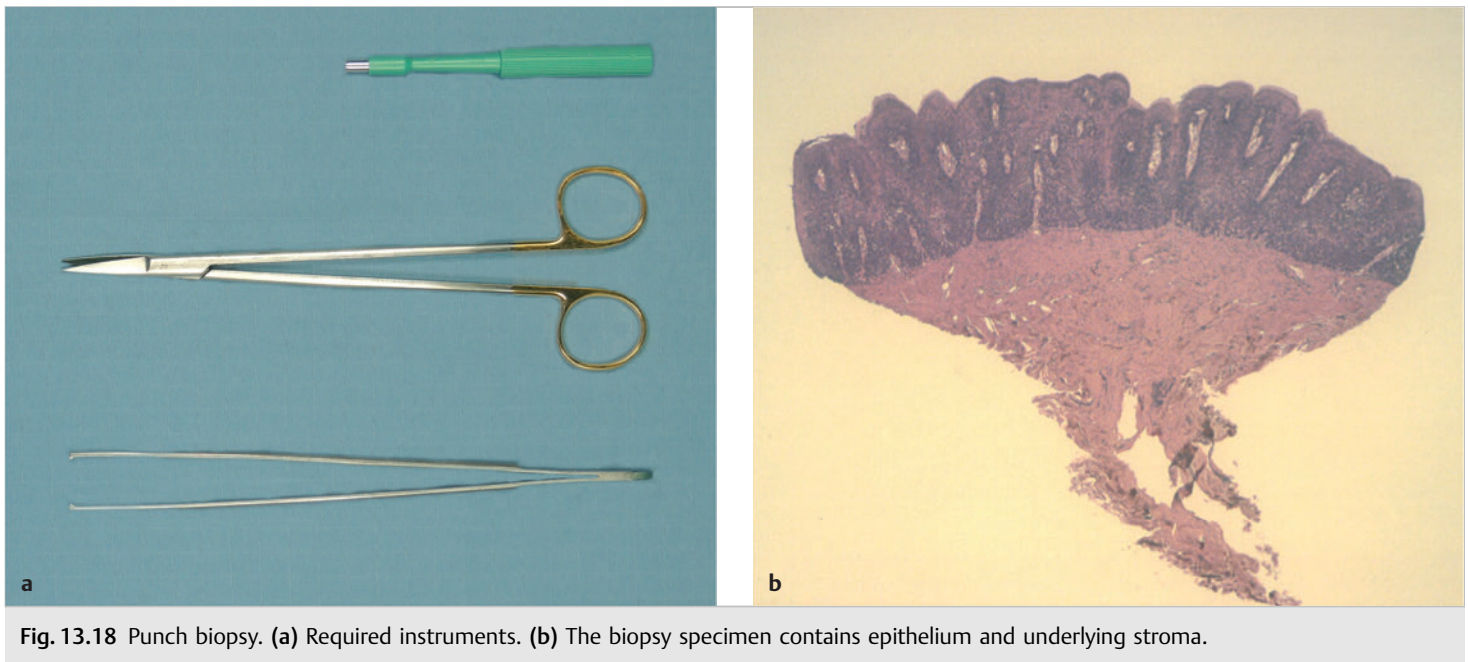


Fig. 13.18 Punch biopsy. (a) Required instruments. (b) The biopsy specimen contains epithelium and underlying stroma.

13.2.9 HPV Testing

HPV testing permits differentiation between low-risk and high-risk infections as well as between (pre)neoplastic conditions associated with HPV and lesions not associated with HPV. HPV testing is also important to define the risk of progression in LSIL because LSIL containing low-risk HPV is histologically indistinguishable from LSIL containing high-risk HPV. HPV testing has a role in the follow-up of patients after treatment for HPV-positive lesions (► Fig. 13.19, ► Fig. 13.20).

13.3 Vulvar Carcinogenesis

Two distinct pathways, one HPV-associated and one HPV-independent, are involved in vulvar carcinogenesis (► Table 13.2).⁴ Typically, HPV-associated carcinogenesis results in warty or basaloid-type SCC via SIL, whereas HPV-independent carcinogenesis results in keratinizing-type SCC, via dVIN. However, there is some overlap between the histologic types and the association with HPV. Some HPV-positive vulvar SCCs are keratinizing, and a few HPV-negative vulvar SCCs show basaloid or warty features.

Vulvar cancers develop over a variable period of time. Typically, HPV-associated vulvar SCCs occur in relatively young women, whereas HPV-negative cancers are commonly found in older patients.⁵ Although HPV-associated SCCs of the head and neck region have a better prognosis than HPV-independent SCCs, it is unclear whether this is true for vulvar cancers (for review see Del Pino et al⁴).

13.3.1 HPV-Dependent Carcinogenesis

HPV-associated SCC of the vulva develops through SIL triggered by transforming infection with high-risk HPVs, predominantly HPV 16 (► Fig. 13.21). The rate of HSIL associated with HPV 16 suggests that the epithelium of the vulva may inhibit the progression of other high-risk HPV types; in contrast, in vaginal mucosa and cervical mucosa, there is greater heterogeneity of HPV

types.⁶ The entry of HPV is most likely by way of skin abrasions (► Fig. 13.22).

SIL mostly affects younger women. The mechanisms are similar to cervical carcinogenesis: the high-risk HPV viral gene products E6 and E7 interact with host cell p53 and Rb proteins, resulting in p53 dysfunction and inactivation of Rb, respectively. Degradation and inactivation of the tumor suppressor genes *p53* and *Rb* lead

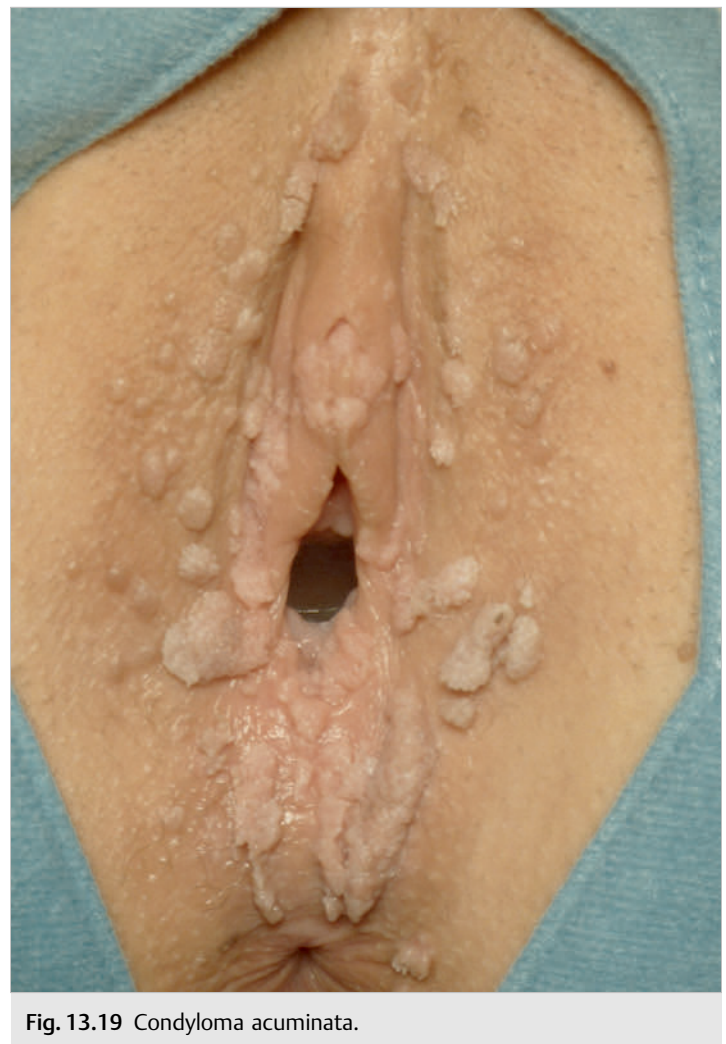

Fig. 13.19 Condyloma acuminata.

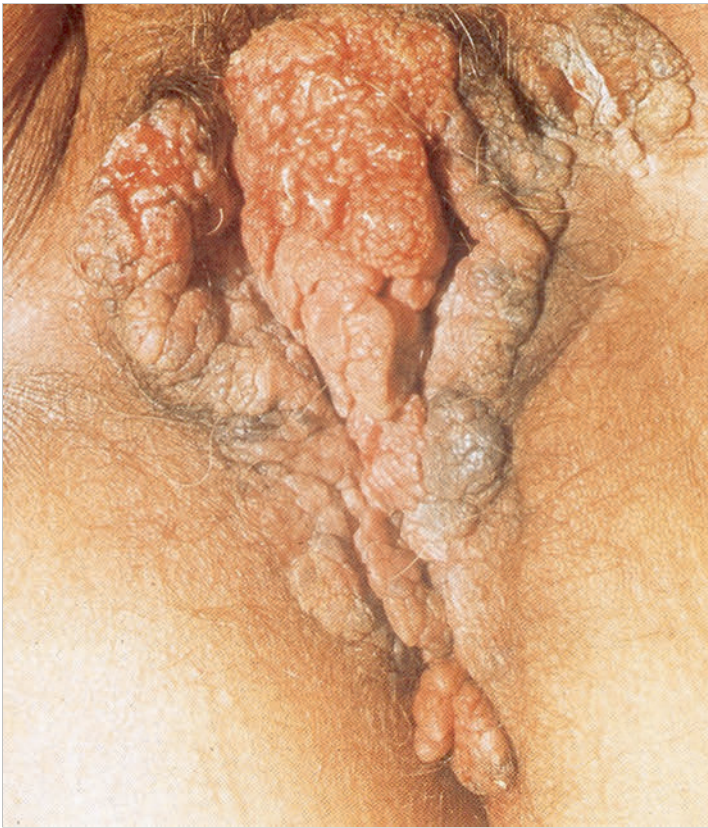

Fig. 13.20 Giant condyloma (Buschke-Löwenstein) with malignant transformation. These tumors are due to low-risk HPV types.

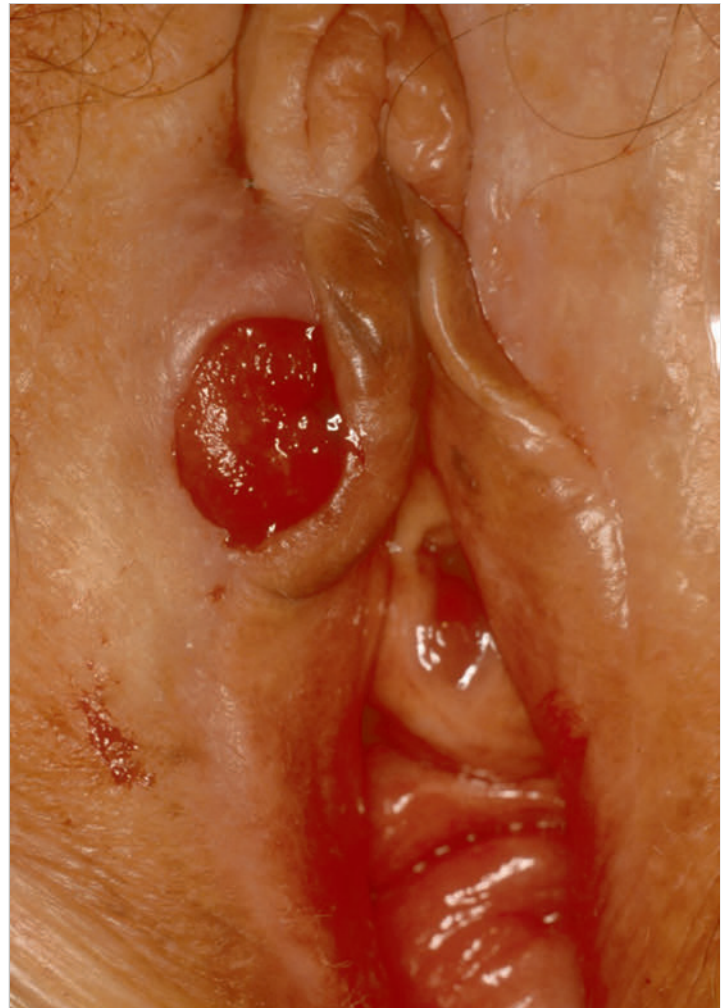


Fig. 13.21 HPV 16-positive invasive squamous cell cancer.

to absence of cell-cycle arrest and hyperproliferation of tumor cells. Frequent detection of overexpression for p16^{INK4a} in SIL suggests that degradation and inactivation of *p53* and *Rb* are early events in the carcinogenesis of HPV-associated SCC of the vulva.⁷ Both HPV-associated vulvar SCC and adjacent HSIL are monoclonal lesions that appear to develop from a single transformed cell.^{4,7}

Table 13.2 Characteristics of the two types of squamous cell carcinoma (SCC) of the vulva

	HPV-associated SCC	HPV-negative SCC
Etiology	Transforming HPV infection, predominantly HPV 16	Long-standing lichen sclerosus or lichen planus
Frequency	40%	60%
Age at diagnosis	Younger	Older
Precursor lesions	SIL	dVIN
Possible molecular pathogenesis	High-risk HPV infection; viral E6/E7 expression, inactivation of p53 and retinoblastoma gene, genetic instability, DNA aneuploidy	Immudysregulation, mutation of p53/PTEN, allelic imbalance, microsatellite instability, DNA aneuploidy
Progression time	Slower	Faster
Prognosis	Better (?)	Worse (?)
Prevention	HPV vaccination	Treatment of underlying dermatosis (?)

Abbreviations: HPV, human papillomavirus; HR, high risk; PTEN, phosphatase and tensin homolog; dVIN, vulvar intraepithelial neoplasia, differentiated type.

13.3.2 HPV-Independent Carcinogenesis

Most SCCs of the vulva develop independently of HPV infection in older women through dVIN. A background of lichen sclerosus or lichen planus is common^{4,5} (► Fig. 13.23, ► Fig. 13.24, ► Fig. 13.25, ► Fig. 13.26).

The mechanism of HPV-independent carcinogenesis is not fully clear. Genetic mutations in *p53* or *PTEN* have been detected in HPV-negative vulvar SCC as well as in dVIN, suggesting that these are early changes in the HPV-independent pathway.^{8,9,10,11} A strong correlation between high *p53* expression and DNA aneuploidy has been reported,¹² but not all HPV-independent vulvar SCCs follow the *p53* pathway, and the pathogenesis of these tumors is unknown.⁴

Allelic imbalance and microsatellite instability may play a role in the malignant potential of lichen sclerosus.¹³ Comparative genomic hybridization studies have shown various chromosomal alterations that might differentiate between HPV-associated and HPV-negative vulvar cancer, with HPV-positive tumors frequently showing gains of 3q and HPV-negative tumors gains of 8q.¹⁴ Most dVIN have a gain of 3p26.¹⁵ More frequent hypermethylation of *RASSF2A*, *MGMT*, and *TSP-1* genes has been found in SCC associated with lichen sclerosus than in SCC not associated with lichen sclerosus, suggesting a possible role of these genes in HPV-independent carcinogenesis.¹⁶

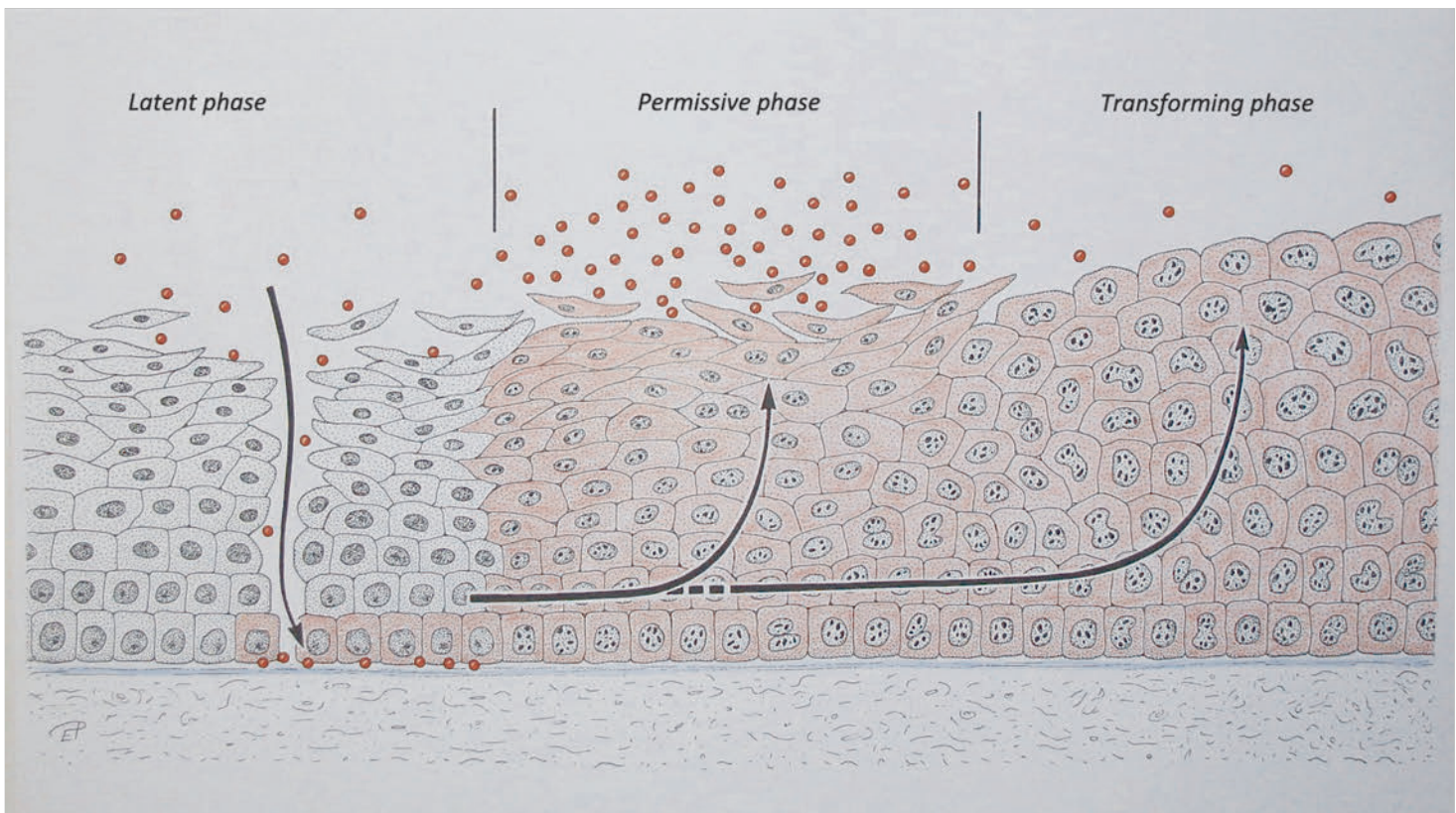


Fig. 13.22 Phases of HPV-infection. Minor lacerations of the squamous epithelium permits contact of HPV with the reserve (stem) cells of the vulva. Latent infection triggers no clinical or histomorphological changes. Permissive (productive) phase of infection can be caused by either low-risk or high-risk HPV-types. Morphological changes correspond to condylomas or LSIL. Transforming infections of the vulva are most associated with HPV 16 and are characterized by a substantial shift of the viral gene expression profile, particularly in the basal cells. These lesions are referred to as HSIL.

It is unknown whether medical treatment of lichen sclerosus or lichen planus can prevent the development of dVIN and malignant transformation.

HPV-negative dVIN cannot always be attributed to lichen sclerosus or lichen planus. Also, HPV-positive SIL is sometimes seen with lichen sclerosus or lichen planus (► Fig. 13.27). It is not clear whether treatment of lichen sclerosus or lichen planus with local immunosuppressive creams (corticosteroids, calcineurin inhibitors) increases the risk for HPV-associated lesions in lichen sclerosus or lichen planus.

Morbus Paget and malignant melanoma are also independent of HPV.

13.4 Preinvasive Intraepithelial Lesions

This group consists of squamous intraepithelial lesions (SIL), differentiated-type vulvar intraepithelial neoplasia (dVIN), Paget disease, and melanoma in situ.

13.4.1 Squamous Intraepithelial Lesions (SIL) and Differentiated-type Vulvar Intraepithelial Neoplasia (dVIN)

SIL is HPV-associated and is by far the most common preinvasive lesion of the vulvar epithelium in younger women. LSIL represents the clinical and morphological manifestation of a productive HPV infection and is associated with low risk of malignant

transformation. HSIL is a true precursor of vulvar cancer and typically corresponds to warty or basaloid-type-invasive disease.

SIL usually causes symptoms, mostly pain and/or pruritus. SIL can present as erythroplakia, leukoplakia, pigmented lesions, papulous lesions, or erosions. These lesions are often multifocal or multicentric, with additional lesions of the cervix, vagina, or anus.

The mean time from high-risk HPV infection to development of HSIL is about 18.5 months.¹⁷ Spontaneous regression can occur and can be related to pregnancy.^{18,19,20} Women younger than 35 years have a higher rate of regression than older women.⁴ The risk of progression from SIL to invasive vulvar cancer is about 10% in untreated women and 3.3% in treated women.^{20,21} The mean interval for the progression of untreated SIL to invasion is reported to be 4 years, with almost all reported cases within 8 years.^{20,22}

Differentiated-type VIN (dVIN) is HPV-negative and typically seen in older women with long-standing and advanced lichen sclerosus or lichen planus. dVIN typically corresponds to keratinizing-type invasive disease. dVIN is by definition well differentiated and is not graded. *Differentiated* refers to the mature appearance of the epithelium, not to the grade of the lesion.

The clinical diagnosis of dVIN is difficult. Symptoms are due to associated vulvar dermatoses. Leukoplakia with a rough and irregular surface, non-healing erosions unresponsive to topical corticosteroids, or erythroplakia are suspicious and should be biopsied. Typically, lesions of dVIN do not change in appearance after application of acetic acid.

The rate of patients with lichen sclerosus or lichen planus who develop dVIN and the mean time from the manifestation of lichen sclerosus or lichen planus to dVIN is unclear. dVIN is considered more aggressive and associated with a higher and faster

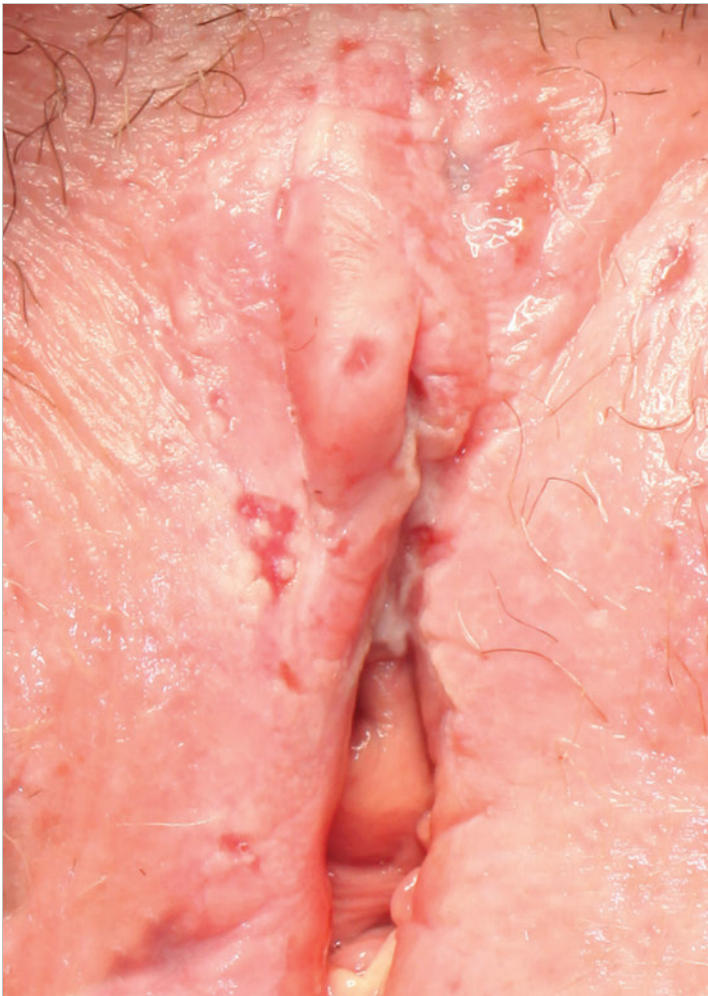

Fig. 13.23 Advanced lichen sclerosus suspicious for dVIN. Leukoplakia shows a rough and irregular surface and non-healing erosions unresponsive to topical corticosteroids.

rate of progression to invasive carcinoma than SIL.^{4,5} The overall percentage of dVIN with subsequent SCC is estimated at about 33%, and the median time for progression from dVIN to SCC is about 23 months.^{5,22,23} Vulvar SCC occurring on a background of dVIN appears more likely to recur.^{15,24,25}

Histologic Terminology and Classification

The history of the terminologies for vulvar lesions can be confusing, because different specialties are involved in caring for these women. In 1965, Kaufman and Gardner grouped premalignant

Table 13.3 ISSVD, WHO 2003 and WHO 2014, and LAST histologic terminologies for squamous vulva precursor lesions

ISSVD 2004 ²⁸	WHO 2003	WHO 2014 ³²
Condyloma	VIN 1 (mild dysplasia)	LSIL
VIN, usual type (wart, basaloid, mixed)	VIN 2 (moderate dysplasia)	HSIL
VIN, usual type (wart, basaloid, mixed)	VIN 3 (severe dysplasia, CIS)	HSIL
VIN, differentiated type	VIN, simplex type, CIS	HSIL

Abbreviations: CIS, carcinoma in situ; HSIL, high-grade intraepithelial neoplasia; ISSVD, International Society for the Study of Vulvovaginal Disease; LAST, Lower Anogenital Squamous Terminology project; LSIL, low-grade intraepithelial neoplasia; VIN, vulvar intraepithelial neoplasia; WHO, World Health Organization

lesions of the vulva into three groups: *Queyrat erythroplasia*, *bowenoid carcinoma in situ*, and *carcinoma simplex*.²⁶ The 1976 International Society for the Study of Vulvovaginal Disease (ISVVD) terminology replaced these terms with *vulvar atypia* and *carcinoma in situ*. In 1986, these terms were in turn replaced by vulvar intraepithelial neoplasia (VIN) with mild dysplasia (VIN 1), moderate dysplasia (VIN 2), and severe dysplasia (VIN 3).²⁷

In 2004, the ISVVD introduced the two-tiered classification with HPV-positive, usual type-VIN, including warty and basaloid variants, and HPV-negative dVIN.²⁸ The term *VIN 1* was abolished. Flat lesions associated with basal atypia and koilocytic changes are considered *condylomas*. The term VIN was applied only to high-grade lesions or dVIN. This system was based on the observation that there was no evidence that the morphologic spectrums of VIN 1, 2, and 3 reflect a biologic continuum or that VIN 1 was a cancer precursor. Besides modifying the classification of VIN, the ISVVD also modified the grading system and proposed a Bethesda-like grading system of low-grade vulvar intraepithelial lesions (LG-VILs) and high-grade vulvar intraepithelial lesions (HG-VILs).²⁹

In 2012, the Lower Anogenital Squamous Terminology (LAST) project recommended a uniform, two-tiered terminology for HPV-associated squamous disease across all anogenital tract tissues (LSIL and HSIL).^{30,31}

Accordingly, the current (2014) WHO classification³² distinguishes low-grade squamous intraepithelial lesions (LSIL) and high-grade squamous intraepithelial lesions (HSIL), both of which are HPV associated. LSILs include what was formerly known as

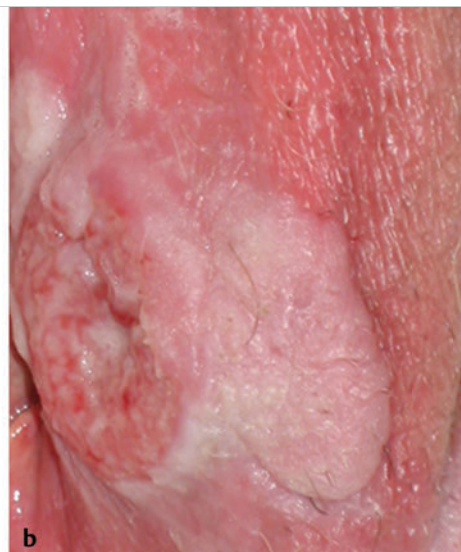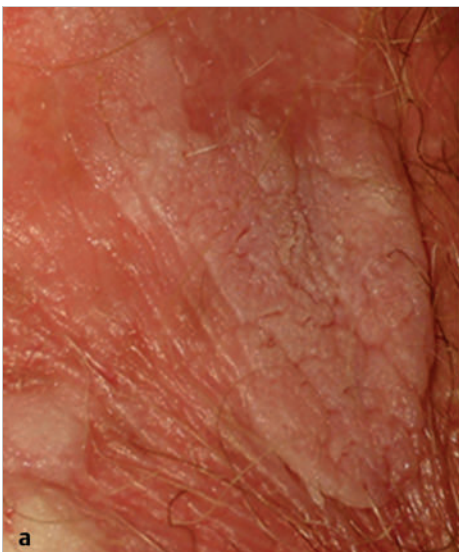


Fig. 13.24 Advanced lichen planus. (a) Leukoplakia with a rough and irregular surface, unresponsive to topical corticosteroids. Histology showed dVIN (b) followed by HPV-negative invasive cancer 6 months later.

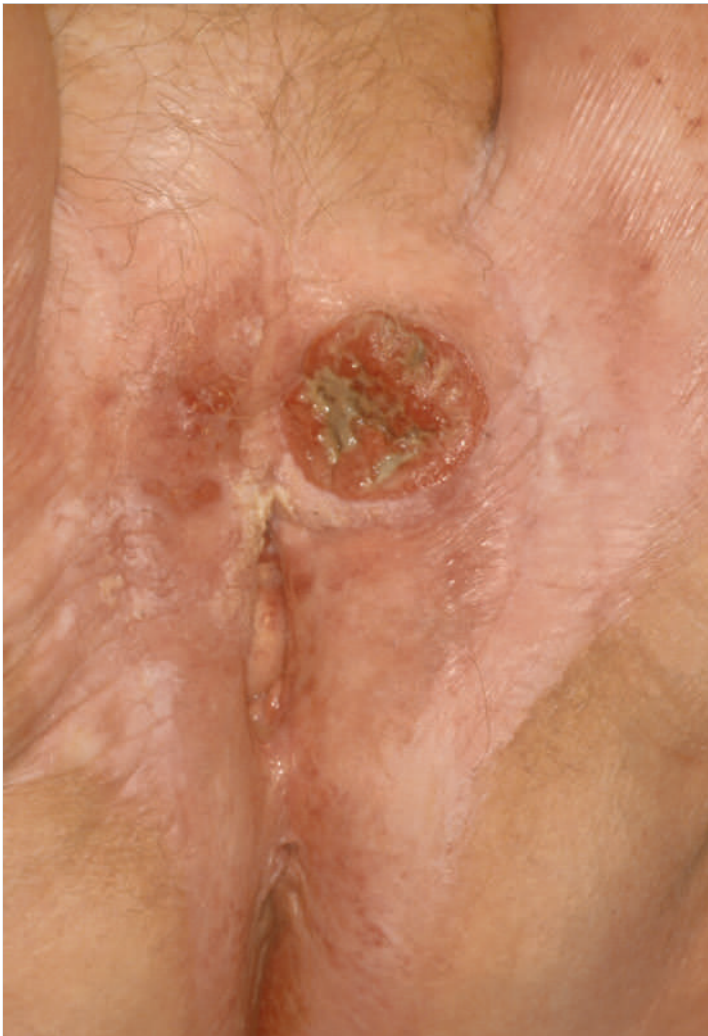

Fig. 13.25 Invasive HPV negative squamous cell cancer in a background of advanced lichen sclerosus.

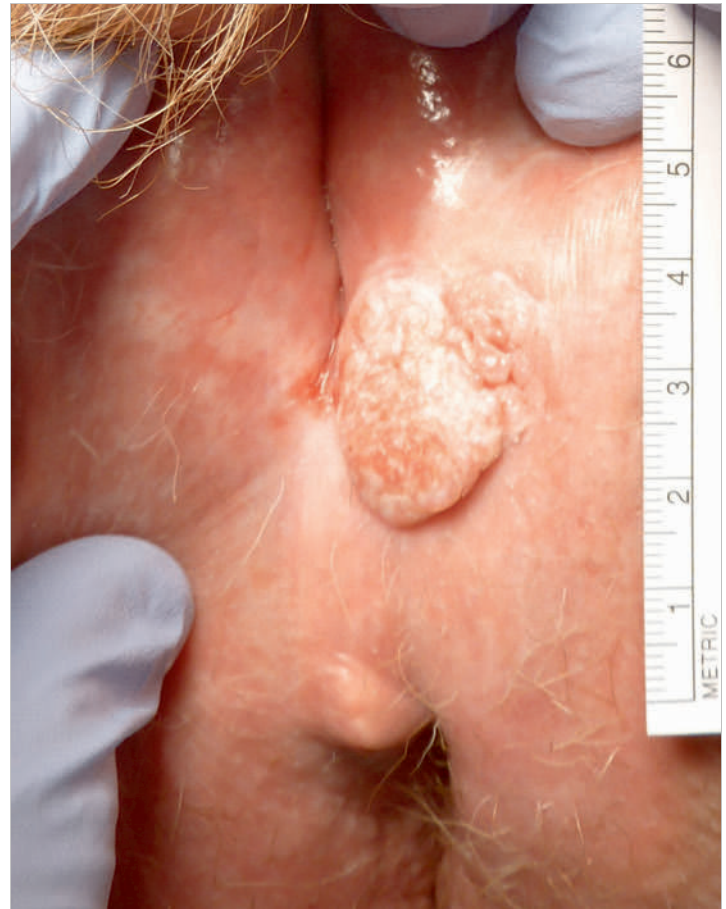

Fig. 13.26 Invasive squamous cell cancer in a background of advanced lichen planus.

VIN 1 (mild squamous dysplasia, flat condyloma, koilocytotic atypia, koilocytosis); HSILs include what was formerly known as usual type VIN 2, VIN 3 (moderate squamous dysplasia, severe squamous dysplasia). Differentiated type vulvar intraepithelial neoplasia (dVIN) is not associated with HPV infection.

Histology of SIL and dVIN

- LSIL: An HPV-positive squamous intraepithelial lesion in which nuclear abnormalities are confined to the lowest one-third of the epithelium. Most SIL are negative for p16^{INK4a}.
- HSIL (formerly VIN 2): An HPV-positive squamous intraepithelial lesion in which nuclear abnormalities are confined to the lower two-thirds of the epithelium.

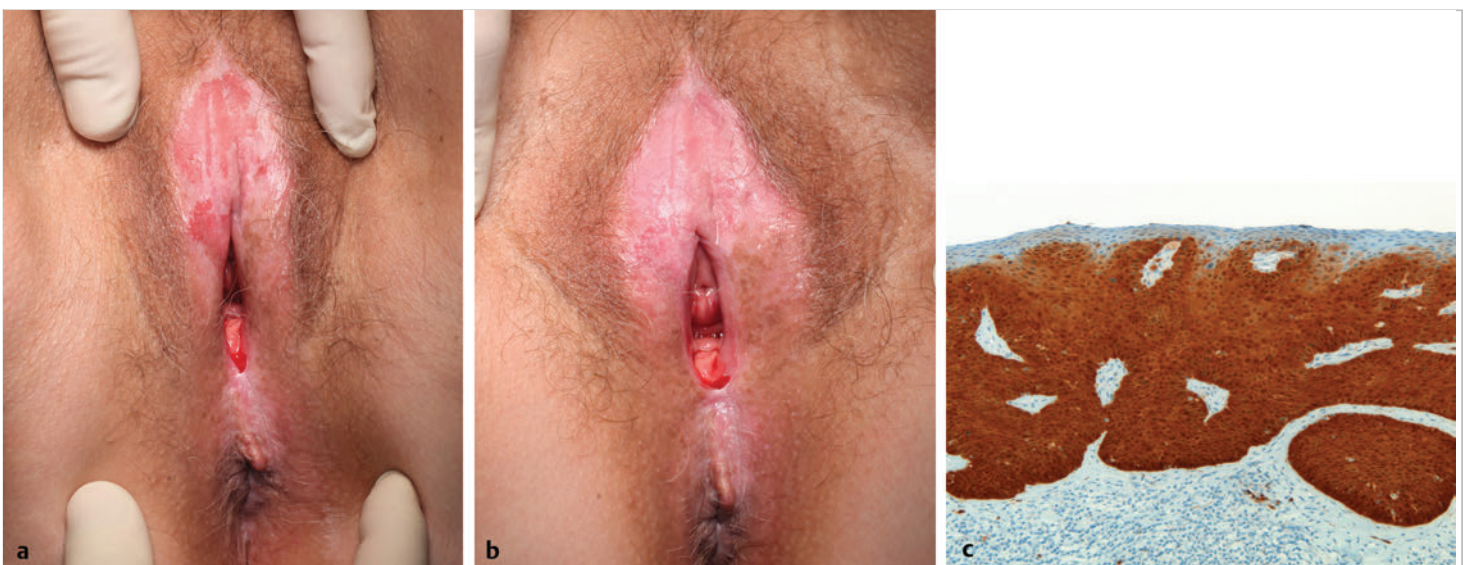


Fig. 13.27 Advanced lichen planus suspicious for HPV-positive vulvar precancer. (a) Note the erythroplakia and leukoplakia. (b) The appearance is changed after application of acetic acid. (c) Histology of the acetowhite epithelium shows p16^{INK4a} positive HSIL, positive for HPV 16.

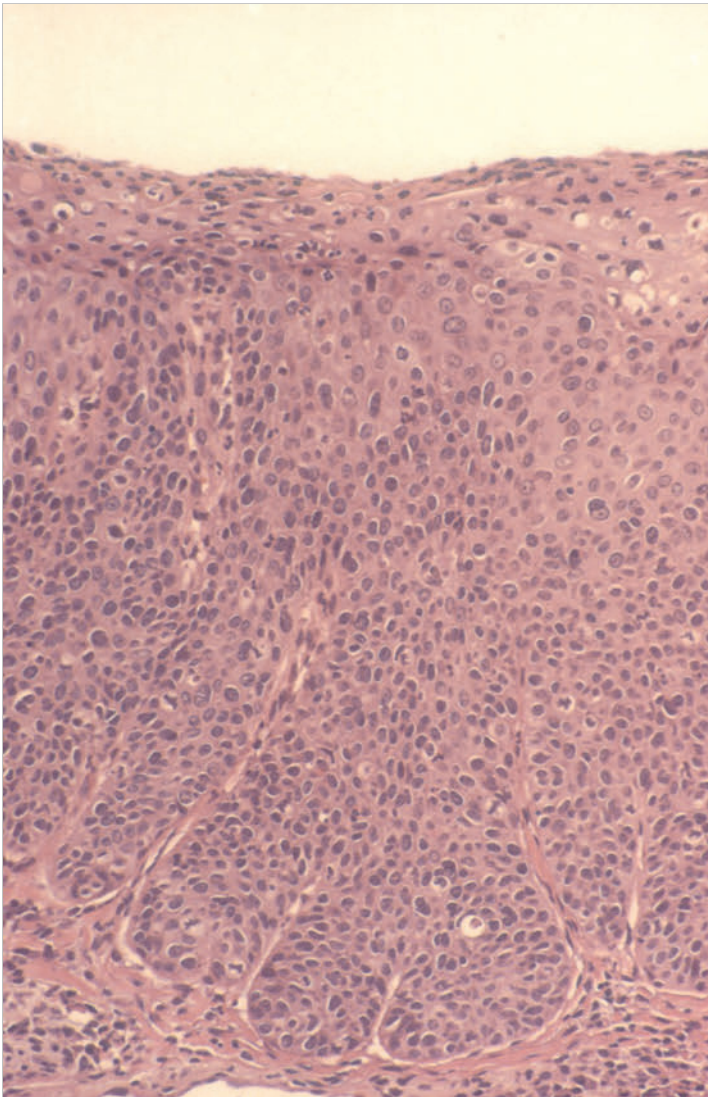


Fig. 13.28 Basaloid SIL with a flat surface. This variant of SIL has smaller cells with less cellular pleomorphism than warty VIN.

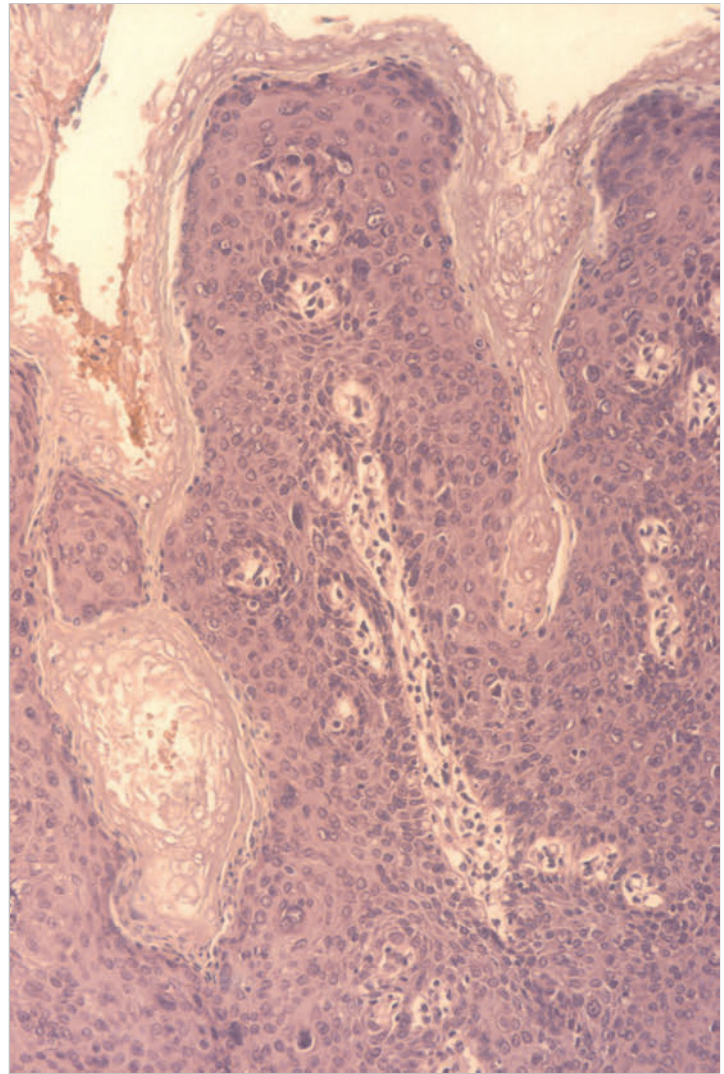


Fig. 13.29 Warty (condylomatous) SIL with a spiked, hyperkeratotic surface, nuclear pleomorphism, and multinucleated epithelial giant cells.

- HSIL (formerly VIN 3 usual type): An HPV -positive squamous intraepithelial lesion in which nuclear abnormalities extend into the upper third of the epithelium or involve the full thickness of the epithelium.
- HSIL has two histomorphologic variants: basaloid and warty. A mixture of both variants can occur.

Basaloid variant: This is a type of HSIL consisting exclusively of relatively uniform, small, and atypical cells that resemble the normal cells of the basal cell layer. They occupy almost the entire thickness of the epithelium. The most superficial layers can show signs of parakeratosis. Mitotic figures are seen in the entire epithelium except for the superficial layer (► Fig. 13.28). Like warty-type HSIL, basaloid-type SIL stains strongly for p16^{INK4a} and is negative for p53.⁴

Warty variant: This is a type of HSIL that no longer shows the regularity of the basaloid type. The cell density is still high, but the cellular uniformity has given way to a more marked anisomorphy and anisokaryosis. Giant nuclei are present. The mitotic rate is high. Marked papillae are common, hence the term *warty*. Hyperkeratosis and parakeratosis is common (► Fig. 13.29). Warty-type HSIL stains strongly for p16^{INK4a} and is negative for p53.⁴

dVIN is HPV negative and is not graded. The lower portion of the epithelium is replaced by a lesion resembling a grade 1

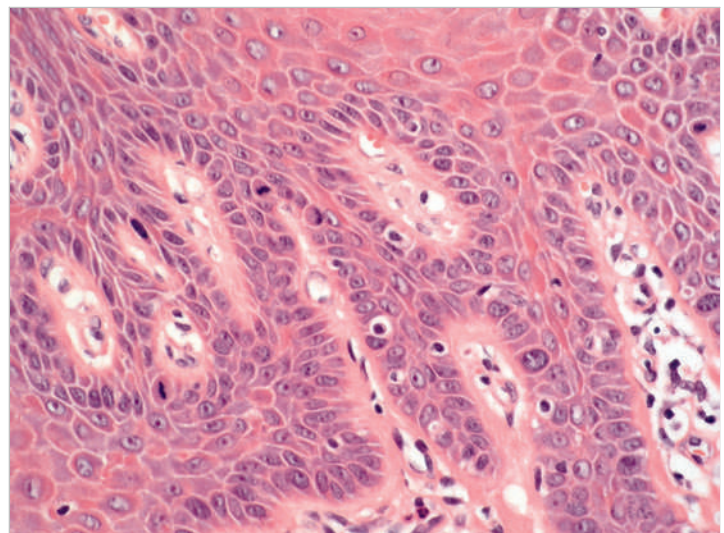


Fig. 13.30 dVIN with abnormal keratinocytes and mitoses confined to the basal and parabasal layers. The rest of the epithelium shows normal maturation (courtesy S. Regauer)²⁵.

squamous cell carcinoma (► Fig. 13.29, ► Fig. 13.30, ► Fig. 13.31). Abnormal keratinocytes are generally confined to the basal and parabasal layers, whereas the rest of the epithelium shows normal maturation. Rete ridges are typically elongated and are

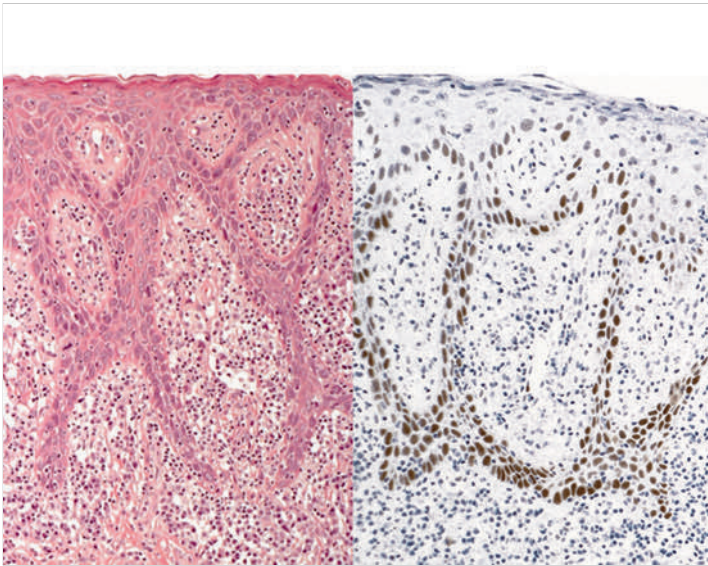


Fig. 13.31 dVIN (a) with typically elongated and branched rete ridges and (b) positive immunohistochemical staining for p53 (right) (courtesy S. Regauer).²⁵

frequently branched. Intercellular bridges are prominent. dVIN usually stains for p53, with p53-positive cells extending above the basal layers into higher levels of the epidermis, but not for p16^{INK4a}.⁴ In contrast to normal vulvar epithelium, which shows an almost completely Ki-67-negative basal layer, the basal layer

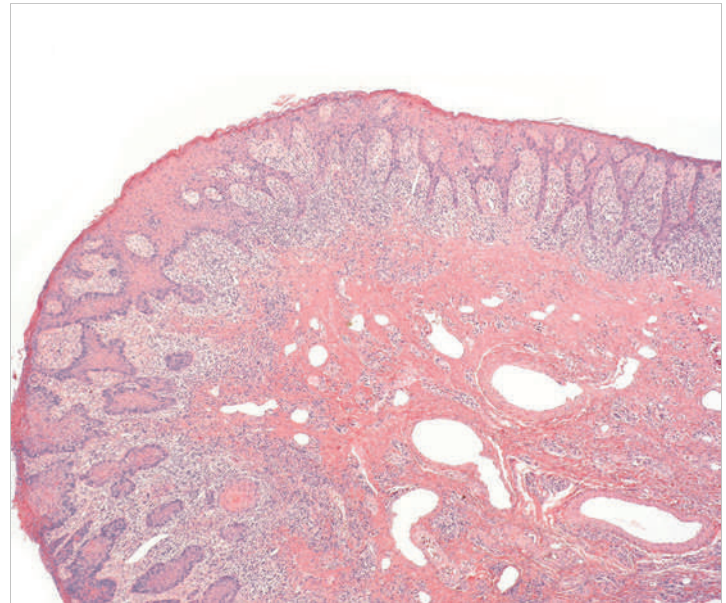


Fig. 13.32 dVIN with elongated and branched rete ridges (right) and transition to early invasive squamous cell cancer (left) (courtesy S. Regauer).²⁵

of dVIN is positive for Ki-67. A small subset of dVIN shows basalioid morphology³³ and requires biomarkers to distinguish it from SIL. VIN-pagetoid type is a rare subtype of VIN resembling Paget disease or superficial spreading melanoma.³⁴

Management of SIL and dVIN

HSIL requires treatment, whereas LSIL can be managed expectantly. However, 30 to 42% of cases of LSIL contain high-risk HPV types and thus have the potential to progress to HSIL or invasive cancer.^{35,36} Treatment plans are based on colposcopy and biopsy results. Treatment of HSIL has become individualized, including different surgical modalities and medical options.

Surgical Therapy of SIL

Surgical therapy consists of ablation (► Fig. 13.33) or excision (► Fig. 13.34). Excision was long considered the standard of care for unifocal lesions but is more difficult for multifocal disease, which can affect large areas of the vulva. The aim is to remove all visible areas of HSIL with a 3- to 5-mm margin of normal-appearing skin.²¹ Skinning vulvectomy is considered on occasion for women with recurrent or confluent multifocal lesions. In general, more extensive surgery is associated with a greater impairment of quality of life and sexual function^{37,38,39} (► Fig. 13.35).

Excisions are associated with positive margins in up to 66% of cases,^{40,41} and recurrences are common. An increased risk of recurrence has been reported in multifocal SIL compared with unifocal lesions.^{20,42} Recurrences have been reported in up to 19% of cases after vulvectomy,^{21,43} 15 to 17% after local excision with negative margins, and 46 to 50% after local excision with positive margins.^{20,21,40,43}

Ablation is generally performed with a CO₂ laser and can result in very satisfactory results. There should be no evidence of invasion on the basis of clinical examination, colposcopy, and biopsy. As with excision, a 3- to 5-mm margin of normal-appearing skin should be treated. Occult invasive cancer (mostly with < 1 mm

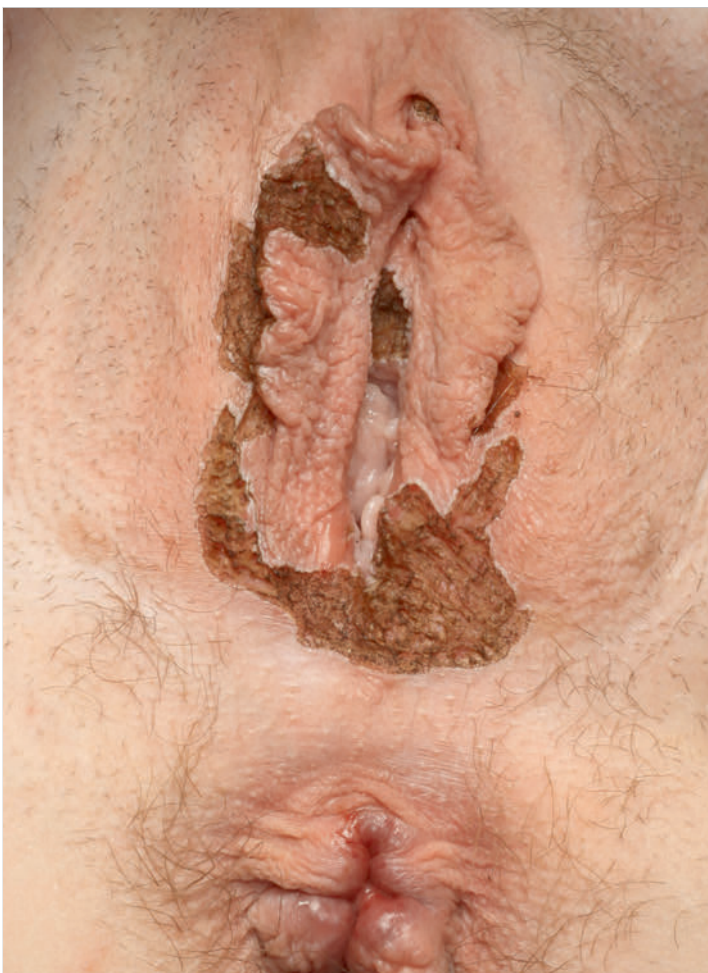

Fig. 13.33 Laser ablation of multifocal HSIL.

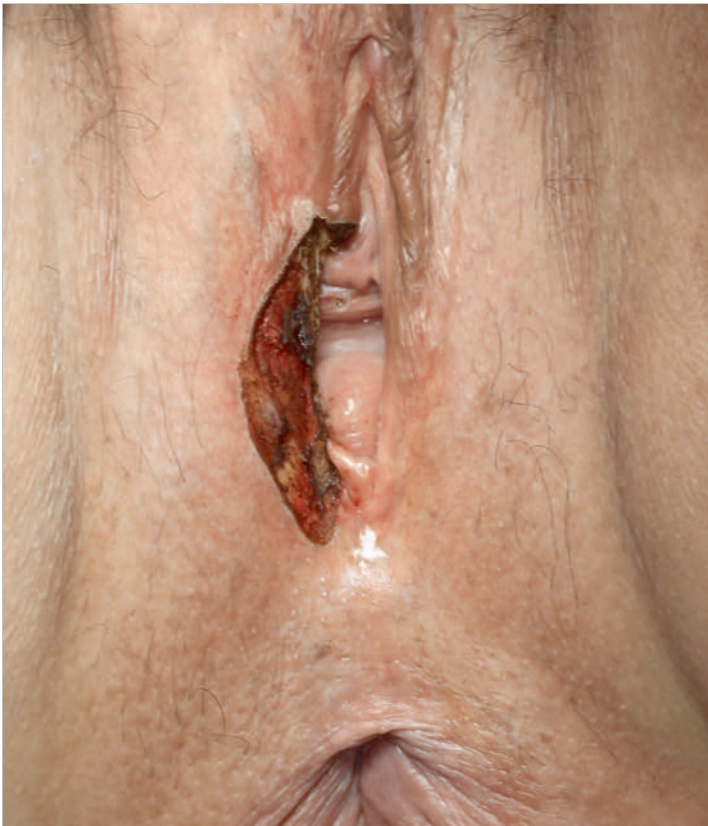

Fig. 13.34 Excision of unifocal HSIL.

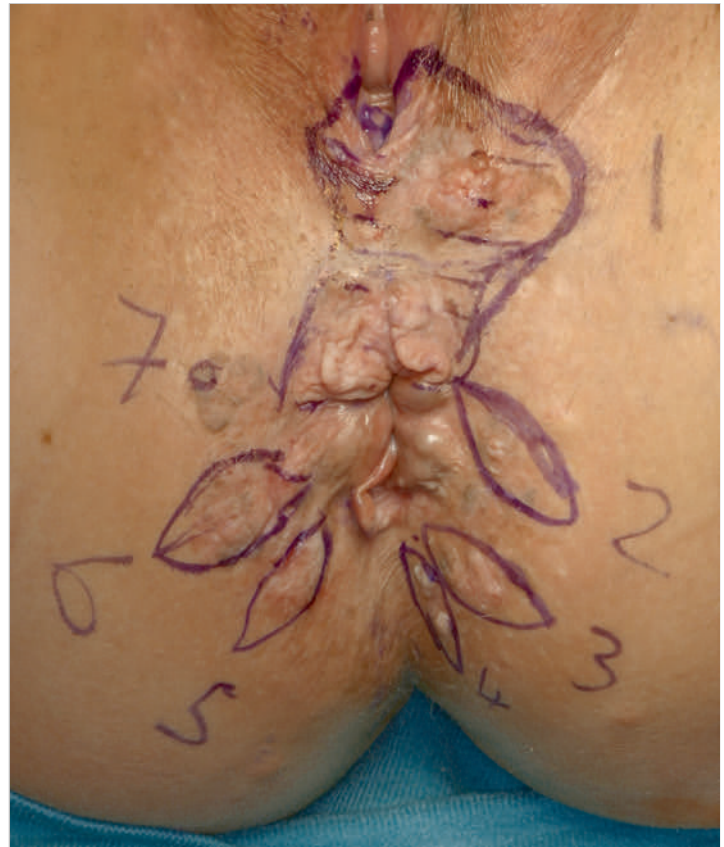

Fig. 13.35 Multifocal HSIL affecting large areas of the vulva, perineum, and perianum.

invasion) has been reported in 3% of women undergoing surgery for SIL²¹ (► Fig. 13.36). In contrast to genital condylomata, for which only superficial ablation is needed, laser ablation of HSIL requires destruction of cells through the entire thickness of the epithelium. In hair-bearing areas, laser ablation must include hair follicles, which can contain SIL and extend 3 mm or more into the subcutaneous fat. Consequently, it may be preferable to excise large lesions over hair-bearing areas. Ablation in non-hair-bearing skin should extend through the dermis (up to 2 mm). The wound can be left to heal by secondary intention, with good cosmetic results. The recurrence rate after laser vaporization is 23 to 40%.^{21,43}

Medical Therapy of SIL

A number of topical medical treatments have been studied for the treatment of SIL. The most widely used today are the immune response modifier imiquimod and the antiviral agent cidofovir. Both can be applied in HPV-associated lesions (SIL).

Successful use of imiquimod for SIL, with response rates from 30 to 90%, has been described in a series of clinical studies including two randomized trials^{21,44,45,46,47,48,49,50,51} (► Fig. 13.37). Imiquimod is applied two or three times a week, usually for 12 to 16 weeks. In responder lesions imiquimod produces a T helper 1-type inflammatory response facilitating significantly increased

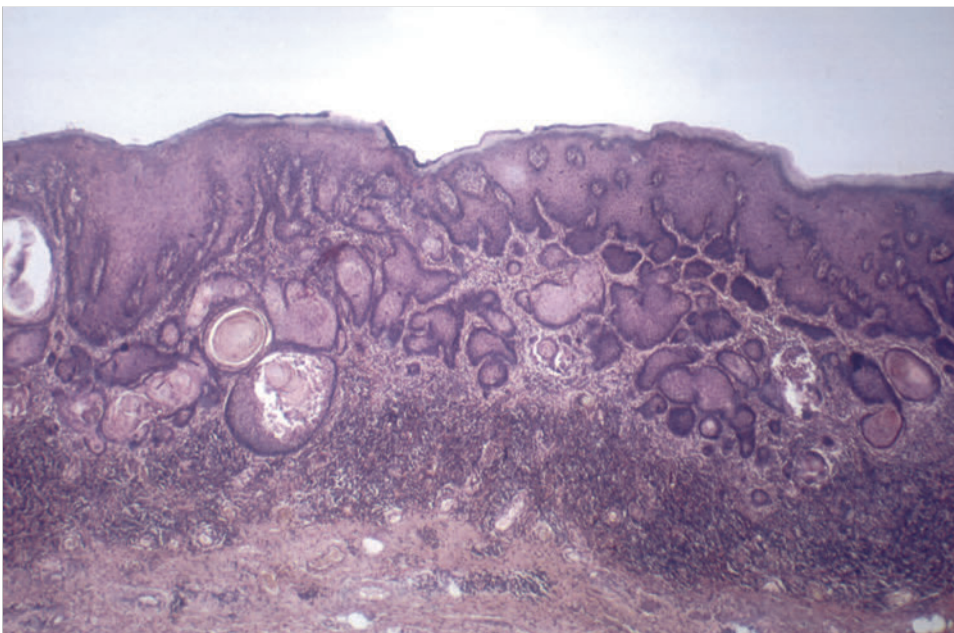


Fig. 13.36 Occult invasive cancer diagnosed histologically in an excisional specimen.

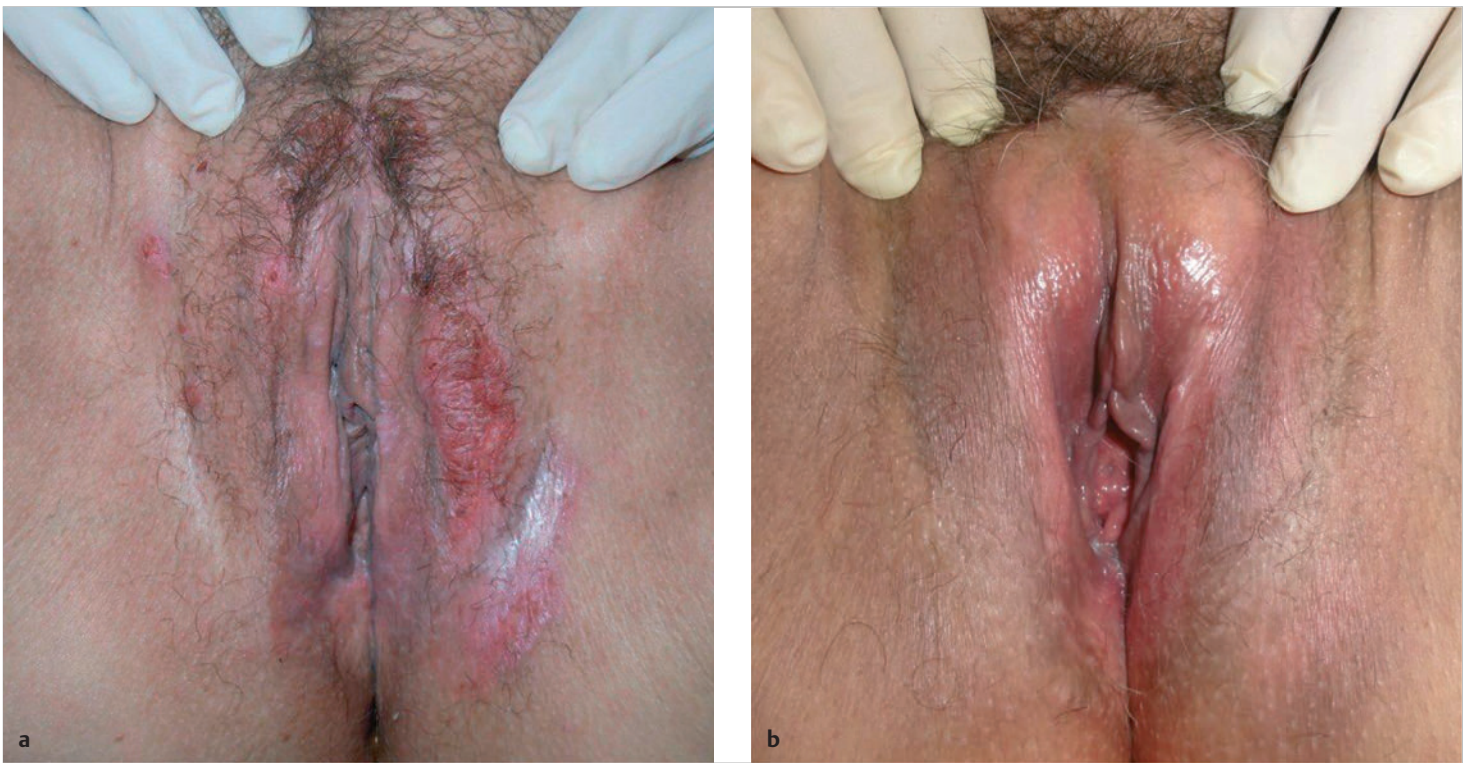

Fig. 13.37 Successful use of imiquimod. (a) SIL before therapy; (b) SIL after therapy.

local cytotoxic T-lymphocyte activity.⁴⁴ Regression of lesions is strongly associated with clearance of HPV. A 7-year follow-up showed a recurrence rate of 9%,⁴⁸ which appears lower than that observed for surgical treatments. Advantages of treatment with imiquimod include enhanced clearance of HPV, self-application, and avoidance of surgery. Drawbacks of imiquimod are that it does not work in all patients, that lesions can progress during treatment potentially to invasive disease, and that local soreness, itching, and inflammation can be considerable.

Cidofovir is an antiviral agent that reduces HPV E6 and E7 expression and the metastatic properties of HPV-positive tumor cells.⁵² A 40% complete regression rate of SIL after topical application of cidofovir was reported in a series of 12 women.⁵³ In our experience, cidofovir causes an intensive ulcerative reaction at the site of dVIN with no effects on the healthy skin. Cidofovir is expensive and has to be specially transferred into gel form.

Photodynamic therapy of SIL has also been used.^{43,54,55} Overall regression rate is reported to be in the range of 40 to 60%.⁵⁴ The combination of photodynamic therapy with imiquimod is reported to have a 60% treatment response.⁵⁵

Medical treatments used in the past include bleomycin and trinitrochlorobenzene. Interferon and 5-fluorouracil are no longer used because of severe local side effects.⁵¹ Retinoids did not prove effective.⁵⁶

Therapeutic Vaccination

Therapeutic vaccines aim to induce or boost HPV T-cell adaptive immunity⁴⁴ and appear to have promise in small initial series.^{57,58}

Therapy of dVIN

Therapy of dVIN requires surgical treatment. There is no medical treatment for dVIN and it should not be followed expectantly.

13.4.2 Paget Disease

Paget disease of the vulva is an uncommon intraepithelial carcinoma with erythroleukoplakic appearance. Vulvar Paget disease arises from an intraepidermal pluripotent stem cell.^{59,60} Most cases occur in the epidermis and mucosa, but some invade the dermis. Paget cells can extend into the excretory duct of sweat glands and pilosebaceous units. The risk of invasion is about 1 to 2% per year.⁵ (► Fig. 13.38, ► Fig. 13.39, ► Fig. 13.40, ► Fig. 13.41)

Diagnosis

Paget disease can occur anywhere on the vulva, perineum, perianum, or inner thigh. The most common symptoms are itching

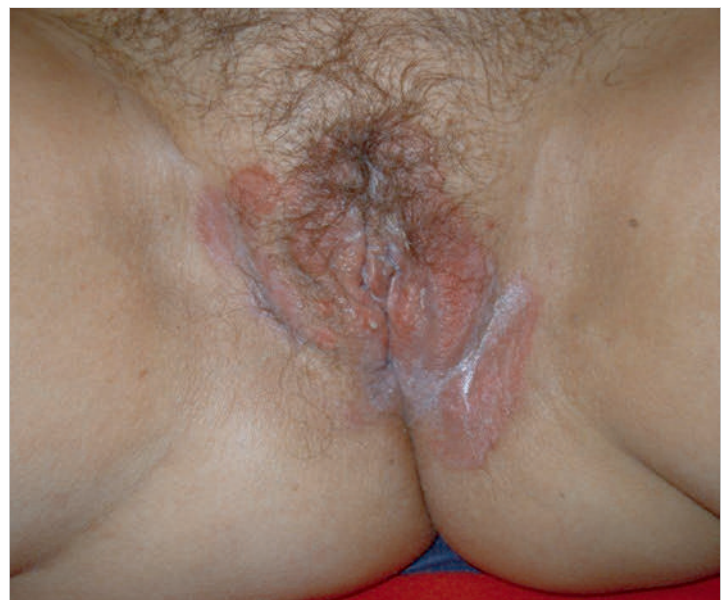

Fig. 13.38 Paget disease with an erythroleukoplakic appearance.

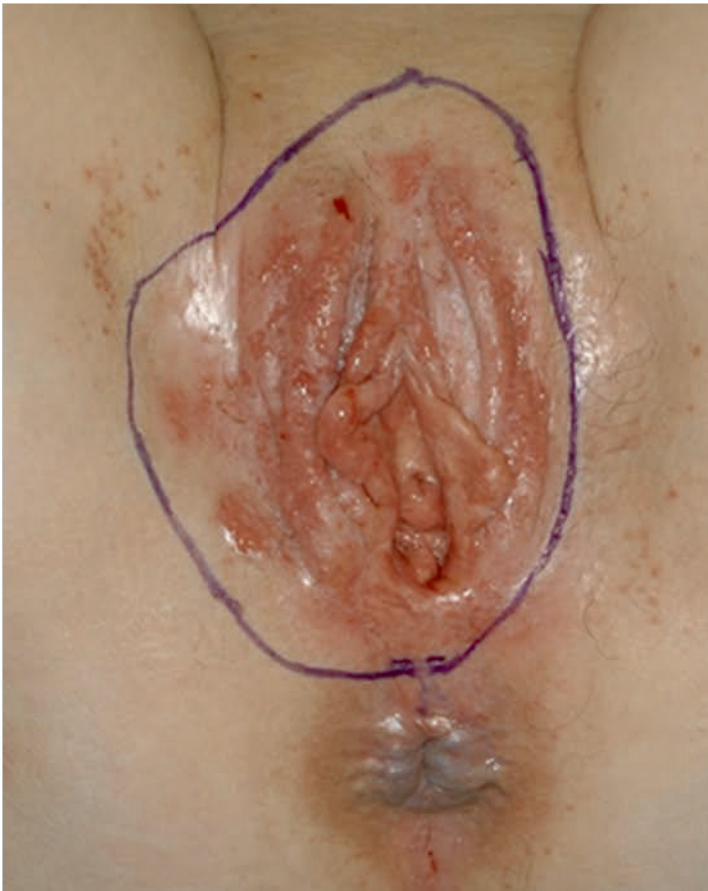

Fig. 13.39 Paget disease with an erythroplakic appearance.⁶⁸

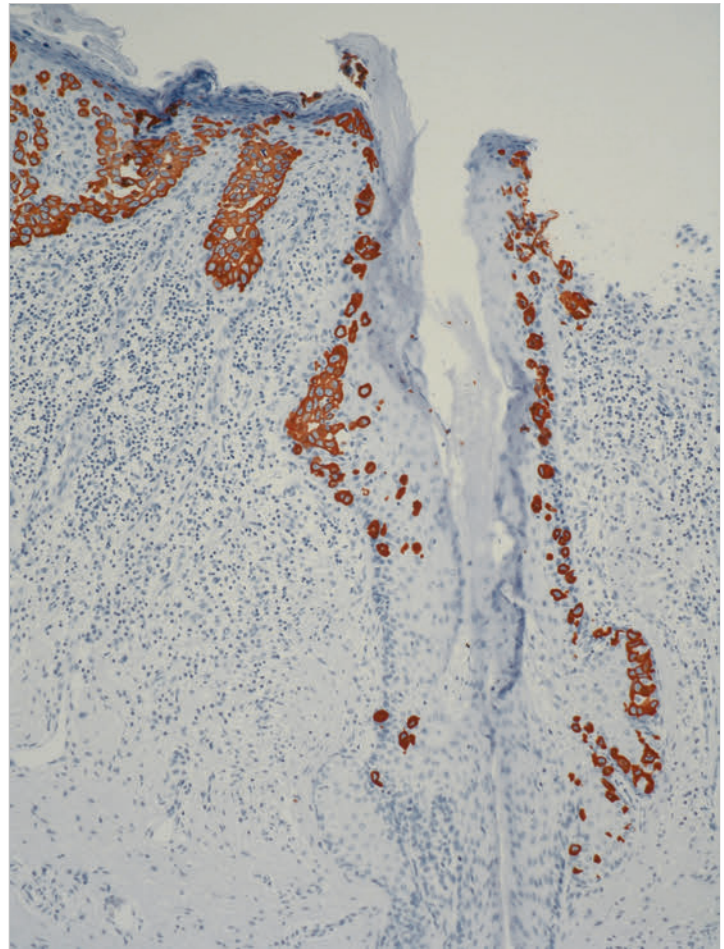


Fig. 13.40 Paget disease. Cytokeratin-7-positive Paget cells are distributed along the interfollicular epidermis, isthmus, infundibulum of a hair follicle and within a sebaceous gland (courtesy S. Regauer).

and burning. A substantial delay between appearance of symptoms and diagnosis is common, and this is associated with larger lesions. The diagnosis is made histologically after punch biopsy. Vulvar Paget disease can be a secondary manifestation of anal or urologic neoplasia. If the lesion extends to the urethral meatus urethroscopy should be performed; similarly, rectoscopy should be performed in patients with perianal lesions.^{59,61} An association of vulvar Paget disease with synchronous malignancy at other sites now seems questionable and more due to the advanced age of these patients than to a causal association.

Treatment

Treatment of vulvar Paget disease is challenging because of the nature of the disease and the anatomical and surgical limitations in this region. The extent of the disease is difficult to assess clinically and surgical margins in normal-appearing skin are frequently involved histologically. Surgical excision with a 1 cm

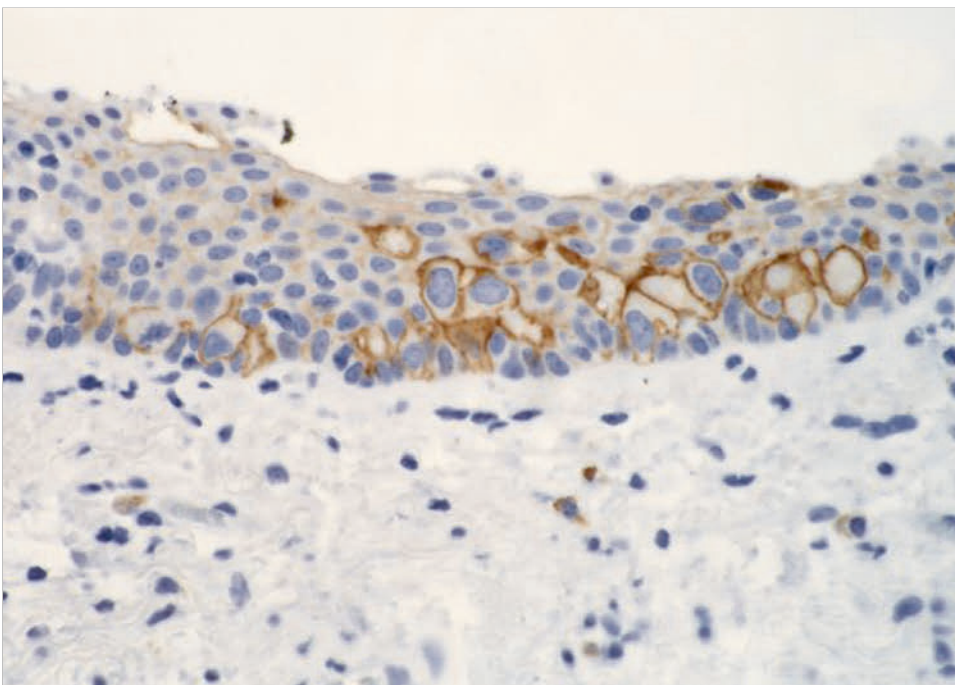


Fig. 13.41 Overexpression of p185^{Her2} in Paget disease (courtesy S. Regauer).⁶⁸

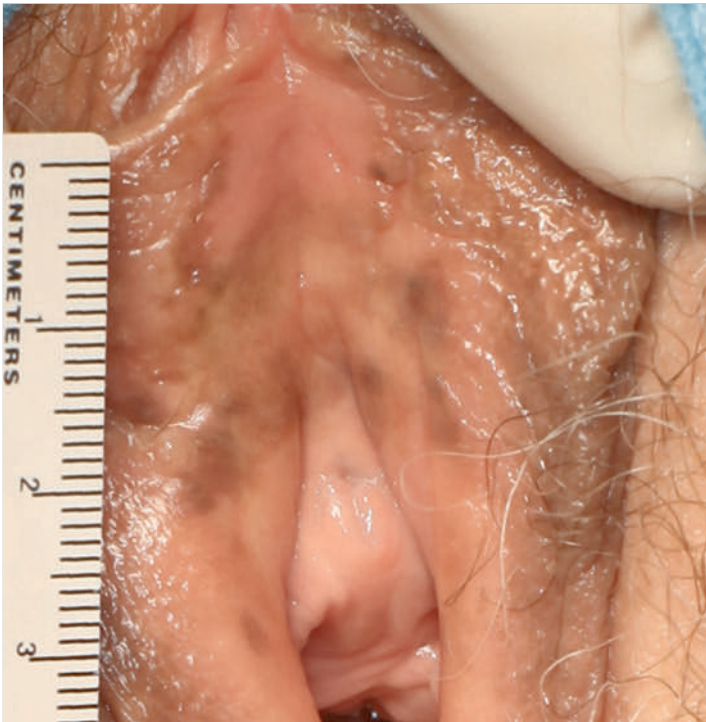

Fig. 13.42 Vulvar melanosis. The darkly pigmented macular areas have irregular borders.

margin of normal skin is the standard treatment,⁶² but associated with recurrence rates of up to 60%.^{63,64,65} In a retrospective series of 100 women with Paget disease treated at eight institutions, 34% of patients developed recurrences during a follow-up of 3 years.⁶⁵ The major problem with recurrences was extension of the disease to surrounding nongenital skin (inner thigh, perianal skin, and mons pubis), which made excision difficult. Recurrences have also been described in skin grafts from other parts of the body.⁶⁶

Imiquimod has reported to be effective for primary or recurrent vulvar Paget disease in a number of small series. Feldmeyer et al.⁶⁷ reviewed the literature on a total of 12 patients, and complete response was reported in 10.

Overexpression of p185^{Her2} and *HER2* oncogene amplification is common in primary and recurrent vulvar Paget disease, including the invasive components⁶⁸ (► Fig. 13.41). Trastuzumab has been used experimentally in this setting. The role of photodynamic and radiation therapy is unclear.

13.4.3 Intraepithelial Vulvar Melanocytic Lesions and Malignant Melanoma

Pigmented vulvar lesions require biopsy because clinical examination and colposcopy cannot distinguish between benign and malignant lesions. When sampling pigmented areas of the vulva, a biopsy should be taken of the thickest region of the lesion, or of the region with the most suspicious pattern.⁶⁹

Melanosis of the vulva (► Fig. 13.42) is a benign lesion with increased melanin content in the keratinocytes with a slight or no increase in the number of melanocytes. These lesions are non-proliferative and are typically larger than those of genital lentigo and show brown to black pigmented macular areas with irregular borders. Normal pigmented areas can be included. Melanosis of

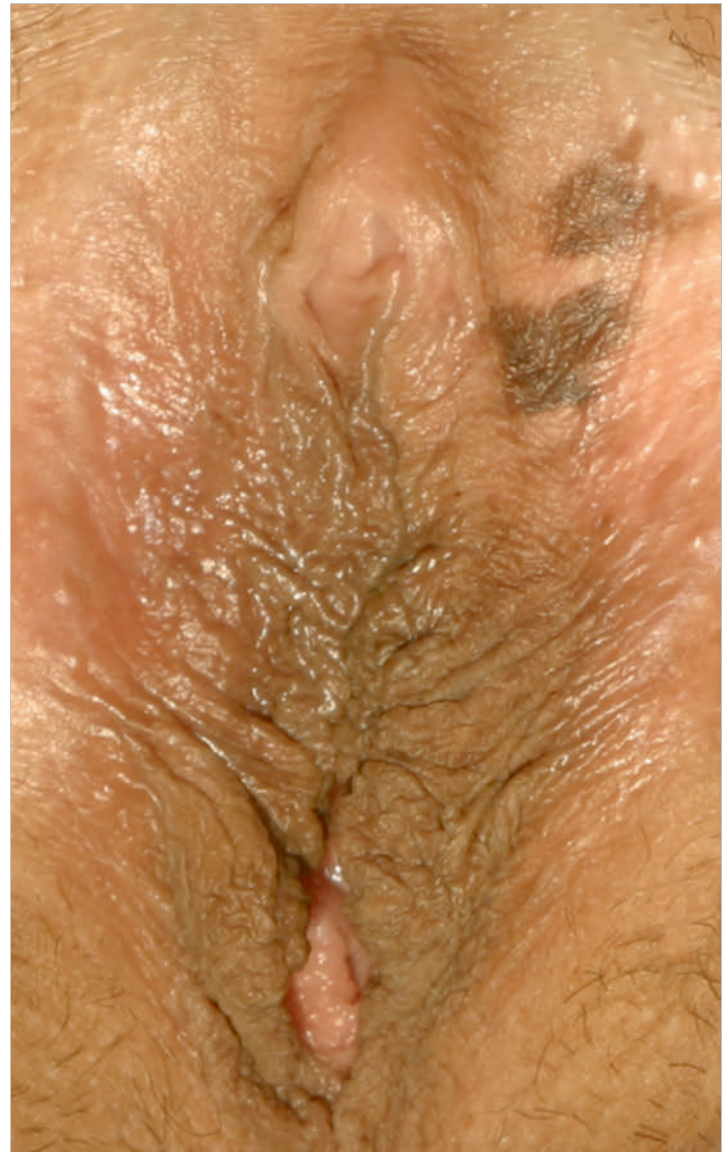

Fig. 13.43 Lentigo simplex. The figure shows two small, flat, well-demarcated, and uniformly pigmented lesions.

the vulva can consist of single or multiple areas and is more common on the labia minora and the introitus.

Genital *lentigo* (► Fig. 13.43) is a linear pattern of normal-appearing melanocytic cell proliferation within the basal layer. Thus, in contrast to melanosis, the number of melanocytes is increased. Clinically, these common benign lesions are typically small, flat, well-demarcated, and uniformly pigmented. They can occur at all sites of the vulva. Neither melanosis nor genital lentigo form papules or plaques. Definitive diagnosis is made by biopsy as melanosis and genital lentigo do not require excision or ablation.

Postinflammatory or post-traumatic pigmentation due to pigment-loaded macrophages (melanophages) can occur in obstetric scars. The specific location of this pigmentation and the presence of scars, for example, after episiotomy, is helpful in the differential diagnosis.

Melanocytic nevi of the vulva are uncommon. Histologically, they show a benign proliferation of nevus cells and may be junctional, compound, or intradermal. Clinically, they usually are well defined, papular, uniformly pigmented and less than 10 mm in diameter. Atypical nevi of the vulva with prominent variable-sized junctional nests and lentiginous spread as well as dysplastic

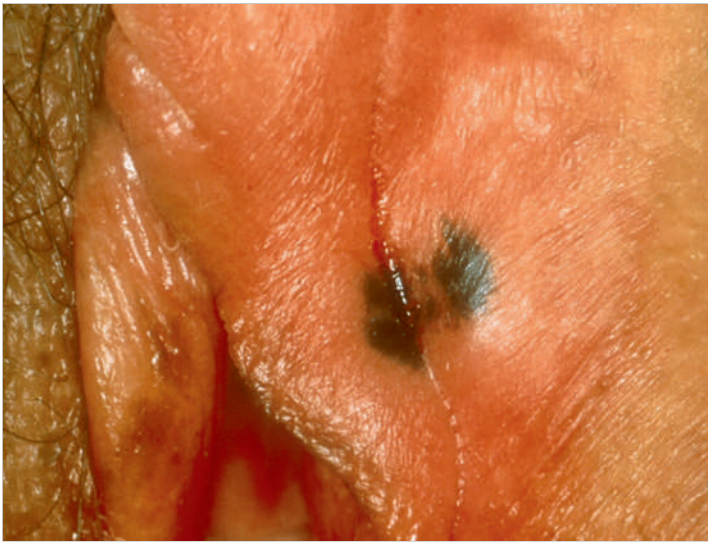

Fig. 13.44 Melanoma in situ. Darkly pigmented flat lesion in the left interlabial sulcus.

nevi with nuclear pleomorphism and irregular borders can occur, especially in young women. Nevi should be considered for excision, particularly if they change appearance or cause symptoms like bleeding.

Malignant melanoma is the second most common malignancy of the vulva and can occur on the clitoris, labia minora, and labia majora with approximately equal frequency. Melanomas can arise de novo or from preexisting benign or atypical pigmented lesions. *Melanoma in situ* consists of malignant melanocytes that spread along the epidermis but do not extend into the papillary dermis. Clinically, these pigmented lesions are flat or slightly raised. *Invasive melanoma* has not only malignant melanocytes in the epidermis but also show invasion in the papillary dermis. In the further course of the disease, invasion in the reticular dermis and subcutaneous fat tissue is observed. Clinically, these tumors show reddish brown to black nodules, sometimes with exulceration. Prognosis depends mostly on depth of invasion (► Fig. 13.44, ► Fig. 13.45, ► Fig. 13.46).

13.5 Non-Neoplastic

13.5.1 Epithelial Disorders of the Vulva

The current classification of non-neoplastic epithelial disorders of the vulva was formulated by the ISSVD in 2006.⁷⁰ Lichen sclerosus and lichen planus are common problems and have a potential for malignant transformation. Accordingly, gynecologists should be well versed in the diagnosis, treatment, and follow-up of these conditions. Lichen sclerosus and lichen planus can have overlapping clinical and morphological features. Further entities include lichen simplex chronicus (formerly known as *squamous hyperplasia*), psoriasis, and eczema of the vulva.

13.5.2 Lichen Sclerosus

Vulvar lichen sclerosus is a chronic localized lymphocyte-mediated dermatosis with a presumed autoimmune origin.⁷¹ A small percentage of patients show systemic evidence of T-cell immune deficiencies.⁷² If the condition is untreated over many years,

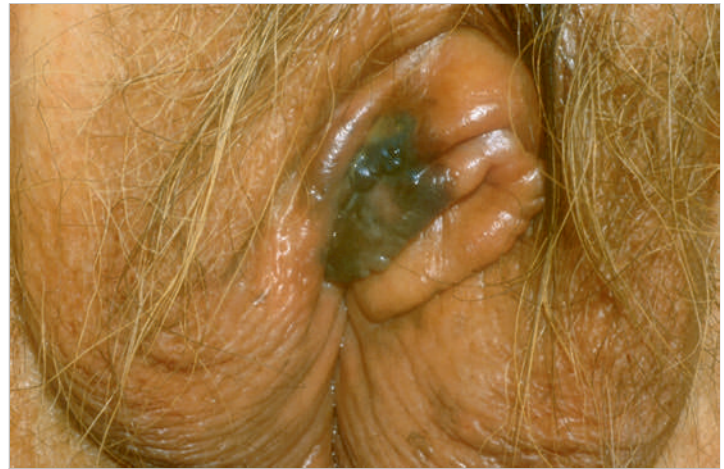

Fig. 13.45 Malignant melanoma. The dark pigmented lesion is raised.

progressive sclerosis results in scarring with severe distortion of the normal vulvar anatomy. The condition can occur in childhood (► Fig. 13.47, ► Fig. 13.48).

The cardinal symptoms of lichen sclerosus are intractable vulvar itching and soreness. Lichen sclerosus begins with uncharacteristic pruritus, burning, dysuria, dyspareunia, and pain. Early symptoms are often ignored or interpreted as secondary effects of yeast infections. Thus, patients with persistent

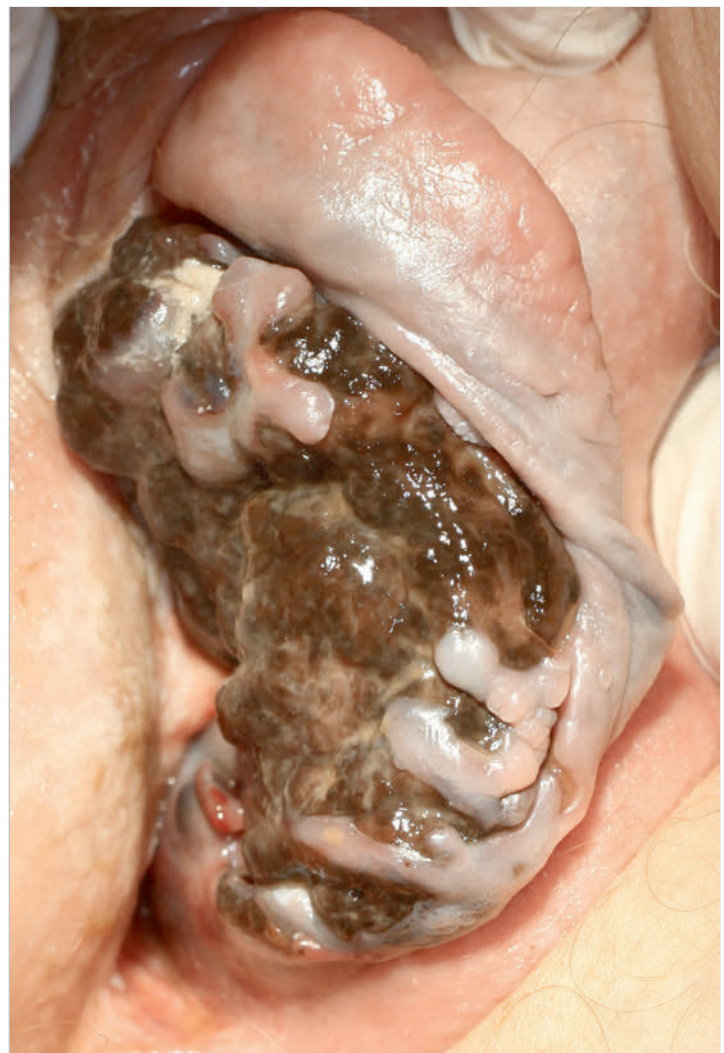

Fig. 13.46 Advanced malignant melanoma with marked nodular growth.

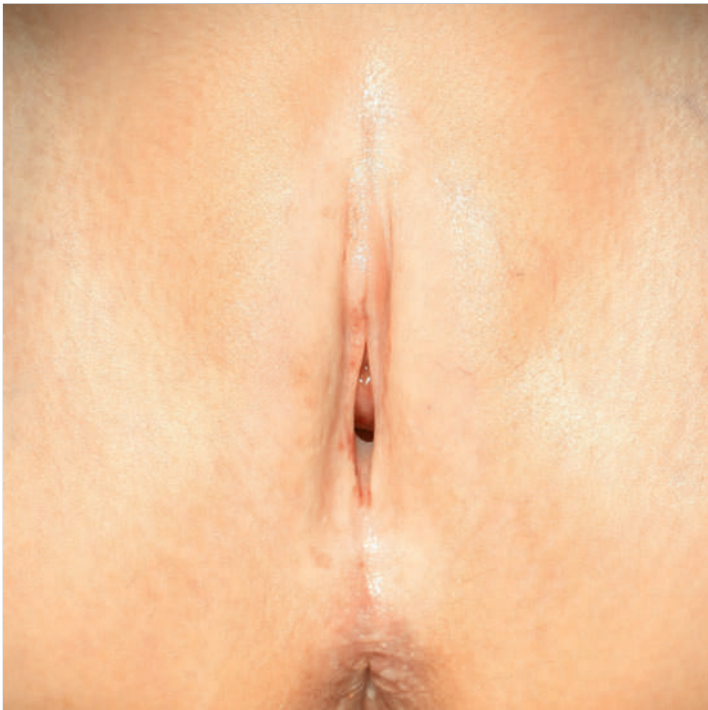

Fig. 13.47 Lichen sclerosus, manifestation in childhood.

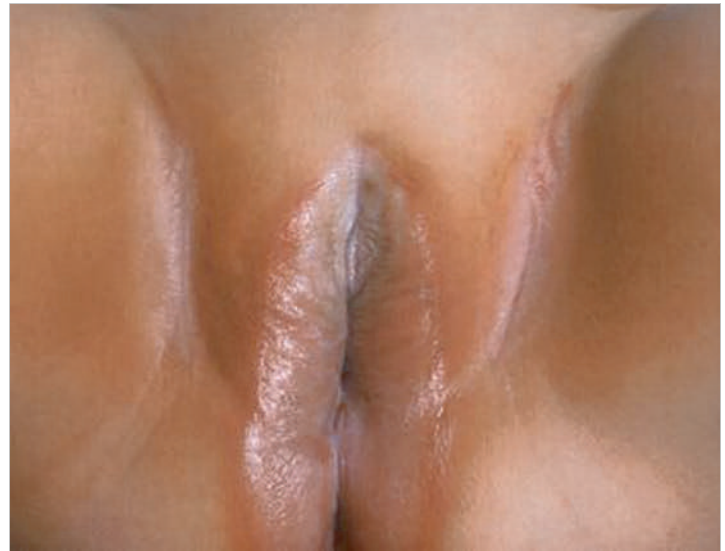

Fig. 13.48 Lichen sclerosus, manifestation in childhood.

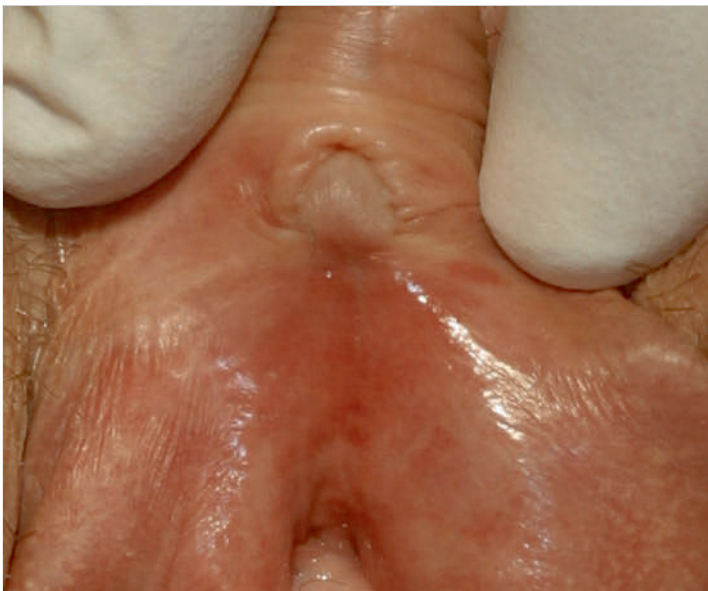

Fig. 13.49 Early lichen sclerosus affecting the periclitoral area. Note the prominent shiny erythema and thinning of the mucosa.

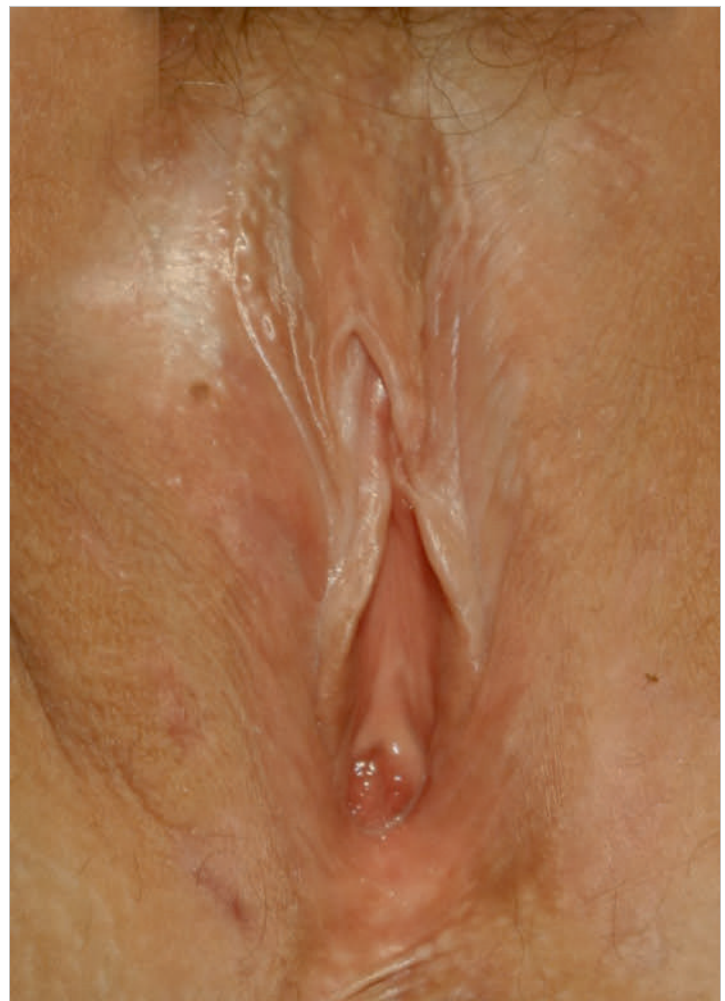

Fig. 13.50 Early lichen sclerosus with spread to the interlabial sulci. Note the mild depigmentation and mild asymmetry of the labia minora.

vulvar symptoms should be evaluated by biopsy early.⁷³ Early lichen sclerosus (► Fig. 13.49, ► Fig. 13.50, ► Fig. 13.51) often affects the periclitoral area and then spreads to the interlabial sulci. Early lichen sclerosus can show prominent shiny erythema, mild depigmentation, thinning of the mucosa, and mild asymmetry of the labia minora. Quite often, lichen sclerosus involves the perineum and the perianal skin in a figure-of-8 distribution. Many patients have slow progression over years (► Fig. 13.52, ► Fig. 13.53) with multiple complete or partial remissions. Late lichen sclerosus (► Fig. 13.54, ► Fig. 13.55) associated with destructive scarring, depigmentation, progressive loss of the labia minora, synechiae, and vaginal stenosis (kraurosis vulvae in the old literature) carries significant morbidity. Progression can be

prevented with consistent treatment and follow-up. Squamous cell carcinomas develop in 3 to 5% of patients with long-standing and untreated vulvar lichen sclerosus.⁷¹ It is unknown whether early diagnosis and treatment of lichen sclerosus and lichen planus reduce the risk of malignant transformation.

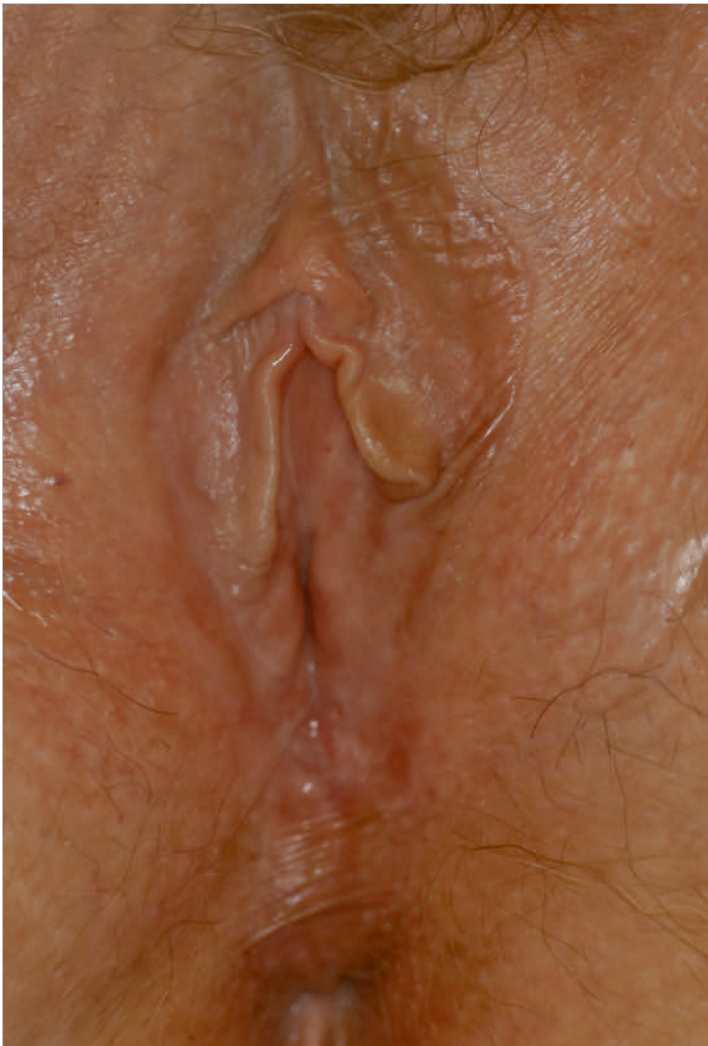

Fig. 13.51 Early lichen sclerosus with pigment incontinence and already considerably reduced labia minora.⁷³

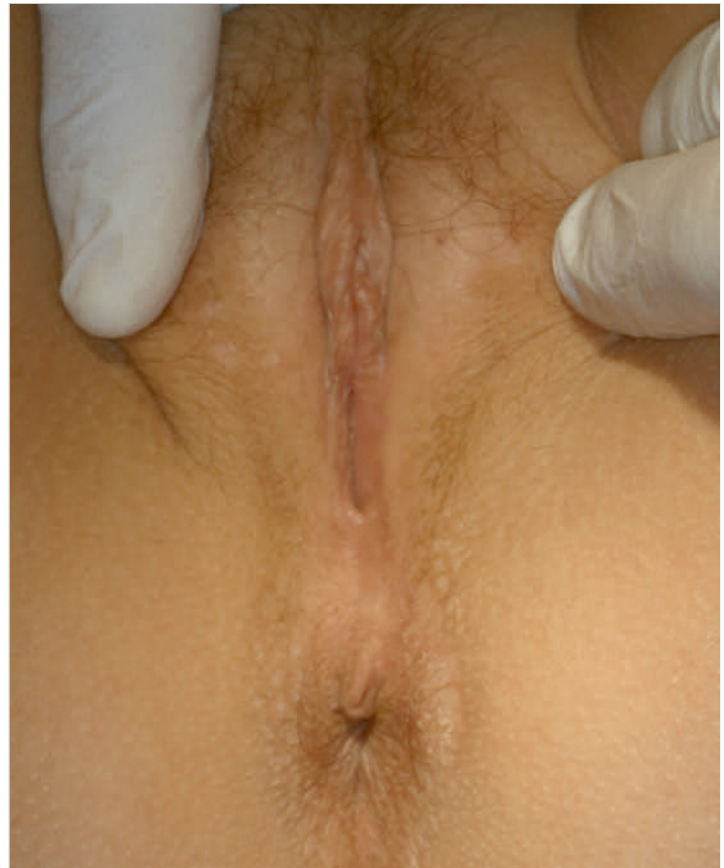

Fig. 13.52 Intermediate lichen sclerosus involving the perineum and perianal skin.

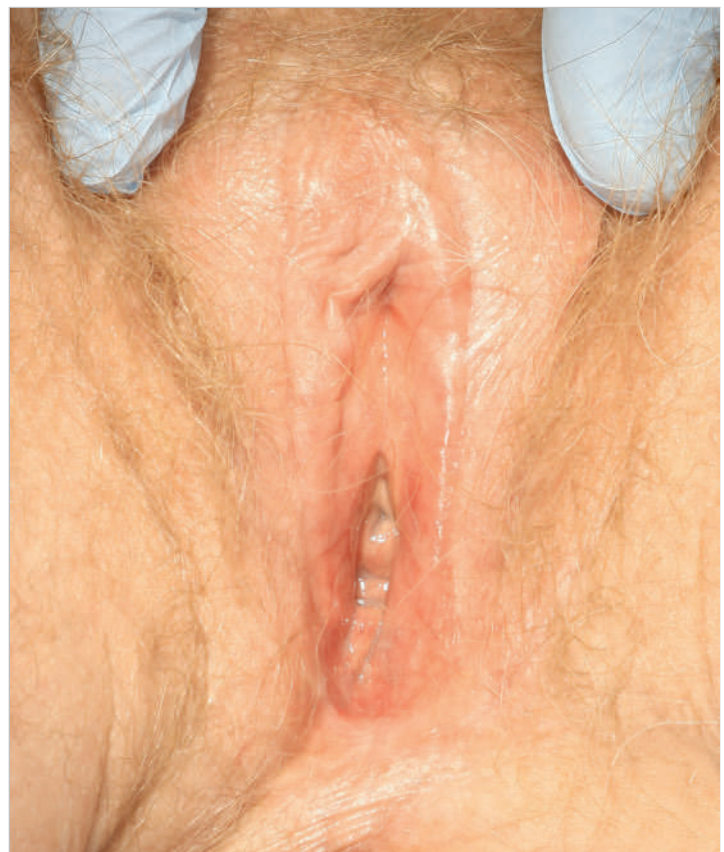

Fig. 13.53 Intermediate lichen sclerosus. Note the depigmentation of the labia minora and interlabial sulci.

First-line treatment of lichen sclerosus with a superpotent topical corticosteroid has a high response rate. A suitable regimen is clobetasol propionate 0.05% ointment once daily for 1 month, alternate days for 1 month, and twice weekly for 1 month, then reducing to as needed. A 30-g tube should last about 3 months, and for most patients it will last longer. A similar regimen may be used in children. Potential side effects of corticoid therapy include cutaneous atrophy or adrenal suppression, but in practice and with careful monitoring, these side effects are rare.^{71,74} Local indifferent ointments should be used to minimize local steroid side effects.

Second-line therapies include topical calcineurin inhibitors: pimecrolimus and tacrolimus have been demonstrated to be effective.⁷⁴ This type of treatment works exclusively through interactions with lymphocytes in active stages of disease.

13.5.3 Lichen Planus

Lichen planus is a mucocutaneous disease of unknown origin that can involve the skin, oral mucosa, genitalia, esophagus, and skin appendages.^{5,75,76} There are three main clinical types: classic,

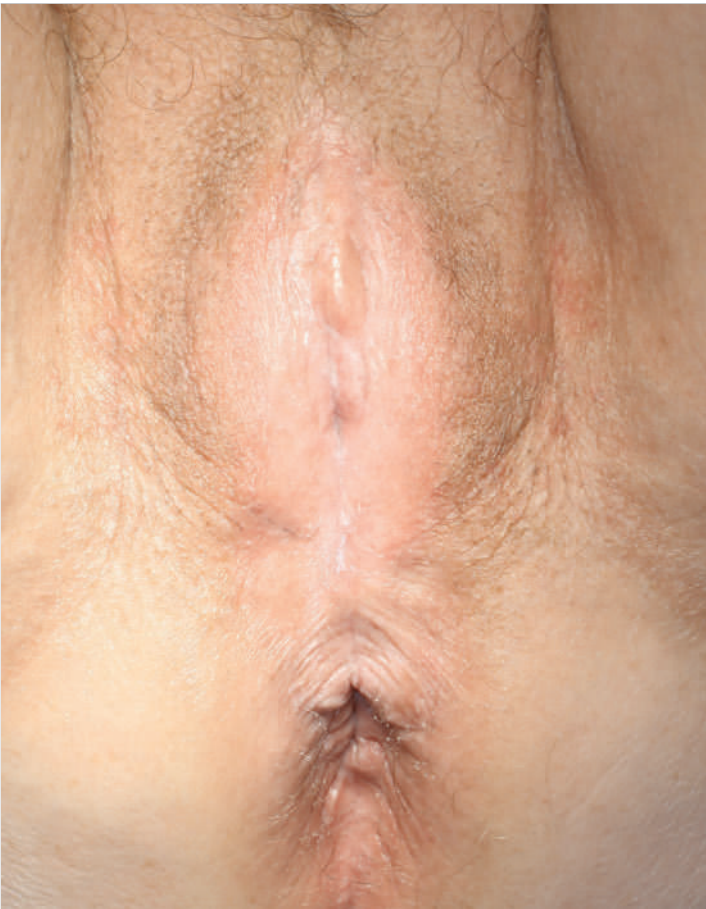

Fig. 13.54 Late lichen sclerosis with scarring and subtotal occlusion of the introitus.

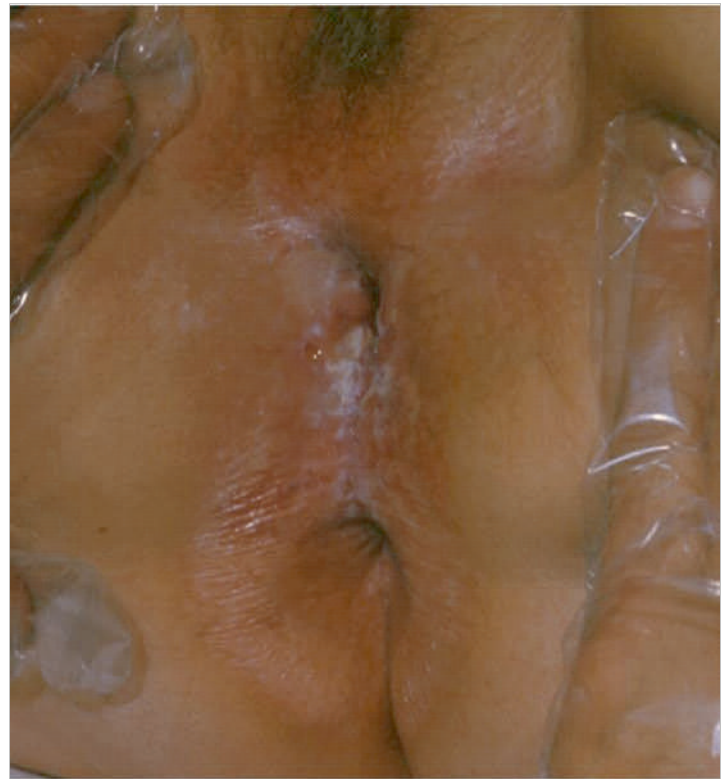

Fig. 13.55 End-stage lichen sclerosis. The anatomy of the vulva is severely distorted.

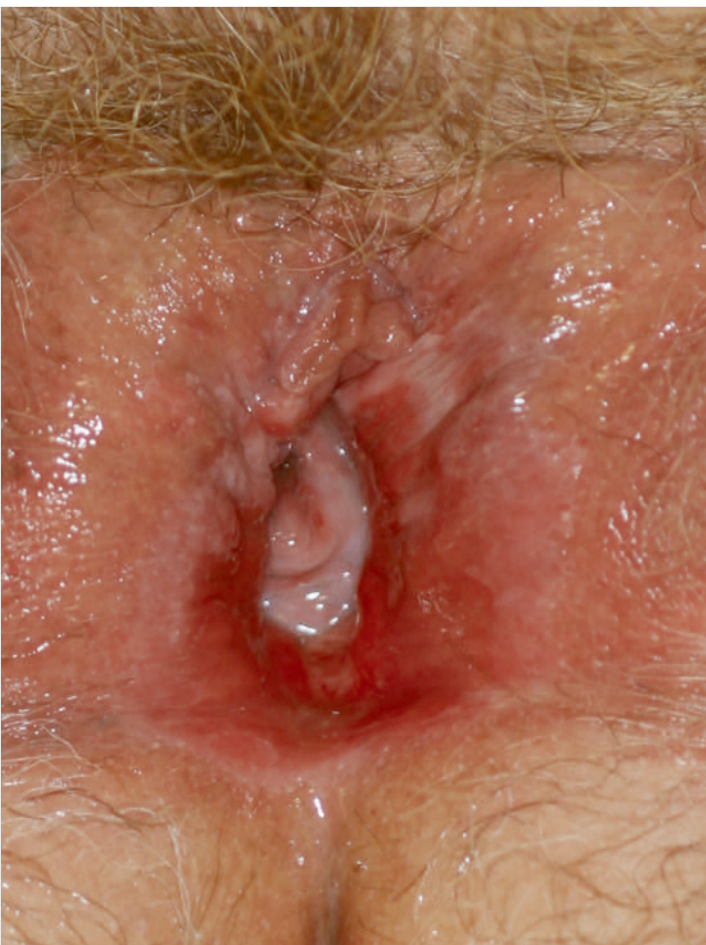

Fig. 13.56 Lichen planus with vaginal involvement.

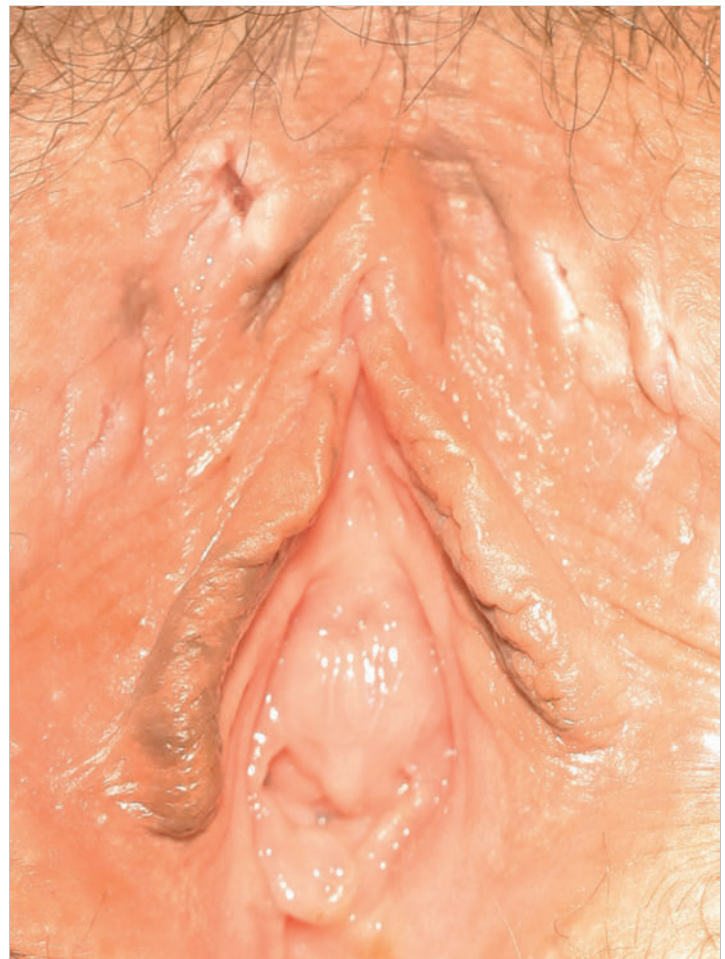

Fig. 13.57 Lichen planus, hypertrophic type.

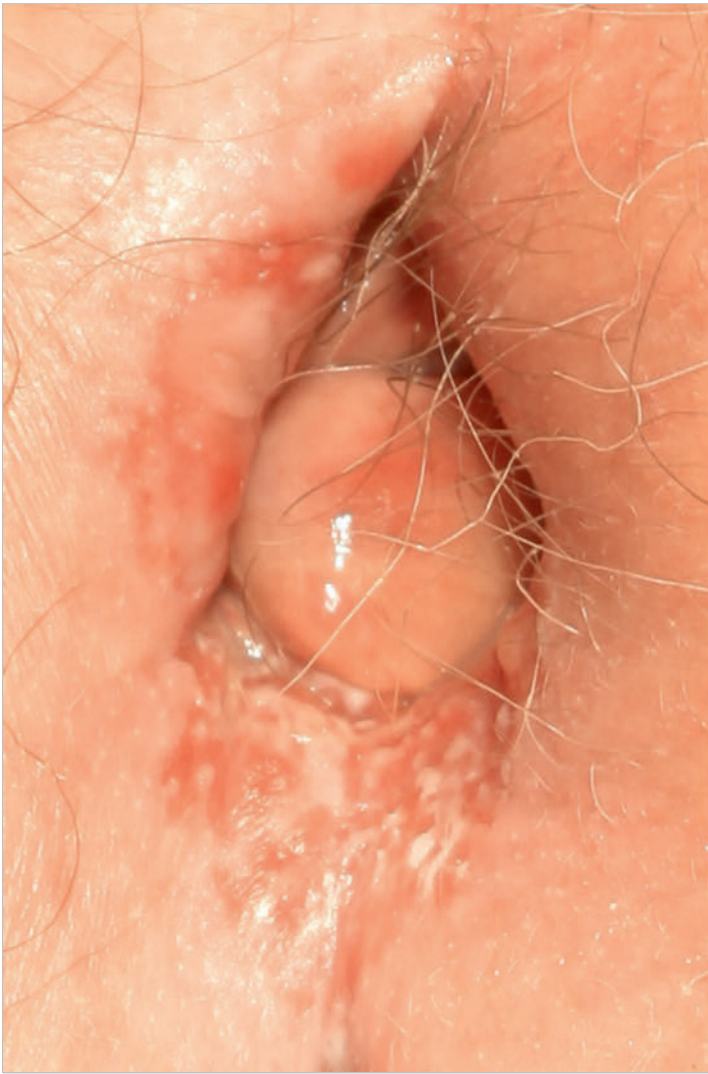

Fig. 13.58 Lichen planus with fine whitish lines (Wickham phenomenon).

erosive, and hypertrophic (► Fig. 13.56, ► Fig. 13.57, ► Fig. 13.58). As in lichen sclerosis, the etiology of lichen planus is probably immunological, with T cells activated by an as yet unknown antigen to attack the basal keratinocytes. There appears to be an association with hepatitis C, and patients with lichen planus should be tested accordingly.⁷⁶

Patients with genital lichen planus usually have severe pruritus and soreness. Lichen planus affecting the mucosal side of the vulva typically involves the inner aspects of the labia minora and consists of a glazed erythema that may easily bleed on touching and fine whitish lines, the Wickham phenomenon.⁷⁷ Erosions may develop. In later stage lichen planus commonly leads to a reduction and fusion of the labia minora and vagina. This may result in a buried clitoris and urethra, a narrow vaginal introitus, and a fused vagina, making penetration impossible.

In contrast to lichen sclerosis, genital lichen planus typically involves the vaginal mucosa. Patients with genital lichen planus should be examined for other mucosal lesions, in particular in the mouth. The vulvovaginal–gingival syndrome is a subgroup of lichen planus and can be a multisystem disorder.⁷⁸

The exact incidence of malignancy associated with lichen planus is unknown. It is unknown whether early diagnosis and treatment of lichen sclerosis and lichen planus reduce the risk of malignant transformation.

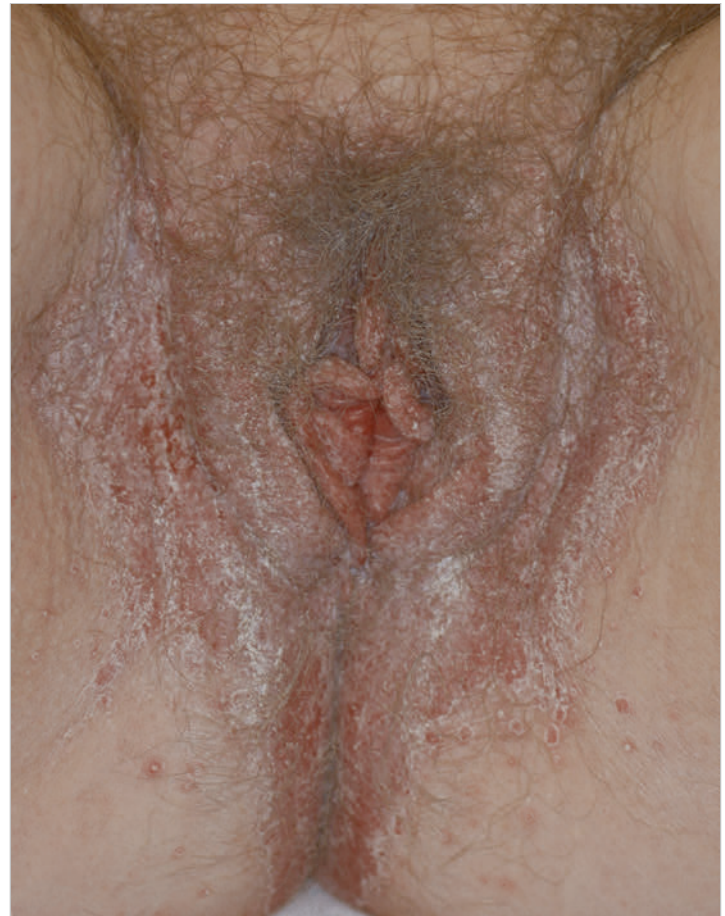

Fig. 13.59 Psoriasis with silvery scaling and sharply demarcated erythema. Note the involvement of the labia majora which usually does not occur in lichen sclerosis and lichen planus.

The treatment of lichen planus is similar to that of lichen sclerosis. Clobetasol propionate (0.05%) ointment is effective.⁷⁹ Foam preparations can be used for vaginal lesions. Calcineurin inhibitors pimecrolimus and tacrolimus are second-line options.

13.5.4 Psoriasis

Psoriasis is a chronic inflammatory skin disease with accelerated epidermal proliferation and disturbed differentiation. There is no increased risk of secondary malignancy. Psoriasis is most commonly seen on the elbows, knees, scalp, and nails but can also occur on the vulva. Clinical features include silvery scaling and sharply demarcated erythema. The erythema and sharp outline tend to remain, and fissuring is seen. In contrast to lichen sclerosis and lichen planus, psoriasis often involves the labia majora (► Fig. 13.59). This can be helpful in the differential diagnosis. Vulvar psoriasis initially is treated with a potent steroid and a vitamin D ointment, always in consultation with a dermatologist.

13.5.5 Lichen Simplex

Lichen simplex describes a dermatological affection seen on the apparently normal vulva secondary to chronic itching and rubbing. The term *lichen simplex chronicus* is used when the lichenification develops as a palpable thickening with increased prominence of skin markings on skin that had been previously normal in appearance and where other disorders (i.e., lichen sclerosis,

lichen planus, psoriasis) have been ruled out. The term *lichenification* is used for similar changes on a background of a visible dermatosis. Lichen simplex chronicus is characterized by an intractable itch-scratch cycle. Lichen simplex chronicus is more common in women with allergies and atopic dermatitis at other sites. Itching normally responds quickly to application of a potent topical steroid to break the itch-scratch cycle. A sedating antihistamine such as hydroxyzine may be helpful at night.

13.5.6 Vulvar Eczema

Vulvar eczemas can be classified as atopic eczema, irritant contact dermatitis (from topical treatments, cosmetic preparations, wet wipes, and mechanical friction from sanitary pads) and allergic contact dermatitis (from delayed-type or cell-mediated immunity). Especially atopic vulvar eczema is characterized by severe itching and lichenification. Known allergens are anesthetics, antibiotics, anticandidal agents, antiseptics, corticosteroids, and spermicides as medications. Additional agents, among others, are cosmetics, preservatives, fragrances, emollients, panty liners, snaps, buckles, pins, and clothing. Patch testing should be done to identify relevant allergens, and causative agents should be withdrawn, and irritative stimuli avoided. In case of atopic eczema, patients should be referred to dermatologists. Topical steroids are prescribed according to severity.

References

- [1] Wilkinson EJ, Stone IK. Atlas of vulvar disease. Baltimore: Williams & Wilkins, 1995:1-9
- [2] Bornstein J, Sideri M, Tatti S, Walker P, Prendiville W, Haefner HK Nomenclature Committee of International Federation for Cervical Pathology and Colposcopy. 2011 terminology of the vulva of the International Federation for Cervical Pathology and Colposcopy. *J Low Genit Tract Dis* 2012; 16: 290-295
- [3] Bergeron C, Ferenczy A, Richart RM, Guralnick M. Micropapillomatosis labialis appears unrelated to human papillomavirus. *Obstet Gynecol* 1990; 76: 281-286
- [4] Del Pino M, Rodriguez-Carunchio L, Ordi J. Pathways of vulvar intraepithelial neoplasia and squamous cell carcinoma. *Histopathology* 2013; 62: 161-175
- [5] Regaver S, Reich O, Eberz B. Vulvar cancers in women with vulvar lichen planus: a clinicopathological study. *JAAD* 2014; (in press)
- [6] Srodon M, Stoler MH, Baber GB, Kurman RJ. The distribution of low and high-risk HPV types in vulvar and vaginal intraepithelial neoplasia (VIN and VaIN). *Am J Surg Pathol* 2006; 30: 1513-1518
- [7] Ueda Y, Enomoto T, Kimura T, Yoshino K, Fujita M, Kimura T. Two distinct pathways to development of squamous cell carcinoma of the vulva. *J Skin Cancer* 2011; 2011: 951250
- [8] Holway AH, Rieger-Christ KM, Miner WR et al. Somatic mutation of PTEN in vulvar cancer. *Clin Cancer Res* 2000; 6: 3228-3235
- [9] Rolfe KJ, MacLean AB, Crow JC, Benjamin E, Reid WM, Perrett CW. TP53 mutations in vulvar lichen sclerosis adjacent to squamous cell carcinoma of the vulva. *Br J Cancer* 2003; 89: 2249-2253
- [10] Choschzick M, Hantaredja W, Tennstedt P, Gieseck F, Wölber L, Simon R. Role of TP53 mutations in vulvar carcinomas. *Int J Gynecol Pathol* 2011; 30: 497-504
- [11] Yang B, Hart WR. Vulvar intraepithelial neoplasia of the simplex (differentiated) type: a clinicopathologic study including analysis of HPV and p53 expression. *Am J Surg Pathol* 2000; 24: 429-441
- [12] van der Avoort IA, van de Nieuwenhof HP, Otte-Höller I et al. High levels of p53 expression correlate with DNA aneuploidy in (pre)malignancies of the vulva. *Hum Pathol* 2010; 41: 1475-1485
- [13] Pinto AP, Lin MC, Sheets EE, Muto MG, Sun D, Crum CP. Allelic imbalance in lichen sclerosis, hyperplasia, and intraepithelial neoplasia of the vulva. *Gynecol Oncol* 2000; 77: 171-176
- [14] Allen DG, Hutchins AM, Hammet F et al. Genetic aberrations detected by comparative genomic hybridisation in vulvar cancers. *Br J Cancer* 2002; 86: 924-928
- [15] Aulmann S, Schleibaum J, Penzel R, Schirmacher P, Gebauer G, Sinn HP. Gains of chromosome region 3q26 in intraepithelial neoplasia and invasive squamous cell carcinoma of the vulva are frequent and independent of HPV status. *J Clin Pathol* 2008; 61: 1034-1037
- [16] Guerrero D, Guarch R, Ojer A et al. Differential hypermethylation of genes in vulvar cancer and lichen sclerosis coexisting or not with vulvar cancer. *Int J Cancer* 2011; 128: 2853-2864
- [17] Garland SM, Insinga RP, Sings HL, Haupt RM, Joura EA. Human papillomavirus infections and vulvar disease development. *Cancer Epidemiol Biomarkers Prev* 2009; 18: 1777-1784
- [18] Stephenson RD, Denehy TR. Rapid spontaneous regression of acute-onset vulvar intraepithelial neoplasia 3 in young women: a case series. *J Low Genit Tract Dis* 2012; 16: 56-58
- [19] Jones RW, Rowan DM. Spontaneous regression of vulvar intraepithelial neoplasia 2-3. *Obstet Gynecol* 2000; 96: 470-472
- [20] Jones RW, Rowan DM, Stewart AW. Vulvar intraepithelial neoplasia: aspects of the natural history and outcome in 405 women. *Obstet Gynecol* 2005; 106: 1319-1326
- [21] van Seters M, van Beurden M, de Craen AJ. Is the assumed natural history of vulvar intraepithelial neoplasia III based on enough evidence? A systematic review of 3322 published patients. *Gynecol Oncol* 2005; 97: 645-651
- [22] van de Nieuwenhof HP, Massuger LF, van der Avoort IA et al. Vulvar squamous cell carcinoma development after diagnosis of VIN increases with age. *Eur J Cancer* 2009; 45: 851-856
- [23] van de Nieuwenhof HP, Bulten J, Hollema H et al. Differentiated vulvar intraepithelial neoplasia is often found in lesions, previously diagnosed as lichen sclerosis, which have progressed to vulvar squamous cell carcinoma. *Mod Pathol* 2011; 24: 297-305
- [24] Eva LJ, Ganesan R, Chan KK, Honest H, Malik S, Luesley DM. Vulval squamous cell carcinoma occurring on a background of differentiated vulvar intraepithelial neoplasia is more likely to recur: a review of 154 cases. *J Reprod Med* 2008; 53: 397-401
- [25] Regauer S. Residual anogenital lichen sclerosis after cancer surgery has a high risk for recurrence: a clinicopathological study of 75 women. *Gynecol Oncol* 2011; 123: 289-294
- [26] Kaufman RH, Gardner HL. Intraepithelial carcinoma of the vulva. *Clin Obstet Gynecol* 1965; 8: 1035-1050
- [27] Wilkinson EJ, Kneale B, Lynch P Report of the ISSVD Terminology Committee *J Reprod Med* 1986; 31: 973-974
- [28] Sideri M, Jones RW, Wilkinson EJ et al. Squamous vulvar intraepithelial neoplasia: 2004 modified terminology, ISSVD Vulvar Oncology Subcommittee. *J Reprod Med* 2005; 50: 807-810
- [29] Medeiros F, Nascimento AF, Crum CP. Early vulvar squamous neoplasia: advances in classification, diagnosis, and differential diagnosis. *Adv Anat Pathol* 2005; 12: 20-26
- [30] Waxman AG, Chelmsow D, Darragh TM, Lawson H, Moscicki AB. Revised terminology for cervical histopathology and its implications for management of high-grade squamous intraepithelial lesions of the cervix. *Obstet Gynecol* 2012; 120: 1465-1471
- [31] <http://www.cap.org/apps/cap.portal>
- [32] World Health Organization Classification of Tumours of the Female Reproductive Organs. 4th edition. Kurman RJ, Carcangiu ML, Herrington CS, Young RH (eds). IARC press, Lyon 2014
- [33] Ordi J, Alejo M, Fusté V et al. HPV-negative vulvar intraepithelial neoplasia (VIN) with basaloid histologic pattern: an unrecognized variant of simplex (differentiated) VIN. *Am J Surg Pathol* 2009; 33: 1659-1665
- [34] Raju RR, Goldblum JR, Hart WR. Pagetoid squamous cell carcinoma in situ (pagetoid Bowen's disease) of the external genitalia. *Int J Gynecol Pathol* 2003; 22: 127-135
- [35] Logani S, Lu D, Quint WG, Ellenson LH, Pirog EC. Low-grade vulvar and vaginal intraepithelial neoplasia: correlation of histologic features with human papillomavirus DNA detection and MIB-1 immunostaining. *Mod Pathol* 2003; 16: 735-741
- [36] Sutton BC, Allen RA, Moore WE, Dunn ST. Distribution of human papillomavirus genotypes in invasive squamous carcinoma of the vulva. *Mod Pathol* 2008; 21: 345-354

- [37] Likes WM, Stegbauer C, Tillmanns T, Pruett J. Correlates of sexual function following vulvar excision. *Gynecol Oncol* 2007; 105: 600–603
- [38] Thuesen B, Andreasson B, Bock JE. Sexual function and somatopsychic reactions after local excision of vulvar intra-epithelial neoplasia. *Acta Obstet Gynecol Scand* 1992; 71: 126–128
- [39] Shylasree TS, Karanjgaokar V, Tristram A, Wilkes AR, MacLean AB, Fiander AN. Contribution of demographic, psychological and disease-related factors to quality of life in women with high-grade vulvar intraepithelial neoplasia. *Gynecol Oncol* 2008; 110: 185–189
- [40] Modesitt SC, Waters AB, Walton L, Fowler WC, Van Le L. Vulvar intraepithelial neoplasia III: occult cancer and the impact of margin status on recurrence. *Obstet Gynecol* 1998; 92: 962–966
- [41] Polteraer S, Dressler A, Grimm C et al. Accuracy of preoperative vulva biopsy and the outcome of surgery in vulvar intraepithelial neoplasia 2 and 3. *Int J Gynecol Pathol* 2009; 28: 559–562
- [42] Küppers V, Stiller M, Somville T, Bender HG. Risk factors for recurrent VIN. Role of multifocality and grade of disease. *J Reprod Med* 1997; 42: 140–144
- [43] Hillemanns P, Wang X, Staehle S, Michels W, Dannecker C. Evaluation of different treatment modalities for vulvar intraepithelial neoplasia (VIN): CO(2) laser vaporization, photodynamic therapy, excision and vulvectomy. *Gynecol Oncol* 2006; 100: 271–275
- [44] Stern PL, van der Burg SH, Hampson IN et al. Therapy of human papillomavirus-related disease. *Vaccine* 2012; 30 Suppl 5: F71–F82
- [45] Jayne CJ, Kaufman RH. Treatment of vulvar intraepithelial neoplasia 2/3 with imiquimod. *J Reprod Med* 2002; 47: 395–398
- [46] Mathiesen O, Buus SK, Cramers M. Topical imiquimod can reverse vulvar intraepithelial neoplasia: a randomised, double-blinded study. *Gynecol Oncol* 2007; 107: 219–222
- [47] Le T, Menard C, Hicks-Boucher W, Hopkins L, Weberpals J, Fung-Kee-Fung M. Final results of a phase 2 study using continuous 5% Imiquimod cream application in the primary treatment of high-grade vulva intraepithelial neoplasia. *Gynecol Oncol* 2007; 106: 579–584
- [48] Terlou A, van Seters M, Ewing PC et al. Treatment of vulvar intraepithelial neoplasia with topical imiquimod: seven years median follow-up of a randomized clinical trial. *Gynecol Oncol* 2011; 121: 157–162
- [49] Diaz-Arastia C, Arany I, Robazetti SC et al. Clinical and molecular responses in high-grade intraepithelial neoplasia treated with topical imiquimod 5%. *Clin Cancer Res* 2001; 7: 3031–3033
- [50] Iavazzo C, Pitsouni E, Athanasiou S, Falagas ME. Imiquimod for treatment of vulvar and vaginal intraepithelial neoplasia. *Int J Gynaecol Obstet* 2008; 101: 3–10
- [51] Pepas L, Kaushik S, Bryant A, Nordin A, Dickinson HO. Medical interventions for high grade vulval intraepithelial neoplasia. *Cochrane Database Syst Rev* 2011; 13: CD007924
- [52] Amine A, Rivera S, Opolon P et al. Novel anti-metastatic action of cidofovir mediated by inhibition of E6/E7, CXCR4 and Rho/ROCK signaling in HPV tumor cells. *PLoS ONE* 2009; 4: e5018
- [53] Tristram A, Fiander A. Clinical responses to Cidofovir applied topically to women with high grade vulval intraepithelial neoplasia. *Gynecol Oncol* 2005; 99: 652–655
- [54] Castano AP, Mroz P, Hamblin MR. Photodynamic therapy and anti-tumour immunity. *Nat Rev Cancer* 2006; 6: 535–545
- [55] Winters U, Daayana S, Lear JT et al. Clinical and immunologic results of a phase II trial of sequential imiquimod and photodynamic therapy for vulvar intraepithelial neoplasia. *Clin Cancer Res* 2008; 14: 5292–5299
- [56] Vilmer C, Havard S, Cavelier-Balloy B, Pelisse M, Dubertret L, Leibowitch M. Failure of isotretinoin and interferon-alpha combination therapy for HPV-linked severe vulvar dysplasia. A report of two cases. *J Reprod Med* 1998; 43: 693–695
- [57] Kenter GG, Welters MJ, Valentijn AR et al. Vaccination against HPV-16 oncoproteins for vulvar intraepithelial neoplasia. *N Engl J Med* 2009; 361: 1838–1847
- [58] Daayana S, Elkord E, Winters U et al. Phase II trial of imiquimod and HPV therapeutic vaccination in patients with vulval intraepithelial neoplasia. *Br J Cancer* 2010; 102: 1129–1136
- [59] Wilkinson EJ, Brown HM. Vulvar Paget disease of urothelial origin: a report of three cases and a proposed classification of vulvar Paget disease. *Hum Pathol* 2002; 33: 549–554
- [60] Regauer S. Extramammary Paget's disease—a proliferation of adnexal origin? *Histopathology* 2006; 48: 723–729
- [61] Dubreuilh W. Paget's disease of the vulva. *Br J Dermatol* 1991; 13: 407–413
- [62] Lloyd J, Flanagan AM. Mammary and extramammary Paget's disease. *J Clin Pathol* 2000; 53: 742–749
- [63] Kodama S, Kaneko T, Saito M, Yoshiya N, Honma S, Tanaka K. A clinicopathologic study of 30 patients with Paget's disease of the vulva. *Gynecol Oncol* 1995; 56: 63–70
- [64] Sarmiento JM, Wolff BG, Burgart LJ, Frizelle FA, Ilstrup DM. Paget's disease of the perianal region—an aggressive disease? *Dis Colon Rectum* 1997; 40: 1187–1194
- [65] Fanning J, Lambert HC, Hale TM, Morris PC, Schuerch C. Paget's disease of the vulva: prevalence of associated vulvar adenocarcinoma, invasive Paget's disease, and recurrence after surgical excision. *Am J Obstet Gynecol* 1999; 180: 24–27
- [66] Misas JE, Larson JE, Podczaski E, Manetta A, Mortel R. Recurrent Paget disease of the vulva in a split-thickness graft. *Obstet Gynecol* 1990; 76: 543–544
- [67] Feldmeyer L, Kerl K, Kamarashev J, de Viragh P, French LE. Treatment of vulvar Paget disease with topical imiquimod: a case report and review of the literature. *J Dermatol Case Rep* 2011; 5: 42–46
- [68] Reich O, Liegl B, Tamussino K, Regauer S. p185HER2 overexpression and HER2 oncogene amplification in recurrent vulvar Paget's disease. *Mod Pathol* 2005; 18: 354–357
- [69] Rock B. Pigmented lesions of the vulva. *Dermatol Clin* 1992; 10: 361–370
- [70] Lynch PJ, Moyal-Barracco M, Bogliatto F, Micheletti L, Scurry J. 2006 ISSVD classification of vulvar dermatoses: pathologic subsets and their clinical correlates. *J Reprod Med* 2007; 52: 3–9
- [71] Powell JJ, Wojnarowska F. Lichen sclerosus. *Lancet* 1999; 353: 1777–1783
- [72] Regauer S. Immune dysregulation in lichen sclerosus. *Eur J Cell Biol* 2005; 84: 273–277
- [73] Regauer S, Liegl B, Reich O. Early vulvar lichen sclerosus: a histopathological challenge. *Histopathology* 2005; 47: 340–347
- [74] Chi CC, Kirtschig G, Baldo M, Brackenbury F, Lewis F, Wojnarowska F. Topical interventions for genital lichen sclerosus. *Cochrane Database Syst Rev* 2011; 12: CD008240
- [75] Le Cleach L, Chosidow O. Clinical practice. Lichen planus. *N Engl J Med* 2012; 366: 723–732
- [76] Cheng S, Kirtschig G, Cooper S, Thornhill M, Leonardi-Bee J, Murphy R. Interventions for erosive lichen planus affecting mucosal sites. *Cochrane Database Syst Rev* 2012; 2: CD008092
- [77] Steffen C, Dupree ML. Louis-Frédéric Wickham and the Wickham's striae of lichen planus. *Skinmed* 2004; 3: 287–289
- [78] Setterfield JF, Neill S, Shirlaw PJ et al. The vulvovaginal gingival syndrome: a severe subgroup of lichen planus with characteristic clinical features and a novel association with the class II HLA DQB1*0201 allele. *J Am Acad Dermatol* 2006; 55: 98–113
- [79] Lewis FM, Pelisse M. Vulvar lichen planus: clinical aspects and guideline to management. *Eur J Gynaecol Oncol* 2005; 10: 188–191

Chapter 14

Colposcopy of the Vagina

14.1 Histology	208
14.2 Vaginal Carcinogenesis	208
14.3 Squamous Intraepithelial Lesions (SIL; formerly known as Vaginal Intraepithelial Neoplasia or VAIN)	208
14.4 Diagnostic Methods for SIL	208
14.5 Histologic Terminology and Classification	211
14.6 Histomorphology of Vaginal SIL	211
14.7 Management of SIL	211
14.8 Vaginal Melanoma	212

14 Colposcopy of the Vagina

14.1 Histology

The squamous mucosa lining the vagina is similar to the original squamous epithelium of the cervix. Embryologically, the epithelium of the distal vagina appears to be derived from the epithelium of the urogenital sinus epithelium, which is itself of endodermal origin, whereas the epithelium of the upper vagina is of mesodermal müllerian origin (► Fig. 14.1).¹ The vaginal stroma is composed of a mixture of elastic fibers and can contain mesonephric or wolffian remnants. The persistence of glands arising from müllerian epithelium (so-called vaginal adenosis) is uncommon, and the vagina usually does not contain glands.

14.2 Vaginal Carcinogenesis

The large majority of malignant vaginal neoplasms are squamous cell carcinomas that develop via squamous intraepithelial lesions (SIL; formerly vaginal intraepithelial neoplasia, VAIN) associated with human papillomavirus (HPV) infection. Many types of HPV have been found in SIL, the most common being HPV 16, HPV 18, and HPV 58.² Patients with risk factors for persisting HPV infection (e.g., smoking, immunosuppression, HIV infection) have an increased risk for vaginal precancer and cancer.^{3,4,5} Occasional squamous cell carcinomas of the vagina may develop in a background of lichen planus independently of HPV infection.⁶ The mechanism of HPV-independent carcinogenesis of the vagina seems to parallel that of the vulva.

14.3 Squamous Intraepithelial Lesions (SIL; formerly known as Vaginal Intraepithelial Neoplasia or VAIN)

SIL of the vagina accounts for less than 1% of lower genital tract intraepithelial neoplasia.⁷ Women with vaginal SIL are usually asymptomatic. The first report of SIL is credited to Graham and Meigs⁸ in in patients years after treatment for carcinoma in situ of the cervix. Vaginal SIL can occur alone or as synchronously or metachronously with cervical or vulvar HPV-related precancer and cancer. Up to 65% of patients with vaginal SIL have been reported to have SIL of the cervix or vulva.⁹

Lesions are often multifocal and occur predominantly in the upper one-third of the vagina, whereas the middle and lower thirds are involved in less than 10%.¹⁰ This is probably due to the dual origin of vaginal epithelium during prenatal development.¹

Most lower-grade SILs probably regress spontaneously (Massad 2008). In contrast, untreated higher-grade SILs progresses to invasive cancer in 5–8% of cases.^{11,12,13,14}

14.4 Diagnostic Methods for SIL

14.4.1 History

A history of CIN is a major risk factor for the development of vaginal SIL. About 0.9–7.4% of patients with hysterectomy for

CIN later develop vaginal SIL.^{15,16} Vaginal SIL can develop as an independent lesion or close to the cervix (or vaginal apex after hysterectomy). In a series of 4,147 patients with CIN, 2.5% had lesions extending onto the vaginal fornices.¹⁷ Patients with residual CIN at the vaginal apex after hysterectomy appear at risk of developing invasive vaginal cancer.

As for other HPV-related neoplasias, smoking is a risk factor for vaginal carcinoma. Vaginal SIL is also known to occur more frequently in patients with a history of pelvic radiation for other malignancies such as cervical or endometrial cancer.^{18,19,20} This increased incidence of vaginal SIL may take some 10 to 15 years to manifest itself. Rome and England¹¹ described 132 cases of vaginal SIL, of which 16% had received prior radiotherapy. Possible mechanisms of postradiation cellular dysplasia include radiation-induced expression of HPV oncoproteins and radiation-induced changes in the cellular response to HPV infection.²¹

Vaginal adenosis is any condition in which columnar epithelium exists within the vagina. Metaplasia can convert this glandular epithelium to squamous epithelium. It is unclear whether high-risk HPV-infected women with vaginal adenosis are at greater risk for HG-VAIN. Vaginal adenosis may be the origin of the rare entities of vaginal adenoma and adenocarcinoma.^{22,23}

14.4.2 Colposcopy of the Vagina

In many cases vaginal SIL cannot be identified by gross inspection only; colposcopy of the vagina is essential. Particularly women who have positive cytology after treatment for CIN should be examined carefully for vaginal SIL. At the examination, it is important to rotate the open duck-billed speculum through 360 degrees, paying particular attention to the upper vagina. In the posthysterectomy patient, vaginal vault angles can be dimpled, precluding complete colposcopic assessment.

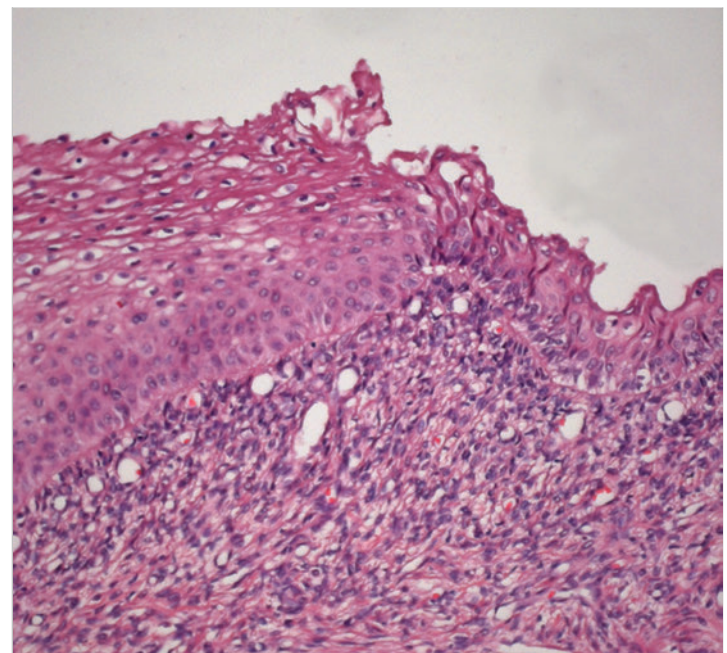


Fig. 14.1 Prenatal development of the vagina. Border between squamous epithelium of the distal vagina, derived from the urogenital sinus (*left*), and the cuboid mesodermal müllerian epithelium of the upper vagina (*right*) at 25 weeks' gestation (courtesy of H. Fritsch).

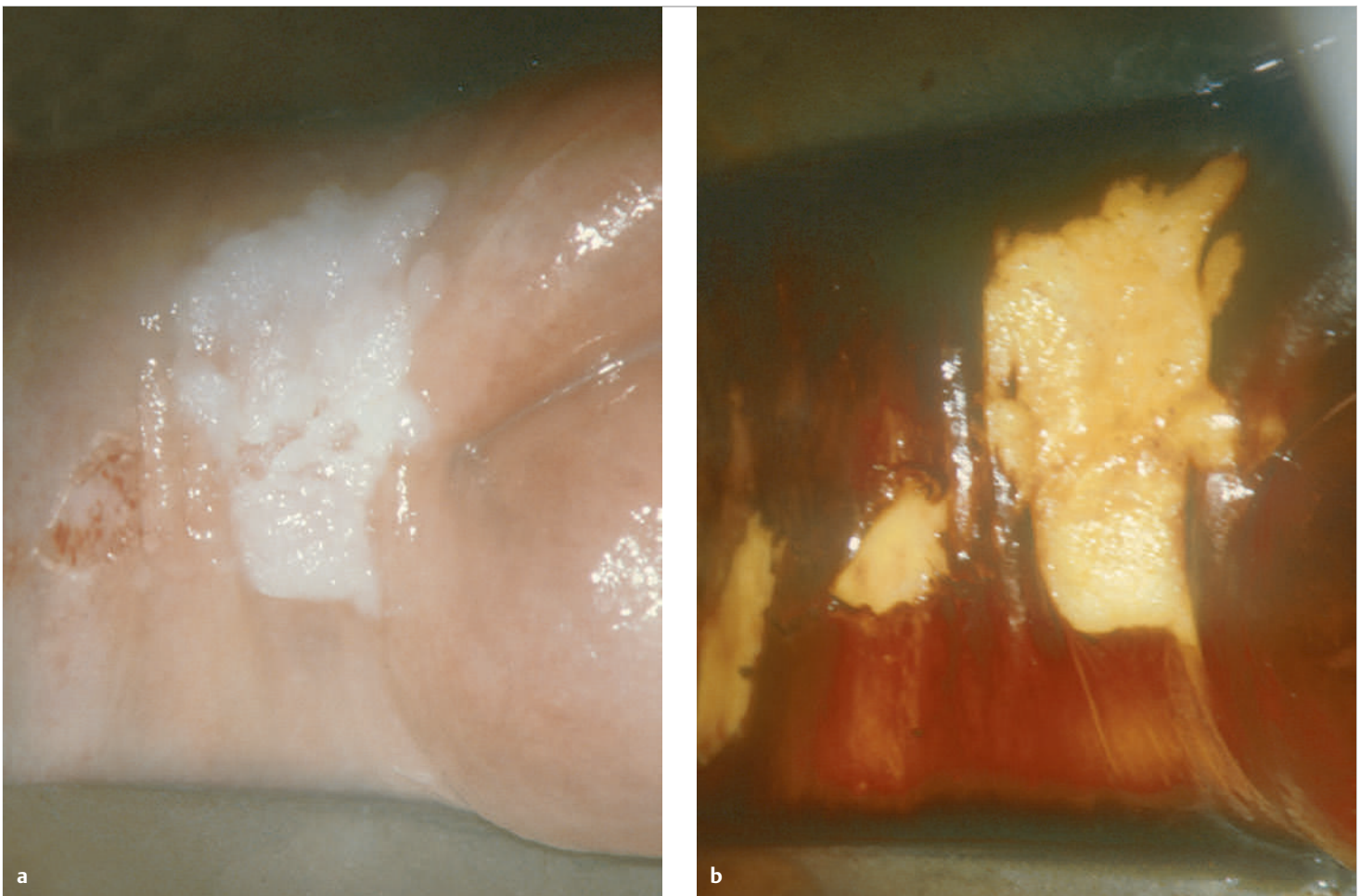


Fig. 14.2 HG-VAIN (a) before and (b) after Lugol's solution. The small erosion next to the lesion is an artifact caused by the speculum.

After application of acetic acid, vaginal SIL is usually acetowhite with sharp borders and a granular surface appearance (► Fig. 14.2). Occasionally, there is a punctation. Mosaic or keratosis is rarely found. The colposcopic appearance of vaginal SIL can be different from that of CIN and may manifest only as iodine-yellow epithelium. Thus the application of iodine is important. After iodine, vaginal SIL usually stains light yellow (► Fig. 14.3). Interpretation of Lugol's test can be difficult in postmenopausal

patients with atrophy. The application of a topical estrogen for up to 3 to 4 weeks can be helpful.

The 2011 International Federation for Cervical Pathology and Colposcopy (IFCPC) colposcopic terminology of the vagina²⁴ distinguishes minor and major lesions, so as to improve the correlation with histology and implications for treatment. Atypical and fragile vessels and lesions with an irregular surface and ulceration are suspicious for invasive disease (► Fig. 14.4)

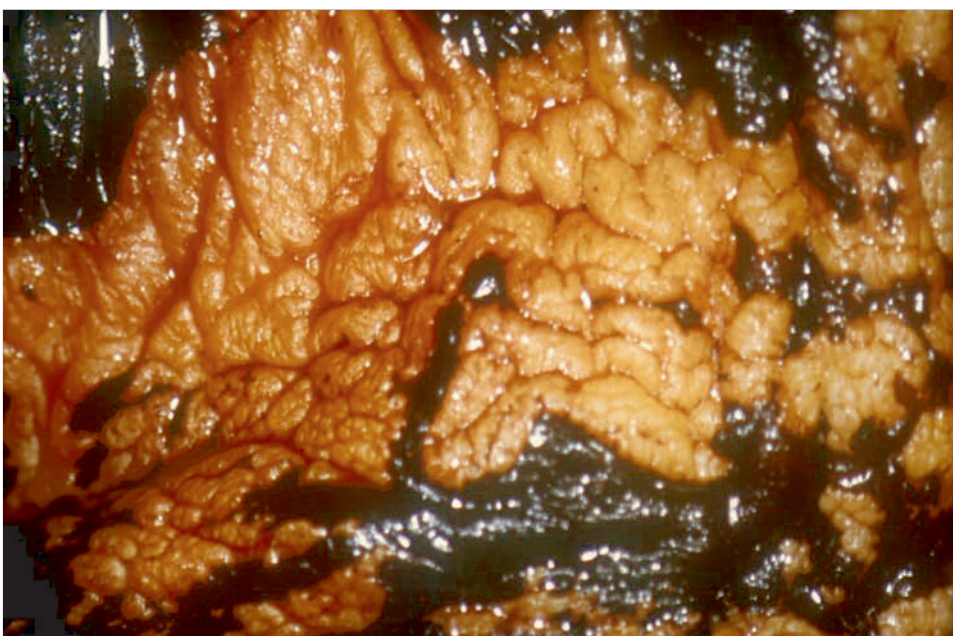


Fig. 14.3 HG-VAIN after Lugol's solution. The slightly elevated lesions stain light yellow.

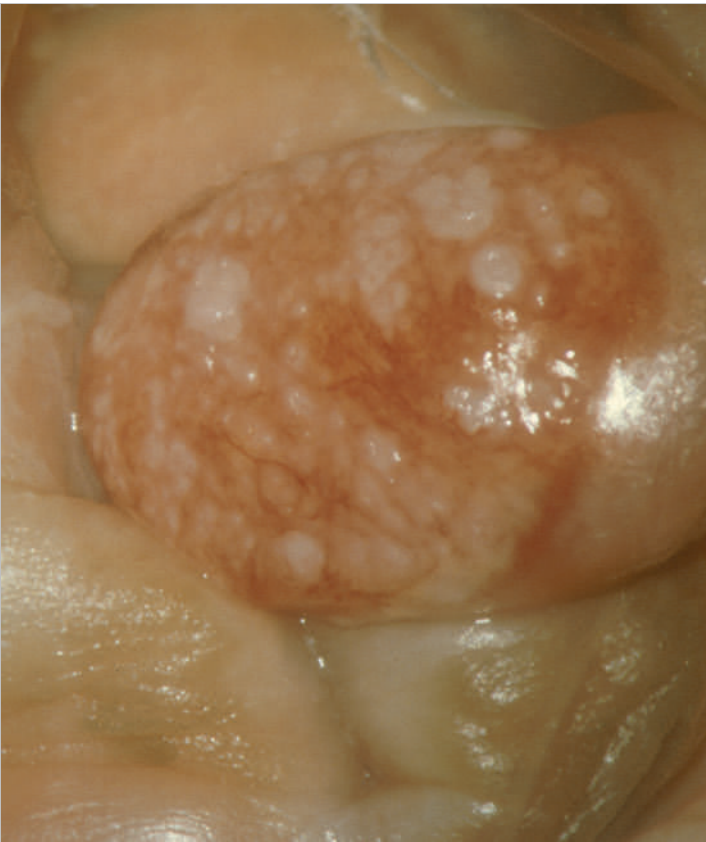


Fig. 14.4 Invasive vaginal cancer. Note the evident atypical vessels.

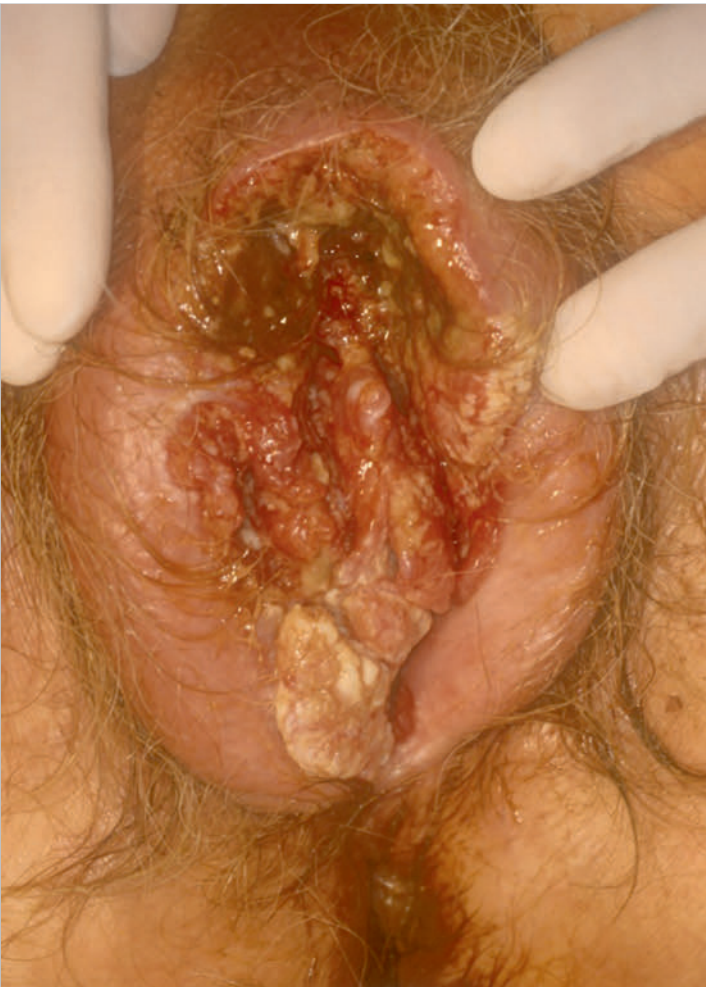

Fig. 14.6 Vulval cancer with infiltration of the vagina.

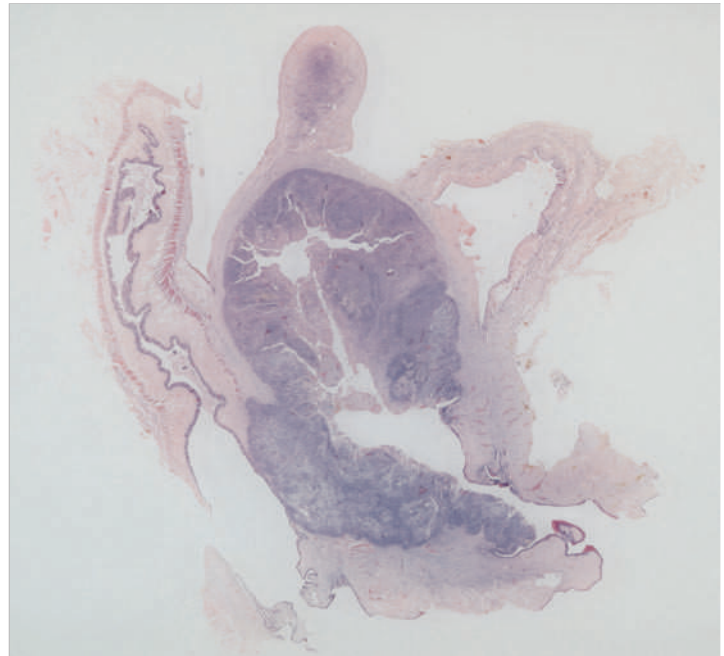


Fig. 14.5 Cervical cancer with extensive infiltration of the vagina. Giant frontal section of an exenteration specimen.

The vagina is frequently involved by advanced primary cancers of neighboring organs such as the cervix, vulva, and rectum (► Fig. 14.5, ► Fig. 14.6).

14.4.3 Cytology

Persisting abnormal cervical cytology in a patient with a colposcopically normal cervix should prompt exact inspection of the vagina. Although patients with the cytologic changes of LSIL may not have an identifiable lesion, cytologic findings of HSIL generally are associated with a corresponding colposcopic and histologic lesion.

14.4.4 Biopsy

Biopsy should be performed on any visible lesions to define the diagnosis and rule out invasion. Injection of local anesthetic is usually not necessary. Histologic examination can also be performed with abrasion of vaginal mucosal fragments. We use small sieves to avoid losing small mucosal fragments (► Fig. 14.7).

14.4.5 Biomarkers

Differentiating between low-risk and high-risk HPV infection is important because LSIL containing HPV 6 or 11 is histologically indistinguishable from LSIL associated with high-risk HPVs. It may well be that only high-risk HPV infections have the potential to induce HSIL and invasive disease. HPV testing is also used in the follow-up of patients treated for vaginal SIL.²⁵

Staining for p16^{INK4a} with or without Ki-67 can be helpful to triage HPV-induced SIL and avoid overtreatment. SIL with negative staining tends to regress, whereas SIL with positive staining denotes transforming HPV infection. These lesions trend to persist or progress (► Fig. 14.8).



Fig. 14.7 Small sieves for histologic processing of vaginal abrasions.

14.5 Histologic Terminology and Classification

In 2012 the Lower Anogenital Squamous Terminology (LAST) Project recommended a uniform two-tiered terminology for HPV-associated squamous disease across all anogenital tract tissues. This terminology distinguishes between LG or HG squamous intraepithelial lesions.²⁷

The WHO has adapted the 2014 classification of vaginal lesions accordingly as LSIL (formerly mild dysplasia) and HSIL (formerly VAIN 2/3, carcinoma in situ).²⁶

14.6 Histomorphology of Vaginal SIL

The microscopic features of vaginal SIL are analogous to those of CIN (see Chapter 4). The spectrum of vaginal SIL includes lesions classified as condylomas (LSIL of the vagina, VAIN 1) and lesions classified as high-grade vaginal intraepithelial neoplasia (HSIL of the vagina, VAIN 2 and 3). Histologically, LSIL of the vagina parallels CIN I and includes exophytic and flat condyloma. HSIL of the vagina is characterized by nuclear abnormalities including enlargement with irregular shape, hyperchromasia, and irregular condensation of chromatin at all levels of the epithelium. Increased mitotic activity with abnormal figures, acanthosis, and dyskeratosis occurs. The differential diagnosis includes atrophy, radiation changes, and immature squamous metaplasia in women with vaginal adenosis.

14.7 Management of SIL

Treatment is planned according to the number, extent, and location of lesions, their grade, and previous treatments as well as patient age and preference. HPV testing with p16^{INK4a} staining is helpful.

14.7.1 LSIL of the Vagina

LSIL often regresses and most often is not associated with neoplastic transformation. Expectant management can be appropriate initially. Patients with nonsuspicious colposcopy of the vagina and only mild cytologic abnormalities do not require treatment. Patients can follow up with a Pap test and colposcopy every 6 months. If associated with high-risk HPV, LSIL can progress.

14.7.2 HSIL of the Vagina

HSIL requires treatment. Up to 10 to 28% of patients are subsequently found to have early invasion.^{11,28,29}



Fig. 14.8 p16^{INK4a}-positive HSIL of the vagina.

14.7.3 Surgical Therapy

Surgical modalities include excision and ablation. The aim is to remove all visibly affected areas with a 3- to 5-mm margin of normal-appearing mucosa. The major advantage of laser ablation is the ability to control the depth and width of ablation under direct vision through the colposcope. As the thickness of the vaginal epithelium affected by SIL is 0.1 to 1.4 mm,³⁰ vaporization should be done to a depth of 2 mm. In patients after hysterectomy with lesions located in the dimples of the vaginal vault, excision should be considered prior to ablation to rule out occult invasive cancer. If a larger area is involved, a partial colpectomy (vaginectomy) can be indicated.

Invasion should be ruled out as far as possible before ablative therapy. In a study of 32 patients with HSIL who underwent upper vaginectomy, nine (28%) had occult invasive disease.²⁹ In a series of 105 patients treated with upper vaginectomy for HSIL, 12% had occult invasive cancer.²⁸

Surgery is successful in about 70 to 80% of cases.^{7,31,32} HSIL following radiation may be more refractory to treatment, more likely to recur, and more likely to progress to invasive cancer than HSIL not associated with radiation therapy.³³

14.7.4 Medical Therapy

Imiquimod is effective in the management of vaginal SIL in the background of HPV infection and is helpful for multifocal lesions.^{34,35,36,37,38} Our practice is to use imiquimod 2.5% vaginal suppositories (week 1 and 2: one vaginal suppository per week; week 3 and 4: two vaginal suppositories per week; after week 5: three suppositories/week for a maximum of 16 weeks). Patients need to be counselled regarding side effects (flu-like symptoms, fever) and off-label use.

Treatment with 5-fluorouracil (5-FU) cream has been reported as an option for VAIN after radiation, VAIN in immunocompromised women, and multifocal VAIN refractory to imiquimod and too extensive to treat with laser vaporization.^{39,40} Usually 1 to 2 mL of 5% 5-FU cream is administered once a week under close observation and stopped when the surface of the lesion peels away. The major complication with 5-FU is sloughing of the vaginal epithelium that will not heal.

14.7.5 Other Treatment Modalities

Electrocoagulation of SIL can lead to vaginal stenosis and is not recommended.

Loop excision is considered contraindicated because of the risk of perforation of the vagina. Radiotherapy has a limited role in the primary treatment but has a role in refractory cases and as an adjunct to surgery in early invasive carcinoma.²⁸ Interferon injection⁴¹ and cavitation ultrasonic surgical aspiration^{42,43} have also been proposed for the treatment of vaginal SIL.

Patients after treatment for preinvasive disease retain a risk for developing invasive disease (in the 2 to 5% range) and should be followed up accordingly.^{13,16,44} We follow up with patients after treatment of vaginal HSIL with Pap tests and colposcopy every 6 months for at least 2 years. HPV testing is an additional method to predict the persistence or recurrence of disease after treatment.⁹

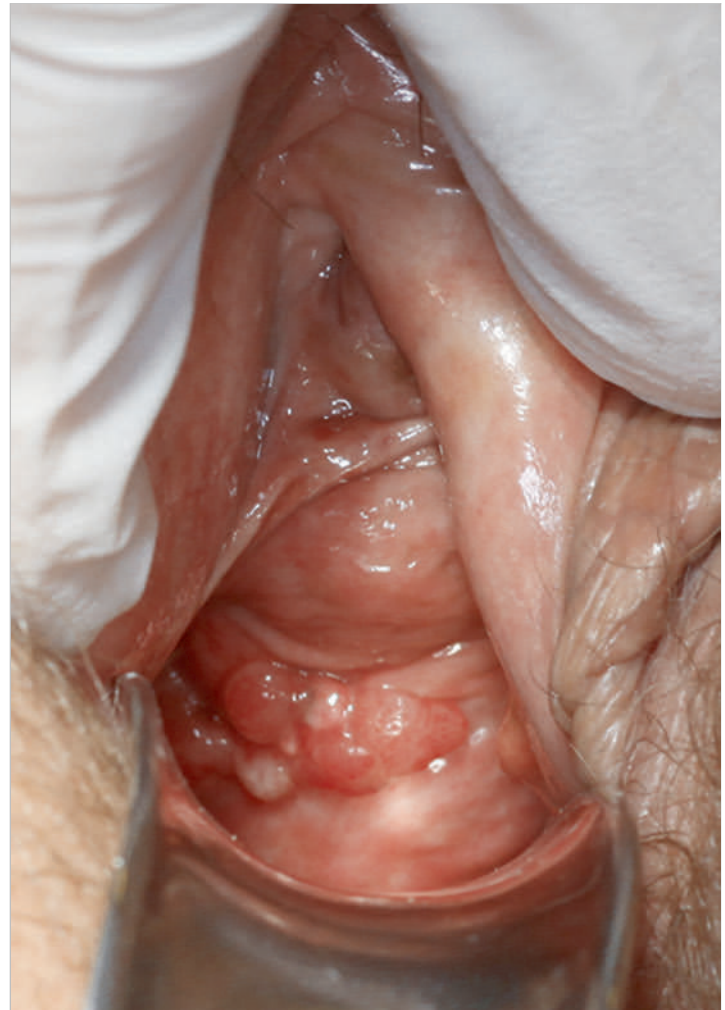

Fig. 14.9 Amelanotic melanoma of the vagina.

14.8 Vaginal Melanoma

Vaginal melanoma (invasive and in situ) is very rare. As a mucosal melanoma, its biology and behavior are distinct from that of cutaneous melanoma. Amelanotic lesions may be detected on the basis of abnormal cytology and colposcopy (► Fig. 14.9). Invasive vaginal melanoma is frequently multifocal and has a substantial in situ component, which renders complete surgical resection difficult. Local and distant recurrences are common even when negative margins are achieved. Outcomes are poor.⁴⁵

References

- [1] Fritsch H, Hoermann R, Bitsche M. Development of epithelial and mesenchymal regionalization of the human fetal utero-vaginal anlagen. *J Anat* 2013; 222: 462–472
- [2] De Vuyst H, Clifford GM, Nascimento MC, Madeleine MM, Franceschi S. Prevalence and type distribution of human papillomavirus in carcinoma and intraepithelial neoplasia of the vulva, vagina and anus: a meta-analysis. *Int J Cancer* 2009; 124: 1626–1636
- [3] Sherman JF, Mount SLO, Evans MF, Skelly J, Simmons-Arnold L, Eltabbakh GH. Smoking increases the risk of high-grade vaginal intraepithelial neoplasia in women with oncogenic human papillomavirus. *Gynecol Oncol* 2008; 110: 396–401
- [4] Bowen-Simpkins P, Hull MGR. Intraepithelial vaginal neoplasia following immunosuppressive therapy treated with topical 5-Fu. *Obstet Gynecol* 1975; 46: 360–362
- [5] Jamieson DJ, Paramsothy P, Cu-Uvin S, Duerr A HIV Epidemiology Research Study Group. Vulvar, vaginal, and perianal intraepithelial neoplasia in women

- with or at risk for human immunodeficiency virus. *Obstet Gynecol* 2006; 107: 1023–1028
- [6] Chiu TL, Jones RW. Multifocal multicentric squamous cell carcinomas arising in vulvovaginal lichen planus. *J Low Genit Tract Dis* 2011; 15: 246–247
- [7] Gurumurthy M, Cruickshank ME. Management of vaginal intraepithelial neoplasia. *J Low Genit Tract Dis* 2012; 16: 306–312
- [8] Graham JB, Meigs JV. Recurrence of tumor after total hysterectomy for carcinoma in situ. *Am J Obstet Gynecol* 1952; 64: 1159–1162
- [9] Frega A, Sopracordevole F, Assorgi C et al. Vaginal intraepithelial neoplasia: a therapeutic dilemma. *Anticancer Res* 2013; 33: 29–38
- [10] Diakomanolis E, Stefanidis K, Rodolakis A et al. Vaginal intraepithelial neoplasia: report of 102 cases. *Eur J Gynaecol Oncol* 2002; 23: 457–459
- [11] Rome RM, England PG. Management of vaginal intraepithelial neoplasia: A series of 132 cases with long-term follow-up. *Int J Gynecol Cancer* 2000; 10: 382–390
- [12] Rutledge F. Cancer of the vagina. *Am J Obstet Gynecol* 1967; 97: 635–655
- [13] Sillman FH, Fruchter RG, Chen YS, Camilien L, Sedlis A, McTigue E. Vaginal intraepithelial neoplasia: risk factors for persistence, recurrence, and invasion and its management. *Am J Obstet Gynecol* 1997; 176: 93–99
- [14] Audet-Lapointe P, Body G, Vauclair R, Drouin P, Ayoub J. Vaginal intraepithelial neoplasia. *Gynecol Oncol* 1990; 36: 232–239
- [15] Schockaert S, Poppe W, Arbyn M, Verguts T, Verguts J. Incidence of vaginal intraepithelial neoplasia after hysterectomy for cervical intraepithelial neoplasia: a retrospective study. *Am J Obstet Gynecol* 2008; 199: e1–e5
- [16] Dodge JA, Eltabbakh GH, Mount SL, Walker RP, Morgan A. Clinical features and risk of recurrence among patients with vaginal intraepithelial neoplasia. *Gynecol Oncol* 2001; 83: 363–369
- [17] Nwabine NJ, Monaghan JM. Vaginal epithelial abnormalities in patients with CIN: clinical and pathological features and management. *Br J Obstet Gynaecol* 1991; 98: 25–29
- [18] Patten SF, Reagan J, Obenauf M, Ballard LA. Postirradiation dysplasia of uterine cervix and vagina: an analytical study of the cells. *Cancer* 1963; 16: 173–182
- [19] Wentz WB, Reagan JW. Clinical significance of postirradiation dysplasia of the uterine cervix. *Am J Obstet Gynecol* 1970; 106: 812–817
- [20] Geelhoed GW, Henson DE, Taylor PT, Ketcham AS. Carcinoma in situ of the vagina following treatment for carcinoma of the cervix: a distinctive clinical entity. *Am J Obstet Gynecol* 1976; 124: 510–516
- [21] Santin AD, Hermonat PL, Ravaggi A, Chiriva-Internati M, Pecorelli S, Parham GP. Radiation-enhanced expression of E6/E7 transforming oncogenes of human papillomavirus-16 in human cervical carcinoma. *Cancer* 1998; 83: 2346–2352
- [22] Talia KL, Scurry J, Manolitsas T, McCluggage WG. Primary vaginal mucinous adenocarcinoma of gastric type arising in adenosis: a report of 2 cases, 1 associated with uterus didelphys. *Int J Gynecol Pathol* 2012; 31: 184–191
- [23] Can B, Gün S, Aydin O, Kandemir B. Primary intestinal-type adenoma of the vagina arising directly from endocervical-type adenosis: a case report. *J Reprod Med* 2012; 57: 68–73
- [24] Bornstein J, Bentley J, Bösze P et al. 2011 colposcopic terminology of the International Federation for Cervical Pathology and Colposcopy. *Obstet Gynecol* 2012; 120: 166–172
- [25] Alonso I, Felix A, Torné A et al. Human papillomavirus as a favorable prognostic biomarker in squamous cell carcinomas of the vagina. *Gynecol Oncol* 2012; 125: 194–199
- [26] Kurman RJ, Carcangiu ML, Herrington CS, Young RH (eds.). *WHO classification of Tumors of the Female Reproductive Organs*. 4th Ed. Lyon, France: IARC Press, 2014.
- [27] Waxman AG, Chelmos D, Darragh TM, Lawson H, Moscicki AB. Revised terminology for cervical histopathology and its implications for management of high-grade squamous intraepithelial lesions of the cervix. *Obstet Gynecol* 2012; 120: 1465–1471
- [28] Indermaur MD, Martino MA, Fiorica JV, Roberts WS, Hoffman MS. Upper vaginectomy for the treatment of vaginal intraepithelial neoplasia. *Am J Obstet Gynecol* 2005; 193: 577–580, discussion 580–581
- [29] Hoffman MS, DeCesare SL, Roberts WS, Fiorica JV, Finan MA, Cavanagh D. Upper vaginectomy for in situ and occult, superficially invasive carcinoma of the vagina. *Am J Obstet Gynecol* 1992; 166: 30–33
- [30] Benedet JL, Wilson PS, Matisic JP. Epidermal thickness measurements in vaginal intraepithelial neoplasia. A basis for optimal CO2 laser vaporization. *J Reprod Med* 1992; 37: 809–812
- [31] Hatch KD. Vaginal intraepithelial neoplasia (VAIN). *Int J Gynaecol Obstet* 2006; 94: S40–S43
- [32] Blanchard P, Monnier L, Dumas I et al. Low-dose-rate definitive brachytherapy for high-grade vaginal intraepithelial neoplasia. *Oncologist* 2011; 16: 182–188
- [33] Liao JB, Jean S, Wilkinson-Ryan I et al. Vaginal intraepithelial neoplasia (VAIN) after radiation therapy for gynecologic malignancies: a clinically recalcitrant entity. *Gynecol Oncol* 2011; 120: 108–112
- [34] Iavazzo C, Pitsouni E, Athanasiou S, Falagas ME. Imiquimod for treatment of vulvar and vaginal intraepithelial neoplasia. *Int J Gynaecol Obstet* 2008; 101: 3–10
- [35] Haidopoulos D, Diakomanolis E, Rodolakis A, Voulgaris Z, Vlachos G, Intsakiis A. Can local application of imiquimod cream be an alternative mode of therapy for patients with high-grade intraepithelial lesions of the vagina? *Int J Gynecol Cancer* 2005; 15: 898–902
- [36] Buck HW, Guth KJ. Treatment of vaginal intraepithelial neoplasia (primarily low grade) with imiquimod 5% cream. *J Low Genit Tract Dis* 2003; 7: 290–293
- [37] Diaz-Arrastia C, Arany I, Robazetti SC et al. Clinical and molecular responses in high-grade intraepithelial neoplasia treated with topical imiquimod 5%. *Clin Cancer Res* 2001; 7: 3031–3033
- [38] Diakomanolis E, Haidopoulos D, Stefanidis K. Treatment of high-grade vaginal intraepithelial neoplasia with imiquimod cream. *N Engl J Med* 2002; 347: 374
- [39] Krebs HB. Treatment of vaginal intraepithelial neoplasia with laser and topical 5-fluorouracil. *Obstet Gynecol* 1989; 73: 657–660
- [40] Murta EF, Neves Junior MA, Sempionato LR, Costa MC, Maluf PJ. Vaginal intraepithelial neoplasia: clinical-therapeutic analysis of 33 cases. *Arch Gynecol Obstet* 2005; 272: 261–264
- [41] Mardegan MC, Ramos MC, Adad SJ, Michelin MA, Shimba D, Murta EF. Immunological evaluation of vaginal secretion in patients with high-grade cervical intraepithelial neoplasia treated with intralesional interferon alpha-2b. *Eur J Gynaecol Oncol* 2011; 32: 297–302
- [42] Robinson JB, Sun CC, Bodurka-Bevers D, Im DD, Rosenshein NB. Cavitational ultrasonic surgical aspiration for the treatment of vaginal intraepithelial neoplasia. *Gynecol Oncol* 2000; 78: 235–241
- [43] Matsuo K, Chi DS, Walker LD, Rosenshein NB, Im DD. Ultrasonic surgical aspiration for vaginal intraepithelial neoplasia. *Int J Gynaecol Obstet* 2009; 105: 71–73
- [44] Yalcin OT, Rutherford TJ, Chambers SK, Chambers JT, Schwartz PE. Vaginal intraepithelial neoplasia: treatment by carbon dioxide laser and risk factors for failure. *Eur J Obstet Gynecol Reprod Biol* 2003; 106: 64–68
- [45] Frumovitz M, Etchepareborda M, Sun CC et al. Primary malignant melanoma of the vagina. *Obstet Gynecol* 2010; 116: 1358–1365

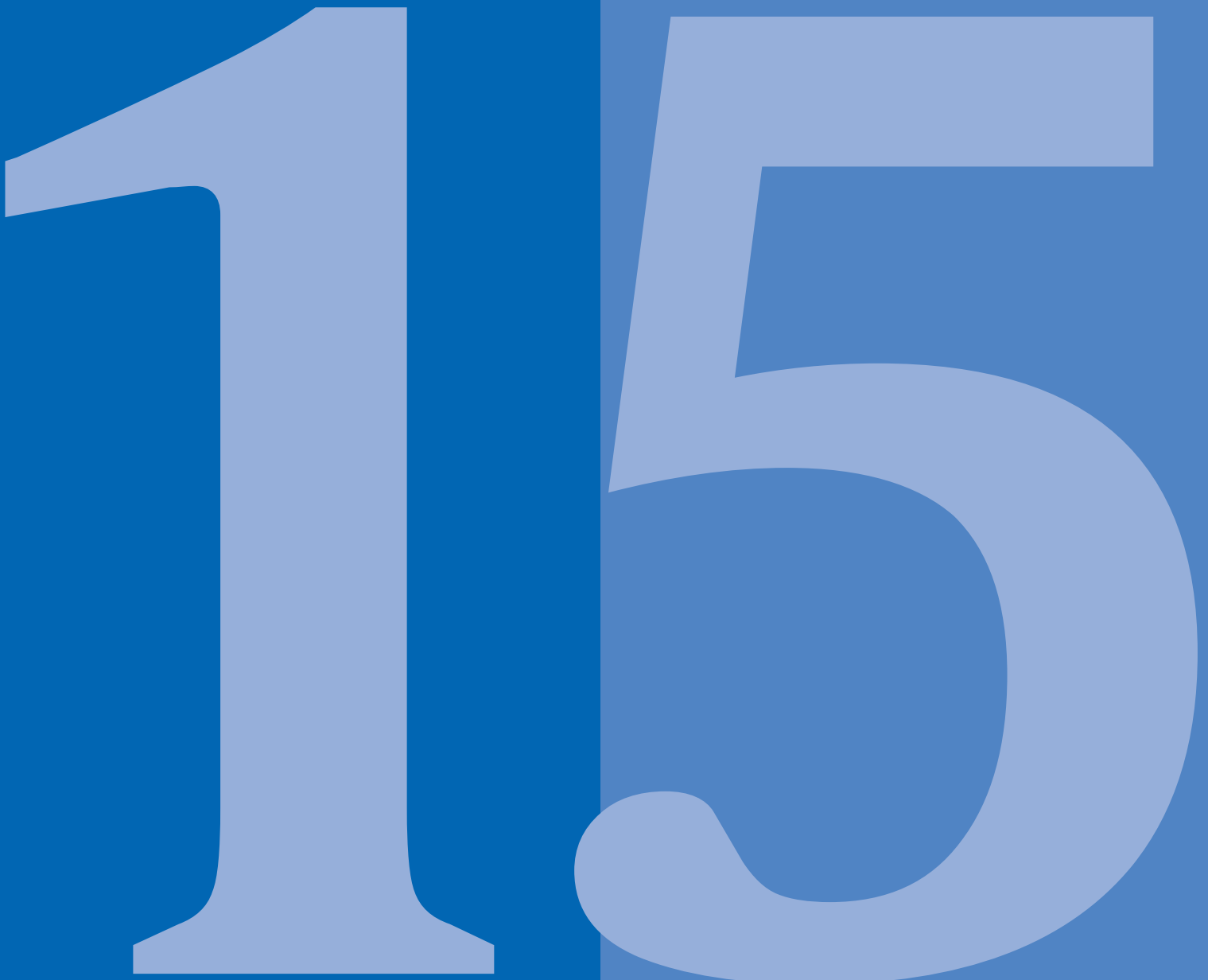Further Reading

- Reich O, Fritsch H. The developmental origin of cervical and vaginal epithelium and their clinical consequences - A systematic review. *J Low Genit Tract Dis* 2014; 18: 358–360
- Song JH, Lee JH, Lee JH et al. High-dose-rate brachytherapy for the treatment of vaginal intraepithelial neoplasia. *Cancer Res Treat* 2014; 46: 74–80
- Zeligs KP, Byrd K, Tarney CM et al. A clinicopathologic study of vaginal intraepithelial neoplasia. *Obstet Gynecol* 2013; 122: 1223–1230

Chapter 15

Colposcopy of the Perianal Region

15.1	Anatomy and Histology	216
15.2	Anal Carcinogenesis	216
15.3	Anal Intraepithelial Neoplasia	216
15.4	Diagnostic Methods for AIN	217
15.5	Histologic Terminology and Classification	218
15.6	Management of AIN	218



15 Colposcopy of the Perianal Region

15.1 Anatomy and Histology

The anus consists of the anal canal and the anal margin. The anal canal begins at the apex of the anal sphincter complex, where the rectum enters the puborectalis sling, and ends with the squamous mucosa blending with the perianal skin. This roughly coincides with the palpable intersphincteric groove. Immediately proximal to the dentate line, a narrow zone of transitional mucosa is variably present—the anal transformation zone (TZ). Distal to this, the mucosa consists of squamous epithelium devoid of hairs and glands. The anal margin extends distal to the anal verge (the junction of the hair-bearing skin) (► Fig. 15.1).^{1,2,3}

15.2 Anal Carcinogenesis

About 80% of anal cancers are of squamous cell origin, with the remainder being adenocarcinomas.² More than 85% of anal cancers are associated with human papillomavirus (HPV)⁴ and develop via anal intraepithelial neoplasia (AIN).^{5,6} In HPV-associated anal cancer, HPV 16 predominates, followed by HPV 18, as well as HPV 33 and HPV 59.⁷

The entry of HPV is most likely by way of skin abrasions. Anal intercourse is a likely risk factor.^{8,9} The proximity of the vaginal introitus to the anus also facilitates nonsexual and autoinoculation in women via vaginal secretions, digital transfer, or transfer of fomites.¹⁰ Women with other HPV-related gynecologic neoplasms are at increased risk for developing anal cancer.¹¹

A minority of squamous cell carcinomas of the anus develop independently of HPV in a background of lichen sclerosus or lichen planus (► Fig. 15.2).^{12,13} The mechanism of HPV-independent carcinogenesis of the anus has not yet been elucidated but seems to parallel that of the vulva (► Fig. 15.3).

Topographically, anal cancers are located in the anal canal or, to a lesser extent, at the anal margin. Most anal cancers originate

from the anal transformation zone (linea dentata) of the anal canal.⁴

15.3 Anal Intraepithelial Neoplasia

The AIN lesions can be intra-anal or perianal. AIN can involve the anal canal by extending from the perianal skin inward or into the canal in isolation. Thus, evidence of perianal HPV infection must prompt the possibility of AIN within the anal canal. More than 75% of AIN lesions are located on the anal TZ.⁴ Risk factors are unprotected receptive anal intercourse, lifetime number of sexual partners, a history of genital warts, immunodeficiency, smoking, and a history of HPV-related gynecologic neoplasm including vulvar intraepithelial neoplasia (VIN) and cervical intraepithelial neoplasia (CIN).^{5,11,14}

AIN can also present as part of a multifocal disease process involving any or all anogenital sites (► Fig. 15.4). In a study of immunocompetent women with CIN, VIN, or vaginal intraepithelial neoplasia (VAIN), 12% had AIN and 8% had high-grade (HG)-AIN.¹⁵ Another study of immunocompetent women found AIN in 17% of women with CIN, with 4% having HG-AIN.¹⁶ Interestingly, patients with multiple lesions in different areas of the female genital tract often show the same HPV type in all of the lesions.¹⁷

HPV 16, 18, 33, and 58 are the types most frequently detected in HG-AIN. The prevalence of multiple-type infections decreased from 54% in low-grade (LG)-AIN 1 to 7% in anal carcinoma.¹⁸

The rate of progression from LG-AIN to HG-AIN is reported to be 36 to 66% over 2 years; the rate of progression from HG-AIN to invasive anal cancer has been reported as 5–26% over 5 years.^{19,20,21}

Patients with AIN report pruritus and burning sensations or are asymptomatic. Clinically, AIN can present as erythroplakia,

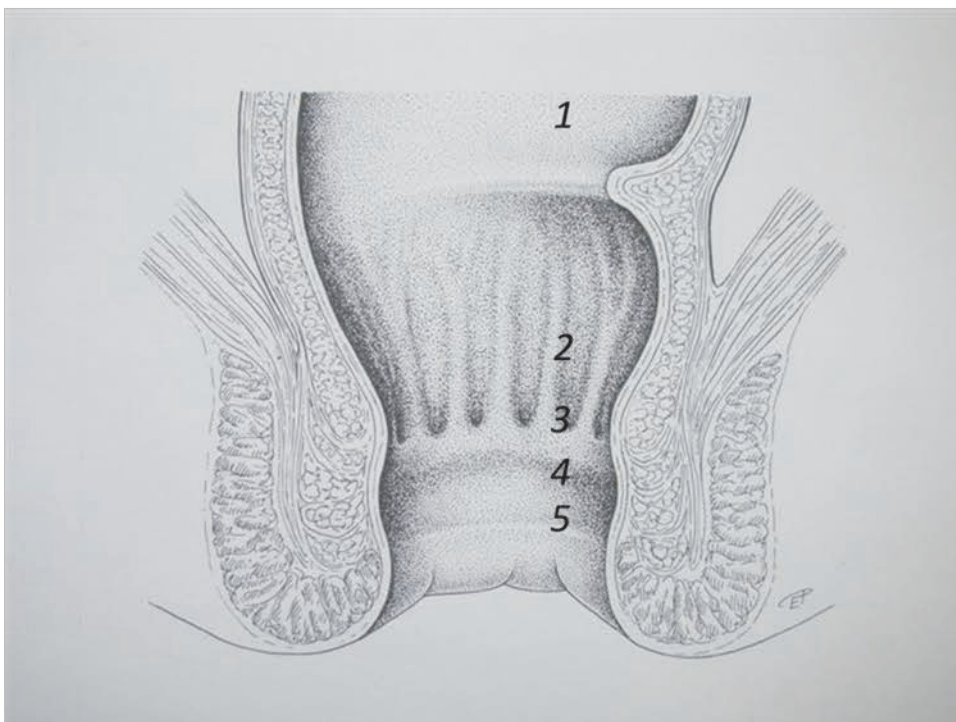


Fig. 15.1 Anatomy of the anus. 1, rectum; 2, anal transformation zone with columns of Morgagni; 3, dentate line; 4, anal canal; 5, anal margin.

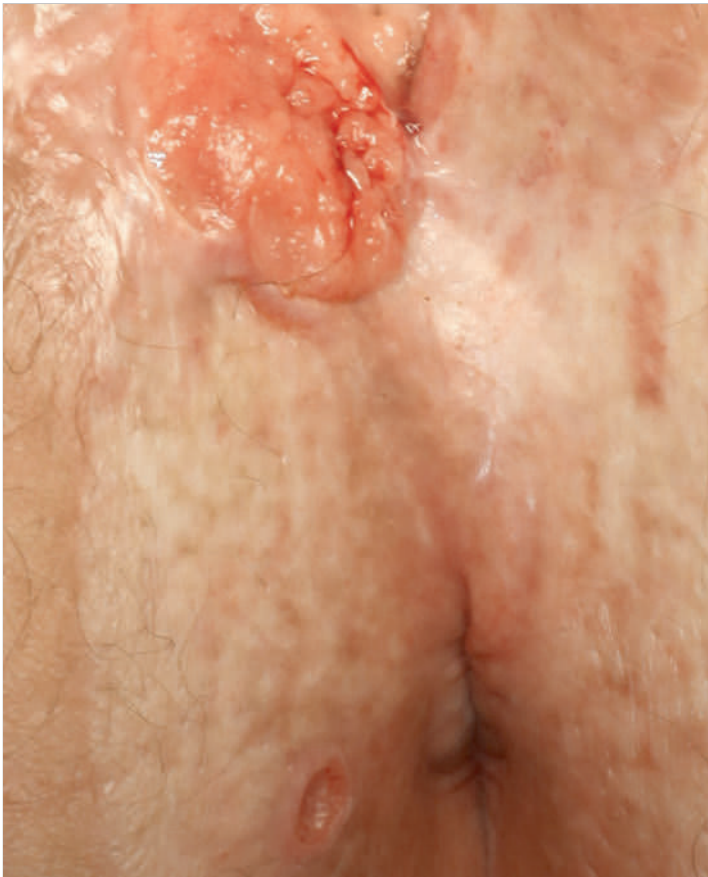

Fig. 15.2 Advanced anogenital lichen sclerosus. The leukoplakic anal margin shows an exophytic lesion and a small ulcer, both suspicious for malignancy.

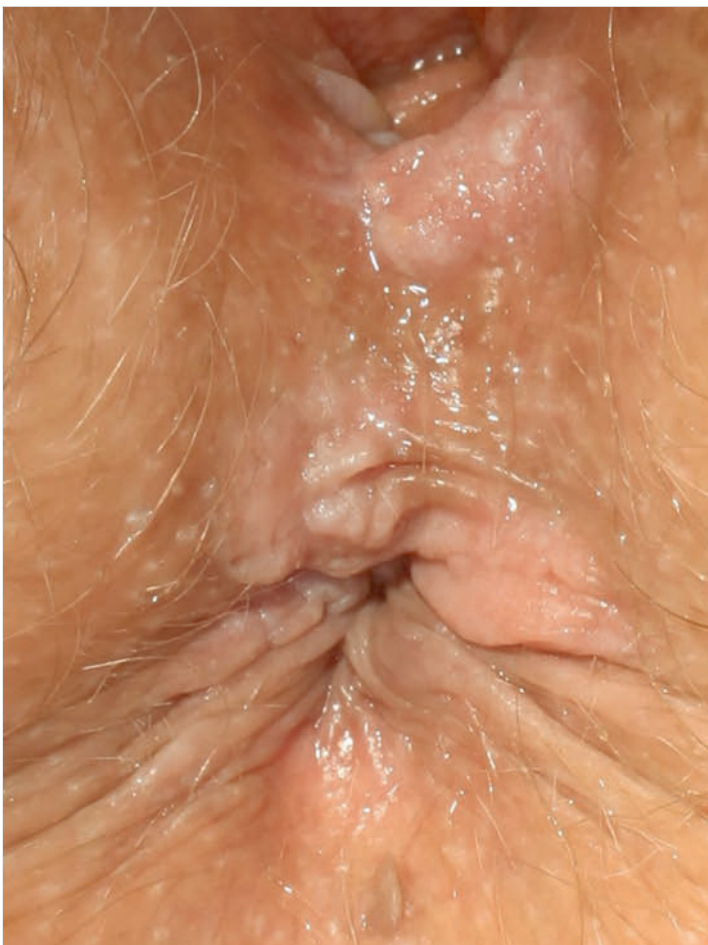

Fig. 15.4 AIN as part of multifocal HPV-associated disease. Note the perianal lesion and the lesion located at the vulva.

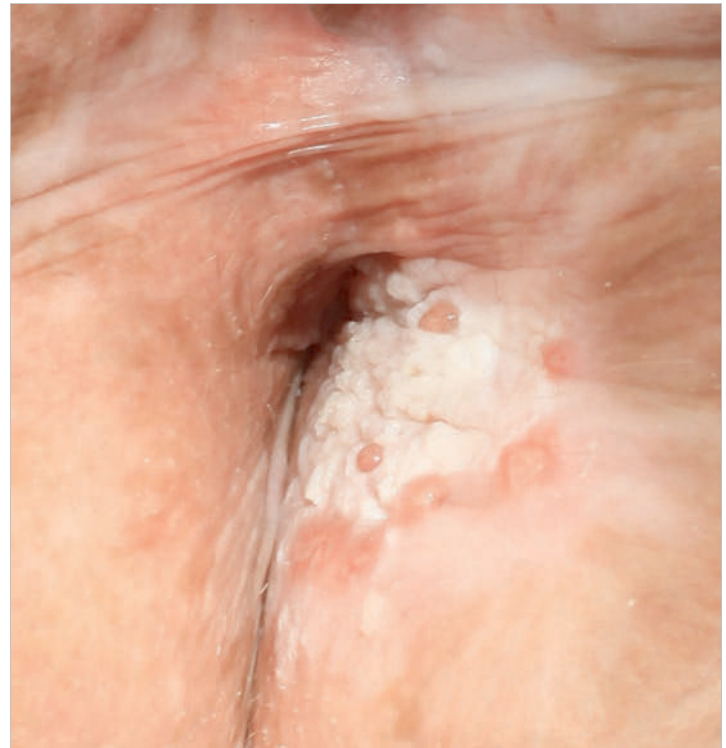

Fig. 15.3 Circumscribed leukoplakia of the anal margin in a patient with advanced anogenital lichen sclerosus. Histology showed changes similar to differentiated vulvar intraepithelial neoplasia (dVIN).

leukoplakia, pigmentation, or verrucous lesions. The lesions are usually flat and solitary; 10 to 20% of patients have multiple foci (► Fig. 15.5).²²

15.4 Diagnostic Methods for AIN

15.4.1 Colposcopy of the Anus (Anoscopy)

Anoscopy permits more precise evaluation and earlier detection of lesions than inspection with the naked eye. Perianal lesions are easily exposed by spreading the buttocks and can be visualized with a conventional colposcope. Lesions of the rectal TZ in the anal canal are visualized with an anoscope. The standard technique is to treat the perianal and anal area with 3% acetic acid for a few minutes and then insert a disposable anoscope and evaluate under magnification. The acetic acid tissue reaction causes the dysplastic tissue to appear whitish. The squamocolumnar epithelial area is examined looking for acetowhite and for abnormal vascular changes such as punctation and mosaic patterns. Lugol's solution can also be used, and suspicious areas with AIN should appear yellow against the brownish background of the normal tissue.^{23,24}

The 2011 International Federation for Cervical Pathology and Colposcopy (IFCPC) terminology for anal findings²⁵ includes acetowhite epithelium, punctation, atypical vessels, surface irregularities, and abnormal squamocolumnar junction as abnormal colposcopic findings (► Fig. 15.6, ► Fig. 15.7, ► Fig. 15.8). In contrast to other sites, the terminology does not distinguish between minor and major changes.

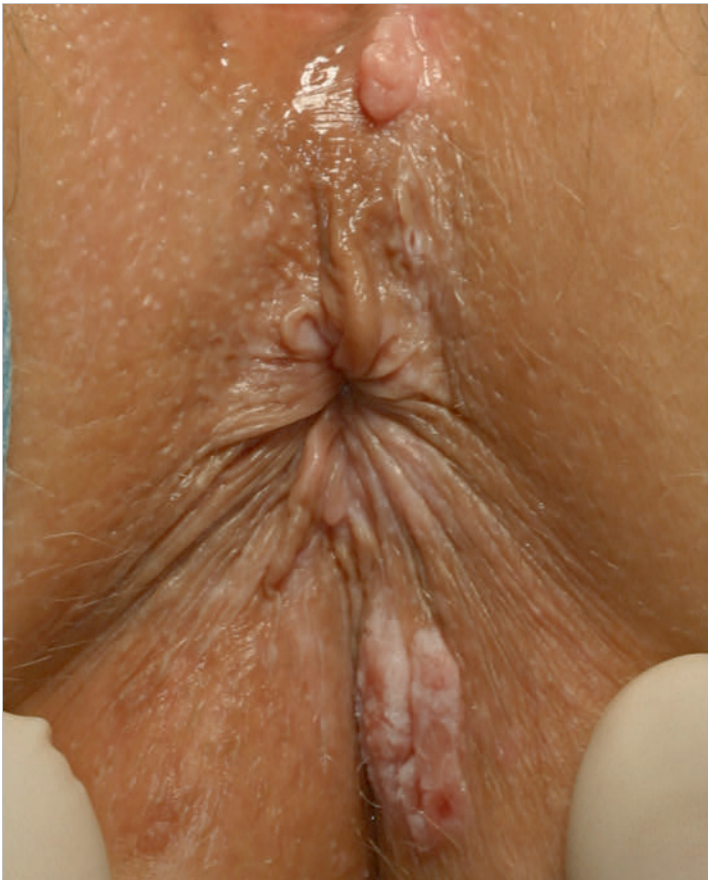

Fig. 15.5 Multiple foci of AIN. Note leucoplakia at 6 o'clock and verrucous lesion at 12 o'clock.

15.4.2 Cytology

Cytology of the anal canal is done by inserting a swab or brush into the anus and rotating it to collect the cells. Patients should avoid anal intercourse for 24 hours before the examination. The sensitivity of anal cytology for HG-AIN is 69 to 93%, the specificity is 32 to 59%.^{26,27} Keratosis may cause false-negative cytologic results. Patients who have abnormalities on cytologic testing should be referred for anoscopy with or without biopsy.

15.4.3 Biopsy

Lesions suspicious for AIN or invasive disease should undergo biopsy.

15.4.4 Biomarkers

HPV testing is performed to distinguish between low-risk and high-risk infections. HPV results are helpful for triage of unclear findings and in follow-up after treatment for AIN. Staining for p16^{INK4a} may provide additional help when deciding between treatment and expectant management.^{28,29,30}

15.5 Histologic Terminology and Classification

AIN is graded histologically, much like CIN (► Table 15.1). Use of the terms LG-AIN to describe mild dysplastic lesions including condylomatous changes (► Fig. 15.9) and HG-AIN to describe moderate and severe dysplastic lesions helps plan appropriate management.

In 2012, the Lower Anogenital Squamous Terminology (LAST) project recommended a uniform two-tiered terminology for HPV-associated squamous disease across all anogenital tract tissues.³¹

15.6 Management of AIN

Treatment methods for AIN are similar to those for VIN and can be divided into surgical and medical therapies. HG-AIN should be referred to specialists for treatment and follow-up.

15.6.1 Surgical Therapy

Surgical therapy consists of excision or ablation. The aim is to remove all visibly affected areas with a 3–5 mm margin of normal-appearing skin or mucosa (► Fig. 15.10). Lesions that may be invasive and AIN involving the perianal skin with hair and glands should generally be excised and the specimens sent for careful histology. Anogenital warts and LG-AIN can be ablated with a laser to a depth of about 2 mm. Recurrences occur in 23–80% of treated patients.³²

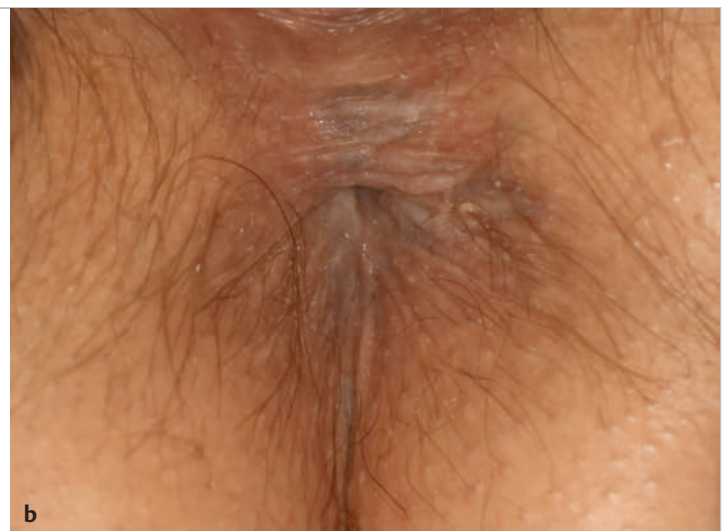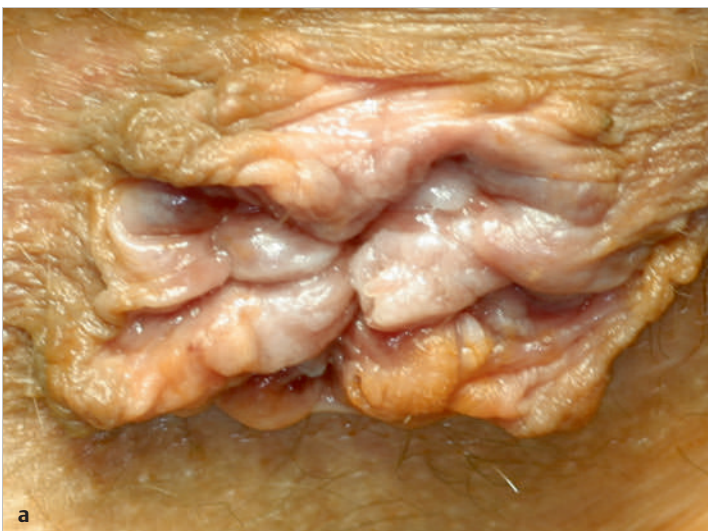


Fig. 15.6 a,b Dense acetowhite epithelium at the anal margin.

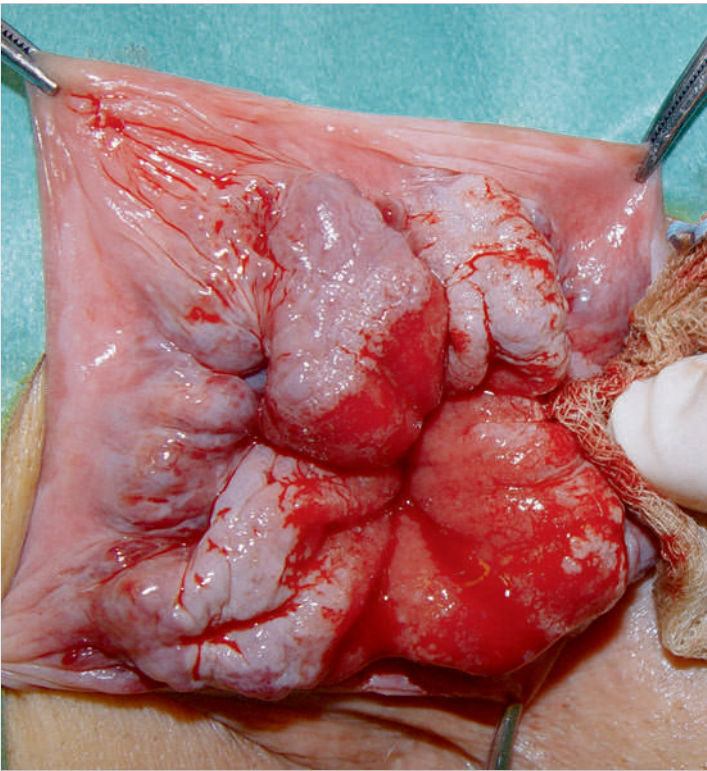


Fig. 15.7 Dense acetowhite epithelium at the anal transformation zone. (Courtesy of A. Salat.)

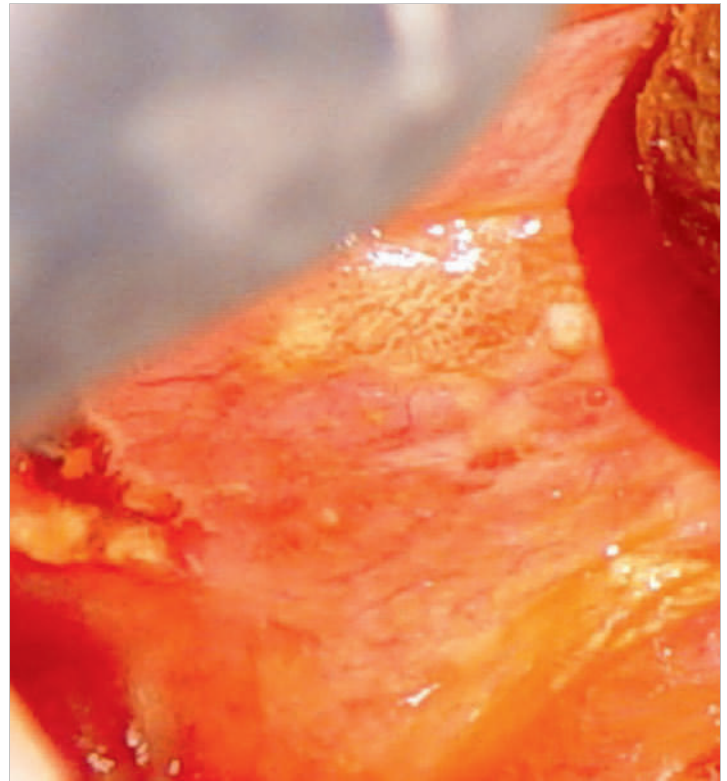


Fig. 15.8 Iodine-positive coarse punctation at the anal canal. (Courtesy of A. Salat.)

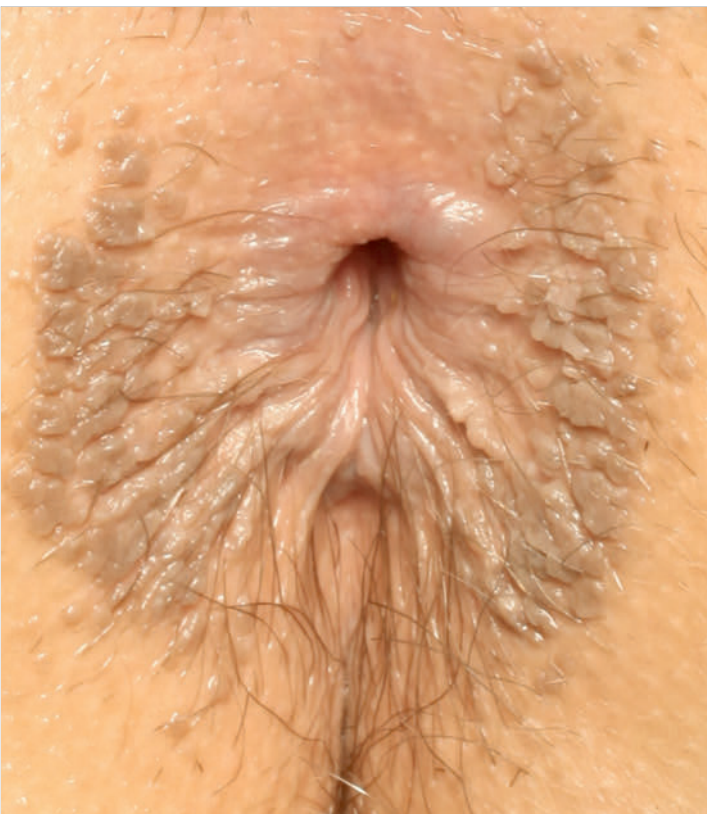

Fig. 15.9 Perianal condylomas.

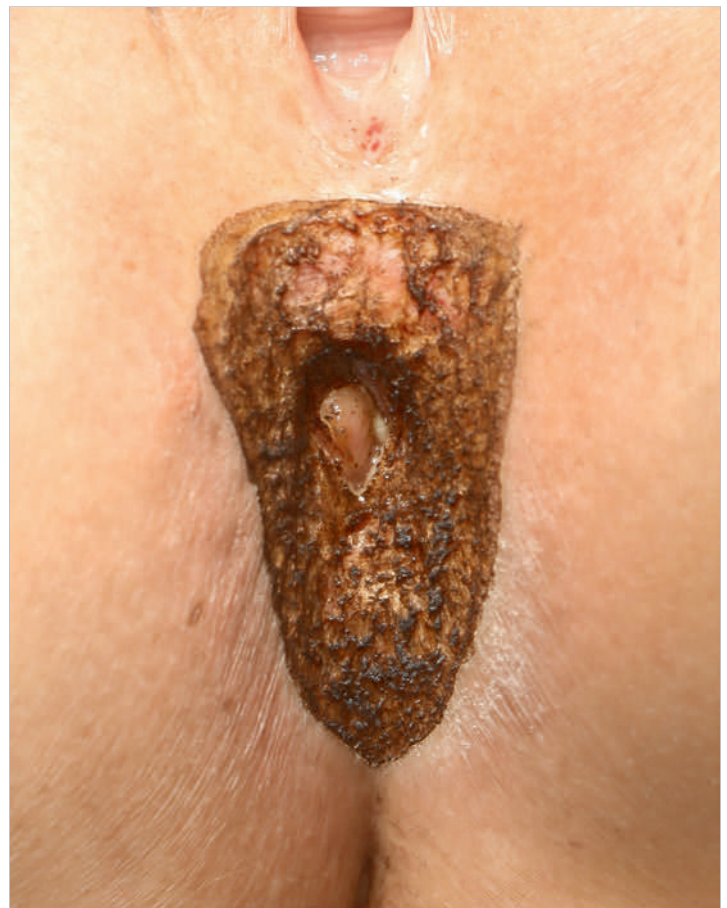

Fig. 15.10 Laser vaporization of multifocal AIN at the anal margin.

Table 15.1 Terminology of premalignant anal and perianal squamous epithelial lesions.^{28,31,36}

Classification	Synonyms
AIN, grade 1	Mild dysplasia; LG-AIN
AIN, grade 2	Moderate dysplasia; HG-AIN
AIN, grade 3	Severe dysplasia; HG-AIN; carcinoma in situ
AIN, anal intraepithelial neoplasia; HG, high grade; LG, low grade.	

15.6.2 Medical Therapy

A Cochrane review identified no consensus and few data from randomized trials on the optimal management of AIN.³³ There have been encouraging results from trials using topical imiquimod, 5-fluorouracil, and cidofovir for the treatment of HG-AIN.^{2,7,34,35} However, most of these studies have been done in men who have sex with men and thus may not apply in women. Medical treatments are frequently combined with surgical modalities, such as ablation.

References

- [1] Pandey P. Anal anatomy and normal histology. *Sex Health* 2012; 9: 513–516
- [2] Simpson JA, Scholefield JH. Diagnosis and management of anal intraepithelial neoplasia and anal cancer. *BMJ* 2011; 343: d6818
- [3] Welton ML, Sharkey FE, Kahlenberg MS. The etiology and epidemiology of anal cancer. *Surg Oncol Clin N Am* 2004; 13: 263–275
- [4] Wieland U, Kreuter A. Anal cancer and intraepithelial neoplasia. In: Phister H (ed): *Prophylaxis and early detection of HPV-related neoplasia*. Basel: Karger, 2012, 72–8
- [5] Daling JR, Madeleine MM, Johnson LG et al. Human papillomavirus, smoking, and sexual practices in the etiology of anal cancer. *Cancer* 2004; 101: 270–280
- [6] Thomas MK, Pitot HC, Liem A, Lambert PF. Dominant role of HPV16 E7 in anal carcinogenesis. *Virology* 2011; 421: 114–118
- [7] Kreuter A, Poththoff A, Brockmeyer NH et al. German Competence Network HIV/AIDS. Anal carcinoma in human immunodeficiency virus-positive men: results of a prospective study from Germany. *Br J Dermatol* 2010; 162: 1269–1277
- [8] Goodman MT, Shvetsov YB, McDuffie K et al. Acquisition of anal human papillomavirus (HPV) infection in women: the Hawaii HPV Cohort study. *J Infect Dis* 2008; 197: 957–966
- [9] Palefsky JM, Holly EA, Ralston ML, Greenblatt RM, Da Costa M. Prevalence and risk factors for anal human papillomavirus infection in human immunodeficiency virus (HIV)-positive and high-risk HIV-negative women. *J Infect Dis* 2001; 183: 383–391
- [10] Moscicki AB, Hills NK, Shiboski S et al. Risk factors for abnormal anal cytology in young heterosexual women. *Cancer Epidemiol Biomarkers Prev* 1999; 8: 173–178
- [11] Saleem AM, Paulus JK, Shapter AP, Baxter NN, Roberts PL, Ricciardi R. Risk of anal cancer in a cohort with human papillomavirus-related gynecologic neoplasia. *Obstet Gynecol* 2011; 117: 643–649
- [12] Fundarò S, Spallanzani A, Ricchi E et al. Squamous-cell carcinoma developing within anal lichen planus: report of a case. *Dis Colon Rectum* 1998; 41: 111–114
- [13] Sloan PJ, Goepel J. Lichen sclerosus et atrophicus and perianal carcinoma: a case report. *Clin Exp Dermatol* 1981; 6: 399–402
- [14] Edgren G, Sparén P. Risk of anogenital cancer after diagnosis of cervical intraepithelial neoplasia: a prospective population-based study. *Lancet Oncol* 2007; 8: 311–316
- [15] Santoso JT, Long M, Crigger M, Wan JY, Haefner HK. Anal intraepithelial neoplasia in women with genital intraepithelial neoplasia. *Obstet Gynecol* 2010; 116: 578–582
- [16] Jacyntho CM, Giraldo PC, Horta AA et al. Association between genital intraepithelial lesions and anal squamous intraepithelial lesions in HIV-negative women. *Am J Obstet Gynecol* 2011; 205: e: 1–e5
- [17] De Bie RP, van de Nieuwenhof HP, Bekkers RL et al. Patients with usual vulvar intraepithelial neoplasia-related vulvar cancer have an increased risk of cervical abnormalities. *Br J Cancer* 2009; 101: 27–31
- [18] De Vuyst H, Clifford GM, Nascimento MC, Madeleine MM, Franceschi S. Prevalence and type distribution of human papillomavirus in carcinoma and intraepithelial neoplasia of the vulva, vagina and anus: a meta-analysis. *Int J Cancer* 2009; 124: 1626–1636
- [19] Wong AK, Chan RC, Aggarwal N, Singh MK, Nichols WS, Bose S. Human papillomavirus genotypes in anal intraepithelial neoplasia and anal carcinoma as detected in tissue biopsies. *Mod Pathol* 2010; 23: 144–150
- [20] Watson AJ, Smith BB, Whitehead MR, Sykes PH, Frizelle FA. Malignant progression of anal intra-epithelial neoplasia. *ANZ J Surg* 2006; 76: 715–717
- [21] Scholefield JH, Harris D, Radcliffe A. Guidelines for management of anal intraepithelial neoplasia. *Colorectal Dis* 2011; 13 Suppl 1: 3–10
- [22] Cox NH, Eedy DJ, Morton CA. Therapy Guidelines and Audit Subcommittee, British Association of Dermatologists. Guidelines for management of Bowen's disease: 2006 update. *Br J Dermatol* 2007; 156: 11–21
- [23] Echenique I, Phillips BR. Anal warts and anal intradermal neoplasia. *Clin Colon Rectal Surg* 2011; 24: 31–38
- [24] Jay N, Berry JM, Hogeboom CJ, Holly EA, Darragh TM, Palefsky JM. Colposcopic appearance of anal squamous intraepithelial lesions: relationship to histopathology. *Dis Colon Rectum* 1997; 40: 919–928
- [25] Bornstein J, Sideri M, Tatti S, Walker P, Prendiville W, Haefner HK. Nomenclature Committee of International Federation for Cervical Pathology and Colposcopy. 2011 terminology of the vulva of the International Federation for Cervical Pathology and Colposcopy. *J Low Genit Tract Dis* 2012; 16: 290–295
- [26] Cachay ER, Agmas W, Mathews WC. Relative accuracy of cervical and anal cytology for detection of high grade lesions by colposcope guided biopsy: a cut-point meta-analytic comparison. *PLoS ONE* 2012; 7: e38956
- [27] Palefsky JM, Holly EA, Hogeboom CJ, Berry JM, Jay N, Darragh TM. Anal cytology as a screening tool for anal squamous intraepithelial lesions. *J Acquir Immune Defic Syndr Hum Retrovirol* 1997; 14: 415–422
- [28] Longacre TA, Kong CS, Welton ML. Diagnostic problems in anal pathology. *Adv Anat Pathol* 2008; 15: 263–278
- [29] Pirog EC, Quint KD, Yantiss RK. P16/CDKN2A and Ki-67 enhance the detection of anal intraepithelial neoplasia and condyloma and correlate with human papillomavirus detection by polymerase chain reaction. *Am J Surg Pathol* 2010; 34: 1449–1455
- [30] Wentzensen N, Follansbee S, Borgonovo S et al. Human papillomavirus genotyping, human papillomavirus mRNA expression, and p16/Ki-67 cytology to detect anal cancer precursors in HIV-infected MSM. *AIDS* 2012; 26: 2185–2192
- [31] Waxman AG, Chelmos D, Darragh TM, Lawson H, Moscicki AB. Revised terminology for cervical histopathology and its implications for management of high-grade squamous intraepithelial lesions of the cervix. *Obstet Gynecol* 2012; 120: 1465–1471
- [32] Marchesa P, Fazio VW, Oliart S, Goldblum JR, Lavery IC. Perianal Bowen's disease: a clinicopathologic study of 47 patients. *Dis Colon Rectum* 1997; 40: 1286–1293
- [33] Macaya A, Muñoz-Santos C, Balaguer A, Barberà MJ. Interventions for anal canal intraepithelial neoplasia. *Cochrane Database Syst Rev* 2012; 12: CD009244
- [34] Snyder SM, Siekas L, Abouafia DM. Initial Experience with Topical Fluorouracil for Treatment of HIV-Associated Anal Intraepithelial Neoplasia. *J Int Assoc Physicians AIDS Care (Chic)* 2011; 10: 83–88
- [35] Stier EA, Goldstone SE, Einstein MH et al. Safety and efficacy of topical cidofovir to treat high-grade perianal and vulvar intraepithelial neoplasia in HIV-positive men and women. *AIDS* 2013; 27: 545–551
- [36] Welton ML, Lambert R, Bosman FT. Tumours of the anal canal. In: Bosman FT, Carneiro F, Hruban RH, Theise ND (eds) *WHO classification of tumours of the digestive system*. 2010, IARC Press, Lyon

Index

5

5-fluorouracil 199, 216

A

abnormal colposcopic findings

- definitions 74–75
- topography 159, 159, 160–161
- treatment generally 164

abnormal Pap smear evaluation 6

acanthosis 29, 125

acetic acid testing

- colposcopic examination 64, 64, 65, 65, 79
- condylomas 99, 150, 159
- differential diagnosis 93, 116, 128, 129, 136
- history of 2
- mosaic 65, 94–95, 96, 129
- Nabothian follicles 133
- pregnancy 141, 142–144, 145, 147–148
- punctuation 65, 100
- squamous epithelium (metaplastic) 90

acetowhite epithelium

- anal intraepithelial neoplasia 218–219
- early stromal invasion 104–105, 107
- gland openings 93
- HSIL 53, 68, 90, 90, 91–93, 101, 103, 186, 186
- in differential diagnosis 136
- Nabothian follicles 91
- sharp borders 128, 128
- squamous epithelium 53, 68, 90, 90, 91–93, 101, 103
- topography 159–161
- vulval 186, 186

adenocarcinoma in situ (AIS)

- Arias–Stella reaction 34, 41
 - clear cell 34
 - clear cell adenocarcinoma 45
 - colposcopic evaluation of 6
 - differential histology 29, 46
 - endocervical 38–39
 - endocervical variants 45
 - endometrioid adenocarcinoma 45
 - forms of 34
 - histologic classification 45
 - histology 34, 38–39, 41, 44
 - intestinal 34, 40
 - intestinal variants 45
 - mesonephric adenocarcinoma 46
 - microinvasive 40, 46, 56, 110, 112–113
 - minimal deviation variant 45
 - morphogenesis generally 16
 - morphogenesis of 17, 19
 - mucinous adenocarcinoma 45
 - serous adenocarcinoma 46
 - signs of 110, 111–112
 - terminology history 32
 - transformation zone 112
 - villoglandular variant 45
- anal intraepithelial neoplasia

- abnormal colposcopic findings 218–219
 - acetowhite epithelium 218–219
 - anoscopy 217
 - biomarkers 218
 - biopsy 218
 - cytology 218
 - diagnostic methods 217
 - grading 219–220
 - histologic terminology, classification 218, 220
 - iodine testing 219
 - laser ablation 219
 - medical therapy 220
 - overview 216
 - rate of progression 218
 - surgical therapy 218, 219
 - symptoms 217, 218, 218
 - types 218
- anatomic anomalies 125
- anoscopy 217
- Arias–Stella reaction 34, 41
- atypical immature squamous metaplasia (AIM) 33, 37

B

basal hyperplasia 29

basaloid SIL 194, 195

Bethesda terminology 33

biomarkers

- anal intraepithelial neoplasia 218
- cervical precancer diagnosis 34
- colposcopic evaluation of 6
- HPV E6/E7 mRNA testing 35
- HPV-DNA genotyping 35
- HPV-DNA testing 34

biopsy

- anal intraepithelial neoplasia 218
 - cone, *see* conization
 - diagnostic accuracy 165
 - instruments 63, 63
 - laser cone 173–174, 177
 - SIL prevalence in 127
 - vulval 188, 189
- bleomycin 199
- blood vessels
- atypical, differential diagnosis 107, 131, 132, 135
 - cervix 27, 132
 - corkscrew, comma-shaped 134
 - differential diagnosis 90, 129, 133
 - in punctuation 133
 - pregnancy, changes in 142
 - retention cysts 89
 - squamous epithelium (metaplastic) 90
 - wide 131, 132–134
- borders, *see* sharp borders
- breastfeeding 143
- Breisky speculum 63
- bulla 76
- Burghardt, Erich 2, 39–40

C

CADM 1 methylation 38

carcinoma in situ 32

Cervarix 20

cervical adenocarcinoma, *see* adenocarcinoma in situ (AIS)

cervical cancer

- etiology 10
- frank invasive 41, 47
- invasive 38
- latency period 13
- lesions, colposcopic evaluation of 6
- lymph vascular invasion (LVSI) 40, 40, 44
- microinvasive adenocarcinoma 40, 46, 56, 110, 112–113
- microinvasive cancers 38–39, 44
- morphogenesis 14, 95, 97, 160
- natural history 10
- reserve cells 10, 11
- vaginal infiltration 210, 211

cervical glands 24

cervical intraepithelial neoplasia (CIN), *see* squamous intraepithelial lesions (SIL)

- CIN 1 (LSIL) 35, 37, 91, 95, 117–118, 127, 147
- CIN 2 (HSIL) 33, 36, 96, 100, 103, 127, 129, 145
- CIN 3 (HSIL) 36, 92–93, 96–97, 100, 103, 105–106, 127, 129
- grade 33
- histology 32

– last gland rule, *see* last gland

– last gland, topographic relationship to 28, 46, 48

– terminology 32–33

cervix

- cold-knife conization changes 124
- colposcopic appearance of 26, 49, 82
- development 27, 28
- dysplastic epithelial fields size, extent 18, 50
- epithelial plane differences 83, 86
- epithelium types 27
- iodine testing 123, 125
- vasculature 27, 132

Chrobak's probe 63, 63

Chrobak's test 57

cidofovir 197

CIN 1, *see* low-grade squamous intraepithelial lesions (LSIL)

CIN 2,3, *see* high-grade squamous intraepithelial lesions (HSIL)

clear cell adenocarcinoma 45

clobetasol propionate 204, 208

Cockscomb-like lesion 80

cold-knife conization

- cervix six weeks post 124
- diagnostic applications 165
- overview 172
- prognosis 167
- technique 172, 175
- treatment comparison 177

Collins test (toluidine blue test) 183, 183

colpitis macularis (strawberry cervix) 119–120, 145

colpophotography 2

colposcopes

- history 62

– mounts 62, 62–63

– video 63

colposcopic examination

- acetic acid test 64, 64, 65, 65, 79
 - process 63
 - colposcopic findings assessment 125
 - colposcopic–histologic correlation
 - last gland rules 155–158, 160
 - overview 154
 - peg formation rules 155–158
 - requirements 154, 159
 - vulval 186
- colposcopy
- applications of generally 6
 - Chrobak's probe 63, 63
 - containers 63
 - findings, understanding 72
 - forceps 63, 63
 - goals of 159
 - history of 2
 - instruments 62, 63
 - morphology, microscopic vs. colposcopic 46
 - role of 6
 - specula 62, 63
 - swabs 63
 - teaching 72
 - tenacula 63, 63
- columnar epithelium
- acetic acid test 65, 65
 - ectopy 80, 82–83
 - epithelial plane differences 83, 86
 - erosion 53
 - metaplastic 50, 97, 140
 - normal 24, 26, 48
 - reactive changes 28
 - Schiller (iodine) test 66, 66
 - vasculature 29
- condyloma acuminatum 189
- condylomas
- acetic acid testing 99, 150, 159
 - atypical condylomas 31, 34
 - condylomatous cervicitis 56, 119
 - fine papillary 115, 117
 - finger-like processes 117
 - flat condylomas, *see* flat condylomas
 - glycogen in 30, 56, 99, 116, 117
 - HPV infection phases 191
 - iodine testing 117, 143
 - laser ablation 164
 - overview 29, 53, 112
 - perianal 219
 - pregnancy 147, 150, 159
 - terminology 192
 - treatment 164
 - vasculature 116–117
 - vulval 189–190
- condylomatous colpitis 105
- condylomatous vaginitis 119
- cone biopsy, *see* conization
- conization
- cold-knife 124, 165, 167, 172, 174, 175, 177
 - complications of 173, 176
 - cone biopsy specimens terminology 75
 - diagnostic 172

- histopathologic processing 175, 177–178, 182
- indications 172
- overview 166, 172
- pregnancy 175
- repeat 167
- scarring 175, 176–177
- specimen processing 154
- specimens 165–167
- technique 172
- therapeutic 172
- cryosurgery 164, 166
- cuffed gland openings 53, 91, 93, 105, 129, 143
- cytokeratin 17 10, 15, 27
- cytology
 - anal intraepithelial neoplasia 218
 - history of 2
 - vaginal 210

D

- decidual polyps 140, 140–141, 143
- depth of invasion 40–41
- developing countries, screen and test approaches in 6
- differential diagnosis
 - abnormalities, combinations of 131, 154–157
 - acetic acid test (white epithelium) 93, 116, 128, 129, 136
 - atypical blood vessels 107, 131, 132, 135
 - blood vessels 90, 129, 133
 - criteria generally 128
 - criteria weighting 137
 - cuffed gland openings, *see* cuffed gland openings
 - inflammation 119
 - iodine uptake 135, 136
 - nonsuspicious vascular pattern 131, 132
 - sharp borders 128, 128
 - surface area (size) 131
 - surface contour 129, 129, 130
 - *See also* mosaic, punctuation
 - suspicious vascular pattern 131, 133–134
- differentiated type vulvar intraepithelial neoplasia (dVIN)
 - clinical diagnosis 194
 - histologic terminology, classification 192
 - histology 193, 194–195
 - lichen planus 194
 - lichen sclerosus 194
 - management 195
 - overview 191
 - therapy 197
- dVIN pathway carcinogenesis 192–193
- dysplasia 32

E

- E2 binding site methylation 38
- E2 gene 14
- E6 gene 13, 14, 35
- E7 gene 13, 14, 35, 191
- E7 oncoprotein 37
- early stromal invasion

- acetic acid testing 105–107
- acetowhite epithelium 104–105, 107
- colposcopic–histologic correlation 155–158
- histology, histopathology 38, 44–45, 56, 127
- microinvasive (microcarcinomas), *see* microinvasive carcinoma (microcarcinomas)
- morphology 101, 127
- signs of 104, 104–105
- surface bumps, bulges 106
- transformation zone 104, 106
- ectopy
 - acetic acid test 64, 79
 - cervix epithelial plane differences 83, 86
 - columnar epithelium 80, 82–83
 - differential histology 86–87
 - glycogen in 164
 - histology, histopathology 24, 25, 26, 28
 - iodine testing 79
 - management 164
 - oral contraceptives effects on 84–85
 - pregnancy 141, 147, 150
 - squamocolumnar junction 79, 82–83, 84
 - transformation zone 83
 - with ectopic residuals 88, 90
- eczema 188, 205
- elevated papillae 130, 131
- endocervical carcinoma 56
- endocervical crypts 48, 48
- endometrial carcinoma 123
- endometrioid adenocarcinoma 45
- endometriosis 125, 126
- endophytic carcinomas 42, 47, 57, 104, 108–109, 110
- eosinophilic dysplasia 34
- erosion
 - squamous epithelium 53, 54, 98, 101, 103, 155–159
 - vaginal 209
 - vaginal SIL 209
 - vulval 183, 188
- erythroplakia 184, 184, 189, 193
- excision
 - complete 166
 - HSIL 196, 197
 - incomplete 124, 166
 - loop diathermy 172, 173–174, 174, 177, 182
 - types, terminology 75
- exophytic carcinomas 42, 47, 107–110

F

- FIGO stages 38
- fistulas 125, 126
- flat condylomas
 - acetic acid testing 136
 - differential diagnosis 56
 - histology, histopathology 32, 116, 118
 - HIV positive patients 117
 - iodine testing 118, 136, 150
 - morphology 55, 117, 130
 - treatment 164
- forceps 63, 63

- Friedell, G. H. 33
- FUTURE studies 20

G

- Gardasil 20
- gland openings
 - acetowhite epithelium 93
 - cuffed 53, 91, 93, 105, 129, 143
 - described 50
 - histology, histopathology 49
 - iodine testing 87
 - morphology 86–87, 91, 93
 - pregnancy 143, 147–148
- glandular intraepithelial lesions, *see* adenocarcinoma in situ (AIS)
- glycogen
 - histology 26–27
 - in condylomas 30, 56, 99, 116, 117
 - in ectopy 164
 - in metaplastic squamous epithelium 48, 128, 142
 - in mosaic, punctuation areas 53, 186
 - in pregnancy 142, 143
 - in regenerating squamous epithelium 49
 - in squamous epithelium 26–27, 66, 81, 125, 189
 - iodine testing 66, 117, 140, 143
 - postpartum 143
 - prolapse 125
 - transformation zone 68, 87
 - Trichomonas infection 119
 - vulvar 183

H

- Hamperl, H. 25
- Hausen, Harald zur 10
- healing of erosions theory 48
- Hepler, T. K. 33
- HER2 oncogene amplification 199
- high-grade squamous intraepithelial lesions (HSIL)
 - acetic acid test 65
 - acetowhite epithelium 53, 68, 90, 90, 91–93, 101, 103, 186, 186
 - basaloid 194, 195
 - biomarkers 212
 - colposcopic evaluation of 6
 - conization specimen 165–166
 - development of 12
 - diagnosis 165
 - differential histology 29, 31, 33, 34, 36–37
 - dysplastic epithelial fields size, extent 18, 50
 - erosion 54
 - erythroplakia 184, 184
 - excision 196, 197
 - histology 195, 196, 211
 - HPV-DNA testing 34
 - HPV-dependent carcinogenesis 189, 190–191
 - hyperpigmentation 185, 185
 - inner border sign 53, 136, 157
 - L1 capsid protein testing 35
 - laser ablation 195, 197
 - last gland rule, *see* last gland
 - leukoplakia 184, 185

- morphogenesis in metaplastic epithelium 17
- mosaic, punctuation patterns 53, 187
- multifocal 196
- predictive lesions 53
- punctuation 187
- ridge sign 53, 136, 148, 157
- Schiller (iodine) test 69
- superficial spread of 46, 48
- surface area (size) 137, 140
- terminology 31, 31, 192
- terminology history 33
- vaginal SIL 211
- warty 194, 195
- Hinselmann, Hans 2
- histology, histopathology
 - atypical condylomas 31, 34
 - colposcopic correlations, *see* colposcopic–histologic correlation
 - condylomatous lesions 31
 - *See also* condylomas
 - ectopy, *see* ectopy
 - epithelial borders 24
 - flat condylomas, *see* flat condylomas
 - inverted condylomas 33
 - morphology, microscopic vs. colposcopic 46
 - subcolumnar reserve cells 14–15, 24
- HIV positive patients 117
- HPV E6/E7 mRNA testing 35
- HPV testing 189, 189, 190
- HPV-DNA genotyping 35
- HPV-DNA testing 34
- human papillomavirus (HPV)
 - classification 10
 - colposcopic evaluation of 2, 6
 - entry model 10, 11
 - epidemiology 10
 - erythroplakia 184, 184
 - infection phases 12, 191
 - infection types 10
 - integration of 15
 - iodine-positive punctuation 98
 - latent phase 13
 - mosaic 187
 - permissive (productive) phase 12, 13, 16
 - replication 14
 - risk factors 10
 - transforming phase 11, 14
 - vaccines 17, 199
- hyperkeratosis 29, 29, 50, 51, 109, 125
- hysterectomy (primary) 167

I

- imiquimod 197, 198–199, 216
- inflammation
 - differential diagnosis 119
 - iodine testing 120
 - vaginal 114, 120
- inflammatory stromal infiltrate 29
- inner border sign 53, 136, 157
- interferon 199
- International Federation for Cervical Pathology and Colposcopy (IFCPC) 2
- intrauterine device 94
- invasive carcinoma, *see* early stromal invasion

- inverted condylomas 33
 iodine test, *see* Schiller (iodine) test
 iodine-positive mosaic 56, 117, 118
- J**
 Jakob, Alfredo 2
- K**
 Kelly, Howard 2
 keratinization
 – condylomas 116, 117, 117
 – differential diagnosis 135
 – squamous epithelium 29, 49–50, 101
 keratinizing invasive carcinoma 53, 109
 keratosis, *see* leukoplakia
 Ki-67 38, 43, 212
 koilocytosis 29–30, 30, 116
 Kolstad, Per 2
 Koss, L. G. 32
- L**
 L1 capsid protein testing 35, 42–43
 L1 gene 14
 L2 gene 14
 laser ablation
 – anal intraepithelial neoplasia 219
 – condylomas 164
 – conization specimen 166
 – HSIL 195, 197
 – SIL 166, 166
 – superficial, lesion selection 165
 laser cone biopsy 173–174, 177
 last gland
 – CIN topographic relationship to 28, 46, 48
 – concept 24, 28
 – rules 155–158, 160
 lentigo 199
 lesion measurement 40–41
 leukoplakia
 – evaluation of 164
 – histology, histopathology 29, 49, 51
 – in transformation zone 113
 – morphology 97–98, 101–102, 108, 113
 – overview 50, 98
 – perianal region 217
 – topography 159, 161
 – vulval 184, 184–185, 186, 187, 189, 192–193
 lichen planus
 – dVIN 194
 – etiology 204
 – malignant potential of 202, 208
 – morphology 192–193, 203–204
 – overview 202
 – symptoms 208
 – treatment 208
 lichen sclerosus
 – dVIN 194
 – morphology 193, 201–203
 – overview 200
 – symptoms 202
 – treatment 204
 lichen simplex 204
 lichenification 184, 184, 188, 208
- loop conization changes 124
 loop diathermy excision
 – pregnancy 182
 – technique 173, 173–174
 – treatment comparison 174, 177
 low-grade squamous intraepithelial lesions (LSIL)
 – acetowhite epithelium 91
 – biomarkers 212
 – cellular location of 16, 18
 – differential histology 32–33, 56
 – histology 35
 – HPV infection phases 191
 – HPV testing 189
 – invasion risk 13
 – L1 capsid protein testing 35, 42
 – last gland rule, *see* last gland
 – morphological effects detection 11
 – mosaic, punctuation patterns 53
 – p16INK4a, *see* p16INK4a
 – spontaneous resolution of 14
 – surface area (size) 137, 140
 – terminology 31, 31, 192
 – terminology history 33
 – transforming infection 11
 – vaginal SIL 211
 lymph vascular invasion (LVSI) 40, 40, 44
 lymphoepitheloma-like carcinoma 44
- M**
 macule 76
 MAL methylation 38
 malignant melanoma 199, 200
 matrix areas 2
 melanoma
 – in situ 200
 – malignant 199, 200
 – vaginal 212, 212
 menopause 25, 48, 66, 81, 104, 210
 mesonephric adenocarcinoma 46
 metaplasia 24, 27
 methylation 38
 Meyer, Robert 48
 microinvasive adenocarcinoma 40, 46, 56, 110, 112–113
 microinvasive carcinoma (microcarcinomas) 38, 44
 – acetic acid testing 106
 – colposcopic–histologic correlations 56, 155–158
 – conization specimen 167
 – diagnosis 166
 – histology, histopathology 44, 55
 – morphology 106
 – mortality 167
 – recurrence 167
 – treatment 167
 microinvasive tumor 39, 44
 micropapillomatosis 182
 miscellaneous findings definitions 74–75
 modified mucosa 182, 183
 mosaic
 – acetic acid test 65, 94–95, 96, 129
 – coarse 95–96, 96, 97, 100–101, 105, 107, 111, 129, 136, 148, 187
 – coarse ridges 129, 131
 – evaluation of 164
 – fine 90, 94, 94, 95–97, 118, 130, 143–144, 147
 – glycogen in 53, 186
 – histology, histopathology 50, 50, 52
 – iodine-positive 56, 117, 118
 – morphology 90, 94, 96, 118
 – occurrence, coexistence 95, 97, 98, 98
 – SIL prevalence in cone biopsy 127
 – suspicious vascular pattern 129–130, 131
 – topography 159–161, 164
 – transformation zone 53, 95, 98
 – vulval 186, 187
 mother-of-pearl surface 116, 118, 129
 mucinous adenocarcinoma 45
- N**
 Nabothian follicles
 – acetic acid test 133
 – acetowhite epithelium 91
 – described 50
 – polyps 121–122
 – squamocolumnar junction transformation 89
 – transformation zone vasculature 131, 133
 neuroendocrine small cell carcinoma 46
 nodule 76
 nonsuspicious iodine-yellow area, iodine testing 66, 72, 110, 112, 113–114, 159, 161
 normal colposcopic findings
 – definitions 74–75
 – portio rugata 80
 – squamous epithelium, *see* under squamous epithelium
- O**
 oral contraceptives effects on ectopy 84–85
- P**
 p16INK4a 13, 34–35, 35, 37, 43, 48, 190, 191, 211, 212
 p53 191
 p63 10, 15
 p185Her2 198, 199
 Paget disease
 – diagnosis 197
 – histology 198
 – morphology 197–198
 – overview 197
 – treatment 198
 – vulval 198
 palpation 183
 Pap smears 64
 Papanicolaou, G. N. 2
 papillary condylomas 30, 31, 164
 papillary verrucous carcinomas 109, 111
 PApilloma TRial against Cancer In young Adults (PATRICIA) 20
 papule 76
 parakeratosis 29, 50, 51
 patch 76
 peg formation rules 155–158
 perianal condylomas 219
 perianal region
 – AIN, *see* anal intraepithelial neoplasia
 – anatomy 216, 216
 – carcinogenesis 216–217, 217
 Peutz–Jeghers syndrome 45
 photodynamic therapy 198
 plaque 76
 polyploid carcinoma 111
 polyps
 – bleeding 123
 – decidual 140, 140–141, 143
 – differential diagnosis 111
 – endocervical 121
 – findings, terminology 74–75
 – instrumentation 64
 – iodine testing 121–122
 – metaplastic 121
 – multiple 122
 – Nabothian follicles 121–122
 – overview 117
 – transformation zone 121
 portio rugata 80
 post conization changes 120, 123–124
 pRB 37
 pRB1 14
 precursor lesions
 – histology 32
 – terminology 31, 31
 – terminology history 31
 pregnancy
 – acetic acid testing 141, 142–144, 145, 147–148
 – Arias–Stella reaction 34, 41
 – benign changes 141, 141, 142–143, 146–147
 – biopsy 67, 145
 – cervical mucosa 141
 – colposcopic evaluation in 6, 140
 – condylomas 147, 150, 159
 – conization 175
 – decidual polyps 140, 140–141, 143
 – ectopy 141, 147, 150
 – findings, effects on 141, 143–144
 – gland openings 143, 147–148
 – glycogen in 142, 143
 – iodine testing 141, 142, 144–145, 150
 – lividity, softness 141, 142–145
 – loop diathermy excision 182
 – postpartum colposcopy 143, 146
 – puerperium 143, 146, 150
 – ridge sign 148
 – SIL/CIN development 142–144, 145, 148–149
 – suspicious changes 143
 – transformation zone 141–143, 145, 145–150
 – vascular changes 142
 prolapse, changes resulting from 125, 125
 proteoglycans 10
 psoriasis 204, 208
 puerperium 143, 146, 150
 punctuation
 – acetic acid testing 65, 100
 – blood vessels in 133
 – capillary loops 133
 – coarse 97, 98, 100–101, 187

- elevated papillae 130, 131
- evaluation of 164
- fine 97, 98–99, 118, 143
- glycogen in 53, 186
- histology, histopathology 50, 50, 52
- iodine testing 99
- iodine-positive 98, 150, 159
- morphology 96, 101, 118
- occurrence, coexistence 95, 97, 98, 98
- overview 96
- SIL prevalence in cone biopsy 127
- slightly prominent 97
- topography 159–161, 164
- transformation zone 53, 95, 98
- vulval 186, 187
- pustule 76

R

- Rb 191
- Reagan, J. W. 32
- repeat conization 167
- reserve cells 10, 11
- retention cyst vasculature 89
- retinoids 199
- Richart, R. M. 32–33
- ridge sign 53, 136, 148, 157

S

- scarring
 - conization 175, 176–177
 - iodine testing 123, 125
- Schauenstein, W. 32
- Schauta, Friedrich 2
- Schiller (iodine) test
 - anal intraepithelial neoplasia 219
 - borders 66–68, 72
 - cervical intraepithelial neoplasia 105
 - cervix 123, 125
 - colpitis macularis (strawberry cervix) 120
 - columnar epithelium 66, 66
 - condylomas 117, 143
 - differential diagnosis 135, 136
 - ectopy 79
 - flat condylomas 118, 136, 150
 - gland openings 87
 - glycogen 66, 117, 140, 143
 - high-grade squamous intraepithelial lesions (HSIL) 69
 - history 2
 - HSIL 69
 - inflammation 120
 - nonsuspicious iodine-yellow area 66, 72, 110, 112, 113–114, 159, 161
 - overview 66
 - polyps 121–122
 - pregnancy 141, 142, 144–145, 150
 - punctuation 99
 - scarring 123, 125
 - SIL 68–69
 - transformation zone 66, 66–67, 68, 68, 70, 79
 - vaginal 67, 81
 - vaginal SIL 209, 210
- Schiller, Walter 2
- Schmitt, A. 2
- septae 127

- serous adenocarcinoma 46
- sharp borders
 - differential diagnosis 128, 128
 - iodine testing 66–68, 72
 - SIL 18
 - squamous cell carcinoma 15, 18, 30, 50, 154–157
 - vulval 186–187, 187–188
- specula 62, 63
- spiked condylomas 30, 54
- squamocolumnar junction
 - anatomy 16, 19, 82
 - cervical development 27, 28
 - ectopy 24, 79, 82–83, 84
 - postconization changes 120
 - terminology 74–75
 - transformation 24–25, 26–27, 89, 90
- squamous cell carcinoma
 - acetic acid testing 109–110
 - grade 1 42, 44
 - grade 2 44
 - grade 3 44
 - grossly invasive 56, 56
 - groups 42
 - histologic grading 42
 - histology 42
 - invasive 107, 107, 108–109, 110, 110–111
 - lymphoepitheloma-like carcinoma 44
 - morphogenesis generally 16
 - morphogenesis in metaplastic epithelium 14–15, 15, 16–17
 - morphogenesis in squamous epithelium 16
 - sharp borders 15, 18, 30, 50, 154–157
 - verrucous carcinoma 44
 - warty (condylomatous) carcinoma 44
- squamous epithelium
 - acetowhite epithelium 53, 68, 90, 90, 91–93, 101, 103
 - atrophic 78, 81
 - benign, dysplastic coexistence 53, 155–158
 - dysplastic 35–36, 49, 91–92
 - epithelial plane differences 83, 86
 - erosion 49, 53, 54, 98, 101, 103, 155–159
 - finger-like processes 88
 - glycogen in 26–27, 66, 81, 125, 189
 - HPV infected 29, 30
 - metaplastic 24, 26, 27, 27, 48, 53, 84–85, 88, 90, 90, 128, 136, 140, 142
 - normal 24, 25, 78, 78, 79, 155–158, 161
 - portio rugata 80
 - reactive changes 28, 29
 - regenerating 49, 53, 66, 66, 102, 106, 155–158
 - role in colposcopic morphology 25, 48, 78
 - stroma 49, 98
 - types 182, 182
 - vasculature 28
- squamous intraepithelial lesions (SIL), see cervical intraepithelial neoplasia (CIN)

- ablative treatment 165, 165, 166
- basaloid 194, 195
- borders 18
- coexistence 16
- corkscrew, comma-shaped blood vessels 133–134
- development of 17
- diagnostic methods 208
- diagnostic prerequisites 164, 165
- epidemiology 191
- histologic terminology, classification 192
- histology 32, 193
- history of CIN 208
- iodine testing 68–69
- L1 capsid protein testing 35, 42
- last gland, topographic relationship to 28, 46, 48
- management 195
- medical therapy 196
- metaplastic epithelium (benign) 127, 127
- mosaic, punctuation patterns 53
- overview 191
- premalignant lesions, treatment 164
- prevalence in cone biopsy 127
- recurrence 166
- superficial spread of 46, 48
- surgical therapy 195, 195, 196
- treatment, medical 167
- vaginal 208, 210
- warty 194, 195
- Štafl, Adolf 2
- stroma 49, 98
- stromal papillae arrangement 50, 52, 101
- subcolumnar reserve cells 14–15, 24
- suspicion of malignancy 75
- suspicious for invasion 74
- swabs 63

T

- tenacula 63, 63
- terminology 74, 74, 75
- toluidine blue test (Collins test) 183, 183
- transformation
 - defined 27
 - mechanism of 27
 - process 24, 27, 79, 81, 86–89, 90
- transformation zone (TZ)
 - acetic acid test 65, 65, 85, 92
 - acetowhite epithelium 92
 - adenocarcinoma in situ 112
 - anatomy 27
 - atypical 94
 - congenital 110, 115, 140
 - early stromal invasion 104, 106
 - ectopy 83
 - finger-like processes 88
 - glycogen 68, 87
 - iodine testing 66, 66–67, 68, 68, 70
 - keratosis (leukoplakia) 113
 - last gland, lesions proximal to 28
 - last gland, topographic relationship to 28, 46, 48
 - leukoplakia in 113
 - metaplastic squamous epithelium 24, 26–27

- morphology 84, 85
- mosaic, punctuation patterns 53, 95, 98
- normal, treatment 164
- polyps 121
- pregnancy 141–143, 145, 145–150
- Schiller (iodine) test 66, 66–67, 68, 68, 70
- septae 127
- steplike border 86
- terminology 74
- topography 160
- vasculature 131, 133
- trastuzumab 200
- Trichomonal infection 119
- trinitrochlorobenzene 199
- TZ with ectopic residuals 88, 90

U

- ulcers
 - columnar epithelium 53, 54
 - prolapse 125
 - squamous epithelium 53, 54, 101, 102–103, 111
 - vulval 183, 188
- uterovaginal procidentia 126
- uterus, mesenchymal tumors 57

V

- vaccines 17, 199
- vagina
 - acetowhite epithelium 209, 210
 - biomarkers 210
 - biopsy 210
 - carcinogenesis 208
 - colposcopic terminology 210
 - colposcopy of 208
 - cytology 210
 - erosion 209
 - histologic terminology, classification 211
 - histology 208, 208
 - inflammatory changes 114, 120
 - invasive disease 210, 210, 211
 - iodine testing 67, 81, 209
 - mucosal fragment abrasion 211, 211
 - Schiller (iodine) test 67, 81
 - terminology 75
 - ulcers, prolapse 125
- vaginal melanoma 212, 212
- vaginal SIL
 - acetic acid testing 209, 210
 - diagnostic methods 208
 - electrocoagulation 216
 - erosion 209
 - histologic terminology, classification 211
 - histomorphology 211
 - history 208
 - HSIL 211
 - iodine testing 209, 210
 - LSIL 211
 - medical therapy 212
 - overview 208
 - surgical therapy 212
 - treatment 212
- vaginitis 56, 119
- verrucous carcinoma 44

- vesicle 76
 - virus-like particles (VLPs) 20
 - vulva
 - acetowhite epithelium 186, 186
 - atypical vessels 188, 188
 - biopsy 188, 189
 - cancer, vaginal infiltration 210, 211
 - carcinogenesis generally 189
 - colposcopic–histologic correlation 186
 - colposcopy of 184
 - condyloma 189–190
 - dark (melanotic) lesions 185, 185
 - dVIN pathway carcinogenesis 192–193
 - eczema 188, 205
 - epithelial disorders 200
 - erosion 183, 188
 - erythroplakia 184, 184, 189, 193
 - excoriation 188
 - fissure 188
 - glycogen 183
 - glycogen-containing mucosa 182, 183
 - histology 182, 182
 - history and symptoms 183
 - HPV testing 189, 189, 190
 - HPV–dependent carcinogenesis 189, 190–191
 - HPV–independent carcinogenesis 190, 190
 - inspection 183
 - keratinized skin 182, 182
 - lentigo 199
 - lesion types terminology 76, 186, 192
 - lesions, diagnostic evaluation of 183, 188, 189
 - leukoplakia 184, 184–185, 186, 187, 189, 192–193
 - lichen planus, *see* lichen planus
 - lichen sclerosus, *see* lichen sclerosus
 - lichen simplex 204
 - lichenification 184, 184, 188, 208
 - psoriasis 204, 208
 - vulvar melanosis 199
- W**
- warty (condylomatous) carcinoma 44
 - white dots 119
 - width of invasion 40–41
 - Woodman, C. B. 10

