

# Clinical Ophthalmic Oncology

---

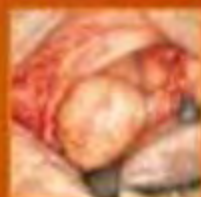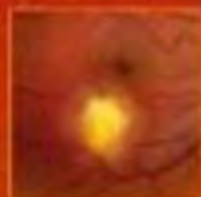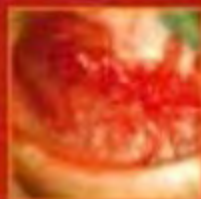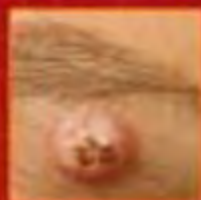**Arun D. Singh**

Bertil E. Damato

Jacob Pe'er

A. Linn Murphree

Julian D. Perry



SAUNDERS  
ELSEVIER

**SAUNDERS**  
ELSEVIER

Saunders is an affiliate of Elsevier Inc.

© 2007, Elsevier Inc. All rights reserved.

First published 2007

No part of this publication may be reproduced, stored in a retrieval system, or transmitted in any form or by any means, electronic, mechanical, photocopying, recording or otherwise, without the prior permission of the Publishers. Permissions may be sought directly from Elsevier's Health Sciences Rights Department, 1600 John F. Kennedy Boulevard, Suite 1800, Philadelphia, PA 19103-2899, USA: phone: (+1) 215 239 3804; fax: (+1) 215 239 3805; or, e-mail: [healthpermissions@elsevier.com](mailto:healthpermissions@elsevier.com). You may also complete your request on-line via the Elsevier homepage (<http://www.elsevier.com>), by selecting 'Support and contact' and then 'Copyright and Permission'.

ISBN-13 978-1-4160-3167-3

ISBN-10 1-4160-3167-7

**British Library Cataloguing in Publication Data**

A catalogue record for this book is available from the British Library

**Library of Congress Cataloging in Publication Data**

A catalog record for this book is available from the Library of Congress

**Notice**

Medical knowledge is constantly changing. Standard safety precautions must be followed, but as new research and clinical experience broaden our knowledge, changes in treatment and drug therapy may become necessary or appropriate. Readers are advised to check the most current product information provided by the manufacturer of each drug to be administered to verify the recommended dose, the method and duration of administration, and contraindications. It is the responsibility of the practitioner, relying on experience and knowledge of the patient, to determine dosages and the best treatment for each individual patient. Neither the Publisher nor the author assume any liability for any injury and/or damage to persons or property arising from this publication.

**The Publisher**

Printed in China

Last digit is the print number: 9 8 7 6 5 4 3 2 1

Working together to grow  
libraries in developing countries  
[www.elsevier.com](http://www.elsevier.com) | [www.bookaid.org](http://www.bookaid.org) | [www.sabre.org](http://www.sabre.org)  
**ELSEVIER** **BOOK AID** **Sabre Foundation**  
International

The  
Publisher's  
policy is to use  
**paper manufactured**  
from sustainable forests



Commissioning Editor: Russell Gabbedy  
Development Editor: Nani Clansey  
Project Manager: Bryan Potter  
Design Manager: Andy Chapman  
Illustration Manager: Gillian Richards  
Illustrator: Paul Banville  
Marketing Manager(s) (UK/USA): John Canelon/Lisa Damico

# Foreword

---

The editors of this fine book have recruited contributions from a large number of authorities on various aspects of ophthalmic tumors. The result is a comprehensive review of the subject that is well organized and easy to read.

Unlike other books of ocular tumors, an entire introductory section is devoted to basic principles of cancer as it relates to the eye and ocular adnexa. That section includes general topics like epidemiology, pathology immunology, genetics and principles of laser treatment, radiation therapy and chemotherapy. The subsequent sections, like other books on the subject, specifically cover tumors of the eyelids, conjunctiva, uvea, retina, and orbit.

The book is well endowed with illustrations, pertinent references, and tables that should assist the reader in understanding the

subject. This book will be useful to clinicians and researchers who have a part-time or full time interest in ocular neoplasms and related conditions. Such individuals will be grateful to the authors for their enormous and successful efforts in producing a very useful contribution.

Jerry A. Shields, M.D  
Director, Ocular Oncology Service  
Wills Eye Institute  
Professor of Ophthalmology  
Thomas Jefferson University  
Philadelphia, PA, USA

# Preface

---

The management of patients with an ophthalmic tumor presents particular challenges. Ophthalmic tumors are rare and diverse so that their diagnosis can be quite complex. Treatment usually requires special expertise and equipment and in many instances is controversial. The field is advancing rapidly, because of accelerating progress in tumor biology, pharmacology, and instrumentation. Increasingly, the care of patients with an ocular or adnexal tumor is provided by a multidisciplinary team, comprising ocular oncologists, general oncologists, radiotherapists, pathologists, psychologists, and other specialists. Such expertise may only be available far from the patient's home, in which case the local ophthalmologist will continue to be involved in the patient's care. For all these reasons, we felt that there was scope for a textbook of ophthalmic oncology, which would amalgamate knowledge from several different disciplines, thereby helping the various specialists to understand each other better and to cooperate more efficiently.

The purpose of *Clinical Ophthalmic Oncology* is to provide up-to-date information of the whole spectrum of the eyelid, conjunctival, intraocular, and orbital tumors. The first section is devoted to basic principles of chemotherapy, radiation therapy, cancer epidemiology, angiogenesis, and cancer genetics. We have also included a chapter on counseling patients with ophthalmic cancer.

Special attention has been paid to make the text easily readable. Each chapter has a similar layout with boxes that highlight the key features, tables that provide comparison, and flow diagrams that outline therapeutic approaches. Several chapters authored by radiation oncologists, medical physicists, pediatric oncologists, hematologist-oncologists, and medical geneticists have been included to provide a broader perspective.

The authors followed a tight timeline to keep the contents of the book current. All 124 authors from 18 countries were gracious

to accept editorial changes so as to present a balanced view of clinical practice. As evidence-based data are sparse in the field of ophthalmic oncology, it is anticipated that *Clinical Ophthalmic Oncology* will act as a stimulus for further thought and investigation.

As we undertook this ambitious task of editing a multi author textbook, we were supported and guided by the staff at Elsevier; Paul Fam, Belinda Kuhn, Joanne Scott, Russell Gabbedy, Sven Pinczewski, Nani Clansey, and Bryan Potter. Sue Srnovski kept the seemingly chaotic process under control. Ms. Judith Fisher provided tremendous support in the preparation and in editing of the chapters.

It is our sincere hope that readers will find as much pleasure reading this textbook as we had writing and editing it. If you find *Clinical Ophthalmic Oncology* informative, it is because (paraphrasing Isaac Newton), "we have seen further, by standing on the shoulders of the giants."

Arun D. Singh, MD  
Cleveland, United States

Bertil E. Damato, MD, FRCS,  
Liverpool, United Kingdom

Jacob Pe'er, MD  
Jerusalem, Israel

A. Linn Murphree, MD  
Los Angeles, United States

Julian D. Perry, MD  
Cleveland, United States

# List of contributors

---

**Thomas M. Aaberg Jnr MD**

Associated Retinal Consultants  
Grand Rapids  
USA

**Charlotta All-Ericsson MD, PhD**

Senior Staff Ophthalmic Surgeon  
Ocular Oncology Service  
Department of Vitreoretinal Diseases  
St Eriks Eye Hospital  
Stockholm  
Sweden

**Carryn Anderson MD**

Radiation Oncology Resident  
Department of Radiation & Ophthalmic  
Oncology  
Cole Eye Institute  
Cleveland Clinic Foundation  
Cleveland  
USA

**Sophie Bakri MD**

Retina Fellow  
Cole Eye Institute  
Cleveland Clinic Foundation  
Cleveland  
USA

**Aubin Balmer MD**

Lecturer  
Department of Ophthalmology  
Jules Gonin Eye Hospital  
Lausanne  
Switzerland

**David Sander Bardenstein**

Director of Ocular Oncology and Ocular  
Pathology  
Departments of Ophthalmology and Pathology  
Case Western Reserve University School of  
Medicine  
University Hospitals of Cleveland  
Cleveland  
USA

**Rafael I. Barraquer MD PhD**

Assistant Director, Centro de Oftalmologia  
Barraquer  
Director, Ocular Oncology Service  
Barcelona  
Spain

**Valentina de Belvis MD**

Lecturer  
Department of Ophthalmology  
University of Padova  
Padova  
Italy

**Louise Bergman**

Senior Vitreoretinal Surgeon  
Department of Vitreoretinal Diseases  
Karolinska Institute  
St. Eriks Eye Hospital  
Stockholm  
Sweden

**Michiel R. de Boer PhD**

Senior Lecturer in Epidemiology & Applied  
Biostatistics  
Faculty of Earth and Life Sciences  
Institute of Health Sciences  
VU University  
Amsterdam  
Netherlands

**James P Bolling MD**

Associate Professor and Chair  
Department of Ophthalmology  
Mayo Clinic  
Jacksonville  
USA

**Ernest Borden PhD**

Staff Hematologist Oncologist  
Department of Oncology  
Cleveland Clinic Foundation  
Cleveland  
USA

**Norbert Bornfeld MD**

Professor of Ophthalmology  
Zentrum für Augenheilkunde  
Universitätsklinikum Essen  
Essen  
Germany

**Lex M. Bouter PhD**

Professor of Epidemiology; Scientific Director  
Institute for Research in Extramural Medicine  
VU University Medical Center  
Amsterdam  
Netherlands

**Julie Bray**

Nurse Practitioner  
Taussig Cancer Center  
Cleveland Clinic Foundation R20  
Cleveland  
USA

**Greta R. Bunin PhD**

Research Associate Professor of Pediatrics  
Children's Hospital of Philadelphia  
Division of Oncology  
Philadelphia PA  
USA

**Devron H. Char MD**

President  
The Tumori Foundation;  
Clinical Professor  
Stanford University  
San Francisco CA  
USA

**Guillermo Luis Chantada MD**

Principal Physician  
Hemato-Oncology Department  
Hospital J.P. Garrahan  
Buenos Aires  
Argentina



**Benson Chen MD**

Research Fellow  
Cole Eye Institute  
The Cleveland Clinic Foundation  
Cleveland  
USA

**Patricia Chevez-Barrios MD**

Associate Professor of Pathology  
Department of Pathology  
Weill Medical College of Cornell University  
The Methodist Hospital  
Houston TX  
USA

**Murali Chintagumpala MD**

Associate Professor of Pediatrics  
Texas Children's Cancer Center at Baylor  
College  
Houston  
USA

**Robin Clark MD**

Associate Clinical Professor of Medical Genetics  
Departments of Pediatrics & Ophthalmology  
Keck School of Medicine  
Riverside  
USA

**Kimberly Cockerham MD**

Associate Professor  
Department of Ophthalmology  
University of California  
San Francisco  
USA

**Javier Coloma MD**

Ophthalmologist  
Centro Oftalmologico Moreiras  
Orbital-Ophthalmoplastic and Reconstructive  
Surgery  
A Coruna  
Spain

**Sharon Cook MD**

Health Psychologist  
Ocular Oncology Service  
University of Liverpool  
Liverpool  
UK

**Sarah E. Coupland MBBS PhD**

Senior Lecturer in Ophthalmic Pathology  
Department of Cellular and Molecular  
Pathology  
University of Liverpool  
Liverpool  
UK

**Jihan Dennaoui**

Research Student  
Department of Ophthalmology  
Leiden University Medical Center  
Leiden  
Netherlands

**Karin Dieckmann MD**

Staff  
Department of Radiation Oncology  
Medical University of Vienna  
General Hospital Vienna  
Vienna  
Austria

**Ira J. Dunkel MD**

Associate Attending Pediatrician  
Department of Pediatrics  
Memorial Sloan-Kettering Cancer Center  
New York NY  
USA

**Omar M Durrani MD FRCS**

Oculoplastic & Orbit Surgeon  
Birmingham & Midland Eye Centre  
City Hospital  
Birmingham  
UK

**Jonathan Dutton MD**

Professor and Vice Chair  
Department of Ophthalmology  
University of North Carolina  
Chapel Hill  
USA

**Michael A. Dyer PhD**

Associate Member  
Department of Developmental Neurobiology  
St Jude Children's Research Hospital  
Memphis TN  
USA

**Javier Elizalde MD**

Ophthalmologist  
Vitreous Retina Service  
Ocular Oncology Service  
Centro de Oftalmologia Barraquer  
Barcelona  
Spain

**Ralph C. Eagle Jr. MD**

Director  
Department of Pathology  
Wills Eye Hospital Thomas Jefferson University  
Philadelphia  
USA

**Evelyn Fu MD**

Resident Physician  
Department of Ophthalmic Oncology  
Cole Eye Institute  
Cleveland Clinic Foundation  
Cleveland  
USA

**Peter Fleming MD**

Staff Radiation Oncologist  
Department of Radiation & Ophthalmic  
Oncology  
Cole Eye Institute  
Cleveland Clinic Foundation  
Cleveland  
USA

**Robert Folberg MD**

Frances B Geever Professor and Head  
Department of Pathology  
University of Illinois College of Medicine  
Chicago  
USA

**Jill A. Foster MD**

Assistant Clinical Professor  
The Ohio State University  
The William H. Havener Eye Institute  
Columbus  
USA

**Debra Friedman MD**

Associate Professor of Pediatrics  
Fred Hutchinson Cancer Research Center  
Seattle  
USA

**Joseph Frucht-Perry MD**

Associate Professor of Ophthalmology  
Head of the Cornea and Refractive Surgery  
Unit  
Department of Ophthalmology  
Hadassah-Hebrew University Medical Center  
Jerusalem  
Israel

**Anat Galor**

Chief Resident  
Cole Eye Institute  
Cleveland Clinic Foundation  
Cleveland  
USA

**Roberta E. Gausas MD**

Associate Professor of Ophthalmology  
Scheie Eye Institute  
University of Pennsylvania Medical school  
Philadelphia PA  
USA

**Dan S. Gombos MD FACS**

Assistant Professor of Ophthalmology  
Department of Head & Neck Surgery  
The University of Texas  
MD Anderson Cancer Center  
Houston TX  
USA

**Evangelos S. Gragoudas MD**

Director, Retina Service  
Professor of Ophthalmology, Harvard Medical  
School  
Massachusetts Eye and Ear Infirmary  
Boston  
USA

**Jennifer Gravette RN BS CPON**

Nurse  
Department of Pediatric Hematology/  
Oncology  
Cleveland Clinic Foundation  
Cleveland  
USA

**Carl Groenewald MD**

Consultant Vitreoretinal Surgeon  
St Paul's Eye Unit  
Royal Liverpool University Hospital  
Liverpool  
UK

**J. William Harbour MD**

Paul A. Cibis Distinguished Professor of  
Ophthalmology, Cell Biology, and Molecular  
Oncology  
Director, Ocular Oncology Service  
Department of Ophthalmology  
Washington University School of Medicine  
St Louis MO  
USA

**Martin Heur MD**

Resident  
Cole Eye Institute  
Cleveland Clinic Foundation  
Cleveland  
USA

**Joanne Hilden MD**

Chair, Pediatric Hematology/Oncology  
Medical Director, Pediatric Palliative Care  
Cleveland Clinic Foundation  
Cleveland  
USA

**Paul Hiscott MD**

Professor of Ophthalmology  
Unit of Ophthalmology, School of Clinical  
Science  
University of Liverpool  
Liverpool  
UK

**Santosh Honavar MD**

Director  
Ocular Oncology Service  
LV Prasad Eye Institute  
Hyderabad  
India

**Jennifer I. Hui MD**

Lecturer  
Bascom Palmer Eye Institute  
University of Miami Miller School of Medicine  
Miami FL  
USA

**Saskia Marijke Imhof MD PhD**

Doctor  
VU University Medical Center  
Amsterdam  
Netherlands

**Martine J. Jager MD PhD**

Head, Laboratory of Ophthalmology  
Department of Ophthalmology  
Leiden University Medical Center  
Leiden  
Netherlands

**Bennie H. Jeng MD**

Associate Staff  
Cornea and External Disease  
Cole Eye Institute  
Cleveland Clinic Foundation  
Cleveland  
USA

**David R. Jordan MD FACS FRCS(C)**

Professor of Ophthalmology  
University of Ottawa  
Ottawa ON  
Canada

**Hanneke J.G. Journée-de Korver PhD**

Senior Scientist  
Scientific Research, Department of  
Ophthalmology  
Leiden University Medical Center  
Leiden  
Netherlands

**Rima F. Jubran**

Pediatric Oncologist  
Children's Hospital Los Angeles  
Los Angeles  
USA

**Peter K. Kaiser MD**

Director of Clinical Research  
Cole Eye Institute  
Cleveland Clinic Foundation  
Cleveland  
USA

**Hayyam Kiratli MD**

Professor of Ophthalmology  
Department of Ophthalmology  
Hacettepe University School of Medicine  
Sihhiye  
Ankara  
Turkey

**Tero Kivelä MD FEBO**

Professor of Ophthalmology  
Department of Ophthalmology  
Helsinki University Central Hospital  
Helsinki  
Finland

**Stephen R. Klapper MD FACS**

Ophthalmologist  
Klapper Eyelid & Facial Plastic Surgery  
Carmel  
USA

**Alfred G. Knudson Jr. MD PhD**

Senior Member  
Division of Population Science  
Fox Chase Cancer Center  
Philadelphia, PA  
USA

**Anne Marie Lane MPH**

Manager  
Retina Research Unit  
Massachusetts Eye and Ear Infirmary  
Boston  
USA

**Gerald Langmann**

Ophthalmologist  
Department of Ophthalmology  
Universitaets-Augenklinik Graz  
Graz  
Austria

**Carlos Leal-Leal MD**

Pediatric Oncologist  
Instituto Nacional de Pediatra  
Mexican Retinoblastoma Group  
Mexico

**Michael Levien MD**

Staff Pediatric Oncologist  
Department of Pediatric Oncology  
Cleveland Clinic Foundation  
Cleveland  
USA

**Hilel Lewis MD**

Director of Cole Eye Institute,  
Professor and Chairman  
Division of Ophthalmology  
The Cleveland Clinic Foundation  
Cleveland  
USA

**Karin U. Loeffler MD**

Professor of Ophthalmology  
Department of Ophthalmology  
University of Bonn  
Bonn  
Germany

**Cari E. Lyle MD**

Instructor  
Department of Ophthalmology  
University of Tennessee Health Sciences Center  
Memphis  
USA

**Roy Ma MD**

Staff  
Department of Radiation Oncology  
Medical University of Vancouver  
BC Cancer Agency  
Vancouver  
Canada

**Willem Maat MD**

Resident in Ophthalmology  
Department of Ophthalmology  
Leiden University Medical Center  
Leiden  
Netherlands

**Nancy Mansfield PhD**

Assistant Clinical Professor of Ophthalmology  
Keck School of Medicine  
Institute for Families  
Los Angeles  
USA

**Eduardo Marback MD**

Consultant Ophthalmologist  
Ophthalmology Clinic  
Federal University of Bahia  
Salvador  
Brazil

**Anna T. Meadows MD**

Professor of Pediatrics  
University of Pennsylvania  
Children's Hospital of Philadelphia  
Philadelphia PA  
USA

**Thomas E. Merchant DO PhD**

Chief of Radiation Oncology  
St Jude Children's Research Hospital  
Memphis TN  
USA

**Edoardo Midena MD**

Professor of Ophthalmology and Visual  
Sciences  
Department of Ophthalmology  
University of Padova  
Padova  
Italy

**David Miller MD**

Associate Professor  
Clinical Obstetrics, Gynecology and Pediatrics  
Keck School of Medicine  
Los Angeles  
USA

**Annette C. Moll MD PhD FEBOPhth**

Associate Professor of Ophthalmology  
Department of Ophthalmology  
VU University Medical Center  
Amsterdam  
Netherlands

**Hardeep Singh Mudhar BSc PhD MBBChir  
MRCPATH**

Consultant Ophthalmic Histopathologist  
Department of Histopathology  
Royal Hallamshire Hospital  
Sheffield

**Francis Munier MD**

Associate Professor  
Hôpital Ophtalmique Jules Gonin  
Lausanne  
Switzerland

**Michael D. Onken PhD**

Post-Doctoral Fellow  
Department of Ophthalmology & Visual  
Sciences  
Washington University School of Medicine  
St Louis MO  
USA

**Manuela Orjuela**

Assistant Professor of Clinical Pediatrics  
(Oncology)  
Department of Environmental Health Sciences  
Mailman School of Public Health  
Columbia University  
New York  
USA

**Lisa Paquette MD**

Assistant Professor of Pediatrics  
Division of Neonatal Medicine  
University of Southern California Keck School  
of Medicine  
Children's Hospital Los Angeles  
Los Angeles CA  
USA

**Michael Andrew Parsons MB ChB FRCPath**

Senior Lecturer and Honorary Consultant in  
Ophthalmic Pathology  
Department of Ophthalmology and Orthoptics  
University of Sheffield  
Royal Hallamshire Hospital  
Sheffield  
UK

**Bhupendra Patel**

Professor of Ophthalmology and Chief  
Division of Oculoplastic and Orbital Service  
John A. Moran Eye Center  
Salt Lake City  
USA

**Maria Fideliz de la Paz MD**

Ophthalmologist  
Centro de Oftalmologia Barraquer  
Barcelona  
Spain

**David Peereboom MD**

Staff Physician  
Brain Tumor Institute  
Solid Tumor Oncology  
Cleveland Clinic Foundation  
Cleveland  
USA

**Jose Perez-Moreiras MD PhD**

Ophthalmologist  
Calle Eduardo Pondal  
A Coruna  
Spain

**R Poetter MD**

Chair  
Department of Radiation Oncology  
Medical University of Vienna  
General Hospital Vienna  
Vienna  
Austria

**Patrick De Potter**

Professor of Ophthalmology  
Ophthalmology Department  
Cliniques Universitaires St Luc  
Brussels  
Belgium

**Consuelo Prada MD**

Ophthalmologist  
Calle Eduardo Pondal  
A Coruna  
Spain

**Paul L Proffer MD FACS**

Assistant Clinical Professor  
Ohio State University  
Columbus  
USA

**Ian George Rennie MB ChB FRCS(Ed)****FRCOphth FEBO**

Professor of Ophthalmology  
Academic Unit of Ophthalmology and  
Orthoptics  
Royal Hallamshire Hospital  
Sheffield  
UK

**Carlos Rodriguez-Galindo MD**

Associate Member  
Department of Hematology/Oncology  
Division of Solid Tumours  
St Jude's Children's Research Hospital  
Memphis  
USA

**Geoffrey Edward Rose BSc MBBS MS DSc****MRCP FRCS FRCOphth**

Consultant Ophthalmic Surgeon  
Moorfields Eye Hospital  
London  
UK

**Mordechai Rosner MD**

Associate Clinical Professor and Vice-Chairman  
Goldschleger Eye Institute  
Sheba Medical Center, Sackler School of  
Medicine  
Tel-Aviv University  
Israel

**Paul Anthony Rundle MBBS FRCOphth**

Consultant Ophthalmologist  
Ocular Oncology Clinic  
Royal Hallamshire Hospital  
Sheffield  
UK

**Stefan Sacu MD**

Ophthalmologist  
Department of Ophthalmology and Optometry  
Medical University of Vienna  
Vienna  
Austria

**Andrew P. Schachat MD**

Vice Chairman for Clinical Affairs  
Cole Eye Institute  
Cleveland Clinic Foundation  
Cleveland  
USA

**Nicoline Elisabeth Schalijs-Delfos MD PhD**

Doctor  
Leiden University Medical Center  
Leiden  
Netherlands

**Lynn Schoenfield MD**

Staff Pathologist  
Department of Anatomic Pathology  
Cleveland Clinic Foundation  
Cleveland  
USA

**Ursula Schmidt-Erfurth**

Professor and Chair  
Department of Ophthalmology & Optometry  
Medical University of Vienna  
Vienna  
Austria

**Mona Schmutzer MD**

Ophthalmology Resident  
Department of Ophthalmology  
Medical University Graz  
Graz  
Austria

**Luann Sculley**

Ultrasonographer  
Cole Eye Institute  
Cleveland Clinic Foundation  
Cleveland  
USA

**Jonathan E. Sears MD**

Vitreoretinal Fellow  
The Cleveland Clinic Foundation  
Cleveland  
USA

**Stefan Seregard MD PhD**

Professor and Chairman  
St Erik's Eye Hospital  
Stockholm  
Sweden

**Rishi P. Singh MD**

Retina Fellow  
Department of Ophthalmic Oncology  
Cole Eye Institute  
Cleveland Clinic Foundation  
Cleveland  
USA

**Julie Ann Stoner PhD**

Associate Professor of Biostatistics  
University of Nebraska Medical Center  
Omaha  
USA

**Mehran Taban MD**

Ophthalmology Resident  
Cole Eye Institute  
Cleveland Clinic Foundation  
Cleveland  
USA

**Mehryar Taban MD**

Ophthalmology Resident  
Cole Eye Institute  
Cleveland Clinic Foundation  
Cleveland  
USA

**Azzam Taktak MD**

Clinical Scientist  
Ocular Oncology Service  
Department of Clinical Engineering  
Royal Liverpool University Hospital  
Liverpool  
UK

**Madhura Tamhankar MD**

Associate Professor  
Department of Ophthalmology  
University of Pennsylvania Medical School  
Philadelphia  
USA

**Elias I. Traboulsi MD**

Head, Department of Pediatric Ophthalmology  
Director, The Center for Genetic Eye Diseases  
The Cole Eye Institute  
The Cleveland Clinic Foundation  
Cleveland  
USA

**Nikolaos Trichopoulos MD**

Ocular Oncology Fellow  
Ocular Oncology Service  
Royal Liverpool University Hospital  
Liverpool  
UK

**David T. Tse MD FACS**

Professor of Ophthalmology  
Department of Ophthalmology  
Bascom Palmer Eye Institute  
Miami  
USA

**Geeta K. Vemuganti MD DNB**

Director, Ophthalmic Pathology Service  
Head, Stem Cell Laboratory  
Ophthalmic Pathology Service  
L.V. Prasad Eye Institute  
Hyderabad  
India

**Judith Villablanca MD**

Associate Professor of Clinical Pediatrics  
Hematology/Oncology  
Children's Hospital of Los Angeles  
Los Angeles  
USA



**Werner Wackernagel MD**

International Fellow  
Cole Eye Institute  
Cleveland Clinic Foundation  
Cleveland  
USA

**Allan Wilkinson PhD**

Vice-Chief of Medical Physics  
Department of Radiation Oncology and the  
Department of Ophthalmic Oncology  
Cole Eye Institute  
Cleveland Clinic Foundation  
Cleveland  
USA

**Matthew W. Wilson MD FACS**

Associate Professor of Ophthalmology  
University of Tennessee Health Science Center  
Memphis TN  
USA

**Leonidas Zografos MD**

Professor of Ophthalmology  
Jules Gonin Eye Hospital  
Lausanne  
Switzerland

**Martin Zehetmayer MD**

Staff  
Department of Ophthalmology-Oncology  
Service  
Medical University of Vienna  
General Hospital Vienna  
Vienna  
Austria

# Acknowledgements

---

To my parents who educated me beyond their means, my wife Annapurna, and my children, Nakul and Rahul, who make all my efforts worthwhile. (ADS)

To my family, Frankanne, Erika, and Stephen. (BED)

To my wife Edith and my children Liron, Neta and Doron, for years of support and patience. (JP)

To my family, Rogel, Nancy, Gary, Gayle and Maxine. (ALM)

To Clifford, Agnes, Jim, and Bud for my foundation; to Bob, Norm, and Neil for my education; to Wendy, Julian, Liam, and Remy for my inspiration. (JDP)

# Principles of clinical epidemiology

Annette C. Moll, Michiel R. de Boer and Lex M. Bouter

## INTRODUCTION

During the last decade evidence-based medicine (EBM) became a dominant approach in many medical fields, including ophthalmology.<sup>1,2</sup> Clinical epidemiologic studies provide evidence that can aid the decision-making process. The aim of this chapter is to provide the reader with some basic knowledge to allow them to judge the value of clinical epidemiological papers. Examples from ocular oncology will be used to illustrate the methodological principles.

## RESEARCH QUESTION

A clinical epidemiological study should always start with a well-defined research question. Similarly, when reading a paper, one should always keep in mind the question(s) the authors wish to address (Fig. 1.1). Research questions can be aimed at explanation or description and are often categorized as etiologic, diagnostic or prognostic (Table 1.1). For example, an explanatory research question related to etiology in the field of ocular oncology is: are children born after in vitro fertilization at higher risk of developing retinoblastoma than children born after natural conception?<sup>3</sup> A correct explanatory research question should contain information on the patients, interventions, contrast and outcomes (PICO).

## OUTCOME MEASURES

Traditionally, prevalence, incidence and mortality (survival) have been the outcome measures in clinical cancer epidemiology studies. More recently, quality of life has become increasingly popular. In ophthalmic oncology, visual acuity is an important outcome measure.

**Prevalence** refers to the proportion of the population with the condition of interest. Usually prevalence is given for a specific moment in time (point prevalence), but sometimes it is estimated for a period of time (e.g. 1-year or lifetime prevalences). For example, the lifetime prevalence of uveal melanoma in a white population with ocular (dermal)melanocytosis is estimated to be 0.26%.<sup>4</sup>

**Incidence** Whereas prevalence relates to existing cases, incidence relates to the proportion of new cases in a certain population. It is important that the population under investigation is at risk of developing the condition. For example, persons with bilateral enucleation are no longer at risk of developing uveal melanoma. There are two different measures of incidence: cumulative incidence (CI) and incidence density (ID). CI is the proportion of new cases in a population at risk over a specified period. For example, the cumulative incidence of

second malignant neoplasms in hereditary retinoblastoma patients is 17% at the age of 35 years.<sup>5</sup> ID refers to the rate of developing the condition during follow-up, usually expressed as a proportion of person-years at risk.

**Mortality** refers to the incidence of death. The mortality rate can be all-cause, indicating all deaths, or disease specific, for instance mortality caused by melanoma or retinoblastoma. Case fatality rate refers to the proportion of patients with a given disease who will die from that disease, and thus reflects the seriousness of the condition. More formally put, it concerns the cumulative incidence of death among the diseased. Often the survival rate is presented. For example, the 2-year survival rate after breast cancer metastases to the choroid is 30%.<sup>6</sup> This means that of all the patients diagnosed with choroidal metastases from breast cancer, 30% are still alive 2 years after diagnosis. It is important to realize that these mortality figures are highly dependent on certain characteristics of the population, such as age, stage of cancer, and comorbidity.

**Quality of life** With the increasing survival rate and severe side effects of some treatment modalities, quality-of-life measures have become increasingly important in ophthalmic oncology. These measures encompass symptoms as well as physical, social and psychological functioning from the patient's perspective. Usually quality of life is assessed with a structured questionnaire and scores are summarized assuming an interval scale. Several questionnaires have recently been developed for patients with ocular diseases, such as the measure of outcome in ocular disease (MOOD).<sup>7</sup>

## MEASURES OF ASSOCIATION

In epidemiological research we are usually interested in associations between certain interventions or exposures and their respective outcomes, e.g. is there an association between paternal age and retinoblastoma in the offspring?<sup>8</sup> There are several statistical approaches that can be used to quantify associations, either as a ratio or as a difference, depending on the study design and statistical method used (Table 1.2).

**Relative risk** The ratio of cumulative incidence between a group of exposed and unexposed individuals or treated and untreated patients is the relative risk (RR). For example, in The Netherlands the RR of retinoblastoma in children conceived by in vitro fertilization is between 4.9 and 7.2. This implies that the risk of developing retinoblastoma is

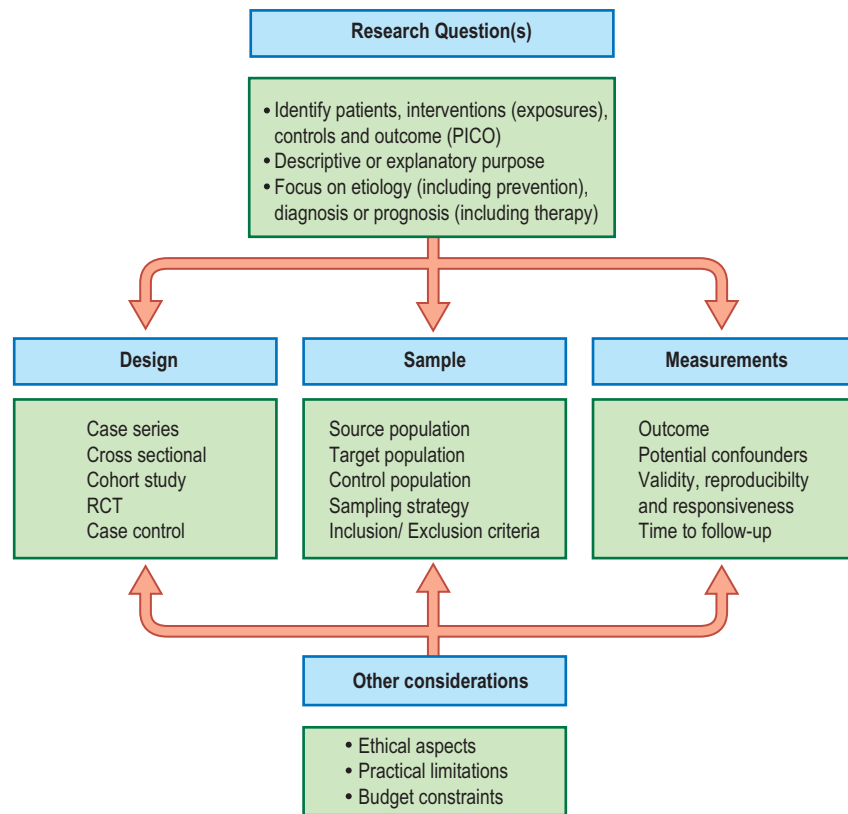


Fig. 1.1 Steps in designing clinical epidemiological research.

Table 1.1 Types of epidemiological research		
Type of research	Purpose	Example
Etiology (including prevention)	To examine possible etiological factors for the occurrence of a disease	Association between ultraviolet radiation and uveal melanoma
Diagnosis	To examine the usefulness of diagnostic tests for the disease	Accuracy of magnetic resonance imaging in determining choroidal invasion of retinoblastoma
Prognosis (including interventions)	To examine possible prognostic factors for the disease	Association between external beam therapy for retinoblastoma and the incidence of second malignant neoplasms

between 4.9 and 7.2 times higher for children conceived after IVF than for naturally conceived children.

**Hazard ratio** The ratio of incidence density between a group of unexposed and exposed patients is the hazard ratio (HR), which has a similar interpretation to the RR. This measure is often used in relation to mortality, because we are generally interested not only in the proportion of patients that die, but also in the time from baseline (diagnosis or start treatment) until death. A special application of the HR is the ratio of the observed to the expected number of cases (O/E ratio). In this case the observed ID is calculated for the study population and this is compared to the expected ID derived from a population registry (e.g. cancer registration). For example, in a study of lifetime risks of common cancers among hereditary retinoblastoma survivors ( $n = 144$ ), 41 cancer deaths were observed, whereas only 7.58 deaths due to cancer were expected. These data can be expressed as a standardized mortality ratio of 5.41.<sup>9</sup>

**Odds ratio** The odds ratio (OR) is the most commonly reported measure of association in the literature, because this is the statistic that can be derived from popular logistic regression analysis. The OR is the ratio of the odds of outcome of interest between the exposed and the unexposed.

**Differences in risk** are preferably reported as the outcome of randomized controlled trials. The risk difference (RD) is easy to interpret and can be used to calculate the number of patients needed to treat (NNT) to prevent one extra event (e.g. death) compared to the standard treatment or placebo. The NNT can be calculated as inverse of RD ( $1/\text{RD}$ ).

**Differences in mean score** For scores on interval scales, such as quality of life, differences in mean score between exposed and unexposed participants are the only measure of interest.



**Table 1.2 The relation between outcome, measures of association, study design, and statistical methods**

Outcome	Measure of association	Computation	Study design	Statistical method
Prevalence	Prevalence rate	$P_1/P_2$	Cross-sectional	$\chi^2$ test Logistic regression analysis
Odds of exposure	Prevalence difference	$P_1 - P_2$	Cross-sectional	$\chi^2$ test
	Odds ratio	Odds of exposure group 1/odds of exposure group 2	Case control study (cohort study, RCT)	$\chi^2$ test Logistic regression
Cumulative incidence (CI)	Relative risk	$CI_1/CI_2$	Cohort study/RCT	$\chi^2$ test
	Risk difference	$CI_1 - CI_2$	RCT	
Incidence density (ID)	Hazard ratio	$ID_1/ID_2$	Cohort study/RCT	Kaplan–Meier Cox regression
	Risk difference	$ID_1 - ID_2$	RCT	Kaplan–Meier
	O/E ratio	Observed ID/expected ID in general population	Cohort study/registry study	
Quality of life	Difference in mean score	$\chi_1 - \chi_2$	Cohort study/RCT	Independent t-test Linear regression analyses

$P_1$ , prevalence group 1;  $P_2$ , prevalence group 2; CI = cumulative incidence;  $CI_1$ , CI group 1;  $CI_2$ , CI group 2; ID, incidence density;  $ID_1$ , ID group 1;  $ID_2$ , ID group 2; O/E ratio, observed to expected ratio; RCT, randomized controlled trial;  $\chi_1$ , mean score group 1;  $\chi_2$ , mean score group 2.

## PRECISION OF THE ESTIMATE

When interpreting an outcome, we want to know not only the numerical value of the point estimate, but also the precision with which it has been estimated. In other words, can we be confident that the observation is not just a chance finding? The usual standard for accepting an outcome beyond chance is  $P$  (probability)  $< 0.05$ . A more informative description is provided by the 95% confidence interval (CI). The rough interpretation of the 95% CI is that there is a 95% chance that the real value lies within the span of the confidence interval.

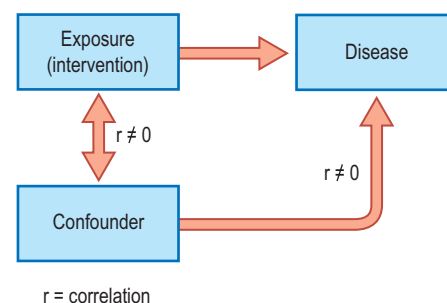
Statistical significance is strongly dependent on the sample size of a study. This means that in very large samples an only marginally elevated association can be statistically significant. In contrast, in small samples, strong associations are sometimes not statistically significant. The associations, although statistically significant, need not be clinically important. Therefore, the interpretation of findings should not rely solely on statistical significance.

## BIAS

An estimate can be very precise, but still not be accurate because of bias. Three main sources of bias exist: confounding, selection, and information bias.

**Confounding** occurs when the association between exposure and outcome is influenced by a third variable that is related to both the exposure and the outcome (Fig. 1.2). A recent study found an association between cooking (as occupation) and the incidence of ocular melanoma.<sup>10</sup> It could be argued that as many cooks work at night it is possible that they could have relatively high exposures to sunlight, as their leisure activities take place during the day, compared to people who work during the day. It is implied that the association between cooking and ocular melanoma could potentially (in part) be explained by a higher exposure of cooks to sunlight.

**Selection bias** may occur when the chance of being included in the study population is not random for all members of the source



**Fig. 1.2** Schematic representation of confounding.

population. For example, patients with an advanced tumor stage are more likely to be referred to a special cancer center than are patients with a less advanced stage. This is called referral bias. Selection bias could also be introduced in a study by choosing the wrong control group, especially if controls are selected from hospital patients.

**Information bias** occurs when outcome or exposure variables are not accurately assessed. This is especially problematic when this occurs differently for exposed versus non-exposed cases, or for cases versus controls. A well known type of information bias is recall bias. This refers to the phenomenon that patients tend to remember more details about exposures that are possibly related to their disease than do controls. For example, patients with uveal melanoma are probably more aware of the fact that their disease could be related to sunlight exposure. This can lead to an underestimation of exposure in controls and hence an overestimation of the association with sunlight exposure.

## STUDY DESIGNS

There are several research designs, such as case series, cross-sectional, cohort, randomized control trial, and case-control study, that can be adopted to address the research question. Each design has its advantages and disadvantages (Table 1.3).

**Table 1.3 Advantages and disadvantages of study designs**

Considerations		Type of study			
		Cross-sectional	Cohort	RCT	Case-control
Methodological	Confounding	–	–	+	–
	Selection bias	–	+/-	+/-	–
	Information bias	+/-	+/-	+/-	–
	Prior exposure	–	+	+	–
	Incident cases	–	+	+	+
Practical	Length of study	+	–	+/-	+
	Organization	+	+/-	–	+/-
	Expenses	+	–	–	+

Negative score (–) indicates disadvantage compared to other study designs.  
Positive score (+) indicates advantage compared to other study designs.  
Equivocal score (+/-) indicates neither advantage nor disadvantage compared to other study designs.  
RCT, randomized controlled trial.

**Case series** In a case series the authors present the clinical data regarding a group of patients, e.g. the response of tumors to chemotherapy combined with diode laser in retinoblastoma patients. The disadvantage is that this kind of study is not randomized and does not have a comparative design, and does not permit an answer to a question such as ‘there is a good response, but compared to what?’<sup>11</sup>

**Cross-sectional study** In a cross-sectional study the outcome (and exposure) are assessed at one point in time. In addition, outcome between exposed and unexposed study participants can be compared in order to explore etiological questions. In a cross-sectional study on the association between iris color and posterior uveal melanoma, melanoma patients ( $n = 65$ ) with a light iris color were significantly more likely to have darker choroidal pigmentation than controls ( $n = 218$ ) ( $P = 0.005$ ). In addition, darker choroidal pigmentation was associated histologically with an increased density of choroidal melanocytes ( $P = 0.005$ ). The authors concluded that increased choroidal pigmentation, as a result of an increase in the density of pigmented choroidal melanocytes, is not protective but may actually be a risk factor for the development of posterior uveal melanoma in white patients.<sup>12</sup>

The cross-sectional study design has the advantage that it is relatively easy to plan, only one measurement is needed, and it is inexpensive and quick to perform. As both exposure and outcome are measured at the same time, we cannot be sure that the exposure preceded the outcome (the most important criterion for causality). Moreover, the associations found in a cross-sectional study might not be applicable to incident cases.

**Cohort study** Some of the problems listed above can be overcome by conducting a cohort study. At baseline, one starts with a cohort of people free from disease and the exposure(s) of interest being assessed at baseline. During or at the end of follow-up, incident cases in both the unexposed and the exposed group are identified and RRs or HRs can be calculated. Despite the theoretical advantages of a cohort design, there are some practical disadvantages. The cohort studies are often expensive because they need large sample sizes and/or long follow-up to accumulate enough incident cases for meaningful analysis.

Moreover, the potential bias of (residual) confounding can never be totally excluded.

**Randomized controlled trial** is a specific type of cohort study. At the start of the study, participants are randomly assigned to the intervention group (treatment under investigation) or a control group (no treatment, placebo, or standard treatment). After the start of a treatment patients often get better. This may be due to the treatment or to other circumstances, such as spontaneous resolution, effective co-interventions, and placebo effects. The best comparison is often between the new treatment and the best available one, not the sham treatment.<sup>13</sup> The randomization, if successful, ensures that confounding factors are evenly distributed between the intervention and control groups.

For clinicians interested in evidence pertaining most directly to a particular class of patient, subgroup analysis can be very informative. The strength of evidence for subgroup effects depends on whether hypotheses have been defined prior to analysis, whether potential problems regarding multiple comparisons have been considered, and whether the effects found are biologically plausible. Using these guidelines, the reader of a trial report should be able to decide whether the presented subgroup effects are of clinical importance or if the overall result is a better estimate of treatment effect.<sup>14</sup>

**Case-control study** In contrast to cohort studies, the starting point in case-control is to assess not the exposure status, but the disease status. People with the disease of interest are selected and a control group of people without the disease is subsequently recruited. The control group should include people from the same source population as the cases, implying that if any of the controls had developed the disease, they would have been eligible for inclusion in the study as a case.

The selection of a valid control group is important in case-control studies. It is possible to select population controls, hospital controls, friends or relatives of patients, or any variant of these.<sup>15</sup> Case-control studies have the advantage of being relatively quick and inexpensive to conduct, and are especially appealing in rare diseases. A disadvantage is the large potential for selection bias, especially in the recruitment of controls. In addition there is also a real danger of information (recall) bias.

**Pilot study** A pilot study is often performed before the start of a large study. Its aim is to improve the methodological quality and evaluate the feasibility of the study. The results of a pilot study are often used to gain an impression of the efficacy of an intervention, which should then be tested in a larger study. The inclusion of pilot study results in a later cumulative meta-analysis may lead to sufficient power to assess the efficacy of an experimental intervention.<sup>16</sup>

**Systematic review** In a systematic review all the available evidence (literature) on a certain topic is reviewed in a systematic, transparent, and reproducible manner. These studies can be especially useful when results from single studies are contradictory and/or have large confidence intervals because of small sample sizes. When the studies in a systematic review are reasonably homogeneous, their results can be pooled in a meta-analysis. This results in one effect size for all the studies together, with a much smaller confidence interval than for the individual studies. An example is a systematic review on

the survival of patients with uveal melanoma treated with brachytherapy. The result of this meta-analysis showed that the 5-year melanoma-related mortality rate was 6% for small and medium tumors, and 26% for large tumors.<sup>17</sup>

## CONCLUSIONS

In general, ophthalmic tumors are rare compared to other ophthalmic diseases. Therefore, it is difficult to conduct large studies with enough power to obtain statistically significant and clinically relevant results. Several studies are published each year, most of them descriptive and concerning retrospective patient series. To conduct a randomized clinical trial international collaboration is necessary, so as to include enough patients in the different treatment arms of the study. Furthermore, uniform definitions and study methodologies are very important so that the different studies in the literature can be compared and systematic reviews and meta-analyses performed.

## REFERENCES

- Sackett DL. Clinical epidemiology. What, who, and whither? *J Clin Epidemiol* 2002; 55: 1161–1166.
- Guyatt GH, Haynes RB, Jaeschke RZ et al. Users' guides to the medical literature: XXV. Evidence-based medicine: principles for applying the Users' Guides to patient care. Evidence-Based Medicine Working Group. *JAMA* 2000; 284: 1290–1296.
- Moll AC, Imhof SM, Cruysberg JR et al. Incidence of retinoblastoma in children born after in-vitro fertilisation. *Lancet* 2003; 361: 309–310.
- Singh AD, De Potter P, Fijal BA et al. Lifetime prevalence of uveal melanoma in white patients with oculo(dermal) melanocytosis. *Ophthalmology* 1998; 105: 195–198.
- Moll AC, Imhof SM, Bouter LM et al. Second primary tumors in patients with hereditary retinoblastoma: a register-based follow-up study, 1945–1994. *Int J Cancer* 1996; 67: 515–519.
- Shakin EP, Shields JA, Shields CL. Metastatic cancer to the uvea: a survey of 300 cases. In: Shields JA, Shields CL, eds. *Intraocular tumors: a text and atlas*. Philadelphia: WB Saunders; 1992: 235.
- Foss AJ, Lamping DL, Schroter S et al. Development and validation of a patient based measure of outcome in ocular melanoma. *Br J Ophthalmol* 2000; 84: 347–351.
- Moll AC, Imhof SM, Kuik DJ et al. High parental age is associated with sporadic hereditary retinoblastoma: the Dutch retinoblastoma register 1862–1994. *Hum Genet* 1996; 98: 109–112.
- Fletcher O, Easton D, Anderson K et al. Lifetime risks of common cancers among retinoblastoma survivors. *J Natl Cancer Inst* 2004; 96: 357–363.
- Stang A, Ahrens W, Baumgardt-Elms C et al. Cooking and uveal melanoma risk: results from two German case-control studies. *Cancer Causes Control* 2003; 14: 377–380.
- Harbour JW. What is the best treatment for retinoblastoma? *Am J Ophthalmol* 2004; 138: 471–473.
- Harbour JW, Brantley MA Jr, Hollingsworth H et al. Association between choroidal pigmentation and posterior uveal melanoma in a white population. *Br J Ophthalmol* 2004; 88: 39–43.
- Abel U, Koch A. The role of randomization in clinical studies: myths and beliefs. *J Clin Epidemiol* 1999; 52: 487–497.
- Oxman AD, Guyatt GH. A consumer's guide to subgroup analyses. *Ann Intern Med* 1992; 116: 78–84.
- Lasky T, Stolley PD. Selection of cases and controls. *Epidemiol Rev* 1994; 16: 6–17.
- Friedman LM, Furberg CD, De Mets DL. *Fundamentals of clinical trials*. St Louis: Mosby; 1996.
- Seregard S. Long-term survival after ruthenium plaque radiotherapy for uveal melanoma. A meta-analysis of studies including 1,066 patients. *Acta Ophthalmol Scand* 1999; 77: 414–417.

## FURTHER READING

- Fletcher RH, Fletcher SW, Wagner EH. *Clinical epidemiology: the essentials*. Baltimore: Williams & Wilkins; 1996.
- Guyatt G, Rennie D (eds) *Users' guide to the medical literature: A manual for evidence-based clinical practice*. Chicago: AMA Press; 2002.
- Rothman KJ. *Epidemiology: an introduction*. New York: Oxford University Press; 2002.
- Sackett DL, Strauss SE, Richardson WS, Rosenberg W, Haynes RB. *Evidence-based medicine*. Edinburgh: Churchill Livingstone; 2000.
- [www.cche.net/usersguides/main.asp](http://www.cche.net/usersguides/main.asp). User's guide to evidence-based practice. Educative series of articles from the JAMA.
- [www.cebm.net](http://www.cebm.net). Website of the centre for evidence-based medicine, Oxford, UK.

# Cancer etiology

Evelyn X. Fu and Arun D. Singh

## INTRODUCTION

Cancer is an abnormal mass of tissue resulting from the clonal expansion of a single precursor cell that has incurred genetic damage. Such genetic damage may be inherited in the germline, acquired by the action of chemicals, radiation, or microorganisms, or a combination of both. The principal classes of gene targeted by these agents are growth-promoting proto-oncogenes, growth-inhibiting tumor suppressor genes, genes that regulate programmed cell death (apoptosis), and genes involved in DNA repair (Fig. 2.1). In this chapter we discuss the major categories of carcinogen and their role in the etiology of cancer, with emphasis on common ophthalmic cancers.

## CARCINOGENIC AGENTS

Carcinogenic agents, either individually or in combination with genetic predisposition, cause cancers. For example, squamous cell carcinoma of the conjunctiva is caused by certain strains of human papillomavirus (HPV), familial retinoblastoma is essentially determined by genetic susceptibility, and uveal melanoma is caused by multiple factors that remain obscure. Carcinogenic agents may be classified as chemical, ultraviolet light, microbial, or dietary. Separate categories of genetic predisposition to cancer and iatrogenic cancers are also considered (Table 2.1).

## CHEMICAL CARCINOGENS

Since Sir Percival Pott's observation that chronic exposure to soot increased the incidence of scrotal skin cancer among chimney sweeps in the early 18th century, hundreds of chemicals have been shown to be carcinogenic in humans. Exposure to these carcinogens can be a result of occupation (asbestos, radon, dyes), cultural behavior (alcohol, tobacco, salted fish), or chemotherapy (see section on Iatrogenic cancers). Relatively few carcinogens are direct acting because the innate reactivity of these chemical compounds makes them unstable in the environment. Rather, most carcinogens require metabolic activation to a more stable reactive intermediate if they are to cause genetic damage.

**Occupational exposure** More than 20 substances have been associated with an increased risk of cancer in the workplace. Approximately half of these have been implicated in lung cancer, with asbestos being the best-known example. Many studies have identified aromatic amines such as auramine, naphthylamine, and benzidine as main compounds that induce bladder cancer.

## Behavioral exposure

**Tobacco** is a major cause of malignancy and accounts for more than 30% of mortality due to cancer. It is associated with cancers of the oral cavity, pharynx, larynx, lung, esophagus, stomach, pancreas, colon, rectum, kidney, bladder, ureter, and cervix. Although more than 60 carcinogens have been identified in tobacco, most of the carcinogenicity is due to polycyclic aromatic hydrocarbons, nitrosamines, and aromatic amines.

The risk of lung cancer increases in proportion to both duration of smoking and amount smoked per day. Studies show the risk of lung cancer among long-term heavy smokers is at least 20 times greater than in non-smokers. Unlike the risk of coronary heart disease, the absolute risk of lung cancer in former smokers never declines to the level in non-smokers. However, encouragingly, 10 years after smoking cessation the risk is reduced by at least 60%.

**Alcohol** has been implicated in the etiology of liver, rectal, and breast cancers. Smoking and drinking are synergistic in increasing the risk of oral cancer over 35-fold among two-pack-a-day smokers who consume more than four alcoholic drinks per day. Similar tobacco–alcohol interactions have been observed for esophageal and laryngeal cancers.

## ULTRAVIOLET LIGHT

Voluminous evidence indicates that electromagnetic waves such as ultraviolet light, X-rays,  $\gamma$ -rays, and accelerated atomic particles (electrons, protons, neutrons) are carcinogenic. Among different spectrums of ultraviolet (UV) light, UVB (280–320 nm) is believed to be oncogenic. Ultraviolet light A, with longer wavelengths (320–400 nm) does not have enough energy to induce genetic damage. Ultraviolet light C (200–280 nm) is filtered out by the ozone and is not considered significant in causing cancer.

Epidemiologic studies indicate that ultraviolet light from sun exposure is associated with an increased incidence of skin cancers: squamous cell carcinoma, basal cell carcinoma, and melanoma.<sup>1</sup> In the eye, ultraviolet light exposure has been linked to ocular surface squamous neoplasia.<sup>2,3</sup> Although Caucasian race, light skin color, blond hair, and blue eyes are risk factors for uveal melanoma, sunlight exposure has not been implicated as a cause for this condition. In fact, physiologic, epidemiological, and genetic evidence argues against a role for ultraviolet exposure in the pathogenesis of uveal melanoma.<sup>4</sup>

The mechanism by which ultraviolet light induces cancer is well studied in patients with the autosomal recessive disorder xeroderma



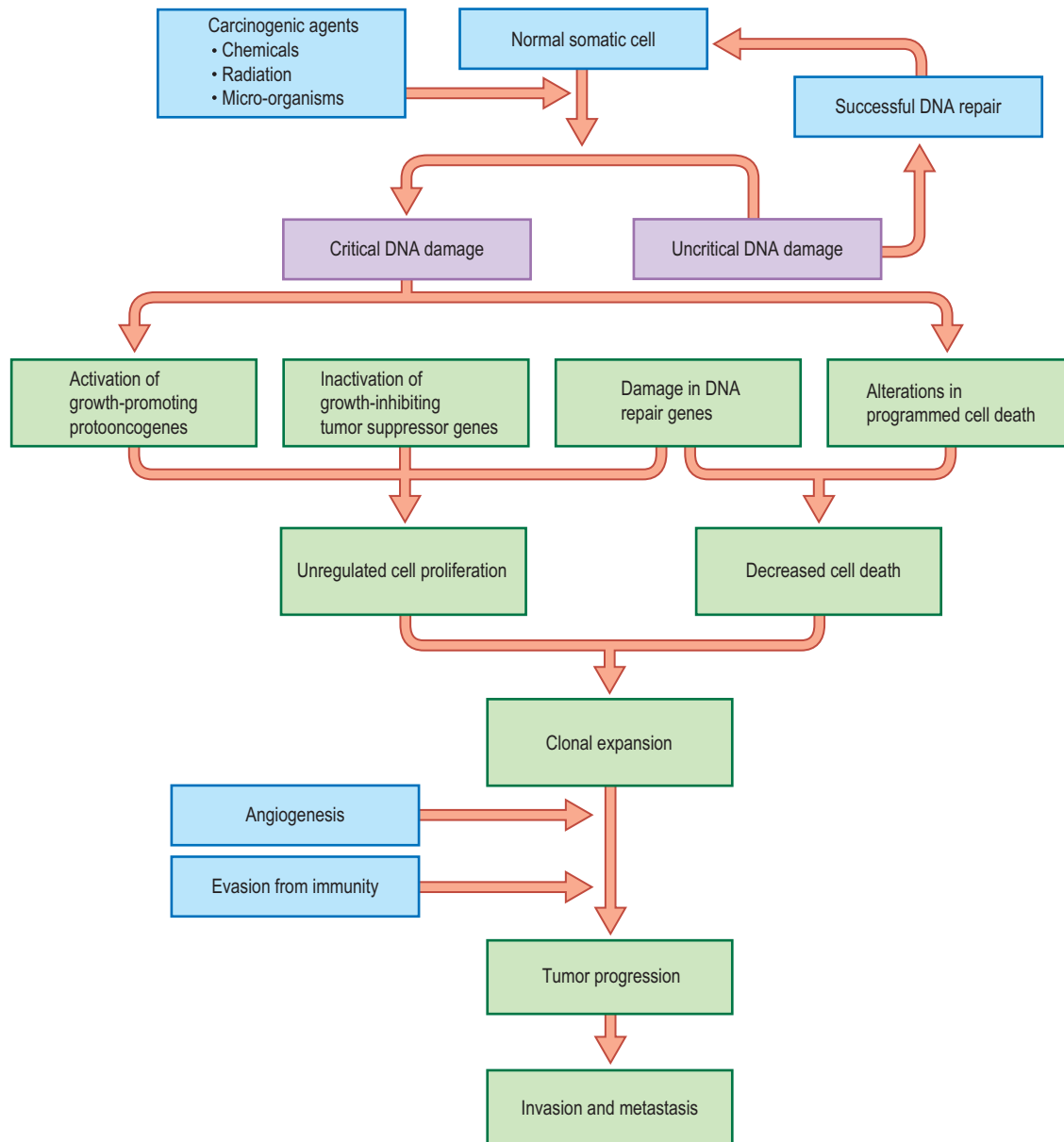


Fig. 2.1 Mechanism of carcinogen action.

Chemicals	Radiation	Infectious	Dietary	Iatrogenic
Occupational Arsenic Asbestos Coal tars Soot Benzene Vinyl chloride	UV light X-ray γ-Ray Nuclear radiation	Virus HPV EBV KSHV HTLV-1 HEP B/C	Fat Calorie Low fiber	Radiation Immunosuppression Chemotherapy
Behavioral Tobacco Alcohol		Bacteria <i>H. pylori</i> <i>C. psittaci</i> Fungus <i>A. flavus</i> Parasite <i>Schistosoma</i> <i>Clonorchis</i>		

pigmentosum (XP). In normal cells the nucleotide excision repair pathway (NER) recognizes and repairs the DNA damage (pyrimidine dimer formation) induced by ultraviolet light. Because of mutations in the NER pathway, XP patients lack the ability to repair ultraviolet light-induced DNA damage, thereby have an increased risk of skin cancer of 2000-fold.<sup>5</sup> Ultraviolet light rays also cause mutations in proto-oncogenes and tumor suppressor genes (e.g. p53).<sup>6</sup> The substitution of thymidine for cytosine in the tumor suppressor gene p53 is pathognomonic for ultraviolet light-induced skin damage and is found in more than 90% of squamous cell carcinomas.<sup>7</sup>

## MICROBIAL AGENTS

A number of microbial agents have been recognized by the International Agency for Research on Cancer as carcinogenic. The mechanism by which each pathogen induces carcinogenesis is complex. Simplistically, infectious agents induce genomic instability by chronic inflammation, impairment of the host immune system, modulation of proliferation–antiproliferation pathways, or a combination of mechanisms (Fig. 2.2).

**Viruses** It has been estimated that approximately 15% of all human cancers are caused by DNA and RNA viruses.<sup>1</sup> Human papillomavirus (HPV), Epstein–Barr virus (EBV), hepatitis viruses B and C, and Kaposi sarcoma herpesvirus (KSHV) are some of the important oncogenic viruses implicated in human cancers.

**Human papillomavirus** The association between HPV and cancer was first recognized in the early 1930s. Since then, more than 200 genotypes of HPV have been identified and most infect the squamous epithelium. A subset has been shown to cause benign papilloma (wart) or squamous cell carcinoma of the oral, laryngeal, cervical, and anogenital regions. HPV 16 and 18, and less commonly HPV 31, 33, 35, and 51, have been found in approximately 85% of invasive cervical

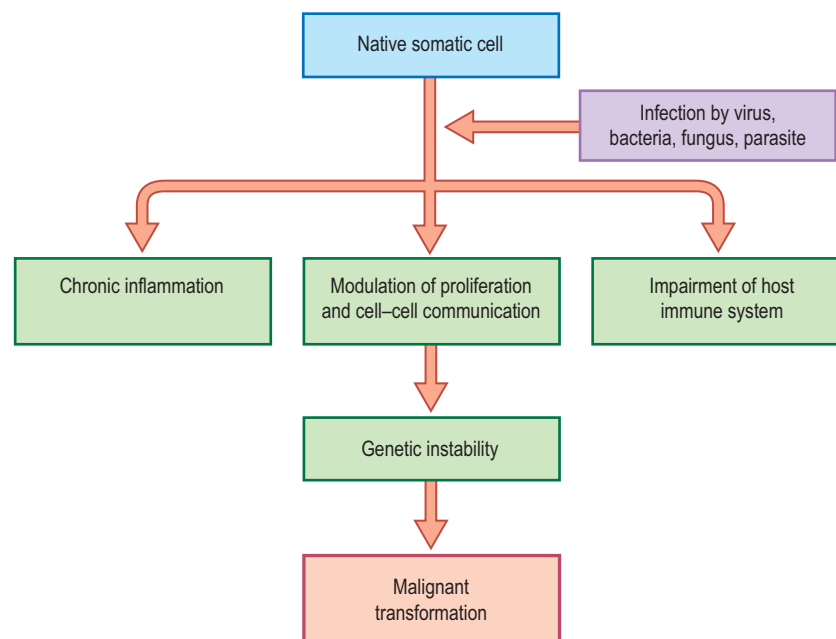
squamous cell carcinomas. The oncogenicity of HPV strains depend on their ability to disable p53 and pRB, two important tumor suppressor proteins that regulate the cell cycle.

Recently, several studies have suggested a role for HPV in ocular surface squamous neoplasia (OSSN), which includes dysplasia, carcinoma in situ, and squamous cell carcinoma of the conjunctiva or cornea.<sup>8</sup> DNA from HPV 6, 11, 16, and 18 has been found in OSSN tissue using polymerase chain reaction amplification and immunostaining.<sup>9</sup> However, some believe that HPV alone may not be capable of inducing OSSN. Several studies have detected HPV in apparently healthy conjunctiva.<sup>10</sup>

**Epstein–Barr virus (EBV)** has been implicated in the pathogenesis of a number of cancers, including the African form of Burkitt lymphoma, B-cell lymphomas in immunosuppressed individuals, Hodgkin lymphoma, and nasopharyngeal carcinomas. The molecular basis of EBV-induced cellular transformation is complex and is beyond the scope of this chapter.

The role of EBV in ocular cancers is under investigation. EBV DNA was detected in two of 21 (9.5%) patients with primary intraocular lymphoma and four of 14 (28.5%) patients with adnexal lymphoma.<sup>11</sup> At present there is no conclusive evidence to link EBV to any type of OSSN, despite the demonstration of EBV nuclear antigen-1 (EBNA-1) in four of 15 cases of OSSN.<sup>12</sup>

**Kaposi sarcoma herpesvirus (KSHV)** also known as human herpesvirus 8, has been shown to cause Kaposi sarcoma (KS) of the eyelid and conjunctiva. Since the AIDS epidemic in 1980, KS of the eyelid or conjunctiva has almost become pathognomonic for AIDS.<sup>13</sup> Fortunately, the incidence of eyelid and conjunctival KS has markedly diminished, with the advent of highly active antiretroviral therapy (HAART).



**Fig. 2.2** Pathogens induce carcinogenesis by complex mechanisms. Malignant transformation results from chronic inflammation, modulation of proliferation, cell–cell communication, and impairment of immune surveillance.

**Human T-cell lymphotropic virus-1 (HTLV-1)** infection is endemic in Japan, the Caribbean, and parts of Central Africa and South America. HTLV-1 has been associated with T-cell leukemia/lymphoma and demyelinating neurological disorders. Known ophthalmic manifestations of HTLV-1 include direct ocular infiltration in patients with adult T-cell leukemia/lymphoma, retinal degeneration, neuro-ophthalmic disorders, uveitis, necrotizing retinal vasculitis, and keratoconjunctivitis sicca.<sup>14</sup>

**Hepatitis B and C virus** Chronic infections by hepatitis B or C viruses are a major risk factor for hepatocellular carcinoma. HBV and HCV have not been associated with any ophthalmic cancers, but have been implicated in the causation of corneal ulceration, keratitis, cataract, uveitis, papillitis, and ophthalmoplegia.<sup>15</sup>

## Bacteria

**Helicobacter pylori** There is strong epidemiological evidence associating *Helicobacter pylori* infection with gastric carcinomas and mucosa-associated lymphoid tissue (MALT) lymphoma.<sup>16</sup> It is believed that chronic inflammation due to *H. pylori* infection leads to atrophic gastritis with resultant achlorhydria, which in turn favors bacterial growth that convert nitrates (dietary components) to nitrites. These nitrites, in combination with genetic factors, promote abnormal cellular proliferation, genetic mutations, and eventually cancer.

**Chlamydia psittaci** Chlamydia is a family of obligate intracellular bacteria known to cause a wide spectrum of diseases. Antigenic stimulation due to chronic *Chlamydia* infection has been suspected to induce cellular transformation and the development of cancer. Infections by *C. trachomatis* and *C. pneumoniae* have been shown to be associated with cervical carcinoma and lung cancer. Recent evidence suggests that *C. psittaci* may be associated with the development of ocular adnexal lymphomas.<sup>17</sup> *C. psittaci* DNA was detected in biopsy samples from 80% of 40 patients with ocular adnexal lymphoma, and in peripheral-blood mononuclear cells (PBMC) of 40% of these patients. One month after doxycycline treatment, objective regression of the ocular adnexal lymphoma was observed and chlamydial DNA in the PBMC became undetectable.<sup>18</sup>

**Fungus** Aflatoxins derived from *Aspergillus flavus* are a major cause of liver cancer in certain regions of the world, such as China and South Africa. These highly carcinogenic toxins are found in 'moldy' grain and peanuts.

**Parasites** *Schistosoma*, *Clonorchis*, and *Opisthorchis* are known to cause cancer by producing chronic inflammation. Bladder cancer is one of the most severe complications of chronic schistosomiasis.

## DIETARY FACTORS

One-third of all cancer deaths are thought to be related to diet. Two major dietary influences are fat and calorie consumption. Fat consumption is strongly associated with hormone-dependent cancers such as breast, ovarian, endometrial, and prostate cancers. It is unclear whether these relationships are causal and, if so, whether they relate to the type of fat, the overall caloric content, or a combination of both.

A low-fiber diet has also been implicated in carcinogenesis, specifically colorectal cancer. It is hypothesized that a high-fiber diet may

lower the risk of colon cancer by increasing fecal bulk and diluting the concentration of carcinogens in the colon, thereby limiting the exposure of colonic mucosa to potential mutagens. However, prospective trials have failed to demonstrate a protective effect of dietary fiber against the development of colorectal cancers.

## GENETIC SUSCEPTIBILITY

In addition to carcinogen exposure genetic predisposition increases the risks of certain types of cancer. A number of cancers, retinoblastoma being the most striking example, show an autosomal dominant inheritance pattern. Others have an autosomal recessive inheritance, such as skin cancer in patients with xeroderma pigmentosum. Some cancers occur at higher frequency in families without a clearly defined pattern of transmission. The role of genetic factors in neoplasia is discussed in detail elsewhere (see Chapter 16).

## IATROGENIC CANCERS

**Immunosuppression** Patients with immunosuppression have increased risks for lymphomas and carcinomas. Rates of post-transplant lymphoma (PTLD) have been reported to be as high as 25% in liver transplant and 1–5% in kidney transplant patients.<sup>19</sup> Other carcinomas of several sites are also observed in post-transplant patients. In the majority of cases localized infections with agents such as EBV, HPV, and KPSV play a pivotal role in carcinogenesis.

**Chemotherapy** Second primary cancers have been estimated to occur in 5–10% of patients who have received chemotherapy. The treatment of Hodgkin's disease, ovarian cancer, multiple myeloma, or small cell carcinoma of the lung using multiagent chemotherapy is associated with the long-term complication of acute myeloid leukemia (AML).<sup>20</sup> The risk of AML is most strongly associated with the alkylating agents, particularly cyclophosphamide, melphalan, busulfan, treosulfan, semustine, and epipodophyllotoxins.<sup>21</sup> At present it is not known whether chemotherapy for retinoblastoma increases the long-term risk of iatrogenic leukemia.

**Radiation therapy** Follow-up of survivors of the Hiroshima and Nagasaki atomic bombs shows a marked increase in the incidences of leukemia and solid tumors involving the breast, colon, thyroid, and lung. Since the nuclear power plant accident in Chernobyl in 1986, more than 2000 cases of thyroid cancers have been recorded in children living in the area.<sup>22</sup> However, a more common cause of exposure to ionizing radiation is iatrogenic. Ionizing radiation used for radiation therapy (X-rays) causes DNA damage and changes chromosomal structure by colliding with atoms and molecules in its path. These high-energy collisions give rise to ions and free radicals that break chemical bonds and cause a number of DNA alterations in cells. Second malignant neoplasms following radiation therapy of retinoblastoma are discussed elsewhere (Chapter 81).

## SUMMARY

The etiology of cancer is multifactorial and the mechanisms are complex. Exposure to carcinogenic agents, genetic predisposition, and immune status, both individually and combined, are responsible for causing cancer. Chemotherapy, radiation therapy, and immunosuppression are iatrogenic causes.

## REFERENCES

- Cleaver JE, Crowley E. UV damage, DNA repair and skin carcinogenesis. *Front Biosci* 2002; 7: 1024–1043.
- Lee GA, Williams G, Hirst LW, Green AC. Risk factors in the development of ocular surface epithelial dysplasia. *Ophthalmology* 1994; 101: 360–364.
- Newton R, Ferlay J, Reeves G, et al. Effect of ambient solar ultraviolet radiation on incidence of squamous-cell carcinoma of the eye. *Lancet* 1996; 347: 1450–1451.
- Singh AD, Rennie IG, Seregard S, et al. Sunlight exposure and pathogenesis of uveal melanoma. *Surv Ophthalmol* 2004; 49: 419–428.
- Kraemer KH, Lee MM, Andrews AD, Lambert WC. The role of sunlight and DNA repair in melanoma and nonmelanoma skin cancer. The xeroderma pigmentosum paradigm. *Arch Dermatol* 1994; 130: 1018–1021.
- Selivanova G, Wiman KG. p53: a cell cycle regulator activated by DNA damage. *Adv Cancer Res* 1995; 66: 143–180.
- Harris CC, Hollstein M. Clinical implications of the p53 tumor-suppressor gene. *N Engl J Med* 1993; 329: 1318–1327.
- McDonnell JM, Mayr AJ, Martin WJ. DNA of human papillomavirus type 16 in dysplastic and malignant lesions of the conjunctiva and cornea. *N Engl J Med* 1989; 320: 1442–1446.
- Nakamura Y, Mashima Y, Kameyama K et al. Detection of human papillomavirus infection in squamous tumours of the conjunctiva and lacrimal sac by immunohistochemistry, in situ hybridisation, and polymerase chain reaction. *Br J Ophthalmol* 1997; 81: 308–313.
- Karcioglu ZA, Issa TM. Human papilloma virus in neoplastic and non-neoplastic conditions of the external eye. *Br J Ophthalmol* 1997; 81: 595–598.
- Chan CC. Molecular pathology of primary intraocular lymphoma. *Trans Am Ophthalmol Soc* 2003; 101: 275–292.
- Restelli M, Grinstein S, Gattuso P et al. Immunolocalization of the Epstein–Barr nuclear antigen-1 in conjunctival squamous carcinomas and dysplasias. *Hum Pathol* 2005; 36: 325–329.
- Kurumety UR, Lustbader JM. Kaposi's sarcoma of the bulbar conjunctiva as an initial clinical manifestation of acquired immunodeficiency syndrome. *Arch Ophthalmol* 1995; 113: 978.
- Levy-Clarke GA, Buggage RR, Shen D, et al. Human T-cell lymphotropic virus type-1 associated T-cell leukemia/lymphoma masquerading as necrotizing retinal vasculitis. *Ophthalmology* 2002; 109: 1717–1722.
- Wilson SE, Lee WM, Murakami C et al. Mooren-type hepatitis C virus-associated corneal ulceration. *Ophthalmology* 1994; 101: 736–745.
- Parsonnet J, Friedman GD, Vandersteen DP et al. *Helicobacter pylori* and the risk of gastric carcinoma. *N Engl J Med* 1991; 325: 1127–1131.
- Ferreri AJM, Guidoboni M, Ponzoni M et al. Evidence for an association between *Chlamydia psittaci* and ocular adnexal lymphomas. *J Natl Cancer Inst* 2004; 96: 586–594.
- Ferreri AJM, Ponzoni M, Guidoboni M et al. Regression of ocular adnexal lymphoma after *Chlamydia psittaci*-eradicating antibiotic therapy. *J Clin Oncol* 2005; 23: 5067–5073.
- Opelz G, Dohler B. Lymphomas after solid organ transplantation: a collaborative transplant study report. *Am J Transplant* 2004; 4: 222–230.
- Kaldor JM, Day NE, Clarke EA et al. Leukemia following Hodgkin's disease. *N Engl J Med* 1990; 322: 7–13.
- Pui CH, Ribeiro RC, Hancock ML et al. Acute myeloid leukemia in children treated with epipodophyllotoxins for acute lymphoblastic leukemia. *N Engl J Med* 1991; 325: 1682–1687.
- Williams D. Cancer after nuclear fallout: lessons from Chernobyl accident. *Nat Rev Cancer* 2002; 2: 543–549.

# Cancer pathology and angiogenesis

## PART A: CANCER PATHOLOGY

Stefan Seregard and Charlotta All-Ericsson

This text is intended as an overview of cancer pathology with particular reference to sampling and diagnostic techniques for ocular cancer. Traditionally, cancer diagnoses were made using light microscopic examination, but recent advances in molecular pathology and biology have created a complete new set of tools whereby tumors may be more accurately diagnosed and better characterized. Some of these techniques are outlined below.

### INTRODUCTION

Neoplasia (Greek for ‘new growth’) indicates cell growth that may be distinct (a lump or tumor) or diffuse (e.g. leukemia). Originally used to denote a lump of any origin (neoplastic or inflammatory), tumor as a concept is now often perceived as identical to neoplasia.

### CLASSIFICATION OF NEOPLASIA

Tumors may be either benign or malignant. Moreover, benign tumors may be precursors to malignant tumors. The most significant difference between benign and malignant tumors is that the malignant tumors have metastatic potential, whereas benign tumors do not. However, any benign or malignant tumor may cause death if inappropriately located. Characteristic differences between benign and malignant tumors are summarized in Table 3A.1.

**Benign tumors** are usually labeled by the suffix *-oma*, for example adenoma of the lacrimal gland, a benign tumor composed of cells originating from the glandular epithelium of the lacrimal gland. Some exceptions tend to cause confusion: lymphoma and melanoma are by definition malignant, irrespective of the suffix *-oma*. To emphasize this, terms such as malignant lymphoma and malignant melanoma are sometimes used.

- Hamartoma is a benign tumor composed of histologically normal cells that normally occur at the affected site.
- Choristoma is a benign tumor composed of cells not normally occurring at the affected site, but otherwise histologically normal.
- Teratoma is a tumor composed of pluripotent cells forming different types of tissue that originate from one or more of the three germ cell layers. Teratoma may be benign or malignant.

### Malignant tumors

- Carcinoma is a malignant neoplasm of epithelial origin is a carcinoma. For example, adenocarcinoma of the lacrimal gland is a cancer derived from the glandular epithelium of the lacrimal gland, and squamous cell carcinoma is a cancer originating from squamous epithelial cells.
- Sarcoma is a malignant neoplasm derived from mesenchymal tissue. For example, fibrosarcoma originates from the fibroblasts or fibrocytes of connective tissue.
- Blastoma is a malignant tumor of embryonic origin and identified by the suffix *-blastoma*. For example, retinoblastoma is derived from retinoblasts in the developing retina.
- Leukemia is a malignancy of blood cells that arises from the bone marrow precursor cells and is present in the peripheral blood.
- Lymphoma is a malignancy derived from lymph nodes, but may occasionally be present in other organs, such as the lacrimal gland or in peripheral blood.
- Melanoma is a malignant tumor that originates from melanocytes, i.e. cells containing intracytoplasmic pigment lodged in specific organelles – melanosomes. These cells appear in the skin, uvea, conjunctiva, and a variety of other tissues.

### MICROSCOPIC FEATURES OF NEOPLASIA

Certain histopathologic features differentiate benign and malignant tumors from the surrounding normal tissues (Box 3A.1). In general, the extent of such changes from the normal is more marked in malignant tumors than in benign tumors.

**Cellular proliferation** Many malignant tumors feature a large number of dividing cells with abnormal mitotic figures (Fig. 3A.1A). Cell proliferation markers such as proliferating cell nuclear antigen (PCNA) and Ki-67 often reveal a larger proportion of proliferating cancer cells than are detected by mitotic counts alone (Fig. 3A.1B). A high mitotic index (mitotic count per unit of microscopic area) is often found in rapidly growing tumors, although this is usually balanced by the presence of many apoptotic cells. Not all cancers show high cell proliferation rates: typically, many uveal melanomas feature comparatively low counts, but may none the less metastasize. However,

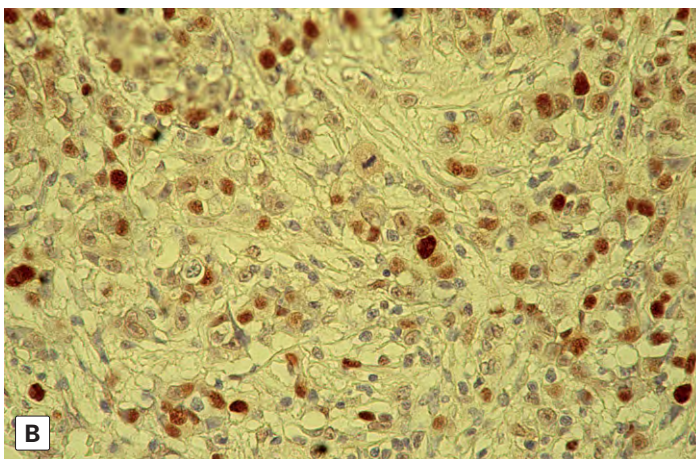
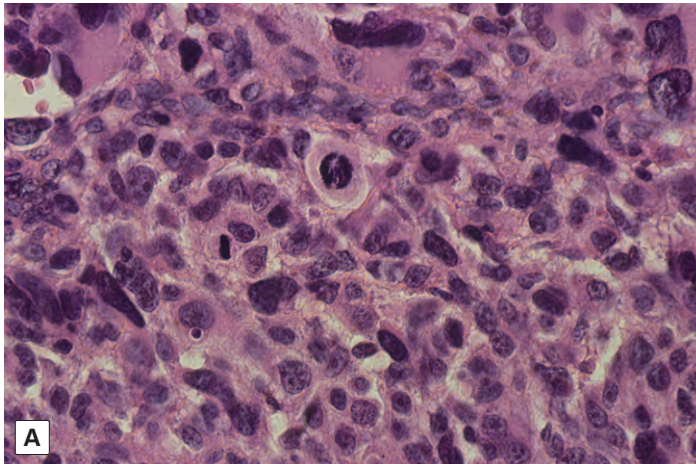


**BOX 3A.1 Microscopic Features of Neoplasia**

- Cellular proliferation
- Cellular pleomorphism
- Cellular dedifferentiation
- Nuclear cytoplasmic ratio
- Invasion of surrounding tissues

**Table 3A.1 Characteristic differences between benign and malignant tumors**

Feature	Benign	Malignant
Cellular pleomorphism	None or mild	Mild to severe
Cellular dedifferentiation	None or mild	Mild to severe
Necrosis	Rare	Occasionally
Basement membrane invasion	Never	Frequent
Metastatic spread	Never	Occasionally



**Fig. 3A.1** Many malignant tumors feature a large amount of dividing cells with abnormal mitotic figures (A). Cell proliferation markers such as proliferating cell nuclear antigen and Ki-67 often reveal a larger proportion of proliferating cancer cells than is detected by mitotic counts alone (B).

in many cancers, including uveal melanoma, a high cell proliferation rate is associated with a poor prognosis.<sup>1,2</sup>

**Cellular pleomorphism** When tissue and or cellular architecture is distorted, the tissue is classified as dysplastic. Epithelial dysplasia may be divided into mild, moderate, and severe; severe dysplasia includes full-thickness dysplasia with prominent cellular atypia and is synonymous with carcinoma in situ. It is debatable whether a slight or even a moderate degree of dysplasia is precancerous – a condition that inevitably leads to cancer. When tissue architecture is considerably distorted with individual cells showing a significant degree of variation in shape and size, including abnormal nuclei which may sometimes be binucleate or multinucleate, this is referred to as pleomorphism at the cellular level. Cellular pleomorphism, including the extreme state when the tissue of origin is no longer recognizable (anaplasia), is a hallmark of cancer.

**Cellular differentiation** Typically, cancers to some extent reproduce the architecture of the tissue of their origin. This reproduction may close resemble the original structure, and such cancers are highly differentiated, whereas others are poorly differentiated or even anaplastic. Usually, poorly differentiated cancers carry a worse prognosis than those that more closely mimic the appearance of the original tissue. The rosettes that appear in moderately and highly differentiated retinoblastoma are believed to be an attempt to reproduce the original retinal structure (Fig. 3A.2A). In uveal melanoma, the morphology of the tumor spindle cells resembles the original melanocytes, and the presence of less differentiated epithelioid cells is associated with an adverse outcome (Fig. 3A.2B, C).<sup>3</sup>

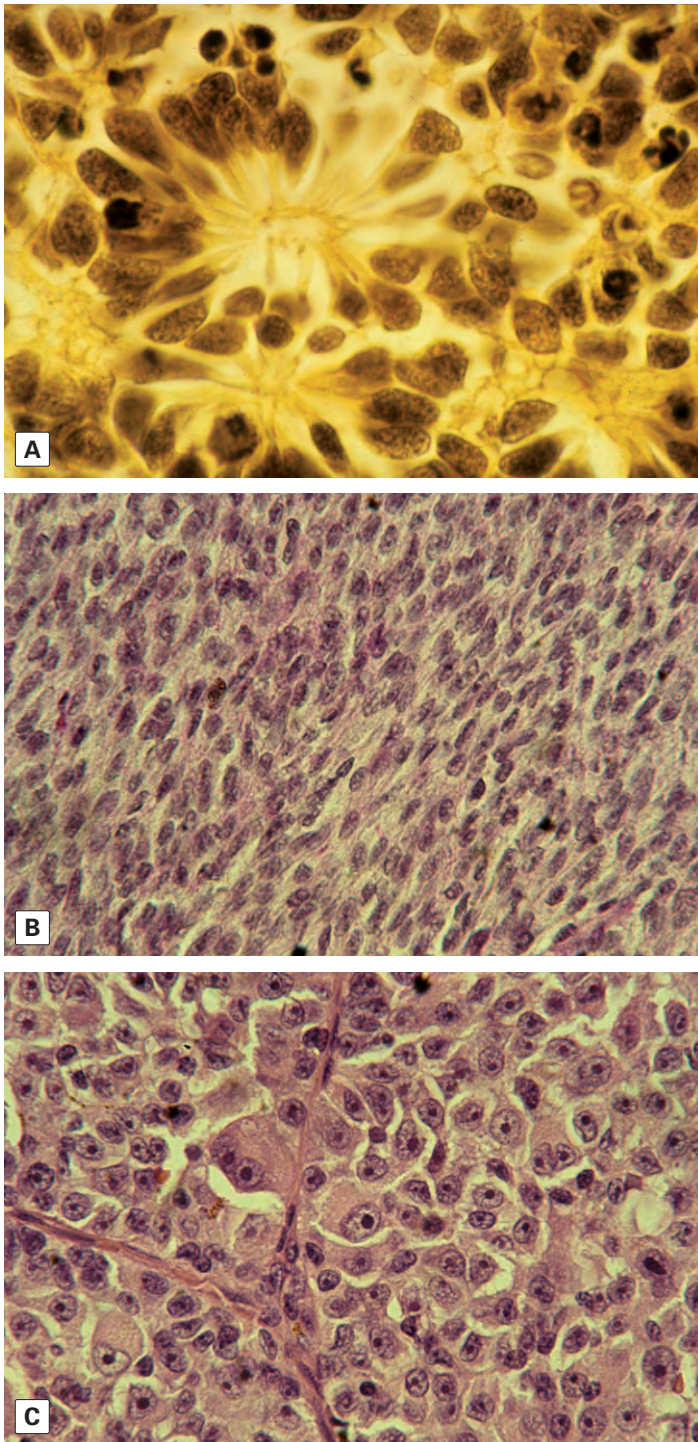
**Nuclear cytoplasmic ratio** Most neoplastic cells have a relatively large nucleus in relation to the amount of cytoplasm. However, this varies significantly with the type of neoplasia. Clear cell carcinoma of the kidney features large cells with abundant cytoplasm, whereas retinoblastoma typically is composed of cells with relatively large nuclei and small amounts of cytoplasm.

**Invasion of surrounding tissues** Tumor cells invade the surrounding tissue either by direct spread or by spreading along natural routes. In carcinomas, breakdown of the basement membrane and stromal invasion signify the progression of an in-situ carcinoma (confined to the tissue of origin) to invasive carcinoma. Cancers with minimal invasive features are sometimes referred to as microinvasive. Stromal invasion requires the degradation of tissue by a diverse family of matrix metalloproteinases and subsequent tissue remodeling. Also, most tumors must acquire a new vasculature by angiogenesis in order to be able to grow beyond a size of approximately 2 mm<sup>2</sup>.

Some malignant tumors show a particular affinity for spread along peripheral nerves, extending a considerable distance away from the primary site (e.g. perineural growth in adenocystic carcinoma of the lacrimal gland, and in some variants of squamous cell carcinoma of the skin). In some of these tumors, exuberant pain due to invasion or compression of sensory nerve fibers may be the first clinical presenting sign.

**Tumor infiltration by normal cells** In some malignant tumors, infiltration by macrophages or lymphocytes is a well known feature and probably represents an immune response to the tumor. Macrophage infiltration in uveal melanoma has recently been recognized and is (surprisingly) associated with a poor prognosis.<sup>4</sup>





**Fig. 3A.2** Highly differentiated retinoblastoma with tumor cells arranged in a radiating, flower-like pattern referred to as Flexner-Wintersteiner rosettes (A). Uveal melanoma specimens featuring spindle-type tumor cells (B), and cells with an epithelioid appearance (C).

## METASTATIC PROCESS

The most significant difference between benign and malignant tumors is the metastatic potential of the latter. Individual tumor cells may dislodge from the primary tumor and spread via the blood (hematogenous spread) or lymphatic vessels (lymphatic spread). Carcinoma tends to spread via the lymphatics, whereas sarcoma preferentially undergoes hematogenous spread.

### BOX 3A.2 Steps in the Metastatic Process

- Tumor invasion of the vasculature or lymph vessels
- Tumor cell survival in the circulation
- Cellular extravasation
- Establish a metastasis at a distant site
- Acquiring an intrinsic vasculature

The dissemination of cancer is a complex, multifactorial process whereby tumor cells must be able to invade the vasculature or lymph vessels, survive in the circulation, and then extravasate and establish a metastasis at a distant site (Box 3A.2). The cells must then be able to adapt to a very different environment from that of the primary tumor. Acquiring an intrinsic vasculature is probably important for primary tumors to be able to disseminate and for metastases to grow beyond a certain size. Indirect evidence for this has been obtained in uveal melanoma (and many other tumors), as tumor vessel counts have been associated with a poor prognosis.<sup>5</sup> In addition, it is not uncommon for the cancer cell phenotype to change significantly from the primary tumor to the metastases. In uveal melanoma there is loss of pigmentation and an increase in less differentiated epithelioid cell types in the metastases compared to the primary tumor.<sup>6</sup>

## TISSUE SAMPLING AND PROCESSING

**Cytological sampling** includes a number of individual cells disrupted from their original tissue. Diagnosis is therefore usually made on the morphological appearance of individual cells because the relationship to surrounding cells is lost. Cytological samples may be used for immunocytochemistry, allowing the detection of individual proteins and for auxiliary techniques such as flow cytometry (see below). Two basic techniques are used for sampling, exfoliative cytology and aspiration cytology.

1. **Exfoliative cytology** involves the sampling of cells that are spontaneously exfoliated and dispersed in fluids (e.g. cerebrospinal fluid sampled by lumbar puncture) or forcibly removed by a spatula, brush, or some other instrument or filter paper. Cells may also be dislodged from a surface by a touch preparation (imprint cytology for conjunctival tumors). The exfoliative sample is then spread on a glass slide and stained. Vitrectomy samples may be filtered through a membrane (e.g. millipore filter) or centrifuged in a pellet (cyto-spin preparation) and paraffin embedded as a cell block.
2. **Aspiration cytology** may be applied to palpable lesions or guided by ultrasound or computed tomography (CT). Intraocular fine-needle aspiration biopsy (FNAB) is performed with needles between 21 and 25 gauges.<sup>7</sup> A pars plana approach guided by indirect ophthalmoscopy may be used, but clear cornea and trans-scleral routes have also been advocated.<sup>7-9</sup> The various techniques of intraocular biopsy are discussed in detail elsewhere (see Chapter 4). The risk of local tumor spread by the use of FNAB in loosely cohesive tumors is a concern. For this reason, FNAB should only be used with extreme caution and almost never in suspected cases of retinoblastoma. The requirements for tissue handling vary between laboratories, therefore it is prudent to contact the local cytopathologist before sampling.



**Histopathologic sampling and processing** Typically tissue is obtained by incisional or excisional biopsy of the lesion. Caution not to coagulate or otherwise maltreat the tissue sample is advised. Incisional biopsies or coarse needle biopsies should be avoided in tumors prone to local recurrence, such as the pleomorphic adenoma of the lacrimal gland. For such tumors, primary complete excision (or possibly diagnostic FNAB followed by complete excision) is recommended. The optimal fixative for the surgical biopsy varies depending on the local setting and the technique used for histopathologic examination, but in most cases formaldehyde is sufficient.

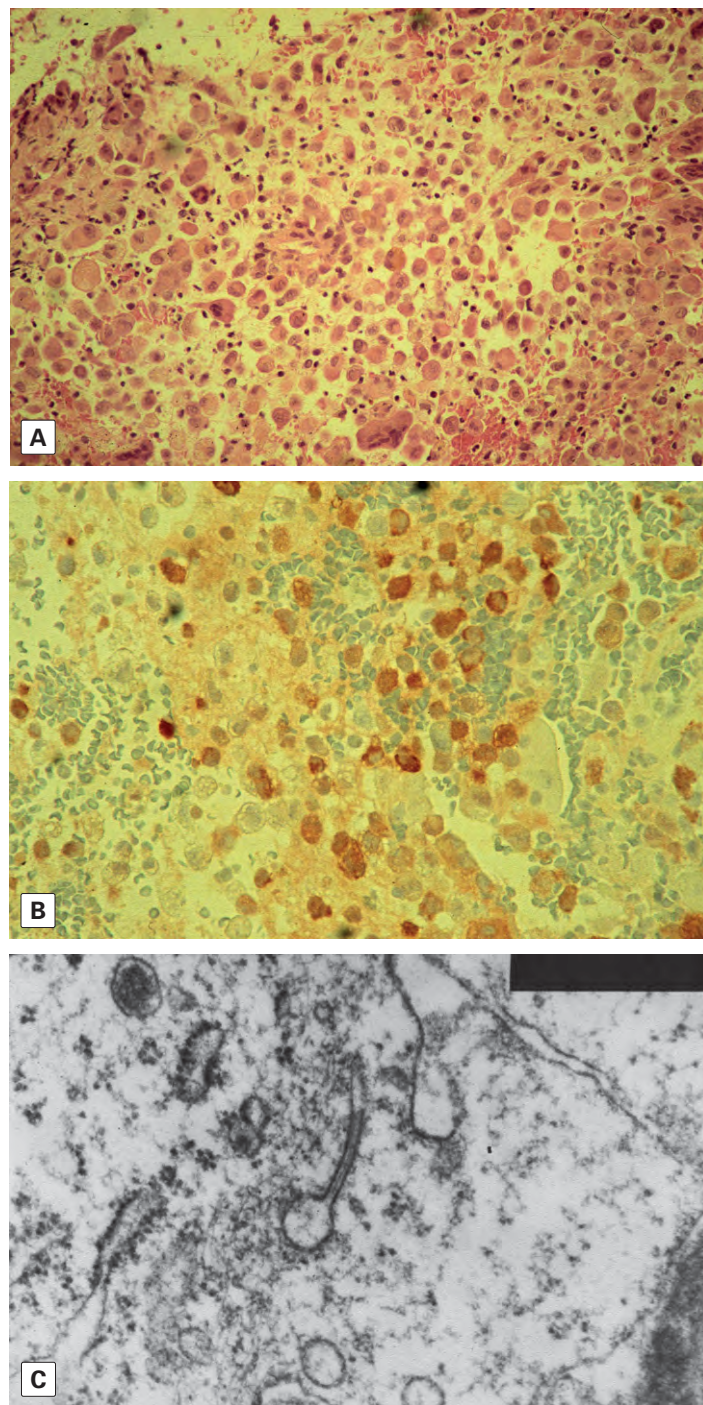
When biopsying tissues such as the conjunctiva or iris, care should be taken to orientate the specimen and to make sure the tissue is maintained flat and does not curl. This can be achieved by attaching the tissue to a piece of filter paper and annotating the specimen mount before immersing it in the fixative. Assessment of the surgical margins is paramount in any excisional tumor biopsy. To facilitate this, the surgical margins may be inked by the pathologist before gross sectioning and paraffin embedding. Also, special techniques, such as Mohs' technique using cryosectioning, or modifications using vertical paraffin-embedded sections, have been advocated for eyelid and skin tumors.<sup>10,11</sup> Cryosectioning allows for a rapid assessment (within 30 minutes) of margins or malignancy and can be used as a preoperative procedure; however, paraffin sections allow for a more reliable assessment of malignancy. Specific guidelines for histopathology reports on cancer specimens from the eye and adnexa have been issued elsewhere.<sup>12</sup>

## DIAGNOSTIC TECHNIQUES

**Light microscopy** When processed for routine light microscopy, samples are usually fixed in formaldehyde and then embedded in paraffin. This allows for the cutting of 3–4  $\mu\text{m}$  thin sections. Embedding in epoxy resin (Epon) allows for even thinner (1  $\mu\text{m}$ ) sections, which may be stained with toluidine blue. This technique is more laborious than paraffin embedding and is often used only when optimal cellular detail is required, or for orientation before examination using transmission electron microscopy. Paraffin sections are usually routinely stained with hematoxylin and eosin, although this may differ depending on the local setting (Fig. 3A.3A). Other stains, such as periodic acid–Schiff, preferentially stain mucopolysaccharides and glycogen and are appropriate for the study of basement membrane material such as the lens capsule.

**Immunohistochemistry** This technique has rapidly evolved from a research tool to a diagnostic one and has revolutionized diagnostic pathology. Many commercially available antibodies may be used in combination with routine fixatives such as formaldehyde, and staining may be enhanced by antigen retrieval techniques (Fig. 3A.3B). Fixation over prolonged periods may cause reduced staining, and the wary pathologist uses both negative and positive controls.

**Electron microscopy** provides excellent spatial resolution and allows for the visualization of individual cell organelles. The technique requires optimal sampling and special fixatives such as osmium tetroxide, although routinely processed tissue can be deparaffinized and used for electron microscopy (EM). Although transmission EM (TEM) provides high-resolution tissue cross-sectioning, scanning EM (SEM) is used for tissue surface imaging. Cell organelles and cell membranes viewed by TEM allow for some assumptions to be made as to the his-



**Fig. 3A.3** Langerhans' cell histiocytosis. Light microscopy (A), immunohistochemical stain recognizing S-100 protein (B), and electron microscopy detecting intracytoplasmic Birbeck granules (C).

togenesis of tumors (Fig. 3A.3C). However, EM technique is time-consuming and the ultrastructural features are not always helpful for diagnosis. For these reasons, TEM as a diagnostic tool in surgical pathology has now been largely replaced by immunohistochemistry.

**Additional techniques** Recent advances in molecular pathology have generated numerous techniques for the study of DNA, RNA, and proteins. Some of these have become a routine part of the diagnostic arsenal (flow cytometry in lymphoma, and tissue imprints for gene rearrangement studies in rhabdomyosarcoma). In many cases tissue



needs to be submitted fresh, and close collaboration with the examining laboratory is required for optimal results.

## RESEARCH TECHNIQUES

In situ hybridization is used to detect messenger RNA transcripts, but non-specific background staining or hybridization to homologous transcripts limits its use in diagnostic pathology. The polymerase chain reaction (PCR) in particular, when used as a competitive or 'real-time'

technique, allows for sensitive assays of gene expression at the RNA level. Gene profiling using the microarray technique is still a research tool, but is expected to become more readily available. Proteomics holds a similar promise and generates vast amount of data on protein expression. Laser capture techniques may be used to provide a minimal sample for further study from a tissue block. Many of the above techniques are used to generate data on the molecular mechanisms and prognostic parameters in ocular cancer.<sup>13–15</sup>

## REFERENCES

1. Seregard S, Oskarsson M, Spangberg B. PC-10 as a predictor of prognosis after antigen retrieval in posterior uveal melanoma. *Invest Ophthalmol Vis Sci* 1996; 37: 1451–1458.
2. Seregard S, Spangberg B, Juul C, Oskarsson M. Prognostic accuracy of the mean of the largest nucleoli, vascular patterns, and PC-10 in posterior uveal melanoma. *Ophthalmology* 1998; 105: 485–491.
3. Seregard S, Kock E. Prognostic indicators following enucleation for posterior uveal melanoma. A multivariate analysis on long-term survival with minimized loss to follow-up. *Acta Ophthalmol Scand* 1995; 73: 340–344.
4. Makitie T, Summanen P, Tarkkanen A, Kivela T. Tumor-infiltrating macrophages (CD68(+) cells) and prognosis in malignant uveal melanoma. *Invest Ophthalmol Vis Sci* 2001; 42: 1414–1421.
5. Foss AJ, Alexander RA, Jefferies LW et al. Microvessel count predicts survival in uveal melanoma. *Cancer Res* 1996; 56: 2900–2903.
6. Toivonen P, Makitie T, Kujala E, Kivela T. Microcirculation and tumor-infiltrating macrophages in choroidal and ciliary body melanoma and corresponding metastases. *Invest Ophthalmol Vis Sci* 2004; 45: 1–6.
7. Char DH, Kemnitz AE, Miller T. Intraocular biopsy. *Ophthalmol Clin North Am* 2005; 18: 177–185.
8. Shields JA, Shields CL, Ehya H, Eagle RC Jr, De Potter P. Fine-needle aspiration biopsy of suspected intraocular tumors. The 1992 Urwick Lecture. *Ophthalmology*. 1993; 100: 1677–1684.
9. Bechrakis NE, Foerster MH, Bornfeld N. Biopsy in indeterminate intraocular tumors. *Ophthalmology* 2002; 109: 235–242.
10. Spencer JM, Nossa R, Tse DT, Sequeira M. Sebaceous carcinoma of the eyelid treated with Mohs micrographic surgery. *J Am Acad Dermatol* 2001; 44: 1004–1009.
11. Malhotra R, Chen C, Huilgol SC, Hill DC, Selva D. Mapped serial excision for periocular lentigo maligna and lentigo maligna melanoma. *Ophthalmology* 2003; 110: 2011–2018.
12. Folberg R, Salomao D, Grossniklaus HE et al. and the Association of Directors of Anatomic and Surgical Pathology. Recommendations for the reporting of tissues removed as part of the surgical treatment of common malignancies of the eye and its adnexa. *Am J Surg Pathol* 2003; 27: 999–1004.
13. Zuidervaart W, van der Velden PA, Hurks MH et al. Gene expression profiling identifies tumour markers potentially playing a role in uveal melanoma development. *Br J Cancer* 2003; 89: 1914–1919.
14. Onken MD, Worley LA, Ehlers JP, Harbour JW. Gene expression profiling in uveal melanoma reveals two molecular classes and predicts metastatic death. *Cancer Res* 2004; 64: 7205–7209.
15. Missotten GS, Beijnen JH, Keunen JE, Bonfrer JM. Proteomics in uveal melanoma. *Melanoma Res* 2003; 13: 627–629.

## PART B: CANCER ANGIOGENESIS

Werner Wackernagel, Lynn Schoenfield and Arun D. Singh

### INTRODUCTION

Angiogenesis, the growth of new blood vessels from other pre-existing vasculature, is both a physiologic and a pathologic process. The formation of new vessels is important during embryogenesis, wound healing, and in female reproductive organs associated with the menstrual cycle. Interest in the role of angiogenesis in the development and treatment of cancer began in the early 1970s, when it was postulated that the formation of new and large vessels in tumors is essential for tumor growth and metastasis.<sup>1</sup> Since then our growing understanding of the regulation of angiogenesis has revealed an important role in other diseases, such as proliferative diabetic retinopathy and age-related macular degeneration, rheumatoid arthritis and psoriasis.<sup>2</sup>

In this chapter we provide a brief review of mechanism of tumor angiogenesis, current applications in general oncology, and experimental drugs with the potential for clinical applications. The final section deals with angiogenic aspects of a few specific ophthalmic tumors.

### TUMOR ANGIOGENESIS

Small tumors can obtain their nutrients and oxygen by diffusion alone. However, with increasing distance from a capillary vessel, oxygen supply is insufficient for the proliferation of tumor cells (Fig. 3B.1).<sup>3</sup> Tumorigenesis is a multistep process, caused by mutations in the course of time.<sup>4</sup> Only those cells that know how to build their own vessels can grow to a tumor of visible size if experimentally implanted into another location. The others remain microscopic, with no sign of growth, a phenomenon called 'no take.'

**Cooption** At an early stage, some tumors and metastases can invade healthy vascularized tissue, forming microcylinders up to a diameter of 200  $\mu\text{m}$  diameter around pre-existing capillaries, a mechanism that is called cooption.<sup>5</sup>

**Angiogenic switch** Ultimately, all tumors rely on the formation of new blood vessels to grow to a clinically detectable size. Tumor cells implanted in a rabbit cornea show a low growth rate as long as the cornea remains avascular. With the onset of revascularization the tumor cells switch to a higher proliferation rate, and the tumor grows rapidly.<sup>6</sup> The same is observed for tumors in the anterior chamber of a rabbit eye. Although revascularization of the iris soon develops, the tumors do not grow to a large size until they are in touch with the iris and the new-formed vessels.<sup>7</sup> The ability of a tumor to induce growth of its own vessels is called angiogenic switch, and usually occurs after malignant transformation.<sup>8</sup> However, cervical dysplasia demonstrates an angiogenic phenotype even before definite signs of malignancy are present.<sup>9</sup>

### STEPS IN ANGIOGENESIS

Angiogenesis begins with vasodilation and an increase in vascular permeability because of the dissolution of adherens junctions, with consequent vascular leakage leading to extravasation of plasma.<sup>10</sup> Matrix metalloproteinases degrade the basement membrane and the surrounding extracellular matrix, amplifying the angiogenic stimulus by releasing basic fibroblast growth factor (bFGF) and vascular

endothelial growth factor (VEGF). Proliferating endothelial cells now migrate away from the vessel. The new sprout appears as a solid column and a lumen is formed, either by intracellular vacuolar fusion or by arrangement of cells around a central lumen.<sup>11</sup> The new capillary then builds anastomoses with other capillaries, and the new vessel is stabilized by a new basal membrane and pericytes.

### TUMOR VESSELS

The vascular density in a tumor can be many times that of normal tissue.<sup>12</sup> However, the vessels remain functionally insufficient. They are disorganized, tortuous, and show a chaotic blood flow.<sup>13</sup> Often they leak fluid or bleed. So, despite a high vascular density, the tumor remains hypoxic. In some tumors, including uveal melanoma, fluid-conducting structures similar to vessels can be found that do not have endothelial cell lining (vascular mimicry).<sup>14</sup>

### METASTATIC CASCADE

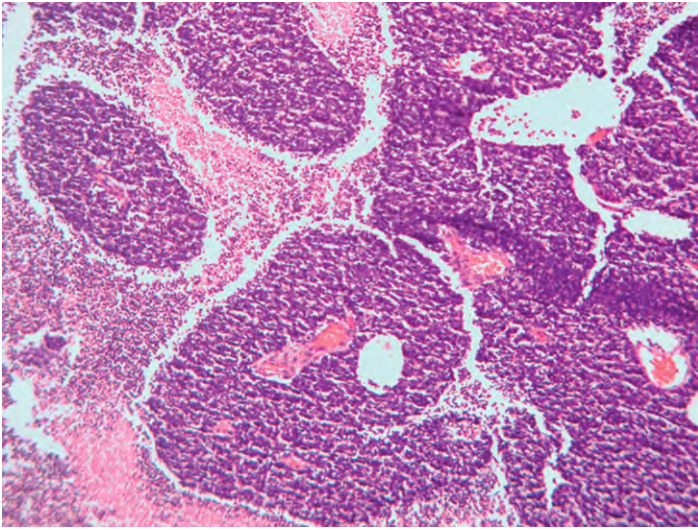
The different steps a tumor has to take to metastasize successfully are called the metastatic cascade (see Chapter 3A). A tumor must obtain access to the circulation to disperse malignant cells into it (Fig. 3B.2). The capillaries in the tumor often lack a proper basement membrane, making it easier for cells to invade the lumen; and the higher the density of vessels within a tumor, the more cells can escape to the circulation.<sup>15</sup> Once the metastatic cells reach their target organ, they can settle and then start to grow to form a secondary tumor. However, without inducing the growth of new vessels, these secondary tumors will grow slowly and might never reach a size that is clinically detectable. In fact, the proliferation rate does not differ significantly in such a dormant metastasis and in growing metastases. Rather, the total number of cells is balanced by a high rate of apoptosis.<sup>16</sup>

### PROMOTERS OF ANGIOGENESIS

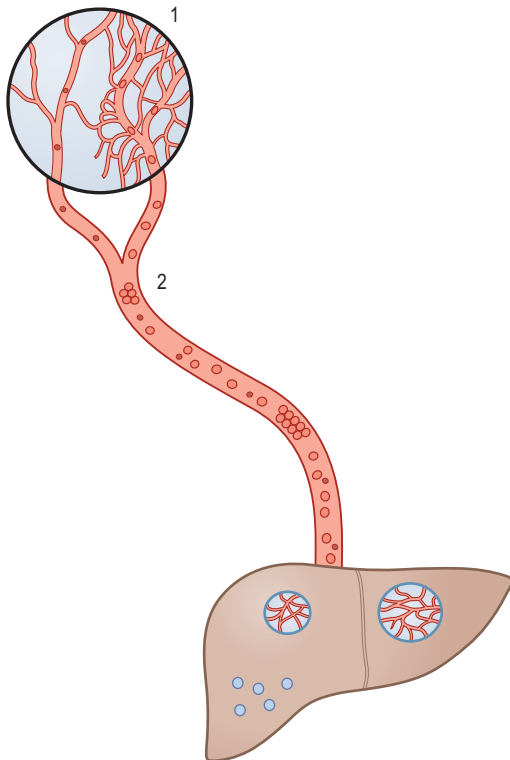
Angiogenesis can be induced by different factors and different conditions. Inflammation, hypoxia, and mechanical factors can induce the production or the release of proangiogenic factors and cytokines. It has also been shown that the products of many oncogenes are proangiogenic, and that this angiogenic activity might be one of their mechanisms of action.

**Vascular endothelial growth factor (VEGF)** was discovered in 1989 for its ability to increase vascular permeability and called vascular permeability factor.<sup>17</sup> Since then we have learned that it is a central player in physiologic and pathologic angiogenesis. Lack of a single VEGF gene leads to abnormal blood vessel formation, resulting in early embryonic death.<sup>18</sup>

**Functions** *In vitro* and *in vivo* experiments have demonstrated that it is a strong mitogen and survival factor for endothelial cells, promoting endothelial cell motility and the growth of new blood and lymphatic vessels.<sup>19</sup> The VEGF-induced vasculature consists of primitive vascular plexuses, highly fragile and hemorrhagic.<sup>20</sup> *In vivo* it is expressed physiologically in areas of wound healing, bone growth, and the female reproductive organs.<sup>21</sup> VEGF plays a role in the patho-



**Fig. 3B.1** With increasing distance from a capillary vessel, oxygen supply is insufficient for the proliferation of tumor cells. Note viable cells surrounding the central vessel. Areas of tumor necrosis are evident away from the vascular channels (untreated retinoblastoma). (Hematoxylin and eosin; original magnification  $\times 10$ ).



**Fig. 3B.2** Metastatic cascade. The metastatic cascade begins when tumor cells escape from the primary solid tumor and enter the general circulation. It seems that this shedding of tumor cells starts at an early stage, and uveal melanoma cells have been detected in the peripheral blood long before metastasis could be seen clinically. (1) Different parts of the tumor can show different vascular densities, a fact that might contribute to the number of the cells that can give rise to metastasis. However, only very few of those tumor cells can survive in the general circulation. (2) Formation of larger cell aggregates, which also include platelets, contributes to an increased survival of tumor cells. At their target site they embolize a capillary or adhere to the vessel wall, pass it, and settle in the new organ. The mechanism behind the organotropism of metastasis is not fully understood. Besides hemodynamics specific properties of the vessels, properties of the endothelium as well as characteristics of the target organ, such as the expression of certain growth and chemotactic factors, might be important.

genesis of retinopathy of prematurity (ROP), choroidal neovascularization in age-related macular degeneration, and neovascularization of the iris.<sup>22–24</sup> It is hoped that modulation of VEGF function would be therapeutic in these diseases.

**Subtypes (VEGF A)** The VEGF family of growth factors consists of a least six members that bind to different VEGF receptors (VEGFR) on the cell surface. In general terms, when VEGF is mentioned it is VEGF-A that is being referred to. VEGF-A is a secreted, freely diffusible glycoprotein with a half-life in the circulation of only 3 minutes. It forms homodimers and binds to VEGFR-1 and VEGFR-2 on the surface of endothelial cells. The gene for VEGF is located on the short arm of chromosome 6 (6p21), and alternative splicing results in the different isoforms of protein, which are named after the number of their amino acids.<sup>25,26</sup> VEGF 121, 145, 165, 189, and 206 differ in their affinities to the VEGF receptors and to structures of the extracellular matrix.

**VEGF receptors** The function of VEGF is mediated by different cell surface receptors, the VEGF receptors (VEGFR-1, VEGFR-2, and VEGFR-3) and neuropilin-1 (NP-1). The VEGFRs are a family of transmembrane receptor tyrosine kinases. They transfer a phosphate group from adenosine triphosphate (ATP) to a target protein. They all have an extracellular immunoglobulin-like domain, a lipophilic transmembrane region, and an intracellular domain that includes a tyrosine kinase (TK).<sup>27</sup>

### Regulation of VEGF

**HYPOXIA** An important factor for the upregulation of VEGF under physiologic as well as pathologic conditions is hypoxia. When tumors grow to a large size they usually show areas of necrosis, surrounded by underperfused regions. Hypoxia in those regions with low oxygen tension induces the expression of two hypoxia-inducible factors, HIF-1 and HIF-2.<sup>28</sup>

In hypoxic conditions HIF becomes active. Its  $\alpha$  subunit translocates to the nucleus, and binds to the  $\beta$  subunit and to hypoxia response elements. This induces the expression of VEGF and more than 60 other genes.<sup>29</sup> However, under normoxic conditions this rarely happens, because HIF undergoes rapid degradation. The von Hippel–Lindau (vHL) protein plays a key role in the degradation process by forming a complex with ElonginB–ElonginC–cullin-2.<sup>30</sup> If the vHL protein is missing, mutated, or not functional, HIF is not properly inactivated and normoxic tissue behaves as if under hypoxic conditions.

**OTHER FACTORS** Apart from hypoxia, several other growth factors can upregulate VEGF expression both in vitro and in vivo. Epidermal growth factor (EGF), transforming growth factor- $\beta$  (TGF- $\beta$ ), keratinocytic growth factor (KGF), and insulin-like growth factor (IGF) can all induce VEGF in vitro or in vivo, as can prostaglandin (PGE<sub>2</sub>), interleukin (IL)-1 $\alpha$ , thyroid-stimulating hormone (TSH), and angiotensin II.

**Fibroblast growth factor (FGF)** is a family of at least 22 members, but only few of them have been shown to be related to angiogenesis. FGF was the first angiogenic protein to be purified. It has a strong affinity for heparin and heparin sulfate, and is stored in the extracellular matrix. Proteases can release FGF, which then can bind to their tyrosine kinase FGF receptors on the cell surface and lead to activation of the MAPK pathway by protein kinase C (PKC)-dependent signaling.

The basic fibroblast growth factor (bFGF or FGF-2) and the acid fibroblast growth factor (aFGF or FGF-1) are best described by their

effects on angiogenesis, which are multiple and include almost all steps of angiogenesis.<sup>31</sup> FGF is elevated in the serum of cancer patients and also seems to play a role in Kaposi's sarcoma and hemangioma.<sup>32</sup>

**Angiopoietins** The four members of the angiopoietin family, ang-1, ang-2, ang-3, and ang-4, all bind to another group of receptor tyrosine kinases (RTK), the Tie-1 and Tie-2 receptors. All the four angiopoietins bind to the Tie-2 receptor. They do not induce proliferation, but influence cell migration, sprouting, tube formation, and survival. Additionally, ang-1 reduces vascular leakage induced by VEGF.<sup>33</sup> No ligand for the Tie-1 receptor has yet been found. However, Tie-1 deficiency results in severe vascular defects and increased vascular density. It seems that Tie-1 is important for stopping endothelial growth.

## INHIBITORS OF ANGIOGENESIS

Angiogenesis inhibitors can be classified in two ways, first according to their mechanism of action. Indirect inhibitors block endothelial cell stimulation by preventing the tumor to produce angiogenic stimuli, neutralizing or blocking the receptors for those stimulating factors. Direct inhibitors block endothelial cells directly, inhibiting their response to any proangiogenic stimulus. As direct inhibition targets the genetically stable endothelial cell instead of the tumor cells, it is less prone to drug resistance and treatment failure. Second, we can classify inhibiting factors into endogenous and pharmaceutical inhibitors.

### Endogenous

**Thrombospondin** was the first naturally occurring inhibitor to be discovered. It has an indirect effect by inhibiting matrix metalloproteinase MMP-9, but also a direct effect on endothelial cells. During tumorigenesis it becomes downregulated by several oncogenes (*ras*, *c-myc*, *v-src*, *c-jun*) whereas tumor suppressor genes (*p53*, *PTEN*) induce thrombospondin.

**Angiostatin** is a fragment of plasminogen that is generated from plasminogen by, among others, urokinase plasminogen activator (uPA) and matrix metalloproteinases (MMP). It can be found in urine and serum only in the presence of a tumor, and its half-life in the circulation is approximately 2.5 days, much longer than for VEGF. The effects of angiostatin are very selective for endothelial cells, including the induction of cell arrest and apoptosis. It can also reduce the number of circulating precursor endothelial cells from bone marrow, which also contributes to angiogenesis. This makes angiostatin an interesting candidate for anti-angiogenic therapy. It has been successfully used in animal models,<sup>34</sup> and has been transfected to uveal melanoma in dogs.<sup>35</sup> As angiostatin levels decrease in the serum after radiation therapy of the primary tumor, substitution therapy with angiostatin could be used to prevent accelerated growth of metastatic tumors.<sup>36</sup>

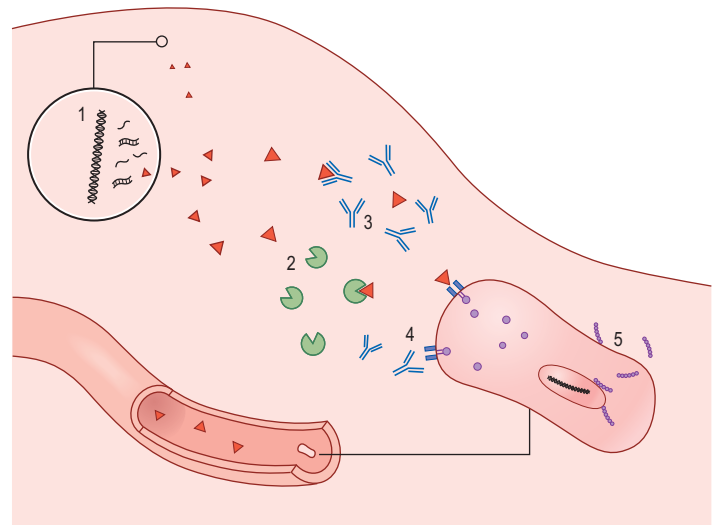
**Endostatin** Like angiostatin, endostatin is a fragment of a larger molecule. Proteolytic enzymes, elastase, cathepsin L and matrix metalloproteinases cleave the internal fragment of collagen XVIII, generating endostatin. The gene for collagen XVIII is located on chromosome 21, and patients with Down's syndrome show higher levels of endostatin with a lower overall incidence of solid tumors. Like angiostatin, effects of endostatin are very specific for endothelial cells, inhibiting many steps in angiogenesis. It inhibits VEGF and metalloproteinases, and

downregulates *c-myc*, inhibits cyclin D-1, and promotes endothelial cell apoptosis. Another effect is the decrease of vascular permeability, and reduction of edema could enhance the effect of chemotherapy (see below). In animal models it shows regression of tumors to microscopic levels, and so far no toxicity or drug resistance has been observed. Endostatin also plays a critical role in the development of the retinal vessels. In Knobloch syndrome, a deficiency of endostatin, the hyaloid artery of the vitreous fails to regress,<sup>37</sup> and endostatin levels are elevated in eyes with proliferative diabetic retinopathy.<sup>38</sup> Phase I clinical trials testing endostatin in advanced solid tumors demonstrated low toxicity, and showed reduced blood flow and increased apoptosis of tumor and endothelial cells.<sup>39,40</sup>

### Pharmaceutical

**Anti-VEGF agents** VEGF is one of the most important factors in angiogenesis and great efforts have been made to block its effects to inhibit angiogenesis. There are both direct and indirect ways to inhibit VEGF, which include blocking VEGF at the mRNA level with small interfering RNA (siRNA),<sup>41</sup> targeting the soluble VEGF ligand with antibodies or antibody fragments, blocking the extracellular domain of the VEGF receptors (VEGFR-2), and inhibition of the intracellular signaling pathway by blocking the receptor tyrosine kinase domain (Fig. 3B.3).<sup>42</sup>

BEVACIZUMAB is a monoclonal anti-VEGF antibody that binds the free, soluble ligand. By doing so, bevacizumab inactivates VEGF and has been shown to reduce VEGF level. Bevacizumab is currently being used in combination with chemotherapy and has been shown to improve outcome in previously untreated patients.



**Fig. 3B.3** Direct and indirect ways of inhibiting angiogenesis. Anti-angiogenic therapy can interfere with pro-angiogenic stimuli on different levels. (1) Antisense oligonucleotides bind to mRNA of pro-angiogenic factors, thus inhibiting translation by the ribosome and inducing degradation. (2) Small molecules, oligonucleotides, and (3) antibodies against diffusible circulating angiogenic factors bind and inactivate those factors before they reach the endothelial cell. (4) Antibodies can also bind to the cell surface/transmembrane receptor and prevent stimulation by angiogenic factors. (5) Direct inhibitors bind to the cell surface or become internalized, exerting an inhibiting function on their target cells.



RANIBIZUMAB is an antibody fragment binding with high affinity to VEGF and intended for treatment of age-related macular degeneration (AMD). In a monkey model it can penetrate through the internal limiting membrane in the subretinal space.<sup>43</sup>

PEGABTANIB is an aptamer, a small 28-base oligonucleotide that binds to VEGF with very high affinity, and specifically blocks the 165-amino acid isoform of VEGF from binding to its receptor. Like ranibizumab, it is approved for the treatment of AMD.

SU5416, (SEMAXANIB), is a small molecule inhibitor of receptor tyrosine kinases (RTK). As its effect targets more than one receptor it is called a multitarget tyrosine kinase inhibitor (TKI). It inhibits the intracellular domain of the VEGF receptor 2 (KDR), but also Kit and Flt-3, two other RTKs that are important in hematopoiesis.<sup>44</sup> SU5416 has no direct cytotoxicity, but shows inhibition of tumor growth in animal models for many types of tumors. It has been used with promising results in the treatment of central nervous and retinal hemangioma in von Hippel–Lindau disease and also for suppression of choroidal neovascularization.<sup>42</sup>

CELECOXIB is a cyclo-oxygenase (COX)-2 inhibitor showing anti-angiogenic effects, probably due to a downregulation of endostatin. In a murine model of retinoblastoma, and in retinoblastoma cell lines, it has failed to inhibit cell proliferation.<sup>45</sup>

TRASTUZUMAB (HERCEPTIN) is a recombinant monoclonal antibody against an epidermal growth factor receptor (EGFR)-related tyrosine kinase. The corresponding gene *HER-2* (*ERBB2/NEU*) is overexpressed in 20–25% of breast cancers (primary tumor and metastasis). Although many tumors show progression after 1 year of treatment, Herceptin could be an alternative to radiation treatment for choroidal metastases (see Chapter 54).

INTERFERON- $\alpha_{2a}$  (IFN)- $\alpha_{2a}$  was the first angiogenesis inhibitor to be tested in clinical trials. As it works in part by downregulation of bFGF, it shows the best results for tumors that express bFGF. It is used for life- or vision-threatening hemangioma, but because of its neurologic toxicity it must be used carefully, and improvements often cannot be seen until after 6 weeks of treatment.<sup>46</sup> Angioblastomas and giant cell tumor of the mandible have also been shown to improve after prolonged treatment for up to 1 year.<sup>47</sup> A randomized trial for AMD, however, did not show any improvement, so that interferon can not be recommended for this indication.<sup>48</sup>

### ANTIANGIOGENIC THERAPY IN CLINICAL PRACTICE

A detailed review of the clinical applications of several commercially available anti-angiogenic agents is beyond the scope of this chapter. Moreover, excellent reviews on this topic have been published.<sup>49</sup> Nevertheless, it is important to point out that, despite the effects of anti-VEGF therapy on tumor vessels,<sup>50</sup> anti-VEGF monotherapy (i.e. without chemotherapy or radiation therapy) has failed to produce improvements in overall patient survival.<sup>49</sup> However, the beneficial effects of prolonging overall survival are apparent when bevacizumab (Avastin) is added to standard chemotherapy for patients with colorectal and lung cancer, and progression-free survival in breast cancer patients.<sup>49</sup> There is also evidence to support a survival benefit of multitargeted tyrosine kinase inhibitors in patients with renal cell carcinoma.<sup>51</sup>

The relationship between anti-VEGF therapy and the usual methods of treatment, such as radiation therapy and chemotherapy, are complex and perhaps best explained by the concept of ‘vascular normalization.’<sup>52</sup> It is suggested that anti-VEGF therapy not only reduces vascular density but induces structural and functional changes in the tumor vasculature that improve cellular oxygenation and perfusion (‘normalization’).<sup>52</sup> Improved oxygenation consequently increases the efficacy of radiation therapy and improves the delivery of chemotherapy. Theoretical considerations of combining novel anti-VEGF therapies with standard forms of therapy are discussed in detail elsewhere.<sup>49</sup>

### ANGIOGENIC ASPECTS OF SPECIFIC OPHTHALMIC TUMORS

**Retinoblastoma** is the most common primary intraocular malignant tumor in children (see Chapter 67). The average annual incidence of retinoblastoma in the United States is 10.9 per million for children younger than 5 years.<sup>53</sup> Leukocoria, or white pupil, and strabismus are the most common presenting signs.

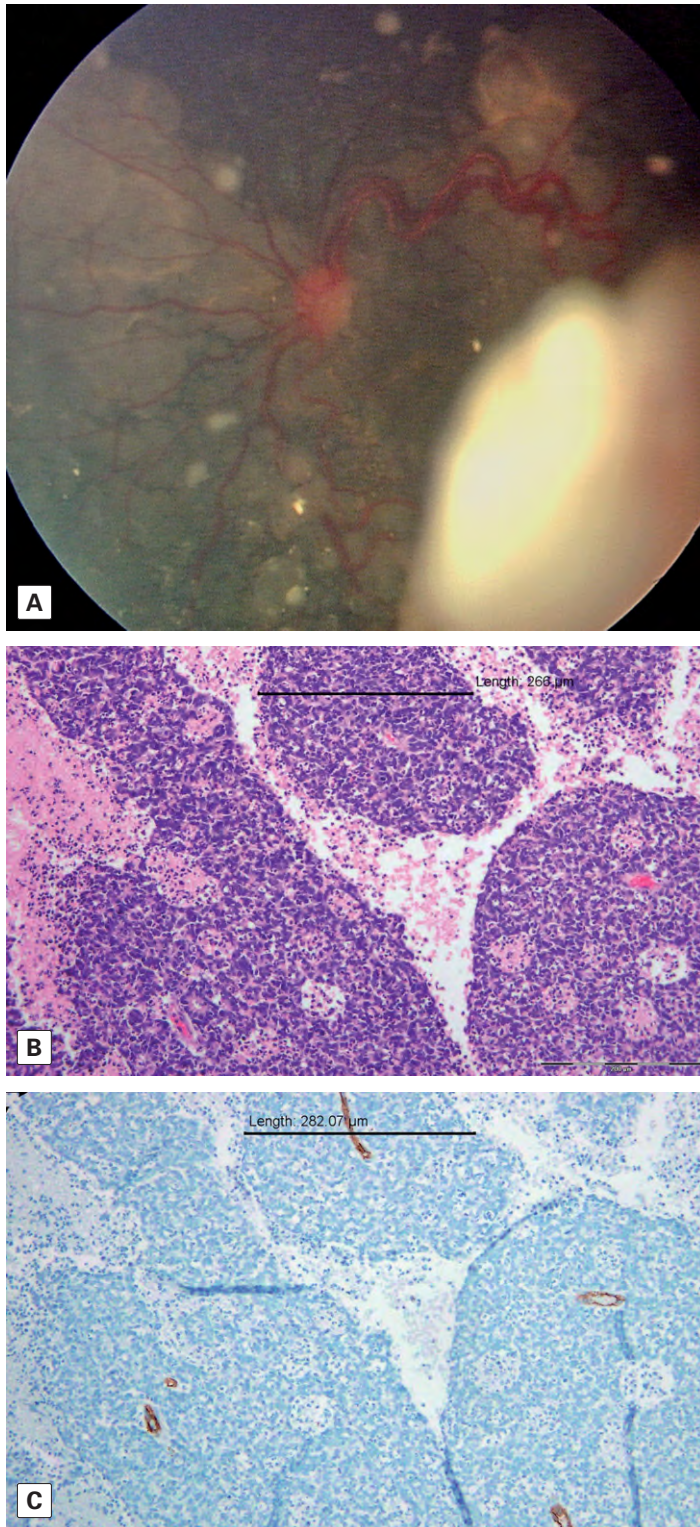
**Pathogenesis** Retinoblastoma is a familial disorder with an autosomal dominant inheritance and can be classified as familial or sporadic, bilateral or unilateral, and heritable or non-heritable (Chapter 70). The human retinoblastoma susceptibility gene (*RB1*), a tumor suppressor gene, is located on chromosome 13q region 13–14 (see Chapter 66).<sup>54</sup>

Histopathologic examination shows a highly vascular tumor in which the vessels are cuffed by a layer of viable cells having a mean thickness of 90–100  $\mu\text{m}$  and surrounded by necrotic debris (Fig. 3B.4).<sup>55</sup> The extent of angiogenesis in retinoblastomas may be a predictor of their metastatic potential.<sup>56</sup> In a pilot study of patients with unilateral retinoblastoma treated solely by enucleation, it was observed that a tumor with a relative vascular area  $\geq 3.9\%$  was a better predictor of disease dissemination than either choroidal or optic nerve invasion.<sup>56</sup> Retinoblastomas expresses high amounts of VEGF.<sup>57</sup> Moreover, retinoblastoma cell lines, which express low levels of VEGF under normal culture conditions, show a strong increase in VEGF secretion under hypoxia, suggesting that focal hypoxia may act as a stimulus for VEGF production in retinoblastoma, which in turn contributes to tumor growth by stimulating angiogenesis.<sup>57</sup>

**Treatment** In recent years there has been a trend away from enucleation with the increased use of alternative globe-conserving methods of treatment, including laser photocoagulation, cryotherapy, transpupillary thermotherapy, plaque radiotherapy, external beam radiotherapy, and chemotherapy (see Chapters 74 and 75).

As predicted from studies outlined above, subconjunctival injections of combretastatin A-4 phosphate (CA-4P), an angiostatic prodrug, induces a dose-dependent decrease in microvessel density and consequent tumor volume reduction in an animal model of hereditary retinoblastoma.<sup>58,59</sup> However, the clinical challenge in the management of advanced retinoblastoma is the presence of vitreous seeding, which is not vasculature dependent (Fig. 3B.4). Therefore, solely on theoretical grounds, it is unlikely that anti-angiogenic therapies will play a major role in the management of advanced intraocular disease associated with vitreous seeding.

**Uveal melanoma** is the most common primary intraocular malignant tumor.<sup>60</sup> Even so, melanomas of the ocular and adnexal structures comprise approximately 5% of all melanomas.<sup>61</sup> The major-



**Fig. 3B.4** Retinoblastoma. Prominent feeder vessel (A). Vitreous seeds are about 200 μm in diameter, which is the maximum attainable size in the absence of intrinsic circulation. Islands of viable tumor cells surrounding a central blood vessel (B). (Hematoxylin and eosin; original magnification  $\times 10$ ) and with endothelial stain (C). (CD 34 stain; original magnification  $\times 10$ .)

ity (85%) of ocular melanomas are uveal in origin, whereas primary eyelid, conjunctival, and orbital melanomas are very rare (see Chapter 35).<sup>60,61</sup> Based on anatomic location, uveal melanoma has three types: iris, ciliary body, and choroidal. The diagnosis of uveal melanoma is

essentially clinical, based on indirect ophthalmoscopy, angiographic studies, and ultrasonographic pattern (Chapters 32 and 36). Survival in patients with uveal melanoma is compromised by its tendency to undergo hepatic metastasis (Chapter 47).

### Pathogenesis

**PRIMARY UVEAL MELANOMA** is a malignant tumor arising from uveal melanocytes. Although uveal melanocytes and cutaneous melanocytes share a common embryologic origin and some morphologic properties, several significant differences exist between cutaneous and uveal melanomas in terms of prognostic factors, sites of distant metastasis, and the response of metastatic disease to chemotherapy.

**PSEUDOVASCULAR CHANNELS (VASCULOGENIC MIMICRY)** Among other factors, tumor size, cell type, pseudovascular channels, and the presence of cytogenetic changes are significant prognostic factors in uveal melanoma (Chapter 46).<sup>62,63</sup> The pseudovascular channels are identified as PAS-positive loops or networks in histological preparations (Fig. 3B.5) as well as in vitro studies.<sup>62</sup> It is now believed that pseudovascular channels are laminin-rich extravascular matrix patterns that conduct plasma.<sup>64</sup> As these channels lack endothelial cells, are independent of angiogenesis, and do not conduct blood cells, the term ‘vasculogenic mimicry’ is used to describe their origin. As a corollary, it can be predicted that anti-angiogenic therapy will not be effective in the treatment of primary uveal melanoma.

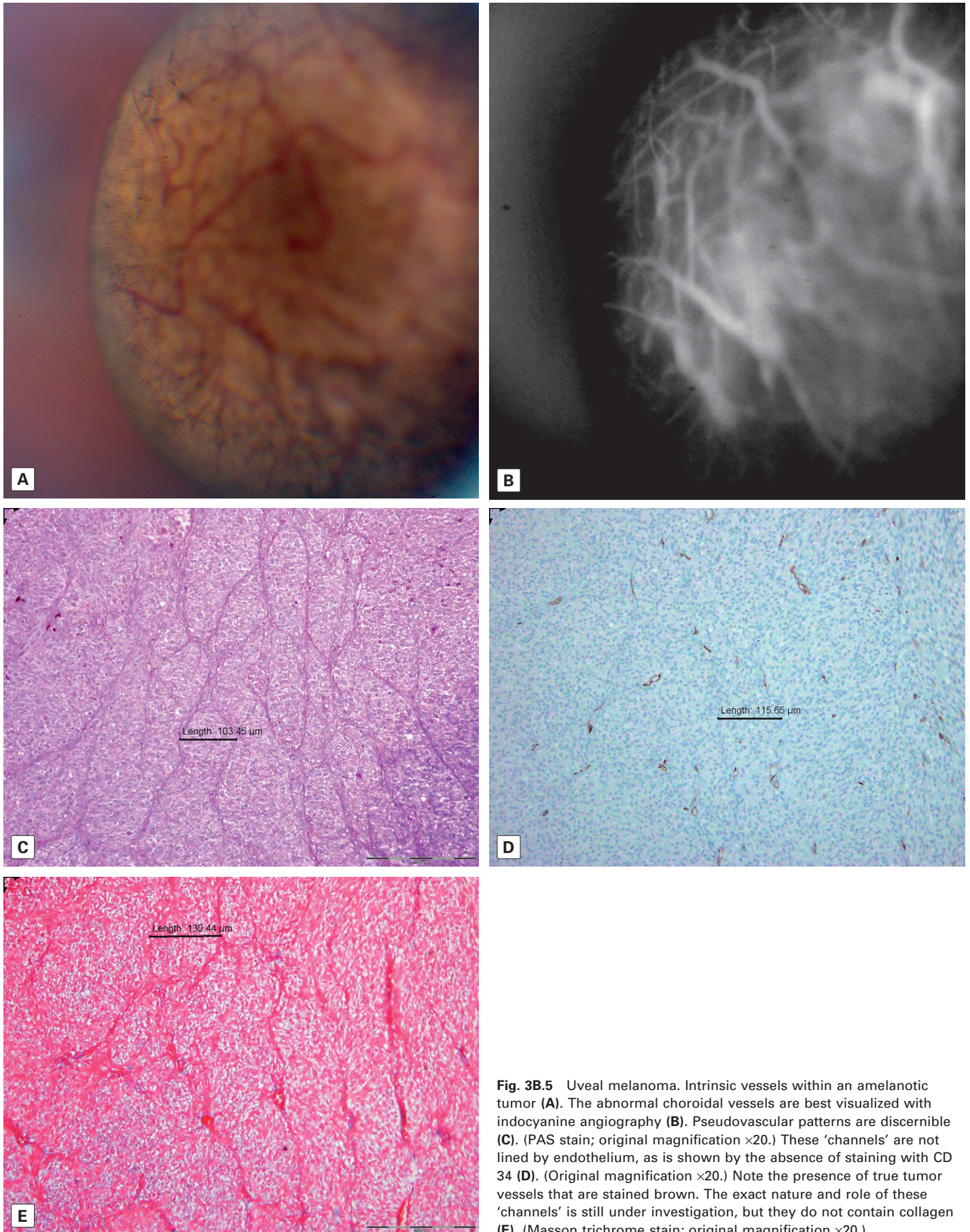
**MICROVESSEL DENSITY** There are contradictory reports about the presence<sup>65,66</sup> or absence<sup>67,68</sup> of a relationship between microvessel density and prognosis in uveal melanoma. Furthermore, the relationship between microvessel density and pseudovascular patterns is not clearly established.<sup>66,69</sup> Such conflicting results may be due to variations in the methodologies used by different investigators.<sup>70</sup>

**INDOCYANINE GREEN ANGIOGRAPHIC PATTERNS** Two independent investigators have shown a correlation between indocyanine green (ICG) angiographically visualized microcirculatory patterns and risk for growth (malignant transformation) of a small choroidal melanocytic lesion.<sup>71,72</sup> However, the investigators differ in their interpretation of the nature of vascular patterns observed with ICG. One group believes that these represent pseudovascular channels,<sup>71,73</sup> whereas the other believes that they represent microcirculatory patterns derived from true vessels.<sup>72</sup> The latter view is compatible with the concept of ‘angiogenic switch’ outlined above.

**VEGF EXPRESSION** studies have also indicated conflicting results because of technical variations between studies. One of the initial studies indicated a lack of overexpression of VEGF in uveal melanoma.<sup>57</sup> However, subsequent studies have indicated significant overexpression of not only VEGF<sup>74–76</sup> but also  $\beta$ FGF in uveal melanoma.<sup>75</sup> There seems to be no correlation between level of VEGF expression and tumor microvascular density,<sup>74</sup> 6p21 region copy number,<sup>76</sup> and metastasis.<sup>74</sup> Tumor necrosis<sup>74</sup> and previous radiotherapy<sup>77</sup> correlate with level of VEGF expression. Overall,  $\beta$ FGF expression is more frequently observed than VEGF expression in uveal melanoma.<sup>75</sup>

**METASTATIC UVEAL MELANOMA** Besides the growth of the primary tumor, angiogenesis also plays an important role in the growth of





**Fig. 3B.5** Uveal melanoma. Intrinsic vessels within an amelanotic tumor (A). The abnormal choroidal vessels are best visualized with indocyanine angiography (B). Pseudovascular patterns are discernible (C). (PAS stain; original magnification  $\times 20$ .) These 'channels' are not lined by endothelium, as is shown by the absence of staining with CD 34 (D). (Original magnification  $\times 20$ .) Note the presence of true tumor vessels that are stained brown. The exact nature and role of these 'channels' is still under investigation, but they do not contain collagen (E). (Masson trichrome stain; original magnification  $\times 20$ .)



metastases. Of the four clinical patterns of presentation of metastases (early, simultaneous, occult primary, long-term dormancy),<sup>2</sup> uveal melanomas seem typically to manifest a pattern of long-term dormancy (see Chapters 47 and 48).<sup>78</sup> Different explanations for the different patterns have been given, including accumulating genetic mutations over time, changes in immunologic surveillance, and hormonal stimuli. However, with growing insight into the mechanisms of angiogenesis, an explanation based on a balance of pro-angiogenic and anti-angiogenic factors becomes persuasive.<sup>16</sup> The lack of angiogenic switch can explain the long-term dormancy of micrometastases. Production of anti-angiogenic factors such as thrombospondin, angiostatin, or endostatin by the primary tumor keeps metastatic tumors at a small size.<sup>79,80</sup> Because these anti-angiogenic factors have a longer half-life than the pro-angiogenic stimuli their effect on metastases is stronger. With the removal of the primary tumor, the pro-angiogenic stimuli predominate, resulting in growth of metastases.<sup>81</sup>

Although such a pattern of post-enucleation rise in mortality with uveal melanoma was attributed to the shedding of cells (Zimmerman–Mclean–Foster hypothesis),<sup>82</sup> recent critical appraisal of the published evidence confirms such a trend in mortality but does not attribute it to mechanical cell shedding.<sup>83</sup> Rather, alternative explanations based on cell doubling models have been put forward.<sup>83–85</sup> Additional investigations are necessary to explain the clinically observed relationship between primary and metastatic uveal melanomas.

### Treatment

**PRIMARY UVEAL MELANOMA** The treatment of primary uveal melanoma is essentially surgery or radiation (see Chapter 39). In a murine model of uveal melanoma, topical application of 1% anecortave acetate (an angiostatic agent) significantly slowed tumor growth.<sup>86</sup> The other potential application of anti-angiogenic therapy is in the treatment of radiation retinopathy, which is essentially untreatable over the long term (see Chapter 9). A recent report suggests an encouraging response of radiation-induced rubeosis iridis to a intravitreal injection of bevacizumab (Avastin).<sup>87</sup>

**METASTATIC UVEAL MELANOMA** The COMS data indicate approximate melanoma-related mortality at 5 years of 1%, 10%, and 25% for small, medium, and large choroidal melanomas, respectively (see Chapter 45).<sup>88</sup> The chemotherapy regimens currently used in the treatment of metastatic cutaneous melanoma are ineffective against metastatic uveal melanoma (Chapter 48).<sup>89</sup> Initial promising reports of a combination of IFN- $\alpha_2$  with bleomycin, vincristine, lomustine, and dacarbazine were disproved in the larger number of patients<sup>91</sup> by a multicenter phase II trial conducted by the European Organization for Research and Treatment of Cancer.<sup>92</sup>

**Von Hippel–Lindau disease** Clinical, statistical, and genetic studies of Von Hippel–Lindau disease (VHL) have suggested that tumor formation follows the ‘two-hit model’ initially hypothesized by Knudson for retinoblastoma (see Chapters 64 and 65).<sup>93,94</sup> According to this model, in inheritable cases one allele is constitutionally inactivated (first hit) and the second is inactivated in specific tissues (second hit), whereas in acquired cases both alleles are inactivated in the specific tissues.

**Pathogenesis** The VHL gene is represented in three exons contained within a 20 kb region on chromosome 3p25–26.<sup>95</sup> Patients with VHL disease show an overexpression of hypoxia-inducible genes. The role of VEGF, as one of the upregulated genes, in retinal hemangioma, CNS

hemangioblastoma, renal cell carcinoma, and pheochromocytoma in VHL syndrome is well established (Fig. 3B.6).<sup>96</sup>

**Treatment** Retinal capillary hemangioma is usually treated with laser photocoagulation and cryotherapy (Chapter 57). In cases not amenable to the usual therapies, systemic use of SU5416 (Semaxanib) has been described.<sup>97</sup> In two reported cases there was stabilization of the lesion, reduction of retinal edema, and improved visual function.<sup>97,98</sup> The same drug has also been used for CNS hemangioblastomas in small series of patients.<sup>99</sup> The effects of bevacizumab for renal cell carcinoma in VHL disease is currently being tested in phase II clinical trials.<sup>100</sup>

**Hemangioma of the eyelid** are common and are present in 1% of neonates (see Chapters 20 and 90). The eyelid and orbit are frequent sites of involvement, and because of their location may cause amblyopia and astigmatism (Fig. 3B.7).

**Pathogenesis** These tumors grow rapidly in the first year of life, slowly over the next 5 years, and eventually regress by age 10–15 years. They are composed of endothelial cells, endothelial progenitor cells, and perivascular and hematopoietic cells that respond to various pro- and anti-angiogenic factors.<sup>101</sup>

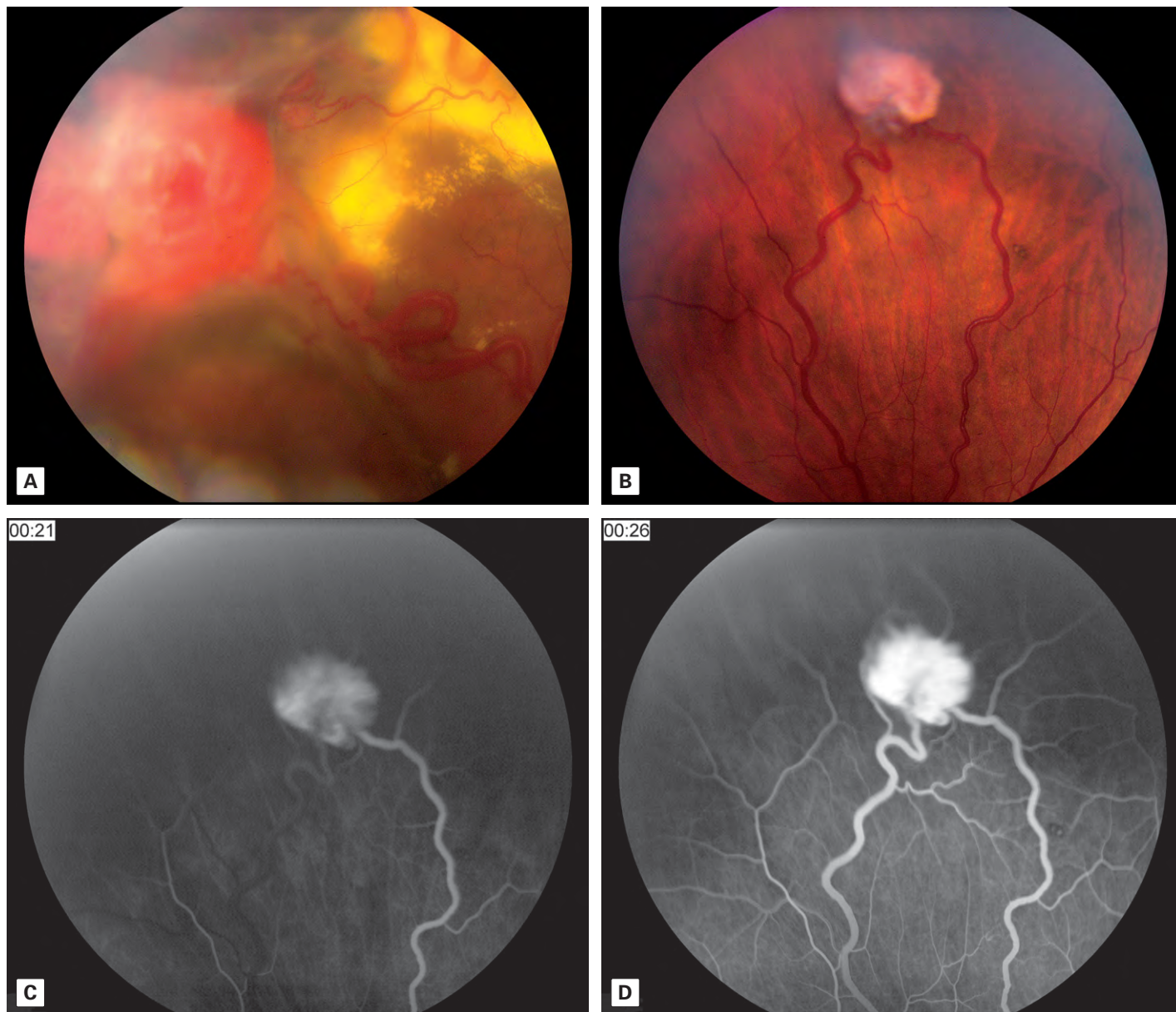
**Treatment** Steroids (oral or intralesional) are the most frequently prescribed method of treatment.<sup>102</sup> Life-threatening hemangiomas have responded well to therapy with IFN- $\alpha_{2a}$ .<sup>103,104</sup> In a series of 15 children with sight-threatening hemangioma unresponsive to steroids who were treated with anti-angiogenic IFN- $\alpha_{2b}$  (3 million units/m<sup>2</sup> subcutaneously daily for 3 months), there was a significant regression of the hemangioma in all patients who completed treatment.<sup>46</sup> Moreover, IFN- $\alpha_{2b}$  was well tolerated by all children. Similar observations for capillary hemangioma extending into the orbit and pharynx have also been reported.<sup>105</sup>

**Conjunctival squamous cell carcinoma (SCC)** is the most common malignancy of the conjunctiva in the United States (Fig. 3B.8).<sup>106</sup> Most squamous tumors originate from the interpalpebral limbus and involve both the conjunctiva and the cornea (see Chapter 25).

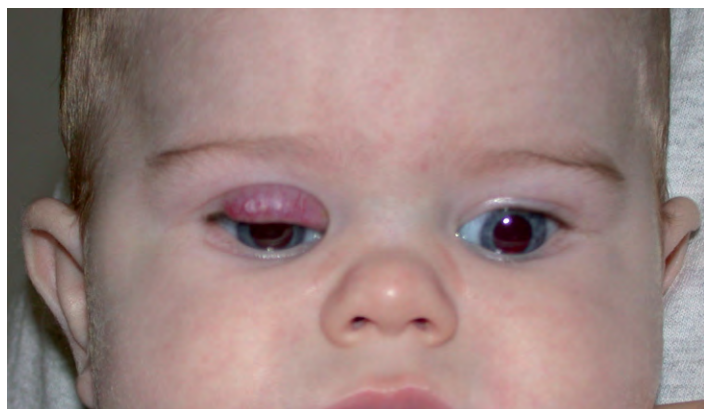**Pathogenesis** Ultraviolet-B light exposure has consistently emerged as a major etiologic factor.<sup>107</sup> Human papillomavirus (subtypes 16 and 18) has been associated with SCC but is probably not an independent cause of conjunctival neoplasia (see Chapter 2).<sup>108</sup> Systemic immunosuppression, as seen in acquired immune deficiency syndrome (AIDS) is also a risk factor.<sup>109</sup>

**Treatment** is influenced primarily by the extent of the lesion. Surgical excision with 2–3 mm margins has been the preferred approach for localized disease. Application of intraoperative supplemental cryotherapy (double freeze–thaw cycles) to conjunctival margins reduces the risk of tumor recurrence.<sup>110</sup> Topical chemotherapy has been advocated as an adjuvant for incomplete excision of large and diffuse primary or recurrent tumors.<sup>111</sup> Although mitomycin-C is the best-studied of the chemotherapeutic agents, other topical agents, including IFN- $\alpha_{2b}$ , have also been investigated.<sup>112,113</sup> In a series of six patients, all were given a single subconjunctival/perilesional injection of recombinant IFN- $\alpha_{2b}$  (3 million IU in 0.5 mL) followed by interferon drops





**Fig. 3B.6** Retinal capillary hemangioma. Ophthalmoscopic appearance of a large hemangioma with retinal exudation and detachment (**A**). Note prominent feeder vessels (**B**). Fluorescein angiogram initially fills the supplying artery (**C**) and the draining vein fluoresces a few seconds later (**D**).

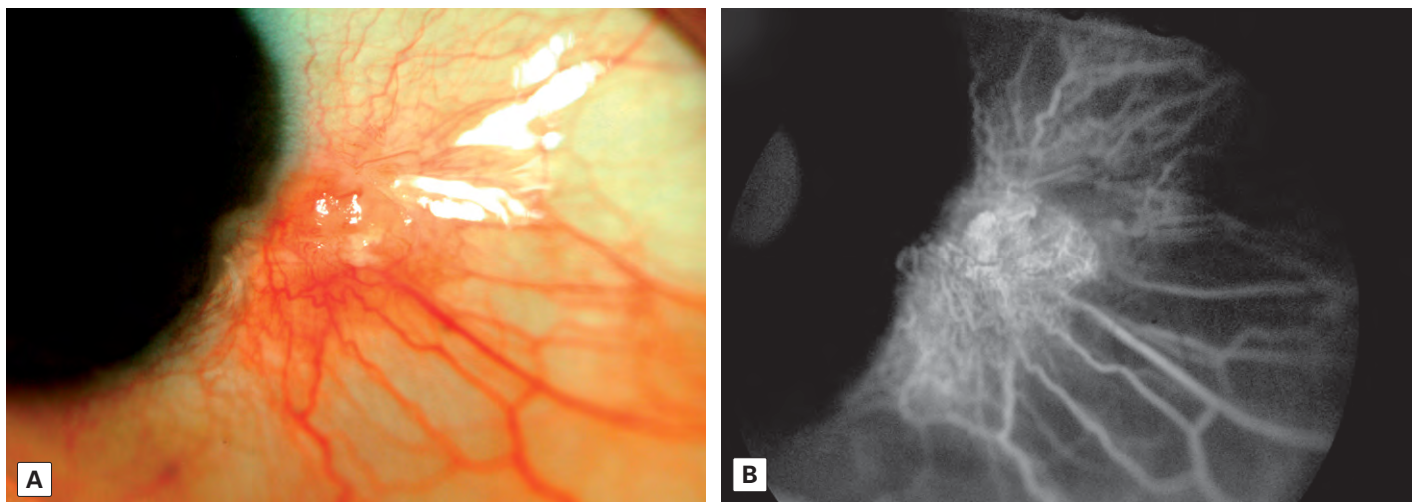


**Fig. 3B.7** Capillary hemangioma of the eyelid. (Courtesy of Elias Traboulsi, MD.)

(1 million U/mL) four times a day for a month after clinical resolution. All six had complete clinical resolution with an average follow-up of 7.2 months.<sup>112</sup> The antineoplastic effects of IFN- $\alpha_{2b}$  are due to direct antiproliferative effects, indirect anti-angiogenic effects, and immune-mediated effects.<sup>114</sup>

## CONCLUSIONS

Advances in technology offer the possibility of designing pharmaceutical agents that specifically target cellular pathways. Angiogenesis represents one such important pathway. Optimal clinical application and the efficacy of angiogenic inhibitors are currently under investigations. It is anticipated that treatment with angiogenic inhibitors will have broad application in the management of intraocular and adnexal tumors.



**Fig. 3B.8** Squamous cell carcinoma of the conjunctiva. Clinical appearance with prominent feeder and intrinsic vessels (A). The vessels are best visualized with fluorescein angiography (B).

## REFERENCES

- Folkman J. Tumor angiogenesis: therapeutic implications. *N Engl J Med* 1971; 285: 1182–1186.
- Folkman J. Angiogenesis in cancer, vascular, rheumatoid and other disease. *Nature Med* 1995; 1: 27–31.
- Tannock IF. Population kinetics of carcinoma cells, capillary endothelial cells, and fibroblasts in a transplanted mouse mammary tumor. *Cancer Res* 1970; 30: 2470–2476.
- Achilles EG, Fernandez A, Allred EN et al. Heterogeneity of angiogenic activity in a human liposarcoma: a proposed mechanism for ‘no take’ of human tumors in mice. *J Natl Cancer Inst* 2001; 93: 1075–1081.
- Holash J, Maisonpierre PC, Compton D et al. Vessel cooption, regression, and growth in tumors mediated by angiopoietins and VEGF. *Science* 1999; 284: 1994–1998.
- Gimbrone MA Jr, Cotran RS, Leapman SB, Folkman J. Tumor growth and neovascularization: an experimental model using the rabbit cornea. *J Natl Cancer Inst* 1974; 52: 413–427.
- Gimbrone MA Jr, Leapman SB, Cotran RS, Folkman J. Tumor dormancy in vivo by prevention of neovascularization. *J Exp Med* 1972; 136: 261–276.
- Hanahan D, Christofori G, Naik P, Arbeit J. Transgenic mouse models of tumour angiogenesis: the angiogenic switch, its molecular controls, and prospects for preclinical therapeutic models. *Eur J Cancer* 1996; 32A: 2386–2393.
- Smith-McCune KK, Weidner N. Demonstration and characterization of the angiogenic properties of cervical dysplasia. *Cancer Res* 1994; 54: 800–804.
- Pepper MS. Role of the matrix metalloproteinase and plasminogen activator–plasmin systems in angiogenesis. *Arterioscler Thromb Vasc Biol* 2001; 21: 1104–1117.
- Milkiewicz M, Ispanovic E, Doyle JL, Haas TL. Regulators of angiogenesis and strategies for their therapeutic manipulation. *Int J Biochem Cell Biol* 2006; 38: 333–357.
- Thompson WD, Shiach KJ, Fraser RA, McIntosh LC, Simpson JG. Tumours acquire their vasculature by vessel incorporation, not vessel ingrowth. *J Pathol* 1987; 151: 323–332.
- Jain RK. Molecular regulation of vessel maturation. *Nature Med* 2003; 9: 685–693.
- Folberg R, Maniotis AJ. Vasculogenic mimicry. *Apms* 2004; 112: 508–525.
- Gassmann P, Enns A, Haier J. Role of tumor cell adhesion and migration in organ-specific metastasis formation. *Onkologie* 2004; 27: 577–582.
- Holmgren L, O’Reilly MS, Folkman J. Dormancy of micrometastases: balanced proliferation and apoptosis in the presence of angiogenesis suppression. *Nature Med* 1995; 1: 149–153.
- Dvorak HF. Tumors: wounds that do not heal. Similarities between tumor stroma generation and wound healing. *N Engl J Med* 1986; 315: 1650–1659.
- Carmeliet P, Ferreira V, Breier G et al. Abnormal blood vessel development and lethality in embryos lacking a single VEGF allele. *Nature* 1996; 380: 435–439.
- Ferrara N, Houck K, Jakeman L, Leung DW. Molecular and biological properties of the vascular endothelial growth factor family of proteins. *Endocr Rev* 1992; 13: 18–32.
- Cao Y. Tumor angiogenesis and therapy. *Biomed Pharmacother* 2005; 59 Suppl 2: S340–343.
- Ferrara N. Vascular endothelial growth factor: basic science and clinical progress. *Endocr Rev* 2004; 25: 581–611.
- Alon T, Hemo I, Itin A, Pe’er J, Stone J, Keshet E. Vascular endothelial growth factor acts as a survival factor for newly formed retinal vessels and has implications for retinopathy of prematurity. *Nature Med* 1995; 1: 1024–1028.
- Young TL, Anthony DC, Pierce E, Foley E, Smith LE. Histopathology and vascular endothelial growth factor in untreated and diode laser-treated retinopathy of prematurity. *J Aapos* 1997; 1: 105–110.
- Adams AP, Aiello LP, D’Amato RA. Angiogenesis and ophthalmic disease. *Angiogenesis* 1999; 3: 9–14.
- Vincenti V, Cassano C, Rocchi M, Persico G. Assignment of the vascular endothelial growth factor gene to human chromosome 6p21.3. *Circulation* 1996; 93: 1493–1495.
- Houck KA, Ferrara N, Winer J et al. The vascular endothelial growth factor family: identification of a fourth molecular species and characterization of alternative splicing of RNA. *Mol Endocrinol* 1991; 5: 1806–1814.
- Matthews W, Jordan CT, Gavin M et al. A receptor tyrosine kinase cDNA isolated from a population of enriched primitive hematopoietic cells and exhibiting close genetic linkage to c-kit. *Proc Natl Acad Sci USA* 1991; 88: 9026–9030.
- Zagzag D, Zhong H, Scalzitti JM et al. Expression of hypoxia-inducible factor 1alpha in brain tumors: association with angiogenesis, invasion, and progression. *Cancer* 2000; 88: 2606–2618.
- Harris AL. Hypoxia – a key regulatory factor in tumour growth. *Nat Rev Cancer* 2002; 2: 38–47.
- Iliopoulos O, Levy AP, Jiang C, Kaelin WG Jr, Goldberg MA. Negative regulation of hypoxia-inducible genes by the von Hippel–Lindau protein. *Proc Natl Acad Sci USA* 1996; 93: 10595–10599.
- Javerzat S, Auguste P, Bikfalvi A. The role of fibroblast growth factors in vascular development. *Trends Mol Med* 2002; 8: 483–489.
- Ensoli B, Gendelman R, Markham P et al. Synergy between basic fibroblast growth factor and HIV-1 Tat protein in induction of Kaposi’s sarcoma. *Nature* 1994; 371: 674–680.
- Eklund L, Olsen BR. Tie receptors and their angiopoietin ligands are context-dependent regulators of vascular remodeling. *Exp Cell Res* 2006; 312: 630–641.
- O’Reilly MS, Holmgren L, Chen C, Folkman J. Angiostatin induces and sustains dormancy of human primary tumors in mice. *Nature Med* 1996; 2: 689–692.
- Andrawiss M, Maron A, Beltran W et al. Adenovirus-mediated gene transfer in canine eyes: a preclinical study for gene therapy of human uveal melanoma. *J Gene Med* 2001; 3: 228–239.
- Camphausen K, Moses MA, Beecken WD et al. Radiation therapy to a primary tumor accelerates metastatic growth in mice. *Cancer Res* 2001; 61: 2207–2211.
- Sertie AL, Sossi V, Camargo AA et al. Collagen XVIII, containing an endogenous inhibitor of angiogenesis and tumor growth, plays a critical role in the maintenance of retinal structure and in neural tube closure (Knobloch syndrome). *Hum Mol Genet* 2000; 9: 2051–2058.
- Noma H, Funatsu H, Yamashita H et al. Regulation of angiogenesis in diabetic retinopathy: possible balance between vascular endothelial growth factor and endostatin. *Arch Ophthalmol* 2002; 120: 1075–1080.
- Thomas JP, Arzooonian RZ, Alberti D et al. Phase I pharmacokinetic and pharmacodynamic study of recombinant human endostatin in patients with advanced solid tumors. *J Clin Oncol* 2003; 21: 223–231.



40. Herbst RS, Hess KR, Tran HT et al. Phase I study of recombinant human endostatin in patients with advanced solid tumors. *J Clin Oncol* 2002; 20: 3792–3803.
41. Reich SJ, Fosnot J, Kuroki A et al. Small interfering RNA (siRNA) targeting VEGF effectively inhibits ocular neovascularization in a mouse model. *Mol Vis* 2003; 9: 210–216.
42. Takeda A, Hata Y, Shiose S et al. Suppression of experimental choroidal neovascularization utilizing KDR selective tyrosine kinase inhibitor. *Graefes Arch Clin Exp Ophthalmol* 2003; 241: 765–772.
43. Mordenti J, Cuthbertson RA, Ferrara N et al. Comparisons of the intraocular tissue distribution, pharmacokinetics, and safety of <sup>125</sup>I-labeled full-length and Fab antibodies in rhesus monkeys following intravitreal administration. *Toxicol Pathol* 1999; 27: 536–544.
44. O'Farrell AM, Yuen HA, Smolich B et al. Effects of SU5416, a small molecule tyrosine kinase receptor inhibitor, on FLT3 expression and phosphorylation in patients with refractory acute myeloid leukemia. *Leukemia Res* 2004; 28: 679–689.
45. Tong CT, Howard SA, Shah HR et al. Effects of celecoxib in human retinoblastoma cell lines and in a transgenic murine model of retinoblastoma. *Br J Ophthalmol* 2005; 89: 1217–1220.
46. Hastings MM, Milot J, Barsoum-Homsy M et al. Recombinant interferon alfa-2b in the treatment of vision-threatening capillary hemangiomas in childhood. *J Apos* 1997; 1: 226–230.
47. Kaban LB, Troulis MJ, Ebb D et al. Antiangiogenic therapy with interferon alpha for giant cell lesions of the jaws. *J Oral Maxillofac Surg* 2002; 60: 1103–1111; discussion 1111–1103.
48. Reddy U, Kryzstolik M. Antiangiogenic therapy with interferon alfa for neovascular age-related macular degeneration. *Cochrane Database Syst Rev* 2006; CD005138.
49. Jain RK, Duda DG, Clark JW, Loeffler JS. Lessons from phase III clinical trials on anti-VEGF therapy for cancer. *Nat Clin Pract Oncol* 2006; 3: 24–40.
50. Willett CG, Boucher Y, di Tomaso E et al. Direct evidence that the VEGF-specific antibody bevacizumab has antivascular effects in human rectal cancer. *Nature Med* 2004; 10: 145–147.
51. Rini BI, Sosman JA, Motzer RJ. Therapy targeted at vascular endothelial growth factor in metastatic renal cell carcinoma: biology, clinical results and future development. *BJU Int* 2005; 96: 286–290.
52. Jain RK. Normalization of tumor vasculature: an emerging concept in antiangiogenic therapy. *Science* 2005; 307: 58–62.
53. Young J, J.L., Smith MA, Roffers SD, Liff JM, Bunin GR. Retinoblastoma. In: Ries LAG, Smith MA, Gurney JG et al., eds. *Cancer incidence and survival among children and adolescents: United States SEER Program 1975–1995*. Bethesda, MD: National Cancer Institute, SEER Program. NIH Pub. No. 99–4649, 1999.
54. Friend SH, Bernards R, Rogelj S et al. A human DNA segment with properties of the gene that predisposes to retinoblastoma and osteosarcoma. *Nature* 1986; 323: 643–646.
55. Burnier MN, McLean IW, Zimmerman LE, Rosenberg SH. Retinoblastoma. The relationship of proliferating cells to blood vessels. *Invest Ophthalmol Vis Sci* 1990; 31: 2037–2040.
56. Marback EF, Arias VE, Paranhos A Jr et al. Tumour angiogenesis as a prognostic factor for disease dissemination in retinoblastoma. *Br J Ophthalmol* 2003; 87: 1224–1228.
57. Kvanta A, Steen B, Seregard S. Expression of vascular endothelial growth factor (VEGF) in retinoblastoma but not in posterior uveal melanoma. *Exp Eye Res* 1996; 63: 511–518.
58. Conway RM, Wheeler SM, Murray TG, Jockovich ME, O'Brien JM. Retinoblastoma: animal models. *Ophthalmol Clin North Am* 2005; 18: 25–39, vii.
59. Escalona-Benz E, Jockovich ME, Murray TG et al. Combretastatin A-4 prodrug in the treatment of a murine model of retinoblastoma. *Invest Ophthalmol Vis Sci* 2005; 46: 8–11.
60. Singh AD, Bergman L, Seregard S. Uveal melanoma: epidemiologic aspects. *Ophthalmol Clin North Am* 2005; 18: 75–84, viii.
61. Chang AE, Karnell LH, Menck HR. The National Cancer Data Base report on cutaneous and noncutaneous melanoma: a summary of 84,836 cases from the past decade. The American College of Surgeons Commission on Cancer and the American Cancer Society. *Cancer* 1998; 83: 1664–1678.
62. Folberg R, Hendrix MJ, Maniotis AJ. Vasculogenic mimicry and tumor angiogenesis. *Am J Pathol* 2000; 156: 361–381.
63. Singh AD, Shields CL, Shields JA. Prognostic factors in uveal melanoma. *Melanoma Res* 2001; 11: 255–263.
64. Bajcsy P, Lee SC, Lin A, Folberg R. Three-dimensional volume reconstruction of extracellular matrix proteins in uveal melanoma from fluorescent confocal laser scanning microscope images. *J Microsc* 2006; 221: 30–45.
65. Foss AJ, Alexander RA, Jefferies LW et al. Microvessel count predicts survival in uveal melanoma. *Cancer Res* 1996; 56: 2900–2903.
66. Makitie T, Summanen P, Tarkkanen A, Kivela T. Microvascular density in predicting survival of patients with choroidal and ciliary body melanoma. *Invest Ophthalmol Vis Sci* 1999; 40: 2471–2480.
67. Schaling DF, van der Pol JP, Schlingemann RO, Parys-Van Ginderdeuren R, Jager MJ. Vascular density and vascular patterns in the prognosis of choroidal melanoma. In: Schaling DF, ed. *Radionuclides and radiolabelled antibodies in choroidal melanoma (diagnosis and therapy)*. Leiden: Rijksuniversiteit te Leiden, 1996; 43–54.
68. Lane AM, Egan KM, Yang J et al. An evaluation of tumour vascularity as a prognostic indicator in uveal melanoma. *Melanoma Res* 1997; 7: 237–242.
69. Foss AJ, Alexander RA, Hungerford JL et al. Reassessment of the PAS patterns in uveal melanoma. *Br J Ophthalmol* 1997; 81: 240–246; discussion 247–248.
70. Mudhar HS, Parsons MA, Sisley K et al. A critical appraisal of the prognostic and predictive factors for uveal malignant melanoma. *Histopathology* 2004; 45: 1–12.
71. Mueller AJ, Freeman WR, Schaller UC, Kampik A, Folberg R. Complex microcirculation patterns detected by confocal indocyanine green angiography predict time to growth of small choroidal melanocytic tumors: MuSIC Report II. *Ophthalmology* 2002; 109: 2207–2214.
72. Singh AD, Mokashi A, Bena JF et al. Small choroidal melanocytic lesions: Indocyanine angiographic features predictive of growth: A pilot study. *Ophthalmology* 2006; 113: 1061–1064.
73. Mueller AJ, Bartsch DU, Folberg R et al. Imaging the microvasculature of choroidal melanomas with confocal indocyanine green scanning laser ophthalmoscopy. *Arch Ophthalmol* 1998; 116: 31–39.
74. Sheidow TG, Hooper PL, Crukley C, Young J, Heathcote JG. Expression of vascular endothelial growth factor in uveal melanoma and its correlation with metastasis. *Br J Ophthalmol* 2000; 84: 750–756.
75. Boyd SR, Tan DS, de Souza L et al. Uveal melanomas express vascular endothelial growth factor and basic fibroblast growth factor and support endothelial cell growth. *Br J Ophthalmol* 2002; 86: 440–447.
76. Abdel-Rahman MH, Craig EL, Davidorf FH, Eng C. Expression of vascular endothelial growth factor in uveal melanoma is independent of 6p21-region copy number. *Clin Cancer Res* 2005; 11: 73–78.
77. Boyd SR, Tan D, Bunce C et al. Vascular endothelial growth factor is elevated in ocular fluids of eyes harbouring uveal melanoma: identification of a potential therapeutic window. *Br J Ophthalmol* 2002; 86: 448–452.
78. Kujala E, Makitie T, Kivela T. Very long-term prognosis of patients with malignant uveal melanoma. *Invest Ophthalmol Vis Sci* 2003; 44: 4651–4659.
79. O'Reilly MS. Angiostatin: an endogenous inhibitor of angiogenesis and of tumor growth. *Exs* 1997; 79: 273–294.
80. O'Reilly MS, Boehm T, Shing Y et al. Endostatin: an endogenous inhibitor of angiogenesis and tumor growth. *Cell* 1997; 88: 277–285.
81. O'Reilly MS, Holmgren L, Shing Y et al. Angiostatin: a novel angiogenesis inhibitor that mediates the suppression of metastases by a Lewis lung carcinoma. *Cell* 1994; 79: 315–328.
82. Zimmerman LE, McLean IW, Foster WD. Does enucleation of the eye containing a malignant melanoma prevent or accelerate the dissemination of tumour cells. *Br J Ophthalmol* 1978; 62: 420–425.
83. Singh AD, Rennie IG, Kivela T, Seregard S, Grossniklaus H, Zimmerman–McLean–Foster hypothesis: 25 years later. *Br J Ophthalmol* 2004; 88: 962–967.
84. Eskelin S, Pyrhonen S, Summanen P, Hahka-Kemppinen M, Kivela T. Tumor doubling times in metastatic malignant melanoma of the uvea: tumor progression before and after treatment. *Ophthalmology* 2000; 107: 1443–1449.
85. Singh AD. Uveal melanoma: implications of tumor doubling time. *Ophthalmology* 2001; 108: 829–830.
86. Clark AF, Mellon J, Li XY et al. Inhibition of intraocular tumor growth by topical application of the angiostatic steroid anecortave acetate. *Invest Ophthalmol Vis Sci* 1999; 40: 2158–2162.
87. Davidorf FH, Mouser JG, Derick RJ. Rapid improvement of rubeosis iridis from a single bevacizumab (Avastin) injection. *Retina* 2006; 26: 354–356.
88. Singh AD, Kivela T. The collaborative ocular melanoma study. *Ophthalmol Clin North Am* 2005; 18: 129–142, ix.
89. Singh AD, Borden EC. Metastatic uveal melanoma. *Ophthalmol Clin North Am* 2005; 18: 143–150, ix.
90. Pyrhonen S, Hahka-Kemppinen M, Muhonen T. A promising interferon plus four-drug chemotherapy regimen for metastatic melanoma. *J Clin Oncol* 1992; 10: 1919–1926.
91. Pyrhonen S, Hahka-Kemppinen M, Muhonen T et al. Chemoimmunotherapy with bleomycin, vincristine, lomustine, dacarbazine (BOLD), and human leukocyte interferon for metastatic uveal melanoma. *Cancer* 2002; 95: 2366–2372.
92. Kivela T, Suci S, Hansson J et al. Bleomycin, vincristine, lomustine and dacarbazine (BOLD) in combination with recombinant interferon alpha-2b for metastatic uveal melanoma. *Eur J Cancer* 2003; 39: 1115–1120.
93. Knudson AG Jr. Mutation and cancer: statistical study of retinoblastoma. *Proc Natl Acad Sci USA* 1971; 68: 820–823.
94. Singh AD, Shields CL, Shields JA. von Hippel–Lindau disease. *Surv Ophthalmol* 2001; 46: 117–142.
95. Latif F, Tory K, Gnarr J et al. Identification of the von Hippel–Lindau disease tumor suppressor gene. *Science* 1993; 260: 1317–1320.
96. Chan CC, Vortmeyer AO, Chew EY et al. VHL gene deletion and enhanced VEGF gene expression detected in the stromal cells of retinal angioma. *Arch Ophthalmol* 1999; 117: 625–630.
97. Aiello LP, George DJ, Cahill MT et al. Rapid and durable recovery of visual function in a patient with von Hippel–Lindau syndrome after systemic therapy with vascular endothelial growth factor receptor inhibitor su5416. *Ophthalmology* 2002; 109: 1745–1751.
98. Girmens JF, Erginay A, Massin P, Scigalla P, Gaudric A, Richard S. Treatment of von Hippel–Lindau retinal hemangioblastoma by the vascular endothelial growth factor receptor inhibitor SU5416 is more effective for associated macular edema than for hemangioblastomas. *Am J Ophthalmol* 2003; 136: 194–196.
99. Madhusudan S, Deplanque G, Braybrooke JP et al. Antiangiogenic therapy for von Hippel–Lindau disease. *JAMA* 2004; 291: 943–944.
100. Yang JC, Haworth L, Sherry RM et al. A randomized trial of bevacizumab, an anti-vascular endothelial growth factor antibody, for metastatic renal cancer. *N Engl J Med* 2003; 349: 427–434.

101. Khan ZA, Melero-Martin JM, Wu X et al. Endothelial progenitor cells from infantile hemangioma and from umbilical cord blood display unique cellular responses to endostatin. *Blood* 2006; Mar 30; [Epub ahead of print].
102. Bilyk JR, Adamis AP, Mulliken JB. Treatment options for periorbital hemangioma of infancy. *Int Ophthalmol Clin* 1992; 32: 95–109.
103. White CW, Sondheimer HM, Crouch EC, Wilson H, Fan LL. Treatment of pulmonary hemangiomatosis with recombinant interferon alfa-2a. *N Engl J Med* 1989; 320: 1197–1200.
104. Ezekowitz RA, Mulliken JB, Folkman J. Interferon alfa-2a therapy for life-threatening hemangiomas of infancy. *N Engl J Med* 1992; 326: 1456–1463.
105. Fledelius HC, Illum N, Jensen H, Prause JU. Interferon-alfa treatment of facial infantile haemangiomas: with emphasis on the sight-threatening varieties. A clinical series. *Acta Ophthalmol Scand* 2001; 79: 370–373.
106. Sun EC, Fears TR, Goedert JJ. Epidemiology of squamous cell conjunctival cancer. *Cancer Epidemiol Biomarkers Prev* 1997; 6: 73–77.
107. Lee GA, Hirst LW. Ocular surface squamous neoplasia. *Surv Ophthalmol* 1995; 39: 429–450.
108. McDonnell JM, McDonnell PJ, Sun YY. Human papillomavirus DNA in tissues and ocular surface swabs of patients with conjunctival epithelial neoplasia. *Invest Ophthalmol Vis Sci* 1992; 33: 184–189.
109. Kestelyn P. Ocular problems in AIDS. *Int Ophthalmol* 1990; 14: 165–172.
110. Fraunfelder FT, Wingfield D. Management of intraepithelial conjunctival tumors and squamous cell carcinomas. *Am J Ophthalmol* 1983; 95: 359–363.
111. Frucht-Pery J, Rozenman Y, Pe'er J. Topical mitomycin-C for partially excised conjunctival squamous cell carcinoma. *Ophthalmology* 2002; 109: 548–552.
112. Vann RR, Karp CL. Perilesional and topical interferon alfa-2b for conjunctival and corneal neoplasia. *Ophthalmology* 1999; 106: 91–97.
113. Esquenazi S, Fry CL, Holley E. Treatment of biopsy proved conjunctival intraepithelial neoplasia with topical interferon alfa-2b. *Br J Ophthalmol* 2005; 89: 1221.
114. Jonasch E, Haluska FG. Interferon in oncological practice: review of interferon biology, clinical applications, and toxicities. *Oncologist* 2001; 6: 34–55.

# Cancer immunology

Martine J. Jager, Jihan Dennaoui and Willem Maat

## INTRODUCTION

The original enthusiasm for immunotherapy was tempered when it became clear that in many patients immunotherapy did not improve survival. However, we have since learned a great deal about the specific immunological characteristics of the eye, and of uveal melanoma in particular. In this chapter we review various types of anti-tumor immune response, types of immune cells, and the mechanisms that may potentially counteract their effectiveness. We will also investigate options to overcome these inhibitions to make the immune system more effective.

## INNATE AND SPECIFIC IMMUNE RESPONSES

One can differentiate between basic general immune responses and induced specific ones. The most primitive and direct defense against either microbes, trauma or abnormal cells is the innate immune response. As soon as 'danger' is encountered, granulocytes and macrophages are alerted and will try to inactivate the danger. If this response is inadequate, antigen-presenting cells will pick up parts of the microbes or abnormal cells and take them to the regional lymph node. Proteins of the microbe or the abnormal cells are degraded into peptides, which will be presented by the antigen-presenting cell to T lymphocytes. If the appropriate T cell encounters its own antigen, it will proliferate and become an activated T cell. There are different kinds of T cell, such as T cells that can kill (cytotoxic T cells; CTLs); those that can cause local inflammation (delayed-type hypersensitivity T cells); and regulatory T cells that are able to suppress other T cells. Furthermore, T cells are necessary to stimulate B cells to begin the production of specific antibodies. Finally, the different T and B cells will try to deal with the aggressor, and the end result is usually that the body takes care of the 'danger.' If not, the lack of an effective response may lead to the death of the host.

## IMMUNOLOGICAL ESCAPE

It appears that the immune responses that do exist are limited in their effectiveness inside the eye, which is known to be an immunologically privileged site. This implies that, similar to the brain and the placenta, many immunological reactions are actively or passively downregulated, leading to the suppression of effective immunity. The development of effective anti-tumor antibodies or cytotoxic T lymphocytes (CTLs) is halted, as well as their activity. It is even possible that the presence of the tumor in the eye will induce systemic tolerance, thereby inhibiting effective immune responses against metastases.

The presence of regulatory T cells may suppress an effective immune response. This is observed when antigens are injected into the anterior

chamber of the eye of a mouse, which leads to the induction of a unusual immune response known as anterior chamber-associated immune deviation (ACAID).<sup>1</sup> ACAID is characterized by the presence of regulatory splenic T cells that prevent the development of delayed-type hypersensitivity, and prevent the maturation and differentiation of precursor CTLs.<sup>2</sup> In experimental animal models, it has been shown that tumor cells that are rejected when placed in the skin enjoy an immune-privileged ocular environment when placed inside the eye.

## IMMUNOLOGICAL ASPECTS OF UVEAL MELANOMA

Uveal melanoma develops in the choroid or the ciliary body, both of which are highly vascularized tissues that are easily accessible to immunologically active cells. The uveal melanoma cells are antigenic and patients can develop specific anti-tumor antibodies or T cells, as the tumors express a wide range of antigens. However, in spite of these anti-tumor immune responses, the tumor manages to escape immunological destruction and expands inside the eye, and especially large tumors give rise to metastases. Metastases are most frequently found in the liver, and may remain dormant for years. Eventually they proliferate, and often cause the death of the patient.

**Tumor antigen expression in uveal melanoma** In order for a CTL to be able to kill a tumor cell, it needs to identify its specific antigen on the tumor cell surface, presented by an HLA class I antigen. The first potential tumor antigens were identified by monoclonal antibodies, most of which were developed against cutaneous melanoma. Van der Pol<sup>3</sup> observed both a differential expression and heterogeneity between tumors. Antigen gp100 (recognized by monoclonal antibody NKI-beteb), for instance, was expressed on 50% of the tumors.<sup>3</sup>

The subsequent use of T cells as tools to identify specific tumor antigens led to the recognition of many more antigens, and insight into their immunological role. Some of these T-cell targets are composed of tumor-associated antigens, expressed in different types of tumors and originally related to the developmental stage of tissues. Antigens that belong to this category are the MAGE antigens, which are expressed on tumors and in male germline cells. Expression of these antigens was demonstrated in uveal melanoma cell lines, but different studies found conflicting results on primary tumors (Table 4.1). Another family of antigens include proteins that are related to the melanocytic lineage of the tumor cells, and that occur on normal melanocytes as well as uveal melanomas. Such antigens are tyrosinase, Melan-A/melanoma-antigen recognized by T cells (MART), and

**Table 4.1 Expression of MAGE, tyrosinase, gp100 and Melan-A/MART-1 on uveal melanoma. Shown are the number of samples positive for a specific antigen**

Tissue	MAGE-1	MAGE-2	MAGE-3	Tyrosinase	gp100	Melan-A/MART-1
Skin melanocytes <sup>1</sup>	Negative	Negative	Negative	Not tested	Not tested	Not tested
Choroidal melanocytes <sup>1</sup>	Negative	Negative	Negative	Not tested	Not tested	Not tested
Primary tumor <sup>2,4</sup>	0/27	0/27	0/27	57/59	55/59	57/59
Cultured primary tumor <sup>1</sup>	7/17	9/17	9/17	Not tested	Not tested	Not tested
Primary cell lines <sup>3</sup>	1/5	1/5	1/5	5/5	4/5	Not tested
Metastases <sup>2,4</sup>	0/26	0/26	0/26	28/30	27/30	29/30
Metastases cell lines <sup>3</sup>	1/3	1/3	1/3	3/3	1/3	Not tested

<sup>1</sup>Chen PW, Murray TG, Salgaller ML, Ksander BR. Expression of MAGE genes in ocular melanoma cell lines. *J Immunother* 1997;20:265–75.

<sup>2</sup>Mulcahy KA, Rimoldi D, Brasseur F et al. Infrequent expression of the MAGE gene family in uveal melanomas. *Int J Cancer* 1996;66:738–42.

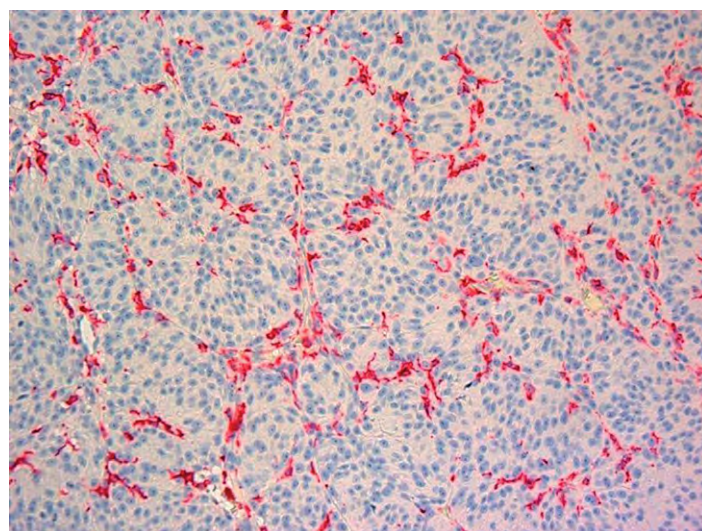
<sup>3</sup>Luyten GP, van der Spek CW, Brand I et al. Expression of MAGE, gp100 and tyrosinase genes in uveal melanoma cell lines. *Melanoma Res* 1998;8:11–16.

<sup>4</sup>de Vries TJ, Trancikova D, Ruiter DJ, van Muijen GN. High expression of immunotherapy candidate proteins gp100, MART-1, tyrosinase and TRP-1 in uveal melanoma. *Br J Cancer* 1998;78:1156–61.

gp100. A high expression of these three antigens was observed in uveal melanomas.<sup>4–7</sup> In cutaneous melanoma the expression of tyrosinase, tyrosinase-related protein (TRP-2), and MART-1 on metastases was correlated with survival.<sup>8</sup> These antigens are considered to be good targets for immunotherapy.

**HLA expression in uveal melanoma** In order to achieve lysis of tumor cells by antigen-specific CTLs, the T cell must be able to recognize the specific antigen in association with the correct HLA class I antigen. Tumors are known to lack specific HLA antigens, and this would block the effectiveness of specific CTL responses. One would expect that tumor cells that can thus escape CTL-mediated lysis would give rise to metastases, but in uveal melanoma the opposite occurs.<sup>9,10</sup> An explanation of this unexpected finding may be the role of natural killer (NK) cells. NK cells are specifically able to recognize cells that have lost the expression of HLA class I antigens. We hypothesize that during hematogenous spread uveal melanoma micrometastases with a low expression of HLA class I are removed from the blood by circulating NK cells, before they can reach the liver.<sup>11</sup> This hypothesis is supported by earlier experimental studies by Ma and Niederkorn<sup>12</sup> in mice: when uveal melanoma cells with a low HLA class I expression were injected into the bloodstream of mice they did not induce metastases, whereas cells with a high HLA class I expression did. It is therefore likely that NK cells in particular are the protective barrier against the formation of metastases in uveal melanoma.

**Infiltrating immune cells in uveal melanoma** Uveal melanoma contains varying numbers of lymphocytes and macrophages. In a series of 326 patients with primary uveal melanoma, an association between increased numbers of lymphocytes and a worse survival was observed.<sup>13</sup> Additionally, it was demonstrated that patients who survived at least 15 years after enucleation had fewer infiltrating T or B lymphocytes than patients who died earlier.<sup>14</sup> De Waard-Siebinga<sup>15</sup> found small numbers of T cells in all tumors, and performed monoclonal antibody staining for specific types of T cell, B cell and macrophage. She observed a predominance of T cells (CD4+ and CD8+ cells). Furthermore, most tumors contained CD11b-positive macrophages. A significant positive correlation was observed between the presence of CD3+ T cells and HLA class I expression, and between CD11b-positive



**Fig. 4.1** Positive staining for macrophages in a uveal melanoma.

cells (macrophages) and expression of HLA class I. Subsequently, Mäkitie et al.<sup>16</sup> compared the presence of macrophages with survival (Fig. 4.1). Using a monoclonal antibody against marker CD68 in 139 tumors, a low number of macrophages was seen in 17% of the tumors, moderate numbers in 51%, and high numbers in 32%. An increased number of macrophages was associated with a large basal diameter of the tumor, the presence of epithelioid cells, and a high microvascular density, all known to be poor prognostic factors. The number of macrophages was related to survival: the 10-year cumulative probability of survival was 0.90 for patients with few macrophages, 0.58 with a moderate number, and 0.43 with many.

**Anti-uveal melanoma T-cell responses** Although the leukocyte migration assay is no longer used owing to the availability of elegant CTL tests, the first data on anti-tumor cellular immune responses in patients were obtained with this test. When peripheral blood leukocytes identify an antigen that they are familiar with, they secrete factors such as macrophage-inhibition factor, inhibiting the migration



of leukocytes. Using soluble melanoma antigens derived from a metastasis, Char<sup>17</sup> demonstrated that only uveal melanoma patients showed an active immune response against those antigens, and not healthy controls. Using leukocyte migration assays and formalinized melanoma cells, Cochran<sup>18</sup> demonstrated that the majority of patients with uveal melanoma, conjunctival melanoma, and cutaneous melanoma had anti-tumor T-cell reactivity. However, this was not specific: one-third of healthy controls showed a similar reaction. A significant difference was seen between patients with extraocular spread and those without: the first group more often showed an anti-tumor T-cell response. Also, anti-tumor antibodies were observed more frequently in the group with extraocular spread. Taken together, these observations indicate that immune responses do not stop the tumor cells invading into extraocular tissues or prevent metastases.

With the availability of uveal melanoma cell lines it became possible to test for the presence of cytotoxic antiuveal melanoma T cells.<sup>19</sup> Out of 27 samples of peripheral blood leukocytes from uveal melanoma patients incubated with irradiated OCM-1 uveal melanoma cells in vitro, 21 showed positive CTL-mediated lysis against OCM-1. Whether the presence of CTLs is related to survival has not been elucidated.

**Antibodies against uveal melanoma** Sera from patients with uveal melanoma often test positively for antibodies against cytoplasmic or cell surface antigens of uveal melanoma and tumor-specific antibodies.<sup>20</sup> Immunoglobulin M antibodies are found more frequently than more specific IgG antibodies.<sup>18,20</sup> However, the effect of anti-tumor antibodies has only a limited effect on uveal melanoma cells, as immunohistochemical examination of sections of primary uveal melanoma has shown the expression of several complement inhibitors. Both complement decay-accelerating factor and complement-regulatory protein CD59 were expressed on the tumor cells that block complement-mediated attacks against the uveal melanoma cells.<sup>21</sup>

**Inducing anti-tumor immune responses** That immune responses may have clinical relevance was shown by a description of one specific case,<sup>22</sup> where repeated injections of an experimental melanoma vaccine led to the shrinkage of an intraocular melanoma. When treatment was discontinued the tumor regrew, and after resumption of the vaccinations it shrank again. Even though other trials focus on metastases, not on primary uveal melanoma, this type of success is not often observed.

The first trials to boost systemic anti-tumor immune responses assumed that for some reason the patient had not been able to develop a strong enough immune response, due either to a lack of expression of tumor antigens, the presence of ineffective antigen presentation, or to a lack of effector T cells. This led to a multitude of trials to stimulate the immune system with interleukin (IL)-2, interferon- $\alpha$ , and the injection of tumor peptides with adjuvants such as activated dendritic cells (DCs). Although these treatments had worked well in murine models, they worked in only a limited number of patients. This may have been because an effective suppressive immunological response had already developed that was able to inhibit anti-tumor responses.

**Immunosuppressive environment** One cause for the induction of a suppressor instead of an effector immune response may be the presence of ineffective antigen-presenting cells in the tumor. Subsequently, active T-cell suppression may be induced instead of stimulation. Mature myeloid DCs are able to induce strong T helper-type immune responses. However, such DCs are not common in tumors,

and there are many factors present in tumor stroma and, in case of the eye, in the intraocular fluid, that are able to inhibit the differentiation and maturation of dendritic cells. In 1992, Wilbanks<sup>23</sup> showed that macrophages that had been incubated in intraocular fluid, which contains transforming growth factor (TGF)- $\beta$ , were able to induce immune suppression instead of stimulation.

Other factors that may come from the tumor cells themselves are immunosuppressive factors such as vascular endothelial growth factor (VEGF), IL-6, IL-10, and TGF- $\beta$ .<sup>24</sup> Tumor cells may regulate the production of cytokines in tumor-infiltrating DCs or monocytes.<sup>25,26</sup> Woodward<sup>27</sup> observed that another cytokine, macrophage inflammatory protein-1 $\beta$  (MIP-1 $\beta$ ) stimulated both migration in vitro and the invasion of cultured uveal melanoma cells through a fibronectin-coated membrane, stimulating cell movement during metastasis. It is therefore clear that there can be various host-tumor interactions thanks to the presence of different types of macrophage/dendritic cell inside a uveal melanoma, which affect the behavior of the tumor cells and the immune response against the tumor.

Factors that stimulate the differentiation of DCs are granulocyte-macrophage colony-stimulating factor, IL-4, IL-12, and interferon- $\gamma$ , but these are generally not present in human tumors.<sup>28</sup> The presence of immature DCs may induce either suppressive regulatory T cells or T-cell unresponsiveness.<sup>29</sup> Not only do local dendritic cells influence the development of immune responses, they also play a role in the formation of blood vessels.<sup>30</sup>

**Other tumor defense mechanisms** In many types of cancer, irradiation or chemotherapy is used to treat the primary tumor or metastases. It has been suggested that uveal melanomas are resistant to chemotherapy because of an inherent resistance to the development of apoptosis. Almost a decade ago, we showed that uveal melanoma cells express high levels of multidrug resistance-related proteins.<sup>31</sup> Li<sup>32</sup> tested the sensitivity of 11 human uveal melanoma cell lines for tumor necrosis factor-related apoptosis-inducing ligand (TRAIL) and observed that only four were susceptible. Resistance was correlated with the expression of survivin, and blocking survivin with antisense RNA rendered resistant melanoma cells susceptible to TRAIL-induced apoptosis. Actinomycin-D decreased survivin expression and also helped to increase apoptosis. Using the induction of apoptosis as a way to kill tumor cells may become an important approach in uveal melanoma treatment.

## FUTURE IMMUNE INTERVENTION STUDIES AGAINST HUMAN MELANOMA

Although many effective treatments have been developed for intraocular tumors, hardly any treatment is available for distant metastases. A specific advantage of uveal melanoma is the high expression of HLA class I antigens on the metastases.<sup>33</sup> It may well be that the best results will be obtained in patients without clinical metastases, using immunotherapy for a 'pre-emptive strike.' Therefore, ways to identify patients who have the highest risk of developing metastases could be critical.

An improved response to vaccines may be expected by adding components to tumor treatments that will oppose the immunetolerizing conditions due to regulatory T cells, inactivated dendritic cells, and suppressive cytokines. Vaccines can be created that express HLA class I, HLA class II, and co-stimulatory molecules, in order to increase the stimulatory effect on CD4 lymphocytes.<sup>34,35</sup> In addition, natural immune effectors cells such as NK cells and effector cytokines



should be enhanced. Combining chemotherapy and immunotherapy by NK cells appears to be logical because of observations that one of the ligands for NK cells, i.e. MIC-A/B, is upregulated following treatment with fotemustine.<sup>36</sup>

The presence of tumor-infiltrating cells, anti-tumor antibodies or DTH is usually associated with a poorer prognosis. Under natural

circumstances the body is unable to develop an effective anti-tumor immune response, not only against the primary tumor in an immunologically privileged site, but also against the metastases. In order to obtain better survival, the combination of chemotherapy with immunotherapy will be essential. Finding ways to overcome these immunosuppressive tendencies will be a challenge.

## REFERENCES

- Streilein JW. Ocular immune privilege: therapeutic opportunities from an experiment of nature. *Nat Rev Immunol* 2003; 3: 879–889.
- Ksander BR, Rubsamen PE, Olsen KR, Cousins SW, Streilein JW. Studies of tumor-infiltrating lymphocytes from a human choroidal melanoma. *Invest Ophthalmol Vis Sci* 1991; 32: 3198–3208.
- van der Pol JP, Jager MJ, de Wolff-Rouendaal D et al. Heterogeneous expression of melanoma-associated antigens in uveal melanomas. *Curr Eye Res* 1987; 6: 757–765.
- Mulcahy KA, Rimoldi D, Brasseur F et al. Infrequent expression of the MAGE gene family in uveal melanomas. *Int J Cancer* 1996; 66: 738–742.
- Chen PW, Murray TG, Salgaller ML, Ksander BR. Expression of MAGE genes in ocular melanoma cell lines. *J Immunother* 1997; 20: 265–275.
- Luyten GP, van der Spek CW, Brand I et al. Expression of MAGE, gp100 and tyrosinase genes in uveal melanoma cell lines. *Melanoma Res* 1998; 8: 11–16.
- de Vries TJ, Trancikova D, Ruiters DJ, van Muijen GN. High expression of immunotherapy candidate proteins gp100, MART-1, tyrosinase and TRP-1 in uveal melanoma. *Br J Cancer* 1998; 78: 1156–1161.
- Takeuchi H, Kuo C, Morton DL, Wang HJ, Hoon DS. Expression of differentiation melanoma-associated antigen genes is associated with favorable disease outcome in advanced-stage melanomas. *Cancer Res* 2003; 63: 441–448.
- Blom DJ, Luyten GP, Mooy C et al. Human leukocyte antigen class I expression. Marker of poor prognosis in uveal melanoma. *Invest Ophthalmol Vis Sci* 1997; 38: 1865–1872.
- Ericsson C, Seregard S, Bartolazzi A et al. Association of HLA class I and class II antigen expression and mortality in uveal melanoma. *Invest Ophthalmol Vis Sci* 2001; 42: 2153–2156.
- Jager MJ, Hurks HM, Levitskaya J, Kiessling R. HLA expression in uveal melanoma: there is no rule without some exception. *Hum Immunol* 2002; 63: 444–451.
- Ma D, Luyten GP, Luider TM, Niederkorn JY. Relationship between natural killer cell susceptibility and metastasis of human uveal melanoma cells in a murine model. *Invest Ophthalmol Vis Sci* 1995; 36: 435–441.
- Davidorf FH, Lang JR. Lymphocytic infiltration in choroidal melanoma and its prognostic significance. *Trans Ophthalmol Soc UK* 1977; 97: 394–401.
- Whelchel JC, Farah SE, McLean IW, Burnier MN. Immunohistochemistry of infiltrating lymphocytes in uveal malignant melanoma. *Invest Ophthalmol Vis Sci* 1993; 34: 2603–2606.
- de Waard-Siebinga I, Hilders CG, Hansen BE, van Delft JL, Jager MJ. HLA expression and tumor-infiltrating immune cells in uveal melanoma. *Graefes Arch Clin Exp Ophthalmol* 1996; 234: 34–42.
- Makitie T, Summanen P, Tarkkanen A, Kivela T. Tumor-infiltrating macrophages (CD68(+) cells) and prognosis in malignant uveal melanoma. *Invest Ophthalmol Vis Sci* 2001; 42: 1414–1421.
- Char DH. Inhibition of leukocyte migration with melanoma-associated antigens in choroidal tumors. *Invest Ophthalmol Vis Sci* 1977; 16: 176–179.
- Cochran AJ, Foulds WS, Damato BE et al. Assessment of immunological techniques in the diagnosis and prognosis of ocular malignant melanoma. *Br J Ophthalmol* 1985; 69: 171–176.
- Kan-Mitchell J, Liggett PE, Harel W et al. Lymphocytes cytotoxic to uveal and skin melanoma cells from peripheral blood of ocular melanoma patients. *Cancer Immunol Immunother* 1991; 33: 333–340.
- Wong IG, Oskvig RM. Immunofluorescent detection of antibodies to ocular melanomas. *Arch Ophthalmol* 1974; 92: 98–102.
- Goslings WR, Blom DJ, de Waard-Siebinga I et al. Membrane-bound regulators of complement activation in uveal melanomas. CD46, CD55, and CD59 in uveal melanomas. *Invest Ophthalmol Vis Sci* 1996; 37: 1884–1891.
- Mitchell MS, Liggett PE, Green RL et al. Sustained regression of a primary choroidal melanoma under the influence of a therapeutic melanoma vaccine. *J Clin Oncol* 1994; 12: 396–401.
- Wilbanks GA, Streilein JW. Fluids from immune privileged sites endow macrophages with the capacity to induce antigen-specific immune deviation via a mechanism involving transforming growth factor-beta. *Eur J Immunol* 1992; 22: 1031–1036.
- Gabrilovich DI, Chen HL, Girgis KR et al. Production of vascular endothelial growth factor by human tumors inhibits the functional maturation of dendritic cells. *Nature Med* 1996; 2: 1096–1103.
- Cools-Lartigue J, Marshall JC, Caissie AL, Saraiva VS, Burnier MN Jr. Secretion of interleukin-6 and prostaglandin E2 during uveal melanoma-monocyte in vitro interactions. *Exp Eye Res* 2004; 79: 451–454.
- Cools-Lartigue J, Marshall JC, Caissie AL, Saraiva VS, Burnier MN Jr. Secretion of hepatocyte growth factor and vascular endothelial growth factor during uveal melanoma-monocyte in vitro interactions. *Melanoma Res* 2005; 15: 141–145.
- Woodward JK, Elshaw SR, Murray AK et al. Stimulation and inhibition of uveal melanoma invasion by HGF, GRO, IL-1alpha and TGF-beta. *Invest Ophthalmol Vis Sci* 2002; 43: 3144–3152.
- Zou W. Immunosuppressive networks in the tumour environment and their therapeutic relevance. *Nat Rev Cancer* 2005; 5: 263–274.
- Dhodapkar MV, Steinman RM, Krasovsky J, Munz C, Bhardwaj N. Antigen-specific inhibition of effector T cell function in humans after injection of immature dendritic cells. *J Exp Med* 2001; 193: 233–238.
- Curiel TJ, Cheng P, Mottram P et al. Dendritic cell subsets differentially regulate angiogenesis in human ovarian cancer. *Cancer Res* 2004; 64: 5535–5538.
- van der Pol JP, Blom DJ, Flens MJ et al. Multidrug resistance-related proteins in primary choroidal melanomas and in vitro cell lines. *Invest Ophthalmol Vis Sci* 1997; 38: 2523–2530.
- Li H, Niederkorn JY, Neelam S, Alizadeh H. Resistance and susceptibility of human uveal melanoma cells to TRAIL-induced apoptosis. *Arch Ophthalmol* 2005; 123: 654–661.
- Blom DJ, Schurmans LR, De Waard-Siebinga I et al. HLA expression in a primary uveal melanoma, its cell line, and four of its metastases. *Br J Ophthalmol* 1997; 81: 989–993.
- Thompson JA, Dissanayake SK, Ksander BR et al. Tumor cells transduced with the MHC class II transactivator and CD80 activate tumor-specific CD4+ T cells whether or not they are silenced for invariant chain. *Cancer Res* 2006; 66: 1147–1154.
- Ostrand-Rosenberg S. CD4+ T lymphocytes: a critical component of anti-tumor immunity. *Cancer Invest* 2005; 23: 413–419.
- Vetter CS, Lieb W, Brocker EB, Becker JC. Loss of nonclassical MHC molecules MIC-A/B expression during progression of uveal melanoma. *Br J Cancer* 2004; 91: 1495–1499.

# Cancer genetics

J. William Harbour and Michael D. Onken

## INTRODUCTION

A fundamental characteristic of cancer cells is that they proliferate and survive outside their normal physiologic context. This ability is acquired through genetic mutations and epigenetic alterations in the genes responsible for sensing, interpreting, and responding to tissue-specific homeostatic signals. Hence some of the most common cancer-related genes are involved in cell cycle, differentiation, apoptosis, and angiogenesis. These genes are often referred to as oncogenes and tumor suppressor genes, depending on whether cancer-causing mutations result in gain or loss of function, respectively. In this chapter we will review some of the genes and pathways that commonly are deregulated in cancer (Fig. 5.1).

## PROLIFERATION AND THE CELL CYCLE

**Growth factor signaling pathways** Because a fundamental characteristic of cancer cells is their uncontrolled proliferation, it is not surprising that many cancer-related genes are involved in cell cycle regulation. Normal cells are limited in their proliferative capacity by the availability of mitogenic (growth-stimulating) signals. Cancer cells often overcome this limitation and become mitogen independent by mutations in growth factor receptors, which were some of the first oncogenes identified. Gain-of-function mutations in genes encoding proteins such as the epithelial growth factor receptor and the *c-kit* receptor circumvent the requirement for growth factors and can lead to constitutive growth signaling and autocrine stimulation.<sup>1</sup> Alternatively, growth factor signaling can be disrupted by mutations downstream of the receptor. For example, the Ras-Raf-MAPK (mitogen activated protein kinase) pathway is frequently disrupted in cancer.<sup>2</sup> The Ras oncoproteins are regulated by a wide variety of growth factor receptors, but also can become constitutively activated through specific mutations independent of this regulation.<sup>3</sup> Raf oncoproteins are activated downstream of Ras, and B-Raf is a frequent target of activating mutations in cutaneous melanoma.<sup>4</sup> Although B-Raf mutations are rare in uveal melanoma,<sup>5</sup> the MAPK pathway is disrupted in these tumors by as yet unknown mutations.<sup>6</sup>

The tumor growth factor (TGF)- $\beta$  pathway is also a frequent target of cancer mutations. TGF- $\beta$  acts on its receptors to regulate a broad range of physiologic events, including cell proliferation.<sup>7</sup> One of the key activities of TGF- $\beta$  is to induce nuclear localization of the transcription factor Smad4, which activates cell cycle inhibitory genes such as p15Ink4b, p21CIP, and p27KIP. Cancer cells can disrupt this pathway through various mechanisms, including mutation of the TGF- $\beta$  receptor or Smad4. Uveal melanomas frequently exhibit defects

in the TGF- $\beta$  pathway, although specific mutations are yet to be identified.<sup>8</sup>

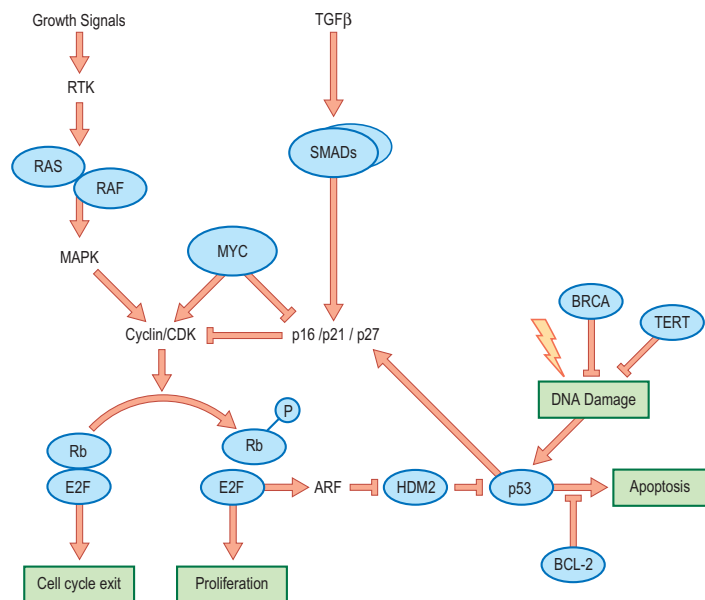
**Rb-p16Ink4a-cyclin D pathway** The ultimate downstream target of most growth signaling pathways is the core cell cycle machinery, which is regulated by the retinoblastoma protein (Rb) pathway.<sup>9</sup> Consistent with the fundamental importance of this pathway, virtually all cancers harbor mutations that disrupt Rb function. Although the Rb gene itself is mutated in only a subset of cancers, including its namesake, mutations elsewhere in the Rb pathway that functionally inactivate Rb are more common. Typically, the effect of these mutations is to maintain Rb in a hyperphosphorylated (inactive) state where it is incapable of inhibiting cell cycle progression. In uveal melanomas, for example, Rb is inappropriately phosphorylated as a result of cyclin D overexpression or p16Ink4a inactivation, both of which result in excessive Rb kinase activity.<sup>10</sup> Not surprisingly, cyclin D overexpression is associated with a poor prognosis.<sup>10,11</sup>

**Myc** The *Myc* genes, human homologs of the avian viral myelocytomatosis (*v-myc*) gene, are often upregulated and/or amplified in cancers and can support neoplastic transformation.<sup>12</sup> The proteins encoded by the *Myc* genes regulate many genes involved in proliferation and apoptosis, such as cyclin D and CDK4, which in turn regulate the Rb pathway. The *c-Myc* gene is located at chromosome 8q24 within the region that is frequently amplified in uveal melanoma.<sup>13</sup> Moreover, most uveal melanomas overexpress the *c-Myc* protein.<sup>14</sup> Sporadic amplifications of the *N-Myc* gene have been reported in retinoblastoma, but unlike in neuroblastoma these amplifications have no impact on prognosis.<sup>15</sup>

## APOPTOSIS AND SENESCENCE

Normal cells undergo apoptosis (programmed cell death) or senescence (permanent cell cycle withdrawal) if they stray from their normal environmental restraints.<sup>16</sup> The success of cancer cells depends on their ability not only to proliferate, but also to avoid apoptosis and senescence as they deviate further from their normal physiologic milieu. In fact, the rate of tumor growth is most accurately thought of as a balance between cell proliferation and cell attrition. Mutations in the p53, Rb and other pathways are ubiquitous in cancer cells, which is indicative of their importance in tumor suppression.

**p53 and HDM2** The p53 tumor suppressor can activate senescence and apoptotic programs in response to abnormalities associated with



**Fig. 5.1** This diagram illustrates some of the major components of proliferative and apoptotic pathways that are linked through a complex, interdependent network of interactions that pose a formidable obstacle to neoplastic transformation and cancer progression. Rb and p53 pathways are interconnected and form a cornerstone for the cellular strategy against neoplastic transformation. When Rb is hypophosphorylated and able to bind E2F transcription factors, it inhibits proliferation and promotes cell cycle exit (differentiation or senescence). However, when Rb is phosphorylated as a result of upstream signaling through the Ras-Raf-MAPK, TGF- $\beta$  or signaling pathways, cell cycle progression is permitted. If this cell proliferation is deregulated, for example when an oncogene such as Ras is mutated, excessive levels of E2F are released from inhibition by Rb and trigger apoptosis through activation of p53. Likewise, DNA damage and other cellular abnormalities can activate p53, which serves to arrest or sacrifice the cell if potentially neoplastic aberrations are encountered. Cancer cells overcome these tumor suppressor mechanisms by many different strategies that aim to disrupt the Rb-p53 network.

neoplastic transformation, such as excessive proliferation and DNA damage.<sup>17</sup> Over half of all cancers contain loss-of-function mutations in the p53 gene, and most other cancers functionally inhibit p53. In uveal melanoma p53 is rarely mutated, and exhibits normal activation in response to DNA damage.<sup>18</sup> However, the p53 pathway is functionally impaired, and this is explained at least in part by overexpression of the p53 inhibitor HDM2.<sup>18,19</sup> In fact, increased HDM2 expression is associated with poor outcome in uveal melanoma patients.<sup>11</sup> Similarly, retinoblastomas rarely contain p53 mutations,<sup>20</sup> but they die rapidly when treated with an HDM2 inhibitor, suggesting that HDM2 may also antagonize p53 in this eye cancer.<sup>21</sup>

**Bcl-2** is an anti-apoptotic factor and the namesake of a family of pro- and anti-apoptotic proteins that interact in a complex manner to regulate apoptosis via the intrinsic mitochondrial pathway.<sup>22</sup> Bcl-2 is overexpressed in many cancer types as a mechanism for inhibiting apoptosis. The vast majority of uveal melanomas express high levels of Bcl-2.<sup>21</sup> As evidence that Bcl-2 overexpression may contribute to the resistance to death of these tumors, we showed that inhibition of Bcl-2 by a selective small molecule inhibitor causes tumor cell apoptosis.<sup>21</sup>

**Telomerase** Cell cycling is normally accompanied by shortening of the telomeres until they are reduced to a critical length that triggers a DNA damage response and p53-mediated senescence or apoptosis.<sup>23</sup> Telomerase is an enzyme capable of extending the length of telomeres.<sup>23</sup> Consequently, cancer cells often commandeer this enzyme by upregulating its catalytic subunit, TERT, to maintain telomere length. For example, telomerase activity is detected in most uveal melanomas, although the significance of this finding is not yet clear.<sup>24</sup>

**BRCA** BRCA-1 and -2 are DNA damage repair proteins, and mutation of these genes leads to an accumulation of DNA damage and an increased likelihood of acquiring cancerous mutations.<sup>25</sup> The BRCA genes were originally identified as common mutations associated with familial breast cancer, but they have since been linked to many other cancers. For instance, germline BRCA2 mutations have been found in up to 3% of uveal melanoma patients.<sup>26,27</sup> Although these findings strongly implicate a role for DNA damage repair defects in the pathogenesis of uveal melanoma in these patients, these studies were limited to selected patients who were highly likely to have a genetic predisposition to melanoma, so the role of BRCA mutations in the vast majority of sporadic uveal melanoma patients remains unclear.

## ANGIOGENESIS

Cancer cells require a supply of nutrients and oxygen to survive. Passive diffusion of nutrients is limited to about a distance of 3 mm.<sup>28</sup> Thus, for tumors to grow beyond this size they must develop a blood supply. Tumor angiogenesis can involve many mechanisms, the most familiar of which are discussed here.

**Growth factors** Vascular endothelial growth factor (VEGF) and fibroblast growth factor (FGF) are two important factors that are often involved in tumor angiogenesis.<sup>28</sup> Retinoblastomas are highly vascular tumors that express VEGF.<sup>29</sup> Recent work suggests that targeting the tumor vasculature may be an effective treatment for retinoblastoma.<sup>30</sup> Uveal melanomas also express VEGF, but it remains unclear whether VEGF alone accounts for the complex tumor vasculature in these tumors.<sup>31</sup>

**HIF/VHL** Hypoxia-inducible factor (HIF) is a sensor of hypoxia and a regulator of the cellular hypoxic response. HIF is a heterodimeric complex comprised of an  $\alpha$ -subunit, usually HIF-1 $\alpha$ , and a  $\beta$ -subunit, usually the aryl hydrocarbon receptor nuclear translocator (ARNT). Under normoxic conditions HIF-1 $\alpha$  is polyubiquitylated and targeted for proteasomal degradation. However, under hypoxic conditions HIF-1 $\alpha$  is no longer polyubiquitylated and accumulates, allowing it to dimerize with ARNT and activate transcription of target genes. HIF appears to be able to function as an oncogene, as it is overexpressed in some cervical, breast, ovarian, endometrial, and stomach cancers, and is associated with a poor prognosis.<sup>32</sup>

Von Hippel-Lindau syndrome (VHL) is a phakomatosis that features retinal and cerebellar haemangioblastomas, as well as renal cell carcinomas and other tumors. The VHL gene encodes a tumor suppressor that binds to HIF-1 $\alpha$  and targets it for degradation via the ubiquitin pathway, thereby maintaining HIF in an inactive state. VHL binds a domain of HIF-1 $\alpha$  that must be hydroxylated for binding to occur. This hydroxylation in turn requires molecular oxygen as a substrate. Thus, when oxygen levels are low, VHL binding to HIF-1 $\alpha$

is impaired, thereby freeing HIF-1 $\alpha$  to activate genes involved in angiogenesis, such as VEGF.<sup>33</sup> This mechanism would suggest that retinal hemangioblastomas may be responsive to VEGF inhibitors.<sup>34</sup>

## CONCLUSION

All cancers face a similar set of obstacles that must be overcome for them to survive and flourish. The tissue-specific regulatory environments will determine the specific details of how these obstacles must

be overcome, but there is a common theme throughout most cancers: circumvention of cell cycle control, suppression of apoptosis, avoidance of senescence, and induction of angiogenesis. Ocular cancers are no exception to this rule and, in fact, uveal melanoma and retinoblastoma are ideal models for studying some of these mechanisms. As we gain further understanding of these molecular processes, it will become increasingly possible to design targeted therapies to delay or prevent cancer progression.

## REFERENCES

- Bafico A, Aaronson SA. Growth factors and signal transduction in cancer. In: Kufe DW, Pollock R, Weichselbaumet RR et al.(eds) Cancer medicine, 6th edn. Hamilton, Ontario: BC Decker Inc; 2003.
- Sebolt-Leopold JS, Herrera R. Targeting the mitogen-activated protein kinase cascade to treat cancer. *Nat Rev Cancer* 2004; 4: 937–947.
- Bos JL. ras Oncogenes in human cancer: a review. *Cancer Res* 1989; 49: 4682–4689.
- Pollock PM, Meltzer PS. A genome-based strategy uncovers frequent BRAF mutations in melanoma. *Cancer Cell* 2002; 2: 5–7.
- Cohen Y, Goldenberg-Cohen N, Parrella P et al. Lack of BRAF mutation in primary uveal melanoma. *Invest Ophthalmol Vis Sci* 2003; 44: 2876–2878.
- Zuidervaart W, van Nieuwpoort F, Stark M et al. Activation of the MAPK pathway is a common event in uveal melanomas although it rarely occurs through mutation of BRAF or RAS. *Br J Cancer* 2005; 92: 2032–2038.
- Elliott RL, Blobe GC. Role of transforming growth factor beta in human cancer. *J Clin Oncol* 2005; 23: 2078–2093.
- Woodward JK, Rennie IG, Burn JL, Sisley K. A potential role for TGFbeta in the regulation of uveal melanoma adhesive interactions with the hepatic endothelium. *Invest Ophthalmol Vis Sci* 2005; 46: 3473–3477.
- Harbour JW, Dean DC. The Rb/E2F pathway: expanding roles and emerging paradigms. *Genes Dev* 2000; 14: 2393–2409.
- Brantley MA Jr, Harbour JW. Inactivation of retinoblastoma protein in uveal melanoma by phosphorylation of sites in the COOH-terminal region. *Cancer Res* 2000; 60: 4320–4323.
- Coupland SE, Anastassiou G, Stang A et al. The prognostic value of cyclin D1, p53, and MDM2 protein expression in uveal melanoma. *J Pathol* 2000; 191: 120–126.
- Henriksson M, Luscher B. Proteins of the Myc network: essential regulators of cell growth and differentiation. *Adv Cancer Res* 1996; 68: 109–182.
- Parrella P, Caballero OL, Sidransky D, Merbs SL. Detection of c-myc amplification in uveal melanoma by fluorescent in situ hybridization. *Invest Ophthalmol Vis Sci* 2001; 42: 1679–1684.
- Royds JA, Sharrard RM, Parsons MA et al. C-myc oncogene expression in ocular melanomas. *Graefes Arch Clin Exp Ophthalmol* 1992; 230: 366–371.
- Lillington DM, Goff LK, Kingston JE et al. High level amplification of N-MYC is not associated with adverse histology or outcome in primary retinoblastoma tumours. *Br J Cancer* 2002; 87: 779–782.
- Dragovich T, Rudin CM, Thompson CB. Signal transduction pathways that regulate cell survival and cell death. *Oncogene* 1998; 17: 3207–3213.
- Prives C, Hall PA. The p53 pathway. *J Pathol* 1999; 187: 112–126.
- Brantley MA Jr, Harbour JW. Deregulation of the Rb and p53 pathways in uveal melanoma. *Am J Pathol* 2000; 157: 1795–1801.
- Sun Y, Tran BN, Worley LA et al. Functional analysis of the p53 pathway in response to ionizing radiation in uveal melanoma. *Invest Ophthalmol Vis Sci* 2005; 46: 1561–1564.
- Nork TM, Poulsen GL, Millecchia LL et al. p53 regulates apoptosis in human retinoblastoma. *Arch Ophthalmol* 1997; 115: 213–219.
- Harbour JW, Worley L, Ma D, Cohen M. Transducible peptide therapy for uveal melanoma and retinoblastoma. *Arch Ophthalmol* 2002; 120: 1341–1346.
- Gross A, McDonnell JM, Korsmeyer SJ. BCL-2 family members and the mitochondria in apoptosis. *Genes Dev* 1999; 13: 1899–1911.
- Blasco MA. Telomeres and human disease: ageing, cancer and beyond. *Nature Rev Genet* 2005; 6: 611–622.
- Heine B, Coupland SE, Kneiff S et al. Telomerase expression in uveal melanoma. *Br J Ophthalmol* 2000; 84: 217–223.
- Risinger MA, Groden J. Crosslinks and crosstalk: human cancer syndromes and DNA repair defects. *Cancer Cell* 2004; 6: 539–545.
- Iscovich J, Abdulrazik M, Cour C et al. Prevalence of the BRCA2 6174 del T mutation in Israeli uveal melanoma patients. *Int J Cancer* 2002; 98: 42–44.
- Scott RJ, Vajdic CM, Armstrong BK et al. BRCA2 mutations in a population-based series of patients with ocular melanoma. *Int J Cancer* 2002; 102: 188–191.
- Folkman J. Fundamental concepts of the angiogenic process. *Curr Mol Med* 2003; 3: 643–651.
- Kvanta A, Steen B, Seregard S. Expression of vascular endothelial growth factor (VEGF) in retinoblastoma but not in posterior uveal melanoma. *Exp Eye Res* 1996; 63: 511–518.
- Escalona-Benz E, Jockovich ME, Murray TG et al. Combretastatin A-4 prodrug in the treatment of a murine model of retinoblastoma. *Invest Ophthalmol Vis Sci* 2005; 46: 8–11.
- Sheidow TG, Hooper PL, Crukley C et al. Expression of vascular endothelial growth factor in uveal melanoma and its correlation with metastasis. *Br J Ophthalmol* 2000; 84: 750–756.
- Quintero M, Mackenzie N, Brennan PA. Hypoxia-inducible factor 1 (HIF-1) in cancer. *Eur J Surg Oncol* 2004; 30: 465–468.
- Kaelin WG Jr. Molecular basis of the VHL hereditary cancer syndrome. *Nat Rev Cancer* 2002; 2: 673–682.
- Aiello LP, George DJ, Cahill MT et al. Rapid and durable recovery of visual function in a patient with von Hippel–Lindau syndrome after systemic therapy with vascular endothelial growth factor receptor inhibitor su5416. *Ophthalmology* 2002; 109: 1745–1751.

# Principles of cryotherapy

Dan S. Gombos

## INTRODUCTION

Cryotherapy (or cryosurgery) is the technique of precise freezing and thawing of undesirable tissue, resulting in cell death and regression. It is a highly effective technique available to the ophthalmologist for local control and eradication of various intra- and periocular tumors, and can serve as an alternative or adjunct to other methods, such as surgery or radiotherapy.

In the mid 19th century Arnott<sup>1</sup> described the use of crushed ice and salt (NaCl) to freeze advanced breast and uterine malignancies. By the beginning of the 20th century solid CO<sub>2</sub> was being used to treat various skin and gynecologic cancers.<sup>1</sup> During this period most freezing devices were crude and were only able to penetrate superficial layers of tissue, which limited the clinical application of the technique.

The commercial availability of liquid nitrogen and the introduction of the cryoprobe by Cooper and Lee in the 1960s heralded significant advancements in the field.<sup>1,2</sup> For the ophthalmologist, modification of the cryoprobe led to significant surgical advances in cataract extraction, glaucoma management, and repair of retinal tears. Subsequent pioneering work by Lincoff,<sup>3</sup> Fraunfelder,<sup>4</sup> and Jackobeic<sup>5</sup> led to application of cryotherapy in the management of various intra- and periocular tumors.

## MECHANISM OF TISSUE INJURY

Initially, the cryoprobe begins cooling the tissues by removing heat. Over time, tissue in contact with the probe freezes. Subsequently, the freezing interface progresses in an outward direction, resulting in a temperature distribution that is coldest at the point of contact with the probe. Once freezing is complete, thawing is facilitated by heat from the adjacent tissues.<sup>1,6</sup>

**Direct effects** Microscopically, the initial decline in temperature in the extracellular space forms crystals, leading to a hyperosmotic environment, extracting water from the cells and causing them to shrink. As the temperature lowers, intracellular crystals form, leading to disruption of organelles and cell membranes. This affects the ability of membrane proteins to control intracellular ionic content. During the thawing phase, as the frozen water crystals dissolve, the extracellular space becomes hypotonic. Limited only by a defective cell membrane, extracellular water enters the cell and disrupts it.<sup>7</sup> In addition, the cold temperature physically disrupts the cellular cytoskeleton and denatures proteins.<sup>1,6</sup>

**Indirect effects** Freezing temperatures are also associated with vascular stasis and cellular anoxia. Initially the cold temperatures lead to vasoconstriction, followed by vasodilation, increased vascular permeability, and edema during the thawing process. Endothelial damage leads to stagnation of blood and the formation of thrombus. The resultant hypoxia promotes tissue necrosis. Some experiments suggest that this mechanism is more important in the death of tumor cells than is direct injury from freezing.

## TECHNICAL ASPECTS

Certain technical factors, such as tissue temperature, cooling rate, the freeze-thaw cycle, and the number of repetitions influence the efficacy of cryotherapy.<sup>8,9</sup>

**Tissue temperature** is the most important factor, with cell death occurring at temperatures between  $-20^{\circ}\text{C}$  and  $-50^{\circ}\text{C}$ .<sup>10</sup>

**Cooling rate** A rapid cooling rate is more effective in causing cell death.

**Freeze-thaw cycle** Studies indicate that a slow thaw is among the most important variables contributing to cell death.

**Number of repetitions** Multiple freeze-thaw cycles further increase cell damage and death.<sup>11</sup>

## INDICATIONS

Over the past 40 years the indications for cryotherapy have expanded to a number of intra- and periocular tumors. In some instances it serves as the primary treatment, whereas in others it functions in an adjuvant setting.

**Eyelid tumors** including actinic and seborrheic keratosis, are generally amenable to cryotherapy, sometimes combined with surgical excision. Basal cell carcinoma, particularly lesions less than 1 cm in diameter, can be cured with this approach. Select cases of squamous cell and meibomian gland carcinoma of the lid have also been treated with cryotherapy as an alternative to surgery and/or radiotherapy.<sup>12-15</sup>

**Conjunctival tumors** In the adjuvant setting cryotherapy plays an important role in the management of conjunctival lesions. Conjunctival intraepithelial neoplasia and squamous cell carcinoma,<sup>16</sup> conjunc-



tival melanoma, and primary acquired melanosis with atypia<sup>5</sup> are amenable to adjuvant cryotherapy.<sup>17</sup> It has also been described in the management of large bulky lesions where complete excision was challenging, including papillomas and lymphomas.<sup>18</sup>

**Intraocular tumors** Certain intraocular tumors (particularly those anterior to the equator) are amenable to cryotherapy as the treatment of choice. Small peripheral retinal capillary hemangiomas,<sup>19</sup> Coats' disease, and retinoblastoma foci (those less than 2 mm thick) respond well to cryotherapy.<sup>20</sup>

**Orbital tumors** The cryoprobe can be used intraoperatively to assist in the excision of orbital lesions such as cavernous hemangiomas and dermoid cysts. The probe is applied directly to the lesion, allowing for traction and careful dissection from adjacent structures. The technique of freezing uveal melanoma prior to transection of the optic nerve ('no-touch' enucleation) is currently used infrequently.<sup>21,22</sup>

### TECHNIQUES OF CRYOTHERAPY

Cryotherapy can be applied in various fashions depending on the indication and location of the tumor.

**Eyelid tumors** can be treated with a liquid nitrogen spray. Following local anesthesia the area is draped and an ocular protector placed over the eye to prevent freezing of the globe or adjacent structures. A thermocoupler is inserted into the center of the lesion to monitor its temperature (recommended target temperature  $-50^{\circ}\text{C}$ ). Freezing is applied to both the lesion and a margin of adjacent normal-appearing skin. A double freeze cycle is usually administered.

**Conjunctival tumors** are generally treated with a hammerhead-shaped cryoprobe. In most instances cryotherapy is performed as an adjunct to surgical excision. Following removal of the tumor, double or triple cryotherapy is administered to the underside of the conjunctiva (adjacent to the resection) and the scleral bed.<sup>17</sup> Cryotherapy as primary therapy can also be performed with newly designed cryoprobes.<sup>23</sup>

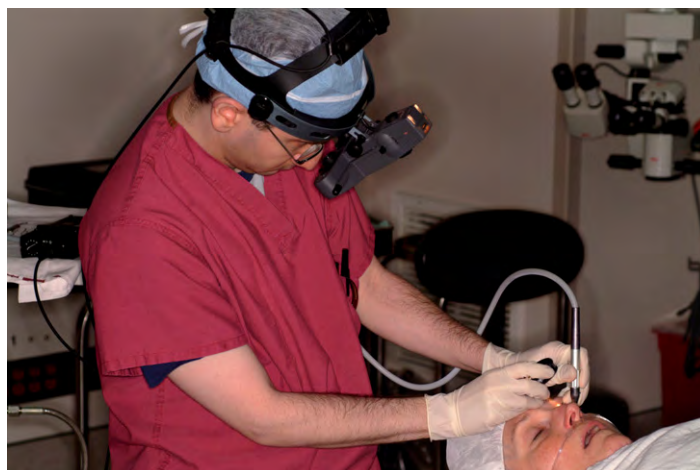**Intraocular tumors** such as retinoblastoma and retinal capillary hemangioma are generally treated using a nitrous oxide retinal cryoprobe (Fig. 6.1). Local (retrobulbar) or general anesthesia (for children) is indicated. Using indirect ophthalmoscopy and scleral indentation the lesion is isolated (Fig. 6.2). It is frozen under direct visualization such that the resulting ice ball completely encompasses the entire tumor (usually to a temperature of  $-70^{\circ}\text{C}$ ). The lesion is allowed to slowly thaw and the freeze-thaw cycle is repeated three times.<sup>20</sup> The tumor is re-examined in 3–4 weeks and may require additional therapy (Fig. 6.3). Most lesions can be treated transconjunctivally, but those significantly posterior to the equator may require a conjunctival incision.<sup>20</sup>

### COMPLICATIONS

Although cryotherapy is generally safe and effective there are numerous complications that must be considered.<sup>24</sup> In most instances transient edema and injection occur at the site of treatment. Lesions on the eyelid and close to the lash margin can develop ptosis, trichiasis, and ectropion. Hypertrophic scarring can occur, as can skin depigmentation in darker patients.

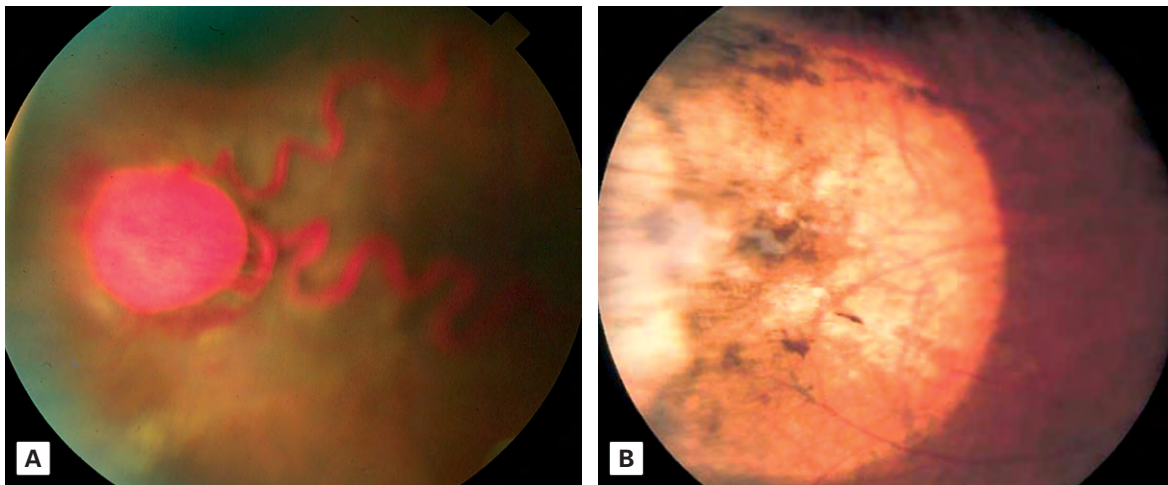


**Fig. 6.1** A retinal cryoprobe. Note the ice ball on the tip of the probe.



**Fig. 6.2** Technique for transcleral cryotherapy of an intraocular tumor under indirect ophthalmoscopic visualization.

The conjunctiva generally tolerates freezing well. However, repeated application can lead to limbal stem cell failure, dry eye, and symblepharon formation. Periocular edema and pain are not uncommon following cryotherapy of intraocular lesions. Uveitis may develop,



**Fig. 6.3** (A) Retinal capillary hemangioma treated with cryotherapy. (B) Ten months later the hemangioma appears as a gliotic nodule in an area of chorioretinal atrophy. (Reproduced with permission from Singh AD, Shields CL, Shields JA. Von Hippel–Lindau disease. *Surv Ophthalmol* 2001; 46: 117–142.

requiring the use of topical steroids. Cryotherapy can increase the risk of exudative and rhegmatogenous retinal detachment, as well as vitreous hemorrhage. Muscle paresis and changes in pupillary response have also been described.

## CONCLUSIONS

Cryotherapy is an excellent means of treating certain intra- and periocular tumors. In ophthalmic oncology this generally translates to

high cure rates and minimal ocular morbidity. Cryotherapy is effective in treating small and well-defined tumors. Good technique is critical, with a rapid freeze and slow thawing being most effective in causing the cell death. Multiple freeze–thaw cycles further increase the effectiveness of treatment. When indicated, cryotherapy can serve as an alternative to more destructive treatment modalities, such as surgical excision, chemotherapy, and radiation therapy.

## REFERENCES

- Rubinsky B. Cryosurgery. *Annu Rev Biomed Eng* 2000; 21: 157–187.
- Cooper I, Lee A. Cryostatic congelation: a system for producing a limited controlled region of cooling or freezing of biological tissue. *J Nerv Ment Dis* 1961; 1961: 259–263.
- Lincoff H, McLean J, Long R. The cryosurgical treatment of intraocular tumors. *Am J Ophthalmol* 1967; 63: 389–399.
- Fraunfelder FT, Wallis TR, Farris HE et al. The role of cryosurgery in external ocular and periocular disease. *Trans Am Acad Ophthalmol Otolaryngol* 1977; 83: 713–724.
- Jokobiec FA, Rini FJ, Fraunfelder FT et al. Cryotherapy for conjunctival primary acquired melanosis and malignant melanoma. Experience with 62 cases. *Ophthalmology* 1988; 95: 1058–1070.
- Gage AA, Baust J. Mechanisms of tissue injury in cryosurgery. *Cryobiology* 1998; 37: 171–186.
- Muldrew K, McGann LE. The osmotic rupture hypothesis of intracellular freezing injury. *Biophys J* 1994; 66: 532–541.
- Gage AA, Baust JG. Cryosurgery for tumors – a clinical overview. *Technol Cancer Res Treat* 2004; 3: 187–199.
- Baust JG, Gage AA. Progress towards optimization of cryosurgery. *Technol Cancer Res Treat* 2004; 3: 95–101.
- Gage AA. What temperature is lethal for cells? *J Dermatol Surg Oncol* 1979; 5: 459–460.
- Gill W, Fraser J, Carter D. Repeated freeze–thaw cycles in cryosurgery. *Nature* 1968; 219: 410–413.
- Bullock JD, Beard C, Sullivan JH. Cryotherapy of basal cell carcinoma in oculoplastic surgery. *Am J Ophthalmol* 1976; 82: 841–847.
- Lubritz RR. Cryosurgery for benign and malignant skin lesions: treatment with a new instrument. *South Med J* 1976; 69: 1401–1405.
- Fraunfelder FT, Zacarian SA, Wingfield DL et al. Results of cryotherapy for eyelid malignancies. *Am J Ophthalmol* 1984; 97: 184–188.
- Kuflik EG. Cryosurgery updated. *J Am Acad Dermatol* 1994; 31: 925–944.
- Divine RD, Anderson RL. Nitrous oxide cryotherapy for intraepithelial epithelioma of the conjunctiva. *Arch Ophthalmol* 1983; 101: 782–786.
- Shields JA, Shields CL, De Potter P. Surgical approach to conjunctival tumors. The 1994 Lynn B. McMahan Lecture. *Arch Ophthalmol* 1997; 115: 808–815.
- Eichler MD, Fraunfelder FT. Cryotherapy for conjunctival lymphoid tumors. *Am J Ophthalmol* 1994; 118: 463–467.
- Singh AD, Nouri M, Shields CL et al. Treatment of retinal capillary hemangioma. *Ophthalmology* 2002; 109: 1799–1806.
- Shields JA, Parsons H, Shields CL et al. The role of cryotherapy in the management of retinoblastoma. *Am J Ophthalmol* 1989; 108: 260–264.
- Fraunfelder FT, Boozman FW, Wilson RS et al. No-touch technique for intraocular malignant tumors. *Arch Ophthalmol* 1977; 95: 1616–1620.
- Wilson RS, Fraunfelder FT. ‘No-touch’ cryosurgical enucleation: a minimal trauma technique for eyes harboring intraocular malignancy. *Ophthalmology* 1978; 85: 1170–1175.
- Finger PT. ‘Finger-tip’ cryotherapy probes: treatment of squamous and melanocytic conjunctival neoplasia. *Br J Ophthalmol* 2005; 89: 942–945.
- Wood JR, Anderson RL. Complications of cryosurgery. *Arch Ophthalmol* 1981; 99: 460–463.



# Principles of laser therapy

Stefan Sacu and Ursula Schmidt-Erfurth

## INTRODUCTION

The theoretical principles behind the laser were developed as early as 1917, when Einstein laid the groundwork for stimulated emission in his treatise *On the Quantum Theory of Radiation*. In 1949, Meyer-Schwickerath created chorioretinal burns around retinal holes using the sun as the light source. A variety of different light sources were investigated in the prototype instruments before Carl Zeiss developed the first commercial model in 1956 using a Xenon lamp.<sup>1</sup>

In 1960 Maiman and Gould invented the ruby laser, considered to be the first successful laser. This was followed by the argon (L'Esperance, Zweng, and Little, 1968–1969) and krypton (Tek, 1978) lasers.

Further innovations, such as the Nd:YAG (neodymium:yttrium–aluminum–garnet) laser (Frankhauser and Aron Rosa, 1981), the excimer laser (Trokel, 1983), and the dye laser (L'Esperance, 1986) followed.

Clinical trials of laser photocoagulation were first initiated by Campbell, Noyori, and Zweng. More recently, photodynamic therapy for the treatment of intraocular tumours (Murphree, 1987) and of age-related macular degeneration (Schmidt-Erfurth and Miller, 1999) have vastly expanded the range of clinical laser applications.<sup>2</sup>

## BASIC CONSIDERATIONS

**Laser properties** LASER is an acronym for Light Amplification by the Stimulated Emission of Radiation. A laser beam is a monochromatic (single wavelength), coherent, and parallel beam of light, usually of high energy. The range of laser radiation extends from the ultraviolet through the visible to the infrared regions of the optical spectrum (Fig. 7.1).<sup>3</sup>

**Laser output** The output of a laser can be continuous-wave or pulsed. Retinal photocoagulation is usually performed with a continuous-wave laser with output generally delivered over an interval of 0.1–1.0 s.

**Tissue effects** There are two forms of interaction between light and ocular tissue: absorption and ionization. Ionization is used primarily to incise the tissues of the eye, for example in Yag capsulotomy. Absorption interaction is used in laser photocoagulation, thermotherapy, and photodynamic therapy.

**Treatment variables** The optical clarity of ocular tissues, the degree of absorption by ocular pigments, specific wavelengths used, spot size, power applied, and the exposure time are some of the important variables that influence the treatment effects.

**Clarity of the media** It is important to take the opacities of the media into consideration, as scattering and absorption of energy may occur while the laser travels toward the target tissue.<sup>4</sup> Longer wavelengths have less scattering and are more efficient in delivering energy to the retina.

**Tissue absorption** spectra of the three ocular pigments (melanin, hemoglobin, and xanthophyll) vary, and this can be used to achieve tissue selectivity of laser effects. Melanin has a maximum absorption between 400 and 600 nm (blue, green, yellow, and red), with greater absorption for shorter than longer wavelengths (Fig. 7.2).<sup>5</sup> Hemoglobin has a narrower range of maximum absorption that includes blue, green, and yellow wavelengths but excludes red. Xanthophyll has maximal absorption limited only to the blue wavelengths.

**Spot size** The laser burn is round and proportional to the square of the radius. Many more small spots are required to ablate the same area of retina as a few large burns. This is an issue in panretinal photocoagulation. Reducing a spot size requires a decrease in power level, whereas increasing a spot size requires an increase in power.

**Magnification factor** The actual spot size on the retina and hence laser irradiance is influenced by the magnification induced by the type of contact lens used (Table 7.1).<sup>6,7</sup> With the area centralis of the three-mirror Goldmann lens, the spot size setting on the slit lamp is about the same size as the actual burn on the retina.

## TYPES OF LASER

**Ruby** A solid-state laser based on a pulsed ruby laser was the first commercially available ophthalmic laser photocoagulator and operated at a constant coagulation or exposure time of about 500  $\mu$ s. The drawback of the ruby laser was its pulsed and uneven output.

**Argon** laser was the first laser system to enjoy broad acceptance. It is a continuous-wave laser and emits two wavelengths: 514 nm (green) and 488 nm (blue). It is ideally suited for retinal use, as there is excellent absorption at the level of the retinal pigment epithelium and the hemoglobin. Photochemical damage to the macula induced by blue light (due to xanthophyll) can be reduced by incorporating a green filter.

**Krypton** laser sources emitting 647 nm as a continuous wave overcome the absorption difficulties of the argon laser. Krypton is poorly

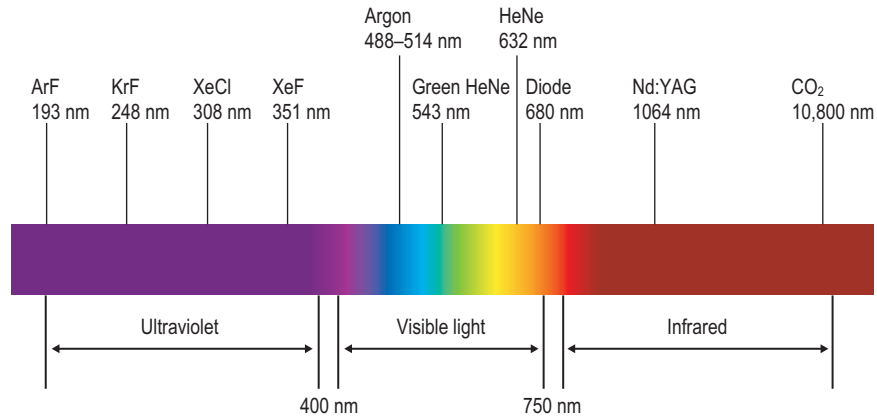


Fig. 7.1 Electromagnetic spectrum of lasers used in ophthalmology.

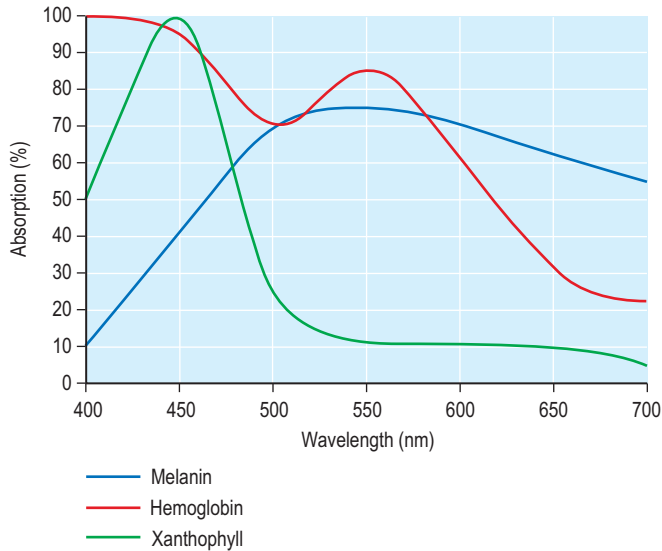


Fig. 7.2 Absorption of visible wavelengths by three ocular pigments (melanin, hemoglobin, and xanthophyll). Modified with permission from Peyman GA, Raichand M, Zeimer RC. Ocular effects of various laser wavelengths. *Surv Ophthalmol* 1984; 28: 391-404.

Table 7.1 Multiplication factors for retinal spot size in an emmetropic eye.	
Type of lens	Multiplication factor
60-Diopter	0.92
Area Centralis	1.01
Three-mirror Goldmann	1.08
Transequatorial	1.43
Quadrasperic	1.92

absorbed by hemoglobin because it is a red source, and so accidental coagulation of blood vessels can be avoided. The disadvantage of the argon and krypton lasers are their low efficiency of laser production.<sup>8</sup>

**Dye** lasers have the same disadvantages as argon or krypton lasers. Additionally, the dye (rhodamine) is carcinogenic and requires special handling. Therefore, dye lasers are infrequently used today.<sup>9</sup>

**Diode** lasers are compact and portable owing to their small size. Despite their low input power, diode lasers may represent a significant hazard to vision, especially when the output is collimated, invisible, and of higher power (>3–5 mW).<sup>6,10,11</sup>

**Holmium** laser has a CO<sub>2</sub>-laser like action. The holmium laser crystal is similar to the Nd:Yag laser in that the holmium atoms are distributed throughout a Yag host.

**Excimer** laser is a gas laser that generates a powerful ultraviolet beam. This technique can be used to ablate the cornea to any depth. The intensity is graded from the center to the periphery of the circular field so as to control the depth of ablation.

### TECHNIQUES OF LASER THERAPY

**Photocoagulation** is the thermal denaturation of tissues using a high-intensity laser of the wavelength range that is intensively absorbed by hemoglobin or other ocular pigments.

**Indications** Laser photocoagulation is used for a variety of chorio-retinal diseases, such as diabetic retinopathy, retinal tears or holes, age-related macular degeneration (ARM), and chorioretinal tumors such as retinal capillary hemangioma, choroidal hemangioma, and retinoblastoma.

**Complications** With proper attention to detail, complications are infrequent. During laser treatment, focal breaks in Bruch’s membrane and retinal hemorrhage may occur. Following photocoagulation, exacerbation of diabetic macular oedema, retinal pigment epithelial metaplasia, subretinal fibrosis, and absolute scotomas are seen infrequently. Patients may develop choroidal effusion if a large number of burns are applied during a single treatment session. Laser photocoagulation applied over extensive intraretinal hemorrhage can cause damage to the nerve fiber layer.<sup>2,6,11,12</sup>

**Transpupillary thermotherapy** Similar to laser photocoagulation, transpupillary thermotherapy (TTT) is based on the concept of tissue hyperthermia.<sup>13</sup> However, TTT delivers less thermal energy than traditional lasers and is based on the absorption of near-infrared light (810 nm) by the melanin-filled pigment epithelium. In contrast to laser photocoagulation (argon and krypton lasers), TTT uses a lower irradiance with a prolonged exposure and is designed to gently heat

the choroidal lesion (sub-photocoagulation level), thereby limiting damage to the overlying photoreceptors.<sup>14</sup> Variations in blood flow and chromophore concentrations can strongly influence the treatment effect of TTT. The most common use is the treatment of ARMD and small choroidal melanocytic lesions, including small choroidal melanoma.<sup>13,14</sup> Transpupillary thermotherapy is covered in detail elsewhere (see Chapter 41).

**Photodynamic therapy (PDT)** In PDT, light and light-absorbing agents such as verteporfin are combined in an oxygen-rich environment. The chemical reactions follow three main pathways, which start from the common metastable triplet state of the photosensitizer. During the first pathway, an exchange of hydrogen atoms between the photosensitizer and the substrate molecule leads to the formation of peroxide radicals and oxidized substrate molecules. The second pathway includes an electron transfer between photosensitizer and substrate molecules, leading to the formation of radical ions (superoxide radical anion, H<sub>2</sub>O<sub>2</sub>, and hydroxyl radical). Processes 2 and 3 together are called type I reactions. The third pathway is an energy transfer, called type II reaction, that leads to bleaching of the photosensitizer itself ('cage' reaction) or oxidization of the adjacent biomolecular target.<sup>15</sup>

**Practical considerations** PDT is a two-step process. During the first step the patient receives a verteporfin infusion over 10 minutes through a cubital vein. Verteporfin is a special dye with a light absorption peak at 692 nm. It is prepared in a 30-mL glucose solution at a dose of 6 mg/m<sup>2</sup> body surface area.

The second step implies the exposure of the lesion to laser light, i.e. photoradiation. Fifteen minutes after the start of the infusion, the fundus lesion receives a diode laser application via a slit-lamp delivery system and a handheld contact lens. A light dose of 50 J/cm<sup>2</sup> is delivered at an intensity of 600 mW/cm<sup>2</sup> for 83 seconds as one spot covering the lesion in its greatest linear diameter plus a safety zone of 500 μm. The currently recommended treatment protocol has been proved in the TAP and VIP trials to be safe and effective.<sup>16</sup>

**Indications** In ophthalmology, PDT is used in the treatment of choroidal neovascularization due to ARMD and secondary choroidal neovascularization in high myopia, following presumed ocular histoplasmosis syndrome (POHS), central serous retinopathy, and other conditions leading to ingrowth of choroidal vessels following an alteration of Bruch's membrane,<sup>15</sup> as well as retinal capillary hemangioma,<sup>17</sup> and circumscribed choroidal hemangioma.<sup>18</sup>

**Complications** One of the most important problems with current PDT regimens is the high rate of recurrence of choroidal neovascularization in the setting of AMD. Recurrence is triggered by a transient occlusion of the adjacent choriocapillary layer, leading to an increased expression of vascular endothelial growth factor (VEGF).<sup>19</sup> In occult lesions with retinal pigment epithelium (RPE) detachment, a severe loss in vision may occur in 2–4% of treated eyes. RPE tears were described early after PDT owing to enhanced exudation, or later during follow-up as a result of a reactive fibrosis of the membrane. Excessive and multiple additive treatments can cause atrophy of the choriocapillaris and retinal pigment epithelium.<sup>20</sup>

## SUMMARY

There are several diagnostic and therapeutic applications of lasers in ophthalmology. Laser radiation is a parallel, high-energy, coherent, and monochromatic beam of light. The tissue effects of laser use can be due to either absorption or ionization. The ionization is used primarily to incise tissues of the eye, e.g. in Yag capsulotomy. Absorption interaction is used in laser photocoagulation, thermotherapy, and photodynamic therapy. Laser photocoagulation is the thermal denaturation of tissues by using laser wavelengths that are absorbed by ocular pigments. In contrast to laser photocoagulation, thermotherapy uses a lower irradiance with a prolonged exposure, and is designed to gently heat the choroidal lesion. Photodynamic therapy offers selective tissue laser effects by using light-absorbing agents (such as verteporfin).

## REFERENCES

- L'Esperance FJ. Ophthalmic lasers. St Louis: CV Mosby, 1983; 340–350.
- Voke J. Lasers and their use in ophthalmology – Part 3. www.optometry.com, 2005.
- Kohnen T. Laser in eye surgery. www.krager.com/gazette, 2005.
- Pomerantzeff O, Kaneko H, Donovan R et al. Effect of the ocular media on the main wavelengths of argon laser emission. Invest Ophthalmol Vis Sci 1976; 15: 70–77.
- Peyman GA, Raichand M, Zeimer RC. Ocular effects of various laser wavelengths. Surv Ophthalmol 1984; 28: 391–404.
- Fankhauser F, Kwasniewska S, eds. Laser in ophthalmology. Basic, diagnostic and surgical aspects. The Hague: Kugler Publications, 2003.
- Dewey D. Corneal and retinal energy density with various laser beam delivery systems and contact lenses. SPIE 1991; 1423: 105–116.
- Marshall J, Bird A. A comparative histopathologic study of argon and krypton laser irradiation of the human retina. Br J Ophthalmol 1979; 63: 657–668.
- L'Esperance F Jr. Clinical photocoagulation with the organic dye laser. A preliminary communication. Arch Ophthalmol 1985; 103: 1312–1316.
- Noyori K, Shimizu K, Trokel S. Ophthalmic laser therapy. Tokyo: Igaku-Shoin, 1992.
- Folk JC, Pulido JS. Laser photocoagulation of the retina and choroid. San Francisco: American Academy of Ophthalmology, 1997.
- Blanco G, Soparkar CN, Jordan DR et al. The ocular complications of periocular laser surgery. Curr Opin Ophthalmol 1999; 10: 264–269.
- Oosterhuis JA, Journee-de Korver HG, Kakebeeke-Kemme HM, Bleeker JC. Transpupillary thermotherapy in choroidal melanomas. Arch Ophthalmol 1995; 113: 315–321.
- Reichel E, Berrocal AM, Ip M et al. Transpupillary thermotherapy of occult subfoveal choroidal neovascularization in patients with age-related macular degeneration. Ophthalmology 1999; 106: 1908–1914.
- Schmidt-Erfurth U, Michels S, Barbazetto I et al. Photodynamic effects on choroidal neovascularization and physiological choroid. Invest Ophthalmol Vis Sci 2002; 43: 830–841.
- Treatment of Age-Related Macular degeneration with Photodynamic Therapy (TAP) Study Group. Photodynamic therapy of subfoveal choroidal neovascularization in age-related macular degeneration with verteporfin: two-year results of 2 randomized clinical trials – TAP report 2. Arch Ophthalmol 2001; 119: 198–207.
- Schmidt-Erfurth UM, Kusserow C, Barbazetto IA, Laqua H. Benefits and complications of photodynamic therapy of papillary capillary hemangiomas. Ophthalmology 2002; 109: 1256–1266.
- Michels S, Michels R, Beckendorf A et al. Photodynamic therapy for choroidal hemangioma. Long-term results. Ophthalmologie 2004; 101: 569–575.
- Schmidt-Erfurth U, Schlötzer-Schrehard U, Cursiefen C et al. Influence of photodynamic therapy on expression of vascular endothelial growth factor (VEGF), VEGF receptor 3 and pigment epithelium-derived factor. Invest Ophthalmol Vis Sci 2003; 44: 4473–4480.
- Schmidt-Erfurth U, Michels S. Changes in confocal indocyanine green angiography through two years after photodynamic therapy with verteporfin. Ophthalmology 2003; 110: 1306–1314.

# Principles of radiation therapy

Carryn Anderson, Peter Fleming, Allan Wilkinson and Arun D. Singh

## INTRODUCTION

Radioactivity was first described by Henri Becquerel and Pierre and Marie Curie in the late 1890s. Wilhelm Roentgen discovered X-rays in 1895, and subsequent physics and biology research revealed the therapeutic properties of radiation. X-rays were first used to treat cancer in 1897. Soon after, the concept of brachytherapy was developed when radium was implanted into tumors for therapeutic effect. In the 1920s low-voltage X-ray machines were built for the external treatment of superficial tumors. The first cyclotron (used to accelerate heavy particles such as protons, neutrons, and deuterons) was invented in 1932 in California. In 1951, the first clinical cobalt-60 unit was built in London, Ontario, Canada. It created a  $\gamma$ -ray photon beam from the emissions of a cobalt-60 source as it went through nuclear decay. External beam radiation therapy was further refined in 1953 with the development of linear accelerators (linacs) that could produce megavoltage electron and X-ray photon beams using pulsed microwaves and an electron gun.

With improvements in radiographic imaging techniques, such as CT and MRI, conformal radiation therapy has been developed. Three-dimensional conformal radiation therapy (3D-CRT), intensity-modulated radiation therapy (IMRT), stereotactic radiosurgery, and charged particle therapy focus therapeutic dose while minimizing damage to surrounding normal structures. In this chapter we will review the basic principles of radiation therapy and its application as the definitive, adjuvant, salvage, and palliative management of a variety of ophthalmic cancers.

## BASIC PRINCIPLES

The unique characteristics of an individual element are determined by its atomic structure – the number and configuration of electrons, protons, and neutrons. Radiation therapy takes advantage of the energy created by interaction of electrons, protons, and neutrons with each other. This energy can break chemical bonds and create ions such as oxygen radicals.

**Dual nature of radiation** Radiation can be in the form of electromagnetic waves, particles, or both.

**Electromagnetic radiation** or photon radiation has a broad spectrum of wavelengths, ranging from  $10^7$  m (radio waves) to  $10^{-13}$  m (ultrahigh-energy X-rays) (Fig. 8.1). Energy is propagated at the speed of light ( $c$ ), with the frequency ( $\nu$ ) and wavelength ( $\lambda$ ) being inversely related:  $c = \nu\lambda$ . Linear accelerators produce photon beams with wavelengths in the range of  $10^{-11}$ – $10^{-13}$  m.

**Particle radiation** can be neutral (neutrons) or charged (protons, electrons). As the particles travel through space they interact with matter and produce varying degrees of energy transfer to the medium. Linear accelerators and cyclotrons are used to produce this type of radiation.

**Radioactive decay** Radioactive elements are in an unstable, high-energy state and emit radiation to return to a stable, low-energy state. This process of returning to stability is called decay. Three different types of radiation can be emitted from the nucleus during this process:  $\alpha$  particles with a positive electrical charge (helium nucleus),  $\beta$  particles with a negative charge (electrons), and  $\gamma$  rays with no electrical charge. Radioactive decay is the process utilized in cobalt-60 machines, gamma-knife radiotherapy, and brachytherapy.

**Ionizing and non-ionizing radiation** Radiation has both ionizing and non-ionizing effects on tissues. Ions are created when an atomic particle or photon hits another atom, resulting in loss of an electron, proton, or neutron. Ions interact with DNA, resulting in single-strand breaks, double-strand breaks, or base-pair alterations, impairing a cell's ability to regenerate and duplicate. Non-ionizing effects cause excitation of the outermost electrons of an atom. This is of less clinical significance.

## TELE THERAPY SOURCES

Teletherapy is the process of delivering radiation from a remote distance. In modern clinical practice a cobalt-60 unit, linear accelerator, or cyclotron is used to generate and deliver external-beam photon therapy and particle radiotherapy.

**Cobalt-60 unit** holds a radioactive cobalt source that emits  $\gamma$  radiation as it decays to nickel-60. The average energy of the  $\gamma$  photon beam is 1.25 million electron volts (MeV), with the maximum dose being delivered to a depth of 0.5–1 cm.

**Linear accelerator** uses high-frequency electromagnetic waves to accelerate electrons to high energies through a linear vacuum tube. The monoenergetic electron beam can be used to treat superficial tumors. Typical energies used range from 6 to 18 MeV, with 80% of the maximum dose delivered to a depth of 2–6 cm, and a relatively steep dose drop-off beyond this (Fig. 8.2).

When deeper tumors need to be treated, or the skin needs to be spared, the linear accelerator electron beam is directed at a target






Fig. 8.1 The electromagnetic spectrum. Therapeutic X-rays and  $\gamma$ -rays are in the high-frequency high-energy range. Ranges are approximate.

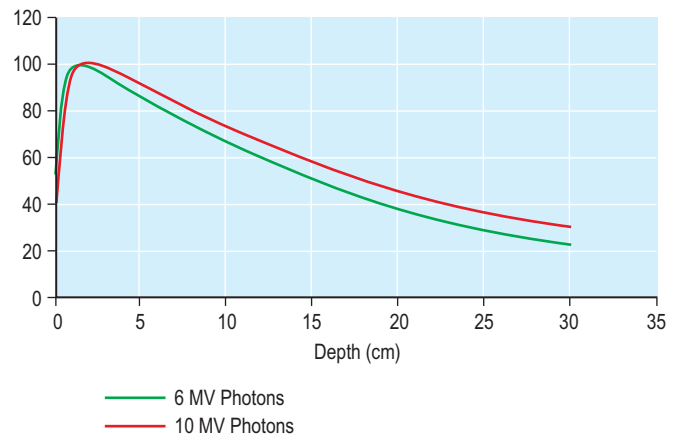


Fig. 8.3 Depth dose curves for commonly used photon beams. The maximum dose ( $D_{max}$ ) for 6 MV photons is deposited at 1.5 cm and the  $D_{max}$  for 10 MV photons is 2.0 cm.

Table 8.1 Relative biological effectiveness (RBE) values of commonly used radiations

Radiation	RBE
Standard (250 kVp X-ray photons)	1.0
Linac (6–25 MeV electrons)	~0.8
Linac (6–25 MV X-ray photons)	~1.0
Cobalt-60 (Gamma-ray photons)	0.8–0.9
Protons	~1.1
Neutrons	1.5–3.0

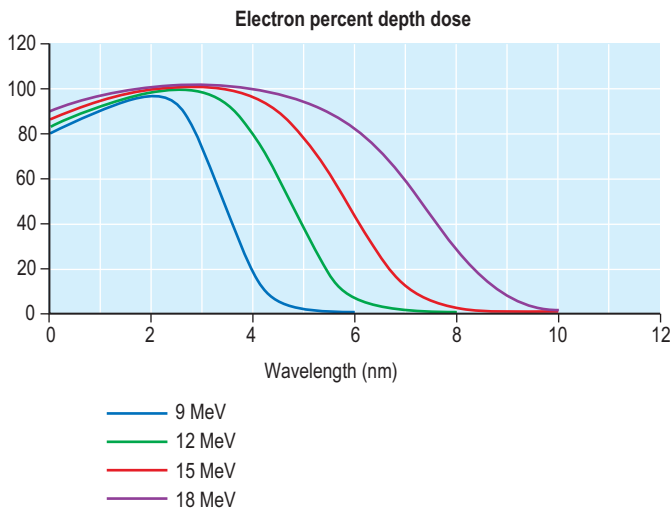


Fig. 8.2 Percent depth dose curves for commonly used electron beams. Divide the beam energy by 3 to estimate the depth in tissue of 80% of the maximum dose. Divide the beam energy by 2 to estimate the range of penetration.

(usually tungsten). The resultant atomic interactions produce a range of high-energy X-rays, also called photons. Photons are characteristically more penetrating than electrons. As an example, a 6 MeV electron beam creates a photon beam with a maximum energy of 6 megavolts (MV). Typical energies of photon beams range from 6 to 18 MV, with the depth of maximum dose ranging from 1.5 to 3.5 cm, and a more gradual dose drop-off beyond (Fig. 8.3).

**Cyclotron** is a heavy particle accelerator capable of producing neutron and proton beams. Neutrons and protons have a higher linear energy transfer than photons, which means they cause more damage

as they pass through tissue. They cause direct damage to the nucleus of an atom, making them potentially more effective at treating hypoxic tumor cells because there is no dependence on the production of oxygen radicals.

Proton beams have a unique dose distribution characteristic called the Bragg peak. There is a steep peak of maximal dose deposit and a sharp distal drop-off. This Bragg peak can be directed accurately and precisely on to the tumor.<sup>1</sup> The sharp distal drop-off and the minimal scatter from the proton beams translates into less dose to surrounding normal tissues. Proton beam radiotherapy is used for treatment of uveal melanoma and retinoblastoma.<sup>2,3</sup> Proton beam radiotherapy of uveal melanoma is discussed in detail elsewhere (Chapter 43).

**RADIATION PARAMETERS**

**Radiation dose** Radiation absorbed dose is defined in grays (Gy), which represents 1 J of energy absorbed per kg mass. Centigray (cGy) is also commonly used and this is 1/100th of a gray. The previous convention was to define dose in 100 ergs absorbed per gram, or rad (1 centigray = 1 rad).

**Relative biological effectiveness (RBE)** is a measure of the efficiency of a specific radiation in producing a specific biologic response. This can be expressed in the equation  $RBE = D_s/D_r$ , where  $D_s$  and  $D_r$  are the doses of standard radiation (250 kVp X-rays) and a test radiation (r) needed to produce an equivalent biologic response (Table 8.1). Protons and neutrons have greater biological effectiveness than photons and electrons.

**Cobalt gray equivalents** The amount of absorbed dose from neutron and proton beams is higher than with X-ray or  $\gamma$ -ray beams. In order to compare to standard doses, the term cobalt gray equivalents (CGE) was developed: CGE = dose in proton or neutron gray multiplied by the corresponding RBE value.

## TREATMENT PARAMETERS

**Target volume** Several target tissue volumes are considered when determining the prescription dose. Gross target volume (GTV) is the visible tumor extension. Clinical target volume (CTV) is the GTV plus margin to cover microscopic tumor extension. Planning target volume (PTV), the volume ultimately treated, is CTV plus a safety margin accounting for set-up variations and organ motion. The treatment margin beyond the GTV typically ranges from 0.5 to 2 cm, depending on the accuracy of the treatment machine, the immobilization device, and the tumor type.

**Total dose** given depends on tumor responsiveness, gross versus microscopic disease, the purpose of the radiation (curative or palliative), and limitations of surrounding normal tissues.

**Fractionation** In general, the total dose is divided into fractions delivered over several weeks. Fractionation is used to minimize late radiation side effects. The larger fraction size (>200 cGy) is associated with a greater tendency for late side effects, such as severe dry eye, cataract, and optic neuropathy. On the other hand, reducing the fraction size diminishes the therapeutic effects of radiation (tumor kill). Conventional fractionation uses one treatment per day, at a dose of 180–200 cGy/fraction for five days a week. Recent data suggest that hyperfractionation (110–120 cGy/fraction twice daily) may reduce the risk of radiation retinopathy in patients treated for head and neck cancer.<sup>4</sup> Palliative radiation therapy often utilizes larger fraction sizes given over a shorter period of time, with the assumption that the natural history of the disease will preclude the development of late radiation effects. Some common dose/fractionation schedules are given in Table 8.2.

**Tissue tolerance** In treating ophthalmic tumors with external beam radiation, the exposure of several critical structures, such as the lens, optic nerve, opposite orbit, pituitary and brain, to radiation must be taken into account. Normal tissue tolerances to external beam radiation (180–200 cGy/fraction) and the total doses that result in 5% and

50% complication rates 5 years after treatment are listed in Table 8.3.<sup>5</sup> The ophthalmic complications of radiation therapy are discussed in detail elsewhere (see Chapter 9).

## TELETERAPY TECHNIQUES

**External beam therapy** When a patient is scheduled for external beam therapy, the first appointment is for simulation. During simulation, the patient is placed in the treatment position, including immobilization devices such as a mask. An MRI scanner, CT scanner or fluoroscope is used to take images of the patient's anatomy in the treatment position. The tumor area and the surrounding normal structures are identified and contoured on the simulation images. The beam arrangement may be set at the time of simulation, or a dosimetrist may later create several plans to determine the best beam arrangement (Fig. 8.4). Several techniques of beam design and arrangements – so-called 'lens-sparing radiation therapy' – have been developed in order to minimize exposure of the lens to radiation and avoid radiation-induced cataract (Table 8.4).<sup>1,6–12</sup>

**Conformal radiation therapy** Standard or conventional radiation therapy uses bony landmarks on fluoroscopy or external landmarks on physical examination to determine gross anatomical boundaries for field shapes and sizes. Using simulation images from MRI and CT scanners, a radiation oncologist can precisely identify tumor and critical structures, calculate the dose they will receive, and design beam arrangements that will minimize long-term damage. This is termed conformal therapy.

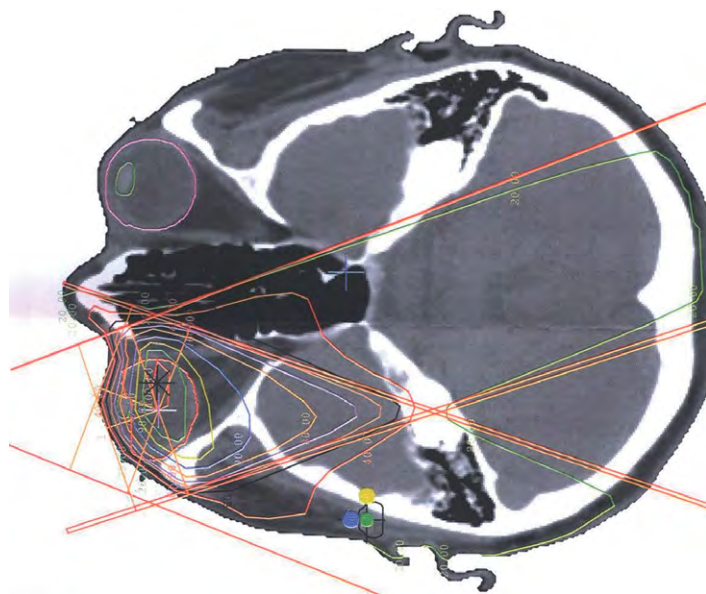
**Table 8.3 Normal tissue tolerance dose to external beam radiation (cGy)<sup>5</sup>**

Organ	Complication rate at 5 years		Clinical endpoint
	5%	50%	
Brain	6000	7500	Necrosis, infarction
Optic nerve	5000	6500	Visual acuity <20/200
Optic chiasm	5000	6500	Visual acuity <20/200
Lens	1000	1800	Symptomatic cataract
Retina	4500	6500	Visual acuity <20/200

**Table 8.2 External beam radiation therapy dose/fractionation schedules for common ophthalmic cancers**

Disease	Total dose	Dose per fraction	Number of fractions
Uveal melanoma	60–70 CGE (protons)	14–15 CGE	4–5
Retinoblastoma	40–50 Gy	2–2.5 Gy	20–25
Uveal/orbital metastasis	40 Gy	2 Gy	20
Orbital lymphoma	30 Gy	2 Gy	15
Basal or squamous cell carcinoma of the eyelid	35–42.5 Gy	4.25–7 Gy	5–10
Palliation	30 Gy	3 Gy	10

CGE, cobalt gray equivalent.



**Fig. 8.4** An example of external beam radiation planning with 6 MV photons to treat choroidal metastasis of the right eye. A right anterior oblique beam and a left anterior oblique beam are used.

**Table 8.4** Lens-sparing techniques for external beam radiation therapy

Technique	Year	Author
Direct lateral field posterior to the lens	1977	Chu <sup>6</sup>
	1982	Brady <sup>8</sup>
	1994	Nylen <sup>10</sup>
Oblique lateral field with lens shielding	1977	Chu <sup>6</sup>
	1977	Maor <sup>7</sup>
Anterior field with lens block	1977	Chu <sup>6</sup>
Right angled wedged fields	1982	Brady <sup>8</sup>
Direct lateral field with D-shape block	1983	Schipper <sup>9</sup>
Proton beam therapy	1983	Goitein <sup>1</sup>
Oblique electron fields with lens block	1997	Steenbakkers <sup>11</sup>
Modified Schipper technique	2003	Bajcsay <sup>12</sup>

**Three-dimensional conformal therapy** or 3D-CRT, is the technique of using CT or MRI simulation images to create a three-dimensional target. Various beam arrangements are entered into the planning computer and altered until an acceptable dose distribution is reached for both the tumor and normal structures. This process of first entering the beam arrangements and then looking at the dosimetric outcomes is termed forward planning.

**Intensity-modulated radiation therapy** In intensity-modulated radiation therapy a process of inverse planning is often used, which means that the dose criteria are set before beam arrangements are designed. The computer generates a plan that best fits the specified criteria. During treatment, a multileaf collimator moves dynamically to create hot and cold spots within the volume of treated tissue. The intention is to place the majority of the hot spots within the tumor volume rather than the surrounding normal tissue.

**Stereotactic radiosurgery** uses highly focused, precisely aimed radiation (usually within 0.5 mm of the specified isocenter) to treat small tumors ( $\leq 4$  cm) at very high doses per fraction. A stereotactic frame fixed to the patient's skull is used for precise localization and positioning. Planning CT and MRI images are taken with the frame in place, so that accurate coordinates can be established for the target. Two forms of stereotactic radiosurgery exist: linac-based and gamma-knife.

**Linac-based stereotactic radiosurgery** utilizes specialized cones to target the tumor during multi-arc therapy.<sup>13</sup> Stereotactic radiosurgery for uveal melanoma is discussed in detail elsewhere (see Chapter 44).

**Gamma-knife radiosurgery** With gamma-knife therapy,  $\gamma$ -ray beams from 201 cobalt-60 sources are collimated to focus on a single point. The patient's head is positioned to place the tumor at that isocentric point.<sup>14</sup> Gamma-knife radiosurgery for uveal melanoma is discussed in detail elsewhere (see Chapter 44).

## BRACHYTHERAPY

Brachytherapy is the process of placing a radioactive source next to or within a tumor. The dose characteristics of the isotopes used in brachytherapy are such that a very high dose of radiation is given within millimeters of the source and there is a steep dose drop-off outside that range, thus protecting surrounding normal structures. Isotopes that have been employed include cobalt-60, iridium-192, ruthenium-106, gold-198, palladium-103, and iodine-125.<sup>15</sup> Brachytherapy is used for the treatment of intraocular tumors such as choroidal metastases,<sup>16</sup> uveal melanoma,<sup>15,17</sup> and retinoblastoma.<sup>18</sup> Brachytherapy for uveal melanoma is discussed in detail elsewhere (see Chapter 44).

## SUMMARY

Radiation therapy takes advantage of the energy created when electrons, protons, and neutrons interact with each other. Radiation can be in the form of particles and electromagnetic waves. Linear accelerators and cyclotrons are used to produce radiation. In addition, radioactive decay of an isotope can generate radiation. Radioactive decay is the process utilized in cobalt-60 machines, gamma-knife radiotherapy and brachytherapy. Radiation interacts with DNA, resulting in single-strand breaks, double-strand breaks, or base-pair alterations, impairing a cell's ability to regenerate and duplicate. Protons and neutrons have greater biological effectiveness than photons and electrons. Several treatment parameters, such as target volume, total dose, and fractionation, influence tissue effects. The larger fraction size ( $>200$  cGy) is associated with a greater tendency for late side effects, such as severe dry eye, cataract, and optic neuropathy. Normal tissues vary greatly in their tolerance to external beam radiation. Teletherapy techniques include conventional external beam therapy, three-dimensional conformal therapy, intensity-modulated radiation therapy, stereotactic radiosurgery, and gamma-knife radiosurgery. Brachytherapy is the process of placing a radioactive source next to or within a tumor. Ruthenium-106, palladium-103, and iodine-125 are commonly used isotopes for the treatment of ophthalmic tumors. With continued improvements in radiographic imaging techniques and better understanding of radiation tissue effects at the molecular level, it will be possible to focus therapeutic dose precisely while minimizing damage to surrounding normal structures.

## REFERENCES

- Goitein M, Miller T. Planning proton therapy of the eye. *Med Phys* 1983; 10: 275–283.
- Gragoudas ES, Marie Lane A. Uveal melanoma: proton beam irradiation. *Ophthalmol Clin North Am* 2005; 18: 111–118, ix.
- Krengli M, Hug EB, Adams JA et al. Proton radiation therapy for retinoblastoma: comparison of various intraocular tumor locations and beam arrangements. *Int J Radiat Oncol Biol Phys* 2005; 61: 583–593.
- Monroe AT, Bhandare N, Morris CG, Mendenhall WM. Preventing radiation retinopathy with hyperfractionation. *Int J Radiat Oncol Biol Phys* 2005; 61: 856–864.
- Emami B, Lyman J, Brown A et al. Tolerance of normal tissue to therapeutic irradiation. *Int J Radiat Oncol Biol Phys* 1991; 21: 109–122.
- Chu FC, Huh SH, Nisce LZ, Simpson LD. Radiation therapy of choroid metastasis from breast cancer. *Int J Radiat Oncol Biol Phys* 1977; 2: 273–279.
- Maor M, Chan RC, Young SE. Radiotherapy of choroidal metastases: breast cancer as primary site. *Cancer* 1977; 40: 2081–2086.
- Brady LW, Shields JA, Augsburger JJ, Day JL. Malignant intraocular tumors. *Cancer* 1982; 49: 578–585.
- Schipper J. An accurate and simple method for megavoltage radiation therapy of retinoblastoma. *Radiother Oncol* 1983; 1: 31–41.
- Nylen U, Kock E, Lax I et al. Standardized precision radiotherapy in choroidal metastases. *Acta Oncol* 1994; 33: 65–68.
- Steenbakkens RJ, Altschuler MD, D'Angio GJ et al. Optimized lens-sparing treatment of retinoblastoma with electron beams. *Int J Radiat Oncol Biol Phys* 1997; 39: 589–594.
- Bajcsay A, Kontra G, Recsan Z et al. Lens-sparing external beam radiotherapy of intraocular metastases: our experiences with twenty four eyes. *Neoplasma* 2003; 50: 459–464.
- Zehetmayer M, Kitz K, Menapace R et al. Local tumor control and morbidity after one to three fractions of stereotactic external beam irradiation for uveal melanoma. *Radiother Oncol* 2000; 55: 135–144.
- Rennie I, Forster D, Kemeny A et al. The use of single fraction Leksell stereotactic radiosurgery in the treatment of uveal melanoma. *Acta Ophthalmol Scand* 1996; 74: 558–562.
- Finger PT. Radiation therapy for choroidal melanoma. *Surv Ophthalmol* 1997; 42: 215–232.
- Shields CL. Plaque radiotherapy for the management of uveal metastasis. *Curr Opin Ophthalmol* 1998; 9: 31–37.
- Diener-West M, Earle JD, Fine SL et al. The COMS randomized trial of iodine 125 brachytherapy for choroidal melanoma, III: initial mortality findings. COMS Report No. 18. *Arch Ophthalmol* 2001; 119: 969–982.
- Shields CL, Shields JA, De Potter P et al. Plaque radiotherapy for retinoblastoma. *Int Ophthalmol Clin* 1993; 33: 107–118.



# Ocular complications of radiotherapy

Mehran Taban, Mehryar Taban, James Bolling and Arun D. Singh

## INTRODUCTION

Ocular and orbital complications may occur either as a result of direct irradiation for intraocular tumors, or indirectly when the eye is within the treatment beam for orbital, skull-based, paranasal sinus, or central nervous system tumors.<sup>1</sup> Ocular and orbital structures have a wide range of dose-dependent sensitivities to radiation exposure and there is the potential for functional, cosmetic, visual, and, rarely, lethal consequences.<sup>2</sup> Tissue tolerance to radiation is an important consideration in treatment planning.<sup>3</sup> Various aspects of radiation treatment planning are discussed in detail elsewhere (see Chapter 8 [1–8]).

In general, acute radiation effects (<4 weeks) manifest as anterior segment changes and late complications (>4 weeks) involve the posterior segment and the orbital tissues. This chapter aims to analyze the ocular effects of radiation, with emphasis on radiation retinopathy and optic neuropathy.

## EYELID/PERIORBITAL SKIN

**Acute** Loss of eyelashes is one of the first and most common adverse effects to occur after radiotherapy, although they do usually grow back (Fig. 9.1). Erythema may occur within hours of radiotherapy.<sup>4</sup> Desquamation and scaling of the skin can follow lower-dose (10 Gy) radiation exposure, and more severe dermatitis occurs with higher doses (40 Gy).<sup>4</sup>

**Late** Loss of eyelashes and eyebrows may be permanent.<sup>2,4</sup> Other late sequelae of regular and high-dose radiotherapy (40 Gy or higher) to the eyelids include trichiasis, telangiectasia, hyperpigmentation, hyperkeratosis, entropion, ectropion, and punctal occlusion. Eyelid atrophy, necrosis, and frank ulceration are uncommon.

**Management** Mild acute radiation effects can be relieved with the administration of topical corticosteroids, such as 1% hydrocortisone. Late effects may be remedied by wound debridement, antibiotic therapy, and reconstructive surgery.

## CONJUNCTIVA

**Acute** Conjunctivitis, chemosis, and a clear or purulent discharge may occur when radiotherapy doses of >5 Gy are used.<sup>2,4</sup>

**Late** effects of radiotherapy to the conjunctiva include telangiectasia, symblepharon, and sequelae of loss of goblet cells (keratinization and scarring).<sup>2,4</sup> Doses of approximately 50 Gy lead to conjunctival scarring. Severe contracture occurs with doses of more than 60 Gy, and symblepharon is frequent with doses above 80–100 Gy.<sup>5</sup>

**Management** Topical corticosteroids are indicated for early conjunctivitis and chemosis. Artificial tears and ointment help replace the moisture lost due to damage to goblet cells and keratinization.

## CORNEA

**Acute** The corneal epithelium is affected with radiation doses of 10–20 Gy. Early effects include decreased corneal sensation, corneal epithelial defects, and punctate keratitis (Fig. 9.1).<sup>4</sup>

**Late** radiation effects to the cornea include keratinization, epithelial desquamation, edema, neovascularization, ulceration, and perforation.<sup>2,4,5</sup>

**Management** should be directed at the underlying pathology, such as repair of lid malpositioning, excision of metaplastic conjunctiva, and aggressive lubrication. Soft contact lenses and tarsorrhaphy are sometimes used to promote corneal healing. Surgical intervention, such as keratoplasty, has a guarded prognosis.

## SCLERA

The sclera is the most radioresistant ocular structure and can tolerate radiation doses of up to 900 Gy from radioactive plaques. However, scleral thinning or atrophy can occur several years after doses of 20–30 Gy. Scleral perforation is rare.<sup>2,4</sup>

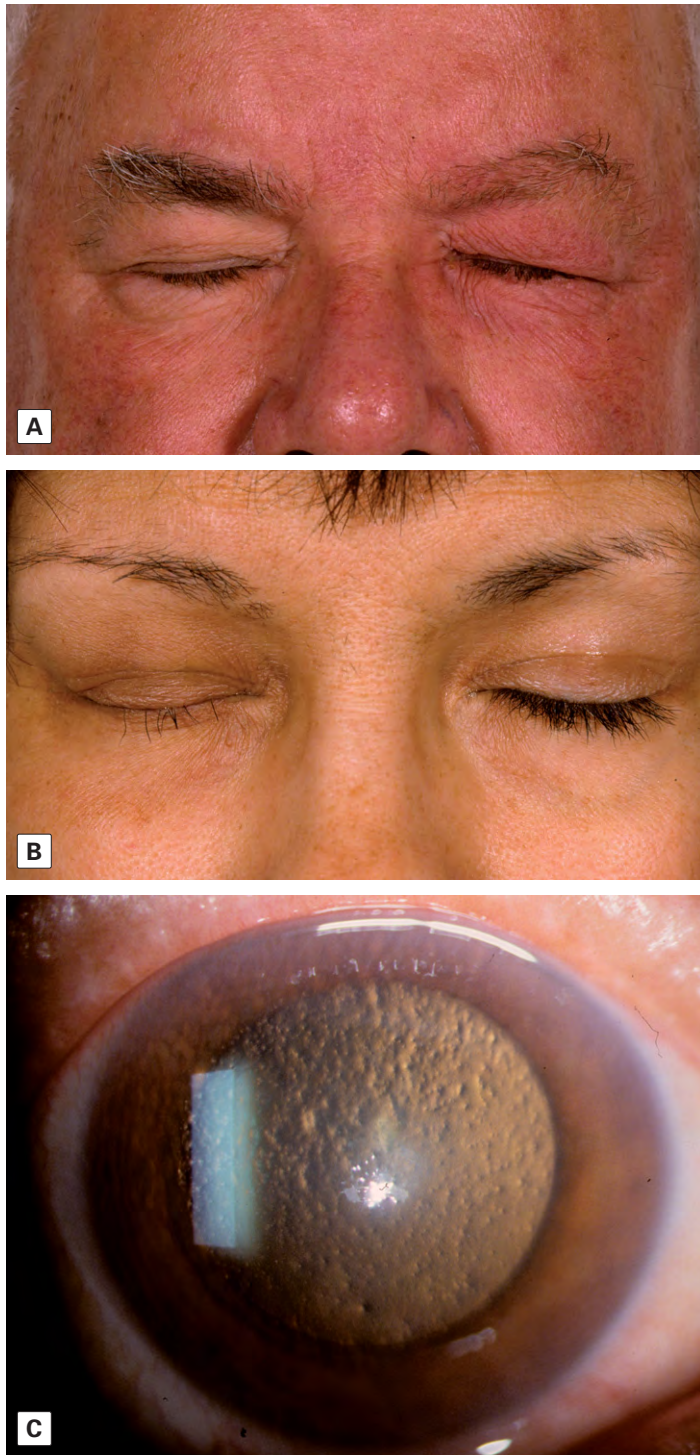
## IRIS

Acute iritis is dose related and occurs with at least a single dose of 20 Gy or a fractionated dose of >60 Gy.<sup>4</sup> The main long-term effects of irradiation to the iris include iris atrophy, posterior synechiae, rubeosis iridis, and neovascular glaucoma.<sup>2,4</sup>

## LENS

The lens is the most radiosensitive structure of the eye and cataract is a well recognized long-term consequence of radiotherapy.<sup>4</sup> The severity and latency of radiation cataract are inversely related to radiation dose. In addition, fractionation of radiation reduces the overall risk and delays the onset of radiation cataract. In most human studies, total fractionated doses under 500 cGy have not produced visually significant lens opacities. Whereas a single dose as low as 2 Gy can induce cataract, higher doses of 10–15 Gy are required with fractionated radiotherapy to induce cataracts.<sup>6</sup>

The time of onset of cataract ranges from 6 months to many years, with an average of about 2–3 years. Radiation cataract usually presents



**Fig. 9.1** Acute complications of radiotherapy. (A) Radiation dermatitis. (B) Loss of eyelashes. (C) Punctate keratitis.

as posterior subcapsular opacification; however, in some cases an anterior subcapsular change is noted initially.<sup>7</sup>

Cataract formation is best prevented by fractionation of the radiation dose and by customized lens shielding. Specially mounted lead discs on plastic contact lenses and techniques of radiation such as lens-sparing radiotherapy can be used to protect the lens from complications.<sup>8</sup> Management of radiation cataract is complicated by concurrent anterior segment effects of radiation, such as dryness, eyelid defor-

mity, and corneal keratinization. In addition, there are risks of excessive postoperative iritis and poor visual outcome due to radiation retinopathy.

### ORBIT SOFT TISSUE, LACRIMAL GLAND, AND ORBITAL BONES

**Orbit soft tissue** The late effects of radiation can induce orbital fat atrophy, fibrosis, and diffuse socket contracture in an anophthalmic socket.<sup>9,10</sup>

**Lacrimal gland** Dry eyes are most commonly a result of radiation to the conjunctiva and only partially from delayed atrophy of the lacrimal gland associated with high doses (50–60 Gy) of radiation exposure.<sup>2,11</sup>

**Orbital bones** Late effects of radiation on the orbital bones are seen primarily when external beam irradiation is applied to the growing facial bones of children, as in the treatment of retinoblastoma and rhabdomyosarcoma.<sup>9,10</sup> Marked facial deformities can occur years after a dose of 40–70 Gy.<sup>2</sup> Socket reconstruction may be required as prostheses may fit poorly as a result of soft tissue atrophy, a contracted socket, and orbital hypoplasia.

Children with heritable retinoblastoma (bilateral or familial) are genetically predisposed to develop second malignant neoplasms (SMN) later in life. Radiation therapy of the retinoblastoma further increases this risk. SMN are discussed in detail elsewhere (see Chapter 71; Non-ocular tumors).

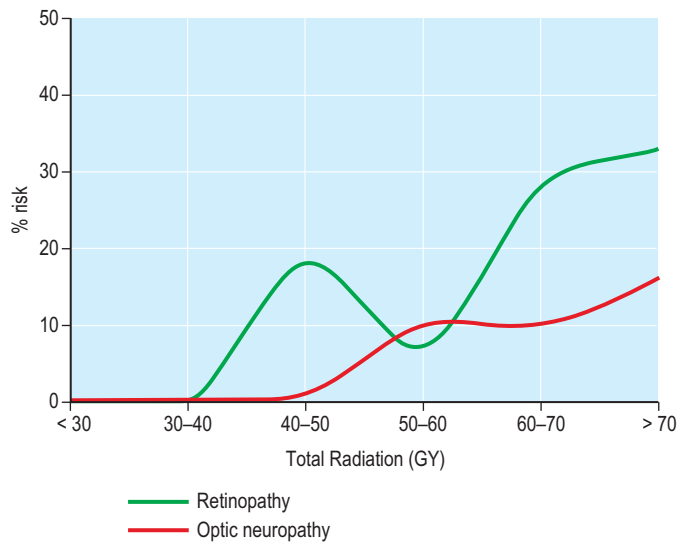
### RADIATION RETINOPATHY

Radiation retinopathy is a delayed-onset, slowly progressive occlusive retinal microangiopathy.<sup>12</sup> The median time to diagnosis of radiation retinopathy is about 2.6 years.<sup>1</sup> The precise incidence is probably underestimated because many patients with mild retinopathy have no symptoms.

**Pathogenesis** Radiation insult to vascular endothelial cells as the underlying basis of radiation retinopathy has been demonstrated in an animal model.<sup>13</sup> In contrast to diabetic retinopathy, in which pericyte loss predominates, a predilection for endothelial cell loss is observed in radiation retinopathy.<sup>12</sup> Additional contributions may come from radiation damage to the choroidal vasculature, as evidenced by areas of choriocapillaris perfusion defects in areas remote from retinal ischemia.<sup>14</sup>

**Clinical features** It is generally accepted that the total dose and fraction size of radiation are the key determinants of radiation retinopathy.<sup>1</sup> Analysis of 186 eyes receiving significant radiation for head and neck cancers revealed an overall incidence of 20% at 5 years.<sup>1</sup> There was uniform absence of radiation retinopathy in eyes receiving less than 40 Gy.<sup>1</sup> Doses of 40–60 Gy produced retinopathy in only 10% of cases, compared to 30% of patients receiving more than 60 Gy (Fig. 9.2). Hyperfractionation (2 fractions/day) appears to reduce the risk of radiation retinopathy by as much as 50% in cases receiving a higher dose.<sup>1</sup> Host factors such as diabetes and a history of prior chemotherapy increase the risk and severity of radiation retinopathy (Box 9.1).<sup>15–17</sup>

The incidence of radiation retinopathy is higher in eyes irradiated for choroidal melanoma than those indirectly irradiated for head and



**Fig. 9.2** Total dose of radiation and risk of radiation retinopathy and radiation optic neuropathy. Modified with permission from Monroe AT, Bhandare N, Morris CG, Mendenhall WM. Preventing radiation retinopathy with hyperfractionation. *Int J Radiat Oncol Biol Phys* 2005; 61: 856–864 and Bhandare N, Monroe AT, Morris CG et al. Does altered fractionation influence the risk of radiation-induced optic neuropathy? *Int J Radiat Oncol Biol Phys* 2005; 62: 1070–1077.

### BOX 9.1 Salient Features of Radiation Retinopathy

- Total dose and fraction size of radiation are the key determinants
- The presence of diabetes and a history of prior chemotherapy increase the risk and severity of radiation retinopathy
- Doses of less than 45 Gy (fractions size  $\leq 2.0$  Gy) are unlikely to cause significant retinopathy in the absence of coexisting host risk factors
- Insult to vascular endothelial cells is the underlying basis of radiation retinopathy
- Discrete foci of capillary non perfusion (cottonwool spots) and telangiectasia are the earliest features
- The incidence peaks 2–3 years after radiation exposure
- At present there is no effective treatment for radiation retinopathy

neck cancers. This is because of higher radiation doses and low or no fractionation of radiation used for the treatment of choroidal melanoma. In a series of patients treated with proton beam radiation (70 cobalt Gray equivalents/5 fractions), the cumulative 5-year rate for radiation maculopathy was 64%.<sup>16</sup> With plaque radiotherapy (85 Gy apical dose), Kaplan–Meier estimates of non-proliferative and proliferative radiation retinopathy were respectively 42% and 8% at 5 years.<sup>18</sup>

The source of the radiation also influences the dose to other ocular structures. Ruthenium-106 and strontium-90 have a limited dose distribution compared to iodine-125. Strontium-90 may be used to deliver a dose of 15 Gy to the macula with minimal effects on the rest of the eye.<sup>19</sup>

**Symptoms** Blurred vision, metamorphopsia, and visual field changes can occur weeks, months, or years after radiotherapy.

### Signs

- **Non-proliferative radiation retinopathy.** The earliest features of radiation retinopathy include discrete foci of occluded capillaries (cottonwool spots) and irregular dilatation of the neighboring retinal microvasculature (Fig. 9.3). Late changes include RPE atrophy, generalized dispersion of the RPE, and vascular obstructions.<sup>15</sup>
- **Radiation maculopathy.** As the retinopathy progresses, microaneurysms, telangiectatic changes, exudation, and edema develop, predominantly in the macular region.
- **Proliferative radiation retinopathy.** Later, the evolution of large areas of retinal ischemia and capillary non-perfusion may lead to retinal and disc neovascularization, vitreous hemorrhages, and retinal detachment. Most patients who develop proliferative retinopathy develop the new vessels within 2 years of the onset of radiation retinopathy.<sup>20</sup> Anterior segment neovascularization may also occur, leading to neovascular glaucoma.

**Diagnostic evaluation** A history of radiotherapy and the presence of an ischemic retinopathy usually suffice to secure a diagnosis of radiation retinopathy. However, fluorescein angiography is used to demonstrate characteristic features of radiation retinopathy (Fig. 9.3).<sup>21</sup>

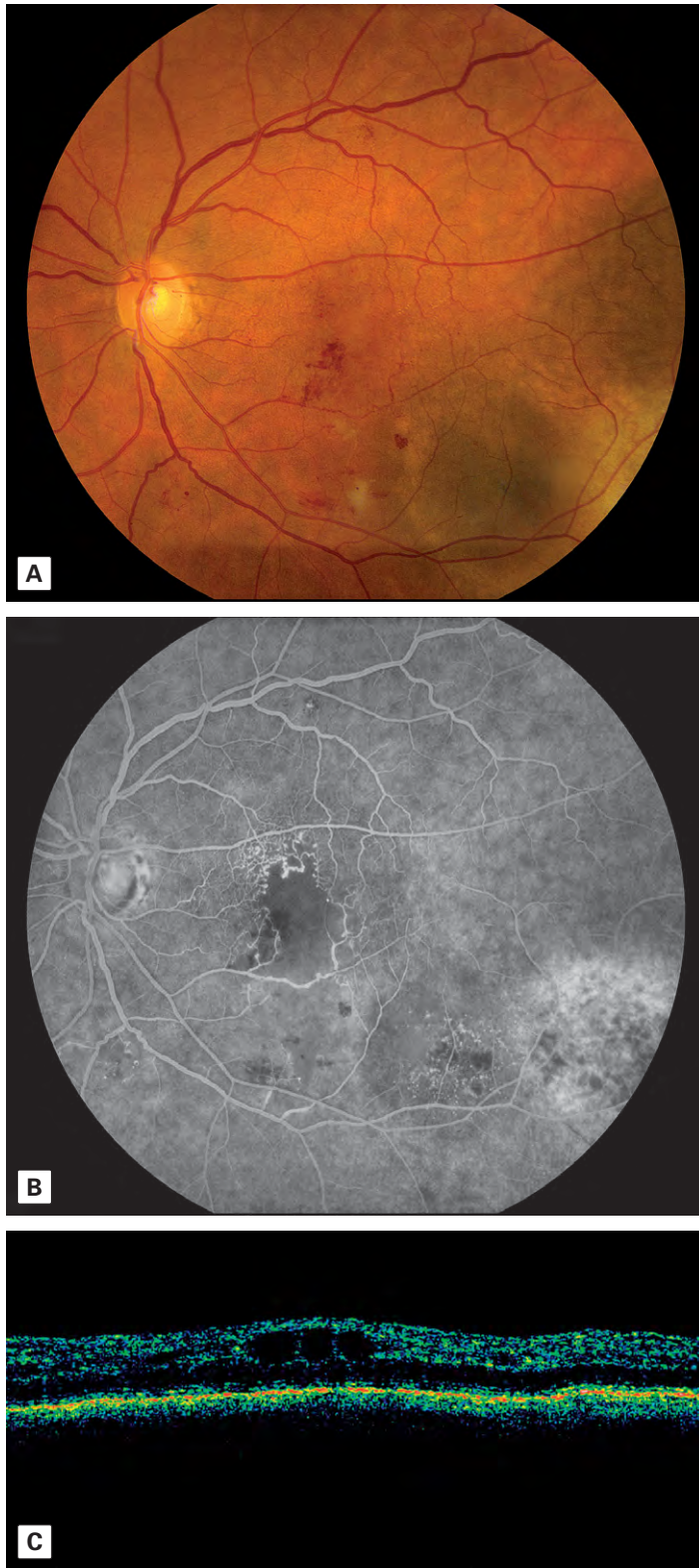
**Differential diagnosis** The diagnosis of radiation retinopathy is usually self-evident, given the history of radiotherapy. However, certain entities can closely resemble radiation retinopathy (Box 9.2). Of these, diabetic retinopathy is the most commonly encountered, and in diabetic patients who receive radiotherapy it may be difficult to decide the exact nature of the retinopathy.

**Treatment** Minor degrees of retinopathy may not affect vision and may remain stable for years. No treatment is required, but such patients merit periodic follow-up as the disease is slowly progressive. Extramacular radiation retinopathy (both non-proliferative and proliferative) responds well to sector laser photocoagulation and may even reduce the risk of developing radiation retinopathy if the laser is applied prophylactically.<sup>22</sup>

However, it is the treatment of visually significant radiation maculopathy that has not been promising. Grid laser photocoagulation has been reported to resolve the macular edema with only minimal improvement of visual acuity.<sup>23</sup> In another retrospective comparative study the long-term outcome of treated cases was similar to that in a matched group that did not undergo laser therapy.<sup>24</sup> Therefore, the benefit of grid laser photocoagulation for the treatment of radiation maculopathy remains to be established. Intravitreal triamcinolone provides only temporary resolution of retinal edema with no effect on the underlying retinal ischemia.<sup>25</sup>

**Prognosis** In general, patients with non-proliferative retinopathy can expect to retain a visual acuity of 20/50 for at least 4 years.<sup>23</sup> Visual outcome after plaque radiation therapy for choroidal melanoma are generally worse (<20/200 in 40% after 3 years).<sup>26</sup> The worst visual outcome is expected in eyes with proliferative radiation retinopathy.





**Fig. 9.3** (A) Characteristic ophthalmoscopic features of non-proliferative radiation retinopathy, such as cottonwool spots, telangiectasia, retinal hemorrhages, and macular edema following brachytherapy for choroidal melanoma. (B) Retinal capillary non-perfusion in the macula and microaneurysms are most evident on the fluorescein angiography. (C) Cystoid macular edema on the optical coherent tomograph.

### BOX 9.2 Differential Diagnosis of Radiation Retinopathy

- Diabetic retinopathy
- Hypertensive retinopathy
- Interferon retinopathy
- Collagen-vascular disease
- Sickle cell retinopathy
- Ocular ischemia syndrome
- Retinopathy of anemia/thrombocytopenia
- Leukemic retinopathy
- Perifoveal telangiectasia
- Coats' disease
- Central/branch retinal vein occlusion

### RADIATION OPTIC NEUROPATHY

The diagnostic criteria of RON include acute loss of vision, visual field defects, the onset of symptoms within 3 years of radiation therapy, and no evidence of visual pathway compression by neuroimaging.

**Pathogenesis** The histopathologic evaluation of RON specimens reveals endothelial hyperplasia, obliterative endarteritis, ischemic demyelination, and reactive astrocytosis.<sup>27</sup> These observations indicate initial damage to capillaries and arterioles, with subsequent axonal damage. Diabetes appears to be a significant risk factor for RON.<sup>16</sup>

**Clinical features** The incidence and latency of optic nerve injury after radiation is predominantly dose dependent.<sup>28</sup> The risk of RON increases with age (>50 years).<sup>28</sup> The lowest dose recorded as producing RON is 36 Gy; however, RON generally occurs with doses exceeding 50 Gy.<sup>28</sup> Doses of 50–70 Gy produced RON in only 10% of cases, compared to 16% of patients receiving more than 70 Gy (see Fig. 9.2). A shorter latency after plaque therapy than after external beam therapy (mean 12 vs 19 months) may be related to the higher dose and absence of fractionation with brachytherapy.<sup>29</sup>

**Symptoms** Vision loss and visual field defects occur within months to years following radiation, but typically after 1.5–2 years.

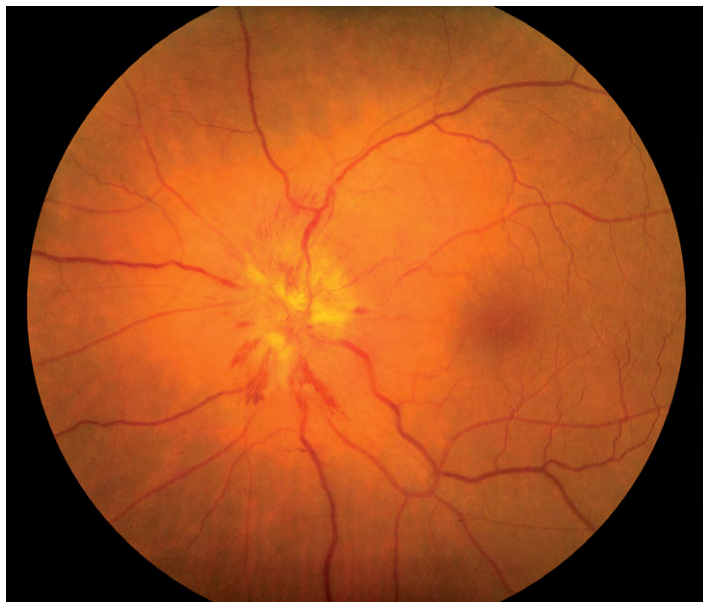**Signs** Typically, RON manifests acutely as disc swelling with surrounding exudates, hemorrhages, and subretinal fluid (Fig. 9.4).<sup>29</sup> Optic atrophy may ensue in the later stages.

**Diagnostic evaluation** MRI reveals optic nerve enhancement with gadolinium and is the diagnostic procedure of choice.<sup>30</sup> Computed tomographic (CT) scanning is typically normal and shows no abnormal enhancement with contrast material.<sup>27</sup>

**Treatment** As with radiation retinopathy, there is as yet no effective treatment for visual loss after RON. High-dose steroids, anti-coagulation, and hyperbaric oxygen have been tried without proven effectiveness.<sup>31</sup>

**Prognosis** The visual prognosis in RON is guarded.<sup>28</sup>





**Fig. 9.4** Typical appearance of radiation optic neuropathy. Note optic disc swelling with surrounding exudates and hemorrhages.

## SUMMARY

The early reactions of the eye to radiation commonly manifest as transient eyelid erythema, conjunctivitis, and iritis. The most frequent late radiation complication is cataract. The most severe late complications are radiation retinopathy and radiation optic neuropathy, both of which are thought to be secondary to radiation induced microangiopathy. Visual loss is common, and complete blindness can be seen with high doses in the range of 50–60 Gy. Host factors such as diabetes and previous chemotherapy potentiate radiation retinopathy. Radiation exposure is especially carcinogenic in genetically predisposed individuals, such as children with bilateral or familial retinoblastoma. As there are no effective treatments for the ophthalmic complications of radiotherapy, an attempt should be made to spare the orbit and globe, and hyperfractionation of the dose should be considered. Newer modalities of treatment for radiation retinopathy and optic neuropathy need to be explored.

## REFERENCES

1. Monroe AT, Bhandare N, Morris CG, Mendenhall WM. Preventing radiation retinopathy with hyperfractionation. *Int J Radiat Oncol Biol Phys* 2005; 61: 856–864.
2. Brady LW, Shields J, Augusburger J et al. Complications from radiation therapy to the eye. *Front Radiat Ther Oncol* 1989; 23: 238–250.
3. Emami B, Lyman J, Brown A et al. Tolerance of normal tissue to therapeutic irradiation. *Int J Radiat Oncol Biol Phys* 1991; 21: 109–122.
4. Servodidio CA, Abramson DH. Acute and long-term effects of radiation therapy to the eye in children. *Cancer Nurs* 1993; 16: 371–381.
5. Hempel M, Hinkelbein W. Eye sequelae following external irradiation. *Recent Results Cancer Res* 1993; 130: 231–236.
6. Merriam GR, Jr., Szechter A, Focht EF. The effects of ionizing radiations on the eye. *Front Radiation Ther Onc* 1972; 6: 346–385.
7. Cogan DG, Donaldson DD, Reese AB. Clinical and pathological characteristics of radiation cataract. *AMA Arch Ophthalmol* 1952; 47: 55–70.
8. Hungerford JL, Toma NM, Plowman PN et al. Whole-eye versus lens-sparing megavoltage therapy for retinoblastoma. *Front Radiat Ther Oncol* 1997; 30: 81–87.
9. Heyn R, Ragab A, Raney RB Jr et al. Late effects of therapy in orbital rhabdomyosarcoma in children. A report from the Intergroup Rhabdomyosarcoma Study. *Cancer* 1986; 57: 1738–1743.
10. Larson DL, Kroll S, Jaffe N et al. Long-term effects of radiotherapy in childhood and adolescence. *Am J Surg* 1990; 160: 348–351.
11. Parsons JT, Fitzgerald CR, Hood CI et al. The effects of irradiation on the eye and optic nerve. *Int J Radiat Oncol Biol Phys* 1983; 9: 609–622.
12. Archer DB, Amoaku WM, Gardiner TA. Radiation retinopathy – clinical, histopathological, ultrastructural and experimental correlations. *Eye* 1991; 5: 239–251.
13. Irvine AR, Wood IS. Radiation retinopathy as an experimental model for ischemic proliferative retinopathy and rubeosis iridis. *Am J Ophthalmol* 1987; 103: 790–797.
14. Midena E, Segato T, Valenti M et al. The effect of external eye irradiation on choroidal circulation. *Ophthalmology* 1996; 103: 1651–1660.
15. Brown GC, Shields JA, Sanborn G et al. Radiation retinopathy. *Ophthalmology* 1982; 89: 1494–1501.
16. Gragoudas ES, Li W, Lane AM et al. Risk factors for radiation maculopathy and papillopathy after intraocular irradiation. *Ophthalmology* 1999; 106: 1571–1577.
17. Viebahn M, Barracks ME. Potentiating effect of diabetes in radiation retinopathy. *Int J Radiat Oncol Biol Phys* 1993; 25: 379–380.
18. Gunduz K, Shields CL, Shields JA et al. Radiation retinopathy following plaque radiotherapy for posterior uveal melanoma. *Arch Ophthalmol* 1999; 117: 609–614.
19. Jaakkola A, Heikkonen J, Tommila P et al. Strontium plaque brachytherapy for exudative age-related macular degeneration. *Ophthalmology* 2005; 112: 567–573.
20. Kinyoun JL, Lawrence BS, Barlow WE. Proliferative radiation retinopathy. *Arch Ophthalmol* 1996; 114: 1097–1100.
21. Amoaku WM, Archer DB. Fluorescein angiographic features, natural course and treatment of radiation retinopathy. *Eye* 1990; 4: 657–667.
22. Finger PT, Kurli M. Laser photocoagulation for radiation retinopathy after ophthalmic plaque radiation therapy. *Br J Ophthalmol* 2005; 89: 730–738.
23. Kinyoun JL, Zamber RW, Lawrence BS et al. Photocoagulation treatment for clinically significant radiation macular oedema. *Br J Ophthalmol* 1995; 79: 144–149.
24. Hykin PG, Shields CL, Shields JA, Arevalo JF. The efficacy of focal laser therapy in radiation-induced macular edema. *Ophthalmology* 1998; 105: 1425–1429.
25. Sutter FK, Gillies MC. Intravitreal triamcinolone for radiation-induced macular edema. *Arch Ophthalmol* 2003; 121: 1491–1493.
26. Melia BM, Abramson DH, Albert DM et al. Collaborative ocular melanoma study (COMS) randomized trial of I-125 brachytherapy for medium choroidal melanoma. I. Visual acuity after 3 years COMS report no. 16. *Ophthalmology* 2001; 108: 348–366.
27. Kline LB, Kim JY, Ceballos R. Radiation optic neuropathy. *Ophthalmology* 1985; 92: 1118–1126.
28. Bhandare N, Monroe AT, Morris CG et al. Does altered fractionation influence the risk of radiation-induced optic neuropathy? *Int J Radiat Oncol Biol Phys* 2005; 62: 1070–1077.
29. Brown GC, Shields JA, Sanborn G et al. Radiation optic neuropathy. *Ophthalmology* 1982; 89: 1489–1493.
30. Guy J, Mancuso A, Beck R et al. Radiation-induced optic neuropathy: a magnetic resonance imaging study. *J Neurosurg* 1991; 74: 426–432.
31. Miller NR. Radiation-induced optic neuropathy: still no treatment. *Clin Exp Ophthalmol* 2004; 32: 233–235.

# Principles of chemotherapy

Michael G. Levien, Jennifer Gravette and Joanne M. Hilden

## INTRODUCTION

The overall survival rate for cancer has improved dramatically since the institution of chemotherapy for the treatment of childhood leukemia in the 1940s.<sup>1</sup> The ultimate prognosis for each cancer is contingent on the histologic type, the extent of disease, and several other biologic parameters.<sup>2</sup>

Recent progress in molecular biology, biochemistry, and genetics has provided new insights into the complex molecular changes associated with malignant transformation of a cell. These discoveries are offering new classes of drug that are being currently evaluated in clinical trials along with conventional agents.<sup>3</sup> This chapter will review some of the basic principles of chemotherapy, with examples from common ophthalmic cancers.

## BASIC PRINCIPLES

Most conventional anticancer drugs have non-selective mechanisms of action that target DNA, RNA, or metabolic pathways in both malignant and normal cells. In the latter, undesirable and potentially severe toxic effects can result.

**Mechanism of action** Alkylating agents such as cyclophosphamide, cisplatin, and carboplatin damage DNA by covalently binding to and cross-linking nucleosides within the DNA. Antimetabolites such as methotrexate block the synthesis of nucleotide precursors, or are incorporated directly into DNA as fraudulent bases. Topoisomerases are nuclear enzymes that maintain the three-dimensional structure of DNA, critical for DNA replication, transcription, and recombination. Etoposide (VP-16), anthracyclines (doxorubicin), and camptothecins (topotecan, irinotecan) interfere with the religation of DNA, resulting in DNA strand breaks. Commonly used antineoplastic agents and their mechanisms of action are summarized in Table 10.1.

A relatively new class of chemotherapy drugs, such as the monoclonal antibody rituxan (anti-CD 20), has been used successfully in the treatment of CD 20-positive non-Hodgkin's lymphomas. Other agents such as prednisone, cyclosporin, and interferons alter immune system function. Thalidomide, because of its antiangiogenic effects, has become important in the treatment of chemotherapy-resistant brain tumors. Advances in basic research continue to offer new cancer therapies based on our understanding of the pathogenesis of cancer. For example, the development of tyrosine kinase inhibitors such as Gleevec, which allows for apoptosis of the cancer cells, is effective for the treatment of chronic myeloid leukemia.

**The cell generation cycle** Drugs affect different stages of the cell cycle (Fig. 10.1). Knowledge of the normal cell cycle and how different chemotherapeutic anticancer drugs disrupt this cycle is integral in helping to develop effective chemotherapy regimens. Agents that are cell-cycle phase specific will kill a fraction of cells passing through that phase of the cycle. On the other hand, agents that are not phase specific produce a continuous exponential decrease in cell survival because they affect all cells, regardless of their phase in the cycle.<sup>4,5</sup>

Combining agents that enhance the disruption of vital intracellular processes through concurrent and/or sequential blockade of the cell cycle, as well as inhibition of specific metabolic pathways, has been a traditional approach in designing chemotherapy protocols.<sup>4</sup>

**Tumor cell kinetic model** Exposing a tumor to a drug at a predetermined concentration over an established period will result in a constant fraction of tumor cells being killed, regardless of tumor size. This fractional cell kill hypothesis forms the rationale for repeated courses of therapy at maximum tolerated doses. The chemotherapy is given in cycles as soon as blood counts recover to achieve the goal of reducing tumor cells to zero.<sup>5</sup>

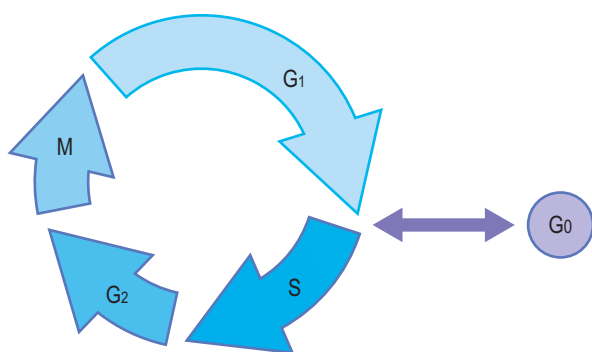
**Combination regimen** The importance of administering anticancer drugs in combination regimens was first recognized in the treatment of childhood cancers. In acute lymphocytic leukemia, for example, a complete remission can be achieved in 60% of patients treated with a single agent, such as aminopterin, prednisone, vincristine, L-asparaginase, or daunomycin. However, most of these patients relapsed despite the continued use of that agent.<sup>6</sup> Patients retreated with the same agent at the time of relapse do not respond. These observations implied the emergence of a pre-existing drug-resistant subclone and/or residual subclinical disease. The use of combination chemotherapy with alternating regimens of non-cross-resistant drugs decreases the incidence of the development of drug resistance. The most successful combination chemotherapy uses agents that also have additive or synergistic mechanisms of action, with non-overlapping toxicities (if possible) to allow each agent to be used at optimal dosing.<sup>4</sup> This approach has contributed to the significant improvement in survival (90% cure rate) in acute lymphocytic leukemia.<sup>2</sup>

## DRUG RESISTANCE

Resistance to anticancer drugs is the primary reason for treatment failure in cancer patients. Drug resistance can be present at diagnosis or develop over time by exposure to chemotherapy. Cancer cells

**Table 10.1 Commonly used anti-neoplastic agents and their mechanisms of action**

Group	Drug	Mechanism of action
Antimetabolites	Mercaptopurine	Arrests purine synthesis – interrupts DNA/RNA synthesis
	Methotrexate	Prevents thymidine synthesis – arrests conversion of folate to active form
	Cytosine arabinoside	Disrupts DNA by inhibiting DNA polymerase
	5-Fluorouracil	Disrupts DNA/RNA synthesis – inhibits thymidine synthesis
Alkaloids	Vinca alkaloids: vincristine, velban	Inhibits mitosis by binding tubulin
	Etoposide (VP-16)	DNA strand breaks (topoisomerase II mediated)
	Taxanes	Mitotic arrest by stabilizing microtubules
	Camptotecans: topotecan, irinotecan	DNA strand breaks (topoisomerase I mediated)
Alkylating agents	Cyclophosphamide, melphalan, ifosfamide	DNA disruption by intra- and interstrand cross-linking
	Cisplatin, carboplatin	Intra- and interstrand cross-linking of DNA by platination
Antibiotics	Anthracyclines: adriamycin, daunomycin	DNA strand breaking, free radical formation, interference of DNA religation (topoisomerase II mediated)
Miscellaneous	Corticosteroids	Lympholysis
	L-Asparaginase	Inhibition of protein synthesis by L-asparagine
	Rituxan	Anti CD 20 antibody
	Thalidomide	Antiangiogenesis
	Retinoic acid	Differentiating agent



**Fig. 10.1** The cell generation cycle is divided into four phases. G<sub>1</sub> begins immediately after mitosis. It is a period when the cell carries on its usual non-mitotic functions, and lasts until the beginning of the S phase. The S phase is the synthetic period when synthesis of DNA occurs and the genome is replicated. G<sub>2</sub> is the period between the end of DNA synthesis and the beginning of cell division. M phase is the mitotic phase during which chromosome condensation occurs, the mitotic spindle appears, sister chromosomes separate, and the process of cell division occurs. G<sub>0</sub> cells are those that have left the cycling pool, either temporarily or permanently. Cells that are temporarily in G<sub>0</sub> can be recruited back into the proliferative cycle by appropriate stimuli or growth factors. Some G<sub>0</sub> cells may be terminally differentiated and cannot be recruited back into the proliferative cycle.

undergo spontaneous generation of drug-resistant clones by mutation, deletion, gene amplification, translocation, or chromosomal rearrangement. This is due to the inherent genetic instability of each cancer cell. Drug resistance can target a single drug or multiple drugs. For example, P-glycoprotein (P-gp) expression leads to a reduction of the intracellular concentration of a drug owing to increased activity of membrane-bound ATP drug-dependent efflux pumps.<sup>3</sup> Drugs such as verapamil, calcium channel blockers, and ciclosporin can act as chemosensitizers and reverse multidrug resistance caused by P-gp. Multidrug resistance is also the result of the cancer cell's enhanced ability to repair DNA, decreased levels of the target enzyme (topoisomerase II), and

the suppression of apoptotic pathways. The mechanism of drug resistance is important to consider in designing treatment protocols for relapsed patients.

## DRUG DEVELOPMENT

The initial critical step in the development of anticancer drugs is to identify new candidate drugs. The National Cancer Institute's Drug Screening Program uses a panel of 60 human tumor cell lines to identify new candidate drugs. The screening program identifies more than 10 000 new chemical agents per year. New gene chip technology has now been incorporated into the NCI's drug screening program. Candidate compounds are then tested in mice and dogs to determine the maximum tolerated dose (MTD). Pharmacokinetic parameters are also studied in animals to establish a safe starting dose for human clinical trials.<sup>3,5,7</sup>

## CLINICAL TRIALS

**Phase I** A phase I trial is designed to determine the MTD for a specific dosing schedule, define the toxicity profile in humans, identify-dose limiting toxicities, and study the pharmacokinetics of a drug. Phase I studies are open to patients who have had relapse(s) and have exhausted standard and established therapies. Usually a small numbers of patients (15–30) are enrolled and the dose is then escalated in successive cohorts of three to six patients until a dose-limiting toxicity is consistently observed.

**Phase II** After the optimal dose and schedule for a new drug is determined, phase II trials are conducted to determine the spectrum of antitumor activity and the response rate of the drug against a number of different tumors. Patients who have failed standard therapy are eligible for phase II trials.<sup>3,8</sup>

**Phase III** New chemotherapy agents that have successfully been tested in phase I and II trials enter into phase III trials. Phase III trials are randomized studies in which new agents are studied in previously

untreated patients (standard therapy and new agent versus standard therapy alone). Additional factors that must be considered in the development of treatment protocols include the drug's mechanism of action, pharmacokinetics, toxicities, potential drug interactions, and mechanisms of drug resistance.<sup>1,6</sup>

### SIDE EFFECTS

Antineoplastic drugs have the lowest therapeutic index of any class of drug. They therefore predictably produce significant, and at times life-threatening, toxicities (Table 10.2). The oncologist must balance the risk of toxicities against the risk of relapse as a result of inadequate treatment. Even a small reduction or delay in therapy to mitigate toxicities can result in tumor recurrence, which may lead to the death of the patient.

### MULTIMODALITY THERAPY

At times other treatment modalities, such as surgery and radiation therapy, are used in conjunction with chemotherapy for maximal clinical benefit.

**Adjuvant chemotherapy** wherein patients receive local therapy at diagnosis (surgery and/or radiation therapy) to the primary tumor prior to chemotherapy (Table 10.3).

**Neo-adjuvant chemotherapy** In the neo-adjuvant setting patients receive chemotherapy at diagnosis to reduce the cancer burden prior to local measures being undertaken. In retinoblastoma, chemotherapy is used as a chemoreductive approach (neo-adjuvant therapy). Currently six cycles of vincristine, etoposide (VP-16), and carboplatinum are given every 3–4 weeks. This is followed by local measures such as thermotherapy, cryotherapy, and plaque radiotherapy to treat intraocular tumors so as to avoid the use of external beam radiotherapy and enucleation.<sup>8</sup>

### SUMMARY

Most conventional anticancer drugs have non-selective mechanisms of action that target DNA, RNA, or metabolic pathways in both malignant and normal cells. Recent progress in molecular biology, biochemistry,

**Table 10.2 Drug toxicity of commonly used anti-neoplastic agents\***

Group	Drug	Toxicity
Antimetabolites	Mercaptopurine	Hepatotoxicity
	Methotrexate	Hepatotoxicity, nephrotoxicity
	Cytosine arabinoside	Hepatotoxicity, nephrotoxicity, neurotoxicity
Alkaloids	Vinca alkaloids: vincristine, velban	Neurotoxicity, constipation
	Etoposide (VP-16)	Hepatotoxicity, nephrotoxicity
Alkylating agents	Cyclophosphamide	Hepatotoxicity, nephrotoxicity, cystitis
	Cisplatinum, carboplatinum	Nephrotoxicity, ototoxicity
Antibiotics	Anthracyclines: adriamycin, daunomycin	Hepatotoxicity, cardiotoxicity
Miscellaneous	Corticosteroids	GI bleed, Cushing's syndrome, diabetes
	L-Asparaginase	Pancreatitis
	Interferon- $\alpha$	Fever, malaise, myalgia
	Thalidomide	Teratogenicity
	Retinoic acid	Hypervitaminosis A

\*Bone marrow depression, alopecia, nausea, and vomiting are frequent side effects of many anti-neoplastic agents.

**Table 10.3 Multidisciplinary treatment of common ophthalmic tumors**

Tumor	Chemotherapy	Surgery	Radiotherapy
Orbital rhabdomyosarcoma (embryonal: non-metastatic)	Vincristine	+	+
	Actinomycin D		
Optic nerve glioma	Vincristine + carboplatin	±	+ (age > 5 years)
	Vincristine + actinomycin D		
	Velban		
Retinoblastoma (non-metastatic)	Vincristine + etoposide + carboplatin	+	+
Retinoblastoma (metastatic)	Vincristine + etoposide + carboplatin	+	+
Uveal melanoma (non-metastatic)	Multiagent	+	
Uveal melanoma (metastatic)	Multiagent	+	
Conjunctival melanoma (non-metastatic)	±	+	–
Conjunctival squamous cell carcinoma (non-metastatic)	±	+	–



and genetics is offering new classes of drugs. Exposing a tumor to a drug at a predetermined concentration over an established period results in a constant fraction of the tumor cells being killed, regardless of tumor size. This fractional cell kill hypothesis forms the rationale for repeated courses of therapy at maximum tolerated doses. Combining agents that work through concurrent and/or sequential blockade of the cell cycle as well as inhibition of specific metabolic pathways

has been a traditional approach in designing chemotherapy protocols. The use of combination chemotherapy with alternating regimens of non-cross-resistant drugs decreases the incidence of the development of drug resistance. Antineoplastic drugs have the lowest therapeutic index of any class of drug. The oncologist must balance the risk of toxicities against the risk of relapse as a result of inadequate treatment.

## REFERENCES

1. Balis F, Holcenberg J, Blaney S. General principles of chemotherapy. In: Pizzo P, Poplack D, eds. *Principles and practice of pediatric oncology*, 4th edn. Philadelphia: Lippincott, Williams & Wilkins, 2002.
2. Levien M. Clinical signs and prognostic factors in common pediatric malignancies. In: Sabella C, Cunningham R, Moodie D, eds. *Intensive review of pediatrics*. Philadelphia: Lippincott, Williams & Wilkins, 2003.
3. Berg S, Poplack D. Pharmacology of antineoplastic agents and multidrug resistance. In: Nathan D, Orkin S, Ginsberg D, Look AT, eds. *Nathan and Oski's hematology of infancy and childhood*, 6th edn. Philadelphia: WB Saunders, 2003.
4. Berger N, Lazarus H. Medical therapy of hematologic malignancies. In: Handin R, Lux S, Stosfel T, eds. *Blood, principles and practice of hematology*. Philadelphia: JB Lippincott, 1995.
5. Chabner B, Allegra C, Curt G, Calabresi P. Antineoplastic agents. In: Hardman J, Limbird L, Molinoff P et al., eds. *Goodman and Gilman's The pharmacologic basis of therapeutics*, 9th edn. New York: McGraw-Hill, 1996; 1233–1287.
6. Steinherz PG. Acute lymphoblastic leukemia of childhood. *Hematol Oncol Clin North Am* 1987; 1: 549–566.
7. Newell DR. Pharmacologically based phase I trials in cancer chemotherapy. *Hematol Oncol Clin North Am* 1994; 8: 257–275.
8. Chan HS, Gallie BL, Munier FL, Beck Popovic M. Chemotherapy for retinoblastoma. *Ophthalmol Clin North Am* 2005; 18: 55–63.

# Counseling patients with cancer

Sharon Cook and Bertil Damato

## INTRODUCTION

All those involved in cancer care need to understand their patients' needs and fears. They must also be able to recognize and respond appropriately to patients' psychological concerns. Every oncology service should have a system for providing appropriate psychological support to patients and their relatives.

## EMOTIONS AND FEARS

It is common for people with cancer to experience psychological distress, which is an understandable response to a traumatic and threatening life event (Box 11.1). On receiving a diagnosis of cancer many patients experience a range of strong emotions, such as fear, anger, sadness, and many others, which may be overwhelming in their intensity. For the majority this distress will be a short-lived experience, not causing lasting problems.<sup>1</sup> In such cases it can be understood as part of the patient's normal adjustment to their diagnosis. However, for some the diagnosis and treatment for cancer increase the risk of developing depression, anxiety, and other forms of psychological morbidity, such as adjustment disorder.

Uncertainty is always unsettling, and so it is only natural for patients to be afraid of 'the unknown' and to worry about what side effects might occur as a result of their treatment, whether their tumor will recur, and how long they might live. These valid concerns make many individuals feel 'like a walking time-bomb' or 'in limbo,' as if their life has been 'put on hold.'

Not surprisingly, the diagnosis of eye cancer comes as a shock to most patients. Many want to know why this has happened to them 'out of the blue.' They wonder whether they have done anything to deserve their illness and can feel angry, especially if they feel they have led a healthy life, so that they perceive their situation as being 'unfair.' In addition to worries about their general health and mortality, patients with ocular malignancy are concerned about loss of sight and all its implications. Some fear that they will lose their ability to work and their independence, becoming a burden to others. Their self-esteem and identity are therefore threatened.

Quite reasonably, patients are also afraid that they might lose their eye and that this may cause disfigurement, which might disrupt social relationships, work, and other important aspects of life. Many patients are concerned about the potential for tumor recurrence or metastatic disease. Therefore, although it may be a relief when treatment has ended, for some it may also raise concerns about not being watched over as carefully, as they lose the support and reassurance they received from clinicians.<sup>2</sup>

## COPING MECHANISMS

Patients develop their own individual coping mechanisms, with varying degrees of success depending on their personality, background, previous experiences of challenges, perceptions of illness, and support from family and friends. Crying and other manifestations of distress sometimes make patients feel that they are not coping, which is not the case. It is often helpful to remind people that their emotions are quite understandable given the circumstances. In the early stages some people reduce their distress by retreating into a form of temporary denial or avoidance of their illness. Such responses represent a normal psychological defense that can be adaptive in the short term. However, a complication for patients with ocular malignancy is that some common distraction strategies, such as watching TV or reading, might be difficult if vision is impaired.

## PATIENTS' NEEDS

Understandably, patients desperately want to survive and resume normal life as quickly and painlessly as possible (Box 11.2) and are anxious to do everything possible to achieve these ends. They therefore want to know that they are receiving the best possible treatment. Most want to be informed about their condition and its treatment, and are usually keen to be involved in decisions about their treatment and care. However, it should be noted that patients vary in the amount of information they want, and that this changes over time.<sup>3</sup> Furthermore, Burkitt-Wright and colleagues<sup>4</sup> highlighted the fact that although patients wish to feel involved in decision making, this does not necessarily mean they want to take responsibility for medical decisions. Above all, patients want to be treated as individuals, with dignity and respect. They wish to have their say and need to feel understood. Different patients have different needs at different stages of their illness, and psychological management needs to be responsive to this variability.<sup>5</sup>

## ELICITING AND ADDRESSING PATIENTS' EMOTIONAL NEEDS

Although the potential for psychological distress among cancer patients is recognized, in many cases it remains undetected and untreated.<sup>6</sup> Eliciting and addressing patients' emotional needs should not be considered as something separate from medical care. Instead, it should be recognised as routine clinical practice.<sup>5</sup>

However, many barriers inhibit this process, some attributable to patients' attitudes, beliefs, and behavior, and some to clinicians.<sup>7</sup> Often patients normalize or somatize their feelings, and this may reduce the

**BOX 11.1 Patients' Emotions and Fears when Informed of Their Diagnosis and Treatment**

- Uncertainty about local tumor control and survival
- Sense of 'unfairness'
- Concerns about possible loss of independence
- Fears about facial deformity

**BOX 11.2 Patients' Emotional Needs**

- Reassurance that they are receiving the best possible treatment
- Involvement in decision making
- To be treated with dignity, as individuals
- To feel they are understood

chance of their being detected. Furthermore, many feel that their concerns are silly or unreasonable, or that it is inappropriate to raise them with the clinician.<sup>7</sup> Some clinicians also feel that it is not their role to address patients' psychological needs.<sup>7</sup> They may feel uncomfortable, or may consider themselves inadequately trained to respond to emotional distress. As a result, clinicians might employ techniques such as changing the subject, ignoring the cues, normalizing distress, and/or offering false or premature reassurance, which inhibit patients' disclosure.<sup>7</sup> Practitioners may also be concerned that by responding to patients' distress they may lengthen the consultation, whereas research indicates that the opposite is often the case.<sup>8</sup>

Even when clinicians feel that it is their role to address patients' psychological concerns they sometimes lack the necessary skills or knowledge to elicit symptoms.<sup>7</sup> It is therefore important that clinicians are trained in techniques that increase their confidence and encourage rather than discourage emotional disclosure. Such techniques might include demonstrating empathy through active listening, the use of open questions, responding to emotional cues (verbal and non-verbal), acknowledging patients' distress and the use of a patient-centered consulting style.<sup>7</sup>

**COMMUNICATION**

Effective communication is the key to eliciting and addressing patients' psychological needs (Box 11.3). It also fosters good relationships between patients and carers. Patients' psychological wellbeing is greatly influenced by the way in which they are informed about their diagnosis and treatment. The manner in which healthcare staff respond to patients' concerns is also important.<sup>9,10</sup> If information is poorly communicated and patients' concerns are left undisclosed and unresolved, patients can become confused and resentful and have a high risk of developing clinical anxiety or depression.<sup>9,11</sup> Good communication can lessen distress and assist understanding and adaptation.<sup>10,11</sup>

Consequently it is important to ensure that patients receive as much information as they want and that it is provided honestly and compassionately in simple and unambiguous language.<sup>12</sup> When counseling patients about their condition, it is useful to describe the ocular anatomy and the tumor briefly, using a model eye and pictures of the

**BOX 11.3 Requirements for Effective Communication**

- Quiet surroundings, free of interruptions and distractions
- Compassion and empathy
- Close friend or relative accompanying patient
- Respect for how much they wish to know
- Opportunity to ask questions and express opinions
- Help remembering what was said
- Chance to speak to previously treated patients

tumor. Next, the patient is informed of how the tumor is likely to behave and what might happen to the eye and vision if it is not treated. This is a good lead-in to a short discussion on the objectives of treatment, explaining what is and is not achievable. The preferred treatment is introduced, together with the logistics involved (i.e. anesthesia, days in hospital etc.). Estimates of the chances of achieving the main objectives and of developing complications are given, in terms that the patient can understand. Alternative treatments are discussed, with reasons why they are less suitable than the preferred approach. The patient is then informed of plans for early after-care and long-term follow-up. The scope of adjuvant therapy and screening for metastasis is discussed. The impact of the patient's condition on driving and other activities is considered. Finally, any family implications are discussed, whether the disease is hereditary or not.

The information given to the patient should be summarized in the charts. The author has prepared a list of outcomes and complications so that any estimates given to patients are recorded. It is preferable if these discussions are conducted by a senior clinician who has special skills in counseling cancer patients. Ideally, the discussions should take place in surroundings that are quiet, private, and comfortable. Enough time for proper discussion should be allowed, and precautions should be taken to prevent interruption by non-urgent phone calls and distractions. If possible, a close relative or friend should be present. The physician should try to find out how much the patient wishes to know about prognosis and other sensitive issues, and should respect their wishes. The patient and any accompanying persons should be given plenty of opportunity to ask questions and to express their views. The physician should confirm that the patient has understood what has been said. It is often difficult for patients to remember what they were told at times of high emotion.<sup>12</sup> Therefore, for several years the author has given each new patient an audiocassette tape-recording of the actual consultation. Feedback has been positive, although a few patients have preferred not to listen to the tape.<sup>13</sup> Other useful aids to communication are a guide to the oncology service, which can be mailed to the patient before the first appointment; information leaflets specific to the selected treatment; and an information sheet regarding after-care, which is given to the patient on discharge from hospital.

Immediately after the consultation the patient and any accompanying persons should ideally spend some time with a specialist nurse in a quiet room. There are usually many questions that patients consider too trivial to trouble a doctor with, and it is often necessary for the nurse to provide consolation, reassurance, and other psychological support. Some patients find it helpful to speak to someone who has been through a similar experience, and it is useful to have a 'bank' of volunteer patients who are available on the telephone. During their

stay in hospital, patients find it reassuring when they are kept informed of how their treatment is progressing. It is well known that many patients feel particularly 'low' soon after their return home from hospital. It is therefore comforting for them to receive a telephone call from a specialist nurse at this difficult time.

Because of the rarity of ophthalmic tumors, patients find it difficult to get appropriate information and advice from their family doctor and from general ophthalmologists at their own hospital. It is therefore useful for them to be able to contact the ocular oncology service at any time if they ever have any questions or concerns. Appropriate contact information, such as telephone number or e-mail addresses, should be provided. Patients and their families should also be informed of any organizations and websites they might find helpful.

Increasingly in Britain, correspondence to the family doctor and general ophthalmologist is also sent to the patient. The author has followed this practice for several years, with positive feedback. However, the results of pathological studies, cytogenetics, and other investigations are not mailed to patients, as face-to-face communication is required when new information might cause distress.

Follow-up assessments provide a good opportunity for psychological support, and the ocular oncologist can be particularly effective in this regard, for example reminding the patient of a good prognosis that was originally given, or emphasizing that the chances of local recurrence become very small once a tumor has responded well to conservative therapy. In patients who were initially given a guarded prognosis, there might be scope for encouraging optimism once the 'danger period' has passed without incident.

## PSYCHOLOGICAL SUPPORT

As they begin to adjust to their diagnosis and its implications, patients will each face a unique set of challenges shaped by their own personal circumstances, prior experience, and beliefs.<sup>10</sup> Consequently, patients are likely to require individualized psychological support, which may change at different stages of their illness.<sup>5</sup> Because of this variability no single approach will meet the needs of all patients, and it is therefore best to view the patient as 'expert' in his or her own emotional adjustment.<sup>5</sup>

The build-up of a patient's unresolved concerns has been shown to predict later distress.<sup>9</sup> Careful assessment by interview is therefore recommended to identify and explore the specific challenges faced by each patient; the availability of emotional support; and the patient's ability to use different ways of coping. It may be helpful at this time to engage with patients in problem solving, including identifying and accessing sources of practical and emotional support; and considering alternative coping responses that may reduce the emotional impact of their illness, as well as promoting adaptation. Eventually, in a supportive environment most patients will adjust to their condition and its implications in their own time.<sup>5</sup> However, some may require more specialized help (Box 11.4).

## SELF-HELP

Every opportunity should be taken to encourage and facilitate self-help. There are many ways in which patients can improve their own wellbeing, and most are successful in discovering their individual ways of coping. Patients seem to do particularly well if they feel that some good has come out of their crisis, for example discovering what is and what is not important in their life, helping others, fundraising, and getting closer to their friends and family. Many patients find it helpful to write down their experiences, and so this idea should be given to

### BOX 11.4 Patients Requiring Additional Psychological Support

- Failing to adjust over time
- Experiencing an intense emotional reaction that compromises their mechanisms for family and social support
- 'Stuck' in a way that is likely to inhibit future adjustment
- Experiencing emotional problems that are unlikely to resolve over time in a supportive environment

### BOX 11.5 Considerations for Providing Effective Psychological Care

- Appropriate training of all staff coming into contact with patients, so that distress can be recognized
- Mechanisms to empower patients to recognize and manage their own psychological needs
- Protocols for assessing all patients psychologically at key points in their care pathway
- Protocols for providing psychological support that is appropriate to the severity of any distress, with mechanisms for organizing specialist care if needed
- Information on how to contact emergency psychiatric services, readily available wherever patients are at risk of self-harm
- Systems enabling patients and caregivers to participate in their own care, in self-help activities, and peer support
- Mechanisms for ensuring that the psychological needs of staff caring for patients and caregivers are adequately met

new patients in case the thought of a diary might not occur to them. All patients should also be informed of any self-help groups that are available, both in their community and on the internet. Considerations for organizing effective psychological care to be available to patients with eye cancer are summarized in Box 11.5.

## CHILDREN WITH CANCER – WHAT SHOULD THEY BE TOLD ?

It is difficult to speak to a child about cancer and its implications. However, even very young children can sense fear and anxiety among family members.<sup>10</sup> If children are deprived of information about what is happening they may generate their own ideas, causing them to fantasize or worry. Consequently, it is generally recommended that parents be as honest as possible with their child, allowing them to openly express fears and ask questions.<sup>14</sup>

However, parents know their children better than anyone else; therefore, their judgement of what is the right thing to do for their child and how much they should tell them should be supported and encouraged.<sup>10</sup> In a recent study of parents who had lost a child to cancer, it was observed that of all those who talked to their child about the fact that they were dying ( $n = 147$ ) had no regrets about having



done so,<sup>15</sup> but some parents, who had decided not to talk to their child about death, subsequently wished they had done (n = 69 of 258). Clearly, the clinician's aim in such circumstances should be to help people make the best decision for their family.<sup>14</sup>

As with adults, when providing any information to a child it is clearly important to use language that can be understood.<sup>5</sup> It should

be noted that children are developing all the time, and so information considered appropriate at one age may no longer be sufficient as the child gets older.<sup>10</sup> Therefore, it is important to establish the child's intellectual capacity as well as their level of understanding of the illness or treatment in question. Explanation and reassurance can then be provided in ways that make sense to the child.<sup>5</sup>

## REFERENCES

- White CA. Cognitive behaviour therapy for chronic medical problems. Chichester: Wiley, 2001.
- Back AL, Arnold RM, Baile WF, Tulsky JA, Fryer-Edwards K. Approaching difficult communication tasks in oncology. *CA Cancer J Clin* 2005; 55: 164–177.
- Leydon GM, Boulton M, Moynihan C et al. Cancer patients' information needs and information seeking behaviour: in depth interview study. *Br Med J* 2000; 320: 909–913.
- Wright EB, Holcombe C, Salmon P. Doctors' communication of trust, care, and respect in breast cancer: qualitative study. *Br Med J* 2004; 328: 864.
- Salmon P. The psychology of medicine and surgery: a guide for psychologists, doctors, nurses and counsellors. Chichester: Wiley, 2000.
- Maguire P. Improving the detection of psychiatric problems in cancer patients. *Soc Sci Med* 1985; 20: 819–823.
- Ryan H, Schofield P, Cockburn J et al. How to recognize and manage psychological distress in cancer patients. *Eur J Cancer Care (Engl)* 2005; 14: 7–15.
- Butow PN, Brown RF, Cogar S, Tattersall MH, Dunn SM. Oncologists' reactions to cancer patients' verbal cues. *Psychooncology*. 2002; 11: 47–58.
- Maguire P. Breaking bad news. *Eur J Surg Oncol* 1998; 24: 188–191.
- Brennan J. *Cancer in context*. Oxford: Oxford University Press, 2004.
- Fallowfield L, Jenkins V. Communicating sad, bad, and difficult news in medicine. *Lancet* 2004; 363: 312–319.
- Kim MK, Alvi A. Breaking the bad news of cancer: the patient's perspective. *Laryngoscope* 1999; 109: 1064–1067.
- Ah-Fat FG, Sharma MC, Damato BE. Taping outpatient consultations: a survey of attitudes and responses of adult patients with ocular malignancy. *Eye* 1998; 12: 789–791.
- Editorial. Discussing death with a dying child. *CA Cancer J Clin* 2005; 55: 2–3.
- Kreicbergs U, Valdimarsdottir U, Onelov E, Henter JI, Steineck G. Talking about death with children who have severe malignant disease. *N Engl J Med* 2004; 351: 1175–1186.

# Examination techniques

Julian D. Perry

## INTRODUCTION

Neoplasia can develop within any of the eyelid structures. Examination of the eyelid is relatively straightforward, given the anterior location and the ability to visualize both anterior and posterior surfaces. However, structures of the eyelid, such as the levator muscle and preaponeurotic fat, are in continuity with the orbit, and tumors of the eyelid may develop posterior extension. This is especially true in the medial canthus, where the orbital septum is less robust. The examination of an eyelid tumor determines the need for any ancillary tests and the surgical plan.

## HISTORY

The history begins with a description of the symptoms and their severity, onset, and rate of progression. A targeted review of systems reveals additional clues to the etiology.

**Presenting symptoms** Eyelid neoplasia presents with a limited spectrum of symptoms (Box 12.1). Most often, the structural symptoms are an abnormal appearance of the eyelid or asymmetry compared to the fellow lid. The lid may harbor a distinct lesion, with elevation, ulceration, crusting, bleeding, altered pigmentation, telangiectasia, or other visible cutaneous changes. The patient may complain of loss of eyelashes or an irregularity along the lid margin.

Eyelid neoplasia may produce symptoms that occur with or without structural symptoms. Sensory symptoms such as pain, tenderness, itching, or visual changes due to keratopathy, induced astigmatism, or obstruction of vision may develop. Motor symptoms, such as blepharoptosis or lagophthalmos, may develop owing to involvement of the eyelid retractors and protractors, or indirectly from a mass effect. Functional symptoms develop from mechanical keratoconjunctivitis, exposure keratopathy, or decreased lacrimal outflow.

**Rate of onset** and progression helps characterize the pathology. Most symptoms from eyelid tumors develop over weeks to months; however, associated hemorrhage, infection, or inflammation can produce acute symptoms. Both benign (angiomas, papillomas) and malignant (cutaneous malignancies, metastases) eyelid tumors can produce hemorrhage. Any eyelid tumor that blocks lacrimal outflow or causes diminished cutaneous integrity can result in infection. Several eyelid tumors, such as keratoacanthoma, may be associated with a significant inflammatory reaction.

**Past medical history** Because the majority of eyelid neoplasia are epidermal in origin, the past medical history should focus on risk factors for epidermal malignancy. Information should be obtained regarding family history of cutaneous malignancy, skin type, freckle density, eye color, hair color, and prior history of skin cancer. Patients of Celtic or Scandinavian descent with red hair, blue eyes, and fair skin carry a higher risk for cutaneous malignancy.<sup>1,2</sup> The history should also describe tobacco use, prior radiotherapy, sun exposure, and similar growths elsewhere on the skin.

## EXAMINATION

The physical examination of an adult with suspected eyelid neoplasia does not end with direct visualization of the lesion. It should include a comprehensive inspection of the eyelid, ocular adnexa and orbit, eye, and other cutaneous lesions described in the history.

**Eyelid examination** The patient should point out smaller lesions to the examiner using a hand mirror. The entire face should be evaluated to note Fitzpatrick skin type and any other cutaneous lesions. The eyelid examination should characterize the appearance of the lesion as well as associated anatomical deformities and palpation. The dimensions should be measured using a ruler or slit lamp beam. Areas of telangiectasia, nodularity, pearly translucency, ulceration, bleeding, crusting, irregularity of the eyelid margin, and loss of cilia should be particularly looked for, as these features are suggestive of malignancy (Fig. 12.1; Box 12.2). Palpation results should refer to the mobility of the lesion or associated tenderness. Any color change should be noted.

Levator function, orbicularis function, and corneal sensation should all be tested. Any lagophthalmos should be measured.

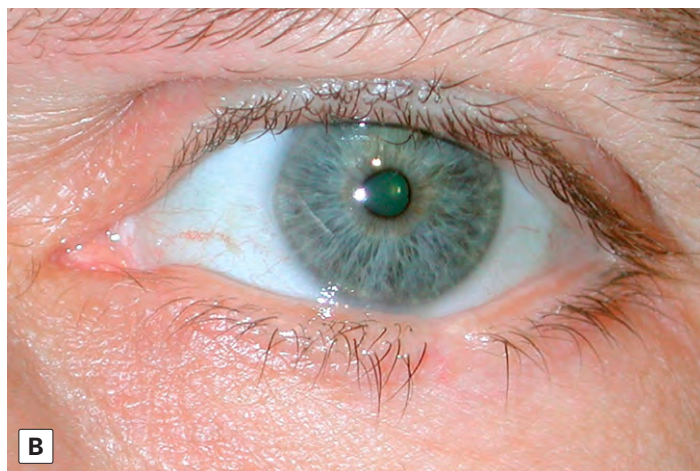
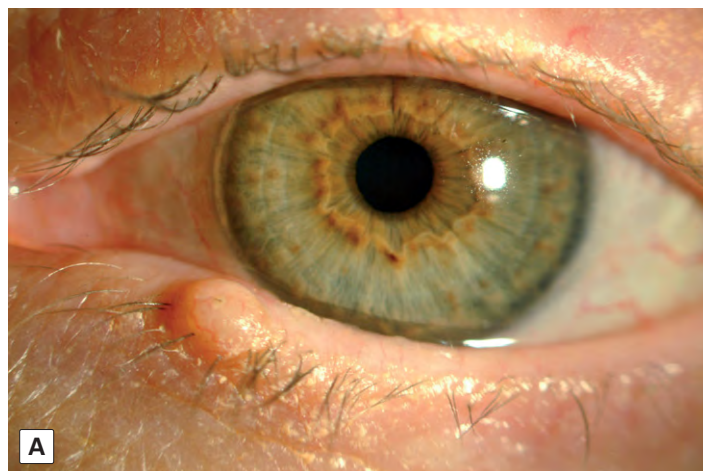**Ocular adnexal examination** Eyelid tumors may spread directly to the lacrimal gland, orbit, or lacrimal outflow apparatus. Conversely, primary tumors of these areas can occasionally present with only eyelid signs and symptoms. The structure and function of the orbit and ocular adnexal tissues in proximity to the lesion should be evaluated. The examiner should palpate for preauricular, submandibular, and supraclavicular adenopathy. Cranial nerves V and VII should be tested carefully to assess for possible perineural spread of an eyelid malignancy.

**BOX 12.1 Symptoms of Eyelid Neoplasia**

- Sensory: tenderness, itching, visual changes
- Motor: ptosis, lagophthalmos
- Structural: visible or palpable lesion, change in symmetry
- Functional: keratopathy or tearing
- Secondary: pigmentation, lymphadenopathy

**BOX 12.2 Signs of Malignant Eyelid Tumor**

- Telangiectasia
- Nodularity, pearly translucency
- Ulceration, bleeding, crusting, margin notch
- Loss of cilia
- Effacement of meibomian gland orifice



**Fig. 12.1** Lower eyelid showing a benign nodule without loss of lashes (A) and loss of eyelid tissue with cilia loss secondary to a malignant tumor (B).

**Eye examination** should focus on detecting findings caused by or associated with the eyelid lesion. The conjunctiva and cornea should be inspected for signs of mechanical or exposure keratoconjunctivitis using the slit lamp. The sclera and episclera should be observed for pigmentary changes during the evaluation of an eyelid nevus. Direct intraocular extension of eyelid tumors is extremely rare, but funduscopy should be performed to observe for signs of ocular or orbital involvement (choroidal folds, venous congestion) in suspected cases.

### DIAGNOSTIC EVALUATION

Ancillary testing is occasionally required during the clinical evaluation of a suspected eyelid tumor. If an eyelid granuloma is suspected, elevated cANCA titers may reflect underlying Wegener's granulomatosis, or high angiotensin-converting enzyme levels may point to sarcoidosis. If the examination reveals associated orbital or lacrimal outflow signs, CT or MR imaging may help to determine the extent of the lesion.

Dermoscopy represents an *in vivo* non-invasive technique that may improve the clinical accuracy in diagnosing melanoma and other pigmented skin lesions. Optical coherence tomography may represent a new and promising technique for non-invasive investigation of skin tumors. Although non-invasive techniques should improve diagnostic ability, the clinical diagnosis of eyelid tumors is imperfect and biopsy remains the gold standard.

### BIOPSY

Based on clinical examination, the histopathologic accuracy of suspected benign lesions is about 98%, and only 90% for lesions clinically suspected to be malignant.<sup>3</sup> Malignant lesions can be clinically misdiagnosed as benign, especially when they are small and have nondescript surface features, thereby emphasizing the need for a confirmatory histology via incisional or excisional biopsy.<sup>3,4</sup> Tumor location and the presumptive clinical diagnosis largely dictate the approach and technique. For smaller lesions, excisional biopsy is preferred. Epidermal malignancies require margin-controlled excision and repair. Melanoma, sebaceous cell carcinoma, and Merkel cell carcinoma require excision with wide margins. Some tumors, such as capillary hemangioma or keratoacanthoma, may resolve spontaneously or require surgical or other treatment. Surgical techniques are discussed in Chapter 21.

### CONCLUSION

A systematic approach to the evaluation of eyelid neoplasms allows the clinician to diagnose and treat these tumors efficiently. Current clinical diagnostic techniques remain inaccurate, and the clinician should often consider performing a biopsy. The future calls for less invasive diagnostic and therapeutic techniques, as well as prevention and improved early detection to limit the morbidity of these common tumors.

---

**REFERENCES**

1. Gandini S, Sera F, Cattaruzza MS et. al. Meta-analysis of risk factors for cutaneous melanoma: III. Family history, actinic damage and phenotypic factors. *Eur J Cancer* 2005; 41: 2040–2059.
2. Cook BE, Bartley GB. Epidemiologic characteristics and clinical course of patients with malignant eyelid tumors in an incidence cohort in Olmsted County, Minnesota. *Ophthalmology* 1999; 106: 746–750.
3. Kersten RC, Ewing-Chow D, Kulwin DR, Gallon M. Accuracy of clinical diagnosis of cutaneous eyelid lesions. *Ophthalmology* 1997; 104: 479–484.
4. Margo CE. Eyelid tumors: accuracy of clinical diagnosis. *Am J Ophthalmol* 1999; 128: 635–636.



# Classification and differential diagnosis of eyelid tumors

Jacob Pe'er

## INTRODUCTION

Despite being a small organ, the eyelid contains numerous histological elements that can be the origin of several types of benign or malignant tumors. In this chapter we review the basic anatomy of the eyelid, outline a clinically relevant classification of eyelid tumors, and briefly discuss their differential diagnosis.

## ANATOMICAL FEATURES

The eyelids are composed of four layers: skin and subcutaneous tissue, striated muscle (orbicular oculi), tarsus, and conjunctiva.<sup>1</sup> The rest of the orbital entrance, which clinically may be considered as part of the eyelids, is covered, behind the skin and the orbicularis muscle, by the orbital septum that holds back the orbital fat (Fig. 13.1).

**Eyelid skin** especially that of the lower eyelid, is among the most sunlight-exposed anatomical structures. The eye and the eyelids are one of the most observed parts of the eye, and therefore eyelid tumors are usually diagnosed at an early stage. The eyelid skin is the thinnest in the body and lacks subcutaneous fat, but otherwise contains all other skin structures. In the pretarsal part the skin and orbicular oculi muscle are normally firmly attached to the tarsal plate, whereas in the preseptal part they are more loosely attached. The skin epithelium is keratinized stratified squamous epithelium, the origin of all types of benign and malignant epidermal tumor. Melanocytes are spread in the basal layer of the epithelium, and may give rise to melanocytic cutaneous lesions. The dermis contains also fibrous tissue, blood and lymphatic vessels, and nerves, that can give rise to many types of fibrous tissue tumor, fibrohistiocytic tumors, vascular tumors, and neural tumors.

**Adnexal glands** The eyelids are rich in glandular tissue that may be the origin of various glandular tumors. Eccrine gland tumors may arise from the sweat glands of the eyelid skin, as well as from the accessory lacrimal glands of Krause and Wolfring. The gland of Moll can give rise to apocrine tumors. The sebaceous glands of Zeis and the meibomian gland are the origin of sebaceous gland tumors.

**Orbicularis oculi** The entire orbital entrance is covered by the orbicularis oculi, a striated muscle that is divided into pretarsal and preseptal parts which are part of the eyelids and are involved in eyelid

movement, and the orbital part that is located over the external orbital bones.

**Tarsus** The tarsi are firm plates composed of dense connective tissue that serve as the skeleton of the eyelids. The upper tarsal plates are much larger than the lower ones. The meibomian glands, large sebaceous glands, are embedded in the connective tissue of the tarsal plates. The superior tarsal muscle (Muller's muscle), a smooth muscle, is attached to the upper margin of the tarsus. The upper and lower orbital septum, a thin sheet of fibrous tissue, arises from the periosteum in the orbital rim and fuses with the levator aponeurosis superiorly and the lower margin of the lower tarsus inferiorly. All these histological structures can give rise to rare fibrous, striated and smooth muscle and glandular tumors. The orbital fat behind the septum and the fat under the orbital part of the orbicularis oculi can be the origin of rare lipomatous tumors.

**Palpebral conjunctiva** The posterior eyelid surface is lined by the conjunctiva, a translucent mucous membrane that is composed of epithelium and subepithelial stroma – the substantia propria. The anatomical and histological features of the conjunctiva and the possible tumors that can originate from this tissue are described elsewhere (see Chapter 23).

**Eyelid margin** is a flat area on the edge of each eyelid. The anatomical structures that are seen in the margin from the skin backwards are the eyelashes and their lash follicles; the gray line, which consists of the tips of the pretarsal orbicularis muscle – the muscle of Riolan; the meibomian gland orifices; and the mucocutaneous junction just posterior to them.

**Vascular system** The venous and lymphatic drainage is important in understanding the routes of possible eyelid tumor metastases. The eyelid has extensive vascularity that comes from two main sources, the internal carotid and external carotid arteries, with anastomoses between these two systems. The venous drainage is into the angular vein medially, the superficial temporal vein laterally, and the orbital veins, anterior facial vein, and pterygoid plexus posteriorly. The lymphatic drainage of the medial portions of the eyelids is into the sub-mandibular lymph nodes, and of the lateral portions into the superficial preauricular nodes, and then into the deeper cervical nodes.

**Nerve supply** The sensory nerve supply to the eyelids is from the fifth cranial nerve and the motor nerve supply to the striated muscles is from the third and seventh cranial nerves, and to the smooth muscles from sympathetic nerves.

### CLASSIFICATION OF EYELID TUMORS

Like tumors in other organs, tumors of the eyelid may be classified according to their tissue or cell of origin, and as benign or malignant. In most groups of tumors, unique histological subtypes behave differently in spite of having the same cell of origin.

The classification of eyelid tumors that appears in this section is based primarily on the second edition of the “Histological typing of tumours of the eye and its adnexa” in the World Health Organization

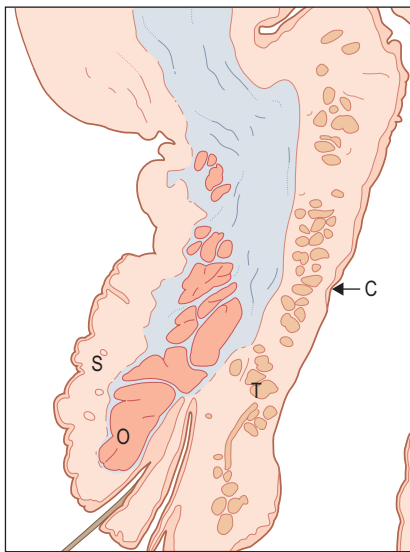
(WHO) International Histological Classification of Tumours series (Table 13.1).<sup>2</sup> The epithelial tumor classification has been modified and divided into groups according to the cell of origin. Some tumors that are missing from the WHO list have been added from other sources.<sup>3,4,5</sup>

The vast majority of eyelid tumors, benign and malignant, are of cutaneous origin, mostly epidermal. They are divided into non-melanocytic and melanocytic, based on the presence or absence of melanocytic proliferation (Table 13.2). Benign epithelial proliferations, basal cell carcinoma, cystic structures and melanocytic nevi represent about 85% of all eyelid tumors.<sup>6,7</sup> Squamous cell carcinoma and melanoma are relatively rare.<sup>7</sup> Tumors arising from adnexal glands (Table 13.3), fibrous tissue and fibrohistiocytic tumors (Table 13.4), and other stromal tissues are very rare (Tables 13.5, 13.6).

### DIFFERENTIAL DIAGNOSIS

**Epidermal non-melanocytic tumors** The most common benign epithelial tumor is the squamous papilloma, which is often sessile or pedunculated with a papillary shape and keratinized surface (Table 13.2). Squamous papillomata may be multiple. Other epithelial tumors, including the premalignant actinic keratosis that may be multiple or small squamous cell carcinoma, may look similar. Basal cell carcinoma (BCC) comprises over 90% of all malignant eyelid tumors.<sup>7</sup> Its common location is the lower eyelid and medial canthus; it is usually firm, and often has an ulcerated center. Other ulcerated eyelid tumors, such as keratoacanthoma or the more rare papillary syringadenoma, should be differentiated from BCC. Features of keratoacanthoma, such as rapid growth and possible spontaneous regression, can help in its diagnosis.

**Epidermal melanocytic tumors** The most common pigmented eyelid lesions are the nevi, which are usually flat or mildly elevated and can appear anywhere in the eyelid in any size, and when they appear on the eyelid margin they can be sessile (Table 13.2). Congenital nevi usually appear at birth, and acquired nevi between the ages of 5 and 10 years. Nevi should be differentiated on the one hand from flat epithelial pigmentation such as ephelis or freckles, and on



**Fig. 13.1** A cross-section through the eyelid. S-skin, O-orbicularis oculi muscle, T-tarsal plate, C-conjunctiva.

**Table 13.1** Major types of eyelid tumors

Category	Subtypes	
Epidermal tumors	Non-melanocytic tumors	Melanocytic tumors
Adnexal tumors	Sebaceous gland tumors	Hair follicle tumors
	Sweat gland tumors	Cystic lesions
Stromal tumors	Fibrous tissue tumors	Fibrohistiocytic tumors
	Lipomatous tumors	Neural tumors
	Smooth muscle tumors	Skeletal muscle tumors
	Vascular tumors	Perivascular tumors
	Lymphoid and plasmacytic	Cartilage and bone tumors
	Hamartoma	Choristoma
Secondary tumors		
Metastatic tumors		
Inflammatory and infectious lesions that simulate neoplasms		

Table 13.2 Classification of epidermal tumors		
Category		Subtypes
Non-melanocytic	Benign	Squamous cell papilloma
		Seborrheic keratosis
		Inverted follicular keratosis
		Keratoacanthoma
		Reactive hyperplasia (pseudoeplitheliomatous hyperplasia)
	Premalignant	Actinic (solar) keratosis
		Intraepithelial neoplasia
		Sebaseous nevus (of Jadassohn)
	Malignant	Basal cell carcinoma
		Squamous cell carcinoma
Melanocytic	Epithelial pigmentation	Ephelis or freckles
		Lentigo simplex
		Solar lentigo
	Benign	Junctional nevus
		Intradermal nevus
		Compound nevus
		Spitz nevus
		Balloon cell nevus
		Blue nevus
		Cellular blue nevus
		Oculodermal nevus of Ota
		Congenital dysplastic nevus
	Premalignant	Lentigo maligna (melanotic freckle of Hutchinson)
		Melanoma arising from nevi
	Malignant	Melanoma arising in lentigo maligna
		Melanoma arising de novo

Table 13.3 Classification of adnexal and cystic tumors		
Category		Subtypes
Sebaceous gland tumors	Benign	Sebaceous gland hyperplasia Sebaceous gland adenoma
	Malignant	Sebaceous gland carcinoma
Sweat gland tumors	Benign	Syringoma
		Papillary syringadenoma
		Eccrine spiradenoma
		Eccrine acrospiroma
		Pleomorphic adenoma (benign mixed tumor)
		Eccrine cylindroma
		Apocrine adenoma
		Other benign tumors
		Malignant
	Hair follicle tumors	Benign
Trichofolliculoma/trichoadenoma		
Trichilemmoma		
Malignant		Pilomatrixoma (calcifying epithelioma of Malherbe)
		Carcinoma of hair follicles
		Other cystic lesions
Other cystic lesions	Benign	Epidermal inclusion cyst Sebaceous cyst Retention cyst Eccrine hydrocystoma Apocrine hydrocystoma Trichilemmal cyst Other benign cystic lesions

the other hand from the flat premalignant lentigo maligna, or from malignant melanoma, which is relatively rare in the eyelids.

**Adnexal and cystic tumors** The eyelid adnexa include many different glands that are the origin of various benign and malignant tumors (Table 13.3). These include cystic lesions such as eccrine and apocrine hydrocystoma, which are totally benign and may be transparent, or have a distinct color, such as the blue apocrine hydrocystoma. On the other hand, there are very malignant solid sebaceous gland carcinomas that may resemble chalazion, but unlike chalazion cause loss of eyelashes.

**Stromal tumors** usually have a smooth surface, being under the skin (Tables 13.4–13.6). The tumor elevation may have normal skin color, but many of the tumors will have a distinct color. Xanthomatous lesions are usually yellow. Most hemangiomas, diffuse or localized,

are red. Subcutaneous varix is soft and blue, and Kaposi's sarcoma is blue or red. Merkel cell tumor is red or violaceous. Sometimes also subcutaneous tumors can be sessile or even ulcerated, so such phenomena, which are usually seen in epidermal tumors, should not exclude their diagnosis.

**Inflammatory and infective simulating conditions** The differential diagnosis of eyelid tumors should include lesions that simulate tumors. The most common simulating lesions are inflammatory lesions such as chalazion or pyogenic granuloma, or infectious viral lesions such as molluscum contagiosum or verruca vulgaris, which is clinically and histologically similar to squamous papilloma. Many dermatological diseases, such as amyloidosis, malakoplakia, and others, or connective tissue disease and systemic metabolic diseases such as hemochromatosis, may sometimes simulate eyelid tumors and should be differentiated from them.

**Table 13.4 Classification of fibrous, fibrous histiocytic, and muscular tumors**

Origin	Type	Tumor	
Fibrous	Benign	Fibroma	
		Keloid	
		Nodular fasciitis	
		Proliferative fasciitis	
		Fibromatosis	
Fibrous histiocytic	Malignant	Fibrosarcoma	
		Congenital fibrosarcoma	
		Benign	Xanthelasma
			Xanthoma
			Dermatofibroma
Xanthogranuloma			
Fibrous histiocytic	Intermediate	Juvenile xanthogranuloma	
		Necrotic xanthogranuloma	
		Reticulohistiocytoma	
		Atypical fibroxanthoma	
		Dermatofibrosarcoma protuberans	
Fibrous histiocytic	Malignant	Angiomatoid fibrous histiocytoma	
		Malignant fibrous histiocytoma	
		Malignant giant cell fibrous histiocytoma	
		Malignant fibroxanthoma	
		Smooth muscle	Benign
Angiomyoma			
Smooth muscle	Malignant	Leiomyosarcoma	
		Skeletal muscle	Benign
Skeletal muscle	Malignant		

**Table 13.5 Classification of vascular/perivascular tumors**

Category		Subtypes	
Vascular	Benign	Nevus flammeus (port-wine stain)	
		Papillary endothelial hyperplasia	
		Capillary hemangioma	
		Cavernous hemangioma	
		Venous hemangioma	
		Epithelioid hemangioma (angiolymphoid hyperplasia)	
		Arteriovenous malformation	
		Lymphangioma	
		Malignant	Angiosarcoma
			Lymphangiosarcoma
		Perivascular	Benign
	Hemangiopericytoma		
	Glomus tumor		
Malignant	Malignant hemangiopericytoma		
	Malignant glomus tumor		

**Table 13.6 Classification of neural tumors**

Category	Subtypes
Benign	Traumatic neuroma
	Neurofibroma
	Plexiform neurofibroma
	Schwannoma (neurilemmoma)
	Others, e.g. neuroglial choristoma
Malignant	Malignant peripheral nerve sheath tumor
	Merkel cell tumor



**REFERENCES**

1. Bedrossian EH. Embryology and anatomy of the eyelid. In: Tasman W, Jaeger EA. Duane's foundation of clinical ophthalmology. Volume 1: Ocular anatomy, embryology and teratology. Philadelphia: Lippincott Williams & Wilkins, 2004; 1–24.
2. Campbell RJ, Sobin LH. Tumours of the eyelid. Histological typing of tumours of the eye and its adnexa, 2nd edn. World Health Organization International Histological Classification of Tumors. Berlin: Springer Verlag, 1998; 3–9.
3. Hassan AS, Nelson CC. Benign eyelid tumors and skin diseases. *Int Ophthalmol Clin* 2002; 42: 135–149.
4. Soparkar CN, Patrinely JR. Eyelid cancers. *Curr Opin Ophthalmol* 1998; 9: 49–53.
5. Shields JA, Shields CL. Atlas of eyelid and conjunctival tumors. Philadelphia: Lippincott Williams & Wilkins, 1999; 3–189.
6. Kersten RC, Ewing-Chow D, Kulwin DR, Gallon M. Accuracy of clinical diagnosis of cutaneous eyelid lesions. *Ophthalmology* 1997; 104: 479–484.
7. Cook BE, Bartley GB. Epidemiologic characteristics and clinical course of patients with malignant eyelid tumors in an incidence cohort in Olmsted County, Minnesota. *Ophthalmology* 1999; 106: 746–750.

# Benign epidermal tumors

Edoardo Midena, Valentina de Belvis, Lynn Schoenfield and Arun D. Singh

## INTRODUCTION

Benign tumors of the eyelid include a variety of epidermal tumors, adnexal tumors (Chapter 19), and stromal tumors (Chapter 20). The benign epidermal tumors of the eyelid are similar to those observed in the other sun-exposed areas of the skin. Some benign eyelid lesions may represent manifestations of systemic disease (Chapter 22). A classification of epidermal eyelid tumors is presented in Table 14.1. Only the most common and frequently observed benign and premalignant epidermal tumors (non-melanocytic and melanocytic) are described in this chapter.

## NON-MELANOCYTIC BENIGN EPIDERMAL TUMORS

**Squamous cell papilloma** are common benign tumors of the eyelid that occur in middle-aged or older adults.

**Clinical features** Appearance of either a pedunculated or a sessile nodular growth with a convoluted surface.

**Histopathologic features** Benign squamous epithelium with variable acanthosis and hyperkeratosis overlies a fibrovascular core (Fig. 14.1).

**Treatment** If symptomatic, surgical excision is usually performed.

**Seborrheic keratosis** are commonly acquired eyelid lesions affecting middle-aged and elderly patients.

**Clinical features** The clinical appearance varies considerably in terms of size and degree of pigmentation, making it sometimes difficult to differentiate from nevi, pigmented basal cell carcinoma, and melanoma.<sup>1</sup> Eyelid lesions usually appear lobulated, papillary or pedunculated, with friable, cerebriform excrescences on the surface (Fig. 14.2).

**Histopathologic features** Seborrheic keratoses are divided into several types according to the predominant histologic features: hyperkeratotic, acanthotic, adenoid, clonal, inflamed, and irritated (Fig. 14.2). They are usually hyperpigmented and variable degrees of hyperkeratosis and acanthosis are observed in all types.

**Treatment** Surgical excision involves shaving the lesions from the skin surface. Even in large lesions the growth pattern is superficial, therefore deep excision is unnecessary.

**Inverted follicular keratosis** is commonly seen on the face, and the eyelid margin is a frequent site of involvement.<sup>2</sup>

**Clinical features** Usually a solitary lesion of recent onset (less than 3 months), it may be nodular, papillomatous, or cystic in appearance. Inverted follicular keratosis can be easily mistaken for squamous cell carcinoma.

**Histopathologic features** Histopathologically, it demonstrates acanthosis, a hyperkeratotic endophytic growth pattern, and squamous eddies (Fig. 14.3). For lesions arising in the eyelid region an endophytic growth pattern may not be present. Moreover, it appears that these lesions do not arise from follicles but rather from basal and squamous cells. Therefore, inverted follicular keratosis is a misnomer and alternative terminology includes irritated seborrheic keratosis or seborrheic wart.<sup>3</sup>

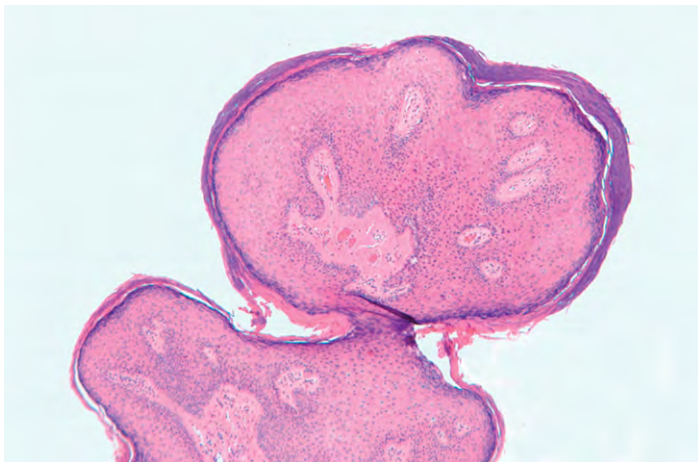
**Treatment** Complete excision should be performed.

**Keratoacanthoma** Although trauma and sunlight exposure have been implicated in the pathogenesis of keratoacanthoma, the exact etiology remains unknown.<sup>4</sup> Middle-aged or elderly patients are typically affected, males more frequently than females.

**Clinical features** The lesion begins as a small flesh-coloured papule on the lower lid that develops rapidly over the course of a few weeks into a cup-shaped configuration with a central, keratin-filled crater and elevated rolled margins (Fig. 14.4). Gradual resolution over the course of 3–6 months ensues, and macroscopic sequelae are rare (generally a mildly depressed scar). Multiple keratoacanthomas may be a marker for internal neoplasms such as in Muir–Torre syndrome (Chapter 22).<sup>5</sup> Other forms of multiple keratoacanthoma include Ferguson–Smith syndrome, an autosomal dominant disease characterized by multiple large lesions.<sup>6</sup> Other variants, such as eruptive keratoacanthoma and giant keratoacanthoma, are rare.<sup>4</sup>

**Histopathologic features** A keratoacanthoma typically has a dome-shaped nodular elevation with thickening of the epidermis. The epidermis contains islands of well-differentiated squamous epithelium surrounding a central mass of keratin (Fig. 14.4). Microabscesses may be present within the islands of squamous epithelium. The dermis shows a polymorphous inflammatory infiltrate. Observation has been advocated, but the prolonged healing period and the potential delay

Table 14.1 Classification of epidermal tumors of the eyelid		
Types		Subtypes
Non-melanocytic	Benign	Squamous cell papilloma
		Seborrheic keratosis
		Inverted follicular keratosis
	Premalignant	Reactive hyperplasia (pseudoepitheliomatous hyperplasia)
		Actinic (solar) keratosis
		Intraepithelial neoplasia
Malignant	Sebaceous nevus (of Jadassohn)	
	Basal cell carcinoma	
	Squamous cell carcinoma	
Melanocytic	Epithelial pigmentation	Keratoacanthoma
		Ephelis or freckles
		Lentigo simplex
	Benign	Solar lentigo
		Junctional nevus
		Intradermal nevus
		Compound nevus
		Spitz nevus
		Balloon cell nevus
		Blue nevus
		Cellular blue nevus
		Oculodermal nevus of Ota
	Premalignant	Congenital dysplastic nevus
		Lentigo maligna (melanotic freckle of Hutchinson)
	Malignant	Melanoma arising from nevi
Melanoma arising in lentigo maligna		
Melanoma arising de novo		



**Fig. 14.1** Squamous papilloma. Polypoid lesion consisting of benign squamous epithelium with variable acanthosis and hyperkeratosis overlying a fibrovascular core. (Hematoxylin and eosin; original magnification  $\times 4$ .)

in treatment of a misdiagnosed malignancy justify a more definitive treatment strategy.<sup>7</sup>

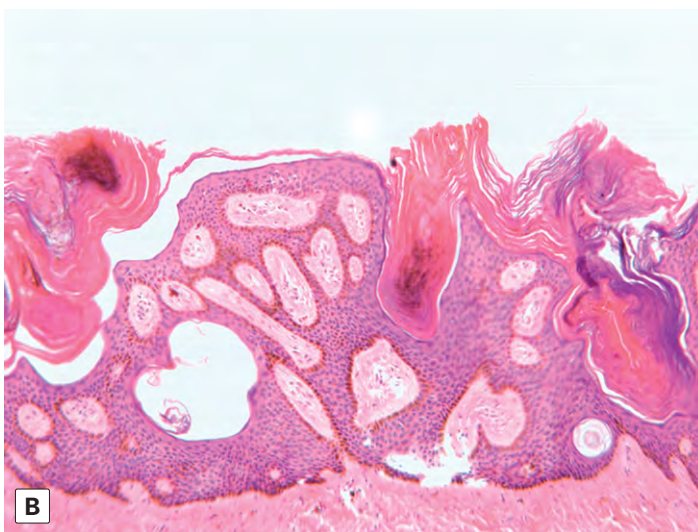
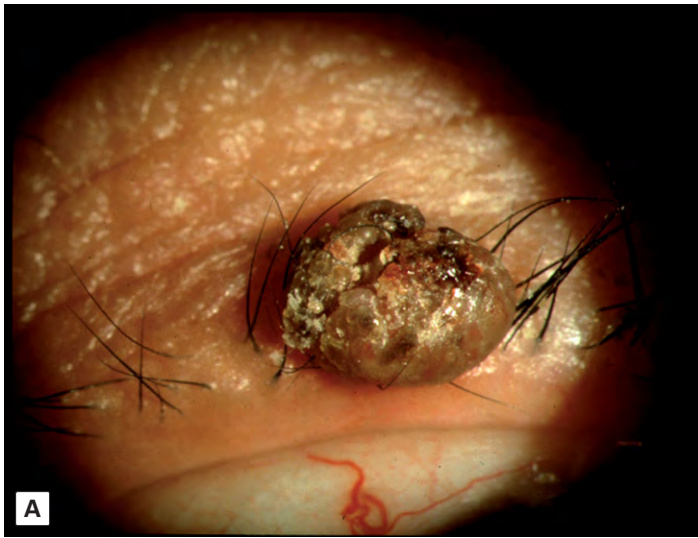
**Treatment** As keratoacanthoma is now considered a variant of squamous cell carcinoma (keratocarcinoma)<sup>4,8</sup> or keratoacanthoma-like squamous cell carcinoma, excisional biopsy should be performed.<sup>9</sup> Multiple or diffuse lesions need diagnostic incisional biopsy. If the diagnosis is confirmed, complete surgical excision is the recommended treatment.<sup>10</sup> Alternative treatment modalities include radiotherapy, cryotherapy, and topical or intralesional 5-fluorouracil.

**Reactive hyperplasia (pseudoepitheliomatous hyperplasia)** Epithelial hyperplasia typically occurs as a reaction to surgical wound, cryotherapy, burn, radiation, or fungal infection.

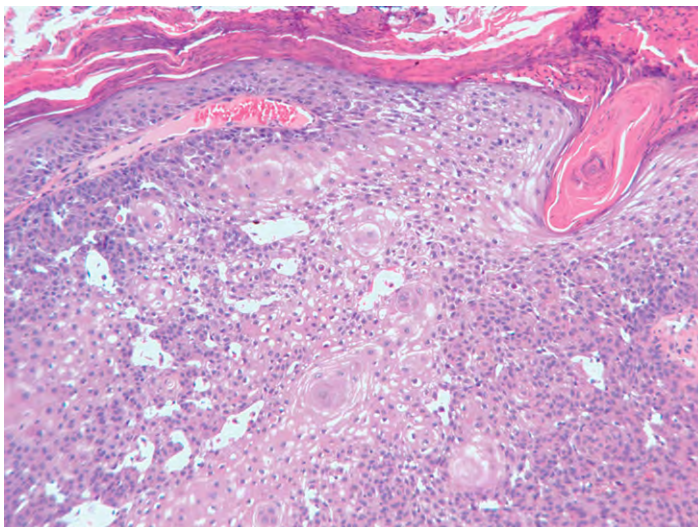
**Clinical features** An elevated nodular or ulcerative lesion resembling basal or squamous cell carcinoma.

**Histopathologic features** There is epidermal hyperplasia with elongated and sometimes anastomosing rete ridges, acanthosis, and

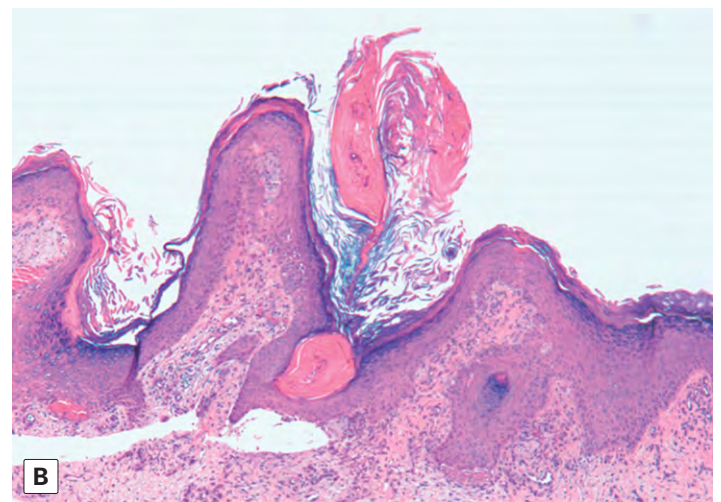
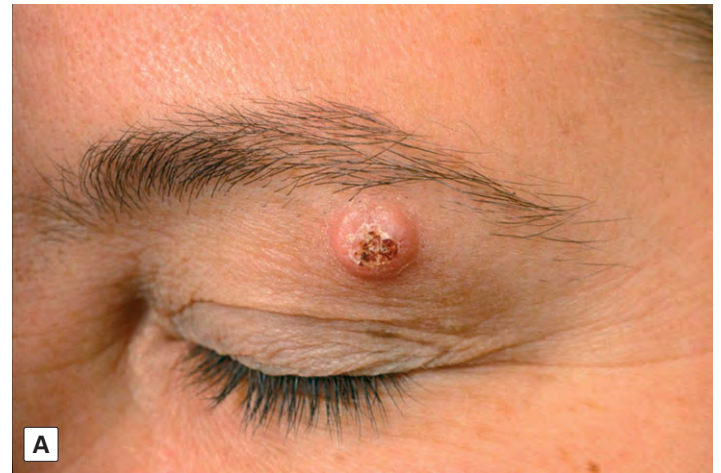



**Fig. 14.2** Seborrheic keratosis. Upper eyelid involvement in a 75-year-old man (A). Retiform pattern of squamous epithelium surrounding islands of connective tissue and composed of sheets of basaloid cells with keratin-filled horn pseudocysts (B). (Hematoxylin and eosin; original magnification  $\times 10$ .)



**Fig. 14.3** Inverted follicular keratosis. Note hyperkeratotic endophytic growth pattern. Flattened concentric epidermal cells within acanthotic areas are called squamous eddies. (Hematoxylin and eosin; original magnification  $\times 10$ .)



**Fig. 14.4** Keratoacanthoma. Nodular lesion with central keratin crater (A). (Courtesy of Dr Anjali G. Laungani). Cup-shaped architecture with variable squamous atypia. Generally considered a subtype of squamous cell carcinoma (B). (Hematoxylin and eosin; original magnification  $\times 4$ .)

variable hyperkeratosis (Fig. 14.5). The epithelium shows normal maturation without dysplasia or other features of malignancy.

**Treatment** Complete excision is recommended.

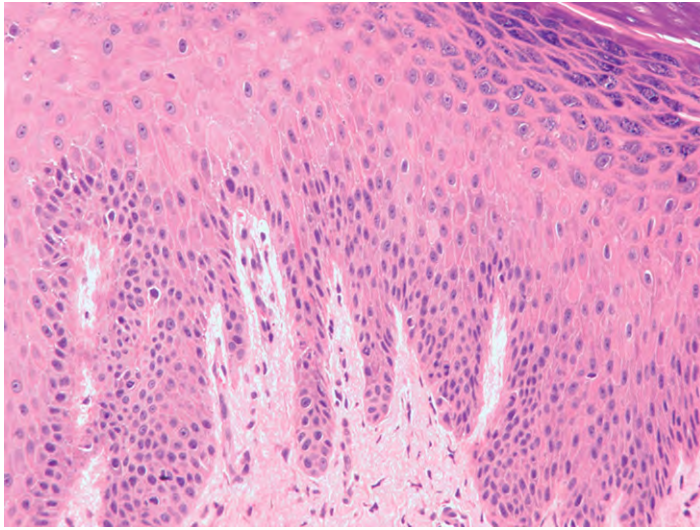
## NON-MELANOCYTIC PREMALIGNANT EPIDERMAL TUMORS

**Non-specific keratosis** Cutaneous horn is a clinically descriptive, non-diagnostic term for a non-specific keratosis (hyperkeratotic lesion, either benign or malignant).

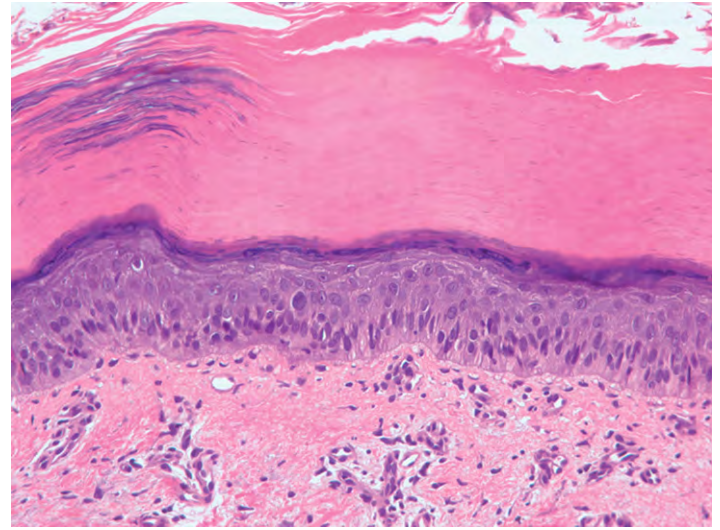
**Clinical features** A protruding keratotic lesion (Fig. 14.6), can be associated with a variety of benign or malignant lesions. In a study of 48 cases involving the eyelids, the most common associated lesions were seborrheic keratosis, actinic keratosis, basal cell carcinoma, and squamous cell carcinoma.<sup>11</sup>

**Histopathologic features** There are no specific histopathologic features other than hyperkeratosis. The findings are solely dependent on the particular type of lesion present.

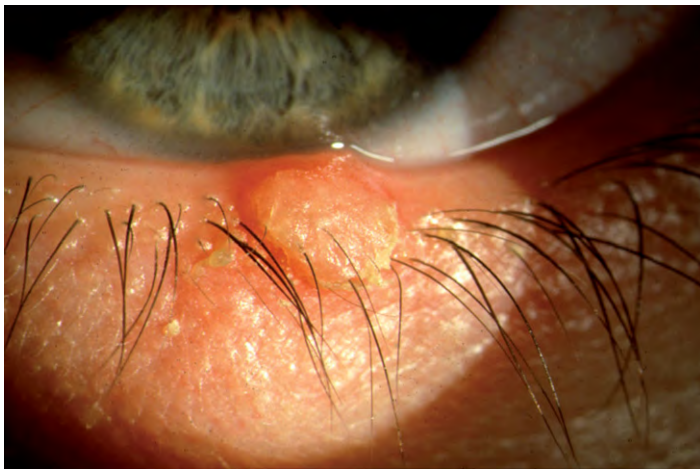




**Fig. 14.5** Reactive hyperplasia (pseudoeplitheliomatous hyperplasia). Epidermal hyperplasia with elongated and sometimes anastomosing rete ridges, normal maturation of epithelium, and variable hyperkeratosis. Note the absence of atypia. (Hematoxylin and eosin; original magnification  $\times 20$ .)



**Fig. 14.7** Actinic (solar) keratosis. Dysplastic squamous epithelium, usually with hyperkeratosis and parakeratosis with underlying solar elastosis of the dermis. (Hematoxylin and eosin; original magnification  $\times 20$ .)



**Fig. 14.6** Cutaneous horn is a clinically descriptive, non-diagnostic term for a non-specific keratosis.

**Treatment** Treatment should be directed at the underlying cutaneous lesion.

**Actinic (solar) keratosis** is a result of damage to the epidermal cells of the skin by ultraviolet radiation. Fair-skinned, older patients and those with a history of excessive sun exposure are typically affected.

**Clinical features** It has a variety of clinical presentations, usually characterized by multiple, erythematous, excoriated sessile plaques.<sup>12</sup> Although it is a precursor to squamous cell carcinoma, the mitotic activity is low.<sup>13</sup> In a study wherein histopathologic evaluation of the resected squamous cell carcinomas was undertaken, 25% of cases were associated with actinic keratosis, and in about 50% of cases actinic keratosis was in close proximity.<sup>14</sup> However, population-based studies indicate a much lower annual rate of malignant transformation of actinic keratosis of 0.01%.<sup>15</sup> Such discrepancy may exist because of

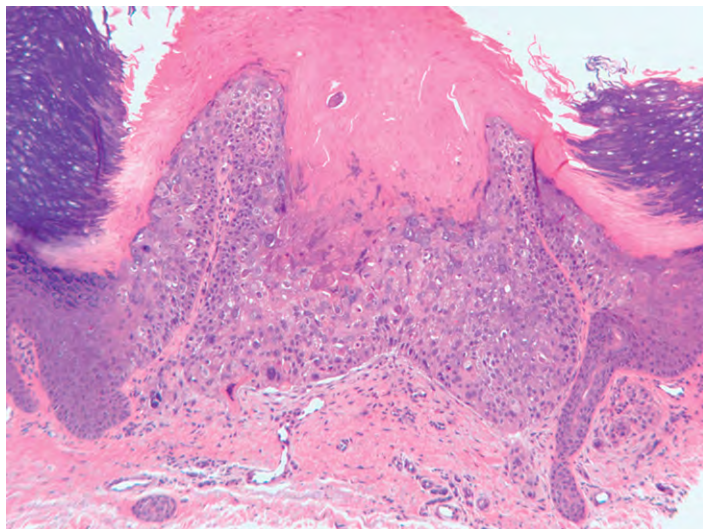
differences in the clinical and pathological nomenclature used to describe actinic keratosis and early squamous cell carcinoma. It is now believed that actinic keratosis is an incipient form of squamous cell carcinoma requiring treatment.<sup>16,17</sup> Squamous cell carcinoma that arises from actinic keratosis is low grade and offers an excellent prognosis.

**Histopathologic features** Histopathology generally shows hyperkeratosis and parakeratosis (with or without hyperpigmentation), with loss of epithelial cell polarity and dysmaturation. Subtypes include hypertrophic (when the epithelium is acanthotic), atrophic (when the epithelium is atrophic or thin), acantholytic (when there is prominent discohesion of the basal cells), and lichenoid (when there is a dense mononuclear cell infiltrate in the upper dermis). Solar elastosis of varying degrees is present in the dermis (Fig. 14.7).

**Treatment** Management is close observation and excision of more suspicious lesions. Multiple lesions can be treated with topical chemotherapeutic agents or cryotherapy.<sup>18</sup> A meta-analysis of published studies indicates that 3% diclofenac in 2.5% hyaluronan gel is effective in the treatment of actinic keratosis.<sup>19</sup> Topical gel must not be applied to the eyelids as it is not approved for ophthalmic use.

**Intraepithelial neoplasia** Squamous intraepithelial neoplasia is also considered as squamous carcinoma in situ. It occurs most commonly in fair-skinned elderly individuals who have a history of chronic sun exposure. The majority of patients are 60 years of age or older.<sup>13</sup> Periocular squamous intraepithelial neoplasia occurs most frequently on the lower eyelid.<sup>20</sup>

**Clinical features** Although the clinical presentation of squamous intraepithelial neoplasia varies, most often it appears as a painless elevated, nodular or plaque-like lesion with chronic scaling and fissuring of the skin. Additional presenting features include a small erythematous scaly patch, cyst-like lesion, papillomatous lesion, a cutaneous horn, and a large ulcerated lesion (Chapter 16).<sup>11</sup>



**Fig. 14.8** Squamous intraepithelial neoplasia. Marked squamous dysplasia (Bowen's disease, also considered as squamous carcinoma in situ). (Hematoxylin and eosin; original magnification  $\times 10$ .)

**Histopathologic features** There is hyperkeratosis, parakeratosis, variable acanthosis, and marked squamous dysplasia without invasion beyond the basement membrane (Fig. 14.8). Lipid stains may be necessary to differentiate between squamous intraepithelial neoplasia and intraepithelial spread of sebaceous gland carcinoma (Chapter 17).

**Treatment** Wide excision with clear margins, similar to that for squamous cell carcinoma, should be performed (Chapter 16).

**Sebaceous nevus (of Jadassohn)** is a sporadic clinical disorder characterized by cutaneous sebaceous nevus and extracutaneous manifestations.<sup>21</sup> The term sebaceous nevus is used to emphasize the epidermal and adnexal composition (sebaceous glands, sweat glands, and hair follicles) of cutaneous hamartoma (organoid nevus) and to differentiate it from typical melanocytic nevi. Cutaneous lesions are most commonly found on the head and neck region and appear as irregular linear lesions with alopecia (Chapter 66). In adulthood there is a tendency for both benign and malignant skin tumors, such as sebaceous adenoma and basal cell carcinoma to arise within the area of the organoid nevus.<sup>22</sup>

## MELANOCYTIC BENIGN EPIDERMAL TUMORS

### Epithelial pigmentation

**Freckles or ephelides** are flat brown skin spots that appear in childhood. Freckles characteristically darken with sunlight exposure and fade in winter in the absence of sunlight exposure. In contrast, solar lentigines do not fade with cessation of sunlight exposure.

**Lentigo simplex** The lesion of lentigo simplex is a flat, brown to black macule measuring 1–2 mm in diameter. Similar-appearing multiple lesions of the eyelid may be associated with the autosomal dominant Peutz–Jeghers syndrome of mucocutaneous pigmentation and intestinal polyposis (Chapter 30). Histology shows hyperpigmentation of the basal layer with increased numbers of melanocytes.

**Solar lentigo** The lesions of solar lentigo are light to dark brown, slowly expanding macules that develop in chronically sun-exposed

areas of the skin, including the eyelids. They occur in over 90% of elderly Caucasians. Presenting as small macules 3–5 mm in diameter, the lesions may gradually grow to several centimeters. Differentiation from lentigo maligna and lentigo maligna melanoma is imperative. Solar lentigo lesions respond to treatment with topical 0.1% tretinoin, 2% hydroxyanisole, laser therapy, and cryotherapy.

**Melanocytic nevus** is considered a hamartoma or a benign tumor of neural crest-derived melanocytes.<sup>23</sup> An eyelid nevus can be congenital or acquired.

**Congenital nevus** is present in about 1% of newborns.<sup>24</sup>

**CLINICAL FEATURES** Congenital nevi may be single or multiple, with sharp borders. They tend to become darker and the surface undergoes papular or nodular change with age.

**SIZE-BASED CLASSIFICATION** The congenital nevi are classified by their largest diameter as small (<1.5 cm), medium (1.5–19.9 cm), and large or giant congenital melanocytic nevi (>20 cm).<sup>25</sup>

**MALIGNANT TRANSFORMATION** The risk of malignant transformation varies significantly with the size of the lesion. The lifetime risk of about 6% is highest with giant nevus.<sup>26</sup> Despite irrefutable evidence supporting the origin of melanoma in small congenital nevi, the risk associated with small and medium-sized congenital nevi is probably much less, although no reliable data exist.<sup>24,27</sup> The risk is particularly negligible in the prepubertal years.<sup>24</sup>

**HISTOPATHOLOGIC FEATURES** Although certain histopathologic features, such as preferential involvement of the lower dermis, perifollicular and perivascular distribution of nevus cells are typical of congenital nevi, these features are not pathognomonic.<sup>24,28</sup>

**TREATMENT** Surgical excision is recommended for cosmesis or because of concerns about malignant transformation in a large nevus.<sup>29</sup>

### Clinicopathologic variants

**NEUROCUTANEOUS MELANOSIS (NCM)** is a rare association of multiple and large congenital cutaneous nevi and meningeal melanosis or melanoma (Chapter 66).<sup>30</sup>

**SPLIT NEVUS (KISSING NEVUS)** A variant of congenital compound nevus involving both upper and lower eyelids, kissing nevus can be associated with significant cosmetic and functional defect of the eyelids (Fig. 14.9).<sup>31</sup> Such a contiguous involvement suggests that the nevus develops between the ninth and the 20th weeks of gestation when the eyelids are fused.<sup>32</sup> As these nevi tend to be large, there is the potential for malignant transformation.<sup>33</sup> Surgical treatment involves excision and repair with full-thickness skin grafts.<sup>34</sup>

**BLUE NEVUS** arises from dermal, deeply located melanocytes that have been arrested in the dermis before reaching the epidermis.<sup>35</sup> Within the spectrum of blue nevi, clinicopathologic variants of common blue nevus, cellular blue nevus, and epithelioid blue nevus represent the localized forms, and oculodermal melanocytosis is considered as a diffuse variant of blue nevus.<sup>35</sup>



Rights were not granted to include this figure in electronic media.  
Please refer to the printed publication.

**Fig. 14.9** Split nevus. A sharply demarcated brown plaque involving the upper and lower eyelids in a 45-year-old Asian woman. Nevomelanocytes migrate from the neural crest to the skin after the 10th week in utero, but before 24 weeks when splitting of eyelids occurs. (Reproduced with permission from: Wolff K, Johnson RA, Suurmond D. *Melanoma precursors and primary cutaneous*. In: FitzPatrick's color atlas and synopsis of clinical dermatology – 5<sup>th</sup> ed. New York: The McGraw-Hill Companies; 2001.)

**CLINICAL FEATURES** The cellular blue nevus appears as a large bluish nodule (2–3 cm or more in diameter). The blue color is due to the deep location of the melanocytes, with absorption of longer wavelengths of light as it passes through the dermis (Tyndall phenomenon). Such eyelid changes can extend to involve adjacent conjunctiva (Chapter 24), orbit, and intracranial cavity.

**MALIGNANT TRANSFORMATION** The blue nevus can rarely undergo malignant transformation<sup>36</sup> and present as a conjunctival,<sup>37</sup> eyelid,<sup>38</sup> orbital,<sup>38–40</sup> or intracranial melanoma.<sup>38</sup>

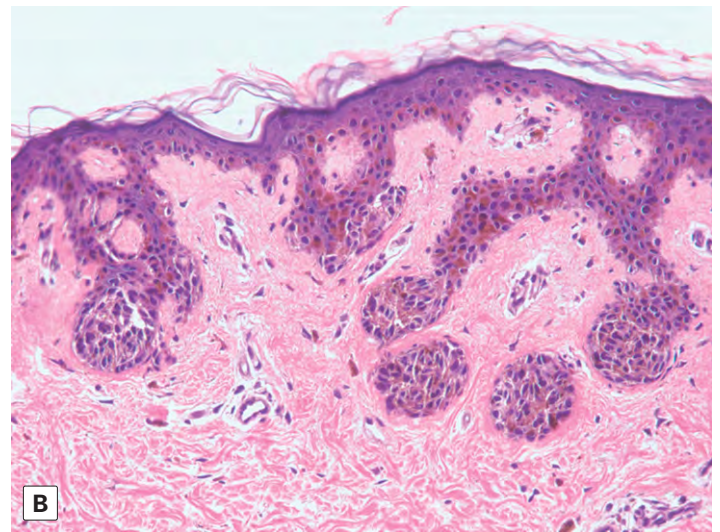
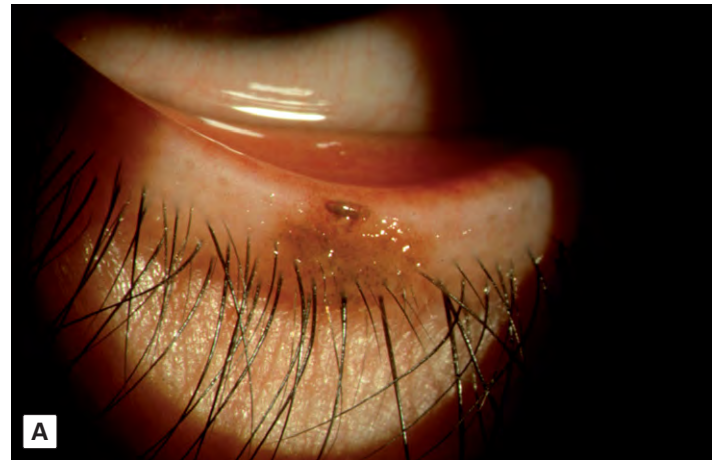**HISTOPATHOLOGIC FEATURES** Histologically, the common blue nevus is composed of dendritic melanocytes. The cellular blue nevus has a population of spindle-shaped cells and dendritic melanocytes. The malignant change is usually seen in the region of the spindle cells.<sup>41</sup>

**TREATMENT** Surgical excision is recommended for cosmesis or to establish a definitive diagnosis.

**NEVUS OF OTA** (oculodermal melanocytosis) occurs as a bluish discoloration of the eyelids, periorbital skin, and episclera, representing a proliferation of dermal and uveal melanocytes. The temple, forehead, malar region, sclera, and mucosa of the nose and mouth may also be involved (Chapter 24). Melanocytosis of structures such as the uvea, orbit, and ipsilateral meninges may not be readily apparent (Chapter 34).

**CLINICAL FEATURES** Nevus of Ota may appear at birth, or may develop during the first year of life or during adolescence. It tends to follow the distribution of the first and second divisions of the trigeminal nerve. It may rarely be bilateral.

**HISTOPATHOLOGIC FEATURES** Histopathologically, nevus of Ota is characterized by excess scattered dendritic and plump polyhedral melanocytes in the dermis.



**Fig. 14.10** Eyelid nevus. Pigmented melanocytic nevus on the margin of the lower eyelid in a 18-year-old woman (A). Junctional nevus consisting of melanocytic nests without cytologic atypia confined to the dermoepidermal junction (B). (Hematoxylin and eosin; original magnification  $\times 20$ .)

**MALIGNANT TRANSFORMATION** Frequent follow-up with dilated fundus examination is required because of a small risk of developing uveal melanoma.<sup>42</sup> The possibility of malignant transformation of the cutaneous component is even more remote.<sup>43</sup>

**TREATMENT** Periodic observation, including dilated fundus examination, is the recommended treatment.

**Acquired nevus** develops between the ages of 5 and 10 years. Mild to moderate sun exposure in early life induces the development of nevi,<sup>44</sup> and their density is highest in the sun-exposed areas.<sup>45</sup>

**CLINICAL FEATURES** Acquired nevi appear as small, flat or minimally elevated lesions that are light brown in color (Fig. 14.10). They have a limited growth phase, often corresponding to adolescence, after which they stabilize. Acquired nevi may be located anywhere on the eyelids, and frequently involve the eyelid margin and conjunctiva.

**HISTOPATHOLOGIC FEATURES** Junctional, compound, and dermal nevus may be recognized, depending on the location of nevus cells.

There is migration of nevus cells from the junction of the epidermis (junctional nevus) to the dermis, with combined junctional and dermal components (compound nevus) (Fig. 14.11), and finally with only a dermal component (dermal nevus), reflecting the process of nevocgenesis (Fig. 14.12).<sup>23</sup> Junctional nevi are most frequent in the first decade, compound nevus in the second decade, and the proportion of dermal nevi increases with age.<sup>46</sup> The location also influences the type of nevus present. For example, dermal nevi are more frequent in the head and neck region, whereas junctional nevi are mostly seen in the extremities.<sup>46</sup>

**TREATMENT** Surgical excision of large eyelid nevi may necessitate significant tissue loss, so frequent observation rather than routine excision may be warranted in many cases.

### MELANOCYtic PREMALIGNANT EPIDERMAL TUMORS

**Spitz nevus** A more distinctive type of eyelid nevus is the Spitz nevus,<sup>47</sup> which is usually reported only in childhood and adolescence.<sup>48</sup>

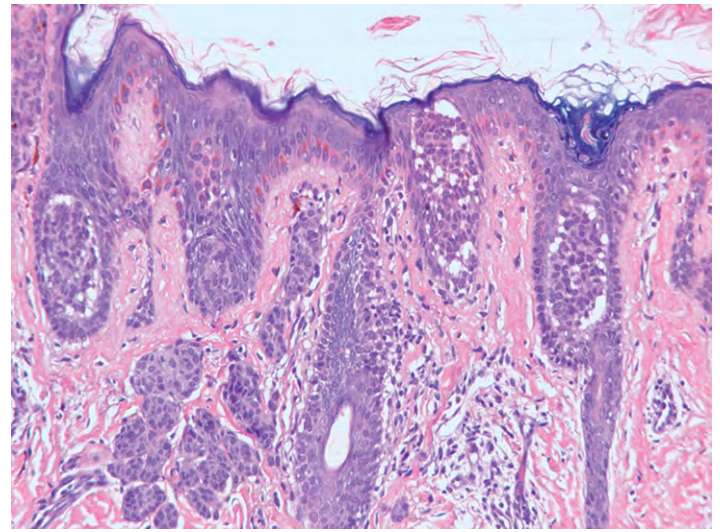
**Clinical features** These lesions are rapidly growing red or tan-colored lesions that should be differentiated from pyogenic granuloma, capillary hemangioma and, more importantly, from melanoma, which is extremely uncommon in children. At present there is considerable controversy regarding the true nature of Spitz nevus, as some lesions are benign and some may be malignant, with inadequate histopathological criteria to distinguish between them.<sup>49</sup>

**Histopathologic features** Histologically, eyelid Spitz nevus features fascicles of spindle nevus cells that are uniformly and symmetrically arranged. In some cases epithelioid cells may predominate.<sup>48</sup> Superficially located mitotic figures, when few in number, reflect the rapid clinical growth and do not indicate malignancy.<sup>48</sup>

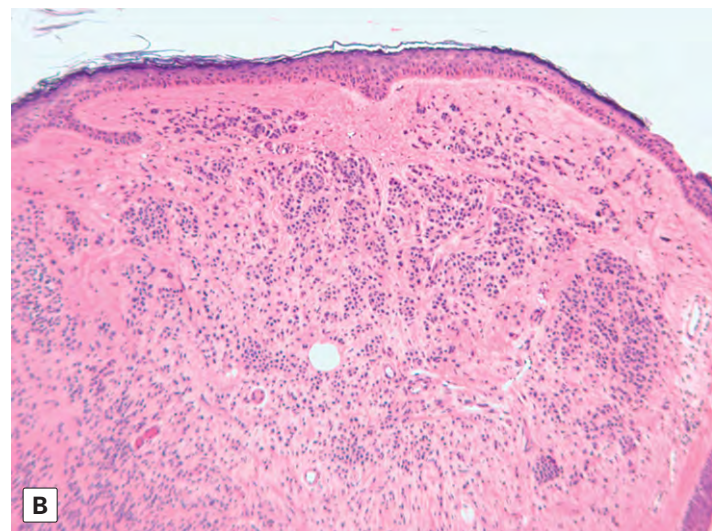
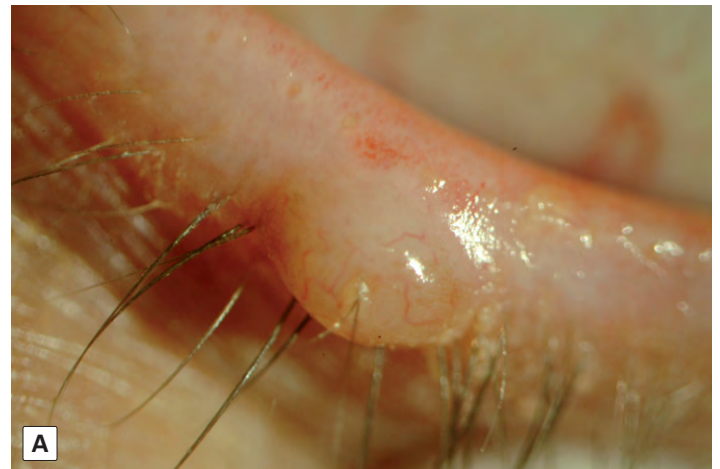**Treatment** As the clinical features of rapid onset are alarming, excision to exclude the possibility of eyelid melanoma should be performed.

**Atypical or dysplastic nevus** are present in 2–5% of the white population. Such nevi are larger (>5 mm), with ill-defined borders, and are variegated in color.<sup>27</sup> Atypical nevi are associated with an increased risk for malignant melanoma. In addition to educating such patients about the dangers of sun exposure, periodic total-skin examinations starting at puberty should be recommended.<sup>50</sup>

**Familial atypical mole and melanoma syndrome (dysplastic nevus syndrome)** denotes a specific clinicopathologic entity that is associated with an increased risk for the development of cutaneous melanoma.<sup>51</sup> The syndrome of autosomal dominant predisposition to cutaneous melanoma was originally described by Clark<sup>52</sup> as BK mole syndrome. Familial atypical mole and melanoma (FAM-M) syndrome is now the preferred terminology.<sup>53</sup> The National Institutes of Health (Maryland, USA) consensus panel has defined FAM-M syndrome as the occurrence of a large number of atypical (often more than 50) cutaneous nevi that show certain distinct histologic features and cutaneous melanomas in one or more first- or second-degree relatives.<sup>53</sup> FAM-M syndrome is due to mutations of the CDKN2A gene on chromosome 9p21.<sup>54</sup> Even so, the concept of FAM-M syndrome



**Fig. 14.11** Compound nevus. Nevus with combined features of junctional and intradermal nevi. (Hematoxylin and eosin; original magnification  $\times 20$ .)



**Fig. 14.12** Eyelid nevus. Non-pigmented intradermal nevus of the eyelid margin. Note that the surface epithelium and lashes are intact (A). Intradermal nevus composed of nevus cells confined to the dermis and arranged in nests, cords, and singly with maturation (nuclei becoming smaller) in the deeper dermis (B). (Hematoxylin and eosin; original magnification  $\times 10$ .)



remains controversial.<sup>55</sup> The association between FAM-M syndrome and uveal nevi and uveal melanoma is discussed elsewhere (Chapter 35).

### Lentigo maligna (melanotic freckle of Hutchinson)

**Clinical features** Lentigo maligna refers to an acquired pigmented macule in the sun-exposed skin of middle-aged or elderly individuals.<sup>56</sup> It was initially described by Hutchinson, hence it is also called melanotic freckle of Hutchinson.<sup>57</sup> Lentigo maligna is now believed to represent an in situ phase of lentigo maligna melanoma.

**Histopathologic features** Lentigo maligna is characterized by intraepidermal proliferation of atypical melanocytes and any dermal involvement is classified as lentigo maligna melanoma.

**Malignant transformation** Lentigo maligna can slowly enlarge horizontally before entering a vertical growth phase and transforming into lentigo maligna melanoma. Overall, it is estimated that about 50% of lentigo maligna cases (if left untreated) will eventually transform into lentigo maligna melanoma.

**Treatment** Surgery is the preferred method of treatment as it offers the possibility of histopathologic review.<sup>56</sup> Margins of at least 5 mm are recommended. Moh's microsurgery is associated with the lowest recurrence rate, at about 5%. Cryotherapy and radiotherapy are suitable alternatives in cases where surgery is not feasible or is declined.<sup>56</sup>

### SUMMARY

Benign epidermal tumors of the eyelid are similar to those observed in other sun-exposed areas of the skin. Some benign eyelid lesions may represent manifestations of systemic disease. They can be classified as non-melanocytic or melanocytic, or considered as benign and premalignant tumors. It is at times difficult if not impossible to differentiate benign tumors from malignant ones, especially in the early stages of malignant transformation. Where indicated, excisional biopsy with suitable margins is the preferred treatment. Melanocytic lesions of the eyelid are similar to such lesions elsewhere. Therefore, management of such patients should be guided by the general principles of dermatology and dermatopathology.

### REFERENCES

- Font RL. Eyelids and lacrimal drainage system. In: Spencer WH, ed. Ophthalmic pathology. An atlas and textbook. Philadelphia: WB Saunders, 1996; 2229–2232.
- Boniuk M, Zimmerman LE. Eyelid tumors with reference to lesions confused with squamous cell carcinoma. II. Inverted follicular keratosis. Arch Ophthalmol 1963; 69: 698–707.
- Lever WF. Inverted follicular keratosis is an irritated seborrheic keratosis. Am J Dermatopathol 1983; 5: 474.
- Schwartz RA. Keratoacanthoma: a clinico-pathologic enigma. Dermatol Surg 2004; 30: 326–333; discussion 333.
- Ponti G, Ponz de Leon M, Muir-Torre syndrome. Lancet Oncol 2005; 6: 980–987.
- Kato N, Ito K, Kimura K, Shibata M. Ferguson Smith type multiple keratoacanthomas and a keratoacanthoma centrifugum marginatum in a woman from Japan. J Am Acad Dermatol 2003; 49: 741–746.
- Grossniklaus HE, Wojno TH, Yanoff M, Font RL. Invasive keratoacanthoma of the eyelid and ocular adnexa. Ophthalmology 1996; 103: 937–941.
- Kwitken J. Dermatologic pseudobenzignities. Mt Sinai J Med 1980; 47: 34–37.
- Leibovitch I, Huilgol SC, James CL et al. Periocular keratoacanthoma: can we always rely on the clinical diagnosis? Br J Ophthalmol 2005; 89: 1201–1204.
- Donaldson MJ, Sullivan TJ, Whitehead KJ, Williamson RM. Periocular keratoacanthoma: clinical features, pathology, and management. Ophthalmology 2003; 110: 1403–1407.
- Mencia-Gutierrez E, Gutierrez-Diaz E, Redondo-Marcos I, Ricoy JR, Garcia-Torre JP. Cutaneous horns of the eyelid: a clinicopathological study of 48 cases. J Cutan Pathol 2004; 31: 539–543.
- Fu W, Cockerell CJ. The actinic (solar) keratosis: a 21st-century perspective. Arch Dermatol 2003; 139: 66–70.
- Lebwohl M. Actinic keratosis: epidemiology and progression to squamous cell carcinoma. Br J Dermatol 2003; 149 Suppl 66: 31–33.
- Mittelbronn MA, Mullins DL, Ramos-Caro FA, Flowers FP. Frequency of pre-existing actinic keratosis in cutaneous squamous cell carcinoma. Int J Dermatol 1998; 37: 677–681.
- Marks R, Rennie G, Selwood TS. Malignant transformation of solar keratoses to squamous cell carcinoma. Lancet 1988; 1: 795–797.
- Person JR. An actinic keratosis is neither malignant nor premalignant: it is an initiated tumor. J Am Acad Dermatol 2003; 48: 637–638.
- Anwar J, Wrono DA, Kimyai-Asadi A, Alam M. The development of actinic keratosis into invasive squamous cell carcinoma: evidence and evolving classification schemes. Clin Dermatol 2004; 22: 189–196.
- Lober BA, Fenske NA. Optimum treatment strategies for actinic keratosis (intraepidermal squamous cell carcinoma). Am J Clin Dermatol 2004; 5: 395–401.
- Pirard D, Vereecken P, Melot C, Heenen M. Three percent diclofenac in 2.5% hyaluronan gel in the treatment of actinic keratoses: a meta-analysis of the recent studies. Arch Dermatol Res 2005; 297: 185–189.
- Cook BE Jr, Bartley GB. Treatment options and future prospects for the management of eyelid malignancies: an evidence-based update. Ophthalmology 2001; 108: 2088–2098; quiz 2099–2100, 2121.
- Vujevich JJ, Mancini AJ. The epidermal nevus syndromes: multisystem disorders. J Am Acad Dermatol 2004; 50: 957–961.
- Domingo J, Helwig EB. Malignant neoplasms associated with nevus sebaceus of Jadassohn. J Am Acad Dermatol 1979; 1: 545–556.
- Krengel S. Neovogenesis – new thoughts regarding a classical problem. Am J Dermatopathol 2005; 27: 456–465.
- Tannous ZS, Mihm MC Jr, Sober AJ, Duncan LM. Congenital melanocytic nevi: clinical and histopathologic features, risk of melanoma, and clinical management. J Am Acad Dermatol 2005; 52: 197–203.
- Kopf AW, Bart RS, Hennessey P. Congenital nevocytic nevi and malignant melanomas. J Am Acad Dermatol 1979; 1: 123–130.
- Watt AJ, Kotsis SV, Chung KC. Risk of melanoma arising in large congenital melanocytic nevi: a systematic review. Plast Reconstr Surg 2004; 113: 1968–1974.
- Anonymous. Consensus conference: Precursors to malignant melanoma. JAMA 1984; 251: 1864–1866.
- Mark GJ, Mihm MC, Liteplo MG, Reed RJ, Clark WH. Congenital melanocytic nevi of the small and garment type. Clinical, histologic, and ultrastructural studies. Hum Pathol 1973; 4: 395–418.
- Margo CE, Rabinowicz IM, Habal MB. Periocular congenital melanocytic nevi. J Pediatr Ophthalmol Strabismus 1986; 23: 222–226.
- Makkar HS, Frieden IJ. Neurocutaneous melanosis. Semin Cutan Med Surg 2004; 23: 138–144.
- McDonnell PJ, Mayou BJ. Congenital divided naevus of the eyelids. Br J Ophthalmol 1988; 72: 198–201.
- Hamming N. Anatomy and embryology of the eyelids: a review with special reference to the development of divided nevi. Pediatr Dermatol 1983; 1: 51–58.
- Nawa Y, Hara Y, Saishin M. Conjunctival melanoma associated with extensive congenital conjunctival nevus and split nevus of eyelid. Arch Ophthalmol 1999; 117: 269–271.
- Ribuffo D, Cavalieri L, Sonnino M et al. Divided nevus of the eyelid: a case report. Ophthalm Plast Reconstr Surg 1996; 12: 186–189.
- Folberg R, Jakobiec FA, Bernardino VB, Iwamoto T. Benign conjunctival melanocytic lesions. Clinicopathologic features. Ophthalmology 1989; 96: 436–461.
- Mones JM, Ackerman AB. 'Atypical' blue nevus, 'malignant' blue nevus, and 'metastasizing' blue nevus: a critique in historical perspective of three concepts flawed fatally. Am J Dermatopathol 2004; 26: 407–430.
- Demirci H, Shields CL, Shields JA, Eagle RC Jr. Malignant melanoma arising from unusual conjunctival blue nevus. Arch Ophthalmol 2000; 118: 1581–1584.
- Gunduz K, Shields JA, Shields CL, Eagle RC Jr. Periocular cellular blue nevus leading to orbitopalpebral and intracranial melanoma. Ophthalmology 1998; 105: 2046–2050.
- Loffler KU, Witschel H. Primary malignant melanoma of the orbit arising in a cellular blue naevus. Br J Ophthalmol 1989; 73: 388–393.
- Odashiro AN, Arthurs B, Pereira PR et al. Primary orbital melanoma associated with a blue nevus. Ophthalm Plast Reconstr Surg 2005; 21: 247–248.
- Aloi F, Pich A, Pippione M. Malignant cellular blue nevus: a clinicopathological study of 6 cases. Dermatology 1996; 192: 36–40.
- Singh AD, De Potter P, Fijal BA et al. Lifetime prevalence of uveal melanoma in white patients with ocular(dermal) melanocytosis. Ophthalmology 1998; 105: 195–198.
- Patel BC, Egan CA, Lucius RW et al. Cutaneous malignant melanoma and oculodermal melanocytosis (nevus of Ota): report of a case and review of the literature. J Am Acad Dermatol 1998; 38: 862–865.

44. Wiecker TS, Luther H, Buettner P, Bauer J, Garbe C. Moderate sun exposure and nevus counts in parents are associated with development of melanocytic nevi in childhood: a risk factor study in 1,812 kindergarten children. *Cancer* 2003; 97: 628–638.
45. MacLennan R, Kelly JW, Rivers JK, Harrison SL. The Eastern Australian Childhood Nevus Study: site differences in density and size of melanocytic nevi in relation to latitude and phenotype. *J Am Acad Dermatol* 2003; 48: 367–375.
46. Winkelmann RK, Rocha G. The dermal nevus and statistics. An evaluation of 1,200 pigmented lesions. *Arch Dermatol* 1962; 86: 310–315.
47. Spitz S. Melanoma of the childhood. *Am J Pathol* 1948; 24: 591–609.
48. Hiscott P, Seitz B, Naumann GO. Epithelioid cell Spitz nevus of the eyelid. *Am J Ophthalmol* 1998; 126: 735–737.
49. Piepkorn M. The Spitz nevus is melanoma. *Am J Dermatopathol* 2005; 27: 367–369.
50. Marghoob AA. The dangers of atypical mole (dysplastic nevus) syndrome. Teaching at-risk patients to protect themselves from melanoma. *Postgrad Med* 1999; 105: 147–148, 151–142, 154 passim.
51. Salopek TG. The dilemma of the dysplastic nevus. *Dermatol Clin* 2002; 20: 617–628.
52. Clark WH Jr, Reimer RR, Greene M, Ainsworth AM, Mastrangelo MJ. Origin of familial malignant melanomas from heritable melanocytic lesions: 'The B-K Mole syndrome'. *Arch Dermatol* 1978; 114: 732–738.
53. NIH. NIH Consensus conference. Diagnosis and treatment of early melanoma. *JAMA* 1992; 268: 1314–1319.
54. de Snoo FA, Bergman W, Gruis NA. Familial melanoma: a complex disorder leading to controversy on DNA testing. *Fam Cancer* 2003; 2: 109–116.
55. Wetherington RW, Cockerell CJ. The 'dysplastic' nevus: an update at 25 years. *Adv Dermatol* 2003; 19: 237–248.
56. Stevenson O, Ahmed I. Lentigo maligna: prognosis and treatment options. *Am J Clin Dermatol* 2005; 6: 151–164.
57. Hutchinson J. Notes on the cancerous process and on new growths in general. *Arch Surg* 1890; 2: 83–86.

# Basal cell carcinoma

Mordechai Rosner

## INTRODUCTION

Basal cell carcinoma (BCC) is a malignant cutaneous neoplasm capable of extensive tissue destruction. It is often observed on the head and neck, and the eyelids are a common location.

BCC was initially described as a distinct entity by Krompecher<sup>1</sup> at the beginning of the 20th century. Some authorities preferred the term ‘epithelioma’ to carcinoma because of the tumor’s limited capacity to metastasize.<sup>1</sup>

BCC is the most common human malignancy and accounts for nearly 90% of all non-melanoma skin cancers. It is also the most common skin cancer of the eyelid, accounting for 80–90% of cases. In the United States the incidence of BCC is more than 500 per 100 000, and in parts of Australia it reaches 2400 per 100 000.<sup>1–3</sup> Although mortality from BCC is low, the morbidity may be considerable.

## ETIOLOGY

The risk factors for periocular BCC include ultraviolet (UV) irradiation, local and systemic immune dysfunction, previous ionizing radiation, and focal trauma. It is believed that exposure to UV light causes defects in immune function, and that this has a role in the pathogenesis of BCC. Other risk factors are fair skin color, inability to tan, and exposure to trivalent inorganic arsenic, such as from medications including arsenical compounds.<sup>1</sup> Genetic or congenital diseases predisposing to BCC are Gorlin–Goltz syndrome, xeroderma pigmentosum, albinism, Basex–Dupré syndrome, Muir–Torre syndrome, Rombo syndrome, linear basocellular hamartoma, and sebaceous hamartoma of Jadassohn.<sup>2</sup>

## PATHOGENESIS

The origin of BCC is controversial. It could arise from the basal cell of the epidermis, from the infundibular cells of the hair follicle, or from a pluripotential cell. BCC does not arise from a precursor lesion.<sup>1</sup>

## CLINICAL FEATURES

Approximately 95% of all BCCs occur in people between 40 and 79 years of age, and the average age at diagnosis for BCC of the eyelid is 60. BCC may occur in young adults and in children who have an inherited predisposition to cutaneous neoplasia. However, rarely, a solitary BCC may arise in an adolescent or young adult who has no known risk factors. Men may be more afflicted than women. In most cases BCC arises as solitary lesion on hair-bearing sun-exposed skin, particularly the face. Most periocular BCCs arise on the lower eyelid

and medial canthus, and least often near the lateral canthus. Tumors are usually present for many months prior to diagnosis.<sup>1,3</sup>

**Symptoms and signs** There are several different clinical features of BCC, including nodular and nodulo-ulcerative, pigmented, cystic, and infiltrating (which is called also morpheaform or sclerotic) BCC. All the clinical features are usually accompanied by loss of adnexa (hair and lashes), they are firm to palpation, and are painless unless secondarily infected.<sup>1</sup>

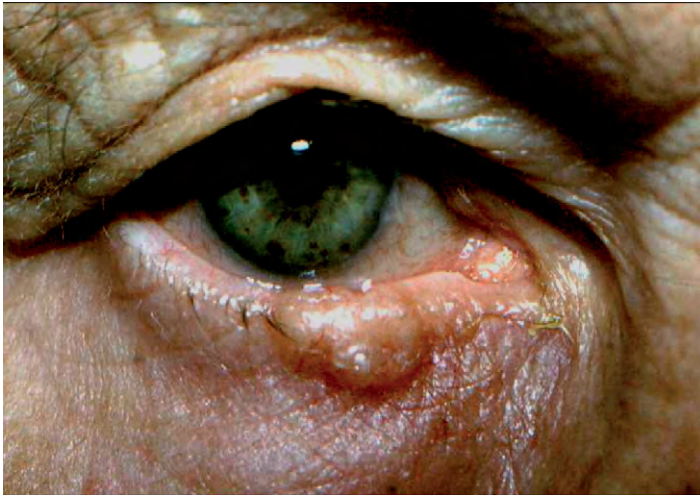
The nodular BCC begins as a small papule and slowly enlarges to an irregular, dome-shaped tumor (Fig. 15.1). The epithelial surface of the tumor is usually smooth, often described as pearly, with fine telangiectatic vessels beneath it. Ulceration may develop and is filled with a crusty exudate. The pigmented BCC is usually nodular or nodulo-ulcerative, ranging in color from light tan to deep brown. The cystic BCC may attain significant dimensions (Fig. 15.2). The infiltrating BCC presents as an indurated, yellowish to tan patch or plaque with occasional focal ulceration and poorly defined margins (Fig. 15.3). Patchy crusts, papules, and nodules are scattered throughout some morpheaform tumors. Infiltration within the eyelid can cause deformities and malpositioning of the lid margin (Box 15.1).

## HISTOPATHOLOGIC FEATURES

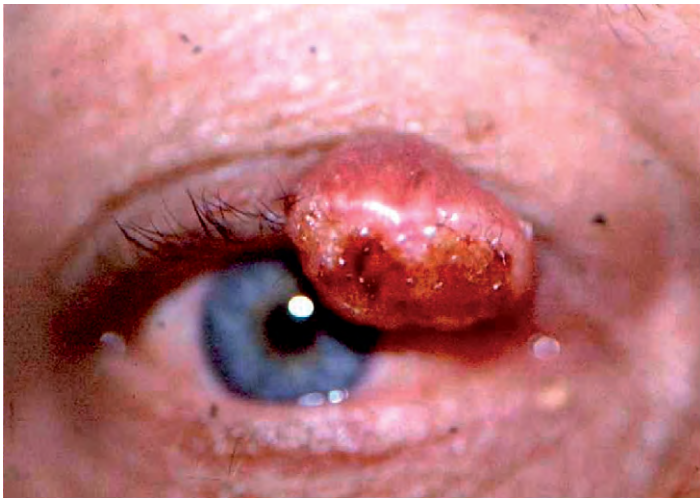Histopathologically, BCC is characterized by a proliferation of cells with oval nuclei and scant cytoplasm that form infiltrative nests or strands (Fig. 15.4). The neoplastic cells are relatively uniform in appearance and seldom display significant anaplasia or mitotic figures. At the periphery of the nests they are usually arranged in a radial pattern called ‘palisading’ (Fig. 15.5): although this is not diagnostic, in its absence the diagnosis of BCC should be questioned. The nests of tumor cells characteristically retract from the stroma, creating a gap (Fig. 15.5). Initially thought to be a processing artifact, this gap reflects defects in the production of adhesion-like substances by tumor cells. Necrosis is a common finding in BCC and the necrotic debris eventually calcifies or is replaced by fibrous scar tissue. BCC also demonstrates an inflammatory infiltrate of variable intensity around the nests of tumor cells that consists predominantly of lymphocytes. The junction between the stroma of the neoplasm and normal connective tissue is ill defined.<sup>1</sup>

There is no universally accepted histopathologic subclassification of BCC according to patterns of growth and cellular differentiation. The two most important growth patterns are the circumscribed and the infiltrative. Circumscribed BCC is characterized by nests and sheets of

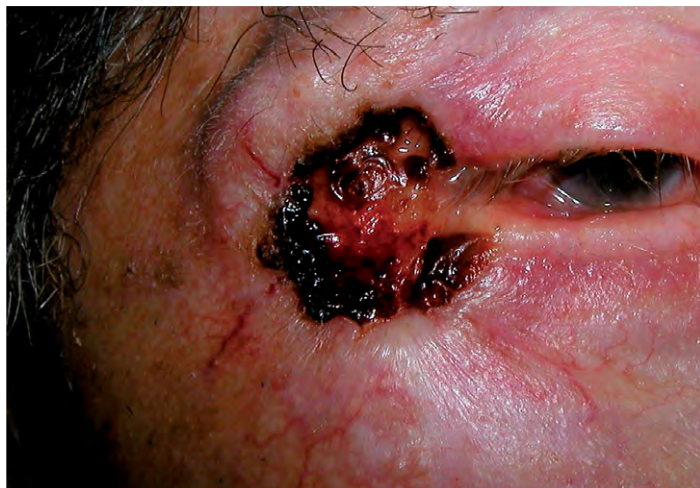



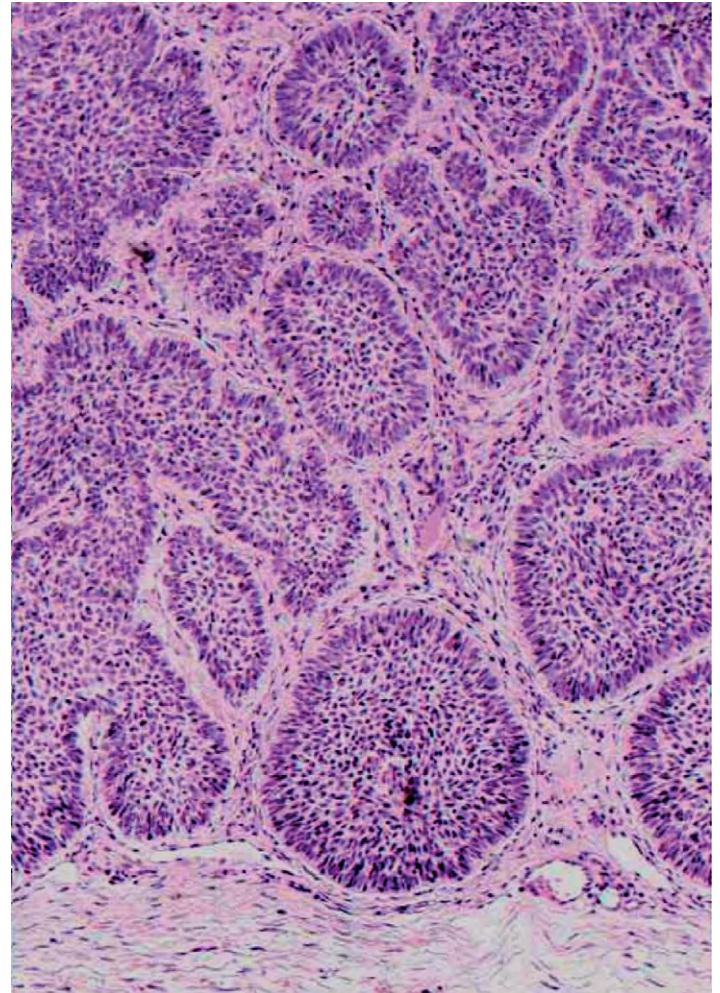
**Fig. 15.1** Nodular BCC of the lower lid margin, presenting as an irregular, pearly dome-shaped tumor.



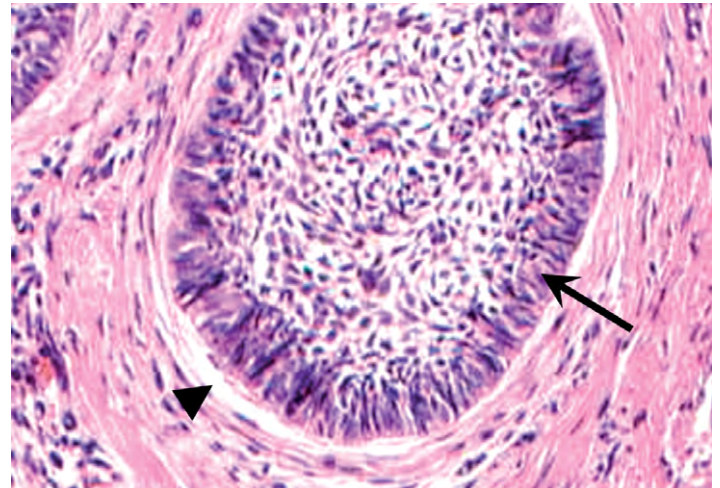
**Fig. 15.2** Cystic BCC of the upper lid.



**Fig. 15.3** Infiltrating BCC presenting as an indurated, yellowish to tan patch or plaque with focal ulceration and poorly defined margins.



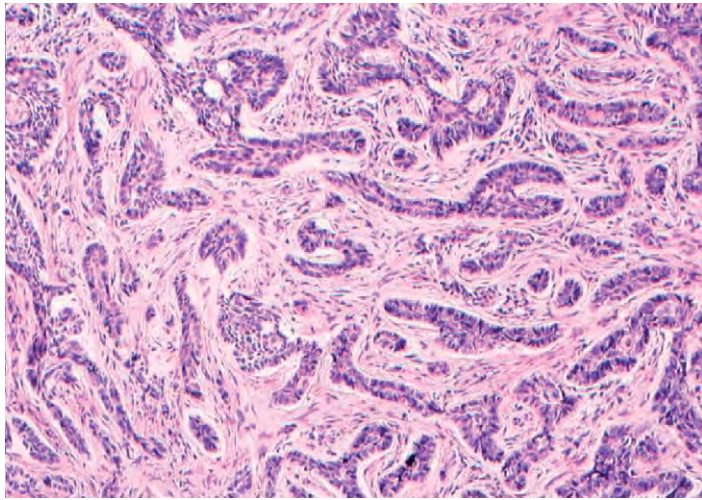
**Fig. 15.4** Histopathologically, BCC is characterized by a proliferation of cells with oval nuclei and scant cytoplasm that form infiltrative nests or strands.



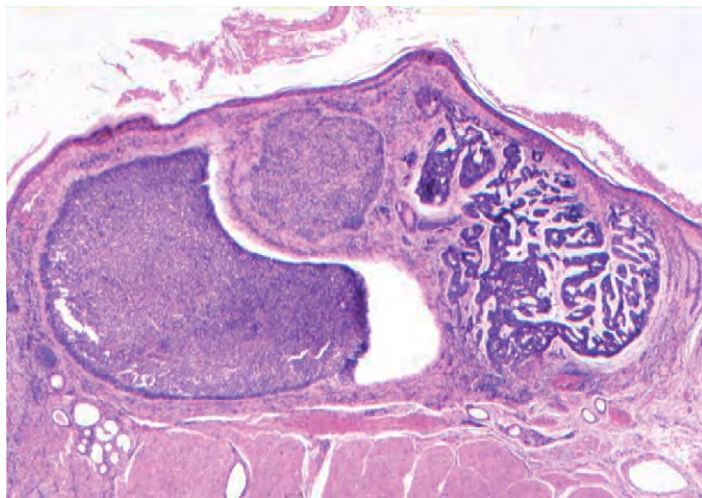
**Fig. 15.5** At the periphery of the nests the tumor cells are usually arranged in a radial pattern called 'palisading' (arrow), and these are characteristically retracted from the stroma, creating a gap (arrowhead).



tumor cells and usually corresponds clinically to a nodular tumor. In contrast, an infiltrative BCC is composed mainly of elongated strands of tumor cells that are several cell layers thick, with no peripheral cellular palisading (Fig. 15.6), and usually corresponds to a morpheic variety. However, in many cases different growth patterns occur in the same tumor (Fig. 15.7). There is a third important histologic pattern, the superficial BCC, which is presumed to be of multicentric origin and with horizontal spread. Superficial BCC is described mainly on the trunk and extremities.<sup>1</sup> More than 20 types of cellular differentiation or histologic patterns have been described in BCC as signs of sebaceous, apocrine, or eccrine gland, as well as pilar differentiation in an otherwise typical BCC.<sup>1,4</sup> However, only the metatypical (basosquamous) carcinomas have an impact on prognosis. Basosquamous carcinoma displays various degrees of squamous differentiation and has been suggested to occupy a conceptual intermediate ground between squamous cell carcinoma and BCC.<sup>1</sup>



**Fig. 15.6** An infiltrative BCC is composed mainly of elongated strands of tumor cells that are several cell layers thick, with no peripheral cellular palisading.



**Fig. 15.7** In many cases different growth patterns of BCC occur in the same tumor.

## DIAGNOSTIC EVALUATION

### Histopathologic examination of excisional or incisional biopsy

The most important diagnostic evaluation of BCC is histopathologic examination of the excised tissue. Incisional biopsy should be taken only in cases where the clinical diagnosis is highly questionable, otherwise excisional biopsy should be performed.

**Exfoliative cytology** has been shown to have a high diagnostic accuracy for BCC but may be considered only occasionally, when the plan is to treat the tumor non-surgically.<sup>5</sup>

**Imaging** When orbital or intraocular invasion is suspected, imaging is used to evaluate it. T<sub>1</sub> contrast-enhanced fat-suppressed MRI scans are the modality of choice for demonstrating a soft tissue mass or infiltration. Computed tomographic (CT) bone windows with axial and coronal views of the orbit are best for demonstrating bony destruction – which, however, is uncommon in BCC patients.<sup>6</sup>

**Other non-invasive methods** Pulsed ultrasound at 20 MHz has been used for the non-invasive measurement of BCC thickness in order to plan photodynamic therapy (PDT) and to evaluate the rate of tumor regression after treatment. It was found that such measurements can distinguish between skin, fibrosis, and tumor, and can even trace recurrences of BCC prior to clinical findings.<sup>7</sup>

Near-infrared reflectance-mode confocal scanning laser microscopy is a novel imaging technique for microscopic analysis of skin lesions that may offer a sensitive and specific tool for the non-invasive diagnosis of BCC in vivo.<sup>8,9</sup>

## DIFFERENTIAL DIAGNOSIS

The clinical and histopathologic differential diagnosis is broad. Challenging examples are trichoepithelioma and desmoplastic trichoepithelioma, metastatic carcinoma, sebaceous carcinoma, squamous cell carcinoma, and keratoacanthoma. However, as BCC is by far the most common malignant lesion of the periocular skin, most periocular nodular or cystic skin lesions should be treated as suspicious.

## TREATMENT

The main treatment modality for BCC is surgical excision of the lesion with microscopic monitoring of its margins, or Mohs micro-surgery.<sup>1,10</sup> The other surgical and non-surgical modalities include curettage and electrodesiccation, cryosurgery, radiotherapy, chemotherapy, photodynamic therapy, and immunotherapy. Selection of the appropriate therapy depends on the patient's age, anticipated life expectancy, and the location, size, and pattern of growth character-

### BOX 15.1 Salient Diagnostic Findings

- Painless, firm, nodular, or flat skin lesion with smooth, pearly epithelium and subepithelial telangiectatic vessels, accompanied by loss of adnexa
- Microscopic findings of infiltrative nests, sheets or strands of cells with oval nuclei and scant cytoplasm, which are arranged at the periphery of the nests in a radial 'palisading' pattern
- Presence of a gap between the nests of tumor cells and the stroma

istics of the tumor. However, therapies that are not surgical and do not include microscopic monitoring should be avoided for BCCs when they are not very small, when they are located in the medial canthus, or when the margins are clinically ill defined. The importance of preventing sun exposure needs to be stressed to children and young adults in order to reduce the incidence of BCC in the future.<sup>1</sup>

**Surgical excision** Only by surgical excision of the tumor with safe margins it is possible to assess the adequacy of extirpation. However, in cases with deep infiltration into the orbit or in proximity to the eyeball tissues, excision with safe margins is not possible and exenteration is inevitable. A variety of ways are used to examine the surgical margins and good results have been reported when frozen section control is used. Mohs' micrographic surgery has been considered to be the most reliable method for tumor extirpation, or as reliable as excision with frozen-section or permanent-section control, with the lowest recurrence rate and best cure rate.<sup>1,10,11</sup> However, the significant extra difficulty, time, and expense of Mohs' surgery may not be justified in all BCCs of the eyelid, and thus it is usually reserved for deeply infiltrative tumors with a high risk of recurrence.<sup>1</sup>

The carbon dioxide laser has a few advantages over the conventional scalpel in the excision of BCC, including the possibility of bloodless excision of tissue in thin layers for histological examination of the margins, and the possibility of obviating electrocautery, which is important for patients taking anticoagulants or who have a cardiac pacemaker.<sup>1</sup>

Special reconstructive techniques are used to maintain the functions of the eyelid and to achieve the best cosmetic results after surgical excision of periocular BCC.

**Curettage and electrodesiccation** and lately, vaporization of the tumor by CO<sub>2</sub> laser are commonly used techniques to treat small BCC in areas remote from the eye. As the adequacy of margins is not determined, there is always the risk that residual tumor will escape destruction, especially near embryonic fusion planes. Also, the amount of secondary scarring and contracture with electrodesiccation may be cosmetically unacceptable in the periocular area.<sup>1</sup>

**Cryotherapy** is a tissue-sparing modality with no control of the adequacy of tumor removal that is used to treat BCC remote from the eye. It has been suggested that cryotherapy of eyelid BCC with a well-defined border has a high cure rate, and is cost-effective and well tolerated.<sup>1,12-15</sup>

**Radiation therapy** The role of radiation therapy in the management of BCC is controversial. It has been found that there is significant recurrence after radiotherapy for BCC,<sup>1,16</sup> and such recurrences, particularly those in the midface, are exceptionally difficult to treat successfully by any means, and are at high risk ultimately to cause death.<sup>1</sup> Radiotherapy can be used as an adjuvant therapy to exenteration in cases with orbital invasion by periocular basal cell carcinoma.<sup>17</sup>

**Chemotherapy and other therapies** Chemotherapy is used for cases of non-resectable BCC, when for some reason surgery cannot be undertaken, or for rare cases of metastatic BCC. Cisplatin chemotherapy, used alone or in combination with doxorubicin or with paclitaxel, has been beneficial in case reports.<sup>1,18</sup> The results of

preliminary studies using retinoids (etretinate and isotretinoin) in the management of BCC have been varied.<sup>1</sup>

Over a decade ago intralesional injection of human recombinant  $\alpha$ -interferon was used to treat BCC, with some success.<sup>1,19</sup> A new class of immune response modifier, represented by topical imiquimod cream, was demonstrated to have the potential to provide topical treatment of BCC, either alone or in combination with retinoids.<sup>19,20</sup>

Photodynamic therapy (PDT) is a new, non-invasive procedure that produces tumor destruction. However, although photodynamic therapy with  $\delta$ -aminolevulinic acid is a promising approach in the therapy of dermal lesions, it is not yet an acceptable alternative in the treatment of BCC of the eyelids.<sup>10,21</sup>

## FOLLOW-UP

As two-thirds of recurrences appear within 3 years of treatment and 18% appear between 5 and 10 years, long-term clinical follow-up is necessary.<sup>1,2</sup>

## PROGNOSIS

**Prognostic factors** The prognosis of BCC depends on the size of the tumor, its anatomic location, its pattern of infiltrative growth, and the age of the patient.<sup>1</sup> Large tumors and location in the medial canthal region are the most important clinical features predicting recurrence. A high risk for orbital invasion was found for BCC of the medial and lateral canthus.<sup>1,6</sup> The morpheiform clinical pattern, the histologic finding of an infiltrative growth pattern, or metatypical (basosquamous carcinoma), differentiation have been correlated with deep invasion and greater recurrence after treatment.<sup>1</sup> More aggressive tumors and a higher frequency of recurrence was found in patients under 35 years of age.<sup>1</sup>

**Local spread** The vast majority of BCC grow in a slow but relentless manner. However, localized spontaneous regression has been documented.<sup>22</sup>

BCC invades along the paths of least resistance and then destroys adjacent tissues. Destruction of bone, cartilage, and muscle is usually seen only in the very late stages of the disease. Invasion of lymphatics is common, but does not correlate with the rarely occurring regional metastasis. Some BCCs follow peripheral nerves and can thereby gain access to deeper tissues. Spread to the central nervous system may occur via cranial nerves, the orbital fissure, and cranial foramina. Intraocular invasion by BCC is rare and usually occurs in advanced cases with orbital invasion. The globe is entered through a scleral emissary canal or an old surgical wound.<sup>1</sup>

**Recurrence** The recurrence rate of treated BCC of the eyelid averages 4.2% in the short term and 8.7% for more than 5 years. This varies according to the therapeutic method used. Tumors that recur tend to be more aggressive and difficult to manage.<sup>1-3</sup>

**Metastases and mortality** Metastatic BCC is extremely rare and its rate has been estimated to be between 0.0028 and 0.01%. The most frequent sites of metastasis are the lymph nodes, lungs, bone, liver, and spleen.<sup>1</sup> Clinical features suggesting a greater probability of metastasis include multiple recurrences, an aggressive histological appearance, perineural invasion, and a history of previous ionizing radiation.<sup>18</sup>

Mortality from eyelid and medial canthal BCC is rare, and all deaths recorded were related to intracranial extension.<sup>1</sup>

## REFERENCES

- Margo CE, Waltz K. Basal cell carcinoma of the eyelid and periocular skin. *Surv Ophthalmol* 1993; 38: 169–192.
- Allali J, D'Hermies F, Renard G. Basal cell carcinomas of the eyelids. *Ophthalmologica* 2005; 219: 57–71.
- Malhotra R, Huilgol SC, Huynh NT, Selva D. The Australian Mohs Database, Part I: Periocular basal cell carcinoma. Experience over 7 years. *Ophthalmology* 2004; 111: 624–630.
- Wade TR, Ackerman AB. The many faces of basal-cell carcinoma. *J Dermatol Surg Oncol* 1978; 4: 23–28.
- Bakis S, Irwig L, Wood G, Wong D. Exfoliative cytology as a diagnostic test for basal cell carcinoma: a meta-analysis. *Br J Dermatol* 2004; 150: 829–836.
- Leibovitch I, McNab A, Sullivan T et al. Orbital invasion by periocular basal cell carcinoma. *Ophthalmology* 2005; 112: 717–723.
- Allan E, Pye DA, Levine EL, Moore JV. Non-invasive pulsed ultrasound quantification of the resolution of basal cell carcinomas after photodynamic therapy. *Lasers Med Sci* 2002; 17: 230–237.
- Nori S, Rius-Diaz F, Cuevas J et al. Sensitivity and specificity of reflectance-mode confocal microscopy for in vivo diagnosis of basal cell carcinoma: a multicenter study. *J Am Acad Dermatol* 2004; 51: 923–930.
- Murra DE, Torres A, Schanbacher CF, Gonzales S. Detection of residual basal cell carcinoma by in vivo confocal microscopy. *Dermatol Surg* 2005; 31: 538–541.
- Cook BE Jr, Bartley GB. Treatment options and future prospects for the management of eyelid malignancies: an evidence-based update. *Ophthalmology* 2001; 108: 2088–2098.
- Malhotra R, Huilgol SC, Huynh NT, Selva D. The Australian Mohs Database, Part II. Periocular basal cell carcinoma outcome at 5-year follow-up. *Ophthalmology* 2004; 111: 631–636.
- Lindgren G, Larko O. Long-term follow-up of cryosurgery of basal cell carcinoma of the eyelid. *J Am Acad Dermatol* 1997; 36: 742–746.
- Tuppurainen K. Cryotherapy for eyelid and periocular basal cell carcinomas: outcome in 166 cases over an 8-year period. *Graefes Arch Clin Exp Ophthalmol* 1995; 233: 205–208.
- Kokoszka A, Scheinfeld N. Evidence-based review of the use of cryosurgery in treatment of basal cell carcinoma. *Dermatol Surg* 2003; 29: 566–571.
- Jaramillo-Averbe F. Cryosurgery in difficult to treat basal cell carcinoma. *Int J Dermatol* 2000; 39: 223–229.
- Avril MF, Auferin A, Margulis A et al. Basal cell carcinoma of the face: surgery or radiotherapy? Results of a randomized study. *Br J Cancer* 1997; 76: 100–106.
- Leibovitch I, McNab A, Sullivan T et al. Orbital invasion by periocular basal cell carcinoma. *Ophthalmology* 2005; 112: 717–723.
- Jefford M, Kiffer JD, Somers G et al. Metastatic cell carcinoma: rapid symptomatic response to cisplatin and paclitaxel. *Aust NZ J Surg* 2004; 74: 704–705.
- Wang I, Bauer B, Andersson-Engels S et al. Photodynamic therapy utilising topical delta-aminolevulinic acid in non-melanoma skin malignancies of the eyelid and the periocular skin. *Acta Ophthalmol Scand* 1999; 77: 182–188.
- Ingves C, Jemec GBE. Combined imiquimod and acitretin for non-surgical treatment of basal cell carcinoma. *Scand J Plast Reconstr Surg Hand Surg* 2003; 37: 293–295.
- Rhodes LE, de Rie M, Enström Y et al. Photodynamic therapy using topical methyl aminolevulinate vs surgery for nodular basal cell carcinoma. Results of a multicenter randomized prospective trial. *Arch Dermatol* 2004; 140: 17–23.
- Curson C, Weedon D. Spontaneous regression in basal cell carcinoma. *J Cutan Pathol* 1979; 6: 432–437.

# Squamous cell carcinoma

Mordechai Rosner

## INTRODUCTION

Squamous cell carcinoma (SCC) is an invasive epithelial malignancy that arises from the prickle–squamous cell layers of the epidermis and shows keratinocytic differentiation. It is capable of metastasis to regional lymph nodes and is potentially lethal. SCC was first distinguished from basal cell carcinoma by Kompecher in 1902.<sup>1</sup> The terms ‘squamous cell epithelioma,’ ‘epidermoid carcinoma,’ ‘epithelioma spinocellular,’ ‘prickle cell epithelioma’ and ‘spinalioma’ have all been used in the literature, but ‘squamous cell carcinoma’ is the preferred terminology.

## EPIDEMIOLOGICAL ASPECTS

SCC is the second most common malignant neoplasm of the eyelids after basal cell carcinoma (BCC), comprising 5–10% of all eyelid malignancies.<sup>1–3</sup> Its reported incidence relative to BCC ranges from 1:11 to 1:40.<sup>4,5</sup> The incidence of eyelid SCC varies from 0.9 to 2.42 cases per 100 000 population, with the highest incidence reported from Australia.<sup>3,6,7</sup>

## ETIOLOGY

Extrinsic risk factors for SCC include ultraviolet light and actinic damage, exposure to arsenic, hydrocarbons, radiation, or immunosuppressive drugs.<sup>8</sup> Intrinsic risk factors include albinism, pre-existing chronic skin lesions, and genetic skin disorders such as xeroderma pigmentosum and epidermodysplasia verruciformis.<sup>9</sup>

## CLINICAL FEATURES

SCC occurs most commonly in fair-skinned elderly individuals who have a history of chronic sun exposure.<sup>1,2,9,10</sup> The majority of patients with SCC are 60 years of age or older.<sup>9,10</sup> It has been suggested that the distinct male predominance may represent increased occupational sunlight exposure by males, rather than a genetic predisposition.<sup>9</sup> Periocular SCC occurs most frequently on the lower eyelid, followed by the medial canthus, the upper eyelid, and the lateral canthus, in that order of frequency. The preponderance of lower lid involvement in SCC is not as pronounced as in BCC.<sup>1,10</sup> In some series, SCC of the medial canthus have outnumbered those confined to the eyelid. SCC also has a predilection for the eyelid margin.<sup>1</sup>

**Symptoms and signs** Although the clinical presentation of SCC varies, most often it appears as a painless, elevated, nodular or plaque-like lesion with chronic scaling and fissuring of the skin. Pearly irregular borders and a tendency to develop ulceration with irregular

rolled edges are also characteristic features.<sup>1,10</sup> In a well-differentiated tumor, keratin gives the lesion a grayish-white, granular appearance (Fig. 16.1). Additional presenting features include a small erythematous scaly patch, a cyst-like lesion, a papillomatous lesion, a cutaneous horn, and a large ulcerated lesion. The edges of the lesion are well circumscribed in some cases, and ill defined in others.<sup>1,9,10</sup> Patients with SCC tend to have other tumors of the skin, including intraepidermal carcinoma (Bowen’s disease), senile keratosis, and basal cell carcinoma.<sup>1</sup>

Squamous intraepidermal carcinoma (Bowen’s disease) represents full-thickness involvement of the epidermis by neoplastic cells (carcinoma in situ) with a relatively high risk of progression to invasive SCC.<sup>9</sup> Its clinical manifestation is of a persistent and slowly enlarging erythematous, scaly, or crusted lesion with a sharp, irregular outline.<sup>1,11</sup>

## HISTOPATHOLOGIC FEATURES

**Pathogenesis** SCC arises from the epidermal prickle and squamous cells. Although it may develop de novo, actinic keratosis, Bowen’s disease, and radiation dermatoses are all precursors to the development of SCC.<sup>9,10</sup>

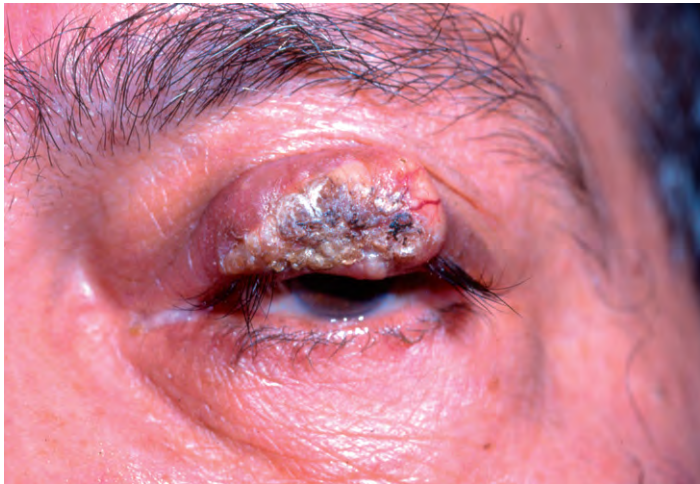
**Evolution** SCC of the eyelid usually begins with an early epithelial phase referred to as actinic keratosis (senile keratosis, solar keratosis), with subtotal replacement of the epidermis by atypical cells (intraepithelial squamous dysplasia). Intraepithelial squamous cell carcinoma or squamous cell carcinoma in situ is diagnosed when there is complete disorganization of the epidermis, with numerous atypical cells that are rounded, large, and with homogeneous, eosinophilic cytoplasm. Invasion of the dermis is the hallmark for the histopathologic diagnosis of invasive SCC (Fig. 16.2).<sup>1</sup>

**Light microscopic features** The invading cells show different degrees of differentiation leading to variable histologic features. In well-differentiated tumors the cells are polygonal, with abundant acidophilic cytoplasm, and prominent hyperchromatic nuclei that vary in size and staining properties. Characteristic findings are of abnormal keratinization with dyskeratotic cells and keratin pearls, and intercellular bridges. Poorly differentiated lesions show an increased degree of cellular anaplasia, with irregularly shaped and sized cells, enlarged nuclei, abnormal mitoses, little or no evidence of keratinization, and loss of intercellular bridges (Fig. 16.3).



**BOX 16.1 Salient Diagnostic Features of Squamous Cell Carcinoma**

- Painless nodular, plaque-like or ulcerated lesions with scaling and fissuring of the skin and irregular, rolled, pearly borders
- Microscopic findings of infiltrative neoplasm arising from the epidermis and composed of polygonal cells with abundant acidophilic cytoplasm and prominent, hyperchromatic, pleomorphic nuclei
- The presence of dyskeratotic cells with the formation of keratin pearls and intercellular bridges



**Fig. 16.1** Squamous cell carcinoma of the upper lid presenting as an irregular, elevated lesion with masses of keratin.

**Variants** Less common histologic variants include the spindle cell and adenoid (adenoacanthoma or pseudoglandular) squamous cell carcinoma. The adenoid SCC variant is characterized by extensive acantholysis and tubular and pseudoglandular patterns.<sup>1</sup>

**DIAGNOSTIC EVALUATION**

Because of its variable clinical presentation, biopsy and histological examination are required for an accurate diagnosis.<sup>1</sup> Examination of the face or extremities for other types of premalignant lesions may aid in the diagnosis.<sup>1,10</sup> The diagnosis of perineural spread and orbital invasion may be confirmed with appropriate imaging techniques.

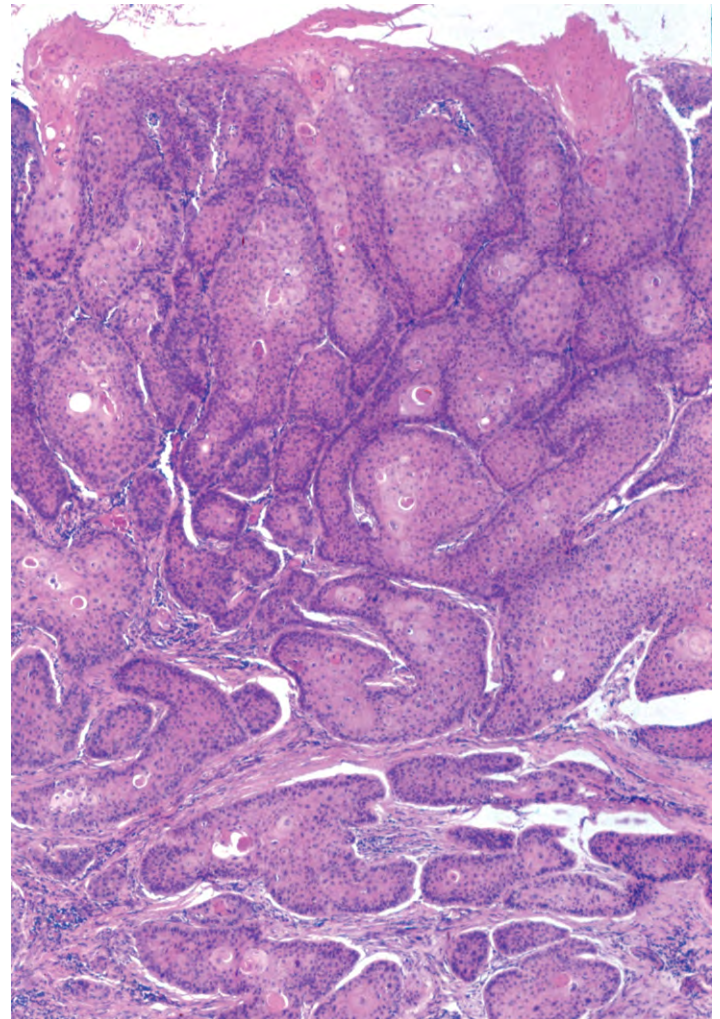
**DIFFERENTIAL DIAGNOSIS**

SCC of the eyelid and periocular region typically has no pathognomonic feature that allows its differentiation from other cutaneous lesions, and it may mimic many other types of skin lesion, both benign and malignant.<sup>1,10</sup>

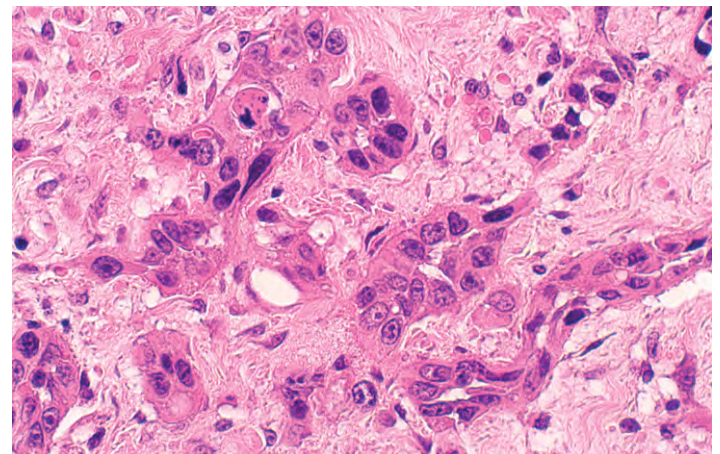
**TREATMENT**

**Preventive** Prevention by minimizing sun exposure, especially in childhood and adolescence, remains of prime importance in minimizing the morbidity and mortality associated with SCC.

**Therapeutic** The main treatment modality used for eyelid SCC is surgical excision, with microscopic monitoring of the margins or Mohs' microsurgery. A variety of other forms of therapy, such as



**Fig. 16.2** Invasive well-differentiated squamous cell carcinoma showing invasion of the dermis by tumor polygonal cells that vary in size and staining properties.



**Fig. 16.3** Poorly differentiated squamous cell carcinoma showing cellular anaplasia with irregularly shaped and sized cells, enlarged nuclei, and no evidence of keratinization.

radiation therapy, cryotherapy, chemotherapy, curettage with carbon dioxide laser, photodynamic therapy, and treatment with retinoids or  $\alpha$ -interferone. When used alone, these therapies have high recurrence rates, which are not acceptable for SCC of the eyelid, where recurrent tumors can be more aggressive and invasive. However, they may be appropriate for patients who cannot tolerate or who decline surgery.<sup>10</sup>

**Surgery** Only surgical excision with monitoring of the margins using either a frozen-section or a paraffin-section control, or Mohs' micrographic surgery are acceptable treatment options for periocular SCC.<sup>1,2,10,11</sup> The treatment of choice for secondary orbital invasion of SCC is orbital exenteration.<sup>1,9</sup>

**Sentinel lymph node biopsy** The presence of regional lymph node metastases is the single most important prognostic factor for most solid neoplasms, and complete lymph node dissection with pathologic examination of a cross-section of a lymph node is considered the gold standard in staging patients for adjuvant therapy. However, its therapeutic value is questionable and it may be associated with considerable morbidity.<sup>10</sup> The sentinel lymph node biopsy has been suggested as a potentially useful technique to stage periocular SCC, especially in patients with recurrent, large, or highly invasive lesions, or those with perineural invasion.<sup>10,12</sup>

**Radiation therapy** has been used in the treatment of eyelid malignancies since the beginning of the 20th century. However, SCC is relatively radioresistant and responds even less than BCC to radiation.<sup>1</sup> However, postoperative radiotherapy has been recommended in all patients with microscopic perineural invasion.<sup>13</sup> Three-dimensional conformal planning or intensity-modulated radiation therapy is needed to minimize damage to adjacent structures, and synchronous chemotherapy should be considered to potentiate the effectiveness of radiation. The role of surgery in the treatment of perineural spread is only palliative.<sup>14</sup>

**Chemotherapy** may be used for patients with systemic disease and for those who cannot tolerate surgical excision or who decline surgery.<sup>15</sup> It is usually used as an adjuvant to surgery and radiotherapy in aggressive infiltrating SCC.

**Photodynamic therapy (PDT)** is emerging as a promising treatment for patients with multiple or large SCC or in whom surgery is not appropriate. In such cases PDT is associated with reasonable efficacy, good cosmesis, and limited morbidity. However, until prospective controlled trials are performed, the precise role of PDT in relation to more conventional surgical approaches remains to be defined.<sup>16,17</sup>

## PROGNOSIS

**Prognostic factors** High-risk eyelid SCC lesions are those larger than 2 cm, with poor histological differentiation, deep invasion, and the presence of perineural invasion. Recurrent tumors and tumors developing in scars or in immunocompromised patients also imply a poor prognosis.<sup>18,19</sup> The histologic variant of adenoid SCC is associated with a better prognosis.<sup>1</sup>

**Local spread** Eyelid SCC is potentially fatal and responsible for considerable morbidity.<sup>9</sup> Aggressive or neglected cases of eyelid SCC may spread into the lacrimal passages, the orbit, and the intracranial cavity. SCC is by far the most frequent of the secondary epithelial neoplasms in the orbit.<sup>1</sup> However, orbital invasion is a rare complication that has been reported to occur in 2.5% of all eyelid BCC and SCC.<sup>20</sup> Orbital invasion of eyelid SCC may take years to occur, often preceded by several surgical interventions, irradiations, and recurrences of the tumor. If left unattended, the entire orbital region and a major portion of the face are destroyed in an ulcerating, fungating crater.<sup>1</sup> Orbital spread is usually associated with complete ptosis, ophthalmoplegia, and proptosis. Eventually, involvement of the orbital nerves and bones causes severe and constant pain.<sup>1,9</sup>

**Perineural spread** of SCC occurs in up to 14% of facial lesions.<sup>21</sup> The perineural infiltration of SCC of the eyelids along branches of the trigeminal nerve, the extraocular motor nerves, and the facial nerve facilitates its spread into the orbit, periorbital structures, and intracranial cavity.<sup>22</sup> Once clinical signs or symptoms of perineural spread have developed the prognosis is poor, with around 50% recurrence after simple excision.<sup>21</sup>

**Local recurrence** The 5-year local recurrence rate for SCC is about 23%. The 5-year metastatic rates vary between 5% and 45%.<sup>18,23</sup> The recurrence rate of periocular squamous intraepithelial carcinoma is 5% and 12% for primary and recurrent lesions, respectively.<sup>11</sup>

**Metastasis** Unlike BCC, SCC has a tendency to metastasize to regional lymph nodes and distant sites through hematogenous and lymphatic pathways. The incidence of lymph node metastasis from eyelid SCC has ranged from 0% to as high as 21%, and of distant metastasis varies from 1% to 21%.<sup>1,24,25</sup> The incidence of metastasis of SCC arising from actinic keratoses is lower than for SCC arising de novo.<sup>1</sup>

**Mortality** The tumor-related mortality rates have been reported to be as high as 40%, and an increased rate is associated with lesions of the upper lid and medial canthus.<sup>1</sup> However, if detected early and treated adequately, the prognosis of SCC is generally excellent and the risk of death and disability can be minimized.<sup>9</sup>

## REFERENCES

- Reiffer DM, Hornblass A. Squamous cell carcinoma of the eyelid. *Surv Ophthalmol* 1986; 30: 349-365.
- Malhotra R, Huilgol SC, Huynh N, Selva D. The Australian Mohs database: periocular squamous cell carcinoma. *Ophthalmology* 2004; 111: 617-623.
- Cook BE Jr, Bartley GB. Epidemiological characteristics and clinical course of patients with malignant eyelid tumors in an incidence cohort in Olmsted County, Minnesota. *Ophthalmology* 1999; 106: 746-750.
- Kwitko ML, Boniuk M, Zimmerman LE. Eyelid tumors with reference to lesions confused with squamous cell carcinoma. I. Incidence and errors in diagnosis. *Arch Ophthalmol* 1963; 69: 693-697.
- Aurora A, Blodi F. Lesions of the eyelids. A clinicopathologic study. *Surv Ophthalmol* 1970; 15: 94-104.
- Scotto J, Kopf AW, Urbach F. Non-melanoma skin cancer among Caucasians in four areas of the United States. *Cancer* 1974; 34: 1333-1338.
- Green A. Changing patterns in incidence of non-melanoma skin cancer. *Epith Cell Biol* 1992; 1: 47-51.
- Maclean H, Dhillon B, Ironside J. Squamous cell carcinoma of the eyelid and the acquired immunodeficiency syndrome. *Am J Ophthalmol* 1996; 121: 219-221.
- Donaldson MJ, Sullivan TJ, Whitehead KJ, Williamson RM. Squamous cell carcinoma of the eyelids. *Br J Ophthalmol* 2002; 86: 1161-1165.

10. Cook BE Jr, Bartley GB. Treatment options and future prospects for the management of eyelid malignancies: an evidence-based update. *Ophthalmology* 2001; 108: 2088–2098.
11. Malhotra R, James CL, Selva D et al. The Australian Mohs database: periocular squamous intraepidermal carcinoma. *Ophthalmology* 2004; 111: 1925–1929.
12. Faustina M, Diba R, Ahmadi MA et al. Patterns of regional and distant metastasis in patients with eyelid and periocular squamous cell carcinoma. *Ophthalmology* 2004; 111: 1930–1932.
13. McNab AA, Francis IC, Bengner R et al. Perineural spread of cutaneous squamous cell carcinoma via the orbit: clinical features and outcome in 21 cases. *Ophthalmology* 1997; 104: 1457–1462.
14. Boweyer JD, Sullivan TJ, Whitehead KJ et al. The management of perineural spread of squamous cell carcinoma to the ocular adnexae. *Ophthalmol Plast Reconstr Surg*. 2003; 19: 275–281.
15. Luxenberg MN, Guthrie TH Jr. Chemotherapy of basal cell and squamous cell carcinoma of the eyelids and periorbital tissues. *Ophthalmology* 1985; 93: 504–510.
16. Marmur ES, Schmults CD, Goldberg DJ. A review of laser and photodynamic therapy for the treatment of nonmelanoma skin cancer. *Dermatol Surg* 2004; 30: 264–271.
17. Rossi R, Puccioni M, Mavilia L et al. Squamous cell carcinoma of the eyelid treated with photodynamic therapy. *J Chemother* 2004; 16: 306–309.
18. Rowe DE, Carroll RJ, Day CL Jr. Prognostic factors for local recurrence, metastasis, and survival rates in squamous cell carcinoma of the skin, ear, and lip. Implications for treatment modality selection. *J Am Acad Dermatol* 1992; 26: 976–990.
19. Committee on Guidelines of Care, Task Force on Cutaneous Squamous Cell Carcinoma. Guidelines of care for cutaneous squamous cell carcinoma. *J Am Acad Dermatol* 1993; 28: 628–631.
20. Howard GR, Nerad JA, Carter KD et al. Clinical characteristics associated with orbital invasion of cutaneous basal cell and squamous cell tumours of the eyelid. *Am J Ophthalmol* 1992; 113: 123–133.
21. Goepfert H, Dichtel WJ, Medina JE et al. Perineural invasion in squamous cell carcinoma of the head and neck. *Am J Surg* 1984; 148: 542–547.
22. Cotel WI. Perineural invasion by squamous-cell carcinoma. *J Dermatol Surg Oncol* 1982; 8: 589–600.
23. Petter G, Hausteil UF. Histologic subtyping and malignancy assessment of cutaneous squamous cell carcinoma. *Dermatol Surg* 2000; 26: 521–530.
24. Loeffler M, Hornblase A. Characteristics and behavior of eyelid carcinoma. *Ophthalmic Surg* 1990; 21: 513–518.
25. Faustina M, Diba R, Ahmadi MA et al. Patterns of regional and distant metastasis in patients with eyelid and periocular squamous cell carcinoma. *Ophthalmology* 2004; 111: 1930–1932.



# Sebaceous gland carcinoma

Mordechai Rosner

## INTRODUCTION

Sebaceous gland carcinoma (SGC) is a malignant neoplasm capable of aggressive local behavior and metastasis to regional lymph nodes and distant organs. It originates from cells of the sebaceous glands and occurs most often in the periorbital area, usually in the eyelid.<sup>1</sup> This lesion is considered among the most lethal of all ocular adnexal tumors.<sup>2</sup>

Thiersch may have reported the first case of periorbital SGC in 1865, and Baldauf reported another case in 1870. However, Allaire is credited with the first well-documented case of adenocarcinoma of the meibomian gland in 1891, and most of the modern understanding of eyelid SGC was initiated by the review of Straatsma in 1956.<sup>2</sup> The terms ‘sebaceous gland carcinoma,’ ‘sebaceous cell carcinoma’ and ‘sebaceous carcinoma’ are all used interchangeably in the literature.

## EPIDEMIOLOGICAL ASPECTS

The incidence of SGC varies in different series. In the United States, SGC accounts for only 5% of all malignant eyelid tumors, whereas basal cell carcinoma (BCC) accounts for 90%, and squamous cell carcinoma (SCC) and others tumors including melanoma, represent the remaining 5% of cases. The annual incidence of eyelid SGC in the United States is about 0.5 per million in the white population older than 20 years, and the incidence may be increasing.<sup>3,4</sup> In addition, SGC is more common in Caucasians than in African-Americans.<sup>5</sup> A higher incidence of SGC has been observed in China, India, and other Asian countries, where it may be as prevalent as or even more common than periocular BCC and SCC.<sup>1</sup>

## ETIOLOGY

There are no systemic conditions that convincingly predispose to SGC. Ocular or facial irradiation for the treatment of hereditary retinoblastoma, acne, cutaneous hemangioma, and eczema are important risk factors.<sup>1</sup> The relationship between the use of diuretic medications and the development of SGC is not firmly proven.<sup>1,4</sup> Occasional reports have suggested an association between SGC at a relatively young age and immune dysfunction. A possible relationship between SGC and human papillomavirus (HPV) has also been observed.<sup>1</sup>

## CLINICAL FEATURES

SGC is generally a disease of older individuals, with a reported mean age at diagnosis of 57–72 years.<sup>2,6</sup> However, it may develop in older children and young adults, particularly after irradiation for

retinoblastoma.<sup>1</sup> Although reports regarding gender have varied, SGC is usually reported to have an over 70% predominance in women.<sup>1,6</sup>

Although SGC has a marked tendency to arise in the ocular region, it is estimated that approximately 25% occur in regions other than the head and neck.<sup>7</sup> The majority of SGC arise from the meibomian glands within the tarsus. About 65% occur in the upper eyelid, 25% in the lower eyelid, 5% involve both eyelids,<sup>2,6</sup> and 5% arise in the caruncle.<sup>4,6,8</sup> Occasional cases of primary SGC of the conjunctiva and even of the lacrimal gland are reported.<sup>1</sup> (Box 17.1)

## Symptoms and signs

**Solitary nodule of the eyelid** The most common clinical variant of SGC is a solitary, firm, painless, sessile subcutaneous round nodule fixed to the tarsus (Fig. 17.1). With enlargement, the tumor may assume a yellow color owing to the lipids it contains. However, SGC that arises from the glands of Zeis is located at the eyelid margin and has no firm attachment to the tarsus. The tumor eventually causes loss of cilia, as observed with other eyelid malignant tumors (Fig. 17.1).<sup>1</sup> Rarely, SGC may become ulcerated.

**Diffuse thickening of the eyelid** Unilateral diffuse thickening of the eyelid is the second most frequent presentation of SGC. The diffuse tumor may extend into the epithelium of the forniceal or bulbar conjunctiva, and even the cornea (Fig. 17.2). Rarely, SGC arising from the glands of Zeis can become pedunculated, keratinized, and even appear as a cutaneous horn. When SGC develops in the caruncle, it appears as an irregular yellow mass that usually is not fixed to adjacent structures.<sup>1,9</sup>

## HISTOPATHOLOGIC FEATURES

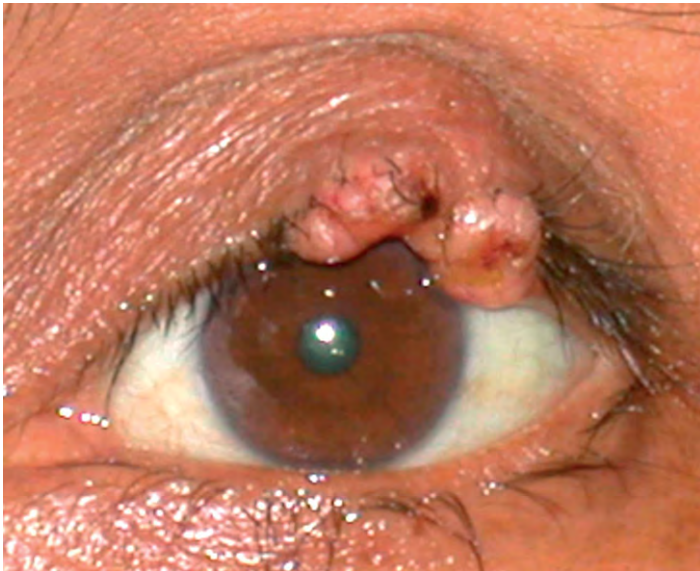**Pathogenesis** Periocular SGC arises from the sebaceous glands in the ocular region, including meibomian glands in the tarsus, glands of Zeis of the cilia, pilosebaceous glands of the caruncle, and from the conjunctival epithelium.<sup>1</sup> It may exhibit multicentric origins.<sup>10,11</sup> Most SGC appear to arise de novo and not from a pre-existing sebaceous adenoma, sebaceous hyperplasia, or sebaceous (organoid) nevus.<sup>1</sup>

**Light microscopic features** Histopathologically, SGC is an unencapsulated infiltrating mass composed of cells with finely vacuolated, frothy cytoplasm, pronounced nuclear pleomorphism, and usually high mitotic activity (Fig. 17.3).<sup>1</sup> The presence of lipid can be demonstrated with the oil red-O stain (Fig. 17.4). This lipid can incite a foreign body giant cell reaction. SGC is associated with a chronic inflammatory response that is less intense than in BCC.<sup>1,12</sup>

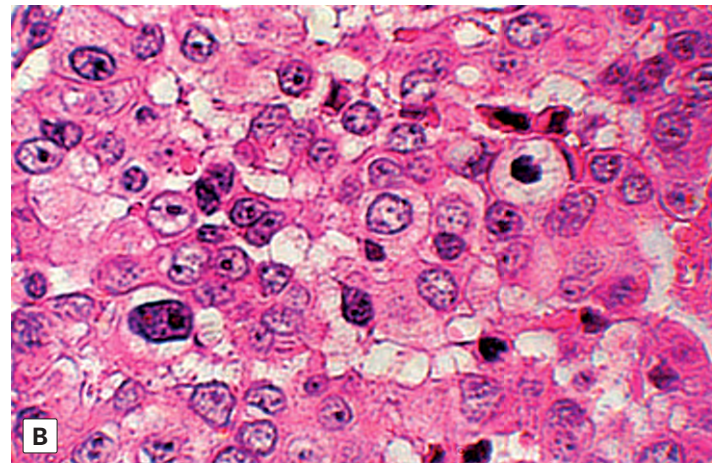
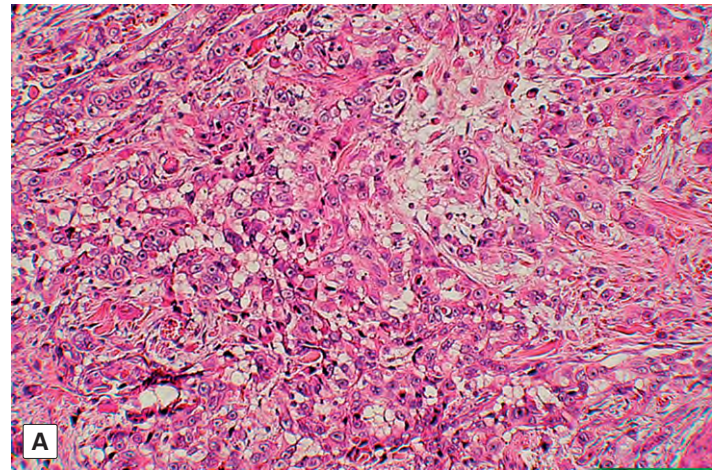
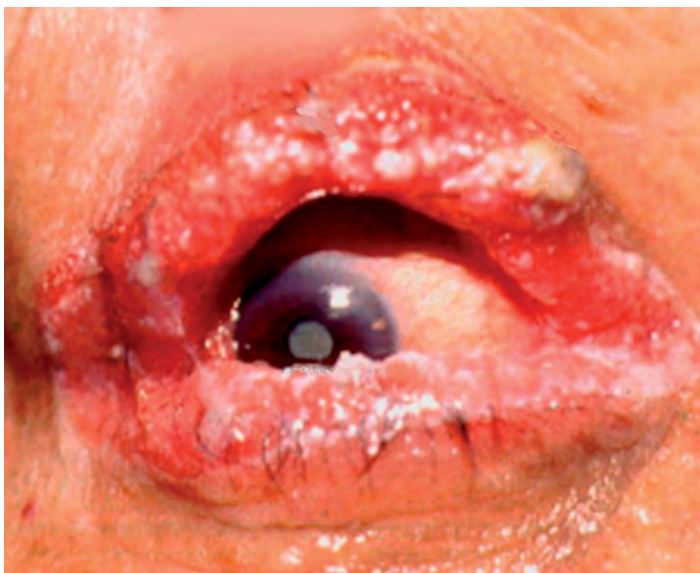

**BOX 17.1 Salient Diagnostic Features of Sebaceous Gland Carcinoma**

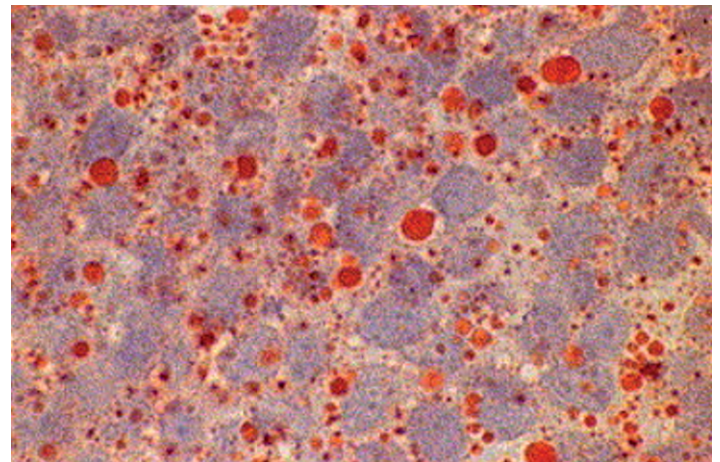
- A unilateral, solitary, sessile subcutaneous round nodule that is firm, painless, and yellow, masquerading as chalazion
- Unilateral diffuse thickening of the eyelid and/or the conjunctiva masquerading as blepharoconjunctivitis
- Microscopic findings of an infiltrating mass composed of cells with lipid vacuoles in the cytoplasm, pronounced nuclear pleomorphism, and mitotic activity
- Flat superficial involvement of the epithelium – ‘pagetoid growth pattern’
- Positive oil red-O stain for lipid
- Immunohistologic expression of HMFG1, EMA and BRST-1, but not of cytokeratins



**Fig. 17.1** Sebaceous gland carcinoma arising in left upper eyelid – a firm, sessile subcutaneous round nodule fixed to the tarsus. (Courtesy of Dr Santosh Honavar.)



**Fig. 17.3** (A) Histopathologically sebaceous gland carcinoma is an unencapsulated infiltrating mass. (Hematoxylin–eosin  $\times 100$ .) (B) The tumor is composed of cells with finely vacuolated, frothy cytoplasm and pronounced nuclear pleomorphism. (Hematoxylin–eosin  $\times 400$ .)



**Fig. 17.4** Accentuation of the lipid using oil red-O stain. The lipid globules have a red color. (Frozen section, oil red-O  $\times 250$ .) Reproduced with permission from Shields JA, Demirci H, Marr BP et al. Sebaceous carcinoma of the ocular region: a review. *Surv Ophthalmol* 2005; 50: 103–122.

**Fig. 17.2** Diffuse involvement of the eyelids by sebaceous gland carcinoma causing loss of cilia. (Courtesy of Dr Santosh Honavar.)



**Table 17.1 Immunohistochemistry profile of common malignant eyelid tumors**

Tumor antibody	Tumor type (% positive cases)		
	Sebaceous gland carcinoma	Basal cell carcinoma	Squamous cell carcinoma
EMA and BRST-1	64	0	36
EMA and Cam 5.2	73	6	0
EMA and Cam 5.2	55	0	0

EMA, anti-epithelial membrane antigen; BRST-1, anti-BCA 225; Cam 5.2, anti-low molecular weight keratin. (Modified from Sinard JH. Immunohistochemical distinction of ocular sebaceous carcinoma from basal cell and squamous cell carcinoma. Arch Ophthalmol 1999; 117: 776–783)

**Pagetoid spread** SGC exhibits peculiar intraepithelial spread into the eyelid epidermis and the conjunctival epithelium in 44–80% of cases.<sup>1,5,6</sup> This flat superficial involvement of the epithelium is usually referred to as ‘pagetoid spread.’

**Immunohistochemistry** The histopathologic diagnosis of SGC can usually be made readily on routine light microscopy. However, immunohistochemistry replaces the need for fat stains on frozen sections and may help to differentiate SGC from basal and squamous cell carcinoma. The central foamy cells of SGC express human milk fat globulin-1 (HMFG1) and epithelial membrane antigen (EMA), but not cytokeratins, whereas the small peripheral basal and duct cells generally express cytokeratin but not HMFG1 or EMA. SGC also expresses Cam 5.2 and BRST-1, whereas BCC expresses neither EMA nor BRST-1, and SCC expresses EMA but not Cam 5.2 (Table 17.1).<sup>1,13</sup>

**Histopathological classification** In addition to being well, moderately, or poorly differentiated,<sup>1</sup> SGC can be readily classified into one of four patterns: lobular, comedocarcinoma, papillary, and mixed.<sup>1</sup>

**Lobular pattern** is the most common and has an architecture similar to that of a normal sebaceous gland, with fewer differentiated cells peripherally and more differentiated lipid-producing cells located centrally.

**Comedocarcinoma pattern** A large necrotic central core surrounded by viable cells characterizes the comedocarcinoma pattern.

**Papillary pattern** which occurs frequently in small conjunctival lesions, is distinguished by papillary projections and areas of sebaceous differentiation.

**Mixed pattern** exhibits any combination of these three patterns.

## DIAGNOSTIC EVALUATION

Full-thickness excisional or incisional biopsy of the eyelid is the preferred method of confirming the suspected clinical diagnosis of SGC. When diffuse involvement of eyelid and conjunctiva is suspected, multiple conjunctival map biopsies should be performed to determine the extent of the disease.<sup>1,6</sup> Fine needle aspiration biopsy and

impression cytology have been used to detect conjunctival spread, but these methods are generally not advisable because of the limited amount of tissue obtained. However, fine needle biopsy may be acceptable for the diagnosis of regional lymph node metastases.<sup>1</sup> Only in cases with suspected diffuse involvement of the eyelid and conjunctiva is orbital imaging indicated, either before or after the initial biopsy, to rule out posterior extension.<sup>1</sup>

## DIFFERENTIAL DIAGNOSIS

SGC is notorious for its variable clinical presentation and its ability to masquerade, both clinically and histopathologically, as common benign or less invasive conditions, resulting in delayed diagnosis and treatment.<sup>1,2,6</sup>

**Chalazion** In the early stages SGC of the eyelids can be very similar to chalazion. However, in contrast to SGC, chalazion generally occurs in younger individuals, is more circumscribed and painful, and is usually not associated with loss of cilia. However, recurrent chalazia, as well as chalazia in older patients, should undergo a biopsy to rule out SGC.

**Inflammatory conditions** Virtually any inflammatory condition of the eyelid and the conjunctiva must be included in the differential diagnosis of SGC. These include unilateral blepharitis, conjunctivitis, meibomitis, superior limbic keratoconjunctivitis, papillary conjunctivitis, cicatricial pemphigoid, conjunctival granuloma, and sarcoidosis. Thus, SGC should be suspected in every middle-aged or older patient with a diagnosis of unilateral blepharitis or other inflammatory conditions that do not respond to usual therapy.<sup>1</sup>

**Benign and malignant tumors** Several benign and malignant tumors can have a clinical appearance similar to that of SGC. These include BCC, SCC, melanoma, Merkel cell carcinoma, lymphoma, sweat gland neoplasm, junctional squamous papilloma, hereditary benign intraepithelial dyskeratosis, metastatic carcinoma, and other rare tumors.<sup>1</sup>

**Basal cell carcinoma** The nodular BCC is more common on the lower lid and is white rather than yellow. BCC is also more likely to become ulcerated than SGC. Although diffuse sclerosing BCC may closely simulate SGC, it very rarely exhibits diffuse invasion of the conjunctiva. Histologically, BCC typically shows peripheral palisading of nuclei and retraction artifact that are not seen in SGC.

**Squamous cell carcinoma** SCC is more superficial and lacks a yellow color. Conjunctival intraepithelial neoplasia can be very similar to diffuse epithelial invasion by SGC, except for eyelid involvement, which is less likely to be present in SGC. Histopathologically, SCC is the lesion most often confused with SGC.<sup>6,14,15</sup> Unlike SGC, SCC cells have more abundant eosinophilic cytoplasm, lack lipid vacuoles, and demonstrate eddy formation and keratin cysts.

**Melanoma** Nodular or diffuse cutaneous melanoma in the eyelid or conjunctiva can usually be distinguished from SGC by its black or brown pigmentation, but amelanotic melanoma can resemble SGC.

**Other tumors** Merkel cell carcinoma of the eyelid is distinguished by its red or red-blue color. Lymphoma of the eyelid arises from deeper layers than does SGC, and in the conjunctiva it has a

characteristic 'salmon patch' color. Moreover, inflammatory signs that are commonly associated with SGC are lacking in lymphoma.

## TREATMENT

**Surgery** The most acceptable management of periocular SGC is complete surgical removal.<sup>16</sup> Excisional biopsy of a small lesion is recommended even before histopathologic verification of the diagnosis.<sup>1</sup> Either frozen section control or Mohs' microsurgery is usually used at the time of tumor excision, to evaluate the margins, and the resection is continued until the margins are histopathologically clear. However, there is controversy as to which is preferable and whether either technique is better than waiting for permanent sections, because of the difficulty in diagnosing SGC in frozen sections.<sup>1,17,18</sup> It has been suggested that wide margins, of at least 5 mm, should be taken in order to prevent recurrence. Orbital exenteration is currently performed less often, but is still indicated for advanced and diffuse SGC with orbital invasion in the absence of metastasis.<sup>1</sup>

**Cryotherapy** As the removal of wide margins is not possible in the case of conjunctival lesions, supplemental treatment by double freeze-thaw cycle cryotherapy is indicated. Combination therapy with cryotherapy, topical chemotherapy,<sup>19-21</sup> and radiotherapy<sup>22</sup> can also be used in advanced cases.<sup>1</sup>

**Topical chemotherapy** Topical chemotherapy with mitomycin C drops has been found to be effective as an alternative to complete conjunctivectomy or exenteration in selected cases.<sup>19-21</sup>

**Sentinel lymph node biopsy** The technique of sentinel node biopsy has been suggested as a potentially useful method for SGC of the eyelid and conjunctiva.<sup>23</sup> Localized regional lymph node metastasis is treated by lymph node dissection or by a combination of chemotherapy and radiotherapy.<sup>24</sup>

**Radiotherapy** Although irradiation is not highly effective in the management of SGC, it has occasionally been advocated in selected cases.<sup>1,22,24</sup>

**Systemic chemotherapy** Regional spread to lymph nodes and hematogenous metastasis to distant organs is treated by chemotherapy.<sup>1,24</sup>

## PROGNOSIS

**Metastasis** The most common path of metastasis of eyelid SGC is via the lymphatic channels to regional lymph nodes, which occurs in about 30% of cases. From the upper eyelid it tends to metastasize to

**Table 17.2 Survival rates with eyelid sebaceous gland carcinoma**

First author	Year	Country	Cases	Mortality rate (%)	Follow-up (years)
Boniuk	1968	United States	88	30	5
Ni	1979	China	100	41	5-15
Ni	1982	China	82	24	4
Rao	1982	United States	104	22	5
Doxanas	1984	United States	40	15	Not available
Zurcher	1998	England	43	9	3
Muqit	2004	Scotland	32	3	5

(Reproduced with permission from Muqit MM, Roberts F, Lee WR, Kemp E. Improved survival rates in sebaceous carcinoma of the eyelid. *Eye* 2004;18:49-53)

preauricular and parotid nodes, which are the most common sites of metastasis, and from the lower lid region it tends to metastasize to the submandibular and cervical nodes.<sup>1</sup> Advanced cases of eyelid SGC occasionally exhibit distant metastasis, probably by hematogenous spread, mainly to the liver, lung, bone, and brain.<sup>1,4</sup>

**Local growth** Regardless of its origin, SGC can show direct local extension beyond its original site and involve the entire eyelid, the adjacent eyelid, and invade the orbital soft tissues, lacrimal secretory system, lacrimal excretory system, and the cranial cavity. Such local growth is more likely to occur in neglected or recurrent cases.<sup>1,5</sup>

**Local recurrence** The 5-year local recurrence rates following wide excision have ranged from 9% to 36%.<sup>25</sup>

**Prognostic factors** The visual prognosis varies with the extent of the disease and the type of treatment employed.<sup>1</sup> Various factors have been associated with a worse prognosis, including vascular, lymphatic, and orbital invasion; involvement of both upper and lower eyelids; poor differentiation; multicentric origin; duration of symptoms more than 6 months; tumor diameter exceeding 10 mm; a highly infiltrative pattern; pagetoid invasion; and hyperexpression of tumor suppressor gene p53.<sup>1</sup> All patients with SGC should be followed regularly because of the risk of recurrence as well as the potential for metastasis and mortality.

**Mortality** Although the 5-year tumor-related death rate was estimated in the past to be as high as 30%,<sup>26</sup> increased awareness and earlier aggressive treatment have markedly improved this to less than 10% (Table 17.2).<sup>2,27</sup>

## REFERENCES

- Shields JA, Demirci H, Marr BP et al. Sebaceous carcinoma of the ocular region: a review. *Surv Ophthalmol* 2005; 50: 103-122.
- Kass LG, Hornblass A. Sebaceous carcinoma of the ocular adnexa. *Surv Ophthalmol* 1989; 33: 477-490.
- Margo CE, Mulla ZD. Malignant tumors of the eyelid: a population-based study of non-basal cell and non-squamous cell malignant neoplasms. *Arch Ophthalmol* 1998; 116: 195-198.
- Khan JA, Doane JF, Grove AS. Sebaceous and meibomian carcinomas of the eyelid. Recognition, diagnosis, and management. *Ophthalm Plast Reconstr Surg* 1991; 7: 61-66.
- Rao NA, Hiadayat AA, McLean IW et al. Sebaceous carcinomas of the ocular adnexa: A clinicopathologic study of 104 cases, with five-year follow-up data. *Hum Pathol* 1982; 13: 113-122.
- Shields JA, Demirci H, Marr BP, Eagle RC Jr, Shields CL. Sebaceous carcinoma of the eyelids. Personal experience with 60 Cases. *Ophthalmology* 2004; 111: 2151-2157.
- Wick MR, Goellner JR, Wolfe JT et al. Adnexal carcinomas of the skin. II. Extraocular sebaceous carcinomas. *Cancer* 1985; 56: 1163-1172.
- Shields CL, Shields JA, White D et al. Types and frequency of lesions of the aruncle. *Am J Ophthalmol* 1986; 102: 771-778.

9. Shields JA, Shields CL. Sebaceous carcinoma of the glands of Zeis. *Ophthalm Plast Reconstr Surg* 1988; 4: 11–14.
10. Cavanagh HD, Green WR, Goldberg HK. Multicentric sebaceous adenocarcinoma of the meibomian gland. *Am J Ophthalmol* 1974; 77: 326–332.
11. von Below H, Rose GE, McCartney AC et al. Multicentric sebaceous gland carcinoma of the lid? *Br J Ophthalmol* 1993; 77: 819–820.
12. Herman DC, Chan CC, Bartley GB et al. Immunohistochemical staining of sebaceous cell carcinoma of the eyelid. *Am J Ophthalmol* 1989; 107: 127–132.
13. Sinard JH. Immunohistochemical distinction of ocular sebaceous carcinoma from basal cell and squamous cell carcinoma. *Arch Ophthalmol* 1999; 117: 776–783.
14. Kwitko ML, Boniuk M, Zimmerman LE. Eyelid tumors with reference to lesions confused with squamous cell carcinoma: incidence and errors in diagnosis. *Arch Ophthalmol* 1963; 69: 696–697.
15. Lai TF, Huilgol SC, Selva D et al. Eyelid sebaceous carcinoma masquerading as in situ squamous cell carcinoma. *Dermatol Surg* 2004; 30: 222–225.
16. Cook BE Jr, Bartley GB. Treatment options and future prospects for the management of eyelid malignancies: an evidence-based update. *Ophthalmology* 2001; 108: 2088–2098.
17. Folberg R, Whitaker DC, Tse DT et al. Recurrent and residual sebaceous carcinoma after Mohs' excision of the primary lesion. *Am J Ophthalmol* 1987; 103: 817–823.
18. Spencer JM, Nossa R, Tse DT et al. Sebaceous carcinoma of the eyelid treated with Mohs micrographic surgery. *Am Acad Dermatol* 2001; 44: 1004–1009.
19. Shields CL, Naseripour M, Shields JA et al. Topical mitomycin-C for pagetoid invasion of the conjunctiva by eyelid sebaceous gland carcinoma. *Ophthalmology* 2002; 109: 2129–2133.
20. Rosner M, Hadar I, Rosen N. Successful treatment with mitomycin C eye drops for conjunctival diffuse intraepithelial neoplasia with sebaceous features. *Ophthalm Plast Reconstr Surg* 2003; 19: 477–479.
21. Tumuluri K, Kourt G, Martin P. Mitomycin C in sebaceous gland carcinoma with pagetoid spread. *Br J Ophthalmol* 2004; 88: 718–719.
22. Yen MT, Tse DT, Wu X et al. Radiation therapy for local control of eyelid sebaceous cell carcinoma: report of two cases and review of the literature. *Ophthalm Plast Reconstr Surg* 2000; 16: 211–215.
23. Nijhawan N, Ross MI, Diba R et al. Experience with sentinel lymph node biopsy for eyelid and conjunctival malignancies at cancer center. *Ophthalm Plast Reconstr Surg* 2004; 20: 291–295.
24. Murthy R, Honavar SG, Burman S et al. Neoadjuvant chemotherapy in the management of sebaceous gland carcinoma of the eyelid with regional lymph node metastasis. *Ophthalm Plast Reconstr Surg* 2005; 21: 307–309.
25. Callahan EF, Appert DL, Roenigk RK, Bartley GB. Sebaceous carcinoma of the eyelid: a review of 14 cases. *Dermatol Surg* 2004; 30: 1164–1168.
26. Boniuk M, Zimmerman LE. Sebaceous carcinoma of the eyelid, eyebrow, caruncle, and orbit. *Trans Am Acad Ophthalmol Otolaryngol* 1968; 72: 619–641.
27. Muqit MM, Roberts F, Lee WR, Kemp E. Improved survival rates in sebaceous carcinoma of the eyelid. *Eye* 2004; 18: 49–53.



# Melanoma of the eyelid

Jacob Pe'er and Robert Folberg

## INTRODUCTION

Cutaneous melanoma of the eyelid is a rare tumor, representing fewer than 1% of all malignant neoplasms of the eyelid skin,<sup>1</sup> 1% of all skin melanomas,<sup>2</sup> and 7% of cutaneous malignant melanomas of the head and neck region.<sup>3</sup> Many primary melanomas of the eyelid involve the mucosal surfaces of the palpebral and bulbar conjunctiva, and in these cases one must manage not only the eyelid but also the conjunctival component of the lesion. One may reasonably argue that primary conjunctival melanomas may secondarily affect the eyelid.

This chapter therefore focuses on the rare subset of melanomas confined to the eyelid skin. Our knowledge of cutaneous melanoma of the eyelid is based on very few case series and some case reports. It is thus difficult to draw definite conclusions about its epidemiology, etiology, clinical behavior, prognosis, and appropriate management.

## EPIDEMIOLOGICAL ASPECTS

The vast majority of reported cases are of white patients from series in North America and Europe,<sup>4-9</sup> but eyelid skin melanoma is also reported in Asians.<sup>10,11</sup> The incidence is similar in men and women.<sup>7-9</sup> Cutaneous melanoma of the eyelid is a tumor of adults and the elderly, with a peak incidence in the sixth and seventh decades of life.<sup>7-9</sup>

## ETIOLOGY AND PATHOGENESIS

**Sunlight exposure (ultraviolet radiation)** most likely contributes to the etiology of eyelid melanoma. A higher incidence in fair-skinned elderly adults, the histological findings of solar elastosis in most cases of cutaneous melanoma, the higher incidence of the tumor in the lower eyelid, and the relatively frequent association with basal cell carcinoma support this pathogenesis.<sup>7,9</sup>

**Precursor lesions** Eyelid cutaneous melanoma arises most frequently from a pre-existing long-standing pigmented lesion that shows a gradual increase in size.<sup>9</sup>

**Lentigo maligna** It is likely that most eyelid melanomas evolve through the precursor lesion lentigo maligna. Lentigo maligna is a slowly developing non-palpable pigmented macule, usually on exposed cutaneous surfaces in elderly patients. It enlarges slowly, although some areas may undergo regression. The lesions change shape and size, and may change color from tan to brown to black. When there is transformation to lentigo maligna melanoma, the invasive areas are usually marked by small nodular formations and are usually dark

brown or black, although invasion may occur without any obvious clinical changes.

**Dysplastic nevus** Theoretically, eyelid melanomas may also evolve from a dysplastic nevus that affects the eyelid.

**Oculodermal melanocytosis** Ten cases of cutaneous melanoma were reported in the eyelids and periorbital region in patients with oculodermal melanocytosis (nevus of Ota).<sup>12</sup>

## CLINICAL FEATURES

Eyelid cutaneous melanoma arises most frequently in the lower eyelid (Figs 18.1 and 18.2).<sup>9</sup> In one series<sup>7</sup> the three most frequently listed clinical characteristics of the melanoma were pigmentation, documented growth, and ulceration or hemorrhage. Other suspicious signs are irregular borders and variegated shades of brown, red, white, blue, or dark black. Cutaneous eyelid melanoma can be amelanotic.

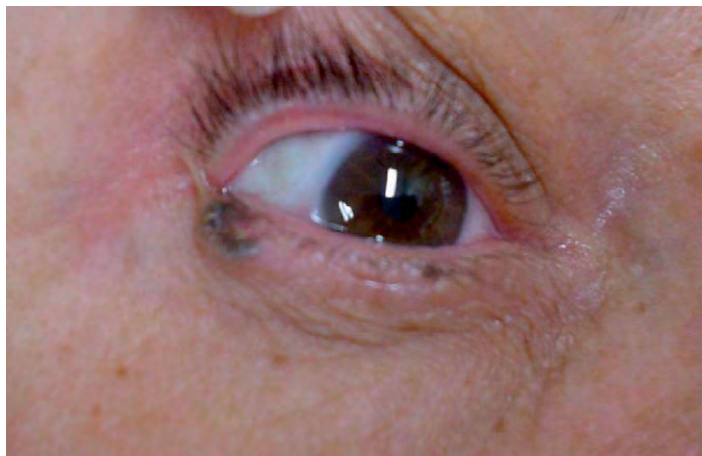
Eyelid melanoma can often involve the eyelid margins (Fig. 18.3). In such cases the mucocutaneous junction may be breached and the palpebral conjunctiva may be involved. In such cases it is often difficult to know whether the melanoma originated in the skin or in the conjunctiva. Such cases have a worse prognosis, because conjunctival involvement may grow unseen for many years.<sup>8</sup>

## DIFFERENTIAL DIAGNOSIS

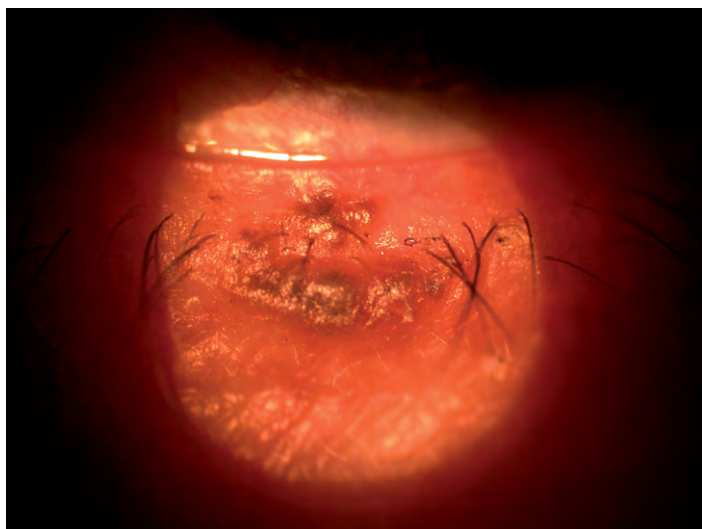
**Eyelid nevus** Most nevi of the eyelid margin are nodular, a reflection of the space-occupying characteristics of the intradermal collection of nevus cells. Spitz nevus may be confused clinically and histologically for an eyelid melanoma.

**Seborrheic keratosis** Lesions that feature a roughened or exaggerated skin texture are more likely to be epithelial in origin, even if pigmented. Thus, melanocytes may generate pigmentation within seborrheic keratosis, but such lesions can be differentiated from melanoma as (a) the precursor lesions of most melanomas in the periocular skin are flat (pigmented seborrheic keratosis is elevated), and (b) seborrheic keratosis has an irregular surface texture, whereas invasive melanoma typically produces a smooth nodular surface in the context of an otherwise flat precursor lesion.

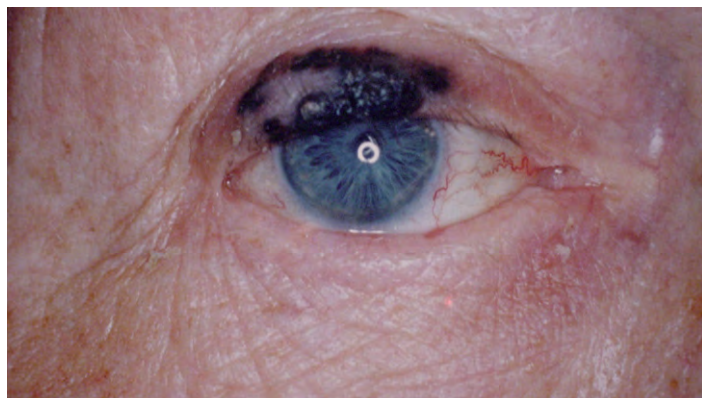
**Basal cell carcinoma** may be pigmented by virtue of the generation of excess melanin pigment in an otherwise 'mundane' basal cell carcinoma of the nodular type. Such lesions are rare and may be



**Fig. 18.1** A partially pigmented cutaneous melanoma in the lateral aspect of the lower eyelid of the right eye, near the lateral canthus, that shows recent changes in its shape. (Photograph courtesy of Peter A. Martin, MD.)



**Fig. 18.2** High magnification of superficial cutaneous melanoma involving the lower eyelid margin but not the palpebral conjunctiva. (Photograph courtesy of Peter A. Martin, MD.)



**Fig. 18.3** Large cutaneous melanoma of the upper eyelid of the right eye involving the eyelid margin. (Photograph courtesy of Peter A. Martin, MD.)

mistaken for malignant melanomas of the nodular type. As nodular eyelid melanomas are exceptionally rare, a small heavily pigmented nodule at the eyelid margin is more likely to represent pigmented basal cell carcinoma.

## HISTOPATHOLOGIC FEATURES

**Lentigo maligna** Histologically, lentigo maligna is remarkable for epidermal atrophy in the context of effacement of the rete and solar elastosis. Upon this background, atypical melanocytes populate the basal layers of the epidermis and may be identified along adnexal structures such as the pilar units of the eyelash. It must be realized that in the dermatopathology literature such lesions may be classified as ‘melanoma in situ,’ meaning that atypical melanocytes are within the epidermis, confined above the epidermal basement membrane. The term ‘melanoma in situ’ is roughly equivalent to ‘primary acquired melanosis (PAM) with atypia’ in the conjunctiva; however, the latter term is not used in dermatopathology and the term ‘melanoma in situ’ is seldom used in describing the pathology of the conjunctiva.

**Malignant melanoma** Any breach of the epidermal basement membrane by atypical melanocytes renders the lesion a malignant melanoma. Should the invasive component arise in the context of an intradermal melanocytic lesion featuring melanocytes in a pagetoid distribution, one might then state that the melanoma is of a superficial spreading type. The type of melanoma (lentigo maligna melanoma or superficial spreading melanoma) does not influence the clinical behavior of the lesion.

**Prognostic factors** Clark’s microstaging of melanoma<sup>13</sup> does not apply to the eyelid skin because in this location the dermis is not stratified into papillary and reticular zones, and there is no subcutaneous fat in the eyelid (if one encounters adipose tissue in the examination of an eyelid biopsy, then the pathologist should conclude that the surgeon violated the orbital septum). The major prognostic parameter for melanomas of the eyelid skin is the depth of invasion, as measured by a calibrated ocular micrometer from the top of the granular layer of the epidermis to the point of deepest invasion into the dermis.<sup>14</sup> Other prognostic factors of importance in cutaneous melanoma at other body sites include the presence of ulceration (a poor prognostic sign), which is seldom seen in primary eyelid melanoma. Cell type, so significant among the histological characteristics of uveal melanoma, does not appear to play an independent role in the histological prognosis of eyelid melanoma.

## TREATMENT

**Surgical excision** There is a general consensus that complete surgical excision with clear surgical margins is the treatment of choice for cutaneous malignant melanoma in general, and for eyelid melanoma in particular. However, the ideal width of the surgical margins that are necessary in order to prevent recurrences is a matter of controversy. Harris et al.<sup>15</sup> recommended simple excision for in-situ melanoma, 1 cm margins for tumors of 1 mm thickness or less, 2 cm margins for tumors of 1–4 mm depth, and 2 cm or more for those more than 4 mm deep. However, because of difficulties in eyelid reconstruction, most studies exclude eyelid melanomas from these recommendations. In order to attain adequate functional and cosmetic lid reconstruction, early diagnosis and treatment are essential in managing eyelid melanomas.

**Mohs' surgery** Malhotra et al. have recommended a modified Mohs' surgery (mapped serial excision) using paraffin sections as the treatment of choice in cases of lentigo maligna and lentigo maligna melanoma.<sup>16</sup> They found that this technique offers a high early cure rate in conjunction with tissue conservation. They also found that the recommendation of 1 cm margins for melanoma less than 1 mm thick is insufficient for complete excision. Cook and Bartley<sup>1</sup> recommended a modified Mohs' technique using frozen tissue as the treatment of choice, but the use of frozen tissue sections for melanoma is controversial because of freeze artifacts that make accurate interpretation difficult. A recent survey of 44 cases did not find that margins of excision have a statistically significant effect on local, regional, or distant recurrence.<sup>17</sup>

**Reconstruction** Resection of periorbital and eyelid melanomas is challenging because of the important anatomic structures in this region.<sup>18</sup> The surgeon should not compromise the adequate margins of resection in order to facilitate periorbital reconstruction. The type of reconstruction performed depends on the size of the surgical defect and its location (see Chapter 21).<sup>18</sup> The needs of most patients can be met by one procedure, but in difficult cases two or more may be required.

**Other methods of treatment** The primary use of destructive treatment in cutaneous melanoma is not recommended.<sup>16</sup> Methods of treatment such as cryotherapy, radiotherapy, topical treatment with azelaic acid, and curettage electrodissection are associated with high recurrence rates. In addition, these techniques do not provide tissue for histologic assessment of tumor thickness, the single most significant prognostic parameter in the management of melanoma. Cryotherapy and external beam radiation can be used as adjuvant therapy, although according to one study<sup>9</sup> adjuvant radiotherapy did not add at all to cure, thus the use of radiotherapy is at best palliative. One group reported a successful treatment with brachytherapy, using iodine-125 applicator in malignant melanoma of the eyelid.<sup>19</sup>

**Sentinel lymph node biopsy** The issue of elective lymph node dissection in patients with periocular melanoma is controversial.<sup>18</sup> The procedure is probably not indicated for lesions less than 1.0 mm thick, and may offer little advantage for lesions thicker than 4.0 mm. It is currently recommended to perform elective lymph node dissection for

melanomas of 'intermediate' thickness (1–4 mm) that may have occult nodal metastases. In recent years, sentinel lymph node mapping using lymphoscintigraphy has been advocated in order to locate suspicious involved lymph nodes and prevent unnecessary lymph node dissection. The technique has evolved into intraoperative lymphatic mapping and facilitates selective sentinel lymphadenectomy.<sup>20</sup> When positive, fine needle aspiration biopsy or excision of the node should be performed for histologic confirmation of the metastatic disease. In those patients with histologic confirmation of nodal metastases but no evidence of distant metastases, parotidectomy or modified neck dissection is performed.<sup>18</sup>

**Metastatic melanoma** In advanced metastatic cutaneous melanoma, chemotherapy has recently been used with limited success, mostly increasing survival but not curing the disease. Immunotherapy has been introduced in recent years to treat metastatic cutaneous melanoma, but is still considered experimental. Inhibition of the growth of experimental eyelid melanoma in a mouse model, using gene transfer of soluble receptor of VEGF, was successful.<sup>21</sup>

## PROGNOSIS

**Local recurrence** of eyelid cutaneous melanoma is common with incompletely excised tumors. However, local recurrence and regional lymph node metastases are not rare even when the melanoma is completely excised.<sup>9</sup>

**Prognostic factors** such as age, gender, and histologic type are not of prognostic significance.<sup>20</sup> Location of the tumor in the upper or lower lid and in the canthi also does not affect prognosis. However, involvement of the eyelid margin and the mucocutaneous junction is associated with a higher mortality.<sup>5</sup>

**Mortality** rate from eyelid cutaneous melanoma varies significantly in different series, ranging from 6%–58%.<sup>5,7</sup> Higher mortality in a series from a major tertiary cancer center most probably reflects advanced cases that may have been selectively treated there.<sup>9</sup> The time from diagnosis to death ranges from 8 months to 14 years.<sup>19</sup> The late recurrence in a significant number of patients reinforces the need for long-term follow-up of patients treated for cutaneous eyelid melanoma.

## REFERENCES

- Cook BE Jr, Bartley GB. Treatment options and future prospects for the management of eyelid malignancies: an evidence-based update. *Ophthalmology* 2001; 108: 2088–2100.
- Rodriguez-Sains RS, Jakobiec FA, Iwamoto T. Lentigo maligna of the lateral canthal skin. *Ophthalmology* 1981; 88: 1186–1192.
- Batsakis J. Tumors of the head and neck. Baltimore: Williams & Wilkins, 1974.
- Naidoff MA, Bernardino VB, Clark WH. Melanocytic lesions of the eyelid skin. *Am J Ophthalmol* 1976; 82: 371–382.
- Garner A, Koornneef L, Levene A et al. Malignant melanoma of the eyelid skin: histopathology and behaviour. *Br J Ophthalmol* 1985; 69: 180–186.
- Zoltie N, O'Neill TJ. Malignant melanomas of eyelid skin. *Plast Reconstr Surg* 1989; 83: 994–996.
- Grossniklaus HE, McLean IW. Cutaneous melanoma of the eyelid. *Clinicopathologic features*. *Ophthalmology* 1991; 98: 1867–1873.
- Tahery DP, Goldberg R, Moy RL. Malignant melanoma of the eyelid. A report of eight cases and a review of the literature. *J Am Acad Dermatol* 1992; 27: 17–21.
- Vaziri M, Buffam FV, Martinka M et al. Clinicopathologic features and behavior of cutaneous eyelid melanoma. *Ophthalmology* 2002; 109: 901–908.
- Wang JK, Liao SL, Jou JR et al. Malignant eyelid tumours in Taiwan. *Eye* 2003; 17: 216–220.
- Takamura H, Yamashita H. Clinicopathological analysis of malignant eyelid tumor cases at Yamagata University Hospital: Statistical comparison of tumor incidence in Japan and in other countries. *Jpn J Ophthalmol* 2005; 49: 349–354.
- Patel BC, Egan CA, Lucius RW et al. Cutaneous malignant melanoma and oculodermal melanocytosis (nevus of Ota): Report of a case and review of the literature. *J Am Acad Dermatol* 1998; 38: 862–865.
- Clark WH Jr, From L, Bernardino EA et al. The histogenesis and biologic behavior of primary human malignant melanomas of the skin. *Cancer Res* 1969; 29: 705–727.
- Breslow A. Thickness, cross-sectional areas and depth of invasion in the prognosis of cutaneous melanoma. *Ann Surg* 1970; 172: 902–908.
- Harris MN, Shapiro RL, Roses DF. Malignant melanoma. Primary surgical management (excision and node dissection) based on pathology and staging. *Cancer* 1995; 75: 715–725.
- Malhotra R, Chen C, Huilgol S et al. Mapped serial excision for periocular lentigo maligna and lentigo maligna melanoma. *Ophthalmology* 2003; 110: 2011–2018.

17. Esmaeli B, Youssef A, Naderi A et al. for the Collaborative Eyelid Skin Melanoma Group. Margins of excision for cutaneous melanoma of the eyelid skin: The Collaborative Eyelid Skin Melanoma Group report. *Ophthalm Plast Reconstr Surg* 2003; 19: 96–101.
18. Glat P, Longaker M, Jelks EB et al. Periorbital melanocytic lesions: excision and reconstruction in 40 patients. *Plast Reconstr Surg* 1998; 102: 19–27.
19. Stanowsky A, Krey HF, Kopp J et al. Irradiation of malignant eyelid melanoma with iodine-125 plaque. *Am J Ophthalmol* 1990; 110: 44–48.
20. Esmaeli B, Wang B, Deavers M et al. Prognostic factors for survival in malignant melanoma of the eyelid skin. *Ophthalm Plast Reconstr Surg* 2000; 16: 250–257.
21. Shiose S, Sakamoto T, Yoshikawa H et al. Gene transfer of a soluble receptor of VEGF inhibits the growth of experimental eyelid malignant melanoma. *Invest Ophthalmol Vis Sci* 2000; 41: 2395–2403.



# Eyelid adnexal tumors

Karin U. Loeffler

## INTRODUCTION

Eyelid adnexal tumors are frequent and comprise a large variety of different entities, because the lid is an organ rich in adnexal structures such as hairs (lashes) and glands. Overall, benign adnexal lesions of the eyelids are much more frequent than the malignant lesions.<sup>1,2</sup> In a series of 864 eyelid lesions that were biopsied, 82% were benign.<sup>1</sup> As with all malignant tumors, clinical symptoms include progressive growth, recurrence after incomplete excision, infiltrative growth, and destruction of adjacent tissue (loss of eyelashes). Ulceration and hemorrhage can be present in the advanced stages. Pain is an uncommon presenting feature. It is reassuring to note that the accuracy of clinical suspicion of a malignant eyelid tumor is reported to be in the range of 90%.<sup>1,2</sup>

## CLASSIFICATION

Eyelid adnexal tumors may be classified as cystic lesions, benign, and malignant tumors arising from sweat glands, hair follicles, and sebaceous glands (Table 19.1). Sometimes the precise clinical as well as the histopathologic diagnosis can be difficult because the distinction into various tumor subtypes is somewhat arbitrary and theoretical, with tumors demonstrating overlapping features. Therefore, only the most frequent and relevant adnexal tumors are reviewed in this chapter. Management is similar for the majority of these tumors: benign lesions are excised for histologic confirmation and malignant tumors are removed surgically with a tumor-free margin.

## CYSTIC LESIONS

**Epidermal inclusion cyst** usually occur as smooth dome-shaped nodules of varying size, frequently revealing a punctum or pore. Occasionally they appear pigmented. The characteristic feature is a cystic space filled with keratin, lined by regular keratinizing stratified squamous epithelium. If keratin is extruded after cyst rupture, a marked inflammatory reaction can develop. Milia are a miniature variant of epidermal cysts. Histologically, comedonal cyst is similar to an epidermoid cyst, in that the lining consists of keratinizing stratified squamous epithelium. Clinically, a comedonal cyst is characterized as a 'black-head' (comedo with an opening on to the surface) or 'whitehead' (comedo with blocked opening).

**'Sebaceous' cyst** This is a clinical misnomer, as despite the yellowish color of many cysts, histologic findings do not qualify any of them as sebaceous. Clinically, the term is used most often for epidermoid or trichilemmal cysts.

**Retention cyst** All glands can lead to retention cysts, particularly in cases of duct obstruction. The most frequent of these is the so-called sudoriferous cyst, originating from sweat glands. The typical cyst lining consists of a layer of non-keratinizing glandular epithelium surrounded by a thin layer of myoepithelial cells.

**Trichilemmal (pillar) cyst** is found on the scalp in 90% of cases; they are solitary in 30% and multiple in 70%. They appear as intradermal yellowish smooth intradermal swellings without a punctum. The cyst lining is composed of basophilic cells surrounded by a rim of fibrous tissue. Towards the lumen the cells develop into squamous epithelium with pale and fairly high keratocytes that abruptly turn into keratin without a granular layer. Sometimes calcification occurs, and often cholesterol clefts are seen.

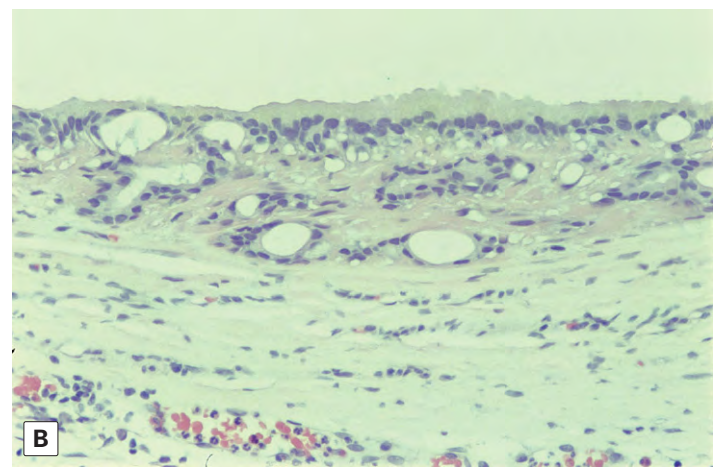
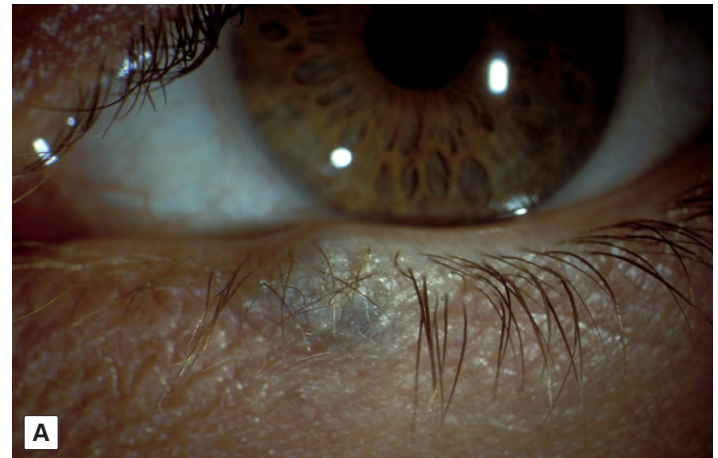## SWEAT GLAND TUMORS

There are two types of sweat gland, eccrine and apocrine. Eccrine sweat glands are widely distributed in the body and each consists of a single duct with a coiled deeper component.<sup>3</sup> By contrast, the apocrine sweat glands are limited to particular regions, such as the axilla, nipple, external ear, external genitalia, and the eyelids.<sup>3</sup> The apocrine glands and their ductal openings are closely associated with eyelashes.<sup>4</sup> In a series of 130 sweat gland lesions of the eyelids seen at the Armed Forces Institute of Pathology, Washington DC, hidrocystoma represented 22% of all cases.<sup>5</sup>

**Benign tumors** Apocrine hidrocystoma (cyst of Moll) and eccrine hidrocystoma represent the majority of benign sweat gland tumors. In contrast to apocrine hidrocystoma, the eccrine hidrocystoma does not involve the eyelid margin. This is because the eccrine sweat glands are distributed throughout the eyelid skin and are not confined to the margin, unlike the apocrine glands.<sup>4</sup> In a clinicopathologic series of 55 tumors of the sweat gland 54 (98%) were benign, with syringomas representing more than half of all cases.<sup>6</sup>

**Apocrine hidrocystoma** (cystadenoma, apocrine tubular adenoma, cyst of Moll) is usually a solitary nodule affecting mostly the head (cheek) or neck in middle-aged people of either sex. It presents as a translucent or bluish-black nodule up to about 1 cm in diameter involving the eyelid margin (Fig. 19.1A).<sup>7</sup> In rare instances it can occur as multiple lesions<sup>8</sup> and can be a feature of Schopf-Schulz-Passarge syndrome.<sup>9</sup> Histopathology reveals a unilocular or multilocular cystic space lined by a double layer of epithelial cells; the outer layer

Table 19.1 Classification of cystic and adnexal tumors			
Types	Subtypes		
Cystic lesions	Benign	Epidermal inclusion cyst	
		Sebacous cyst	
Sweat gland tumors	Benign	Retention cyst	
		Trichilemmal cyst	
		Apocrine hidrocystoma	
		Eccrine hidrocystoma	
		Syringoma	
		Eccrine spiradenoma	
		Pleomorphic adenoma (benign mixed tumor)	
		Eccrine acrospiroma	
		Eccrine cylindroma	
		Apocrine adenoma	
		Other benign tumors	
		Malignant	Sweat gland adenocarcinoma
		Mucinous sweat gland adenocarcinoma	
	Apocrine gland adenocarcinoma		
Porocarcinoma			
Hair follicle tumors	Benign	Trichoepithelioma	
		Trichofolliculoma/trichoadenoma	
		Trichilemmoma	
		Pilomatrixoma (calcifying epithelioma of Malherbe)	
	Malignant	Carcinoma of hair follicles	
Sebaceous gland tumors	Benign	Sebaceous gland hyperplasia	
		Sebaceous gland adenoma	
	Malignant	Sebaceous gland carcinoma	



**Fig. 19.1** Apocrine hidrocystoma. Note bluish color of the cystic lesion involving the eyelid margin (A) Apical decapitation of the lining epithelium is evident (B).

represents myoepithelial cells, whereas the inner layer frequently shows the typical decapitation secretion (Fig. 19.1B).

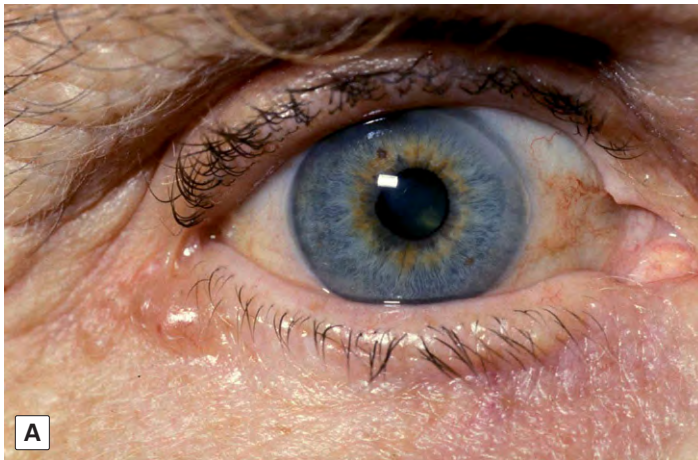**Eccrine hidrocystoma** A typical eccrine hidrocystoma of the eyelid in an adult manifests as a solitary clear cystic lesion (Smith and Chernosky type),<sup>10</sup> although cases with simultaneous bilateral involvement (Robinson type)<sup>11</sup> have also been reported (Fig. 19.2A). The tumor is usually located along the medial or lateral aspect of the eyelid and characteristically occurs close to but does not involve the eyelid margin. On average, eccrine hidrocystoma measures 4 mm in its largest dimension and it is rare for them to be larger than 10 mm.<sup>12</sup> Histologically, this tumor is probably just a markedly dilated sweat gland duct with a presumably functional pathogenesis (Fig. 19.2B). Myoepithelial cells and decapitation secretion are absent (Fig. 19.2C).

**Syringoma** is common on the upper eyelids, especially in females. They usually present as multiple small asymptomatic nodules 2–3 mm in diameter but show a wide variety of clinical pictures (Fig. 19.3). Histology shows interconnecting eccrine ducts and strands, lined by two layers of flattened cuboidal cells and sometimes giving rise to the characteristic tadpole configuration. Intracellular glycogen accumulation can cause a clear cell variant.

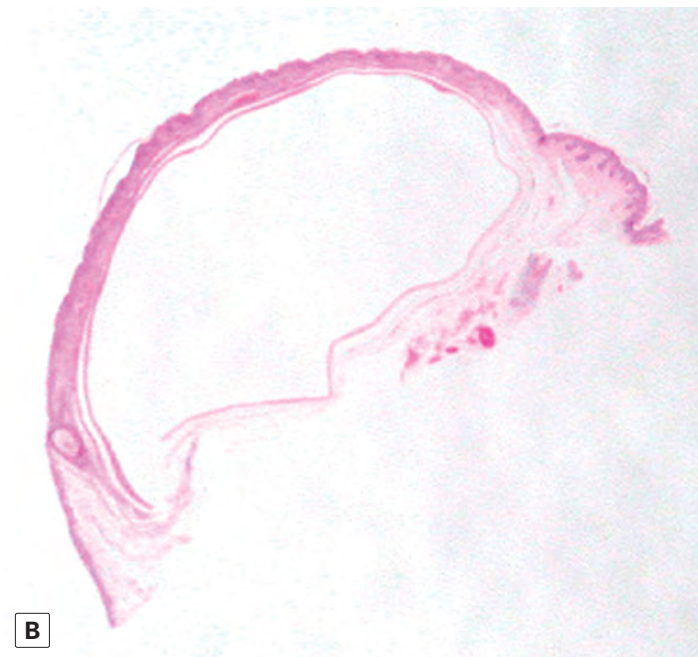**Eccrine spiradenoma** is an uncommon tumor presenting as a mostly tender or painful subcutaneous nodule of fairly characteristic histology. Sharply demarcated aggregations of basaloid cells without connection to the dermis are arranged in a rosette-like fashion. Two types of tumor cell can be distinguished: the more peripheral small basophilic cells with round and hyperchromatic nuclei, and the more central cells with larger oval nuclei and a pale-staining eosinophilic cytoplasm. Owing to a rich vascular supply this tumor can resemble an angioma, hemangiopericytoma, or glomus tumor.

**Pleomorphic adenoma (benign mixed tumor, chondroid syringoma)** presents as a slowly growing, either firm or cystic subcutaneous nodule, usually solitary and asymptomatic. It is more frequent in males, and recurrences are rare. Histologically, it is multilobulated and composed of a mixture of epithelial (sweat ductal) and stromal (mucinous) components. The stromal component can become very prominent, frequently exhibiting a chondroid (pseudocartilaginous) and/or hyalinized appearance.<sup>13</sup>

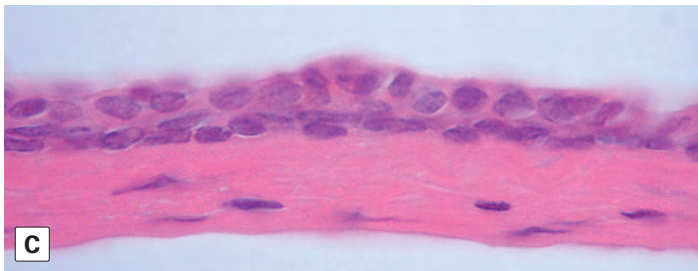
**Syringocystadenoma papilliferum** is usually a solitary lesion that presents as a grey to dark-brown papillary or warty excrescence. Although it can grow in an endophytic or exophytic fashion, histopathology characteristically shows superficially located papillae communicating with duct-like structures in the deeper aspect. The lining



A



B



C

**Fig. 19.2** Eccrine hidrocystoma. Note the gap between the tumor and the eyelid margin (A). There is absence of papillary projections into the cystic cavity (B). The lining cuboidal epithelium is double layered and the cells lack decapitation (C). Reproduced with permission from: Singh AD, McCloskey L, Andrew Parsons M, McDonagh AJG, Slater DN. Eccrine hidrocystoma of the eyelid. *Eye*, 2005;19:77–79.

consists of the typical double-layered epithelium with flattened myoepithelial cells at the outer zone and tall columnar cells at the inner zone.

### Malignant tumors

*Sweat gland adenocarcinoma (malignant syringoma)* most frequently affects the nasolabial and periorbital regions and presents

Rights were not granted to include this figure in electronic media.  
Please refer to the printed publication.

**Fig. 19.3** Multiple bilateral syringomas of upper and lower eyelids in a young woman. Reproduced with permission from: Fitzpatrick's color atlas and synopsis of clinical dermatology. 5<sup>th</sup> Edition. The McGraw-Hill Companies; 2001. Figure 9-45.

non-specifically as a slowly growing plaque-like lesion, sometimes associated with hyperkeratosis.<sup>14</sup> Typically, the margins are not well delineated, and sometimes pain can be present owing to perineural infiltration. Histology shows various features, including small to medium-sized squamous microcysts (also called microcystic adnexal carcinoma), solid strands of cells with ductular lumina, and small solid infiltrative strands, all embedded in a dense fibrous stroma.

*Mucinous sweat gland adenocarcinoma* is a rare neoplasm, shows predilection for the eyelid, and presents as a slowly growing flesh-colored, erythematous, or bluish nodule.<sup>15</sup> It is locally aggressive and frequently recurs, but distant metastases are uncommon. Histology shows islands of tumor cells embedded in an abundant pool of mucin, separated by fibrous septae. The tumor cells are cuboidal, with a pink-staining, sometimes vacuolated cytoplasm and round nuclei. Often a glandular differentiation is present, and sometimes light- and dark-cell forms can be distinguished. Histochemistry supports an eccrine derivation.

*Apocrine gland adenocarcinoma (carcinoma of the glands of Moll)* is rare and most documented cases have affected the axilla. Fewer than 10 cases have been described to arise from the glands of Moll in the eyelid.<sup>16</sup> The clinical appearance is of a reddish cystic-nodular lesion located at the lid margin with a smooth surface. The tumor cells reveal a variably glandular, papillary, or diffuse growth, sometimes with cyst formation and necrosis, and decapitation secretion is a typical feature. Occasionally, intracytoplasmic diastase-resistant, periodic acid–Schiff–positive granules and intracytoplasmic iron can be demonstrated, but glycogen is negative. Normal apocrine glands are often found in close proximity to the tumor, and occasionally a pre-existing apocrine adenoma may be evident. As primary cutaneous apocrine carcinoma is indistinguishable from metastatic mammary ductal apocrine carcinoma, a careful breast assessment should be advised, especially in cases where the diagnosis is questionable.



## TUMORS OF THE HAIR FOLLICLE

### Benign tumors

*Trichoepithelioma* is a hamartomatous lesion that may be solitary, multiple, or even familial.<sup>17</sup> It shows less follicular differentiation than does trichofolliculoma. There can be continuity with the epidermis, but ulceration is exceedingly rare. The typical histologic appearance shows numerous horn cysts, partially within nests of basaloid cells that are sometimes difficult to distinguish from basal cell carcinoma. In trichoepithelioma, however, the perilobular connective tissue is more conspicuous and is frequently associated with the formation of papillary mesenchymal bodies (Brook, Fitzpatrick, Golitz). Occasionally, a foreign body giant cell reaction to free keratin and calcification is seen.

*Trichofolliculoma* is a hamartoma presenting as a single dome-shaped papule with a central pore. Characteristic is the presence of one or more silky white thread-like hairs growing out of this opening.<sup>18</sup> A wide age range is affected, although lesions are very rare in children. Histologically, this tumor consists of a cystic cavity (dilated hair follicle) lined by stratified squamous epithelium, usually continuous with the surface epithelium. Arising from its wall are numerous hair follicles. Abortive pilar differentiation, small primitive sebaceous acini, keratocysts, stromal granulomatous inflammation surrounding hair shaft fragments, and focal calcification are additional features. A variant of trichofolliculoma with numerous additional sebaceous glands is called sebaceous trichofolliculoma. A trichoepithelioma with prominent desmoplastic stroma is categorized as desmoplastic trichoepithelioma.

*Trichoadenoma* is a rare tumor that occurs as a solitary, asymptomatic soft or firm nodule of varying size and yellowish or erythematous in color.<sup>19</sup> Under a normal epidermis there is a well-defined fibroepithelial tumor composed of keratinous cysts and a conspicuous fibrovascular stroma. The cysts are lined by keratinizing epithelium, including a granular layer. Sometimes solid epithelial islands are also present, but evidence of hair follicle formation is lacking.

*Trichilemmoma* may be solitary or multiple and presents as a small warty or smooth skin-colored papule on the face of older adults (Fig. 19.4).<sup>20</sup> Solitary trichilemmoma represents a proliferation of the follicular outer root sheath, with close-set lobules connecting with the epidermis. There is usually peripheral nuclear palisading, but pleomorphism and mitoses tend to be absent. Intracellular glycogen can result in a conspicuous clear cell component. Another typical feature is a dense PAS-positive mantle surrounding individual tumor lobules.

A variant with marked keratinization, squamous eddies, and surface hyperkeratosis and parakeratosis is called keratinizing trichilemmoma. Associated with the presence of multiple trichilemmomas is the rare autosomal dominant condition called Cowden's (multiple hamartoma) disease.<sup>21</sup>

*Pilomatrixoma (calcifying epithelioma of Malherbe)* usually presents as a solitary lesion, but can rarely be part of an autosomal dominantly inherited disorder or a systemic disease such as dystrophia myotonia or Gardner's syndrome.<sup>22</sup> It is a slowly growing hard nodule and is frequently located subcutaneously beneath the eyebrow. Most often teenagers and older adults in the sixth and seventh decades are

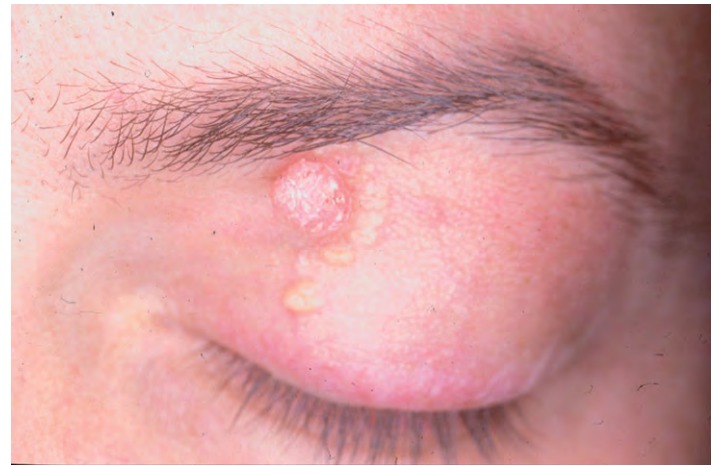

Fig. 19.4 Trichilemmoma of the upper eyelid.

affected.<sup>23</sup> Histology reveals a well-circumscribed tumor consisting of two different cell populations: small basophilic basaloid cells, and the characteristic and diagnostic pale-pinkish ghost cells. Frequently, calcification and a foreign body giant cell reaction are encountered, and occasionally melanin pigment is found. Even bone formation and amyloid deposition may be features. Mitoses are seen in early lesions, but are not abnormal and simply indicate a rapid growth phase.

### Malignant tumors

*Carcinoma of hair follicles (trichilemmal carcinoma)* This is a rare tumor that is found predominantly on sun-exposed skin in the elderly. The clinical presentation ranges from papule or a nodule to plaque that often ulcerates. Usually the lesion is erythematous or flesh colored, and measures between 5 and 20 mm in diameter. Despite a histologically worrying picture, recurrences and metastases are absent.

## SEBACEOUS GLAND TUMORS

### Benign tumors

*Sebaceous gland hyperplasia* usually presents as a yellowish umbilicated papule 1–2 mm in size on the face of older adults. Clinically, it can be mistaken for basal cell carcinoma. Histopathologically, regular mature but hyperplastic sebaceous glands are seen that are situated rather higher in the dermis than usual, and the epidermis is normal.

*Sebaceous gland adenoma* is rare and presents as a tan, yellow, or reddish papule/nodule about 5 mm in diameter, most frequently located on the face of older people (mean age 60 years). Clinically, they can easily be misdiagnosed as basal cell carcinoma. Sebaceous gland adenoma in a younger person can be an indication for Muir–Torre syndrome (see Chapter 22).<sup>24</sup>

*Nevus sebaceus of Jadassohn* is a complex choristoma comprising abnormalities of the hair follicles, sweat glands, sebaceous glands, and epidermis.<sup>25</sup> All of these tissues can proliferate, and can constitute the major part of the tumor. Malignant transformation of any of the components is possible, with basal cell carcinoma being the most frequent (see Chapters 64).



**Malignant tumors**

**Sebaceous epithelioma** is a variant of basal cell carcinoma with sebaceous differentiation. Compared to sebaceous gland adenoma, the cells are less mature and show numerous mitotic figures.

**Sebaceous gland carcinoma** is covered separately in Chapter 17.

**SUMMARY**

Among benign lesions of the eyelid, adnexal tumors are common and display a variety of clinical and histologic features. Most commonly they originate from sweat glands or hair follicles. Malignant neoplasms are rare. Excision and histopathologic evaluation is recommended even for less suspicious tumors.

**REFERENCES**

1. Kersten RC, Ewing-Chow D, Kulwin DR, Gallon M. Accuracy of clinical diagnosis of cutaneous eyelid lesions. *Ophthalmology* 1997; 104: 479–484.
2. Margo CE. Eyelid tumors: accuracy of clinical diagnosis. *Am J Ophthalmol* 1999; 128: 635–636.
3. Warwick R, Williams PL. Gray's anatomy, 35th edn. Edinburgh: Longman, 1973; 1168–1169.
4. Warwick R. Eugene Woll's anatomy of the eye and orbit, 7th edn. London: HK Lewis 1976; 195–197.
5. McLean IW, Burnier MN, Zimmerman LE, Jakobiec FA. Tumors of the eye and ocular adnexa. Washington DC: Armed Forces Institute of Pathology, 1993; 9–11.
6. Ni C, Dryja TP, Albert DM. Sweat gland tumor in the eyelids: A clinicopathological analysis of 55 cases. *Int Ophthalmol Clin* 1981; 23: 1–22.
7. Smith JD, Chernosky ME. Apocrine hidrocystoma (cystadenoma). *Arch Dermatol* 1974; 109: 700–702.
8. Sacks E, Jakobiec FA, McMillan R, Fraunfelder F, Iwamoto T. Multiple bilateral apocrine cystadenomas of the lower eyelids. Light and electron microscopic studies. *Ophthalmology* 1987; 94: 65–71.
9. Verplancke P, Driessen L, Wynants P, Naeyaert JM. The Schopf–Schulz–Passarge syndrome. *Dermatology* 1998; 196: 463–466.
10. Smith JD, Chernosky ME. Hidrocytomas. *Arch Dermatol* 1973; 108: 676–679.
11. Robinson AR. Hidrocytoma. *J Cutan Genitourin Dis* 1893; 11: 293–303.
12. Singh AD, McCloskey L, Andrew Parsons M, McDonagh AJG, Slater DN. Eccrine hidrocystoma of the eyelid. *Eye* 2005; 19: 77–79.
13. Jordan DR, Nerad JA, Patrinely JR. Chondroid syringoma of the eyelid. *Can J Ophthalmol* 1989; 24: 24–27.
14. Esmaeli B, Ramsay JA, Chorneyko KA, Wright CL, Harvey JT. Sclerosing sweat-duct carcinoma (malignant syringoma) of the upper eyelid: a patient report with immunohistochemical and ultrastructural analysis. *Ophthalm Plast Reconstr Surg* 1998; 14: 441–445.
15. Boynton JR, Markowitch W Jr. Mucinous eccrine carcinoma of the eyelid. *Arch Ophthalmol* 1998; 116: 1130–1131.
16. Paridaens D, Mooy CM. Apocrine sweat gland carcinoma. *Eye* 2001; 15: 253–254.
17. Aurora AL. Solitary trichoepithelioma of the eyelid. *Indian J Ophthalmol* 1974; 22: 32–33.
18. Carreras B Jr, Lopez-Marin I Jr, Mellado VG, Gutierrez MT. Trichofolliculoma of the eyelid. *Br J Ophthalmol* 1981; 65: 214–215.
19. Shields JA, Shields CL, Eagle RC Jr. Trichoadenoma of the eyelid. *Am J Ophthalmol* 1998; 126: 846–848.
20. Hidayat AA, Font RL. Trichilemmoma of eyelid and eyebrow. A clinicopathologic study of 31 cases. *Arch Ophthalmol* 1980; 98: 844–847.
21. Bardenstein DS, McLean IW, Nerney J, Boatwright RS. Cowden's disease. *Ophthalmology* 1988; 95: 1038–1041.
22. Boniuk M, Zimmerman LE. Pilomatrixoma (benign calcifying epithelioma) of the eyelids and eyebrow. *Arch Ophthalmol* 1963; 70: 399–406.
23. Yap EY, Hohberger GG, Bartley GB. Pilomatrixoma of the eyelids and eyebrows in children and adolescents. *Ophthalm Plast Reconstr Surg* 1999; 15: 185–189.
24. Singh AD, Mudhar H, Bhola R, Rundle PA, Rennie IG. Sebaceous adenoma of the eyelid in Muir–Torre syndrome. *Arch Ophthalmol* 2005; 123: 562–565.
25. Traboulsi EI, Zin A, Massicotte SJ et al. Posterior scleral choristoma in the organoid nevus syndrome (linear nevus sebaceus of Jadassohn). *Ophthalmology* 1999; 106: 2126–2130.

**FURTHER READING**

1. McKee PH. Pathology of the skin with clinical correlations, 2nd edn. London: Mosby, 1999.
2. Rapini RP. Practical dermatopathology. Philadelphia: Elsevier Mosby, 2005.

# Eyelid stromal tumors

Geeta K. Vemuganti and Santosh G. Honavar

## INTRODUCTION

Eyelid stromal tumors can be considered under several distinct categories based on the tissue of origin: fibrous tissue tumors, fibrohistiocytic tumors, lipomatous tumors, smooth muscle tumors, skeletal muscle tumors, vascular tumors, perivascular tumors, neural tumors, lymphoid, plasmacytic, and leukemic tumors, cartilage and bone tumors, secondary tumors, metastatic tumors, and hamartomas, choristomas, and other miscellaneous lesions. Some of the inflammatory and infective conditions, such as chalazion, pyogenic granuloma, verruca vulgaris, and molluscum contagiosum, may manifest with features that clinically simulate a tumor. This chapter describes the salient features and management of common eyelid stromal tumors.

## FIBROUS TISSUE TUMORS

Fibrous tissue tumors comprise several benign lesions (fibroma, keloid, nodular fasciitis, and proliferative fasciitis), fibromatosis, and a malignant tumor (fibrosarcoma).

### Fibromas

**Clinical features** Fibromas are rare tumors that can be congenital, developmental, or acquired.<sup>1</sup> Congenital fibroma presents as a diffusely infiltrative lower eyelid nodule that recurs following local excision. The histological and electron-microscopic features point to the hamartomatous origin of this tumor, with partial myofibroblastic differentiation.<sup>1</sup> Developmental fibroma has a propensity to involve the infraorbital region and lower eyelid, and is diffusely infiltrative. Recurrence often follows local excision.<sup>2</sup>

**Histopathologic features** A typical fibroma is sparsely cellular with prominent collagen bundles separated by compressed fibroblasts. A characteristic feature is the lack of inflammation without a zonal pattern. Pleomorphic fibroma is a variant with multinucleate giant cells.

**Eyelid keloids** are hypertrophic cutaneous scars or nodular outgrowths on the surface or the margin of the eyelid that follow surgical intervention or trauma, and can occur de novo. Rarely, keloids arise from the tarsus and simulate a tumor.<sup>3</sup>

**Nodular fasciitis** is a relatively common benign reactive fibroblastic proliferation of the soft tissues with acute manifestations that progress rapidly.

**Clinical features** Nodular fasciitis of the eyelid is rare and presents with a solitary subcutaneous nodule.<sup>4</sup> Although excisional biopsy is curative, the nodule may often resolve spontaneously.<sup>4</sup>

**Histopathologic features** Nodular fasciitis is an infiltrative lesion that consists of a proliferation of immature and activated fibroblasts with slit-like spaces between the cells. Foci of myxoid change, endothelial proliferation, lipid-laden macrophages, multinucleated giant cells, and acute and chronic inflammatory cell infiltration are also seen. Ultrastructurally, the cells show characteristic features of myofibroblasts. The clinical presentation and histologic appearance of a pleomorphic spindle cell neoplasm with frequent mitotic figures may raise concern regarding a malignant neoplasm and lead to unnecessary and overly aggressive therapy. The lesion is therefore called pseudosarcomatous fasciitis.

**Fibromatosis** may be juvenile or adult in onset. Juvenile fibromatoses are a distinct group of benign fibrous lesions with aggressive clinical behavior and a predilection to occur in the lower eyelid and inferior orbit.<sup>5</sup> Infiltration of the local tissues, including extraocular muscle and periosteum, results in incomplete removal and local recurrence (Fig. 20.1).

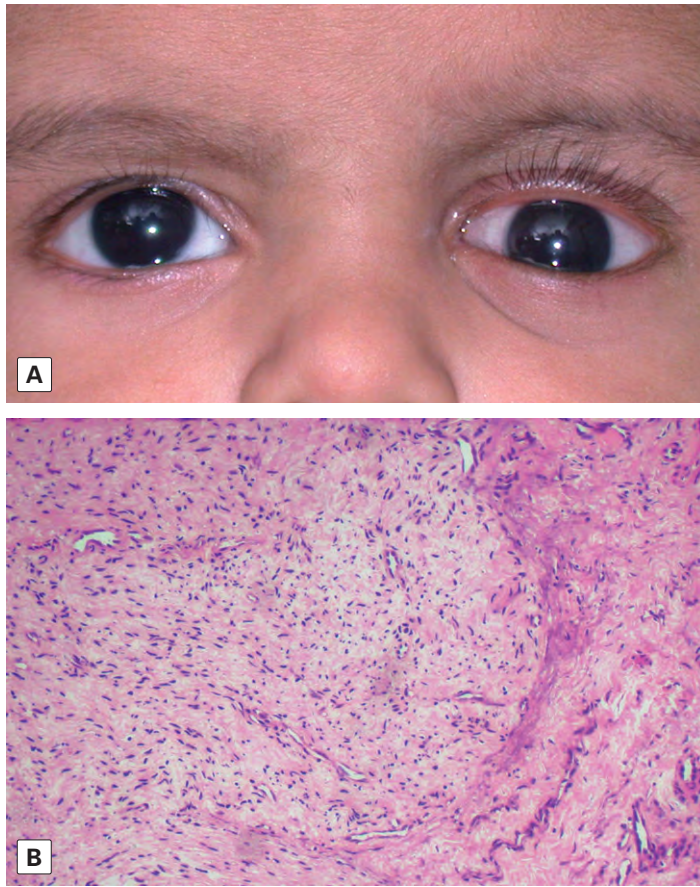
**Fibrosarcoma** is a highly malignant tumor that can be locally destructive and can metastasize.

**Clinical features** It manifests as a rapidly progressive, poorly circumscribed eyelid nodule, or as a second malignant neoplasm in hereditary retinoblastoma survivors with or without prior radiotherapy.<sup>6</sup> Wide surgical excision or orbital exenteration may minimize the risk of local recurrence.<sup>6</sup>

**Histopathologic features** The lesion consists of closely packed cells that assume an interlacing, woven herringbone pattern. The cells contain a vesicular nucleus with prominent nucleoli, tapering pointed ends, and moderate mitotic activity.

## FIBROHISTIOCYTIC TUMORS

Fibrohistiocytic tumors may be subclassified as benign (xanthelasma, xanthoma, dermatofibroma, xanthogranuloma, juvenile xanthogranuloma, reticulohistiocytoma), intermediate (atypical fibroxanthoma, dermatofibrosarcoma protuberans, angiomatoid fibrous histiocytoma), or malignant (malignant fibrous histiocytoma, malignant fibroxanthoma).



**Fig. 20.1** Eyelid fibromatosis. (A) A 6-month-old child with a tethering of the eyelid to a deeper firm mass in the superonasal aspect with consequent lagophthalmos. (B) Histopathology showed infiltrating bundles of spindle cells with a lobulated pattern in a few areas diagnostic of fibromatosis (Hematoxylin & eosin, original magnification  $\times 200$ ).

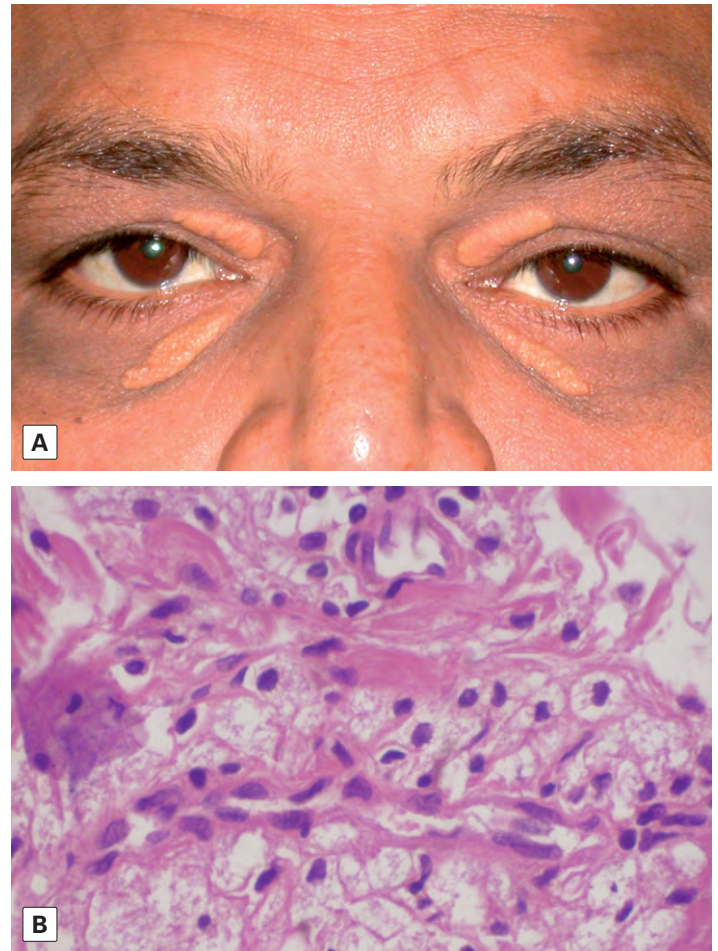
**Xanthelasma** is a common bilateral subcutaneous lesion of the eyelid seen in normolipemic individuals and in those with primary hyperlipemia (type II and III) or secondary hyperlipemia (diabetes mellitus, biliary cirrhosis).

**Clinical features** Xanthelasma manifests as a yellowish-tan soft plaque in the inner canthus in middle-aged individuals (Fig. 20.2). Large nodular xanthelasma is called xanthoma or tuberous xanthoma, which has a known association with Erdheim–Chester disease. Acute-onset eruptive xanthoma occurs in patients experiencing a rapid rise in serum triglyceride levels. Management should include systemic evaluation for the causative etiology, and excision, or laser or radio-frequency-assisted vaporization of large cosmetically unacceptable lesions.<sup>7</sup>

**Histopathologic features** Microscopically, xanthelasma consists of lipid-laden macrophages in the superficial dermis, and around the blood vessels and adnexa.

**Xanthogranuloma** is an idiopathic inflammatory granuloma with juvenile and adult variants.<sup>8</sup>

**Clinical features** Juvenile xanthogranuloma of the eyelid may be a part of a systemic affliction seen as multiple fleshy superficial eyelid



**Fig. 20.2** Xanthelasma. (A) Bilateral yellowish placoid lesions clinically diagnostic of xanthelasma. (B) Sheets of large foamy lipid laden cells on histopathology. (Hematoxylin & eosin, original magnification  $\times 400$ ).

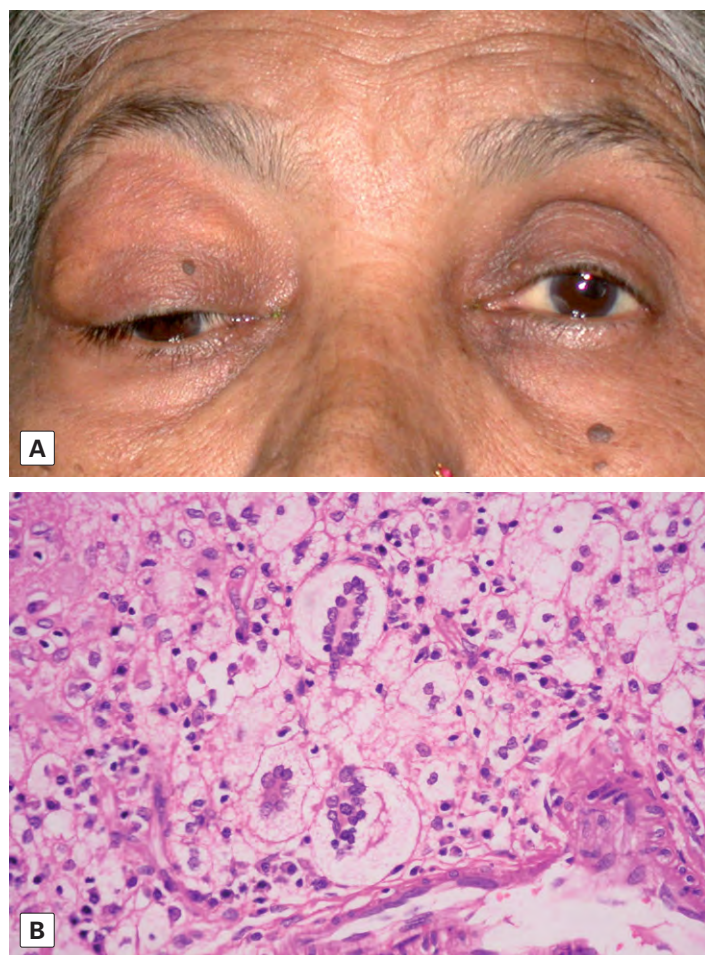
nodules with or without coexisting involvement of the conjunctiva, iris, and orbits. The adult variant may be diffuse and associated with bronchial asthma (Fig. 20.3).<sup>8</sup> Juvenile xanthogranuloma is known to involute spontaneously, thus qualifying for observation. Systemic corticosteroids are indicated in recalcitrant juvenile xanthogranuloma and as primary therapy for the adult variant.<sup>8</sup> Extensive, cosmetically disfiguring, and steroid-resistant lesions may be excised or treated with systemic chemotherapy or radiotherapy.

**Histopathologic features** Xanthogranuloma consists of monomorphic infiltrate of histiocytes intermixed with lymphocytes and the classic Touton giant cell, with a wreath-like arrangement of nuclei and a peripheral clear zone.

**Malignant fibrous histiocytoma** is a pleomorphic soft tissue sarcoma that occurs rarely in the eyelid.

**Clinical features** Malignant fibrous histiocytoma presents as a firm subcutaneous mass.<sup>9</sup> Dermatofibrosarcoma protuberans, which manifests as a rapidly growing eyelid nodule, is considered an aggressive form of malignant fibrous histiocytoma.<sup>10</sup> It has a tendency for local invasion and is known to metastasize. The mainstay of treatment is complete surgical excision with wide margins. Because of the risk of recurrence following excision, consideration should be given to histologic margin control and adjuvant radiotherapy.<sup>11</sup>





**Fig. 20.3** (A) Adult-onset xanthogranuloma presenting as a diffuse eyelid mass with a yellowish haze. (B) Sheets of foamy histiocytes and classic Touton-type multinucleated giant cells with a wreath-like arrangement of the nuclei on histopathology. (Hematoxylin & eosin, original magnification  $\times 250$ ).

**Histopathologic features** Malignant fibrous histiocytoma differs from the benign variant in exhibiting marked nuclear pleomorphism, high mitotic activity, pericytoma-like areas with foci of xanthoma cells, and multinucleated giant cells.

### LIPOMATOUS TUMORS

The lipomatous tumors that affect the eyelid are lipoma, lipoma variants, and liposarcoma.

**Lipoma and lipoma variants** Lipoma may be congenital or acquired. Nasopalpebral lipoma—coloboma syndrome is an autosomal dominant syndrome characterized by congenital upper eyelid and nasopalpebral lipomas, upper and lower eyelid colobomas, telecanthus, and maxillary hypoplasia.<sup>12</sup> Lipoblastoma is an uncommon benign tumor of adipose tissue that occurs in infants and young children.<sup>13</sup> Intramuscular lipoma of the eyelid manifesting as a slowly growing globular lesion has been described in elderly individuals. Hibernoma is a variant of lipoma that contains embryonal brown fat and is relatively more vascular. If treatment is indicated for cosmetic and functional reasons, complete excision of the tumor is adequate.

**Liposarcoma** Primary liposarcoma is a rare orbital tumor that may involve the eyelid by local extension.

### SMOOTH MUSCLE TUMORS

Smooth muscle tumors of the eyelid are very rare and may be benign (leiomyoma, angiomyoma)<sup>14</sup> or malignant (leiomyosarcoma).<sup>15</sup>

### SKELETAL MUSCLE TUMORS

Rhabdomyoma and rhabdomyosarcoma are the skeletal muscle tumors of the eyelid.

**Rhabdomyoma** is a benign tumor of the skeletal muscle and is seen in two forms. The adult form consists of well-differentiated, large, rounded or polygonal cells with abundant acidophilic cytoplasm containing lipid and glycogen. Some cells appear like spider cells and some may show cross-striations. The fetal form is very cellular and consists of immature skeletal muscle fibers and primitive mesenchymal cells. One case of adult-onset rhabdomyoma attributed to chronic irritation by a prosthetic eye has been reported in the literature.<sup>16</sup>

**Rhabdomyosarcoma** is primarily a malignant orbital tumor that involves the eyelid only in about 3% of cases<sup>17</sup> (see Chapter 97).

### VASCULAR TUMORS

Benign vascular tumors of the eyelid include nevus flammeus, papillary endothelial hyperplasia, capillary hemangioma, cavernous hemangioma, venous hemangioma, epithelioid hemangioma, arteriovenous malformation, and lymphangioma. Angiosarcoma, lymphangiosarcoma, and Kaposi's sarcoma are the malignant vascular eyelid tumors.

**Nevus flammeus (port wine stain)** is a diffuse congenital vascular malformation of the face that involves the periocular area and eyelid (see Chapters 64).

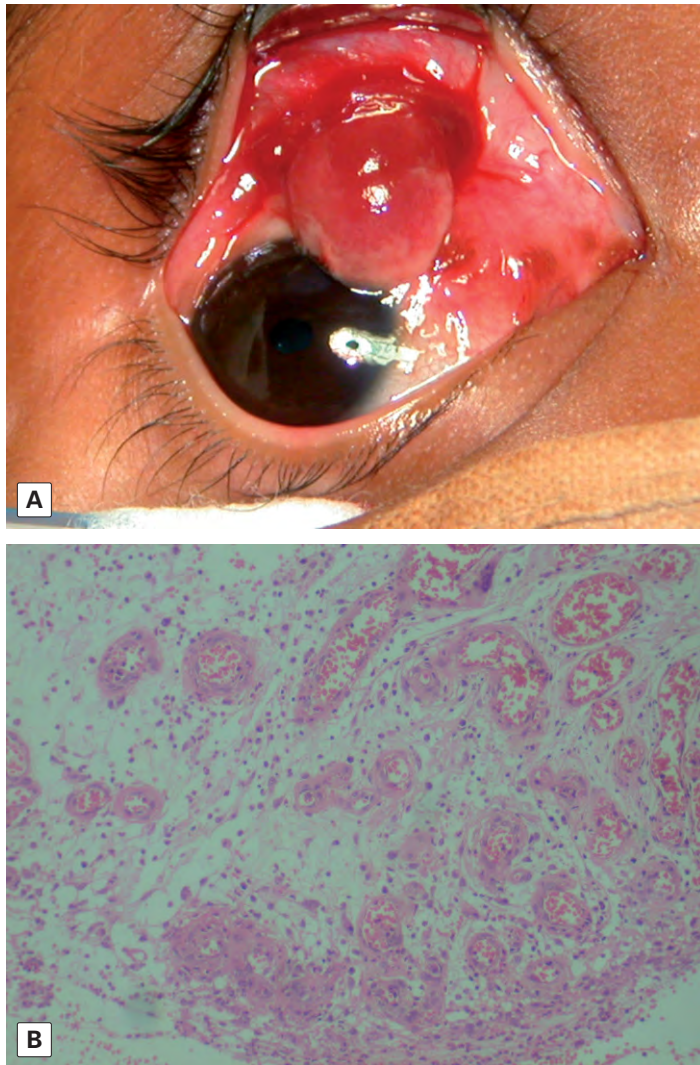
**Pyogenic granuloma** Papillary endothelial hyperplasia or 'pyogenic granuloma' is the most common acquired vascular lesion of the eyelid. It is neither pyogenic, nor is it a granuloma.

**Clinical features** Pyogenic granuloma occurs anywhere in the eyelid as a rapidly growing, pedunculated reddish-pink mass with or without superficial ulceration, and may easily bleed on touching (Fig. 20.4). It usually follows trauma or surgery. Local excision of the lesion is curative.<sup>18</sup>

**Histopathologic features** Pyogenic granuloma consists of an exuberant mass of proliferating radiating capillaries, and edematous stroma with mixed inflammatory infiltrates. Intravascular papillary endothelial hyperplasia is a rare form of pyogenic granuloma in which the angiomatous proliferation is confined entirely within the lumen of a vessel.<sup>19</sup>

**Capillary hemangioma** of the eyelid is the most common vascular tumor of the eyelid in children (Fig. 20.5). It is usually congenital and is often sporadic. Newborns of mothers who have undergone amniocentesis and premature infants are at risk of developing capillary hemangioma.<sup>20</sup> The pathogenesis of this tumor is not well understood,



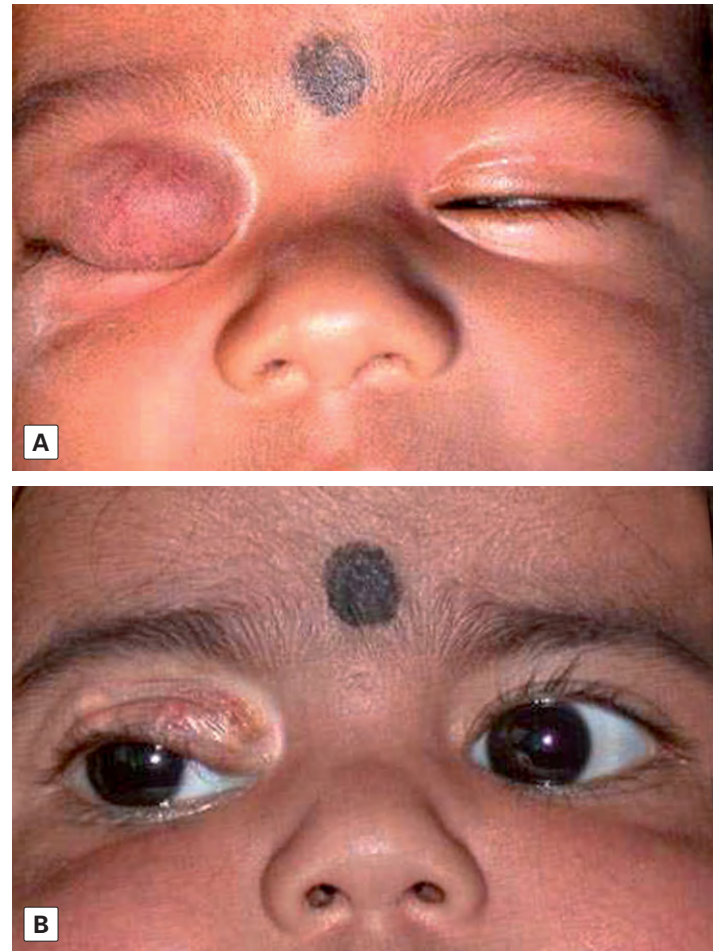


**Fig. 20.4** Pyogenic granuloma. **(A)** The tarsal conjunctiva of the upper eyelid shows a vascular polypoidal reddish pink mass with superficial ulceration. **(B)** Histopathologically a loose edematous stroma with surface necrosis, proliferating blood vessels, and mixed inflammatory infiltrates, characteristic of inflammatory granulation tissue, are present. (Hematoxylin & eosin, original magnification  $\times 200$ ).

but affected infants have an increased urinary level of basic fibroblastic growth factor, a marker of angiogenesis. Familial congenital capillary hemangioma with autosomal dominant inheritance and incrimination of chromosome 5q has been reported.<sup>21</sup>

**Clinical features** Congenital capillary hemangioma usually manifests at birth or within the first months of life. There are two distinct clinical variants, superficial and deep. The superficial variant, better known as strawberry hemangioma, appears as a bright red to deep purple lobulated, spongy, soft eyelid mass that typically blanches on the application of direct pressure and engorges when the infant cries or strains. Contiguous conjunctival and orbital extension is known to occur. The superficial variant is localized to the epidermis and dermis, whereas the deep variant lies in the subcutaneous tissue and is bluish or blue-gray in color.

**Natural history** Congenital capillary hemangioma grows rapidly in size and reaches its final size by 6–12 months of age. It then becomes



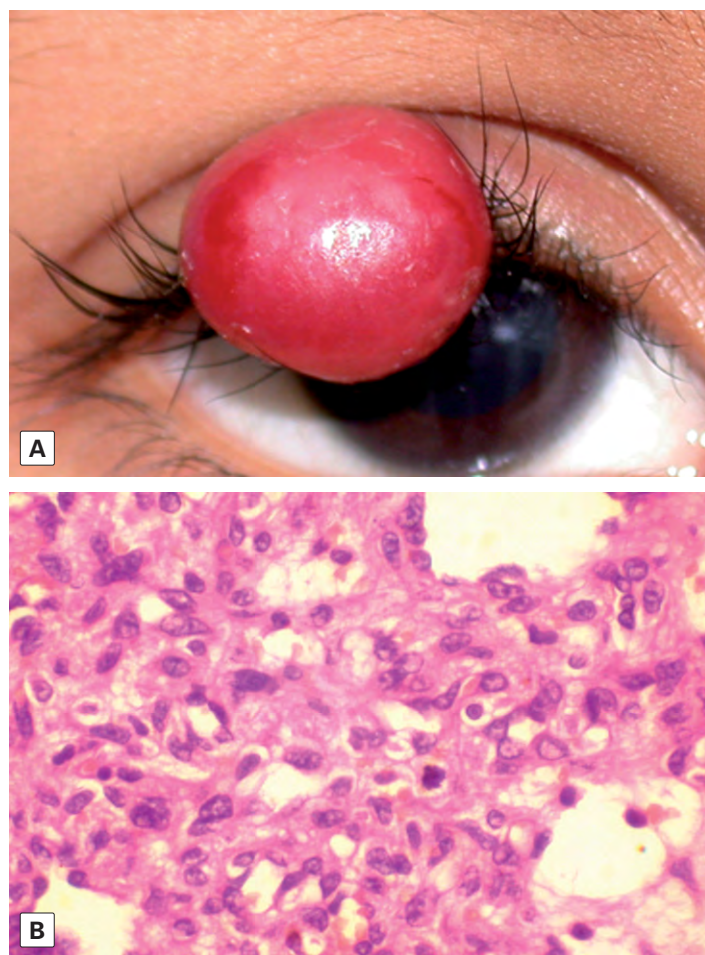
**Fig. 20.5** **(A)** Capillary hemangioma of the upper eyelid manifesting as a bright red, spongy, soft mass causing total ptosis. **(B)** It resolved following treatment with intralesional triamcinolone injection.

stable and slowly involutes by 4–7 years of age.<sup>22</sup> About 70% regress by 7 years.<sup>22</sup>

**Histopathologic features** Histologically, capillary hemangioma of the eyelid consists of lobules of capillaries separated by sparse fibrous septa. The morphology of the lesion changes with age. An early immature lesion tends to have an obliterated lumen with plump endothelial cells and occasional mitotic figures (Fig. 20.6), whereas in the later stages the lumen enlarges and the endothelial cells become attenuated, with increasing fibrosis and fat infiltration.

**Systemic association** In most instances congenital capillary hemangioma is a sporadic condition, but in approximately 20% of patients it may manifest as multiple tumors involving the cutaneous tissue elsewhere, the central nervous system, the liver, and the gastrointestinal tract.<sup>20</sup> Systemic lesions, especially those found in association with Kasabach–Merritt syndrome, may proliferate aggressively and lead to hemorrhage, platelet consumption, disseminated intravascular coagulation, cardiac failure, and death.<sup>20</sup>

**Treatment** The main ocular complications are amblyopia and strabismus. Amblyopia may be meridional because of induced astigmatism or because of stimulation deprivation secondary to mechanical ptosis. Because most lesions regress spontaneously, observation, refractive correction, and appropriate amblyopia management is the standard



**Fig. 20.6** An older child with a large red vascular mass in the upper eyelid (A) that was excised. (B) Histopathology shows a lobulated appearance with vascular channels lined by plump endothelial cells. The presence of a few mitotic figures can be seen in proliferating lesions. (Hematoxylin & eosin, original magnification  $\times 400$ ).

treatment. Active intervention in the form of intralesional, local, or systemic corticosteroids is indicated if the lesion extensively involves the face, or is ulcerated with episodes of bleeding, if there is mechanical ptosis with obscuration of the pupillary axis, or induced astigmatism with amblyopia. Extensive lesions are treated with oral prednisolone 1–2 mg/kg body weight tapered over 4–6 weeks. The application of topical clobetasol propionate may help.<sup>23</sup> Intralesional steroid injections (Fig. 20.5) are reserved mainly for eyelid and anterior orbital lesions. Most lesions regress after one to three injections of triamcinolone or a combination of dexamethasone and triamcinolone injected at 6–8-weekly intervals.<sup>24</sup> The recommended dosage per injection is 6 mg/kg body weight equivalent of prednisolone. Using a small-bore (25 or 26 gauge) needle and aqueous solutions (rather than particulate suspensions), aspiration before injection to confirm that the injection is not intra-arterial, gentle administration maintaining a steady and low injection pressure, injection into multiple sites to achieve diffuse pallor of the lesion as the ideal endpoint, and limiting the dose and volume of injection comprise a safe and effective treatment technique. Although uncommon, reported complications of intralesional steroid injection include central retinal artery occlusion, eyelid depigmentation, fat atrophy, eyelid necrosis, and adrenal suppression.<sup>24</sup> Alternative treatment modalities include interferon, laser sclerotherapy, and excision of circumscribed anterior lesions (Fig. 20.6).

**Cavernous hemangioma** of the eyelid is a rare acquired condition and is generally seen in adults.<sup>25</sup> It may be associated with blue rubber bleb nevus syndrome.<sup>26</sup>

**Clinical features** The lesions are ill circumscribed, bluish in color, and may undergo slow progression. Epithelioid hemangioma, also known as angiolymphoid hyperplasia with eosinophilia, occurs as a nodular lesion in the eyelid. Kimura disease, which is predominant in Asian populations, shares both clinical and histopathologic features with angiolymphoid hyperplasia with eosinophilia and may be clinically indistinguishable.<sup>27</sup>

**Histopathologic features** Cavernous hemangioma is composed of large dilated vascular channels filled with blood, hemosiderin-laden macrophages, scattered lymphoplasmacytic infiltrates, and secondary changes such as calcification, phleboliths, and fibrosis.

**Arteriovenous malformations** as the name suggests, are communications between arteries and veins that bypass the normal capillary beds. In contrast to arteriovenous fistulas, arteriovenous malformations are mainly congenital lesions with multiple large feeding arteries, a central nidus, and numerous dilated draining veins (Fig. 20.7). Rarely, arteriovenous malformations may follow trauma or surgery.<sup>28</sup> Although surgical embolization or excision alone may be possible, a combined approach is considered ideal.<sup>28</sup>

**Lymphangioma** commonly manifests in the orbit rather than in the eyelid. An eyelid lesion generally represents the anterior extension of an orbital lymphangioma (see Chapter 90).<sup>29</sup>

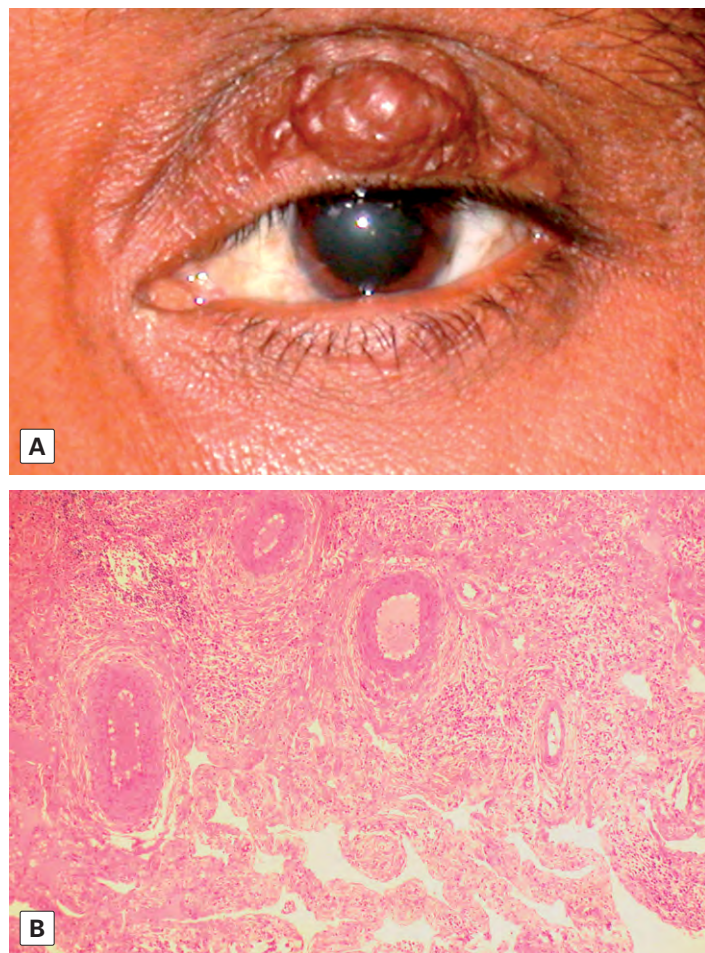
**Angiosarcoma** is an uncommon malignant vascular eyelid tumor. It appears as a raised, reddish-purple or violaceous subcutaneous plaoid lesion, or a mass that tends to ulcerate and bleed spontaneously. Angiosarcoma most often develops de novo, but may arise from pre-existing benign vascular tumors such as nevus flammeus or irradiated lymphangioma. It is an aggressive tumor that tends to recur locally and disseminate widely, with a 5-year survival ranging from 12% to 29%.<sup>30</sup>

**Kaposi's sarcoma** is a malignant vascular tumor that most often presents in the setting of acquired immunodeficiency syndrome (AIDS); it is the most common malignancy seen in patients with AIDS.<sup>31</sup> However, it can also occur in immunocompetent elderly men. The possibility of occult AIDS should be entertained in a young individual with an atypical hordeolum or avascular eyelid mass, as Kaposi's sarcoma sometimes mimics these common lesions and represents the initial presenting sign of AIDS.<sup>31</sup>

**Clinical features** Kaposi's sarcoma appears as a solitary or multifocal, circumscribed or diffuse smooth blue subcutaneous lesion.

**Histopathologic features** Infection by human herpes virus 8 possibly transforms normal mesenchymal cells to become abnormally sensitive to the high levels of cytokines seen in patients with AIDS.<sup>31</sup> Subsequent proliferation and additional mutation result in clinically apparent disease. Histopathologically, Kaposi's sarcoma appears as a network of proliferating endothelial cells that forms slit-like spaces surrounded by spindle-shaped mesenchymal cells and collagen.<sup>31</sup>





**Fig. 20.7** Arteriovenous malformation. (A) A lobulated soft compressible upper eyelid lesion. (B) Vascular channels of varying sizes, including medium-sized feeder vessels on histopathology. (Hematoxylin & eosin, original magnification  $\times 200$ ).

**Treatment** An improvement in immunological status and highly active antiretroviral therapy may result in spontaneous regression of Kaposi's sarcoma. Treatment modalities include local methods such as excision, cryotherapy, and radiotherapy. Systemic chemotherapy is indicated for widespread disease.<sup>31</sup>

**Perivascular tumors** of the eyelid are very rare and include benign or malignant hemangiopericytoma and glomus tumor (see Chapter 90).

### NEUROGENIC TUMORS

Neurogenic tumors of the eyelid include a variety of benign (neurofibroma, schwannoma, and neuroglial choristoma) and malignant tumors (malignant peripheral nerve sheath tumor and Merkel cell tumor).

**Neurofibroma** of the eyelid may be plexiform, multifocal, localized, or solitary (see Chapter 91).

**Schwannoma (neurilemmoma)** is one of the common benign peripheral nerve sheath tumors. Clinically it appears as a slow-growing, well-defined, firm, subcutaneous eyelid nodule that might simulate a large chalazion (see Chapter 91).<sup>32</sup> Solitary schwannoma lacks a

systemic association. Multiple lesions, however, are associated with neurofibromatosis type 1.<sup>32</sup>

**Merkel cell tumor** First described in 1972, a Merkel cell tumor is an aggressive primary cutaneous neuroendocrine malignant neoplasm that arises from Merkel cells, which are specialized neuroendocrine receptors of touch located in the eyelid and conjunctiva.<sup>33, 34</sup>

**Clinical features** Merkel cell tumors are rare, comprising <3% of malignant eyelid tumors. They usually occur in older patients as a painless, rapidly progressive, vascular purplish-red nodule of the upper eyelid.<sup>33,34</sup>

**Histopathologic features** On histopathology the tumor cells are seen to grow in interconnecting sheets and cords (trabecular pattern). The individual cells are uniformly round, with scant cytoplasm, large oval nuclei, prominent nucleoli, and abundant mitotic figures.

**Treatment** Wide surgical excision with tumor-free margins under frozen section control achieves fair local control, although recurrence and metastasis to regional lymph nodes and viscera are not uncommon.<sup>33–35</sup> Adjuvant radiotherapy may help reduce the risk of local recurrence if margins are suspect. Radiation is reserved for recurrent or surgically unresectable tumors.<sup>33–35</sup>

### LYMPHOID, PLASMACYTIC, AND LEUKEMIC TUMORS

Lymphoma represents about 13% of primary malignant eyelid tumors.<sup>36</sup> B-cell lymphoma is more common. It can either be confined to the eyelid or have contiguous anterior orbital extension. It manifests as a smooth, firm, subcutaneous nodule. In contrast, the less common T-cell lymphoma or mycosis fungoides may present with skin infiltration and ulceration, simulating an infectious lesion.

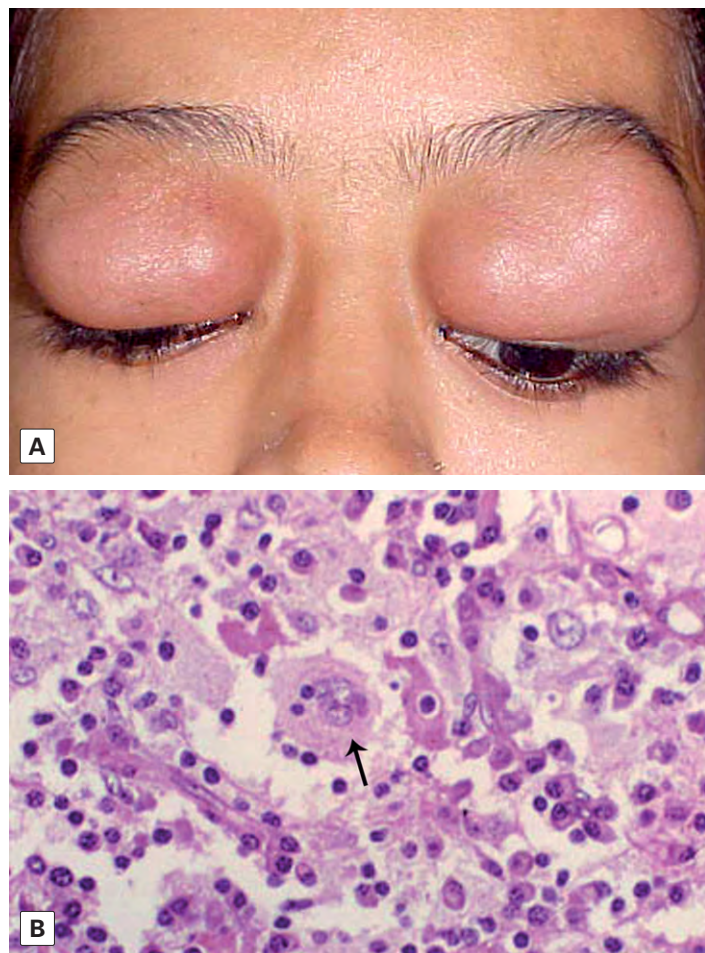Plasmacytoma, a tumor of plasma cell origin, may rarely occur in the eyelid. It may be a primary extramedullary manifestation or be associated with multiple myeloma (see Orbital tumors).

Leukemic infiltration of the eyelid presenting as a nodular subcutaneous mass or as a diffuse swelling can occur in patients with acute or chronic leukemias.<sup>37</sup> It may even be the primary presentation, in the form of granulocytic sarcoma.<sup>37</sup> Relapse of leukemia in the eyelid is also known.<sup>37</sup>

Rosai–Dorfman disease is a distinct histiocytic disorder presenting with bilateral, painless, massive cervical lymphadenopathy with a protracted clinical course, and in most instances associated with fever, anemia, neutrophilia, elevated erythrocyte sedimentation rate, and polyclonal gammopathy.<sup>38</sup> Eyelid involvement is one of the extranodal manifestations of the disease that is noted in 43% of these patients, the other sites being the skin, nasal cavity and paranasal sinus, orbit, bone, and salivary gland (Fig. 20.8).<sup>39</sup> The presence of benign histiocytes with emperipolesis, the absence of cellular atypia, the immunohistochemical profile, and associated clinical features distinguish Rosai–Dorfman disease from other simulating disorders. Management options include observation for mild manifestations with no cosmetic or functional abnormality, surgical excision or debulking, and systemic corticosteroids.<sup>39</sup>

### Hamartomas, choristomas, and miscellaneous tumors

Dermoid can involve the eyelid as a contiguous extension of an orbital or a conjunctival lesion. It may, however, primarily involve the eyelid as a very rare manifestation. Cosmetically disturbing and functionally



**Fig. 20.8** Rosai–Dorfman disease. (A) An 18-year-old girl with a bilaterally symmetrical firm eyelid mass and massive cervical lymphadenopathy and anemia. (B) Histopathology showing a polymorphous population of cells with characteristic histiocytes showing lymphophagocytosis (emperipolesis). (Hematoxylin & eosin, original magnification  $\times 400$ ).

significant dermoids are surgically excised. An ectopic lacrimal gland in the eyelid may present in infancy or early childhood as a cystic mass with or without epiphora.<sup>40</sup> Often it may be a part of a complex choristoma.<sup>41</sup> Heterotopic neuroglial tissue or neuroglial choristoma may manifest as a congenital eyelid mass. Its occurrence is usually associated with other anomalies of cerebral organogenesis.<sup>42</sup>

Phakomatous choristoma or Zimmerman's tumor is a rare congenital hamartoma of lens tissue that probably develops from an abnormal separation or migration of cells from the lens placode into the mesodermal structures of the eyelid.<sup>43, 44</sup> It presents in newborns or young infants as a subcutaneous mass in the medial lower eyelid.<sup>43</sup> Histologically, this lesion consists of cuboidal cells forming cystic dilated and irregularly branched ducts and cords within a densely fibrotic stroma. Also present are eosinophilic basement membrane-like material, psammoma body-like calcifications, and intraluminal degenerated ghost cells.

### METASTATIC TUMORS

Eyelid metastases represent about 1% of all malignant tumors of the eyelid. A rapidly progressive subcutaneous nodule in a patient with prior history of cancer should raise the suspicion. The common primary sources of metastases are breast, lung, and cutaneous melanoma.

### INFLAMMATORY AND INFECTIVE LESIONS

Some common lesions with an inflammatory and infective etiology that often simulate an eyelid tumor include chalazion, pyogenic granuloma, verruca vulgaris, amyloidosis (see Chapter 22), lipid proteinosis, and molluscum contagiosum.

### SUMMARY

Eyelid stromal tumors manifest with a wide spectrum of clinical features that may confound even the experienced clinician. Careful attention to clinical history, vital clinical signs, and systemic features may help in reaching a logical differential diagnosis and appropriate management of the patient.

## REFERENCES

- Witschel H. Congenital solitary fibromatosis of the eyelid. *Ophthalmologica* 1982; 185: 1–6.
- Hidayat AA, Font RL. Juvenile fibromatosis of the periorbital region and eyelid. A clinicopathologic study of six cases. *Arch Ophthalmol* 1980; 98: 280–285.
- D'Hermies F, Dolle C, Verola O et al. Hypertrophic eyelid conjunctival scar. A tarsal keloid. *J Fr Ophtalmol* 2003; 26: 315–318.
- Hymas DC, Mamalis N, Pratt DV et al. Nodular fasciitis of the lower eyelid in a pediatric patient. *Ophthalm Plast Reconstr Surg* 1999; 15: 139–142.
- De Wan J, Evens F, De Mey A. Eyelid tumour and juvenile hyaline fibromatosis. *Br J Plast Surg* 2005; 58: 106–111.
- Weiner JM, Hidayat AA. Juvenile fibrosarcoma of the orbit and eyelid. A study of five cases. *Arch Ophthalmol* 1983; 101: 253–259.
- Griffith DG, Salasche SJ, Clemons DE. Cutaneous abnormalities of eyelid and face. New York: McGraw Hill, 1987; 150–152.
- Jakobiec FA, Mills MD, Hidayat AA et al. Periocular xanthogranulomas associated with severe adult-onset asthma. *Trans Am Ophthalmol Soc* 1993; 91: 99–125; discussion 125–129.
- Khong JJ, Chen CS, James CL et al. Malignant fibrous histiocytoma of the eyelid: differential diagnosis and management. *Ophthalm Plast Reconstr Surg* 2005; 21: 103–108.
- Brazzo BG, Saffra N. Dermatofibrosarcoma protuberans of the brow and eyelid. *Ophthalm Plast Reconstr Surg* 2004; 20: 332–334.
- Font RL, Hidayat AA. Fibrous histiocytoma of the orbit. A clinicopathologic study of 150 cases. *Hum Pathol* 1982; 13: 199–209.
- Bock-Kunz AL, Lyon DB, Singhal VK, Grin TR. Nasopalpebral lipoma–coloboma syndrome. *Arch Ophthalmol* 2000; 118: 1699–1701.
- Enghardt MH, Warren RC. Congenital palpebral lipoblastoma. First report of a case. *Am J Dermatopathol* 1990; 12: 408–411.
- Jolly SS, Brownstein S, Jordan DR. Leiomyoma of the anterior orbit and eyelid. *Can J Ophthalmol* 1995; 30: 366–370.
- Lin IC, Wu CT, Liao SL, Lin LL. Primary orbital leiomyosarcoma. *Ophthalm Plast Reconstr Surg* 2005; 21: 451–453.
- Verdolini R, Goteri G, Brancorsini D et al. Adult rhabdomyoma: report of two cases of rhabdomyoma of the lip and of the eyelid. *Am J Dermatopathol* 2000; 22: 264–267.
- Shields CL, Shields JA, Honavar SG, Demirci H. Clinical spectrum of primary ophthalmic rhabdomyosarcoma. *Ophthalmology* 2001; 108: 2284–2292.
- Ferry AP. Pyogenic granulomas of the eye and ocular adnexa: a study of 100 cases. *Trans Am Ophthalmol Soc* 1989; 87: 327–343; discussion 343–347.
- Werner MS, Hornblass A, Reifler DM, Dresner SC, Harrison W. Intravascular papillary endothelial hyperplasia: collection of four cases and a review of the literature. *Ophthalm Plast Reconstr Surg* 1997; 13: 48–56.
- Shields CL, Shields JA, Minzter R, Singh AD. Cutaneous capillary hemangiomas of the eyelid, scalp, and digits in premature triplets. *Am J Ophthalmol* 2000; 129: 528–531.
- Walter JW, Blei F, Anderson JL et al. Genetic mapping of a novel familial form of infantile hemangioma. *Am J Med Genet* 1999; 82: 77–83.
- Jackson R. The natural history of strawberry naevi. *J Cutan Med Surg* 1998; 2: 187–189.
- Cruz OA, Zarnegar SR, Myers SE. Treatment of periocular capillary hemangioma with topical clobetasol propionate. *Ophthalmology* 1995; 102: 2012–2015.
- Kushner BJ. Local steroid therapy in adnexal hemangioma. *Ann Ophthalmol* 1979; 11: 1005–1009.



25. Bajaj MS, Nainiwal SK, Pushker N, Balasubramanya R. Multifocal cavernous hemangioma: a rare presentation. *Orbit* 2003; 22: 155–159.
26. McCannel CA, Hoenig J, Umlas J et al. Orbital lesions in the blue rubber bleb nevus syndrome. *Ophthalmology* 1996; 103: 933–936.
27. Hidayat AA, Cameron JD, Font RL, Zimmerman LE. Angiolymphoid hyperplasia with eosinophilia (Kimura's disease) of the orbit and ocular adnexa. *Am J Ophthalmol* 1983; 96: 176–189.
28. Hayes BH, Shore JW, Westfall CT, Harris GJ. Management of orbital and periorbital arteriovenous malformations. *Ophthalm Surg* 1995; 26: 145–152.
29. Rootman J, Hay E, Graeb D, Miller R. Orbital–adnexal lymphangiomas. A spectrum of hemodynamically isolated vascular hamartomas. *Ophthalmology* 1986; 93: 1558–1570.
30. Conway RM, Hammer T, Viestenz A, Holbach LM. Cutaneous angiosarcoma of the eyelids. *Br J Ophthalmol* 2003; 87: 514–515.
31. Brun SC, Jakobiec FA. Kaposi's sarcoma of the ocular adnexa. *Int Ophthalmol Clin* 1997; 37: 25–38.
32. Butt Z, Ironside JW. Superficial epithelioid schwannoma presenting as a subcutaneous upper eyelid mass. *Br J Ophthalmol* 1994; 78: 586–588.
33. Singh AD, Eagle RC Jr, Shields CL, Shields JA. Merkel cell carcinoma of the eyelids. *Int Ophthalmol Clin* 1993; 33: 11–17.
34. Kivela T, Tarkkanen A. The Merkel cell and associated neoplasms in the eyelids and periocular region. *Surv Ophthalmol* 1990; 35: 171–187.
35. Peters GB 3rd, Meyer DR, Shields JA et al. Management and prognosis of Merkel cell carcinoma of the eyelid. *Ophthalmology* 2001; 108: 1575–1579.
36. Margo CE, Mulla ZD. Malignant tumors of the eyelid: a population-based study of non-basal cell and non-squamous cell malignant neoplasms. *Arch Ophthalmol* 1998; 116: 195–198.
37. Yaghouti F, Nouri M, Mannor GE. Ocular adnexal granulocytic sarcoma as the first sign of acute myelogenous leukemia relapse. *Am J Ophthalmol* 1999; 127: 361–363.
38. Rosai J, Dorfman RF. Sinus histiocytosis with massive lymphadenopathy. A newly recognized benign clinicopathological entity. *Arch Pathol* 1969; 87: 63–70.
39. Foucar E, Rosai J, Dorfman RF. The ophthalmologic manifestations of sinus histiocytosis with massive lymphadenopathy. *Am J Ophthalmol* 1979; 87: 354–367.
40. McCulley TJ, Yip CC, Kersten RC, Kulwin DR. An ectopic site of lacrimal gland secretion mimicking epiphora. *Arch Ophthalmol* 2002; 120: 1586–1587.
41. Gordon AJ, Patrinely JR, Knapp JA, Font RL. Complex choristoma of the eyelid containing ectopic cilia and lacrimal gland. *Ophthalmology* 1991; 98: 1547–1550.
42. Holbach LM, Naumann GO, Font RL. Neuroglial choristoma presenting as congenital lid tumor. *Graefes Arch Clin Exp Ophthalmol* 1989; 227: 584–588.
43. Ellis FJ, Eagle RC Jr, Shields JA et al. Phakomatous choristoma (Zimmerman's tumor). Immunohistochemical confirmation of lens-specific proteins. *Ophthalmology* 1993; 100: 955–960.
44. Dithmar S, Schmack I, Volcker HE, Grossniklaus HE. Phakomatous choristoma of the eyelid. *Graefes Arch Clin Exp Ophthalmol* 2004; 242: 40–43.

# Surgical techniques

Jennifer I. Hui and David T. Tse

## INTRODUCTION

The goals in the management of a malignant eyelid lesion are to establish an early accurate diagnosis, to achieve a permanent cure by total eradication of the tumor, and to preserve or restore both eyelid function and cosmesis.

## GENERAL PRINCIPLES

**Diagnostic biopsy** An eyelid lesion that exhibits clinical features suggestive of malignancy should first undergo biopsy to establish a definitive diagnosis. If the lesion is small, an excisional biopsy including at least a 2–3 mm margin of normal tissue should be considered. Following simple elliptical excision, the tissue margins of the specimen must be examined histologically to confirm tumor clearance. If the size of the anticipated excisional defect is such that closure might cause eyelid malposition, an incisional biopsy should be considered before proceeding with further manipulation of the surgical site. If a graft or flap is anticipated in the repair of the defect, the surgical margins must be evaluated microscopically to confirm tumor eradication.

**Definitive treatment** Following histologic confirmation of a malignant lesion, definitive excision is pursued. Mohs' micrographic surgery and excision with frozen- or permanent-section control yield high cure rates.<sup>1</sup> The authors' treatment of choice for primary periorbital malignant eyelid lesions is Mohs' micrographic surgery followed by immediate reconstruction. The Mohs method allows for maximal tissue conservation with careful evaluation of surgical margins. First, the gross mass of the tumor plus a small peripheral margin of normal tissue is removed.<sup>1–5</sup> A thin layer of tissue (2 mm) is further excised from the base and edges of the wound. The specimen is divided and placed on glass slides and the edges are carefully marked with different-colored dyes to maintain orientation. Frozen sections are obtained from the undersurface and skin edges; the locations of residual tumor are mapped and only those areas are subsequently re-excised (Fig. 21.1). Once tumor-free margins have been achieved, the oculoplastic surgeon reconstructs the eyelid defect on the same or the following day.

**Sentinel lymph node biopsy** In a patient with a biopsy-proven malignant eyelid lesion with demonstrated biological behavior for regional lymph node metastasis, careful evaluation of preauricular and submandibular lymph nodes is essential. An additional consideration is the use of lymphatic mapping and sentinel lymph node biopsy for

early accurate staging of solid tumors exhibiting a propensity for regional nodal metastasis.<sup>6</sup>

The most common approach to detect microscopic metastases in clinically negative regional lymph nodes utilizes two pharmaceuticals: technetium-labeled sulfur colloid, and blue dye. The mapping process begins with preoperative lymphoscintigraphy to assess the afferent lymphatics. Technetium (Tc)-99m (<sup>99m</sup>Tc)-labeled sulfur colloid is injected around the lesion.<sup>6</sup> Approximately 15–30 minutes after the injection, lymphoscintigrams of the ipsilateral neck region are taken. On the day of surgery, <sup>99m</sup>Tc-labeled sulfur is injected around the lesion. Five to 10 minutes prior to surgical incision, a blue dye is injected into the peritumoral region. Five to 10 minutes following blue dye detection, the  $\gamma$  detector probe is used to survey the skin overlying the draining lymphatic basin in search of an area of increased radioactivity, representing the sentinel lymph node. A small incision is made over the area of increased activity. Using a combination of visualization and the  $\gamma$  detector probe (sound), the lymphatic basin is explored until the blue sentinel node is identified and excised. The use of lymphoscintigraphy with intraoperative  $\gamma$  probe and vital dye guidance is a valuable tool to better stage malignant tumors of the eyelid, as it may prevent unnecessary dissection of the neck.

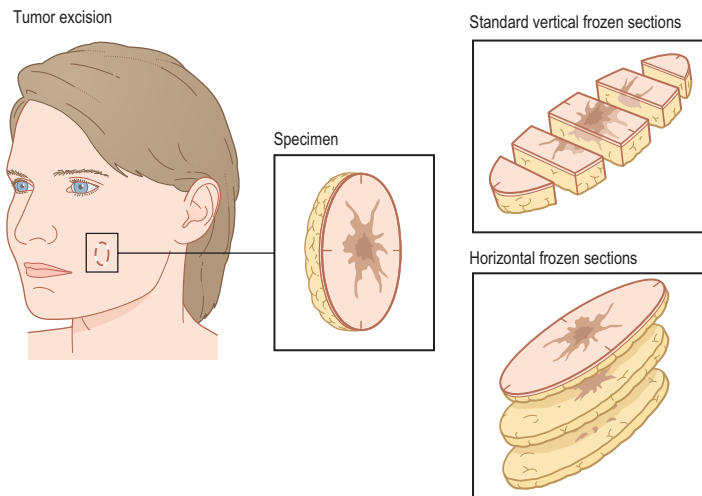
**Eyelid reconstruction** Optimum functional and cosmetic outcomes are possible if the following general principles of eyelid reconstruction are taken into consideration:

- The eyelid is a bilamellar structure; the anterior lamella consists of the skin and orbicularis oculi muscle, and the posterior lamella of the tarsal plate and conjunctiva.
- The anterior or posterior lamella must have its own blood supply.
- Provision must be made for maximal horizontal stabilization with minimal vertical tension, proper canthal fixation, and an epithelialized internal surface.<sup>8</sup>
- Undermining should be sufficient to allow for tension-free closure.
- Identification of the transverse edge of the levator aponeurosis and a knowledge of facial nerve anatomy are essential in maintaining the opening and closing functions of the eyelid.

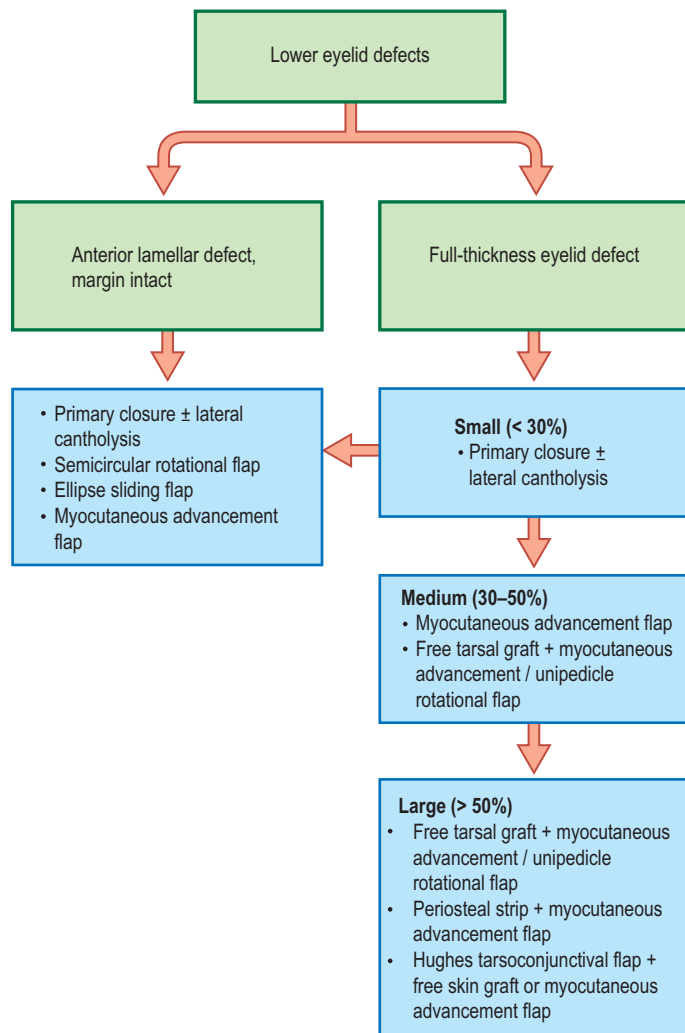
## LOWER EYELID DEFECTS (FIG. 21.2)

### Anterior lamellar deficit, lid margin intact

**Primary closure** In general, anterior lamellar defects without lid margin involvement may be closed primarily if this does not induce



**Fig. 21.1** Mohs' micrographic surgery. Frozen sections are obtained from the undersurface and skin edges of the excised lesion. Locations of residual tumor are marked on a map for subsequent second-stage excision.



**Fig. 21.2** Algorithm for the repair of lower eyelid defects.

distortion. The wound is closed in two layers using deep, interrupted 6/0 Vicryl sutures and interrupted, superficial 6/0 or 7/0 nylon or silk sutures in the skin. If insufficient anterior lamella remains, a full-thickness pentagonal wedge, including the anterior lamellar defect, may be excised with Wescott scissors. The tarsal borders should be sharp and perpendicular to the lid margin. The resulting full-thickness defect may then be closed primarily as described below.

**Skin graft** For defects that are too large to close primarily, full-thickness skin grafts may be employed. Possible donor sites include the ipsilateral or contralateral upper eyelid, preauricular or retroauricular skin, and less commonly the supraclavicular fossa and the upper inner arm. In general, split-thickness skin grafts are not recommended in eyelid reconstruction.<sup>1</sup> If a skin graft is obtained from the upper eyelid or retroauricular area, it must be thinned of subcutaneous fat and connective tissue. The graft is then trimmed to size and sutured to the edges of the defect with interrupted 7/0 nylon or silk sutures.<sup>7</sup>

**Ellipse sliding flap** An elliptical sliding flap may also be used to close some anterior lamellar defects.<sup>9</sup> This flap, however, should not be used to reconstruct anterior lamellar defects near the lid margin because ectropion or retraction may be induced by excessive perpendicular tension. The ellipse should be oriented parallel to the relaxed skin tension lines. The long axis should be four times longer than the short axis, with the ellipse angle at approximately 30°. The flap is secured in two layers.

**Myocutaneous advancement flap** An ideal method to address a large anterior lamellar deficit is the myocutaneous advancement flap because it provides the best tissue match with an independent blood supply (Fig. 21.3). Incision lines should be oriented horizontally and blend within naturally occurring skin creases. Planes of dissection should be determined before the undermining is advanced past the lateral orbital rim.<sup>7,8</sup>

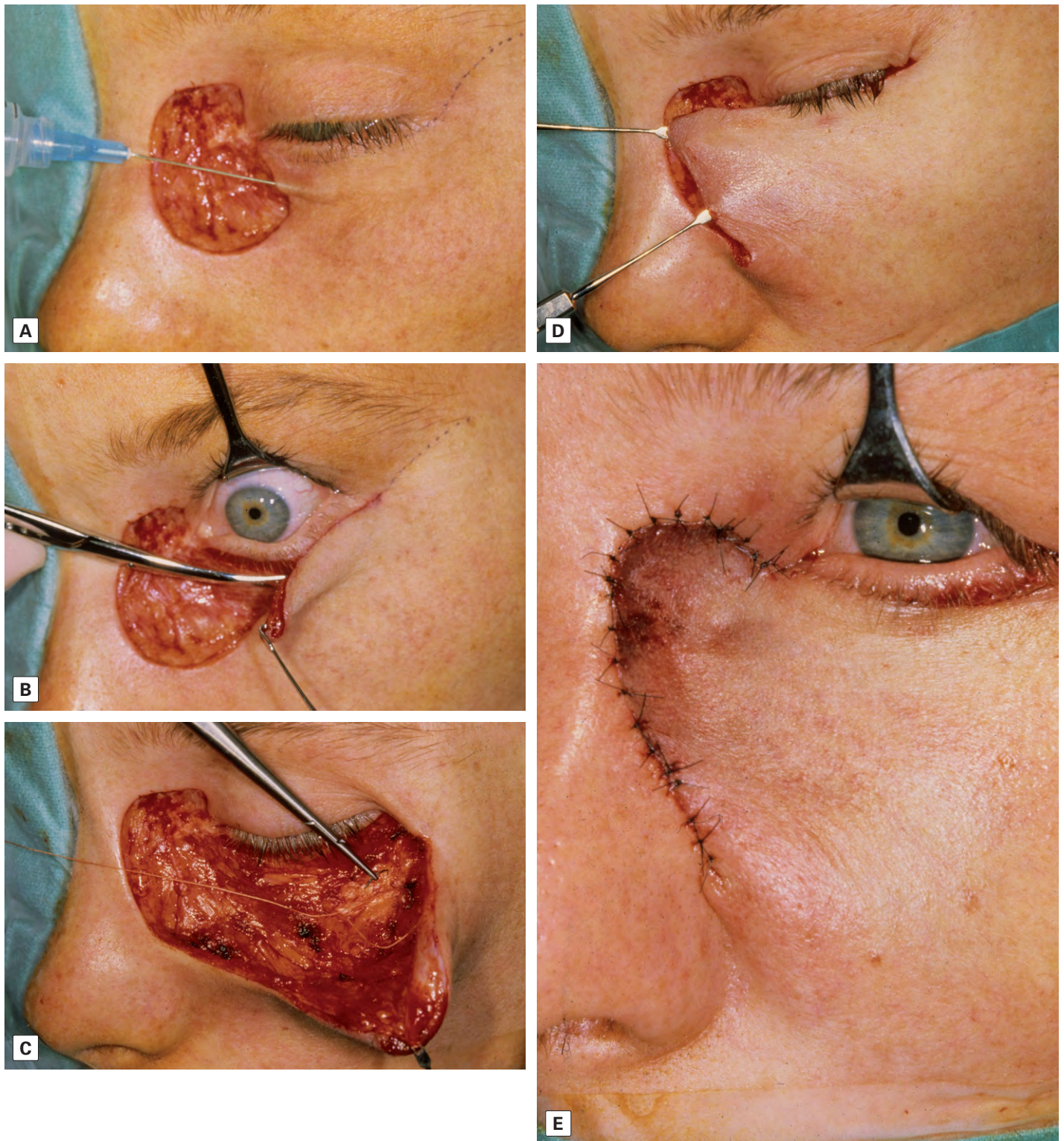
The flap consists of skin and muscle and is designed to advance medially to fill an anterior lamellar defect. The creation of a myocutaneous advancement flap begins with an infralash incision that extends laterally to the canthus and arches superiorly. The key component is a tension-bearing permanent suture (4/0 Prolene) at the zygoma or the lateral orbital rim; the flap is then closed in two layers. This technique provides an anterior lamella replacement with an inherent vascular supply.

### Full-thickness eyelid defect

**Primary closure** For small defects involving less than one-third of the lower eyelid margin, primary closure without lateral cantholysis is the best option. Primary layered closure provides the best tissue match, a smooth lid margin, and a continuous eyelash line. If tension is present and precludes proper lid margin reapproximation, a lateral canthotomy with inferior cantholysis may be performed to yield 5–6 mm of medial advancement of the temporal eyelid margin.<sup>7,9</sup>

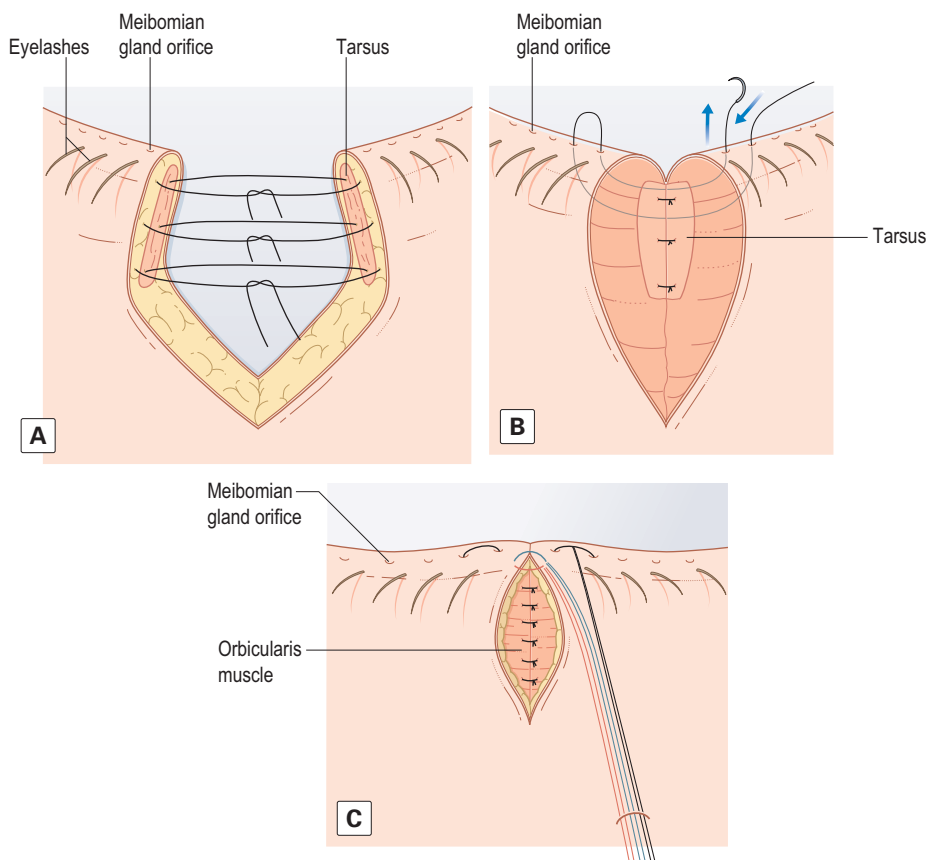
The first step requires trimming of the eyelid defect edges. The tarsal borders should be sharp and perpendicular to the lid margin. The tissue inferior to the tarsus is cut into a wedge, forming a pentagonal-shaped defect. Direct closure may be utilized if the borders of this defect can be reapproximated without excess tension; otherwise a lateral cantholysis is needed.





**Fig. 21.3** Myocutaneous advancement flap. (A) A large anterior lamellar deficit may be repaired with a myocutaneous advancement flap because it provides the best tissue match with an independent blood supply. (B) A flap of sufficient size that allows for tension-free closure is dissected from the underlying tissue. (C) Proper placement of a tension-bearing permanent suture (4/0 Prolene) at the zygoma or the lateral orbital rim is important for securing the flap in position. (D) Closure at the tip of the flap should be devoid of tension. (E) The myocutaneous advancement flap with its inherent vascular supply now covers the anterior lamellar defect.





**Fig. 21.4** Lid margin repair, full-thickness defect. The eyelid margin defect may be closed primarily if less than one-third of the margin is involved. An important step in primary closure of a full-thickness lid margin defect is precise approximation of the tarsal edges. Accurate vertical alignment provides the tension-bearing support of the wound. **(A)** Three interrupted 5/0 Vicryl sutures are placed at partial thickness through the tarsal plate. **(B)** The lid margin is closed with a vertical mattress suture using 6/0 silk sutures, which provide proper anteroposterior alignment. A vertical lid margin suture induces puckering of the wound edges to avoid notching after healing. **(C)** Two additional sutures, one posterior and another inferior to the lashes, are placed to align the lid margin. The three 6/0 silk sutures should be left long and secured away from the wound on to the lower lid skin with a suture.

To perform a cantholysis, a 4–5 mm horizontal incision through skin and orbicularis muscle is made from the lateral canthal angle toward the orbital rim. The tip of the Wescott scissors should be used to identify the lateral attachment of the lower lid, and the inferior crus of the lateral canthal tendon is cut by making a vertical incision.

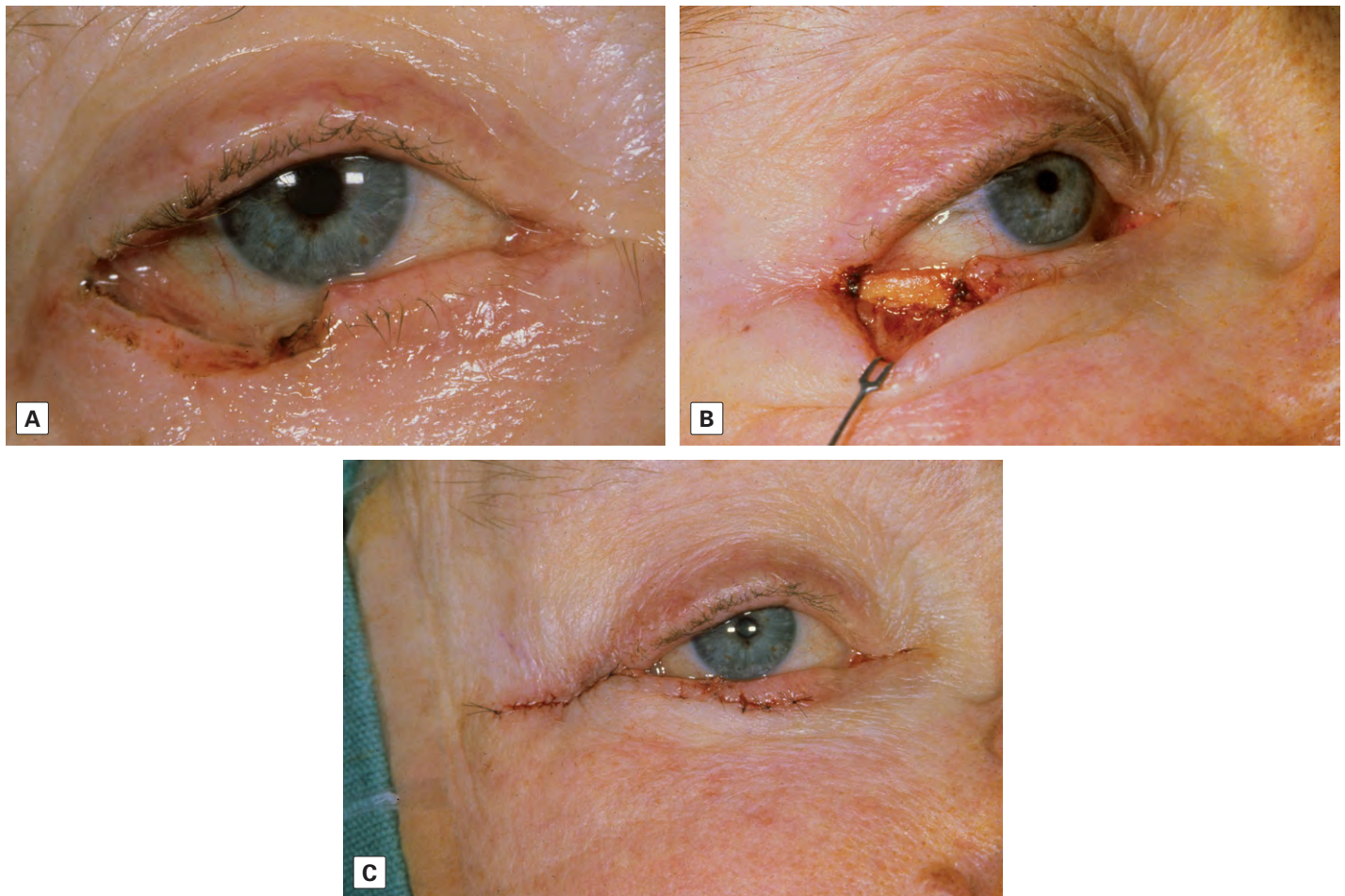
The most important step in primary closure of the pentagonal lid margin defect is precise approximation of the tarsal edges. Accurate vertical alignment provides most of the tension-bearing support of the wound. Following lid margin reapproximation and repair of the tarsal defect as outlined in Figure 21.4, the anterior lamella is closed in two layers.

**Semicircular rotational flap** A lateral semicircular rotational flap may be used to reconstruct up to two-thirds of a central lower lid defect if there is a sufficient temporal tarsal remnant. The temporal tarsal remnant and a myocutaneous flap are moved as a unit.<sup>7</sup> The first step is to outline a semicircle, approximately 20 mm in diameter, starting at the lateral canthal angle. The outline should arc superiorly and temporally, but not pass the lateral extent of the brow. In addition, a lateral canthotomy of the inferior crus is performed with the scissors extending to the inside of the orbital rim. The lateral lower lid and flap are moved medially until the lid margin defect may be covered and closed without tension. Once the defect is closed, the lateral

canthus is reformed. Fixation of the lateral edge of the flap is needed to provide posterior and lateral vector forces so that the reconstructed lower eyelid lies in apposition with the globe. The deep edge of the flap is sutured to the inner aspect of the lateral orbital rim inferior to the superior crus using 4/0 Vicryl sutures. Finally, the conjunctival edge previously cut during the canthotomy is advanced superiorly and attached to the skin edge of the lateral lid margin with a running 7/0 Vicryl suture.

**Free tarsal graft and myocutaneous advancement flap** For larger defects where primary closure is not possible, a free tarsal graft from the ipsilateral or contralateral upper eyelid can be used for posterior lamella replacement.<sup>9</sup> The graft provides posterior lamellar support and a mucous membrane lining for the reconstructed lower lid. A myocutaneous advancement flap is then fashioned to provide blood supply to the free graft (Fig. 21.5). This option is most appropriate for patients whose involved eyelid is on the side of the only seeing eye.

The harvest of a free autogenous tarsal graft first involves the placement of a 4/0 silk traction suture through the central upper lid margin. The lid is everted to expose the tarsoconjunctival surface. The inferior edge of the graft is parallel to and 4 mm or more from the lid margin. The superior tarsal border determines the vertical height of the graft.



**Fig. 21.5** Free tarsal graft plus myocutaneous advancement flap. (A) A full-thickness lower eyelid defect may be repaired with a free tarsal graft for posterior lamella replacement and an overlying myocutaneous advancement flap to provide vascular support. (B) The free tarsal graft, harvested from either the ipsilateral or the contralateral upper eyelid, provides posterior lamellar replacement. (C) The myocutaneous advancement flap, fashioned in the manner of a lower eyelid blepharoplasty, provides an inherent blood supply to the underlying free tarsal graft. This figure demonstrates the key principle that either the reconstructed anterior or posterior lamella must have its own inherent vascular supply (pedicle flap), thus ensuring tissue survival and optimum surgical outcome for the patient.

The incision is made through the conjunctiva and full-thickness tarsus along the inferior and vertical edges. Dissection is used to separate the levator aponeurosis from the underlying tarsus. Mueller's muscle and conjunctiva are cut from the superior tarsal border, leaving 2 mm of conjunctiva attached to the graft. The donor site is allowed to heal by secondary intention.

The graft is secured into the defect with the conjunctival surface in contact with the globe and the superior edge of the graft, with the conjunctival remnant along the new lid margin. The medial edges are secured with interrupted 5/0 Vicryl sutures passed at partial thickness to avoid ocular irritation. The superior edge is attached to the superior forniceal conjunctiva and the edges of Mueller's muscle and levator aponeurosis using interrupted 6/0 Vicryl sutures. The graft may subsequently be covered with a vascularized myocutaneous advancement flap (similar to the previously described rotational flap).

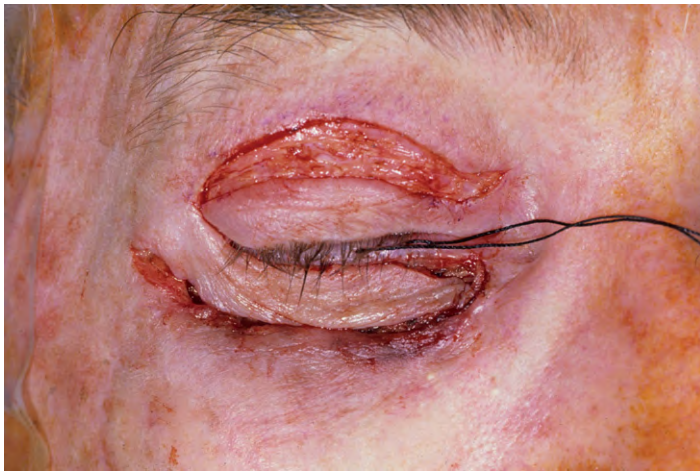
**Periosteal strip and myocutaneous advancement flap** The periosteal strip with myocutaneous advancement flap is an alternative to the free tarsal graft.<sup>7</sup> This method may be used to reconstruct the lower lid when the lateral third of the tarsus is not present. The perio-

steal strip may also be used in combination with other procedures for larger defects.

When fashioning the periosteal strip, the skin overlying the flap is first outlined with a marking pen in a semicircle, or as a cheek flap extended 1–2 cm past the lateral commissure. Once the skin–muscle flap is mobilized and reflected, the lateral orbital rim is exposed. A rectangular strip of periosteum based at the inner aspect of the rim is then formed. The strip should be 1 cm wide, angled at 45° to follow the lower lid contour. The distance from the lateral edge of the tarsal defect to the orbital rim determines the length. The fascia is dissected from the temporalis muscle and separated from the bony rim with a periosteal elevator. The strip is reflected nasally to fill the tarsal defect. The anterior periosteum lies against the globe and the distal end is secured to the lateral border of the remaining tarsus with partial-thickness 5/0 Vicryl sutures. The strip thus provides posterior lamellar support for the reconstructed lower eyelid. The myocutaneous advancement flap is then rotated and secured to fill the anterior lamellar defect.

**Free tarsal graft and unipedicle flap from the upper eyelid** A free tarsal graft with a unipedicle flap from the upper eyelid is





**Fig. 21.6** Unipedicle flap. A unipedicle flap from the upper eyelid with an inherent vascular supply is used to replace an anterior lamellar defect in the lower eyelid.

another method used to close full-thickness lower eyelid defects. The free tarsal graft is first harvested. Next, a flap is harvested from excess upper lid skin and subcutaneous tissue, based at the lateral canthus (Fig. 21.6), rotated inferiorly to fill the lower anterior lamellar defect, and then closed in two layers. The unipedicle flap may leave the patient with a lump of tissue at the lateral canthus. If necessary, a second procedure may be undertaken 6–8 weeks later to thin the base of the flap and remove this excess tissue.

**Tarsoconjunctival (Hughes) flap and free skin graft, or myocutaneous advancement flap** For large defects involving more than 50% of the eyelid margin a tarsoconjunctival flap (Hughes flap) with a free skin graft or myocutaneous advancement flap may be considered.<sup>7</sup> In this procedure (Fig. 21.7), a tarsoconjunctival flap from the upper eyelid is passed behind the upper eyelid remnant and advanced into the posterior lamellar defect of the lower eyelid. The anterior lamella is then recreated with a skin advancement flap or a free skin graft from the preauricular or retroauricular area. The main disadvantage is that the pupil remains covered for 4–8 weeks by the tarsoconjunctival bridge. This vascularized pedicle is severed and released in a second procedure after the lower eyelid flap is revascularized.

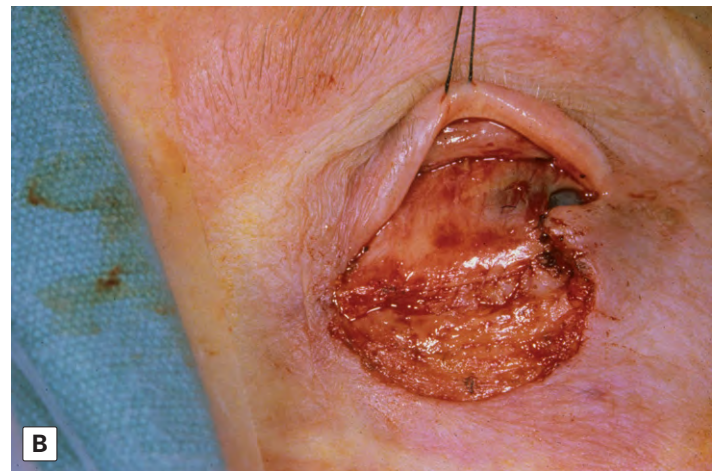
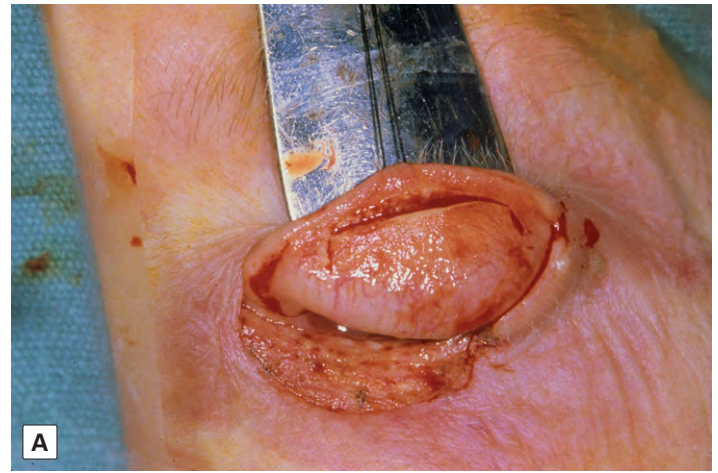
#### UPPER EYELID DEFECTS (FIG. 21.8)

##### Anterior lamellar deficit, lid margin intact

**Primary closure** As in the case of the lower eyelid, small defects may be closed primarily if lid distortion will not be induced. If insufficient anterior lamella remains, a full-thickness pentagonal wedge may be used.

**Skin graft** For larger defects not involving the lid margin, a free full-thickness skin graft may be employed.<sup>7,8</sup>

**Ellipse sliding flap** An elliptical sliding flap is a technique used to close some anterior lamellar defects, as described in the section on lower eyelid defects.<sup>7</sup> The main advantage of this flap is the ability to repair an anterior lamellar defect without sacrificing significant amounts of normal tissue.



**Fig. 21.7** Hughes tarsoconjunctival flap. **(A)** With the upper eyelid everted over a retractor, a three-sided flap is created in the central tarsal conjunctiva of the upper eyelid. The horizontal incision should be at least 4 mm from the lid margin to avoid entropion, lid margin contour deformity, loss of lashes, and trichiasis. The vertical incisions course up toward the superior fornix perpendicular to the lid margin. All incisions are made through the conjunctiva and tarsus. The Mueller's muscle is dissected off the conjunctiva and remains in the upper eyelid proper. **(B)** The tarsoconjunctival flap is mobilized into the lower lid defect to align the superior tarsal border of the upper lid with the remnant of the lower lid margin.

**Myocutaneous advancement flap** As with lower lid defects, a myocutaneous advancement flap may also be used. Flaps provide the best tissue match, the best cosmetic result, and an inherent vascular supply.

##### Full-thickness eyelid defect

**Primary closure** Central upper lid defects – up to 30% in younger patients and 50% in older patients – may be closed using the same technique as in the lower lid. The main difference is that the vertical height of the tarsus is two to three times longer than that of the lower lid. Also, the levator aponeurotic attachments should not be disturbed, so as to avoid postoperative ptosis. If necessary, lateral cantholysis may provide 3–5 mm of medial mobilization of the remaining lateral eyelid margin.

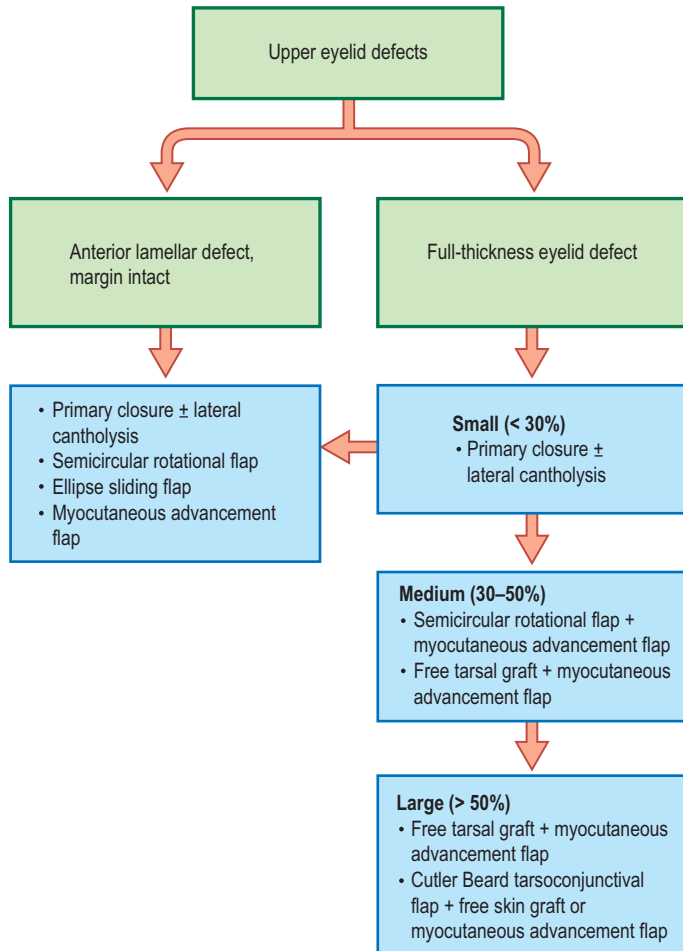


Fig. 21.8 Algorithm for the repair of upper eyelid defects.

**Semicircular rotational flap** Up to half of the medial or central upper lid may be reconstructed with primary closure and a lateral semicircular or myocutaneous flap, similar to that described for the lower lid.<sup>7</sup> The first difference is an inferiorly, not superiorly, arching semicircle flap. The second is that the superior, not inferior, crus of the lateral canthal tendon should be lysed.

**Free tarsal graft and myocutaneous advancement flap** With larger defects, a free tarsal graft with a myocutaneous advancement flap may be needed.<sup>7</sup> A free tarsoconjunctival graft may be harvested from the contralateral upper eyelid. Once the flap is secured, the conjunctival remnant is advanced anteriorly and secured to the inferior flap skin edge with a running 7/0 Vicryl suture to re-establish the mucocutaneous junction. Finally, the superior eyelid must be immobilized and kept on stretch to minimize postoperative retraction. A temporary 4/0 silk suture is tied over bolsters and placed on inferior traction.

**Tarsoconjunctival flap (Cutler–Beard flap) and free skin graft or myocutaneous advancement flap** The Cutler–Beard procedure is a less commonly used, two-stage method of closing large, full-thickness upper eyelid defects involving more than 50% of the lid margin. The procedure is similar to the Hughes flap. It involves the advancement of a lower eyelid flap, consisting of skin and muscle (anterior lamella) and conjunctiva, behind the lower eyelid margin remnant into the defect of the upper eyelid. The main disadvantage of the procedure is the creation of a thick, relatively immobile upper eyelid without tarsal support. This procedure, in combination with a myocutaneous advancement flap, is used when there are no alternative methods of closing the defect.<sup>7,8</sup>

## SPECIAL CIRCUMSTANCES (FIG. 21.9)

### Medial canthal defect

**Median forehead flap** The median forehead flap is a unipedicle flap used to close large anterior lamellar defects of the lower eyelid

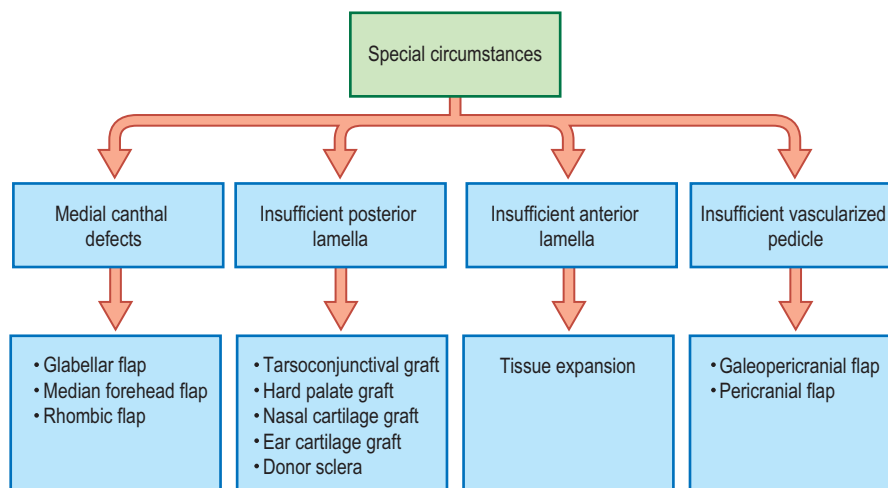
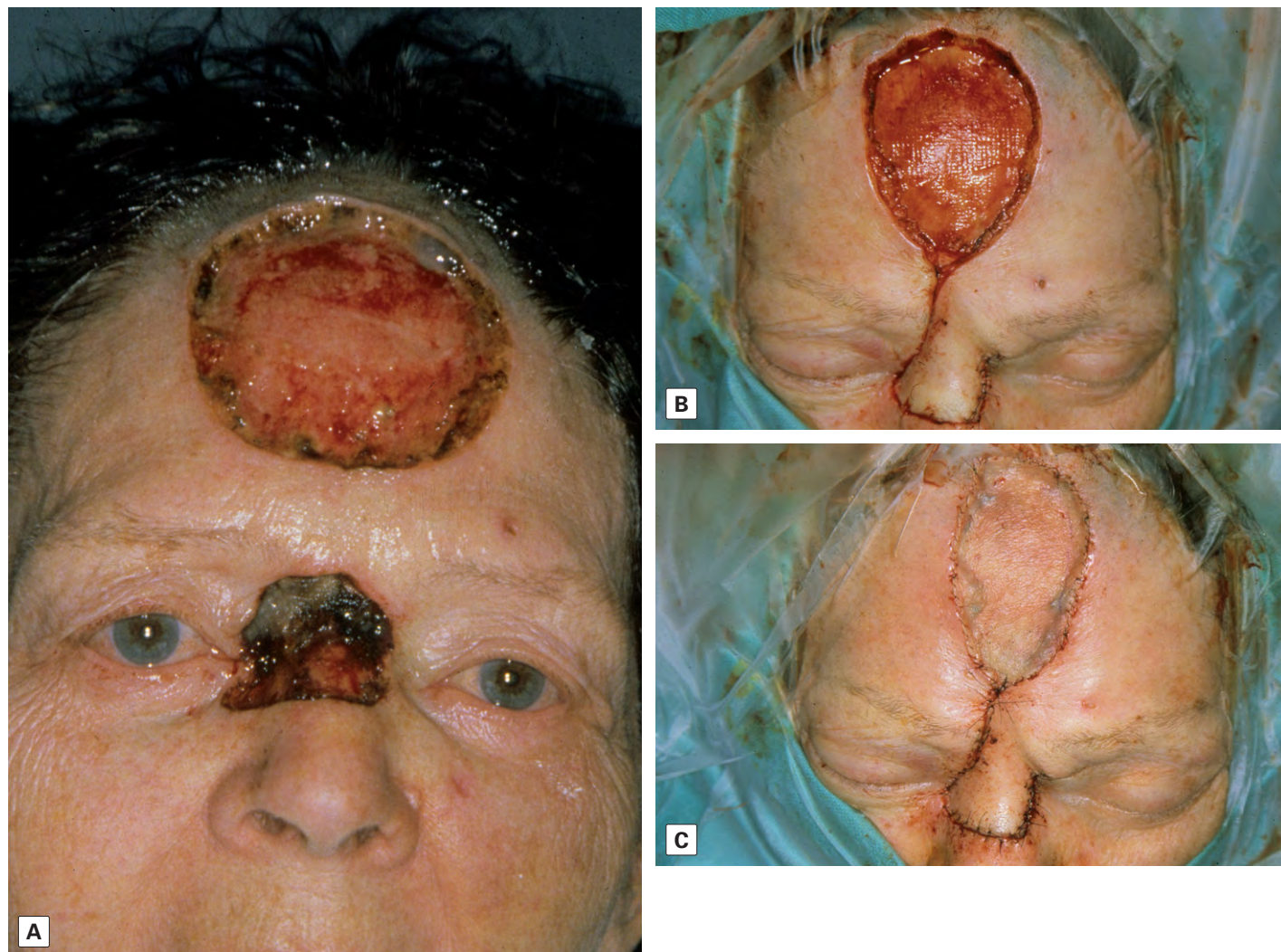


Fig. 21.9 Algorithm for surgical repair in special circumstances.





**Fig. 21.10** Median forehead flap. **(A)** This patient has a large forehead and right-sided medial canthal defects following the excision of two lesions in these respective areas. **(B)** The medial canthal defect is repaired by rotating a median forehead flap, with its own inherent vascular supply, down into the area of deficient tissue. **(C)** The large forehead defect is not amenable to primary closure, thus it may be repaired with a free skin graft. This case illustrates the simultaneous use of two reconstructive options to correct two disparate defects.

and medial canthus (Fig. 21.10).<sup>8</sup> The flap is based on the axis of the contralateral supraorbital neurovascular bundle. Following 120–180° of rotation into the defect, the flap is secured with a two-layered closure. It may be combined with other rotational flaps for very large defects.

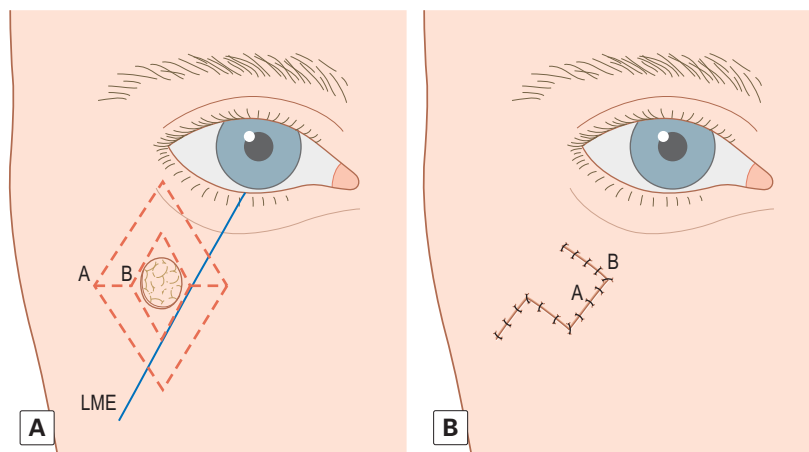
**Glabellar flap** Medial canthal defects may also be repaired with a glabellar flap, which is a modified V–Y rotation flap<sup>8</sup> in the shape of an inverted V, which begins at the midpoint of the glabella just above the brow, with an angle of less than 60°. Following rotation into the defect, the apex is placed at the lateral edge and the point at the inferior tip. Finally, the donor site is sutured in a V–Y closure which may induce a shortening of the interbrow distance. This flap may require secondary debulking.

**Rhombic flap** The rhombic flap is a non-transposition flap used in the closure of medial and lateral canthal defects.<sup>7</sup> With minimal sacrifice of normal tissue, most defects may be converted to a rhombic

configuration with angles of 60° and 120° and all sides of equal length (Fig. 21.11).

**Insufficient posterior lamella** In defects with insufficient posterior lamella, tarsoconjunctival grafts are preferred because they provide a smooth surface over the cornea. If such a graft is not available, nasal or ear cartilage grafts and donor sclera may be used to reconstruct the deficiency. Hard palate grafts in particular are being used with increasing frequency, harvested from the gingival surface of the roof of the mouth.<sup>10,11</sup> The key points are the need to avoid the central palatine raphe, the anterior palatine rugae, and the area overlying the greater palatine foramen where the anterior palatine artery exits.

**Insufficient anterior lamella** More extensive defects of the anterior lamella may require more involved methods of repair. The posterior lamella is first replaced with a graft, as described above. If a free graft is used, the anterior lamella must be reconstructed with a vascular



**Fig. 21.11** Rhombic flap. **(A)** First, the defect is made into a rhombus by marking two lines parallel to the lines of maximum extensibility (LME). These LME are oriented perpendicular to the relaxed skin tension lines (RSTL). The first rhombic flap is made by placing two more parallel lines equal in length to and tangential to the defect, at either  $60^\circ$  or  $120^\circ$  to the first set of lines while sacrificing the minimal amount of normal tissue possible. Next, a line is drawn from each end of the shorter diagonal that bisects the  $120^\circ$  angle. This line should be equal in length to the sides of the rhombus. Further lines are marked from the end of the previous mark at a  $60^\circ$  angle parallel to the sides of the rhombic defect. **(B)** Of the four possible flaps that are designed, only one of the two flaps oriented to close the donor site along LME, which causes the least interference with surrounding structures, should be chosen. With medial rotation, this flap is advanced into the defect so that point B aligns with medial point of the defect, and point A is placed in the inferior apex.

flap. Tissue expanders allow for the use of vascularized skin that is similar in appearance, thickness, and texture to that adjacent to the defect without sacrificing normal tissue.<sup>12</sup> Most importantly, tissue expansion seems to enhance the vascularity of the skin flap. Other advantages include the non-hair-bearing nature and pliability of the created tissue. The main disadvantage is the creation of temporary disfigurement.

In tissue expansion, skin is recruited from the adjacent skin, such as the forehead, the temporalis and preauricular regions, and the lid proper. Adequate tissue area is created in a staged procedure. A skin incision is made along the hairline, brow, or a pre-existing incision line, and a recipient pocket is dissected in the subcutaneous tissue. The expander is soaked in an antibiotic solution, tested for leaks, placed into the recipient pocket, and filled with saline. A remote expander is then placed into the pocket as well and the wound is closed in two layers.

Serial expansion is begun 2–3 weeks after placement. A 27-gauge needle is used to inflate the expander with saline percutaneously through the injection port until the expander feels taut. Usually 10–15% of the total expander volume is injected at any one time, and the process is usually repeated twice weekly. Once adequate tissue has been created, the expander is removed and the newly created skin is ready for use as a local skin flap in eyelid reconstruction.

**Insufficient vascularized pedicle** For large defects with an insufficient vascularized pedicle, galeal and pericranial flaps may be used.<sup>13</sup> They provide an excellent vascular supply for the recipient site and any underlying free tarsconjunctival or overlying skin grafts. The main difference from a median forehead flap is that skin is not transposed with a galeal or pericranial flap. The thinner nature of these flaps reduces the amount of bunching over the nasal bridge. Although

both types of flap may be employed in upper eyelid reconstruction, the galeopericranial flap is thought to be superior to the pericranial flap because of its increased vascularity.

In the repair of large upper eyelids defects, the posterior lamella is first reconstructed using one of the previously described grafts. The galeopericranial or pericranial flap is then created to fill the soft tissue defect. A standard bicoronal incision is outlined over the skull vertex. It is important to avoid a transverse incision of the flap two finger-breadths above the superior orbital rim, as this is the region where the frontalis nerve penetrates into the frontalis muscle. A transcoronal incision is then made to access the pericranium of the forehead. For a galeopericranial flap the plane of dissection is between the subcutaneous tissue and the galea (for pericranial flaps the plane is subgaleal, leaving the loose areolar tissue and periosteum adherent to the frontal bone). Dissection is carried towards the supraorbital rim while preserving the supraorbital and supratrochlear vessels. The pericranium and galea are then incised and elevated off the frontal bone. The flap is mobilized, turned down anteriorly through the skin defect, and subsequently serves as a well-vascularized bed for a skin graft.

### SUMMARY (BOX 21.1)

The treatment of malignant eyelid lesions includes complete excision of the tumor as well as reconstruction to provide optimum function, globe protection, and esthetics. Mohs' micrographic surgery technique is the preferred method of excision of periocular malignancies, as it allows for clearance of the tumor margin while maximally conserving normal tissues. Repair of the eyelid depends on the size of the defect and whether or not the lid margin is involved. Most importantly, either the reconstructed anterior or the posterior lamella must have its own inherent blood supply (pedicle flap), as this will ensure tissue survival and optimal surgical outcome for the patient.

**BOX 21.1 Techniques for Eyelid Reconstruction****Anterior lamella defect lower eyelid, eyelid margin intact**

- Primary closure
  - with lateral cantholysis
  - without lateral cantholysis
- Skin graft (of non-hair-bearing skin)
  - ipsilateral upper eyelid
  - preauricular skin graft
  - retroauricular skin graft
  - supraclavicular skin graft
  - upper inner arm skin graft
- Ellipse sliding flap
- Myocutaneous advancement flap

**Full-thickness eyelid defect lower eyelid**

- Primary closure
  - with lateral cantholysis
  - without lateral cantholysis
- Semicircular rotational flap
  - temporal tarsal remnant + myocutaneous advancement flap
    - only feasible if sufficient temporal tarsal remnant
- Free tarsal graft + myocutaneous advancement flap
- Periosteal strip + myocutaneous advancement flap
- Free tarsal graft + unipedicle rotational flap from the upper eyelid
- Hughes tarsoconjunctival flap + free skin graft or myocutaneous advancement flap

**Anterior lamellar defect upper eyelid, eyelid margin intact**

- Primary closure
  - with lateral cantholysis
  - without lateral cantholysis

- Skin graft (of non-hair-bearing skin)
  - contralateral upper eyelid
  - preauricular skin graft
  - retroauricular skin graft
  - supraclavicular skin graft
  - upper inner arm skin graft

## ■ Ellipse sliding flap

## ■ Myocutaneous advancement flap

**Full-thickness upper eyelid defect**

- Primary closure
  - with lateral cantholysis
  - without lateral cantholysis
- Semicircular rotational flap
  - temporal tarsal remnant + myocutaneous advancement flap
    - only feasible if sufficient temporal tarsal remnant
- Free tarsal graft + myocutaneous advancement flap
- Cutler–Beard tarsoconjunctival flap + free skin graft or myocutaneous advancement flap

**Medial canthal defect**

- Median forehead flap
- Glabellar flap
- Rhombic flap

**Insufficient posterior lamella**

- Tarsoconjunctival graft
- Hard palate graft
- Nasal cartilage graft
- Ear cartilage graft
- Donor sclera

**Insufficient anterior lamella**

- Tissue expansion

**Insufficient vascularized pedicle**

- Galeopericranial flap
- Pericranial flap

**REFERENCES**

1. Cook BE Jr, Bartley GB. Treatment options and future prospects for the management of eyelid malignancies: an evidence-based update. *Ophthalmology* 2001; 108: 2088–2098; quiz 2099–2100, 2121.
2. Tse DT, Gilberg SM. Malignant eyelid tumors. In: Krachmer JH, Mannis MJ, Holland EJ, eds. *Cornea: Surgery of the cornea and conjunctiva*, 2nd edn. Philadelphia: Mosby, 2005; v. II.
3. Esmali B, Wang B, Deavers M et al. Prognostic factors for survival in malignant melanoma of the eyelid skin. *Ophthalm Plast Reconstr Surg* 2000; 16: 250–257.
4. Coleman WP III, Davis RS, Reed RJ, Krementz ET. Treatment of lentigo maligna and lentigo maligna melanoma. *J Dermatol Surg Oncol* 1980; 6: 476–479.
5. Zitelli JA, Mohs FE, Larson P, Snow S. Mohs micrographic surgery for melanoma. *Dermatol Clin* 1989; 7: 833–843.
6. Esmali B. Sentinel lymph node mapping for patients with cutaneous and conjunctival malignant melanoma. *Ophthalm Plast Reconstr Surg* 2000; 16: 170–172.
7. Kronish J. Eyelid reconstruction. In: Tse DT, ed. *Color atlas of ophthalmic surgery: oculoplastic surgery*. Philadelphia: JB Lippincott, 1992.
8. Nerad JA. The requisites in ophthalmology oculoplastics surgery: eyelid reconstruction. In: Krachmer JH, ed. *Requisites in ophthalmology: oculoplastic surgery*. St Louis: Mosby, 2001.
9. Kersten RC, Codère F, Dailet RA et al. Basic and clinical science course: Section 7, Orbit, eyelids, and lacrimal system. San Francisco: American Academy of Ophthalmology, 2003.
10. Bartley GB, Kay PP. Posterior lamellar eyelid reconstruction with a hard palate mucosal graft. *Am J Ophthalmol* 1989; 107: 609–612.
11. Beatty RL, Harris G, Bauman GR, Mills MP. Intraoral palatal mucosal graft harvest. *Ophthalm Plast Reconstr Surg* 1993; 9: 120–124.
12. Tse DT, McCafferty LR. Controlled tissue expansion in periocular reconstructive surgery. *Ophthalmology* 1993; 100: 260–268.
13. Tse DT, Goodwin WJ, Johnson T et al. Use of galeal or pericranial flaps for reconstruction of orbital and eyelid defects. *Arch Ophthalmol* 1997; 115: 932–937.

# Systemic associations of eyelid tumors

Arun D. Singh and Elias I. Traboulsi

## INTRODUCTION

There are several rare eyelid tumors that may be manifestations of a systemic disease. In such instances it is imperative for ophthalmologists to recognize the systemic association and initiate appropriate systemic and genetic evaluation. In this chapter a brief description of these eyelid tumors is given and the associated systemic diseases are outlined (Table 22.1). Where applicable, the inheritance pattern of the syndromic association and its molecular genetics are also included.

Patients with an inherited predisposition for tumors tend to develop them at an earlier age, have multiple tumors with bilateral involvement, and there may be a positive family history of similar lesions.<sup>1</sup> The majority of eyelid tumors in the setting of an inherited predisposition are benign, but some malignant tumors are also known to have a syndromic association, such as one may see, for example, in the setting of the Gorlin–Goltz syndrome. One of the most important clues to the existence of an associated systemic disease is the unusual histopathologic nature of the tumor. For example, tumors such as myxomas or sebaceous adenomas of the eyelid are unlikely to occur in the absence of a syndromic association.

## NEUROFIBROMA

Neurofibroma is the hallmark finding of neurofibromatosis type 1. Neurofibromas tend to be multiple and develop towards the end of the first decade of life. They appear as discrete, soft tumors on the face (including the eyelids, hands and trunk). Based on their appearance and the extent of tissue involvement, neurofibromas can be classified as cutaneous, subcutaneous, nodular plexiform, and diffuse plexiform (see Chapter 65).

## NEVUS FLAMMEUS

In general, only about 10% of all patients with nevus flammeus or port-wine stain of the eyelid are associated with Sturge–Weber syndrome (SWS).<sup>2</sup> Sturge–Weber syndrome only occurs in patients who have hemangiomas in the V1 or V2 areas of distribution of the trigeminal nerve. Bilateral port-wine stains of the eyelids have a higher likelihood of being associated with Sturge–Weber syndrome than do unilateral lesions.<sup>2</sup> In the absence of leptomeningeal involvement, patients should only be given a diagnosis of nevus flammeus, port-wine stain, or facial angioma to avoid the stigmata associated with a diagnosis of Sturge–Weber syndrome (see Chapter 65).

## GARDNER SYNDROME

Extracolonic manifestations of Gardner syndrome include dental anomalies, pigmented ocular fundus lesions that resemble congenital hypertrophy of the retina pigment epithelium, soft tissue tumors, desmoid tumors, and other cancers.<sup>3,4</sup> Orbital osteoma, soft tissue tumors of the brows or eyelids, and epidermoid cysts of the eyelid may also occur (see Chapter 65).<sup>5–7</sup>

## NEVOID BASAL CELL CARCINOMA SYNDROME (GORLIN–GOLTZ SYNDROME)

Nevoid basal cell carcinoma syndrome (NBCCS) is also referred to as basal cell nevus syndrome, Gorlin syndrome, or Gorlin–Goltz syndrome.<sup>8,9</sup> Although basal cell nevi may occur in early childhood, it is the risk of multiple basal cell carcinoma and developmental anomalies that characterizes NBCCS.<sup>10</sup> Other features include the development of multiple jaw keratocysts and characteristic facial features.

**Inheritance** NBCCS is inherited as an autosomal dominant trait. About 30% of probands have a de novo mutation.

**Molecular genetics** This disorder is due to mutations in the *PTCH* gene located on chromosome 9q22.3.<sup>11,12</sup> *PTCH* sequence alterations can be detected in about 60–85% of cases that meet the clinical diagnostic criteria for NBCCS.<sup>12</sup>

**Ophthalmic features** A wide variety of ophthalmic manifestations may be present in 26% of patients with NBCCS.<sup>10</sup> Periocular basal cell carcinoma,<sup>13,14</sup> hypertelorism, nystagmus, and cataracts are some of the common features (Fig. 22.1).<sup>10,14</sup> The occurrence of microphthalmia,<sup>15</sup> coloboma, combined retinal and RPE hamartoma,<sup>16</sup> and vitreoretinal abnormalities<sup>17</sup> in the setting of NBCCS implicates the *PTCH* gene in ocular development.<sup>15,17</sup>

**Systemic features** Jaw keratocysts and calcification of the falx cerebri are some of the most frequent (90%) manifestations of NBCCS (Fig. 22.1).<sup>10,18</sup> Basal cell carcinomas tend to be multiple (more than five in a lifetime) and occur before the age of 30 years. They may arise from pre-existing basal cell nevi or de novo. In general, about 0.5% of patients with basal cell carcinoma have underlying NBCCS.<sup>19</sup> The proportion is much higher (22%) in patients with basal cell carcinoma prior to age 20.<sup>20</sup> White race, sun exposure, and radiation therapy are major risk factors for inducing basal cell carcinoma.<sup>21</sup> The characteristic



**Table 22.1 Various eyelid tumors that are markers of a syndromic association**

Entity	Eyelid tumor	Associated features	Locus/gene
Neurofibromatosis type 1	Neurofibroma	Lisch nodules Café au lait spots Pheochromocytoma	17q <i>NF1</i> gene
Sturge–Weber syndrome	Diffuse hemangioma	Leptomeningeal hemangioma	Sporadic
Gardner syndrome	Epidermoid cyst Fibroma Orbital osteoma	CHRPE Colorectal polyps/carcinoma	5q21 <i>APC</i> gene
Gorlin–Goltz syndrome	Basal cell carcinoma	Odontogenic cysts Bifid ribs Palmar pits Ovarian tumor	9q 22 <i>PTC</i> gene
Cowden syndrome	Trichilemmoma	Oral papilloma Breast tumor Thyroid tumor	10q23 <i>PTEN</i> gene
Carney complex	Myxoma	Spotty mucocutaneous pigmentation Schwannoma Endocrine overactivity Testicular tumor	17q <i>PRKAR1A</i> gene chromosome 2
Muir–Torre syndrome	Sebaceous adenoma	Keratoacanthoma Basal cell carcinoma Colorectal adenocarcinoma	2p <i>hMLH1</i> <i>hMSH2</i>

CHRPE, congenital hypertrophy of retinal pigment epithelium.

facial features include forehead bossing and macrocephaly.<sup>18</sup> The diagnostic criteria for NBCCS are summarized in Table 22.2.<sup>10</sup>

### MULTIPLE HAMARTOMA SYNDROME (COWDEN SYNDROME)

Cowden syndrome was first described in 1963 and is named after the patient in whom the initial observations were made.<sup>22</sup> As the majority of tumors in this syndrome are hamartomatous malformations, it has also been referred to as multiple hamartoma syndrome.<sup>23</sup> Other features include benign and malignant tumors of the thyroid, breast, and endometrium.<sup>23</sup>

**Inheritance** Cowden syndrome is inherited as an autosomal dominant trait with 90–99% penetrance by age 30.<sup>24</sup> Although it is generally overlooked, about 10–50% of individuals with Cowden's syndrome may have an affected parent.<sup>25</sup>

**Molecular genetics** Approximately 80% of individuals who meet the clinical diagnostic criteria have detectable *PTEN* missense mutations.<sup>26,27</sup> Identification of such mutations is necessary to make the diagnosis of Cowden syndrome. As *PTEN* mutations are also present in closely related clinical entities, Cowden syndrome is now considered within the spectrum of the *PTEN* hamartoma tumor syndrome, which includes Bannayan–Riley–Ruvalcaba syndrome, Proteus syndrome, and Proteus-like syndrome.<sup>27</sup>

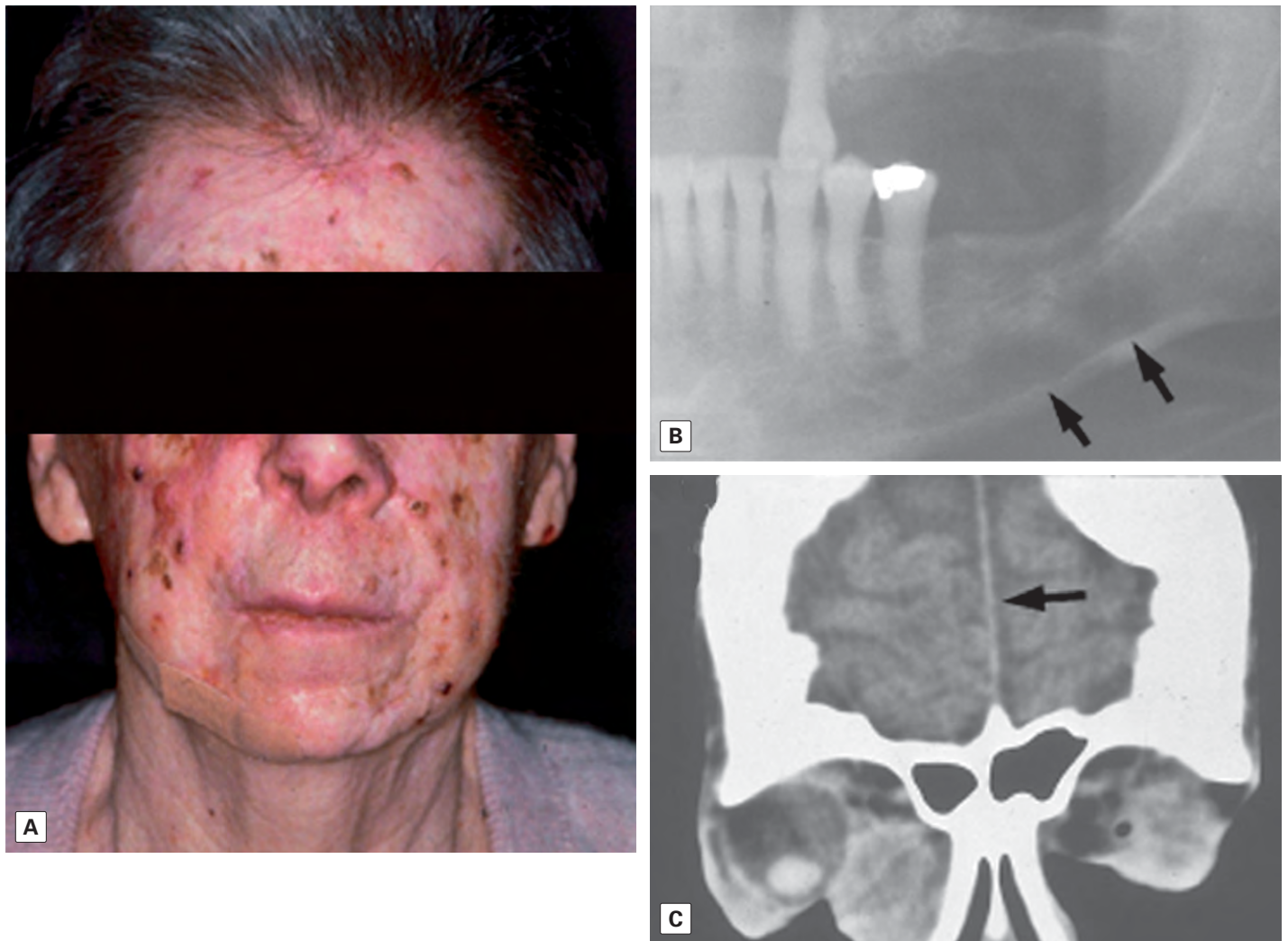
**Ophthalmic features** Eyelid trichilemmomas are the hallmark manifestation of Cowden syndrome (Fig. 22.2). The tumors appear as multiple flesh-colored papular lesions.<sup>28</sup>

**Systemic features** In a review of published cases the age of onset ranged from 4 to 75 years.<sup>29</sup> Mucocutaneous lesions such as trichilemmomas, papillomatous papules, acral keratoses, and plantar keratoses are the most striking manifestations. More significantly, Cowden syndrome is associated with a lifetime increased risk for breast tumors (benign 67%, malignant 25–50%),<sup>30</sup> thyroid tumors (benign 75%, malignant 10%),<sup>31</sup> and uterine tumors (benign fibroids and malignant 10%). Other uncommon hamartomatous manifestations include gastrointestinal polyps and cerebellar dysplastic gangliocytoma (Lhermitte–Duclos disease).<sup>27</sup>

Consensus diagnostic criteria include pathognomonic, major, and minor criteria based on which a clinical diagnosis of Cowden syndrome is made (Table 22.3).<sup>24</sup> However, the identification of a *PTEN* mutation is necessary to establish the diagnosis. The presence of multiple (three or more) trichilemmomas among other mucocutaneous manifestations should raise a strong suspicion of Cowden syndrome.<sup>24</sup>

### CARNEY COMPLEX

Carney complex is characterized by cutaneous pigmentary abnormalities, myxomas, endocrine tumors, and schwannomas.<sup>32</sup> It has

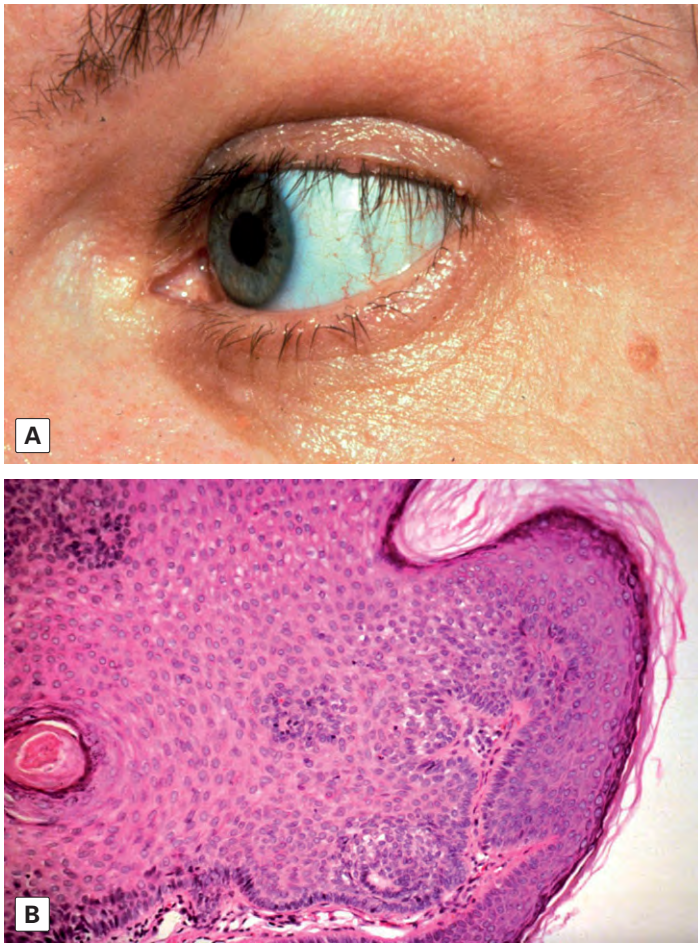


**Fig. 22.1** (A) External photograph showing multiple facial basal cell carcinomas. (B) Orthopantomograph of the right mandible shows odontogenic keratocysts seen as round, well-circumscribed radiolucent areas (arrows). (C) Coronal non-contrast CT scan of the skull showing falx cerebri (arrow) and large diffuse lesion in the medial orbit. (Reproduced with permission from Honavar SG, Shields JA, Shields CL et al. Basal cell carcinoma of the eyelid associated with Gorlin–Goltz syndrome. *Ophthalmology* 2001; 108: 1115–1123.)

**Table 22.2 Clinical diagnostic criteria for nevoid basal cell nevus syndrome**

<b>Major criteria</b>	≥2 major and ≥1 minor criteria	Jaw keratocyst Falx calcification Palmar or plantar pits Basal cell carcinoma >5 in a lifetime or before the age of 30
<b>Minor criteria</b>	≥1 major and ≥3 minor criteria	Affected first-degree relative Macrocephaly Medulloblastoma Lymphomesenteric or pleural cysts Cleft lip/palate Vertebral anomalies Polydactyly Ovarian/cardiac fibromas Ocular anomalies

(Modified from Evans DG, Ladusans EJ, Rimmer S et al. Complications of the nevoid basal cell carcinoma syndrome: results of a population based study. *J Med Genet* 1993;30:460–464.)



**Fig. 22.2** (A) Clinical photograph of flesh-colored papular lesions at the eyelid margin. (B) High-power photomicrograph of trichilemmoma with basal palisading and bland-looking cells with more cytoplasm than basal cell carcinoma cells. (H&E, original magnification  $\times 200$ .) (Reproduced with permission from Bardenstein DS, McLean IW, Nerney J, Boatwright RS. Cowden disease. *Ophthalmology* 1988; 95: 1038–1041.)

also been given descriptive acronyms such as NAME syndrome (nevi, atrial myxomas, ephelides) and LAMB syndrome (lentigines, atrial myxoma, blue nevi). Carney complex should be differentiated from a completely unrelated entity, ‘Carney triad,’ which refers to gastric leiomyosarcoma, pulmonary chondroma, and extra-adrenal paraganglioma.<sup>33</sup>

**Inheritance** Carney complex is inherited as an autosomal dominant trait.<sup>34</sup> About 30% of cases are due to a de novo mutation.

**Molecular genetics** *PRKARIA* (cAMP-dependent protein kinase type I- $\alpha$  regulatory subunit) on 17q23-q24 is one of the genes involved in Carney complex.<sup>35</sup> About 30% of families have been linked to a locus on 2p16.<sup>36</sup>

**Ophthalmic features** Periocular involvement, both by pigmentary changes<sup>37</sup> and with myxomas,<sup>38</sup> is frequent.<sup>39,40</sup> In a study of 63 patients, facial and eyelid lentigines were observed in 70%, conjunctival and caruncular pigmentation in 27%, and eyelid myxomas in 16% (Fig. 22.3).<sup>39</sup>

**Table 22.3** International Cowden Consortium criteria for clinical diagnosis

Pathognomonic	Adult cerebellar dysplastic gangliocytoma	Operational diagnosis
	Trichilemmomas (facial)	$\geq 6$ facial papules, of which $\geq 3$ are trichilemmomas
	Acral keratoses	Facial papules and oral papillomatosis
	Papillomatous lesions	Acral keratoses and oral papillomatosis
	Mucosal lesions	$\geq 6$ palmoplantar keratoses
<b>Major</b>	Breast cancer	$\geq 2$ major criteria
	Thyroid cancer (non-medullary)	One major and $\geq 3$ minor criteria
	Macrocephaly	
	Endometrial carcinoma	
<b>Minor</b>	Other thyroid lesions	$\geq 4$ minor criteria
	Mental retardation	
	Hamartomatous intestinal polyps	
	Fibrocystic disease of the breast	
	Lipomas	
	Fibromas	
	Genitourinary tumors	
	Genitourinary malformation	
	Uterine fibroids	

(Modified from Eng C. Will the real Cowden syndrome please stand up: revised diagnostic criteria. *J Med Genet* 2000;37:828–830.)

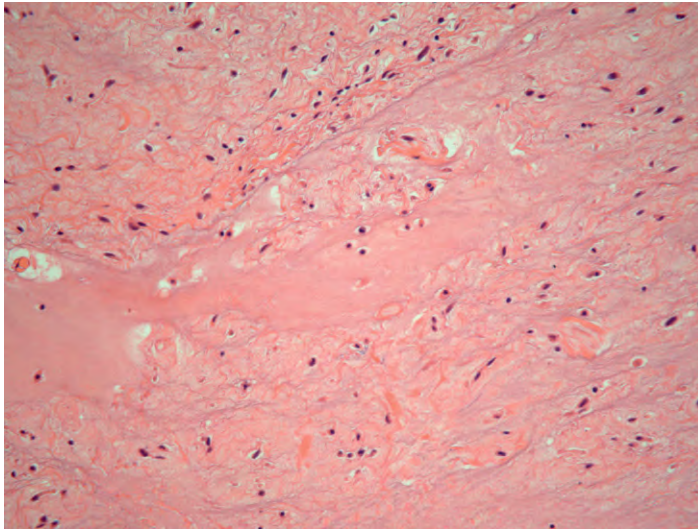
**Systemic features** The median age at diagnosis is 20 years. Cutaneous pigmentary abnormalities are the most common presenting feature. The brown or black lentigines may be present anywhere in the body and become prominent during puberty. Although cardiac myxomas are typical, myxomas may occur in the skin and at other sites. Endocrine tumors and overactivity may manifest as thyroid adenoma (75%), Sertoli cell tumors (33%) in males, Cushing syndrome (25%), and acromegaly (10%).<sup>41</sup> Psammomatous melanotic schwannoma, a rare variant of schwannoma, is also a manifestation of Carney complex.<sup>42</sup> The clinical diagnostic criteria for Carney complex are summarized in Table 22.4.<sup>41</sup>

### MUIR–TORRE SYNDROME

Muir–Torre syndrome is a rare cancer predisposition syndrome characterized by unusual cutaneous tumors and internal malignancy.<sup>43,44</sup> The cutaneous tumors include mainly sebaceous gland neoplasms (sebaceous adenoma and sebaceous carcinoma), keratoacanthoma, and basal cell carcinoma.<sup>43–45</sup>

**Inheritance** Although Muir–Torre syndrome is characterized by autosomal dominant inheritance, sporadic cases are known to occur.





**Fig. 22.3** Eyelid myxoma in a patient with Carney's complex. Hypocellular myxomatous mass composed of ground substance and collagen fibers. (H&E, original magnification  $\times 200$ .) (Courtesy of Ralph C. Eagle Jr, MD.)

Table 22.4. Clinical diagnostic criteria for Carney complex		
<b>Disease manifestation</b>	Any $\geq 2$ present	Multiple lentiginos Blue nevus Cutaneous myxoma Cardiac myxoma Breast myxomatosis Endocrine tumors/overactivity Psammomatous melanotic schwannoma
<b>Supplemental manifestation</b>	$\geq 1$ Disease manifestation and $\geq 1$ Supplemental manifestation	Affected first-degree relative Inactivating mutation of the <i>PRKAR1A</i> gene
(Modified from Stratakis CA, Kirschner LS, Carney JA. Clinical and molecular features of the Carney complex: diagnostic criteria and recommendations for patient evaluation. <i>J Clin Endocrinol Metab</i> 2001;86:4041–4046.)		

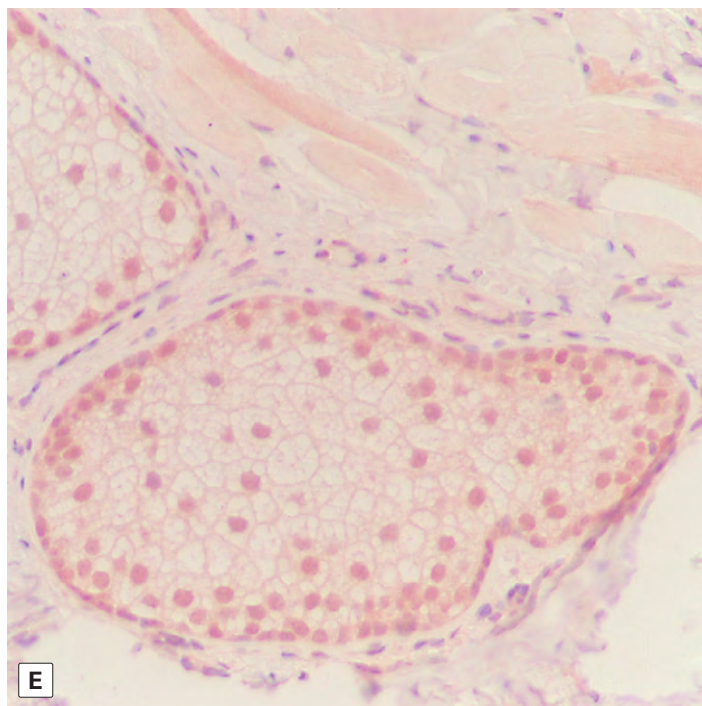
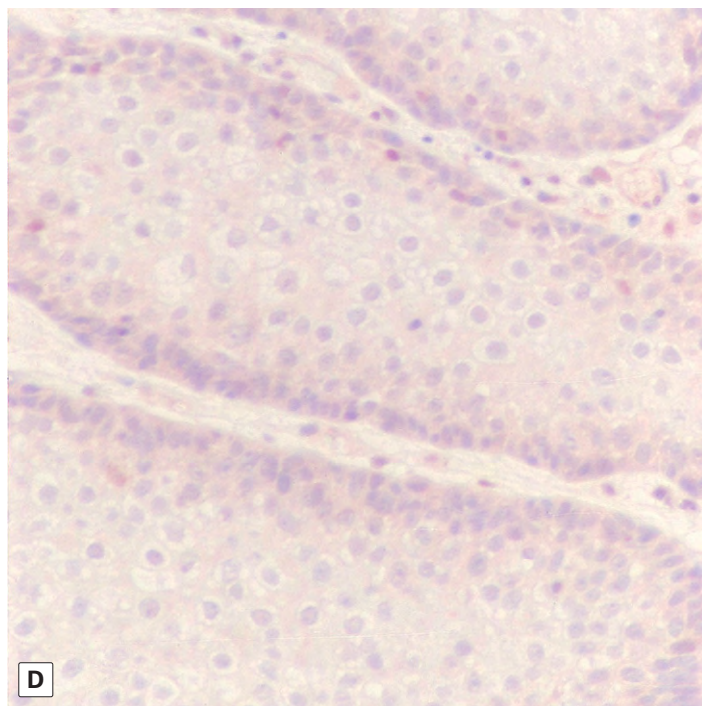
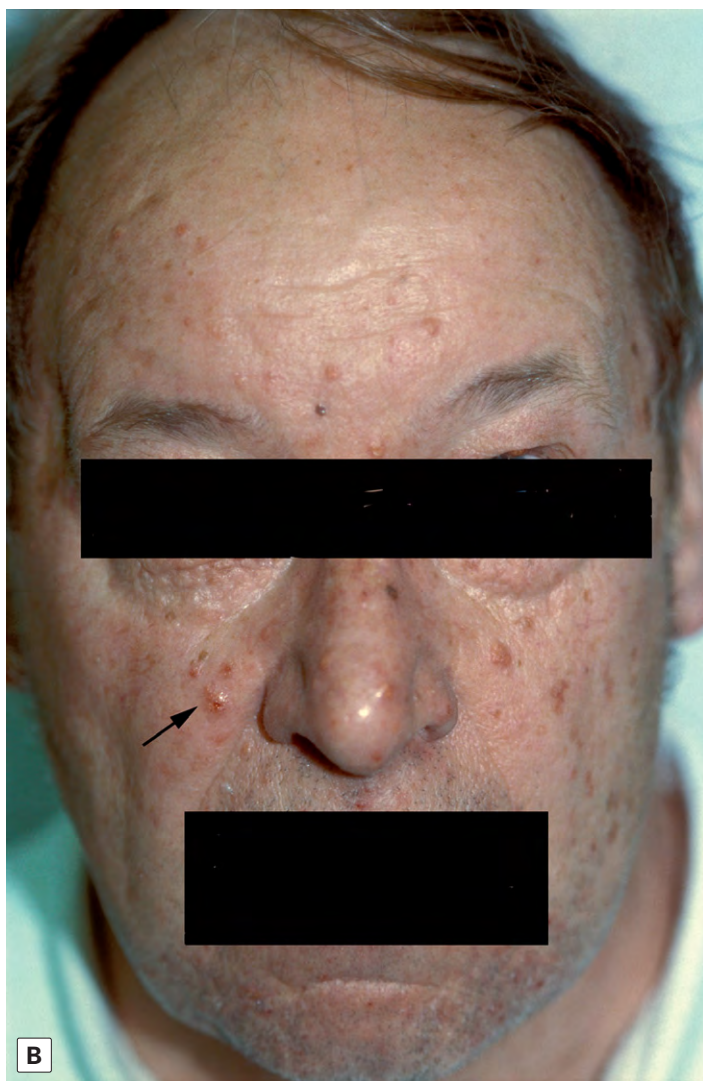
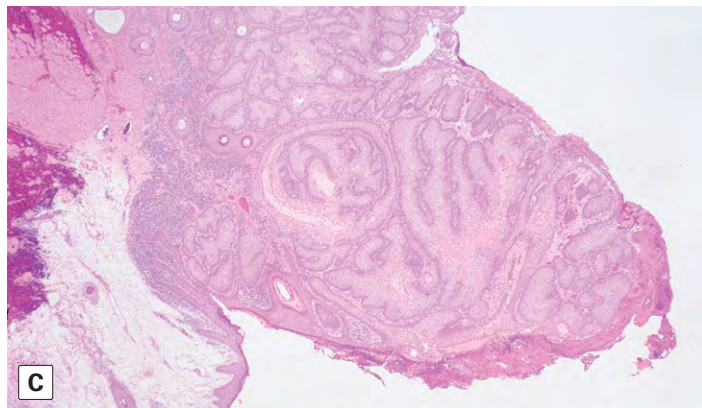
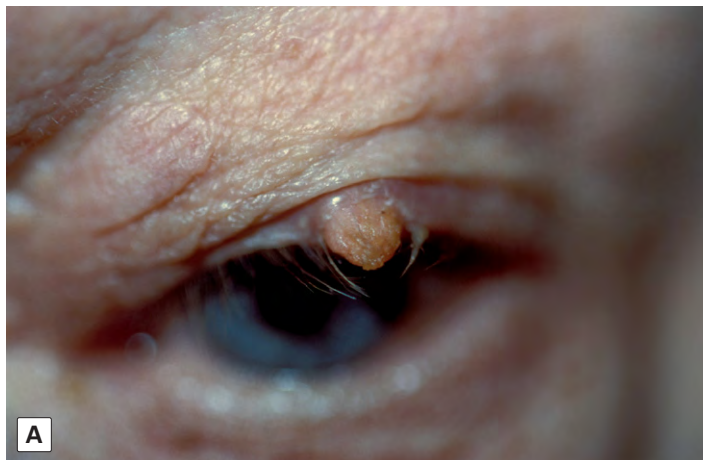
**Molecular genetics** Recent investigations have revealed genomic replication errors, known as microsatellite instabilities, due to mutations in the mismatch repair genes *hMSH2* and *hMLH1*.<sup>46</sup> The absence of *hMLH-1* and *hMSH-2* nuclear expression on immunohistochemical staining is a reliable screening method for the diagnosis of Muir–Torre syndrome.<sup>47</sup>

**Ophthalmic features** Sebaceous gland adenomas are rare. The meibomian glands and Zeis glands of the eyelids are modified sebaceous glands and can also be the site of origin of a sebaceous adenoma.<sup>48</sup> Solitary or multiple sebaceous adenomas appear as yellow nodules, typically on the face, and are considered one of the diagnostic criteria of Muir–Torre syndrome (Fig. 22.4).<sup>45</sup> Cystic changes within a sebaceous adenoma are indicative of Muir–Torre syndrome because sporadic sebaceous adenomas do not exhibit this feature.<sup>49</sup> Although sebaceous gland carcinoma of the eyelid and extraocular sites<sup>50</sup> has been reported in patients with Muir–Torre syndrome, such patients

also had sebaceous adenomas.<sup>51</sup> Meibomian gland carcinoma of the eyelid by itself is not indicative of Muir–Torre syndrome.<sup>52,53</sup> Similarly, keratoacanthoma and basal cell carcinoma without sebaceous adenoma are also not diagnostic of Muir–Torre syndrome.

**Systemic features** In a review of 120 patients with Muir–Torre syndrome, sebaceous tumors were diagnosed prior to the internal malignancy in almost 40%.<sup>45</sup> Almost half of the patients with Muir–Torre syndrome develop colorectal adenocarcinoma and one-quarter develop genitourinary tumors. Adenocarcinoma of the colon in the setting of Muir–Torre syndrome tends to be multifocal and occurs almost a decade earlier than in sporadic cases.<sup>45</sup> In addition, the proximal colon is more often affected, compared with unifocal involvement of the distal colon in sporadic cases.<sup>54</sup> There are significant variations in the phenotypic manifestations of Muir–Torre syndrome, and some individuals may resemble those with the syndrome of hereditary non-polyposis colorectal carcinoma.<sup>55,56</sup>





**Fig. 22.4** Sebaceous adenomas on the face in a patient with Muir–Torre syndrome. Note a yellowish pink warty growth arising from anterior lamella of the left upper eyelid (A). Multiple yellow nodular lesions involving the central forehead, nose, and adjacent cheek area (B). Both eyelid and facial biopsies revealed sebaceous adenomas (C). (Original magnification  $\times 10$ .) (D) Immunohistochemical staining with an antibody to MSH2 protein was absent in the sebaceous adenoma (Magnification  $\times 50$ .) (E) Normal positive nuclear staining of sebaceous lobules adjacent to the sebaceous adenoma serves as an internal control. (Magnification  $\times 50$ .) (Reproduced with permission from Singh AD, Mudhar H, Bhola R et al. Sebaceous adenoma of the eyelid in Muir–Torre syndrome. *Arch Ophthalmol* 2005; 123: 562–565.)

## REFERENCES

- Ponder BAJ. Inherited cancer syndromes. In: Carney D, Sikora K, eds. *Genes and cancer*. New York: John Wiley & Sons, 1990.
- Tallman B, Tan OT, Morelli JG et al. Location of port-wine stains and the likelihood of ophthalmic and/or central nervous system complications. *Pediatrics* 1991; 87: 323–327.
- Blair NP, Trempe CL. Hypertrophy of the retinal pigment epithelium associated with Gardner's syndrome. *Am J Ophthalmol* 1980; 90: 661–667.
- Gardner EJ, Richards RC. Multiple cutaneous and subcutaneous lesions occurring simultaneously with hereditary polyposis and osteomatosis. *Am J Hum Genet* 1953; 5: 139–147.
- Gardner EJ. Follow-up study of a family group exhibiting dominant inheritance for a syndrome including intestinal polyps, osteomas, fibromas and epidermal cysts. *Am J Hum Genet* 1962; 14: 376–390.
- Whitson WE, Orcutt JC, Walkinshaw MD. Orbital osteoma in Gardner's syndrome. *Am J Ophthalmol* 1986; 101: 236–241.
- Lewis RA, Crowder WE, Eierman LA et al. The Gardner syndrome. Significance of ocular features. *Ophthalmology* 1984; 91: 916–925.
- Gorlin RJ, Goltz RW. Multiple nevoid basal-cell epithelioma, jaw cysts and bifid rib. A syndrome. *N Engl J Med* 1960; 262: 908–912.
- Gorlin RJ. Nevoid basal-cell carcinoma syndrome. *Medicine (Baltimore)* 1987; 66: 98–113.
- Evans DG, Ladusans EJ, Rimmer S et al. Complications of the naevoid basal cell carcinoma syndrome: results of a population based study. *J Med Genet* 1993; 30: 460–464.
- Farndon PA, Del Mastro RG, Evans DG, Kilpatrick MW. Location of gene for Gorlin syndrome. *Lancet* 1992; 339: 581–582.
- Hahn H, Wicking C, Zaphiropoulos PG et al. Mutations of the human homolog of *Drosophila* patched in the nevoid basal cell carcinoma syndrome. *Cell* 1996; 85: 841–851.
- Nerad JA, Whitaker DC. Periocular basal cell carcinoma in adults 35 years of age and younger. *Am J Ophthalmol* 1988; 106: 723–729.
- Honavar SG, Shields JA, Shields CL et al. Basal cell carcinoma of the eyelid associated with Gorlin–Goltz syndrome. *Ophthalmology* 2001; 108: 1115–1123.
- Ragge NK, Salt A, Collin JR et al. Gorlin syndrome: the PTCH gene links ocular developmental defects and tumour formation. *Br J Ophthalmol* 2005; 89: 988–991.
- De Potter P, Stanescu D, Caspers-Velu L, Hofmans A. Combined hamartoma of the retina and retinal pigment epithelium in Gorlin syndrome. *Arch Ophthalmol* 2000; 118: 1004–1005.
- Black GC, Mazerolle CJ, Wang Y et al. Abnormalities of the vitreoretinal interface caused by dysregulated Hedgehog signaling during retinal development. *Hum Mol Genet* 2003; 12: 3269–3276.
- Shanley S, Ratcliffe J, Hockey A et al. Nevoid basal cell carcinoma syndrome: review of 118 affected individuals. *Am J Med Genet* 1994; 50: 282–290.
- Springate JE. The nevoid basal cell carcinoma syndrome. *J Pediatr Surg* 1986; 21: 908–910.
- Rahbari H, Mehregan AH. Basal cell epithelioma (carcinoma) in children and teenagers. *Cancer* 1982; 49: 350–353.
- O'Malley S, Weitman D, Olding M, Sekhar L. Multiple neoplasms following craniospinal irradiation for medulloblastoma in a patient with nevoid basal cell carcinoma syndrome. Case report. *J Neurosurg* 1997; 86: 286–288.
- Lloyd KM, 2nd, Dennis M. Cowden's disease. A possible new symptom complex with multiple system involvement. *Ann Intern Med* 1963; 58: 136–142.
- Weary PE, Gorlin RJ, Gentry WC Jr et al. Multiple hamartoma syndrome (Cowden's disease). *Arch Dermatol* 1972; 106: 682–690.
- Eng C. Will the real Cowden syndrome please stand up: revised diagnostic criteria. *J Med Genet* 2000; 37: 828–830.
- Schrager CA, Schneider D, Gruener AC et al. Clinical and pathological features of breast disease in Cowden's syndrome: an underrecognized syndrome with an increased risk of breast cancer. *Hum Pathol* 1998; 29: 47–53.
- Liaw D, Marsh DJ, Li J et al. Germline mutations of the PTEN gene in Cowden disease, an inherited breast and thyroid cancer syndrome. *Nature Genet* 1997; 16: 64–67.
- Zhou XP, Marsh DJ, Morrison CD et al. Germline inactivation of PTEN and dysregulation of the phosphoinositide-3-kinase/Akt pathway cause human Lhermitte–Duclos disease in adults. *Am J Hum Genet* 2003; 73: 1191–1198.
- Bardenstein DS, McLean IW, Nerney J, Boatwright RS. Cowden's disease. *Ophthalmology* 1988; 95: 1038–1041.
- Starink TM. Cowden's disease: analysis of fourteen new cases. *J Am Acad Dermatol* 1984; 11: 1127–1141.
- Brownstein MH, Wolf M, Bikowski JB. Cowden's disease: a cutaneous marker of breast cancer. *Cancer* 1978; 41: 2393–2398.
- Harach HR, Soubeyran I, Brown A et al. Thyroid pathologic findings in patients with Cowden disease. *Ann Diagn Pathol* 1999; 3: 331–340.
- Carney JA, Gordon H, Carpenter PC et al. The complex of myxomas, spotty pigmentation, and endocrine overactivity. *Medicine (Baltimore)* 1985; 64: 270–283.
- Carney JA. The triad of gastric epithelioid leiomyosarcoma, pulmonary chondroma, and functioning extra-adrenal paraganglioma: a five-year review. *Medicine (Baltimore)* 1983; 62: 159–169.
- Carney JA, Hruska LS, Beauchamp GD, Gordon H. Dominant inheritance of the complex of myxomas, spotty pigmentation, and endocrine overactivity. *Mayo Clin Proc* 1986; 61: 165–172.
- Kirschner LS, Carney JA, Pack SD et al. Mutations of the gene encoding the protein kinase A type I-alpha regulatory subunit in patients with the Carney complex. *Nature Genet* 2000; 26: 89–92.
- Stratakis CA, Carney JA, Lin JP et al. Carney complex, a familial multiple neoplasia and lentiginosis syndrome. Analysis of 11 kindreds and linkage to the short arm of chromosome 2. *J Clin Invest* 1996; 97: 699–705.
- Cohen C, Turner ML, Stratakis CA. Pigmented lesions of the conjunctiva in Carney's complex. *J Am Acad Dermatol* 2000; 42: 145.
- Grossniklaus HE, McLean IW, Gillespie JJ. Bilateral eyelid myxomas in Carney's complex. *Br J Ophthalmol* 1991; 75: 251–252.
- Kennedy RH, Waller RR, Carney JA. Ocular pigmented spots and eyelid myxomas. *Am J Ophthalmol* 1987; 104: 533–538.
- Kennedy RH, Flanagan JC, Eagle RC Jr, Carney JA. The Carney complex with ocular signs suggestive of cardiac myxoma. *Am J Ophthalmol* 1991; 111: 699–702.
- Stratakis CA, Kirschner LS, Carney JA. Clinical and molecular features of the Carney complex: diagnostic criteria and recommendations for patient evaluation. *J Clin Endocrinol Metab* 2001; 86: 4041–4046.
- Carney JA. Psammomatous melanotic schwannoma. A distinctive, heritable tumor with special associations, including cardiac myxoma and the Cushing syndrome. *Am J Surg Pathol* 1990; 14: 206–222.
- Muir EG, Bell AJY, Barlow KA. Multiple primary carcinomata of the colon, duodenum, and larynx associated with keratoacanthomata of the face. *Br J Surg* 1967; 54: 191–195.
- Torre D. Multiple sebaceous tumors. *Arch Dermatol* 1968; 98: 549–551.
- Cohen PR, Kohn SR, Kurzrock R. Association of sebaceous gland tumors and internal malignancy: the Muir–Torre syndrome. *Am J Med* 1991; 90: 606–613.
- Honchel R, Halling KC, Schaid DJ et al. Microsatellite instability in Muir–Torre syndrome. *Cancer Res* 1994; 54: 1159–1163.
- Mathiak M, Rutten A, Mangold E et al. Loss of DNA mismatch repair proteins in skin tumors from patients with Muir–Torre syndrome and MSH2 or MLH1 germline mutations: establishment of immunohistochemical analysis as a screening test. *Am J Surg Pathol* 2002; 26: 338–343.
- Singh AD, Mudhar HS, Bhola R et al. Sebaceous adenoma of the eyelid in Muir–Torre syndrome. *Arch Ophthalmol* 2005; 123: 562–565.
- Burgdorf WH, Pitha J, Fahmy A. Muir–Torre syndrome. Histologic spectrum of sebaceous proliferations. *Am J Dermatopathol* 1986; 8: 202–208.
- Propeck PA, Warner T, Scanlan KA. Sebaceous carcinoma of the breast in a patient with Muir–Torre syndrome. *AJR Am J Roentgenol* 2000; 174: 541–542.
- Mencia-Gutierrez E, Gutierrez-Diaz E, Santos-Briz A, Madero-Garcia S. Sebaceous gland carcinoma of the eyelid and palpebral conjunctiva in a patient with Muir–Torre syndrome. *Br J Ophthalmol* 2000; 84: 1325–1326.
- Jakobiec FA, Zimmerman LE, La Piana F et al. Unusual eyelid tumors with sebaceous differentiation in the Muir–Torre syndrome. Rapid clinical regrowth and frank squamous transformation after biopsy. *Ophthalmology* 1988; 95: 1543–1548.
- Meier-Gibbons F, Messmer E. Sebaceous gland adenoma of the palpebral conjunctiva in a patient with Muir–Torre syndrome: a case report. *Graefes Arch Clin Exp Ophthalmol* 1994; 232: 734–736.
- Rustgi AK. Hereditary gastrointestinal polyposis and nonpolyposis syndromes. *N Engl J Med* 1994; 331: 1694–1702.
- Hall NR, Williams MA, Murday VA et al. Muir–Torre syndrome: a variant of the cancer family syndrome. *J Med Genet* 1994; 31: 627–631.
- Kruse R, Rutten A, Lamberti C et al. Muir–Torre phenotype has a frequency of DNA mismatch-repair-gene mutations similar to that in hereditary nonpolyposis colorectal cancer families defined by the Amsterdam criteria. *Am J Hum Genet* 1998; 63: 63–70.



# Examination techniques, classification, and differential diagnosis of conjunctival and corneal tumors

Jacob Pe'er

## INTRODUCTION

The conjunctiva is a translucent vascularized mucous membrane.<sup>1</sup> It may be divided into three portions: the bulbar conjunctiva, including the corneconjunctival limbus, which covers the sclera in the anterior part of the eyeball; the superior, inferior and lateral conjunctival fornices; and the palpebral conjunctiva, including the mucocutaneous transitional zone in the lid margin, which covers the back surface of the upper and lower eyelids. The conjunctiva is movable over the globe and in the fornix, where it is loosely adherent to the sclera, but fixed to the posterior eyelid surface where it is markedly adherent to the tarsal plate.

## HISTOLOGY

The conjunctiva is composed of the epithelium and the subepithelial stroma – the substantia propria.

**Epithelium** near the limbus, where it is continuous with the corneal epithelium, and in the mucocutaneous epithelial zone, where it is continuous with the eyelid skin epidermis, is non-keratinized stratified squamous epithelium. The epithelial cells are stratified columnar in the fornix, and tend to be cuboidal on the bulbar and tarsal conjunctiva. Goblet cells appear to be present in the middle and superficial layers of the epithelium and are most numerous in the lower forniceal portion. Melanocytes are scattered in the basal layer of the epithelium.

**Stroma** is composed of fibrovascular connective tissue that is thicker in the fornix and thinner over the globe and the back surface of the eyelids. It contains collagenous and elastic tissue; vessels including arteries, veins and lymphatics; nerves; and accessory lacrimal glands of Krause. Like other mucous membranes, the conjunctiva contains associated lymphoid tissue. Numerous lymphocytes, plasma cells, mast cells, and neutrophils can be normally present in the conjunctival stroma. Lymphocytes may be aggregated into nodules, but they are not true lymphoid follicles.

## Specialized regions

**Plica semilunaris** is a vertical fold of conjunctiva lying lateral to the caruncle. There are eight to 10 layers of epithelial cells containing many goblet cells. The loose, highly vascular stroma may have some non-striated muscle fibers supplied by sympathetic nerves and may contain fatty tissue.

**Caruncle** is a fleshy prominence located in the medial canthus that contains both conjunctival and cutaneous structures. It is covered by non-keratinized stratified squamous epithelium with many goblet cells, and contains hair, sebaceous and sweat glands, and accessory lacrimal glands. Its blood and nerve supply is abundant. Tumors of the caruncle can be of both mucosal and skin origin.

## EXAMINATION TECHNIQUES

The conjunctiva and cornea are readily visible tissues; thus, tumors and related lesions that occur on the ocular surface are usually recognized and diagnosed at a relatively early stage. External ocular examination and detailed slit lamp examination are vital to diagnose conjunctival and corneal tumors correctly. Because many of these tumors have characteristic clinical features, an accurate diagnosis can often be made by the experienced ophthalmologist using clinical examination alone.

**External examination** The entire eyeball and eyelids should be examined for possible involvement. It is important, whenever malignancy is suspected, to palpate the preauricular and submandibular areas for enlarged lymph nodes, to rule out regional metastases.

**Slit lamp examination** The extent of conjunctival and corneal involvement should be accurately documented by slit lamp examination prior to treatment, as it may be difficult to evaluate conjunctival lesions under the diffuse lighting of an operating microscope. Fluorescein or rose Bengal stains can be used to delineate abnormal epithelium and the tumor's margins, mainly when the lesions are diffuse.

It is very important to evaluate not only the easily examined bulbar conjunctiva, but also the upper and lower fornices and palpebral conjunctiva, in order to look for possible extension of conjunctival tumors. The abnormal conjunctiva should be gently pushed with a cotton-tipped applicator to evaluate whether it moves freely, indicating sparing of the sclera. Conjunctival lesions that adhere to the sclera may indicate scarring or malignancy.

## Ancillary studies

**Drawings/photography** The lesion should be drawn (or preferably photographed) externally or via the slit lamp in order to document the tumors accurately, particularly their margins.

**High-frequency ultrasonography** When the tumor is thick or adheres to its surroundings, high-frequency ultrasonography can be



used to determine its depth and its extension into the sclera, cornea, or rarely into intraocular structures.

**Histopathologic evaluation** The definite diagnosis of conjunctival and corneal tumors is by histopathology. However, benign-looking asymptomatic tumors are often managed by periodic observation, and only when there is evidence of growth or malignant changes is a biopsy taken.

**Excisional biopsy** If a small tumor does require a biopsy, it is preferable to remove the lesion completely.

**Incisional biopsy** In large conjunctival lesions, where complete removal of the tumor may severely compromise the ocular surface, or when it is impossible to perform total excision, it is appropriate to perform an incisional biopsy, sampling the tumor by wedge or punch biopsy. Incisional biopsy is also appropriate when complete excision is not the treatment of choice, and in tumors that are preferably treated by radiotherapy, chemotherapy, and local means such as cryotherapy and topical chemotherapy.

**Exfoliative cytology** has been used for the evaluation of conjunctival and corneal tumors. However, it is important to recognize that this method provides information only on the superficial layers of the lesion, and does not show the invasiveness of the tumor, which may be a very important parameter in deciding the appropriate management.

### DIAGNOSTIC CONSIDERATIONS

In the differential diagnosis of conjunctival tumors, details such as history (slow, rapid, or recurrent growth), the patient's demographic features (race, age and gender), the existence of systemic diseases (metabolic disease or systemic malignancies), and specific tumor features provide diagnostic clues.

The characteristics of diagnostic significance include the color of the lesion – pigmented or non-pigmented, red, pink, blue, white, or yellow; its consistency – hard, soft, rubbery, or gelatinous; its composition – solid or cystic; size; number of tumors – solitary or multiple; surface – smooth, irregular, granular, papillary, ulcerated or umbilicated, or covered by keratin; shape – flat or raised, pedunculated or papillary; thickness – thin or thick; location – bulbar, palpebral, forniceal conjunctiva or caruncle; the layer involved – epithelial or stromal; mobility – movement with conjunctiva or fixation to globe. The existence of diseases or malignancies in the surrounding anatomical structures – the eyeball, eyelids, orbital structures, and the lacrimal drainage system – is also of diagnostic significance.

### CLASSIFICATION OF CONJUNCTIVAL AND CORNEAL TUMORS

Conjunctival and corneal tumors, like tumors elsewhere, may be classified according to two major considerations: the tissue or cell of origin, and whether the tumor is benign or malignant. Owing to their special histological structures, features, and location, subtypes of tumors can appear or behave differently in spite of having a common cell of origin.

Most conjunctival tumors are epithelial or melanocytic in origin (Table 23.1). Most of the other tumors are of various elements of the conjunctival stroma and include vascular, fibrous, neural, histiocytic,

**Table 23.1 Major types of conjunctival tumor**

Type	Subtypes	
Epidermal Stromal	Non-melanocytic	Melanocytic
	Vascular	Fibrous tissue
	Neural	Histiocytic
	Myxoid	Myogenic
	Lipomatous	Lymphoproliferative
Congenital	Hamartoma	Choristoma
Caruncular		
Metastatic		
Secondary		
Simulating lesions		

myogenic, myxoid, lipomatous, and lymphoproliferative tumors. Three unique groups of conjunctival tumors are the hamartomas and choristomas, the caruncular tumors, and metastatic and secondary tumors.

The classification of the conjunctival and corneal tumors that appears in this section is based primarily on the second edition of the volume entitled "Histological typing of tumours of the eye and its adnexa" in the World Health Organization (WHO) International Histological Classification of Tumours series.<sup>2</sup> As this does not include all conjunctival tumors, the list has been completed by using other major series of conjunctival and corneal tumors.<sup>3-5</sup> The following list includes both common and rare tumors in order to familiarize the reader with the terminology.

### DIFFERENTIAL DIAGNOSIS

The majority of conjunctival tumors are benign. Malignant tumors of the conjunctiva are relatively rare.

**Epithelial tumors** are usually classified into non-melanocytic and melanocytic, based on the clinical presence or absence of brown-black pigmentation and the histological presence of melanocytes (Table 23.2). Rarely, non-melanocytic tumors can also appear pigmented owing to the secondary accumulation of melanocytes, especially in the dark races.

**Non-melanocytic epithelial tumors** are superficial in location and generally have an irregular, granular, or papillary surface with leukoplakia (covered by keratin). Sometimes they may be gelatinous or even fleshy in appearance.

**Melanocytic epithelial tumors** include nevi, melanoses, and melanoma. Whereas melanoses are superficial, nevi and melanoma involve the stroma. In contrast to melanoma, which is usually adherent to the globe, melanoses and nevi are movable with the conjunctiva.

**Stromal tumors** including secondary tumors in the stroma, have a smooth surface, being under the conjunctival surface (Table 23.3). Most vascular tumors are red, pink, or sometimes blue. Fibrous tumors are white, but may be pink. Neural, histiocytic, and lipomatous tumors are yellow, and lymphoid tumors and leukemic infiltrates are pink, similar to smoked salmon, hence the term 'salmon patch.'

**Table 23.2 Classification of epidermal tumors of the conjunctiva**

Type		Subtypes
Non-melanocytic	Benign	Squamous papilloma
		Keratotic plaque
		Keratoacanthoma
		Reactive hyperplasia (pseudoepitheliomatous hyperplasia)
		Inverted follicular keratosis
	Premalignant and malignant	Hereditary intraepithelial dyskeratosis
		Oncocytoma
		Dacryoadenoma
		Actinic (solar) keratosis
		Conjunctival intraepithelial neoplasia (CIN)
Melanocytic	Benign	Squamous cell carcinoma
		Xeroderma pigmentosum
		Junctional nevus
		Compound nevus
		Spitz nevus
	Premalignant and malignant	Blue nevus
		PAM without atypia
		Congenital melanosis
		Racial melanosis
		PAM without atypia
		Melanoma arising from nevi
		Melanoma arising in PAM
		Melanoma arising de novo

PAM, primary acquired melanosis.

**Table 23.3 Classification of stromal tumors of the conjunctiva**

Category		Subtypes
Vascular	Capillary hemangioma	Cavernous hemangioma
	Varix	Racemose malformation
	Hemangiopericytoma	Lymphangiectasia
	Kaposi's sarcoma	Lymphangioma
	Malignant hemangioendothelioma	
Fibrous	Nodular fasciitis	Fibroma
	Benign fibrous histiocytoma	Malignant fibrous histiocytoma
Neural	Neurofibroma (localized)	Neurofibroma (diffuse)
	Schwannoma (neurilemmoma)	Granular cell tumor
Histiocytic	Xanthoma	Juvenile xanthogranuloma
	Reticulohistiocytoma	
Myxoid	Myxoma	
Myogenic	Rhabdomyosarcoma	
Lipomatous	Lipoma	Herniated orbital fat
	Liposarcoma	
Lymphoproliferative	Benign reactive lymphoid hyperplasia	Lymphoma
	Leukemic infiltrates	

**Table 23.4 Congenital tumors of the conjunctiva (hamartomas and choristomas)**

Dermoid
Dermolipoma
Osseous choristoma
Lacrimal gland choristoma
Complex choristoma

**Congenital tumors** Congenital epibulbar tumors diagnosed in infancy and childhood are usually hamartomatous or choristomatous (Table 23.4).

**Caruncular tumors** Lesions of the caruncle present a special challenge as they include both conjunctival and cutaneous tumors.

**Metastatic and secondary tumors** In the case of metastatic tumors, there is usually a history of primary malignancy elsewhere.

With secondary involvement of the conjunctiva by tumors in the surrounding structures, the primary tumor is usually well known, except for many cases of pagetoid spread of sebaceous gland carcinoma of the eyelid, in which the initial presentation may be in the conjunctiva.

**Simulating lesions** It is interesting to note that the WHO histological classification of conjunctival tumors includes lesions that simulate tumors, such as pinguecula and pterygium. These common conjunctival lesions, although not neoplastic in origin, can be confused with tumors when they are covered by keratin plaque or have a gelatinous appearance. Among conditions that may simulate pigmented conjunctival tumors, drug and metallic deposits, mascara deposits, foreign body, postinflammatory melanosis, and systemic conditions with flat pigmentary patches, such as in Addison's disease, should be considered.<sup>6</sup> Inflammatory and infectious lesions such as lepromatous and sarcoidal nodules and, more commonly, allergic and granulomatous nodules, should also be included in the differential diagnosis of conjunctival tumors.

## REFERENCES

1. Pepperl JE, Ghuman T, Gill KS et al. Conjunctiva. In: Tasman W, Jaeger EA. Duane's foundations of clinical ophthalmology, Vol. 1. Ocular anatomy, embryology and teratology. Philadelphia: Lippincott Williams & Wilkins, 2004; 1–30.
2. Campbell RJ, Sobin LH. Tumors of the conjunctiva and caruncle. In: Histological typing of tumours of the eye and its adnexa, 2nd edition. World Health Organization International Histological Classification of Tumours. Berlin: Springer Verlag, 1998; 9–15.
3. Shields CL, Shields JA. Tumors of the conjunctiva and cornea. *Surv Ophthalmol* 2004; 49: 3–24.
4. Grossniklaus HE, Green WR, Luckenbach M, Chan CC. Conjunctival lesions in adults. A clinical and histopathologic review. *Cornea* 1987; 6: 78–116.
5. Elsas FJ, Green WR. Epibulbar tumors in childhood. *Am J Ophthalmol* 1975; 79:1001–1007.
6. Folberg R, Jakobiec FA, Bernardino VB, Iwamoto T. Benign conjunctival melanocytic lesions. Clinicopathologic features. *Ophthalmology* 1989; 96: 436–501.



# Benign conjunctival tumors

Jacob Pe'er

## INTRODUCTION

Benign tumors of the conjunctiva are much more common than malignant tumors of the conjunctiva. In this chapter, benign tumors of epithelial and melanocytic origin, which comprise the majority of conjunctival tumors, are described. Benign conjunctival tumors of stromal origin are described in Chapter 28.

## BENIGN TUMORS OF THE EPITHELIUM

Abnormal cellular proliferation and differentiation that is confined to the conjunctival epithelium may cause thickening, papillary or nodular focal elevation of the conjunctiva, and sometimes plaque-like opacification (leukoplakia). Such lesions rarely progress to malignancy.

**Squamous cell papilloma** Conjunctival squamous papilloma is a benign and common epithelial tumor that can be seen at almost any age, although it more commonly occurs in young adults.<sup>1-4</sup> More males than females develop conjunctival papilloma.<sup>4</sup> Conjunctival squamous papillomas are often located in the inferior fornix or bulbar conjunctiva, but may appear in any part of the conjunctiva, including the palpebral conjunctiva, lid margin, caruncle, and plica semilunaris. According to one study, most papillomas are located medially and inferiorly, a fact that is explained by the direction of the tear flow.<sup>4</sup>

### Clinical features

**CHILDHOOD PAPILLOMA** In children the papillomas have been documented to be associated with human papillomavirus (mostly types 6, 11, and 16) infection of the conjunctiva. The papilloma appears as a sessile or pedunculated pink/red fleshy frond of tissue or finger-like projections with irregular surfaces that sometimes resemble a cauliflower (Fig. 24.1A). They are often asymptomatic, with no associated inflammatory reaction. However, large and more pedunculated lesions are usually symptomatic and may cause a foreign body sensation, mucous secretion, hemorrhagic tears, incomplete eyelid closure, and poor cosmetic appearance. They are usually solitary, but can be bilateral, multiple, and may become confluent.

**ADULTHOOD PAPILLOMA** In adults the conjunctival squamous papilloma is usually a single unilateral lesion, commonly arising close to the limbal area or bulbar conjunctiva. It is usually flat with a broad base, may be large and cover a large area of the conjunctiva, and may cover the cornea and interfere with vision. Sometimes it may be difficult to differentiate clinically from squamous cell carcinoma.

**Histopathologic features** Histologically, the squamous papilloma of childhood is composed of epithelial projections covered by non-keratinized acanthotic stratified squamous epithelium, which may have goblet cells, and has a fibrovascular core in which acute and chronic inflammatory cells are often found (Fig. 24.1B). The basement membrane is always intact. Human papillomavirus has been demonstrated in these papillomas by various immunohistochemical and molecular techniques.<sup>5,6</sup>

In adults the squamous papilloma has usually a broader base, its acanthotic epithelium may show varying degrees of epithelial pleomorphism, and even dysplasia can occur, albeit generally mild. Although the lesion is usually non-keratinized, moderate keratinization may be present. The basement membrane is typically intact.

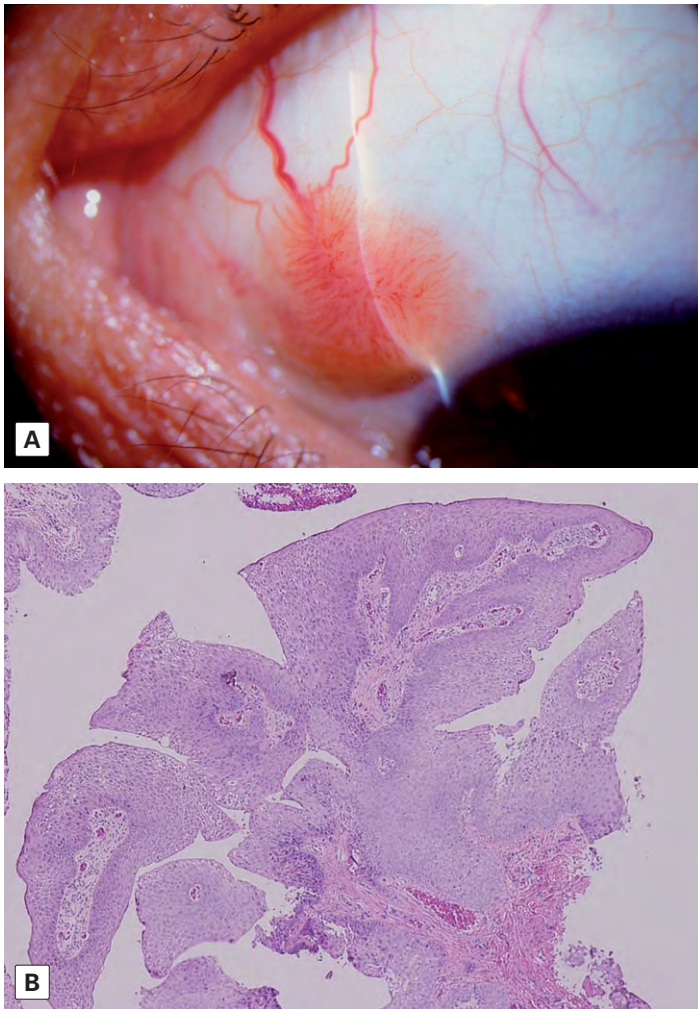
**Treatment** Small papillomas in children can be managed by observation alone, as there usually is a slow spontaneous resolution. However, larger papillomas should be treated by complete surgical excision, preferably by the 'no-touch technique' in order to avoid spreading the papilloma-related virus.<sup>3</sup> Cryotherapy is often used in conjunction with surgical excision, either to the conjunctiva around the excised lesion, or to the lesion itself, which is then excised in a frozen state. Sometimes cryotherapy may be performed without excision, letting the lesion slough off the conjunctival surface later.

Conjunctival papillomas tend to recur often, usually when multiple lesions are caused by papillomavirus. Such lesions may be treated by adjuvant interferon- $\alpha_{2B}$  locally or systemically,<sup>7,8</sup> or by topical mitomycin C.<sup>9</sup> Others have used carbon dioxide laser vaporization,<sup>10</sup> and there is one report of effective treatment of recurrent conjunctival papillomas using oral cimetidine.<sup>11</sup>

**Inverted papilloma (inverted follicular keratosis)** These lesions derive their name from their propensity to invaginate inward into the underlying conjunctival substantia propria, instead of growing in an exophytic manner outwards, as do the other conjunctival papillomas. Some lesions may show a mixed inverted-exophytic papilloma.<sup>12</sup>

**Clinical features** These are rare lesions that appear as solid or cystic solitary nodules in the conjunctiva. They have been reported to appear in the limbal area, plica semilunaris, and tarsal conjunctiva.

**Histopathologic features** Lobules of proliferating epithelium without keratinization or inflammation invaginate the underlying



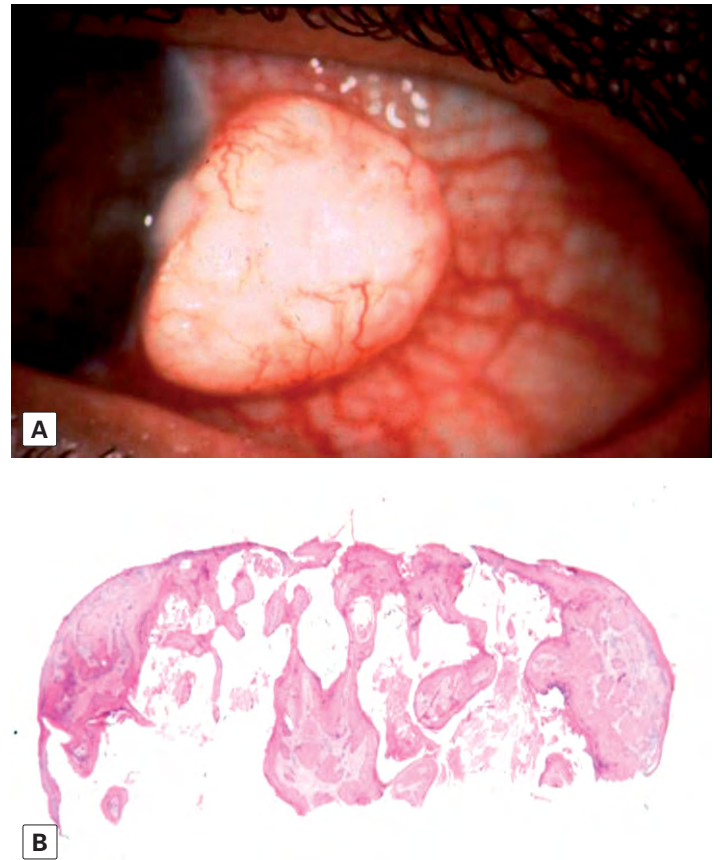
**Fig. 24.1** A solitary sessile squamous papilloma of the bulbar conjunctiva. Clinical appearance (A). Histopathology shows papillomatous fronds of acanthotic non-keratinized squamous epithelium with central fibrovascular cores (B). (Hematoxylin and eosin, original magnification  $\times 4$ .)

connective tissue. Mucus-producing goblet cells are scattered throughout the lesions, and mucoid material, when it exists, is found in the wall of the cyst.

Unlike inverted papillomas in other sites, such as the nose, paranasal sinuses and lacrimal sac, conjunctival inverted papilloma does not exhibit locally aggressive behavior, does not involve extensive segments of the conjunctival epithelium, and does not display diffuse spread or multicentricity. Therefore, it is suggested that a clear distinction be made from inverted squamous papillomas of the nasal cavity and sinuses.<sup>13</sup> However, complete removal of these lesions is still recommended.

**Reactive epithelial hyperplasia (pseudoeplitheliomatous hyperplasia, pseudocarcinomatous hyperplasia)** This conjunctival lesion is secondary to irritation by concurrent or pre-existing stromal inflammation.<sup>1-3</sup>

**Clinical features** It appears as an elevated leukoplakic pink lesion in the limbal area.



**Fig. 24.2** A rapidly growing keratoacanthoma of the bulbar conjunctiva at the limbus. Clinical appearance (A). Histopathology of the lesion demonstrates squamous epithelium with invasive acanthosis and hyperkeratosis (B). (Hematoxylin and eosin, original magnification  $\times 2$ .) (Reproduced with permission from Munro S, Brownstein S, Liddy B. Conjunctival keratoacanthoma. *Am J Ophthalmol* 1993; 116: 654-655.)

**Histopathologic features** Acanthosis, hyperkeratosis or parakeratosis, and subepithelial inflammation are observed. Mitotic figures may be present, but cytologic atypia is generally lacking. Because of the possible clinical and histological difficulty of differentiating such lesions from conjunctival squamous cell carcinoma, it should be completely excised and additional cryotherapy may be considered.

**Keratoacanthoma** This is a variant of conjunctival reactive epithelial hyperplasia that does not show spontaneous regression.<sup>1,3,14</sup>

**Clinical features** Keratoacanthoma appears as a benign, solitary, gelatinous or leukoplakic rapidly growing nodule on the bulbar conjunctiva surrounded by dilated blood vessels.<sup>1,3,14</sup> In some cases an umbilicated center is observed (Fig. 24.2A).

**Histopathologic features** The lesion shows marked invasive acanthotic epithelium with keratin-filled pseudocysts, hyperkeratosis, and parakeratosis (Fig. 24.2B). Usually there is minimal cytologic atypia. In cases with a marked degree of atypia it may be difficult to distinguish the lesion from well-differentiated squamous cell carcinoma.

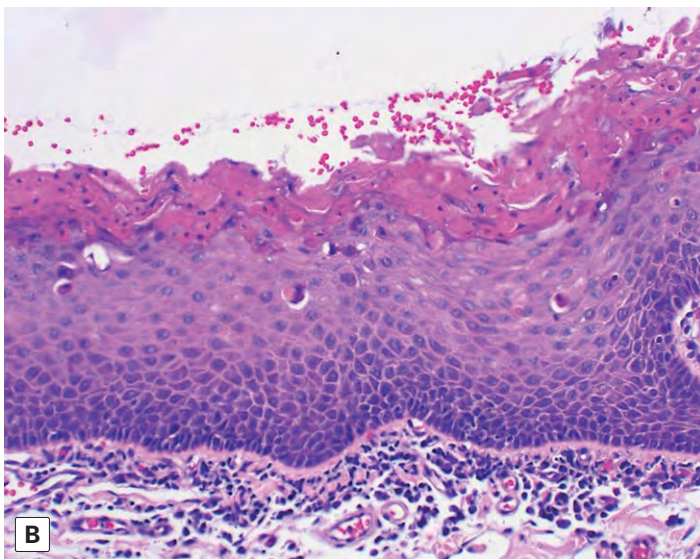
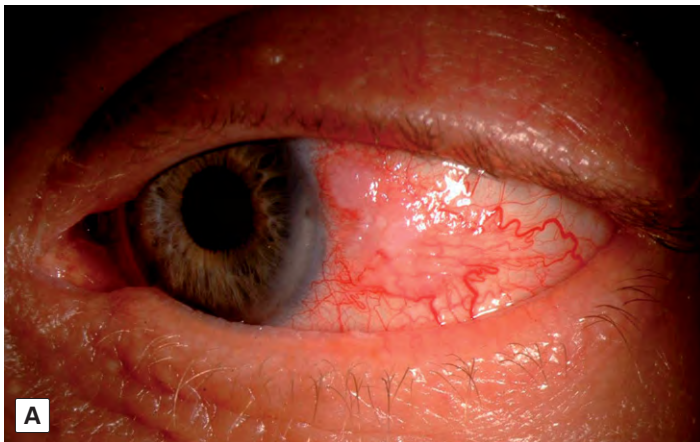
**Treatment** Conjunctival keratoacanthoma should be treated by complete excision, and additional cryotherapy should be considered.



**Hereditary benign intraepithelial dyskeratosis (HBID)**

HBID is an autosomal dominant disorder with a high degree of penetrance that occurs in descendants of an inbred isolate of European, African-American, and Native American (Haliwa Indian) origin in northeastern North Carolina. HBID has been subsequently detected in other parts of the United States. Using genetic linkage analysis, the HBID gene was localized to chromosome 4 (4q35).<sup>15</sup>

**Clinical features** HBID is characterized by bilateral elevated fleshy plaques on the nasal or temporal perilimbal bulbar conjunctiva, with dilated conjunctival vessels around it, causing the eye to appear red<sup>1,3</sup> (Fig. 24.3A). In mild cases the patient is asymptomatic, but in severe cases most of the bulbar conjunctiva and cornea are involved, causing corneal opacification and vascularization leading to loss of vision. Patients may complain of foreign body sensation, photophobia, and tearing, especially in the spring. Similar lesions may occur in the buccal mucosa.



**Fig. 24.3** Hereditary benign intraepithelial dyskeratosis. The typical clinical appearance is of a white lesion of the temporal conjunctiva with dilated conjunctival vessels around it (A). Histopathology showing acanthosis, hyperkeratosis, dyskeratosis, and marked chronic inflammation in the stroma beneath the intact basement membrane (B). (Hematoxylin and eosin, original magnification  $\times 20$ .) (Courtesy of Gordon Klintworth, MD.)

**Histopathologic features** The lesions are characterized by acanthosis, prominent dyskeratosis in the surface and deep epithelium, and severe chronic inflammation in the stroma (Fig. 24.3B). The basement membrane is intact. The lesions do not have malignant potential.

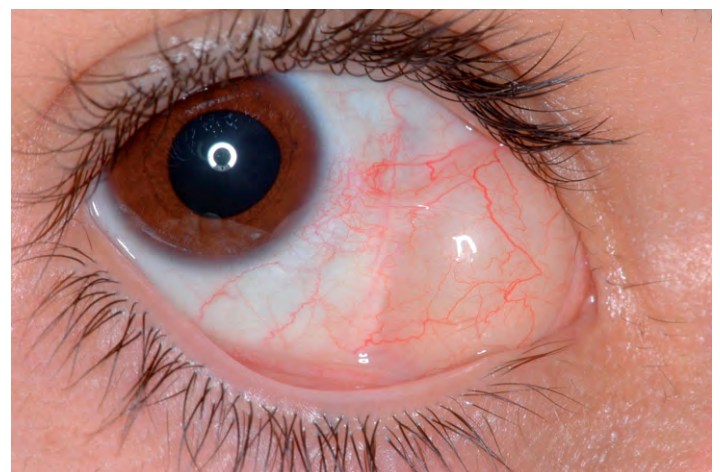
**Treatment** HBID does not usually require aggressive treatment. Mild cases can be treated by ocular lubricants and, if needed, by topical corticosteroids. Larger lesions can be treated by local excision. Mucous membrane grafting can be used when excision is wide. Recurrence is common.

**Dacryoadenoma** is a rare conjunctival tumor that occurs in children and young adults. It appears as a translucent pink lesion in the bulbar, forniceal, or palpebral conjunctiva.<sup>3</sup> It is uncertain whether the lesion is congenital or acquired. Histologically it is a benign epithelioid cell proliferation forming glandular lobules, similar to the lacrimal gland. In one reported case scattered myoepithelial cells were associated with acinar-type epithelium, and goblet cells were intermixed.<sup>16</sup> The lesions are treated by simple excision.

**Oncocytoma** also known as oxyphilic cell adenoma, is a rather common lesion of the lacrimal gland (see Chapter 95). It often arises in the caruncle or the adjacent plica semilunaris and canthal conjunctiva as a slowly growing benign yellow-tan or reddish lesion in older individuals, mostly women.<sup>2</sup> Histologically, large cells with eosinophilic granular cytoplasm are arranged in nests, cords, or sheets, and may form glandular or ductal structures. Ultrastructurally the cytoplasm is laden with mitochondria. The lesion is treated by simple excision. Rarely, the tumor may undergo carcinomatous transformation.

**Epithelial cysts** Conjunctival cysts are common and may be congenital or acquired. The acquired type are more common and are mostly epithelial inclusion cysts that can occur spontaneously or following surgical or non-surgical trauma<sup>1,3</sup> (Fig. 24.4). Other common cysts are ductal cysts, usually of accessory lacrimal gland origin.

**Clinical features** The conjunctival cyst is a smooth translucent lesion that contains clear fluid, although the fluid may be turbid or



**Fig. 24.4** A large conjunctival epithelial inclusion cyst in the nasal bulbar conjunctiva that occurred after strabismus surgery.

contain epithelial debris in the lumen that is layered like pseudohypopyon. In dark-skinned patients the cyst can be pigmented.

**Histopathologic features** The epithelial inclusion cyst is lined by conjunctival epithelium. The lumen can be clear, or it can contain mucinous material, epithelial debris, and occasionally keratin. Ductal cysts are lined by two layers of epithelium and may contain PAS-positive material.

**Treatment** The cyst can be stable and asymptomatic, or can enlarge and become symptomatic, necessitating excision. In most cases the cyst eventually undergoes spontaneous resolution.

**Keratotic plaque** This is a leukoplakic lesion that may develop in the limbal or bulbar conjunctiva, usually in the interpalpebral region.<sup>1,2</sup> Histologically there is a focal thickening of keratin and the epithelial layer, characterized mainly by acanthosis, hyperkeratosis, or parakeratosis. No dyskeratosis is seen. These lesions have little or no potential for carcinomatous change.

**Actinic keratosis** of the conjunctiva is a rarely diagnosed focal leukoplakic lesion occurring at the intrapalpebral limbus, usually located over a chronically inflamed pinguecula or pterygium.<sup>2,3,17</sup> It is classified among precancerous lesions, and it is also referred to as conjunctival dysplasia, actinic keratosis variety. Histologically the epithelium exhibits acanthosis, hyperkeratosis, and occasionally parakeratosis. The degree of dysplasia is minimal. Owing to suspicion of a squamous cell carcinoma, these lesions are usually excised.

### BENIGN MELANOCYTIC TUMORS

Conjunctival nevi are the most common conjunctival lesions. The various types of nevi are discussed here, together with other benign melanocytic lesions of the conjunctiva, the episclera, and the sclera, such as complexion-associated melanosis, ocular melanocytosis, and primary acquired melanosis (PAM) without atypia. There are many other pigmented conjunctival lesions that are not melanocytic in origin and should always be included in the differential diagnosis of melanocytic conjunctival lesions (see Chapter 26).

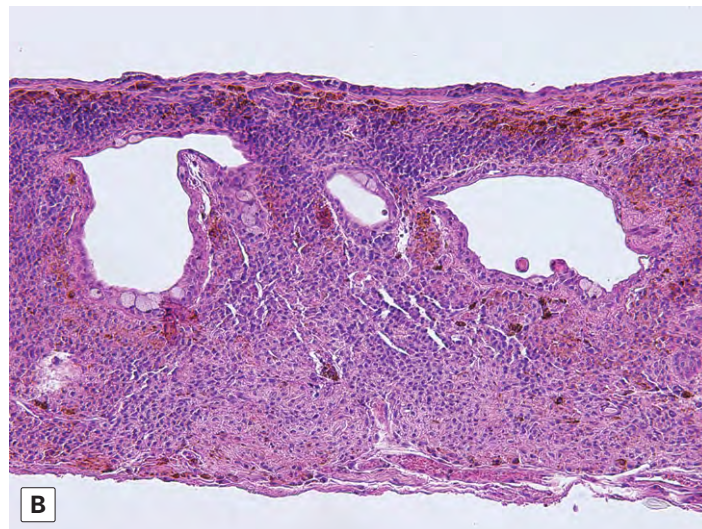
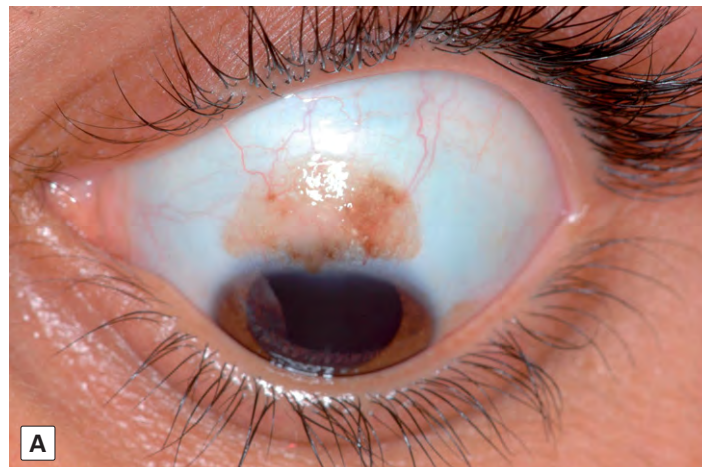
**Conjunctival nevus** The circumscribed nevus is the most common melanocytic conjunctival tumor.<sup>18,19</sup> It appears in all races, but is more common in Caucasians. Many ophthalmic oncologists and pathologists will consider nevi that appear at birth or within the first 6 months of life as congenital, and those that appear more than 6 months after birth to be acquired. Most acquired conjunctival nevi will appear during the first two decades of life. Melanocytic conjunctival lesions that appear later in life should be suspicious for PAM or melanoma (Box 24.1).

**Clinical features** Conjunctival nevi are typically located in the interpalpebral bulbar conjunctiva, commonly near the limbus, and rarely involve the cornea.<sup>19</sup> The finding of melanocytic tumors in locations other than the bulbar conjunctiva, plica semilunaris, and caruncle is rare, and should raise suspicion for PAM or malignant melanoma. Clinically, conjunctival nevus is a discrete, variably pigmented, slightly elevated sessile lesion that in most cases contains cystic structures that can be seen by the naked eye or on slit-lamp biomicroscopy (Fig. 24.5A). Conjunctival nevi may vary in size, from tiny lesions to ones that occupy large parts of the bulbar conjunctiva. Nevi may become darker or lighter, but will not usually change in size and color after

adolescence. Changes in adulthood should raise suspicion for malignant transformation. The overall risk of malignant transformation is about 1%.<sup>19</sup> The presence of cystic structures can help in differentiating nevi from other possible amelanotic conjunctival lesions. In childhood and adolescence, conjunctival nevi may become more pink and congested, owing to inflammatory infiltration. These inflamed nevi will be discussed separately.

#### BOX 24.1 Clinical Features of Conjunctival Nevus that are Suspicious for Melanoma

- Onset in adulthood
- Recent growth of the nevus
- Recent color change of the nevus
- Location other than bulbar conjunctiva, plica semilunaris, and caruncle
- Prominent feeder vessels
- Recurrence of excised lesion



**Fig. 24.5** A typical partially pigmented compound conjunctival nevus with cystic elements, in an atypical location in the upper bulbar conjunctiva at the limbus (A). Histopathology of a compound nevus of the conjunctiva with cystic structures lined by conjunctival epithelium (B). (Hematoxylin and eosin, original magnification  $\times 10$ .)



**Histopathologic features** Conjunctival nevi range from junctional through compound to subepithelial in type, and reflect stages in the evolution of the nevus. Most excised nevi that are examined in the ophthalmic pathology laboratory are compound. Two distinct types of nevus cell were described in the conjunctiva: balloon cells and spindle cells, and they usually appear in otherwise typical conjunctival nevus.

**JUNCTIONAL NEVUS** is found only early in life and shows nests of nevus cells along the interface of the epithelium and the substantia propria. The cells contain abundant cytoplasm.

**COMPOUND NEVUS** In the compound nevus, nests of nevus cells are found in the substantia propria in addition to the junctional area, and have less cytoplasm, which may reflect maturation. Solid nests of epithelium and epithelial cysts are very common within a compound nevus, and may confuse the pathologist who is not familiar with conjunctival nevi (Fig. 24.5B).

**SUBEPITHELIAL NEVUS** Over time, the connection of the nevus to the overlying epithelium may be lost. When the nevus is confined entirely beneath the epithelium, it is designated a subepithelial nevus.<sup>18</sup>

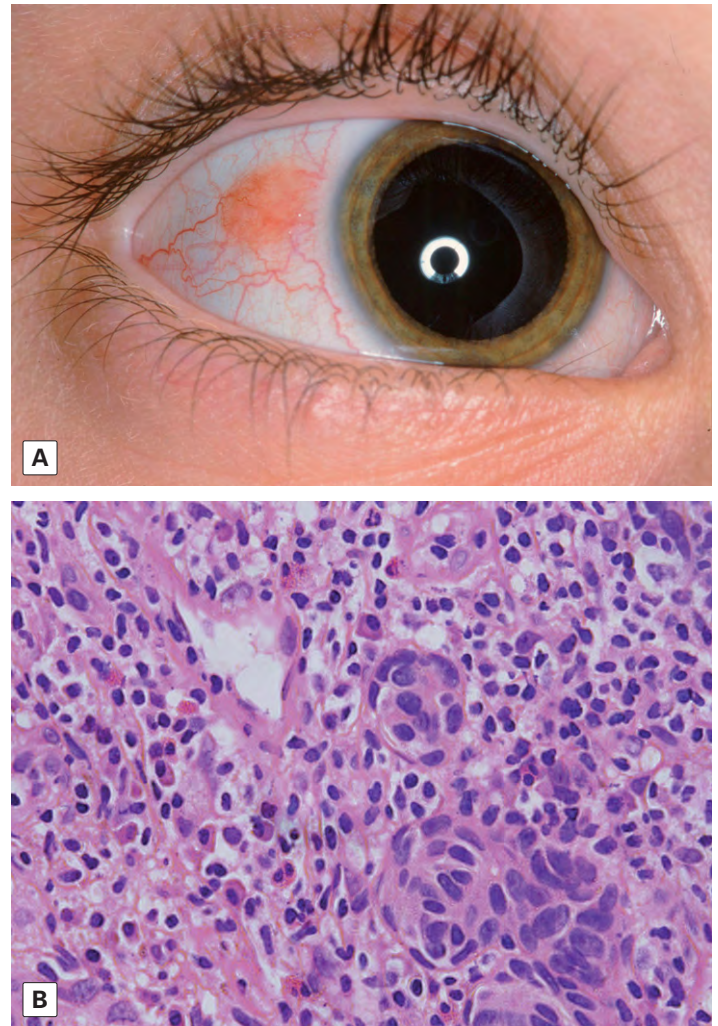
#### **Clinicopathologic variants**

**SPITZ NEVUS** A more distinctive type of conjunctival nevus is the Spitz nevus, which has been reported only in childhood and adolescence.<sup>20</sup> Clinically, these lesions are rapidly growing non-pigmented lesions that should be differentiated from pyogenic granuloma and, more importantly, from melanoma, which is extremely uncommon in children. Histologically, conjunctival Spitz nevi feature fascicles of spindle nevus cells that are usually oriented perpendicular to the epithelial surface and are uniformly and symmetrically arranged, unlike spindle cells in typical conjunctival nevi, which are oriented parallel to the surface. Mitotic figures reflect the rapid clinical growth and do not indicate malignancy.<sup>18</sup>

**BLUE NEVUS** Blue and cellular blue nevi are rare conjunctival lesions that arise from neural crest cells, are situated in the deep conjunctival substantia propria, and do not reach the surface epithelium. Clinically, they appear brown or black.<sup>18,21</sup> Histologically, the blue nevus is composed of spindle-shaped cells with uniform melanin pigmentation. Elements of a blue nevus may be present in a typical conjunctival nevus. Such lesions have been termed 'mixed nevus.' In cellular blue nevi the fascicles of spindle-shaped cells are admixed with fibrillar collagen. There has been only one report of conjunctival melanoma arising from a blue nevus.<sup>22</sup>

**INFLAMED JUVENILE CONJUNCTIVAL NEVUS (IJCN)** is a benign, juxtalimbal nevus that appears in children and adolescents, can grow rapidly, shows lesional redness, often shows cystic structures, and can be surrounded by vascular congestion.<sup>23</sup> Therefore, these lesions are frequently approached with undue concern by patients and clinicians, usually suspecting malignancy. More than half of these nevi are amelanotic, and changes in the pigmentation of amelanotic lesions have been documented (Fig. 24.6A).

Histologically, these rapidly growing lesions do not differ from simple compound conjunctival nevi in their benign histopathologic features.<sup>23</sup> Cystic and solid epithelial elements are found in most of these nevi. In all lesions there is significant lymphocytic infiltration in



**Fig. 24.6** Amelanotic inflamed juvenile conjunctival nevus in the temporal conjunctiva with cystic elements and dilated vessels around it (A). Histopathology showing nevus nests with marked chronic inflammation around it and a remarkable number of eosinophils (B). (Hematoxylin and eosin, original magnification  $\times 40$ .)

and around the nevus, and significant infiltration of eosinophils is found in areas in most of these nevi (Fig. 24.6B). Periods of rapid growth of inflamed nevi represent inflammatory infiltration and cystic enlargement, rather than malignant proliferation.

IJCNs are almost always associated with symptomatic allergic conjunctivitis or asymptomatic conjunctival papillary reaction. Increased expression of nerve growth factor (NGF), eosinophils, and mast cells in IJCN and modulation of eosinophil properties by lesional fibroblasts partly through NGF suggest a possible association between IJCN and allergic inflammation.<sup>24</sup>

Typical cases of IJCN can be differentiated on clinical grounds from conjunctival melanoma. IJCN should also be differentiated from the 'salmon patch' lesions of conjunctival lymphoma, which is exceedingly rare in childhood. The patient's young age and the cystic nature of typical lesions are indicators of a benign lesion.

**Treatment** Most conjunctival nevi do not require excision, as most patients say that the lesion has been present and stable for many years, often since childhood or adolescence. The best management is usually

periodic observation with photographic comparison; if growth is documented, local excision should be considered.<sup>19</sup> In general, incisional biopsy is contraindicated in lesions that can be resected in their entirety. Some of the indications for excisional biopsy of conjunctival nevi include recent growth; recent color change; cosmetic concerns; recurrence of an excised lesion; and clinical suspicion of malignant melanoma. At the time of excision the entire mass is removed, and if it is adherent to the globe a thin lamella of underlying sclera is also removed. Cryotherapy is often applied to the conjunctival margins. These measures are employed in order to prevent recurrence, as the majority of cases that come to excision are due to suspicion of malignant transformation.

In cases with typical IJCN observation alone may suffice, although excisional biopsy is recommended in atypical lesions, or whenever the clinician cannot make a definite diagnosis of IJCN. Similarly, lesions causing functional problems, such as dellen, interference with contact lens wear, or a significant cosmetic blemish, should be excised.

### Complexion-associated conjunctival pigmentation (racial melanosis)

Complexion-associated conjunctival pigmentation, also known as racial pigmentation, is a common bilateral condition of flat conjunctival pigmentation found in individuals with dark skin color.<sup>3,18</sup> However, the distribution of pigmentation may be asymmetric.

**Clinical features** The pigmentation is commonly present at the limbus, often for 360°, and may involve the adjacent cornea and limbal conjunctiva. Uncommonly, pigmentation may involve the fornix, and rarely the palpebral conjunctiva.

**Histopathologic features** The basal layer of the conjunctival epithelium appears hyperpigmented owing to the presence of benign melanocytes in this layer.

**Treatment** As malignant transformation is extremely rare in racial melanosis, apart from observation there is no need for treatment.

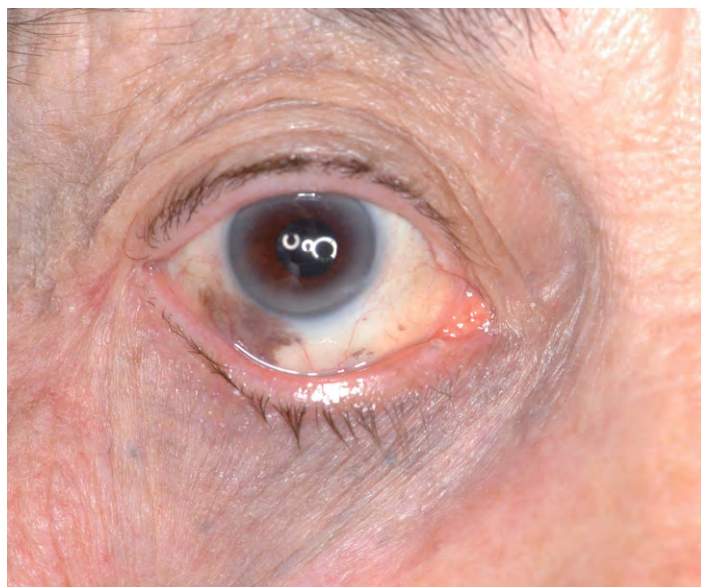
### Congenital melanosis oculi (congenital ocular melanocytosis)

Congenital melanosis oculi is a pigmentary condition of the sclera and uvea that usually involves the periocular skin, orbit, meninges, and soft palate.<sup>3,18</sup> In this condition the conjunctiva is usually not pigmented; it is included here because it is often considered in the clinical differential diagnosis of conjunctival pigmented lesion. Owing to its diffuse pattern, congenital melanosis oculi is often confused with conjunctival primary acquired melanosis. When the periocular skin is involved the condition is called 'oculodermal melanocytosis' or 'nevus of Ota' (Fig. 24.7).

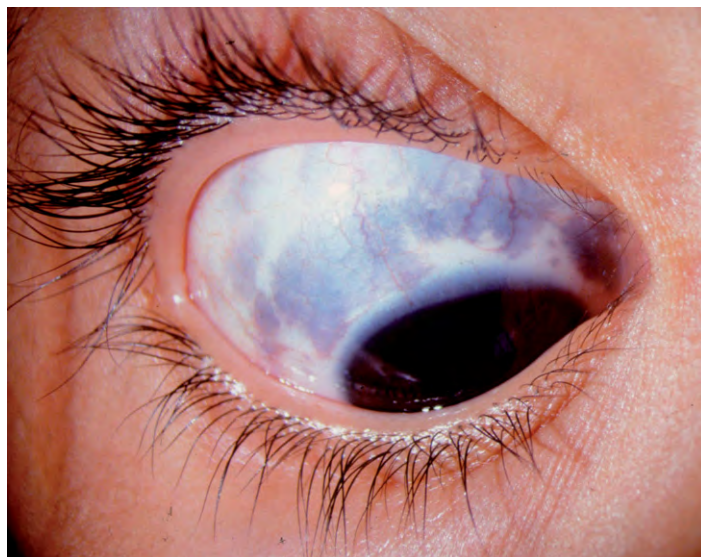
**Clinical features** The surface of the eye appears slate gray or blue, and not brown or black as seen in conjunctival melanocytic lesions, owing to the Tyndall effect of the pigmented melanin that is seen through the layers of the episclera and sclera (Fig. 24.8).

**Histopathologic features** Because the pigmentation is due to dendritic melanocytes that are present within the episcleral and scleral tissue, it does not move with the bulbar conjunctiva.

**Treatment** Conjunctival melanoma has not been described in melanosis oculi. However, the risk of uveal melanoma is 1:400. Therefore,



**Fig. 24.7** Oculodermal melanocytosis (nevus of Ota) with gray pigmentation of the periocular skin and melanosis of the sclera.



**Fig. 24.8** Congenital melanosis oculi with gray-blue pigmentation of the sclera.

affected patients should be followed regularly for the development of uveal melanoma.<sup>25</sup>

### Primary acquired melanosis (PAM) without atypia

Primary acquired melanosis appears as a flat, variably brown, and usually monocular lesion. Histologically, PAM lesions are flat, intra-epithelial melanocytic lesions and are divided into two major groups: PAM without atypia and PAM with atypia. Both types are discussed in Chapter 26.



## TUMORS OF THE CARUNCLE

The caruncle contains both conjunctival and cutaneous elements. Consequently, any tumor of the conjunctiva and skin may occur in the caruncle. In three large series of caruncular lesions<sup>26–28</sup> the vast major-

ity were benign, led by squamous papillomas and nevi. Only about 5% of these tumors were malignant. The various benign and malignant tumors that can appear in the caruncle are discussed in the relevant chapters.

## REFERENCES

- Spencer WH. Conjunctiva. In: Spencer WH. Ophthalmic pathology, an atlas and textbook, 4th edn. Philadelphia: WB Saunders, 1996; 106–125.
- Campbell RJ, Sobin LH. Tumors of the conjunctiva and caruncle. In: Histological typing of tumours of the eye and its adnexa, 2nd edn. World Health Organization Histological Classification of Tumours. Berlin: Springer Verlag, 1998; 9–15.
- Shields CL, Shields JA. Tumors of the conjunctiva and cornea. *Surv Ophthalmol* 2004; 49: 3–24.
- Sjo N, Heegaard S, Prause JU. Conjunctival papilloma. A histopathologically based retrospective study. *Acta Ophthalmol Scand* 2000; 78: 663–666.
- Lass JH, Jenson AB, Papale JJ et al. Papillomavirus in human conjunctival papillomas. *Am J Ophthalmol* 1983; 95: 364–368.
- Sjo NC, Heegaard S, Prause JU et al. Human papillomavirus in conjunctival papilloma. *Br J Ophthalmol* 2001; 85: 785–787.
- Schechter BA, Rand WJ, Velazquez GE et al. Treatment of conjunctival papillomata with topical interferon Alfa-2b. *Am J Ophthalmol* 2002; 134: 268–270.
- Lass JH, Foster CS, Grove AS et al. Interferon-alpha therapy of recurrent conjunctival papillomas. *Am J Ophthalmol* 1987; 103: 294–301.
- Hawkins AS, Yu J, Hamming NA et al. Treatment of recurrent conjunctival papillomatosis with mitomycin C. *Am J Ophthalmol* 1999; 128: 638–640.
- Bosniak SL, Novick NL, Sachs ME. Treatment of recurrent squamous papillomata of the conjunctiva by carbon dioxide laser vaporization. *Ophthalmology* 1986; 93: 1078–1082.
- Shields CL, Lally MR, Singh AD et al. Oral cimetidine (Tagamet) for recalcitrant, diffuse conjunctival papillomatosis. *Am J Ophthalmol* 1999; 128: 362–364.
- Streeten BW, Carrillo R, Jamison R et al. Inverted papilloma of the conjunctiva. *Am J Ophthalmol* 1979; 88: 1062–1066.
- Jakobiec FA, Harrison W, Aronian D. Inverted mucoepidermoid papillomas of the epibulbar conjunctiva. *Ophthalmology* 1987; 94: 283–287.
- Munro S, Brownstein S, Liddy B. Conjunctival keratoacanthoma. *Am J Ophthalmol* 1993; 116: 654–655.
- Allingham RR, Seo B, Rampersaud E et al. A duplication in chromosome 4q35 is associated with hereditary benign intraepithelial dyskeratosis. *Am J Hum Genet* 2001; 68: 491–494.
- Jakobiec FA, Perry HD, Harrison W et al. Dacryoadenoma. A unique tumor of the conjunctival epithelium. *Ophthalmology* 1989; 96: 1014–1020.
- Mauriello JA Jr, Napolitano J, McLean I. Actinic keratosis and dysplasia of the conjunctiva: a clinicopathological study of 45 cases. *Can J Ophthalmol* 1995; 30: 312–316.
- Folberg R. Melanocytic lesions of the conjunctiva. In: Spencer WH. Ophthalmic pathology, an atlas and textbook, 4th edn. Philadelphia: WB Saunders, 1996; 125–155.
- Shields CL, Fasiuddin AF, Mashayekhi A et al. Conjunctival nevi: clinical features and natural course in 410 consecutive patients. *Arch Ophthalmol* 2004; 122: 167–175.
- Kantelip B, Boccari R, Nares JM et al. A case of conjunctival Spitz nevus: review of literature and comparison with cutaneous locations. *Ann Ophthalmol* 1989; 21: 176–179.
- Blicker JA, Rootman J, White VA. Cellular blue nevus of the conjunctiva. *Ophthalmology* 1992; 99: 1714–1717.
- Demirci H, Shields CL, Shields JA et al. Malignant melanoma arising from unusual conjunctival blue nevus. *Arch Ophthalmol* 2000; 118: 1581–1584.
- Zamir E, Mechoulam H, Micera A et al. Inflamed juvenile conjunctival naevus: clinicopathological characterisation. *Br J Ophthalmol* 2002; 86: 28–30.
- Levi-Schaffer F, Micera A, Zamir E et al. Nerve growth factor and eosinophils in inflamed juvenile conjunctival nevus. *Invest Ophthalmol Vis Sci* 2002; 43: 1850–1856.
- Singh AD, De Potter P, Fijal BA et al. Lifetime prevalence of uveal melanoma in white patients with ocular (dermal) melanocytosis. *Ophthalmology* 1998; 105: 195–198.
- Luthra CL, Doxanos MT, Green WR. Lesions of the caruncle: a clinicohistopathologic study. *Surv Ophthalmol* 1978; 23: 183–195.
- Shields CL, Shields JA, White D, Augsburger JJ. Types and frequency of lesions of the caruncle. *Am J Ophthalmol* 1986; 103: 771–778.
- Santos A, Gomez-Leal A. Lesions of the lacrimal caruncle. Clinicopathologic features. *Ophthalmology* 1994; 101: 943–949.

# Ocular surface squamous neoplasia

Jacob Pe'er and Joseph Frucht-Pery

## INTRODUCTION

Ocular surface squamous neoplasia (OSSN) is the currently preferred term for precancerous and cancerous epithelial lesions of the conjunctiva and cornea.<sup>1,2</sup> It includes dysplasia and carcinoma in situ, and squamous cell carcinoma (SCC). The most common previously used names for the intraepithelial lesions are 'intraepithelial epithelioma,' 'Bowen's disease' of the conjunctiva or 'Bowenoid epithelioma.' Because of differences in the histology of conjunctiva and skin, the term Bowen's disease should be reserved only for cutaneous lesions. Other terms for the intraepithelial ocular surface neoplasia are conjunctival intraepithelial neoplasia<sup>3</sup> or corneal intraepithelial neoplasia (CIN), or both (CCIN).

## EPIDEMIOLOGICAL ASPECTS

OSSN is found in all races. It is uncommon in northern countries, but is common in countries that are closer to the equator and in those where exposure to sunlight is greater. In an NIH study the incidence of OSSN was 0.3 per million in the United States.<sup>4</sup> In a study that was performed in Uganda, the incidence of OSSN was 1.3 per million, and in Australia the incidence is reported to be as high as 19 per million population.<sup>1</sup> OSSN occurs predominantly in adults, although a few cases in children have been reported. In most series OSSN is more common in males,<sup>4</sup> a fact that is explained by their greater exposure to sunlight. According to some studies, patients with CIN are younger by 5–9 years than those with invasive SCC, a fact that implies the precancerous nature of the CIN.<sup>5</sup>

## ETIOLOGY AND ASSOCIATED DISEASES

There are several possible factors and mechanisms that may explain or be associated with the development of OSSN. The most important are exposure to solar ultraviolet radiation, human papillomavirus, AIDS, and the stem cell theory.

**Sunlight exposure** Exposure to solar ultraviolet radiation has been identified in many studies as a major etiologic factor in the development of OSSN.<sup>3,5</sup> The rarity of OSSN in Europe and North America and its higher incidence in sub-Saharan African countries and in Australia,<sup>1</sup> where people are more exposed to sunlight, suggests an important role of solar ultraviolet light in the development of OSSN. Lee et al.<sup>1</sup> observed a relationship between lifetime exposure to solar ultraviolet light and the risk of developing OSSN. Newton et al.<sup>6</sup> noted that the incidence of SCC of the eye increases by 29% per unit increase

in ambient solar ultraviolet light exposure, corresponding to a 49% increase in incidence with each 10° decline in latitude.

A history of actinic skin lesions, such as solar keratoses and SCC, is also strongly associated with the development of OSSN. It is well known that ultraviolet B rays cause damage to DNA in human epithelial cells. Failure of DNA repair, as occurs in xeroderma pigmentosum, leads to somatic mutation and the development of cancerous cells of OSSN.

**Human papillomavirus** In recent years human papillomavirus (HPV), mainly type 16, has been demonstrated in the tissue of OSSN.<sup>7</sup> DNA of HPV was found in fresh tissue of OSSN, using amplification with PCR and sequencing of the DNA, in ocular surface swabs of patients with OSSN, and in studies of formalin-fixed paraffin-embedded tissue using immunostaining. However, HPV was also detected in uninvolved eyes with apparently healthy conjunctiva, and in cases of persistence of infection many years after successful eradication of OSSN lesions. In one study where antibodies against HPV were examined in patients with OSSN, there was no evidence of a statistically significant association between anti-HPV antibody status and the risk of conjunctival neoplasia. These facts lead to the assumption that HPV alone may be incapable of causing OSSN, and that other factors in conjunction with HPV are involved in its causation.

**Acquired immunodeficiency syndrome (AIDS)** The incidence of OSSN has increased significantly since the eruption of the AIDS epidemic, especially in sub-Saharan African countries.<sup>8</sup> In studies from Rwanda, Uganda, Congo Kinshasa and Zimbabwe, HIV infection was strongly associated with an apparent increase in the incidence of OSSN. In these countries the OSSN occurred at a younger age than previously reported, and tended to be aggressive. Although HIV infection seems to be an obvious risk factor by itself, its interaction with ultraviolet light and HPV, which is also prevalent in African countries, can accelerate the development of OSSN.

**Stem cell theory** Because of the tendency for OSSN to arise in the limbal area, where the stem cells for the corneal and conjunctival epithelium are located, Lee et al.<sup>1</sup> proposed the limbal transition zone/stem cell theory for the development of OSSN. Based on Tseng's concept of the long-living and high proliferation rate of stem cells in the limbal area, they postulated that alterations in this anatomical site, influenced by other factors, cause abnormal maturation of the conjunctival and corneal epithelium, resulting in the formation of OSSN.



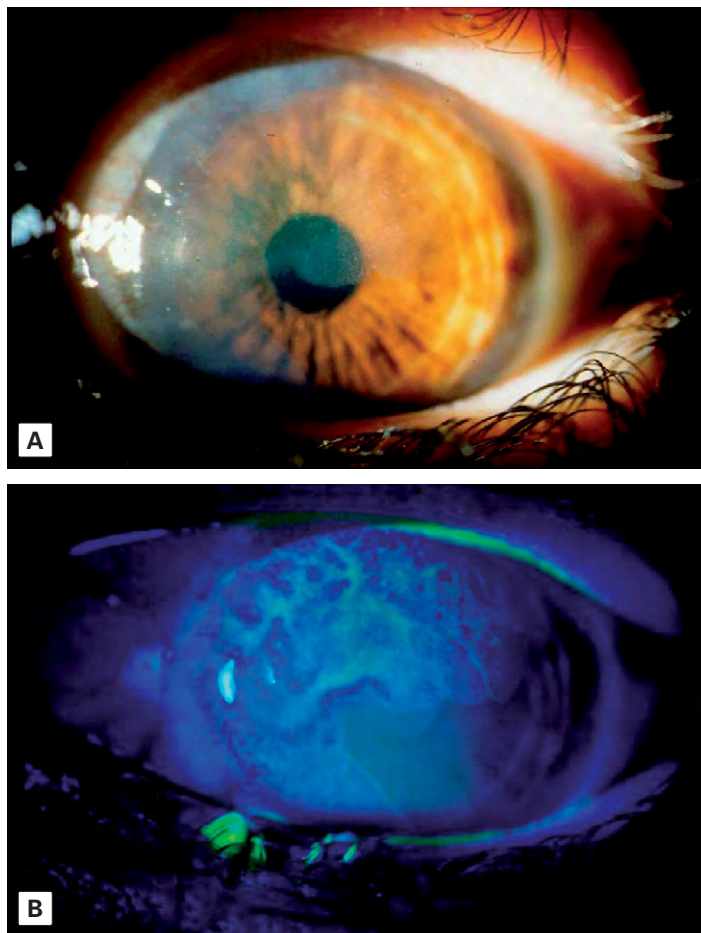
## CLINICAL FEATURES

**Symptoms** In addition to the presence of the lesion on the ocular surface, other symptoms include ocular redness and irritation. Visual acuity is usually not reduced, unless the center of the cornea is affected.<sup>9</sup> OSSN may grow within weeks to years; in most cases the history is of several months.

**Signs** Clinically it may be difficult to distinguish among conjunctival epithelial dysplasia, carcinoma in situ, and invasive squamous cell carcinoma, although suspicion towards one of these three lesions may exist. These lesions arise commonly within the interpalpebral fissure, mostly at the limbus, although they may be found in any part of the conjunctiva and cornea (Figs 25.1–25.4). OSSN may appear gelatinous, with superficial vessels; papilliform, when it has a papillary appearance; or leukoplakic, with a white keratin plaque covering the lesion.<sup>3</sup> It may also appear as a nodular lesion, especially when it is invasive SCC, or as a diffuse lesion masquerading as chronic conjunctivitis. Usually OSSN appears non-pigmented, although pigmented conjunctival SCC has been reported.

## DIFFERENTIAL DIAGNOSIS

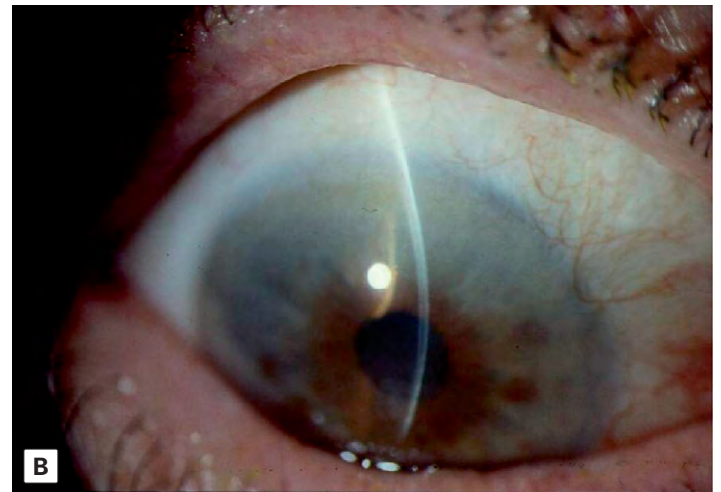
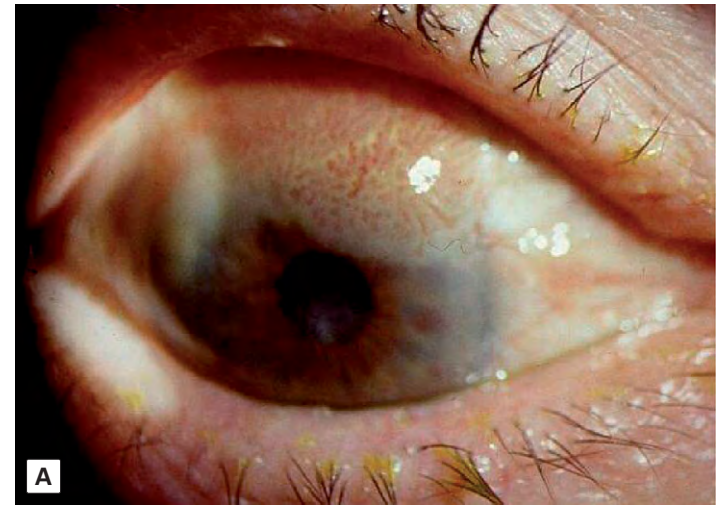The main lesions in the differential diagnosis of OSSN are pinguecula, pterygium, and squamous papilloma.<sup>3</sup>



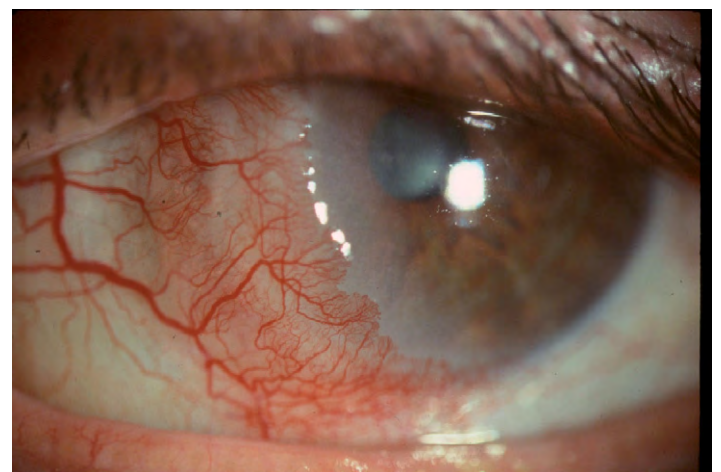**Fig. 25.1** Diffuse corneal involvement by CIN showing hazy and irregular corneal surface (A). Staining with fluorescein shows the granular surface of the involved cornea and clearly delineates the border between the affected and non-affected areas (B).

## DIAGNOSTIC EVALUATION

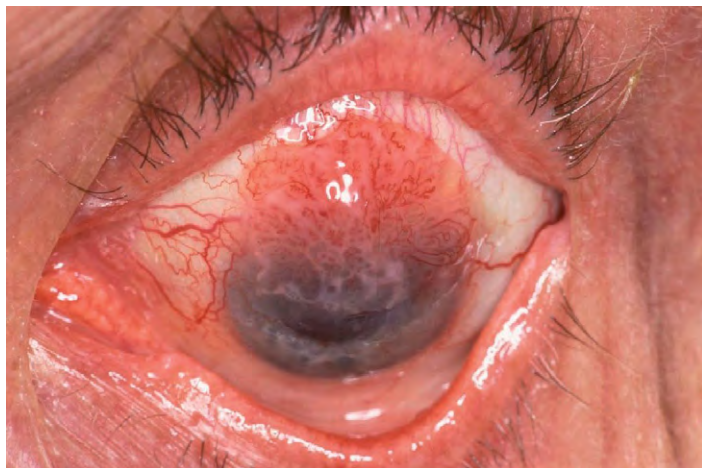It may be difficult to distinguish clinically between intraepithelial and invasive squamous neoplasia, and between these and other lesions such as pinguecula and pterygium, especially those with leukoplakia and squamous papilloma.



**Fig. 25.2** Elevated CIN in the upper limbal area with irregular papillary surface (A). The same eye after treatment with topical mitomycin C, showing total eradication of the lesion (B).



**Fig. 25.3** Carcinoma in situ with early subepithelial invasion growing from the temporal conjunctiva into the cornea.



**Fig. 25.4** Papillary conjunctival SCC invading into the upper half of the cornea.

**Fluorescein staining** In the authors' experience the use of fluorescein staining can help in the diagnosis, emphasizing the papillary or granular surface of part of the OSSN lesion and delineating its borders (Fig. 25.1).<sup>9,10</sup> Others have used rose Bengal staining.

**Ultrasound biomicroscopy** Recent publications have described the use of high-frequency ultrasound in the diagnosis of OSSN, particularly in estimating the depth of invasion.<sup>11</sup> However, the definitive diagnosis must be a histological one.

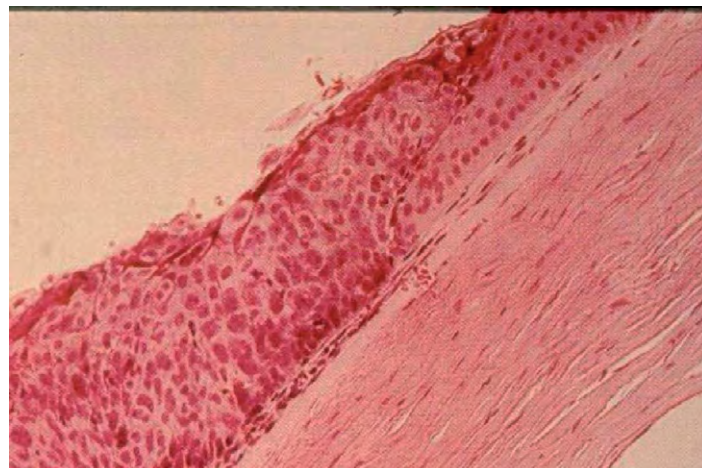
**Diagnostic cytology** Preoperative cytologic diagnosis may be of value in planning surgery in order to prevent the unnecessary removal of large pieces of normal conjunctiva in the case of a benign lesion, and to prevent partial excision in cases of malignancy.

**Exfoliative cytology** Cells from the conjunctival surface are obtained by platinum spatula, brush, and cotton-tip, and Papanicolaou and Giemsa stains are used to examine the specimen.<sup>12</sup> The advantages of this technique are the ability to obtain prospective cytologic information on the nature of the lesion, mainly in differentiating between benign and malignant lesions, the ability to sample multiple sites, and in easy follow-up evaluation after treatment. The major disadvantage is the superficial nature of the samples obtained. Sometimes only keratinized cells are obtained. This does not provide information about the degree of tumor invasion, which may be crucial in the overall management.

**Impression cytology** Another method of obtaining cells from the surface of the conjunctival lesion is by impression cytology.<sup>13</sup> In this technique several types of filter paper, such as cellulose acetate, millipore, or a biopore membrane device, are gently placed in contact with the ocular surface, sampling the most superficial cells. These are fixed and stained with the Papanicolaou stain. The advantages and disadvantages of exfoliation cytology also apply to impression cytology.

### HISTOPATHOLOGIC FEATURES

Only histological evaluation of excised lesions, from either incisional or excisional biopsy, can differentiate between the three lesions within the spectrum of OSSN.<sup>1,2</sup>



**Fig. 25.5** Histologic picture of acanthotic conjunctival epithelium with dysplastic changes involving most of the epithelial thickness. The epithelium lost its normal cellular polarity. Normal conjunctival epithelium is seen on the right side. (Hematoxylin & eosin, original magnification  $\times 100$ .)

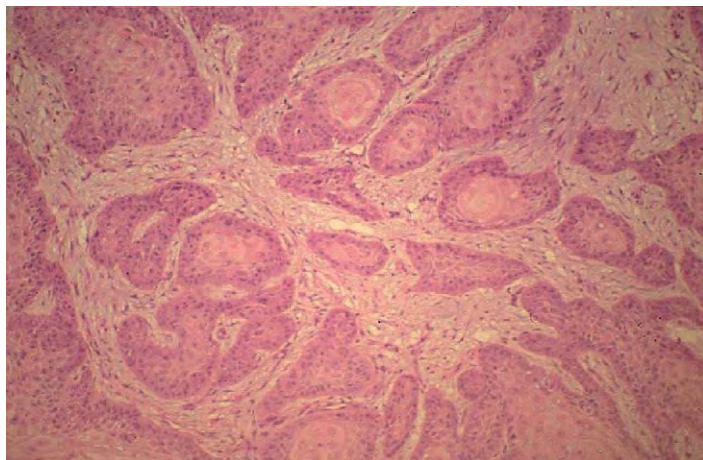
**Dysplasia** Dysplastic lesions exhibit mild, moderate, or severe degrees of cellular atypia that may involve various thicknesses of the epithelium, starting from the basal layer outwards (Fig. 25.5). They show modification of epithelial cell organization with various degrees of loss of the normal cellular polarity. Usually the most superficial layers are uninvolved. In cases with severe dysplastic changes it may be difficult to distinguish the lesion from carcinoma in situ.

**Carcinoma in situ** may exhibit all the histological features of SCC. However, it usually remains confined to the epithelium, respecting the basement membrane. Carcinoma in situ usually shows a total loss of normal cellular maturation, affecting the full thickness of the epithelium. The cells are large and usually elongated. Keratinized cells may be identified and mitotic figures can be present in all layers.

**Invasive squamous cell carcinoma** shows features similar to carcinoma in situ, but the basement membrane of the epithelium is breached and the subepithelial tissue of the conjunctiva is invaded. Most conjunctival SCC are well differentiated and often show surface keratinization (Fig. 25.6). The tumor may show various degrees of cellular pleomorphism. In examining such lesions, hyperplastic and hyperchromatic cells, individually keratinized cells (dyskeratosis), concentric collections of keratinized cells (horn pearls), loss of cellular cohesiveness, and atypical mitotic figures may be observed. The subepithelial tissue in invasive SCC is usually inflamed and contains islands of atypical epithelial cells. In pigmented individuals OSSN can be pigmented owing to abnormal proliferation of melanocytes in the lesions.

**Histopathologic variants** Three types of invasive conjunctival SCC with rather aggressive behavior have been reported.<sup>2</sup> Because of the aggressiveness of these variants, which often invade the eyeball and the orbital tissue, and even metastasize to lymphatics and distant sites, they should be histopathologically differentiated from less aggressive conventional SCC.





**Fig. 25.6** Histologic picture of well-differentiated conjunctival SCC showing deep invasion of tumor cell islands. (Hematoxylin & eosin, original magnification  $\times 100$ .)

- **Spindle cell squamous carcinoma.** The spindle cell variant of SCC exhibits spindle-shaped cells that may be difficult to distinguish from fibroblasts.
- **Mucoepidermoid carcinoma.** Mucoepidermoid carcinoma is a variant of conjunctival SCC that shows, besides the squamous cells, mucus-secreting cells that are stained positively with stains for mucopolysaccharides.
- **Adenoid squamous cell carcinoma.** Another variant of conjunctival SCC with aggressive behavior is the adenoid squamous carcinoma, which histologically shows extracellular hyaluronic acid but no intracellular mucin.

**Squamous cell carcinoma of cornea** OSSN arising in the corneal epithelium is rarely observed.<sup>5,14</sup> There is controversy about its origin. Some authors support the possible potential of the corneal epithelium to undergo dysplastic and cancerous changes, whereas others believe that the origin of corneal OSSN is at the limbus. Histologically, the corneal CIN is similar to those in the limbus and conjunctiva. Usually Bowman's layer is intact. Corneal CIN has a tendency to recur because of inadequate scraping, but with current methods of treatment this rarely occurs.<sup>9,10</sup>

## TREATMENT

**Surgery** Surgical excision is the traditional method of treatment for OSSN lesions. Its success depends on the involvement of the peripheral and deep margins. In order to avoid recurrence, it is recommended to excise the tumor tissue with wide surgical margins of 2–3 mm.<sup>3,15</sup> When the deep cornea or sclera is involved, deep lamellar keratectomy or sclerectomy is performed. Recurrence rates following excision of OSSN alone range from 15% to 52%, with an average of 30%.<sup>1</sup> Erie et al.<sup>5</sup> found a 5% recurrence rate when the surgical margins were free and 53% recurrence when they were involved. Similarly, Pizzarello and Jakobiec<sup>3</sup> found 69% recurrence when dysplastic tissues were left at the surgical margins.

Therefore, techniques to ensure clear surgical margins have been applied. Frozen sections were used by Char et al.<sup>16</sup> to assess the surgical margins. However, there was a disparity between the apparently free surgical margins and recurrence of the OSSN. Buus et al.<sup>17</sup> have used a modified Mohs' micrographic technique, that was developed for

cutaneous tumors, in order to ensure clear surgical margins. No recurrences were documented in their series of 19 patients.

Two cases of OSSN with intraocular involvement were managed by local excision. Char et al.<sup>16</sup> reported a successful iridocyclochoroidectomy with adjunctive cryotherapy. Most eyes with intraocular invasion of OSSN are enucleated,<sup>18</sup> and in cases with orbital invasion exenteration is required.

**Cryotherapy** Because of the high recurrence rate of OSSN after surgical excision alone, Fraunfelder et al.<sup>19</sup> advocated the use of cryosurgery in the treatment of eyelid and ocular surface tumors. Later, he and others reported the use of combined excision and cryotherapy treatment for OSSN, with recurrence rates as low as 0–12%. Cryotherapy acts both by destroying the tumor cells and by obliterating its microcirculation, resulting in ischemic infarction of both normal and tumor tissue. Side effects include iritis, alterations in intraocular pressure, inflammation, corneal edema, scarring, superficial corneal vascularization, sector iris atrophy, ablation of the peripheral retina, and ectropion.

**Reconstruction** of the ocular surface may be needed after large excisions, and the use of autologous conjunctival transplantation and autologous limbal transplants to restore corneal and limbal areas has been described. Espana et al.<sup>20</sup> used amniotic membrane transplantation for reconstruction after the excision of large ocular surface neoplasias.

**Brachytherapy** has long been used for the treatment of OSSN. The most commonly used radioactive material has been strontium-90, with a recommended dose of 20–180 Gy to the tumor surface.<sup>21</sup> Another  $\beta$  source is ruthenium-106, with recommended doses of 290–320 Gy to the tumor bed.<sup>22</sup>  $\gamma$  Radiation as well as applicators containing radioactive phosphorus have also been used. Recurrence rates after brachytherapy ranged between 2% and 47%; brachytherapy alone is therefore not recommended. Reported complications include post-irradiation conjunctivitis, dry eye, conjunctival telangiectasis and scarring, symblepharon, scleral ulceration, corneal perforation, and cataract.

## Topical chemotherapy

**Mitomycin C** Because of the possible complications of surgical excision, cryotherapy, and brachytherapy, in the early 1990s our group introduced and promoted the use of topical chemotherapy, using mitomycin C drops, in treating conjunctival and corneal intraepithelial squamous neoplasia (see Fig. 25.2).<sup>9</sup> Our protocol included treatment with 0.02% (0.2 mg/ml) mitomycin C drops four times daily for 2 weeks,<sup>2,9,10</sup> repeated as necessary. After follow-up of our first 39 patients for 12–120 months, 19 had responded to one course of mitomycin C, 13 needed two courses, and seven needed three to five courses. Thirty-seven of the 39 patients (95%) responded to treatment, but two were refractive to treatment and needed surgical excision.

The main adverse reaction to the mitomycin C drops was conjunctival hyperemia, and some patients experienced pain or a burning sensation. The side effects disappeared within 2 weeks of stopping the topical mitomycin C, with or without the addition of topical steroids.

Because of the superficial effect of mitomycin C drops we do not recommend using them in invasive SCC as primary treatment. However,



we have used them successfully in five patients with partially excised invasive conjunctival SCC without evidence of recurrence.<sup>23</sup>

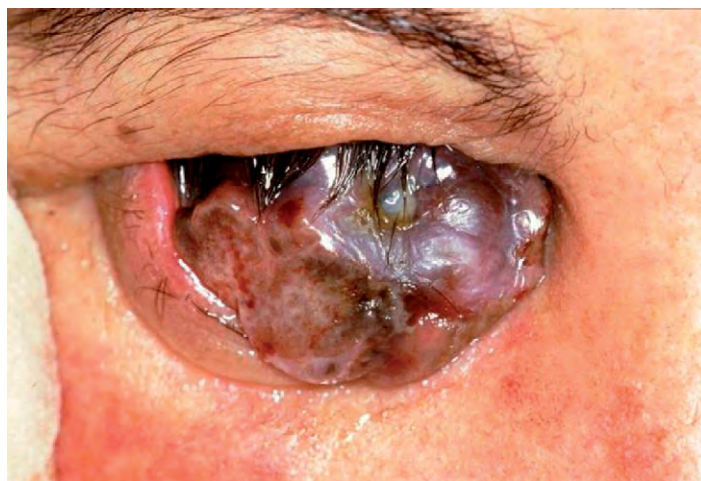**5-Fluorouracil** Midena and others<sup>24</sup> have used topical 5-fluorouracil (5FU) 1% drops four times daily for 4 weeks in the treatment of CIN, with a very good response. All patients experienced toxic keratoconjunctivitis, but no long-term side effects were found.

**Interferon- $\alpha_{2b}$**  Other groups have used recombinant interferon- $\alpha_{2b}$  in treating CIN, either via intralesional injection or via drops, with complete clinical resolution of the tumors.<sup>25</sup>

## PROGNOSIS

**Local recurrence** OSSN is considered to be a low-grade malignancy.<sup>3,5</sup> The conjunctival intraepithelial neoplasia (CIN), including dysplasia and carcinoma in situ, are regarded as precancerous lesions that rarely progress to invasive SCC. However, recurrences of these lesions are common after surgical excision, depending on the involvement of the surgical margins.<sup>3,5</sup> Erie et al.<sup>5</sup> reported 24% recurrence after excision of CIN and 41% after excision of SCC. Lee et al.<sup>1</sup> found recurrence rates of 17% for conjunctival dysplasia, 40% for carcinoma in situ, and 30% for SCC. In this series 31% had a second recurrence and 8% had more than two recurrences. Most tumors tend to recur within 2 years, but later recurrences have been reported. New methods of treatment reduce the recurrence rate significantly, as discussed in the treatment section.

**Intraocular invasion** Intraocular invasion, although rare, may occur in OSSN.<sup>19</sup> It occurs in older patients who had SCC located near the corneoscleral limbus, with one or more recurrences after surgical excision. Histopathologic examination may show growth of the SCC through the limbus, with involvement of Schlemm's canal, the trabecular meshwork, anterior chamber, iris, ciliary body, suprachoroid-



**Fig. 25.7** Advanced conjunctival SCC protruding through the eyelid aperture. The tumor invaded the eyeball and the orbit.

dal space, and choroid, sometimes extending even behind the equator. In very advanced cases the tumor may involve the entire orbit (Fig. 25.7).

**Metastasis** Metastasis of conjunctival SCC is extremely rare.<sup>5,15</sup> Sites of metastasis include preauricular, submandibular and cervical lymph nodes, parotid gland, lungs, and bones. The main cause of metastasis is delay in diagnosis and treatment. Regional lymph node involvement precedes the development of distant metastases, therefore regular examination of these lymph nodes should be performed in suspicious patients, to enable lymph node and radical neck dissection in cases of nodal involvement. Local invasion and distant metastases may lead to death in very rare cases.<sup>15</sup>

## REFERENCES

- Lee GA, Hirst LW. Ocular surface squamous neoplasia. *Surv Ophthalmol* 1995; 39: 429-450.
- Pe'er J. Ocular surface squamous neoplasia. *Ophthalmol Clin North Am* 2005; 18: 1-13.
- Pizzarello LD, Jakobiec FA. Bowen's disease of the conjunctiva: a misnomer. In: Jakobiec FA, ed. *Ocular and adnexal tumors*. Birmingham, AL: Aesculapian, 1978; 553-571.
- Sun EC, Fears TR, Goedert JJ. Epidemiology of squamous cell conjunctival cancer. *Cancer Epidemiol Biomarkers Prev* 1997; 6: 73-77.
- Erie JC, Campbell RJ, Liesegang J. Conjunctival and corneal intraepithelial and invasive neoplasia. *Ophthalmology* 1986; 93: 176-183.
- Newton R, Ferlay J, Reeves G et al. Effect of ambient solar ultraviolet radiation on incidence of squamous cell carcinoma of the eye. *Lancet* 1996; 347: 1450-1451.
- McDonnell JM, Mayr AJ, Martin WJ. DNA of human papillomavirus type 16 in dysplastic and malignant lesions of the conjunctiva and cornea. *N Engl J Med* 1989; 320: 1442-1446.
- Goedert JJ, Cote TR. Conjunctival malignant disease with AIDS in USA. *Lancet* 1995; 346: 257-258.
- Frucht-Pery J, Rozenman Y. Mitomycin C therapy for corneal intraepithelial neoplasia. *Am J Ophthalmol* 1994; 117: 164-168.
- Frucht-Pery J, Sugar J, Baum J et al. Mitomycin C treatment for conjunctival-corneal intraepithelial neoplasia: a multicenter experience. *Ophthalmology* 1997; 104: 2085-2093.
- Finger PT, Tran HV, Turbin RE et al. High-frequency ultrasonographic evaluation of conjunctival intraepithelial neoplasia and squamous cell carcinoma. *Arch Ophthalmol* 2003; 121: 168-172.
- Spinak M, Friedman AH. Squamous cell carcinoma of the conjunctiva. Value of exfoliative cytology in diagnosis. *Surv Ophthalmol* 1977; 21: 351-355.
- Nolan GR, Hirst LW, Bancroft BJ. The cytomorphology of ocular surface squamous neoplasia by using impression cytology. *Cancer* 2001; 93: 60-67.
- Waring GO III, Roth AM, Ekins MB. Clinical and pathologic description of 17 cases of corneal intraepithelial neoplasia. *Am J Ophthalmol* 1984; 97: 547-559.
- Iliff WJ, Marback R, Green WR. Invasive squamous cell carcinoma of the conjunctiva. *Arch Ophthalmol* 1975; 93: 119-122.
- Char DH, Crawford JB, Howers EL et al. Resection of intraocular squamous cell carcinoma. *Br J Ophthalmol* 1992; 76: 123-125.
- Buus DR, Tse DT, Folberg R. Microscopically controlled excision of conjunctival squamous cell carcinoma. *Am J Ophthalmol* 1994; 117: 97-102.
- Shields JA, Shields CL, Gunduz K et al. The 1998 Pan American Lecture. Intraocular invasion of conjunctival squamous cell carcinoma in five patients. *Ophthalm Plast Reconstr Surg* 1999; 15: 153-160.
- Fraunfelder FT, Wallace TR, Farris HE et al. The role of cryosurgery in external ocular and periocular disease. *Trans Am Acad Ophthalmol Otolaryngol* 1977; 83: 713-724.
- Espana EM, Prabhasawat P, Grueterich M et al. Amniotic membrane transplantation for reconstruction after excision of large ocular surface neoplasias. *Br J Ophthalmol* 2002; 86: 640-645.
- Lommatzsch P. Beta-ray treatment of malignant epithelial tumors of the conjunctiva. *Am J Ophthalmol* 1976; 81: 198-206.
- Zehetmayer M, Menapace R, Kulnig W. Combined local excision and brachytherapy with Ruthenium-106 in the treatment of epibulbar malignancies. *Ophthalmologica* 1993; 207: 133-139.
- Frucht-Pery J, Rozenman Y, Pe'er J. Topical mitomycin-C for partially excised conjunctival squamous cell carcinoma. *Ophthalmology* 2002; 109: 548-552.
- Midena E, Angeli CD, Valenti M et al. Treatment of conjunctival squamous cell carcinoma with topical 5-fluorouracil. *Br J Ophthalmol* 2000; 84: 268-272.
- Karp CL, Moore JK, Rosa RH Jr. Treatment of conjunctival and corneal intraepithelial neoplasia with topical interferon alpha-2b. *Ophthalmology* 2001; 108: 1093-1098.

# Primary acquired melanosis

Jacob Pe'er and Robert Folberg

## INTRODUCTION

The term primary acquired melanosis (PAM) was adopted by the World Health Organization in 1980 in its International Histological Classification of Tumours<sup>1</sup> to represent flat, brown, intraepithelial conjunctival lesions. 'Primary' denotes that the lesion is not the result of generalized (racial) dark pigmentation, systemic disease (e.g. Addison's disease), or local factors (foreign body, injury, inflammation, medication, etc.); 'acquired' distinguishes these lesions from those that are congenital; 'melanosis' indicates that the pigment in the lesion is derived specifically from the production of melanin rather than another pigment or a drug deposit (Table 26.1).<sup>2</sup>

Several terms have been used to describe PAM. Hutchinson,<sup>3</sup> who was the first to describe these lesions clinically in 1892, called them 'senile freckle' or 'lentigo melanosis,' and Dubreuilh,<sup>3</sup> who was the first to describe these lesions histologically in 1912, used the term 'mélanose circonscrite précancéreuse.' Miescher in 1936 used the term 'melanotische precancerose,' Reese in 1966<sup>4</sup> 'precancerous melanosis,' Zimmerman in 1966<sup>5</sup> 'benign acquired melanosis' and 'primary idiopathic acquired melanosis',<sup>6</sup> and Silvers in 1978<sup>7</sup> used the terms 'intraepithelial melanocytic hyperplasia' and 'atypical melanocytic hyperplasia.'

The prevalence and natural behavior of PAM are controversial. One study<sup>8</sup> reported the prevalence of PAM in Caucasians with no known non-European ancestry to be 36%. This is exceptionally high compared with other studies. It is important to consider that the authors of this study included lesions that were detectable only by slit lamp high magnification, and some were so small that they would not have been detected on routine clinical examination. Furthermore, there was no histological confirmation of the diagnosis in this series.

## ETIOLOGY

PAM is more prevalent in fair-complexioned individuals than in those with dark skin tones, and is almost always unilateral. If bilateral conjunctival pigmentation is encountered, the ophthalmologist should first consider either complexion-associated conjunctival pigmentation or a systemic condition associated with bilateral conjunctival pigmentation.

**Sunlight exposure** The importance of sun exposure in the development of PAM is not clear. However, in one study<sup>8</sup> those who lived south of Washington, DC for 5 or more years had a significantly greater prevalence of PAM lesions of their exposed intrapalpebral

conjunctiva than those who did not. Also, patients with pinguecula or pterygium had a higher prevalence of PAM. Silvers et al.<sup>7</sup> noted a high incidence of solar elastosis in biopsy specimens from patients with conjunctival pigmented lesions. These facts suggest a possible role of sunlight exposure, but although they might explain PAM arising in the bulbar conjunctiva in the interpalpebral fissure, they do not explain cases in which PAM originates in the fornices and the palpebral conjunctiva.

**Relationship to nevi and dysplastic nevus syndrome** The prevalence of PAM was shown to increase significantly as the number of facial nevi increased.<sup>8</sup> Seregard et al.,<sup>9</sup> in a case-control study, observed that ocular melanocytic lesions, including PAM, are not more common in individuals with dysplastic nevus syndrome than in the general population.

**Cigarette smoking** Cigarette smoking and hypertension have been observed to be significant independent factors in the development of PAM.<sup>8</sup> No other etiological factors have been so implicated.

## CLINICAL FEATURES

Primary acquired melanosis appears clinically as a flat and variably brown conjunctival lesion, ranging from golden brown to dark chocolate in color (Figs 26.1–26.4).<sup>2</sup> There are no published size criteria for the clinical diagnosis of PAM.<sup>8</sup> PAM is usually monocular, although binocular cases may occur. The lesion may involve any area of the conjunctiva in a contiguous or multispotted pattern, necessitating eversion of the eyelids to examine both the upper and lower palpebral zones. PAM develops most commonly at the limbus and epibulbar interpalpebral region, and may extend into the corneal epithelium. In some patients with widespread lesions the eyelid epidermis may also be involved.<sup>2</sup> PAM occurs typically in middle-aged or elderly white patients, although it may appear also in young adults, but typically not in children. In one study<sup>10</sup> the mean age at the time of diagnosis was 45 years, and in another study 62 years.<sup>8</sup> There is no significant difference in the prevalence of PAM between males and females.<sup>8</sup>

PAM lesions may remain stable for long periods or may increase in size. A 'waxing and waning' phenomenon, in which areas in the lesions darken or lighten, is well known.<sup>2</sup> Parts of – or, rarely, the entire – lesion can be amelanotic (*sine pigmento*); thus the borders often cannot be identified, and the clinically identified borders are misleading.<sup>10</sup>



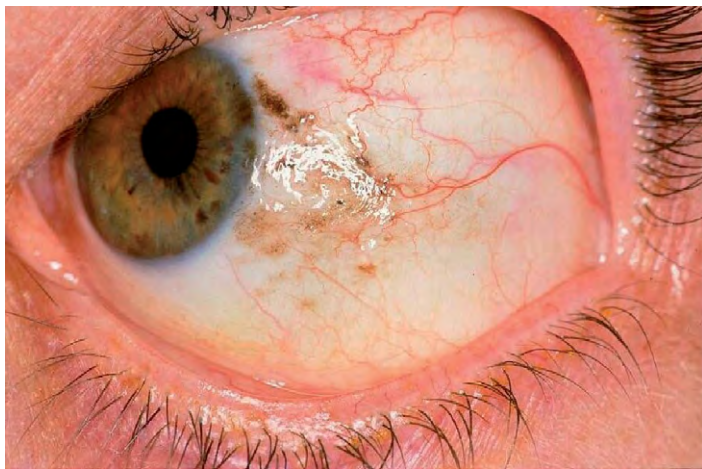**HISTOPATHOLOGIC FEATURES**

Histologically, PAM is divided into two major groups: PAM without atypia and PAM with atypia. Most conjunctival melanomas arise in the context of PAM with atypia. PAM with atypia is confined to the epithelium and is called by some pathologists ‘melanoma in situ,’<sup>3</sup> and is thus not associated with any risk of metastasis. The mortality of conjunctival melanoma is approximately 25%. Therefore, a particularly effective method for prevention of malignant melanoma is by completely extir-

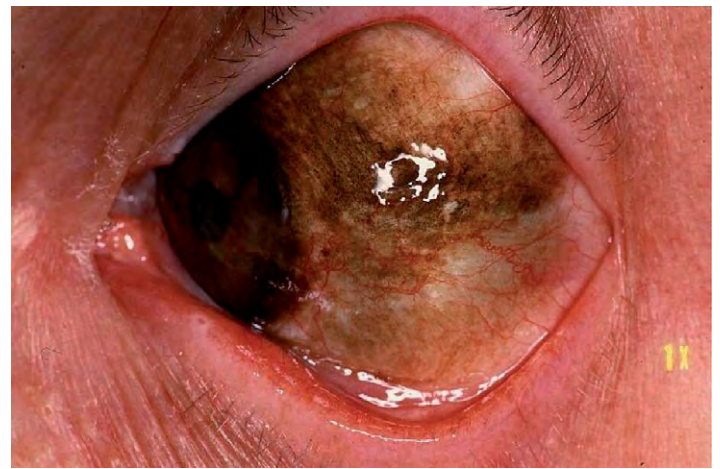
pating lesions showing histological evidence of PAM with atypia. The lesion designated as PAM without atypia does not evolve into melanoma. It is important to realize that there are no clinical criteria by which ophthalmologists can anticipate the histological diagnosis. For this reason, an ophthalmologist who encounters a fair-complexioned patient with a unilateral, acquired, flat patch of brown pigmentation should subject the lesion to biopsy to allow the pathologist to classify the lesion as PAM without atypia, or PAM with atypia.

**Table 26.1** Types of conjunctival melanosis

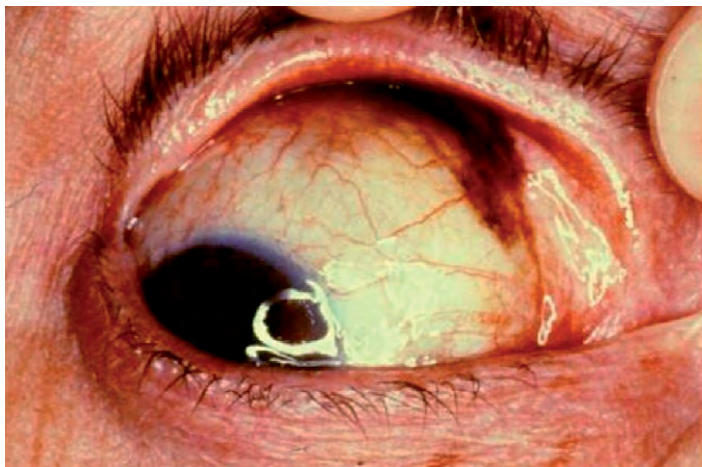Category	Subtype	Etiology		
Congenital	Ocular melanosis Oculodermal melanosis	Developmental episcleral hyperpigmentation		
Acquired	Racial	Normal pigmentation in darker races		
	Primary	Idiopathic		
	Secondary	Localized	Postinflammatory	Post traumatic
		Systemic	Foreign body	Drug deposition
	Syndromic	Addison's disease	Ochronosis	
		Carney's complex	Peutz-Jeghers syndrome	



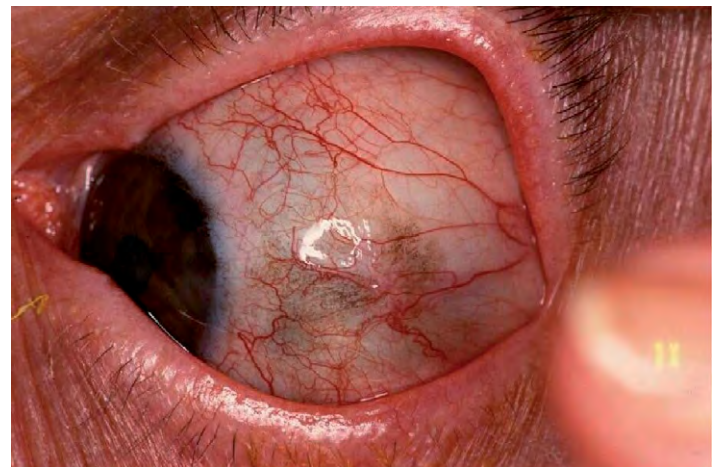
**Fig. 26.1** Localized PAM (with atypia) in the temporal bulbar conjunctiva of the left eye.



**Fig. 26.3** Diffuse PAM (with atypia) covering the entire temporal part of the bulbar conjunctiva.



**Fig. 26.2** Diffuse PAM with atypia in the upper bulbar conjunctiva and fornix.

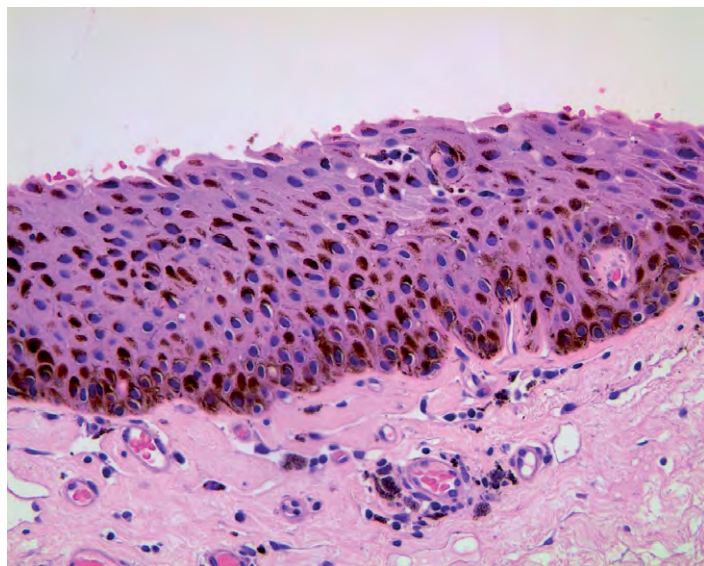


**Fig. 26.4** The same eye as in Figure 26.3 after treatment with topical mitomycin C. Some pigmentation, probably PAM without atypia, has remained unchanged for 6 years.

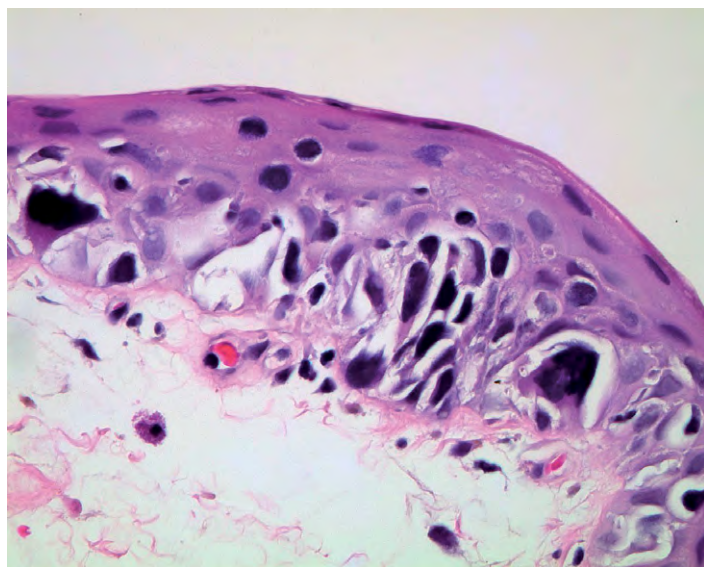


**Light microscopy** Histologically, the detection of conjunctival epithelial pigmentation with or without melanocytic hyperplasia – but without melanocytic atypia – qualifies a lesion to be designated as PAM without atypia (Fig. 26.5). One might think conceptually of such a lesion as an ‘ephelis’ (freckle) or lentigo (despite the fact that there are no rete structures in the normal conjunctiva, and therefore ‘lentigo’ is difficult to identify in this location). Histologically, the detection of atypical melanocytes within the epithelium qualifies the lesion to be designated as PAM with atypia.

In rendering a diagnosis of PAM with atypia, the pathologist should take note of both cytological and architectural features. Melanocytic atypia is identified through the detection of melanocytes of different sizes and shapes that appear to have a ‘disregard’ for (i.e. they are spatially separated from) adjacent epithelial cells (Fig. 26.6). These



**Fig. 26.5** Melanin pigmentation is distributed throughout the conjunctival epithelium. There is no evidence of melanocytic hyperplasia or atypia. This lesion would therefore be designated histologically as PAM without atypia. (Hematoxylin & eosin,  $\times 20$ ).



**Fig. 26.6** Highly atypical melanocytes populate the conjunctival epithelium singly and in nests. Note the lack of contact between these cells and the epithelium. This lesion should be designated PAM with atypia. (Hematoxylin & eosin,  $\times 40$ ).

atypical cells may be small and round, spindle-shaped, or even epithelioid. Architecturally, the atypical melanocytes may be distributed along the epithelial basement membrane (basilar hyperplasia pattern), may be segregated into nests that appear to be anchored along the basement membrane, or may be dispersed upward into the epithelium, either individually or as intraepithelial nests (pagetoid spread). In some areas the atypical melanocytes may completely replace the epithelium. PAM with atypia that extends into pseudoglands of Henle should not be mistaken for invasion (the lining of the pseudoglands is considered to be contiguous with the epithelium).

It is important for both pathologists and ophthalmologists to understand that junctional nevi of the conjunctiva are exceptionally rare, even in children. Therefore, the diagnosis of ‘junctional nevus,’ when rendered by a pathologist who is not experienced in ophthalmic pathology, especially if the lesion is not taken from a young child, should prompt a review: such a lesion is likely to represent PAM with atypia. The histological identification and differential diagnosis of PAM with atypia is among the most difficult in the practice of surgical ophthalmic pathology. A detailed description of the histological differential diagnosis is beyond the scope of this chapter, and the reader is referred to a more specialized text for details.<sup>11</sup>

**Immunohistochemistry** Chowers et al.<sup>12</sup> showed that on immunostaining for Ki-67 and PCNA, PAM with atypia had significantly higher proliferation activity than PAM without atypia. Sharara et al.<sup>13</sup> observed significantly higher expression of HMB-45 in PAM with atypia compared to PAM without atypia and conjunctival nevi.

## DIAGNOSTIC EVALUATION

The clinical suspicion of PAM is based on the features described above. Because PAM lesions are flat and intraepithelial, there are no imaging tools that can aid in the diagnosis. A Wood’s lamp may help in the detection of subclinical pigmentation, but is seldom used in clinical practice.<sup>14</sup>

## DIFFERENTIAL DIAGNOSIS

Primary acquired melanosis should be differentiated from any pigmented lesion of the conjunctiva, especially the flat ones.<sup>15</sup> Like PAM, conjunctival nevi are always movable. The presence of cysts within the lesion supports a diagnosis of conjunctival nevus rather than PAM. In episcleral melanosis, as in ocular melanosis or oculodermal melanosis, the pigmentation is blue-gray, non-movable, and usually multifocal. Conjunctival melanoma is usually elevated or nodular, but in early stages, when it arises from PAM with atypia, it may appear flat.

Other melanocytic lesions of the conjunctiva are racial pigmentation, which is associated with dark skin color and is usually bilateral and typically most intense at the limbus, fading in tone toward the fornices; post-inflammatory melanosis; and systemic conditions with flat bilateral conjunctival pigmented patches, such as Addison’s disease. Various benign and malignant conjunctival tumors that are usually amelanotic may be pigmented and simulate conjunctival pigmented lesions, and when flat may simulate PAM.

## TREATMENT

The appropriate management approach to PAM remains controversial.

**Observation** A small minority of ophthalmologists believe that the subtle PAM lesions do not meet the criteria for biopsy, and

recommend periodic follow-up which should include a thorough examination of the bulbar and palpebral conjunctiva and documentation of each lesion's location, size, and appearance.<sup>8</sup> However, PAM lesions that differ from the common, subtle lesions, including widespread or large lesions, dark lesions, lesions of the palpebral conjunctiva, and progressive lesions, should undergo biopsy.

**Surgery** The overwhelming consensus among ophthalmic oncologists and pathologists endorses biopsy of all conjunctival lesions that meet the clinical criteria for PAM.<sup>10,13</sup> Small lesions should be completely excised, whereas in widespread lesions incisional biopsy should be performed from various sites of the affected conjunctiva. The specimen should be examined to determine the presence or absence of cytologic atypia, and for the involvement of surgical margins.

**Cryotherapy** Because of recurrences of PAM with atypia and the development of melanoma in these lesions, Brownstein et al.<sup>16</sup> and Jakobiec et al.<sup>17</sup> recommended adding cryotherapy to the surgical excision. Shields et al.<sup>18</sup> suggested six-step surgery: alcohol corneal epitheliectomy, no-touch local removal of distinct lesions, staging conjunctival biopsy specimens, limbal peritomy, double freeze-thaw cryotherapy to the involved bulbar conjunctiva, and wound closure. In the Jakobiec series<sup>17</sup> none of the patients treated by surgical excision and cryotherapy progressed to invasive melanoma.

As mentioned above, in PAM the clinical examination may not indicate the full extent of the intraepithelial melanocytic lesions. Additionally, the waxing-and-waning phenomenon of PAM may prevent the identification of all locations of intraepithelial proliferating melanocytes that require treatment. Therefore, local excision and localized cryotherapy, even in cases of PAM that seem to be localized, may not cover the entire lesion. Furthermore, cryotherapy can cause complications, such as scarring of the substantia propria, loss of eyelashes, ptosis, lax eyelids, tarsal floppiness, symblepharon, pseudopterygium, iritis, anterior segment necrosis, macular edema, scleral melting, and cataract.<sup>16</sup>

**Topical mitomycin chemotherapy** In order to cover the entire conjunctival and corneal surface, treating hidden areas of the PAM and preventing the complications of cryotherapy, we treated a patient with widespread PAM with atypia using mitomycin C.<sup>19</sup> Summarizing our experience with the first 12 consecutive patients,<sup>20</sup> we recommended a protocol of 0.04% (0.4 mg/mL) mitomycin C drops four times daily

for 2 weeks. This regimen is repeated as necessary, with a pause of 2 weeks between courses, until the remnants of the pigmentation disappear or stabilize. At least three courses were recommended. In all patients there was complete or partial disappearance of pigmentation. In four patients the pigmentation disappeared, whereas in eight some remnants of pigmentation remained (Fig. 26.4). In one patient there was a regrowth of the PAM, and she was treated again with 0.04% mitomycin C, with success. All patients had conjunctival hyperemia during the treatment; some complained of irritation, tearing and eyelid swelling; in a few patients the cornea was affected. All side effects resolved after cessation of treatment.

It is important to note that treatment with mitomycin C should be applied only to intraepithelial lesions and should not be used in invasive conjunctival melanoma. Other groups have shown similar results in treating PAM with atypia using mitomycin C.<sup>21,22</sup>

## PROGNOSIS

Study of the natural history of PAM in humans is not possible. A successful attempt in an animal model,<sup>23</sup> by applying a 1% solution of DMBA to the conjunctiva in rabbits, showed a spectrum from increased melanin production and melanocytic hyperplasia without atypia through atypical melanocyte hyperplasia of PAM.

The incidence of recurrence of PAM depends on the presence or absence of atypia.<sup>10</sup> Recurrence after excision is rare in PAM without atypia; when it recurs it appears without atypical cytological changes. On the other hand, about 60% of lesions designated as PAM with atypia recur after excision alone; half of them recur initially as malignant melanoma. In one study<sup>10</sup> the median interval between the biopsy of PAM and the biopsy of melanoma was 2.5 years. Progression after 6 years is very rare, and progression to melanoma more than 10 years after the biopsy of PAM with atypia has not been observed. Recurrence is more likely when the lesion is incompletely excised or when the cornea is involved. Thus, it is very important to treat the entire conjunctival and corneal PAM with atypia.

It is important to note that the mortality rate from conjunctival melanoma is about 25%, with no difference between patients who had melanoma with PAM and those who had melanoma without PAM.<sup>13</sup> However, no mortality has been reported from PAM without transformation to melanoma. Although patients with PAM without atypia tend to be younger than those with PAM with atypia,<sup>10</sup> there is no evidence to indicate progression of PAM without atypia to PAM with atypia.

## REFERENCES

- Zimmerman LE, Sobin LH. International histological classification of tumours. No. 24: Histological typing of tumours of the eye and its adnexa. Geneva: World Health Organization, 1980; 30.
- Jakobiec FA, Folberg R, Iwamoto T. Clinicopathologic characteristics of premalignant and malignant melanocytic lesions of the conjunctiva. *Ophthalmology* 1989; 96: 147-166.
- Ackerman AB, Sood R, Koenig M. Primary acquired melanosis of the conjunctiva is melanoma in situ. *Mod Pathol* 1991; 4: 253-263.
- Reese AB. Precancerous and cancerous melanosis. *Am J Ophthalmol* 1966; 61: 1272-1277.
- Zimmerman LE. Criteria for management of melanosis [Letter]. *Arch Ophthalmol* 1966; 76: 307-308.
- Zimmerman LE. The histogenesis of conjunctival melanoma; the first Algernon B. Reese lecture. In: Jakobiec FA, ed. *Ocular and adnexal tumors*. Birmingham, AL: Aesculapius, 1978; 600-630.
- Silvers DN, Jakobiec FA, Freeman TR et al. Melanoma of the conjunctiva: A clinicopathologic study. In: Jakobiec FA, ed. *Ocular and adnexal tumors*. Birmingham, AL: Aesculapius, 1978; 583-599.
- Gloor P, Alexandrakis G. Clinical characterization of primary acquired melanosis. *Invest Ophthalmol Vis Sci* 1995; 36: 1721-1729.
- Seregard S, af Trampe E, Mansson-Brahme E et al. Prevalence of primary acquired melanosis and nevi of the conjunctiva and uvea in the dysplastic nevus syndrome. A case-control study. *Ophthalmology* 1995; 102: 1524-1529.
- Folberg R, McLean IW, Zimmerman LE. Primary acquired melanosis of the conjunctiva. *Hum Pathol* 1985; 16: 129-135.
- Folberg R. Tumors of the eye and ocular adnexae. In: Fletcher C, ed. *Diagnostic histopathology of tumors*, 3rd edn. Edinburgh: Elsevier (in press).
- Chowers I, Livni N, Solomon A et al. MIB-1 and PC-10 immunostaining for the assessment of proliferative activity in primary acquired melanosis without and with atypia. *Br J Ophthalmol* 1998; 82: 1316-1319.
- Sharara NA, Alexander RA, Luthert PJ et al. Differential immunoreactivity of melanocytic lesions of the conjunctiva. *Histopathology* 2001; 39: 426-431.
- Folberg R, McLean IW, Zimmerman LE. Conjunctival melanosis and melanoma. *Ophthalmology* 1984; 91: 673-678.
- Folberg R, Jakobiec FA, Bernardino VB et al. Benign conjunctival melanocytic lesions. Clinicopathologic features. *Ophthalmology* 1989; 96: 436-461.

16. Brownstein S, Jakobiec FA, Wilkinson RD et al. Cryotherapy for precancerous melanosis (atypical melanocytic hyperplasia) of the conjunctiva. *Arch Ophthalmol* 1981; 99: 1224–1231.
17. Jakobiec FA, Rini FJ, Fraunfelder FT et al. Cryotherapy for conjunctival primary acquired melanosis and malignant melanoma. Experience with 62 cases. *Ophthalmology* 1988; 95: 1058–1070.
18. Shields JA, Shields CL, De Potter P. Surgical management of conjunctival tumors. *Arch Ophthalmol* 1997; 115: 808–815.
19. Frucht-Pery J, Pe'er J. Use of mitomycin C in the treatment of conjunctival primary acquired melanosis with atypia. *Arch Ophthalmol* 1996; 114: 1261–1264.
20. Pe'er J, Frucht-Pery J. The treatment of primary acquired melanosis (PAM) with atypia by topical mitomycin C. *Am J Ophthalmol* 2005; 139: 229–234.
21. Yuen VH, Jordan DR, Brownstein S et al. Topical mitomycin treatment for primary acquired melanosis of the conjunctiva. *Ophthalm Plast Reconstr Surg* 2003; 19: 149–151.
22. Kurli M, Finger PT. Topical mitomycin chemotherapy for conjunctival malignant melanoma and primary acquired melanosis with atypia: 12 years' experience. *Graefes Arch Clin Exp Ophthalmol* 2005; 243: 1108–1114.
23. Folberg R, Baron J, Reeves RD et al. Animal model of conjunctival primary acquired melanosis. *Ophthalmology* 1989; 96: 1006–1013.



# Conjunctival melanoma

Jacob Pe'er and Robert Folberg

## INTRODUCTION

Conjunctival melanoma is a rare unilateral tumor with a mortality rate of 23–30%.<sup>1,2</sup> In various sources of the medical literature, conjunctival melanoma is labeled together with uveal melanoma as 'ocular melanoma.' The clinical behaviors and the histopathologic features of conjunctival and uveal melanomas are clearly different. Conjunctival melanoma should therefore be approached as an entity separate from uveal melanoma.

Conjunctival nevi, conjunctival primary acquired melanosis (PAM), and conjunctival melanomas all arise from melanocytes that migrate from the neural crest to reside in the conjunctival epithelium. Conjunctival melanoma may arise *de novo*, or in the context of conjunctival nevus, PAM, or both.

## EPIDEMIOLOGY

Owing to the rarity of conjunctival melanoma, most published data on this malignancy appear as case reports and case series. Incidence studies based on population-based data are scarce. According to a Dutch survey, the annual incidence of conjunctival melanoma ranges between 0.028 and 0.034 new cases per 100 000 inhabitants,<sup>3</sup> and a Swedish national survey reported an annual incidence rate of 0.024 new cases per 100 000 inhabitants.<sup>4</sup>

An epidemiologic analysis using population-based registry data from the Surveillance, Epidemiology and End Results (SEER) program of the National Cancer Institute (NCI) of the USA showed a significant increased incidence rate of conjunctival melanoma, from 0.22 cases per million per year in 1973–79 to 0.3 cases in 1980–89, and to 0.46 in 1990–1999.<sup>5</sup> The major significant increase was in white men. Because changes in incidence coincide with those seen in cutaneous melanoma, the authors suggested a possible link to sunlight-related etiology. However, according to a Danish study there was no increase in the incidence of conjunctival melanoma between the years 1943 and 1997 (0.04 cases per 100 000 persons per year for men, and 0.03 for women).<sup>6</sup>

According to several studies, conjunctival melanoma accounts for 2–5% of ocular malignant melanomas<sup>1</sup> and less than 3% of excisional biopsies of conjunctival lesions.<sup>7</sup> Cutaneous melanoma was found to be 450–900 times more common than conjunctival melanoma, a ratio that is increasing.

Population-based data show that an equal number of men and women develop conjunctival melanoma,<sup>3,4</sup> but recent studies have shown a higher incidence in males.<sup>5,6</sup> Conjunctival melanoma is more common in middle-aged and older persons, between the fourth to

seventh decades of life,<sup>3,4</sup> and only a few incidences of its appearance in children have been reported.<sup>8</sup> Conjunctival melanomas are much less common in the black population and in other non-white individuals,<sup>1,5</sup> and according to one study the white-to-black ratio was found to be 13.6:1.0.<sup>7</sup>

## ETIOLOGY AND ASSOCIATED DISEASES

There is no clear evidence that ultraviolet radiation is a causative factor in the development of conjunctival melanoma, in spite of the fact that most of these tumors develop in the exposed bulbar conjunctiva.<sup>1,9</sup>

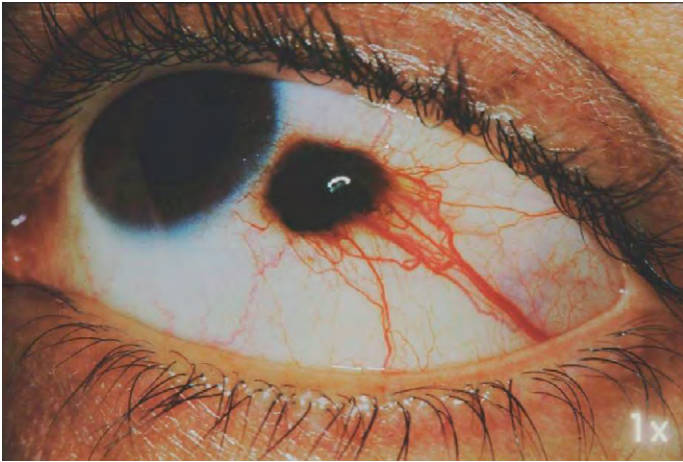The main precursors to conjunctival melanoma are PAM with atypia and conjunctival nevi. According to one study<sup>4</sup> 71% of conjunctival melanomas were associated with PAM with atypia, whereas 17% were associated with conjunctival nevus. In another study<sup>2</sup> 74.8% of conjunctival melanomas were associated with PAM and almost 20% were associated with nevus. The rest are considered to have developed *de novo*. No significant association was found with cutaneous melanoma, dysplastic nevus syndrome, or ocular or oculodermal melanocytosis.

## CLINICAL FEATURES

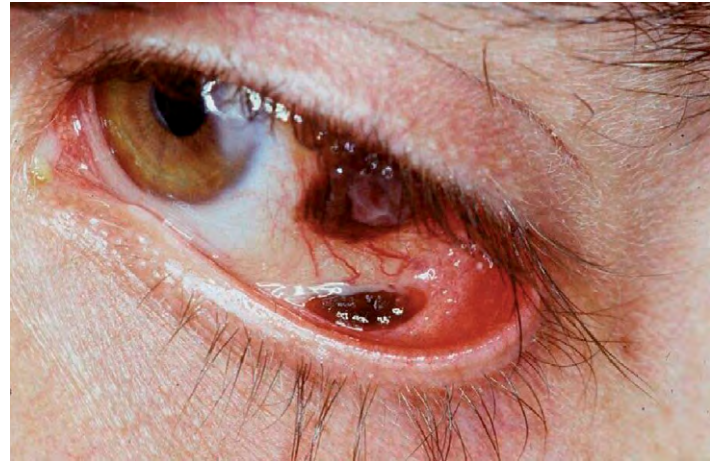Conjunctival melanoma usually affects one eye, and although these tumors are typically pigmented, amelanotic conjunctival melanomas do occur and can be mistaken for squamous cell carcinomas and lymphomas. Careful examination with high magnification under the slit lamp typically reveals flecks of pigmentation somewhere in most amelanotic melanomas.

It may arise in any region of the conjunctiva, including the bulbar, palpebral and fornical conjunctiva, and in the caruncle and plica semilunaris (Figs 27.1–27.4). Most conjunctival melanomas develop at the limbus. Multifocal conjunctival melanomas have been reported, and most of these originated from PAM with atypia.<sup>10</sup> Conjunctiva nevi are very rare in the palpebral conjunctiva and fornix. Therefore, pigmented lesions in these areas should be viewed as suspicious for melanoma and excised.

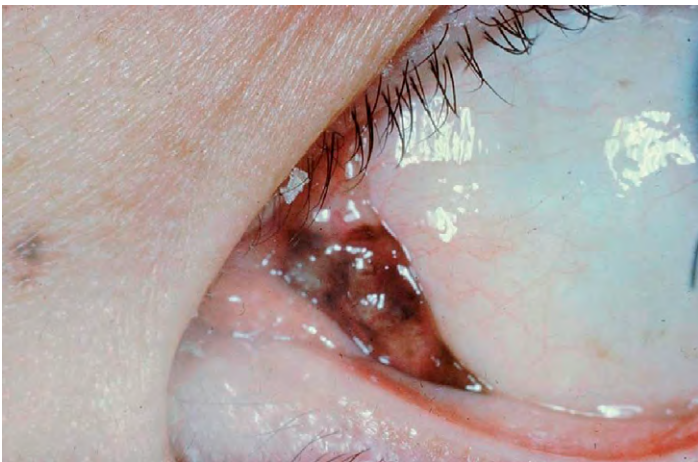Conjunctival melanomas are usually divided into two clinical and pathologic forms: those that are associated with and most probably arise from PAM with atypia, and those that evolve directly without antecedent PAM.<sup>11</sup> Microinvasive melanoma arising in PAM with atypia may be difficult to identify clinically, and ophthalmologists should look carefully for subtle placoid thickening in the PAM area without the development of a discretely elevated nodule. The more dramatic clinical evidence for the development of melanoma from



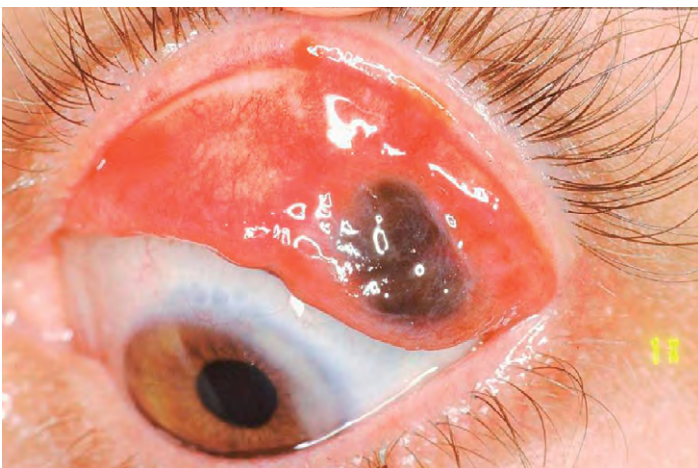**Fig. 27.1** Melanoma of the perilimbal bulbar conjunctiva with 'feeder vessels' entering the tumor.



**Fig. 27.4** Multifocal melanoma arising from PAM with atypia, with a tumor in the bulbar conjunctiva and a tumor in the lower fornix.



**Fig. 27.2** Melanoma of the plica semilunaris.



**Fig. 27.3** Melanoma of the upper palpebral conjunctiva.

PAM is the sudden emergence of one or more nodules in the otherwise flat lesion.<sup>11</sup> In multifocal melanomas arising from PAM with atypia, tumors can appear simultaneously or gradually in various parts of the conjunctiva. Melanoma with PAM may affect the adjacent eyelid skin.<sup>2</sup>

When conjunctival melanoma arises from a nevus or de novo it appears as a solitary pigmented or non-pigmented smooth vascularized nodule, commonly in the limbal area, and rarely can be pedunculated.<sup>1</sup>

The substantia propria of the bulbar conjunctiva is movable over the surface of the globe. Moreover, the sclera is relatively resistant to invasion by epibulbar cancers. Therefore, most of the epibulbar melanomas that develop away from the limbus are movable over the surface of the eye. By contrast, melanomas arising in the palpebral conjunctiva, where the substantia propria is densely adherent to the underlying tarsus, are not movable, and although these tumors may be minimally elevated if at all, they can be deeply invasive.<sup>11</sup>

Primary melanoma of the cornea is very rare, although several cases have been reported.<sup>1</sup> Many of these cases represent examples of corneal invasion from a limbal melanoma. It is important to remember that Bowman's layer is a barrier to the penetration of surface malignancies into the corneal stroma. Therefore, pigmented neoplasms affecting the cornea are usually superficial to Bowman's layer, unless this tissue has previously been violated by the surgeon.

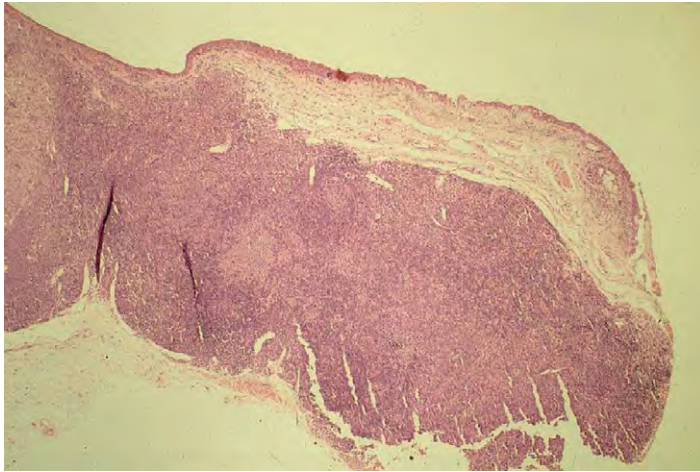
### DIAGNOSIS AND DIFFERENTIAL DIAGNOSIS

Any conjunctival pigmented lesion may simulate conjunctival melanoma. Conjunctival nevi may be elevated and dark, and in the absence of cysts (typical of compound conjunctival nevi) may be difficult to differentiate from melanoma by clinical examination alone.<sup>11</sup> Most conjunctival nevi become apparent in childhood and adolescence. Therefore, any new, elevated pigmented conjunctival lesion that develops in adulthood should be viewed with suspicion. Conjunctival nevi almost always arise in the bulbar conjunctiva and caruncle. Therefore, any pigmented lesion presenting in the palpebral conjunctiva or fornix should be suspicious for melanoma.<sup>11</sup>

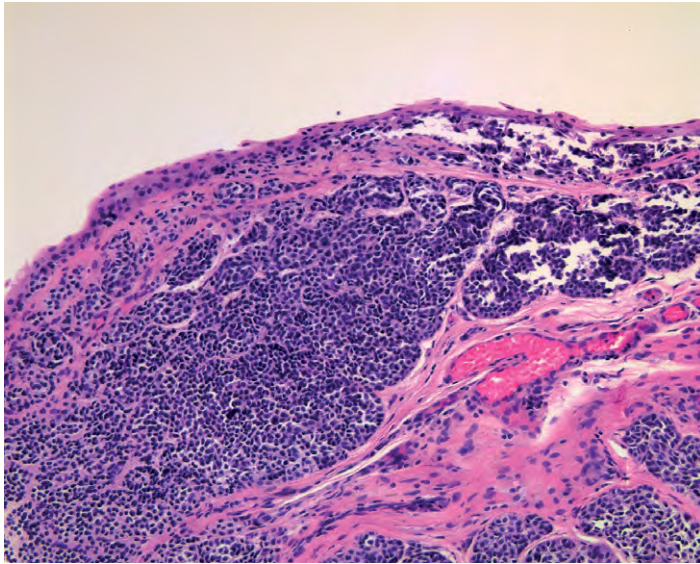
Epithelial lesions such as squamous papilloma, conjunctival intraepithelial neoplasia, and invasive squamous cell carcinomas may acquire melanin pigment in darkly complexioned individuals.<sup>12</sup> Staphylomas, subconjunctival hematomas, foreign bodies, and hematic cysts may also be confused clinically with conjunctival melanoma.<sup>1</sup> The rare occurrence of metastatic cutaneous melanoma to the conjunctiva has been reported.<sup>13</sup> Epibulbar extension of uveal melanoma or melanocytoma should also be considered in the differential diagnosis,<sup>14</sup> and in these cases the trans-scleral nature of this lesion can be identified by high-frequency ocular ultrasound.



The definite diagnosis of conjunctival melanoma is made by histopathologic examination. Most cases can be diagnosed with confidence by light microscopic features (Fig. 27.5). Four types of atypical melanocytes have been described in conjunctival melanoma: small polyhedral, spindle, balloon, and round epithelioid cells with eosinophilic cytoplasm.<sup>11</sup> Invasive melanoma is often accompanied by intraepithelial PAM with atypia, which may be the precursor to the melanoma (Fig. 27.6). Any breaching of the basement membrane by atypical melanocytes in PAM with atypia should be considered as invasive melanoma. Other melanomas may be associated with conjunctival nevus. The common presence of cystic and solid epithelial inclusions in compound conjunctival nevi may confuse a pathologist without experience in ophthalmic pathology, who may consider these findings to be signs of malignancy. If in doubt, pathologists can apply immunohistochemical stains such as HMB-45 or Melan-A, either individually or in a cocktail, to demonstrate melanocytes.<sup>15-17</sup>



**Fig. 27.5** Low-magnification histological picture showing thick conjunctival melanoma involving the specimen's margin. (Hematoxylin & eosin, original magnification  $\times 4$ .)



**Fig. 27.6** This photomicrograph illustrates conjunctival melanoma arising in the context of PAM with atypia. Note the lack of maturation or architectural organization from top to bottom, and the presence of atypical intraepithelial melanocytes that do not appear to be cohesive or to have any architectural relationship with the epithelial cells. (Hematoxylin & eosin, original magnification  $\times 20$ .)

There are several histopathologic features that predict an adverse prognosis for conjunctival melanoma; the most important are the presence of pagetoid spread, mixed cell tumors versus spindle cell tumors, histologic evidence of lymphatic invasion, high numbers of mitotic figures, and a high cell proliferation index using immunostainings such as PCNA.<sup>1,2</sup> The presence of PAM itself was not found to be a useful prognostic indicator.<sup>2</sup>

The pathologist's report should include information to guide the ophthalmic surgeon through management of the patient. Specifically, mention should be made of the adequacy of the lateral and deep margins. The major prognostic factor predictive of metastasis is the depth of invasion, measured with an ocular micrometer from the top of the epithelium to the deepest point of invasion. Thin lesions ( $<0.8$  mm thick) seldom give rise to metastases unless lymphatic involvement is identified (see below).

## TREATMENT

The primary treatment of conjunctival melanoma is excision of the entire tumor with wide surgical margins of 3–5 mm. When deep limbal and scleral involvement is suspected, scleroconjunctivectomy should be considered.<sup>18</sup>

Most surgeons will add an adjuvant treatment to the primary excision. The most common supplemental treatment is cryotherapy to the surgical margins and/or the surgical bed.<sup>10</sup> Others advocate supplemental brachytherapy, usually using  $\beta$  irradiation.<sup>19</sup> Some surgeons use absolute alcohol to devitalize corneal epithelial cells adjacent to a limbal melanoma before excision.<sup>18</sup>

Areas of PAM with atypia, either around the excised melanoma or distant from it, must be treated as they can be the origin of recurrent melanomas. The PAM can be treated by surgery, cryotherapy, or brachytherapy, and in recent years topical chemotherapy using mitomycin C has been advocated (see Chapter 26).

When wide excision is performed, reconstruction of the conjunctiva is often needed. Such reconstruction can be achieved by transplanting mucosal tissue either from the mouth or from the contralateral conjunctiva. The successful use of amniotic membrane after the excision of large conjunctival melanoma, in order to prevent conjunctival scars and symblepharon, has been described.<sup>20</sup>

Conjunctival melanoma is not radiosensitive. Therefore, brachytherapy should not be used as sole treatment.<sup>19</sup> Similarly, cryotherapy, using a double freeze–thaw cycle, should not be used alone but rather as adjuvant therapy to surgical excision, and can also be used prior to excision. In recent years proton beam radiotherapy was used to treat extensive conjunctival melanoma as an alternative to exenteration.<sup>21</sup>

In the past, exenteration was the preferred treatment for conjunctival melanoma, or even when only PAM was present. However, a review of the literature of recent years has failed to demonstrate the advantages of mutilating radical surgery over a conservative approach.<sup>22</sup> Therefore, exenteration of the orbit, including the eyelids in order to include the palpebral and forniceal conjunctiva, is currently reserved only as a palliative treatment for advanced stages of conjunctival melanoma in its aggressive phase. Exenteration will usually not be performed when there is evidence of metastatic disease.

Regional lymph node metastasis is associated with a poor prognosis;<sup>22</sup> however, it has been found that regional metastases are linked with longer survival rates than systemic metastases.<sup>23</sup> Therefore, in recent years preoperative lymphoscintigraphy and sentinel lymph node biopsy have been advocated in order to evaluate the metastatic status of these patients, which is a very significant prognostic factor



for tumor recurrence and for survival.<sup>24</sup> Regional metastases can be treated by lumpectomy and adjuvant radiotherapy.<sup>22</sup> Most patients with disseminated conjunctival melanoma are treated by systemic chemotherapy, with the possible combination of interferon or interleukin-2. However, the prognosis is poor and life expectancy only a few months.

## CLINICAL COURSE

Conjunctival melanoma may spread locally in the conjunctiva before sending regional and systemic metastases. 'In-transit' metastases of conjunctival melanoma, which are believed to be local lymphatic spread within the conjunctiva, have been described. 'Local metastasis' due to dissemination of melanoma cells during the time of tumor excision has also been reported. Spreading of conjunctival melanoma through the nasolacrimal duct to the nasal cavity and paranasal sinuses has been attributed to the shedding of exfoliated melanoma cells in the tear film, or by direct extension or as regional hematogenous metastases.<sup>1</sup> Very rare cases of conjunctival melanoma invade the eyeball or extend directly into the orbit.<sup>1</sup>

Local recurrence of conjunctival melanoma has been reported in 56–65% of patients. About half of them experienced more than one recurrence.<sup>1,3,4,25</sup> The mean interval between the first treatment and the first recurrence was 2.5 years. Patients treated by surgical excision alone have more recurrences than those receiving adjuvant treatment

as well. Patients with multifocal disease, usually originating in PAM with atypia, are more likely to develop recurrences than patients with one tumor. Other risk factors for recurrence are location of the melanoma other than in the limbus, and the involvement of surgical margins.<sup>25</sup> Local recurrences are managed by the same methods used for the primary melanoma.

Conjunctival melanoma can metastasize to any organ in the body. However, the most common primary location of metastases is regional: the preauricular and submandibular lymph nodes. In about half of patients with metastases regional lymph node metastases are detected before systemic ones.<sup>23,25</sup> Other common locations are the brain, liver, and lung.<sup>25</sup>

According to several studies, the conjunctival melanoma-related mortality rate is 12–19% in 5 years and 23–30% in 10 years.<sup>1,3,4,19,25,26</sup> There are many risk factors for metastatic spread of conjunctival melanoma, the most important being tumor location and tumor thickness. Unfavorable tumor locations with a high risk of metastatic spread are the palpebral conjunctiva, fornices, plica, caruncle, and lid margins, which means any non-limbal or non-bulbar conjunctival tumors.<sup>26</sup>

Regarding a critical thickness that may serve as a prognostic factor, according to various studies the values that are found are between 0.8 and 4.0 mm.<sup>1,23,25,26</sup> It can be concluded that there is a continuous worsening in prognosis with increasing tumor thickness, with no critical threshold.

## REFERENCES

- Seregard S. Conjunctival melanoma. *Surv Ophthalmol* 1998; 42: 321–350.
- Folberg R, McLean IW, Zimmerman LE. Malignant melanoma of the conjunctiva. *Hum Pathol* 1985; 16: 136–143.
- De Woolf-Rouendaal D. Conjunctival melanoma in the Netherlands: a clinicopathological and follow-up study. [Thesis] Katwijk, All in BV, 1990.
- Seregard S, Kock E. Conjunctival malignant melanoma in Sweden 1969–91. *Acta Ophthalmol* 1992; 70: 289–296.
- Yu GP, Hu DN, McCormick S et al. Conjunctival melanoma: Is it increasing in the United States? *Am J Ophthalmol* 2003; 135: 800–806.
- Isager P, Osterlind A, Engholm G et al. Uveal and conjunctival malignant melanoma in Denmark, 1943–1997: Incidence and validation study. *Ophthalm Epidemiol* 2005; 12: 223–232.
- Grossniklaus HE, Green WR, Luckenbach M et al. Conjunctival lesions in adults. A clinical and histopathologic review. *Cornea* 1987; 6: 78–116.
- McDonnell JM, Carpenter JD, Jacobs P et al. Conjunctival melanocytic lesions in children. *Ophthalmology* 1989; 96: 986–993.
- Pane AR, Hirst LW. Ultraviolet light exposure as a risk factor for ocular melanoma in Queensland, Australia. *Ophthalm Epidemiol* 2000; 7: 159–167.
- Jakobiec FA, Rini FJ, Fraunfelder FT et al. Cryotherapy for conjunctival primary acquired melanosis and malignant melanoma. Experience with 62 cases. *Ophthalmology* 1988; 95: 1058–1070.
- Jakobiec FA, Folberg R, Iwamoto T. Clinicopathologic characteristics of premalignant and malignant melanocytic lesions of the conjunctiva. *Ophthalmology* 1989; 96: 147–166.
- Folberg R, Jakobiec FA, Bernardino VB et al. Benign conjunctival melanocytic lesions. Clinicopathologic features. *Ophthalmology* 1989; 96: 436–461.
- Kiratli H, Shields CL, Shields JA et al. Metastatic tumours to the conjunctiva: report of 10 cases. *Br J Ophthalmol* 1996; 80: 5–8.
- Rummelt V, Naumann GO, Folberg R et al. Surgical management of melanocytoma of the ciliary body with extrascleral extension. *Am J Ophthalmol* 1994; 117: 169–176.
- Heegaard S, Jensen OA, Prause JU. Immunohistochemical diagnosis of malignant melanoma of the conjunctiva and uvea: comparison of the novel antibody against Melan-A with S-100 protein and HMB-45. *Melanoma Res* 2000; 19: 350–354.
- Sharara NA, Alexander RA, Luthert PJ et al. Differential immunoreactivity of melanocytic lesions of the conjunctiva. *Histopathology* 2001; 39: 426–431.
- Iwamoto S, Burrows RC, Grossniklaus HE et al. Immunophenotype of conjunctival melanomas: Comparisons with uveal and cutaneous melanomas. *Arch Ophthalmol* 2002; 129: 1625–1629.
- Shields JA, Shields CL, dePotter P. Surgical management of conjunctival tumors. The 1994 Lynn B. McMahan Lecture. *Arch Ophthalmol* 1997; 115: 808–815.
- Lommatzsch PK, Lommatzsch RE, Kirsch I et al. Therapeutic outcome of patients suffering from malignant melanoma of the conjunctiva. *Br J Ophthalmol* 1990; 74: 615–619.
- Dalla Pozza G, Ghirlando A, Busato F et al. Reconstruction of conjunctiva with amniotic membrane after excision of large conjunctival melanoma: a long-term study. *Eur J Ophthalmol* 2005; 15: 446–450.
- Wuestemeyer H, Sauerwein W, Meller D et al. Proton radiotherapy as an alternative to exenteration in the management of extended conjunctival melanoma. *Graefes Arch Clin Exp Ophthalmol* 2006; 244: 438–446.
- Tatla T, Hungerford J, Plowman N et al. Conjunctival melanoma: The role of conservative surgery and radiotherapy in regional metastatic disease. *Laryngoscope* 2005; 115: 817–822.
- Tuomaala S, Kivela T. Metastatic pattern and survival in disseminated conjunctival melanoma: Implications for sentinel lymph node biopsy. *Ophthalmology* 2004; 111: 816–821.
- Amato M, Esmali B, Ahmadi MA et al. Feasibility of preoperative lymphoscintigraphy for identification of sentinel lymph node in patients with conjunctival and periocular skin malignancies. *Ophthalm Plast Reconstr Surg* 2003; 19: 102–106.
- Shields CL, Shields JA, Gunduz K et al. Conjunctival melanoma: Risk factors for recurrence, exenteration, metastasis and death in 150 consecutive patients. *Arch Ophthalmol* 2000; 118: 1497–1507.
- Paridaens AD, Minassian DC, McCartney AC et al. Prognostic factors in primary malignant melanoma of the conjunctiva: a clinicopathological study of 256 cases. *Br J Ophthalmol* 1994; 78: 252–259.

# Conjunctival stromal tumors

Jacob Pe'er

## INTRODUCTION

The conjunctival stroma contains various tissue elements, such as vascular, fibrous, neural, and others; naturally, benign and malignant tumors may originate from these types of tissue (Table 28.1). However, conjunctival stromal tumors are rare. This chapter describes the salient features of conjunctival stroma tumors according to their tissue of origin.

## VASCULAR TUMORS

**Pyogenic granuloma** The term 'pyogenic granuloma' is a misnomer, as it is neither pyogenic nor granulomatous. It is granulation tissue, although some consider it a polypoid form of acquired capillary hemangioma.<sup>1</sup> Pyogenic granuloma is a fibrovascular response to a tissue insult, such as surgical or non-surgical trauma or inflammation, although spontaneous pyogenic granulomas have also been reported. Pyogenic granuloma is commonly observed in the conjunctiva after chalazion surgery, strabismus surgery, excision of conjunctival lesions, and in the anophthalmic socket following enucleation, when it is considered an aberrant wound-healing response.

**Clinical features** Pyogenic granuloma has been reported in every part of the conjunctiva and even in the limbus and the cornea, mostly following corneal epithelial defects.<sup>2</sup> Pyogenic granuloma appears as a fleshy, elevated, red, richly vascularized mass (Fig. 28.1A).

**Histopathologic features** Pyogenic granuloma is composed of granulation tissue with marked chronic inflammation and proliferation of small, mostly capillary-sized blood vessels (Fig. 28.1B).

**Treatment** Pyogenic granuloma often responds to topical corticosteroids when diagnosed early, but many cases require surgical excision.

**Capillary hemangioma** appears during early infancy, and, like its counterpart in the skin, may grow over several months and then regress spontaneously over several years.

**Clinical features** Capillary hemangioma is a distinct or diffuse red, elevated conjunctival lesion.

**Histopathologic features** Like capillary hemangiomas in other locations, it shows numerous capillary channels and proliferation of endothelial cells.

**Treatment** Usually no treatment is needed and the child should only be observed. There are rare cases in which surgical excision or local or systemic corticosteroids are employed.<sup>3</sup>

**Cavernous hemangioma** presents as a red or blue lesion in the deep conjunctival stroma in children.<sup>3</sup> Histologically, like such lesions in other locations it is composed of large blood-filled spaces, lined by endothelial cells and separated by fibrous septae. It can be managed by surgical excision.

## Varix and racemose hemangioma

**Conjunctival varix** and racemose hemangioma are rare vascular malformations of the conjunctiva. Varix is a mass of dilated venous channels that may range from a single channel to complex venous channels. Some consider it to be in the spectrum of lymphangioma. Management should be conservative, by observation and symptomatic treatment. Surgical excision bears the risk of prolonged bleeding.<sup>3</sup>

**Conjunctival racemose hemangioma** is a lesion of dilated arteries and veins communicating directly without a capillary bed between them. It appears as a loop of dilated vessels in the conjunctival stroma. It should be managed conservatively by observation. Wyburn-Mason syndrome should be ruled out in such cases.<sup>3</sup>

**Hemangiopericytoma** is very rare in the conjunctiva. It appears as an elevated, pedunculated red mass. Histologically, it is a solid tumor composed of spindle-shaped pericytes and small blood vessels.<sup>4</sup> Treatment is by complete surgical excision with tumor-free margins and close follow-up.

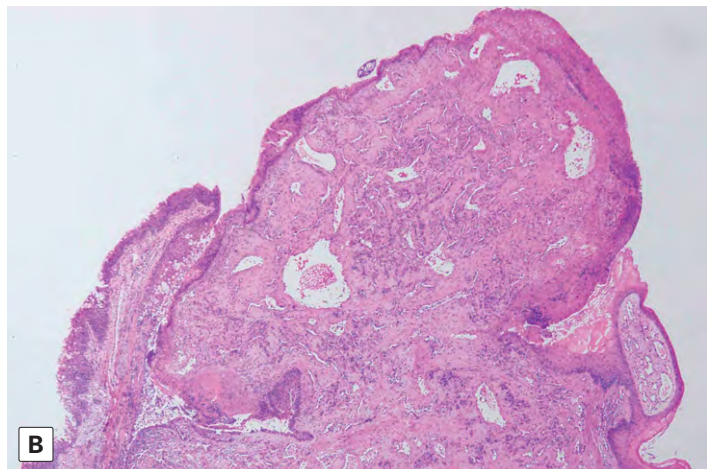
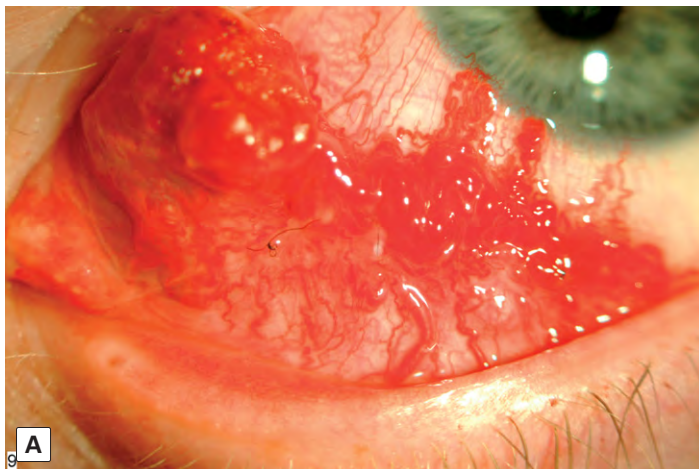
**Kaposi's sarcoma** Before the AIDS era, Kaposi's sarcoma in general, and in the conjunctiva in particular, was a rare tumor that mainly affected elderly and immunosuppressed patients. Since the eruption of the AIDS epidemic, this malignant tumor is diagnosed much more frequently in AIDS patients. Sometimes the conjunctival Kaposi's sarcoma is the first sign of AIDS.<sup>8</sup>

**Clinical features** Kaposi's sarcoma appears as a single or multiple red conjunctival mass.

**Histopathologic features** The tumors are composed of malignant spindle-shaped cells with elongated oval nuclei, well-formed capillary channels, and vascular slits containing blood but no definite endothelial lining.

**Table 28.1 Classification of stromal tumors of the conjunctiva**

Category	Subtypes	
Vascular tumors	Capillary hemangioma	Cavernous hemangioma
	Varix	Racemose malformation
	Hemangiopericytoma	Kaposi's sarcoma
	Lymphangiectasia	Lymphangioma
	Malignant hemangioendothelioma	
Fibrous tumors	Fibroma	Nodular fasciitis
	Benign fibrous histiocytoma	Malignant fibrous histiocytoma
Neural tumors	Neurofibroma (localized)	Neurofibroma (diffuse)
	Schwannoma (neurilemmoma)	Granular cell tumor
Histiocytic tumors	Xanthoma	Juvenile xanthogranuloma
	Reticulohistiocytoma	
Myxoid tumors	Myxoma	
Myogenic tumors	Rhabdomyosarcoma	
Lipomatous tumors	Lipoma	Herniated orbital fat
	Liposarcoma	
Lymphoproliferative tumors	Benign reactive lymphoid hyperplasia	Lymphoma
	Leukemic infiltrates	
Choristomas	Dermoid	Dermolipoma
	Osseous choristoma	Lacrimal gland choristoma
	Complex choristoma	
Metastatic tumors		
Secondary tumors		



**Fig. 28.1** Pyogenic granuloma. A 31-year-old man with a 3-week history of a rapidly growing recurrent conjunctival vascular growth in the inferonasal conjunctival fornix. Note prominent vascularity (A). Polypoid lesion with lobular pattern of capillary proliferation. The vessels are variably dilated (B). (Original magnification  $\times 4$ ).

**Treatment** Localized tumors can be excised surgically. However, Kaposi's sarcoma is responsive to chemotherapy and low-dose radiation.<sup>9</sup>

## LYMPHANGIECTASIA AND LYMPHANGIOMA

**Lymphangiectasia** When lymphatic channels in the conjunctiva are dilated and prominent, the condition is called lymphangiectasia.

**Clinical features** As a result of the communication with conjunctival veins these dilated channels may be filled with blood, and if so are termed 'hemorrhagic lymphangiectasia' (lymphangiectasia hemorrhagica conjunctivae of Leber).<sup>5</sup> The surrounding conjunctiva appears edematous, and occasionally associated subconjunctival hemorrhage is present. This phenomenon can occur spontaneously or after trauma or inflammation. Congenital cases have been reported.



**Histopathologic features** The lesion shows markedly dilated lymphatics that may be filled with blood, partially surrounded by scattered inflammatory cells. The phenomenon is intermittent, with resolution between episodes.

**Treatment** Usually no treatment is required.

**Conjunctival lymphangioma** is a benign tumor of the lymphatic vessels that usually appears in the first decade of life. It can occur as an isolated conjunctival lesion, but more often represents a superficial component of orbital lymphangioma.

**Clinical features** Conjunctival lymphangioma appears as a multiloculated lesion composed of dilated cystic spaces. These spaces may contain clear fluid, but often some of them contain blood and are called ‘chocolate cysts.’

**Histopathologic features** Conjunctival lymphangioma shows dilated lymphatic channels filled with lymph and/or blood, lined by endothelium and separated by thin walls.

**Treatment** Treatment of lymphangioma is difficult, and surgical excision or radiotherapy usually do not eradicate the tumor. Carbon dioxide laser<sup>6</sup> and brachytherapy<sup>7</sup> have been used to treat conjunctival lymphangioma, with partial success.

## FIBROUS TUMORS

### Fibroma

**Clinical features** Fibroma of the conjunctiva is rare.<sup>10</sup> It is generally a slowly-progressing acquired white stromal tumor in adults, and may range from well-circumscribed lesion to a multinodular lesion. One case of malignant fibrosarcoma has also been reported.<sup>11</sup>

**Histopathologic features** The tumor is composed of compact fibroblasts and collagen. Rare variants such as elastofibroma oculi, giant cell angiofibroma, and solitary fibrous tumor have been described.<sup>12</sup>

**Treatment** Conjunctival fibroma is treated by complete surgical excision.

**Benign and malignant fibrous histiocytoma (FH)** of the conjunctiva can be benign, locally aggressive, or malignant. FH generally occurs in adults, but a case of FH in a child with xeroderma pigmentosum has also been reported.

**Clinical features** Conjunctival FH appears as an amelanotic mass that can range from well-circumscribed to diffuse. It often presents in the limbus.<sup>13</sup>

**Histopathologic features** FH shows a mixture of spindle-shaped fibroblasts, often arranged in a storiform pattern, and lipid-laden histiocytes. Conjunctival FH with benign histological appearance may show a malignant clinical course. Malignant FH of the conjunctiva is extremely rare and shows marked pleomorphism, many mitotic figures, and multinucleated giant cells. Malignant FH is accepted as originating from primitive mesenchymal cells with the capacity to differentiate along either or both histiocytes and fibroblasts.<sup>14</sup> Malignant

FH can metastasize to regional lymph nodes and hematogenously to distant organs, causing death.

**Treatment** Whereas benign FH can be treated by complete surgical excision, malignant FH should be treated by radical surgery, which may include exenteration and radical dissection of regional lymph nodes.

**Nodular fasciitis** is a benign rare nodular tumor of unknown cause that can occur at any age.

**Clinical features** Nodular fasciitis appears as a solitary white episcleral enlarging nodule at the limbus or over the sclera anterior to the insertion of one of the rectus muscles, and can cause discomfort or pain. The nodule may grow quickly and show signs of inflammation. It is thought to originate from Tenon’s capsule.<sup>15</sup>

**Histopathologic features** The lesion tends to be round or oval and is not encapsulated. It is composed of bundles of fibroblasts that vary in configuration from spindle to stellate. There is a variable amount of intercellular myxoid ground substance interspersed with slit-like vascular spaces or capillaries and scanty infiltration of chronic inflammatory cells. Numerous mitotic figures can lead to its being misdiagnosed as a sarcoma.

**Treatment** The prognosis is excellent and complete excision is usually sufficient, although recurrence can occur.

## NEURAL TUMORS

**Neurofibroma** is a peripheral nerve sheath tumor that can occur in the conjunctival stroma as a solitary circumscribed diffuse or plexiform mass.<sup>16</sup> The solitary type usually is not associated with systemic disease, but the latter is generally associated with neurofibromatosis type 1 (von Recklinghausen’s disease).

**Clinical features** The solitary neurofibroma is a pink-yellow growing mass, whereas the plexiform neurofibroma is diffuse.

**Histopathologic features** Neurofibroma demonstrates benign proliferation of Schwann cells, axons, and endoneurial fibroblasts, which may be difficult to differentiate from other spindle cell tumors.

**Treatment** Solitary tumors are usually treated by complete surgical excision. Plexiform neurofibroma may be difficult to excise completely. In such cases, debulking of the tumor is performed.

**Neurilemmoma (schwannoma)** of the conjunctiva is a benign rare ocular tumor that can arise from any part of the conjunctiva – bulbar, forniceal, or palpebral.<sup>17</sup>

**Clinical features** Neurilemmoma (schwannoma) appears as a pink-yellow elevated mass in the conjunctival stroma.

**Histopathologic features** The tumor is the result of proliferation of Schwann cells of a peripheral nerve sheath, and is composed of spindle cells that may be arranged in Antoni A or Antoni B pattern.

**Treatment** Conjunctival neurilemmoma is treated by complete excision within the tumor capsule. Incomplete excision may lead to recurrence. Malignant schwannoma has not been recorded in the conjunctiva.

**Granular cell tumor** Conjunctival granular cell tumor, known also as myoblastoma, is a very rare benign tumor of disputed origin.<sup>18</sup> Originally thought of as having a striated muscle origin, the recent suggestion is that it is of neural derivation, probably from Schwann cells.

**Clinical features** The tumor appears as a pink, elevated smooth mass of the conjunctival stroma, indistinguishable from other well-circumscribed tumors.

**Histopathologic features** The tumor is composed of groups and cords of cells with small round to oval nuclei and voluminous cytoplasm containing fine eosinophilic granules.

**Treatment** The tumor should be completely excised.

## HISTIOCYTIC TUMORS

**Xanthoma** Conjunctival xanthoma appears as a yellow subepithelial mass on the epibulbar surface. In a case of xanthoma disseminatum, in which multiple lesions are found, lesions have been described in the limbus of both eyes.<sup>19</sup> Histopathologically, the lesion shows subepithelial infiltrate of lipid-laden histiocytes, eosinophils and Touton giant cells.

### Xanthogranuloma

**Clinical features** Conjunctival involvement in juvenile xanthogranuloma usually occurs as a solitary orange-pink stromal mass, usually near the limbus.<sup>20</sup> Sometimes associated systemic findings may not be present.<sup>20</sup> Bilateral conjunctival xanthogranuloma in adults has also been recorded.<sup>21</sup>

**Histopathologic features** The lesions show typical findings of histiocytes and Touton's giant cells; in addition, lymphocytes, plasma cells, and eosinophils can be found.

**Treatment** Most lesions are treated by excision. When xanthogranuloma is suspected clinically, it may be observed for spontaneous resolution or can be treated by topical or systemic corticosteroids.

### Reticulohistiocytoma

**Clinical features** Reticulohistiocytoma is a rare benign conjunctival lesion that usually occurs as an isolated skin nodule or as part of a systemic disorder known as 'multicentric reticulohistiocytosis.' The cases reported in the ocular surface were single, painless masses localized to the cornea and limbus without systemic disease.<sup>22</sup>

**Histopathologic features** The lesions are composed predominantly of large mononuclear and a few multinucleated cells with finely granular 'ground-glass' cytoplasm and large nuclei with prominent nucleoli.

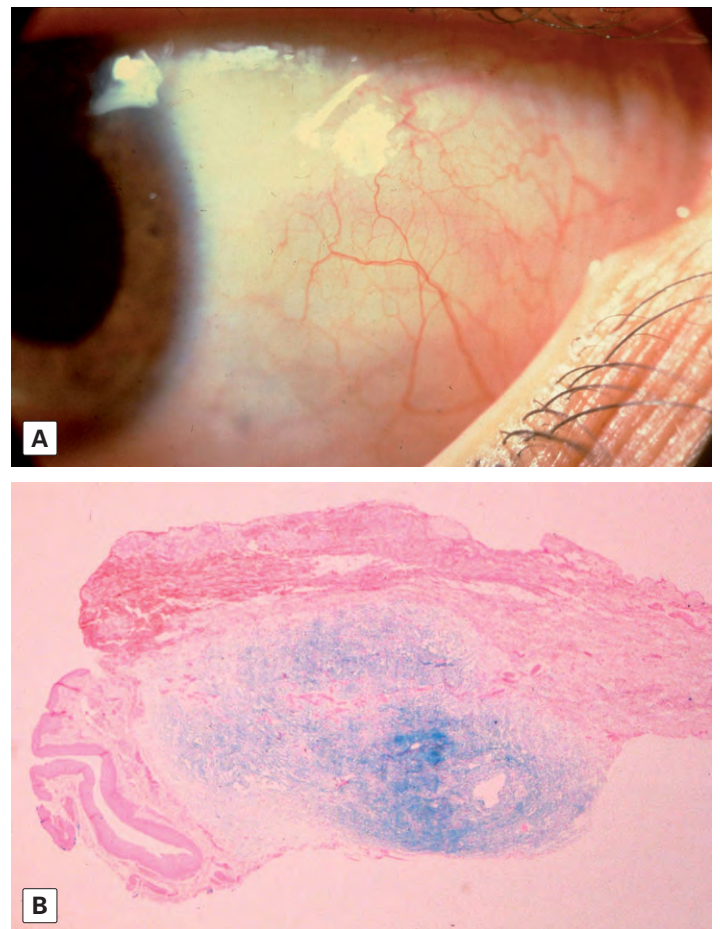
**Treatment** The lesions are treated by complete excision.

## MYXOID TUMORS (MYXOMA)

**Clinical features** Conjunctival myxoma is a rare benign stromal tumor that occurs in adults. It appears as a slowly growing asymptomatic, freely movable, usually unilateral solitary lesion in any part of the conjunctiva, but primarily located in the temporal bulbar conjunctiva<sup>23</sup> (Fig. 28.2A). The lesion may appear pink or fleshy in color. Eyelid and conjunctival myxoma may be associated with Carney's complex (Chapter 22).

**Histopathologic features** The tumors are well circumscribed, located in the conjunctival substantia propria, and covered by conjunctival epithelium. They are hypocellular and composed of stellate and spindle-shaped cells, some with small intracytoplasmic and intranuclear vacuoles that represent dilated cisternae of rough-surfaced endoplasmic reticulum. The stroma contains abundant mucoid material, which stains positively for hyaluronidase-sensitive mucopolysaccharides, and sparse reticulin and delicate collagen fibers (Fig. 28.2B). Scattered mast cells are found in many lesions.

**Treatment** Simple surgical excision is curative.



**Fig. 28.2** Conjunctival myxoma appearing as a cyst-like mass in nasal bulbar conjunctiva of the right eye (A). Histologically, myxoma is a mass of very loose connective tissue in the conjunctival stroma containing abundant hyaluronidase-sensitive mucopolysaccharides stained positively with Alcian blue (B). (Original magnification  $\times 4$ ).

**MYOGENIC TUMORS**

**Rhabdomyosarcoma** is the most common childhood primary orbital malignancy, but its occurrence in the conjunctiva alone, without orbital involvement, is rare.

**Clinical features** Rhabdomyosarcoma appears as a pink, rapidly growing conjunctival vascular mass. The initial clinical manifestation may be a non-inflamed pedicle of soft tissue, but occasionally swelling and erythema precede visible tumor formation.

**Histopathologic features** Most conjunctival rhabdomyosarcomas are of the embryonal type, and as a submucosal tumor, some call it 'botryoid' rhabdomyosarcoma (sarcoma botryoides).<sup>24,25</sup>

**Treatment** Complete surgical excision is recommended when this is possible without affecting ocular function. Adjuvant therapy with chemotherapy and radiotherapy is also indicated (Chapter 97).

**Other myogenic tumors** Some other myogenic tumors of the conjunctiva, such as infantile myofibromatosis and leiomyosarcoma, have been very rarely recorded.<sup>26</sup>

**LIPOMATOUS TUMORS**

True lipomatous tumors of the conjunctiva are very rare. On the other hand, herniated orbital fat under the conjunctiva is not rare and may be mistaken for a lipomatous tumor. Dermolipoma is discussed later in this chapter.

**Lipoma** Conjunctival lipoma occurs in adults and appears as a yellow-pink stromal mass. Histopathologically, it is usually of the pleomorphic type and shows variably sized adipocytes surrounded by stellate cells. The stroma shows loose myxoid connective tissue. Floret giant cells and nuclear pyknosis have been described in this tumor. Mitotic activity is absent.<sup>27</sup>

**Liposarcoma** of the conjunctiva shows clinical features similar to lipoma. Histopathologically, the tumor reveals numerous neoplastic cells containing stellate and hyperchromatic nuclei.<sup>28</sup> The cytoplasm of these cells contains vacuoles resembling lipid droplets, and signet-ring type cells can be observed. The stroma may be myxomatous. The tumor is treated by complete surgical excision.

**LYMPHOPROLIFERATIVE TUMORS**

The conjunctival lymphoid tumors may be subdivided into reactive lymphoid hyperplasia, atypical lymphoid hyperplasia, and the more common conjunctival lymphoma. The conjunctival lymphoid tumors belong to the group of lymphoid tumors that affect the orbit and eyelids (Chapter 95).<sup>29</sup>

**Clinical features** Conjunctival lymphoid tumors can occur as an isolated lesion of the conjunctiva, but in up to one-third of patients it is a manifestation of systemic lymphoma, which can be present simultaneously with the conjunctival disease or during follow-up. Lymphoid tumors may involve additional ocular sites, mainly the orbit, but simultaneous involvement of the eyelid and uvea has also been reported.<sup>30</sup>

**Symptoms** Most patients diagnosed as having lymphoproliferative conjunctival lesions are symptomatic at the time of diagnosis.

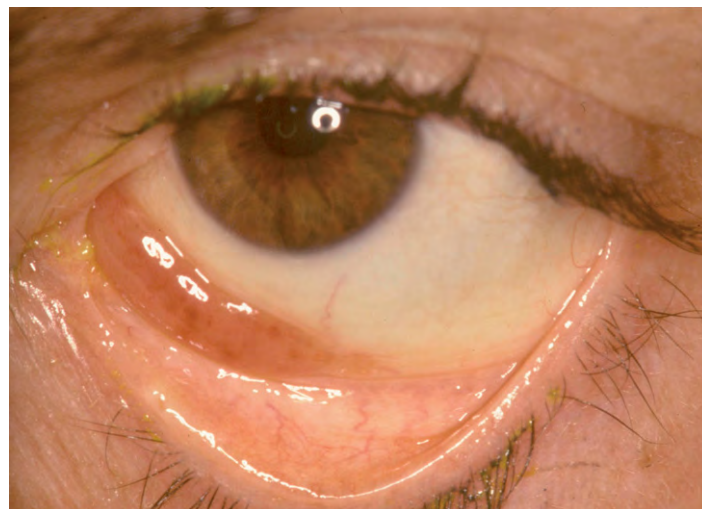
Symptoms include a conjunctival mass, or irritation, and, less commonly, ptosis, epiphora, blurred vision, proptosis and diplopia. Some patients are asymptomatic.<sup>30</sup>

**Signs** The lymphoproliferative tumor of the conjunctiva appears as a diffuse, slightly elevated pink mass, resembling smoked salmon, hence it is termed 'salmon patch' (Fig. 28.3). Most conjunctival lymphoid tumors are located at the bulbar conjunctiva and fornix, usually hidden by the eyelid in the superior and inferior quadrants and not in the horizontal exposed parts of the bulbar conjunctiva or the limbus. Some of these tumors appear in the caruncle or plica semilunaris, but almost never in the palpebral conjunctiva.

**Histopathologic features** As it is not possible to differentiate between benign and malignant conjunctival lymphoid tumors by clinical examination, biopsy is needed to establish the diagnosis. The vast majority of conjunctival lymphomas are non-Hodgkin's B-cell lymphoma, mostly of low grade; T-cell lymphoma is extremely rare in the conjunctiva. The major lymphoma subtypes, according to the Revised European and American Lymphoma (REAL) classification, include extranodal marginal zone B-cell lymphoma, diffuse large B-cell lymphoma, follicular lymphoma, plasmacytoma, lymphoplasmacytic lymphoma/immunocytoma, and mantle cell lymphoma.<sup>29</sup>

**Treatment** A systemic evaluation should be performed in order to exclude the presence of systemic lymphoma. Treatment modalities for conjunctival lymphoid tumors include excisional biopsy, cryotherapy, low-dose external beam radiation (2000–4000 cGy), local injections of interferon (IFN)- $\alpha$ , and brachytherapy using ophthalmic applicator or radioactive plaque. When systemic lymphoma is diagnosed, chemotherapy is used. Recently, intravenous anti-CD20 monoclonal antibody (rituximab) has been used successfully in treating relapsed mucosa-associated lymphoid tissue (MALT) lymphoma of the conjunctiva.<sup>31</sup>

**Prognosis** Local treatment is usually effective, but semi-annual systemic evaluation should be performed in case of possible recurrence in extranodal sites. In one study, systemic lymphoma was eventually discovered in 15% of patients at 5 years and in 28% at 10 years.<sup>30</sup>



**Fig. 28.3** 'Salmon patch' lymphoma lesion in the lower fornix and bulbar conjunctiva of the left eye.



Because most conjunctival lymphomas are low grade, the mortality rate is low. The main prognostic factors for developing systemic lymphoma are the presence of the lymphoma in the fornix or midbulbar conjunctiva, as opposed to the limbus, and the presence of multiple conjunctival tumors. Other factors are the stage of the disease at first presentation and the lymphoma subtype.

### LEUKEMIC INFILTRATES

Leukemic infiltration in the eye most commonly occurs in the choroid and retina, but conjunctival infiltration is also a well-recognized complication of many types of leukemia. Conjunctival involvement in leukemia shows myriad clinical presentations that can involve one or both eyes, have focal or diffuse infiltration of the substantia propria, can occur on the bulbar or palpebral conjunctiva, and can cause microvascular changes due to hyperviscosity (leukostasis) from markedly elevated leukemic cell counts. Conjunctival lesions have also been reported as the presenting manifestation of acute leukemia in patients who were not recognized to have the disease, and in others they signified relapse.<sup>32</sup> Conjunctival leukemic involvement is consistent with good visual acuity, with no reports of vision reduction associated with the conjunctival infiltration; however, it portended a poor prognosis, with a median survival of 3 months. Although clinical reports of conjunctival leukemia in the literature are relatively uncommon, autopsy studies of leukemic patients indicate that many harbor unsuspected disease, and that most cases of conjunctival leukemia are probably subclinical or go unrecognized.

**Clinical features** Conjunctival leukemia occurs most commonly in patients with acute leukemia. Leukemic infiltrations are often firm and not tender, may appear as a pink smooth mass, and are usually associated with small areas of hemorrhage.<sup>32</sup>

**Histopathologic features** Clinicopathologic studies indicate that conjunctival leukemic lesions are cellular invasions that occur at all levels of the substantia propria; they can be diffuse or patchy, and are generally localized along blood vessels.

**Treatment** The treatment includes various combinations of chemotherapy and, commonly, local radiotherapy, with a good local response in most cases. However, patients who achieve a complete local response may eventually die of the systemic disease. These patients die from refractory leukemia or leukemia-related complications, most commonly from infections.

### CHORISTOMA

Choristomas are congenital lesions representing normal tissue in an abnormal location. When the lesion is composed of one type of tissue it is considered to be a simple choristoma; when combinations of displaced tissue are involved, it is termed 'complex choristoma.' Epibulbar choristomas are the most common epibulbar tumors in children.<sup>33</sup> Among them, dermoids and dermolipomas are very common. Epibulbar choristomas affect the cornea, limbus, or subconjunctival space, and range in appearance from a small, flat lesion to large masses filling most of the epibulbar region. They often can cause astigmatism. Epibulbar choristomas can affect other parts of the eye and orbit and may be associated with coloboma, Goldenhar's syndrome or organoid nevus syndrome (Chapter 66).

**Dermoid** Epibulbar dermoid is a well-circumscribed firm, solitary congenital mass that involves the bulbar conjunctiva and often the corneoscleral limbus (Fig. 28.4). Rarely, more than one is found.

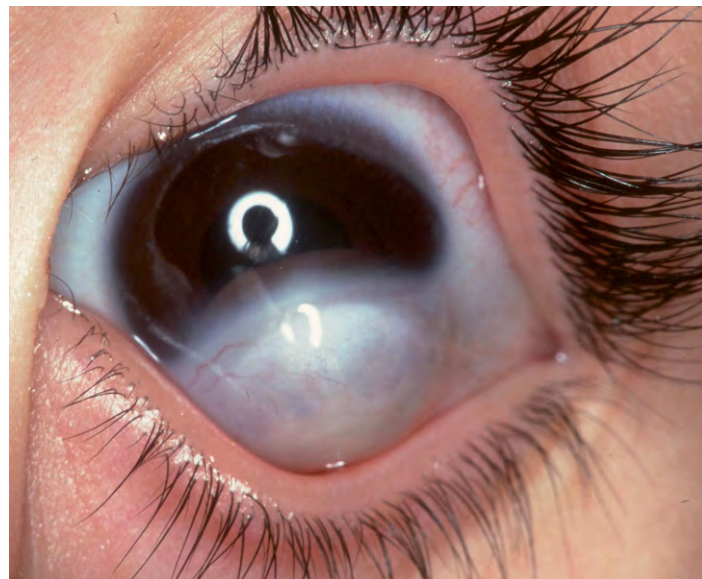
**Clinical features** Conjunctival dermoid is usually a yellow-white solid mass and sometimes fine hairs protrude from the lesion. The size of epibulbar dermoids is variable, from the more common small limbal dermoid through large dermoids involving most or the entire corneal surface, to extensive dermoids that involve also the anterior chamber and the iris. The typical dermoid occurs in the inferotemporal limbus. It may be associated with Goldenhar's syndrome which, in addition to the epibulbar dermoid, may include preauricular skin appendages, vertebral anomalies, eyelid coloboma, hearing loss, and mandibular hypoplasia. Epibulbar dermoid, in addition to being a cosmetic blemish, can cause severe astigmatism and amblyopia.

**Histopathologic features** Epibulbar dermoid is a simple choristoma that consists of dense fibrous tissue covered by stratified squamous epithelium. It usually contains dermal elements such as hair follicles, sebaceous glands, sweat glands, and sometimes fatty tissue.

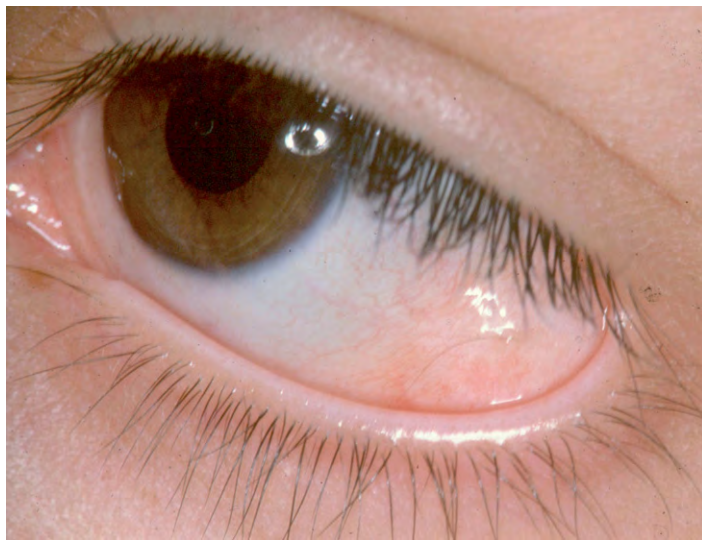**Treatment** When the epibulbar dermoid is very small and does not cause visual symptoms, it can be managed by observation alone. Larger dermoids can be managed by excision (lamellar keratosclerectomy) without or with conjunctival flap. In most cases a corneal scar will remain in the excision site. Lamellar or penetrating keratoplasty may be needed in advanced cases. When amblyopia is present, early treatment is advised.

### Dermolipoma

**Clinical features** Dermolipoma is a yellowish-tan, soft, fusiform tumor, usually localized to the temporal or superotemporal aspect of the conjunctiva, near the lateral canthus (Fig. 28.5). Although it is congenital, it may remain asymptomatic for years until detected when it protrudes from the superotemporal conjunctival fornix. Epibulbar dermolipoma often extends between the lateral and superior rectus



**Fig. 28.4** Limbal dermoid in the lower temporal aspect of the cornea and conjunctiva.



**Fig. 28.5** Dermolipoma in the temporal part of the bulbar conjunctiva.

muscles to lie close to the lacrimal gland. It may also extend posteriorly into the orbit or anteriorly toward the limbus.

**Histopathologic features** The epithelium on the surface of the dermolipoma is stratified squamous epithelium that may be partially keratinized. The stroma contains variable quantities of dense collagenous tissue and large amounts of adipose tissue, mainly in the deeper aspects of the lesion. Pilosebaceous structures are usually absent.

**Treatment** The majority of dermolipomas require no treatment, but when symptomatic or cosmetically blemished can be managed by simple excision of the anterior portion, or by excising the entire lesion, including the orbital part, through the conjunctival fornix.

### Osseous choristoma

**Clinical features** Epibulbar osseous choristoma is a rare solitary congenital lesion that most frequently presents as an isolated epibulbar lesion in the superotemporal quadrant, but may occur in other locations on the surface of the globe, or in association with other choristomatous lesions.<sup>34</sup> Bilateral lesions have been reported. The lesion may be freely movable or adherent to the bulbar conjunctiva and to the sclera. Not uncommonly, the lesion may involve the extraocular muscle sheath.

**Histopathologic features** The lesion is composed of mature, compact bone surrounded by connective tissue in which additional choristomatous elements may occasionally be found.

**Treatment** Epibulbar osseous choristoma typically remains undetectable until palpated by the patient, who feels the hard lesion. The diagnosis can be confirmed by ultrasonography or computed tomography, which illustrates the calcifications. The tumor is generally managed by periodic observation, but if it causes ocular inflammation, foreign body sensation, tearing, or is cosmetically unappealing, it may be treated by surgical excision. When lesions adhere to the sclera, superficial sclerectomy may be warranted. Imaging of the globe with the tumor may aid in avoiding iatrogenic globe perforation during surgical excision.<sup>34</sup>

### Lacrimal gland choristoma (ectopic lacrimal gland)

**Clinical features** Epibulbar lacrimal gland choristoma is a simple choristomatous congenital lesion that presents as an asymptomatic pink stromal mass, typically in the superotemporal or temporal parts of the conjunctiva, but it has also been described in the limbal area.<sup>35</sup>

**Histopathologic features** Lacrimal gland tissue, similar to normal lacrimal gland, is seen in the conjunctival stroma. Epibulbar complex choristoma may contain lacrimal gland tissue together with other tissue elements.<sup>36</sup>

**Treatment** Excision of the lesion usually suffices.

**Complex choristoma** is a congenital, unilateral lesion that contains tissue derived from two germ layers, ectoderm and mesoderm.

**Clinical features** Epibulbar complex choristoma has a variable clinical appearance, and ranges from a localized lesion to one that covers much of the epibulbar surface. A large pedunculated mass protruding through the eyelid aperture has been reported<sup>37</sup> (Fig. 28.6A). The choristoma may invade the cornea. The consistency and color depend on the types of tissue present in the choristoma: for example, dermal elements containing fat appear yellowish, whereas lacrimal tissue appears pink.

**Histopathologic features** Complex choristoma may include a variable combination of ectopic tissues, such as dermal tissue-containing adipose tissue, collagen and pilosebaceous structures, lacrimal gland, smooth muscle, cartilage, bone, nerves, and blood vessels. It may appear cystic (Fig. 28.6B). Epibulbar complex choristoma may be associated with organoid nevus syndrome, of which the most frequent cutaneous feature is the sebaceous nevus of Jadassohn.<sup>37</sup>

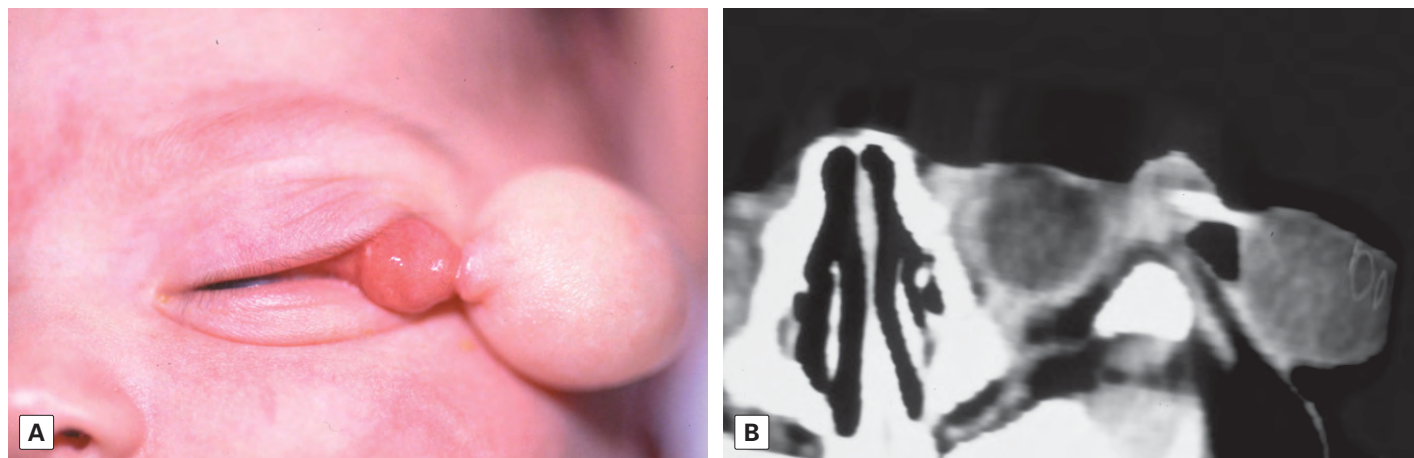
**Treatment** The management of epibulbar complex choristoma depends on the extent of the lesion and the symptoms it causes. Asymptomatic small lesions can be managed by observation, whereas large symptomatic lesions should be excised. Reconstruction of the ocular surface is sometimes needed. In very advanced cases enucleation may be necessary.

## METASTATIC AND SECONDARY TUMORS

**Metastatic tumors** of the conjunctiva are rare, and usually appear at an advanced stage of the systemic malignancy when there is evidence of other ocular and organ metastases.<sup>38</sup> Similar to sources of metastases in other ocular sites, the primary tumor is usually a carcinoma, in particular breast carcinoma or a cutaneous melanoma.

The metastatic carcinoma appears as a fleshy, yellow or pink, vascularized stromal tumor, whereas metastatic cutaneous melanoma may be pigmented. The metastasis may be located in any part of the conjunctiva and is usually solitary, but may be multiple. Conjunctival metastases are treated by excisional biopsy, radiotherapy, and/or chemotherapy. The survival time after diagnosis of the conjunctival metastasis is on the order of months.

**Secondary tumors** The conjunctiva may be secondarily involved by extraocular extension of intraocular tumors, and by extension of eyelid and orbital tumors.<sup>3</sup> The most important tumor in this category



**Fig. 28.6** Epibulbar complex choristoma in a 5-day-old child, associated with linear nevus sebaceous. A large pedunculated mass protrudes temporally through the left eyelid aperture (A). CT scan shows calcifications (bone) in the tumor base and a cyst-like structure in the polypoid mass (B).

is a sebaceous gland carcinoma of the eyelid, which often exhibits pagetoid invasion into the conjunctival epithelium. Ciliary body melanoma, when extending through the sclera into the subconjuncti-

val tissue, may simulate conjunctival melanoma. Orbital tumors, such as rhabdomyosarcoma in children, can present first in the conjunctiva.

## REFERENCES

- Ferry AP. Pyogenic granulomas of the eye and ocular adnexa: a study of 100 cases. *Trans Am Ophthalmol Soc* 1989; 87: 327–343.
- Cameron JA, Mahmood MA. Pyogenic granulomas of the cornea. *Ophthalmology* 1995; 102: 1681–1687.
- Shields CL, Shields JA. Tumors of the conjunctiva and cornea. *Surv Ophthalmol* 2004; 49: 3–24.
- Grossniklaus HE, Green WR, Wolff SM, Iliff NT. Hemangiopericytoma of the conjunctiva. Two cases. *Ophthalmology* 1986; 93: 265–267.
- Awdry P. Lymphangiectasia haemorrhagica conjunctivae. *Br J Ophthalmol* 1969; 53: 274–278.
- Spector JA, Zide BM. Carbon dioxide laser ablation for treatment of lymphangioma of the conjunctiva. *Plast Reconstr Surg* 2006; 117: 609–612.
- Behrendt S, Bernsmeier H, Randzio G. Fractionated beta-irradiation of a conjunctival lymphangioma. *Ophthalmologica* 1991; 203: 161–163.
- Kurumety UR, Lustbader JM. Kaposi's sarcoma of the bulbar conjunctiva as an initial clinical manifestation of acquired immunodeficiency syndrome. *Arch Ophthalmol* 1995; 113: 978.
- Ghabrial R, Quivey JM, Dunn JP Jr, Char DH. Radiation therapy of acquired immunodeficiency syndrome-related Kaposi's sarcoma of the eyelids and conjunctiva. *Arch Ophthalmol* 1992; 110: 1423–1426.
- Jakobiec FA, Sacks E, Lisman RL, Krebs W. Epibulbar fibroma of the conjunctival substantia propria. *Arch Ophthalmol* 1988; 106: 661–664.
- Delgado-Partida P, Rodriguez-Trujillo F. Fibrosarcoma (malignant fibroxanthoma) involving conjunctiva and ciliary body. *Am J Ophthalmol* 1972; 74: 479–485.
- Pe'er J, Maly A, Deckel Y, Frenkel S. Solitary fibrous tumor of the conjunctiva. *Arch Ophthalmol* (in press).
- Jakobiec FA. Fibrous histiocytoma of the corneoscleral limbus. *Am J Ophthalmol* 1974; 78: 700–706.
- Pe'er J, Levinger S, Ilisar M, Climenhaga H, Okon E. Malignant fibrous histiocytoma of the conjunctiva. *Br J Ophthalmol* 1990; 74: 624–628.
- Ferry AP, Sherman SE. Nodular fasciitis of the conjunctiva apparently originating in the fascia bulbi (Tenon's capsule). *Am J Ophthalmol* 1974; 78: 514–517.
- Kalina PH, Bartley GB, Campbell RJ, Buettner H. Isolated neurofibromas of the conjunctiva. *Am J Ophthalmol* 1991; 111: 694–698.
- Charles NC, Fox DM, Avendano JA, Marroquin LS, Appleman W. Conjunctival neurilemoma. Report of 3 cases. *Arch Ophthalmol* 1997; 115: 547–549.
- Ferry AP. Granular cell tumor (myoblastoma) of the palpebral conjunctiva causing pseudoepitheliomatous hyperplasia of the conjunctival epithelium. *Am J Ophthalmol* 1981; 91: 234–238.
- Giller RH, Folberg R, Keech RV, Piette WW, Sato Y. Xanthoma disseminatum. An unusual histiocytosis syndrome. *Am J Pediatr Hematol Oncol* 1988; 10: 252–257.
- Chaudhry IA, Al-Jishi Z, Shamsi FA, Riley F. Juvenile xanthogranuloma of the corneoscleral limbus: case report and review of the literature. *Surv Ophthalmol* 2004; 49: 608–614.
- Kobayashi A, Shirao Y, Takata Y et al. Adult-onset limbal juvenile xanthogranuloma. *Arch Ophthalmol* 2002; 120: 96–97.
- Allaire GS, Hidayat AA, Zimmerman LE, Minardi L. Reticulohistiocytoma of the limbus and cornea. A clinicopathologic study of two cases. *Ophthalmology* 1990; 97: 1018–1022.
- Pe'er J, Hidayat AA. Myxomas of the conjunctiva. *Am J Ophthalmol* 1986; 102: 80–86.
- Cameron JD, Wick MR. Embryonal rhabdomyosarcoma of the conjunctiva. A clinicopathologic and immunohistochemical study. *Arch Ophthalmol* 1986; 104: 1203–1204.
- Polito E, Pichiari P, Loffredo A, Lasorella G. A case of primary botryoid conjunctival rhabdomyosarcoma. *Graefes Arch Clin Exp Ophthalmol* 2006; 244: 517–519.
- White VA, Damji KF, Richards JS, Rootman J. Leiomyosarcoma of the conjunctiva. *Ophthalmology* 1991; 98: 1560–1564.
- Bryant J. Pleomorphic lipoma of the bulbar conjunctiva. *Ann Ophthalmol* 1987; 19: 148–149.
- Miyashita K, Abe Y, Osamura Y. Case of conjunctival liposarcoma. *Jpn J Ophthalmol* 1991; 35: 207–210.
- Coupland SE, Hellmich M, Auw-Haedrich C, Lee WR, Stein H. Prognostic value of cell-cycle markers in ocular adnexal lymphoma: an assessment of 230 cases. *Graefes Arch Clin Exp Ophthalmol* 2004; 242: 130–145.
- Shields CL, Shields JA, Carvalho C, Rundle P, Smith AF. Conjunctival lymphoid tumors: clinical analysis of 117 cases and relationship to systemic lymphoma. *Ophthalmology* 2001; 108: 979–984.
- Nuckel H, Meller D, Steuhl KP, Duhrsen U. Anti-CD20 monoclonal antibody therapy in relapsed MALT lymphoma of the conjunctiva. *Eur J Haematol* 2004; 73: 258–262.
- Lee SS, Robinson MR, Morris JC et al. Conjunctival involvement with T-cell polymorphocytic leukemia: report of a case and review of the literature. *Surv Ophthalmol* 2004; 49: 525–536.
- Mansour AM, Barber JC, Reinecke RD, Wang FM. Ocular choristomas. *Surv Ophthalmol* 1989; 33: 339–358.
- Gayre GS, Proia AD, Dutton JJ. Epibulbar osseous choristoma: case report and review of the literature. *Ophthalm Surg Lasers* 2002; 33: 410–415.
- Pfaffenbach DD, Green WR. Ectopic lacrimal gland. *Int Ophthalmol Clin* 1971; 11: 149–159.
- Pokorny KS, Hyman BM, Jakobiec FA et al. Epibulbar choristomas containing lacrimal tissue. Clinical distinction from dermoids and histologic evidence of an origin from the palpebral lobe. *Ophthalmology* 1987; 94: 1249–1257.
- Pe'er J, Ilisar M. Epibulbar complex choristoma associated with nevus sebaceous. *Arch Ophthalmol* 1995; 113: 1301–1304.
- Kiratli H, Shields CL, Shields JA, DePotter P. Metastatic tumours to the conjunctiva: report of 10 cases. *Br J Ophthalmol* 1996; 80: 5–8.



# Surgical techniques

Anat Galor, Bennie H. Jeng and Arun D. Singh

## INTRODUCTION

A variety of tumors affect the conjunctiva and cornea, ranging from benign growths to malignant neoplasms. Several types of conjunctival neoplasms originate from or involve the limbus region and extend into the cornea. Therefore, surgical techniques involve the excision of both corneal and conjunctival tissues.

## PRESURGICAL EVALUATION

A detailed slit lamp examination is not only vital to diagnose conjunctival and corneal tumors correctly, but is also critical for planning the appropriate surgery. It is also important to evaluate the upper and lower palpebral conjunctivae to look for extension of lesions and to palpate the preauricular and submandibular areas for enlarged lymph nodes. Corneal involvement must be accurately documented, as it is difficult to appreciate under the diffuse lighting of an operating microscope. Rose Bengal stain can be used to help delineate abnormal epithelium. A drawing or photograph clearly depicting the extent of involvement that can be readily viewed during surgery is helpful for obtaining adequate surgical margins. Free movement of the abnormal conjunctiva, as tested by gentle pushing with a cotton-tipped applicator, indicates sparing of the sclera. Ultrasound biomicroscopy can sometimes assist in determining the depth of tumor extension into the cornea or sclera.

## ANESTHESIA

Local anesthesia can be used for most procedures, depending on patient cooperation. Most authors recommend retrobulbar anesthesia with sedation to avoid disruption of the conjunctival architecture.<sup>1</sup> Others prefer subconjunctival injection of 1% lidocaine with epinephrine to elevate the lesion from the underlying sclera.<sup>2</sup>

## GENERAL SURGICAL PRINCIPLES

The goal of surgery is the total removal of tissues (conjunctiva, cornea, sclera) affected by the neoplasm. All but the most extensive conjunctival lesions can be approached by excisional biopsy to achieve this goal. However, incisional biopsy may be performed in some circumstances.

## GENERAL SURGICAL TECHNIQUE

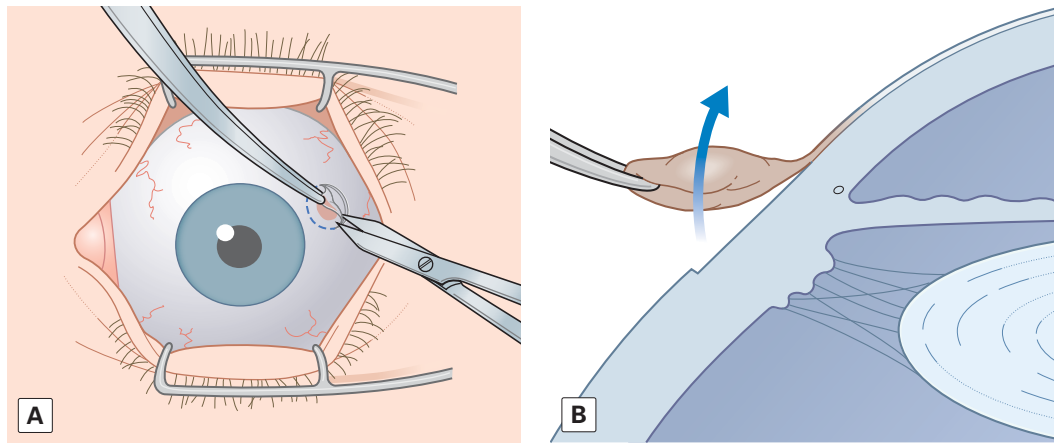
In general, the surgical technique depends on the location and type of tumor. The surgical procedure can be divided into four sequential steps: corneal excision (if corneal involvement is present), conjunctival excision, supplemental cryotherapy (if needed), and wound closure.

**Corneal excision** As corneal involvement by a conjunctival tumor tends to be superficial, the corneal excision is usually limited to the removal of corneal epithelium (corneal epitheliectomy). Care must be taken not to disrupt Bowman's layer, as it is thought to serve as a natural ocular barrier to invasion. Deeper invasion of the cornea, if present, necessitates lamellar keratectomy. Prior to scraping off the affected epithelium with a no. 57 Beaver blade, absolute alcohol is applied with a cotton-tipped applicator to the involved corneal epithelium and a 2 mm margin of clinically non-affected tissue. The purpose of this is to denature the cells, thereby minimizing the risk of seeding of cancer cells. Alcohol is applied to dry cornea so as to limit spillage. The uninvolved cornea may also be protected with a viscoelastic applied to unaffected areas. After about a minute the cornea is irrigated. The corneal epithelium is removed in one piece, placed on a sponge, and submitted to pathology.

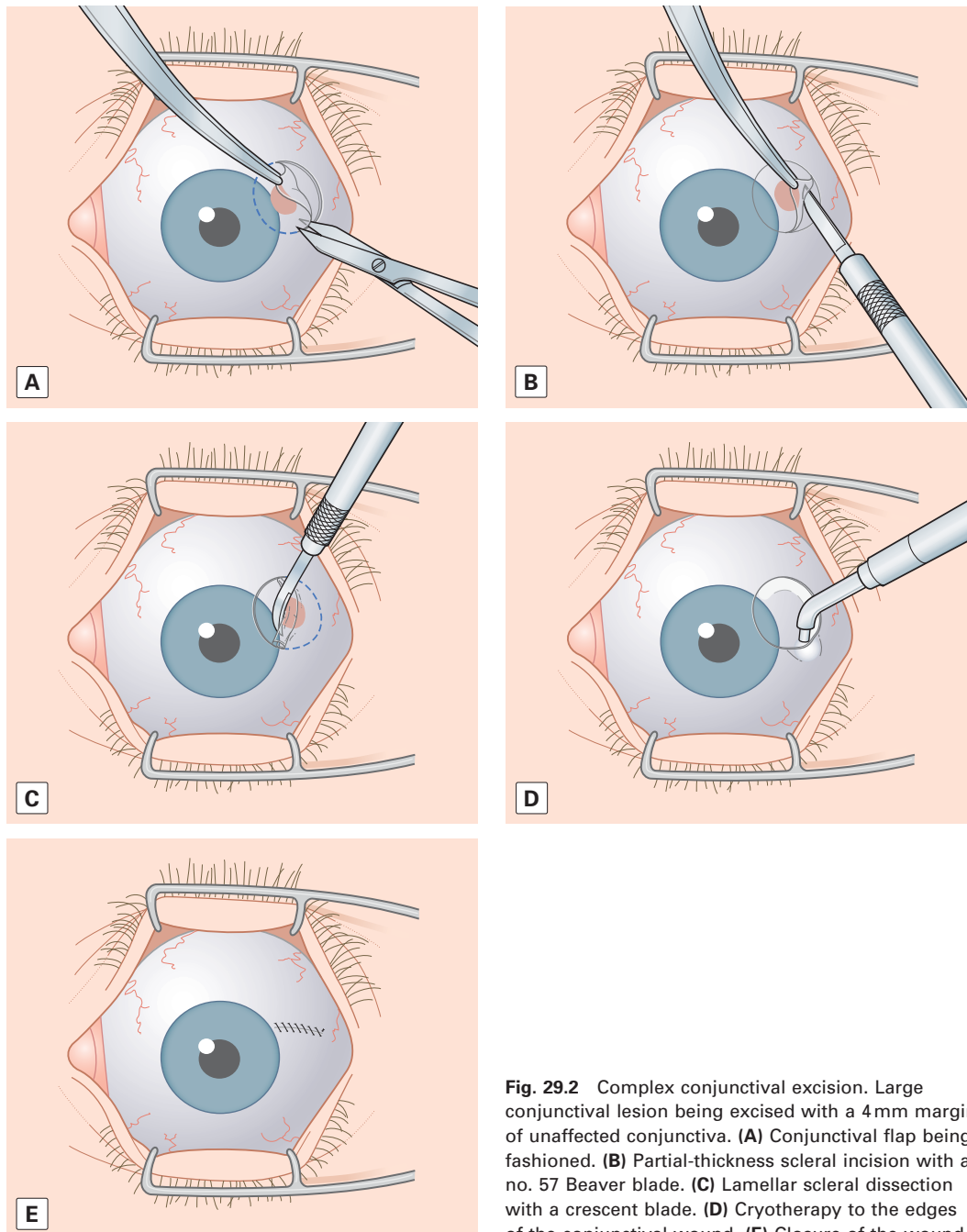
**Conjunctival excision** The removal technique for the conjunctival portion of a neoplasm depends on the type of lesion and its depth of invasion.

**Simple** Benign lesions that do not penetrate the sclera can be removed by a simple excisional biopsy. The surrounding conjunctiva is grasped with non-toothed forceps and excised along with a 1–2 mm margin of clinically non-affected tissue using scissors (Fig. 29.1). It is important not to touch the affected conjunctiva and to use different instruments for affected and non-affected tissues, so as not to plant tumor cells iatrogenically on the unaffected tissue.<sup>3</sup>

**Complex** For potentially malignant tumors a more extensive excision is suggested, with a wider margin of excision of clinically non-affected tissue (4–5 mm) and lamellar sclerectomy. The conjunctiva and Tenon's fascia are incised with scissors, exposing the underlying sclera (Fig. 29.2A). Bipolar cautery is applied to the episcleral vessels to achieve hemostasis. A partial sclerectomy is performed with a fresh no. 57 Beaver blade by fashioning a semicircular groove, approximately 20% of the depth of the sclera and 2 mm posterior to the tumor margin (Fig. 29.2B). A thin flap of sclera is then dissected with a crescent blade anteriorly up to the limbus (Fig. 29.2C). The specimen is removed in one piece with forceps grasping the normal scleral margin. For tumors extending more than 5 mm posterior to the limbus, it is helpful to hook and isolate the appropriate rectus muscle with a suture to provide traction, to allow for better exposure, and to avoid inadvertent injury to the muscle.



**Fig. 29.1** Simple conjunctival excision. Small conjunctival lesion being excised with a 2 mm margin of unaffected conjunctiva.



**Fig. 29.2** Complex conjunctival excision. Large conjunctival lesion being excised with a 4 mm margin of unaffected conjunctiva. **(A)** Conjunctival flap being fashioned. **(B)** Partial-thickness scleral incision with a no. 57 Beaver blade. **(C)** Lamellar scleral dissection with a crescent blade. **(D)** Cryotherapy to the edges of the conjunctival wound. **(E)** Closure of the wound.

**Supplemental cryotherapy** Cryotherapy with a flat-tipped nitrous oxide probe is used as a supplemental treatment for malignant lesions to reduce recurrence rates. The probe is placed on the underside of the conjunctival edge, lifting the conjunctiva to avoid damage to the sclera, and applied to the tissue for 3–10 seconds (Fig. 29.2D).<sup>3</sup> The tissue is allowed to thaw spontaneously and is re-frozen in a similar manner for a ‘double freeze–thaw’ cycle. The probe is applied to the margin to overlap with the previously treated area, and the process is repeated until all margins have been treated.

**Wound closure** To prevent the possibility of planting tumor cells on unaffected tissue, it is important to use a different set of instruments to close the conjunctiva than were used to remove the lesion. If a simple excisional biopsy is performed, the surrounding conjunctiva can be left to re-epithelialize without sutures. For larger defects, the conjunctiva can be primarily closed by undermining the surrounding conjunctivae and using a running or interrupted 6/0 or 7/0 absorbable suture to reapproximate the tissue edges (Fig. 29.2E). Alternatively, fibrin glue can be used for closure.<sup>4</sup> A defect too large to be closed primarily can be closed with a conjunctival graft harvested from the opposite eye, or with an amniotic membrane. The amniotic membrane is cut to the appropriate size and sutured epithelial side up to the corneal and conjunctival margins using 10/0 nylon and 9/0 Vicryl sutures, respectively. The use of amniotic membrane helps to reduce inflammation and facilitate epithelialization.<sup>5–7</sup> With the commercial availability of amniotic membrane grafts, mucous membrane grafts are rarely used.

## SPECIFIC SURGICAL TECHNIQUES

### Melanocytic tumors

**Conjunctival nevus** Excision of conjunctival nevus is considered for cosmetic reasons, ocular irritation, or parental concern. A simple excisional biopsy is the procedure of choice.<sup>3</sup>

**Primary acquired melanosis** Because of the diffuse nature of primary acquired melanosis (PAM), the surgical approach is different from that of an isolated conjunctival lesion. Corneal epitheliectomy is performed if corneal involvement is documented. Suspicious nodules are excised to evaluate for the possibility of melanoma. Staging consists of removing 3 mm pieces of bulbar conjunctiva with the use of fresh forceps and scissors halfway between the rectus muscles and the fornix in all four quadrants. These small areas can be left to heal without sutures.<sup>1</sup> Complete removal is possible with small areas of PAM, whereas diffuse areas may be treated with double freeze–thaw cycle cryotherapy alone (one quadrant per session) if atypia is documented histopathologically.<sup>8</sup> Topical mitomycin-C (MMC) has also been reported as a possible primary or adjuvant treatment for diffuse PAM (See also Chapter 26).<sup>9,10</sup>

**Conjunctival malignant melanoma** Conjunctival melanomas are managed by excision and cryotherapy.<sup>11,12</sup> Recurrent conjunctival melanoma is managed by repeat excision, cryotherapy, MMC eye drops, or irradiation. More extensive recurrences may require exenteration (See also Chapter 27).<sup>3</sup>

### Squamous tumors

**Squamous cell papilloma** If removal is contemplated, a combined-modality treatment should be used, as simple excision often leads to a more extensive recurrence than the original lesion.<sup>3</sup>

Cryotherapy, as described above, is the supplemental treatment of choice.

**Conjunctival epithelial neoplasia** Combined-modality treatment (excision supplemented with cryotherapy) as described above is advocated, given the high rate of recurrence after simple excision.<sup>3</sup> Other variations on the above technique have been described and include the application of cryotherapy to the scleral bed as well as the surrounding conjunctivae,<sup>13</sup> and performing cryosurgery prior to and after excision.<sup>2</sup> A variant of Mohs’ micrographic surgery has been described as an approach to treating CIN.<sup>14</sup> Topical MMC,<sup>15,16</sup> 5-fluorouracil,<sup>17</sup>  $\beta$  irradiation,<sup>18</sup> topical cidofovir,<sup>19</sup> and topical interferon- $\alpha$ <sup>20,21</sup> can be used as an adjuvant treatment for patients with incompletely excised lesions or with diffuse disease, or in patients with multiple recurrences after surgery (See also Chapter 25).

### Substantia propria tumors

**Lymphoid tumor** If feasible, complete excision of lymphoid tumor is desirable. Debulking is reserved for larger tumors that adhere to vital orbital structures.

**Limbal dermoid** Limbal dermoid can cause irregular astigmatism, irritation, or unacceptable cosmesis. Given the deep extent of these tumors, a lamellar sclerectomy and keratectomy are performed, both towards the limbus.<sup>3</sup> The lesion can be excised manually by lifting the conjunctival edge with forceps and locating a plane of normal sclera under the tumor with a blade. Alternatively, a handheld trephine on bare sclera can be used to delineate the boundaries of the lesion. A slightly oversized trephine is then used to remove donor corneoscleral tissue after performing a lamellar dissection of equal depth. The donor tissue is sewn into the recipient bed with interrupted 10/0 nylon sutures.<sup>22</sup>

### SPECIMEN PREPARATION

Prior discussion with a pathologist is important to identify the proper fixative agent; most commonly, 10% formalin is used. For suspected lymphoid tumors, tissue should be transported fresh in a small amount of saline for flow cytometric analysis. Specimens are prepared by laying the tissue flat, epithelial side up, on sterile paper wetted with a balanced salt solution. Orientation is drawn with a graphite pencil.

### POSTOPERATIVE MANAGEMENT

Following surgery, a cycloplegic eye drop along with a combination antibiotic/corticosteroid ointment and a double patch are applied for 24 hours. Topical combination antibiotic/corticosteroid eye drops or ointment are used for a period of 1–3 weeks until re-epithelialization occurs. Patients in whom a graft is used may require a bandage contact lens and topical treatment for a longer time.<sup>3</sup>

### COMPLICATIONS

Although uncommon, complications can occur after surgical resection, including infection, bleeding, delayed epithelial healing, pyogenic granuloma formation, Tenon cyst formation, conjunctival and corneal scarring, and restrictive strabismus. Complications related to the use of MMC include scleral ischemia and cataract formation. Vigorous cryotherapy to the scleral bed can result in damage to the sclera, iris, and ciliary body.<sup>3</sup> These complications can be minimized by adhering to good surgical techniques.



## REFERENCES

- Shields JA, Shields CL, De Potter P. Surgical management of conjunctival tumors. The 1994 Lynn B. McMahan Lecture. *Arch Ophthalmol* 1997; 115: 808–815.
- Peksayar G, Altan-Yaycioglu R, Onal S. Excision and cryosurgery in the treatment of conjunctival malignant epithelial tumours. *Eye* 2003; 17: 228–232.
- Schwartz GS HE. *Management of Conjunctival and Corneal Neoplasia*. Vol. III. St. Louis: Mosby, 1997; 1991–1924.
- Dadeya S, Ms K. Strabismus surgery: fibrin glue versus vicryl for conjunctival closure. *Acta Ophthalmol Scand* 2001; 79: 515–517.
- Paridaens D, Beekhuis H, van Den Bosch W et al. Amniotic membrane transplantation in the management of conjunctival malignant melanoma and primary acquired melanosis with atypia. *Br J Ophthalmol* 2001; 85: 658–661.
- Chen Z, Yan J, Yang H et al. Amniotic membrane transplantation for conjunctival tumor. *Yan Ke Xue Bao* 2003; 19: 145, 165–167.
- Kobayashi A, Takahira M, Yamada A et al. Fornix and conjunctiva reconstruction by amniotic membrane in a patient with conjunctival mucosa-associated lymphoid tissue lymphoma. *Jpn J Ophthalmol* 2002; 46: 346–348.
- Hungerford JL. Surgical treatment of ocular melanoma. *Melanoma Res* 1993; 3: 305–312.
- Finger PT, Czechonska G, Liarikos S. Topical mitomycin C chemotherapy for conjunctival melanoma and PAM with atypia. *Br J Ophthalmol* 1998; 82: 476–479.
- Pe'er J, Frucht-Pery J. The treatment of primary acquired melanosis (PAM) with atypia by topical mitomycin C. *Am J Ophthalmol* 2005; 139: 229–234.
- Jakobiec FA, Rini FJ, Fraunfelder FT, Brownstein S. Cryotherapy for conjunctival primary acquired melanosis and malignant melanoma. Experience with 62 cases. *Ophthalmology* 1988; 95: 1058–1070.
- Jakobiec FA, Brownstein S, Albert W et al. The role of cryotherapy in the management of conjunctival melanoma. *Ophthalmology* 1982; 89: 502–515.
- Fraunfelder FT, Wingfield D. Management of intraepithelial conjunctival tumors and squamous cell carcinomas. *Am J Ophthalmol* 1983; 95: 359–363.
- Buus DR, Tse DT, Folberg R, Buuns DR. Microscopically controlled excision of conjunctival squamous cell carcinoma. *Am J Ophthalmol* 1994; 117: 97–102.
- Frucht-Pery J, Sugar J, Baum J et al. Mitomycin C treatment for conjunctival–corneal intraepithelial neoplasia: a multicenter experience. *Ophthalmology* 1997; 104: 2085–2093.
- Frucht-Pery J, Rozenman Y, Pe'er J. Topical mitomycin C for partially excised conjunctival squamous cell carcinoma. *Ophthalmology* 2002; 109: 548–552.
- Yamamoto N, Ohmura T, Suzuki H, Shirasawa H. Successful treatment with 5-fluorouracil of conjunctival intraepithelial neoplasia refractive to mitomycin-C. *Ophthalmology* 2002; 109: 249–252.
- Jones DB, Wilhelmus KR, Font RL. Beta radiation of recurrent corneal intraepithelial neoplasia. *Trans Am Ophthalmol Soc* 1991; 89: 285–298; discussion 298–301.
- Sherman MD, Feldman KA, Farahmand SM, Margolis TP. Treatment of conjunctival squamous cell carcinoma with topical cidofovir. *Am J Ophthalmol* 2002; 134: 432–433.
- Chen HC, Chang SW, Huang SF. Adjunctive treatment with interferon alpha-2b may decrease the risk of papilloma-associated conjunctival intraepithelial neoplasm recurrence. *Cornea* 2004; 23: 726–729.
- Karp CL, Moore JK, Rosa RH Jr. Treatment of conjunctival and corneal intraepithelial neoplasia with topical interferon alpha-2b. *Ophthalmology* 2001; 108: 1093–1098.
- Mader TH, Stulting D. Technique for the removal of limbal dermoids. *Cornea* 1998; 17: 66–67.

# Systemic associations of conjunctival and corneal tumors

Arun D. Singh and Elias I. Traboulsi

## INTRODUCTION

Conjunctival tumors may be some of the most prominent manifestations of systemic inherited diseases. In such instances, ophthalmologists should recognize the systemic association and initiate the appropriate systemic and genetic evaluation. Conjunctival tumors and tumor-like conditions with syndromic association can be considered under the categories of pigmented lesions (Peutz–Jeghers syndrome), benign tumors (Goldenhar syndrome), malignant tumors (xeroderma pigmentosum), and amyloidosis (Table 30.1). We will briefly review such conjunctival lesions and their associated systemic disorders. Some entities may also have associated eyelid tumors and are covered in detail elsewhere (see Chapter 22). Where applicable, the inheritance patterns of the syndromic association and molecular genetics are also included.

## CARNEY COMPLEX

Carney complex is characterized by cutaneous pigmentary abnormalities, myxomas, endocrine tumors, and schwannomas.<sup>1</sup> Conjunctival and caruncular pigmentation may be present in about one-quarter of cases<sup>2</sup> (see Chapter 22).

## PEUTZ–JEGHERS SYNDROME

Peutz–Jeghers syndrome refers to the association of gastrointestinal hamartomatous polyposis and mucocutaneous pigmentation.<sup>3,4</sup>

**Inheritance** Autosomal dominant pattern.

**Molecular genetics** Mutations of *STK11* are detectable in about 20–70% of patients.<sup>5</sup>

**Ophthalmic features** CHRPE-like lesions of the fundus that are characteristic of patients with Gardner's syndrome do not occur in Peutz–Jeghers syndrome.<sup>6</sup> However, pigmented spots of the eyelids and conjunctiva have been observed (Fig. 30.1).<sup>7</sup>

**Systemic features** Perioral pigmentation is pathognomonic, particularly if it occurs across the vermilion border. The oral mucosa and fingertips are also commonly affected. About 50% of patients develop a wide variety of cancers in adulthood.<sup>8</sup>

## SEBACEUS NEVUS SYNDROME

Sebaceous nevus syndrome (of Jadassohn), also known as Schimmelpenning–Feuerstein–Mims syndrome, is a distinct clinical disorder

within the spectrum of epidermal nevus syndrome (of Solomon) characterized by cutaneous sebaceous nevus and extracutaneous manifestations. Ocular involvement is observed in about 40% of cases, with epibulbar choristomas and coloboma being the most common. The limbal choristomas can be simple or complex and are usually dermoid or lipodermoid in nature (see Chapter 63 for further discussion).

## GOLDENHAR SYNDROME (OCULO-AURICULO-VERTEBRAL DYSPLASIA)

Goldenhar<sup>9</sup> described a triad of epibulbar dermoids, preauricular appendages, and pretragal fistulae. Since then, the spectrum of manifestations has expanded to include vertebral anomalies and is also called oculoauriculovertebral dysplasia (OAV).<sup>10</sup> It is now considered a specific subtype of hemifacial microsomia which is associated with epibulbar dermoids.

**Inheritance** The majority of cases occur sporadically. Exceptional cases with autosomal dominant and recessive inheritance patterns have also been reported.

**Molecular genetics** OAV represents a non-random cluster of development anomalies of the first and second branchial arch derivatives rather than a single gene defect.<sup>11</sup> Maternal diabetes may be etiologically significant.<sup>12</sup>

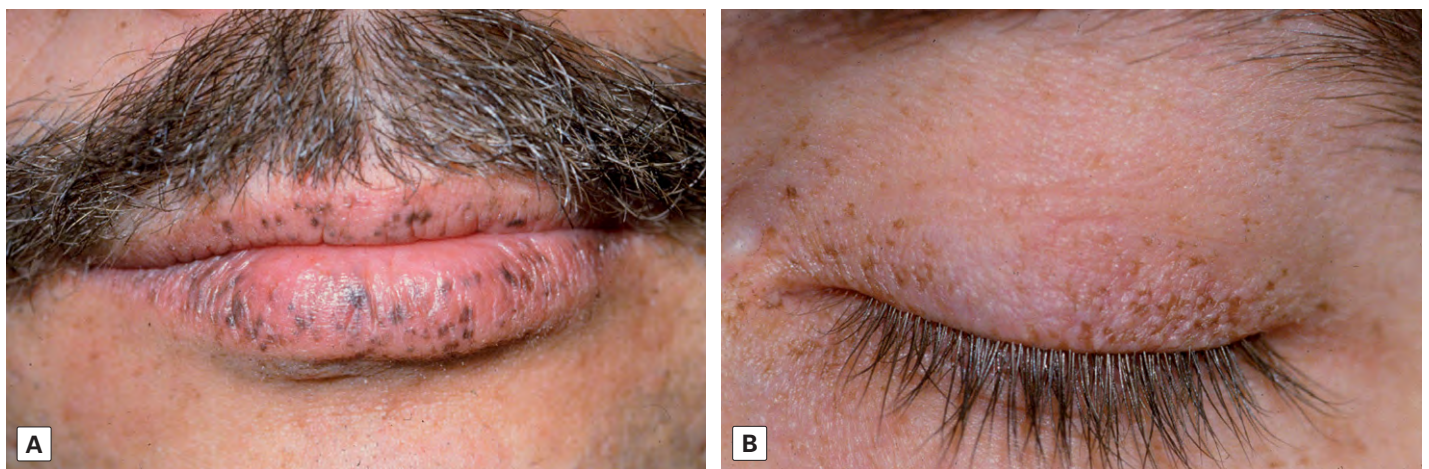
**Ophthalmic features** Epibulbar dermoid is a necessary feature for the diagnosis of Goldenhar syndrome (Fig. 30.2). The epibulbar dermoids are almost always located near the limbus in the inferotemporal quadrant. Secondary irregular astigmatism and anisometropic amblyopia may also be present. Dermolipomas are typically in the subconjunctival plane and appear as a yellow soft mass in the superotemporal quadrant. Other associated anomalies include eyelid coloboma,<sup>13</sup> Duane syndrome,<sup>14</sup> and caruncular anomalies.<sup>15</sup> Involvement of the globe itself manifesting as microphthalmia and coloboma is uncommon.<sup>16</sup>

**Systemic features** In addition to ophthalmic, ear, and vertebral anomalies, about 50% of cases have anomalies such as micrognathia, macrostomia, cleft lip and palate, and developmental defects of the heart.<sup>17</sup> Recent analysis of data suggests a statistical association with the VATER anomaly (Vertebral defects, Anal atresia, Tracheoesophageal fistula with Esophageal atresia, and Radial dysplasia) and CHARGE syndrome (Coloboma, Heart anomaly, choanal Atresia, Retardation, Genital and Ear anomalies).<sup>18</sup>

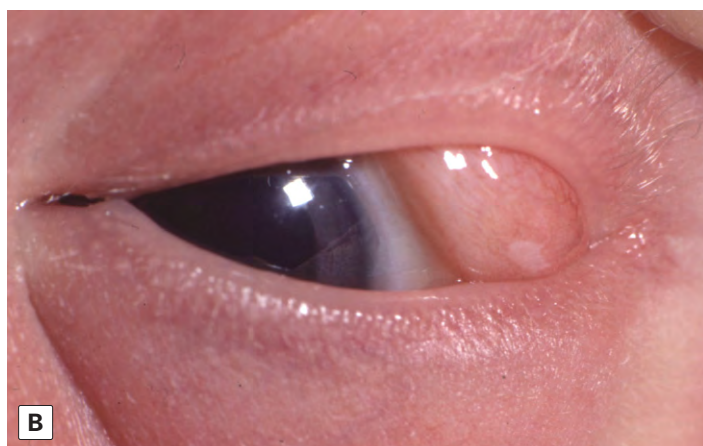
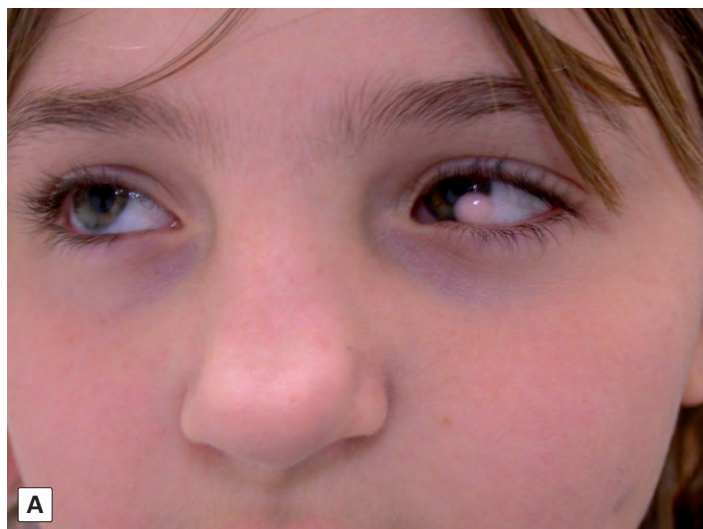**Table 30.1** Various conjunctival tumors that are markers of syndromic association

Pattern	Entity	Conjunctival features	Associated features	Locus/Gene	
Pigmentation	Carney complex	Conjunctival pigmentation	Spotty mucocutaneous pigmentation Schwannoma Endocrine overactivity Testicular tumor	17q <i>PRKAR1A</i> gene chromosome 2	
	Peutz–Jeghers	Conjunctival pigmentation	Mucocutaneous pigmentation Gastrointestinal polyposis	19p13.3 <i>STK11</i>	
Benign tumors	Dermoid	Organoid nevus syndrome	Epibulbar dermoid Coloboma	Cutaneous sebaceous nevus	Sporadic
		Goldenhar syndrome	Epibulbar dermoid	Preauricular appendages Pretragal fistula Vertebral anomalies	Sporadic
	Proteus	Epibulbar dermoid Strabismus Orbital exostoses	Connective tissue nevi Lipoma Vascular malformations Epidermal nevi	Sporadic	
	Neuroma	MEN-2B	Conjunctival neuroma	Thickened corneal nerves Mucocutaneous neuroma Endocrine tumor	10q11.2 <i>RET</i> protooncogene
Malignant tumors	Xeroderma pigmentosum	Conjunctiva xerosis Keratitis Ocular surface neoplasms	Skin atrophy with pigmentary changes Neurological abnormalities	Variable	
Amyloidosis		Conjunctival nodule Conjunctival hemorrhage	Variable	Sporadic Familial	

MEN, multiple endocrine neoplasia.

**Fig. 30.1** (A) Perioral and (B) eyelid pigmentation in Peutz–Jeghers syndrome. (Reproduced with permission from El Traboulsi. A compendium of inherited disorders and the eye. New York: Oxford University Press, 2006; 140–141.)





**Fig. 30.2** (A) Epibulbar dermoid and facial pit and (B) dermolipoma in Goldenhar syndrome.

### PROTEUS SYNDROME

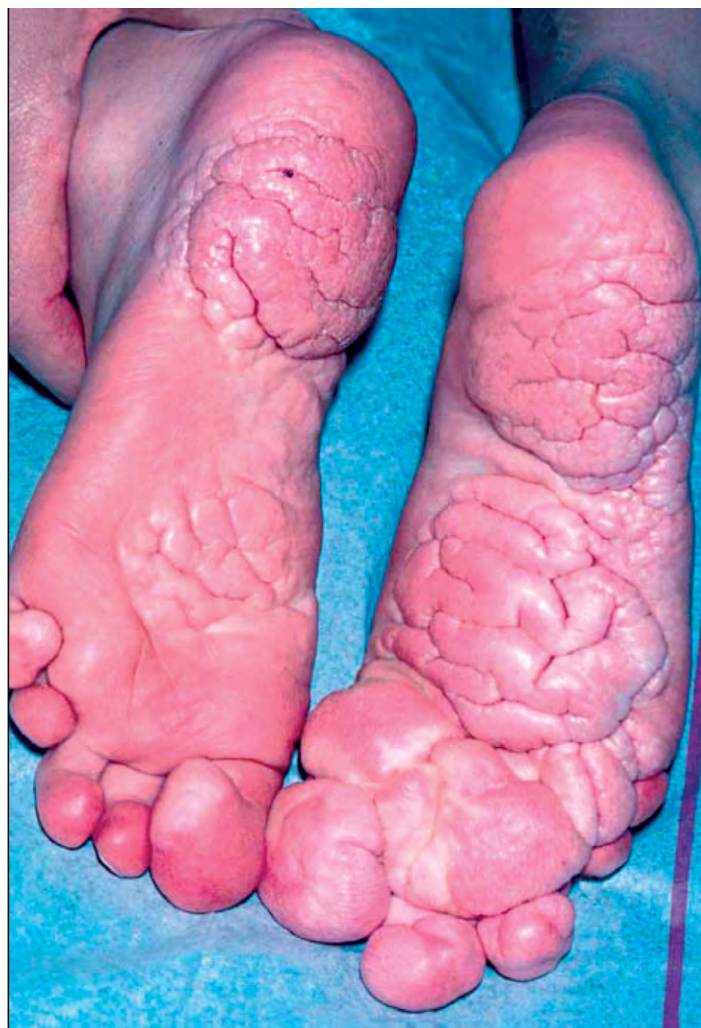Proteus syndrome is a severe and highly variable disorder characterized by asymmetric and disproportionate overgrowth of body parts and hamartomas. It was first recognized as a specific entity in 1979<sup>19</sup> and named after the Greek god Proteus, who could change his shape, emphasizing the varied manifestations of the syndrome.<sup>20</sup>

**Inheritance** Sporadic, as it is due to mutations that are lethal unless they occur in a mosaic fashion.<sup>21</sup>

**Molecular genetics** Recent data<sup>22</sup> have refuted the role of germline PTEN mutation in the causation of Proteus syndrome.<sup>23</sup>

**Ophthalmic features** Ophthalmic involvement is common. A review of more than 200 published cases revealed that more than 40% of cases that met the diagnostic criteria had one or more ophthalmic features.<sup>24</sup> Epibulbar and eyelid dermoids, strabismus, nystagmus, high myopia, orbital exostoses, and posterior segment hamartoma are most commonly observed.<sup>25–27</sup> A complete list of published ophthalmic findings is given elsewhere.<sup>24–26</sup>

**Systemic features** The manifestations are usually present at birth and progress during childhood. Owing to its varied manifestations, the diagnosis of Proteus syndrome is frequently missed. A critical



**Fig. 30.3** Cerebriform connective tissue nevi of both soles are characteristic of Proteus syndrome. (Reproduced with permission from Nguyen D, Turner JT, Olsen C et al. Cutaneous manifestations of Proteus syndrome: correlations with general clinical severity. *Arch Dermatol* 2004; 140: 947–953.)

review of published cases revealed that only 47% met the diagnostic criteria.<sup>24</sup> General features suggestive of the diagnosis include mosaic distribution of lesions, progressive course, and sporadic occurrence.<sup>24</sup> Connective tissue nevi are pathognomonic. Other features include lipoma (92%), vascular malformations (88%), and epidermal nevi (67%) (Fig. 30.3).<sup>22</sup> The list of diagnostic criteria is reviewed elsewhere.<sup>28</sup> Individuals with significant clinical features but who do not meet the diagnostic criteria are labeled as having Proteus-like syndrome. The differential diagnosis of Proteus syndrome includes neurofibromatosis type 1, Klippel–Trenaunay–Weber syndrome, Maffucci syndrome, Ollier's disease, and Bannayan–Riley–Ruvalcaba syndrome (Table 30.2).

### MULTIPLE ENDOCRINE NEOPLASIA TYPE 2B

Multiple endocrine neoplasia (MEN) refers to a genetic predisposition to develop benign and malignant tumors of the various endocrine glands. Based on the pattern of glandular involvement, MEN is classified as types 1 and 2. MEN-2 is comprised of three subtypes: familial medullary thyroid carcinoma, MEN-2A, and MEN-2B. MEN-2B is also called mucosal neuroma syndrome or Wagenmann–Froboese

**Table 30.2 The differential diagnosis of Proteus syndrome**

Syndrome	Features	Inheritance
Proteus syndrome	Asymmetric overgrowth, lipoma	Mosaicism
Neurofibromatosis type 1	Neurofibroma	Autosomal dominant
Klippel–Trenaunay–Weber syndrome	Asymmetric overgrowth, hemangioma	Sporadic
Maffucci syndrome	Enchondromatosis, hemangioma	Sporadic
Ollier's disease	Enchondromatosis	Sporadic
Bannayan–Riley–Ruvalcaba syndrome	Macrocephaly, intestinal polyposis, lipoma	Autosomal dominant

(Modified with permission from Sheard RM, Pope FM, Snead MP. A novel ophthalmic presentation of the Proteus syndrome. *Ophthalmology* 2002; 109: 1192–1195)

syndrome, and is the only MEN subgroup that is of ophthalmic interest because of its association with mucosal neuromas.<sup>29,30</sup>

**Inheritance** MEN-2B is inherited as an autosomal dominant trait. About half the cases are due to de novo mutations.

**Molecular genetics** More than 95% of patients with MEN-2B have a point mutation in the RET gene.<sup>31</sup>

**Ophthalmic features** A comprehensive review of all published cases of MEN-2B reveals that common ophthalmic manifestations include prominent corneal nerves (100%), eyelid neuroma or thickening (88%), subconjunctival neuroma (79%), and dry eyes (48%) (Fig. 30.4).<sup>32–34</sup> With rare exceptions,<sup>35</sup> the presence of prominent corneal nerves in an otherwise normal cornea should lead to investigations to exclude MEN-2B.<sup>32,33</sup> Other infrequent causes of prominent corneal nerves, such as neurofibromatosis, leprosy, and congenital ichthyosis, should also be considered in the differential diagnosis.<sup>32</sup> Histopathologic findings of the cornea have shown that prominent corneal nerves are axonal bundles of non-myelinated nerves in association with Schwann cells.<sup>36,37</sup>

**Systemic features** The clinical diagnosis of MEN-2B is suspected in the presence of a marfanoid body habitus, mucosal neuromas of the lips and tongue, prominent corneal nerves, and medullary thyroid carcinoma.<sup>30</sup> As medullary thyroid carcinoma tends to be aggressive, early prophylactic thyroidectomy is recommended.<sup>38</sup> About half the cases also develop pheochromocytoma. Unlike other types of MEN, the involvement of parathyroid gland is rare in MEN-2B.<sup>39</sup>

## XERODERMA PIGMENTOSUM

Xeroderma pigmentosum is a genetic disorder characterized by extreme sensitivity to sunlight and a constellation of cutaneous, ophthalmic, and neurological findings.<sup>40</sup> It is rarely seen in Europe and North America, and is relatively more common in Japan, North Africa, and the Middle East.

**Inheritance** Xeroderma pigmentosum is inherited as an autosomal recessive trait,<sup>40</sup> therefore the possibility of consanguinity should be explored.

**Molecular genetics** Xeroderma pigmentosum is due to mutations of one of eight genes that are involved in nucleotide excision repair (Table 30.3).<sup>41–43</sup> Cockayne syndrome and trichothiodystrophy are

two related disorders of defective nucleotide excision repair mechanisms<sup>44</sup> that, unlike xeroderma pigmentosum, are not associated with the risk of developing skin cancers.<sup>45</sup>

**Ophthalmic features** Ophthalmic complications are present in about 20% of cases and are limited to the sun-exposed eyelids, conjunctiva, and cornea.<sup>45</sup> Eyelid skin atrophy with pigmentary changes and loss of lashes is common. Similar changes of the conjunctiva, such as xerosis and pigmentation, also occur (Fig. 30.5). Corneal complications include keratitis, pterygium, vascularization, and ulceration. Most significant is the predisposition to develop multiple eyelid and ocular surface neoplasms, including basal cell carcinoma, squamous cell carcinoma, and melanoma.<sup>45</sup> One case of iris melanoma has been reported.<sup>46</sup> The posterior segment usually remains unaffected.

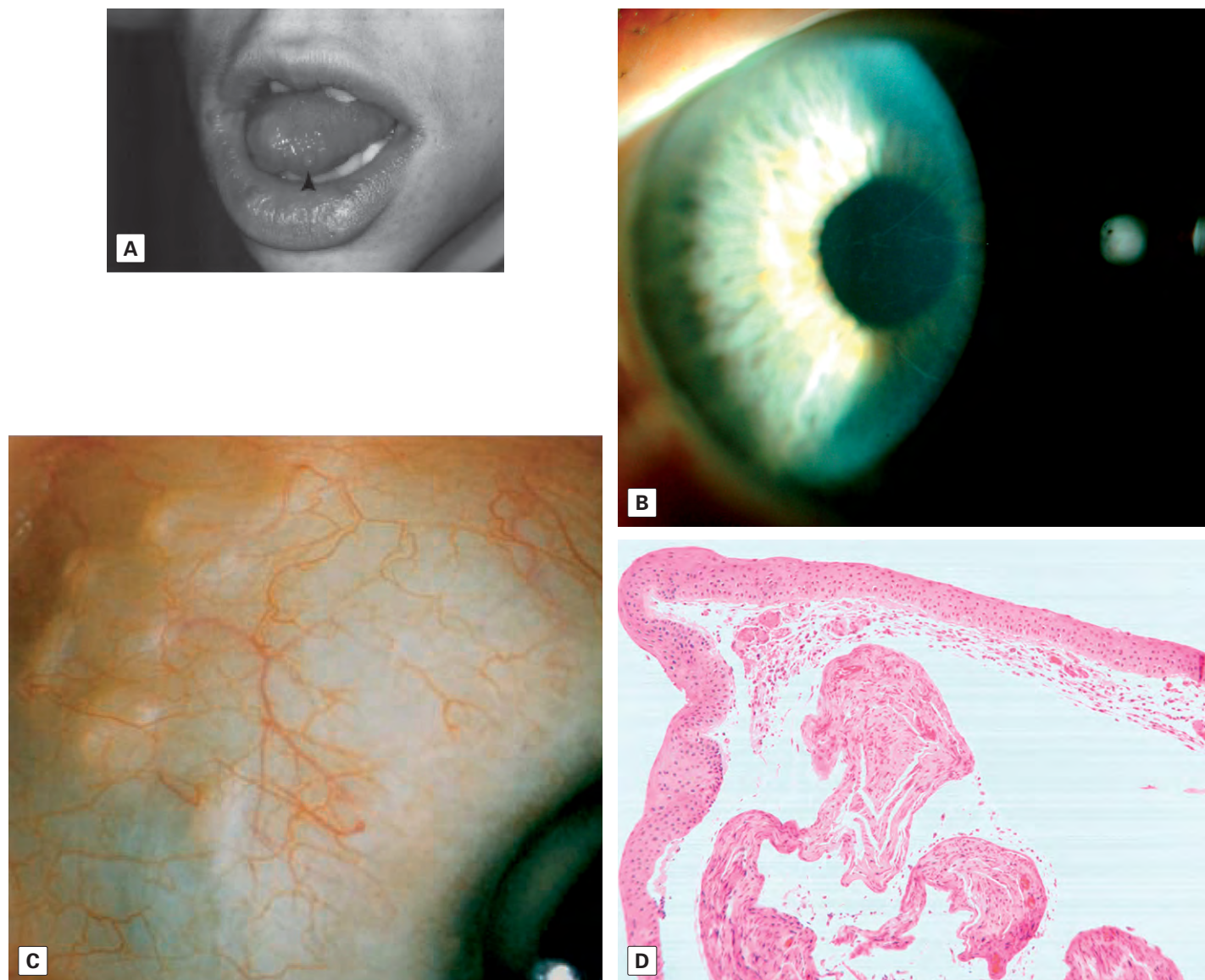
**Systemic features** The cutaneous findings are the defining features of this entity.<sup>40</sup> A tendency to sunburn is evident in early childhood and may be the earliest sign of xeroderma pigmentosum. This is followed by freckling in sun-exposed areas. These changes eventually progress to parchment-like dry pigmented skin, hence the name xeroderma pigmentosum.<sup>40</sup> There is a 1000-fold increased risk of developing cutaneous cancers such as squamous cell carcinoma, basal cell carcinoma, and melanoma.<sup>42</sup> Tumors tend to be multifocal and occur at a median age of less than 10 years. If the individual is protected from sunlight from an early age, the debilitating cutaneous changes can be almost completely avoided.

Neurological abnormalities, present in about 20% of cases, include the absence of deep tendon reflexes due to axonal loss and demyelination, progressive hearing loss, and ataxia.<sup>40</sup>

## AMYLOIDOSIS

Amyloidosis is the extracellular deposition of insoluble proteinaceous material called amyloid by Virchow in 1854.<sup>47</sup> Because of its structure and composition, amyloid deposits in tissues exhibit characteristic staining reaction to iodine and Congo red stain (birefringence) (Fig. 30.6). From a clinical standpoint, amyloidosis can be classified as systemic when there is multisystem involvement due to underlying neoplastic, inflammatory, genetic, iatrogenic, or idiopathic causes. Localized amyloidosis occurs in isolated organs without evidence of systemic involvement, and is associated with aging and diabetes.<sup>47</sup> Another classification system is based on the identity of the fibril-forming proteins, such as immunoglobulin light chains, serum amyloid A, and transthyretin.<sup>48</sup>





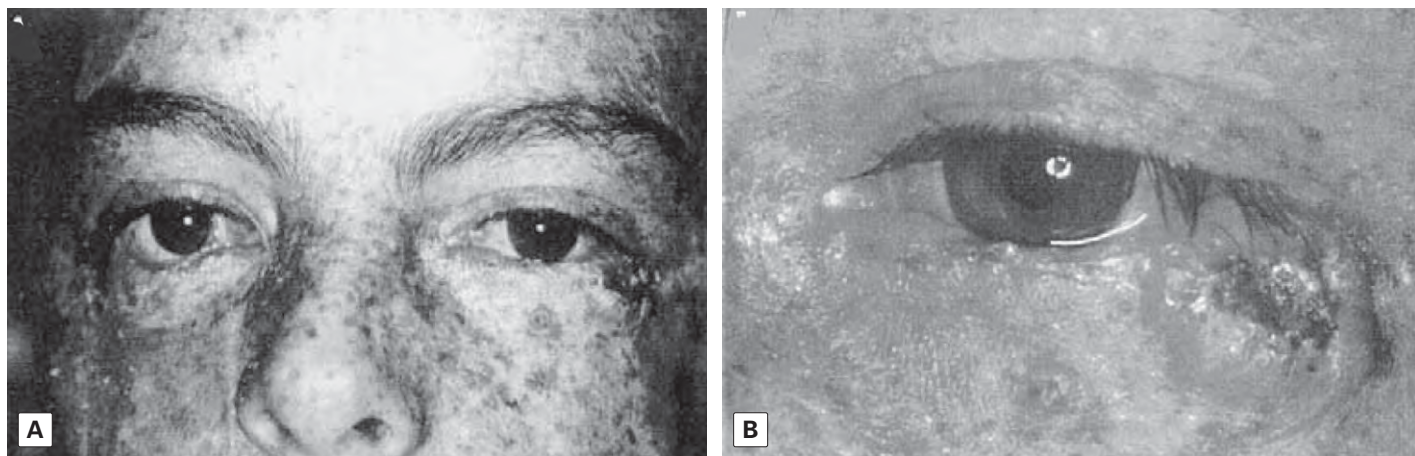
**Fig. 30.4** (A) Characteristic features of MEN-2B syndrome. Submucosal lip and tongue neuroma (arrow). (Reproduced with permission from Jacobs JM, Hawes MJ. From eyelid bumps to thyroid lumps: report of a MEN-2B family and review of the literature. *Ophthalm Plast Reconstr Surg* 2001; 17: 195–201.) (B) Prominent corneal nerves. (C) Plexiform subconjunctival neuroma. (Reproduced with permission from Eter N, Klingmuller D, Hoppner W, Spitznas M. Typical ocular findings in a patient with multiple endocrine neoplasia MEN-2B syndrome. *Graefes Arch Clin Exp Ophthalmol* 2001; 239: 391–394.) (D) Histopathologic section of the conjunctiva shows thickened abnormal nerves in the substantia propria.

**Table 30.3** Genotype–phenotype correlations in xeroderma pigmentosum and related disorders

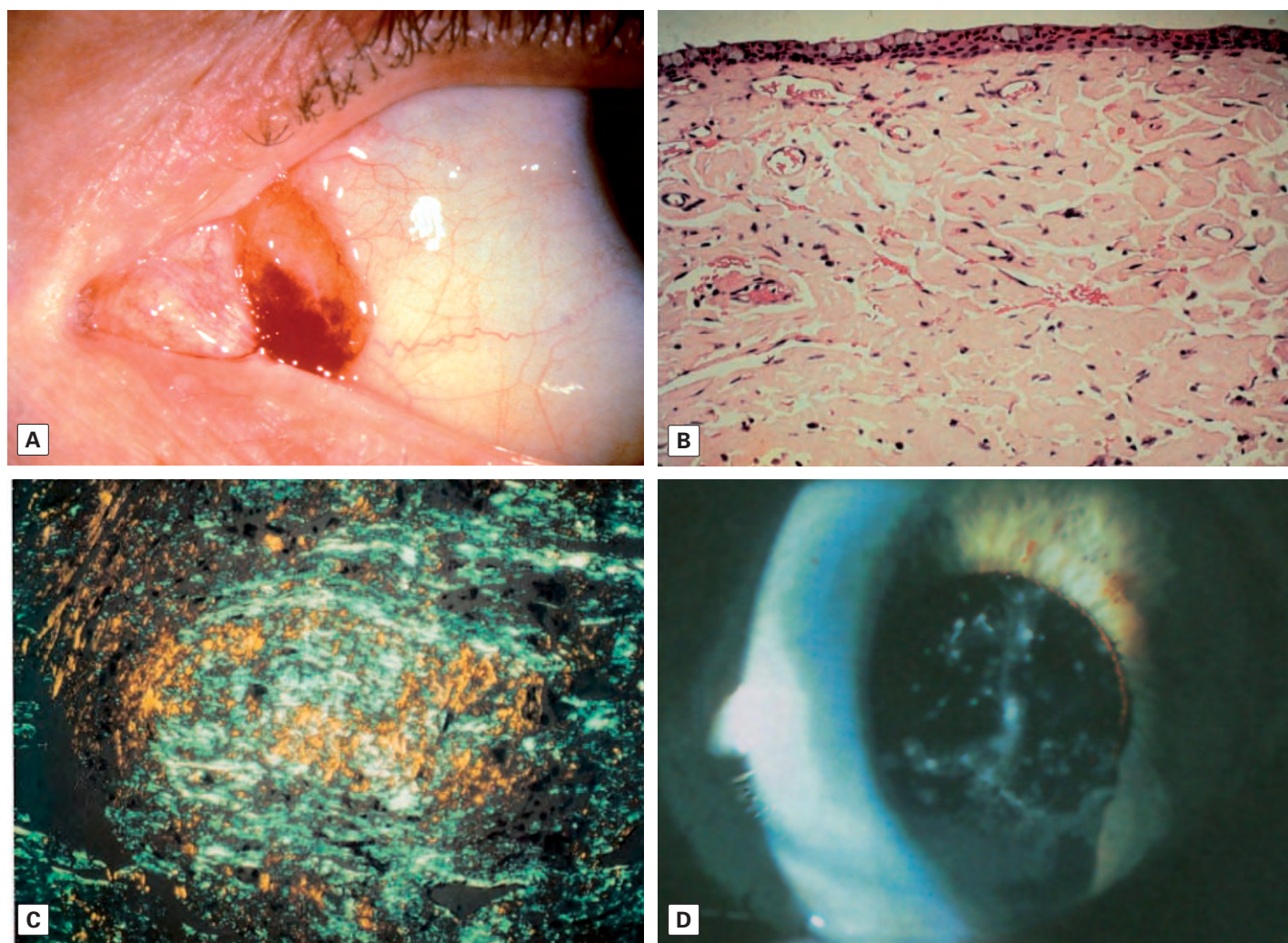
Complementation group	Gene symbol	Locus	Phenotype
A	XPA	9q22.3	XP with no neurologic abnormalities
B	XPB/ERCC3	2q21	XP/CS/TTD
C	XPC	3p25	XP with no neurologic abnormalities
D	XPD/ERCC2	19q13.2-q13.3	XP/CS/TTD/COFS
E	XPE/DDB2	11p12-p11	XP with no neurologic abnormalities
F	XPF/ERCC 4	16p13.3-p13.13	XP with variable neurologic abnormalities
G	XPG/ERCC 5/	13q33	XP/CS
XP variant	POLH	6p21.1-p12	XP with no neurologic abnormalities

XP, xeroderma pigmentosum; CS, Cockayne syndrome; TTD, trichothiodystrophy; COFS, cerebro-ocular-facial syndrome. (Modified from Wattendorf DJ, Kraemer KH (2005). Xeroderma pigmentosum, [www.genetest.org](http://www.genetest.org))





**Fig. 30.5** Xeroderma pigmentosum in a 15-year-old boy. **(A)** Freckles, hyperpigmentation, and hyperkeratosis are noted on the skin. **(B)** Squamous cell carcinoma of the left inferior lid after 1 year. (Reproduced with permission from Dollfus H, Porto F, Caussade P et al. Ocular manifestations in the inherited DNA repair disorders. *Surv Ophthalmol* 2003; 48: 107–122.)



**Fig. 30.6** **(A)** A salmon-colored lesion in the conjunctival semilunar fold with hemorrhagic inferior portion. **(B)** Amorphous material in the conjunctival stroma. **(C)** Dichroism, showing typical apple-green color. (Reproduced with permission from Shields JA, Eagle RC, Shields CL et al. Systemic amyloidosis presenting as a mass of the conjunctival semilunar fold. *Am J Ophthalmol* 2000; 130: 523–525.) **(D)** Slit-lamp photograph of the anterior vitreous surface after intracapsular cataract surgery, showing 'pseudopodia lentis' of vitreous amyloidosis. (Reproduced with permission from Sandgren O. Ocular amyloidosis, with special reference to the hereditary forms with vitreous involvement. *Surv Ophthalmol* 1995; 40: 173–196.)

**Ophthalmic features** Ophthalmic amyloidosis can affect the eyelids, conjunctiva, orbital tissues, cornea (lattice corneal dystrophy), and vitreous (Fig. 30.6). Unilateral or bilateral eyelid involvement is frequent in systemic amyloidosis. Clinical manifestations include recurrent purpura or periorbital bleeding because of a tendency for the prevascular deposition of amyloid,<sup>49</sup> and waxy nodules.<sup>50,51</sup> Conjunctival amyloidosis appears as a pale yellow nodule associated with recurrent subconjunctival hemorrhage.<sup>52</sup> In general, conjunctival amyloidosis tends to be localized,<sup>52</sup> but an association with systemic amyloidosis has also been reported.<sup>52,53</sup> Orbital amyloidosis may involve the lacrimal gland, extraocular muscles, orbital fat, and lacrimal sac, mimicking an inflammatory or lymphoproliferative disorder.<sup>54,55</sup> Deposition within the levator palpebrae muscle may present as ptosis of unknown cause.<sup>54,56</sup> Although orbital amyloidosis is almost always localized, systemic disease should be excluded.<sup>54</sup>

With rare exceptions, amyloid deposits in the vitreous signify a familial neuropathic form of amyloidosis due to mutations in the transthyretin gene.<sup>57</sup> Neural manifestations are of a slowly progressive

peripheral polyneuropathy with sparing of the central nervous system.<sup>57</sup> The vitreous deposits are grayish, cobweb-like, and may be attached to the posterior surface of the lens as white dots resembling foot plates (pseudopodia lentis).<sup>58</sup> Similar white opacities may be observed in the retina over arterioles and venules that are otherwise clinically and angiographically normal.<sup>59</sup>

**Systemic features** The most common form of systemic amyloidosis is light chain amyloidosis, which may be idiopathic in origin or associated with multiple myeloma. Amyloid A amyloidosis occurs most frequently as a complication of chronic inflammatory disease. Familial amyloidosis is most frequently due to mutations that lead to folding disorder of the protein transthyretin.<sup>47</sup> The clinical features are varied, depending upon the organ involved. Proteinuria is associated with renal involvement in systemic amyloidosis, peripheral polyneuropathy is associated with familial amyloidoses, and cardiomegaly with amyloid deposition in the heart.

## REFERENCES

- Carney JA, Gordon H, Carpenter PC et al. The complex of myxomas, spotty pigmentation, and endocrine overactivity. *Medicine (Baltimore)* 1985; 64: 270–283.
- Kennedy RH, Waller RR, Carney JA. Ocular pigmented spots and eyelid myxomas. *Am J Ophthalmol* 1987; 104: 533–538.
- Peutz JLA. On a very remarkable case of familial polyposis of the mucous membrane of the intestinal tract and nasopharynx accompanied by peculiar pigmentations of the skin and mucous membrane. *Ned Tijdschr Geneesk* 1921; 10: 839–847.
- Jeghers H, McKusick VA, Katz KH. Generalized intestinal polyposis and melanin spots of the oral mucosa, lips and digits; a syndrome of diagnostic significance. *N Engl J Med* 1949; 241: 1031–1036.
- Jenne DE, Reimann H, Nezu J et al. Peutz–Jeghers syndrome is caused by mutations in a novel serine threonine kinase. *Nature Genet* 1998; 18: 38–43.
- Traboulsi EI, Maumenee IH, Krush AJ et al. Pigmented ocular fundus lesions in the inherited gastrointestinal polyposis syndromes and in hereditary nonpolyposis colorectal cancer. *Ophthalmology* 1988; 95: 964–969.
- Traboulsi EI, Maumenee IH. Periocular pigmentation in the Peutz–Jeghers syndrome. *Am J Ophthalmol* 1986; 102: 126–127.
- Giardiello FM, Offerhaus JG. Phenotype and cancer risk of various polyposis syndromes. *Eur J Cancer* 1995; 31A: 1085–1087.
- Goldenhar M. Associations malformatives de l'oeil et de l'oreille: en particulier, le syndrome: dermoide epibulbaire–appendices auriculaires–fistula auris congenita et ses relations avec la dysostose mandibulo-faciale. *J Genet Hum* 1952; 1: 243–282.
- Gorlin RJ, Jue KL, Jacobsen U, Goldschmidt E. Oculoauriculovertebral dysplasia. *J Pediatr* 1963; 63: 991–999.
- Grabb WC. The first and second branchial arch syndrome. *Plast Reconstr Surg* 1965; 36: 485–508.
- Wang R, Martinez-Frias ML, Graham JM Jr. Infants of diabetic mothers are at increased risk for the oculo-auriculo-vertebral sequence: A case-based and case-control approach. *J Pediatr* 2002; 141: 611–617.
- Baum JL, Feingold M. Ocular aspects of Goldenhar's syndrome. *Am J Ophthalmol* 1973; 75: 250–257.
- Velez G. Duane's retraction syndrome associated with Goldenhar's syndrome. *Am J Ophthalmol* 1970; 70: 945–946.
- Nijhawan N, Morad Y, Seigel-Bartelt J, Levin AV. Caruncle abnormalities in the oculo-auriculo-vertebral spectrum. *Am J Med Genet* 2002; 113: 320–325.
- Margolis S, Aleksic S, Charles N et al. Retinal and optic nerve findings in Goldenhar–Gorlin syndrome. *Ophthalmology* 1984; 91: 1327–1333.
- Rollnick BR, Kaye CI, Nagatoshi K et al. Oculoauriculovertebral dysplasia and variants: phenotypic characteristics of 294 patients. *Am J Med Genet* 1987; 26: 361–375.
- Kallen K, Robert E, Castilla EE et al. Relation between oculo-auriculo-vertebral (OAV) dysplasia and three other non-random associations of malformations (VATER, CHARGE, and OEIS). *Am J Med Genet A* 2004; 127: 26–34.
- Cohen MM Jr, Hayden PW. A newly recognized hamartomatous syndrome. *Birth Defects Orig Artic Ser* 1979; 15: 291–296.
- Wiedemann HR, Burgio GR, Aldenhoff P et al. The proteus syndrome. Partial gigantism of the hands and/or feet, nevi, hemihypertrophy, subcutaneous tumors, macrocephaly or other skull anomalies and possible accelerated growth and visceral affections. *Eur J Pediatr* 1983; 140: 5–12.
- Happle R. Lethal genes surviving by mosaicism: a possible explanation for sporadic birth defects involving the skin. *J Am Acad Dermatol* 1987; 16: 899–906.
- Nguyen D, Turner JT, Olsen C et al. Cutaneous manifestations of proteus syndrome: correlations with general clinical severity. *Arch Dermatol* 2004; 140: 947–953.
- Eng C. PTEN: one gene, many syndromes. *Hum Mutat* 2003; 22: 183–198.
- Turner JT, Cohen MM Jr, Biesecker LG. Reassessment of the Proteus syndrome literature: application of diagnostic criteria to published cases. *Am J Med Genet A* 2004; 130: 111–122.
- Bouzas EA, Krasnewich D, Koutroumanidis M et al. Ophthalmologic examination in the diagnosis of Proteus syndrome. *Ophthalmology* 1993; 100: 334–338.
- De Becker I, Gajda DJ, Gilbert-Barness E, Cohen MM Jr. Ocular manifestations in Proteus syndrome. *Am J Med Genet* 2000; 92: 350–352.
- Sheard RM, Pope FM, Snead MP. A novel ophthalmic presentation of the Proteus syndrome. *Ophthalmology* 2002; 109: 1192–1195.
- Biesecker LG, Happle R, Mulliken JB et al. Proteus syndrome: diagnostic criteria, differential diagnosis, and patient evaluation. *Am J Med Genet* 1999; 84: 389–395.
- Schimke RN, Hartmann WH, Prout TE, Rimoin DL. Syndrome of bilateral pheochromocytoma, medullary thyroid carcinoma and multiple neuromas. A possible regulatory defect in the differentiation of chromaffin tissue. *N Engl J Med* 1968; 279: 1–7.
- Morrison PJ, Nevin NC. Multiple endocrine neoplasia type 2B (mucosal neuroma syndrome, Wagenmann–Froboese syndrome). *J Med Genet* 1996; 33: 779–782.
- Eng C, Smith DP, Mulligan LM et al. Point mutation within the tyrosine kinase domain of the RET proto-oncogene in multiple endocrine neoplasia type 2B and related sporadic tumours. *Hum Mol Genet* 1994; 3: 237–241.
- Robertson DM, Sizemore GW, Gordon H. Thickened corneal nerves as a manifestation of multiple endocrine neoplasia. *Trans Sect Ophthalmol Am Acad Ophthalmol Otolaryngol* 1975; 79: OP772–787.
- Jacobs JM, Hawes MJ. From eyelid bumps to thyroid lumps: report of a MEN type IIb family and review of the literature. *Ophthalm Plast Reconstr Surg* 2001; 17: 195–201.
- Eter N, Klingmuller D, Hoppner W, Spitznas M. Typical ocular findings in a patient with multiple endocrine neoplasia type 2b syndrome. *Graefes Arch Clin Exp Ophthalmol* 2001; 239: 391–394.
- Gomez JM, Biarnes J, Volpini V, Marti T. Neuromas and prominent corneal nerves without MEN-2B. *Ann Endocrinol (Paris)* 1998; 59: 492–494.
- Riley FC Jr, Robertson DM. Ocular histopathology in multiple endocrine neoplasia type 2b. *Am J Ophthalmol* 1981; 91: 57–64.
- Spector B, Klintworth GK, Wells SA Jr. Histologic study of the ocular lesions in multiple endocrine neoplasia syndrome type IIb. *Am J Ophthalmol* 1981; 91: 204–215.
- O'Riordain DS, O'Brien T, Weaver AL et al. Medullary thyroid carcinoma in multiple endocrine neoplasia types 2A and 2B. *Surgery* 1994; 116: 1017–1023.
- Eng C, Clayton D, Schuffenecker I et al. The relationship between specific RET proto-oncogene mutations and disease phenotype in multiple endocrine neoplasia type 2. International RET mutation consortium analysis. *JAMA* 1996; 276: 1575–1579.
- Kraemer KH, Lee MM, Scotto J. Xeroderma pigmentosum. Cutaneous, ocular, and neurologic abnormalities in 830 published cases. *Arch Dermatol* 1987; 123: 241–250.

41. Cleaver JE. Common pathways for ultraviolet skin carcinogenesis in the repair and replication defective groups of xeroderma pigmentosum. *J Dermatol Sci* 2000; 23: 1–11.
42. Kraemer KH, Lee MM, Andrews AD, Lambert WC. The role of sunlight and DNA repair in melanoma and nonmelanoma skin cancer. The xeroderma pigmentosum paradigm. *Arch Dermatol* 1994; 130: 1018–1021.
43. Wattendorf DJ, Kraemer KH. *Xeroderma pigmentosum*. Seattle: University of Washington, 2005.
44. Cleaver JE, Afzal V, Feeney L et al. Increased ultraviolet sensitivity and chromosomal instability related to P53 function in the xeroderma pigmentosum variant. *Cancer Res* 1999; 59: 1102–1108.
45. Dollfus H, Porto F, Caussade P et al. Ocular manifestations in the inherited DNA repair disorders. *Surv Ophthalmol* 2003; 48: 107–122.
46. Johnson MW, Skuta GL, Kincaid MC et al. Malignant melanoma of the iris in xeroderma pigmentosum. *Arch Ophthalmol* 1989; 107: 402–407.
47. Sipe JD, Cohen AS. Amyloidosis. In: Kasper DL, Braunwald E, Fauci AS et al., eds. *Harrison's principles of internal medicine*, 16th edn. New York: McGraw-Hill, 2005.
48. Westermark P, Benson MD, Buxbaum JN et al. Amyloid: toward terminology clarification. Report from the Nomenclature Committee of the International Society of Amyloidosis. *Amyloid* 2005; 12: 1–4.
49. Landa G, Aloni E, Milshtein A et al. Eyelid bleeding and atypical amyloidosis. *Am J Ophthalmol* 2004; 138: 495–496.
50. Brownstein MH, Elliott R, Helwig EB. Ophthalmologic aspects of amyloidosis. *Am J Ophthalmol* 1970; 69: 423–430.
51. Knowles DM 2nd, Jakobiec FA, Rosen M, Howard G. Amyloidosis of the orbit and adnexae. *Surv Ophthalmol* 1975; 19: 367–384.
52. Purcell JJ Jr, Birkenkamp R, Tsai CC, Riner RN. Conjunctival involvement in primary systemic nonfamilial amyloidosis. *Am J Ophthalmol* 1983; 95: 845–847.
53. Shields JA, Eagle RC, Shields CL et al. Systemic amyloidosis presenting as a mass of the conjunctival semilunar fold. *Am J Ophthalmol* 2000; 130: 523–525.
54. Taban M, Piva A, See RF et al. Review: orbital amyloidosis. *Ophthalm Plast Reconstr Surg* 2004; 20: 162–165.
55. Marcet MM, Roh JH, Mandeville JT, Woog JJ. Localized orbital amyloidosis involving the lacrimal sac and nasolacrimal duct. *Ophthalmology* 2006; 113: 153–156.
56. Dinakaran S, Singh AD, Rennie IG. Orbital amyloidosis presenting as ptosis. *Eye* 2005; 19: 110–112.
57. Sandgren O. Ocular amyloidosis, with special reference to the hereditary forms with vitreous involvement. *Surv Ophthalmol* 1995; 40: 173–196.
58. Hitchings RA, Tripathi RC. Vitreous opacities in primary amyloid disease. A clinical, histochemical, and ultrastructural report. *Br J Ophthalmol* 1976; 60: 41–54.
59. Savage DJ, Mango CA, Streeten BW. Amyloidosis of the vitreous. Fluorescein angiographic findings and association with neovascularization. *Arch Ophthalmol* 1982; 100: 1776–1779.



# Examination techniques

Nikolaos Trichopoulos and Bertil Damato

## INTRODUCTION

This chapter highlights procedures that are specific to the assessment of a patient with a uveal tumor (Box 31.1). It is assumed that a full ophthalmic and systemic history is routinely obtained in all patients, in addition to complete examination of both eyes and appropriate systemic assessment, consisting of both clinically and relevant ancillary investigations.

## HISTORY TAKING

**Initial assessment** The history can sometimes provide diagnostic clues, for example if the patient has been a heavy smoker for many years, or if a previous mastectomy has been performed. Although such information might suggest the source of an intraocular metastasis, it should not be relied upon to distinguish between a metastasis and other types of tumor, such as melanoma and hemangioma. This is because dual pathology is not uncommon. The history also provides an understanding of the patient's visual needs, which may help in the selection of the most appropriate form of treatment. The duration of the visual loss can have prognostic significance, for example in patients with choroidal hemangioma in whom visual loss is irreversible if long-standing.

**Follow-up** Routine use of a questionnaire ensures that at every follow-up visit each patient is asked all the relevant questions about their general health, visual symptoms, ocular discomfort, and concerns about possible ocular complications and survival.

## VISUAL ACUITY

If possible, the visual acuity should be measured using a LogMAR chart,<sup>1</sup> which overcomes the limitations of the Snellen test and which also facilitates statistical analysis of vision in any outcomes analysis. If central vision is lost, the eccentric visual acuity should be measured using the optotype and, if necessary, finger counting before checking for hand movement vision.

## SLIT LAMP EXAMINATION

It is necessary to define the primary tumor, recognizing any secondary effects, predisposing factors, and concurrent disease:

- Site of origin (iris, ciliary body, choroid)
- Location (superior, superonasal, nasal, etc.)
- Circumferential spread, ideally in clock minutes in a clockwise direction (e.g. 5–30 or 55–5). This is easier than using degrees and

more precise than clock hours. For iris tumors there may be scope for recording circumferential spread at the pupil margin, mid-peripheral, and peripheral iris

- Posterior margin (pars plicata, iris surface)
- Anterior margin (iris surface, angle, cornea)
- Consistency (solid, cystic, multicystic)<sup>2</sup>
- Shape (i.e. flat, dome, multinodular)
- Margins (i.e. diffuse, discrete)<sup>3</sup>
- Color (pink, white, yellow, red, orange, tan, brown, black, etc.)
- Vascularity (present or absent)
- Seeding (i.e. across iris or into angle, vitreous)<sup>4</sup>
- Angle involvement (in clock minutes)
- Extraocular spread (i.e. absent, nodular, diffuse)
- Longitudinal and transverse basal dimensions, using the measure on the slit lamp
- Secondary effects (e.g. dilated episcleral vessels, band keratopathy,<sup>5</sup> glaucoma,<sup>6</sup> hyphema,<sup>7</sup> ectropion uveae and pupillary peaking, iris cyst formation, and lens abnormality such as cataract, deformity, and subluxation)
- Predisposing factors (e.g. ocular or oculodermal melanocytosis,<sup>8</sup> Sturge–Weber syndrome and other vascular malformations).

## INDIRECT OPHTHALMOSCOPY

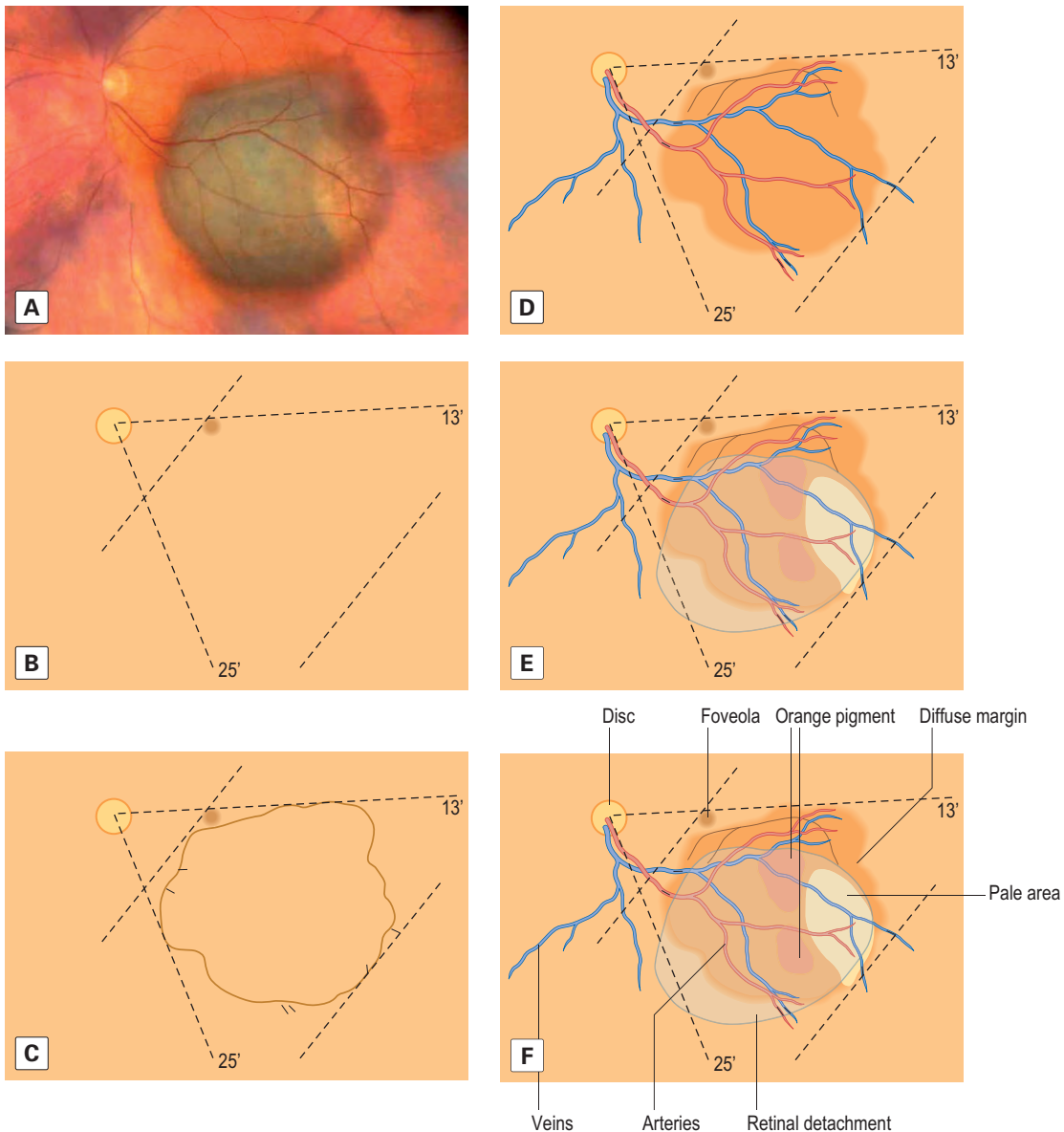
It is essential to examine the entire fundus, with indentation if necessary, to identify any other pathology and to exclude any other tumors. Both eyes should be examined, ideally with mydriasis. The senior author has devised the mnemonic MELANOMA to alert the clinician to the presence of an intraocular tumor in situations where the pupils are not routinely dilated (Box 31.2).

### BOX 31.1 Examination Techniques

- These include history taking, slit-lamp examination and ophthalmoscopy
- Drawings can complement photography
- Tumor dimensions can be estimated both using charts and ophthalmoscopically
- Three-mirror examination is useful in selected cases
- Transillumination gives an approximate indication of tumor extent

**BOX 31.2 Symptoms and Signs Indicating the Presence of an Intraocular Tumor**

- Melanoma or other tumor visible externally in the iris or episclera
- Eccentric visual phenomena, such as photopsia, floaters, and field loss
- Lens abnormalities, such as cataract, astigmatism, and coloboma
- Afferent pupillary defect, mostly caused by secondary retinal detachment
- No optical correction with spectacles because of blurring or metamorphopsia
- Ocular hypertension, especially if asymmetrical
- Melanocytosis, predisposing to melanoma
- Asymmetrical episcleral vessels, indicating a ciliary body tumor



**Fig. 31.1** Drawing a choroidal tumor. (A) Color photograph; (B) locating tumor margins with respect to disk and fovea; (C) delineating tumor margins; (D) drawing vascular details; (E) adding tumor features; (F) annotations. (The numbers indicate circumferential extent with respect to disc, in clock minutes).

It is necessary to describe the primary tumor, any secondary effects, and any predisposing factors, as follows:

- Tissue of origin (choroid, retina, retinal pigment epithelium)
- Quadrant (superotemporal, superior, superonasal, etc.)
- Shape (flat, dome, collar-stud)
- Margins (discrete, diffuse)
- Color (pink, white, yellow, red, orange, tan, brown, black, etc.)
- Vascularity (vascular, avascular)
- Posterior extent, including distances to optic disc margin and fovea (i.e. in disc diameters)
- Anterior extent (post-equatorial, pre-equatorial, pars plana, pars plicata, etc.)
- Circumferential involvement of disc, ciliary body, and perhaps choroid (in clock minutes)
- Internal spread (subretinal space, retina, vitreous)
- Secondary effects (e.g. RPE changes such as drusen and orange pigment over the tumor;<sup>9</sup> RPE changes adjacent to the tumor;<sup>10</sup> exudative retinal detachment; and hemorrhage<sup>11,12</sup>)
- Predisposing factors (e.g. ocular melanocytosis, melanocytoma,<sup>13</sup> diffuse choroidal hemangioma).

## FUNDUS DRAWING

Fundus drawings complement any photography in several ways, for example allowing important features to be highlighted by means of notes and markers. The technique has been described elsewhere (Fig. 31.1).<sup>14</sup>

1. Ask the patient to lie supine on a couch or in a reclining chair.
2. Stand at the patient's head and place the retinal chart on a tray next to them. The top of the chart should be facing towards the patient's feet. You should be able to move around so as to position yourself directly opposite the retinal quadrant being examined.
3. Hold the indirect lens in the non-dominant hand and a pencil in your dominant hand.
4. Draw symbols for the optic disc and fovea, then look at the fundus and rotate the drawing pad so that the optic disc and fovea are aligned in the same way as the fundus image.
5. Identify the meridians, in clock minutes, of the two lateral margins of the tumor, in relation to the disc or fovea, and draw these lines on the chart.
6. Estimate the distance between posterior tumor margin and the disc or fovea, and mark that point on the chart.
7. Estimate the location of the anterior tumor margin in relation to equator or ora serrata, and mark that point on the chart.
8. Draw the profile of the tumor, using the marks already on the chart as guides.
9. Starting at the tumor and working backwards towards the optic disc, draw the major retinal blood vessels, placing conspicuous bifurcations and crossings in their correct positions in relation to tumor margins.
10. Fill in details, such as texture, tumor vessels, RPE changes, hemorrhages, exudates, and retinal detachment.
11. Ensure that the patient's name and hospital number, the date of the examination, and your signature have all been documented. Figure 31.1 shows an example of how fundus lesions are documented.

## ESTIMATION OF INTRAOCULAR TUMOR BASAL DIMENSIONS

Schematic diagrams have been prepared to facilitate the estimation of ocular dimensions on clinical examination (Fig. 31.2). In addition,

indirect ophthalmoscopy can be used to estimate the basal dimensions of intraocular tumors. The chord length tumor basal diameters (anteroposterior or longitudinal and circumferential or latitudinal) are estimated while performing indirect ophthalmoscopy by assessing the proportion of a specific condensing lens field that is filled by the tumor's image. During this assessment, a 20D lens is considered to have a field diameter of approximately 12 mm, whereas a 28D lens is regarded to have a field diameter of 13 mm. For example, a tumor that fills half of the 20D lens field would be judged to have a diameter of approximately 6 mm, whereas one that fills two-thirds of a 28D lens field would be considered to be about 8.5 mm in diameter. Tumor thickness is best estimated by ultrasonography.

## THREE-MIRROR EXAMINATION

The indications for three-mirror examination are to: identify the cause of raised intraocular pressure; determine whether a lesion behind the iris is solid or cystic; find a small retinal angioma; determine the anterior extent of a pre-equatorial tumor; and measure the circumferential extent of ciliary body or angle involvement by a tumor, aligning in turn each lateral tumor margin with the center of the mirror.

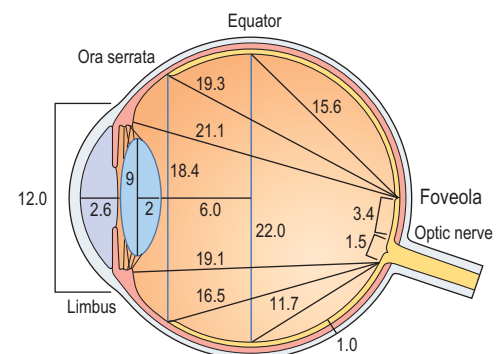
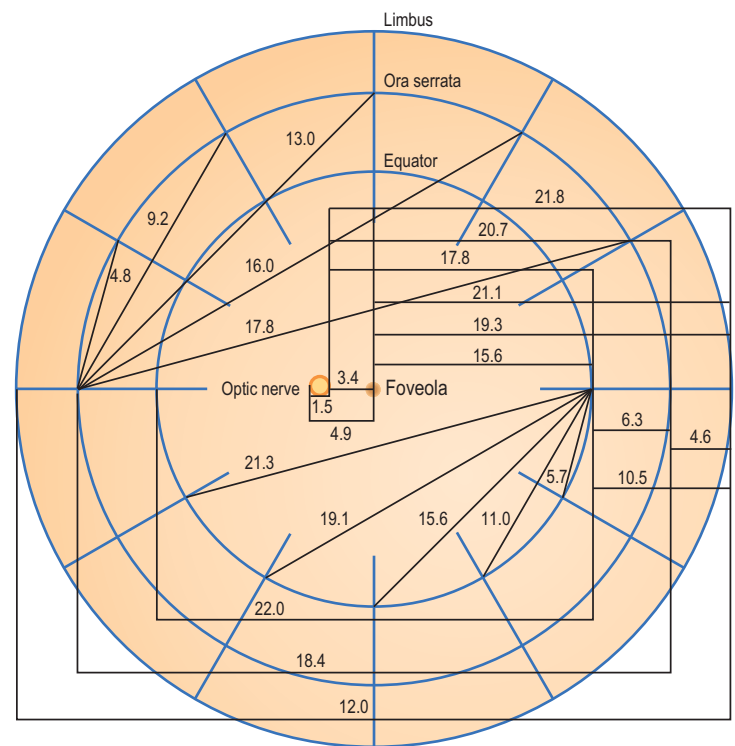
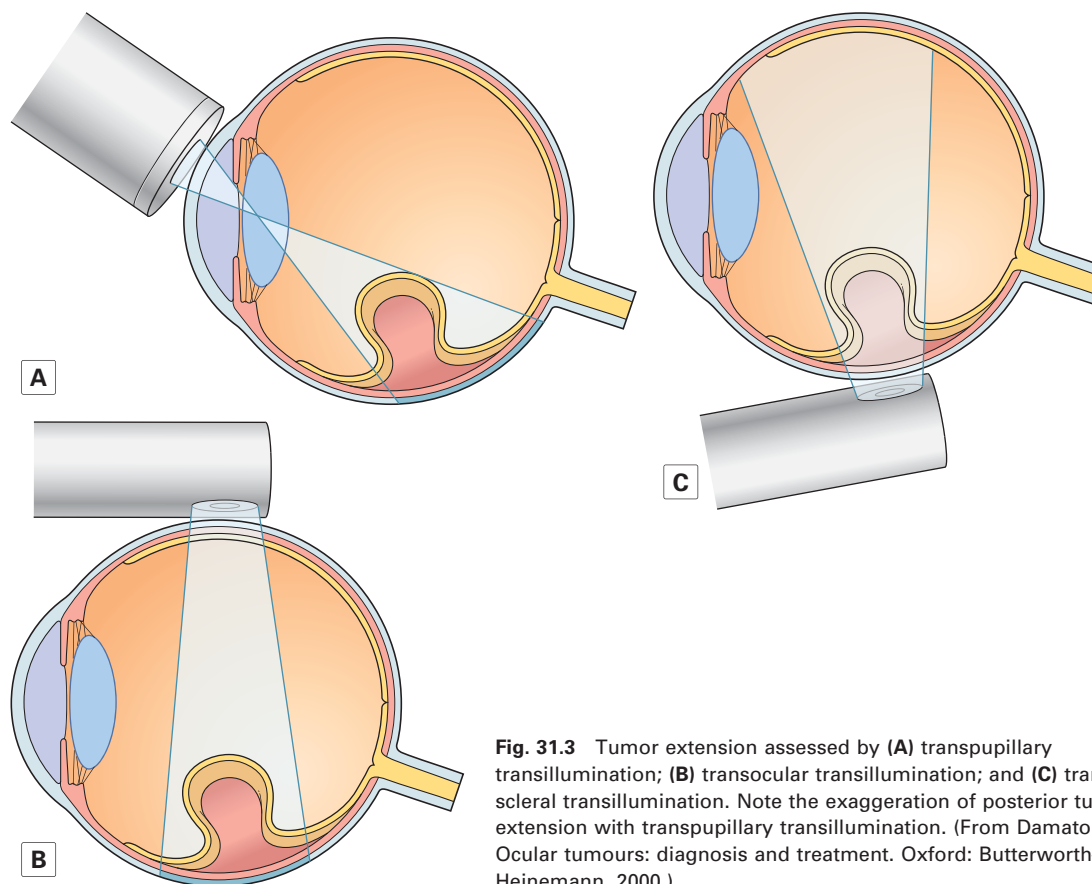


Fig. 31.2 Charts for estimating chord lengths in millimeters in an emmetropic eye. (Courtesy of TA Rice, MD, Stanford, USA).





**Fig. 31.3** Tumor extension assessed by (A) transpupillary transillumination; (B) transocular transillumination; and (C) trans-scleral transillumination. Note the exaggeration of posterior tumor extension with transpupillary transillumination. (From Damato B. Ocular tumours: diagnosis and treatment. Oxford: Butterworth-Heinemann, 2000.)

## TRANSILLUMINATION

Transillumination can be used to locate tumor margins. In general, pigmented tumors and intraocular hemorrhage would block the transmission of light. It must be realized that not all pigmented tumors are melanoma and, conversely, not all melanomas are pigmented.<sup>15</sup> Different techniques are possible (Fig. 31.3). These include:

- Transpupillary, placing the illuminator on the cornea. Care must be taken not to overestimate posterior extension because of an oblique shadow cast by a thick tumor.
- Transocular, with a right-angled transilluminator on the globe directly opposite to the tumor. This is less convenient than transpupillary transillumination but slightly more accurate.

- Trans-scleral, with the light source on the sclera over the tumor. This only determines whether or not the tumor transmits light.

## ANCILLARY TESTS

Ancillary investigations such as photography, angiography, and ultrasonography are discussed in detail elsewhere (see Chapter 32).

## CONCLUSION

The different examination techniques described in this chapter need to be used selectively. Each requires special expertise in performing the test and to ensure that the results are interpreted correctly.

## REFERENCES

1. Westheimer G. Visual acuity. In: Hart WM Jr, ed. *Adler's physiology of the eye: clinical application*. St. Louis: Mosby, 1992.
2. Shields JA, Kline MW, Augsburger JJ. Primary iris cysts. Review of the literature and report of 62 cases. *Br J Ophthalmol* 1984; 68: 152–166.
3. Char DH, Crawford JB, Gonzales J, Miller T. Iris melanoma with increased intraocular pressure. Differentiation of focal solitary tumors from diffuse or multiple tumors. *Arch Ophthalmol* 1989; 107: 548–551.
4. McMenamin PG, Lee WR. Ultrastructural pathology of melanomalytic glaucoma. *Br J Ophthalmol* 1986; 70: 895–906.
5. Shah PG, Shields CL, Shields JA, Di Marco C. Band keratopathy secondary to an iris melanoma. *Cornea* 1991; 10: 67–69.
6. Girkin CA, Goldberg I, Mansberger SL, Shields JA, Shields CL. Management of iris melanoma with secondary glaucoma. *J Glaucoma* 2002; 11: 71–74.
7. Spandau UH, Dithmar S, Grossniklaus HE, Volcker HE, Jonas JB. Recurrent spontaneous hyphema secondary to a melanocytic iris lesion. *Acta Ophthalmol Scand* 2004; 82: 494–495.
8. Singh AD, De Potter P, Fijal BA et al. Lifetime prevalence of uveal melanoma in white patients with oculo (dermal) melanocytosis. *Ophthalmology* 1998; 105: 195–198.
9. Damato BE, Foulds WS. Tumour-associated retinal pigment epitheliopathy. *Eye* 1990; 4: 382–387.
10. Haut J, Sobel-Martin A, Dureuil J, Larricart P, Sarnikowski C. Atrophies 'like flows' of the retinal pigment epithelium: a neuroepithelium-draining method of the posterior pole. *Ophthalmologica* 1984; 189: 121–127.
11. Lee J, Logani S, Lakosha H et al. Preretinal neovascularization associated with choroidal melanoma. *Br J Ophthalmol* 2001; 85: 1309–1312.
12. el Baba F, Hagler WS, De la Cruz A, Green WR. Choroidal melanoma with pigment dispersion in vitreous and melanomalytic glaucoma. *Ophthalmology* 1988; 95: 370–377.
13. Shetlar DJ, Folberg R, Gass JD. Choroidal malignant melanoma associated with a melanocytoma. *Retina* 1999; 19: 346–349.
14. Damato B. Binocular indirect ophthalmoscopy. In: Damato B, ed. *Ocular tumours: diagnosis and treatment*. Oxford: Butterworth-Heinemann, 2000.
15. Robertson DM, Campbell RJ. Errors in the diagnosis of malignant melanoma to the choroid. *Am J Ophthalmol* 1979; 87: 269–275.

# Diagnostic techniques

Sophie J. Bakri, LuAnn Sculley and Arun D. Singh

## INTRODUCTION

Uveal melanoma, which comprises melanomas of the choroid (80%), ciliary body (12%), and iris (8%), is the most frequent primary malignant intraocular tumor of adults.<sup>1</sup> The diagnostic accuracy is over 99% based on indirect ophthalmoscopy, ultrasonography, and angiography.<sup>2</sup> However, in atypical cases there is a variety of other imaging modalities that can be used to establish the diagnosis. This chapter discusses the traditional as well as newer modalities for imaging iris, ciliary body, and choroidal melanomas.

## PHOTOGRAPHY

**Anterior segment photography** is used to document the size, shape, and surface features of iris lesions such as cysts, nevi, and melanomas (Fig. 32.1). Anterior segment photography can also be helpful in documenting large ciliary body melanomas when they are visible through a widely dilated pupil.

**Fundus photography** is used to document choroidal nevi and choroidal melanomas. Fundus photography is particularly useful when evaluating indeterminate choroidal tumors for growth, the response of choroidal melanoma to therapy, and assessing for recurrences (Fig. 32.2A). Fundus photographs can be stored on 35 mm film or in a digital format for rapid retrieval. In addition, digital imaging allows the computer software to measure the size of the lesion and compare it accurately against future images.

Standard fundus cameras allow photography of up to 85° of fundus, and are useful for monitoring lesions limited to the posterior pole and equator. Collages of many photos can be joined together to image larger lesions, but these are not ideal. Lesions located in the peripheral region can be photographed by wide-angle fundus photography systems such as the Panoret-1000 and Optomap, which can image between 130° and 200° of the fundus.<sup>3</sup>

## FLUORESCEIN ANGIOGRAPHY

Fluorescein angiography has limited utility in the diagnosis of choroidal melanomas.<sup>4</sup> The characteristic angiographic features of choroidal melanomas include intrinsic tumor circulation ('double circulation'), hot spots, and late leakage (Fig. 32.2B,C). Intrinsic tumor circulation is evident in medium and large choroidal melanoma as abnormal choroidal vessels seen in early phases representing abnormal vessels within the choroidal tumor. The hot spots are caused by pinpoint leaks from the retinal pigment epithelium that enlarge minimally and stain late. An absence of late diffuse leakage within the choroidal tumor

goes against the diagnosis of choroidal melanoma.<sup>4</sup> However, fluorescein angiography can be useful in differentiating other simulating lesions, such as choroidal hemangiomas, disciform lesions, choroidal detachments, and hemorrhagic lesions. Anterior segment fluorescein angiography has limited applications in rare cases of iris hemangiomas.

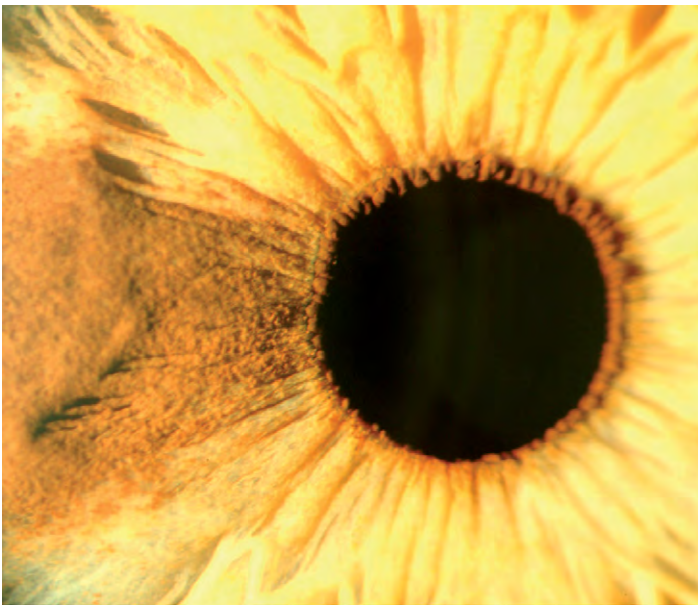
## INDOCYANINE GREEN ANGIOGRAPHY

Indocyanine green angiography allows better visualization of the tumor vasculature than fluorescein angiography because of several physicochemical properties of indocyanine green (ICG) (Fig. 32.2D).<sup>5-7</sup> Indocyanine green absorbs and emits light in the near-infrared spectrum, wavelengths that are absorbed less by the retinal pigment epithelium and choroid.<sup>8</sup> Because of the high affinity of ICG to bind with plasma proteins,<sup>9</sup> it tends to stay within fenestrated choriocapillaris with slow extravasation into choroidal stroma,<sup>10</sup> allowing visualization of larger choroidal vessels.

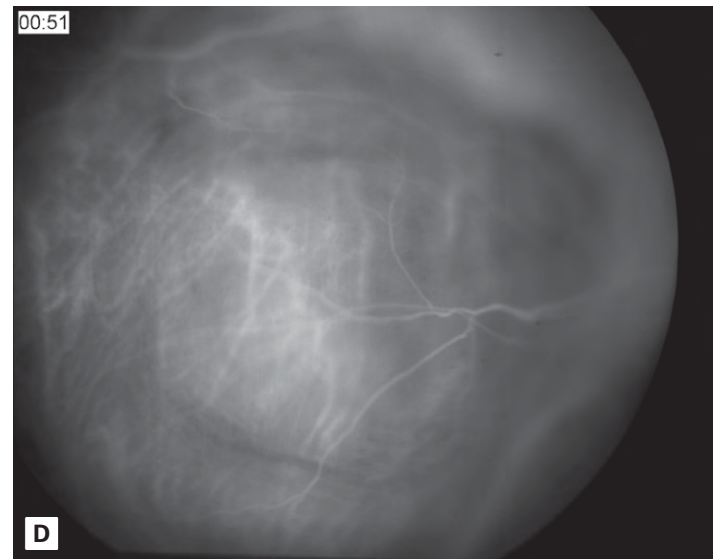
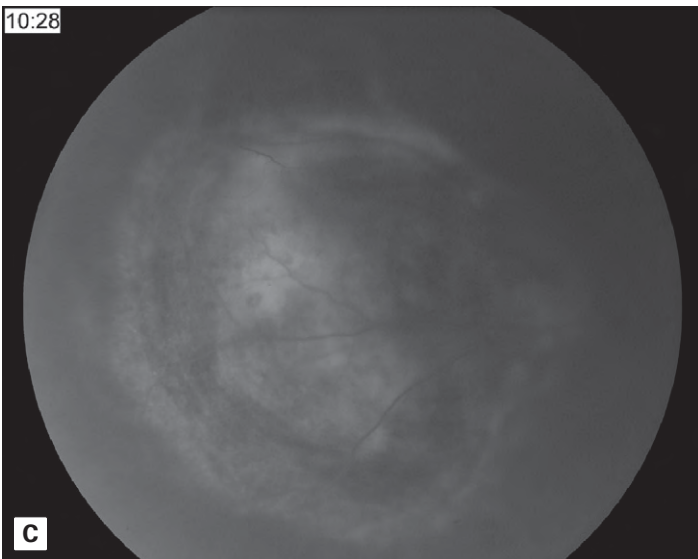
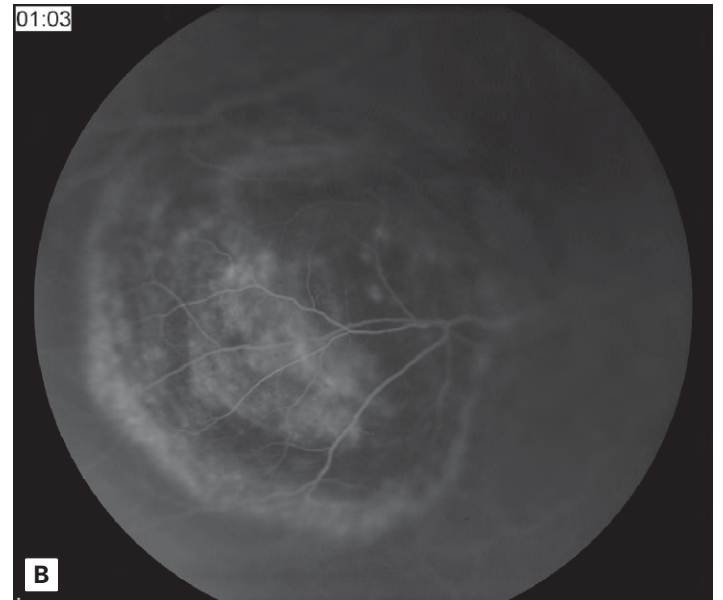
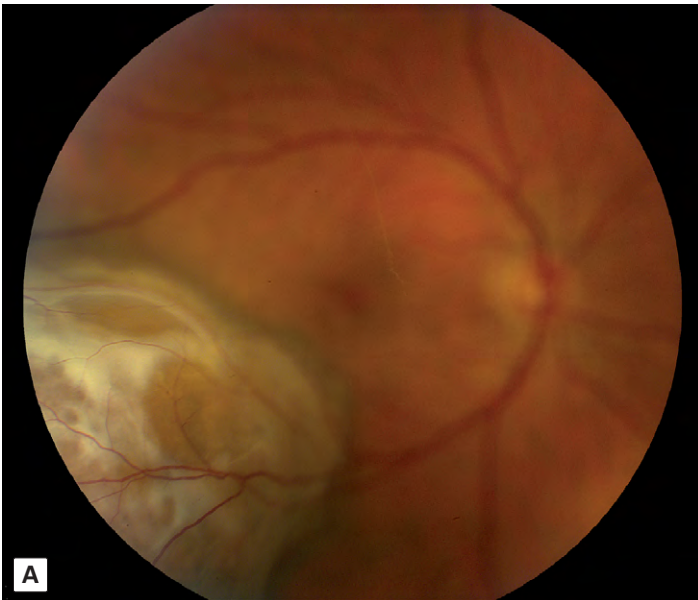
There are technical variations in the way ICG angiography is performed that can influence the microvasculature details observed within choroidal melanoma and the overall appearance of the lesion, especially in the late phases of the angiogram.<sup>11</sup> In general, confocal scanning laser ophthalmoscopic systems such as the Heidelberg system offer better contrast than non-confocal systems, as the scattered light is eliminated.<sup>12</sup> In addition, higher rates of image capture with the scanning laser ophthalmoscope offer greater temporal resolution than conventional systems, a distinct advantage when studying tumor vasculature.<sup>12</sup>

Recent preliminary observations indicate that ICG angiographic findings may be used in conjunction with other known risk factors to predict the risk of tumor growth in suspicious choroidal nevi. In a study of 98 patients with choroidal melanocytic lesions that were observed until growth, a statistically significant association between the presence of complex microcirculatory patterns (parallel with cross-linking, arcs with branching, loop and/or network) and time to tumor growth was observed.<sup>13</sup> In another smaller study there was evidence to suggest that 'loops vascular pattern' on ICG was suggestive of small choroidal melanoma.<sup>14</sup> These preliminary observations need to be corroborated by studies on larger numbers of patients.

Choroidal melanomas achieve maximal fluorescence at an average of 18 minutes after injection of the dye.<sup>15</sup> In general, non-pigmented choroidal melanomas show an earlier onset of fluorescence (<1 minute) than the pigmented variety (3 minutes). Overall, the pattern



**Fig. 32.1** Slit lamp photograph of an iris nevus, demonstrating fine surface nodularity and pupillary distortion.



**Fig. 32.2** Fundus appearance of a choroidal melanoma (A). Fluorescein angiogram showing characteristic ill-defined leakage in the early phase (B) which progresses with angiogram into the late phase (C). Indocyanine green angiography allows better visualization of the intrinsic tumor vasculature (D).



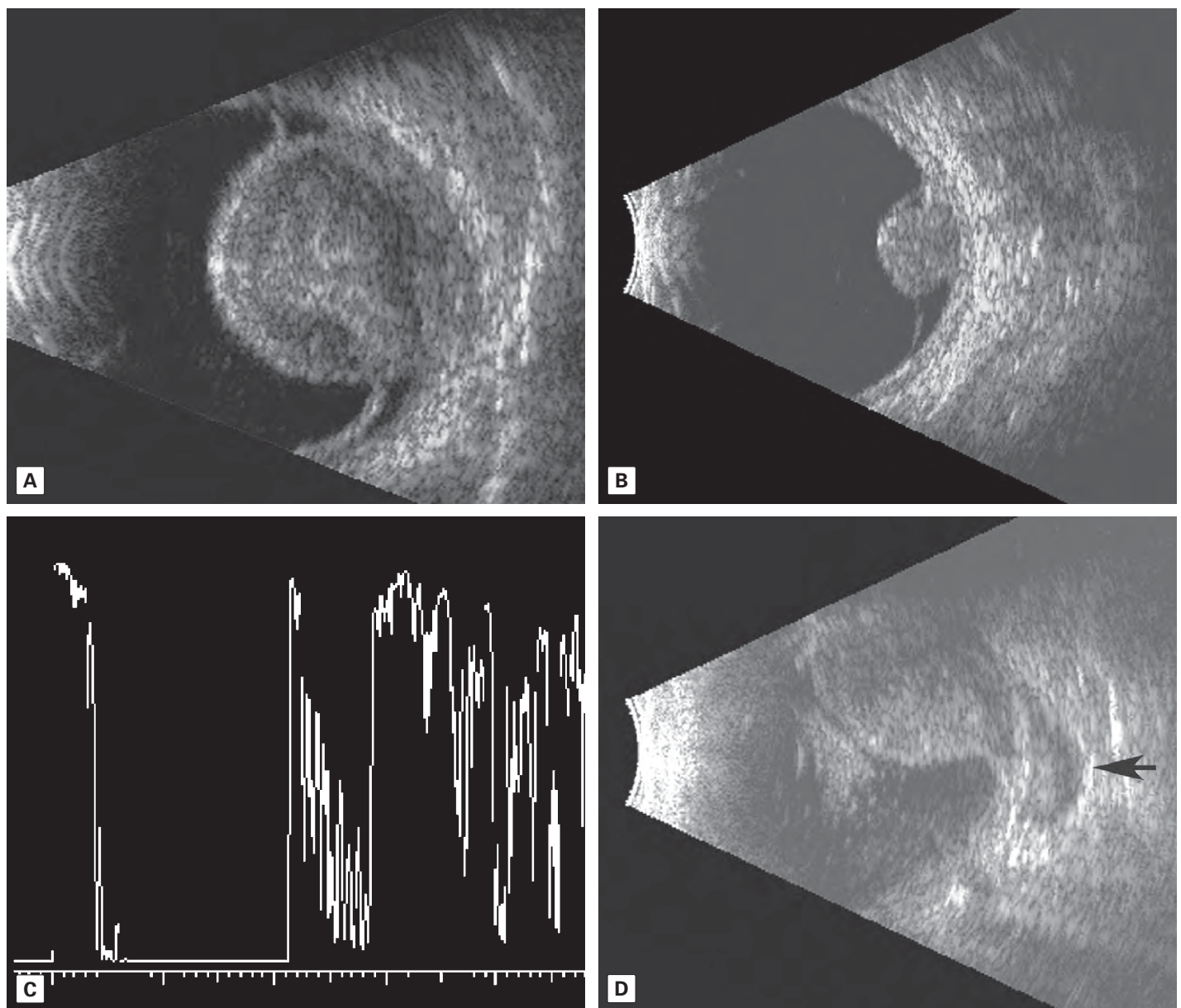
of fluorescence within a choroidal melanoma is heterogeneous and varies from hypofluorescent to isofluorescent and hyperfluorescent, depending on the extent of tumor pigmentation. In contrast, choroidal metastases tend to have a homogeneous and diffuse fluorescence with late isofluorescence. Choroidal hemangiomas have a unique pattern of fluorescence on ICG angiography, characterized by early onset of fluorescence with early maximal fluorescence (within 5 minutes), followed by 'washout' of the dye in the late phases of the angiogram.<sup>16</sup>

## ULTRASONOGRAPHY

**A/B scan ultrasonography** imaging with A and B scan techniques is currently the most important test in the diagnosis of choroidal melanoma.<sup>4,17</sup> It not only provides clues to the diagnosis, but also defines the intraocular extent of the tumor. Extraocular extension of the tumor is also readily detected by ultrasonography.

Typical features of a choroidal melanoma on B-scan ultrasonography include an acoustic quiet zone within the tumor, choroidal excavation, and orbital shadowing (Fig. 32.3A).<sup>4,17</sup> There may be vascular pulsations in a highly vascularized tumor. A mushroom-like configuration, indicating that the tumor has broken through Bruch's membrane, is almost pathognomonic of choroidal melanoma (Fig. 32.3B).<sup>18</sup> On A-scan ultrasonography choroidal melanoma shows characteristic low to medium internal reflectivity, with a high initial spike 'positive-angle  $\kappa$  sign' (Fig. 32.3C).<sup>19</sup> Ultrasonography has also been shown to be superior to computerized tomography (CT) or magnetic resonance imaging (MRI) for detecting extrascleral extension (Fig. 32.3D).<sup>18</sup>

Ultrasonography can be a useful tool to differentiate melanomas from a variety of simulating lesions. However, there are no pathognomonic features that differentiate a choroidal nevus from a small choroidal melanoma.<sup>17</sup> An extramacular disciform lesion usually shows higher internal reflectivity than a melanoma.<sup>20</sup> Other lesions



**Fig. 32.3** Ultrasonographic features of a choroidal melanoma. Acoustic quiet zone within the tumor on B-scan ultrasonography (A). (B) The mushroom-like configuration is almost pathognomonic. (C) Low internal reflectivity on A-scan. (D) Extrascleral extension (arrow). (Reproduced with permission from Bakri SJ, Sculley L, Singh AD. Imaging techniques for uveal melanoma. *Int Ophthalmol Clin* 2006; 46: 1–13.)

mimicking the ultrasonographic characteristics of a melanoma include retinal hamartoma, tuberculoma, neurilemmoma, and a combined choroidal–retinal detachment.

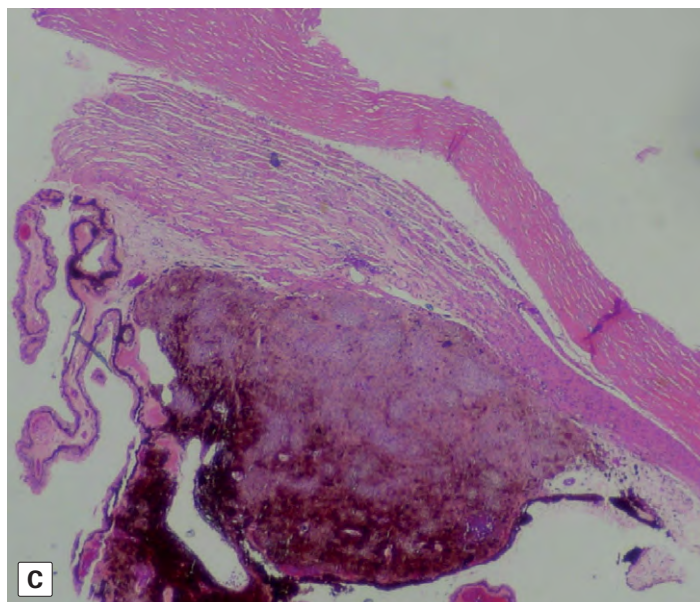
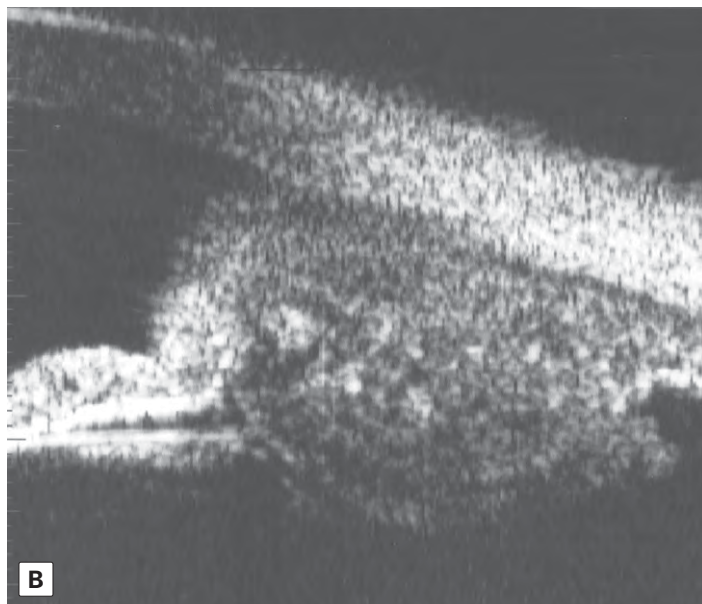
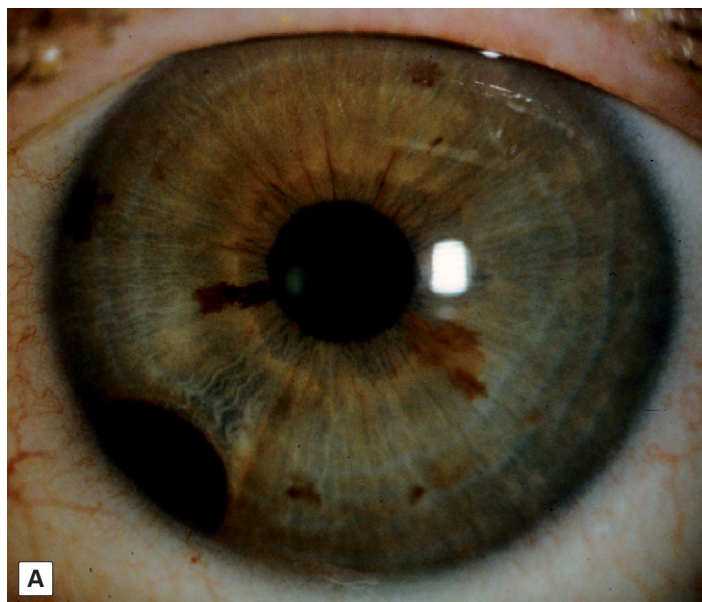Choroidal metastases produce a characteristic echographic pattern, distinct from a choroidal melanoma, with no acoustic shadowing, choroidal excavation, or orbital shadowing. On A-scan, there is medium-high reflectivity with a ‘negative angle  $\kappa$ ’ sign (the back portion of the tumor climbs toward the sclera). Choroidal hemangiomas produce a similar B-scan appearance to metastases, but the A-scan has high reflectivity.<sup>18</sup> A choroidal osteoma shows calcification on B-scan, with shadowing in the orbit and high surface reflectivity.<sup>21</sup>

**Three-dimensional ultrasonography** is used to obtain measurements such as the diameter and height of the tumor, and to estimate its volume.<sup>22</sup> This technique is mainly used for research studies and has not been widely adopted into clinical practice.

**Color Doppler imaging (CDI)** is an ultrasound technique that displays color-encoded Doppler flow information throughout a two-

dimensional gray-scale image. It therefore provides a selective analysis of Doppler spectra in small blood vessels, thereby detecting intrinsic circulation. In one study, CDI was performed on 44 intraocular mass lesions.<sup>23</sup> Abnormal Doppler shifts were demonstrated within 39 neoplastic lesions, but Doppler shifts could not be detected in three simulating lesions. By demonstrating intrinsic tumor blood flow, CDI can help establish the diagnosis of a choroidal melanoma.

**Ultrasound biomicroscopy (UBM)** is useful in the diagnosis and assessment of iris and ciliary body lesions.<sup>24</sup> Unlike standard ultrasonography of anterior segment tumors, high-frequency ultrasound biomicroscopy allows quantitative measurements of tumor size, extension within and posterior to the iris, as well as differentiation of solid and cystic lesions. UBM is superior to conventional B-scan ultrasound for the precise localization of anteriorly located uveal melanoma, allowing for serial monitoring.<sup>25</sup> It appears that ultrasound biomicroscopic images demonstrate a high correlation with histopathologic features of anterior uveal melanomas, including shape, reflectivity, and local extension (Fig. 32.4).<sup>26</sup>



**Fig. 32.4** Ultrasound biomicroscopy of an iridociliary mass. (A) Slit lamp photograph. (B) Ultrasound biomicroscopy revealed a ciliary body mass with anterior extension into the iris root. (C) Note the close correlation between histopathological appearance (after iridocyclectomy) and biomicroscopic findings.



## OPTICAL COHERENCE TOMOGRAPHY

**Anterior segment optical coherence tomography (AS-OCT)** (Carl Zeiss Meditech Inc., Dublin, CA) is a non-contact prototype which can be used in slit lamp or transcleral modes to obtain real-time images of the cornea, sclera, anterior chamber angle, iris, and lens.<sup>27</sup> AS-OCT is an alternative modality to ultrasound biomicroscopy for the assessment of iris and ciliary body lesions.<sup>27</sup>

## Posterior segment optical coherence tomography (OCT)

is useful for detecting subtle changes in the vitreoretinal interface, retina, and retinal pigment epithelium, rather than the structures in the choroid. Melanocytomas tend to have a superficial retinal component which may be detected by OCT, thereby differentiating melanocytoma from melanoma.<sup>28</sup> On OCT melanocytoma shows a high reflectance signal anteriorly, which is continuous with the retinal nerve fiber layer, and optical shadowing posteriorly, corresponding to the known growth patterns of melanocytoma. OCT is also useful in documenting secondary retinal changes, such as small subclinical retinal detachments associated with the presence of choroidal melanomas and choroidal nevi.<sup>29</sup> It is, however, of little value in the differential diagnosis of choroidal tumors.<sup>30</sup>

## COMPUTERIZED TOMOGRAPHY

On CT a uveal melanoma appears as a hyperdense lesion with slight to moderate contrast enhancement. Tumors thinner than 2 mm are not detectable by CT.<sup>31</sup> Moreover, CT is less accurate than ultrasonography in differentiating between uveal masses, which limits its role in the management of patients with uveal melanoma. Even for extrascleral extension of uveal melanoma, ultrasonography is superior to CT.<sup>17</sup> Other disadvantages of CT are its expense and the exposure to ionizing radiation.

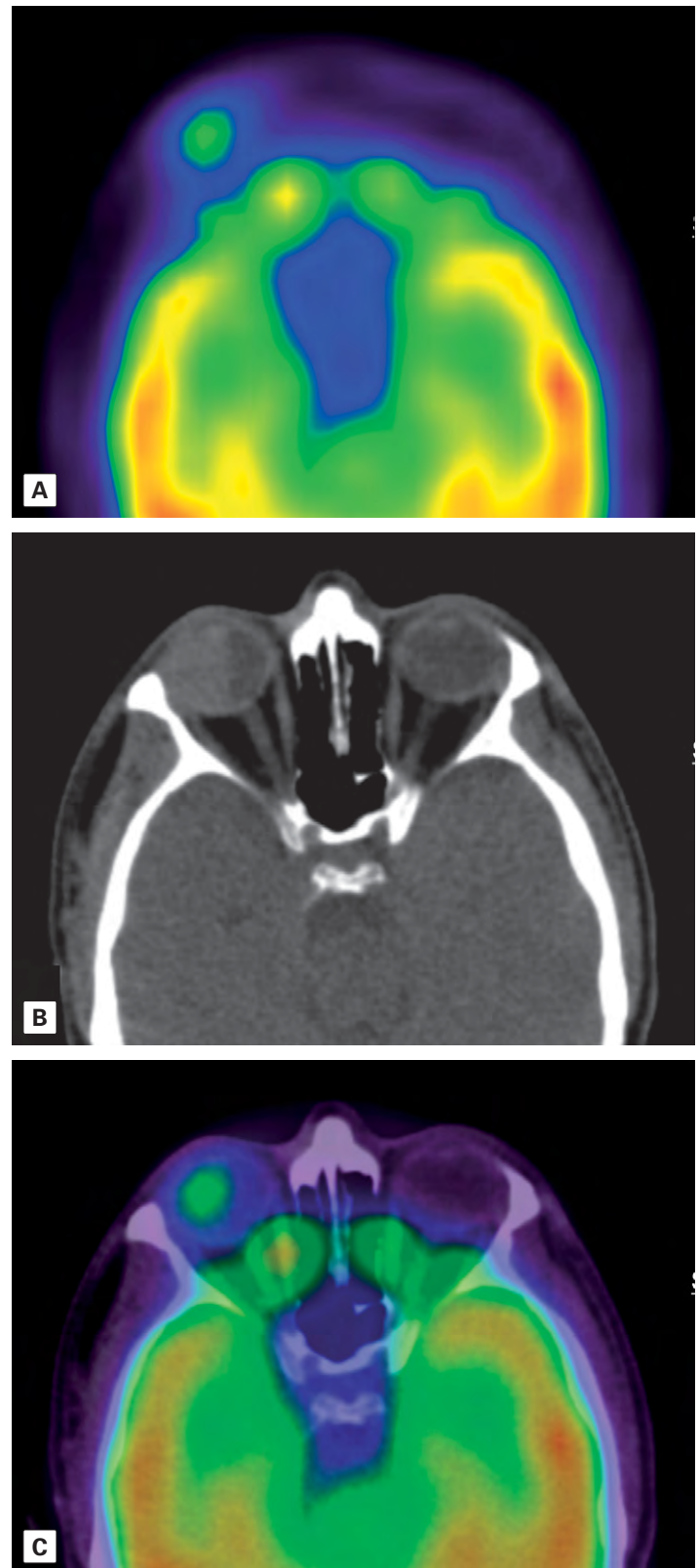
## MAGNETIC RESONANCE IMAGING AND SPECTROSCOPY

MRI can also be used for the diagnosis of uveal melanoma.<sup>32</sup> A choroidal melanoma appears hyperintense on T<sub>1</sub> imaging and hypointense on a T<sub>2</sub>-weighted scan.<sup>32</sup> However, these are also characteristic of a melanocytoma, owing to the presence of the melanin free radical.<sup>33,34</sup> Although the use of the surface coils has greatly facilitated the evaluation of intraocular tumors, MRI is not specific for uveal melanoma. It is also expensive and is not superior to ultrasound, and therefore it is not used routinely for diagnostic evaluation.

Magnetic resonance spectroscopy using phosphorus-31 has been studied for imaging choroidal melanomas.<sup>34,35</sup> Phosphorus-31 magnetic resonance spectroscopy allows the differentiation of choroidal melanomas from normal ocular structures. Differentiating features include significant peaks in tumor spectra due to unusually high concentrations of phosphodiester, which may be considered a marker for uveal melanomas and other choroidal tumors.<sup>36</sup> However, there are limitations in interpretation of the tumor spectra because of contaminating signals from surrounding tissues.

## POSITRON EMISSION TOMOGRAPHY

Positron emission tomography (PET) relies on altered metabolism within a malignant cell to detect tissue abnormalities. Malignant cells have a higher rate of glucose uptake and therefore show preferential uptake of radiolabeled fluorine-18 fluorodeoxyglucose (FDG). We performed a pilot study to evaluate the ability of FDG PET/CT scan to visualize primary uveal melanoma and to evaluate the tumor characteristics that correlated with the tumor identification (Fig. 32.5).<sup>37</sup>



**Fig. 32.5** Positron emission tomograph of the right eye with uptake of 18-fluorodeoxyglucose (A). The tumor is also visible on CT scan (B). Fusion of images localizes the uptake within the intraocular tumor (C). (Reproduced with permission from Singh AD, Bhatnagar P, Bybel B. Visualization of primary uveal melanoma with PET/CT scan. *Eye* 2006; 20: 938–940.



Primary uveal melanoma could be detected with FDG-PET/CT scanning in six of 10 patients (60%). FDG-PET/CT is a functional scan that detects tumor viability: it may have potential in evaluating tumor response to conservative therapies.

## CONCLUSIONS

There are a variety of established, as well as evolving, techniques that assist in the diagnosis of uveal melanoma. Using a combination of techniques based on clinical differential diagnosis often gives the

highest diagnostic yield. Usually photography to document margins and surface features is used in conjunction with ultrasonography to assess for size and extrascleral extension.

## ACKNOWLEDGEMENT

This chapter was modified with permission from SJ Bakri I Sculley, AD Singh. Imaging techniques for uveal melanoma. *Int Ophthalmol Clin* 2005;46.

## REFERENCES

- Singh AD, Topham A. Incidence of uveal melanoma in the United States: 1973–1997. *Ophthalmology* 2003; 110: 956–961.
- Group COMS. Accuracy of diagnosis of choroidal melanomas in the Collaborative Ocular Melanoma Study. COMS report no. 1. *Arch Ophthalmol* 1990; 108: 1268–1273.
- Shields CL, Materin M, Shields JA. Panoramic imaging of the ocular fundus. *Arch Ophthalmol* 2003; 121: 1603–1607.
- Char DH, Stone RD, Irvine AR et al. Diagnostic modalities in choroidal melanoma. *Am J Ophthalmol* 1980; 89: 223–230.
- Flower RW. Infrared absorption angiography of the choroid and some observations on the effects of high intraocular pressures. *Am J Ophthalmol* 1972; 74: 600–614.
- Hochheimer BF. Angiography of the retina with indocyanine green. *Arch Ophthalmol* 1971; 86: 564–565.
- Sallet G, Amoaku WM, Lafaut BA et al. Indocyanine green angiography of choroidal tumors. *Graefes Arch Clin Exp Ophthalmol* 1995; 233: 677–689.
- Geeraets WJ, Berry ER. Ocular spectral characteristics as related to hazards from lasers and other light sources. *Am J Ophthalmol* 1968; 66: 15–20.
- Baker KJ, Bradley SE. Binding of sulfobromophthalein (BSP) sodium by plasma albumin. Its role in hepatic BSP extraction. *J Clin Invest* 1966; 45: 281–287.
- Chang AA, Morse LS, Handa JT et al. Histologic localization of indocyanine green dye in aging primate and human ocular tissues with clinical angiographic correlation. *Ophthalmology* 1998; 105: 1060–1068.
- Shiraki K, Moriwaki M, Yanagihara N et al. Indocyanine green angiograms of choroidal nevi. Comparison between confocal and nonconfocal scanning laser ophthalmoscope and fundus video camera. *Jpn J Ophthalmol* 2001; 45: 368–374.
- Flower RW, Csaky KG, Murphy RP. Disparity between fundus camera and scanning laser ophthalmoscope indocyanine green imaging of retinal pigment epithelium detachments. *Retina* 1998; 18: 260–268.
- Mueller AJ, Freeman WR, Folberg R et al. The Munich/San Diego/Iowa City Collaboration (MuSIC). MuSIC Report I: Design, characteristics of the collective and preliminary results. *Ophthalmology* 2002; 99: 193–199.
- Singh AD, Mokashi AA, Bena JF et al. Small choroidal melanocytic lesions: indocyanine angiographic features predictive of growth. *Ophthalmology* 2006; 113: 1061.
- Shields CL, Shields JA, De Potter P. Patterns of indocyanine green videoangiography of choroidal tumours. *Br J Ophthalmol* 1995; 79: 237–245.
- Arevalo JF, Shields CL, Shields JA et al. Circumscribed choroidal hemangioma: characteristic features with indocyanine green videoangiography. *Ophthalmology* 2002; 107: 344–350.
- Scott IU, Murray TG, Hughes JR. Evaluation of imaging techniques for detection of extraocular extension of choroidal melanoma. *Arch Ophthalmol* 1998; 116: 897–899.
- Verbeek AM, Thijssen JM, Cuypers MH et al. Echographic classification of intraocular tumours. A 15-year retrospective analysis. *Acta Ophthalmol (Copenh)* 1994; 72: 416–422.
- Coleman DJ. Ocular tumor patterns. *Bibl Ophthalmol* 1975: 136–140.
- Ossoinig KC, Bigar F, Kaefering SL. Malignant melanoma of the choroid and ciliary body. A differential diagnosis in clinical echography. *Bibl Ophthalmol* 1975: 141–154.
- Valencia M, Green RL, Lopez PF. Echographic findings in hemorrhagic disciform lesions. *Ophthalmology* 1994; 101: 1379–1383.
- Romero JM, Finger PT, Rosen RB, Iezzi R. Three-dimensional ultrasound for the measurement of choroidal melanomas. *Arch Ophthalmol* 2001; 119: 1275–1282.
- Lieb WE, Shields JA, Cohen SM et al. Color Doppler imaging in the management of intraocular tumors. *Ophthalmology* 1990; 97: 1660–1664.
- Katz NR, Finger PT, McCormick SA et al. Ultrasound biomicroscopy in the management of malignant melanoma of the iris. *Arch Ophthalmol* 1995; 113: 1462–1463.
- Conway RM, Chew T, Golchet P et al. Ultrasound biomicroscopy: role in diagnosis and management in 130 consecutive patients evaluated for anterior segment tumours. *Br J Ophthalmol* 2005; 89: 950–955.
- Marigo FA, Finger PT, McCormick SA et al. Iris and ciliary body melanomas: ultrasound biomicroscopy with histopathologic correlation. *Arch Ophthalmol* 2000; 118: 1515–1521.
- Radhakrishnan S, Rollins AM, Roth JE et al. Real-time optical coherence tomography of the anterior segment at 1310nm. *Arch Ophthalmol* 2001; 119: 1179–1185.
- Muscat S, Srinivasan S, Sampat V et al. Optical coherence tomography in the diagnosis of subclinical serous detachment of the macula secondary to a choroidal nevus. *Ophthalm Surg Lasers* 2001; 32: 474–476.
- Muscat S, Parks S, Kemp E, Keating D. Secondary retinal changes associated with choroidal naevi and melanomas documented by optical coherence tomography. *Br J Ophthalmol* 2004; 88: 120–124.
- Schaudig U, Hassenstein A, Bernd A et al. Limitations of imaging choroidal tumors in vivo by optical coherence tomography. *Graefes Arch Clin Exp Ophthalmol* 1998; 236: 588–592.
- Mafee MF, Peyman GA, McKusick MA. Malignant uveal melanoma and similar lesions studied by computed tomography. *Radiology* 1985; 156: 403–408.
- Bond JB, Haik BG, Mihara F, Gupta KL. Magnetic resonance imaging of choroidal melanoma with and without gadolinium contrast enhancement. *Ophthalmology* 1991; 98: 459–466.
- Mafee MF, Peyman GA, Peace JH et al. Magnetic resonance imaging in the evaluation and differentiation of uveal melanoma. *Ophthalmology* 1987; 94: 341–348.
- Mihara F, Gupta KL, Murayama S et al. MR imaging of malignant uveal melanoma: role of pulse sequence and contrast agent. *AJNR Am J Neuroradiol* 1991; 12: 991–996.
- Kolodny NH, Gragoudas ES, D'Amico DJ et al. Preliminary results on phosphorus-31 nuclear magnetic resonance evaluation of human uveal melanoma in enucleated eyes. *Ophthalmology* 1988; 95: 666–673.
- De Potter P, von Weymarn C, Zografos L. In vivo phosphorus 31 magnetic resonance spectroscopy of human uveal melanomas and other intraocular tumors. *Am J Ophthalmol* 1991; 111: 276–288.
- Singh AD, Bhatnagar P, Bybel B. Visualization of primary uveal melanoma with PET/CT scan. *Eye* 2006; 20: 938–940.

# Classification of uveal tumors

Bertil Damato, Sarah Coupland and Paul Hiscott

## INTRODUCTION

Tumors of the same class should share a unique combination of features that distinguishes them from all other classes.<sup>1,2</sup> Classification, therefore, is the process of defining different tumor classes and correlating these with each other in a hierarchical manner.

Tumor classification has several benefits. It can facilitate diagnosis by helping the clinician to include all relevant conditions in a differential diagnosis. It can improve prognostication, by predicting how the tumor is likely to behave. This in turn can enhance treatment planning as well as enabling the results of treatment to be evaluated properly. Tumor classification also improves communication by allowing the standardization of disease categories in multicenter studies. Classification is also valuable in research, contributing to investigations in tumor biology (Box 33.1).

## CLASSIFICATION OF UVEAL TUMORS

Uveal tumors can be classified according to their location, etiopathology, histopathology, histogenesis, genotype, and various other ontological methods. Each approach has its advantages and limitations. A classification based on tumor location within the uvea would need to mention some tumors more than once if these can arise at different sites and, furthermore, it can be impossible to locate the origin of an extensive tumor. A classification that is superior in one situation may not be useful in other circumstances. For example, a histopathological classification is helpful in a pathology laboratory but of limited value in an ophthalmic clinic when the patient is first seen, that is, before tissue has been examined histologically.

### BOX 33.1 Classification of Uveal Tumors

- Classification of tumors contributes to diagnosis, prognostication, treatment planning, evaluation of treatment results, communication between treatment centers, and oncological research
- Tumors can be classified according to location, etiopathology, histopathology, histogenesis, and other methods
- Each classification has its advantages and disadvantages in any particular situation, so that different classification methods complement each other
- Classification must be distinguished from grading and staging

This chapter considers some conditions that are not uveal, because these might be mistaken for a uveal tumor. For example, adenomas, adenocarcinomas, congenital hypertrophy of the retinal pigment epithelium, and iris cysts are all epithelial but need to be included in the differential diagnosis of several uveal tumors. For the same reasons, conditions such as varix of vortex vein ampulla are mentioned, even if they are not tumors at all.

Strictly speaking, these lists are not classifications because they include tumors that are not biologically, clinically, and histologically related. In any case, it is hoped that this review will make it easier for clinicians to recall all relevant conditions when the need arises, a mental feat that is facilitated by categorizing the different tumors and pseudotumors into meaningful groups.

**Etiopathogenic classification** This system categorizes uveal tumors as congenital, traumatic, inflammatory, neoplastic, degenerative, and idiopathic (Table 33.1). This classification is far from perfect. First, the anatomical listing is only approximate, because tumors can arise in atypical locations. Second, the pathogenesis of some tumors is not known. For example, there is debate as to whether choroidal osteomas are choristomas or whether they develop in response to inflammation. Third, the distinction between hamartomas and benign neoplasms is blurred. For example, melanocytic nevi are regarded both as hamartomas and neoplasms. Fourth, the list is not exhaustive, as there is a wide variety of very rare tumors. It is important to appreciate that the terminology may influence clinical management inappropriately. For example, the term ‘suspicious nevus’ may encourage passive clinical management, whereas if the same lesion is called ‘suspicious melanoma’ it is perhaps more likely to be treated. It may therefore be preferable to refer to an equivocal melanocytic tumor as an ‘indeterminate melanocytic tumor’ or ‘melanocytic tumor of indeterminate malignancy.’ Whether such a tumor is nevus, melanoma, or indeterminate is, of course, subjective if the diagnosis is based on ophthalmoscopy. Finally, some tumors, such as neurilemmoma, neurofibroma, and leiomyoma, are classified separately despite being clinically indistinguishable.

**Histopathological classification** categorizes uveal neoplasms according to their cellular morphology. The World Health Organization (WHO) has classified uveal tumors according to anatomical site, histological type, and degree of malignancy.<sup>3</sup> This classification was developed by pathologists specifically for classifying histopathological material. It therefore excludes tumors caused by granulomas and

**Table 33.1 Uveal tumors classified according to pathogenesis and location**

Category	Subtype	Location				
		<i>Iris</i>	<i>Ciliary body</i>	<i>Choroid</i>		
<b>Inflammatory</b>	Infectious	Granuloma	+	+	+	
	Non-infectious	Sarcoidosis	+	+	+	
		Juvenile xanthogranuloma	+	+		
		Scleritis		+	+	
		Uveal effusion		+	+	
<b>Neoplastic/hamartomatous</b>	Benign	Melanocytes	Melanocytic nevus	+	+	+
			Melanocytosis	+	+	+
			Melanocytoma	+	+	+
			Lisch nodules	+		
			BDUMP*		+	+
		Epithelium	Cyst	+	+	
			RPE detachment			+
			Reactive epithelial hyperplasia		+	+
			Adenomatous hyperplasia		+	+
			Adenoma	+	+	+
			Congenital hypertrophy of RPE			+
			Medulloepithelioma		+	+
			Glioneuroma	+	+	
			Combined hamartoma of retina and RPE			+
			Blood vessels	Circumscribed hemangioma		
	Diffuse hemangioma			+	+	
	Hemangiopericytoma	+			+	
	Racemose angioma	+				
	Neurofibroma	+		+	+	
	Fibroblasts	Neurilemmoma		+	+	
	Neural tissue	Leiomyoma	+	+	+	
	Muscle	Mesectodermal leiomyoma	+	+		
	Lymphocytes	Lymphoid tumor	+	+	+	
	Foreign	Lacrimal gland choristoma	+	+		
	<b>Malignant</b>	Melanocytes	Melanoma	+	+	+
			Epithelium	Adenocarcinoma	+	+
			Medulloepithelioma	+	+	+
		Muscle	Rhabdo-/leiomyosarcoma	+	+	
		Secondary	Melanoma/carcinoma	+	+	+
		Hemopoietic	Lymphoma	+	+	+
			Leukemia	+	+	+
			Metastatic	Carcinoma/sarcoma	+	+
<b>Traumatic</b>			Foreign body	+	+	+
			Implantation cyst	+		
		Miotic cyst	+			
		Suprachoroidal hematoma			+	
<b>Degenerative</b>		Disciform lesion			+	
		Sclerochoroidal calcification			+	
<b>Idiopathic</b>		Osteoma			+	
		Vasoproliferative tumour			+	
		Varicose vortex vein			+	

\* Bilateral Diffuse Uveal Melanocytic Proliferation.



hematomas, which the clinician must consider when preparing a differential diagnosis.

The WHO classification has several additional limitations. For example, although ocular melanocytosis and oculodermal melanocytosis are listed separately, these are indistinguishable histologically. Furthermore, spindle, mixed, and epithelioid melanomas are listed separately, but these are really different grades of the same neoplasm. Another limitation of the WHO classification is that it does not distinguish between secondary tumors invading the uvea from adjacent tissues and metastatic tumors that have originated in distant parts of the body. For these reasons, we prefer an alternative pathological classification of uveal tumors (Table 33.2).

**Histogenetic classification** groups tumors hierarchically according to their embryonic lineage, subclassifying them according to whether they originate from ectodermal, endodermal, or mesodermal cells.<sup>2</sup> Tumors are further subclassified according to whether they arise

from primitive cells (e.g. totipotent cells forming teratomas) or differentiated cells (e.g. melanocytes). Proponents of this biological system of classification argue that it is simple, comprehensive, and capable of developing as molecular biology improves our knowledge about different tumor types. Another advantage of this classification is that tumors with the same lineage tend to share behavioral similarities. Histogenetic classification is not widely used for uveal tumors as the majority are neuroectodermal or mesodermal in origin.

**Genotypic ‘classification’** Tumors of the same class that seem identical on histology can behave very differently from each other. With developments in molecular biology, it has become possible to correlate tumor behavior with gene expression and other novel characteristics. These advances have raised hopes of improving tumor classifications.

**Table 33.2 Pathological classification of uveal tumors**

Category	Subtype		
	Benign	Malignant	
		Primary	Secondary
<b>Uvea</b>			
Melanocytes	Melanocytosis Melanocytoma Melanocytic nevus Diffuse melanocytic hyperplasia	Melanoma	Conjunctival melanoma
Blood vessels	Hemangioma Hemangiopericytoma		
Nerves	Schwannoma Glioneuroma		
Smooth muscle	Leiomyoma Mesectodermal leiomyoma	Leiomyosarcoma	
Striated muscle		Rhabdomyosarcoma	
Fibroblasts	Neurofibroma		
Histiocytes	Juvenile xanthogranuloma		
Lymphocytes	Lymphocytic proliferation	Lymphoma	Lymphoma
Leukocytes			Leukemia
<b>Epithelium</b>			
Non-pigmented	Adenoma Adenomatous hyperplasia Reactive epithelial hyperplasia Cyst Stromal cyst	Adenocarcinoma	Conjunctival carcinoma
Pigmented	Congenital hypertrophy of the RPE Cyst Combined hamartoma of the RPE & retina Adenoma Cyst Medulloepithelioma	Adenocarcinoma Medulloepithelioma	
Ectopic tissue	Lacrimal gland choristoma Osteoma		Metastatic carcinoma Metastatic sarcoma

Cytogenetic studies and microarray technology reveal marked differences between high-grade and low-grade uveal melanomas.<sup>4</sup> For example, monosomy 3 is associated with a reduction in the 5-year survival probability from over 90% to less than 50%.<sup>5,6</sup> Purists would argue that such categorizations actually constitute 'discriminant analysis' rather than classification.<sup>1</sup> This is because uveal melanomas can apparently transform from disomy 3 to monosomy 3 type, as evidenced by the existence of tumors with both monosomy 3 and disomy 3 melanoma cells. A key concept of classification is that members of one class of tumor cannot transform into another class.

**TNM 'classification' (Tumor, Node, Metastasis)** classification categorizes tumors according to the extent of the primary tumor and the presence or absence of lymph node involvement and metastasis.<sup>7</sup> For example, choroidal melanomas are grouped according to basal tumor diameter, tumor height, and extraocular extension.<sup>8</sup> It must be emphasized that this is actually a staging system, because the different groups represent various levels of advancement of the same

tumor rather than different classes. In other words, what is being classified is the stage of disease and not the disease itself. This is not merely a play on words, because when survival statistics are based on the TNM system it must be remembered that the different groups are time dependent, so that it is essential to take lead-time bias into account.

## CONCLUSIONS

Tumor classification is constantly evolving as advancing knowledge changes our perception of what makes a class of tumors unique and how that class relates to other groups in the hierarchy. Different classifications can complement each other, as seen with histological and clinical groupings. Nevertheless, measures should be taken to ensure that alternative classifications match each other as closely as possible, so that ambiguity and misunderstanding are avoided. There is no escaping the fact that terminology and semantics are important. It is essential to distinguish between factors such as class, grade, and stage of tumor, if the benefits of tumor groupings are to be maximized.

## REFERENCES

1. Berman JJ. Tumor classification: molecular analysis meets Aristotle. *BMC Cancer* 2004; 4: 10.
2. Berman J. Modern classification of neoplasms: reconciling differences between morphologic and molecular approaches. *BMC Cancer* 2005; 5: 100.
3. Campbell RJ. *Histological typing of tumours of the eye and its adnexa*. Berlin: Springer Verlag, 1998; 15–20.
4. Singh AD, Damato B, Howard P et al. Uveal melanoma: genetic aspects. *Ophthalmol Clin North Am* 2005; 18: 85–97.
5. Prescher G, Bornfeld N, Hirche H et al. Prognostic implications of monosomy 3 in uveal melanoma. *Lancet* 1996; 347: 1222–1225.
6. Scholes AG, Damato BE, Nunn J et al. Monosomy 3 in uveal melanoma: correlation with clinical and histologic predictors of survival. *Invest Ophthalmol Vis Sci* 2003; 44: 1008–1011.
7. Gospodarowicz MK, Miller D, Groome PA et al. The process for continuous improvement of the TNM classification. *Cancer*. 2004; 100: 1–5.
8. Kujala E, Kivelä T. Tumor, node, metastasis classification of malignant ciliary body and choroidal melanoma evaluation of the 6th edition and future directions. *Ophthalmology* 2005; 112: 1135–1144.

# Tumors of the uvea: benign melanocytic tumors

Arun D. Singh

## INTRODUCTION

Benign melanocytic uveal tumors are generally known as nevi (also spelt 'naevi'). Nevus is a Latin word that means birthmark or mole and is a general term for a congenital mark on the skin. In ophthalmology the term nevus refers to an abnormal, hamartomatous cluster of melanocytes. Uveal melanocytes are of neural crest origin and share embryologic origin with cutaneous melanocytes.<sup>1</sup> This chapter describes iris, ciliary body, and choroidal nevi, as well as oculo(dermal) melanocytosis and melanocytoma, which are considered variants of nevus.

## IRIS NEVUS

Iris nevus is a stromal lesion and therefore quite different from an iris freckle, in which melanocytes collect only superficially, without stromal involvement. Iris freckles can be seen in up to 60% of the population, whereas nevi are less common (4–6%).<sup>2</sup> Both iris freckles and nevi are more frequent in light-colored irides.<sup>2</sup> Patients with dysplastic nevus syndrome may have a tendency to develop iris nevi.<sup>3,4</sup> Although an association between iris nevi and uveal melanomas has been reported,<sup>5</sup> it is doubtful whether the two conditions are genuinely associated.<sup>2</sup>

**Etiology and pathology** Most circumscribed iris nevi are composed of intrastromal, bland spindle cells.<sup>6</sup> In some cases the lesion breaks through to the iris surface, to form a plaque or nodule. The diffuse iris nevus represents hyperplasia and hypertrophy of stromal melanocytes without mass effect. Other variants include epithelioid cell nevus, which is composed of bland, hypopigmented, epithelioid cells with a clear vacuolated cytoplasm,<sup>7,8</sup> and balloon cell nevus, composed of cells with a clear cytoplasm.<sup>9</sup>

**Clinical features** Iris nevus is typically solitary and circumscribed (Fig. 34.1). Most are located in the lower quadrants of the iris and vary in color from tan to dark brown. A nevus that is very dark and almost black is more likely to be a melanocytoma. Intrinsic vasculature may be visible if the tumor is only lightly pigmented.

Pupillary changes such as corectopia, irregularity of the margin, and ectropion iridis may occur with nevi involving the pupillary margin and do not imply malignancy. Similarly, extension into the trabecular meshwork does not signify malignant change. There may be a progressive accumulation of pigment in the trabecular meshwork, especially with melanocytoma (see below). Such pigment in the angle may be localized to the vicinity of the tumor or may be diffuse, giving

rise to secondary glaucoma. Pigment shedding appears smooth on gonioscopy, unlike tumor seeding from a melanoma, which tends to form irregular nodular elevations in the trabecular meshwork.

**Clinical variants** In addition to commonly observed circumscribed iris nevi described above, several clinical variants are well recognized.

*Tapioca iris nevus* is a multinodular, amelanotic, or lightly pigmented iris nevus that resembles tapioca grains.

*Diffuse iris nevus* may be sectoral or may involve the whole iris (Fig. 34.2). This variety is usually observed in association with ocular melanocytosis.<sup>10</sup>

*Iris nevus syndrome* A rare variant of iridocorneal endothelial syndrome, the iris nevus syndrome (Cogan–Reese syndrome), is the result of corneal endothelial overgrowth across the angle and over the iris surface, which gives rise to multiple small iris nodules and secondary glaucoma.<sup>11,12</sup>

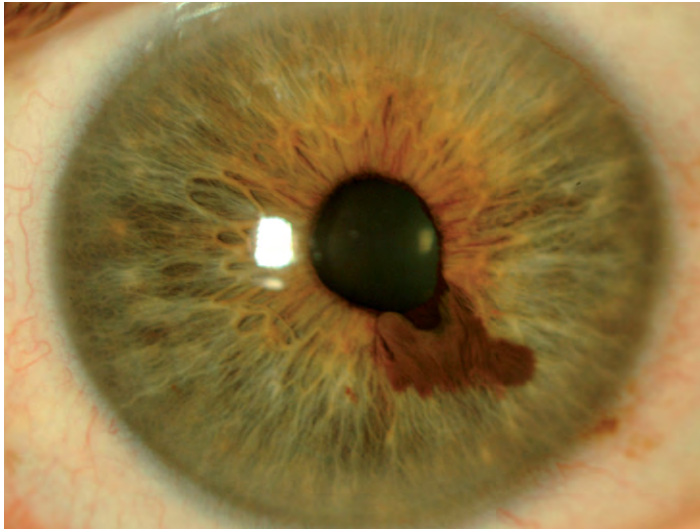
*Iris mammillations* are multiple, dark brown nodular elevations on the iris seen commonly in darkly pigmented races or in association with oculo(dermal) melanocytosis.<sup>13,14</sup>

*Lisch nodules* occur in patients with neurofibromatosis type 1. They consist of small collections of melanocytes and are histologically indistinguishable from common nevi, except that they are perhaps more superficial.<sup>15</sup>

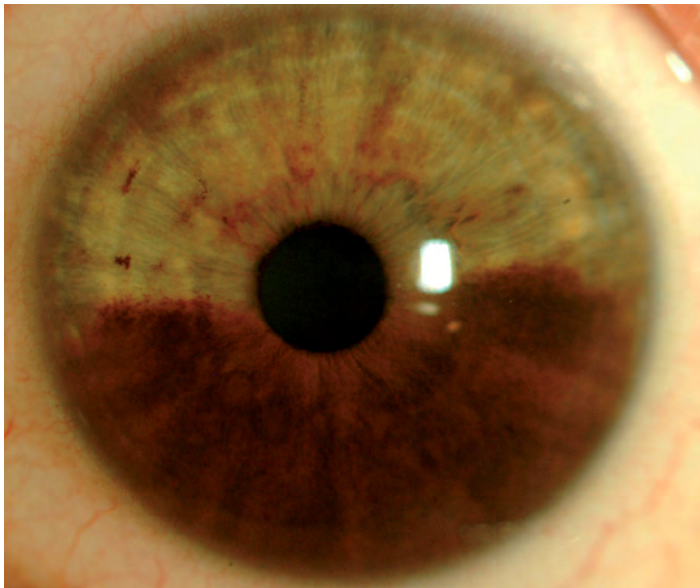
*Aggressive nevi of childhood* As with similar lesions in other parts of the body, iris nevi in children can enlarge rapidly. Such lesions have been observed both sporadically<sup>16</sup> and in a familial setting.<sup>17</sup>

**Diagnostic evaluation** Detailed anterior segment evaluation, including gonioscopy, is essential, with photographic documentation if possible. High-frequency ultrasound biomicroscopy provides quantitative measurements of tumor size, detects any posterior extension, and differentiates solid from cystic lesions.<sup>18</sup> Recent experience with anterior segment optical coherence tomography, using a non-contact prototype (Carl Zeiss Meditech Inc., Dublin, CA), suggests that this can provide useful real-time images of the entire anterior segment, including the angle (Fig. 34.3).<sup>19</sup>





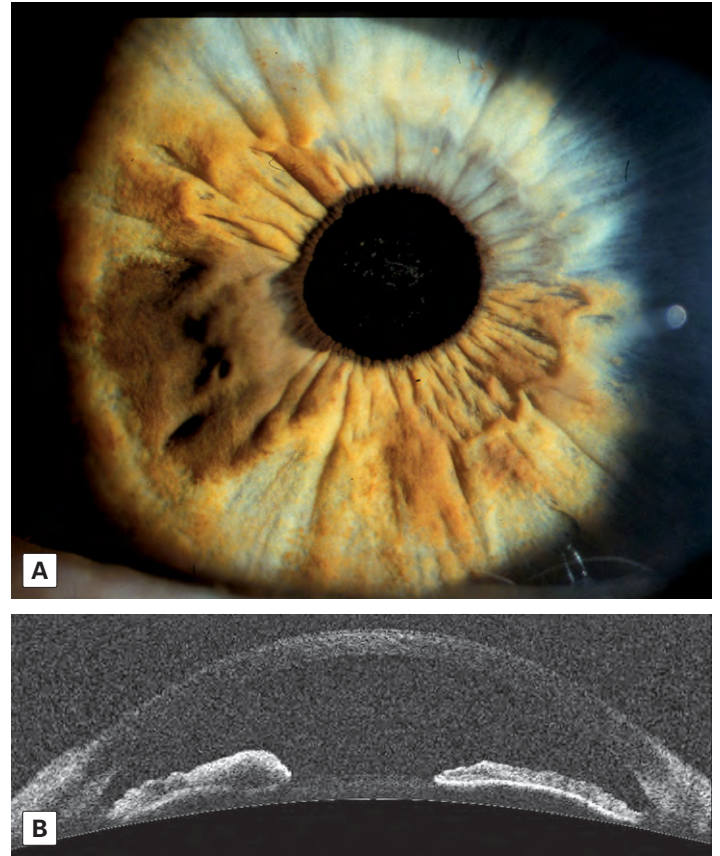
**Fig. 34.1** Slit lamp photograph of a circumscripted iris nevus demonstrating localized iris thickening, pupillary distortion, and ectropion irides.



**Fig. 34.2** Slit lamp photograph of a diffuse iris nevus involving the lower half of the iris in association with oculo(dermal) melanocytosis.

**Differential diagnosis** Differentiation of iris nevus from melanoma is important but often difficult, because there are no criteria that clearly distinguish the two lesions (Box 34.1).<sup>6</sup> In general, patients with iris melanoma tend to be symptomatic more often than those with iris nevi.<sup>20</sup> Prominent tumor vascularity and a larger tumor size (i.e. basal diameter more than 3 mm) also tend to support the diagnosis of melanoma rather than a nevus.<sup>20,21</sup> Pigment dispersion, elevated IOP, and hyphema are more often associated with melanoma.<sup>6,20,21</sup> Evidence of tumor seeding and spread into the ciliary body or extraocularly are also suggestive of malignancy.

**Treatment** Most iris melanocytic lesions are benign.<sup>20,22</sup> Furthermore, iris melanomas tend to be relatively indolent, with only a 3% risk of metastasis at 5 years.<sup>21</sup> For these reasons, observation as initial management is widely recommended. In the presence of features suspicious for melanoma (Box 34.1) or documented rapid growth,



**Fig. 34.3** Slit lamp photograph (A) and wide-field image with anterior segment optical coherence tomography (B) of an iris nevus. (Reproduced with permission from Bakri SJ, Singh AD, Lowder CY et al. Imaging of iris lesions with high speed optical coherence tomography. *Ophthalmic Surg Lasers Imaging* 2007; 38: 1–4.

#### BOX 34.1 Clinical Features Suspicious of Iris Melanoma

- Symptoms
- Tumor size (i.e. basal diameter >3mm)
- Prominent tumor vascularity
- Pigment dispersion
- Secondary glaucoma
- Local spread (i.e. seeding, ciliary body or extraocular extension)
- Documented rapid growth

prompt excision may be considered. Even within the subgroup of lesions that are suspicious enough to be excised, less than 15% prove to be malignant.<sup>6</sup>

**Prognosis** Overall, iris nevi have a good prognosis. In a series of 175 patients observed for a mean duration of 4.7 years, less than 5% of iris nevi showed clinical evidence of enlargement.<sup>22</sup> The only predictor of growth in this study was pigment dispersion on to the adjacent iris and anterior chamber angle. Pupillary distortion, ectropion iridis, and sector cataract were not of prognostic significance.<sup>22</sup> In another study, an initial largest basal tumor diameter exceeding

3.0 mm was the only significant prognostic factor for tumor enlargement.<sup>20</sup>

## CHOROIDAL NEVUS

Although a strict clinical definition of typical choroidal nevus is lacking,<sup>23</sup> the Collaborative Ocular Melanoma Study Group defined it as a choroidal melanocytic lesion that is 5 mm or smaller in largest basal dimension and not more than 1 mm in height.<sup>24,25</sup> The reported prevalence rates vary from 0.2% to 30% because of differences in study design (e.g. autopsy, clinic, population), patient selection (i.e. ophthalmic patients, chemical workers, random population samples), and methods of examination (i.e. histopathology, fundus photography, indirect ophthalmoscopy (Table 34.1)).<sup>26</sup>

**Terminology** In contrast to a choroidal nevus, a choroidal freckle is composed of an increased density of normal melanocytes, which do not disturb the normal architecture so that it is always flat, often with visible, normal choroidal vessels passing undisturbed through the lesion (Fig. 34.4). In addition to typical choroidal nevi, larger choroidal lesions have been variously categorized as suspicious nevi, intermediate lesions, indeterminate lesions, and even small melanomas.<sup>27</sup> Growth of such lesions been reported in 0–41% of cases, depending on the inclusion criteria and the distribution of variables within the study population (Table 34.2).<sup>27</sup>

**Etiology and pathology** Choroidal nevi involve the full thickness of the choroid with sparing of the choriocapillaris.<sup>28</sup> They are composed of bland-looking nevus cells that are plumper than the normal uveal melanocytes.<sup>28</sup> The nevus cells vary in pigmentation and their shape may be polyhedral, fusiform, dendritic, or spindle, some being

of the clear, balloon type.<sup>28</sup> In the modified Callender's classification of uveal melanoma, tumors composed entirely of spindle A cells are regarded as nevi.<sup>29</sup>

## Clinical features

**Symptoms** Choroidal nevi do not usually cause any symptoms and most are diagnosed on routine ophthalmoscopy. A macular nevus can cause visual loss from photoreceptor atrophy. Subretinal fluid in association with nevus may induce symptoms of metamorphopsia or photopsia.

**Signs** Choroidal nevus appears as a slate-gray to brown lesion with minimal thickness (Fig. 34.4). The margins are usually ill defined.

**Risk factors for growth** In addition to recording the size (largest basal diameter and thickness) and location of the choroidal nevus, it is important to evaluate associated features such as drusen, subretinal fluid, orange pigment, and retinal pigment epithelial atrophy/proliferation, as these are statistically significant predictive factors of growth (Fig. 34.5; Table 34.3).<sup>25,27,30–32</sup> Pigment epithelial detachment and choroidal neovascularization are uncommon secondary effects of choroidal nevi, which do not indicate malignancy.<sup>33</sup>

In a large cohort of patients, the risk of growth can be estimated according to the presence or absence of five clinical features (Table 34.4).<sup>34</sup> Nevertheless, in an individual patient the distinction between small choroidal melanoma and choroidal nevus is not absolute.<sup>25</sup> This limitation exists because most of the risk factors predictive of growth, such as the presence of orange pigment and subretinal fluid, indicate secondary effects on adjacent tissues rather than the intrinsic composition of the lesion.<sup>35</sup>

**Table 34.1 Prevalence of choroidal nevi (published studies).**

First author	Year	Study						Prevalence %
		Country	Number	Setting	Population	Race	Age (yrs)	
Albers	1940	USA	2300	Clinic	Consecutive cases	Not stated	Not stated	1.1*
Wilder	1946	USA	3882	Clinic	Surgical trauma cases	Race?	18–38	0.2*
Hale	1965	USA	252	Autopsy	Consecutive cases	95% White	>18	14+*
Naumann	1970	Germany	187	Autopsy	Unselected cases	Not stated	All	11*
Smith	1972	USA	842	Population	Survey	White (64%)	>13	1.9# (3.8)^
Ganley	1973	USA	65	Population	Random sample	White	>30	3.1# (6.2)^
Gass	1977	USA	250	Clinic	Older	White	<90	30
Albert	1980	USA	1126	Population	Chemical workers + controls	White	>30	7.9§
Lang	1982	Germany	3119	Clinic	Army	Not stated	18–41	4.2
Rodriguez-Sains	1986	USA	108	Clinic	Controls	White	11–84	4.6
Sumich	1998	Australia	3583	Population	Survey	White	>49	6.5* (8.6)^
Yoshikawa	2004	Japan	3676	Clinic	Normal volunteers	Japanese	28–86	0.34

\*, indirect ophthalmoscope not used.

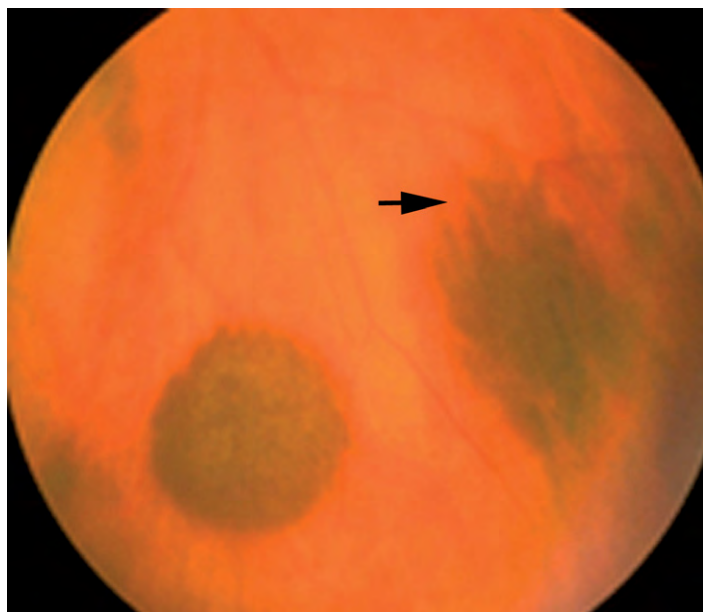
+, including ciliary body nevi.

#, only posterior to the equator.

^, corrected for entire fundus.

§, calculated for white participants.

(Reproduced with permission from Singh AD, Kalyani P, Topham A. Estimating the risk of malignant transformation of a choroidal nevus. *Ophthalmology* 2005; 112: 1784–1789)



**Fig. 34.4** Choroidal nevus and a choroidal freckle (arrow). Note normal choroidal vessels passing undisturbed through the choroidal freckle.

**Diagnostic evaluation** Fundus photography, fluorescein angiography, and ultrasonography can document the size, appearance, and secondary effects of a choroidal nevus. The fluorescein angiographic<sup>25,31</sup> and ultrasonographic features<sup>36</sup> have been investigated as risk factors for growth, with mixed results. The role of fine needle aspiration biopsy remains controversial.<sup>37</sup> Optical coherence tomography of a choroidal nevus is useful only for imaging the overlying retina for secondary changes.<sup>38</sup>

Indocyanine green angiography is more suited for evaluation of the choroidal vascular pattern than is fluorescein angiography, and has been used with confocal scanning laser ophthalmoscopy for this purpose.<sup>35,39,40</sup> In preliminary studies, a statistically significant association between complex microcirculatory patterns (parallel with cross-linking, arcs with branching, loop and/or network) and the growth of indeterminate melanocytic lesions has been observed (Fig. 34.6).<sup>35,39</sup>

**Differential diagnosis** Reactive retinal pigment epithelial (RPE) hyperplasia develops after inflammation or trauma and is usually deeply pigmented, with discrete, irregular edges. Congenital hypertrophy of the retinal pigment epithelium (CHRPE) is dark brown or black, with sharply demarcated margins.<sup>41</sup> CHRPE may have central or

**Table 34.2** Growth rate in patients with choroidal nevus. Note varying inclusion criteria

Author	Year	Number of subjects	Growth (%)	Design	Inclusion criteria	Follow-up (yrs)
Tamler	1970	28	0	Prospective	Base $\leq$ 4.5 mm Height $\leq$ 0.3 mm	9.5
Naumann	1971	112	0	Prospective	Base 0.75–9.0 mm	0.7–16
Gass	1977	38	5	Retrospective	Base $\leq$ 15 mm	2–10
Mims	1978	50	10	Retrospective	Any 2 of the 4 features Base 3–7.5 mm Thickness 0.75–3.0 mm RPE disruption Subretinal fluid present	4 or more
Gass	1980	116	41	Prospective	Observed lesions	5 or more
Augsburger	1989	197	26	Retrospective	Observed lesions	5 or more
Sallet	1993	16	38	Retrospective	Atypical nevi	4.8
Butler	1994	293	36	Retrospective	Any 2 of the 3 features Base < 10 mm Thickness > 6 mm Inactive*	5.6 (mean)
Shields	1995	1287	19	Retrospective	Thickness $\leq$ 3 mm	9.3 (mean)
COMS	1997	188	31	Prospective	Thickness 1–3 mm and Base 5–16 mm	5 or more
Thiagalingam	2004	128	0	Prospective	Choroidal pigmented lesions Base > 0.5 mm	5 or more
Singh	2006	240	5	Prospective	Choroidal pigmented lesions Base > 0.5 mm Observed lesions	3.3 (mean)

<sup>^</sup>Data approximated for comparison; \*Inactive, minimal symptoms, good vision, and absence of subretinal fluid; RPE, Retinal pigment epithelium; COMS, Collaborative Ocular Melanoma Study. (Modified with permission from Singh AD, Mokashi AA, Bena JF et al. Small choroidal melanocytic lesions: Features predictive of growth. *Ophthalmology* 2006; 113: 1032–1039)



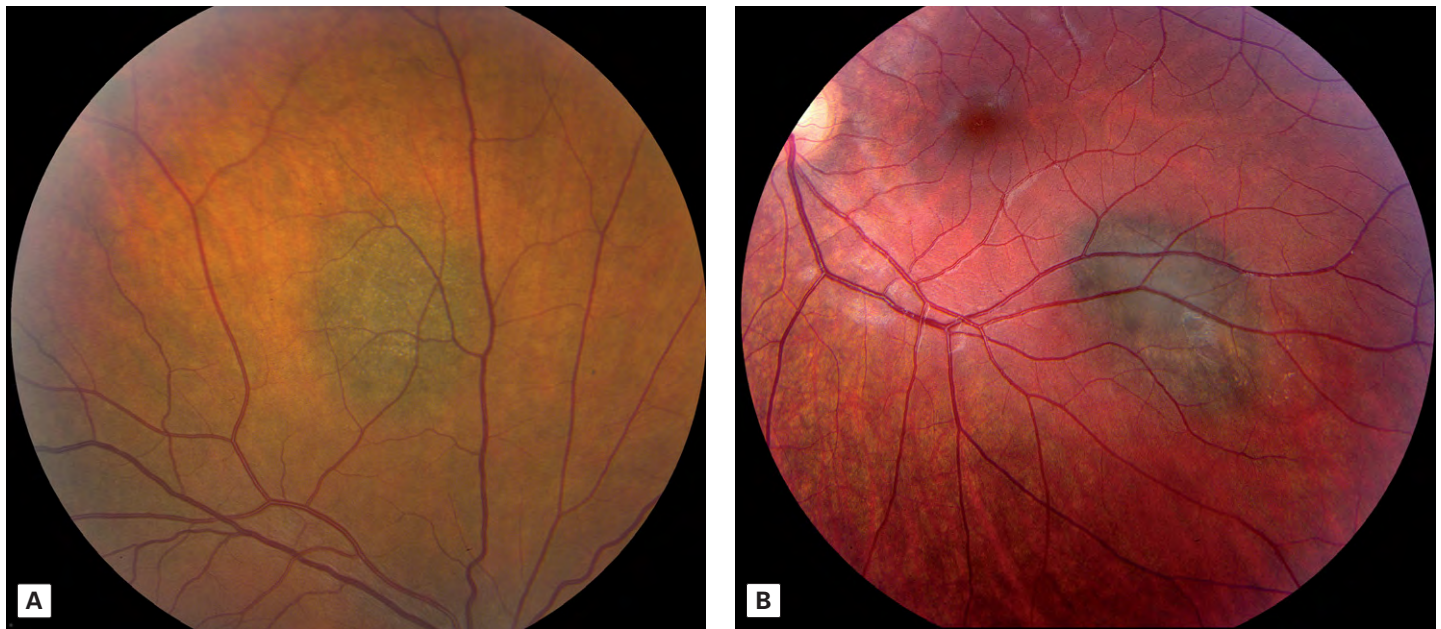


Fig. 34.5 A choroidal nevus with fine drusen (A) and with orange pigment (B). Note localized shallow subretinal fluid along the temporal margin.

**Table 34.3** Statistically significant clinical features predictive of subsequent growth of a choroidal nevus

Author	Risk factor (relative risk)						Symptoms (present)
	Size (mm)		Secondary effects			Juxtapapillary location	
	Basal diameter	Drusen (present)	Orange pigment (present)	Sub retinal fluid	Adjacent RPE Changes		
Gass	S	S	S	NS	S	NA	NS
Augsburger	S	NS	S	S	NS	S	S
	NS						
Butler	NS	NS	S (2.7)	S (3.0)	NS	NS	S (3.3)
	S (1.8)						
Shields	NS	NS	S (1.5)	S(1.4)	NA	S (2.6)	S (1.8)
	S (5.2)						
COMS	S (5.2)	S (0.2)	S(6.4)	NS	S (0.2)	NS	NA
	S (17.7)						
Singh	NS	NS	S (9.6)	NS	NS	S (6.3)	S (4.9)
	S (8.2)						

S, significant; NS, not significant; NA, not assessed; RPE, retinal pigment epithelium; COMS, Collaborative Ocular Melanoma Study. (Modified with permission from Singh AD, Mokashi AA, Bena JF et al. Small choroidal melanocytic lesions: Features predictive of growth. Ophthalmology 2006; 113: 1032–1039)

peripheral clear areas (lacunae) but drusen, orange pigment, subretinal fluid, and RPE fibrosis are absent. There can be slow growth over several years.<sup>41</sup>

**Treatment** At present only periodic observation is recommended for choroidal nevi. Associated subretinal fluid has been treated with surface and surrounding laser photocoagulation.<sup>42</sup> Photodynamic

therapy may be effective in rare cases when associated choroidal neovascularization is present.<sup>43</sup>

**Prognosis** There is clinical and histopathological evidence suggesting that choroidal melanoma may arise from a pre-existing choroidal nevus<sup>28,44</sup> or de novo.<sup>45</sup> However, there is a paucity of risk estimates of malignant transformation of a choroidal nevus because of lack of

**Table 34.4 Risk factors predictive of growth of a choroidal nevus**

Risk factors	Combination of risk factors	Risk (%)
Thickness > 2.0 mm	None present	5
Posterior margin touching the optic disc	Any one present	36
Presence of visual symptoms	Any two present	45
Presence of orange pigment	Any three present	50
Presence of subretinal fluid	Any four present	51
	All present	56

(Derived from Shields CL, Cater J, Shields JA et al. Combination of clinical factors predictive of growth of small choroidal melanocytic tumors. Arch Ophthalmol 2000; 118: 360–364)

reliable population-based data.<sup>26</sup> With the assumption that all melanomas arise from pre-existing nevi, the risk of malignant transformation is estimated to be 1 in 8845.<sup>26</sup> The annual rate of malignant transformation is much lower (1 in 269 565) for the younger age group (15–19 years), with a gradual increase to 1 in 3664 for the older age group (80–84 years).<sup>26</sup> The estimated risk stated above applies only to typical choroidal nevi, and it is expected that it would be higher for indeterminate lesions. Choroidal freckles are not known to undergo malignant transformation.

## CILIARY BODY NEVUS

**Clinical features** Nevi of the ciliary body have been rarely reported in the literature but they are suspected to occur more frequently.<sup>46,47</sup> A ciliary body nevus usually appears as a dome-shaped mass with a smooth surface. Intrinsic vascularity is usually not present. Unexplained sentinel vessels, sectoral cataract, or localized shallowing of the anterior chamber should prompt evaluation of the ciliary body. Gonioscopic evaluation provides a satisfactory view of the extent of the lesion. Ultrasound biomicroscopy provides useful information about its size, extent, and internal consistency (Fig. 34.7); however, no specific features are diagnostic of ciliary body nevus. The differential diagnosis of a pigmented ciliary body nevus includes melanocytoma, melanoma, and adenoma or adenocarcinoma of the pigmented ciliary epithelium. These are described in the relevant chapters of this book. In practice, the diagnosis is usually made histologically, with biopsy or after enucleation.

**Complications** Many ciliary body nevi remain asymptomatic until they reach a critical size, when they may induce secondary cataract or glaucoma as a result of pigment shedding.

**Treatment** There is no consensus as to whether ciliary body tumors should be observed or excised. Before undertaking complex excisional surgery, there may be scope for incisional or fine needle aspiration biopsy.<sup>48</sup> However, the detection of benign cells does not entirely exclude malignancy, because of the risk of sampling error.<sup>49</sup> Excision under a lamellar scleral flap is the treatment of choice for small, circumscribed ciliary body tumors (involving no more than three clock hours) without extrascleral extension.<sup>49</sup> En bloc excision with simultaneous full-thickness corneoscleral resection is indicated when extra-

ocular extension is present.<sup>49,50</sup> Another approach is to treat ciliary body tumors with plaque or proton beam radiotherapy, perhaps excising any extraocular tumor nodule if necessary.

## MELANOCYTOSIS

Ocular melanocytosis is a congenital condition characterized by hyperpigmentation of the episclera and uvea (Fig. 34.8).<sup>51,52</sup> Associated cutaneous hyperpigmentation in the distribution of the trigeminal nerve is called oculodermal melanocytosis (nevus of Ota).<sup>53</sup> The orbit and meninges can also be involved.

**Association with uveal melanoma** In Caucasians several observations support an association between oculo(dermal) melanocytosis and uveal melanoma.<sup>44,54,55</sup> These include the occurrence of uveal melanoma ipsilateral to ocular melanocytosis,<sup>55</sup> and the development of uveal melanoma in the sector of the eye affected with melanocytosis. Although, ocular and oculodermal melanocytosis is common in Orientals, the occurrence of uveal melanoma in this population is rare.<sup>56</sup> A few cases of uveal melanoma in Hispanics<sup>57</sup> and blacks<sup>58</sup> with oculo(dermal) melanocytosis have also been observed.

**Biological basis** for susceptibility to the development of uveal melanoma in oculo(dermal) melanocytosis is not known. Excessive melanocytes in the uveal tract of patients with oculo(dermal) melanocytosis may be the reason for such susceptibility.<sup>52</sup>

**Risk estimate** The age at diagnosis of uveal melanoma in association with oculo(dermal) melanocytosis is no different from that of sporadic uveal melanoma (Fig. 34.9).<sup>52</sup> Overall, it is estimated that the lifetime risk of developing uveal melanoma in a Caucasian with oculo(dermal) melanocytosis is about 1 in 400.<sup>52</sup>

**Clinical variants** In addition to ipsilateral unilateral, unifocal uveal melanoma, rare cases of bilateral<sup>59</sup> and multifocal uveal melanomas<sup>60</sup> tend to occur in the presence of oculo(dermal) melanocytosis. In cases of primary melanoma of the orbit<sup>61</sup> and central nervous system the presence of ocular melanocytosis should be excluded.<sup>62</sup>

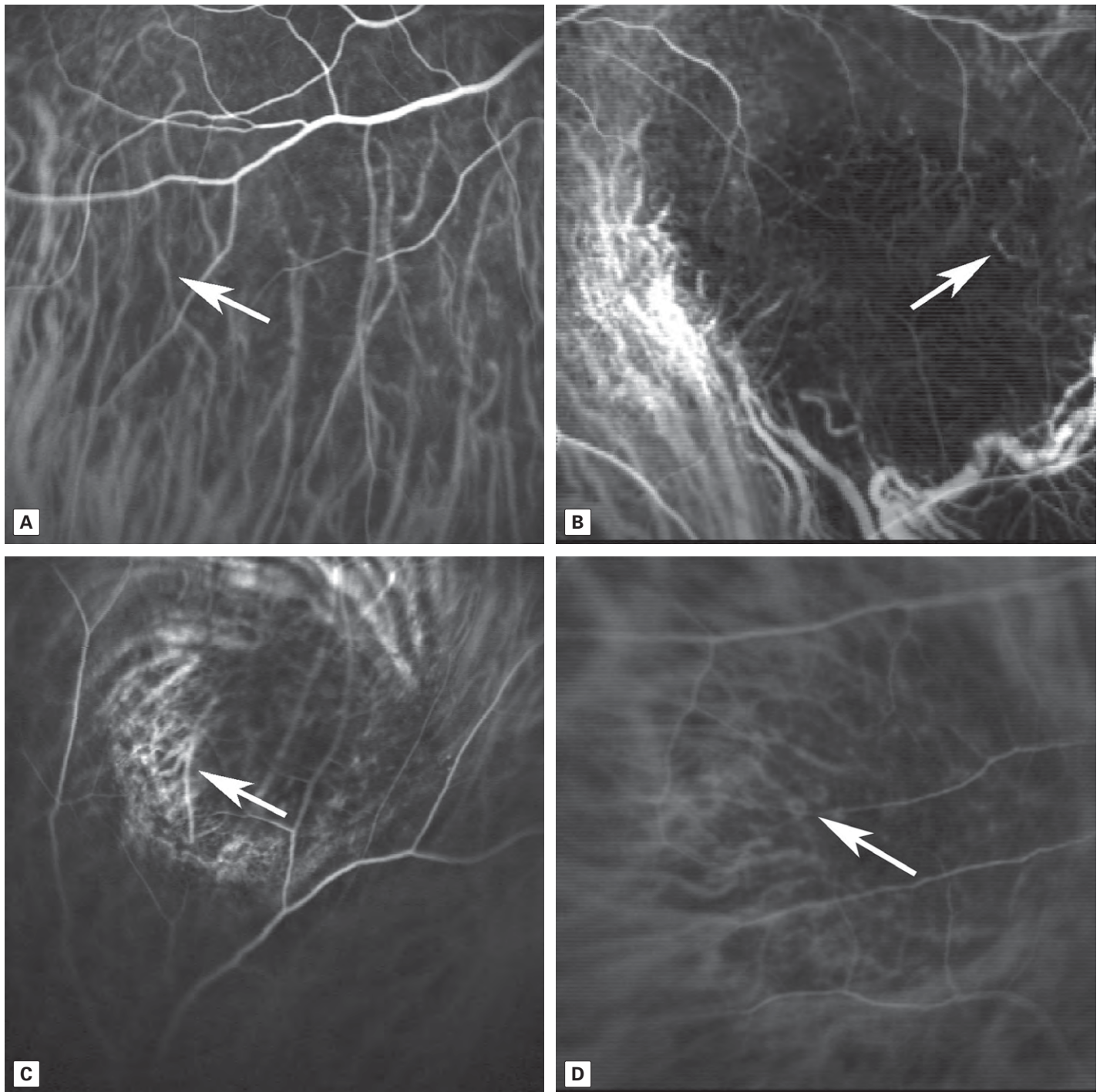
**Treatment** It is generally recommended that patients with oculo(dermal) melanocytosis be monitored annually.

## OPTIC DISC MELANOCYTOMA

Melanocytoma is a benign pigmented ocular tumor that predominantly involves the optic disc and uvea.<sup>63</sup> Other rare sites include the sclera<sup>64</sup> and conjunctiva.<sup>65</sup> The term melanocytoma was proposed by Zimmerman and Garron<sup>23,66</sup> because they observed a resemblance between melanocytoma cells and those seen in ocular melanocytosis (melanosis oculi). An alternative term, magnocellular nevus, emphasizes its neural crest origin as a variant of a nevus.<sup>67</sup> Other descriptive terms, such as benign melanoma of the optic nerve head, are no longer used.<sup>68</sup>

**Etiology** Optic disc and uveal melanocytomas are considered to be congenital hamartomas,<sup>23</sup> arising from dendritic uveal melanocytes scattered throughout the uvea.<sup>69</sup>

**Pathology** Optic disc melanocytoma is a dark pigmented mass, often extending from the optic disc to the surrounding choroid and retina.<sup>23,66</sup> The cells are deeply pigmented because of the presence of



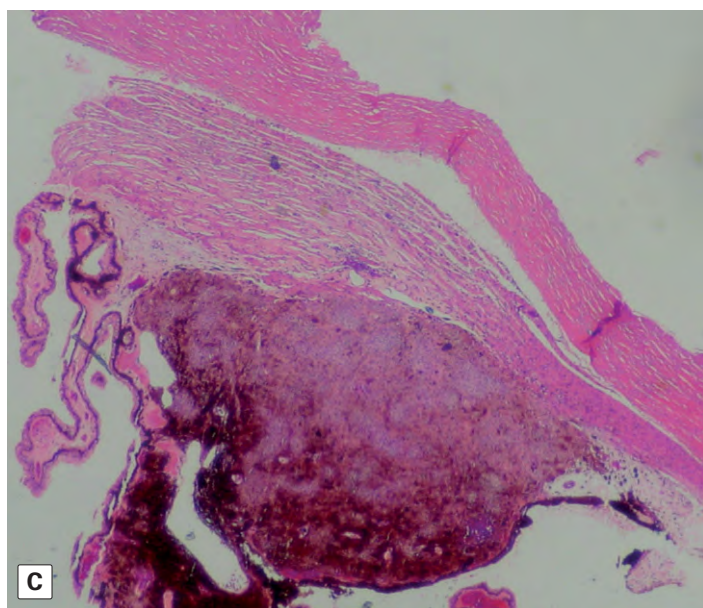
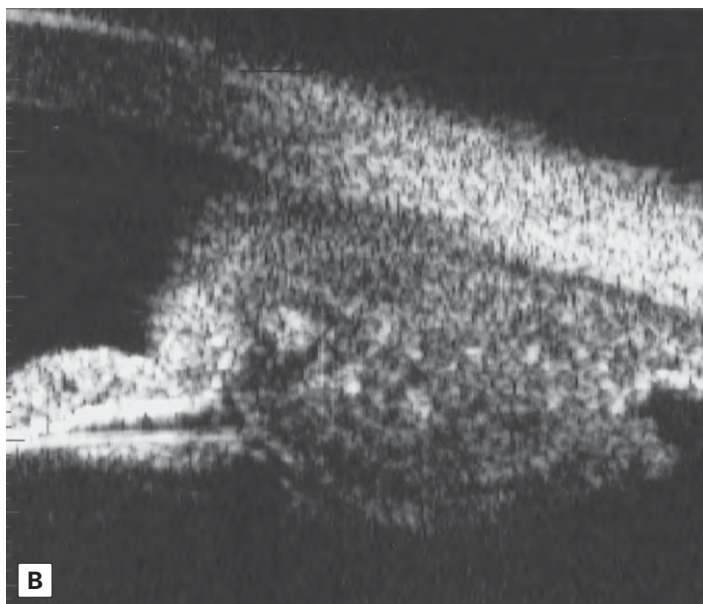
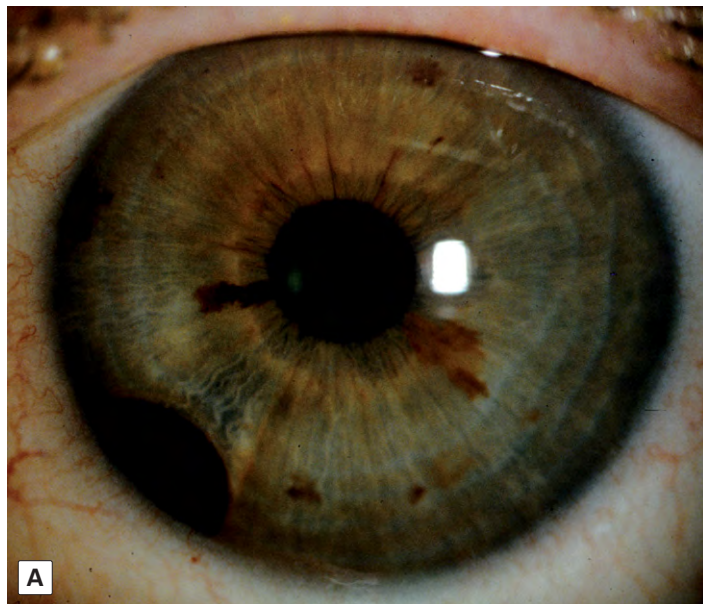**Fig. 34.6** Indocyanine green angiographic vascular patterns of small choroidal melanocytic lesions. In the parallel vascular pattern, linear blood vessels seem to extend from normal adjacent choroid to the region of the tumor and could be traced undisturbed to cross the tumor margin into the surrounding choroid (**A**, arrow). Tortuous vessels were essentially similar to parallel vessels except for minimal tortuosity (**B**, arrow). In a branching vascular pattern, the parallel vessels showed branching (**C**, arrow). The loops vascular pattern comprised circular vascular loops (**D**, arrow). (Reproduced with permission from Singh AD, Mokashi AA, Bena JF et al. Small choroidal melanocytic lesions: Indocyanine angiographic features predictive of growth: A pilot study. *Ophthalmology* 2006; 113: 1061.)

numerous macromelanosomes, and cellular details are not evident histologically until bleaching is performed. Most cells are plump, round, or polyhedral. A smaller population of lightly pigmented spindle-shaped melanocytoma cells may also be present.<sup>70</sup> The nuclei are bland, uniformly small, and normochromic. Mitotic figures are usually absent.

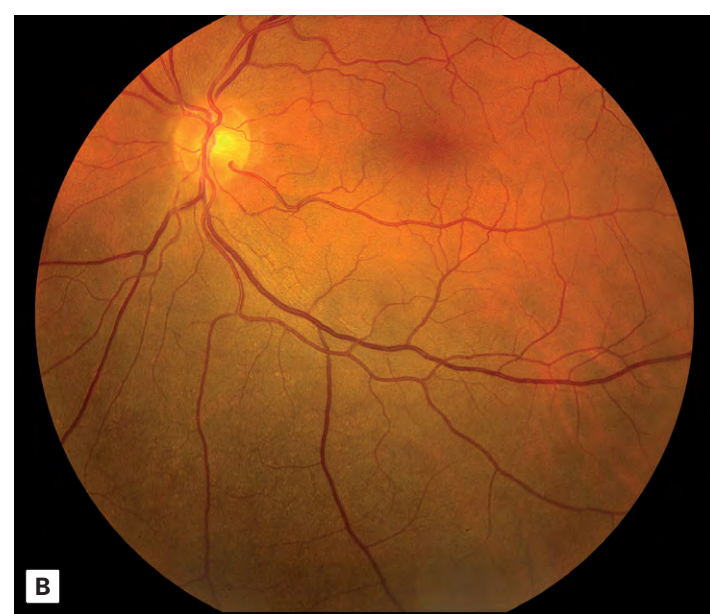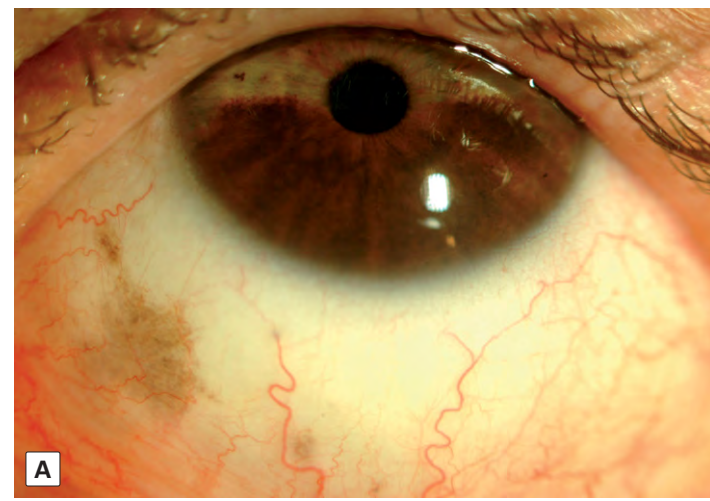
### Clinical features

**Symptoms** Although optic disc melanocytoma is a congenital entity, it is rarely detected in childhood, the mean age at diagnosis being 50 years.<sup>71</sup> Optic disc melanocytoma is more commonly seen in blacks and darker races than in whites.<sup>69</sup> Most patients are asymptomatic<sup>69,71</sup> and the condition is detected on routine ophthalmoscopy.

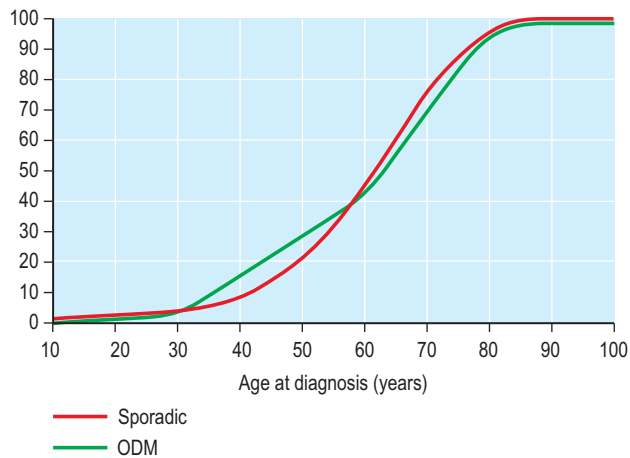




←  
**Fig. 34.7** Ultrasound biomicroscopy of an iridociliary mass. **(A)** Slit lamp photograph. **(B)** Ultrasound biomicroscopy revealed a ciliary body mass with anterior extension into the iris root. **(C)** Note the close correlation between histopathological appearance (after iridocyclectomy) and biomicroscopic findings. (Reproduced with permission from Bakri SJ, Sculley L, Singh AD. Imaging techniques for uveal melanoma. *Int Ophthalmol Clin* 2006;46:1–13.)



**Fig. 34.8** Oculo(dermal) melanocytosis. Note slate-gray episcleral pigmentation, diffuse iris nevus **(A)**, and corresponding inferior sectoral choroidal hyperpigmentation **(B)**.

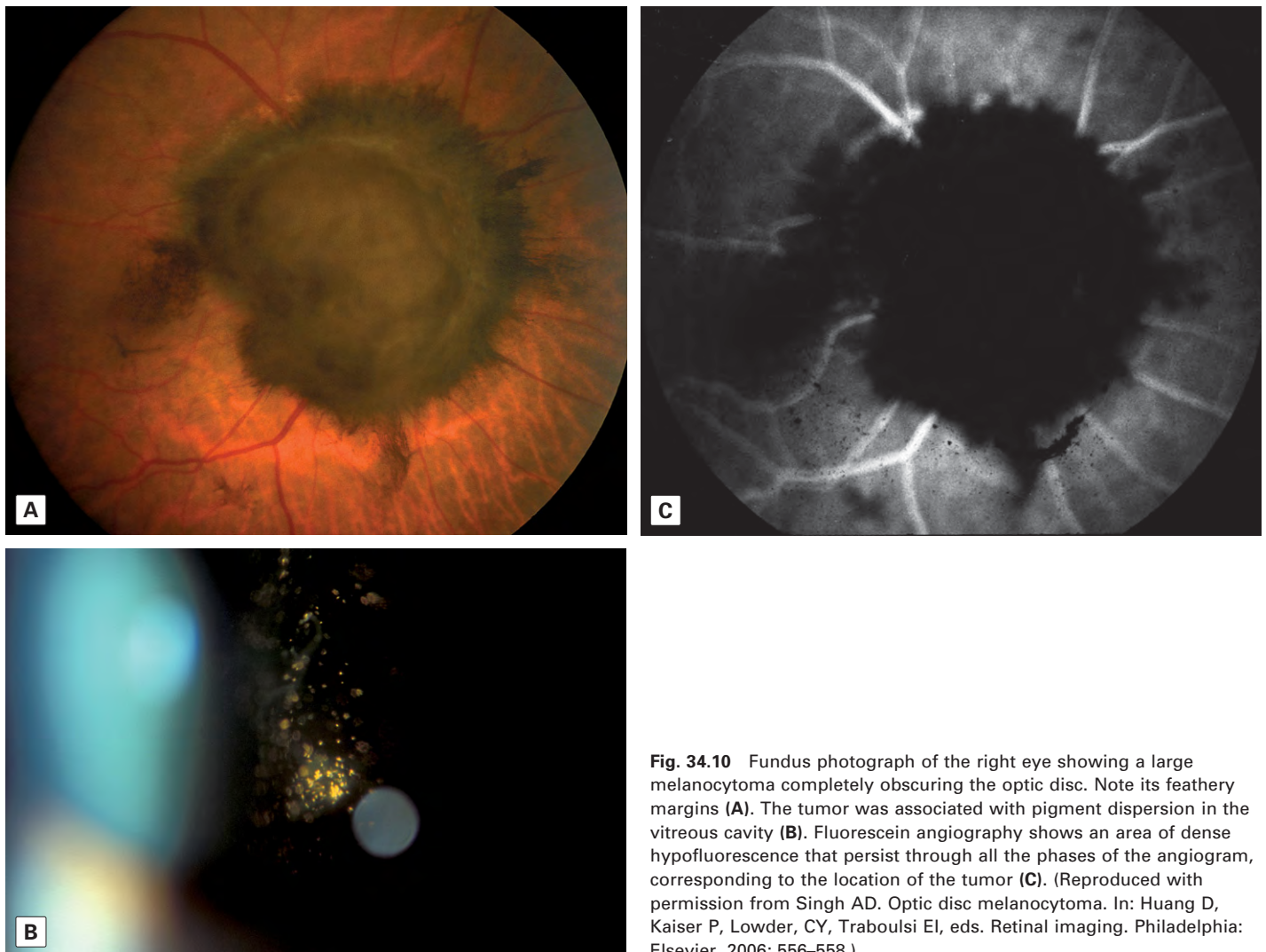


**Fig. 34.9** Comparison of age at diagnosis of uveal melanoma in patients with oculodermal melanocytosis (ODM) and 100 randomly selected sporadic uveal melanoma patients. (Modified with permission from Singh AD, De Potter P, Fijal BA et al. Lifetime prevalence of uveal melanoma in white patients with oculodermal melanocytosis. *Ophthalmology* 1998; 105: 195–198.)

**Signs** On ophthalmoscopy, optic disc melanocytoma is a dark-brown or black, flat or slightly elevated mass, usually located inferotemporally (Fig. 34.10A). The choroid is involved in about 54% of cases and a retinal component is present in about 30%.<sup>71</sup> The retinal involvement usually appears darker than the choroidal component, and has feathery margins because of extensions into the nerve fiber layer. Larger melanocytoma may completely obscure the optic disc and may lead to pigment dispersion into the vitreous cavity (Fig. 34.10B). Prominent intrinsic vasculature, subretinal fluid, and retinal exudation are not usually present.

**Associations** Unilateral optic disc melanocytoma is not associated with other ocular or systemic anomalies; however, bilateral tumors have been reported in association with optic nerve hypoplasia and central nervous system abnormalities.<sup>72</sup>

**Differential diagnosis** Optic disc melanocytoma should be differentiated from optic disc melanoma,<sup>73</sup> adenoma of the juxtapapillary retinal pigment epithelium,<sup>74</sup> and combined hamartoma of the retinal pigment epithelium and retina. Optic disc melanoma usually arises from the juxtapapillary choroid and extends over the optic nerve, causing significant visual symptoms, unlike an optic disc



**Fig. 34.10** Fundus photograph of the right eye showing a large melanocytoma completely obscuring the optic disc. Note its feathery margins (A). The tumor was associated with pigment dispersion in the vitreous cavity (B). Fluorescein angiography shows an area of dense hypofluorescence that persist through all the phases of the angiogram, corresponding to the location of the tumor (C). (Reproduced with permission from Singh AD. Optic disc melanocytoma. In: Huang D, Kaiser P, Lowder, CY, Traboulsi EI, eds. *Retinal imaging*. Philadelphia: Elsevier, 2006; 556–558.)



melanocytoma. In addition, a melanoma is brown, does not usually infiltrate the nerve fiber layer, and may reveal intrinsic vasculature on ophthalmoscopy or angiography. Adenoma of the retinal pigment epithelium may be difficult to differentiate from an optic disc melanocytoma on the basis of clinical findings alone.<sup>74</sup> Combined hamartoma of the retinal pigment epithelium and retina is generally seen in a younger age group and has prominent vascular and gliotic components.

**Diagnostic evaluation** The diagnosis of optic disc melanocytoma is usually suspected on ophthalmoscopic examination. Fundus photographs are used to document and monitor the lesion over prolonged periods. On fluorescein angiography, optic disc melanocytoma appears as an area of dense hypofluorescence, which persists through all phases of the angiogram. Intrinsic vasculature is characteristically absent (Fig. 34.10C). Similar findings are noted on indocyanine angiography. B-scan ultrasonography detects an acoustically solid optic disc mass with high initial spike. Optical coherence tomography shows a high reflectance signal anteriorly, which is continuous with the retinal nerve fiber layer, and there is optical shadowing posteriorly.<sup>75</sup> Magnetic resonance imaging ( $T_1$ -weighted image with fat suppression technique) may be used to detect enlargement of the optic nerve and demarcate the posterior extension. The melanocytoma appears hyperintense with respect to the vitreous owing to the paramagnetic properties of melanin. The tumor may also be enhanced with gadolinium.

**Treatment** Once documented, most optic disc melanocytomas are kept under periodic observation.<sup>71</sup> Any eye demonstrating a rapid increase in the size of an optic disc melanocytoma is usually enucleated because of concerns about malignant transformation.

**Prognosis** A large majority of optic disc melanocytomas remain stable over many years.<sup>69,71</sup> Subtle growth over several years is observed in about 10% of cases.<sup>71,76</sup> An afferent pupillary defect and nerve fiber bundle visual field defects are seen even when visual acuity is normal, suggesting asymptomatic optic nerve dysfunction.<sup>71</sup> Rapid deterioration of vision due to infarction and swelling of an optic disc melanocytoma may manifest as papillitis, neuroretinitis, and central retinal artery or vein occlusion. Rapid enlargement, indicative of malignant transformation into melanoma, is observed in about 2% of cases.<sup>71,77,78</sup>

## UVEAL MELANOCYTOMA

Uveal melanocytomas are histologically similar to optic disc melanocytoma.<sup>69</sup> Such tumors have been seen in the iris, ciliary body, and choroid. Uveal melanocytomas are clinically indistinguishable from uveal nevus and melanoma, and most are probably managed as such. As with optic disc melanocytoma, uveal melanocytoma can give rise to melanoma.<sup>79</sup>

### Iris melanocytoma

**Clinical features** Only about 60 cases of iris melanocytoma have been published.<sup>80</sup> In a study of 189 pathologic samples of iris and ciliary body tumors suspected to be melanoma, about 5% were confirmed to be melanocytomas.<sup>6</sup> The usual age at presentation is about 35 years,<sup>80</sup> with rare presentations in childhood.<sup>81</sup> The tumors are invariably darkly pigmented and nodular in appearance. They most commonly involve the inferior quadrants and have a predilection for the iris root. Associated features that are helpful in suspecting the

diagnosis of iris melanocytoma are the presence of stromal and angle pigment seeding and the absence of ectropion iridis, sectoral cataract, and visible intrinsic vascularization.

**Complications** In a series of 47 patients with iris melanocytoma, the main complications included pigment shedding (34%), progressive enlargement (23%), and secondary glaucoma (11%).<sup>80</sup> Tumor necrosis with the sudden onset of melanocytolytic glaucoma is a rare complication.<sup>82,83</sup> Malignant transformation of iris melanocytoma is extremely uncommon,<sup>84</sup> and slow growth of the tumor usually does not imply such a change.<sup>79,80</sup>

**Treatment** Periodic observation is generally recommended, unless there are concerns about malignancy, in which case fine needle aspiration biopsy or local resection is performed.

### Ciliary body melanocytoma

**Clinical features** Only about 40 cases of ciliary body melanocytoma have been published.<sup>85</sup> The usual age at presentation is about 47 years,<sup>85,86</sup> with rare presentations in childhood.<sup>85</sup> The tumors are invariably darkly pigmented and nodular in appearance. There is no predilection for any particular quadrant. Although benign, ciliary body melanocytomas tend to extend into the anterior chamber and extraocularly. Such extension can mimic extrascleral growth of a ciliary body melanoma. One feature suggestive of melanocytoma is a uniform, black appearance, which is rare in ciliary body melanoma.

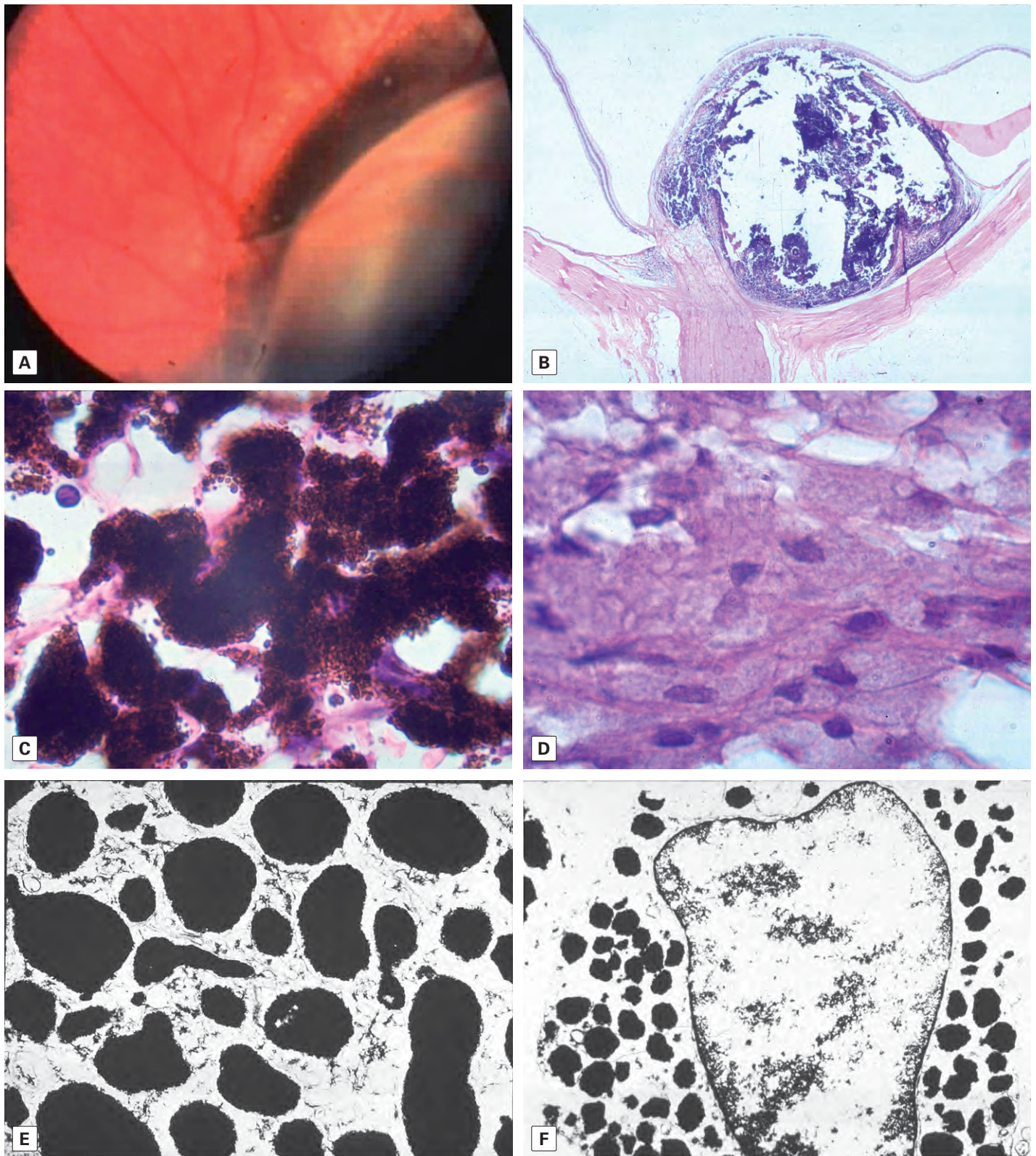
**Complications** In a review of 40 patients with ciliary body melanocytoma, the main complications included anterior chamber extension (85%), progressive enlargement, and secondary glaucoma (13%).<sup>85</sup> Tumor necrosis and uveitis may also occur.<sup>86</sup> Malignant transformation of ciliary body melanocytoma is extremely uncommon, and slow growth of the tumor usually does not imply such a change.<sup>79,85</sup>

**Treatment** Periodic observation is generally not recommended because of the difficulty in differentiating ciliary body melanocytoma from ciliary body melanoma. Fine needle aspiration biopsy followed by ultrasound biomicroscopic observation may be applicable in cases not associated with necrosis and glaucoma.<sup>87</sup> In general, iridocyclectomy under a lamellar corneoscleral flap is the preferred treatment. If the sclera is involved, a full-thickness corneoscleral graft may be required.<sup>49</sup> Enucleation is limited to cases with uncontrolled glaucoma.<sup>88</sup>

### Choroidal melanocytoma

**Clinical features** Only about 15 cases of choroidal melanocytoma have been published.<sup>89</sup> The usual age at presentation is between 30 and 50 years,<sup>89</sup> with rare presentations in childhood.<sup>89,90</sup> The tumors are usually darkly pigmented and dome-shaped in appearance (Fig. 34.11).<sup>89</sup> A diffuse variant has also been described.<sup>91</sup> A choroidal melanocytoma can be indistinguishable from melanoma on ophthalmoscopy, ultrasonography, and angiography.<sup>92,93</sup> In fact, several cases of choroidal melanocytoma in the Collaborative Ocular Melanoma Study have been treated by plaque radiotherapy with a presumptive clinical diagnosis of melanoma, the correct diagnosis being made only retrospectively, when the eye was enucleated for radiation-related complications.<sup>93,94</sup>





**Fig. 34.11** Choroidal melanocytoma. (A) The left fundus shows a tumor with black pigmentation along the base. (B) The enucleated globe shows a pigmented peripapillary mass. (C) The tumor cells are heavily pigmented with large granules. (Hematoxylin & eosin, original magnification  $\times 500$ .) (D) The cells appear fairly uniform, with benign cytologic features. (Hematoxylin & eosin after bleaching; original magnification  $\times 500$ .) (E) Electron micrograph demonstrating cytoplasmic macromelanosomes within the tumor cells. (Original magnification  $\times 14000$ .) (F) Macromelanosomes are about 10 times larger than melanosomes within normal choroidal melanocytes. (Reproduced with permission from Brownstein S, Dorey MW, Mathew B et al. Melanocytoma of the choroid: atypical presentation and review of the literature. *Can J Ophthalmol* 2002; 37: 247–252.)

**Complications** Necrosis and inflammation can occur within a melanocytoma, leading to a blind, painful eye.<sup>95</sup> Choroidal melanocytoma can rarely undergo malignant transformation into melanoma.<sup>79,95,96</sup>

**Treatment** The best management of choroidal melanocytoma is controversial. If clinically suspected, smaller lesions may be observed.

Fine needle aspiration biopsy can be misleading, as it may only reveal melanocytoma and may miss associated regions of melanoma.<sup>95,96</sup> The correct diagnosis may be reached only when the globe is examined histologically after enucleation.<sup>93,95,96</sup>

## REFERENCES

- Johnston MC. A radioautographic study of the migration and fate of cranial neural crest cells in the chick embryo. *Anat Rec* 1966; 156: 143–155.
- Harbour JW, Brantley MA Jr, Hollingsworth H, Gordon M. Association between posterior uveal melanoma and iris freckles, iris naevi, and choroidal naevi. *Br J Ophthalmol* 2004; 88: 36–38.
- Rodríguez-Sains RS. Ocular findings in patients with dysplastic nevus syndrome. An update. *Dermatol Clin* 1991; 9: 723–728.
- Toth-Molnar E, Olah J, Dobozy A, Hammer H. Ocular pigmented findings in patients with dysplastic naevus syndrome. *Melanoma Res* 2004; 14: 43–47.
- Bataille V, Sasieni P, Cuzick J et al. Risk of ocular melanoma in relation to cutaneous and iris naevi. *Int J Cancer* 1995; 60: 622–626.
- Jakobiec FA, Silbert G. Are most iris ‘melanomas’ really nevi? A clinicopathologic study of 189 lesions. *Arch Ophthalmol* 1981; 99: 2117–2132.
- Jakobiec FA, Moorman LT, Jones IS. Benign epithelioid cell nevi of the iris. *Arch Ophthalmol* 1979; 97: 917–921.
- Shields JA, Karan DS, Perry HD, Donoso LA. Epithelioid cell nevus of the iris. *Arch Ophthalmol* 1985; 103: 235–237.
- Margo CE, Groden L. Balloon cell nevus of the iris. *Am J Ophthalmol* 1986; 102: 282–283.
- Ticho BH, Tso MO, Kishi S. Diffuse iris nevus in oculodermal melanocytosis: a light and electron microscopic study. *J Pediatr Ophthalmol Strabismus* 1989; 26: 244–250.
- Cogan DG, Reese AB. A syndrome of iris nodules, ectopic Descemet’s membrane, and unilateral glaucoma. *Doc Ophthalmol* 1969; 26: 424–433.
- Eagle RC Jr, Font RL, Yanoff M, Fine BS. Proliferative endotheliopathy with iris abnormalities. The iridocorneal endothelial syndrome. *Arch Ophthalmol* 1979; 97: 2104–2111.
- Ragge NK, Acheson J, Murphree AL. Iris mammillations: significance and associations. *Eye* 1996; 10: 86–91.
- Gunduz K, Shields CL, Shields JA et al. Iris mammillations as the only sign of ocular melanocytosis in a child with choroidal melanoma. *Arch Ophthalmol* 2000; 118: 716–717.
- Ragge NK, Falk RE, Cohen WE, Murphree AL. Images of Lisch nodules across the spectrum. *Eye* 1993; 7: 95–101.
- Carlson DW, Alward WL, Folberg R. Aggressive nevus of the iris with secondary glaucoma in a child. *Am J Ophthalmol* 1995; 119: 367–368.
- Paridaens D, Lyons CJ, McCartney A, Hungerford JL. Familial aggressive nevi of the iris in childhood. *Arch Ophthalmol* 1991; 109: 1552–1554.
- Conway RM, Chew T, Golchet P et al. Ultrasound biomicroscopy: role in diagnosis and management in 130 consecutive patients evaluated for anterior segment tumours. *Br J Ophthalmol* 2005; 89: 950–955.
- Radhakrishnan S, Rollins AM, Roth JE et al. Real-time optical coherence tomography of the anterior segment at 1310 nm. *Arch Ophthalmol* 2001; 119: 1179–1185.
- Harbour JW, Augsburger JJ, Eagle RC Jr. Initial management and follow-up of melanocytic iris tumors. *Ophthalmology* 1995; 102: 1987–1993.
- Shields CL, Shields JA, Materin M et al. Iris melanoma: risk factors for metastasis in 169 consecutive patients. *Ophthalmology* 2001; 108: 172–178.
- Territo C, Shields CL, Shields JA et al. Natural course of melanocytic tumors of the iris. *Ophthalmology* 1988; 95: 1251–1255.
- Zimmerman LE. Melanocytes, melanocytic nevi, and melanocytomas. *Invest Ophthalmol* 1965; 34: 11–41.
- Group COMS. COMS manual of procedures: accession no. PBS 179693. Springfield, VA: National Technical Information Service, 1995.
- Anonymous. Factors predictive of growth and treatment of small choroidal melanoma: COMS Report No. 5. The Collaborative Ocular Melanoma Study Group. *Arch Ophthalmol* 1997; 115: 1537–1544.
- Singh AD, Kalyani P, Topham A. Estimating the risk of malignant transformation of a choroidal nevus. *Ophthalmology* 2005; 112: 1784–1789.
- Singh AD, Mokashi AA, Bena JF et al. Small choroidal melanocytic lesions: Features predictive of growth. *Ophthalmology* 2006; 113: 1032–1039.
- Naumann G, Yanoff M, Zimmerman LE. Histogenesis of malignant melanomas of the uvea. I. Histopathologic characteristics of nevi of the choroid and ciliary body. *Arch Ophthalmol* 1966; 76: 784–796.
- McLean IW, Foster WD, Zimmerman LE, Gamel JW. Modifications of Callender’s classification of uveal melanoma at the Armed Forces Institute of Pathology. *Am J Ophthalmol* 1983; 96: 502–509.
- Augsburger JJ, Schroeder RP, Territo C et al. Clinical parameters predictive of enlargement of melanocytic choroidal lesions. *Br J Ophthalmol* 1989; 73: 911–917.
- Butler P, Char DH, Zarbin M, Kroll S. Natural history of indeterminate pigmented choroidal tumors. *Ophthalmology* 1994; 101: 710–716; discussion 717.
- Shields CL, Shields JA, Kiratli H et al. Risk factors for growth and metastasis of small choroidal melanocytic lesions. *Ophthalmology* 1995; 102: 1351–1361.
- Zografos L, Mantel I, Schalenbourg A. Subretinal choroidal neovascularization associated with choroidal nevus. *Eur J Ophthalmol* 2004; 14: 123–131.
- Shields CL, Cater J, Shields JA et al. Combination of clinical factors predictive of growth of small choroidal melanocytic tumors. *Arch Ophthalmol* 2000; 118: 360–364.
- Singh AD, Mokashi AA, Bena JF et al. Small choroidal melanocytic lesions: Indocyanine angiographic features predictive of growth: A pilot study. *Ophthalmology* 2006; 113: 1061.
- Coleman DJ, Silverman RH, Rondeau MJ et al. Noninvasive in vivo detection of prognostic indicators for high-risk uveal melanoma: ultrasound parameter imaging. *Ophthalmology* 2004; 111: 558–564.
- Augsburger JJ, Correa ZM, Schneider S et al. Diagnostic transvitreal fine-needle aspiration biopsy of small melanocytic choroidal tumors in nevus versus melanoma category. *Trans Am Ophthalmol Soc* 2002; 100: 225–232; discussion 232–224.
- Shields CL, Mashayekhi A, Materin MA et al. Optical coherence tomography of choroidal nevus in 120 patients. *Retina* 2005; 25: 243–252.
- Mueller AJ, Freeman WR, Schaller UC et al. Complex microcirculation patterns detected by confocal indocyanine green angiography predict time to growth of small choroidal melanocytic tumors: MuSIC Report II. *Ophthalmology* 2002; 109: 2207–2214.
- Flower RW. Infrared absorption angiography of the choroid and some observations on the effects of high intraocular pressures. *Am J Ophthalmol* 1972; 74: 600–614.
- Shields CL, Mashayekhi A, Ho T et al. Solitary congenital hypertrophy of the retinal pigment epithelium: clinical features and frequency of enlargement in 330 patients. *Ophthalmology* 2003; 110: 1968–1976.
- Mines JA, Freilich DB, Friedman AH, Lazar M. Choroidal (subretinal) neovascularization secondary to choroidal nevus and successful treatment with argon laser photocoagulation. Case reports and review of literature. *Ophthalmologica* 1985; 190: 210–218.
- Parodi MB, Boscia F, Piermarocchi S et al. Variable outcome of photodynamic therapy for choroidal neovascularization associated with choroidal nevus. *Retina* 2005; 25: 438–442.
- Yanoff M, Zimmerman LE. Histogenesis of malignant melanomas of the uvea. 3. The relationship of congenital ocular melanocytosis and neurofibromatosis in uveal melanomas. *Arch Ophthalmol* 1967; 77: 331–336.
- Sahel JA, Pesavento R, Frederick AR Jr, Albert DM. Melanoma arising de novo over a 16-month period. *Arch Ophthalmol* 1988; 106: 381–385.
- Cogan DG, Kuwabara T. Tumors of the ciliary body. *Int Ophthalmol Clin* 1971; 11: 27–56.
- Gordon E. Nevus of the choroid and pars plana. Enucleation for suspected malignant melanoma. *Surv Ophthalmol* 1963; 123: 507–511.
- El-Harazi SM, Kellaway J, Font RL. Melanocytoma of the ciliary body diagnosed by fine-needle aspiration biopsy. *Diagn Cytopathol* 2000; 22: 394–397.
- Rummelt V, Naumann GO, Folberg R, Weingeist TA. Surgical management of melanocytoma of the ciliary body with extrascleral extension. *Am J Ophthalmol* 1994; 117: 169–176.
- Raichand M, Peyman GA, Juarez CP et al. Resection of uveal melanocytoma: clinicopathological correlation. *Br J Ophthalmol* 1983; 67: 236–243.
- Fitzpatrick TB, Kitamura H, Kukita A, Zeller R. Ocular and dermal melanocytosis. *AMA Arch Ophthalmol* 1956; 56: 830–832.
- Singh AD, De Potter P, Fijal BA et al. Lifetime prevalence of uveal melanoma in white patients with ocular(dermal) melanocytosis. *Ophthalmology* 1998; 105: 195–198.
- Ota M, Tanino H. Nevus fusco-ceruleus ophthalmomaxillaris. *Tokyo Med J* 1939; 63: 1243–1245.
- Gonder JR, Shields JA, Albert DM et al. Uveal malignant melanoma associated with ocular and oculodermal melanocytosis. *Ophthalmology* 1982; 89: 953–960.
- Velazquez N, Jones IS. Ocular and oculodermal melanocytosis associated with uveal melanoma. *Ophthalmology* 1983; 90: 1472–1476.
- Biswas J, Shanmugam MP, Gopal L. Malignant melanoma of the choroid in association with oculodermal melanocytosis: a case report. *Indian J Ophthalmol* 1995; 43: 140–141.



57. Infante de German-Ribon R, Singh AD, Arevalo JF et al. Choroidal melanoma with oculodermal melanocytosis in Hispanic patients. *Am J Ophthalmol* 1999; 128: 251–253.
58. Nik NA, Glew WB, Zimmerman LE. Malignant melanoma of the choroid in the nevus of Ota of a black patient. *Arch Ophthalmol* 1982; 100: 1641–1643.
59. Singh AD, Shields CL, Shields JA, De Potter P. Bilateral primary uveal melanoma. Bad luck or bad genes? *Ophthalmology* 1996; 103: 256–262.
60. Pomeranz GA, Bunt AH, Kalina RE. Multifocal choroidal melanoma in ocular melanocytosis. *Arch Ophthalmol* 1981; 99: 857–863.
61. Rice CD, Brown HH. Primary orbital melanoma associated with orbital melanocytosis. *Arch Ophthalmol* 1990; 108: 1130–1134.
62. Sang DN, Albert DM, Sober AJ, McMeekin TO. Nevus of Ota with contralateral cerebral melanoma. *Arch Ophthalmol* 1977; 95: 1820–1824.
63. Howard GM, Forrest AW. Incidence and location of melanocytomas. *Arch Ophthalmol* 1967; 77: 61–66.
64. Lee JS, Smith RE, Minckler DS. Scleral melanocytoma. *Ophthalmology* 1982; 89: 178–182.
65. Verdaguer J, Valenzuela H, Strozzi L. Melanocytoma of the conjunctiva. *Arch Ophthalmol* 1974; 91: 363–366.
66. Zimmerman LE, Garron LK. Melanocytoma of the optic disc. *Int Ophthalmol Clin* 1962; 2: 431–440.
67. Cogan DG. Discussion – pigmented ocular tumors. In: Boniuk M, ed. *Ocular and adnexal tumors: new and controversial aspects*. St Louis: CV Mosby, 1964.
68. Reese AB. Congenital melanomas. *Am J Ophthalmol* 1974; 77: 789–808.
69. Reidy JJ, Apple DJ, Steinmetz RL et al. Melanocytoma: nomenclature, pathogenesis, natural history and treatment. *Surv Ophthalmol* 1985; 29: 319–327.
70. Juarez CP, Tso MO. An ultrastructural study of melanocytomas (magnocellular nevi) of the optic disk and uvea. *Am J Ophthalmol* 1980; 90: 48–62.
71. Shields JA, Demirci H, Mashayekhi A, Shields CL. Melanocytoma of optic disc in 115 cases: the 2004 Samuel Johnson Memorial Lecture, part 1. *Ophthalmology* 2004; 111: 1739–1746.
72. Brodsky MC, Phillips PH. Optic nerve hypoplasia and congenital hypopituitarism. *J Pediatr* 2000; 136: 850.
73. Loeffler KU, Tecklenborg H. Melanocytoma-like growth of a juxtapapillary malignant melanoma. *Retina* 1992; 12: 29–34.
74. Shields JA, Eagle RC Jr, Shields CL, De Potter P. Pigmented adenoma of the optic nerve head simulating a melanocytoma. *Ophthalmology* 1992; 99: 1705–1708.
75. Antcliff RJ, ffytche TJ, Shilling JS, Marshall J. Optical coherence tomography of melanocytoma. *Am J Ophthalmol* 2000; 130: 845–847.
76. Mansour AM, Zimmerman L, La Piana FG, Beauchamp GR. Clinicopathological findings in a growing optic nerve melanocytoma. *Br J Ophthalmol* 1989; 73: 410–415.
77. Apple DJ, Craythorn JM, Reidy JJ et al. Malignant transformation of an optic nerve melanocytoma. *Can J Ophthalmol* 1984; 19: 320–325.
78. Meyer D, Ge J, Blinder KJ et al. Malignant transformation of an optic disk melanocytoma. *Am J Ophthalmol* 1999; 127: 710–714.
79. Roth AM. Malignant change in melanocytomas of the uveal tract. *Surv Ophthalmol* 1978; 22: 404–412.
80. Demirci H, Mashayekhi A, Shields CL et al. Iris melanocytoma: clinical features and natural course in 47 cases. *Am J Ophthalmol* 2005; 139: 468–475.
81. Shields JA, Eagle RC Jr, Shields CL, Nelson LB. Progressive growth of an iris melanocytoma in a child. *Am J Ophthalmol* 2002; 133: 287–289.
82. Fineman MS, Eagle RC Jr, Shields JA et al. Melanocytomalytic glaucoma in eyes with necrotic iris melanocytoma. *Ophthalmology* 1998; 105: 492–496.
83. Teichmann KD, Karcioğlu ZA. Melanocytoma of the iris with rapidly developing secondary glaucoma. *Surv Ophthalmol* 1995; 40: 136–144.
84. Cialdini AP, Sahel JA, Jalkh AE et al. Malignant transformation of an iris melanocytoma. A case report. *Graefes Arch Clin Exp Ophthalmol* 1989; 27: 348–354.
85. LoRusso FJ, Boniuk M, Font RL. Melanocytoma (magnocellular nevus) of the ciliary body: report of 10 cases and review of the literature. *Ophthalmology* 2000; 107: 795–800.
86. Frangieh GT, el Baba F, Traboulsi EI, Green WR. Melanocytoma of the ciliary body: presentation of four cases and review of nineteen reports. *Surv Ophthalmol* 1985; 29: 328–334.
87. Mohamed MD, Gupta M, Parsons A, Rennie IG. Ultrasound biomicroscopy in the management of melanocytoma of the ciliary body with extrascleral extension. *Br J Ophthalmol* 2005; 89: 14–16.
88. Biswas J, D'Souza C, Shanmugam MP. Diffuse melanotic lesion of the iris as a presenting feature of ciliary body melanocytoma: report of a case and review of the literature. *Surv Ophthalmol* 1998; 42: 378–382.
89. Brownstein S, Dorey MW, Mathew B et al. Melanocytoma of the choroid: atypical presentation and review of the literature. *Can J Ophthalmol* 2002; 37: 247–252.
90. Lehman LJ, Hohberger GG, Buettner H, Campbell RJ. Necrotic melanocytoma of the choroid in a 2-year-old child. *J Pediatr Ophthalmol Strabismus* 1997; 34: 40–43.
91. Haas BD, Jakobiec FA, Iwamoto T et al. Diffuse choroidal melanocytoma in a child. A lesion extending the spectrum of melanocytic hamartomas. *Ophthalmology* 1986; 93: 1632–1638.
92. Shields JA, Font RL. Melanocytoma of the choroid clinically simulating a malignant melanoma. *Arch Ophthalmol* 1972; 87: 396–400.
93. Robertson DM, Campbell RJ, Salomao DR. Mushroom-shaped choroidal melanocytoma mimicking malignant melanoma. *Arch Ophthalmol* 2002; 120: 82–85.
94. Group COMS. Accuracy of diagnosis of choroidal melanomas in the Collaborative Ocular Melanoma Study. COMS report no. 1. *Arch Ophthalmol* 1990; 108: 1268–1273.
95. Kurli M, Finger PT, Manor T et al. Finding malignant change in a necrotic choroidal melanocytoma: a clinical challenge. *Br J Ophthalmol* 2005; 89: 921–922.
96. Shetler DJ, Folberg R, Gass JD. Choroidal malignant melanoma associated with a melanocytoma. *Retina* 1999; 19: 346–349.



# Uveal malignant melanoma: epidemiologic aspects

Arun D. Singh, Louise Bergman and Stefan Seregard

## INTRODUCTION

Approximately 5% of all melanomas arise in ocular and adnexal structures.<sup>1</sup> Most (85%) ocular melanomas are uveal in origin, whereas primary conjunctival and orbital melanomas are very rare.<sup>1,2</sup> Uveal melanoma is the most common primary intraocular malignant tumor.<sup>3</sup> In this chapter, the incidence of uveal melanoma and various etiological factors implicated in the pathogenesis of uveal melanoma are briefly outlined (Box 35.1).

## INCIDENCE

The reported incidence of uveal melanoma has ranged from 4.3 to 10.9 cases per million population because of variations in inclusion criteria, diagnostic criteria, and the methodology used in calculating the incidence rate. Both crude and age-standardized incidence rates have been published, along with different stratum weights in the standard populations chosen; therefore, these rates are not entirely comparable. In some studies uveal melanoma was included with melanoma of the conjunctiva and eyelids.<sup>4</sup> Some of the older studies have included only histopathologically confirmed cases. Because an increasing proportion of uveal melanomas are treated by radiotherapy or phototherapy, cases should be included in such statistics whether diagnosed clinically or histopathologically.<sup>2</sup> In a recent study from the United States, only diagnostic codes with uvea as the primary site (iris, ciliary body, and choroid) were considered and other ocular sites were excluded.<sup>2</sup> The overall mean incidence of uveal melanoma was 4.3 per million, with a higher rate in males (4.9 per million) than in females (3.7 per million). These data were derived from the Surveillance and Epidemiology and End Result (SEER) program of the National Institutes of Health (Maryland, USA).

**SEER Program** collects and provides reliable population-based incidence data for a wide variety of cancers in the United States, including uveal melanoma.<sup>5</sup> The SEER data are considered to be the 'gold standard' because of a high degree of ascertainment, quality, and completeness.<sup>6</sup> However, SEER data may be hampered in their ability to describe rarer malignancies, such as choroidal melanoma.<sup>7</sup> The greatest likelihood of underreporting is from non-hospital sources; however, this may not be applicable to choroidal melanoma, as most (98%) of cases of uveal melanoma are reported from the hospital-based sources.<sup>7</sup> A recent report based on data from the North American Association of Central Cancer Registries, which tabulated data on 62% of the US population (compared to SEER data, which cover about 16% of the population), reveals comparable incidence rates, thereby indi-

cating that SEER data are robust.<sup>7</sup> Lack of histologic confirmation in cases that are treated with radiotherapy or phototherapy<sup>1</sup> may contribute to underreporting.<sup>8</sup>

**Global incidence** The incidence of uveal melanoma has been reported in several countries (Table 35.1).<sup>2,9</sup> The incidence in the United States and European countries is similar to that in Australia<sup>10</sup> and New Zealand,<sup>11</sup> where the population is exposed to a higher intensity of ultraviolet light.

**Age- and sex-specific incidence** Uveal melanoma is more commonly seen in the older age group, with a progressively rising age-specific incidence rate, which peaks at the age of 70 years (24.5 per million in males and 17.8 per million in females) (Fig. 35.1).<sup>2</sup> Similar data regarding the age distribution have been reported from Sweden, although the peak incidence in females (26.5 cases per million) appeared a decade earlier than the peak incidence in the male population (36.6 per million).<sup>12</sup>

**Temporal stability** Unlike global trends indicating a rising incidence of cutaneous melanoma, the incidence of uveal melanoma has either remained stable or declined slightly over last several decades. In the United States between 1973 and 1977<sup>2</sup> – and even for 25 years prior to that – age-adjusted annual incidences were stable (Fig. 35.2).<sup>3</sup> In Sweden over the last four decades, for both males and females (11.7 to 8.4 per million and from 10.3 to 8.7 per million, respectively), a slight decline in the incidence was observed.<sup>12</sup>

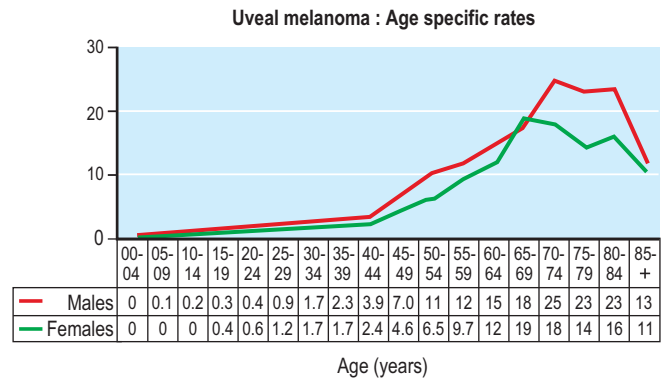
## ETIOLOGICAL FACTORS: HOST FACTORS

The etiology of uveal melanoma remains obscure.<sup>13</sup> Several host factors, such as race, association with choroidal nevi, and genetic predisposition, have been investigated. Various environmental factors such as sunlight exposure and occupational association have also been investigated in case-control studies.

**Race** Among the host factors, race seems to be the most significant, as uveal melanoma is about 150 times more common in whites than in blacks.<sup>13</sup> Among the white population in the United States, uveal melanoma occurs less frequently in Hispanic whites than in non-Hispanic whites.<sup>14</sup> This tumor is also less common in Asians.<sup>15</sup> Light skin color, blond hair, and blue eyes are also specific host risk factors. Nevertheless, the underlying basis of racial predisposition to uveal melanoma remains unknown.<sup>2</sup>

**BOX 35.1 Important Epidemiological Features of Uveal Melanoma**

- 5% of all melanomas arise from the ocular and adnexal structures
- 85% of ocular melanomas are uveal in origin
- The incidence of uveal melanoma in the United States is 4.3 per million (males 4.9 per million; females 3.7 per million)
- The incidence of uveal melanoma has remained stable for the last 50 years
- There are strong racial variations in the incidence, with white populations most commonly affected
- Clinical, epidemiological, physiological, and genetic evidence argues against a major role of UV light in the causation of uveal melanoma
- Oculo (dermal) melanocytosis predisposes to uveal melanoma



**Fig. 35.1** The age-adjusted incidence of uveal melanoma in the United States. (Modified with permission from Singh AD, Topham A. Incidence of uveal melanoma in the United States: 1973–1997. *Ophthalmology* 2003; 110: 956–961.)

**Table 35.1 Published reports on national incidence of uveal melanoma<sup>9</sup>**

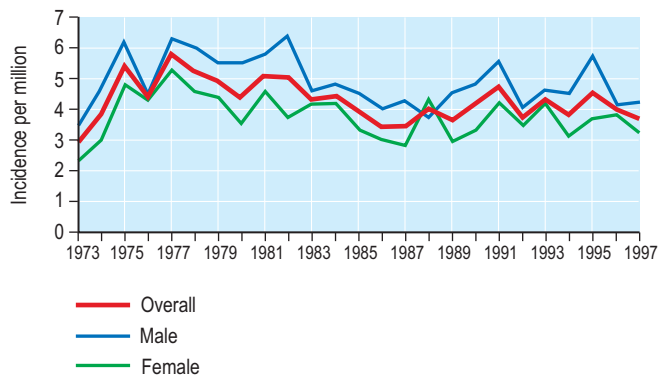
Author	Period	Country	Definition	No. of cases	Criteria	Incidence/million
Mork	1953–1960	Norway	Ocular melanoma	220	Histologic	9.0
Jensen	1943–1952	Denmark	Uveal melanoma	305	Histologic	7.4
Scotto	1969–1971	United States	Eye melanoma	341	Clinical	5.6
Raivio	1953–1973	Finland	Cbd + choroid	359	Histologic	5.3
Strickland	1950–1974	United States	Eye melanoma	–	–	9.0 (Male) 8.0 (Female)
Kaneko	1977–1979	Japan	Uveal melanoma	82	Histologic	0.3
Swerdlow	1962–1977	England (UK)	Ocular melanoma	4284	Clinical	7.2 (Male) 5.7 (Female)
Gislason	1955–1979	Iceland	Cbd + choroid	29	Histologic	7.0 (Male) 5.0 (Female)
Lommatzsch	1961–1980	East Germany	Eye melanoma		Clinical	10.0
Teikari	1973–1980	Finland	Cbd + choroid	382	Clinical	7.6
Iscovich	1961–1989	Israel	Cbd + choroid	502	Clinical	5.7 (Jews)
Vidal	1992	France	Uveal melanoma	412	Clinical	7.0
Bergman	1960–1998	Sweden	Uveal melanoma	2997	Clinical	9.4 (Male) 8.8 (Female)
Singh	1973–1997	United States	Uveal melanoma	2493	Clinical	4.9 (Male) 3.7 (Female)
Kricker	1996–1998	Australia	Choroidal melanoma	539	Clinical	11.0 (Male) 7.8 (Female)

Uveal melanoma, iris, ciliary body (Cbd), and choroidal melanoma; Eye melanoma, uveal and conjunctival melanoma; ocular melanoma, uveal, conjunctival, and eyelid melanoma. (Modified with permission from Singh AD, Topham A. Incidence of uveal melanoma in the United States: 1973–1997. *Ophthalmology* 2003; 110: 956–961)

**Choroidal nevi** There is clinical and histopathological evidence suggesting that choroidal melanomas arise from pre-existing choroidal nevi.<sup>16,17</sup> In addition, choroidal melanomas can arise de novo.<sup>18</sup> The prevalence of choroidal nevi in the white United States population ranges from 4.6% to 7.9%.<sup>19</sup> Assuming that all melanomas arise from pre-existing nevi, the estimated annual risk of malignant transformation of a choroidal nevus is about 1 in 8845.<sup>20</sup> The relationship

between choroidal nevus and melanoma is discussed elsewhere (see Chapter 34).

**Genetic predisposition** Uveal melanomas usually occur sporadically,<sup>13</sup> but there have been rare instances indicative of an inherited predisposition,<sup>21</sup> such as familial uveal melanoma, uveal melanoma in young individuals, bilateral primary uveal melanoma, and multifocal



**Fig. 35.2** The age-adjusted incidence of uveal melanoma in the United States between 1973 and 1977. (Modified with permission from Singh AD, Topham A. Incidence of uveal melanoma in the United States: 1973–1997. *Ophthalmology* 2003; 110: 956–961.)

**Table 35.2 Genetic subtypes of uveal melanoma<sup>21</sup>**

Clinical feature	Subtype
Familial occurrence	Familial uveal melanoma
Occurrence at an earlier age	Uveal melanoma in young individual
Bilateral involvement	Bilateral primary uveal melanoma
Multiple primary tumors	Multifocal primary uveal melanoma
Phenotypic associations	Oculo(dermal) melanocytosis
	Familial atypical mole and melanoma syndrome
	Cutaneous melanoma
	Neurofibromatosis type 1
	Li–Fraumeni syndrome

(Reproduced with permission from: Singh AD, Damato B, Howard P, Harbour JW. Uveal melanoma: genetic aspects. *Ophthalmol Clin North Am* 2005; 18: 85–97)

primary uveal melanoma.<sup>22</sup> Phenotypic associations of uveal melanoma include oculo(dermal) melanocytosis (ODM), familial atypical mole and melanoma (FAM-M) syndrome, neurofibromatosis type 1 (NF1), and Li–Fraumeni syndrome (Table 35.2).

**Familial uveal melanoma** Silcock<sup>23</sup> first reported the occurrence of uveal melanoma in a mother and two daughters. The occurrence of familial uveal melanoma is very rare, comprising only 0.6% of all uveal melanoma cases.<sup>24</sup> A review of published kindreds with familial uveal melanoma reveals that involvement over many generations, typical of autosomal dominant inheritance, is uncommon.<sup>24</sup> In most reported families only two relatives are affected. Familial cases of uveal melanoma lack other features suggestive of a genetic predisposition, such as earlier age at diagnosis, bilateral involvement, multiple primary tumors, and phenotypic associations.<sup>24,25</sup> Therefore, the possibility of two individuals in a given family developing uveal melanoma by chance alone (1 in 10 million) cannot be completely ignored.<sup>25,26</sup>

**Uveal melanoma in young individuals** Approximately 1% of all uveal melanomas occur in patients less than 20 years of age.<sup>27,28</sup> Most of the so-called pediatric uveal melanomas occur around

puberty,<sup>28</sup> although they can very rarely be present at birth.<sup>29</sup> In general, the clinical features and management of uveal melanoma in these young patients are similar to those of older adults. The data regarding systemic prognosis are limited, but suggest that the long-term prognosis is no worse than in adults, whereas the short-term prognosis may be better.<sup>28</sup>

Young patients with uveal melanoma may display associations with oculo(dermal) melanocytosis, which is nine times more frequent in such patients than in older adults.<sup>28,30</sup> An association of atypical cutaneous moles occurring in young individuals with uveal melanoma has also been reported.<sup>29,31</sup> Therefore, young patients with a uveal melanoma should be evaluated to exclude a genetic predisposition.

**Bilateral uveal melanoma** Primary uveal melanoma is rarely bilateral.<sup>32,33</sup> It has been estimated that only one such case will occur every 18 years in the United States.<sup>32</sup> Observations in the Swedish population suggest that such an occurrence may even be rarer than previously reported.<sup>34,35</sup> In a series of eight bilateral primary uveal melanoma patients analyzed for a genetic predisposition, there was no apparent clinical evidence to indicate an inherited cancer predisposition.<sup>33</sup> Bilateral ocular melanocytosis was thought to be contributory in two patients. Similar observations have also been made for multifocal uveal melanoma.<sup>36</sup>

Bilateral primary uveal melanoma should be distinguished from paraneoplastic melanocytic proliferations such as benign diffuse uveal melanocytic proliferation, which occurs in association with a systemic malignancy.<sup>37</sup>

#### Phenotypic associations

**OCULO(DERMAL) MELANOCYTOSIS** Features of ODM include a congenital hyperpigmentation of skin, episclera, uvea, orbit, and meninges.<sup>38</sup> Uveal melanoma is typically ipsilateral to the side of the ocular and dermal hyperpigmentation. It is estimated that about 1 in 400 Caucasian individuals with ODM followed for life will develop uveal melanoma.<sup>39</sup> Excessive melanocytes in the uveal tract of patients with ODM may provide the biologic basis for a susceptibility to the development of uveal melanoma.<sup>39</sup> Patients with ODM should be monitored ophthalmoscopically on an annual basis.

**FAMILIAL ATYPICAL MOLE AND MELANOMA SYNDROME** Atypical mole or dysplastic nevus denotes a specific clinicopathologic entity that is associated with an increased risk for the development of cutaneous melanoma.<sup>40</sup> The syndrome of autosomal dominant predisposition to cutaneous melanoma was originally described by Clark<sup>41</sup> as BK mole syndrome. Familial atypical mole and melanoma (FAM-M) syndrome is now the preferred terminology.<sup>42</sup> The National Institute of Health (Maryland, USA) consensus panel has defined FAM-M syndrome as the occurrence of a large number of atypical (often more than 50) cutaneous nevi that show certain distinct histologic features and cutaneous melanomas in one or more first- or second-degree relatives.<sup>42</sup>

Because cutaneous and uveal melanocytes share similar embryologic, morphologic, and antigenic properties, it is plausible that uveal melanoma may sometimes occur within the spectrum of a FAM-M syndrome. An increased number of uveal nevi and the occurrence of uveal melanoma in patients with FAM-M syndrome and their families support an association between FAM-M syndrome and uveal melanoma.<sup>22,43</sup> This concept is further supported by several case series and case–control studies (Table 35.3).<sup>22</sup> In a prospective study of 207 consecutive patients with ocular melanoma (uveal, conjunctival, and



**Table 35.3 Published case series of uveal melanoma with FAM–M syndrome<sup>21</sup>**

Author	Year	Study		Results/Conclusions
		Design	Method	
Greene	1984	Case series	2 families with uveal MM, cutaneous MM and dysplastic nevus syndrome	Coincidental
Taylor	1984	Prospective	44 uveal MM 46 non familial cutaneous MM	Equal prevalence of atypical moles
Vink	1990	Case series	5 families with atypical moles	2 uveal MM
Bataille	1993	Case series	207 ocular MM*	Excess of atypical moles and MM
Van Hees	1994	Case–control study	109 uveal MM 149 controls	Atypical moles in uveal MM (OR 2.9–5.1)
Bataille	1995	Case–control study	211 ocular MM* 416 controls	Excess of atypical moles in ocular MM (9%)
Singh	1995	Case series	8 cases of uveal MM	Coexisting atypical moles
Hammer	1996	Case–control study	75 uveal MM 86 cutaneous MM 143 controls	Excess of atypical moles (RR 4.4)
Richtig	2004	Case series	136 ocular MM*	Excess of atypical moles in ocular MM (35%)

\*Ocular melanoma includes uveal and conjunctival melanoma.  
MM, melanoma; OR, odds ratio; RR, relative risk.  
(Modified with permission from Singh AD, Damato B, Howard P, Harbour JW. Uveal melanoma: genetic aspects. *Ophthalmol Clin North Am* 2005; 18: 85–97)

eyelid melanoma) a greater than expected prevalence of cutaneous melanoma and FAM-M syndrome was observed.<sup>44</sup> Of the ocular melanoma patients, 9% had the FAM-M syndrome, compared to 1% in the control population.<sup>44</sup> A similar association between uveal melanoma and dysplastic nevi has also been observed, with an odds ratio ranging from 2.9 to 5.1.<sup>45</sup> Conversely, a lack of excessive uveal nevi in patients with FAM-M syndrome has also been reported,<sup>46</sup> suggesting that the coexistence of uveal melanoma and FAM-M syndrome may be coincidental.<sup>47</sup> Some of the discrepancy in the different studies might be attributed to differences in case selection, variations in the study populations, and a lack of uniform criteria used for the diagnosis of FAM-M syndrome. Moreover, CDKN2A mutations, which account for 50% of cases with FAM-M syndrome,<sup>48</sup> have not been observed in patients with uveal melanoma.<sup>49</sup> Although uveal and cutaneous melanomas can occur in the absence of FAM-M syndrome,<sup>50</sup> it would be prudent to exclude such a possibility.

**NEUROFIBROMATOSIS TYPE 1** As NF1 is a disorder of neural crest cells, and because uveal melanocytes are also of neural crest origin, one might suspect a possible association between NF1 and uveal melanoma.<sup>51</sup> Because of a high prevalence of neurofibromatosis type 1 (1 in 3000) in the general population, it is possible that the association between uveal melanoma and neurofibromatosis type 1 is coincidental.<sup>51,52</sup>

**LI–FRAUMENI SYNDROME** The presence of breast cancer in a family with uveal melanoma has led to the suspicion<sup>23</sup> that such patients may have an underlying Li–Fraumeni syndrome, an autosomal dominant cancer predisposition syndrome caused by a germline p53 mutation.<sup>53</sup> Although patients with familial uveal melanoma may have an increased likelihood of developing a second primary malignancy compared to the general population (see below), the occurrence of uveal melanoma

within an inherited cancer predisposition syndrome remains to be established.<sup>22</sup>

**SECOND MALIGNANT NEOPLASMS** Case–control studies have produced conflicting results with regard to the prevalence of second malignant neoplasms (SMN) in patients with primary uveal melanoma. Both increased prevalence<sup>54</sup> and non-significant differences<sup>55,56</sup> in the prevalence of SMN have been reported. Data from nationwide population-based registries reduce the bias of selection and referral. In the Swedish Cancer Registry, no significantly increased risk for SMN was found prior to the diagnosis of uveal melanoma (OR: 1.25 [95% CI: 0.98–1.59]).<sup>35</sup> However, the risk of subsequent SMN was increased by 13%. Specifically, the risk of developing skin melanoma after uveal melanoma was 1.75 times greater than that of the general population.<sup>35</sup> The 5- and 10-year cumulative second primary cancer rates (excluding basal cell carcinoma) in the two randomized trials of the Collaborative Ocular Melanoma Study did not differ significantly from the expected rate for the normal age-matched population.<sup>57</sup>

## ETIOLOGICAL FACTORS: ENVIRONMENTAL FACTORS

### Sunlight exposure

In contrast to cutaneous melanoma, evidence for sunlight exposure in the etiopathogenesis of uveal melanoma is at best weak.<sup>13,58,59</sup> Several case–control studies have attempted to explore the relationship of sunlight and the risk of developing uveal melanoma (Table 35.4).<sup>9</sup> Exposure to sunlight has been quantified by estimating the time spent outdoors,<sup>60</sup> tendency to sunburn,<sup>61</sup> and lifetime cumulative exposure to UV-B light.<sup>62</sup> In general, the results show either a weak positive correlation or lack any statistical significance. In addition, Vadjic<sup>62</sup> implicated sun exposure as a risk factor for melanoma in choroid and ciliary body melanoma, but not for tumors in the iris or conjunctiva, where there is greater exposure to sunlight.

Table 35.4 Summary of results from case-control studies on sunlight exposure in uveal melanoma<sup>9</sup>

Author	Region	Number of cases	Risk factors		
			Significant (relative risk)	Insignificant	
			<b>Positive correlation</b>	<b>Negative correlation</b>	
Gallagher	Western Provinces (Canada)	90	Red/blonde hair color (7.7) Indoor workers (3.5) Blue eyes (3.0) Born in South (2.7) Outdoors activity Sunbathing Use of sunlamps	Sunlight exposure Tanning ability	
Tucker	United States	444	Born in South (2.7) Outdoors activity Sunbathing Use of sunlamps Northern European ancestry (6.5) Light skin color (3.8) Use of sunlamps (3.4) Sun exposure (1.7) Welding burn/snow blindness (7.2) Light-colored eyes (2.5) Exposure to UV light (3.7) Tendency to sunburn (1.8)	Brown eyes (0.6) Complexion Hair color	
Seddon	New England (United States)	197	History of skin melanoma (2.42) Family history of ocular melanoma (6.89) Outdoor activity (1.8)*	Outdoor activity Born in south	
Holly	Western States (United States)	407	Dark skin color (0.72) Brown eyes (0.89) Resistance to sunburn (0.58) Wearing prescription glasses (0.78)		Wearing sunglasses Cumulative lifetime ocular UV-B exposure
Pane	Queensland (Australia)	125			
Vadjic	Australia	290			

\*Sun exposure was an independent risk factor for choroid and ciliary body melanoma, but not for iris or conjunctival melanomas. (Modified with permission from Singh AD, Bergman L, Seregard S. Uveal melanoma: epidemiologic aspects. *Ophthalmol Clin North Am* 2005; 18: 75–84)

**Table 35.5 Summary of results from case-control studies on sunlight exposure in uveal melanoma<sup>9</sup>**

Author	Region	Number of cases	Risk factors	
			Significant (relative risk)	Insignificant
Swerdlow	England and Wales (United Kingdom)	Not specified	Electrical and electronic workers Administrators and managers Technical workers Artists	
Gallagher	Western Provinces (Canada)	90	Indoor managerial workers (3.5)	Electrical and electronic workers
Vagero	England and Wales (United Kingdom)	662	Scientists Judges Teachers	
Ajani	New England (United States)	197	Agriculture work Farming work Machine operators	Industrial carcinogen
Vidal	France	412	No occupational risk factor	
Holly	Western States (United States)	447	Male chemists (5.9) Exposure to artificial UV light (3.0) Welding exposure (2.4) Asbestos exposure (2.2)	
Guenel	France	50	Exposure to artificial UV light Welders (7.3) Male cooks Female metal workers Materials handling operators	Outdoor workers

(Modified with permission from: Singh AD, Bergman L, Seregard S. Uveal melanoma: epidemiologic aspects. *Ophthalmol Clin North Am* 2005; 18: 75–84)

**Occupation** Although several case-control studies have evaluated occupation as a risk factor for uveal melanoma (Table 35.5), there is no consistent evidence indicating occupational exposure to UV light or other agents as a risk factor.<sup>13,58</sup> In an exploratory study, agriculture and farming work was associated with uveal melanoma, but specific exposure to a group of chemicals could not be clearly identified.<sup>63</sup> Studies from England and Canada have shown a significant excess of uveal melanoma cases in electrical workers, managers, technical workers, and other indoor workers such as scientists, judges, and teachers.<sup>58</sup>

The association of occupational exposure to artificial UV light remains questionable. In a French case-control study involving only 50 patients, an increased risk of uveal melanoma was reported in welders,<sup>64</sup> but in a larger study of 412 patients, also from France, no statistically significant association with any occupation could be identified.<sup>65</sup> Other case-control studies have also yielded conflicting results for occupational UV light exposure and the risk of uveal melanoma.<sup>61,63</sup> With regard to recreational UV exposure, some authors have suggested that the use of a sunlamp may be a significant risk determinant for uveal melanoma, but more studies are needed.<sup>60,66</sup>

## SUMMARY

Ocular and adnexal melanomas account for approximately 5% of all tumors of this type. Most ocular melanomas are uveal. The incidence of uveal melanoma in the United States is similar to that in European countries. The overall incidence of uveal melanoma in the United States is 4.3 per million, with a higher rate in males (4.9 per million) than in females (3.7 per million). The age-specific rate increases with age, peaking at the age of 70 years. The age-adjusted annual incidence rate of uveal melanoma in the United States has remained stable for the last 50 years. The etiology of uveal melanoma remains obscure, although several host and environmental factors have been investigated in case-control studies. Clinical, epidemiological, physiological, and genetic evidence argues against a major role of UV light in the causation of uveal melanoma.

## ACKNOWLEDGEMENT

This chapter was modified with permission from Singh AD, Bergman L, Seregard S. Uveal melanoma: epidemiologic aspects. *Ophthalmol Clin North Am* 2005; 18: 75–84.

## REFERENCES

- Chang AE, Karnell LH, Menck HR. The National Cancer Data Base report on cutaneous and noncutaneous melanoma: a summary of 84,836 cases from the past decade. The American College of Surgeons Commission on Cancer and the American Cancer Society. *Cancer* 1998; 83: 1664–1678.
- Singh AD, Topham A. Incidence of uveal melanoma in the United States: 1973–1997. *Ophthalmology* 2003; 110: 956–961.
- Strickland D, Lee JA. Melanomas of eye: stability of rates. *Am J Epidemiol* 1981; 113: 700–702.
- Scotto J, Fraumeni JF Jr, Lee JA. Melanomas of the eye and other noncutaneous sites: epidemiologic aspects. *J Natl Cancer Inst* 1976; 56: 489–491.
- Reis L, Eisner MP, Kosary CL et al. SEER Cancer Statistics Review, 1973–2000. Bethesda, MD: National Cancer Institute, 2003.



6. Barzilai DA, Koroukian SM, Neuhauser D et al. The sensitivity of Medicare data for identifying incident cases of invasive melanoma (United States). *Cancer Causes Control* 2004; 15: 179–184.
7. McLaughlin CC, Wu XC, Jamal A et al. Incidence of noncutaneous melanomas in the US. *Cancer* 2005; 103: 1000–1007.
8. Stang A, Jockel KH. Trends in the incidence of ocular melanoma in the United States, 1974–1998. *Cancer Causes Control* 2004; 15: 95–96.
9. Singh AD, Bergman L, Seregard S. Uveal melanoma: epidemiologic aspects. *Ophthalmol Clin North Am* 2005; 18: 75–84.
10. Vajdic CM, Krickler A, Giblin M et al. Incidence of ocular melanoma in Australia from 1990 to 1998. *Int J Cancer* 2003; 105: 117–122.
11. Michalova K, Clemett R, Dempster A et al. Iris melanomas: are they more frequent in New Zealand? *Br J Ophthalmol* 2001; 85: 4–5.
12. Bergman L, Seregard S, Nilsson B et al. Incidence of uveal melanoma in Sweden from 1960 to 1998. *Invest Ophthalmol Vis Sci* 2002; 43: 2579–2583.
13. Egan KM, Seddon JM, Glynn RJ et al. Epidemiologic aspects of uveal melanoma. *Surv Ophthalmol* 1988; 32: 239–251.
14. Hu DN, Yu GP, McCormick SA et al. Population-based incidence of uveal melanoma in various races and ethnic groups. *Am J Ophthalmol* 2005; 140: 612–617.
15. Kaneko A. Malignant ophthalmic tumors. *Nippon Rinsho* 1993; 51 Suppl: 1013–1020.
16. Naumann G, Yanoff M, Zimmerman LE. Histogenesis of malignant melanomas of the uvea. I. Histopathologic characteristics of nevi of the choroid and ciliary body. *Arch Ophthalmol* 1966; 76: 784–796.
17. Yanoff M, Zimmerman LE. Histogenesis of malignant melanomas of the uvea. II. Relationship of uveal nevi to malignant melanomas. *Cancer* 1967; 20: 493–507.
18. Sahel JA, Pesavento R, Frederick AR Jr, Albert DM. Melanoma arising de novo over a 16-month period. *Arch Ophthalmol* 1988; 106: 381–385.
19. Albert DM, Robinson NL, Fulton AB et al. Epidemiological investigation of increased incidence of choroidal melanoma in a single population of chemical workers. *Int Ophthalmol Clin* 1980; 20: 71–92.
20. Singh AD, Kalyani P, Topham B. Estimating the risk of malignant transformation of a choroidal nevus. *Ophthalmology* 2005; 112: 1784–1789.
21. Ponder BAJ. Inherited cancer syndromes. In: Carney D, Sikora K, eds. *Genes and cancer*. New York: John Wiley and Sons, 1990.
22. Singh AD, Damato B, Howard P, Harbour JW. Uveal melanoma: genetic aspects. *Ophthalmol Clin North Am* 2005; 18: 85–97.
23. Jay M, McCartney AC. Familial malignant melanoma of the uvea and p53: a Victorian detective story. *Surv Ophthalmol* 1993; 37: 457–462.
24. Singh AD, Donoso LA, Jackson L et al. Familial uveal melanoma: absence of constitutional cytogenetic abnormalities in 14 cases. *Arch Ophthalmol* 1996; 114: 502–503.
25. Singh AD, Demirci H, Shields CL et al. Concurrent choroidal melanoma in son and father. *Am J Ophthalmol* 2000; 130: 679–680.
26. Hadden PW, Damato BE. Simultaneous presentation of choroidal melanoma in mother and daughter. *Br J Ophthalmol* 2003; 87: 793–794.
27. Barr CC, McLean IW, Zimmerman LE. Uveal melanoma in children and adolescents. *Arch Ophthalmol* 1981; 99: 2133–2136.
28. Singh AD, Shields CL, Shields JA, Sato T. Uveal melanoma in young patients. *Arch Ophthalmol* 2000; 118: 918–923.
29. Greer CH. Congenital melanoma of the anterior uvea. *Arch Ophthalmol* 1966; 76: 77–78.
30. Verdaguer J Jr. Prepuberal and puberal melanomas in ophthalmology. *Am J Ophthalmol* 1965; 60: 1002–1011.
31. Singh AD, Shields JA, Eagle RC et al. Iris melanoma in a ten-year-old boy with familial atypical mole-melanoma (FAM-M) syndrome. *Ophthalm Genet* 1994; 15: 145–149.
32. Shammas HF, Watzke RC. Bilateral choroidal melanomas. Case report and incidence. *Arch Ophthalmol* 1977; 95: 617–623.
33. Singh AD, Shields CL, Shields JA, De Potter P. Bilateral primary uveal melanoma. Bad luck or bad genes? *Ophthalmology* 1996; 103: 256–262.
34. Seregard S, Daunius C, Kock E, Popovic V. Two cases of primary bilateral malignant melanoma of the choroid. *Br J Ophthalmol* 1988; 72: 244–245.
35. Bergman L, Nilsson B, Ragnarsson-Olding B, Seregard S. Uveal melanoma: A study on incidence of additional cancers in the Swedish population. *Invest Ophthalmol Vis Sci* 2005; 47: 72–77.
36. Honavar SG, Shields CL, Singh AD et al. Two discrete choroidal melanomas in an eye with ocular melanocytosis. *Surv Ophthalmol* 2002; 47: 36–41.
37. Singh AD, Rundle PA, Slater DN et al. Paraneoplastic melanocytic proliferation: uveal and cutaneous involvement. *Arch Ophthalmology* 2003; 121: 1637–1640.
38. Gonder JR, Shields JA, Albert DM et al. Uveal malignant melanoma associated with ocular and oculodermal melanocytosis. *Ophthalmology* 1982; 89: 953–960.
39. Singh AD, De Potter P, Fijal BA et al. Lifetime prevalence of uveal melanoma in white patients with ocular (dermal) melanocytosis. *Ophthalmology* 1998; 105: 195–198.
40. Salopek TG. The dilemma of the dysplastic nevus. *Dermatol Clin* 2002; 20: 617–628.
41. Clark Jr. WH, Reimer RR, Greene M et al. Origin of familial malignant melanomas from heritable melanocytic lesions: 'The B-K Mole syndrome'. *Arch Dermatol* 1978; 114: 732–738.
42. NIH. NIH Consensus conference. Diagnosis and treatment of early melanoma. *JAMA* 1992; 268: 1314–1319.
43. Singh AD, Shields CL, Shields JA et al. Uveal melanoma and familial atypical mole and melanoma (FAM-M) syndrome. *Ophthalm Genet* 1995; 16: 53–61.
44. Bataille V, Sasieni P, Cuzick J et al. Risk of ocular melanoma in relation to cutaneous and iris naevi. *Int J Cancer* 1995; 60: 622–626.
45. van Hees CL, de Boer A, Jager MJ et al. Are atypical nevi a risk factor for uveal melanoma? A case-control study. *J Invest Dermatol* 1994; 103: 202–205.
46. Seregard S, af Trampe E, Mansson-Brahme E et al. Prevalence of primary acquired melanosis and nevi of the conjunctiva and uvea in the dysplastic nevus syndrome. A case-control study. *Ophthalmology* 1995; 102: 1524–1529.
47. Greene MH, Sanders RJ, Chu FC et al. The familial occurrence of cutaneous melanoma, intraocular melanoma, and the dysplastic nevus syndrome. *Am J Ophthalmol* 1983; 96: 238–245.
48. de Snoo FA, Bergman W, Gruis NA. Familial melanoma: a complex disorder leading to controversy on DNA testing. *Fam Cancer* 2003; 2: 109–116.
49. Ohta M, Nagai H, Shimizu M et al. Rarity of somatic and germline mutations of the cyclin-dependent kinase 4 inhibitor gene, CDK4I, in melanoma. *Cancer Res* 1994; 54: 5269–5272.
50. Hurst EA, Harbour JW, Cornelius LA. Ocular melanoma: a review and the relationship to cutaneous melanoma. *Arch Dermatol* 2003; 139: 1067–1073.
51. Honavar SG, Singh AD, Shields CL et al. Iris melanoma in a patient with neurofibromatosis. *Surv Ophthalmol* 2000; 45: 231–236.
52. Foster WJ, Fuller CE, Perry A, Harbour JW. Status of the NF1 tumor suppressor locus in uveal melanoma. *Arch Ophthalmol* 2003; 121: 1311–1315.
53. Li FP, Fraumeni JF, Mulvihill JJ et al. A cancer family syndrome in twenty-four kindreds. *Cancer Res* 1988; 48: 5358–5362.
54. Turner BJ, Siatkowski RM, Augsburger JJ et al. Other cancers in uveal melanoma patients and their families. *Am J Ophthalmol* 1989; 107: 601–608.
55. Lischko AM, Seddon JM, Gragoudas ES et al. Evaluation of prior primary malignancy as a determinant of uveal melanoma. A case-control study. *Ophthalmology* 1989; 96: 1716–1721.
56. Holly EA, Aston DA, Ahn DK et al. No excess prior cancer in patients with uveal melanoma. *Ophthalmology* 1991; 98: 608–611.
57. Diener-West M, Reynolds SM, Agugliaro DJ et al. Second primary cancers after enrollment in the COMS trials for treatment of choroidal melanoma: COMS Report No. 25. *Arch Ophthalmol* 2005; 123: 601–604.
58. Singh AD, Rennie IG, Seregard S et al. Sunlight exposure and pathogenesis of uveal melanoma. *Surv Ophthalmol* 2004; 49: 419–428.
59. Shah CP, Weis E, Lajous M et al. Intermittent and chronic ultraviolet light exposure and uveal melanoma: a meta-analysis. *Ophthalmology* 2005; 112: 1599–1607.
60. Seddon JM, Gragoudas ES, Glynn RJ et al. Host factors, UV radiation, and risk of uveal melanoma. A case-control study. *Arch Ophthalmol* 1990; 108: 1274–1280.
61. Holly EA, Aston DA, Ahn DK, Smith AH. Intraocular melanoma linked to occupations and chemical exposures. *Epidemiology* 1996; 7: 55–61.
62. Vajdic CM, Krickler A, Giblin M et al. Sun exposure predicts risk of ocular melanoma in Australia. *Int J Cancer* 2002; 101: 175–182.
63. Ajani UA, Seddon JM, Hsieh CC et al. Occupation and risk of uveal melanoma. An exploratory study. *Cancer* 1992; 70: 2891–2900.
64. Guenel P, Laforest L, Cyr D et al. Occupational risk factors, ultraviolet radiation, and ocular melanoma: a case-control study in France. *Cancer Causes Control* 2001; 12: 451–459.
65. Vidal JL, Bacin F, Albuissou E et al. 'Melanoma 92.' An epidemiological study of uveal melanoma in France. *J Fr Ophtalmol* 1995; 18: 520–528.
66. Tucker MA, Shields JA, Hartge P et al. Sunlight exposure as risk factor for intraocular malignant melanoma. *N Engl J Med* 1985; 313: 789–792.

# Uveal malignant melanoma: clinical features

Leonidas Zografos

## INTRODUCTION

The presentation of uveal melanoma is mostly influenced by the site of origin (iris, ciliary body, or choroidal), size, pigmentation, extent of secondary changes, and any associated extrascleral extension, hemorrhage or inflammation.

## IRIS MELANOMA

Iris melanoma may be circumscribed or diffuse. Slit lamp examination, gonioscopy, and ultrasound biomicroscopy (UBM) allow staging of the tumor to guide the most appropriate treatment (Box 36.1).<sup>1</sup>

**Circumscribed iris melanoma** has a nodular shape with variable pigmentation (Fig. 36.1). Iris melanoma tends to arise in the inferior half of the iris. It often has an irregular or rarely a smooth surface, covered by a surface plaque. In lightly pigmented tumors the vessels are often visible.<sup>2,3</sup>

**Growth patterns** Iris melanoma can grow anteriorly into the anterior chamber, posteriorly towards the posterior chamber, or in both directions. Iris melanoma involving the anterior chamber angle can subsequently invade the ciliary body, either locally or diffusely. In such cases gonioscopy and UBM should be performed to examine the entire circumference of the ciliary body before making any treatment decisions. Posterior extension is limited by the lens, giving a flat, lion's-paw appearance on UBM examination.

**Complications** Circumscribed iris melanomas can lead to anterior chamber hemorrhage, cataract, and, more rarely, corneal decompensation, with edema and band keratopathy.<sup>4</sup> Tumor progression can also sometimes be complicated by glaucoma, which can be secondary to invasion of the anterior chamber angle by the tumor, tumor necrosis with the accumulation of melanomacrophages in the anterior chamber angle, or mechanical angle closure due to displacement of the lens.

**Diffuse iris melanoma** can develop in two ways. The first consists of primary infiltration of the iris stroma.<sup>5</sup> The iris is thickened, without any obvious nodule formation, and such growth is often associated with heterogeneous pigmentation and a deformed pupil. The intraocular pressure is usually increased as a result of invasion of the anterior chamber angle. The second mechanism consists of seeding of tumor cells from a circumscribed iris or ciliary body melanoma.<sup>6</sup> This phenomenon is often associated with progressive iris discolor-

ation, with disappearance of the iris crypts and the accumulation of pigment in the anterior chamber angle.

In either case, the onset of acquired hyperchromic heterochromia with ipsilateral secondary glaucoma should raise suspicion of a diffuse iris melanoma. The delay in diagnosis is usual, as these patients are initially treated for glaucoma.

**Growth pattern** Disseminated tumor cells accumulate predominantly in the inferior anterior chamber angle. On gonioscopy (Fig. 36.2) this sedimentation typically has a brown, felty appearance, which distinguishes it from clumps of fine, dusty pigment observed in some cases of necrotic melanocytoma.

**Complications** The resulting glaucoma responds poorly to medical therapies and tends to cause severe glaucomatous disc cupping and functional loss.<sup>7</sup> Diffuse iris melanoma tends to be of epithelioid cell type, with a higher risk of metastasis than the circumscribed variety.<sup>8</sup>

## CILIARY BODY MELANOMA

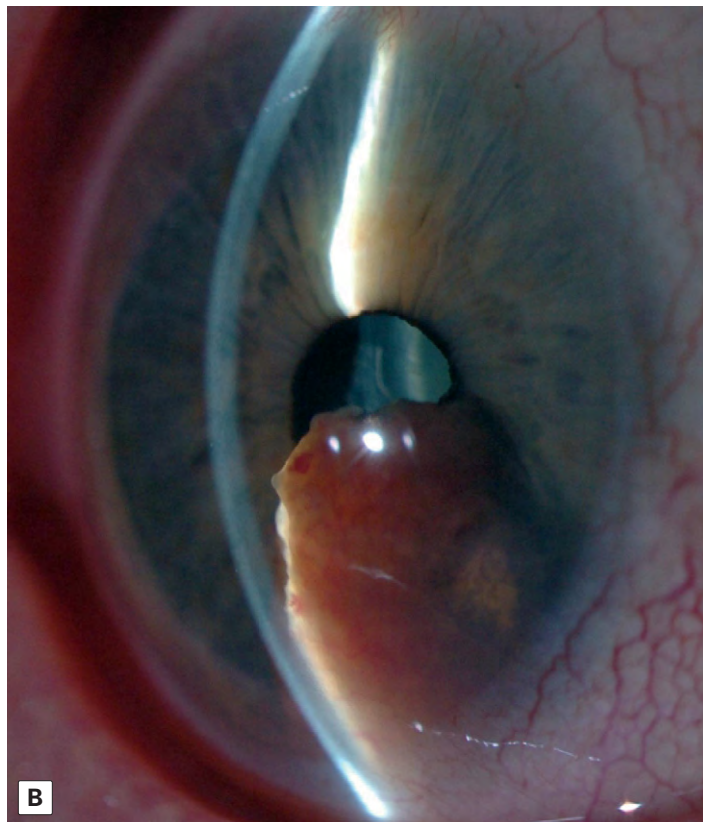
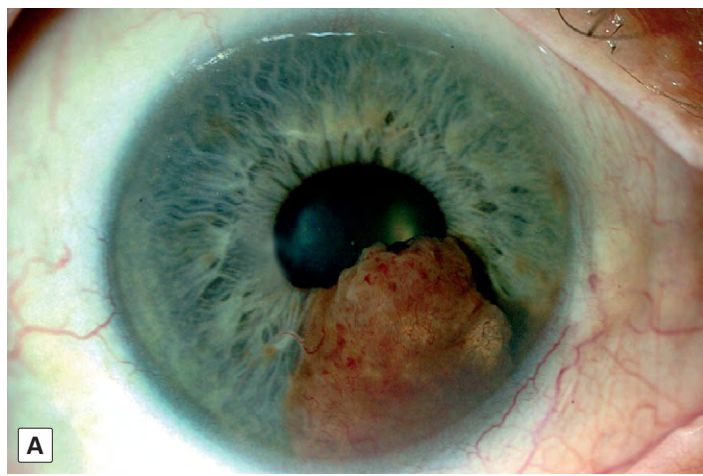
Ciliary body melanoma may be circumscribed or annular (ring). Slit lamp examination, gonioscopy, transillumination, and ultrasound biomicroscopy (UBM) allows staging of the tumor to guide the most appropriate treatment (see Box 36.1).<sup>1</sup>

**Circumscribed ciliary body melanoma** has a nodular shape and at the time of diagnosis are generally larger than iris melanomas. In the early stages these tumors are confined to the ciliary body and are consequently asymptomatic. They are generally brown, corresponding to the color of the overlying pigmented epithelium, unless this has been invaded by the tumor, in which case the true color of the tumor is visible. On UBM they may have a homogeneous or heterogeneous structure, and sometimes appear cavitated (Fig. 36.3).

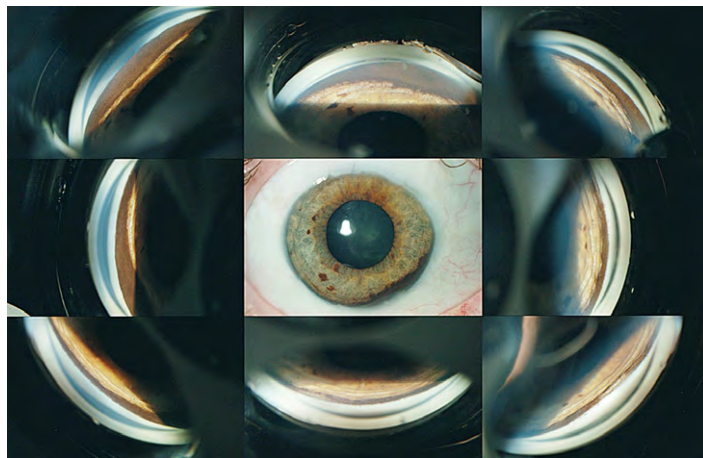
**Growth pattern** Ciliary body melanomas displace or infiltrate the root of the iris and invade the anterior chamber, where they become visible. At this stage they can seed cells throughout the anterior chamber, onto the surface of the iris and into the anterior chamber angle, causing elevated intraocular pressure. Melanomas can also spread around the ciliary body in an annular fashion, and this growth pattern must be excluded in every case by UBM.

**BOX 36.1 Clinical Features of Iridociliary Melanomas**

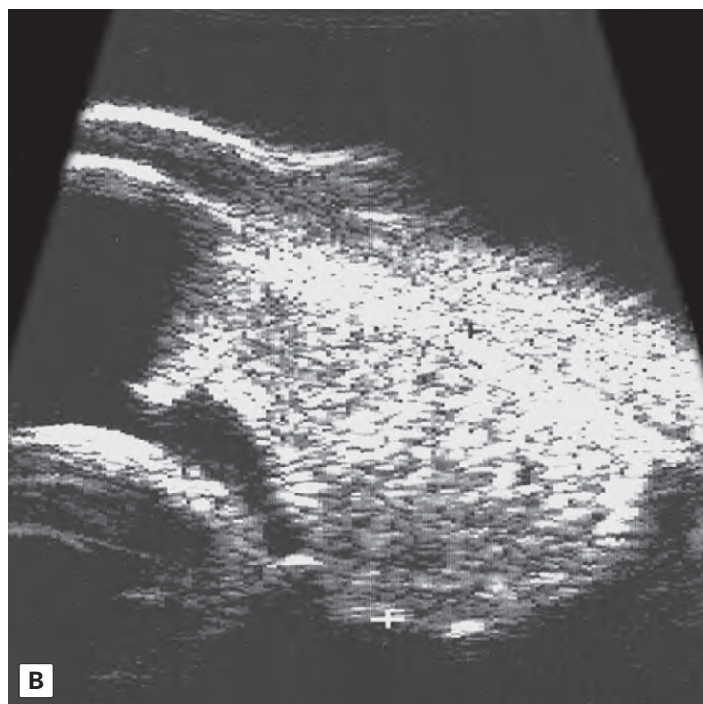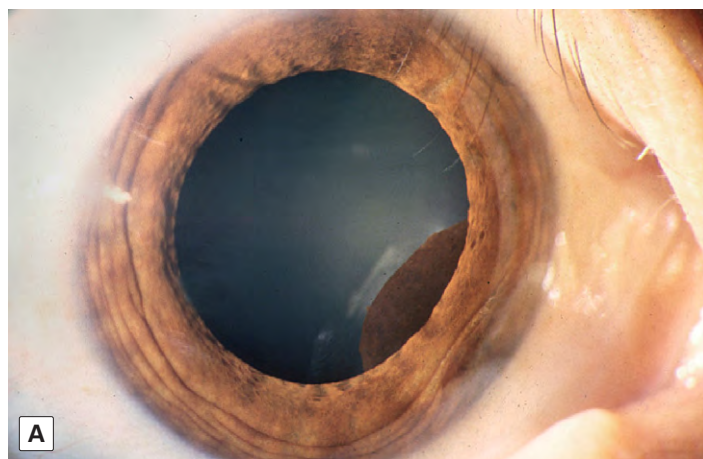
- Circumscribed or diffuse
- Secondary glaucoma, cataract, keratopathy, and hyphema
- Annular growth
- Seeding of cells in anterior chamber



**Fig. 36.1** Circumscribed iris melanoma.



**Fig. 36.2** Diffuse iris melanoma associated with an annular ciliary body melanoma. Clinical and gonioscopic images.



**Fig. 36.3** Circumscribed ciliary body melanoma. (A) Clinical appearance. (B) 20 MHz immersion ultrasonograph.



**Complications** In addition to glaucoma, ciliary body melanoma, as it becomes thicker, gradually compresses the lens equator, causing sectoral opacities and subsequent loss of visual acuity. At more advanced stages, lens subluxation or dislocation may occur.

**Annular (ring) ciliary body melanoma** evades early ophthalmic detection until it has grown substantially. There is usually more than 180° of circumferential ciliary body extension and disproportionately less anteroposterior growth. In some cases there is circumferential growth in the trabecular meshwork, with relative sparing of the ciliary body and iris. Such a variant is classified as ‘ring melanoma of the anterior chamber angle.’<sup>9</sup>

The presence of sentinel vessels, sectoral iris neovascularization, sectoral cataract, localized shallowing of the anterior chamber, and unexplained iridocyclitis should raise the suspicion of circumferential (ring) ciliary body melanoma.<sup>10</sup> Detailed evaluation with slit lamp examination, gonioscopy, transillumination, and UBM is necessary to establish the diagnosis and guide the most appropriate treatment.

## CHOROIDAL MELANOMA

According to various statistical series, 80–90% of uveal melanomas arise in the posterior uvea. The clinical features of choroidal melanomas are varied and multiple symptoms tend to occur sequentially (Box 36.2).

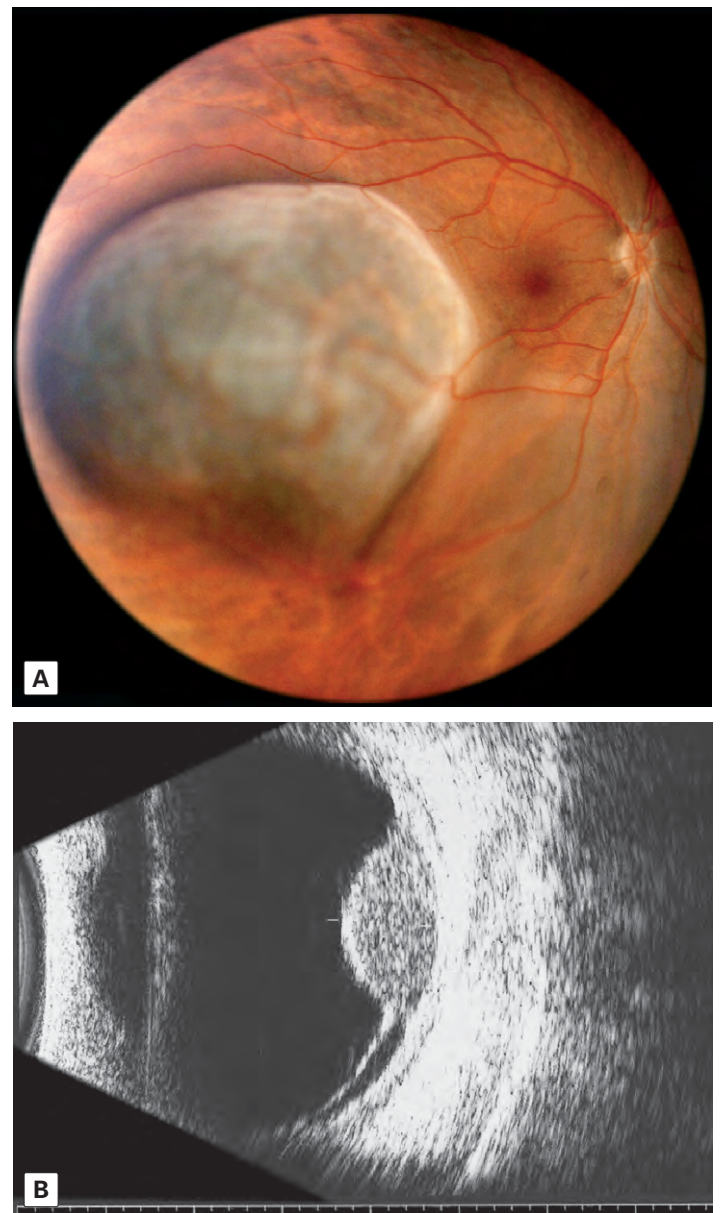
**Symptoms** Most patients complain of decreased visual acuity or an impression of blurred vision. They frequently (10–30% of cases) report photopsia, scotomata, floaters, metamorphopsia, or micropsia, and, rarely (1–9% of cases), xanthopsia, pain, ocular inflammation, lacrimation, oscillopsia, loss of stereoscopic vision and, exceptionally (<1% of cases), monocular diplopia, visual fatigue, decreased sensitivity to light, loss of colour vision, photophobia, hypermetropia, or hemeralopia.<sup>11</sup> About 10% of cases are asymptomatic, usually corresponding to small or medium-sized tumors situated close to the equator, discovered incidentally on routine ocular fundus examination, such as after cataract surgery.

**Size and shape** The axial growth of the tumor is contained by the sclera and the tumor therefore protrudes into the vitreous cavity. Small and medium-sized tumors that are still contained by an intact Bruch’s membrane are dome shaped, with a thickness equal to about half their diameter (Fig. 36.4). If Bruch’s membrane ruptures at the apex of the tumor, the melanoma has a mushroom or collar-button shape (Fig. 36.5). On the other hand, when Bruch’s membrane is ruptured at the rim of the tumor, the tumor develops an irregular and inclined shape.

In some cases, multiple ruptures of Bruch’s membrane give rise to several subretinal neoplastic ‘hernias.’

Having perforated Bruch’s membrane, the tumor can also invade the retina and extend into the vitreous cavity, forming a sphere known as a Knapp–Roone tumor.<sup>12</sup> This tends to have a dark color and a finely granular surface, and may be complicated by seeding of pigmented cells into the vitreous, and sometimes by massive vitreous hemorrhage.

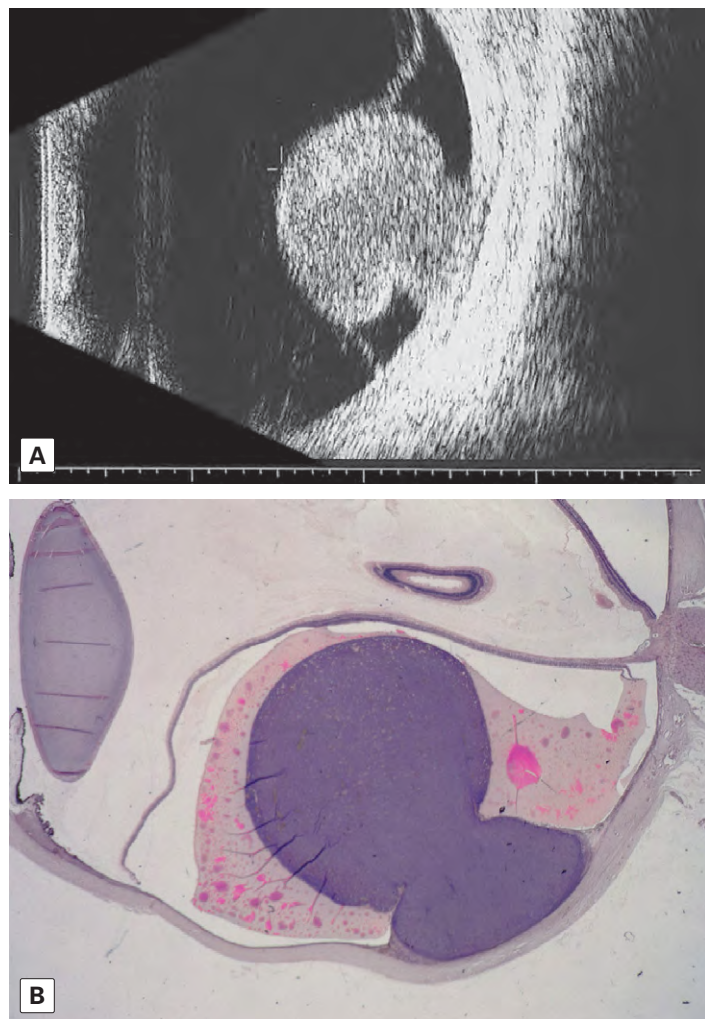
Diffuse melanoma<sup>13,14</sup> constitutes a particular, infiltrative form of flat or slightly raised melanoma with predominantly horizontal growth. It was defined by Reese and Howard<sup>15</sup> as a tumor whose surface area exceeds one-quarter of the choroidal surface area, and whose thickness does not exceed 5 mm (Fig. 36.6). Diffuse melanoma has a crenated margin imitating pseudopodia, with an irregular surface and heterogeneous pigmentation. It tends to develop extrascleral extension and can also induce glaucoma if it invades the anterior segment.



**Fig. 36.4** Dome-shaped melanoma. (A) Clinical appearance. (B) Ultrasonograph.

### BOX 36.2 Clinical Features of Choroidal Melanomas

- Visual symptoms in most patients
- Dome, mushroom, or diffuse configuration
- Variable pigmentation
- Posterior extension in many cases
- Abnormal RPE over tumor
- Extraocular extension
- Glaucoma and inflammation in rare cases



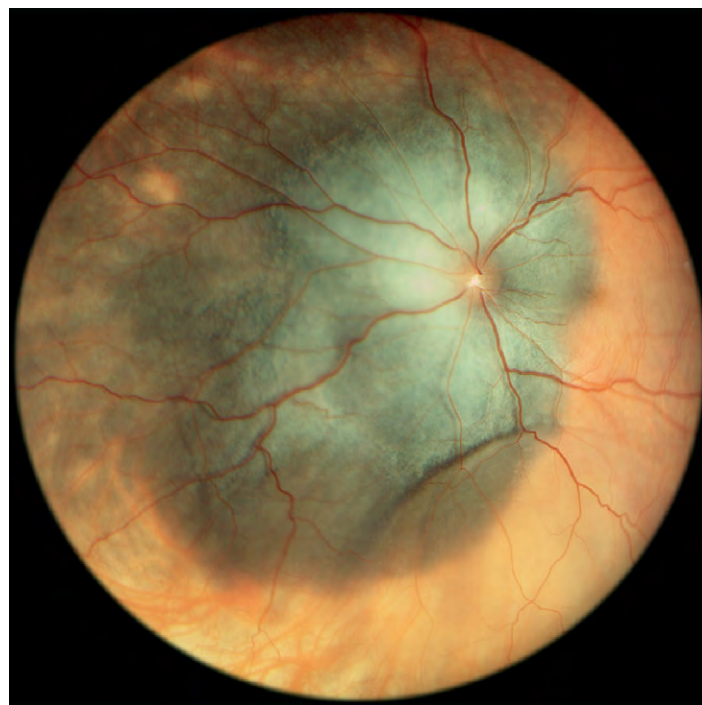**Fig. 36.5** Mushroom-shaped melanoma. **(A)** Ultrasonograph of a mushroom-shaped melanoma with rupture of Bruch's membrane at the apex of the tumor. **(B)** Histopathological image of a mushroom-shaped melanoma with eccentric rupture of Bruch's membrane, inducing an irregular mushroom shape.

**Pigmentation** Melanoma is usually gray or greenish-brown, but the color can range from dark brown to white. Tumor pigmentation is sometimes heterogeneous. Amelanotic melanoma must be distinguished from solitary metastases. Melanoma invading the ciliary body invariably has a chocolate brown color on slit lamp examination, independent of the pigmentation of the tumor. This uniform color is due to the pigment epithelium covering the tumor.

**Site of origin** Very large melanomas often involve all three components of the uvea (choroid, ciliary body, and iris). The precise origin of a tumor can therefore be clearly identified only in the case of a relatively small tumor localized in one part of the uveal tract. However, the tumor is often small at the time of diagnosis. In contrast, tumors situated in the anterior choroid, if not discovered incidentally, are often very large by the time they eventually become symptomatic.

**Variants** Some melanomas are distinguished by particular sites, giving rise to typical clinical features:

- **Small peripapillary melanoma.** When Bruch's membrane is intact a tumor in this location can sometimes encircle the optic disc.



**Fig. 36.6** Diffuse choroidal melanoma.

Increased tumor thickness can lead to rupture of Bruch's membrane at the edge of the disc, resulting in a tumor nodule covering the disc. This type of tumor has an appearance similar to melanocytoma of the optic disc.

- **Multifocal melanoma.** These are rare, with only about 20 published cases so far (see Chapter 34).<sup>11</sup>
- **Bilateral melanoma.** About 50 cases have been published so far (see Chapter 35).<sup>11</sup>

**Alterations of the retina** Choroidal melanoma is almost always accompanied by a secondary exudative retinal detachment. This gradually spreads from the tumor surface to the inferior periphery and macular region. The retinal surface is generally smooth, and subretinal fluid may be clear or cloudy. In the sitting position the detachment occupies the inferior periphery, and in the supine position it shifts towards the posterior pole while raising the macula, accounting for the loss of visual acuity, which is more pronounced on getting out of bed and in the morning. In some cases pigmented cells accumulate in the subretinal fluid, outlining the edges of the retinal detachment. These cells are mainly pigment-laden macrophages, sometimes mixed with tumor cells. The accumulation of pigmented cells in the macular region can lead to a central scotoma associated with a peripheral melanoma.<sup>16</sup> The melanoma associated with this type of complication has an epithelioid or necrotic histological appearance, with poor cellular cohesion. Disseminated pigmented cells may also be observed in the vitreous cavity when the retina is invaded, or when the tumor is situated in the ciliary body.

**Alterations of the retinal pigment epithelium** The retinal pigment epithelium undergoes alterations over the surface of a melanoma, regardless of tumor size. Histological examination shows areas of necrosis and atrophy of pigment epithelial cells, as well as signs of



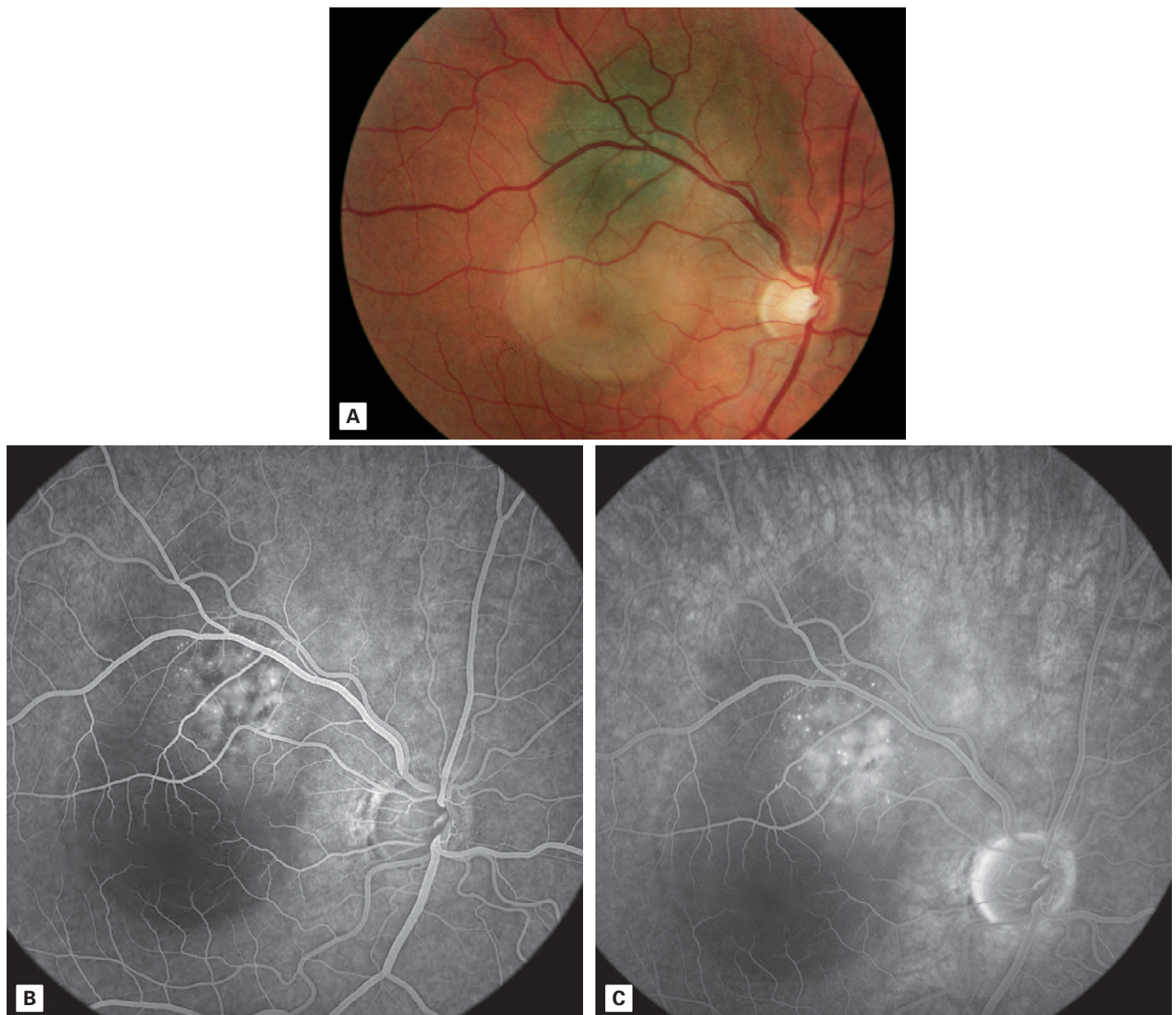
migration, hyperplasia, multilayering, and metaplasia. Small melanomas frequently show confluent orange pigment (Fig. 36.7). On histological examination the orange pigment corresponds to clumps of macrophages containing lipofuscin and melanin derived from retinal pigment epithelial cells.<sup>17,18</sup> The presence of orange pigment on the surface of a small or medium-sized tumor is highly suggestive of melanoma,<sup>19</sup> but can also be observed less frequently at the apex of other choroidal tumors, especially nevi.<sup>20,21</sup>

**Intraocular pressure** About 3% of uveal melanomas are associated with secondary glaucoma at the time of diagnosis.<sup>22</sup> The usual mechanisms responsible for elevated intraocular pressure are tumor invasion of the anterior chamber angle, and iris neovascularization. Rarely, glaucoma is secondary to anterior displacement of the lens-iris diaphragm, because of the large volume and anterior location of the tumor. Melanomas that invade the ciliary body can sometimes induce a relative decrease in intraocular pressure, probably by dis-

turbing the aqueous-producing function of the non-pigmented ciliary epithelium.

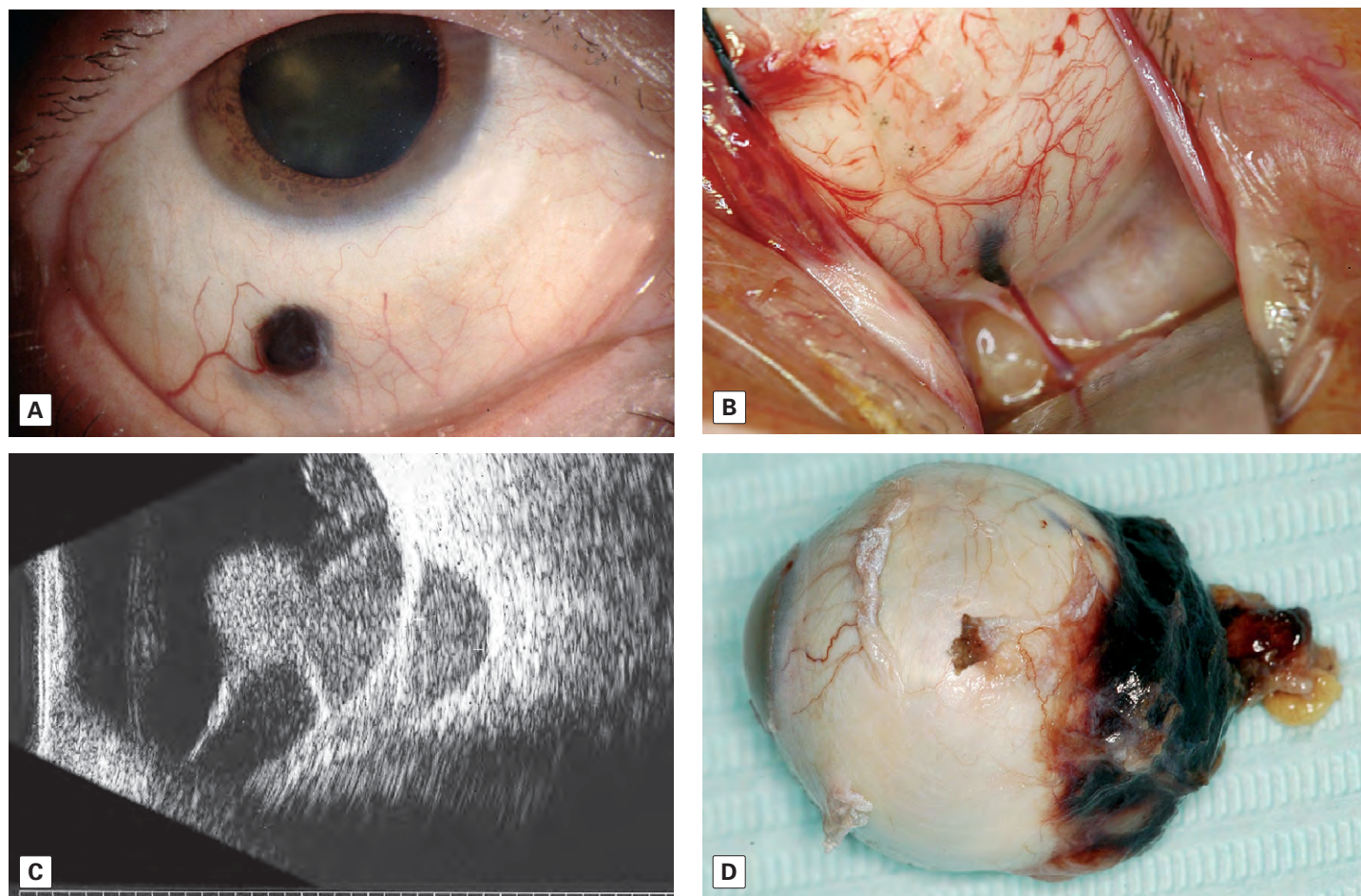
**Inflammatory reaction** A very large melanoma is often accompanied by a moderate inflammatory reaction, the severity of which is correlated with the thickness of the tumor, the extent of the secondary exudative retinal detachment, and the presence of necrosis, leukocyte infiltration, and hemorrhage.<sup>23,24</sup> In some cases the inflammatory reaction can lead to posterior synechiae, resulting in pupillary block. Exceptionally, the inflammatory reaction can present as scleritis or episcleritis,<sup>25</sup> endophthalmitis,<sup>26</sup> or orbital cellulitis.<sup>27</sup>

**Extrascleral extension** The sclera presents a considerable resistance to tumor expansion. The tumor often erodes the scleral wall, but only rarely perforates the wall of the eye. However, the sclera is traversed by many nerves and vessels, along which tumor cells tend to spread to reach the episclera and orbit.



**Fig. 36.7** Small melanoma with orange pigment associated with serous retinal detachment in the macular region. (A) Ophthalmoscopic appearance. (B) Fluorescein angiography. The orange pigment blocks fluorescence in the early sequences. (C) Fluorescein leakage with pinpoints in late sequences.





**Fig. 36.8** Extrasceral extension of the tumor. (A) Anterior extrascleral extension. (B) Tumor invasion of a vortex vein, intraoperative image. (C) Large posterior extrascleral extension, ultrasonograph. (D) Diffuse posterior extrascleral extension, macroscopic image.

**Anterior extension** Melanomas situated in the ciliary body usually spread via scleral channels for aqueous veins and anterior ciliary arteries, giving rise to single or multiple tumor nodules, situated slightly behind the sclerocorneal limbus. These are sometimes associated with sentinel vessels (Fig. 36. 8A).

**Posterior extension** Posterior uveal melanoma spreads via the vortex veins (Fig. 36. 8B) and posterior ciliary arteries, usually forming small nodular lesions adherent to the scleral wall. The extraocular tumor can be nodular (Fig. 36.8C) or diffuse (Fig. 36.8D). As the intra- and extraocular parts of the tumor do not grow at the same rate, the extraocular tumor can sometimes be larger than the intraocular portion.

**Optic nerve invasion** Invasion of the optic disc and optic nerve by the tumor is rare. It is generally secondary to a large peripapillary tumor and is often associated with elevated intraocular pressure, a tumor of epithelioid cell type, and areas of necrosis. However, ciliary body tumors can also lead to optic disc and optic nerve invasion as a result of dissemination of tumor cells into the vitreous cavity. This type of retinoinvasive extension, described by Kivelä and Summanen,<sup>28</sup> has been reported in a limited number of cases. Optic nerve invasion is generally limited to the portion of the nerve close to the posterior scleral wall. However, tumor progression along the nerve towards the orbital apex and the optic chiasm has been rarely described.<sup>29</sup> Absence of light perception should raise suspicion of optic nerve invasion by a tumor situated in contact with the optic disc.

## REFERENCES

- Zografos L, Uffer S. Tumeurs iriennes pigmentées. In: Zografos L, ed. Tumeurs intraoculaires. Paris: Masson, 2002; 281–313.
- Arentsen JJ, Green WR. Melanoma of the iris: report of 72 cases treated surgically. *Ophthalm Surg* 1975; 6: 23–37.
- Shields CL, Shields JA, Materin M et al. Iris melanoma: risk factors for metastasis in 169 consecutive patients. *Ophthalmology* 2001; 108: 172–178.
- Shah PG, Shields CL, Shields JA et al. Band keratopathy secondary to an iris melanoma. *Cornea* 1991; 10: 67–69.
- Brown D, Boniuk M, Font RL. Diffuse malignant melanoma of iris with metastases. *Surv Ophthalmol* 1990; 34: 357–364.
- Char DH, Crawford JB, Gonzales J et al. Iris melanoma with increased intraocular pressure. Differentiation of focal solitary tumors from diffuse or multiple tumors. *Arch Ophthalmol* 1989; 107: 548–551.
- Jakobiec FA, Silbert G. Are most iris ‘melanomas’ really nevi? A clinicopathologic study of 189 lesions. *Arch Ophthalmol* 1981; 99: 2117–2132.
- Demirci H, Shields CL, Shields JA, Eagle RC Jr, Honavar SG. Diffuse iris melanoma: a report of 25 cases. *Ophthalmology* 2002; 109: 1553–1560.
- Demirci H, Shields CL, Shields JA, Eagle RC Jr, Honavar S. Ring melanoma of the anterior chamber angle: a report of fourteen cases. *Am J Ophthalmol* 2001; 132: 336–342.

10. Demirci H, Shields CL, Shields JA, Honavar SG, Eagle RC Jr. Ring melanoma of the ciliary body: report on twenty-three patients. *Retina* 2002; 22: 698–706.
11. Zografos L. Présentation clinique des mélanomes de la choroïde et du corps ciliaire. In: Zografos L, ed. *Tumeurs intraoculaires*. Paris: Masson, 2002; 120–152.
12. Jensen OA. The ‘Knapp–Ronne’ type of malignant melanoma of the choroid. A haemangioma-like melanoma with a typical clinical picture. So-called ‘preretinal malignant choroidal melanoma.’ *Acta Ophthalmol (Copenh)* 1976; 54: 41–54.
13. Shields CL, Shields JA, De Potter P et al. Diffuse choroidal melanoma. Clinical features predictive of metastasis. *Arch Ophthalmol* 1996; 114: 956–963.
14. Font RL, Spaulding AG, Zimmerman LE. Diffuse malignant melanoma of the uveal tract: a clinicopathologic report of 54 cases. *Trans Am Acad Ophthalmol Otolaryngol* 1968; 72: 877–895.
15. Reese AB, Howard GM. Flat uveal melanomas. *Am J Ophthalmol* 1967; 64: 1021–1028.
16. Kok-van Alphen C, Hagedoorn A. Peripheral melanoblastoma of choroid: (para)central scotoma as an initial sign. *Am J Ophthalmol* 1960; 49: 1406–1408.
17. Font RL, Zimmerman LE, Armaly MF. The nature of the orange pigment over a choroidal melanoma. Histochemical and electron microscopical observations. *Arch Ophthalmol* 1974; 91: 359–362.
18. Shields JA, Rodrigues MM, Sarin LK et al. Lipofuscin pigment over benign and malignant choroidal tumors. *Trans Sect Ophthalmol Am Acad Ophthalmol Otolaryngol* 1976; 81: 871–881.
19. Smith LT, Irvine AR. Diagnostic significance of orange pigment accumulation over choroidal tumors. *Am J Ophthalmol* 1973; 76: 212–216.
20. Butler P, Char DH, Zarbin M et al. Natural history of indeterminate pigmented choroidal tumors. *Ophthalmology* 1994; 101: 710–716.
21. Shields CL, Shields JA, Kiratli H et al. Risk factors for growth and metastasis of small choroidal melanocytic lesions. *Ophthalmology* 1995; 102: 1351–1361.
22. Shields CL, Shields JA, Yarian DL et al. Intracranial extension of choroidal melanoma via the optic nerve. *Br J Ophthalmol* 1987; 71: 172–176.
23. Kuchle M, Nguyen NX, Naumann GO. Quantitative assessment of the blood–aqueous barrier in human eyes with malignant or benign uveal tumors. *Am J Ophthalmol* 1994; 117: 521–528.
24. Castella AP, Bercher L, Zografos L et al. Study of the blood–aqueous barrier in choroidal melanoma. *Br J Ophthalmol* 1995; 79: 354–357.
25. Yap EY, Robertson DM, Buettner H. Scleritis as an initial manifestation of choroidal malignant melanoma. *Ophthalmology* 1992; 99: 1693–1697.
26. Bujara K. Necrotic malignant melanomas of the choroid and ciliary body. A clinicopathological and statistical study. *Graefes Arch Clin Exp Ophthalmol* 1982; 219: 40–43.
27. Biswas J, Ahuja VK, Shanmugam MP et al. Malignant melanoma of the choroid presenting as orbital cellulitis: report of two cases with a review of the literature. *Orbit* 1999; 18: 123–130.
28. Kivela T, Summanen P. Retinoinvasive malignant melanoma of the uvea. *Br J Ophthalmol* 1997; 81: 691–697.
29. Shields CL, Shields JA, Shields MB et al. Prevalence and mechanisms of secondary intraocular pressure elevation in eyes with intraocular tumors. *Ophthalmology* 1987; 94: 839–846.

# Uveal malignant melanoma: differential diagnosis

Devron H. Char

## INTRODUCTION

Making the correct diagnosis in a patient with a possible uveal tumor can be difficult. Historically, 20% of eyes that were removed with a clinical diagnosis of a uveal melanoma contained a simulating lesion on histologic examination.<sup>1</sup> In patients with choroidal lesions the diagnostic error rate, using modern diagnostic modalities, should be less than 1%. In anterior tumors involving the ciliary body and iris there is a higher diagnostic error rate, and in some series it still approaches 40%.<sup>2-4</sup> Because choroidal lesions are much more frequent than those involving either the iris or ciliary body, they are discussed first.

Although newer imaging techniques, including optical coherence tomography (OCT), high-resolution MR, positron emission tomography (PET) scans, and combination CT/PET scans have been very helpful in many body sites, their accuracy at differentiating uveal tumors and delineating their margins remains inferior to most purely ophthalmic diagnostic techniques.

## CHOROIDAL MELANOMA

The mean age of diagnosis of uveal melanoma in the United States is approximately 60 years. Most of these are Caucasian patients who present with a painless tumor, which may have some visual symptoms if the lesion is either large enough to distort the optic nerve or fovea, produce sufficient exudative detachment to diminish vision, or, more rarely, to produce cataract, inflammation, or vitreous hemorrhage. An abbreviated differential diagnosis for choroidal tumors is given in Table 37.1.

### Diagnostic features

**Past history and demographics** Several clinical findings are suspicious for a simulating, non-malignant choroidal lesion (Box 37.1). These include patients under age 20 (less than 2% of uveal melanomas), non-white race, and a recent history of an open intraocular procedure such as cataract extraction or glaucoma filtering (a localized subretinal hemorrhagic process), a lesion associated with severe eye pain (scleritis), and a recent history of a visceral malignancy (metastases).

**Location** Approximately two-thirds of choroidal melanomas come within 3 mm of the optic nerve or the fovea.<sup>5</sup>

**Color** Choroidal melanoma can be amelanotic in 30% of cases and various degrees of pigmentation can be present, although it is extra-

ordinarily rare for melanomas to be black. A blackish lesion is more likely to be a hemorrhage, an RPE proliferation, or a melanocytoma.<sup>6</sup>

**Number** Multiple tumors in one eye or bilateral involvement are suggestive of metastases and inflammation rather than choroidal melanoma.

**Configuration** A ‘collar button’ configuration that occurs when a melanoma breaks through Bruch’s membrane (generally tumors over 5 mm in thickness) is almost pathognomonic for choroidal melanoma (Fig. 37.1).

**Vitreous hemorrhage** Vitreous hemorrhage is extremely uncommon in association with melanomas, and almost always occurs when a tumor is thick enough to break through Bruch’s membrane and rupture a retinal vessel in the process. Vitreous hemorrhage associated with an ultrasonographically demonstrable mass under 4 mm thick is much more likely to be due to an extramacular disciform process.

**Ancillary studies** As choroidal melanomas grow they produce an intrinsic tumor circulation, which is visible with fluorescein (Fig. 37.2A). These tumors have a typical ultrasound pattern on both B-scan (Fig. 37.2B) and A-scan (Fig. 37.2C). On B-scan they have internal homogeneity, choroidal excavation, and orbital shadowing. On A-scan there is medium to low reflectivity with a straight posterior climbing scleral spike.<sup>7-11</sup> Although non-invasive techniques can be quite accurate in obvious melanomas, as demonstrated in the COMS study, in atypical large lesions with opaque media or smaller tumors, the diagnostic accuracy of non-invasive techniques can be as low as 90% (see Chapter 85).<sup>12-14</sup>

### Differential diagnosis

**Choroidal nevus** The differentiation of a small choroidal melanoma from a benign, pigmented, atypical choroidal nevus can be challenging.<sup>15</sup> Choroidal nevi are usually flat, less than 6 mm in diameter (<1/2 the aerial diameter of a 20D Nikon lens), and may have overlying drusen and a surrounding hypopigmentation. Much less commonly nevi can be amelanotic, but unlike a small choroidal metastasis these lesions are not associated with exudative detachment. In indeterminate pigmented lesions (1.5–3.0 mm thick and <10.0 mm in diameter), a group we labeled with the neologism ‘choroidal nevoma,’ the differentiation between a small melanoma and a nevus can be more challenging. In most ophthalmic oncology centers the evaluation of



**Table 37.1 Lesions that simulate choroidal melanoma****Choroidal neoplasms**

Choroidal nevus  
 Choroidal metastasis  
 Choroidal hemangioma  
 Choroidal osteoma  
 Choroidal neurilemmoma  
 Choroidal neurofibroma  
 Peripheral melanocytoma  
 Benign lymphoid tumor  
 Choroidal hemangiopericytoma  
 Choroidal leiomyoma

**Hemorrhagic processes**

Involucional macular degeneration  
 Extramacular disciform lesion  
 Ruptured arteriolar macroaneurysm  
 Localized choroidal detachment/hemorrhage

**Retinal pigment epithelial processes**

Retinal pigment epithelial hyperplasia  
 Retinal pigment epithelial hypertrophy  
 Retinal pigment epithelial adenocarcinoma

**Inflammatory processes**

Posterior scleritis  
 Posterior uveitis

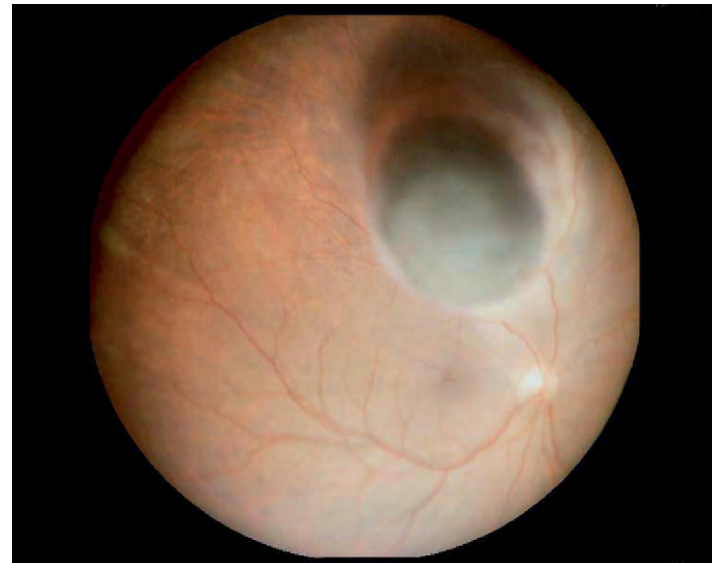
**Miscellaneous**

Hemorrhagic retinal detachment  
 Retinoschisis with hemorrhage  
 Staphyloma  
 Intraocular foreign body granuloma  
 Massive retinal gliosis  
 Acquired retinal hemangioma  
 Retinal glioma

**BOX 37.1 Clinical Features not Suggestive of Choroidal Melanoma**

- Age < 20 years
- Recent intraocular procedure
- Black tumor
- Multiple tumors
- Vitreous hemorrhage associated with a small tumor

patients with a possible choroidal neoplasm includes the standard ophthalmologic evaluation, fluorescein angiography, and ultrasonography. Pigmented choroidal lesions under 3.0 mm thick and less than 10.0 mm in diameter not associated with loss of vision are generally followed with serial examinations. Signs suggestive of possible transformation into a choroidal melanoma are hot spots on fluorescein angiography, exudative detachment (clinically or on OCT), demonstrable growth on serial examination, orange pigment overlying the lesion (lipofuscin), and homogeneity on ultrasound. Unfortunately, in a number of choroidal pigmented tumors 1.5–3.0 mm thick it may be impossible to differentiate clearly between a benign atypical nevoid



**Fig. 37.1** Clinical photograph of a collar-button or mushroom-shaped lesion, which is almost pathognomonic for melanoma.

lesion and an early melanoma. Fortunately, serial observation of such low-risk lesions is safe.<sup>16</sup> Lesions over 3.0 mm thick that are typical for choroidal melanoma on clinical, fluorescein, and ultrasonographic criteria are generally treated immediately in the appropriate manner for a primary choroidal melanoma. In atypical lesions of that size fine needle aspiration biopsy is useful, and this is discussed in Chapter 56.

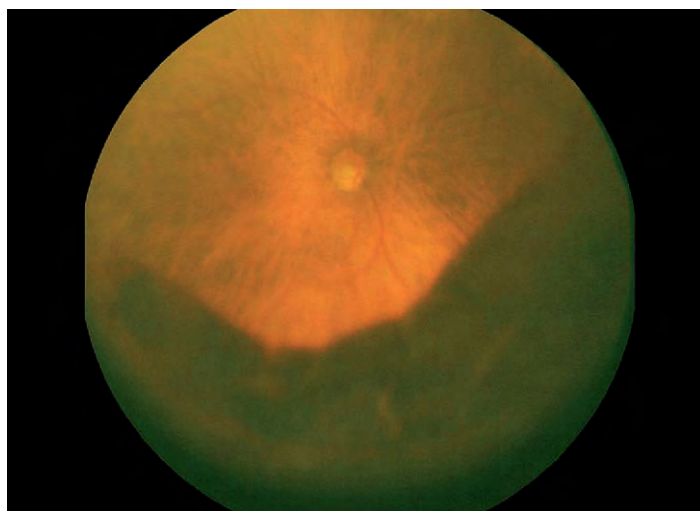
**Hemorrhage** Several hemorrhagic processes can simulate a melanoma, including age-related macular disciform (AMD), extramacular disciform (EMD), subretinal hemorrhage, or an arterial macroaneurysm (Fig. 37.3).<sup>17</sup> Most of these patients have a history of hypertension, macular alteration in the other eye (in the case of an EMD or AMD), or recent intraocular surgery (localized subretinal hemorrhage). Fluorescein angiography can be helpful in differentiating these lesions from melanomas, in that these hemorrhagic processes usually just show blockage from the blood, whereas melanomas have intrinsic vasculature and leakage.

**Choroidal hemangioma** is a benign simulating lesion (Fig. 37.4).<sup>13</sup> Clinically, on fluorescein angiography, ICG, and ultrasound the pattern is characteristic. Clinically these are orangey red-colored lesions. We have seen a number of cases without subretinal fluid, but most are detected when they become symptomatic due to an associated exudative detachment that reduces vision. On fluorescein angiography and indocyanine angiography there is very early fluorescence prior to the arterial venous phase of the angiogram, and delayed washout phenomenon. On ultrasonography a typical pattern is described.<sup>2</sup> Choroidal hemangioma can be diagnosed with 100% accuracy using non-invasive techniques.

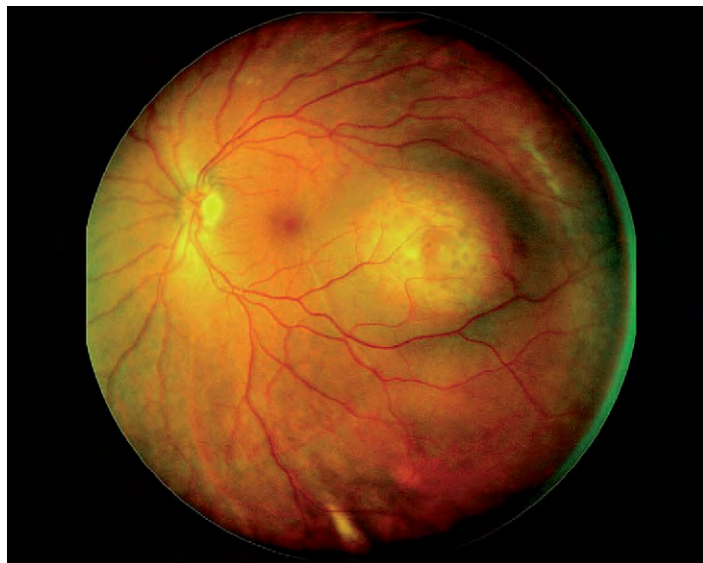**Choroidal metastases** can present prior to the discovery of the primary neoplasm in between 10% and 90% of cases, depending on histology.<sup>18–20</sup> In less than 10% of patients with breast carcinoma the patient will present with an ophthalmic lesion before the discovery of the primary malignancy. In contrast, with renal cell carcinoma as many as 90% of patients will first have an eye lesion and then the primary cancer will be discovered.

Rights were not granted to include this figure in electronic media.  
Please refer to the printed publication.

**Fig. 37.2** (A) Tumor angiogenesis produces an independent tumor circulation as uveal melanomas grow. Initially the earliest signs suggestive of a melanoma on fluorescein angiography are hot spots, which are points of fluorescence that increases in size during the study. (B) On B-scan uveal melanomas have a choroidal acoustic quiet zone in the center of the tumor (\*), choroidal excavation (arrow), and orbital shadowing (o), as shown. (Reproduced with permission from Char DH. Tumors of the eye and ocular adnexa. New York: BC Decker, 2001; 124.) (C) On A-scan the tumor has low to medium reflectivity. On the performance of the scan, the ultrasonographer can see vascular pulsations. The posterior wall is a straight up-and-down spike, unlike a metastasis, for which it typically shows a 'climbing' pattern. (Reproduced with permission from Char DH. Tumors of the eye and ocular adnexa. New York: BC Decker, 2001; 124.)



**Fig. 37.3** Subchoroidal hemorrhage referred as a melanoma. On fluorescein angiography this completely blocks fluorescence.

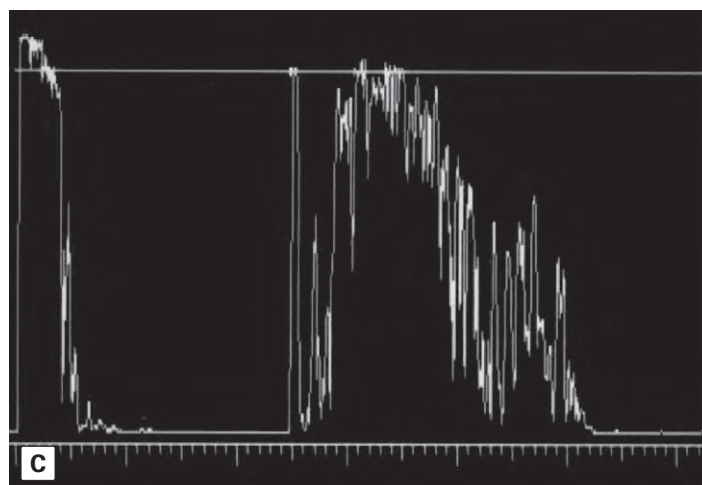
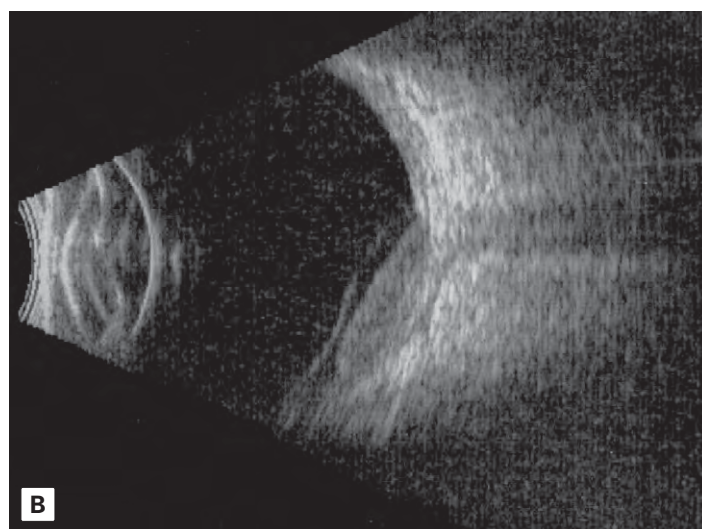
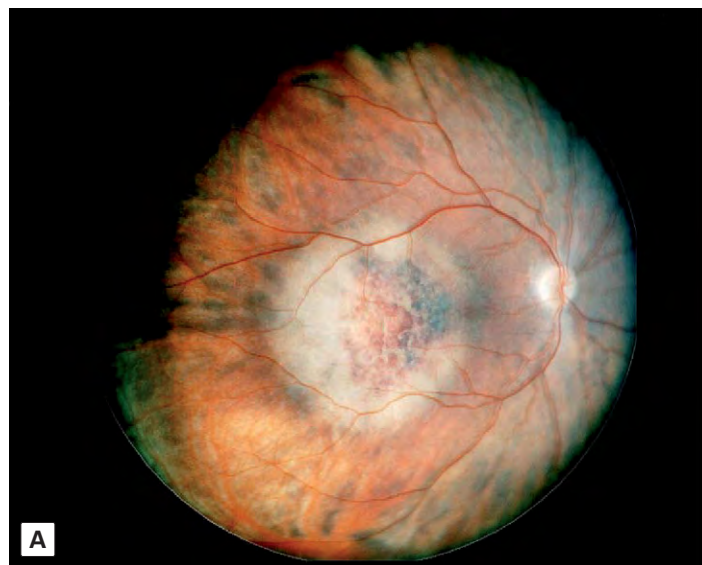


**Fig. 37.4** Choroidal hemangiomas have an orange-red color and typical fluorescein, ICG, and ultrasound patterns.

Choroidal metastases, because they are spread hematogenously, usually occur in the posterior pole (Fig. 37.5A). In approximately 20% of cases they are either multiple in one eye or there is bilateral involvement. They are amelanotic and almost never produce a collar button-shaped configuration. As approximately 10% of patients with choroidal melanomas are old enough to have had another primary malignancy, the subjective finding of a history of a malignancy is not *prima facie* proof that the lesion in the eye is a metastatic deposit. The fluorescein pattern is usually not diagnostic, but ultrasound often can be.<sup>21-24</sup> Unlike choroidal melanoma, ultrasonography of a metastatic lesion shows no choroidal excavation, acoustic quiet zone, or orbital shadowing (Fig. 37.5B). On A-scan the lesion has medium to high reflectivity with a climbing posterior spike (Fig. 37.5C). Useful ancillary serologic tests include plasma CEA, CA125, PSA, etc. When the diagnosis is uncertain, intraocular fine needle biopsy is diagnostic and may provide important ancillary information, such as estrogen or progesterone receptor status in breast metastases (see Chapter 56).

**Melanocytoma** can simulate a melanoma on clinical, fluorescein, and ultrasonographic criteria<sup>25</sup> (Fig. 37.6) As shown in Chapter 56, we have seen a number of very thick melanocytomas that would have been treated as uveal melanomas based on other diagnostic criteria; we demonstrated benign pigment cell proliferation on fine needle aspiration biopsy and long-term follow-up.

**RPE tumors** Congenital hypertrophy of retinal pigment epithelium (CHRPE) in the periphery can occasionally be mistaken for a uveal melanoma (Fig. 37.7). In a peripheral location it is often difficult for the inexperienced ophthalmologist performing indirect ophthalmoscopy to distinguish whether a deeply pigmented tumor that is in sharp contrast to the normal surrounding uveal tract is or is not elevated. Typically these tumors have very sharp margins that can be scalloped and can develop lacunae. Over time they can lose their intrinsic pigmentation. RPE hyperplastic lesions secondary to various insults have deep black pigmentation, but usually, despite having sharply defined margins, they are somewhat jagged and less regular; lacunae do not occur. These RPE lesions remain stationary on serial examinations. RPE



**Fig. 37.5** (A) Choroidal metastases usually involve the posterior pole, are amelanotic, and almost never produce a collar button-shaped mass. (B) On B-scan of the choroidal metastasis there is no acoustic quiet zone, no choroidal excavation, and no orbital shadowing. (C) On A-scan there is medium to high reflectivity with coarse spikes and a climbing posterior spike.



adenomas and RPE carcinomas are much less common. Small RPE adenomas may have almost a 'mini collar button-like' appearance, with a feeder vessel to and from the lesion. RPE carcinomas can simulate a uveal melanoma and are only diagnosed either with fine needle aspiration biopsy or on standard histology.

**Scleritis** may or may not produce intense pain and inflammatory signs. Often with scleritis there is exudative detachment, and if the eye is red and painful the diagnosis is usually obvious. In a painless posterior scleritis the clinical signs may be less obvious. There may be some choroidal striate present or some exudative fluid, but the lesion can nicely simulate a uveal melanoma. On ultrasound there is often fluid in sub-Tenon's space, as well as inflammatory changes in the sclera, and these findings can also be documented with either CT or MRI.

Scleritis can be a benign idiopathic inflammatory process or it can be a manifestation of a localized intraocular or periocular lymphoma.<sup>26,27</sup> It can rarely occur as a manifestation of uveal melanoma,<sup>28</sup>

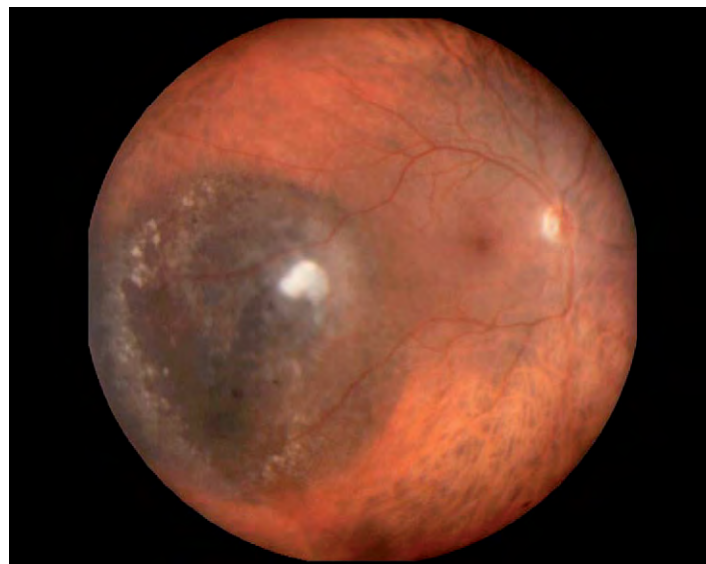

Fig. 37.6 Fine needle aspiration biopsy diagnosed melanocytoma.

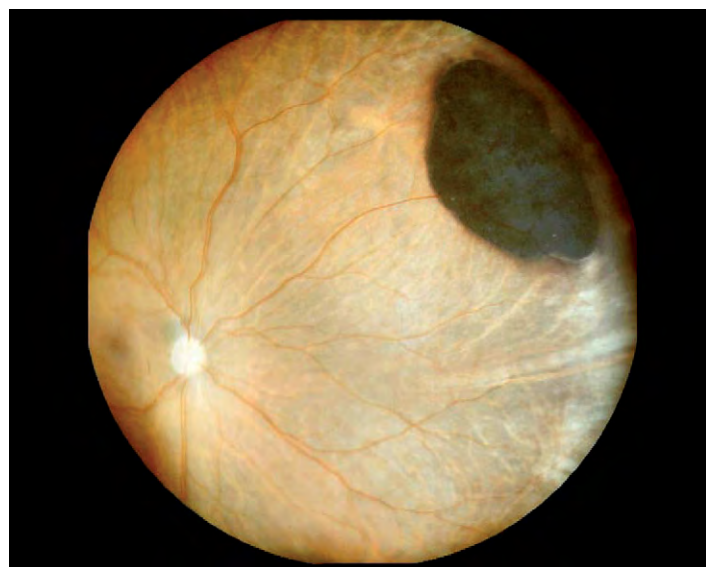

Fig. 37.7 Congenital RPE hypertrophy can simulate a melanoma, but is flat.

and even less frequently can also occur in association with either a metastasis or another cause of systemic inflammation, such as Wegener's granulomatosis.<sup>29</sup>

**Other tumors/lesions** There are a number of other, much less common simulating lesions that are only diagnosed by either cytopathology or histologic examination, and are not discussed in detail here. As an example, although choroidal osteomas are of interest, their classic appearance on ancillary tests should never be mistaken for a melanoma, given their flat, amelanotic nature and the intraocular calcification noted on imaging.

### IRIS, CILIARY BODY, AND CILIOCHOROIDAL TUMORS

Common entities in the differential diagnosis of iris and ciliary body tumors are listed in Table 37.2. Cystic lesions, inflammatory processes, foreign bodies, and benign and malignant neoplasms can simulate iris melanomas.<sup>30–33</sup> Iris melanomas occur with between one-sixth and 1/20th of the frequency of choroidal and ciliary body tumors.<sup>2,34</sup> Their peak incidence is 10–20 years younger than choroidal melanoma patients, and most are detected because of an incidental finding or a cosmetic change. They can produce visual loss from astigmatism or cataract.

Table 37.2 Differential diagnosis of iris and ciliary body tumors

#### Iris tumors

- Iris nevi
- Iris melanoma
- Iris metastases
- Cogan–Reese
- Essential iris atrophy
- Variant of ICE syndrome
- Central iris atrophy
- Iris stromal cyst
- Posterior pigment cyst
- Forward extension of a uveal melanoma to involve the iris
- Iris foreign body
- Amyloid
- JXG
- Sarcoid
- Leiomyoma
- Melanocytoma
- Lymphoma

#### Ciliary body tumors

- Staphyloma
- Leiomyoma
- Mesoectodermal leiomyoma
- Medulloepithelioma
- Melanoma
- Metastasis
- Scleritis
- Lymphoma
- Amyloid
- Plasmacytoma

**Diagnostic features** Iris melanomas have several clinical characteristics. Uniformly, they disrupt the anterior stromal layer of the iris. Often they will produce new tumor vessels on the surface. As they grow circumferentially in the anterior chamber angle they can produce increased intraocular pressure. On serial evaluation some of these lesions grow and distort the pupil. It is less common for an iris melanoma to produce sentinel vessels, unlike iris–ciliary body tumors, which commonly produce this pattern. Also, pure iris tumors less commonly show localized extraocular extension. A variant of the iris melanomas that have higher tumor-related mortality are ring melanomas, which involve 360° of the iris–corneal angle and may produce a limited mass-like effect, with diffuse pigmentation over the iris surface that clinically is apparent as heterochromia associated with increased intraocular pressure.

**Ancillary studies** Angiography of the iris has low sensitivity and specificity in the differential diagnosis of iris tumefactions. In contrast, high-frequency ultrasound is very useful in differentiating an iris melanoma from a common simulating lesion, a posterior pigment epithelial cyst. As shown in Figures 37.8A and B, iris melanoma is demonstrable as a solid tumor, and similarly the cystic quality of the benign iris cyst is nicely shown with this technique (see Chapter 85).

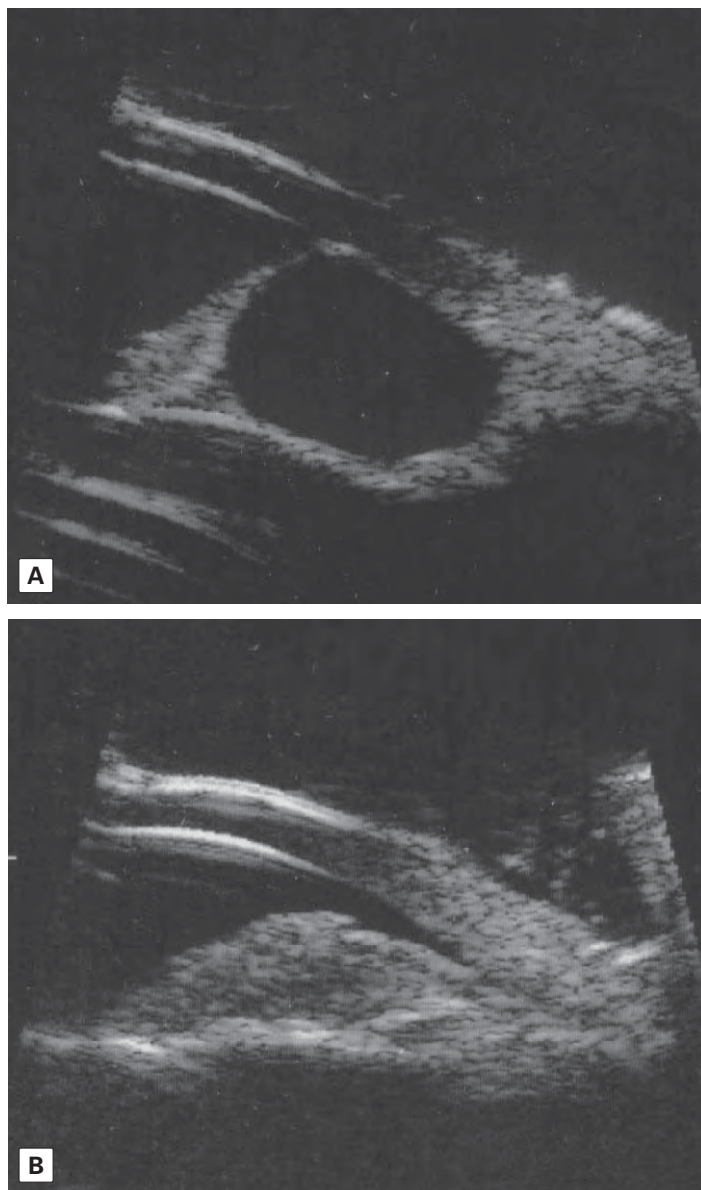
### Differential diagnosis

**Iris nevus** is a small, flat lesion that usually do not distort the pupil, invade the angle, or produce tumor angiogenesis. In a summary of several hundred cases we noted that less than 5% of smaller pigmented iris lesions showed growth and required treatment as iris melanomas. In another paper, Jakobiec<sup>35</sup> noted that 90% of the cases that Algonon Reese had previously resected and categorized as an iris melanoma were, on retrospective evaluation, histologically benign.

**Iris pigment epithelial cyst** The most common simulating iris lesion we evaluate is a posterior pigment epithelial cyst.<sup>36</sup> These do not distort the iris surface, or if they do so mainly have a pressure effect. High-frequency ultrasound is very useful in differentiating iris melanoma from a posterior pigment epithelial cyst (Figs 37.8A,B). Whereas posterior pigment epithelial cysts can be associated with a number of medications, most today are idiopathic and detected on routine examination when the general ophthalmologist notes that the iris plane is distorted forwards. Rarely, stromal cysts of the iris can simulate an iris melanoma.

**Metastases** Iris metastases are always amelanotic unless they are from a cutaneous melanoma. As previously described, depending on the histologic type of the metastasis some will present before the discovery of the primary neoplasm, and in atypical difficult cases fine needle biopsy is diagnostic.

**Other tumors/lesions** In melanotic tumors of the ciliary body that are thick enough to be diagnosed, the differential diagnosis is usually between a melanoma and an atypical melanocytoma, which can occasionally produce localized extraocular extension. It is extremely rare to have a localized hemorrhage in this area. Amelanotic ciliary or iris–ciliary masses have myriad etiologies, including ciliary epithelial tumors, benign stromal neoplasms, amyloidosis, and other rare tumors.<sup>37–43</sup> Ultrasound and other diagnostic techniques have limited accuracy in this setting, and when there is uncertainty about the diagnosis biopsy (fine needle aspiration) is the definitive approach.



**Fig. 37.8** (A) A posterior pigment epithelial cyst demonstrable on high-frequency ultrasound, in contrast to (B), which shows an iris melanoma. Rarely, iris–ciliary body melanomas can have cysts or even become cavitory.

### SUMMARY

In eyes with choroidal tumors that require treatment, the diagnostic accuracy should approach 100%. In iris tumors, the diagnostic accuracy of non-invasive techniques is less accurate. Fortunately, most primary tumors localized to the iris have an extremely low tumor-related mortality. High-frequency ultrasound has markedly improved our ability to differentiate between melanomas and some of the simulating iris benign lesions, and it is a useful adjuvant to determine whether the ciliary body is involved in the neoplastic process. Amelanotic ciliary body tumors remain a difficult diagnostic problem, and often the correct diagnosis can only be established with either cytopathology or histologic examination.

## REFERENCES

- Ferry AP. Lesions mistaken for malignant melanoma of the posterior uvea. A clinicopathologic analysis of 100 cases with ophthalmoscopically visible lesions. *Arch Ophthalmol* 1964; 72: 463–469.
- Char DH. Tumors of the eye and ocular adnexa: New York: BC Decker, 2001.
- Char DH, Stone RD, Irvine AR et al. Diagnostic modalities in choroidal melanoma. *Am J Ophthalmol* 1980; 89: 223–230.
- Long JC, Black WC, Danielson RW. Aspiration biopsy in intraocular tumors. *Arch Ophthalmol* 1953; 50: 303–310.
- Char DH. Uveal melanoma: therapeutic options. *Am J Ophthalmol* 1985; 98: 796–799.
- Augsburger JJ, Coats TD, Lauritzen K. Localized suprachoroidal hematomas. Ophthalmoscopic features, fluorescein angiography, and clinical course. *Arch Ophthalmol* 1990; 108: 968–972.
- Ossoinig K. Echography of the eye, orbit, and periorbital region. In: Arger PH, ed. *Orbit roentgenology*. New York: John Wiley & Sons, 1977; 224–269.
- Coleman DJ, Lizzi FL, Jack RL. *Ultrasonography of the eye and orbit*. Philadelphia: Lea & Febiger, 1977.
- Byrne SF, Green RL. *Ultrasound of the eye and orbit*. St. Louis: Mosby Year Book, 1992.
- Wolff-Kormann PG, Kormann BA, Hasenfratz GC, Spengel FA. Duplex and color Doppler ultrasound in the differential diagnosis of choroidal tumors. *Acta Ophthalmol (Copenh)* 1992; Supp 204: 66–70.
- Guthoff RF, Berger RW, Winkler P, Helmke K, Chumbley LC. Doppler ultrasonography of malignant melanomas of the uvea. *Arch Ophthalmol* 1991; 109: 537–541.
- Char DH, Miller TR. Accuracy of presumed melanoma diagnosis prior to alternative therapy. *Br J Ophthalmol* 1995; 79: 692–696.
- Collaborative Ocular Melanoma Study Group. Accuracy of diagnosis of choroidal melanomas in the Collaborative Ocular Melanoma Study. COMS report No.1. *Arch Ophthalmol* 1990; 108: 1268–1273.
- Margo CE. The accuracy of diagnosis of posterior uveal melanoma. *Arch Ophthalmol* 1997; 115: 432–434.
- Gass JD. Problems in the differential diagnosis of choroidal nevi and malignant melanoma. XXXIII Edward Jackson Memorial Lecture. *Trans Am Acad Ophthalmol Otolaryngol* 1977; 83: 19–48.
- Butler P, Char DH, Zarbin M, Kroll S. Natural history of indeterminate pigmented choroidal tumors. *Ophthalmology* 1994; 101: 710–717.
- Bardenstein DS, Char DH, Irvine AR, Stone RD. Extramacular disciform lesions simulating uveal tumors. *Ophthalmology* 1992; 99: 944–951.
- Ferry AP, Font RL. Carcinoma metastatic to the eye and orbit I. A clinicopathologic study of 227 cases. *Arch Ophthalmol* 1974; 92: 276–286.
- Char DH, Schwartz A, Miller TR, Abele JS. Ocular metastases from systemic melanoma. *Am J Ophthalmol* 1980; 90: 702–707.
- Shields CL, Shields JA, Gross NE, Schwartz GP, Lally SE. Survey of 520 eyes with uveal metastases. *Ophthalmology* 1997; 104: 1265–1276.
- Char DH, Heilbron DC, Juster RP, Stone RD. Choroidal melanoma growth patterns. *Br J Ophthalmol* 1983; 67: 575–578.
- Bardenstein DS, Char DH, Kaleta-Michaels S, Kroll SM. Ki-67 and bromodeoxyuridine labeling of human choroidal melanoma cells. *Curr Eye Res* 1991; 10: 479–484.
- Sobottka B, Schlote T, Krumpaszky HG, Kreissig I. Choroidal metastases and choroidal melanomas: comparison of ultrasonographic findings. *Br J Ophthalmol* 1998; 82: 159–161.
- Davis DL, Robertson DM. Fluorescein angiography of metastatic choroidal tumors. *Arch Ophthalmol* 1973; 89: 97–99.
- Shields JA, Font RL. Melanocytoma of the choroid clinically simulating a malignant melanoma. *Arch Ophthalmol* 1972; 87: 396–400.
- Chang TS, Byrne SF, Gass JD et al. Echographic findings in benign reactive lymphoid hyperplasia of the choroid. *Arch Ophthalmol* 1996; 114: 669–675.
- Grossniklaus HE, Martin DF, Avery R et al. Uveal lymphoid infiltration. Report of four cases and clinicopathologic review. *Ophthalmology* 1998; 105: 1265–1273.
- Yap EY, Robertson DM, Buettner H. Scleritis as an initial manifestation of choroidal malignant melanoma. *Ophthalmology* 1992; 99: 1693–1697.
- Janknecht P, Mittelviehhaus H, Löffler KU. Sclerochoroidal granuloma in Wegener's granulomatosis simulating a uveal melanoma. *Retina* 1995; 15: 150–153.
- Broughton WL, Zimmerman LE. A clinicopathologic study of 56 cases of intraocular medulloepithelioma. *Am J Ophthalmol* 1978; 85: 407–418.
- Shields JA, Campbell DG, Simmons RJ. The essential iris atrophies. *Am J Ophthalmol* 1978; 85: 749–759.
- Ashton N. Primary tumours of the iris. *Br J Ophthalmol* 1964; 48: 650–668.
- Brenkman RF, Oosterhuis JA, Manschot WA. Recurrent hemorrhage in the anterior chamber caused by a (juvenile) xanthogranuloma of the iris in an adult. *Doc Ophthalmol* 1977; 42: 329–33.
- Spencer WH. *Ophthalmic pathology. An atlas and textbook*. Philadelphia: WB Saunders, 1986.
- Jakobiec FA, Silbert G. Are most iris 'melanomas' really nevi? A clinicopathologic study of 189 lesions. *Arch Ophthalmol* 1981; 99: 2117–2132.
- Shields JA, Kline MV, Augsburger JJ. Primary iris cysts: a review of the literature and report of 62 cases. *Br J Ophthalmol* 1984; 68: 152–166.
- Ferry AP. Lesions mistaken for malignant melanoma of the iris. *Arch Ophthalmol* 1965; 74: 9–18.
- Shields JA, Eagle RCJ, Shields CL, De Potter P, Poliak JG. Natural course and histopathologic findings of lacrimal gland choristoma of the iris and ciliary body. *Am J Ophthalmol* 1995; 119: 219–224.
- Ryan SJ Jr, Frank RN, Green WR. Bilateral inflammatory pseudotumors of the ciliary body. *Am J Ophthalmol* 1971; 72: 586–591.
- Kuchle M, Holbach L, Schlotzer-Schrehardt U, Naumann GO. Schwannoma of the ciliary body treated by block excision. *Br J Ophthalmol* 1994; 78: 397–400.
- Campochiaro PA, Gonzalez-Fernandez F, Newman SA, Conway BP, Feldman PS. Ciliary body adenoma in a 10-year-old girl who had a rhabdomyosarcoma. *Arch Ophthalmol* 1992; 110: 681–683.
- Brown HH, Brodsky MC, Hembree K, Mrak RE. Supraciliary hemangiopericytoma. *Ophthalmology* 1991; 98: 378–382.
- Cursiefen C, Schlotzer-Schrehardt U, Holbach LM, Naumann GO. Adenoma of the nonpigmented ciliary epithelium mimicking a malignant melanoma of the iris. *Arch Ophthalmol* 1999; 117: 113–116.



# Uveal malignant melanoma: histopathologic features

Tero Kivelä

## INTRODUCTION

Uveal melanomas develop from melanocytes that reside within the stroma of the choroid, ciliary body, and iris. No basement membrane needs to be breached when the tumor develops.<sup>1</sup>

## GROWTH PATTERNS

**Dome shape** The growing tumor is first flat, but then develops a discoid, or dome, shape. Typically, it assumes dimensions in which its height is approximately half of its diameter (Fig. 38.1A). Most have a circular or oval contour, with irregular shape or multinodularity suggesting clonal evolution and variable growth rates.

**Collar-stud shape** A choroidal melanoma distends the overlying Bruch's membrane, which eventually ruptures so that part of the tumor squeezes through the break to assume a characteristic mushroom, or collar-stud, shape (Fig. 38.1B). The relative sizes of the base and the collar-stud part vary widely, depending on how soon and to what extent Bruch's membrane breaks. The collar stud is rich in dilated, sinusoidal capillaries because of a tourniquet effect of Bruch's membrane, which strangulates the vessels. The tumor can also erode through the retina, which leads to vitreous hemorrhage. Alternatively, the tumor detaches Bruch's membrane along the rim of the optic disc and ora serrata, and bulges in front of the disc or behind the lens.

**Diffuse growth pattern** A third growth pattern is diffuse,<sup>2</sup> in which the tumor, by definition, involves more than a quadrant of the fundus without growing to be more than 7 mm in thickness and without breaking Bruch's membrane (Fig. 38.1C). Diffuse tumors have a particular tendency to grow trans-sclerally.

**Ring melanoma** One subtype of the diffuse growth pattern is ring melanoma,<sup>3</sup> which grows circularly around the ciliary body, often without extending to the choroid.

**Retinoinvasive melanoma** A variant of diffuse melanoma, retinoinvasive melanoma, disseminates to the vitreous and the retinal surface, eventually invading non-adjacent retina and the optic nerve.<sup>4</sup>

## LOCAL INVASION

Uveal melanomas have indistinct borders. Tumor cells are often seen adjacent to visible tumor margin where the choroid is not thickened. This is particularly typical of the diffuse tumor type.

**Sclera** The sclera is resistant to invasion, and uveal melanomas gain access to it mainly along trans-scleral channels for ciliary nerves, ciliary arteries, vortex veins, and aqueous veins. Consequently, extrascleral extension typically occurs posteriorly adjacent to the optic nerve, equatorially adjacent to a vortex vein, and anteriorly adjacent to the limbus.<sup>5</sup> Typically, the intrascleral part of the tumor is narrow, making the tumor dumbbell-shaped, and much narrower than the extrascleral part, which usually can be resected and the remaining tumor irradiated without full-thickness scleral resection.

**Retina** The retina and optic nerve are likewise resistant to invasion by uveal melanoma. The retina overlying a tumor that has broken through Bruch's membrane is typically eroded without invasion of the adjacent retina. Melanomas that have broken through the retina can seed tumor cells to the vitreous. These cells are mostly necrotic, and accompanied by abundant melanophages and other macrophages.

**Optic nerve** Juxtapapillary melanomas can invade the optic disc, but the retrobulbar nerve is usually not invaded unless it has sustained prior glaucomatous damage and the intraocular pressure is high.<sup>6</sup> The rare, retinoinvasive uveal melanomas also invade the optic nerve.<sup>4</sup>

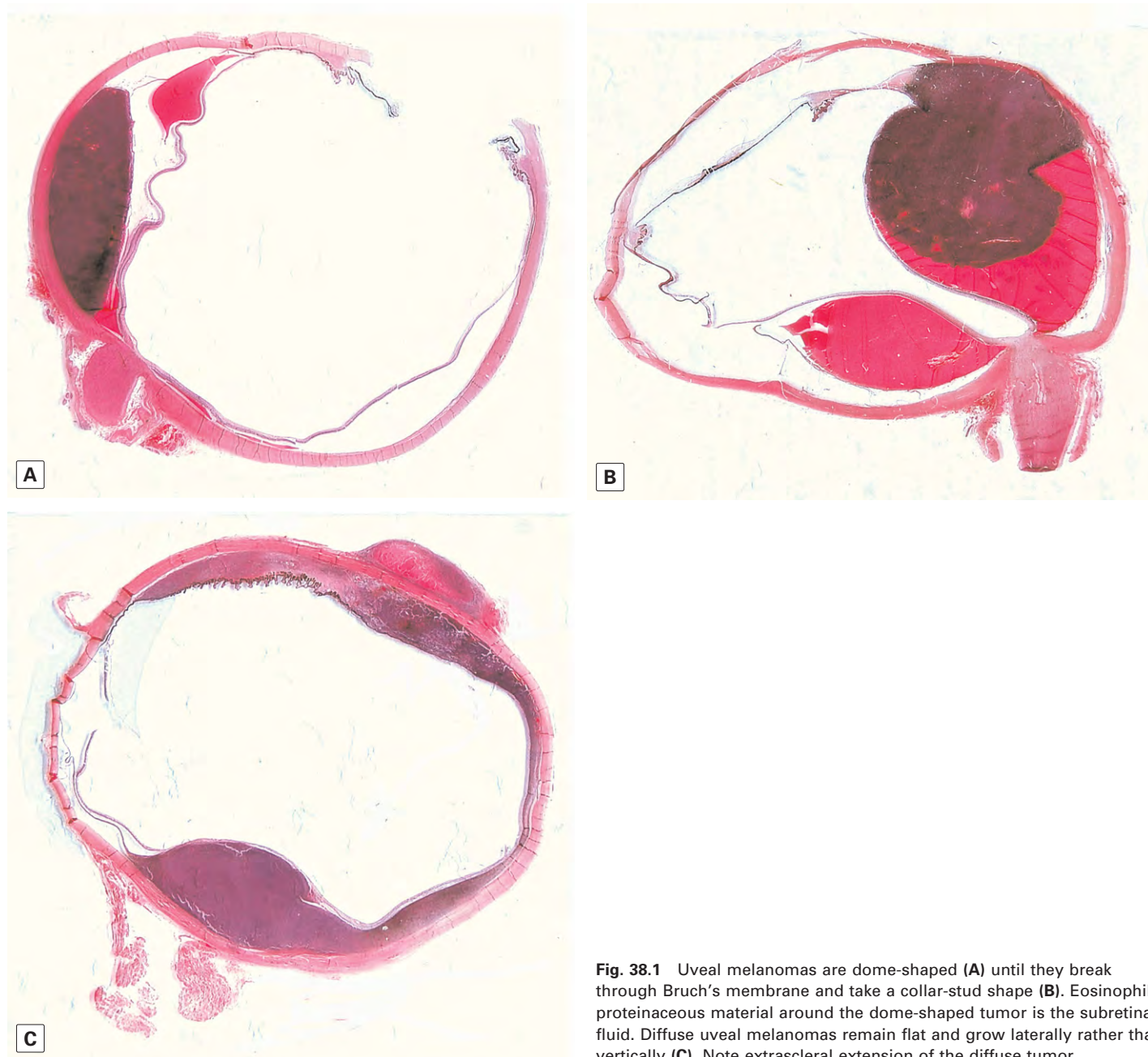## SECONDARY INTRAOCULAR DAMAGE

**Retinal pigment epithelium changes** Low-grade uveal melanomas induce proliferation and metaplasia of retinal pigment epithelial cells and atrophy or cystic degeneration of the retina over their surface, giving rise to subretinal membranes that consist of multi-layered basement membrane material.

**Retinal detachment** Uveal melanomas are moderately to richly vascularized tumors. Retinal detachment develops as a result of leakage from tumor vessels, together with compromised function of the retinal pigment epithelial pump overlying the tumor.<sup>7</sup> On light microscopy eosinophilic proteinaceous subretinal fluid is seen in most eyes, either adjacent to the tumor or displaced to the retinal periphery (Fig. 38.1A and B).

**Secondary glaucoma** Uveal melanoma can induce a secondary glaucoma by several mechanisms.

**Angle-closure glaucoma** Closed-angle glaucoma can be caused by: (1) compression or direct infiltration of the trabecular meshwork



**Fig. 38.1** Uveal melanomas are dome-shaped (A) until they break through Bruch's membrane and take a collar-stud shape (B). Eosinophilic proteinaceous material around the dome-shaped tumor is the subretinal fluid. Diffuse uveal melanomas remain flat and grow laterally rather than vertically (C). Note extrascleral extension of the diffuse tumor.

by a ciliary body tumor; (2) vitreous hemorrhage; or (3) a sudden increase in exudative retinal detachment after irradiation.

**Neovascular glaucoma** can develop in an untreated eye with a large tumor and retinal detachment, but is more common after irradiation, especially if the tumor is located in the ciliary body or if ischemic radiation optic neuropathy has occurred.

**Melanomalytic glaucoma** is caused by blockage of the trabecular meshwork by disseminated necrotic tumor cells and melanophages.<sup>8</sup>

### ASSESSING HISTOPATHOLOGIC INDICATORS OF PROGNOSIS

**Cell type** was the first histopathologic feature of uveal melanoma to be associated with survival (Chapter 46). It also correlates with most subsequently identified prognostic factors, including monosomy 3

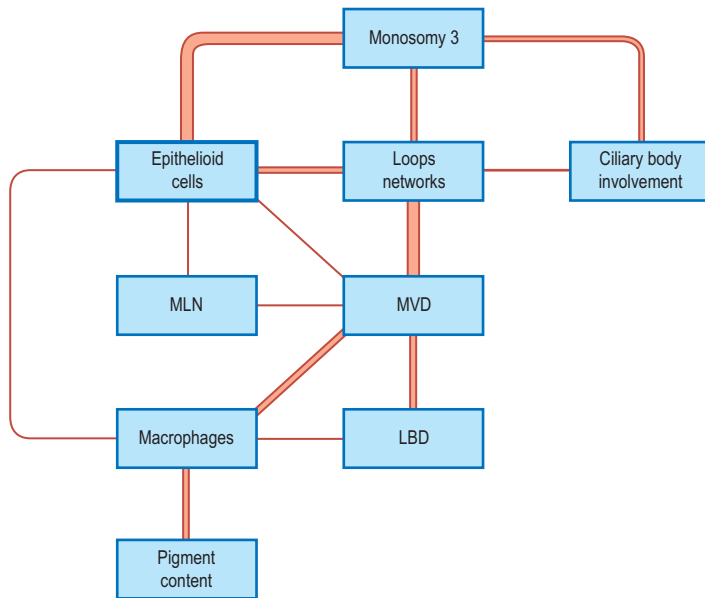
(Fig. 38.2). Originally, six histopathologic types of uveal melanoma were described, but the categories were later simplified into three (Table 38.1).<sup>9–11</sup>

**Spindle cell melanoma** is composed of fusiform cells orientated in bundles and whorls (Fig. 38.3A). Spindle cells have variable amounts of fibrillar cytoplasm, and their borders are difficult to distinguish because the cells adhere to each other. Originally, spindle cell melanomas were divided into spindle A and B types. The former have narrow, oval nuclei and inconspicuous nucleoli, and the latter contain larger, round nuclei and more conspicuous nucleoli (Fig. 38.3A). Most spindle A cell tumors are currently classified as spindle cell nevi (Table 38.1).<sup>10</sup>

**Epithelioid cell melanoma** is composed of polyhedral cells, which are usually but not always large and which morphologically

resemble epithelial cells (Fig. 38.3B). Their abundant cytoplasm is eosinophilic and they characteristically crack apart from their neighbors during tissue processing, resulting in a non-cohesive appearance. The nucleoli are large and prominent.

**Mixed-cell type melanoma** contains variable proportions of spindle and epithelioid cells. Opinion is divided as to what proportion of epithelioid cells distinguishes spindle- from mixed- and mixed- from epithelioid-cell melanomas.<sup>10</sup> Increasingly, even a single well-defined epithelioid cell precludes classification as a spindle cell melanoma because the tumor is likely to harbor additional epithelioid cells elsewhere.



**Fig. 38.2** Associations between cell type and other major histopathologic and immunohistochemical features of uveal melanoma. The thicker the connecting line, the stronger the association. MLN, mean of the ten largest nucleoli; MVD, microvascular density; LBD, largest basal tumor diameter.

**Necrotic melanoma** Significant necrosis is uncommon, but rarely the tumor is too necrotic to be classified by cell type. These necrotic melanomas have a prognosis comparable to that of tumors with epithelioid cells. Widespread necrosis will cause a secondary inflammatory reaction.

**Pigmentation** Uveal melanomas range from heavily pigmented to amelanotic, and many show regional variations in pigmentation. The grade of pigmentation can be semiquantitatively assessed by comparing unstained sections on white paper. A high grade of pigmentation is associated with a high risk of metastasis.

**Nucleolar size** Uveal melanoma cells typically have conspicuous nucleoli, which are visible in hematoxylin–eosin-stained sections but which can be better appreciated with special stains, especially the silver stain (Fig. 38.4).<sup>12</sup> Melanin is first bleached with potassium permanganate and oxalic acid. Large nucleoli are associated with a high risk of metastasis.<sup>13–15</sup> The recommended method is to calculate the mean of the longest diameters of the 10 largest nucleoli found along a 5-mm central strip of the tumor. A filar micrometer or digital photography can be used for the measuring. The exact measurements will depend on the staining and equipment used,<sup>15</sup> and each laboratory must establish its own reference values.

**Mitotic figures** Most uveal melanomas are slow growing, and mitotic figures are consequently usually few in number. The recommended method is to count the number of mitotic figures in 40 high-power fields. Higher numbers are associated with a higher chance of metastasis.

**Extravascular matrix patterns** The stroma of uveal melanomas is scanty. The extravascular matrix can be highlighted with several stains, of which periodic acid–Schiff stain without counterstain is most popular (Fig. 38.5).<sup>16</sup> Melanin is first bleached with potassium permanganate and oxalic acid and, after staining, the slides are evaluated under a dark-green filter to enhance the visibility of the matrix, which is purple (Fig. 38.5).

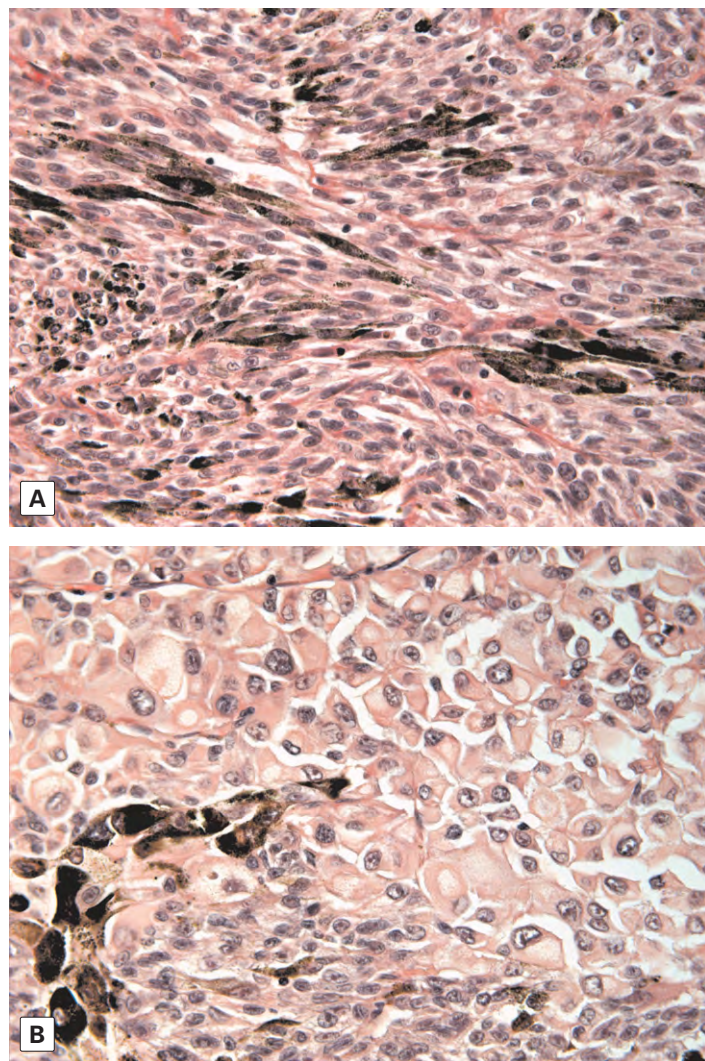
**Table 38.1** Classification of uveal melanoma based on cell type

Original Callender <sup>9</sup>	AFIP <sup>10,11</sup>	Histopathologic characteristics			
		Cell shape and appearance	Cell borders	Nucleus	Nucleolus
Spindle A melanoma*	Spindle cell nevus*	Fusiform cohesive cells	Indistinct	Narrow, oval	Inconspicuous
Spindle B melanoma	Spindle cell melanoma*	Fusiform cohesive cells	Indistinct	Plump	Conspicuous
Mixed cell melanoma	Mixed cell melanoma	Mixed population of spindle and epithelioid cells. Fusiform cohesive cells mixed with (at least single) non-cohesive epithelioid cells			
Epithelioid cell melanoma	Epithelioid cell melanoma	Large polygonal cells, abundant eosinophilic cytoplasm	Distinct	Large, round	Large, prominent
Fascicular melanoma		Spindle cells arranged in fascicles			
Necrotic melanoma		Too extensive tumor necrosis to allow classification into other groups			

\*The majority of spindle A melanoma of the Callender's classification were reclassified as spindle cell nevi and a minority as spindle cell melanoma in the AFIP classification.

AFIP, Armed Forces Institute of Pathology, Washington DC, United States.



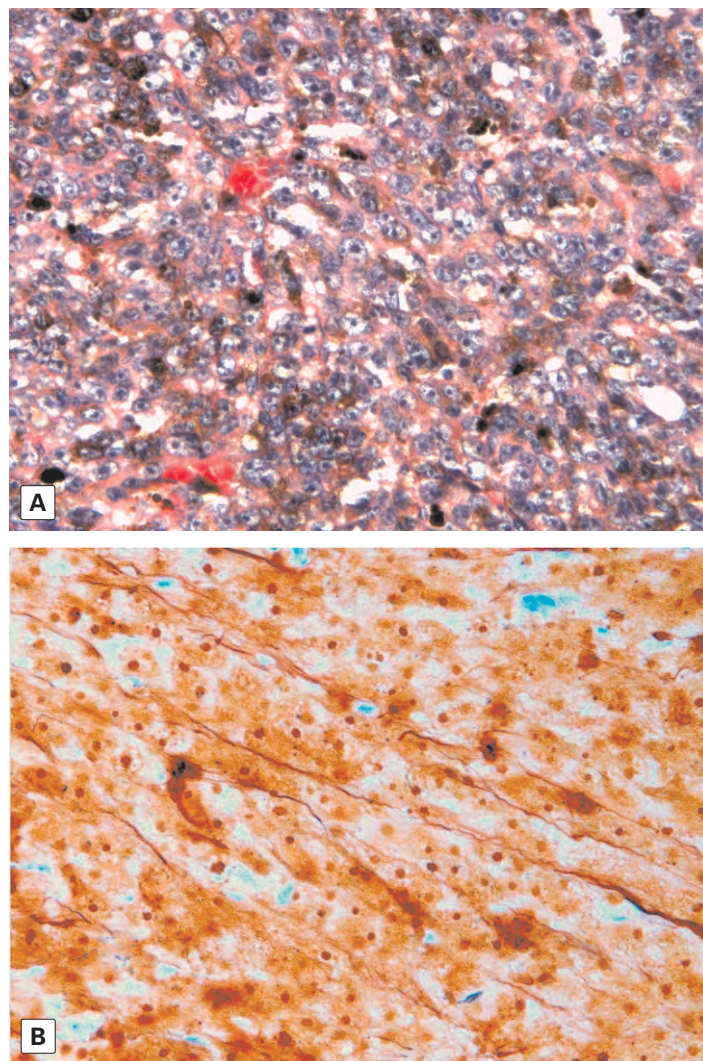


**Fig. 38.3** Main cell types of uveal melanoma. A spindle cell melanoma with mostly B-type cells with round nucleoli intermixed with occasional slender A-type cells with oval nuclei. Both are fusiform, with indistinct borders and arranged in bundles (A). A mixed cell melanoma with a population of polyhedral, non-cohesive, eosinophilic epithelioid cells, which have prominent nucleoli (B).

Nine matrix patterns are distinguished, which often occur in combination in any given tumor (Table 38.2).<sup>16,17</sup> The most widely evaluated patterns are closed loops and networks, the latter consisting of at least three closed loops that are linked back to back (Fig. 38.5). These two patterns are grouped with arcs and arcs with branching into a family of curved patterns. A second family of straight patterns consists of straight, parallel, and parallel with cross-linking. The remaining two patterns, silent and normal, may be seen in uveal melanomas but are more typical of uveal nevi.<sup>18</sup>

Several extravascular matrix patterns are associated with a higher-than-average chance of metastasis. The association is strongest for loops, and in particular for networks.<sup>14,16,19</sup> In evaluating these patterns, loops of any size are accepted. They typically consist of thin matrix strands that separate nests of tumor cells, which range in number from fewer than 10 to several hundred per nest (Fig. 38.5).

**Immunohistochemical indicators of prognosis** Many antigens have been evaluated in uveal melanoma, sometimes with conflicting results. With the exception of cytokeratins and insulin-like growth



**Fig. 38.4** A mixed cell type uveal melanoma with prominent nucleoli (A), which are most distinct in a silver-stained section (B).

factor-1 receptor, the prognostic significance of each immunohistochemical marker discussed in this section has been confirmed by independent studies and by multivariate analyses, adjusted for the most common known clinical and histopathological prognostic factors.

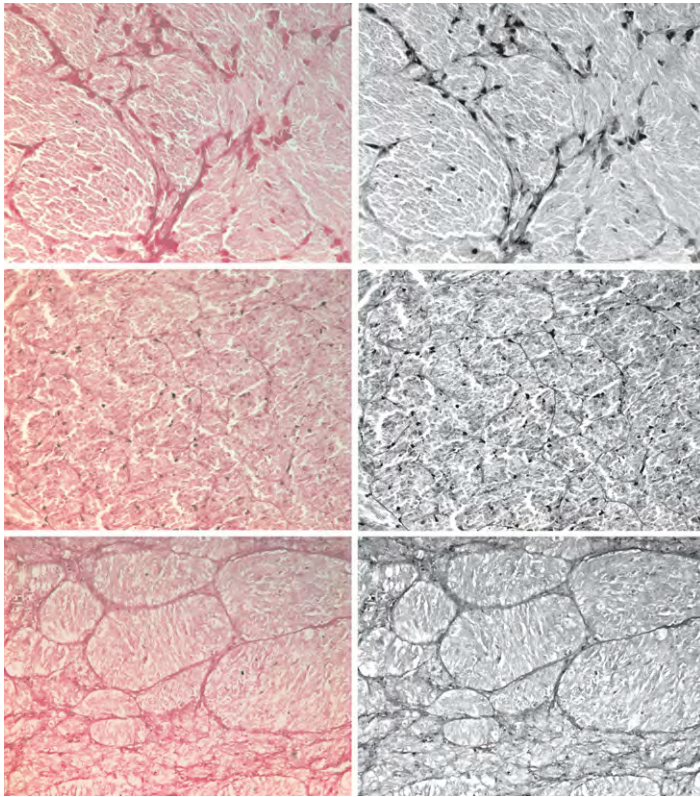
Immunohistochemical studies of uveal melanoma are complicated by the presence of melanin. This can be overcome by bleaching the sections with hydrogen peroxide and sodium dihydrogen phosphate following immunostaining.<sup>20</sup> This staining sequence excludes the possibility that antigenicity would be modified by the bleaching.

**Microvascular density** Immunohistochemical markers of vascular endothelial cells highlight blood vessels in uveal melanomas (Fig. 38.6). The most commonly used antigen is the CD34 epitope, but comparable results can be obtained using antibodies to the CD31 epitope and Factor VIII-related antigen, and some lectins, such as the *Ulex europaeus* I agglutinin.<sup>21–23</sup> The recommended method is to count immunopositive elements under 40 × magnification from a 0.3 mm<sup>2</sup> area of tumor that is most densely vascularized when screened with 10 × magnification. A high number of immunopositive elements per tumor cross-sectional area – called microvascular density (MVD) – is associated with an increased risk of metastasis.<sup>21–23</sup>

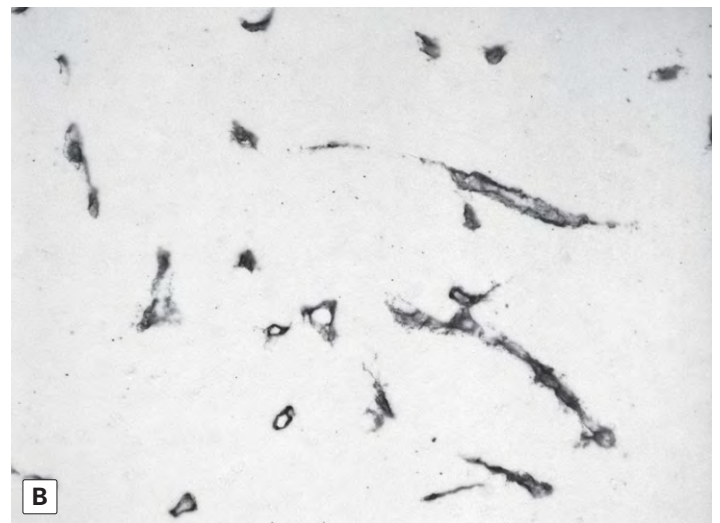
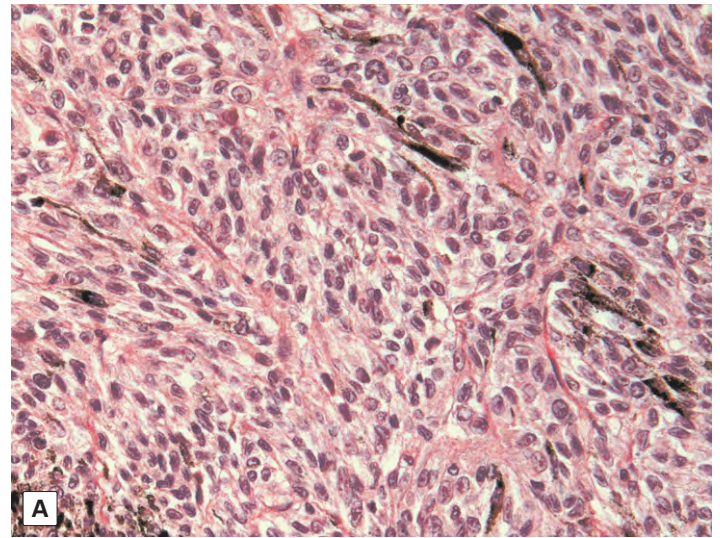


**Tumor-infiltrating macrophages** Uveal melanomas contain variable numbers of tumor-infiltrating macrophages, which can be identified by immunohistochemistry, especially using antibodies to the CD68 epitope (Fig. 38.7). Morphologically, the immunopositive cells vary in shape from dendritic to round.<sup>24</sup> Because dendritic cells are particularly difficult to count in histopathologic sections, the number of macrophages can be semiquantitatively assessed against

standard photographs.<sup>24</sup> A high number of immunopositive cells is associated with an increased risk of metastasis.<sup>24</sup> A similar observation has been made as regards infiltrating lymphocytes in uveal melanomas.<sup>25</sup>



**Fig. 38.5** Extravascular matrix patterns are purple in specimens stained with periodic acid-Schiff stain (left column) and appear dark in red-free photographs (right column). The arcs with branching (top row), loops (middle row) and network patterns (bottom row) all belong to the family of curved patterns. Note that the thickness of the patterns varies, and some are pencil-thin (middle row).

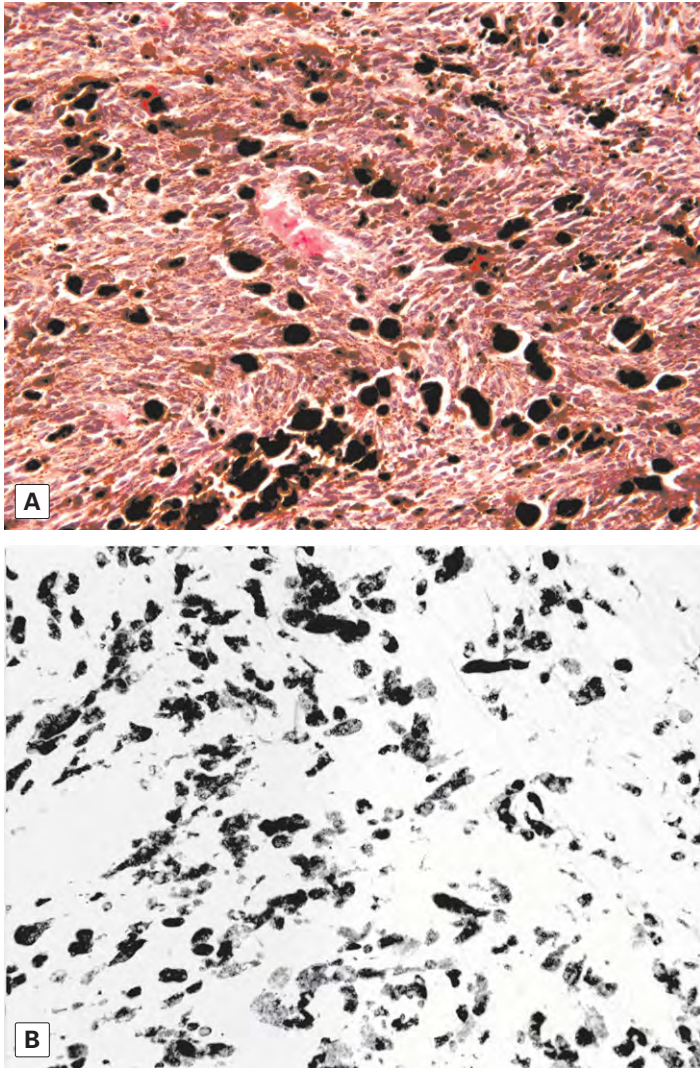


**Fig. 38.6** A mixed cell type uveal melanoma (A) with a high microvascular density (100 immunopositive elements/0.3mm<sup>2</sup>) as revealed with antibodies to the CD34 epitope of endothelial cells (B).

**Table 38.2** Classification of extravascular matrix patterns<sup>16,17,36</sup>

Pattern	Histopathologic characteristics	Group
Normal	Tumor grows around normal choroidal vessels without compressing them in a portion of the tumor beneath Bruch's membrane	Nevus
Silent	No matrix patterns are demonstrated	
Straight	Straight matrix strands, arranged in random orientation without dichotomous branching	Linear
Parallel	Straight matrix strands, arranged in parallel without dichotomous branching	
Parallel with cross-link	Straight matrix strands, arranged in parallel and cross linked to each other in a fashion reminiscent of rail tracks	
Arcs	Curved matrix strands not attached to others forming incomplete loops	Curved
Arcs with branching	Curved matrix strands with dichotomous branching forming incomplete loops	
Loops	At least one completely closed loop of matrix encircling a nest of tumor cells	
Networks	At least three back-to-back closed loops	





**Fig. 38.7** Tumor-infiltrating melanophages (A) in a spindle cell uveal melanoma can be identified in a hematoxylin–eosin-stained specimen, and antibodies to the CD68 epitope reveal additional macrophages (B).

**Cell proliferation antigens** Cycling tumor cells can be identified with several antibodies, of which those recognizing proliferating cell nuclear antigen (PCNA) and Ki-67 antigen have been most widely used to evaluate uveal melanoma. Larger numbers of cells with immunopositive nuclei are associated with a higher risk of metastasis.<sup>14,26</sup>

**Human leukocyte (HLA) antigens** Decreased expression of HLA antigens accompanies progression of many cancers and is thought to allow escape from immune surveillance. Low HLA class I expression in uveal melanoma is paradoxically associated with better survival than normal HLA class I expression.<sup>27</sup> This suggests that natural killer (NK) instead of T cells may be germane to immune surveillance of patients with uveal melanoma.

**Cytokeratins** Many uveal melanomas contain a population of tumor cells with intermediate filaments that are immunopositive for simple epithelial cytokeratins 8 and 18, and vimentin.<sup>28</sup> Tumor cells that co-express cytokeratins and vimentin are more invasive in culture than tumor cells expressing only vimentin;<sup>29</sup> however, it has not been conclusively reported that the presence of cytokeratins significantly alters the risk of metastasis.

**Insulin-like growth factor-1 receptor** Uveal melanoma cells are labeled by antibodies to insulin-like growth factor-1 (IGF-1) receptor, which recognizes IGF-1, a growth factor synthesized by the liver. By multivariate analysis a high level of immunoreaction for the IGF-1 receptor in human uveal melanoma is associated with a greater chance of metastasis.<sup>30</sup> Picropodophyllin, an inhibitor of the IGF-1 receptor, prevents liver metastases in a mouse model.<sup>31</sup>

### IRRADIATED UVEAL MELANOMA

Rather than being sampled systematically, irradiated uveal melanomas have been examined histologically only if enucleated because of tumor regrowth or complications resulting in a blind, painful eye, or if the eye was removed at autopsy.

**Necrosis and lower microvascular density** In general, after secondary enucleation melanomas show more necrosis and a lower microvascular density than tumors treated by primary enucleation.<sup>32</sup> By matched-pair analysis extravascular matrix loops and networks also tend to be less frequent after irradiation. The number of macrophages in non-necrotic tumor areas is not consistently higher in irradiated than in non-irradiated tumors.<sup>32</sup>

**Cell type** Uveal melanomas in eyes enucleated after irradiation are more likely to contain epithelioid cells than those treated by primary enucleation, which is surprising because epithelioid cells are believed to be more radiosensitive than spindle cells.

**Viable and non-proliferating cells** Irradiated tumors often contain tumor cells that appear viable and morphologically indistinguishable from those of untreated uveal melanomas, but which seem to be dormant and non-proliferating.<sup>33,34</sup>

**Vascular and degenerative changes** Obliteration of blood vessels, balloon cells, and other degenerative changes are also typical of irradiated tumors.

### METASTATIC UVEAL MELANOMA

Metastases from uveal melanoma usually (but not always) reflect the cell type of the primary tumor. The metastases are less pigmented, and have more epithelioid cells and a higher microvascular density than the primary tumor.<sup>35</sup> The microvascular density of metastases may be associated with subsequent survival (see Chapter 3B).

## REFERENCES

1. Folberg R. Tumor progression in ocular melanomas. *J Invest Dermatol* 1993; 100: 326S–31S.
2. Reese AB, Howard GM. Flat uveal melanomas. *Am J Ophthalmol* 1967; 64: 1021–1028.
3. Demirci H, Shields CL, Shields JA et al. Ring melanoma of the ciliary body: report on twenty-three patients. *Retina* 2002; 22: 698–706.
4. Kivelä T, Summanen P. Retinoinvasive malignant melanoma of the uvea. *Br J Ophthalmol* 1997; 81: 691–697.
5. Pach JM, Robertson DM, Taney BS et al. Prognostic factors in choroidal and ciliary body melanomas with extrascleral extension. *Am J Ophthalmol* 1986; 101: 325–331.
6. Spencer WH. Optic nerve extension of intraocular neoplasms. *Am J Ophthalmol* 1975; 80: 465–471.



7. Kivelä T, Eskelin S, Mäkitie T, Summanen P. Exudative retinal detachment from malignant uveal melanoma: predictors and prognostic significance. *Invest Ophthalmol Vis Sci* 2001; 42: 2085–2093.
8. McMenamin PG, Lee WR. Ultrastructural pathology of melanomalytic glaucoma. *Br J Ophthalmol* 1986; 70: 895–906.
9. Callender GR. Malignant melanocytic tumors of the eye. A study of histologic types in 111 cases. *Trans Am Acad Ophthalmol Otolaryngol* 1931; 36: 131–140.
10. McLean IW, Zimmerman LE, Evans RM. Reappraisal of Callender's spindle a type of malignant melanoma of choroid and ciliary body. *Am J Ophthalmol* 1978; 86: 557–564.
11. McLean IW, Foster WD, Zimmerman LE, Gamel JW. Modifications of Callender's classification of uveal melanoma at the Armed Forces Institute of Pathology. *Am J Ophthalmol* 1983; 96: 502–509.
12. Moshari A, McLean IW. Uveal melanoma: mean of the longest nucleoli measured on silver-stained sections. *Invest Ophthalmol Vis Sci* 2001; 42: 1160–1163.
13. McLean IW, Keefe KS, Burnier MN. Uveal melanoma: comparison of the prognostic value of fibrovascular loops, mean of the ten largest nucleoli, cell type, and tumor size. *Ophthalmology* 1997; 104: 777–780.
14. Seregard S, Spångberg B, Juul C, Oskarsson M. Prognostic accuracy of the mean of the largest nucleoli, vascular patterns, and PC-10 in posterior uveal melanoma. *Ophthalmology* 1998; 105: 485–491.
15. Al Jamal RT, Mäkitie T, Kivelä T. Nucleolar diameter and microvascular factors as independent predictors of mortality from malignant melanoma of the choroid and ciliary body. *Invest Ophthalmol Vis Sci* 2003; 44: 2381–2389.
16. Folberg R, Rummelt V, Parys-van Ginderdeuren R et al. The prognostic value of tumor blood vessel morphology in primary uveal melanoma. *Ophthalmology* 1993; 100: 1389–1398.
17. Folberg R, Pe'er J, Gruman LM et al. The morphologic characteristics of tumor blood vessels as a marker of tumor progression in primary human uveal melanoma: a matched case-control study. *Hum Pathol* 1992; 23: 1298–1305.
18. Rummelt V, Folberg R, Rummelt C et al. Microcirculation architecture of melanocytic nevi and malignant melanomas of the ciliary body and choroid: a comparative histopathologic and ultrastructural study. *Ophthalmology* 1994; 101: 718–727.
19. Mäkitie T, Summanen P, Tarkkanen A, Kivelä T. Microvascular loops and networks as prognostic indicators in choroidal and ciliary body melanomas. *J Natl Cancer Inst* 1999; 91: 359–367.
20. Kivelä T. Immunohistochemical staining followed by bleaching of melanin: a practical method for ophthalmic pathology. *Br J Biomed Sci* 1995; 52: 325–326.
21. Foss AJE, Alexander RA, Jefferies LW et al. Microvessel count predicts survival in uveal melanoma. *Cancer Res* 1996; 56: 2900–2903.
22. Mäkitie T, Summanen P, Tarkkanen A, Kivelä T. Microvascular density in predicting survival of patients with choroidal and ciliary body melanoma. *Invest Ophthalmol Vis Sci* 1999; 40: 2471–2480.
23. Chen X, Maniotis AJ, Majumdar D et al. Uveal melanoma cell staining for CD34 and assessment of tumor vascularity. *Invest Ophthalmol Vis Sci* 2002; 43: 2533–2539.
24. Mäkitie T, Summanen P, Tarkkanen A, Kivelä T. Tumor-infiltrating macrophages (CD68<sup>+</sup> cells) and prognosis in malignant uveal melanoma. *Invest Ophthalmol Vis Sci* 2001; 42: 1414–1421.
25. de la Cruz POJ, Specht CS, McLean IW. Lymphocytic infiltration in uveal malignant melanoma. *Cancer* 1990; 65: 112–115.
26. Al Jamal RT, Kivelä T. Ki-67 immunopositivity in choroidal and ciliary body melanoma with respect to nucleolar diameter and other prognostic factors. *Curr Eye Res* 2006; 31: 57–67.
27. Blom DJ, Luyten GP, Mooy C et al. Human leukocyte antigen class I expression. Marker of poor prognosis in uveal melanoma. *Invest Ophthalmol Vis Sci* 1997; 38: 1865–1872.
28. Fuchs U, Kivelä T, Summanen P et al. An immunohistochemical and prognostic analysis of cytokeratin expression in malignant uveal melanoma. *Am J Pathol* 1992; 141: 169–181.
29. Hendrix MJ, Seftor EA, Seftor RE et al. Biologic determinants of uveal melanoma metastatic phenotype: role of intermediate filaments as predictive markers. *Lab Invest* 1998; 78: 153–163.
30. All-Ericsson C, Girnita L, Seregard S et al. Insulin-like growth factor-1 receptor in uveal melanoma: a predictor for metastatic disease and a potential therapeutic target. *Invest Ophthalmol Vis Sci* 2002; 43: 1–8.
31. Girnita A, All-Ericsson C, Economou MA et al. The insulin-like growth factor-I receptor inhibitor picropodophyllin causes tumor regression and attenuates mechanisms involved in invasion of uveal melanoma cells. *Clin Cancer Res* 2006; 12: 1383–1391.
32. Toivonen P, Mäkitie T, Kujala E, Kivelä T. Macrophages and microcirculation in regressed and partially regressed irradiated choroidal and ciliary body melanomas. *Curr Eye Res* 2003; 27: 237–245.
33. Fuchs A, Kivelä T, Tarkkanen A, Laatikainen L. Histopathology of enucleated intraocular melanomas irradiated with cobalt and ruthenium plaques. *Acta Ophthalmol (Copenh)* 1988; 66: 255–266.
34. Saornil MA, Egan KM, Gragoudas ES et al. Histopathology of proton beam-irradiated vs enucleated uveal melanomas. *Arch Ophthalmol* 1992; 110: 1112–1118.
35. Toivonen P, Mäkitie T, Kujala E, Kivelä T. Microcirculation and tumor-infiltrating macrophages in choroidal and ciliary body melanoma and corresponding metastases. *Invest Ophthalmol Vis Sci* 2004; 45: 1–6.

# Management of patients with uveal melanoma

Bertil Damato

## INTRODUCTION

The management of patients with uveal melanoma encompasses detection, examination, treatment, prognostication, counseling, and surveillance (Box 39.1). Each of these fields is advancing rapidly, owing to technological developments as well as changing attitudes from our increased understanding of tumor biology. As there is no consensus on preferred practice patterns in relation to uveal melanoma (Box 39.2), this chapter gives the author's personal perspective.

## DETECTION

Early detection of uveal melanoma greatly improves the chance of conserving a useful eye and is perhaps vital in the prevention of metastatic spread, especially if the tumor is small. Opportunities and constraints in the community are rather different from those in specialized ophthalmic clinics, so that these two situations are discussed separately.

**Community** In the community, patients are usually examined in suboptimal conditions, often by non-specialists, who may encounter only a single uveal melanoma in their entire career. In many situations the pupils are dilated only selectively, if there is any suspicion of posterior segment disease. For these reasons, about 20% of all symptomatic patients with melanoma of the posterior segment report that their tumor was not diagnosed at first presentation.<sup>1-3</sup> The situation may improve with greater use of wide-angle non-mydratric fundus photography in the community.

**Ophthalmic clinics** In ophthalmic clinics routine ocular examination is more complete, being performed following mydriasis and by an expert clinician. For these reasons, there is increased likelihood of detecting an asymptomatic uveal melanoma. It is not uncommon, however, for patients to be referred to an ocular oncologist with a large melanoma, despite attending an ophthalmic clinic regularly for several years (Fig. 39.1). This may happen because in some clinics only the optic disc and macula are routinely examined, possibly without mydriasis. The author has devised a mnemonic (MELANOMA) to alert clinicians to clinical features suggestive of an intraocular melanoma (Chapter 31).

## REFERRAL PROCEDURE

The time between initial tumor detection and treatment depends greatly on the method of patient referral. The author has seen long delays with tragic consequences because the referral letter or fax was

not received by the ocular oncology center. It is therefore important to give the patient a contact telephone number together with advice as to what to do if an appointment is not received within a specified time. It is also essential to inform the patient of any suspicion of malignancy, together with any caveats if the diagnosis is uncertain. Investigations such as fluorescein angiography and systemic screening can cause unnecessary delays in the referral process and could be left to ocular oncologists.

## DIAGNOSIS

Diagnosis of uveal tumors requires an awareness of the wide range of conditions and of the diverse clinical manifestations of each (see Chapters 33 and 37).<sup>4,5</sup> With such knowledge, most uveal melanomas can be identified by slit-lamp examination and ophthalmoscopy (Chapters 31 and 36). Investigations such as angiography and ultrasonography can provide helpful diagnostic clues; however, they can also be misleading if the clinician is not skilled in interpreting the results correctly, or if there is a lack of awareness of the diagnostic limitations of each type of investigation (Chapter 32). For example, there is a misconception that on fluorescein angiography choroidal melanomas are hyperfluorescent and masked by an overlying hypofluorescent retinal pigment epithelium. In fact, the converse is often true, because pigmented tumors are relatively hypofluorescent, with most hyperfluorescence arising from retinal pigment epithelial abnormalities.<sup>6</sup> Loss of hypofluorescence after phototherapy, therefore, does not indicate loss of tumor viability.

**Diagnostic uncertainty** It is important to have strategies for coping with diagnostic uncertainty, when this occurs.

**Alternate diagnosis** For example, before enucleating an eye with an amelanotic ciliary body tumor it is advisable to inform the patient in advance of the small possibility of an alternate diagnosis, such as neurilemmoma, adenocarcinoma, or metastasis.

**Indeterminate melanocytic lesions** Another diagnostic challenge is the differentiation between a large choroidal nevus and a small melanoma, which is commonly managed by labeling the tumor as a 'suspicious nevus' or 'indeterminate melanocytic lesion.' Such a lesion is usually managed by careful observation and by delaying treatment for months or years until growth is unequivocally documented. Ocular oncologists have long debated the safety of this practice, because it is not known when uveal melanomas start to metastasize. When

**BOX 39.1 Aspects of Management of Patients with Uveal Melanoma**

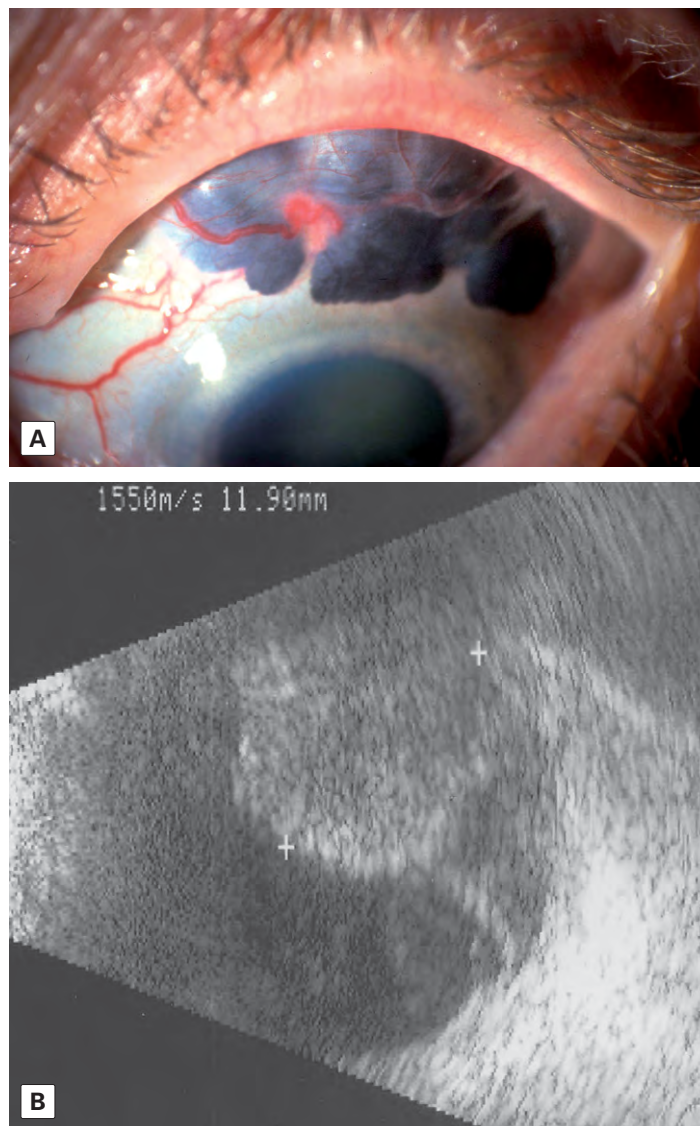
- Detection of tumor
- Referral for specialist care
- Diagnosis and differential diagnosis
- Tumor staging, according to size and extent
- Tumor grading according to histology, cytogenetics, and molecular genetics
- Counseling, to inform on condition and therapeutic options
- Ocular treatment, if possible conserving function
- Systemic investigation, detecting metastatic spread as early as possible
- Long-term surveillance, to enable timely treatment of any complications
- Psychological support for patients and relatives

**BOX 39.2 Uncertainties Regarding the Management of Patients with Uveal Melanoma**

- Is it safe to observe small asymptomatic melanomas?
- Is local tumor recurrence life threatening after conservative therapy?
- Does ocular treatment ever influence survival? If so, when?
- Once metastasis has occurred, does ocular treatment prolong life, by reducing hepatic tumor burden?
- Are radiation-induced complications preventable and treatable?
- What rate of secondary enucleation is generally acceptable after conservative therapy?
- Should the primary melanoma be treated if systemic spread is found?
- Is extraocular tumor spread an indication for orbital radiotherapy?
- Should all patients be screened for metastatic disease before treatment of the primary tumor?
- After treatment of the ocular tumor, which patients should be screened for systemic metastasis, how, and for how long?
- Is there any role for tumor biopsy and grading before radiotherapy?
- Is it ethical to perform predictive tumor genetic testing (cytogenetics and molecular genetics) if there is no curative treatment?

managing a patient with a melanocytic tumor of unknown malignant potential, the requirement for informed consent makes it necessary to discuss such matters with the patient, who may be reluctant to delay treatment if there is any risk to life, however small, irrespective of any visual consequences.

**Histological confirmation** Most uveal tumors are treated without prior histologic confirmation of the diagnosis. This practice seems to work well enough in most patients and avoids the difficulties and



**Fig. 39.1** This patient had originally been diagnosed with left central retinal vein occlusion and primary open-angle glaucoma in 1999 and was subsequently reviewed every 6 months. In December 2005 she underwent right phacoemulsification and also attended a community optometrist. In March 2006 she was referred with a ciliochoroidal melanoma showing extensive extraocular extension (A). B-scan ultrasound confirmed a large ciliochoroidal melanoma (B) (base = 20 mm, thickness = 12 mm).

risks of intraocular biopsy. The recent development of the 25-gauge vitrectomy system enables transconjunctival, sutureless biopsy of uveal tumors to be performed quickly and easily, providing a larger specimen than fine-needle aspiration biopsy.<sup>7</sup> Initial results with this technique are encouraging, but further evaluation is necessary. Other biopsy techniques are outlined in Chapter 56.

**TUMOR STAGING**

Tumor staging is fundamental to patient care and uveal melanoma is no exception (Chapter 33). Unfortunately, unlike other cancers, the TNM staging system has not proved acceptable for uveal melanoma.<sup>8</sup> A variety of alternative systems based on clinical features such as largest basal tumor diameter, tumor thickness, extraocular extension, and ciliary body involvement have been devised (Chapter 46). An added limitation is that factors predictive of mortality do not accurately predict the chance of conserving the eye and vision. These ocular



outcomes are more strongly correlated to features such as proximity of the tumor to the optic disc and fovea, and retinal invasion.<sup>9</sup> There is no suitable staging system for iris melanomas, although it is known that diffuse spread, seeding, extent of angle involvement, and secondary glaucoma are important predictive factors.

## TUMOR GRADING

The management of uveal melanoma is exceptional in that ocular treatment – and indeed screening for metastatic disease – is not based on any form of histologic, cytogenetic, or molecular genetic tumor grading, unless tumor tissue becomes available serendipitously, as a secondary benefit of local resection or enucleation. As mentioned in other chapters, uveal melanoma tends to fall into two distinct categories of low and high grade. These two varieties are more accurately distinguishable using cytogenetic and molecular genetic techniques rather than traditional histopathologic evaluation.<sup>10,11</sup> At present, all melanomas are treated similarly, whereas it might be possible to reduce ocular morbidity while improving local tumor control if treatment is tailored to the grade of malignancy. For these reasons, there is scope for tumor biopsy-dependent grading to guide management, which can be individualized with respect to ocular treatment, screening for metastases, and perhaps adjuvant systemic therapy.

## TREATMENT

**Impact of ocular treatment on survival** As mentioned in Chapter 47, there are essentially two schools of thought regarding the impact of ocular treatment on survival.

**Conventional optimistic hypothesis** The conventional, optimistic view is that treatment of the primary uveal melanoma is often effective at preventing metastatic spread, even with moderate and large tumors, which are therefore treated urgently and aggressively.

**Alternative pessimistic hypothesis** A more pessimistic hypothesis is that ocular treatment rarely influences survival, because most or all high-grade tumors have already metastasized by the time of presentation and treatment, especially if medium-sized or large. Without proper evidence on which to base patient management, decisions of vital importance therefore rely on intuitive impressions of tumor behavior. For example, whether a patient with a small melanocytic tumor of indeterminate malignancy is treated or observed will vary from one center to another.

**Optimal therapeutic modality** Another ongoing debate is concerned with the optimal therapeutic modality for conserving an eye with uveal melanoma (such methods are traditionally referred to as ‘conservative,’ but perhaps ‘conservationist’ might be less confusing). Previously, this controversy centered on which method was best for all tumors. Today, there is a growing acceptance of selecting between the various methods according to tumor size and location and of a multimodality approach wherein different modes of treatment are used to improve local control while minimizing collateral damage to other parts of the eye.

**Episcleral plaque radiotherapy** In most centers, when applicable, the first choice of treatment is episcleral plaque radiotherapy, brachytherapy, administered with a radioactive plaque containing ruthenium-106 or iodine-125 (Chapter 41). Ruthenium plaques are suitable for uveal melanomas up to 5 mm thick, because of the limited

range of  $\beta$  radiation they emit. To reduce collateral damage to the optic disc and fovea, the author has developed a technique for positioning the plaque eccentrically, with its posterior edge aligned with the posterior tumor margin.<sup>12,13</sup> Iodine plaques emit  $\gamma$  radiation and can successfully treat tumors as thick as 10 mm; however, they also deliver large doses to healthy ocular structures. Collimation and dosimetry techniques have been improved to avoid this problem.<sup>14</sup>

**Proton beam radiotherapy** enables a high dose of radiation to be aimed precisely at a uveal melanoma irrespective of the tumor’s size, shape, or location (Chapter 42). Facilities for this treatment are available in only a small number of centers around the world. Some oncologists use proton beam radiotherapy for all choroidal melanomas.<sup>15</sup> Others reserve it for tumors that cannot be treated adequately by brachytherapy, that is, large tumors and those that extend close to the optic disc or fovea.<sup>16</sup> Proton beam radiotherapy is also useful for treating iris melanomas, as a means of avoiding the problems of iridectomy and iridocyclectomy.<sup>17</sup>

**Stereotactic radiotherapy** With stereotactic radiotherapy, a highly collimated beam of photons or  $\gamma$  radiation is aimed at the tumor from many different directions, so that a high dose of radiation is delivered to the melanoma while exposing healthy tissues to only small doses (Chapter 43).<sup>18,19</sup> This method is generally used as an alternative to proton beam radiotherapy, in centers where a cyclotron unit is not available.

**Photocoagulation** of choroidal melanomas is associated with a high complication rate and has been superseded by transpupillary thermotherapy.

**Transpupillary thermotherapy** With transpupillary thermotherapy the tumor is heated by only a few degrees for about 1 minute using a 3 mm diode laser beam (Chapter 40). This treatment has been advocated for tumors up to 4 mm thick. Adjunctive brachytherapy is advocated as a means of avoiding local recurrence from intrascleral tumor (‘sandwich technique’).<sup>20</sup> After radiotherapy, transpupillary thermotherapy of the tumor can be an effective treatment for exudative retinal detachment involving the macula and macular edema.<sup>21</sup>

**Photodynamic therapy** using Verteporfin has recently been described but it is still too soon to assess the efficacy of this treatment, both as primary therapy and as adjunctive treatment for radiation-induced exudation.<sup>22</sup>

**Cryotherapy** can be effective for choroidal melanomas.<sup>23</sup> However, this form of therapy has not gained widespread acceptance.

## Tumor resection

**TRANS-SCLERAL RESECTION** of small ciliary body melanomas has been performed for many years (Chapter 44). Advances in microsurgery and hypotensive anesthesia have also made it possible to remove large tumors extending as far posteriorly as the fovea.<sup>24</sup> Such surgical procedures are difficult and are therefore performed only in a few centers, where they are reserved for tumors that are considered too large for radiotherapy. Trans-scleral resection of an irradiated melanoma can induce regression of exudative retinal detachment and neovascular glaucoma.<sup>24</sup>

**ENDORESECTION** With endoresection the melanoma is removed with a vitreous cutter, either through a hole in the retina or after raising a retinal flap (Chapter 44).<sup>25</sup> This is a controversial procedure because of concerns about seeding of malignant cells to other parts of the eye, as well as the orbit and systemically. For this reason, endoresection is rarely performed, except perhaps for juxtapapillary tumors when other methods are unlikely to conserve vision. Some surgeons administer adjunctive radiotherapy after the endoresection; others give proton beam or stereotactic radiotherapy prior to the procedure.<sup>26</sup>

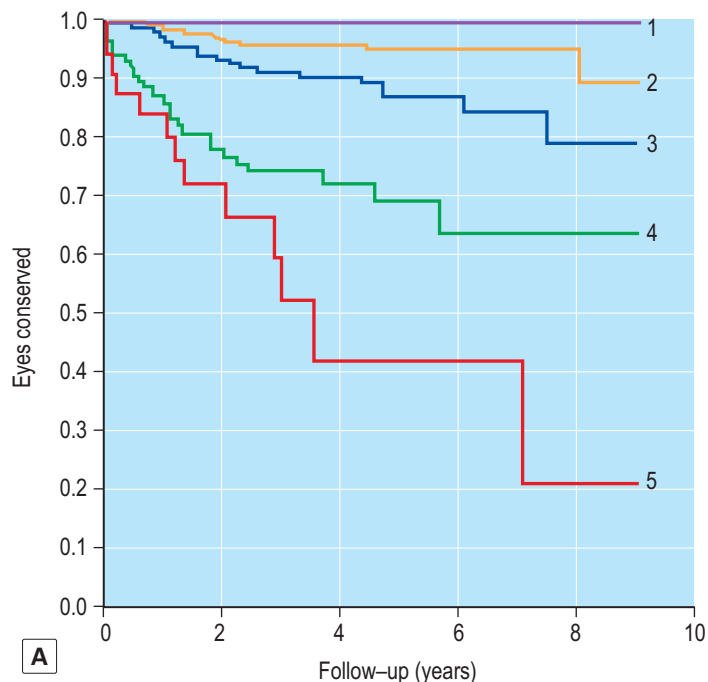
**ENUCLEATION** Primary enucleation for uveal melanoma is now performed only when other methods are considered unlikely to conserve the eye and useful vision without causing excessive morbidity; and/or if the patient is not motivated to try to save the eye. The author currently performs primary enucleation in about 35% of all patients with uveal melanoma, mostly because patients present at a late stage (Fig. 39.2).<sup>9</sup> The enucleation is performed in the standard fashion, using the surgeon's preferred implant. To ensure that the correct eye is removed, the tumor is visualized by binocular indirect ophthalmoscopy, which is done only after draping the patient and covering the other eye.

**Ancillary treatments** Overall outcomes after treatment of uveal melanoma are improving due to advances made in the treatment of cataract, glaucoma, iris coloboma, and rhegmatogenous retinal detachment. Intraocular steroid injection is effective for macular edema after radiotherapy,<sup>27</sup> however, this treatment is not without its complications (glaucoma, cataract). It is likely that anti-angiogenic factors will also be found useful over the next few years.

**SCREENING FOR SYSTEMIC DISEASE**

There is no consensus about which patients should be screened for metastatic disease, what investigations should be performed, how frequently they should be undertaken, and for how long (Chapter 48).<sup>28</sup>

**Before ocular treatment** Before treating the primary tumor some oncologists screen all patients, whereas others investigate only if there is an increased suspicion of metastatic disease (e.g. a large intraocular tumor, abdominal symptoms, palpable liver, or raised liver enzymes). Many consider liver ultrasonography to be quite adequate, although there may be a preference for computerized tomography or magnetic resonance imaging.



Variable	Category	Score
Disk involvement	No	0
	Yes	0.8
Coronal location	Temporal	0
	Nasal/Midline	1
Tumor diameter (mm)	7	0.2
	8	0.3
	9	0.4
	10	0.5
	11	0.6
	12	0.7
	13	0.8
	14	0.9
	15	1.0
	16	1.1
	17	1.2
Tumor height (mm)	18	1.3
	19	1.4
	20	1.5
	21	1.6
	22	1.7
	23	1.8
Total score	4	1.0
	5	1.3
	6	1.6
	7	1.9
	8	2.1
	9	2.4
	10	2.7

**B** Each variable is scored by encircling the appropriate row, and scores are then added to provide a total.

**Fig. 39.2 (A)** Kaplan–Meier analyses for the cumulative probability of secondary enucleation after primary conservative therapy, according to predictive score, shown at the end of each curve. The score sheet **(B)** is specific to the ocular oncology center in Liverpool, but similar principles could be used to derive scoring systems elsewhere. (From Damato B, Lecuona K. Conservation of eyes with choroidal melanoma by a multimodality approach to treatment: an audit of 1632 patients. *Ophthalmology* 2004; 111: 977–983.)

**After ocular treatment** There is similar disagreement as to whether all patients or only high-risk individuals should be prospectively screened after ocular treatment. For example, the author refers patients to a general oncologist for consideration of screening only if there is cytogenetic evidence of monosomy 3, or if there is unusually rapid and complete tumor regression after radiotherapy.

**Methods of screening** Some form of liver imaging is required, ideally every 6 months.<sup>29</sup> Chest radiography and liver function tests are not helpful.<sup>29</sup> Once systemic disease has developed, positron emission tomography is useful for detecting extrahepatic metastases when liver surgery is contemplated.<sup>30</sup> Despite screening, few patients have resectable metastases.<sup>28</sup> Patients are therefore treated with chemotherapy, which is administered either systemically or intrahepatically.<sup>28</sup> Durable responses to such treatment are rare.

### ADJUVANT THERAPY

There would seem to be scope for investigating adjuvant systemic therapy for high-risk patients, starting this treatment as soon as possible after treatment of the primary tumor. Possible therapies include systemic chemotherapy, immunotherapy, anti-angiogenic agents, and COX-2 inhibitors, although each of these treatments is associated with life-threatening complications. Large, multicenter randomized prospective studies are required to evaluate the efficacy and safety of such agents.

### AFTERCARE

After treatment of the primary tumor, patients require continuous ophthalmic care to ensure that any local tumor recurrence and any other ocular complications are detected and treated without delay. There seems to be a general consensus that follow-up should be life-long; however, the frequency of ocular examinations varies greatly between centers. Much depends on the perceived risk of complications in each individual case.

Apart from surveillance it is useful to review patients regularly to answer any questions they may have and to provide psychological support if necessary. Follow-up examinations at an ocular oncology center also enhance outcomes analysis; however, patients should be informed if they are being reviewed solely for this purpose.

### COUNSELING

Patients with uveal melanoma can have special psychological needs, which may change as they progress through their care pathway.<sup>31</sup> When their tumor is first diagnosed, they may benefit from psychological counseling aimed at strengthening their coping mechanisms. Patients may also need assistance when selecting the most appropriate kind of treatment, if a choice exists. The author routinely gives every new patient an audiotape recording of the actual conversation after discussing the diagnosis, prognosis, and therapeutic options.<sup>32</sup> After returning home from their initial treatment some patients become depressed, and these can be helped by a proactive telephone call with advice and support from a psychologist or nurse. Additional psychological help may be required if the patient suffers visual loss, cosmetic deformity, or reduced life expectancy.

### ORGANIZATION OF PATIENT CARE

Increasingly, patients with uveal melanoma are being managed by a multidisciplinary team comprising ocular oncologist, general oncologist, radiation oncologist, pathologist, and psychologist. Ocular oncol-

ogy services may also provide logistic assistance as well as information leaflets, internet support, and a telephone helpline.

### FUTURE TRENDS

Predictions regarding future developments may in retrospect prove to be quite mistaken. Nevertheless, some trends are worth considering.

**Non-mydratric fundus camera** The more widespread use of non-mydratric and wide-angle fundus cameras in the community is likely to increase the detection of melanocytic choroidal tumors, many of which will be of indeterminate malignant potential. In such cases, the management of uncertainty will be influenced more strongly by patients, especially if there is shared responsibility for dealing with the unknown risk of delaying treatment. There is likely to be a greater demand for tumor biopsy. With such difficult cases, multicenter randomized and non-randomized trials are necessary to enroll the large number of patients required to determine the correct therapeutic approach.

### Intraocular tumor biopsy and survival prognostication

Tumor biopsy may play a greater role in the management of patients with clinically diagnosed uveal melanoma, this investigation being performed primarily to determine the grade of malignancy and hence the prognosis regarding local tumor control and disease-free survival. Such information may also influence ocular treatment. For example, radiation safety margins may be adjusted according to the tumor activity. Asymptomatic low-grade tumors might be left untreated, especially if the patient is elderly.

**Adjuvant systemic therapy** The availability of highly accurate survival prognostication will inevitably influence patient care. Unless the treatment of detectable metastases improves, patients with a high-grade melanoma will probably create a demand for adjuvant systemic therapy. The development of promising new agents such as anti-angiogenic factors and tumor growth inhibitors would make such treatment more attractive than it is at present. For these reasons, we are likely to see greater efforts to undertake multicenter studies evaluating prognostic scores, screening for metastatic disease, and adjuvant systemic therapy.

**Improved visual outcomes** It is reasonable to expect improved visual results after radiotherapy, owing to a better understanding of the pathophysiology of radiation-induced complications and greater use of treatments such as phototherapy or local resection of the irradiated ‘toxic tumor,’ intravitreal steroid injections, and anti-angiogenic agents.

**Increased patient expectations** Patients’ expectations regarding local tumor control, visual outcome, and other aspects of care are likely to increase, especially if treatment results and patient satisfaction scores become more readily available on the internet. This may influence referral practices, with the referring ophthalmologist selecting an ocular oncology center according to comparative data at their disposal.

**National ocular oncology standards** In some countries, such as Great Britain, designated ocular oncology centers are required to meet national ocular oncology standards, to undergo regular peer review, and to perform patient satisfaction surveys and outcomes



analyses, making the results of these studies available to public scrutiny. It is likely that this practice will become more widespread internationally.

**Clinical trials** Enrolment of patients in clinical trials not only enhances progress but also tends to enhance the quality of care received by the patients participating in such studies. There are many unresolved questions regarding uveal melanomas and their treatment (e.g. juxtapapillary tumors, iris tumors, extraocular extension, etc.) and there is much scope for multicenter collaboration. Patient participation in outcome assessments and formal clinical trials would increase if funding for such studies were somehow to be incorporated into treat-

ment fees, thereby reducing reliance on the whims of grant-awarding bodies.

## CONCLUSION

These trends, together with the formation of new websites and internet discussion groups, will probably raise standards so that patients and their families will expect more comprehensive care, which in addition to treating the ocular tumor adequately addresses a wide variety of social, spiritual, and psychological needs. Such a demand for a more holistic approach could result in patient management being provided less by ophthalmologists in general eye clinics than by specialized ocular oncologists working in multidisciplinary teams.

## REFERENCES

- Damato B. Detection of uveal melanoma by optometrists in the United Kingdom. *Ophthalm Physiol Opt* 2001; 21: 268–271.
- Bove R, Char DH. Nondiagnosed uveal melanomas. *Ophthalmology* 2004; 111: 554–557.
- Eskelin S, Kivelä T. Mode of presentation and time to treatment of uveal melanoma in Finland. *Br J Ophthalmol* 2002; 86: 333–338.
- Shields JA, Shields CL. Atlas of intraocular tumors. Philadelphia: Lippincott Williams & Wilkins, 1999.
- Damato B. Ocular tumours: diagnosis and treatment. Oxford: Butterworth–Heinemann, 2000; 57–93.
- Damato BE. Tumour fluorescence and tumour-associated fluorescence of choroidal melanomas. *Eye* 1992; 6: 587–593.
- Sen J, Groenewald C, Hiscott PS, Smith P, Damato BE. Transretinal choroidal tumor biopsy with a 25-gauge vitrector. *Ophthalmology* 2006; 113: 1028–1031.
- Kujala E, Kivelä T. Tumor, node, metastasis classification of malignant ciliary body and choroidal melanoma: Evaluation of the 6th edition and future directions. *Ophthalmology* 2005; 112: 1135–1144.
- Damato B, Lecuona K. Conservation of eyes with choroidal melanoma by a multimodality approach to treatment: an audit of 1632 patients. *Ophthalmology* 2004; 111: 977–983.
- Prescher G, Bornfeld N, Hirche H et al. Prognostic implications of monosomy 3 in uveal melanoma. *Lancet* 1996; 347: 1222–1225.
- Scholes AG, Damato BE, Nunn J et al. Monosomy 3 in uveal melanoma: correlation with clinical and histologic predictors of survival. *Invest Ophthalmol Vis Sci* 2003; 44: 1008–1011.
- Damato B, Patel I, Campbell IR, Mayles HM, Errington RD. Local tumor control after <sup>106</sup>Ru brachytherapy of choroidal melanoma. *Int J Radiat Oncol Biol Phys* 2005; 63: 385–391.
- Damato B, Patel I, Campbell IR, Mayles HM, Errington RD. Visual acuity after ruthenium(106) brachytherapy of choroidal melanomas. *Int J Radiat Oncol Biol Phys* 2005; 63: 392–400.
- Astrahan MA, Luxton G, Pu Q, Petrovich Z. Conformal episcleral plaque therapy. *Int J Radiat Oncol Biol Phys* 1997; 39: 505–519.
- Gragoudas ES, Marie LA. Uveal melanoma: proton beam irradiation. *Ophthalmol Clin North Am* 2005; 18: 111–118, ix.
- Damato B, Kacperek A, Chopra M, Campbell IR, Errington RD. Proton beam radiotherapy of choroidal melanoma: the Liverpool–Clatterbridge experience. *Int J Radiat Oncol Biol Phys* 2005; 62: 1405–1411.
- Damato B, Kacperek A, Chopra M et al. Proton beam radiotherapy of iris melanoma. *Int J Radiat Oncol Biol Phys* 2005; 63: 109–115.
- Dieckmann D, Georg D, Bogner J et al. Optimizing LINAC based stereotactic radiotherapy of uveal melanomas: 7 years' clinical experience. *Int J Radiat Oncol Biol Phys* 2006; (in press).
- Langmann G, Wackernagel W, Stucklschweiger G et al. [Dose–volume histogram regression analysis of uveal melanomas after single fraction gamma knife radiosurgery]. *Ophthalmologie* 2004; 101: 1111–1119.
- Bartlema YM, Oosterhuis JA, Journee-de Korver JG, Tjho-Heslinga RE, Keunen JE. Combined plaque radiotherapy and transpupillary thermotherapy in choroidal melanoma: 5 years' experience. *Br J Ophthalmol* 2003; 87: 1370–1373.
- Char DH, Bove R, Phillips TL. Laser and proton radiation to reduce uveal melanoma-associated exudative retinal detachments. *Am J Ophthalmol* 2003; 136: 180–182.
- Wachtlin J, Bechrakis NE, Foerster MH. [Photodynamic therapy with verteporfin for uveal melanoma]. *Ophthalmologie* 2005; 102: 241–246.
- Wilson DJ, Klein ML. Choroidal melanoma treated with cryotherapy. *Arch Ophthalmol* 2002; 120: 393–395.
- Damato BE, Foulds WS. Surgical resection of choroidal melanomas. Chapter 40. In: Schachat AP, Ryan SJ, eds. *Retina*, 4th edn. St Louis: Mosby, 2006; 769–778.
- Damato BE, Groenewald C, McGalliard J, Wong D. Endoresection of choroidal melanoma. *Br J Ophthalmol* 1998; 82: 213–218.
- Bechrakis NE, Hocht S, Martus P et al. [Endoresection following proton beam irradiation of large uveal melanomas]. *Ophthalmologie* 2004; 101: 370–376.
- Shields CL, Demirci H, Dai V et al. Intravitreal triamcinolone acetonide for radiation maculopathy after plaque radiotherapy for choroidal melanoma. *Retina* 2005; 25: 868–874.
- Singh AD, Borden EC. Metastatic uveal melanoma. *Ophthalmol Clin North Am* 2005; 18: 143–150, ix.
- Eskelin S, Pyrhonen S, Summanen P, Prause JU, Kivela T. Screening for metastatic malignant melanoma of the uvea revisited. *Cancer* 1999; 85: 1151–1159.
- Finger PT, Kurli M, Wesley P et al. Whole body PET/CT imaging for detection of metastatic choroidal melanoma. *Br J Ophthalmol* 2004; 88: 1095–1097.
- Damato B. Disease and 'dis-ease' in patients with uveal melanoma. *Br J Ophthalmol* 2000; 84: 343–344.
- Ah-Fat FG, Sharma MC, Damato BE. Taping outpatient consultations: a survey of attitudes and responses of adult patients with ocular malignancy. *Eye* 1998; 12: 789–791.

# Uveal malignant melanoma: management options – thermotherapy

Hanneke J.G. Journée-de Korver, Nicoline E. Schalijs-Delfos and Saskia M. Imhof

## INTRODUCTION

The heat treatment modalities for intraocular tumors include photocoagulation, hyperthermia, and thermotherapy. In this chapter we summarize the technique, indications, contraindications, and reported outcomes of transpupillary thermotherapy.

## PHOTOCOAGULATION

Photocoagulation involves heating of the tumor to temperatures above 65°C. The technique was first described by Meyer-Swickerath in 1949.<sup>1</sup> Other authors subsequently reported their results with light sources such as argon green, using brief applications, and with krypton red, using low-energy and prolonged applications.<sup>2</sup> Photocoagulation as primary treatment has largely been abandoned because it caused excessive retinal complications and provided only inadequate local tumor control.

## HYPERTHERMIA

Hyperthermia implies raising the tumor temperature to 42–45°C. Hyperthermia can be induced by microwave, ultrasound, and a localized current field or ferromagnetic thermoseeds. Hyperthermia makes tumor cells more sensitive to radiotherapy by inactivating the cellular enzymes needed to repair radiation-induced damage. Therefore, combining hyperthermia with radiation allows a reduction of the radiation dose, resulting in a lesser likelihood of radiation retinopathy (12.8%)<sup>3</sup> compared to patients treated with radiotherapy alone (39%).<sup>4</sup>

## THERMOTHERAPY

Thermotherapy bridges the gap between photocoagulation and hyperthermia. During thermotherapy the tumor is heated to a temperature of 60–65°C by means of an infrared diode laser introduced via the pupil (transpupillary thermotherapy, TTT). TTT was introduced by Oosterhuis and co-workers in 1994.<sup>5</sup> A greater depth of tumor necrosis is achieved with TTT than with photocoagulation. Unlike hyperthermia, the cytotoxic effects of TTT are irreversible (Box 40.1).

**Experimental aspects** The infrared laser light used for TTT is mainly absorbed by melanin in the retinal pigment epithelium and in the superficial layers of the tumor, where it is converted into heat.<sup>6</sup> Heat spreads into deeper layers by conduction and transfer through the vascular system.<sup>7</sup> Diode laser light (810nm) provides optimal tissue absorption, as less than 5% of the incident light is absorbed by the normal ocular media.<sup>8</sup> The heat-induced necrosis of TTT is caused

predominantly by a direct thermal effect, and to a lesser extent by ischemia from vascular occlusion.<sup>9</sup>

Histopathology after experimental TTT with a single 1-minute application shows tumor necrosis and occlusion of tumor vessels up to a maximum depth of 3.9 mm.<sup>10</sup> Scattered small hemorrhages, if present, are observed only in the transitional zone of 0.15–0.7 mm between the necrotic and viable parts of the tumor, where the temperature is sufficient to damage the vessel walls but insufficient to cause thrombosis (Fig. 40.1).

## Indications

**TTT as sole treatment** In principle, by inducing an irreversible cytotoxic effect TTT can be applied as sole therapy for choroidal melanoma. Visual outcome may be better following TTT than after plaque radiotherapy because the laser beam can be focused on the target area more precisely than the ionizing radiation. Initial results with primary TTT appeared promising regarding tumor control as well as visual acuity.<sup>11</sup> However, high rates of local tumor recurrence have been reported.<sup>11,12</sup> This may be explained by the lower absorption of infrared light by the non-pigmented sclera, resulting in insufficient heating of the intrascleral tumor cells, which may be present in half of patients (Fig. 40.1).<sup>13</sup> The high rate of late recurrences has diminished enthusiasm for TTT as sole therapy, which is now reserved for small tumors less than 3 mm thick.<sup>12,14</sup>

## TTT combined with plaque radiotherapy (sandwich therapy)

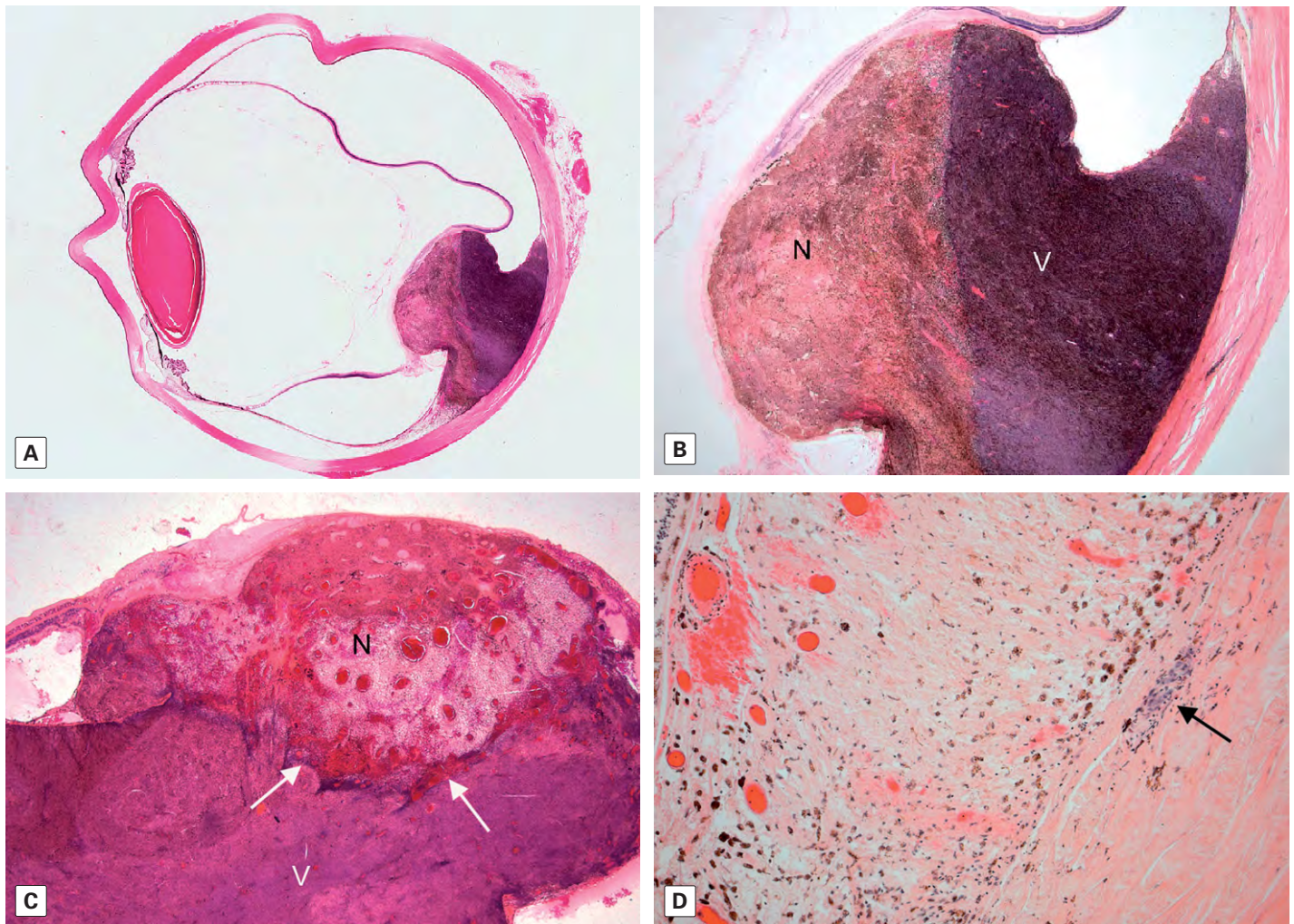
To avoid insufficient treatment of the sclera, a combination of TTT and plaque radiotherapy may be considered.<sup>15</sup> The two treatment modalities are complementary to each other, as TTT destroys approximately 3 mm of the superficial part of the tumor, and plaque radiotherapy adequately treats the deeper portions of the tumor as well as the underlying sclera (Fig. 40.2).

**Secondary TTT** In selected cases secondary TTT may be useful when there is a lack of adequate tumor regression after radiotherapy; for local tumor recurrence after radiotherapy or local resection;<sup>16</sup> and for radiation-induced tumor exudation following plaque or proton beam radiotherapy.<sup>17</sup>

**Contraindications** TTT is contraindicated in patients with media opacities that obscure the retinal image; insufficient dilatation of the pupil; peripherally located tumors; pretreatment subretinal fluid measuring more than 3 mm in elevation,<sup>14,15</sup> and tumor basal diameter

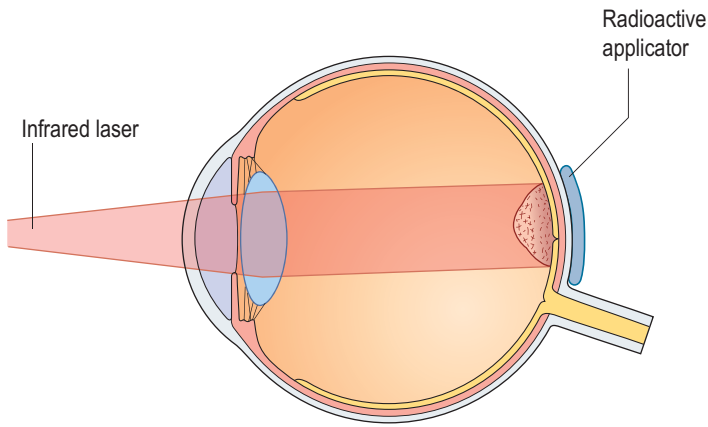
**BOX 40.1 Essential Features of Transpupillary Thermotherapy**

- Indicated for small, posterior tumors not involving the optic disc
- Administered with a 3mm diode laser beam
- Heats the tumor to 60–65°C for about 1 minute
- Is preferably administered with adjunctive radiotherapy
- Is useful after radiotherapy for tumor recurrence or exudation
- Can be augmented using indocyanine green



**Fig. 40.1** Experimental pre-enucleation single 1-minute TTT application to a choroidal melanoma (height 7.3 mm). **(A)** Enucleation was performed 72 hours later. On histopathology the cornea, lens, and vitreous remain clear. **(B)** Higher magnification clearly shows the sharp demarcation between the necrotic (N) and viable (V) parts of the tumor. Atrophy of the retina overlying the tumor corresponds to the diameter of the laser spot. **(C)** Experimental pre-enucleation single 1-minute TTT application to a choroidal melanoma (height 9.1 mm). Enucleation was performed 48 hours later. Histopathology reveals tumor necrosis to a depth of 3.9 mm. All the blood vessels in the necrotic area are dilated and occluded with thrombi. Scattered small hemorrhages are present in the transitional zone (arrows) between the necrotic and viable parts of the tumor. **(D)** Experimental pre-enucleation single 1-minute TTT application to a choroidal melanoma (height 2.0 mm). Enucleation was performed 20 hours later. Histopathology demonstrates tumor necrosis bordering on the sclera and intrascleral tumor cells (arrow) appear viable. Intrascleral cells may not be adequately heated due to the low absorption of infrared light by the non-pigmented sclera.





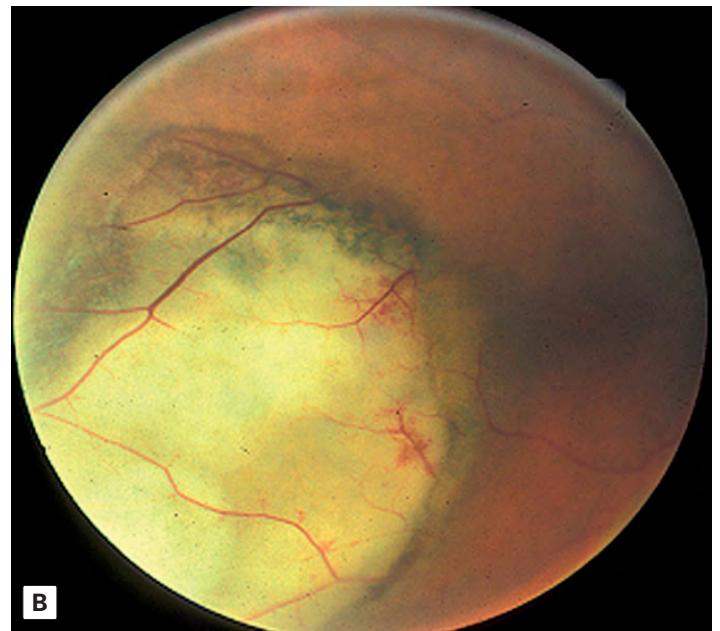
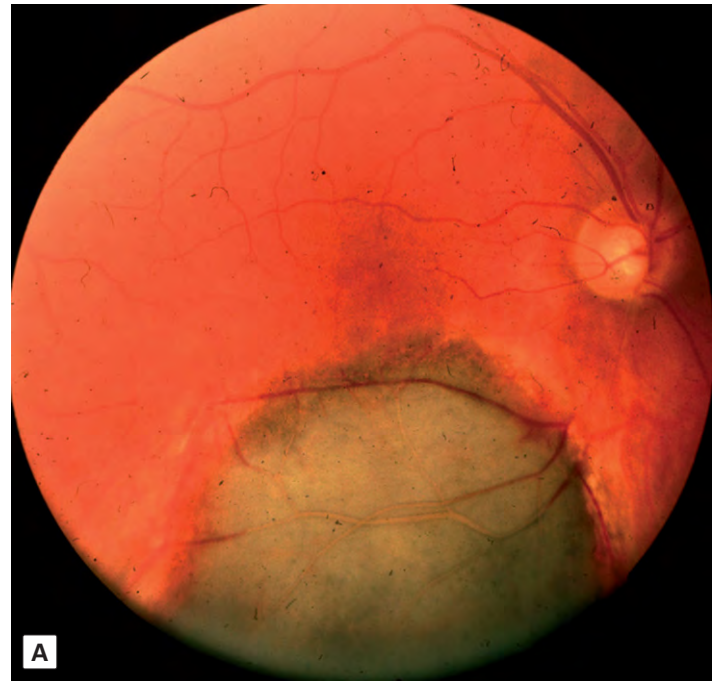
**Fig. 40.2** Schematic drawing of TTT combined with brachytherapy – ‘sandwich therapy.’ The two treatment modalities are complementary to each other. TTT destroys the superficial part of the tumor and radiotherapy treats the deeper areas as well as the underlying sclera.



**Fig. 40.3** The infrared diode laser at 810nm (Iris, Mountain View, California, USA), which is attached to a slit lamp (Haag-Streit, Bern, Switzerland).

exceeding 10 mm and/or thickness more than 4 mm for TTT as sole treatment.

**Technique** Transpupillary thermotherapy is performed as an outpatient procedure. A laser beam diameter varying from 2 to 3 mm and a 1-minute exposure time is used. The infrared diode laser (810 nm) is attached to a slit lamp, an operating microscope, or a binocular indirect ophthalmoscope (Fig. 40.3). Prior to treatment the pupil is dilated and paralytic anesthesia administered.<sup>18,19</sup> The laser beam is directed at the tumor apex through a contact lens with infrared anti-reflective coating. The entire surface of the tumor is covered by overlapping applications extending at least 1.5 mm beyond its margin. Treatment starts with a central 1-minute application on the tumor apex at a relatively low laser power. In the authors’ experience the power setting is begun at 450 mW in normal pigmented tumors, at 600 mW in amelanotic tumors, and at 300 mW laser output power in heavily



**Fig. 40.4** Fundus photograph showing an inferior choroidal melanoma measuring  $10.7 \times 10.4 \times 2.8$  mm that was treated with sandwich therapy. Note the grayish discoloration of tumor tissue after TTT, indicating that a subphotocoagulation-level temperature has been achieved (A). Laser power settings producing a prematurely white coagulation effect should be avoided because the increased reflection and scatter restricts the depth penetration of heat, resulting in only superficial damage to the tumor (B).

pigmented tumors. The energy is raised in a stepwise fashion after each 1-minute exposure until the tumor tissue shows a grayish discoloration after 30–40 seconds, indicating that a sub-photocoagulation temperature has been achieved (Fig. 40.4). It is imperative to apply each application for 1 minute to obtain optimal depth penetration of heat, as it takes 20 seconds to reach a steady state of temperature in the tumor. Exposure times of more than 1 minute do not improve the depth of necrosis.<sup>20</sup> Laser power settings that produce a bright white coagulation effect should be avoided because the increased

reflection and scatter will restrict the depth penetration of the heat, resulting in only superficial damage (Fig. 40.4). Tumor necrosis with vascular occlusion is obvious after a few days. Clearance of the necrotic debris takes 3–4 months, which is faster than after radiotherapy. The sharp demarcation between the heat-treated area and the unaffected surroundings is due to the normal choroid adjacent to the field of thermotherapy acting as a heat sink. Complete flattening of the tumor is not an obligatory endpoint of the treatment. An increase in internal reflectivity on ultrasonography as well as a non-fluorescent residual scar on fluorescein angiography is indicative of successful tumor control. However, in rare instances, viable tumor cells may be present within the non-fluorescent scar manifesting subsequently as a recurrent tumor.

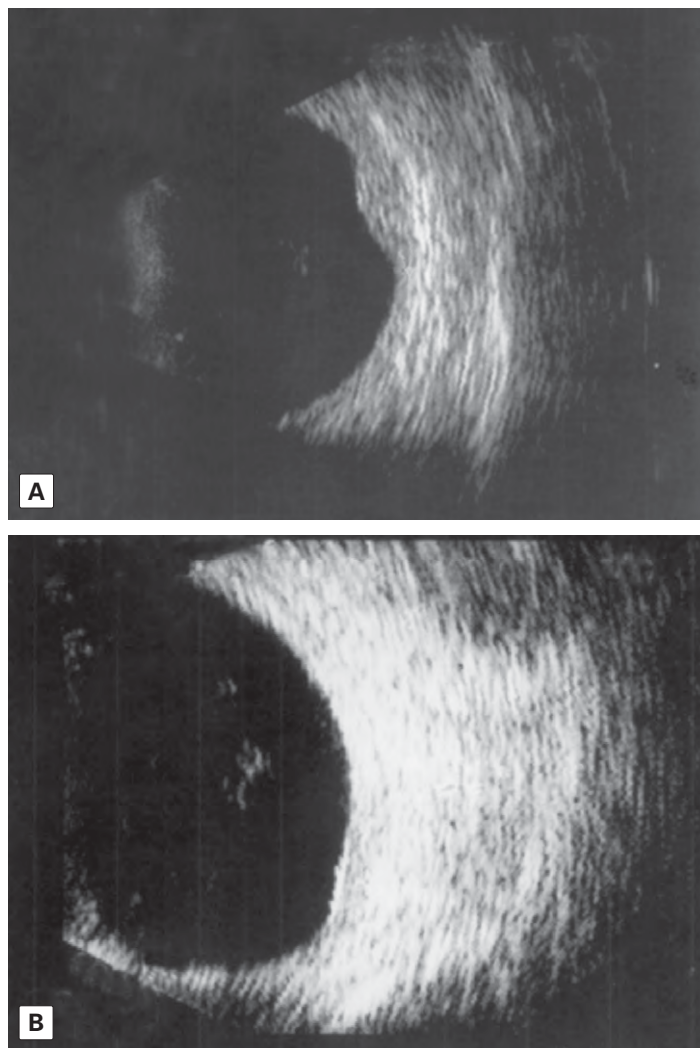
**Augmentation with indocyanine angiography** Heating amelanotic tumors to 60–65°C requires up to 50% more laser power than is used for pigmented tumors.<sup>18,19</sup> The response of TTT in amelanotic melanomas can be enhanced by the intravenous injection of ICG, because the green dye can be used as an absorber of infrared light. The effect is optimal when ICG is administered 30 minutes before TTT.<sup>20</sup> However, the efficacy of this approach is disputed.<sup>21,22</sup>

**Combination with plaque radiotherapy (sandwich technique)** When TTT is administered as part of sandwich therapy it is delivered after radiotherapy because TTT-induced edema may obscure the tumor margin, making positioning of the plaque more difficult. There is also a theoretical concern about the induction of radioresistance by ischemia caused by TTT. Oosterhuis and associates<sup>23</sup> recommend a scleral contact dose for ruthenium-106 plaques of 400 Gy for tumors of 5 mm, and 600 Gy for tumors more than 5 mm. Others prefer a lower dose of 200–300 Gy.<sup>24,25</sup>

**Follow-up** After TTT, patients are reviewed and examined every 2–3 months by ophthalmoscopy and ultrasonography. As a rule the tumor shows gradual regression, eventually resulting in either an area of choroidal atrophy or a hypertrophic retinal pigment epithelial scar. Ultrasonography shows a gradual increase in internal reflectivity together with a gradual reduction in tumor thickness (Fig. 40.5). Fluorescein angiography is not required, but shows the treated area to be relatively hypofluorescent, with well-defined margins (Fig. 40.6). With ultrasonography, special attention should be paid to the retrobulbar region, to exclude extraocular recurrence.<sup>26,27</sup>

## Results

**Tumor control** TTT as sole treatment induces flattening of small melanomas after a single or repeated session. Treatment of melanomas measuring 2.2–4.0 mm thick is successful, with a reduction in tumor thickness to a flat scar in over 90% of cases.<sup>11,12,14,28–30</sup> The number of treatment sessions ranges from one to six. In patients treated with ‘sandwich therapy’ a reduction in thickness to a flat scar in tumors originally up to 8 mm thick was found in 82% of patients after a mean follow-up of 20.5 months.<sup>18</sup> Results after a mean follow-up of 5 years indicate successful tumor regression in 62% of patients within 1 year, in 78% within 2 years, and in 90% within 5 years.<sup>23</sup> Other studies showed local tumor control in 97% at 5 years’ follow-up,<sup>25</sup> and complete flattening in half of the patients after 3 months.<sup>28</sup> Complete regression in 18 patients and partial regression in 11 was found for juxtapapillary or juxtafoveal melanomas after a mean follow-up of 20 months.<sup>24</sup>



**Fig. 40.5** B-scan ultrasonography 1 year after radiotherapy showing a choroidal melanoma measuring 12.3 × 11.8 × 4.1 mm (A). Two months after the second TTT application, the tumor is reduced to a flat scar (B).

## Tumor recurrence

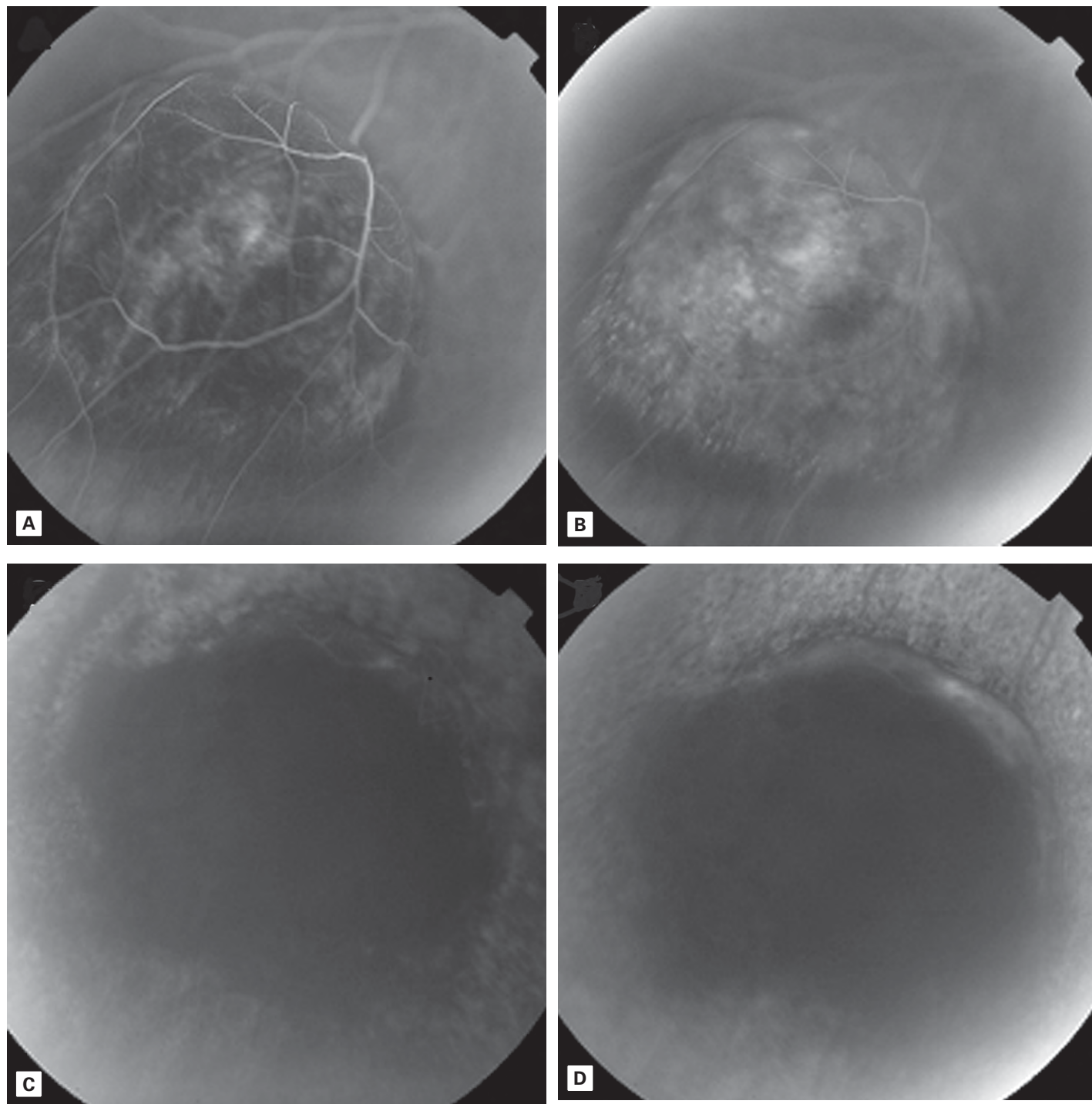
**Incidence** Kaplan–Meier estimates for recurrence in 256 consecutive cases treated only with TTT were 4% at 1 year, 12% at 2 years, and 22% at 3 years’ follow-up.<sup>12</sup> However, the recurrence rate following sandwich therapy is much lower (3–4% at 5 years).<sup>23,25</sup> The high rate of recurrence after TTT alone is perhaps due to low absorption of infrared light by the non-pigmented sclera and consequent insufficient heating of the intrascleral tumor cells (see Fig. 40.1).

**Clinical features** In general, tumor recurrences are observed at a mean interval of about 2 years following TTT, emphasizing the need for prolonged careful follow-up. Failure of local tumor control can be marginal, central, or external.

MARGINAL RECURRENCE is more frequent than central recurrence. Marginal recurrence has the appearance of indistinct, gray or brown discoloration and thickness of the choroid adjacent to the TTT scar (Fig. 40.7).

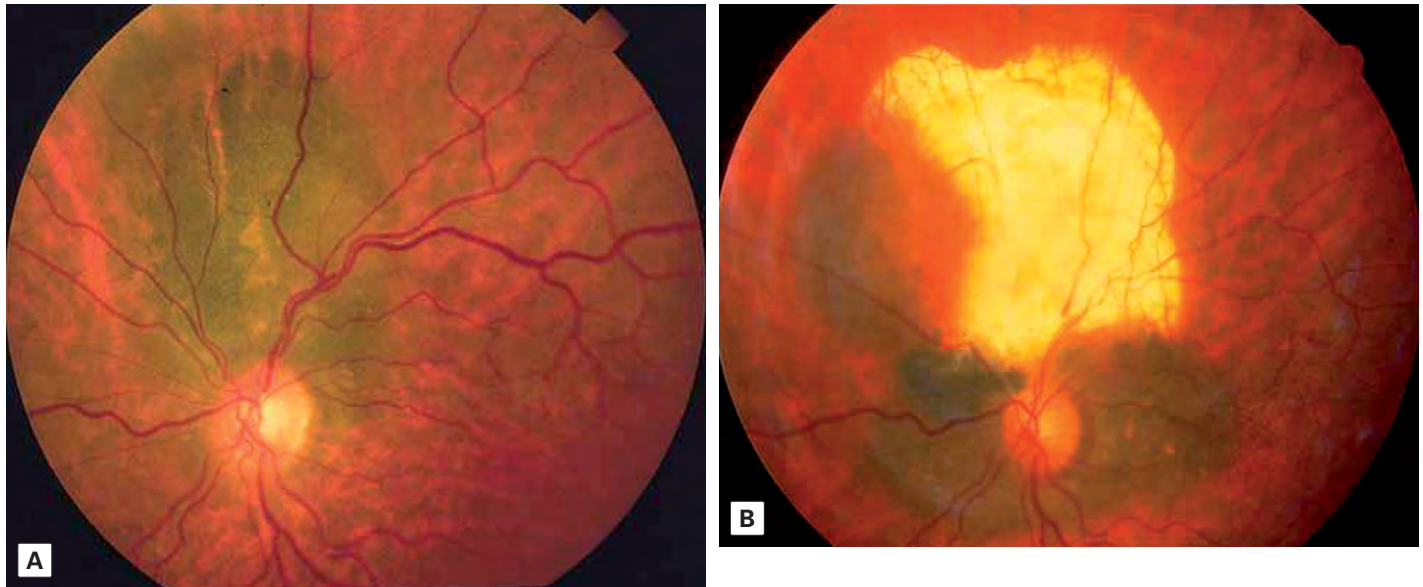
CENTRAL RECURRENCE manifests as an increase in the thickness of the scar (Fig. 40.8).





**Fig. 40.6** Pretreatment fluorescein angiography, (A) early and (B) late phases. Post-treatment fluorescein angiography, (C) early and (D) late phases. Note the sharp demarcation between the non-fluorescent, avascular heat-treated area and the unaffected surrounding tissues. This is because the choroid adjacent to the field of thermotherapy acts as a heat sink.





**Fig. 40.7** Marginal recurrence following TTT. (A) Before transpupillary thermotherapy. (B) Fifteen months after transpupillary thermotherapy, with recurrence along the posterior margin. Enucleation was performed. (Reproduced with permission from Shields CL, Shields JA, Perez N, Singh AD, Cater J. Primary transpupillary thermotherapy for choroidal melanoma in 256 consecutive cases. Outcomes and limitations. *Ophthalmology* 2001; 23: 763–767.)

**EXTRAOCULAR RECURRENCE** Another presentation of recurrence following TTT is the development of an extraocular nodule despite apparently complete regression of the tumor on ophthalmoscopy (Fig. 40.9).<sup>26,27</sup> External recurrence may be easily overlooked unless ultrasonography is performed on a routine basis, even when the ophthalmoscopy reveals a flat and regressed tumor. Local treatment failure is more likely with juxtapapillary tumors and with amelanotic melanomas.<sup>28</sup>

**Treatment of tumor recurrence** The treatment of tumor recurrence following TTT depends upon its extent, location, associated complications, visual potential, and the patient's preference. Therapeutic options include additional TTT, plaque radiotherapy, and enucleation.

**Visual results** The visual outcome depends on the size and location of the original tumor. Inevitably, the laser treatment destroys the retina overlying the tumor, immediately inducing a scotoma corresponding to the treated area and a nerve fibre bundle defect extending peripherally from this scotoma. Initial results after primary TTT appeared promising, as visual acuity remained stable or improved in 47%,<sup>27</sup> 58%,<sup>11</sup> and 75% of cases.<sup>14</sup> A study of 256 consecutive cases mentioned a visual acuity of 20/20–20/40 in 50%, 20/50–20/100 in 18%, and 20/200 or worse in 32% of patients.<sup>12</sup> Another study with 36 tumors did not show a significant difference in the mean visual outcome after TTT alone as compared to plaque radiotherapy. However, in this study tumor location was not taken into consideration.<sup>31</sup>

Radiation retinopathy, the main cause of loss of vision, is observed in 39–58% of patients after sandwich therapy.<sup>23,25</sup> A pretreatment visual acuity of 20/60 or better, present in 82% of patients, remained in 60% after 6 months, in 30% after 1 year, but in only in 18% after 5 years.<sup>23</sup> An important difference between TTT and radiotherapy of macular tumors is that with TTT the visual loss is immediate and inevitable, whereas with radiotherapy central visual loss is usually delayed for 1–2 years and is not inevitable.

## Complications

**Posterior segment complications** Most complications of TTT are limited to the posterior segment.<sup>26</sup> Fine superficial hemorrhages at the tumor apex are commonly observed after TTT, as well as a transient increase in subretinal fluid that resolves within weeks. Branch retinal artery and vein occlusion can occur if excessive laser power is used. Retinal traction folds and epiretinal membranes may occur in 20% of cases.<sup>23</sup> Visual field effects corresponding to the areas of retinal atrophy and vascular occlusions are not unexpected. Subretinal pigment dispersion could be mistaken for a recurrent tumor.<sup>32</sup> Proliferative vitreoretinopathy may occur following multiple applications of TTT.<sup>23</sup>

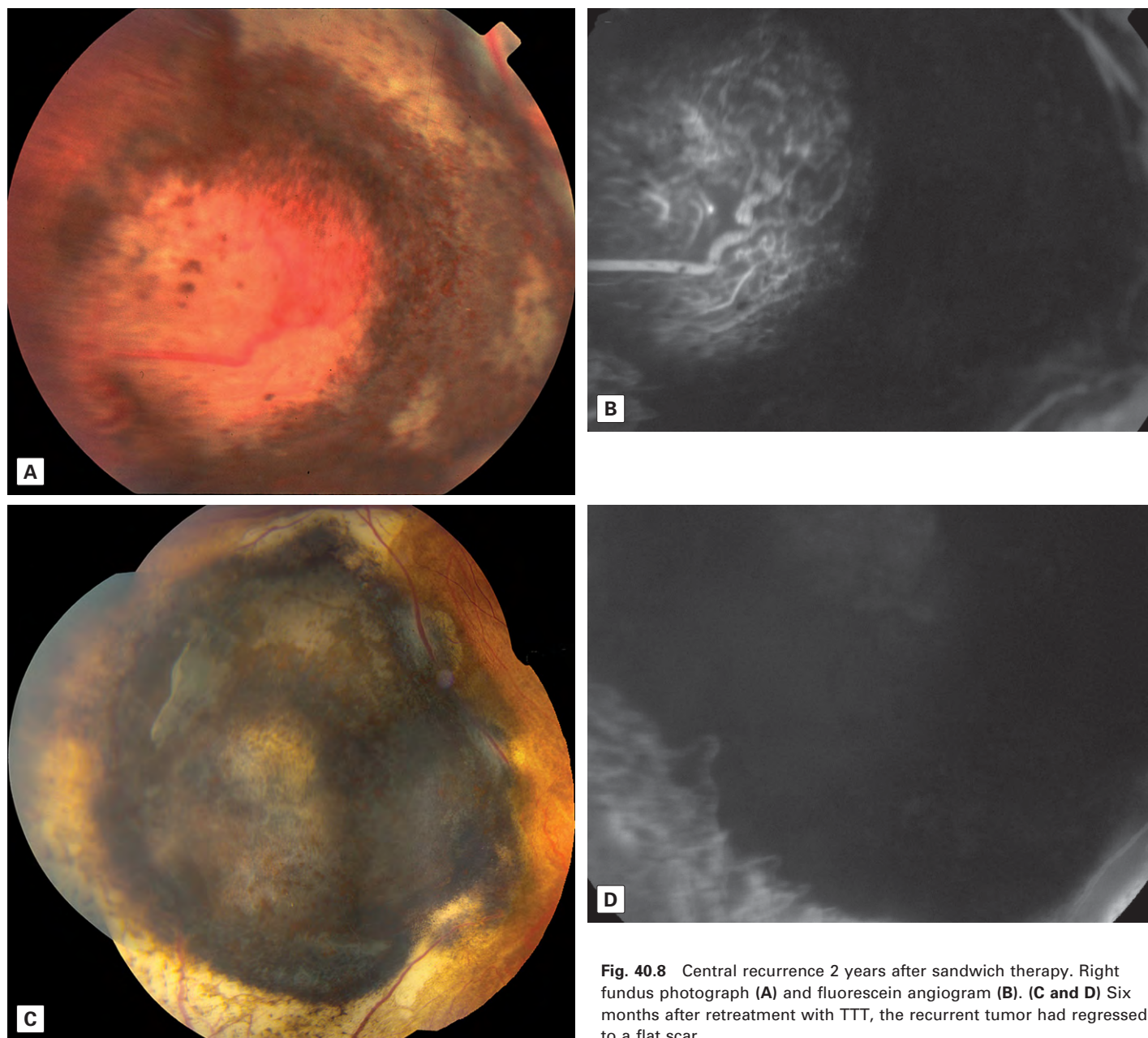
**Anterior segment complications** Occasionally, mild inflammation may be observed after TTT. Focal iris atrophy with posterior synechiae and a sectoral, non-progressive cataract may occur when the laser beam accidentally hits the pupillary margin.

## CONCLUSIONS

Transpupillary thermotherapy was originally advocated for use in combination with plaque radiotherapy, enabling conservative treatment of larger tumors than those that could be treated with ruthenium-106 plaque radiotherapy alone. Treatment with TTT alone has been reported, but is associated with an increased risk of local tumor recurrence. TTT can effectively treat residual or recurrent tumors after radiotherapy, thereby reducing the need for enucleation.<sup>5</sup> It is also effective as a treatment for exudative complications of radiotherapy.<sup>17</sup> Special care must be taken to avoid using excessive laser energy, which induces rapid retinal opacification: consequently there is a reduced effect on the tumor and an increased risk of retinal complications. Trans-scleral thermotherapy is currently under investigation as a safer alternative to radiotherapy.<sup>33</sup>

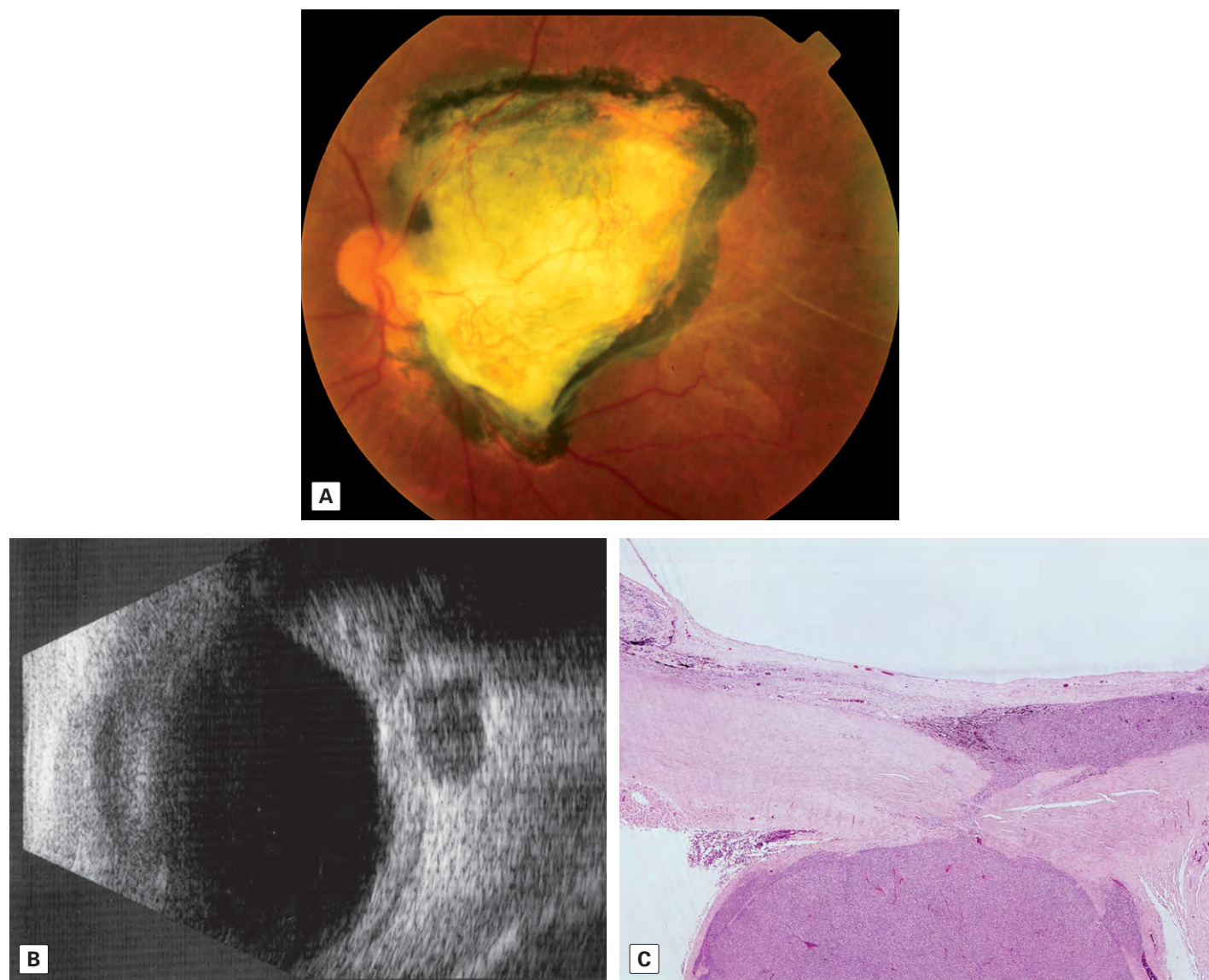
## ACKNOWLEDGEMENT

The authors wish to thank K.G. van der Ham for his photographic expertise.



**Fig. 40.8** Central recurrence 2 years after sandwich therapy. Right fundus photograph (A) and fluorescein angiogram (B). (C and D) Six months after retreatment with TTT, the recurrent tumor had regressed to a flat scar.





**Fig. 40.9** External recurrence following TTT. Fundus photograph showing fibrotic membrane with fine retinal neovascularization at the treated site of small choroidal melanoma following three sessions of TTT **(A)**. **(B)** B-scan ultrasonography demonstrated a nodular extrascleral extension along the base of the original tumor. **(C)** Photomicrograph of the posterior pole of the eye with an extensive chorioretinal scar at the site of thermotherapy. Residual deep choroidal tumour extends via a scleral canal to the extrascleral tumour nodule. (Reproduced with permission from Singh AD, Rundle PA, Berry-Brincat A, Parsons MA, Rennie IG. Extrascleral extension of choroidal malignant melanoma following transpupillary thermotherapy. *Eye* 2004; 18: 91–93.)

## REFERENCES

- Meyer Schwicklerath G, Vogel MH. Malignant melanoma of the choroid treated with photocoagulation. A 10-year follow-up. *Mod Probl Ophthalmol* 1974; 12: 544–549.
- Foulds WS, Damato BE. Low-energy long-exposure laser therapy in the management of choroidal melanoma. *Graefes Arch Clin Exp Ophthalmol* 1986; 224: 26–31.
- Finger PT. Microwave thermoradiotherapy for uveal melanoma: results of a 10 year study. *Ophthalmology* 1997; 104: 1794–1803.
- Packer S, Stoller S, Lesser ML et al. Long-term results of iodine 125 irradiation of uveal melanoma. *Ophthalmology* 1992; 99: 767–774.
- Oosterhuis JA, Journée-de Korver JG, Kakebeeke-Kemme HM et al. Transpupillary thermotherapy in choroidal melanoma. *Arch Ophthalmol* 1995; 113: 315–321.
- Journée-de Korver HG, Midena E, Singh AD. Infrared thermotherapy: from laboratory to clinic. *Ophthalmol Clin North Am* 2005; 18: 99–110.
- Svaasand LO, Morinelli E, Gomer CJ et al. Optical characteristics of intraocular tumors in the visible and near infrared. *Spie Photodynamic Therapy. Mechanics II* 1990; 1203: 1–11.
- Van den Berg TJ, Spekrijse H. Near infrared light absorption in the human eye media. *Vision Res* 1997; 37: 249–253.
- Journée-de Korver JG, Oosterhuis JA, Vrensen GFJM. Light and electron microscopic findings on experimental melanomas after hyperthermia at 50°C. *Melanoma Res* 1992; 5: 393–402.
- Journée-de Korver JG, Oosterhuis JA, de Wolff-Rouendaal D et al. Histopathological findings in human choroidal melanomas after transpupillary thermotherapy. *Br J Ophthalmol* 1997; 81: 234–239.
- Shields CL, Shields JA, Cater J et al. Transpupillary thermotherapy for choroidal melanoma: tumor control and visual results in 100 consecutive cases. *Ophthalmology* 1998; 105: 581–590.
- Shields CL, Shields JA, Perez N et al. Primary transpupillary thermotherapy for small choroidal melanoma in 256 consecutive cases: outcomes and limitations. *Ophthalmology* 2002; 109: 225–234.
- Journée-de Korver HJG, Schalijs-Delfos NE, Imhof SM. Transpupillary thermotherapy of choroidal melanoma. COMS Report no 6. *Am J Ophthalmol* 1998; 125: 745–766.



14. Robertson DM, Buettner H, Bennett SR. Transpupillary thermotherapy as primary treatment for small choroidal melanomas. *Arch Ophthalmol* 1999; 117: 1512–1519.
15. Keunen JEE, Journée-de Korver JG, Oosterhuis JA. Transpupillary thermotherapy with or without brachytherapy: a dilemma. *Br J Ophthalmol* 1999; 83: 987–988.
16. Robertson DM. TTT as rescue treatment for choroidal melanoma not controlled with iodine-125 brachytherapy. *Ocul Immunol Inflamm* 2002; 10: 247–252.
17. Damato B, Patel I, Campbell IR, Mayles HM, Errington RD. Local tumor control after (106)Ru brachytherapy of choroidal melanoma. *Int J Radiat Oncol Biol Phys* 2005; 63: 385–391.
18. Oosterhuis JA, Journée-de Korver JG, Keunen JEE. Transpupillary thermotherapy: results in 50 patients with choroidal melanoma. *Arch Ophthalmol* 1998; 116: 157–162.
19. Journée-de Korver JG, Keunen JEE. Thermotherapy in the management of choroidal melanoma. *Prog Retinal Eye Res* 2002; 21: 303–317.
20. Journée-de Korver JG, Verburg-van der Marel EH, Oosterhuis JA et al. Tumoricidal effect of hyperthermia by near infrared irradiation on pigmented hamster melanoma. *Laser Light Ophthalmol* 1992; 4: 175–180.
21. Stoffels BM. Kinetics of indocyanine green (ICG) and clinical use for enhancement of transpupillary thermotherapy (TTT) in hypopigmented small choroidal melanomas. *Klin Monatsbl Augenheilkd* 2004; 221: 374–378.
22. De Potter P, Jamart J. Adjuvant indocyanine green in transpupillary thermotherapy for choroidal melanoma. *Ophthalmology* 2003; 110: 406–413.
23. Bartlema YM, Oosterhuis JA, Journée-de Korver JG et al. Combined plaque radiotherapy and transpupillary thermotherapy in choroidal melanoma: 5 years' experience. *Br J Ophthalmol* 2003; 87: 1370–1373.
24. Seregard S, Landau I. Transpupillary thermotherapy as an adjunct to ruthenium plaque radiotherapy for choroidal melanoma. *Acta Ophthalmol Scand* 2001; 79: 19–22.
25. Shields CL, Cater J, Shields JA et al. Combined plaque radiotherapy and transpupillary thermotherapy for choroidal melanoma. Tumor control and treatment complications in 270 consecutive patients. *Arch Ophthalmol* 2002; 120: 933–940.
26. Singh AD, Eagle RC Jr, Shields CL, Shields JA. Enucleation following transpupillary thermotherapy of choroidal melanoma: clinicopathologic correlations. *Arch Ophthalmol* 2003; 121: 397–400.
27. Singh AD, Rundle PA, Berry-Brincat A, Parsons MA, Rennie IG. Extrascleral extension of choroidal malignant melanoma following transpupillary thermotherapy. *Eye* 2004; 18: 91–93.
28. Keunen JEE, Bleeker JC, Journée-de Korver JG, Oosterhuis JA, van Best JA. Juxtapapillary melanomas and transpupillary thermotherapy. *Invest Ophthalmol Vision Sci* 1997; 38: S720.
29. Godfrey DG, Waldron RG, Capone A. Transpupillary thermotherapy for small choroidal melanoma. *Am J Ophthalmol* 1999; 128: 88–93.
30. Schneider H, Fischer K, Fietkau R et al. Transpupillary thermotherapy of choroidal melanoma. *Klin Monatsbl Augenheilkd* 1999; 214: 90–95.
31. Harbour JW, Meredith TA, Thompson PA et al. Transpupillary thermotherapy versus plaque radiotherapy for suspected choroidal melanomas. *Ophthalmology* 2003; 110: 2207–2214.
32. Kiratli H, Bilgic S. Subretinal pigment dispersion following transpupillary thermotherapy for choroidal melanoma. *Acta Ophthalmol Scand* 2002; 80: 401–404.
33. Rem AI, Oosterhuis JA, Journée-de Korver JG et al. Transscleral thermotherapy with laser-induced and conductive heating in hamster Greene melanoma. *Melanoma Res* 2004; 14: 409–414.

# Uveal malignant melanoma: management options – brachytherapy

Stefan Seregard, Bertil Damato and Peter Fleming

## INTRODUCTION

Moore first used brachytherapy for uveal melanoma in 1930 by inserting radon-222 seeds into the tumor.<sup>1</sup> This technique was later modified by Stallard, and eventually further refined using radioactive plaques containing cobalt-60 anchored to the episcleral surface.<sup>2,3</sup> In the United States, this radionuclide was gradually replaced by plaques loaded with iodine-125 seeds, as this provided less radiation to surrounding tissues.<sup>4,5</sup> In Europe, the pioneering work of Lommatzsch in the 1970s led to the introduction of ruthenium-106 as a radioactive source for episcleral brachytherapy of uveal melanoma.<sup>6</sup> Although observational data suggested that there was no survival difference compared to patients enucleated for uveal melanoma, the Collaborative Ocular Melanoma Study (COMS) was launched in the mid-1980s and included patients with medium-sized uveal melanoma randomized to either enucleation or iodine brachytherapy.<sup>7</sup> During the late 1980s and 1990s, and in parallel with the COMS recruitment and trial period, episcleral brachytherapy evolved into one of the most commonly used modalities for treating patients with posterior uveal melanoma (Box 41.1).

## RADIATION

Brachytherapy (after the Greek *brachy*, meaning a short distance) refers to the implantation of radioactive material either within or close to the tumor. A nuclide is a type of atom specified by its unique combination of protons and neutrons and its energy state. Isotopes of the same element differ in the number of neutrons. Radionuclides and radioisotopes decay into more stable forms, emitting ionizing radiation, which has the capacity to displace electrons from atoms or molecules and thereby create ions. Tissue absorption of ionizing radiation breaks chemical bonds and forms free radicals, causing DNA damage, loss of reproductive capacity and, if repair mechanisms are overwhelmed, cell death. The absorbed dose is usually measured in Grays (Gy), with 1 Gray being equal to 1 Joule of energy absorbed by 1 kg of tissue.

In general, cancers with a large proportion of dividing cells (e.g. retinoblastoma) are more radiosensitive than those with a lower cell turnover (e.g. uveal melanoma). The acute effects of radiation include breakdown of cell membranes, cell death, and edema. Late effects, which can take years to develop, include fibrosis and vascular decompensation. Because of the dose gradient in episcleral plaque radiotherapy, the most severe effects are seen at the tumor base, where the dose of radiation is the highest.

## EPISCLERAL RADIOACTIVE PLAQUE

The radionuclides used for episcleral brachytherapy of uveal melanoma include cobalt-60 (now obsolete), ruthenium-106,<sup>8,9</sup> iodine-125,<sup>10–12</sup> palladium-103,<sup>13</sup> gold (aurum)-198,<sup>14</sup> iridium-192,<sup>15</sup> and strontium-90 (Table 41.1).<sup>16</sup> Some radionuclides emit almost only  $\beta$  particles, with a minimal  $\gamma$  component (e.g. ruthenium-106), and others emit  $\beta$  particles plus a significant high-energy  $\gamma$ /X-ray component (e.g. cobalt-60) or a pure low-energy  $\gamma$ /X-ray component (e.g. iodine-125).

**Plaque design** Most episcleral plaques are bowl shaped and usually about 15–20 mm in diameter. The inner part contains the radioactive sources, which are either integrated in the plaque or held in place by glue or a silicon mold (Fig. 41.1). The outer surface is lined by a heavy metal, such as silver or gold, to prevent the radiation of tissues external to the eye. Two or more eyelets near the edge of the plaque allow the plaque to be sutured to the episcleral surface.

**Dosimetry** Typically, the total dose provided and the radioactive dose per time unit of exposure (dose rate) are estimated at various distances from the radioactive source. The optimal tumoricidal dose ranges from 80 to 100 Gy. A higher dose tends to increase ocular morbidity, whereas a lower dose may cause inadequate local tumor control. Dosimetry for episcleral plaques is calculated by different methods but the results are reasonably consistent.<sup>17</sup> There have been shortcomings in plaque manufacture and dosimetry (e.g. radiation leakage and inaccurate dose specifications), and so it is important for hospitals to check each new plaque before it is used.

## TREATMENT

**Preoperative assessment** The basal diameter and height of the tumor are measured by funduscopy, fundus photographs, ultrasonography (standardized A- and B-scans) and transillumination, individually or in any combination. A correct estimate of the largest basal diameter is important for the selection of an appropriately sized plaque, and often a 2 mm safety margin around the tumor is added. The height measurement is usually obtained by ultrasonography and is critical for calculation of the appropriate delivery time and hence the radiation dose. Most centers deliver an apex dose of 80–100 Gy, so that the sclera receives a much higher dose of radiation, particularly if the tumor is thick. There is no agreed maximum scleral dose, but up to 1500 Gy using ruthenium-106 have been administered without scleral necrosis.<sup>8</sup> Some centers administer a minimum scleral dose of

300 Gy so that choroidal atrophy becomes visible within 6 months of treatment, thereby providing ophthalmoscopic evidence of the adequacy of plaque placement.<sup>9</sup>

**Plaque positioning** Correct plaque positioning at the time of surgery is essential for a good clinical outcome. General anesthesia is believed by some to facilitate correct positioning,<sup>9</sup> but local anesthesia

#### BOX 41.1 Brachytherapy of Uveal Melanoma

- Administered with plaques containing iodine-125 ruthenium-106
- Delivers a minimum apex dose of 80–100 Gy
- May be combined with TTT
- Can cause damage to ocular tissue, especially with large tumors
- The most common complications include optic neuropathy, maculopathy, cataract, and neovascular glaucoma
- Survival is not significantly worse than after enucleation

**Table 41.1 Characteristics of radionuclides used for brachytherapy of uveal melanoma**

Element	Nuclide	Energy (MeV)	Half-life
Cobalt	Co-60	1.25	5.26 years
Iodine	I-125	2.392	59.4 days
Ruthenium	Ru-106	6.547	373.6 days
Iridium	Ir-192	1.460	73.8 days
Palladium	Pd-103	2.660	17.0 days
Gold	Au-198	1.372	2.7 days
Strontium	Sr-90	6.697	28.8 years

(Data from chemlab.pcmaricopa.edu)

is more widely used. The tumor margins are localized by transillumination, indentation, or both, and marked on the sclera with a pen. If necessary, any overlying extraocular muscles are disinserted, after measuring the knot-to-limbus distances. In many centers a template is sutured to the sclera, and once it is well placed in relation to the tumor it is replaced with the radioactive plaque. In several centers the position of the template or plaque in relation to the tumor is checked by intraoperative ultrasonography. Another approach is to perform indirect ophthalmoscopy while indenting the eye with the edge of the plaque or with a right-angled fiberoptic transilluminator, the tip of this instrument inserted in a hole in the template.<sup>9</sup> Clinically visible extraocular tumor extension can be treated with a radioactive plaque.<sup>18</sup> Alternatively, the extraocular nodule can be excised together with the surrounding episclera and with the superficial lamella of adjacent sclera (Damato, unpublished observation). Care must be taken to avoid tilting the plaque, especially with juxtapapillary tumors, because tissue can become wedged between the plaque and the sclera.<sup>19</sup> The importance of checking the plaque's position at the time of surgery was demonstrated by a study in which 24% of plaques required repositioning when their location was checked by intraoperative ultrasonography.<sup>20</sup> To reduce radiation to the optic disc and fovea, some surgeons deliberately position a ruthenium plaque eccentrically in relation to the tumor, aligning the posterior plaque edge with the posterior tumor margin and relying on side-scatter of radiation to treat any lateral tumor extension.<sup>9,21</sup> Once the plaque is in place, any rectus muscles are repositioned, using slings if necessary, and the conjunctiva is closed. When the prescribed dose of radiotherapy has been delivered, usually after 2–7 days, the plaque is removed by a second procedure. Any disinserted rectus muscles are replaced, ensuring that the knot-to-limbus distances are the same as before. If the inferior oblique muscle is disinserted, it is usually left unattached. Care should be taken to ensure that adequate postoperative analgesia is prescribed.

**Follow-up** As with other forms of conservative therapy, lifelong surveillance is indicated, with assessment initially every 3–6 months, then every 6 months for about 5 years, and eventually once every year.

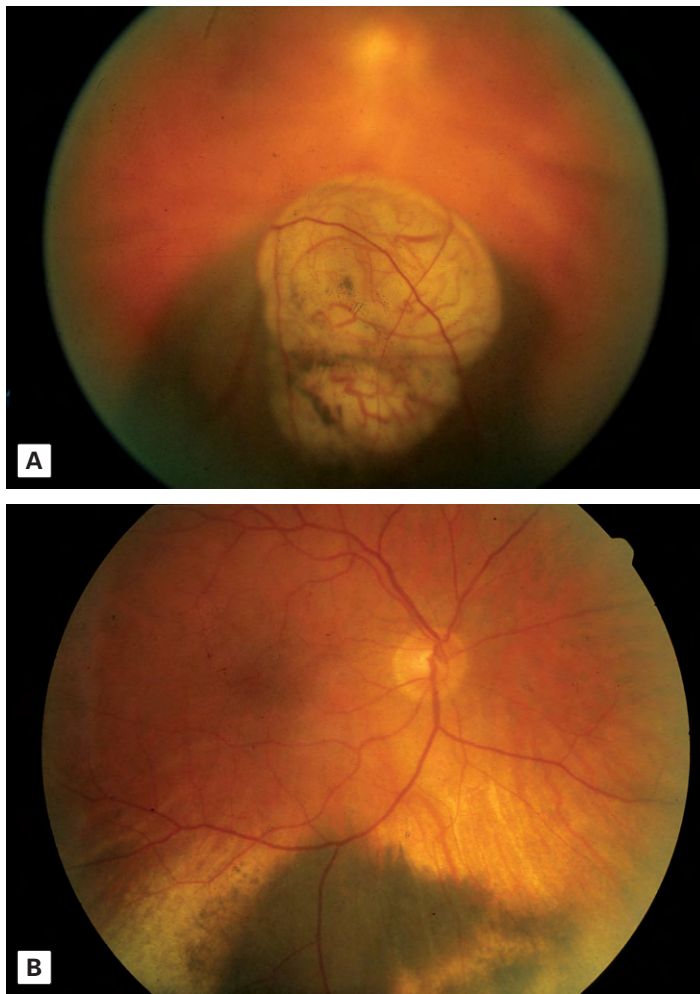


**Fig. 41.1** Episcleral plaques loaded with iodine-125 seeds (A) and containing ruthenium-106 integrated in the applicator (B).



Comparison of ophthalmoscopic appearances with a baseline color photograph or serial fundus photography should reveal any marginal recurrence at an early stage. Ultrasonography is especially useful for measuring changes in tumor thickness. Tumor regression is usually not apparent for the first 3–6 months after brachytherapy. The rate of regression varies significantly between tumors, being more rapid and complete in patients who subsequently develop metastatic disease (Fig. 41.2). Recurrence should be suspected only if any apparent growth exceeds 0.5 mm and if a trend is confirmed by repeated examination.

**Radiation safety** guidelines based on dosimetry modeling indicate that a surgeon can safely perform approximately 100 ruthenium-106 plaque procedures or 50 iodine-125 plaque operations each year. The silver shielding of ruthenium plaques and the gold shielding used for iodine-125 plaques absorb 99% or more of radiation.<sup>22</sup> Once the plaque is inserted, visitors and healthcare personnel working by the bedside should receive minimal doses of radiation. Each hospital has its own safety rules, which must be strictly enforced.



**Fig. 41.2** Fundus with a large uveal melanoma before (A) and 12 months after (B) ruthenium brachytherapy. Significant tumor regression is evident. The patient succumbed to metastatic disease 2 years after brachytherapy.

**Plaque modifications** Custom-designed plaques are sometimes used for non-resectable iris melanomas.<sup>23</sup> Binuclide plaques combine ruthenium-106 and iodine-125 in a single applicator, so that tumors with a thickness of 6.5–9 mm can be treated adequately while minimizing collateral damage to uninvolved ocular tissues.<sup>24</sup> The standardized COMS plaque has recently been modified so that the iodine seeds are held in place with metal cutouts instead of solidified acrylic gel, and are further from the scleral surface than before; these alterations have improved dosimetry and facilitated seed loading.<sup>25</sup>

**Combined treatment** Adjunctive transpupillary thermotherapy (TTT) may eradicate juxtapapillary tumor growth.<sup>26,27</sup> In addition, adjunctive TTT reduces exudation from the irradiated tumor, thereby reducing visual loss due to macular edema. Plaque treatment immediately after trans-scleral local resection is used to reduce the risk of local recurrence.<sup>28</sup>

### COLLATERAL DAMAGE TO OCULAR TISSUES

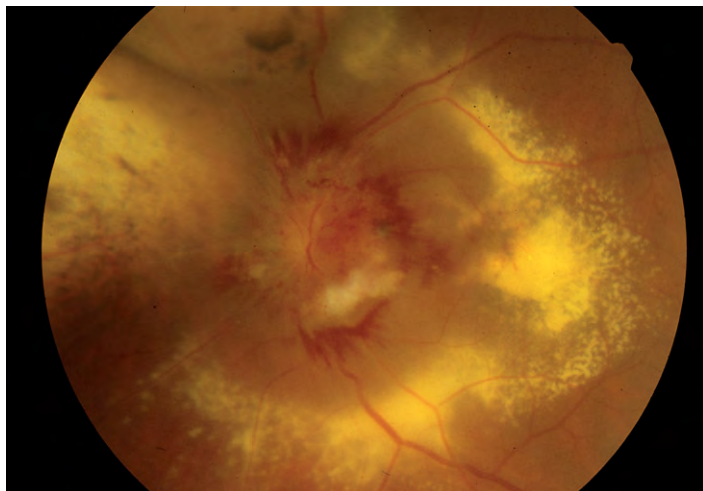
Using simulation software programs, the risk of radiation-related side effects can usually be estimated before brachytherapy.<sup>29</sup> At least 50% of patients with a large uveal melanoma experience significant ocular morbidity.<sup>30</sup> With small tumors, ocular adverse effects are less common and less severe, especially with a low-energy  $\beta$ -emitting source such as ruthenium-106.<sup>8,21</sup> Most radiation-related ocular side effects occur within the first postoperative years, but adverse effects may present after a prolonged period.

**Intraoperative complications** Ocular perforation when suturing can cause subretinal or vitreous hemorrhage as well as retinal detachment. This complication is treated by immediate cryotherapy, performed before the radioactive plaque is inserted. Occasionally the surgical manipulation of the eye may cause small hemorrhages in and around the tumor, which resolve after a few weeks.<sup>31</sup> Choroidal detachments can occur in the immediate postoperative period, if a vortex vein is compressed or when a new ‘hot’ plaque is used, and such uveal effusion can cause angle-closure glaucoma. Troublesome diplopia can develop if any disinserted muscles are not correctly replaced after plaque removal.

**Cataract** Cataract develops more frequently after treatment of anterior tumors.<sup>32</sup> The 5-year cumulative incidence of cataract after iodine brachytherapy for large uveal melanoma is 69%, and more frequent with thicker tumors.<sup>30</sup> Ruthenium plaques have a relatively low incidence of cataract. Phacoemulsification is performed in the standard fashion.

**Optic neuropathy** Collateral damage to the optic nerve head is almost inevitable with juxtapapillary melanoma, but may occur after treatment of any posteriorly located tumor (Fig. 41.3). Nearly half (46%) of patients treated with iodine-125 brachytherapy for large uveal melanoma develop optic neuropathy during the subsequent 5 years.<sup>30</sup> When using ruthenium for smaller tumors, optic neuropathy develops in only 12% of patients at 5 years.<sup>33</sup> Eccentric plaque positioning also reduces the incidence of this complication.<sup>9</sup>

**Retinopathy** In the immediate postoperative period exudative retinal detachment may develop, which can be severe and bullous, taking several weeks or months to resolve. Radiation damage to the macula is more likely in eyes with a large posterior tumor



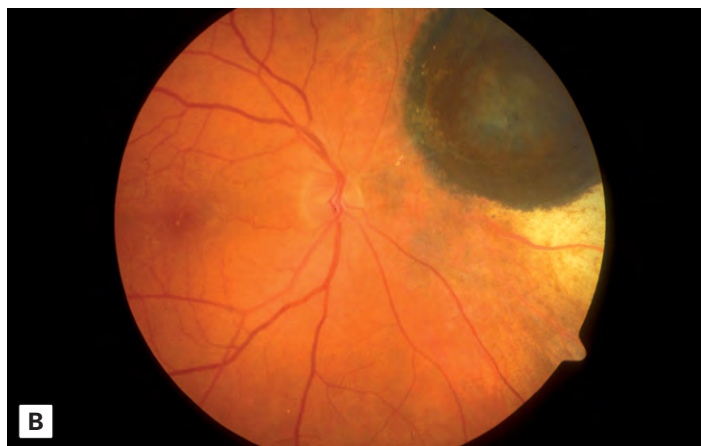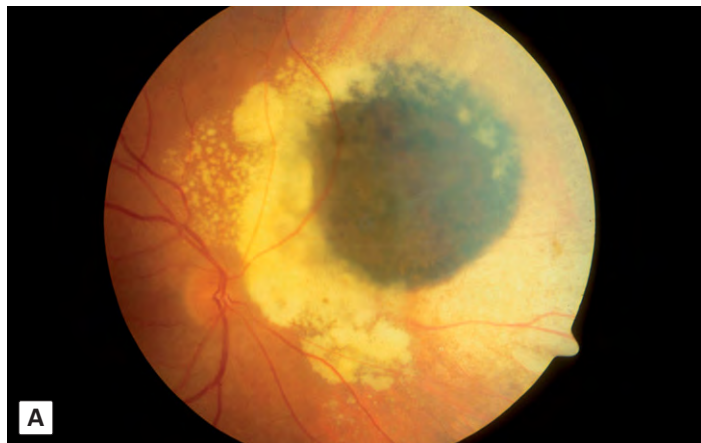**Fig. 41.3** Fundus featuring radiation retinopathy and papillopathy 3 years after iodine brachytherapy for a large choroidal melanoma.

(Fig. 41.3).<sup>32</sup> The 5-year cumulative incidence of radiation maculopathy is 30–52%, depending not only on the size and location of the tumor, but also on the radionuclide used.<sup>30,33</sup> A lower incidence should be expected with small and medium-sized tumors, especially with eccentric plaque positioning.<sup>9</sup> Scatter laser photocoagulation may induce regression of radiation retinopathy.<sup>34</sup> Maculopathy caused by exudates and edema can be treated by administering transpupillary thermotherapy to the tumor (Fig. 41.4).<sup>21</sup> Such maculopathy can also respond transiently to intravitreal triamcinolone injection (Fig. 41.5). Antiangiogenic agents are being investigated with encouraging results.

**Neovascular glaucoma** Rubeosis and neovascular glaucoma have been reported in 12–69% of patients, the incidence increasing with tumor size.<sup>33</sup> This is a major complication, which may cause intractable pain. Trans-scleral diode laser cyclophotocoagulation can be successful in controlling intraocular pressure, thereby reducing symptoms. Local resection of the irradiated tumor induces regression of exudative retinal detachment and neovascular glaucoma after proton beam radiotherapy, and may well be effective after brachytherapy.<sup>28</sup>

**Scleral melting** This severe radiation-related complication is rare. With ruthenium brachytherapy, scleral doses as high as 1500Gy are usually well tolerated.<sup>8</sup> Management may include scleral grafting or enucleation.<sup>35</sup> If scleral grafting is performed, the graft must be larger than the offending plaque so that it can be sutured to non-irradiated sclera.

**Choroidal atrophy** has generally been regarded as an inevitable consequence of brachytherapy, occurring because of the high basal radiation dose required for the delivery of a tumoricidal dose to the tumor apex. Such choroidal atrophy undoubtedly causes a severe defect in the corresponding part of the visual field. The recent introduction of eccentric plaque placement has led to the discovery that marginal tumor recurrence does not occur even when the base of the tumor extends slightly beyond the area of visible choroidal atrophy. This has led to the clinical impression that local tumor control and visual conservation can be achieved simultaneously, even with tumors that extend far posteriorly.



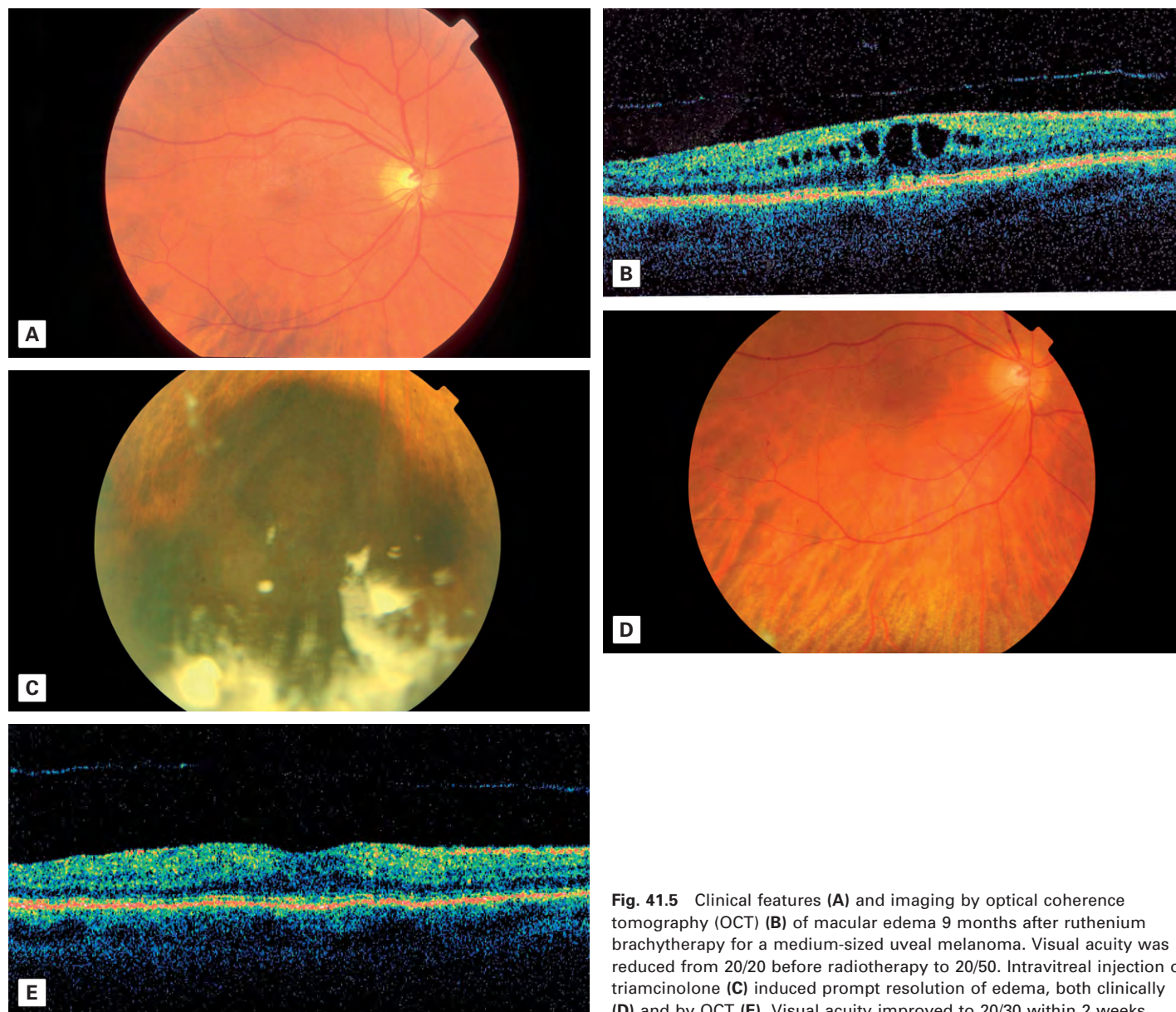
**Fig. 41.4** Fundus with massive intraretinal exudates at 2.5 years after ruthenium brachytherapy for a medium-sized choroidal melanoma (A). Transpupillary thermotherapy (TTT) of the tumor in 1998 caused resolution of exudates (B), with visual acuity improving from 20/40 to 20/20.

## RESULTS

**Visual outcome** Whereas plaque radiation of anterior melanomas is more likely to cause reversible visual loss secondary to cataract, the treatment of posterior tumors is more likely to be associated with irreversible loss caused by retinopathy.<sup>32</sup> Approximately 3–5 years after brachytherapy, half of patients (49–55%) maintain a best corrected visual acuity of 20/200 or better, and one-third (31–33%) have 20/50 visual acuity or better in the affected eye.<sup>8,10</sup> By treating patients with juxtapapillary tumors using eccentric plaque positioning to minimize radiation to the fovea, and administering adjunctive TTT for exudation, as many as 57% of patients may have preservation of 20/200 visual acuity or better 9 years after ruthenium brachytherapy for uveal melanoma (Fig. 41.6).<sup>21</sup> Significant loss of vision following brachytherapy is associated with greater tumor height and proximity of the tumor to the fovea (Fig. 41.7).<sup>12</sup> Useful vision is usually only maintained for 1–2 years following iodine brachytherapy for large uveal melanoma.<sup>36</sup>

**Local tumor recurrence** is the main reason for secondary enucleation following episcleral brachytherapy for uveal melanoma.<sup>8,12</sup> However, many eyes with local recurrence can be retained after





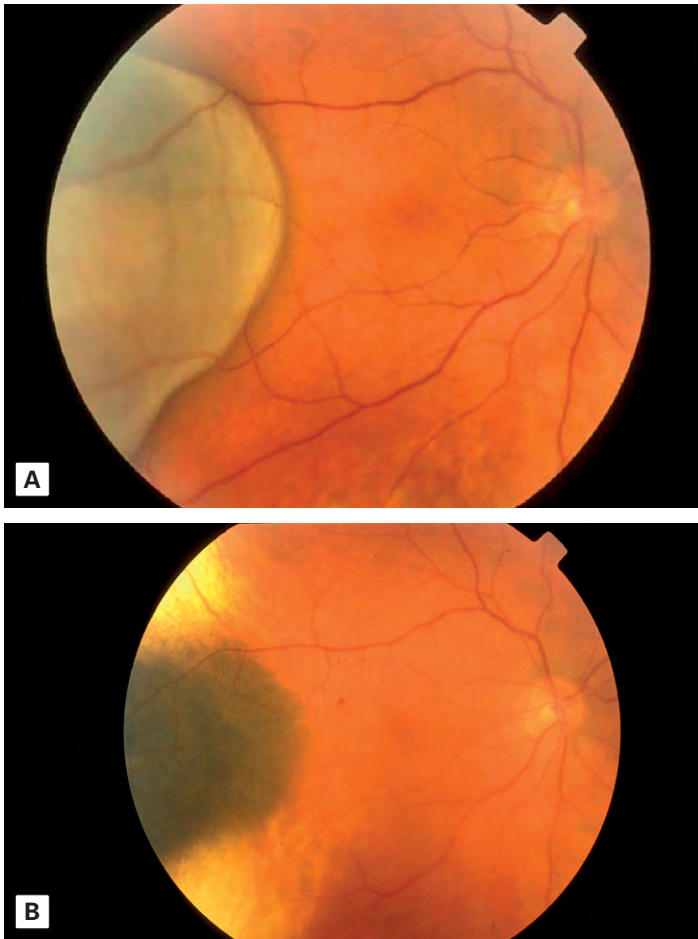
**Fig. 41.5** Clinical features (A) and imaging by optical coherence tomography (OCT) (B) of macular edema 9 months after ruthenium brachytherapy for a medium-sized uveal melanoma. Visual acuity was reduced from 20/20 before radiotherapy to 20/50. Intravitreal injection of triamcinolone (C) induced prompt resolution of edema, both clinically (D) and by OCT (E). Visual acuity improved to 20/30 within 2 weeks.

repeating the brachytherapy, or performing transpupillary thermotherapy or local resection. The overall tumor recurrence rate is approximately 10% at 5 years, and treatment failure is associated with greater size and posterior extension of the tumor (Fig. 41.8).<sup>12</sup> Local control rate is significantly better for smaller tumors and is only 3% at 7 years.<sup>9</sup> An increase in tumor size after initial regression may be caused by intratumoral hemorrhage and does not necessarily indicate local recurrence.<sup>37</sup> Although most recurrences occur within the first few postoperative years, regrowth after 10–15 years has been reported, indicating the need for lifelong follow-up.<sup>8</sup> The need for prolonged surveillance is further suggested by the finding that eyes enucleated for neovascular and other complications have been found histologically to contain cycling tumor cells without any clinical evidence of residual disease.<sup>37</sup> Local tumor recurrence after plaque

radiotherapy is weakly associated with reduced survival.<sup>12</sup> It is not known, however, whether such recurrence is actually the cause of metastatic disease or merely an indicator of increased tumor malignancy.

**Ocular conservation** The probability of ocular conservation depends on many factors.<sup>8</sup> Features associated with secondary enucleation are large tumor size, collar-stud shape (presumably because of retinal invasion), posterior tumor extension, and poor baseline visual acuity in the affected eye.<sup>12</sup> Generally, eyes are enucleated following episcleral brachytherapy in 12–17% of patients at 3–5 years follow-up (Fig. 41.7),<sup>8,12</sup> but eyes with smaller tumors have a much lower risk of secondary enucleation.<sup>9</sup> The reasons for enucleation vary from one study to another, and include local tumor recurrence,<sup>8,12</sup> recurrent





**Fig. 41.6** Right fundus of a 61-year-old man with a temporal choroidal melanoma measuring 11.0 mm in its largest basal diameter and 5.0 mm in height (A). The patient was treated with an eccentrically placed ruthenium plaque delivering a scleral dose of 612 Gy and an apex dose of 90 Gy. Thirty-two months later his vision was 20/20. The tumor appeared atrophic and had regressed to a thickness of 1.7 mm (B). There was no evidence of lateral growth. A small retinal hemorrhage indicated a significant dose of radiation beyond the visible choroidal atrophy.

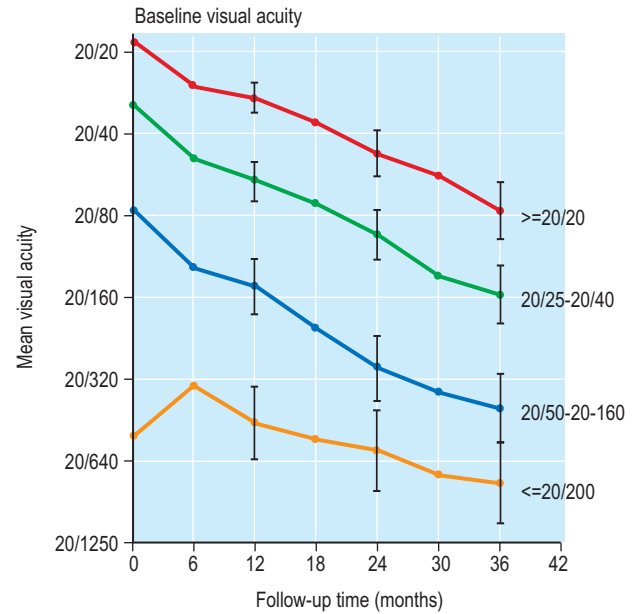
vitreous hemorrhage,<sup>21</sup> and painful neovascular glaucoma.<sup>12</sup> Even eyes with large uveal melanomas may be retained after brachytherapy, although the visual results are poor and cosmetic results variable.<sup>36</sup>

## SURVIVAL

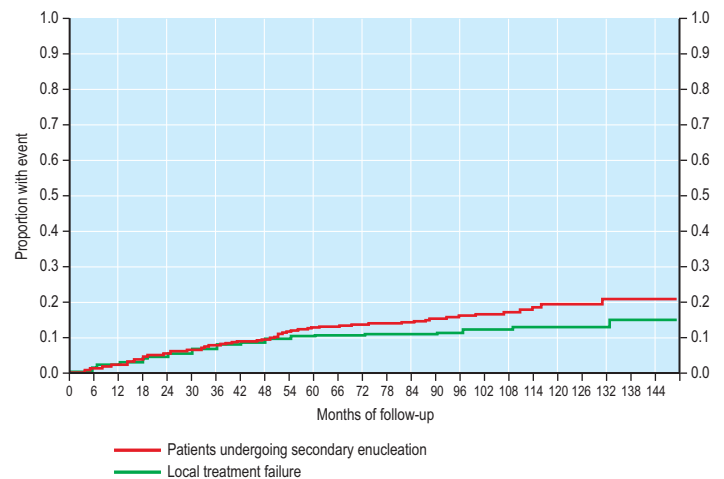
The COMS trials suggest that patient survival following brachytherapy of uveal melanoma is not significantly different from that after enucleation.<sup>11</sup> Patients with uveal melanoma randomized to either enucleation or iodine brachytherapy had unadjusted 5-year survival rates of 81% and 82%, respectively, and histopathologically confirmed melanoma metastases occurred in 11% and 9%, respectively.<sup>11</sup> Patients treated with ruthenium brachytherapy had similar 5- and 10-year survival rates, of 84% and 72%, respectively.<sup>8</sup>

## SUMMARY

In most centers plaque radiotherapy is the first choice of treatment for uveal melanoma. This is more reliable than phototherapy, less



**Fig. 41.7** Mean visual acuity with 95% confidence intervals (indicated by error bars) after iodine brachytherapy of uveal melanoma.<sup>10</sup> (Redrawn from The Collaborative Ocular Melanoma Study Group. Collaborative Ocular Melanoma Study (COMS) randomized trial of I-125 brachytherapy for medium choroidal melanoma. 1. Visual acuity after 3 years. COMS Report no. 16. Ophthalmology 2001; 108: 348–366.)



**Fig. 41.8** Cumulative proportion of patients undergoing secondary enucleation (red line) or with local treatment failure (green line) after iodine brachytherapy.<sup>12</sup> (Redrawn from Jampol LM, Moy CS, Murray TG et al. The COMS randomized trial of iodine 125 brachytherapy for choroidal melanoma: IV. Local treatment failure and enucleation in the first 5 years after brachytherapy. COMS report no.19. Ophthalmology 2002; 109: 2197–2206.)

expensive than proton beam radiotherapy, and less invasive than local resection; however, it can be difficult or impossible to position a plaque accurately over a small, posterior tumor (in which case proton beam radiotherapy may be preferable, given the choice). With proper case selection, a team experienced in brachytherapy can achieve rates of local tumor control that match those of proton beam radiotherapy, without the ocular surface, lacrimal drainage, and eyelid complications of teletherapy. As with any other treatment, conservation of vision depends greatly on the distance between the tumor and the optic disc

and macula. Collateral radiation damage to these two areas can be minimized by collimating iodine-125 radiation, using lower-range isotopes such as ruthenium and strontium, and, in the case of ruthenium, by eccentric plaque placement. Despite insignificant doses of radiation to the optic disc and macula, many patients lose vision after brachytherapy, and this is because of exudation from the irradiated residual tumor ('toxic tumor syndrome'). Such 'secondary' or 'indirect' radiation maculopathy can be treated successfully with transpupillary

thermotherapy to the tumor or by intravitreal steroid injection. Anti-angiogenic agents are also being investigated. Brachytherapy is increasingly used as an adjunctive form of treatment, after transpupillary thermotherapy or local resection. Several studies have shown that survival after brachytherapy is not significantly worse than after enucleation. For all the reasons mentioned above, it is likely that brachytherapy, with or without adjuvant thermotherapy, will continue to be the first line of treatment for small and medium-sized uveal melanomas.

## REFERENCES

- Moore RF. Choroidal sarcoma treated by the intraocular insertion of radon seeds. *Br J Ophthalmol* 1930; 14: 145–152.
- Stallard HB. Radiotherapy of malignant intraocular neoplasm. *Br J Ophthalmol* 1948; 32: 618–639.
- Stallard HB. Radiotherapy for malignant melanoma of the choroid. *Br J Ophthalmol* 1966; 50: 147–155.
- Sealy R, le Roux PLM, Rapley F et al. The treatment of ophthalmic tumors with low-energy sources. *Br J Radiol* 1976; 49: 551–554.
- Packer S, Rotman M. Radiotherapy of choroidal melanoma with iodine-125. *Ophthalmology* 1974; 87: 582–590.
- Lommatzsch PK. Treatment of choroidal melanomas with 106Ru/106Rh beta-ray applicators. *Surv Ophthalmol* 1974; 19: 85–100.
- Straatsma BR, Fine SL, Earle JD et al. Enucleation versus plaque irradiation for choroidal melanoma. *Ophthalmology* 1988; 95: 1000–1004.
- Bergman L, Nilsson B, Lundell G et al. Ruthenium brachytherapy for uveal melanoma, 1979–2003. Survival and functional outcomes in the Swedish population. *Ophthalmology* 2005; 112: 834–840.
- Damato BE, Patel I, Campbell IR et al. Local tumor control after (106)Ru brachytherapy of choroidal melanoma. *Int J Radiat Oncol Biol Phys* 2005; 63: 385–391.
- The Collaborative Ocular Melanoma Study Group. Collaborative Ocular Melanoma Study (COMS) randomized trial of I-125 brachytherapy for medium choroidal melanoma. 1. Visual acuity after 3 years. COMS Report no. 16. *Ophthalmology* 2001; 108: 348–366.
- The Collaborative Ocular Melanoma Study Group. The COMS Randomized trial of iodine 125 brachytherapy for choroidal melanoma, III: Initial mortality findings. COMS Report no. 18. *Arch Ophthalmol* 2001; 119: 969–982.
- Jampol LM, Moy CS, Murray TG et al. The COMS randomized trial of iodine 125 brachytherapy for choroidal melanoma: IV. Local treatment failure and enucleation in the first 5 years after brachytherapy. COMS report no.19. *Ophthalmology* 2002; 109: 2197–2206.
- Finger PT, Berson A, Ng T, Szechter A. Palladium-103 plaque radiotherapy for choroidal melanoma: an 11-year study. *Int J Radiat Oncol Biol Phys*. 2002; 54: 1438–1445.
- Karvat A, Duzenli C, Ma R et al. The treatment of choroidal melanoma with 198 Au plaque brachytherapy. *Radiother Oncol* 2001; 59: 153–156.
- Shields CL, Shields JA, Cater J et al. Plaque radiotherapy for uveal melanoma: visual outcome in 1106 consecutive patients. *Arch Ophthalmol* 2000; 18: 1219–1228.
- Missotten L, Dirven W, Van der Schueren A et al. Results of treatment of choroidal malignant melanoma with high-dose-rate strontium-90 brachytherapy. A retrospective study of 46 patients treated between 1983 and 1995. *Graefes Arch Clin Exp Ophthalmol* 1998; 236: 164–173.
- Soares CG, Vynckier S, Jarvinen H et al. Dosimetry of beta-ray ophthalmic applicators: comparison of different measurement methods. *Med Phys* 2001; 28: 1373–84.
- Gunduz K, Shields CL, Shields JA et al. Plaque radiotherapy for management of ciliary body and choroidal melanoma with extraocular extension. *Am J Ophthalmol* 2000; 130: 97–102.
- Williams DF, Mieler WF, Jaff GJ et al. Magnetic resonance imaging of juxtapapillary plaques in cadaver eyes. *Br J Ophthalmol* 1990; 74: 43–46.
- Tabandeh H, Chaudhry NA, Murray TG et al. Intraoperative echographic localization of iodine-125 episcleral plaque for brachytherapy of choroidal melanoma. *Am J Ophthalmol* 2000; 129: 199–204.
- Damato B, Patel I, Campbell IR et al. Visual acuity after ruthenium (106) brachytherapy of choroidal melanomas. *Int J Radiat Oncol Biol Phys* 2005; 63: 392–400.
- Laube T, Fluhs D, Kessler C et al. Determination of surgeon's absorbed dose in iodine 125 and ruthenium 106 ophthalmic plaque surgery. *Ophthalmology* 2000; 107: 366–368.
- Shields CL, Naseripour M, Shields JA et al. Custom-designed plaque radiotherapy for nonresectable iris melanoma in 38 patients: tumor control and ocular complications. *Am J Ophthalmol* 2003; 135: 648–656.
- Fluhs D, Anastassiou G, Wening J et al. The design and the dosimetry of binuclide radioactive ophthalmic applicators. *Med Phys* 2004; 31: 1481–1488.
- Astrahan MA, Szechter A, Finger PT. Design and dosimetric considerations of a modified COMS plaque: the reusable 'seed-guide' insert. *Med Phys* 2005; 32: 2706–2716.
- Seregard S, Landau I. Transpupillary thermotherapy as an adjunct to ruthenium plaque radiotherapy for choroidal melanoma. *Acta Ophthalmol Scand* 2001; 79: 19–22.
- Bartlema YM, Oosterhuis JA, Journée-De Korver JG et al. Combined plaque radiotherapy and transpupillary thermotherapy in choroidal melanoma: 5 years' experience. *Br J Ophthalmol* 2003; 87: 1370–1373.
- Damato BE, Foulds WS. Surgical resection of choroidal melanoma. In: Schachar AP, Ryan SJ, eds. *The retina*. St Louis: Mosby, 2006; 769–778.
- Puusaari I, Heikkonen J, Kivela T. Effect of radiation dose on ocular complications after iodine brachytherapy for large uveal melanoma: empirical data and simulation of collimated plaques. *Invest Ophthalmol Vis Sci* 2004; 45: 3425–3434.
- Puusaari I, Heikkonen J, Kivela T. Ocular complications after iodine brachytherapy for large uveal melanomas. *Ophthalmology* 2004; 111: 1768–1777.
- Robertson DM, Fuller DG, Anderson RE. A technique for accurate placement of episcleral iodine-125 plaques. *Am J Ophthalmol* 1987; 103: 63–65.
- Finger PT. Tumour location affects the incidence of cataract and retinopathy after ophthalmic plaque radiation therapy. *Br J Ophthalmol* 2000; 84: 1068–1070.
- Summanen P, Immonen I, Kivela T et al. Radiation related complications after ruthenium plaque radiotherapy of uveal melanoma. *Br J Ophthalmol* 1996; 80: 732–739.
- Finger PT, Kurli M. Laser photocoagulation for radiation retinopathy after ophthalmic plaque radiation therapy. *Br J Ophthalmol* 2005; 89: 730–738.
- Shields CL, Shields JA, Karlsson U et al. Reasons for enucleation after plaque radiotherapy for uveal melanoma. Clinical findings. *Ophthalmology* 1989; 96: 919–923.
- Puusaari I, Heikkonen J, Summanen P et al. Iodine brachytherapy as an alternative to enucleation for large uveal melanoma. *Ophthalmology* 2003; 110: 2223–2234.
- Seregard S, Lundell G, Lax I et al. Tumour cell proliferation after failed ruthenium plaque radiotherapy for posterior uveal melanoma. *Acta Ophthalmol Scand* 1997; 75: 148–154.

# Uveal malignant melanoma: management options – proton beam radiotherapy

CHAPTER

42

Anne Marie Lane and Evangelos S. Gragoudas

## INTRODUCTION

Radiotherapy has become the standard treatment for patients with malignant melanoma of the uveal tract, having supplanted enucleation because of its eye- and vision-conserving properties. Although alternative modalities are available, they may be less efficacious than radiotherapy, associated with high rates of complications, or difficult to administer.<sup>1–3</sup> As a result, they have limited use and are increasingly being used in combination with radiotherapy.<sup>3–6</sup>

## RADIOTHERAPY

Both brachytherapy<sup>7</sup> (radioactive plaques sutured on the sclera over the area of the tumor) and external beam radiation (charged particle beams of protons<sup>8</sup> or helium ions<sup>9</sup>) can be used to treat uveal melanoma, and most medium and large tumors are treated in this fashion. High rates of local control are achieved and survival rates are similar to those observed after enucleation<sup>10–12</sup> (Box 42.1).

External beam radiation (EBRT) is an effective treatment modality for patients with ocular melanoma, and is usually preferred if tumors are large and/or located near the optic nerve or macula. In the past helium ions have been employed successfully to irradiate ocular tumors,<sup>9</sup> and more recently stereotactic radiosurgery using the gamma knife<sup>13,14</sup> has been introduced. Further evaluation is necessary to determine whether outcomes are comparable to those of heavy particle irradiation.<sup>13</sup> At present, heavy charged particle irradiation with protons is the most widely used modality of EBRT.

The properties of protons, specifically the manner in which they lose energy in tissue, with minimal scatter due to their mass, low LET (linear energy transfer), and the deposition of most energy at the end of their range (Bragg peak), permit the design of a beam that covers the target volume with a uniform dose and reduces or eliminates the dose proximal and distal to the target.<sup>15</sup> By varying or modulating the beam energy, the Bragg peak can be broadened to conform to any tumor.<sup>16,17</sup> This ability to control the placement and energy of protons should lead to improved local control rates and a reduction in the incidence of radiation-induced damage to normal ocular tissue. These properties are of particular relevance for treating large tumors or tumors located near the optic disc and/or macula.

The use of proton therapy for uveal melanomas has been limited by the lack of availability of proton facilities. There are over 20 proton centers worldwide, including facilities in Canada, England, Germany, Russia, Switzerland, France, and Italy. Approximately 20 000 patients with uveal melanoma have been treated at these centers. Until recently, this treatment was available in the United States at three sites only:

Loma Linda (CA) University Medical Center, the Northeast Proton Therapy Center at Massachusetts General Hospital (at the Harvard Cyclotron before 2002), and later, the Crocker Nuclear Laboratory at University of California, Davis. In early 2004 the Midwest Proton Radiotherapy Institute opened and centers at Shands Medical Center, Jacksonville, FL and the M.D. Anderson Cancer Center, Houston, TX are expected to open in 2006. Plans to construct a proton facility are also underway at the University of Pennsylvania Medical Center. As accessibility to proton therapy expands, so too will its use as a management option for patients with uveal melanoma.

## PROTON BEAM IRRADIATION

**Patient evaluation** The diagnostic work-up for uveal melanoma comprises a complete ophthalmological examination, including indirect ophthalmoscopy, fundus photography, and ultrasonography, including A- and B-scan procedures. In addition a complete systemic evaluation is performed, including chest X-ray and liver function tests to determine that the patient is free of metastases or other malignancies. Suspicious clinical or laboratory findings are followed by CT, MRI, or ultrasound studies of the liver and abdomen.

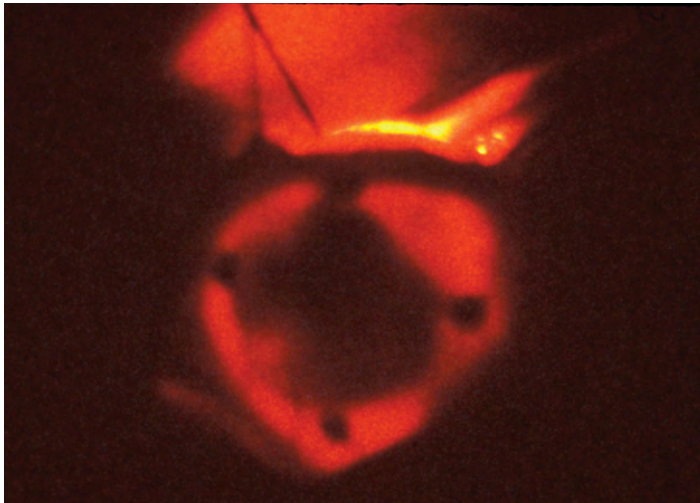
If patients are free of metastases, other primary malignancies, and there are no contraindications for surgery, all melanomas, regardless of size or location, are treated with proton therapy. Proton irradiation is not recommended for patients with very large melanomas that occupy greater than 30% of the ocular volume, large extrascleral extensions, or extensive neovascularization in a painful eye. Such cases are unlikely to benefit from conservative treatment and therefore enucleation is recommended. Asymptomatic patients who present with choroidal lesions less than 2 mm in height and less than 10 mm in diameter are followed closely and treated with proton therapy if tumor growth is observed.

**Pre-radiation surgery** Most patients with uveal melanomas have surgery to localize the tumor prior to receiving proton therapy. This is done by transillumination and/or indirect ophthalmoscopy followed by suturing of four 2.5 mm radio-opaque tantalum rings on the sclera around the borders of the tumor (Fig. 42.1), which serve as reference points for placement of the proton beam at the time of treatment. To further ensure the accuracy of placement of the radiation beam, the tumor is transilluminated again and measured on the sclera. Drawings are then made to document the size and shape of the lesion, as well as the location of the tantalum rings. Surgery is not necessary for patients with tumors involving the iris and ciliary body because



### BOX 42.1 Proton Beam Radiotherapy of Uveal Melanoma

- Deposits most energy at end of beam (Bragg peak)
- Allows good control of radiation
- Is administered with safety margins, 3 mm laterally and up to 4 mm longitudinally
- Achieves a high rate of local tumor control
- The main complications are neovascular glaucoma, maculopathy, optic neuropathy, and cataract
- Survival rates are not significantly different from those after enucleation

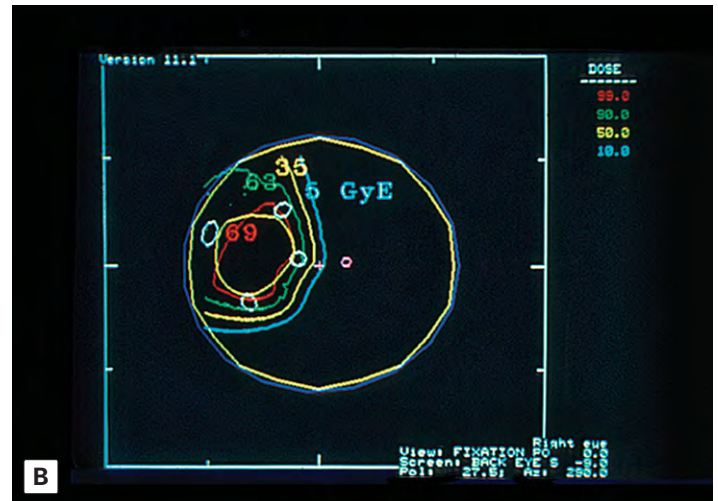


**Fig. 42.1** Tantalum rings sutured to the sclera at the edges of the tumor seen by transillumination. (Reproduced with permission from Gragoudas ES. Charged particle irradiation of uveal melanoma. In: Ryan SJ (ed) *Retina*, 4th edn. Philadelphia: Elsevier/Mosby, 2006.)

tumor margins can be defined in relation to the anatomic landmarks of the iris and cornea.

**Proton treatment planning** The interactive treatment planning system developed for ocular melanomas and used for all patients seen at our site has already been described.<sup>18,19</sup> A team of ocular oncologists, radiation oncologists, and physicists use axial eye length and tumor height, determined by A- and B-mode ultrasonography, tumor dimensions measured using drawings and fundus photographs, and location of the tantalum rings, determined on roentgenograms taken in the treatment position during a simulation session, to develop a specific treatment plan for each patient. These data are used to create a three-dimensional model of the tumor that is superimposed on a model of a normal eye, scaled to the patient's eye. The computer can be made to rotate the eye so that it follows a user-controlled fixation point in near to real time, which allows the planner to choose a fixation angle that will minimize radiation exposure of the lens, optic disc and fovea to the extent possible and maximize the dose to the tumor.<sup>19</sup>

This program also is used to design an aperture that approximates the shape of the tumor and gives a 3 mm margin laterally (1.5 mm at the 90% dose level), to calculate the maximum and minimum depths of the target, and the beam range and modulation width, which



**Fig. 42.2** Graphic depiction of dose distribution from treatment plan for a 13mm diameter tumor (A). Isodose contours shown in a plane through the eye. Isodose contours shown on the retinal surface (B). (Reproduced with permission from Gragoudas ES. Charged particle irradiation of uveal melanoma. In: Ryan SJ (ed) *Retina*, 3rd edn. St Louis: Mosby, 2001.)

includes a 2.5–4 mm margin both distally and proximally. The dose distribution (Fig. 42.2) is calculated and dose volume histograms for the globe, lens, ciliary body, retina, macula, and disc are routinely generated for each treatment plan.

**Irradiation procedure** Prior to the start of irradiation a positioning procedure is performed during which the patient must be immobilized and the eye properly aligned with the proton beam. The patient is treated in the sitting position, with the head immobilized by using a facemask and bite block, which are attached to a headholder (Fig. 42.3). The headholder is attached to the proton beam collimator and the aperture is mounted in the end of the collimator nearest the eye. Orientation of the patient's eye is established by voluntary fixation on a flashing light set at a position determined by the planning program.

Using a fluoroscopic system that provides a virtually instantaneous picture held on an image-storage device, alignment of the tumor relative to the beam axis and the edges of the beam-defining aperture is achieved by moving the headholder until the surgically placed tantalum rings are in the desired position relative to the beam axis. Finally,

a beam-simulation field light is projected through the aperture on to the eye to be treated, to ensure that the light field falls on the eye in relation to the edge of the limbus. After successful completion of this procedure, treatment can begin.


During treatment, the eyelids are retracted by the ophthalmologist using an eye speculum to reduce radiation exposure to the eyelid, and the patient is asked to fixate. Using the same fluoroscopic system as for patient positioning, a magnified picture of the eye, taken by a camera mounted on the collimator, is viewed onscreen in the control area to monitor eye position. This allows for the interruption of treatment and repositioning of the patient if unacceptable eye movement ( $>0.5$  mm) is observed. Each treatment takes approximately 1 minute, and most treatments are completed without interruption.

**Follow-up protocol** Ophthalmological examinations are performed 6 weeks, 6 months, and 12 months after treatment, biannually thereafter up to 5 years after treatment, and then annually, to monitor the status of both tumor and patient.

Visual function, tumor recurrence, ocular complications, and metastasis are monitored at every follow-up examination. Fundus photography and ultrasonography are performed to evaluate and document tumor regression, tumor recurrence, and radiation-induced complications. Metastatic spread is assessed with annual liver function tests and, if indicated, other diagnostic tests, such as chest X-rays and abdominal CT scans.

### PATIENT CHARACTERISTICS

The largest series of uveal melanoma patients have been treated at the Massachusetts Eye and Ear Infirmary (MEEI)/Harvard Cyclotron/Northeast Proton Therapy Center and the Hôpital Ophthalmique Jules Gonin/Paul Scherrer Institute (PSI). Over 2000 patients have been treated at each facility, beginning in 1975 at MEEI<sup>8</sup> and 1984 at PSI,<sup>20,21</sup> and long-term follow-up is available through the late 1990s. Although similar treatment planning programs are used, a total dose of 70 CGE (63.6 proton Gy times 1.1 relative biologic effectiveness) in five equal fractions is delivered at the MEEI, compared to 60 CGE in four fractions at the PSI. Patient demographics are also similar, with approximately equal numbers of men and women treated at each facility, but with



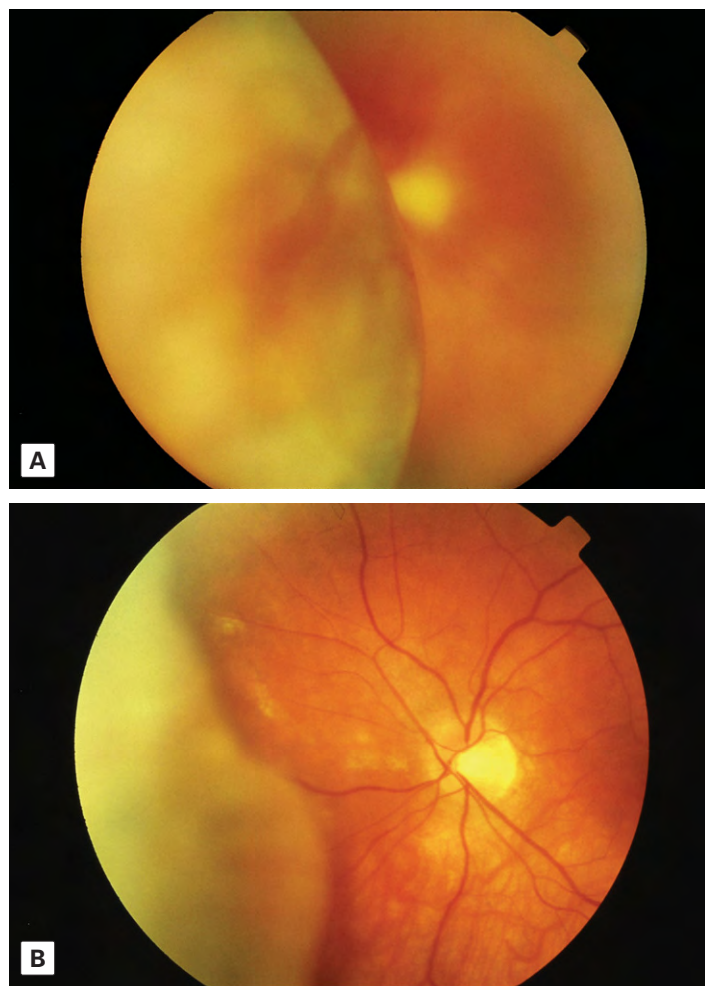
**Fig. 42.3** Patient immobilized for treatment with use of headholder, facemask and bite block. (Reproduced with permission from Gragoudas ES. Charged particle irradiation of uveal melanoma. In: Ryan SJ (ed) Retina, 4th edn. Philadelphia: Elsevier Mosby, 2006.)

slightly younger patients treated at PSI (mean age was 54.5 years<sup>21</sup> compared to 61 years at MEEI). The median basal diameter and median height of treated tumors were 13.2 mm and 5.3 mm, respectively, at MEEI, and 16.2 mm and 5.8 mm, respectively, at PSI,<sup>8,21</sup> and this reflects the practice of referring patients with larger tumors to centers that offer proton therapy. Approximately half of the patients treated at PSI had tumors located within 3.6 mm of the optic nerve or macula,<sup>21</sup> and an even higher proportion of patients with such tumors were treated at the MEEI (68% located within 3 mm of one of these structures)<sup>8</sup> – evidence that proton therapy is preferred for patients with tumors near the optic disc and fovea.

Patients with comparable demographic and tumor characteristics have been treated at other proton facilities following essentially the same or a somewhat modified planning protocol as that developed at the Harvard Cyclotron, including 349 patients at the Clatterbridge Center for Oncology/Douglas Cyclotron,<sup>22</sup> and over 500 at the Biomedical Cyclotron Center (Nice, France).<sup>23</sup>

### OPHTHALMIC OUTCOMES

**Local control** Disappearance of the tumor or the formation of a flat scar occurs infrequently, and the vast majority of lesions continue to regress years after therapy. Regression (Fig. 42.4) is most likely due



**Fig. 42.4** Large ciliochoroidal melanoma extending up to the optic nerve and associated with serous retinal detachment. (A) Before proton irradiation. (B) Approximately 1 year post-treatment a significant reduction of the tumor is seen.

to both direct cell death from irradiation, achieved by damage to chromosomal DNA when the cell enters mitosis, and damage to the vasculature that carries nutrients to the tumor cells. Delayed regression in some patients may be due to the prolonged intermitotic phases of melanoma cells.

In the MEEI series<sup>8</sup> approximately 3% of tumors exhibited growth, confirmed by ultrasonography and fundus photography, and just under half were marginal recurrences. The highest annual rate of recurrence, 1%, occurred 1 year after proton therapy, and the 10-year cumulative rate of regrowth (confirmed and suspected cases) was 4%.<sup>24</sup> Low recurrence rates were also demonstrated in the PSI series, with 5% of patients experiencing regrowth by 10 years after irradiation.<sup>20</sup> Kodjikian and colleagues reported a low proportion of patients with recurrences (4.5%), but found that the percentage approximately doubled (10.5%) in patients with tumors located in the perimacular or peripapillary regions.<sup>25</sup>

**Eye loss** Removal of the eye may become necessary after treatment if the tumor recurs or complications develop. Neovascular glaucoma is the most common complication leading to enucleation.<sup>8,26</sup> Tumor characteristics that increase the risk of enucleation include height,<sup>8,21,22,26</sup> proximity to critical structures,<sup>8,21,27</sup> and diameter.<sup>8,22,25</sup> The probability of retaining the eye for patients treated at the MEEI was 91% at 5 years, 88% at 10 years, and 84% at 15 years after irradiation (Table 42.1), and rates at these timepoints were virtually identical in patients treated at PSI.<sup>21</sup> Poorer outcomes were reported for a small series (N = 78) of patients with medium and large melanomas; 75% retained the eye 5 years after irradiation.<sup>27</sup>

Eyes enucleated after proton therapy and examined histopathologically exhibit degenerative and vascular changes.<sup>28</sup> Thickening or thrombosis of the tumor vasculature is a hallmark effect of radiation: in one study vascular damage was identified over 10 times more often in irradiated tumors than in non-irradiated ones.<sup>28</sup> Consistent with

these findings, fewer vascular regions were identified by color Doppler imaging in proton-irradiated tumors than in pre-irradiation tumors.<sup>29</sup>

**Vision loss** Early studies<sup>30,31</sup> of patients who received proton therapy for uveal melanomas suggested that tumor height and location with respect to the fovea and optic nerve were key prognostic factors for visual outcome after proton beam irradiation. Subsequent studies have provided further evidence that this is the case. In a group of patients with small to moderate-sized tumors located within four disc diameters of the optic nerve or macula, increased dose to the macula, increased tumor height, poorer baseline vision, and a history of diabetes elevated the risk of vision loss, which was 68% at 5 years after proton therapy.<sup>32</sup> In contrast, the 5-year rate of vision loss when all patients were evaluated was 52% (Table 42.1). Fuss et al.<sup>27</sup> found that a radiation dose greater than 35 CGE to the optic disc or macula was associated with visual deterioration, which is similar to the findings of our group<sup>32</sup> and suggests that there may be a threshold dose for deleterious effects. In a series of 349 patients treated with proton therapy who had tumors considered unsuitable for brachytherapy or other conservative modalities, tumor height, initial visual acuity, and retinal invasion were identified as risk factors for vision loss to 20/200 or worse, and proximity to the optic nerve and/or macula predicted vision loss to worse than 20/40.<sup>22</sup> Tumor location within two disc diameters of both the optic nerve and macula was the strongest predictor of poor visual outcome in the MEEI cohort, followed by baseline visual acuity of 20/50 or worse, history of diabetes, degree of retinal detachment, increased tumor height, and increased tumor diameter.<sup>8</sup>

**Complications** The most serious anterior segment complications are rubeosis iridis and neovascular glaucoma because they can lead to vision loss and loss of the eye. In a series of patients with tumors too large to be treated with plaque radiotherapy, larger tumor diameter

**Table 42.1 Cumulative rates (% and 95% confidence intervals) of enucleation, vision loss, and melanoma-related death, by risk group\* and years after proton irradiation**

Endpoint	All patients	Low risk	Low-to-medium risk	Medium-to-high risk	High risk
<b>Loss of eye</b>					
5 years	9 (7, 10)	2 (1, 3)	6 (4, 8)	10 (7, 14)	27 (22, 33)
10 years	12 (10, 14)	3 (2, 6)	8 (6, 11)	14 (10, 20)	33 (27, 41)
15 years	16 (13, 20)	3 (2, 6)	11 (7, 16)	23 (15, 35)	48 (33, 65)
<b>Vision loss to 20/200 or worse</b>					
5 years	52 (50, 55)	9 (7, 15)	40 (35, 45)	71 (67, 76)	95 (91, 98)
10 years	65 (62, 68)	16 (11, 22)	58 (52, 65)	84 (79, 88)	99 (96, 100)
15 years	71 (66, 75)	24 (14, 39)	65 (55, 75)	88 (81, 93)	100 (–, –)
<b>Melanoma-related death</b>					
5 years	14 (13, 16)	2 (1, 4)	7 (5, 9)	19 (16, 22)	40 (35, 47)
10 years	23 (21, 25)	3 (2, 5)	13 (11, 17)	31 (27, 35)	57 (51, 64)
15 years	27 (24, 29)	5 (3, 9)	16 (13, 19)	35 (31, 40)	63 (56, 71)

\*Risk groups derived from values of statistically significant prognostic factors and their coefficients in multivariate Cox regression models. (Reproduced with permission from Gragoudas ES. Uveal melanoma: proton beam irradiation. *Ophthalmol Clin North Am* 2005; 18: 111–118)



and the presence of retinal detachment were highly significant risk factors ( $P < 0.0005$ ) for developing rubeosis.<sup>33</sup> In the MEEI cohort, the most significant predictor of iris neovascularization was larger tumor volume, with a relative risk of 2.4 (95% CI 2.1, 2.8) per doubling volume. Annual rates of developing one or both complications were highest in the first 3 years after irradiation, and dropped to 1% or less 5 years or more after treatment.<sup>34</sup>

The development of posterior subcapsular (PSC) cataract, a vision-impairing complication of the anterior segment, appears to be dependent on tumor height and radiation dose received by the lens during treatment,<sup>35</sup> which in turn is correlated with the extent of the lens included in the radiation field. When less than 10% of the lens was included in the radiation field, the cumulative 5-year rate of PSC was 19%. In contrast, 54% of patients developed a PSC cataract when more than 50% of the lens was irradiated.<sup>34</sup>

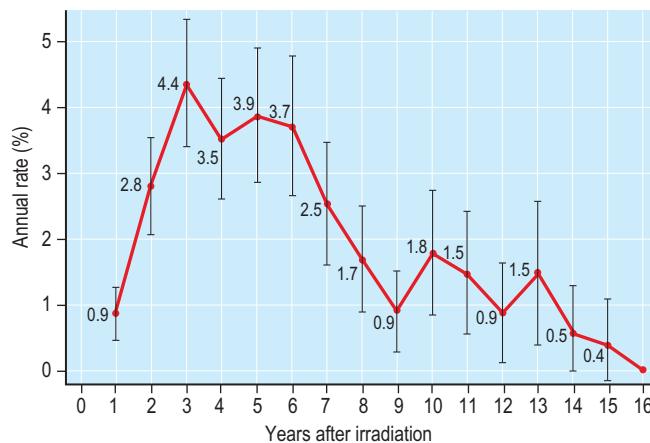
Posterior complications include radiation maculopathy and papillopathy, which are characterized by abnormalities of the vasculature such as capillary closure, telangiectasias, microaneurysms, exudates, and hemorrhages. Despite a reduction in the irradiated volume achieved with proton therapy, radiation exposure of the optic disc or macula may be unavoidable in cases that involve tumors located in close proximity to these structures. For example, 5-year cumulative rates of maculopathy and papillopathy were 40% and 24%, respectively, for all patients treated with proton therapy at MEEI,<sup>34</sup> but these rates increased to 64% and 35%, respectively, when the analysis was restricted to a group of patients with small to moderate-sized tumors located within four disc diameters of the optic nerve or macula.<sup>32</sup> In both analyses these complications were related to total radiation dose to critical structures or its correlate, distance from critical structures.

We also evaluated rates of papillopathy after proton radiation in tumors located within one disc diameter of the optic nerve, regardless of tumor size. More than half (56.8%) of these patients had developed papillopathy by 5 years after treatment, but by 10 years there was little additional change (61%). Rates of vision loss to worse than 20/200 – 80% at 5 years and 91% at 10 years after treatment – were probably due to the rates of papillopathy and maculopathy seen in this population.

Because the effect of these complications can be devastating in terms of visual function, improvements in treatment to reduce complications without compromising high rates of local control are necessary. Toward this end, a randomized, double-blind clinical trial comparing a radiation dose of 50 CGE (experimental treatment arm) to a dose of 70 CGE (standard treatment arm) was completed in patients at high risk of complications due to the location (but not the size) of the tumor. No significant differences in rates of maculopathy, papillopathy, vision loss, recurrence, or metastasis were realized between the experimental and standard treatment arms.<sup>36</sup>

## METASTASIS AND SURVIVAL

Five-, 10- and 15-year tumor-specific survival rates were 86%, 77%, and 73%, respectively (Table 42.1), for patients treated with proton therapy at MEEI. The highest annual death rates were observed between 3 and 6 years after treatment (Fig. 42.5). Patient and tumor characteristics associated with metastatic death included largest tumor diameter, patient age, tumor pigmentation, the presence or absence of symptoms, tumor origin (ciliary body vs choroid), and iris color.<sup>8</sup> Investigators at PSI identified largest tumor diameter, patient age, tumor height, extrascleral extension, degree of retinal detachment, and ocular melanocytosis as risk factors for metastatic death. They also



**Fig. 42.5** Annual rates of melanoma-related deaths, with 95% confidence intervals, up to 15 years after irradiation. Reproduced with permission from Gragoudas ES. Uveal melanoma: proton beam irradiation. *Ophthalmol Clin North Am* 2005; 18: 111–118.

demonstrated that patients with good local control experience better survival outcomes than those with local failure; 10-year rates of melanoma-related mortality were 27.4% and 52.5% for patients without and with tumor recurrences, respectively.<sup>20</sup> This finding supports the findings of an earlier study completed at the MEEI,<sup>26</sup> which revealed an elevated risk of metastatic death in patients who had eyes enucleated secondary to tumor recurrence compared to those who had enucleation performed for other reasons. Other reports of survival outcomes after proton irradiation originate from investigators at newer proton facilities, and thus include fewer patients and more limited follow-up. Survival rates approximately 5 years after proton therapy are similar to<sup>22,37</sup> or somewhat lower<sup>23,25,27</sup> than those observed at MEEI and PSI, and vary between 90%<sup>22</sup> and 75.6%.<sup>27</sup>

Despite high local control rates and low rates of metastasis overall, by 10 years after treatment melanoma-related deaths occur in over 50% of patients who present with high-risk characteristics.<sup>8</sup> The prognosis after a diagnosis of metastasis is poor because the most common site of metastasis is the liver,<sup>38</sup> which is refractory to treatment. As a result, few patients survive more than 1 year after diagnosis regardless of the treatment received.<sup>38–40</sup>

The development of successful therapies for metastasis has remained elusive; with currently available treatments, response rates have been fair to poor. Additionally, many of these therapies, which include systemic<sup>39,41</sup> or regional<sup>39,42,43</sup> administration of chemotherapeutics, and surgical resection,<sup>44,45</sup> are for selected cases only or are associated with dose-limiting toxicities.

## SUMMARY

Proton therapy has become an attractive modality for patients with uveal malignant melanoma. As is the case with brachytherapy, high rates of local control and eye conservation are achieved with proton therapy, and retention of useful vision is possible in many cases. The favorable dose distributions realized with this modality, which allow the delivery of a more homogeneous dose to the target tissue while sparing the surrounding normal ocular tissues, allows the treatment of large tumors and tumors near the optic nerve and fovea.

Although local control of the tumor is achieved in almost all cases, rates of melanoma-related mortality are high, particularly for patients who possess certain constitutional and tumor characteristics, suggest-

ing that subclinical metastases may exist at the time of diagnosis and treatment. Areas of future research should include refining current primary treatment methods to reduce treatment-related morbidity and improve functional outcomes, and identifying risk factors for

metastasis. These factors, whether environmental, clinical, or biochemical, could become targets for interventions that may one day lead to the reduction or prevention of uveal melanoma and melanoma metastasis.

## REFERENCES

- Damato B, Groenewald C, McGalliard J, Wong D. Endoresection of choroidal melanoma. *Br J Ophthalmol* 1998; 82: 213–218.
- Damato B, Groenewald CP, McGalliard JN, Wong D. Rhegmatogenous retinal detachment after transscleral local resection of choroidal melanoma. *Ophthalmology* 2002; 109: 2137–2143.
- Harbour JW, Meredith TA, Thompson PA, Gordon ME. Transpupillary thermotherapy versus plaque radiotherapy for suspected choroidal melanomas. *Ophthalmology* 2003; 110: 2207–2214.
- Damato B, Jones AG. Uveal melanoma: resection techniques. *Ophthalmol Clin North Am* 2005 18: 119–128.
- Char DH, Miller T, Crawford JB. Uveal tumour resection. *Br J Ophthalmol* 2001; 85: 1213–1219.
- Bartlema YM, Oosterhuis JA, Journee-De Korver JG, Tjho-Heslinga RE, Keunen JE. Combined plaque radiotherapy and transpupillary thermotherapy in choroidal melanoma: 5 years' experience. *Br J Ophthalmol* 2003; 87: 1370–1373.
- Nag S, Quivey JM, Earle JD, Followill D. The American Brachytherapy Society recommendations for brachytherapy of uveal melanomas. *Int J Radiat Oncol Biol Phys* 2003; 56: 544–555.
- Gragoudas E, Li W, Goitein M, Lane AM, Munzenrider JE, Egan KM. Evidence-based estimates of outcome in patients irradiated for intraocular melanoma. *Arch Ophthalmol* 2002; 120: 1665–1671.
- Char DH, Kroll SM, Castro J. Ten-year follow-up of helium ion therapy for uveal melanoma. *Am J Ophthalmol* 1998; 125: 81–89.
- Seddon JM, Gragoudas ES, Egan KM et al. Relative survival rates after alternative therapies for uveal melanoma. *Ophthalmology* 1990; 97: 769–777.
- Puusaari I, Heikkonen J, Summanen P, Tarkkanen A, Kivela T. Iodine brachytherapy as an alternative to enucleation for large uveal melanomas. *Ophthalmology* 2003; 110: 2223–2234.
- Diener-West M, Earle JD, Fine SL et al. The COMS randomized trial of iodine 125 brachytherapy for choroidal melanoma, III: initial mortality findings. COMS Report No. 18. *Arch Ophthalmol* 2001; 119: 969–982.
- Mueller AJ, Talies S, Schaller UC et al. Stereotactic radiosurgery of large uveal melanomas with the gamma knife. *Ophthalmology* 2000; 107: 1381–1387; discussion 87–88.
- Haas A, Pinter O, Papaefthymiou G et al. Incidence of radiation retinopathy after high-dosage single-fraction gamma knife radiosurgery for choroidal melanoma. *Ophthalmology* 2002; 109: 909–913.
- Suit H. The Gray Lecture 2001: Coming technological advances in radiation oncology. *Int J Radiat Oncol Biol Phys* 2002; 53: 798–809.
- Suit HD, Gotein M, Tepper J et al. Exploratory study of proton radiation therapy using large field techniques and fractionated dose schedules. *Cancer* 1975; 35: 1646–1657.
- Diener-West M, Schneider R, Sisterson J. Range modulators for protons and heavy ions. *Nucl Instrum Meth* 1975; 131: 437–440.
- Koehler A, Goitein M, Koehler A et al. Proton irradiation of choroidal melanomas: Preliminary results. *Arch Ophthalmol* 1978; 96: 1583–1591.
- Goitein M, Miller T. Planning proton therapy of the eye. *Med Phys* 1983; 10: 275–283.
- Egger E, Schalenbourg A, Zografos L et al. Maximizing local tumor control and survival after proton beam radiotherapy of uveal melanoma. *Int J Radiat Oncol Biol Phys* 2001; 51: 138–147.
- Egger E, Zografos L, Schalenbourg A et al. Eye retention after proton beam radiotherapy for uveal melanoma. *Int J Radiat Oncol Biol Phys* 2003; 55: 867–880.
- Damato B, Kacperek A, Chopra M, Campbell IR, Errington RD. Proton radiotherapy of choroidal melanoma: The Liverpool–Clatterbridge experience. *Int J Rad Oncol Biol Phys* 2005; 62: 1405–1411.
- Courdi A, Caujolle JP, Grange JD et al. Results of proton therapy of uveal melanomas treated in Nice. *Int J Radiat Oncol Biol Phys* 1999; 45: 5–11.
- Gragoudas ES, Lane AM, Munzenrider J, Egan KM, Li W. Long-term risk of local failure after proton therapy for choroidal/ciliary body melanoma. *Trans Am Ophthalmol Soc* 2002; 100: 43–48.
- Kodjikian L, Roy P, Rouberol F et al. Survival after proton-beam irradiation of uveal melanomas. *Am J Ophthalmol* 2004; 137: 1002–1010.
- Egan K, Ryan L, Gragoudas E. Survival implications of enucleation after definitive radiotherapy for choroidal melanoma: An example of regression on time-dependent covariates. *Arch Ophthalmol* 1998; 116: 366–370.
- Fuss M, Loredo LN, Blacharski PA, Grove RI, Slater JD. Proton radiation therapy for medium and large choroidal melanoma: preservation of the eye and its functionality. *Int J Radiat Oncol Biol Phys* 2001; 49: 1053–1059.
- Saornil M, Egan K, Gragoudas E et al. Histopathology of proton beam-irradiated vs enucleated uveal melanomas. *Arch Ophthalmol* 1992; 110: 1112–1118.
- Regan S, Egan KM, Hart L, Gragoudas ES. Color Doppler imaging of untreated and irradiated choroidal melanomas. *Eur J Ophthalmol* 2001; 11: 150–155.
- Seddon JM, Gragoudas ES, Polivogianis L et al. Visual outcome after proton beam irradiation of uveal melanoma. *Ophthalmology* 1986; 93: 666–674.
- Seddon JM, Gragoudas ES, Egan KM et al. Uveal melanomas near the optic disc or fovea. Visual results after proton beam irradiation. *Ophthalmology* 1987; 94: 354–361.
- Gragoudas ES, Li W, Lane AM, Munzenrider J, Egan KM. Risk factors for radiation maculopathy and papillopathy after intraocular irradiation. *Ophthalmology* 1999; 106: 1571–1578.
- Foss AJ, Whelehan I, Hungerford JL et al. Predictive factors for the development of rubeosis following proton beam radiotherapy for uveal melanoma. *Br J Ophthalmol* 1997; 81: 748–754.
- Gragoudas ES, Lane AM. Uveal melanoma: proton beam irradiation. *Ophthalmol Clin North Am* 2005; 18: 111–118.
- Gragoudas ES, Egan KM, Walsh SM et al. Lens changes after proton beam irradiation for uveal melanoma. *Am J Ophthalmol* 1995; 119: 157–164.
- Gragoudas ES, Lane AM, Regan S et al. A randomized controlled trial of varying radiation doses in the treatment of choroidal melanoma. *Arch Ophthalmol* 2000; 118: 773–778.
- Desjardins L, Levy C, d'Hermies F et al. Initial results of proton therapy in choroidal melanoma at the d'Orsey Center for Proton Therapy; the first 464 cases. *Cancer Radiother* 1997; 1: 222–226.
- Gragoudas E, Egan K, Seddon J et al. Survival of patients with metastases from uveal melanoma. *Ophthalmology* 1991; 98: 383–390.
- Bedikian AY, Legha SS, Mavligit G et al. Treatment of uveal melanoma metastatic to the liver: a review of the MD Anderson Cancer Center experience and prognostic factors. *Cancer* 1995; 76: 1665–1670.
- Eskelin S, Pyrhonen S, Hahka-Kemppinen M, Tuomaala S, Kivela T. A prognostic model and staging for metastatic uveal melanoma. *Cancer* 2003; 97: 465–475.
- Flaherty LE, Unger JM, Liu PY, Mertens WC, Sondak VK. Metastatic melanoma from intraocular primary tumors: the Southwest Oncology Group experience in phase II advanced melanoma clinical trials. *Am J Clin Oncol* 1998; 21: 568–572.
- Alexander HR Jr, Libutti SK, Pingpank JF et al. Hyperthermic isolated hepatic perfusion using melphalan for patients with ocular melanoma metastatic to liver. *Clin Cancer Res* 2003; 9: 6343–6349.
- Agarwala SS, Panikkar R, Kirkwood JM. Phase I/II randomized trial of intrahepatic arterial infusion chemotherapy with cisplatin and chemoembolization with cisplatin and polyvinyl sponge in patients with ocular melanoma metastatic to the liver. *Melanoma Res* 2004; 14: 217–222.
- Aoyama T, Mastrangelo MJ, Berd D et al. Protracted survival after resection of metastatic uveal melanoma. *Cancer* 2000; 89: 1561–1568.
- Hsueh EC, Essner R, Foshag LJ et al. Prolonged survival after complete resection of metastases from intraocular melanoma. *Cancer* 2004; 100: 122–129.

# Uveal malignant melanoma: management options – stereotactic radiotherapy

CHAPTER

43

Karin Dieckmann, Gerald Langmann, Roy Ma, Mona Schmutzer, Richard Poetter, Werner Wackernagel, Martin Zehetmayer

## INTRODUCTION

Stereotactic radiotherapy involves precise positioning of the tumor in three-dimensional space by appropriate scanning and the delivery of ionizing radiation to the tumor from multiple directions.<sup>1</sup> A high dose of radiation is therefore focused on the target tissue, with relatively little irradiation of surrounding healthy tissues.

This chapter is based on contributions from independent investigators who jointly present an overview of this novel approach to the radiotherapy of uveal melanoma. The sections on radiosurgery and fractionated stereotactic radiotherapy respectively are written by workers from Graz and Vienna, both in Austria, with a contribution from British Columbia, Canada.

## TYPES OF STEREOTACTIC RADIOTHERAPY

There are two techniques of delivering stereotactic radiation to the eye: stereotactic radiosurgery, and fractionated stereotactic radiotherapy.

**Stereotactic radiosurgery** involves multiple radiation beams focused on the tumor simultaneously from different directions, the treatment usually being completed in a single session, or occasionally fractionated over several days.

**Fractionated stereotactic radiotherapy** During fractionated stereotactic radiotherapy (SRT) a single beam of radiation is aimed at the tumor from successively different directions, the entire treatment being delivered either in a single session or, more usually, in a fractionated manner over several sessions (Box 43.1).

## STEREOTACTIC RADIOSURGERY

Stereotactic radiosurgery (SRS) is minimally invasive and delivers a single focal dose of high-energy X-ray or  $\gamma$  radiation to a stereotactically defined target while sparing healthy surrounding tissue (Fig. 43.1).

**Treatment plans** are based on MRI scans. Gadolinium enhancement is used to distinguish the tumor (gross volume) from subretinal fluid. During treatment planning, critical structures such as the optic nerve, retina, macula, lens, and ciliary body are identified. A dose of 30 Gy is administered. A safety margin of 1–2 mm around the tumor is treated (planned treatment volume) (Fig. 43.2). Dose–volume histogram analysis is also performed to determine the likelihood of complications.<sup>2</sup>

**Procedure** The radiosurgical procedure is usually performed with the patient in the supine position. The eye is immobilized with a precision of +0.3 mm, either by combining a retrobulbar anesthetic block with transconjunctival sutures placed in the rectus muscles,<sup>3</sup> or by using a vacuum device.<sup>4</sup> The patient is positioned with the back of the head very close to the frame. Pins are fixed to the supraorbital region to position the eye as close to the center of the stereotactic space as possible (Fig. 43.3).

**Gamma knife** Radiosurgery is delivered using the Leksell Gamma Knife (LGK), which was invented by Lars Leksell in the early 1950s.<sup>5</sup> This device comprises 201 cobalt sources localized in a hemisphere around the patient's head so that all beams of  $\gamma$  radiation converge on the tumor.

## Results

**Tumor control and complications** Between 1992 and 1998, 60 patients were treated in Graz with prescription doses between 45 and 80 Gy (Fig. 43.4).<sup>2,3,6</sup> The mean basal tumor diameter was 12.2 mm (range 3–22 mm) and the mean height was 6.7 mm (range 3–12 mm). The follow-up period ranged from 16 to 94 months. Tumor regression was achieved in 56 (93%) patients. There were four recurrences, which were treated by enucleation. Neovascular glaucoma developed in 21 (35%) patients in a high-dose group (50–80 Gy) with larger tumors and in proximity to the ciliary body. Reduction of the prescription dose to <40 Gy and the exclusion of ciliary body tumors decreased the rate of glaucoma without affecting the rate of tumor control. Others have reported similar ocular results.<sup>7–12</sup>

**Metastasis** Multivariate analysis indicates that 5 years after treatment survival after stereotactic radiosurgery is not significantly worse than after enucleation.<sup>13</sup>

## FRACTIONATED STEREOTACTIC RADIOTHERAPY

Fractionated stereotactic radiotherapy combines the precision of stereotactic positioning with the radiobiological advantage of fractionation, thereby reducing long-term toxicity.

**Treatment planning** The size, shape, and location of the tumour are defined by ultrasonography, high-resolution CT scanning and MRI. A computerized 3D model of the eye and tumor is generated. The CT and MRI images are fused so that they can be viewed in axial, sagittal, or coronal planes. During CT and MRI delineation, the patient wears

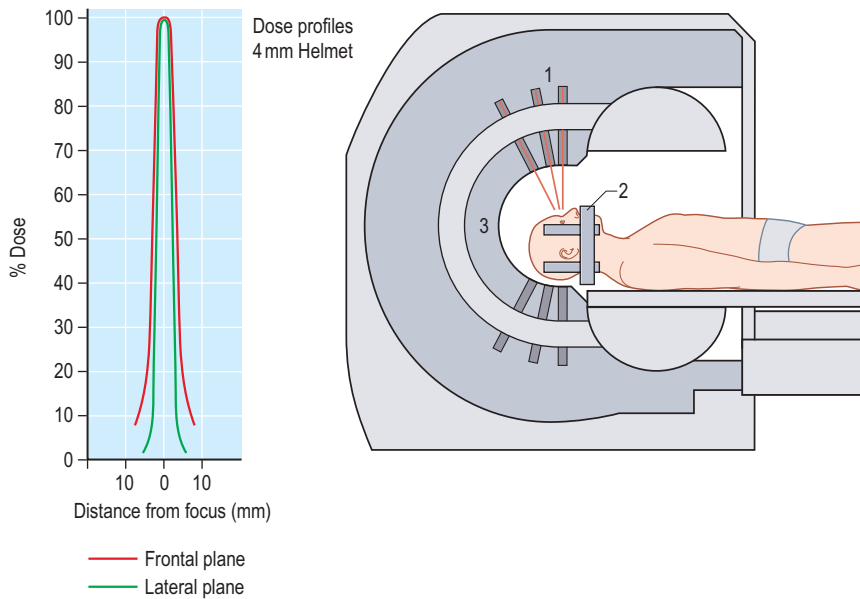


**BOX 43.1 Stereotactic Radiotherapy**

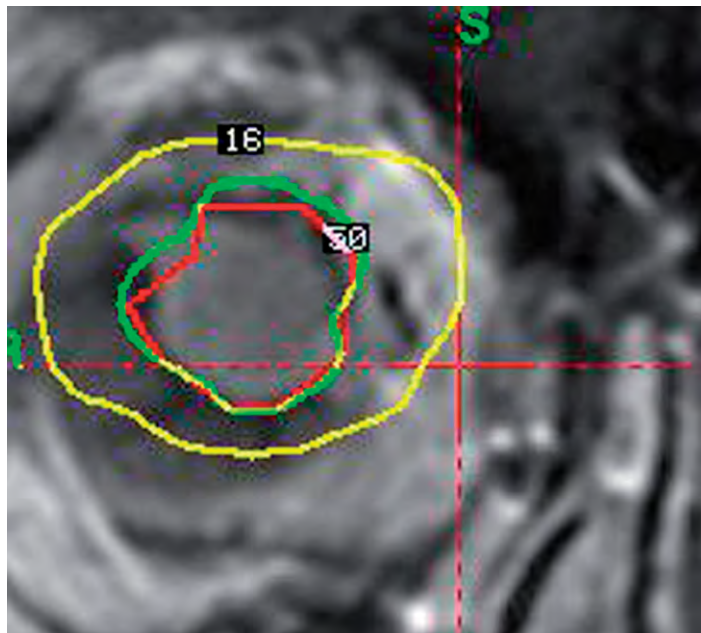
- Ionizing radiation is delivered to the tumor from multiple directions, either concurrently (stereotactic radiosurgery) or sequentially (stereotactic radiotherapy)
- The tumor is positioned precisely in three-dimensional space by appropriate scanning
- The patient's head and eye are immobilized using a variety of methods
- Stereotactic radiotherapy delivers a high dose of radiation to the tumor with small doses to surrounding tissues
- Early results are encouraging, indicating that this modality has a place in the treatment of uveal melanoma
- These methods are used mostly for posterior tumors that are difficult to treat with a plaque, and for large tumors

the same head mask and ocular fixation system as for subsequent treatment. A total dose of 50–60 Gy is usually delivered in five fractions over a period of up to 10 days.<sup>14,15</sup> The tumor is treated with a safety margin of 2.0–2.5 mm in all directions. Additionally, critical structures (lens, optic nerve, anterior eye segment, lacrimal gland) are contoured for treatment plan optimization, which includes dose–volume histograms.

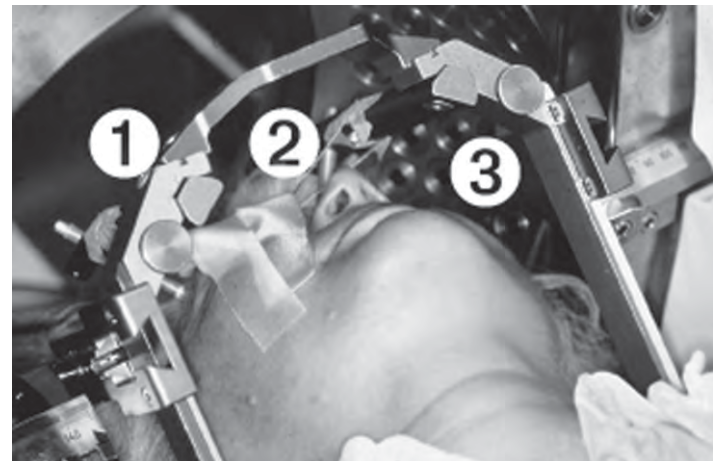
**Procedure** The patient's head is usually immobilized by means of a non-invasive rigid thermoplastic mask and bite block, which are prepared individually for each patient (Fig. 43.5) and attached to the patient's couch. The patient is asked to look at a blinking fixation light



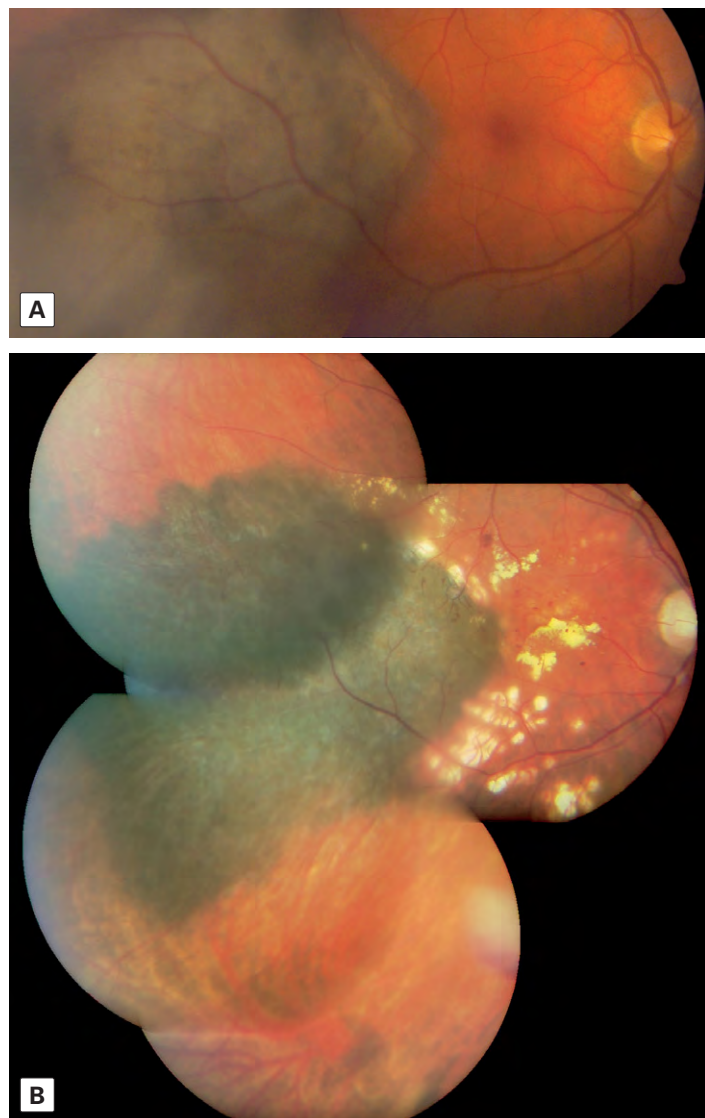
**Fig. 43.1** Drawing showing the Leksell Gamma Knife with the patient lying in the supine position. The beams of the 201  $\gamma$  sources (1) converge in the eye (cross-firing); the patient's head is fixed with the stereotactic frame (2) to the inner collimator helmet (3).



**Fig. 43.2** MRI scans showing juxtapapillary choroidal melanoma (red line). The 50% and 16% isodoses (coronal) view are represented by the green and yellow lines, respectively.




**Fig. 43.3** Patient's head fixed in an eccentric position within the stereotactic frame (1), eye fixed with sutures to the frame (2), stereotactic frame fixated to the inner collimator helmet (3).



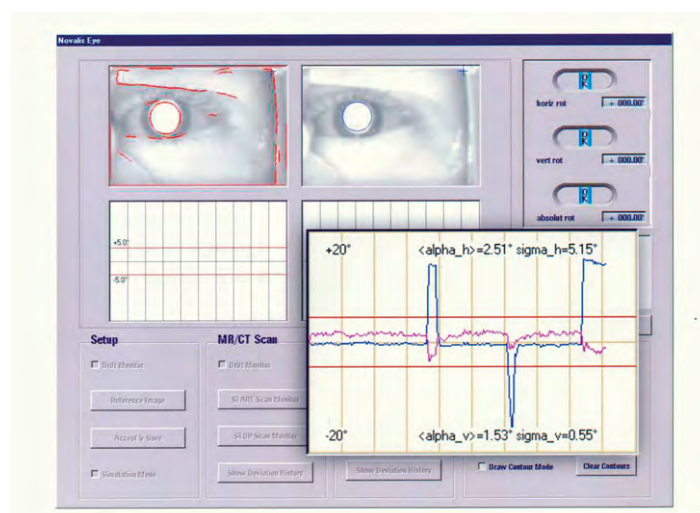
**Fig. 43.4** A 39-year-old man with a medium-sized choroidal melanoma (thickness of 4.8 mm) located in the macula (A). Four years 8 months after radiosurgery with a marginal dose of 35 Gy (max. dose 70 Gy) the visual acuity had deteriorated from 20/25 to 20/250 due to ischemic and exudative maculopathy (treated with photocoagulation). Note chorioretinal atrophy surrounding the tumor.

with the diseased eye or its fellow.<sup>14,15</sup> The eye position is monitored using an infrared illumination system and mini-video camera. Any ocular deviations are detected by means of customized graphic software, and if these exceed calculated limits the beam delivery is automatically interrupted until proper eye position is restored (Fig. 43.6).<sup>16,17</sup> At the start of each treatment session a quality assurance test of the complete setup is undertaken, using a laser positioning system to ensure that the tumor is accurately placed at the focal point of treatment.

**Linear accelerator** Using a linear accelerator (LINAC), a single beam of photons is directed sequentially at the tumor from many different directions through multiple, non-coplanar arcs or collimated static fields. The beam entry is spread over the superior part of the



**Fig. 43.5** LINAC setup with a phantom head with the ocular fixation system attached to the head mask. A micro-multileaf collimator is mounted on the gantry.



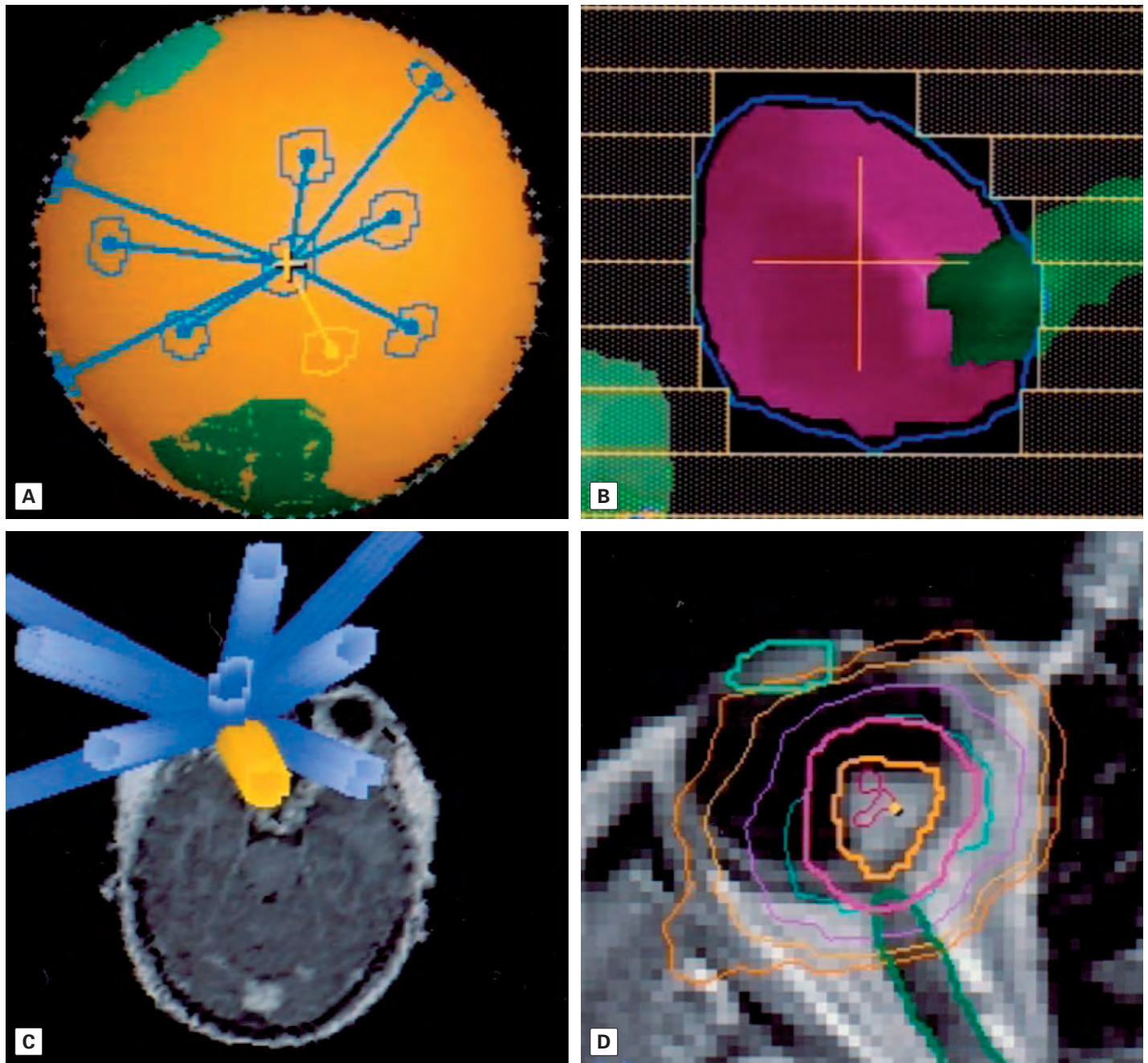
**Fig. 43.6** Software used for analysis of eye movements during LINAC beam delivery. Upper left: actual eye position window; upper right: zero position window; lower right: ocular deviations (blue and pink lines for vertical and horizontal, respectively). If ocular deviation exceeds  $5^\circ$  for more than 2 seconds, the beam delivery is automatically interrupted.

head. This ensures that the dose to surrounding tissue is minimized. In most cases, the beam is collimated with a micro-multileaf collimator consisting of multiple pairs of tungsten leaves (mMLC).<sup>18</sup> Computer software automatically adjusts the collimation in the mMLC for every angle of treatment, according to the contour of the tumor viewed from at that angle (Fig. 43.7). A comparative treatment planning study showed levels of dose conformation to be similar to those of proton beam radiotherapy.<sup>19</sup>

## Results

**Tumor control and complications** Between 1997 and 2004, 158 patients were treated with LINAC SRT in Vienna (Fig. 43.8). This therapy was selected for tumors with a thickness exceeding 7.0 mm or extending to within 3 mm of the optic disc or macula. Interim





**Fig. 43.7** Treatment planning of a choroidal melanoma (basal diameter 12.4 mm; thickness 6.2 mm). The gross treatment volume was 0.5 cm<sup>3</sup> and the planned target volume was 1.4 cm<sup>3</sup> (at 80% isodose). LINAC treatment was administered with 10 conformal static fields using an mmLC. The prescribed dose was 12 Gy (at 80% isodose) in five fractions. Stereographic projection of distribution of conformal static fields (A). Beam eye view of actual collimation with the leaf positions (yellow) used to conform the beam (B). Lens and optic nerve are superimposed in green. 3D overview of beam arrangement (C). Sagittal scans (axial view) after CT/MRI fusion with superimposed dose distributions. Gross tumor volume is shown in yellow and planned target volume is delineated in pink, with lens and optic nerve shown in green (D).

results have been published and more recent data are in press.<sup>7,14,20</sup> The tumors had a mean thickness of 5.2 mm (range 2.5–11.5). The median follow-up time was 33 months, and local control was achieved in 98% of patients. Long-term side effects included retinopathy (n = 70; 44%); cataract (n = 30; 23%); optic neuropathy (n = 65; 41%); and secondary neovascular glaucoma (n = 23; 13.8%). Secondary enucleation was performed in 23 patients (13.8%). Other groups using this technique have reported similar results.<sup>21,22</sup> Radiobiological rationale and experimental studies suggest that there is scope for

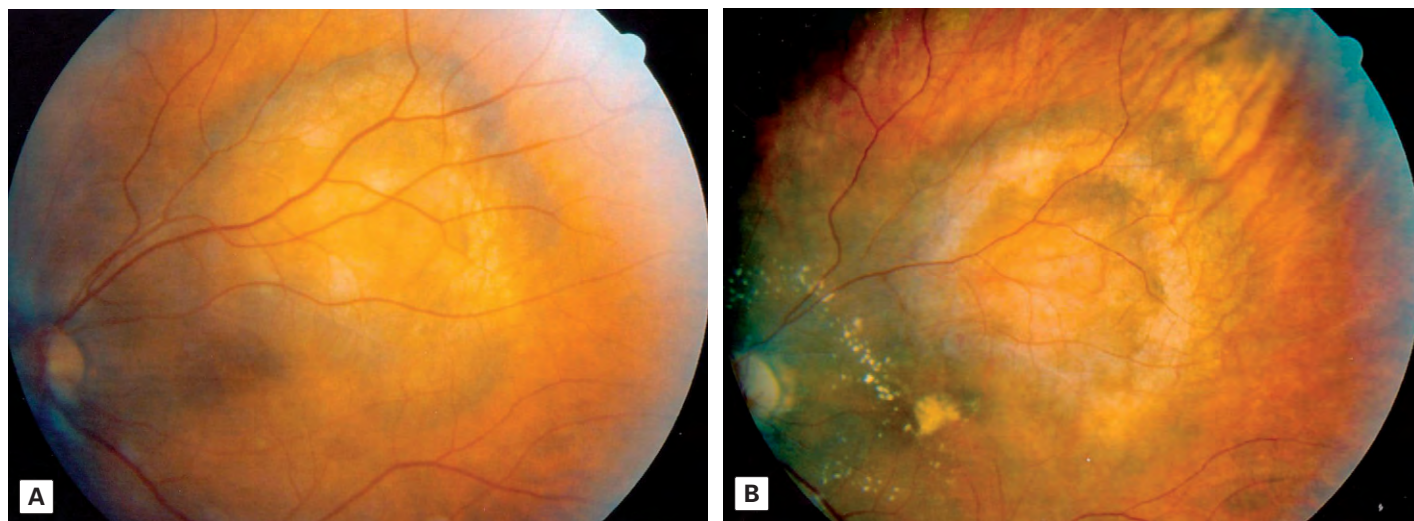
clinical trials using a reduced dose per fraction and a higher number of fractions.<sup>23</sup>

**Metastasis** Fifteen patients (9.0%) developed metastases over a median follow-up period of 33 months.

#### INDICATIONS AND CONTRAINDICATIONS

Both forms of stereotactic radiotherapy are useful for tumors that are considered unsuitable for brachytherapy, either because of posterior





**Fig. 43.8** Choroidal melanoma (thickness 3.3mm) prior to treatment with LINAC (five fractions of 12Gy each) (A); 24 months after treatment, there is tumor regression, optic nerve atrophy, and retinopathy around the tumor (B).

location or large size. With large tumors, stereotactic radiotherapy is contraindicated if the patient does not accept the increased chances of retinal detachment and neovascular glaucoma. Similarly, patients with posterior tumor extension must accept the increased likelihood of optic neuropathy and maculopathy. When there is a high risk of external eye and eyelid complications, careful counseling is required to ensure that the patient understands the implications regarding cosmesis and comfort.

For large uveal melanoma, stereotactic radiotherapy followed routinely by endoresection has been advocated as a means of improving local control while avoiding neovascular glaucoma.<sup>24</sup> The scope of stereotactic radiotherapy in the treatment of iris melanoma has not yet been evaluated.

## CONCLUSIONS

Radiosurgery and stereotactic radiotherapy are relatively new modalities of treatment for uveal melanoma. As the techniques are still evolving, some still regard these modalities as investigational. Preliminary results suggest high rates of local tumor control, with conservation of vision depending on the size and location of the tumor. Therefore, stereotactic radiotherapy administered either alone or in combination with other treatments can be considered for the treatment of selected cases of uveal melanoma.

## ACKNOWLEDGEMENT

The authors wish to thank their co-workers for their contributions.

## REFERENCES

- McKenzie MR, Ma R, Clark B et al. Stereotactic radiosurgery and radiation therapy in British Columbia. *Br Columbia Med J* 2001; 43: 567–572.
- Langmann G, Wackernagel W, Stucklschweiger G et al. [Dose–volume histogram regression analysis of uveal melanomas after single fraction gamma knife radiosurgery]. *Ophthalmologie* 2004; 101: 1111–1119.
- Langmann G, Pendl G, Mullner K et al. High- compared with low-dose radiosurgery for uveal melanomas. *J Neurosurg* 2002; 97: 640–643.
- Zehetmayer M, Menapace R, Kitz K et al. Suction fixation system for stereotactic radiosurgery of intraocular malignancies. *Acta Neurochir* 1995; 63 (Suppl): 115–118.
- Leksell L. The stereotaxic method and radiosurgery of the brain. *Acta Chir Scand* 1951; 102: 316–319.
- Langmann G, Pendl G, Klaus M et al. Gamma knife radiosurgery for uveal melanomas: an 8-year experience. *J Neurosurg* 2000; 93(Suppl 3): 184–188.
- Zehetmayer M, Kitz K, Menapace R et al. Local tumor control and morbidity after one to three fractions of stereotactic external beam irradiation for uveal melanoma. *Radiother Oncol* 2000; 55: 135–144.
- Rennie I, Forster D, Kemeny A et al. The use of single fraction Leksell stereotactic radiosurgery in the treatment of uveal melanoma. *Acta Ophthalmol Scand* 1996; 74: 558–562.
- Marchini G, Babighian S, Tomazzoli L et al. Stereotactic radiosurgery of uveal melanomas: preliminary results with Gamma Knife treatment. *Stereotact Funct Neurosurg* 1995; 64(Suppl 1): 72–79.
- Logani S, Cho AS, Ali BH et al. Single-dose compared with fractionated-dose radiation of the OM431 choroidal melanoma cell line. *Am J Ophthalmol* 1995; 120: 506–510.
- Mueller AJ, Talies S, Schaller UC et al. [Stereotaxic precision irradiation of large uveal melanomas with the gamma knife]. *Ophthalmologie* 2000; 97: 537–545.
- Simonova G, Novotny J, Jr., Liscak R et al. Leksell gamma knife treatment of uveal melanoma. *J Neurosurg* 2002; 97: 635–639.
- Cohen VM, Carter MJ, Kemeny A et al. Metastasis-free survival following treatment for uveal melanoma with either stereotactic radiosurgery or enucleation. *Acta Ophthalmol Scand* 2003; 81: 383–388.
- Zehetmayer M, Dieckmann K, Kren G et al. Fractionated stereotactic radiotherapy with linear accelerator for uveal melanoma – preliminary Vienna results. *Strahlenther Onkol* 1999; 175(Suppl 2): 74–75.
- Muller K, Nowak PJ, de Pan C et al. Effectiveness of fractionated stereotactic radiotherapy for uveal melanoma. *Int J Radiat Oncol Biol Phys* 2005; 63: 116–122.
- Dieckmann K, Bogner J, Georg D et al. A linac-based stereotactic irradiation technique of uveal melanoma. *Radiother Oncol* 2001; 61: 49–56.
- Petersch B, Bogner J, Dieckmann K et al. Automatic real-time surveillance of eye position and gating for stereotactic radiotherapy of uveal melanoma. *Med Phys* 2004; 31: 3521–3527.
- Georg D, Dieckmann K, Bogner J et al. Impact of a micromultileaf collimator on stereotactic radiotherapy of uveal melanoma. *Int J Radiat Oncol Biol Phys* 2003; 55: 881–891.
- Weber DC, Bogner J, Verwey J et al. Proton beam radiotherapy versus fractionated stereotactic radiotherapy for uveal melanomas: A comparative study. *Int J Radiat Oncol Biol Phys* 2005; 63: 373–384.
- Dieckmann D, Georg D, Bogner J et al. Optimizing LINAC based stereotactic radiotherapy of uveal melanomas: 7 years' clinical experience. *Int J Radiat Oncol Biol Phys* 2006 (in press).
- Tokuuye K, Akine Y, Sumi M et al. Fractionated stereotactic radiotherapy for choroidal melanoma. *Radiother Oncol* 1997; 43: 87–91.
- Muller K, Nowak PJ, Luyten GP et al. A modified relocatable stereotactic frame for irradiation of eye melanoma: design and evaluation of treatment accuracy. *Int J Radiat Oncol Biol Phys* 2004; 58: 284–291.
- van den Aardweg GJ, Kilic E, de Klein A et al. Dose fractionation effects in primary and metastatic human uveal melanoma cell lines. *Invest Ophthalmol Vis Sci* 2003; 44: 4660–4664.
- Bornfeld N, Talies S, Anastassiou G et al. [Endoscopic resection of malignant melanomas of the uvea after preoperative stereotactic single dose convergence irradiation with the Leksell gamma knife]. *Ophthalmologie* 2002; 99: 338–344.

# Uveal malignant melanoma: management options – resection techniques

CHAPTER

44

Bertil Damato and Carl Groenewald

## INTRODUCTION

Local resection of uveal melanoma was for many years restricted to small iris and ciliary body melanomas, mostly because of the technical difficulties associated with the excision of larger and more posterior tumors, and also because of theoretical concerns about inducing metastatic spread. In the 1960s, Stallard<sup>1</sup> described trans-scleral resection of choroidal melanoma, recommending this procedure only if the other eye was blind and if radiotherapy was unsuccessful. In the 1970s, Foulds<sup>2</sup> started performing this operation as a primary treatment, irrespective of the functional status of the fellow eye, and in 1984 was joined by the first author,<sup>3</sup> who also performed transretinal resections, introducing several technical refinements for both kinds of procedure. There are now several different methods of local tumor resection (Box 44.1), and techniques and results have been reported by a number of authors.<sup>4–9</sup>

## IRIDECTOMY

Iridectomy is being performed less frequently than before, first because treatment of small iris tumors is increasingly delayed until definite growth is documented, and second because of a trend towards plaque or proton beam radiotherapy.

**Indications and contraindications** Iridectomy is indicated if the iris tumor is considered to be a malignant melanoma. Contraindications include the involvement of more than four clock hours of the iris, and diffuse spread or seeding.

**Surgical technique** (Fig. 44.1) The pupil is dilated if a broad iridectomy is planned and constricted if conservation of the iris sphincter is intended. The tumor is removed with a safety margin of approximately 1–2 mm. After entering the anterior chamber by means of a corneoscleral incision, two radial incisions are made in the iris and the iridectomy completed by cutting the base of the iris with iridectomy scissors. If possible, the iris is sutured with 10/0 Prolene to reform the pupil. The corneoscleral wound is closed with 10/0 nylon.

**Results and complications** Local recurrence can occur if the tumor is incompletely excised. The iris coloboma tends to cause a cosmetic deficit and photophobia, which may require treatment with a painted contact lens or an artificial iris implant. Lens touch can result in cataract.

## IRIDOCYCLECTOMY

Iridocyclectomy involves partial surgical removal of the iris and ciliary body. In general, iridocyclectomy carries a greater risk of complications than does iridectomy. Increasingly, iris and ciliary body melanomas are being treated with radiotherapy.<sup>11</sup>

**Indications and contraindications** Iridocyclectomy is indicated for an iris melanoma involving the angle, and for ciliary body melanomas or adenocarcinomas. This procedure is contraindicated if the tumor involves more than four clock hours of the ciliary body or angle, or if there is diffuse spread. Extraocular spread is a relative contraindication, depending on whether or not it is small and encapsulated.

**Surgical technique** (Fig. 44.2) A fornix-based conjunctival flap is prepared and two traction sutures are placed in the sclera. The tumor extent is defined by transpupillary transillumination and marked on the sclera with a pen. Using a Desmarres scarifier, a limbus-based lamellar scleral flap is prepared, extending into cornea if the tumor involves the iris. A deep scleral incision is made, approximately 1 mm within the superficial incision, so as to create a stepped wound edge. This is done first posteriorly, then laterally, and finally anterior to the tumor. The tumor is excised with safety margins of about 1–2 mm. An incision is made in the peripheral iris, to prevent iris prolapse, and extended either along the anterior margin of the tumor or along the lateral and posterior margins. Alternatively, if the tumor is mostly ciliary, the uvea is perforated in the region of the pars plana and resected either posteroanteriorly or in a circumferential (transverse direction) so as to preserve as much of the iris as possible. The tumor is lifted from the eye using the deep scleral lamella as a handle. Care is taken to avoid damage to the lens. It may be possible to conserve some of the zonules and ciliary epithelium. The vitreous base can usually be left intact, either repositioning prolapsed vitreous as the sclera is closed, or performing a limited vitrectomy, either using the open-sky technique or through a separate sclerotomy. The sclera is closed with interrupted sutures.

An alternative technique is to perform full-thickness corneoscleral excision with grafting, using a corneal trephine.<sup>10</sup>

**Results and complications** The complications of iridocyclectomy are similar to those of iridectomy (Fig. 44.3). In addition, ocular hypotony can occur as a result of excessive cyclectomy (more than four clock hours), wound leakage, or cyclodialysis (which is more

likely to occur if adjunctive radiotherapy is administered at the same time as the resection, instead of being delayed by a few weeks). If more than four clock hours of the ciliary body is excised the lens can subluxate, causing keratopathy if it comes into contact with the corneal endothelium. Malignant glaucoma can develop, but this is rare.

### TRANS-SCLERAL CHOROIDECTOMY

Trans-scleral local resection is a controversial procedure because of its complex nature and the profound systemic hypotension that is required. It is therefore performed only in a few centers, where it is reserved for highly motivated patients.

**Indications and contraindications** Primary tumor resection is indicated in cases where the tumor is considered unsuitable for radiotherapy. Secondary local tumor resection can be useful as a salvage procedure after radiotherapy, either to remove active tumor or as a

treatment for exudative retinal detachment and neovascular glaucoma (i.e. 'toxic tumor syndrome').<sup>2</sup>

Contraindications to trans-scleral local resection include any systemic disease that precludes profound hypotensive anesthesia; a basal tumor diameter greater than 16 mm; retinal perforation; optic disc involvement; invasion of more than three clock hours of the ciliary body or angle; and diffuse disease. Extraocular extension is not a contraindication if the tumor is otherwise resectable or treatable with adjunctive radiotherapy. This type of surgery should ideally be performed only by surgeons having adequate experience, and if the patient is highly motivated to conserve the eye and vision.

**Surgical technique** (Fig. 44.4) A fornix-based conjunctival flap is prepared. Extraocular muscles in the operative field are disinerted after placing sutures and measuring the knot-to-limbus distances. The tumor is localized by transpupillary transillumination. A lamellar scleral flap is dissected, hinged posteriorly. Any vortex veins or long posterior ciliary arteries entering the flap are cauterized and divided. The eye is partially collapsed by performing a limited pars plana vitrectomy, thereby preventing retinal prolapse through the scleral window. The deep sclera is incised with scissors around the tumor, first laterally, then posteriorly, and finally anteriorly. The deep scleral incision is made about 1–2 mm within the superficial incisions so as to create a stepped wound edge. The choroid is opened by gently holding it with two pairs of notched micro-forceps, which are slowly pulled apart. The uveal incision is made with blunt-tipped spring scissors, first anterior to the tumor, then along each side, and finally posteriorly. With ciliochoroidal tumors it is usually possible to conserve most of the ciliary epithelium if the uveal incision is started posterior to the ora serrata. As the uveal incision is made, the tumor is slowly lifted out of the eye using the deep lamellar scleral flap as a handle. The retina usually separates spontaneously from the tumor, but if not it may be necessary to separate these two structures by blunt or sharp dissection (the safety of leaving intraretinal tumor in situ is uncertain).

#### BOX 44.1. Local Resection of Uveal Melanoma\*

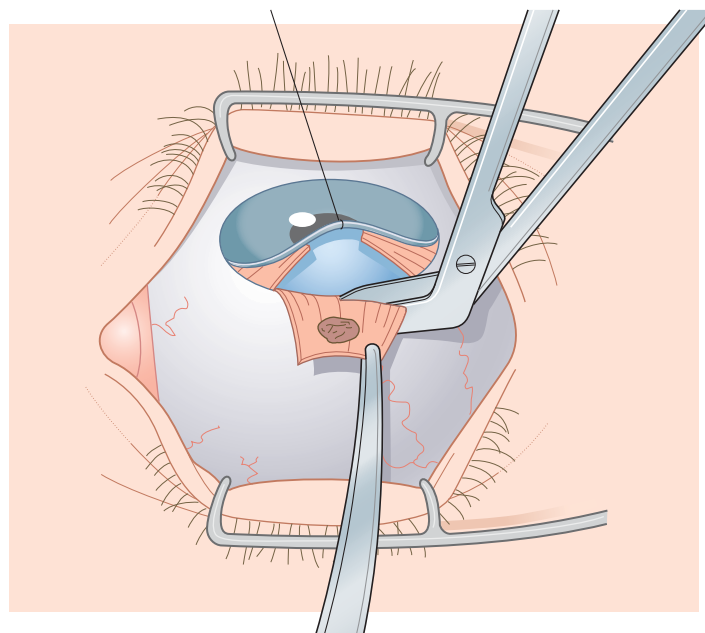
##### Exoresection

- Iridectomy
- Iridocyclectomy/cyclo-iridectomy
- Trans-scleral choroidectomy/choroido-cyclectomy

##### Endoresection

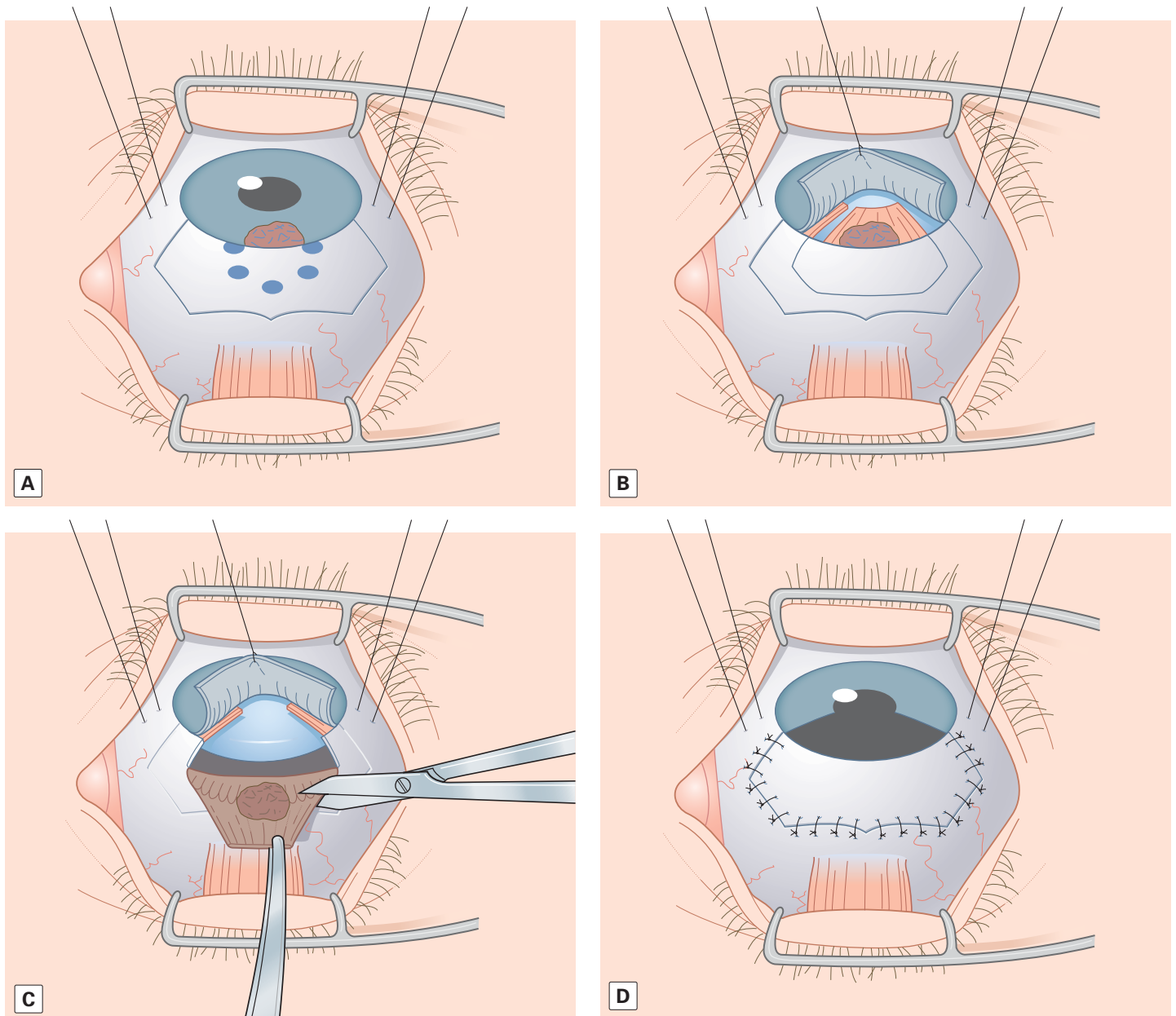
- Transretinal choroidectomy

\*Primary (+/- adjunctive brachytherapy) or secondary (after proton beam or stereotactic radiotherapy)

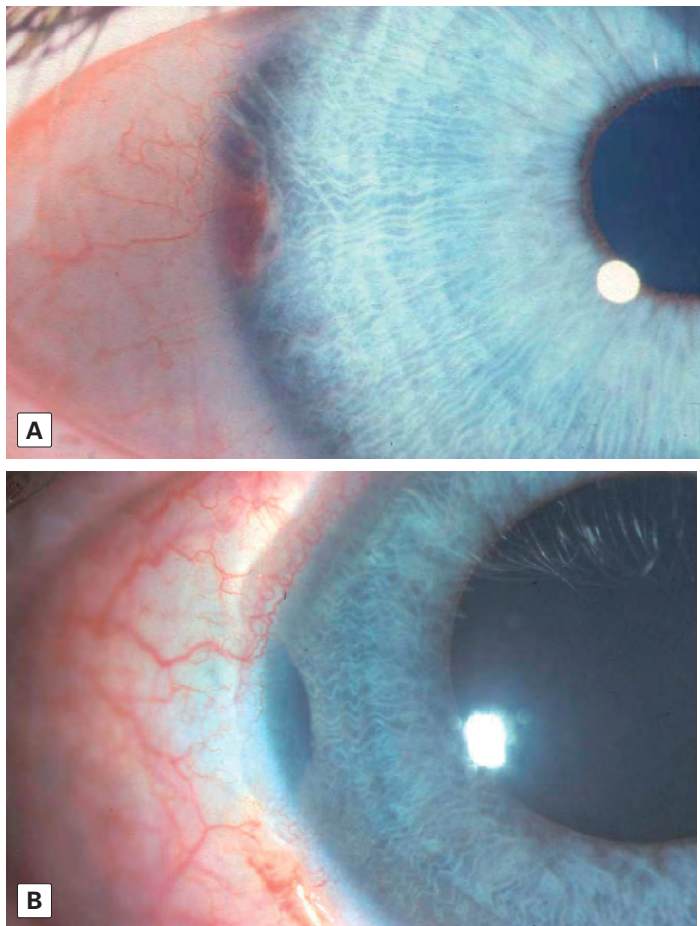


**Fig. 44.1** Technique of iridectomy. (Reproduced with permission from Damato B. *Ocular tumours: diagnosis and treatment*. Oxford: Butterworth-Heinemann, 2000.)





**Fig. 44.2** Technique of iridocyclectomy. Preparation of lamellar scleral flap hinged at the limbus (A). Deep scleral incisions, creating a stepped wound edge (B). Iridocyclectomy, starting anteriorly if broad iridectomy is performed (as shown) or posteriorly if only peripheral iridectomy is done (C). Suturing of scleral flap (D). (Reproduced with permission from Damato B. *Ocular tumours: diagnosis and treatment*. Oxford: Butterworth-Heinemann, 2000.)



**Fig. 44.3** Unidentified iridociliary tumor in the right eye of a 15-year-old boy. Preoperative appearance, showing a pink, multicystic tumor (A). Slit lamp appearance after cycloiridectomy, showing good conservation of the iris sphincter (B). The tumor proved to be an ectopic thyroid gland.<sup>24</sup> Nine months postoperatively the vision was 20/15 and the patient was in good health.

As soon as the tumor has been removed, the traction sutures are pulled gently until the retina starts to bulge through the scleral window. Two sponge cells are placed posterior to the scleral flap to indent the eye, thereby avoiding subretinal hematoma. Using a fresh set of instruments, the eye is closed with interrupted nylon sutures. A balanced salt solution is injected through the pars plana sclerotomy. If adjunctive brachytherapy is to be administered, a 25 mm ruthenium plaque is inserted, reattaching any disinserted extraocular muscles with slings, so that they are in approximately their correct anatomical locations. The conjunctiva is closed in the usual fashion. Antibiotics and steroids are given in the surgeon's preferred manner. If adjunctive brachytherapy is administered, the plaque is removed after delivering a dose of 100 Gy to a depth of approximately 1–2 mm.

Hemorrhage is minimized by lowering the systolic blood pressure to approximately 45 mmHg, with appropriate cardiac and cerebral monitoring. In selected cases, closure of some of the short posterior ciliary arteries is also helpful.

**Results and complications** It is possible to conserve good visual acuity if the tumor does not extend close to fovea (Fig. 44.5).<sup>12</sup> Visual outcome seems superior to that after radiotherapy of large tumors.<sup>13,14</sup> Peripheral visual field loss is not a problem, except when the tumor

**Fig. 44.4** Trans-scleral partial choroidectomy. Preparation of lamellar scleral flap, hinged posteriorly, and deep scleral incision, creating a stepped wound edge (A). Choroidectomy, avoiding retinal damage if possible (B). Closure of scleral flap with interrupted nylon sutures (C). Adjunctive brachytherapy (D). (Reproduced with permission from Damato B. Ocular tumours: diagnosis and treatment. Oxford: Butterworth-Heinemann, 2000.)

is located nasally. Some of the serious complications of trans-scleral choroidectomy include incomplete tumor resection, rhegmatogenous retinal detachment, choroidal tears, expulsive hemorrhage, and systemic complications of hypotensive anesthesia.

**Incomplete tumor resection** results in either visible tumor at the end of the procedure or microscopic, subclinical deposits, which develop into clinically detectable recurrent tumor after months or years.<sup>15</sup> Rarely, the recurrence can be non-contiguous with the site of the original tumor.<sup>16</sup> Failure to detect and treat any recurrence promptly can result in extraocular extension of the tumor. Adjunctive brachytherapy seems to reduce the incidence of local recurrence, especially if a large, 25 mm plaque is used, but the radiotherapy can itself cause complications, such as wound dehiscence, maculopathy, and optic neuropathy.<sup>17</sup> Brachytherapy immediately following cycloectomy can also cause hypotony and phthisis, which seem to be avoidable by delaying the radiotherapy by a few weeks.

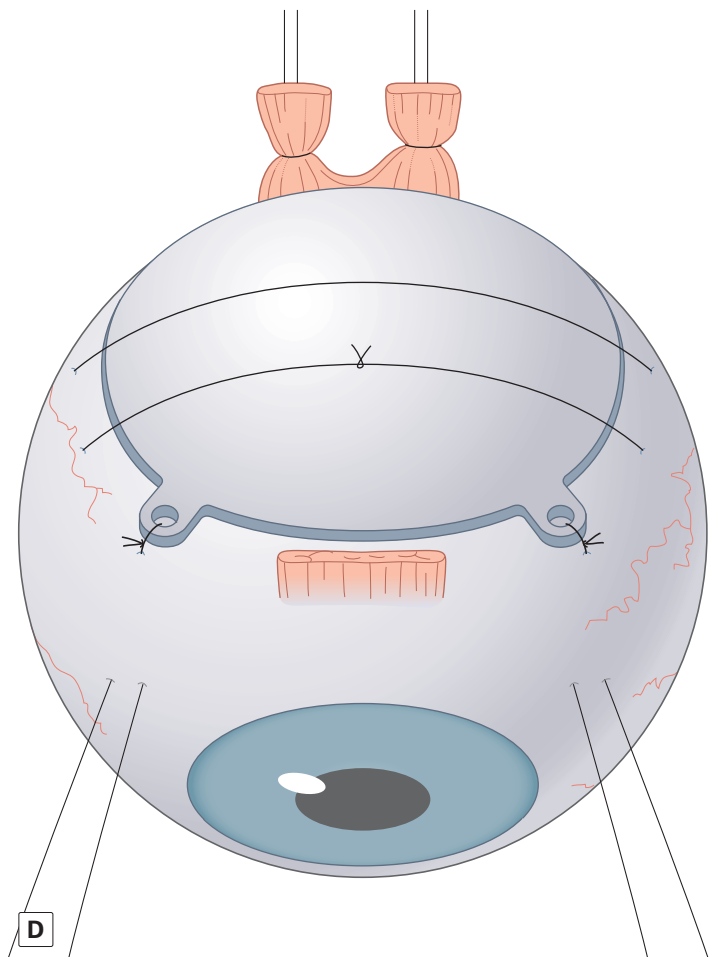
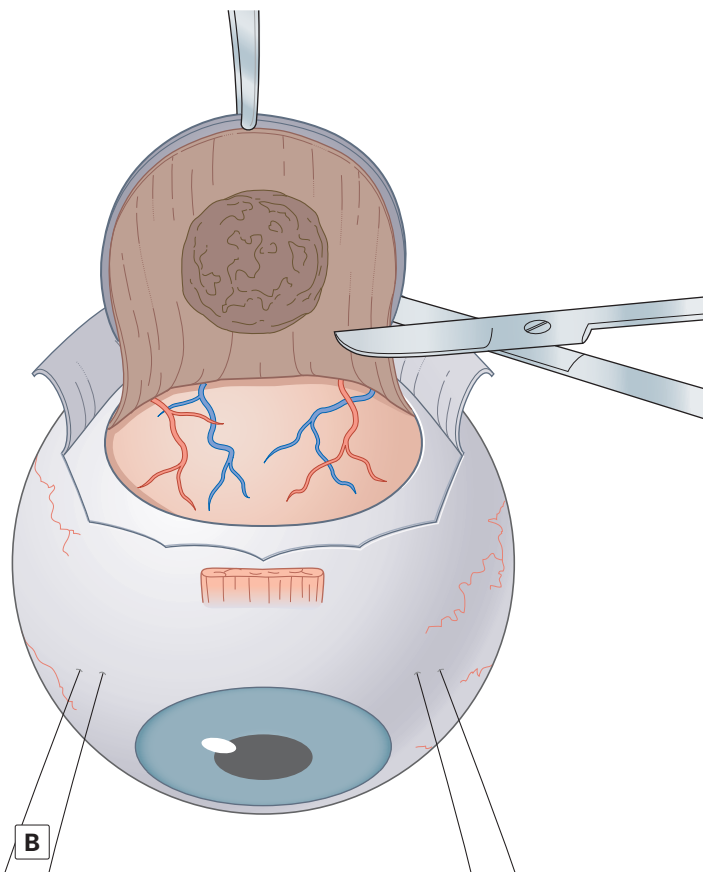
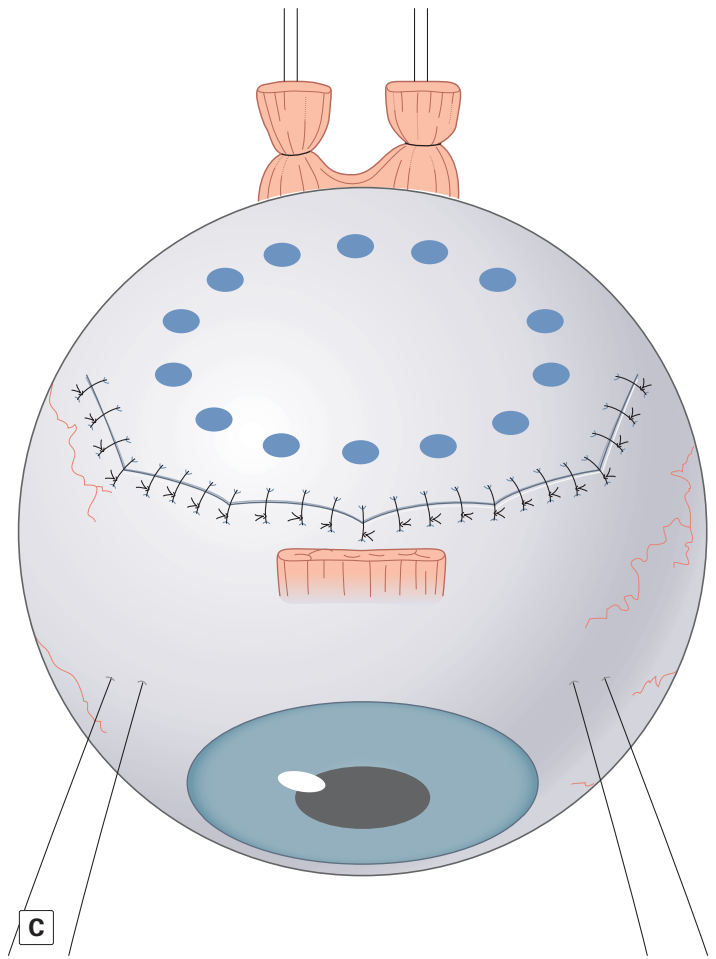
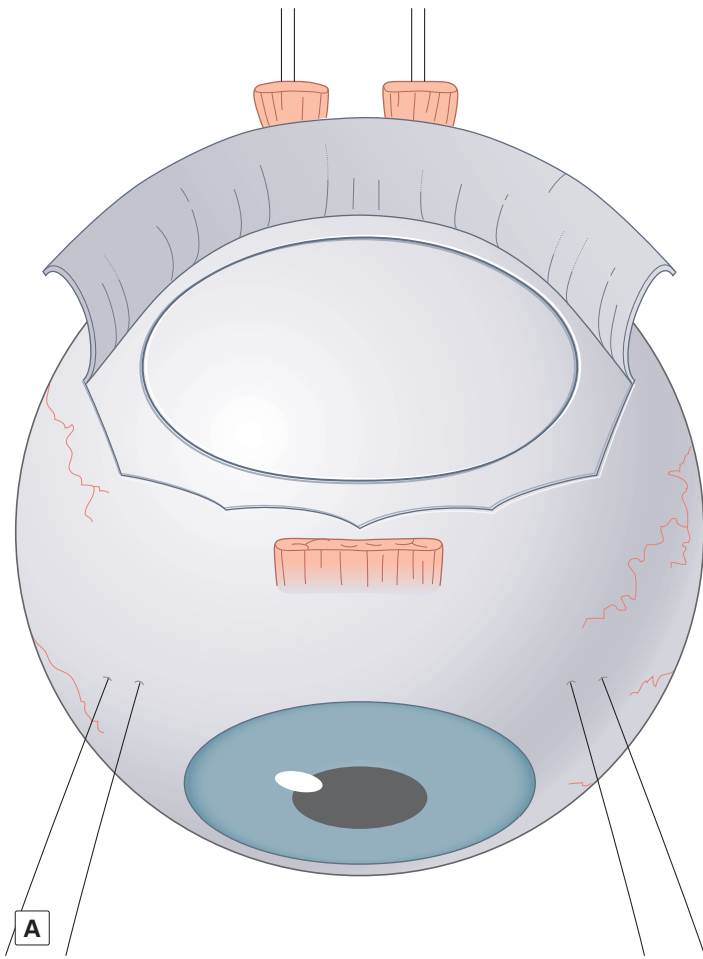
**Rhegmatogenous retinal detachment** is quickly complicated by proliferative vitreoretinopathy and irreversible loss of visual function.<sup>18</sup> If a retinal break occurs immediate treatment is indicated, consisting of total vitrectomy, removal of subretinal blood, endolaser retinopexy, and silicone oil tamponade, with such vitreoretinal surgery performed as soon as the scleral flap has been closed.

**Expulsive hemorrhage** is prevented by profound systemic hypotensive anesthesia. Subretinal hematoma is avoided by exerting traction on the scleral sutures and indenting the eye during scleral closure, as mentioned above; however, if this complication occurs the subretinal blood can be removed surgically. Vitreous hemorrhage developing in the postoperative period indicates the presence of a retinal break requiring treatment.

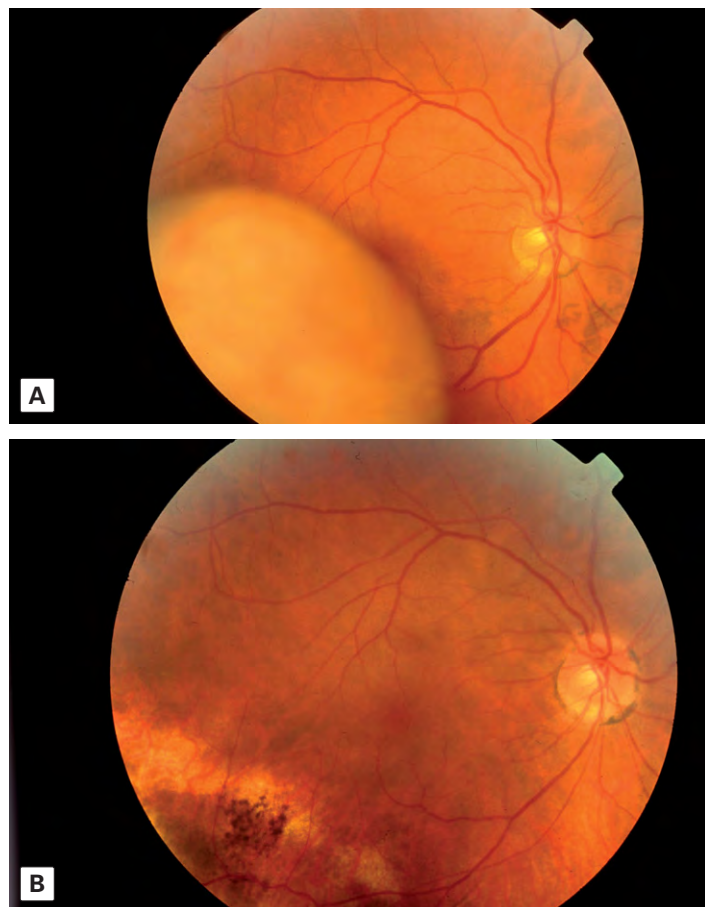
**Choroidal tears** can occur if the tumor is pulled excessively as it is being resected. Choroidal new vessels can arise from such a tear or from the edge of the surgical coloboma, and such neovascularization can result in a disciform macular scar.

**Systemic complications of hypotensive anesthesia** such as myocardial or cerebral infarction, should not occur if the anesthesia is administered by a skilled practitioner with appropriate monitoring, and if the systemic hypotension is immediately abandoned if there are any signs of distress.

**Metastasis** Risk factors for metastatic disease after local resection are similar to those of enucleation.<sup>19</sup> Non-randomized studies suggest that survival after local resection is not significantly worse than after enucleation.<sup>20</sup>







**Fig. 44.5** Preoperative fundus photograph of a 53-year-old man showing an inferior collar-stud melanoma measuring 8.9 × 8.6 mm in its basal dimensions with a thickness of 8.4 mm in the right eye (A). The visual acuity was 20/40. Fundus appearance seven months post-operatively, when the vision had improved to 20/20 (B). Histology confirmed a mixed cell type melanoma, with no closed loops and a low mitotic rate. Cytogenetic studies showed no monosomy 3 and no gains in chromosome 8. These findings indicated that the 5-year survival probability was better than 90%.

## ENDORESECTION

Transretinal local resection of choroidal melanoma is a very controversial procedure because of concerns regarding intraocular, extraocular, and systemic tumor dissemination.

**Indications and contraindications** Primary endoresection is performed in selected cases when radiotherapy is unlikely to conserve visual acuity (juxtapapillary and/or transretinal tumors), and when the patient understands the controversial nature of the operation. As a secondary procedure, endoresection is useful after radiotherapy, either to remove apparently active tumor or as a treatment for exudative maculopathy or retinal detachment.

**Surgical technique** (Fig. 44.6) A total vitrectomy is performed. Access to the tumor is achieved either through a retinotomy directly over the tumor or by making a peripheral retinectomy and folding the

retina away from the tumor. The tumor is removed piecemeal with the vitreous cutter, initially forming a crater into which any hemorrhage will pool. Seemingly normal choroid around the tumor area is also removed in case there are any invisible tumor extensions laterally. Hemorrhage is controlled by raising the intraocular pressure and lowering the systolic pressure. On completion of tumor removal, endolaser treatment is administered to the surgical margins and to the exposed scleral surface to reduce hemorrhage and to destroy any residual tumor. A fluid–air exchange is then performed to flatten the retina, so that retinopexy is performed. The peripheral retina is examined with indentation for entry-site tears, any of which are treated with cryotherapy. The eye is filled with silicone oil, which is removed after 12 weeks.

**Results and complications** The final vision depends on the location of the tumor.<sup>3</sup> If it is far from the fovea then good visual acuity should be retained (Fig. 44.7).

**Tumor recurrence** Local tumor recurrence at the primary site can be marginal or intrascleral, and if left untreated can seed through the retinotomy into the vitreous or can extend extraocularly.<sup>21</sup> Ideally, therefore, all patients should receive adjunctive radiotherapy at the end of the local resection, although this can be difficult if the tumor is juxtapapillary. Dissemination of the tumor throughout the eye has not been seen in the author's series of more than 60 patients, except for one patient who was lost to follow-up and who developed local recurrence, which spread through the retinotomy and around the eye.<sup>22</sup> Some surgeons therefore perform stereotactic or proton beam radiotherapy prior to the resection.<sup>23</sup>

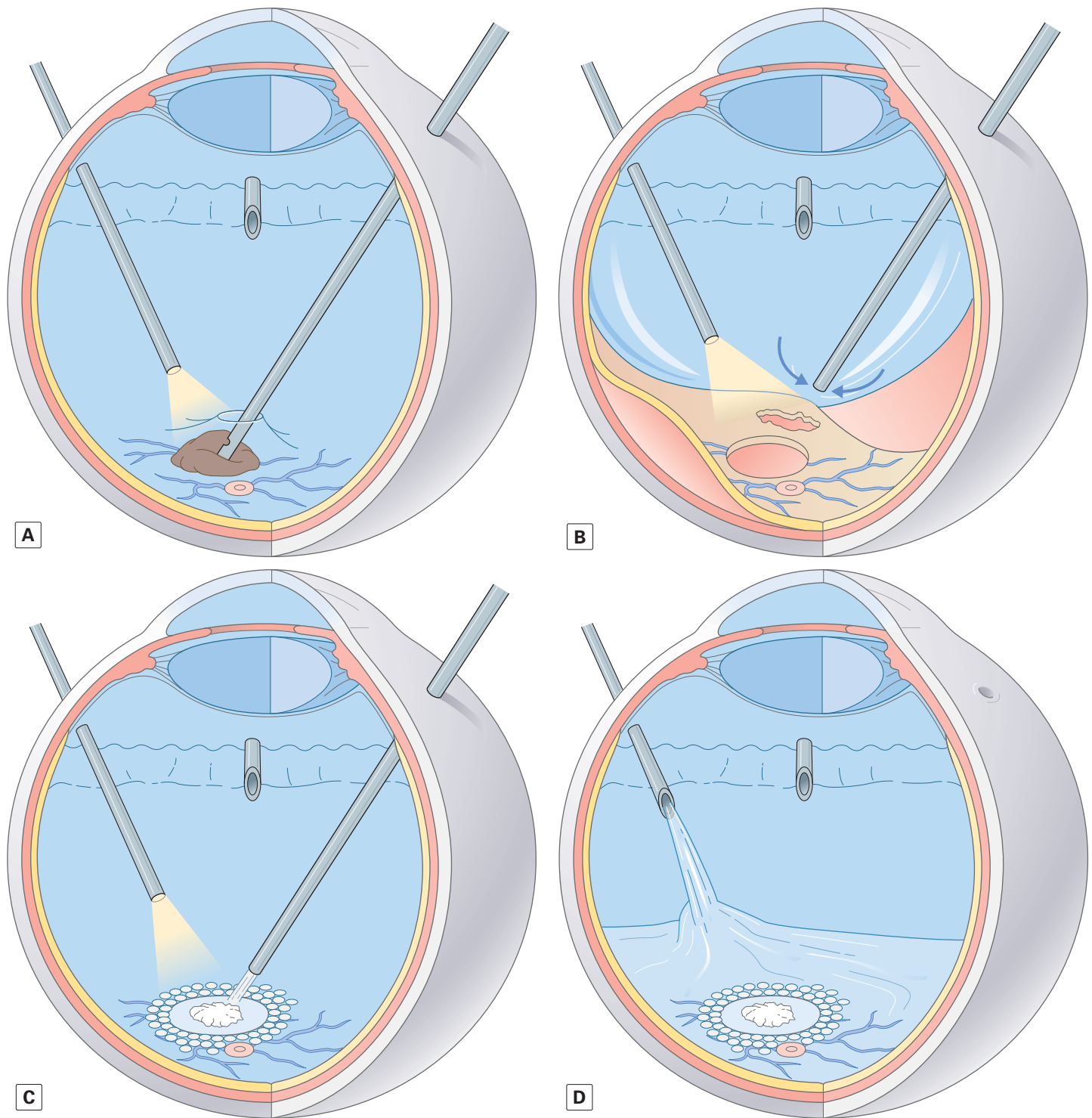
**Rhegmatogenous retinal detachment** can occur if the retinopexy around the coloboma is inadequate, or if entry site tears have not been identified and treated before the silicone oil is removed. Hypotony and phthisis can occur, particularly if the retinotomy is greater than about 7 mm in diameter. Postoperative hemorrhage should not be a problem if there is an adequate fill of silicone oil. Cataract is a common complication of silicone oil tamponade, and is treated in the usual way.

## CONCLUSIONS

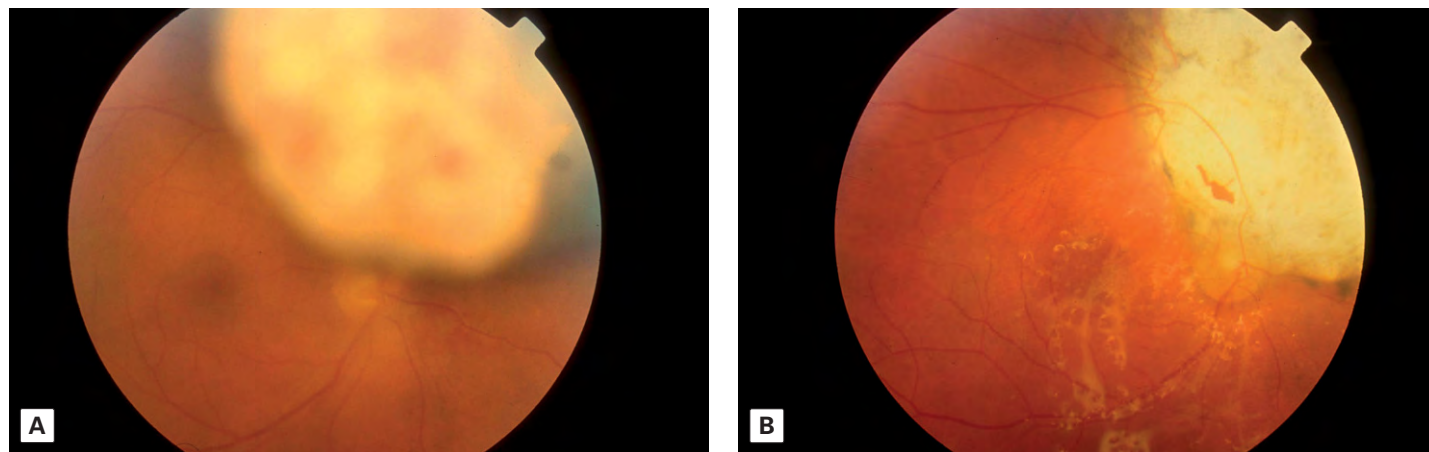
Surgical refinements to local resection have reduced the incidence and severity of complications, which have become treatable thanks to numerous advances in the techniques of vitreoretinal surgery and radiotherapy. In addition, theoretical concerns regarding tumor dissemination have proved to be unfounded. This type of surgery is therefore being increasingly performed, both as primary treatment of uveal melanoma and as salvage therapy after radiotherapy.

The successful treatment of radiation-induced exudative retinal detachment and neovascular glaucoma by local resection suggests that these complications are caused by the persistence of bulky irradiated tumor in the eye ('toxic tumor syndrome'). This recent insight will probably result in a shift from radiotherapy to local resection in selected cases, and, conversely, greater interest in secondary local resection after radiotherapy.

Advances in molecular biology and cytogenetics are increasing the need to obtain tumor tissue so as to improve prognostication. In the future, tumor tissue may also be needed for immunotherapy and other biological treatments for systemic disease.



**Fig. 44.6** Transretinal endoresection. Tumor removal through retinotomy (A). Fluid-air exchange, to flatten the retina (B). Retinopexy and endolaser treatment to scleral bed (C). Air-silicone exchange (D). (Reproduced with permission from Damato B. Ocular tumours: diagnosis and treatment. Oxford: Butterworth-Heinemann, 2000.)



**Fig. 44.7** Recurrent choroidal melanoma in a 51-year-old woman after previous brachytherapy in another center. Preoperative photograph showing a collar-stud tumor measuring  $15.9 \times 15.8$  mm in its basal dimensions, with a thickness of 10.3 mm in the right eye (A). Four clock hours of the optic disc margin were involved by tumor. The visual acuity was 20/100 in the affected eye, which was the only seeing eye, the fellow eye having previously been enucleated after an injury. Fundus appearance 3 months after endoresection, showing reflexes from the intraocular silicone (B). The visual acuity was 20/60. Cytogenetic studies showed monosomy 3 and gains in chromosome 8, indicative of a poor prognosis for survival and referral to an oncologist was advised.

## REFERENCES

1. Stallard HB. Partial choroidectomy. *Br J Ophthalmol* 1966; 50: 660–662.
2. Damato BE, Foulds WS. Surgical resection of choroidal melanoma. In: Schachat AP, Ryan SJ, eds. *Retina*, 4th edn. St Louis: Mosby, 2006; 769–778.
3. Damato B, Groenewald C, McGalliard J, Wong D. Endoresection of choroidal melanoma. *Br J Ophthalmol* 1998; 82: 213–218.
4. Peyman GA, Gremillion CM. Eye wall resection in the management of uveal neoplasms. *Jpn J Ophthalmol* 1989; 33: 458–471.
5. Shields JA, Shields CL. Surgical approach to lamellar sclerouvectomy for posterior uveal melanomas: the 1986 Schoenberg lecture. *Ophthalm Surg* 1988; 19: 774–780.
6. Garcia-Arumi J, Sararols L, Martinez V, Corcostegui B. Vitreoretinal surgery and endoresection in high posterior choroidal melanomas. *Retina* 2001; 21: 445–452.
7. Bornfeld N, Talies S, Anastassiou G, Schilling H, Schuler A, Horstmann GA. [Endoscopic resection of malignant melanomas of the uvea after preoperative stereotactic single dose convergence irradiation with the Leksell gamma knife]. *Ophthalmologie* 2002; 99: 338–344.
8. Char DH, Miller T, Crawford JB. Uveal tumour resection. *Br J Ophthalmol* 2001; 85: 1213–1219.
9. Kertes PJ, Johnson JC, Peyman GA. Internal resection of posterior uveal melanomas. *Br J Ophthalmol* 1998; 82: 1147–1153.
10. Naumann GO, Rummelt V. Block excision of tumors of the anterior uvea. Report on 68 consecutive patients. *Ophthalmology* 1996; 103: 2017–2027.
11. Damato B, Kacperek A, Chopra M et al. Proton beam radiotherapy of iris melanoma. *Int J Radiat Oncol Biol Phys* 2005; 63: 109–115.
12. Damato BE, Paul J, Foulds WS. Predictive factors of visual outcome after local resection of choroidal melanoma. *Br J Ophthalmol* 1993; 77: 616–623.
13. Bechrakis NE, Bornfeld N, Zoller I, Foerster MH. Iodine 125 plaque brachytherapy versus transscleral tumor resection in the treatment of large uveal melanomas. *Ophthalmology* 2002; 109: 1855–1861.
14. Kivela T, Puusaari I, Damato B. Transscleral resection versus iodine brachytherapy for choroidal malignant melanomas 6 millimeters or more in thickness: a matched case-control study. *Ophthalmology* 2003; 110: 2235–2244.
15. Damato BE, Paul J, Foulds WS. Risk factors for residual and recurrent uveal melanoma after trans-scleral local resection. *Br J Ophthalmol* 1996; 80: 102–108.
16. Kim JW, Damato BE, Hiscott P. Noncontiguous tumor recurrence of posterior uveal melanoma after transscleral local resection. *Arch Ophthalmol* 2002; 120: 1659–1664.
17. Damato BE. Adjunctive plaque radiotherapy after local resection of uveal melanoma. *Front Radiat Ther Oncol* 1997; 30: 123–132.
18. Damato B, Groenewald CP, McGalliard JN, Wong D. Rhegmatogenous retinal detachment after transscleral local resection of choroidal melanoma. *Ophthalmology* 2002; 109: 2137–2143.
19. Damato BE, Paul J, Foulds WS. Risk factors for metastatic uveal melanoma after trans-scleral local resection. *Br J Ophthalmol* 1996; 80: 109–116.
20. Foulds WS, Damato BE, Burton RL. Local resection versus enucleation in the management of choroidal melanoma. *Eye* 1987; 1: 676–679.
21. Damato B, Wong D, Green FD, Mackenzie JM. Intrasclear recurrence of uveal melanoma after transretinal 'endoresection.' *Br J Ophthalmol* 2001; 85: 114–115.
22. Hadden PW, Hiscott PS, Damato BE. Histopathology of eyes enucleated after endoresection of choroidal melanoma. *Ophthalmology* 2004; 111: 154–160.
23. Bechrakis NE, Hocht S, Martus P et al. [Endoresection following proton beam irradiation of large uveal melanomas]. *Ophthalmologie* 2004; 101: 370–376.
24. Tiberti A, Damato B, Hiscott P, Vora J. Iris ectopic thyroid tissue. Report of a case. *Arch Ophthalmol* 2006; (in press).



# Uveal malignant melanoma: COMS results

Arun D. Singh and Tero Kivelä

## INTRODUCTION

Until the 1980s, most studies on the treatment of uveal melanoma were retrospective and included only small numbers of patients treated at a given center.<sup>1,2</sup> The optimal management for uveal melanomas, whether small, medium, or large, was debatable<sup>3,4</sup> and the benefit of enucleation was being questioned.<sup>5,6</sup> Therefore, in 1984, at the request of Dr Kupfer, Director of the National Eye Institute (Bethesda, Maryland), the Collaborative Ocular Melanoma Study (COMS) trials were designed. Funding was obtained from the National Eye Institute. In this review we summarize the main objectives, significant design features, and major findings of the COMS.

The COMS is a multicenter study with 43 participating Clinical Centers in North America with centralized units dealing with echography (North Carolina), photography (Iowa), pathology (Wisconsin), radiation physics (Texas), and general coordination (Maryland).<sup>7</sup> The details of the entire protocol and procedures of the study are available elsewhere.<sup>8</sup>

## ELIGIBILITY AND EXCLUSION CRITERIA

The general eligibility criteria for patients with uveal melanoma included a minimum age of 21 years, the ability to give informed consent, and agreement to return for follow-up visits (Box 45.1). Although the name of the trial refers to 'ocular melanoma,' the trial was limited to unilateral, predominantly choroidal melanoma, with the specific exclusion of conjunctival, iris, and ciliary body melanomas. Tumors that touched the optic disc were excluded from the medium choroidal melanoma randomized trial but were included in the large tumor trial. Other exclusion criteria are listed in Box 45.2.

## COMS CLASSIFICATION OF CHOROIDAL MELANOMA

The COMS divided choroidal melanomas into small, medium, or large tumors according to largest basal diameter (LBD) and height (Fig. 45.1).<sup>8</sup> In December 1990, the lower boundary of height for medium-sized tumors was redefined from 3.0 to 2.5 mm so as to increase patient recruitment in this group.

## MAIN OUTCOME MEASURES

About 40% of deaths in patients with uveal melanoma are not melanoma-related,<sup>9</sup> and the proportion of deaths from nonmalignant diseases tends to increase with the length of follow-up and increasing age of the patients.<sup>10</sup> Although the main outcome measure in COMS was all-cause mortality,<sup>8</sup> the cause of death was graded by the Mortality Coding Committee as follows: confirmed melanoma metastasis;

suspected melanoma metastasis; other malignant tumor; no evidence of malignancy; and insufficient evidence to establish melanoma metastasis.<sup>11</sup>

## COMS TRIALS AND OBSERVATIONAL STUDIES

The COMS includes two randomized trials, for medium<sup>12</sup> and large tumors respectively,<sup>13</sup> and two observational studies (Fig. 45.2).<sup>14,15</sup> In addition, several technical<sup>16,17</sup> and adjunct papers relevant to the understanding of choroidal melanoma have been published.<sup>18,19</sup>

**Small choroidal melanoma observational study** A total of 204 patients with a small melanoma (i.e. 93% of those eligible) were enrolled in an observational study aimed at determining the proportion of small melanomas that grew, and their impact on survival.<sup>14</sup> Three-quarters of the patients had been diagnosed less than 1 year prior to enrolment, the remainder having been followed for 1–14 years.

**Growth of small choroidal melanoma** This prospective study identified clinical features associated with time to tumor growth, using a standard set of fundus photographs.<sup>20</sup> Growth was defined as increase from small to either medium or large. Initial observation was chosen for 188 tumors. The Kaplan–Meier estimates of the probability of growth were 11%, 21%, and 31% at 1, 2, and 5 years of enrolment, respectively (Fig. 45.3). Interestingly, 63% of small tumors classified as melanoma did not grow during 5 years.

By multivariate analysis, small melanomas with prominent orange pigment were 6.4 times more likely to grow than tumors lacking this feature, and tumor thickness of at least 2 mm and largest basal diameter of 12 mm or more were respectively 4.4 and 5.2 times more likely to grow than smaller tumors. Additionally, the absence of drusen on the tumor surface and the absence of retinal pigment epithelial (RPE) changes adjacent to the tumor were associated with a higher likelihood of growth (Table 45.1).

**Mortality with small choroidal melanoma** Of the 204 patients 27 had died, and six of these deaths were coded as melanoma-related. The Kaplan–Meier estimate of all-cause mortality was 6% (95% CI 3–9) and of melanoma-related mortality was 1% (95% CI 0–3) at 5 years (Fig. 45.4).<sup>14</sup> This study indicated a low risk of death from a small melanoma within 5 years, even though the majority of these patients were not treated.

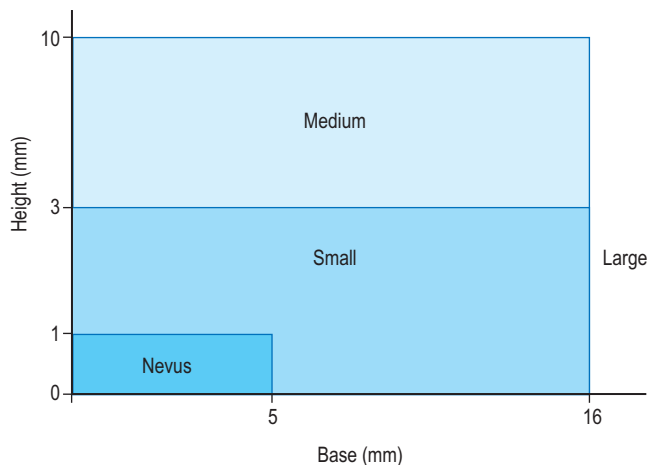
**Medium choroidal melanoma: randomized trial of enucleation versus brachytherapy** Patients with medium-

**BOX 45.1 Eligibility Criteria for Collaborative Ocular Melanoma Study**

- Primary choroidal melanoma in one eye
- Age 21 years or older
- Ability to give informed consent
- Ability to return for scheduled follow-up
- No contraindication for surgery or radiation

**BOX 45.2 Exclusion Criteria for Collaborative Ocular Melanoma Study**

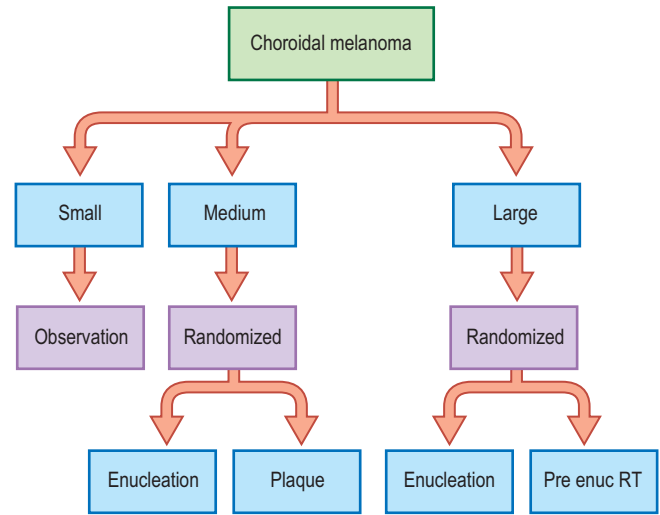
- Previous biopsy of choroidal melanoma
- Previous treatment of choroidal melanoma
- 50% or more of tumor involving the ciliary body
- Gross extrascleral extension
- Use of immunosuppressive therapy
- Any other primary or metastatic malignancy except non-melanotic skin cancer and carcinoma in situ of uterine cervix



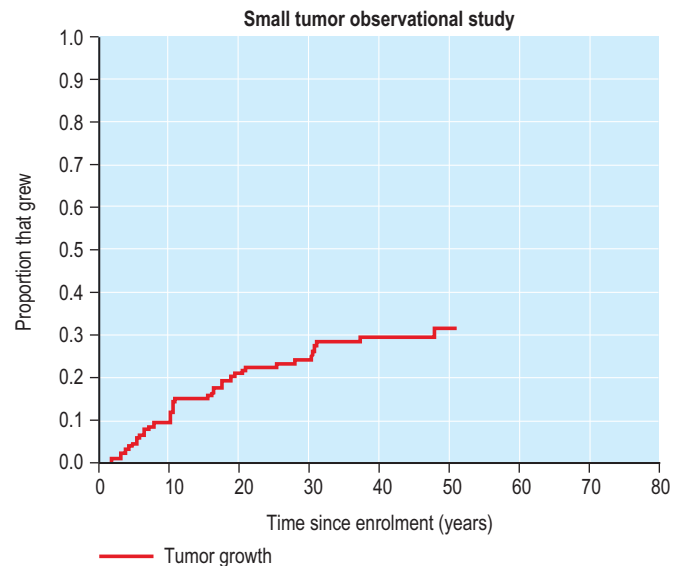
**Fig. 45.1** Collaborative Ocular Melanoma Study classification of choroidal melanoma. In December 1990, patient enrolment into the medium tumor trial was increased by lowering the tumor height threshold from 3mm to 2.5mm.

sized choroidal melanomas were randomized to receive enucleation or iodine-125 brachytherapy.<sup>7,12,21</sup> The rationale was a concern that any treatment other than enucleation might increase mortality. Of the 5046 patients with medium choroidal melanoma, 2882 were eligible and 1317 (46% of eligible patients) were enrolled. The main reasons for not enrolling were the preference of the patient or the ophthalmologist (73%) for a particular form of treatment, and unwillingness to accept random assignment (22%). The patients who did not enrol tended to be younger and to have a smaller tumor, better vision in the affected eye, and worse vision in the fellow eye than the patients who enrolled. Only 31% of non-enrolled patients chose enucleation, and most (58%) opted for brachytherapy.

**Visual outcome following brachytherapy** Visual loss due to radiation-induced complications following brachytherapy was associ-



**Fig. 45.2** Component trials of Collaborative Ocular Melanoma Study.



**Fig. 45.3** Kaplan-Meier plot of time to growth of small choroidal melanoma. (Modified with permission from COMS Group. Factors predictive of growth and treatment of small choroidal melanoma: COMS Report No. 5. Arch Ophthalmol 1997; 115: 1537-1544.)

ated with greater tumor thickness (RR 4.7, 2.5-5.0 vs 7.6-10.0 mm), proximity to the foveal avascular zone (RR 5.9, 0 vs > 8.0mm), a history of diabetes (RR 2.75), and the presence of exudative retinal detachment (RR 1.5-1.7).

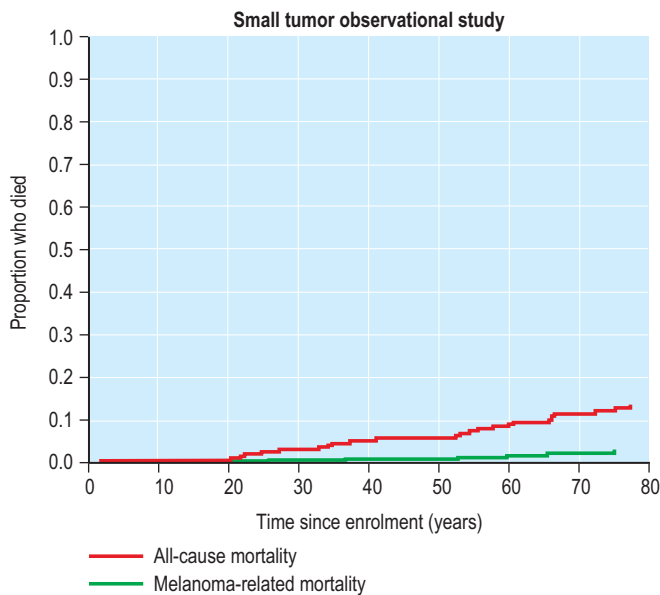
Almost half (49%) of the patients treated in this trial were estimated to have lost six or more lines of vision (quadrupling of the minimum angle of resolution) at 3 years by the life table method. The average loss was two lines per year and loss of vision was usually permanent. Three years after brachytherapy the median visual acuity was 20/125, and 31% and 41% of eyes had 20/40 or better and 20/200 or worse vision, respectively. When counseling the patient, it is useful to know that about 43% (95% CI 38-48) will have a final visual acuity of <20/200 at 3 years and the majority will depend on their fellow eye for visual function, which is expected to remain good.<sup>22</sup>

**Local treatment failure and secondary enucleation** The Kaplan-Meier estimate of the probability of treatment failure was 10%

**Table 45.1 Features associated with growth of small choroidal melanoma**

Feature	Dimensions	Risk ratio	95% Confidence interval
Height (mm)	1.0–1.9	1.0	Reference category
	2.0–2.4	4.41	(0.56–34.9)
	2.5–3.0	17.74	(2.36–133)
Basal diameter (mm)	4.0–8.0	1	Reference category
	8.1–12.0	0.77	(0.29–2.03)
	12.1–16.0	5.16	(1.86–14.3)
Drusen	Absent	1.0	Reference category
	Present	0.24	(0.10–0.59)
Area of RPE changes	Absent	1.0	Reference category
	Present	0.23	(0.09–0.57)
Orange pigment	Absent	1.0	Reference category
	Minimal	1.56	(0.70–3.45)
	Prominent	6.38	(2.80–14.5)

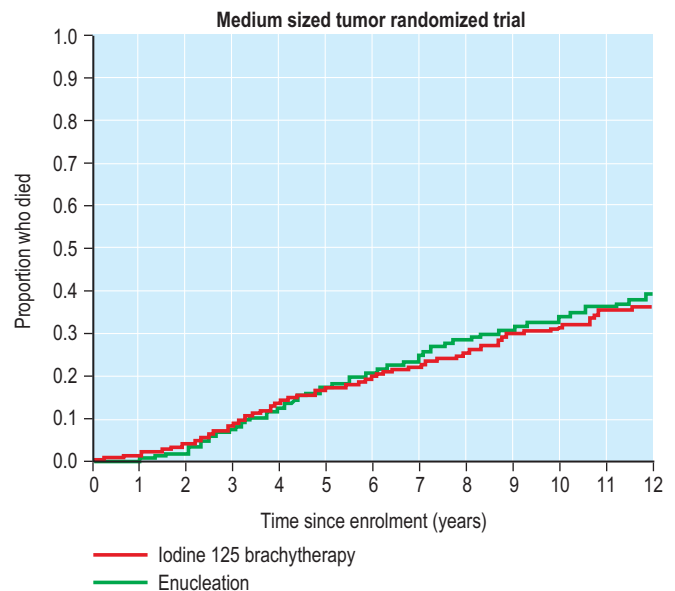
Modified with permission from Group COMS. Factors predictive of growth and treatment of small choroidal melanoma. COMS Report No. 5. Arch Ophthalmol 1997; 115: 1537–1544.



**Fig. 45.4** Kaplan–Meier plot of all-cause (red line) and melanoma-related (green line) mortality from small choroidal melanoma. (Modified with permission from COMS Group. Mortality in patients with small choroidal melanoma. COMS report no. 4. Arch Ophthalmol 1997; 115: 886–893.)

(95% CI 8–13) at 5 years. Risk factors for treatment failure were older age (RR 2.9, < 50 vs = 69 years), greater tumor thickness (RR 2.4, 2.5–5.0 vs 5.1–10.0 mm), and proximity of the tumor to the foveal avascular zone (RR 2.5, 0 vs 2.1–8.0). Most of these cases were managed by enucleation. Ocular pain from radiation-related complications was the second leading cause of enucleation.

**Mortality with medium choroidal melanoma** Of the 345 deaths classified by the Mortality Coding Committee, 46% and 11% were caused by histopathologically confirmed metastatic melanoma and second cancer, and 12% were attributed to an unspecified malignant tumor because of lack of histopathologic or cytologic confirmation. The remaining 26% of deaths were from non-malignant disease.



**Fig. 45.5** Kaplan–Meier plot of all-cause mortality after iodine-125 brachytherapy (red line) and enucleation (green line) for medium-sized choroidal melanoma. Note similar outcome in both study arms. (Modified with permission from Diener-West M, Earle JD, Fine SL et al. The COMS randomized trial of iodine 125 brachytherapy for choroidal melanoma, III: initial mortality findings. COMS Report No. 18. Arch Ophthalmol 2001; 119: 969–982.)

The Kaplan–Meier estimates of 5-year all-cause mortality were comparable for both treatment arms: 19% (95% CI 16–23) for enucleation and 18% (95% CI 15–21) for brachytherapy ( $P = 0.48$ ; Fig. 45.5). The Kaplan–Meier estimate of 5-year melanoma-related mortality based on histopathologically confirmed metastasis was also comparable for both treatment arms: 11% (95% CI 8–13) for enucleation and 9% (95% CI 7–11) for brachytherapy ( $P = 0.56$ ). Higher age at diagnosis, larger tumor size, and proximity to the optic disc were some of the factors associated with higher mortality.

**Large choroidal melanoma: randomized trial of enucleation alone versus pre-enucleation irradiation** Patients



with a large choroidal melanoma were randomly assigned to enucleation with and without prior radiation (20 Gy was delivered in five daily fractions).<sup>13,23</sup> There was a theoretical suggestion that enucleation might promote seeding of tumor cells into the circulation,<sup>5</sup> and preoperative radiotherapy had reduced metastases of other malignant tumors, such as small cell lung cancer.<sup>24</sup>

Of the 1860 patients with large choroidal melanomas 1302 were eligible, and 1003 (77%) of these were enrolled. The most common reasons for not enrolling were preference of the patient or the ophthalmologist (53%), and unwillingness to accept random assignment (25%).<sup>25</sup> Patients who did not enrol had smaller tumors and worse vision in the fellow eye than those who did enrol.

**Local complications of enucleation** In all patients undergoing enucleation, pain (2%) and hemorrhage (1%) were the main complications. Minor complications such as eyelid swelling were slightly more common among those treated with pre-enucleation radiation (8% vs 4%), but the risk of wound dehiscence and infection was equal between two treatment arms. Long-term complications, in both groups, were mainly cosmetic and related to motility of the prosthesis (18% at 5 years), alignment of the prosthesis (4%), and ptosis (3%).

**Mortality with large choroidal melanoma** Of the 435 deaths classified by the Mortality Coding Committee, 62% and 5% were due to histopathologically confirmed metastatic melanoma and second cancer, and 21% were attributed to an unspecified malignant tumor because of lack of histopathologic or cytologic specimens.<sup>26</sup> Only 9% of patients with a large melanoma died of non-malignant disease.

The Kaplan–Meier estimates of 5-year all-cause mortality were comparable for both treatment arms: 57% (95% CI 52–62) for enucleation alone and 62% (95% CI 57–66) for pre-enucleation radiation ( $P = 0.32$ ; Fig. 45.6). The 10-year death rates from histopathologically confirmed metastases were 45% for the pre-enucleation radiation

group and 40% for enucleation alone (risk ratio 1.02 [95% CI 0.93–1.42]).<sup>27</sup> These findings suggest the absence of a clinically or statistically significant difference between the treatment groups. Older age and larger basal tumor diameter were the main predictors of time to death.<sup>27</sup> However, a recently published non-randomized study suggested improved long-term survival in patients treated with pre-enucleation radiotherapy.<sup>28</sup>

### Natural history observational study: medium and large choroidal melanoma

Of the 77 patients with medium and large choroidal melanoma who refused treatment, 61 were eligible and 45 (42 medium and three large tumors) were enrolled to the natural history study. Of the 42 patients with a medium-sized melanoma, 22 (52%) were subsequently treated after a median delay of 1.4 years (range 0.2–5.1). The Kaplan–Meier estimate of all-cause mortality was 30% (95% CI 18–47) at 5 years (Fig. 45.6). Although it was higher than the corresponding 18% (95% CI 16–20) estimated for enrolled patients, the estimates did not differ statistically. The unadjusted risk of death in patients who deferred treatment was about twice the risk of patients who were treated promptly (RR 1.8), but after adjusting for differences in age at enrolment and LBD, which differed significantly between the observational study and the randomized trial, the hazard ratio was smaller (RR 1.5; 95% CI 0.9–2.6).

Given the small number of patients, the study did not rule out that prompt treatment of medium-sized melanoma, by either enucleation or brachytherapy, prolongs survival. A further limitation of the study is that competing causes of death were not taken into account, and that the cause of death often remained undetermined.

### Adjunct studies

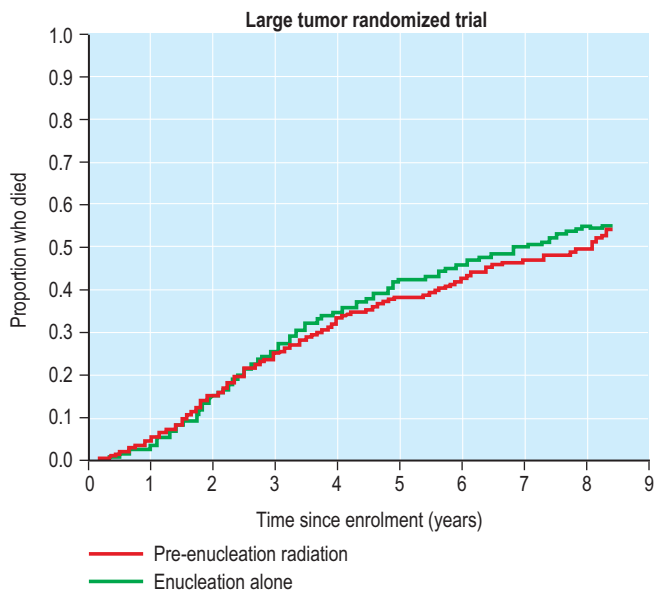
#### Quality of life cross-sectional study of medium choroidal melanoma

An ancillary study to the medium-sized tumor trial was designed to measure the impact of disease and its treatment on quality of life. Of the 1317 enrolled patients, 842 were interviewed at selected intervals during follow-up.<sup>29</sup> The assessments included the SF-36 Health Survey, the Activities of Daily Vision Scale, the Visual Functioning Questionnaire, and the Hospital Anxiety and Depression Scale.<sup>30</sup> Appearance scores were significantly associated with appearance-altering complications, recurrence scores with secondary enucleation following brachytherapy, and stereopsis–binocularity scores were higher in patients with good visual acuity in both eyes. Quality-of-life comparisons between treatment arms are pending.

#### Histopathologic features of choroidal melanoma

Of the 1527 eyes enucleated in the medium-sized and large tumor trials, only five did not contain a malignant melanoma; of these, four harbored a metastatic adenocarcinoma and one a choroidal hemangioma.<sup>18</sup> Thus, the participating investigators were more than 99% accurate in clinically diagnosing medium and large choroidal melanoma. Mixed cell type choroidal melanoma (<50% of cells epithelioid in type) was the most commonly observed type both among medium (85%) and large (82%) melanomas. Large melanoma was associated with higher proportions of the mixed and epithelioid type. There was evidence of invasion of Bruch's membrane (88%), retina (49%), sclera (57%), and optic nerve head (8%) by both medium and large tumors.

**Screening for metastasis** Patients enrolled in the medium and large choroidal melanoma trials were screened annually for metastasis



**Fig. 45.6** Kaplan–Meier plot of all-cause mortality after pre-enucleation radiation (red line) and enucleation alone (green line) for large choroidal melanoma. Note similar outcome in both study arms. (Modified with permission from COMS Group. The Collaborative Ocular Melanoma Study (COMS) randomized trial of pre-enucleation radiation of large choroidal melanoma II: initial mortality findings. COMS report no. 10. *Am J Ophthalmol* 1998; 125: 779–796.)

using liver function tests (alkaline phosphatase, AST, ALT, or bilirubin). In addition, chest radiographs were routinely taken. Abnormal findings prompted a diagnostic or imaging test to confirm or rule out cancer recurrence.<sup>31</sup> The sensitivity, specificity, positive predictive value, and negative predictive values associated with abnormal LFTs before the diagnosis of metastasis were 15%, 92%, 46%, and 71%, respectively. Because the LFTs had low sensitivity, liver imaging is recommended to identify earlier metastatic disease.<sup>31–33</sup> The benefit of annual chest X-ray as a screening method for metastasis is questionable.

### Trends in the size and treatment of choroidal melanoma

Between 1987 and 1997 the evaluation of data on patients who were evaluated at the COMS centers but not enrolled showed a trend towards presentation with a smaller tumor, decreasing rates of enucleation for tumors with LBD less than 15 mm, and increasing choice of enucleation for tumors with LBD exceeding 15 mm.

### SUMMARY

The Small Choroidal Melanoma Prospective Study confirmed several clinical features as being predictive of tumor growth (i.e. orange

pigment, larger tumor dimensions, lack of drusen, and lack of adjacent RPE changes). Most small choroidal tumors did not grow in 5 years, even though they had been diagnosed as melanoma. Moreover, this study indicated a low risk of dying within 5 years from a small choroidal melanoma, even when most patients were not treated.<sup>14</sup> Data for longer follow-up are not available.

The COMS has demonstrated that enucleation and iodine brachytherapy are equally safe alternatives for the management of patients with medium choroidal melanoma, as regards life prognosis.<sup>12</sup> This is also likely to be true of large choroidal melanoma.<sup>34</sup> Furthermore, COMS has documented that pre-enucleation irradiation does not improve survival in patients with a large choroidal melanoma.<sup>27</sup>

### ACKNOWLEDGEMENT

This chapter was modified, with permission, from Singh AD, Kivelä T. The collaborative ocular melanoma study. *Ophthalmol Clin North Am* 2005; 18: 129–142.

### REFERENCES

- Markowitz JA, Hawkins BS, Diener-West M, Schachat AP. A review of mortality from choroidal melanoma. I. Quality of published reports, 1966 through 1988. *Arch Ophthalmol* 1992; 110: 239–244.
- Diener-West M, Hawkins BS, Markowitz JA, Schachat AP. A review of mortality from choroidal melanoma. II. A meta-analysis of 5-year mortality rates following enucleation, 1966 through 1988. *Arch Ophthalmol* 1992; 110: 245–250.
- Schachat AP. Management of uveal melanoma: a continuing dilemma. Collaborative Ocular Melanoma Study Group. *Cancer* 1994; 74: 3073–3075.
- Fine SL. No one knows the preferred management for choroidal melanoma. *Am J Ophthalmol* 1996; 122: 106–108.
- Zimmerman LE, McLean IW, Foster WD. Does enucleation of the eye containing a malignant melanoma prevent or accelerate the dissemination of tumour cells? *Br J Ophthalmol* 1978; 62: 420–425.
- Singh AD, Rennie IG, Kivelä T et al. Zimmerman–McLean–Foster hypothesis: 25 years later. *Br J Ophthalmol* 2004; 88: 962–967.
- Melia BM, Abramson DH, Albert DM et al. Collaborative ocular melanoma study (COMS) randomized trial of I-125 brachytherapy for medium choroidal melanoma. I. Visual acuity after 3 years. COMS report no. 16. *Ophthalmology* 2001; 108: 348–366.
- Group COMS. COMS Manual of Procedures: accession no. PBS 179693. Springfield, VA: National Technical Information Service, 1995.
- Kroll S, Char DH, Quivey J, Castro J. A comparison of cause-specific melanoma mortality and all-cause mortality in survival analyses after radiation treatment for uveal melanoma. *Ophthalmology* 1998; 105: 2035–2045.
- Kujala E, Mäkitie T, Kivelä T. Very long-term prognosis of patients with malignant uveal melanoma. *Invest Ophthalmol Vis Sci* 2003; 44: 4651–4659.
- Moy CS, Albert DM, Diener-West M et al. Cause-specific mortality coding. Methods in the Collaborative Ocular Melanoma Study. COMS report no. 14. *Control Clin Trials* 2001; 22: 248–262.
- Diener-West M, Earle JD, Fine SL et al. The COMS randomized trial of iodine 125 brachytherapy for choroidal melanoma, III: initial mortality findings. COMS Report No. 18. *Arch Ophthalmol* 2001; 119: 969–982.
- Group COMS. The Collaborative Ocular Melanoma Study (COMS) randomized trial of pre-enucleation radiation of large choroidal melanoma II: initial mortality findings. COMS report no. 10. *Am J Ophthalmol* 1998; 125: 779–796.
- Group COMS. Mortality in patients with small choroidal melanoma. COMS report no. 4. The Collaborative Ocular Melanoma Study Group. *Arch Ophthalmol* 1997; 115: 886–893.
- Straatsma BR, Diener-West M, Caldwell R, Engstrom RE. Mortality after deferral of treatment or no treatment for choroidal melanoma. *Am J Ophthalmol* 2003; 136: 47–54.
- Byrne SF, Marsh MJ, Boldt HC et al. Consistency of observations from echograms made centrally in the Collaborative Ocular Melanoma Study COMS Report No. 13. *Ophthalmol Epidemiol* 2002; 9: 11–27.
- Group COMS. Comparison of clinical, echographic, and histopathological measurements from eyes with medium-sized choroidal melanoma in the collaborative ocular melanoma study: COMS report no. 21. *Arch Ophthalmol* 2003; 121: 1163–1171.
- Group COMS. Histopathologic characteristics of uveal melanomas in eyes enucleated from the Collaborative Ocular Melanoma Study. COMS report no. 6. *Am J Ophthalmol* 1998; 125: 745–766.
- Group COMS. Trends in size and treatment of recently diagnosed choroidal melanoma, 1987–1997: findings from patients examined at collaborative ocular melanoma study (COMS) centers: COMS report no. 20. *Arch Ophthalmol* 2003; 121: 1156–1162.
- Group COMS. Factors predictive of growth and treatment of small choroidal melanoma: COMS Report No. 5. The Collaborative Ocular Melanoma Study Group. *Arch Ophthalmol* 1997; 115: 1537–1544.
- Diener-West M, Earle JD, Fine SL et al. The COMS randomized trial of iodine 125 brachytherapy for choroidal melanoma, II: characteristics of patients enrolled and not enrolled. COMS Report No. 17. *Arch Ophthalmol* 2001; 119: 951–965.
- Group COMS. Ten-year follow-up of fellow eyes of patients enrolled in Collaborative Ocular Melanoma Study randomized trials: COMS report no. 22. *Ophthalmology* 2004; 111: 966–976.
- Group COMS. The Collaborative Ocular Melanoma Study (COMS) randomized trial of pre-enucleation radiation of large choroidal melanoma III: local complications and observations following enucleation COMS report no. 11. *Am J Ophthalmol* 1998; 126: 362–372.
- Fried DB, Morris DE, Poole C et al. Systematic review evaluating the timing of thoracic radiation therapy in combined modality therapy for limited-stage small-cell lung cancer. *J Clin Oncol* 2004; 22: 4837–4845.
- Group COMS. The Collaborative Ocular Melanoma Study (COMS) randomized trial of pre-enucleation radiation of large choroidal melanoma I: characteristics of patients enrolled and not enrolled. COMS report no. 9. *Am J Ophthalmol* 1998; 125: 767–778.
- Group COMS. Assessment of metastatic disease status at death in 435 patients with large choroidal melanoma in the Collaborative Ocular Melanoma Study (COMS): COMS report no. 15. *Arch Ophthalmol* 2001; 119: 670–676.
- Group COMS. The Collaborative Ocular Melanoma Study (COMS) randomized trial of pre-enucleation radiation of large choroidal melanoma: IV. Ten-year mortality findings and prognostic factors. COMS report number 24. *Am J Ophthalmol* 2004; 138: 936–951.
- Kilic E, Stijnen T, de Jong PT et al. Reduced melanoma-related mortality in uveal melanoma by preenucleation radiotherapy. *Arch Ophthalmol* 2005; 123: 1363–1367.
- Group COMS. Quality of life assessment in the collaborative ocular melanoma study: design and methods. COMS–QOLS Report No. 1. COMS Quality of Life Study Group. *Ophthalmol Epidemiol* 1999; 6: 5–17.
- Melia M, Moy CS, Reynolds SM et al. Development and validation of disease-specific measures for choroidal melanoma: COMS–QOLS report No. 2. *Arch Ophthalmol* 2003; 121: 1010–1020.
- Diener-West M, Reynolds SM, Agugliaro DJ et al. Screening for metastasis from choroidal melanoma: the Collaborative Ocular Melanoma Study Group Report 23. *J Clin Oncol* 2004; 22: 2438–2444.
- Eskelin S, Pyrhonen S, Summanen P et al. Screening for metastatic malignant melanoma of the uvea revisited. *Cancer* 1999; 85: 1151–1159.
- Eskelin S, Kivela T. Imaging to detect metastases from malignant uveal melanoma. *Arch Ophthalmol* 2002; 120: 676.
- Puusaari I, Heikkonen J, Summanen P et al. Iodine brachytherapy as an alternative to enucleation for large uveal melanomas. *Ophthalmology* 2003; 110: 2223–2234.

# Uveal malignant melanoma: prognostic factors

Robert Folberg and Jacob Pe'er

## INTRODUCTION

Uveal melanomas are among the few cancers to be treated without examining tissue to confirm the clinical diagnosis and establish prognosis. The Collaborative Ocular Melanoma Study has demonstrated that in patients with clear ocular media, clinical misdiagnosis of choroidal melanocytic neoplasms is extremely rare.<sup>1</sup>

Unfortunately, treatment of metastatic uveal melanoma is largely ineffective, only modestly prolonging survival. Why, then, should ophthalmologists be concerned with assessing the prognosis of uveal melanomas? There are two answers to this frequently asked question. First, many patients with uveal melanoma sincerely want to know their life expectancy. Some wish to put their lives in order and settle their affairs if they know they may have only a few years to live. Second, accelerating advances in medical knowledge may soon result in promising novel therapies, which will require evaluation. The assignment of patients to high and low risk for metastasis will facilitate the design of effective clinical trials – hopefully in the very near future.

This chapter is divided into four related discussions of prognostic factors: tumor characteristics that can be detected using conventional clinical methods; pathological features derived from the examination of resected tumors (by enucleation or local excision); analysis of tumor specimens obtained by methods such as fine-needle aspiration biopsy (FNAB); and factors that can be detected by non-invasive imaging and serum biomarkers.

## TUMOR CHARACTERISTICS DETECTABLE BY CONVENTIONAL CLINICAL EXAMINATION

Most patients with uveal melanoma are now treated by eye-preserving methods, such as radiotherapy and transpupillary thermotherapy, so that tumor tissue is never available for evaluation. Clinical prognostic factors are therefore particularly relevant.

Box 46.1 lists the main clinical prognostic factors. The most consistent clinical (and pathological) feature that correlates with mortality is the largest basal tumor diameter.<sup>2</sup> This can be estimated by indirect ophthalmoscopy and by echography. The recent development of wide-angle digital cameras has also made it possible to measure tumor diameter photographically, with great accuracy (Fig. 46.1). In several studies the maximal tumor height or thickness was also found to be of prognostic importance.<sup>3</sup> However, the statistical significance of tumor height is diminished when it is considered in relation to other prognostic factors, in multivariate analyses.

With choroidal melanomas, anterior extension beyond the equator, and especially ciliary body involvement, have been shown to indicate a poor prognosis for survival.<sup>4</sup>

Other clinical features that were found to be important prognostic parameters in posterior uveal melanoma are advanced age of the patient at the time of treatment, extrascleral tumor extension, male gender,<sup>3</sup> and rare growth patterns such as diffuse type of melanoma and ring melanomas. Rapidly growing tumors have a worse prognosis.<sup>5</sup> Recently, rapid and marked tumor regression after radiotherapy was found to be an independent prognostic factor.<sup>3</sup>

Clinical parameters such as the presence of glaucoma, blurred vision, symptoms of flashes and floaters, tumor touching the optic nerve head, the presence of subretinal fluid, and orange pigment on the tumor surface have been cited in some studies as being associated with an aggressive clinical course. An artificial neural network that included only clinical and ultrasonographic parameters has been used successfully to estimate the prognosis of patients with choroidal melanoma more accurately than expert clinicians.<sup>6</sup>

## PATHOLOGICAL FEATURES DERIVED FROM THE EXAMINATION OF RESECTED TUMORS

Most iris melanocytic lesions follow a benign course unless they involve the ciliary body, in which case they are classified as ciliary body melanomas for prognostic purposes. Some iris melanocytic lesions, even nevi, are associated with 'surface plaques,' thin layers of often cytologically bland spindle-shaped melanocytes which can spread over the iris surface, efface the surface iris architecture, invade the angle, and cause secondary glaucoma.

Pathologists are now advised to report on the following features of resected ciliary body and choroidal melanomas:<sup>7</sup> tumor location; the presence or absence of extraocular extension; tumor growth pattern (i.e. nodular vs diffuse), the largest dimension of the tumor in contact with the sclera (which may be measured at the time of the gross examination or from the glass slide);<sup>8</sup> cell type according to the modified Callender classification; tumor cell proliferation, measured by estimating the mitotic rate or by calculating the proliferation index; tumor-infiltrating lymphocytes and extravascular (PAS) matrix patterns, also known as vasculogenic mimicry patterning (Box 46.2 and Fig. 46.2).

In repeated studies, assignment of cell type to the tumor by the Callender classification<sup>9</sup> or its modification<sup>10</sup> has been shown to be independently associated with outcome. The classification is based on assessments of cell shape and nuclear characteristics. Elongated cells



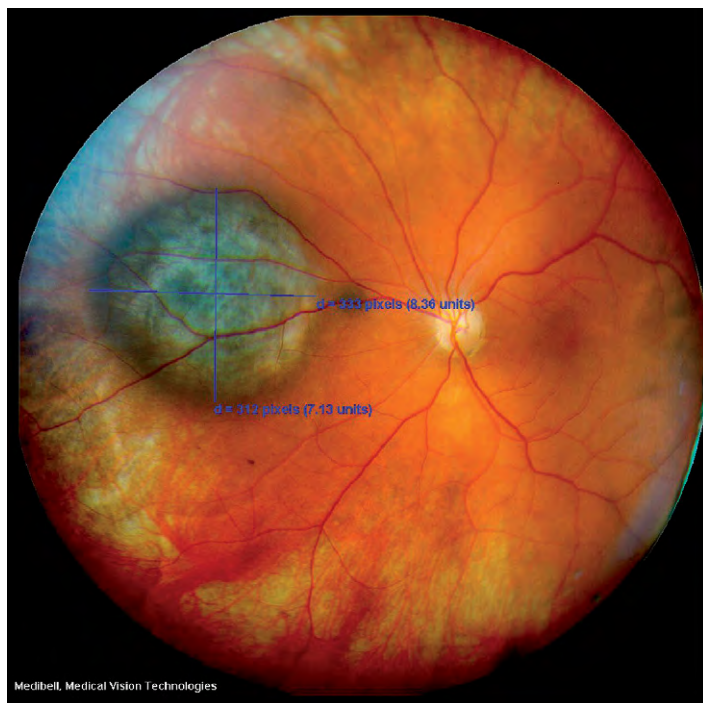
**BOX 46.1 Clinical Prognostic Factors**

- Largest basal tumor diameter
- Tumor thickness/height
- Anterior tumor location/ciliary body involvement
- Extrascleral extension
- Diffuse melanoma
- Older age
- Male gender
- Faster-growing tumor
- Initial tumor regression rate after radiotherapy

**BOX 46.2 Histological Prognostic Factors**

- Location (iris, ciliary body, choroid)
- Extraocular extension (yes, no)
- Growth pattern (focal, diffuse, ring)
- Dimension of largest diameter in contact with the sclera (mm)
- Cell type (Callender classification: spindle, mixed, epithelioid, necrotic)
- Number of mitotic figures per 40 high-power fields or proliferation index
- Presence of >100 tumor infiltrating lymphocytes per 20 high-power fields
- Vasculogenic mimicry patterns (networks or loops, present or absent)

Modified from Folberg R, Salomão D, Grossniklaus HE et al. Recommendations for reporting of tissues removed as part of the surgical treatment of common malignancies of the eye and adnexa. *Am J Surg Pathol* 2003; 27: 999–1004.



**Fig. 46.1** Wide-angle picture of right fundus showing choroidal melanoma nasal to the disc, permitting accurate measurements of the basal tumor diameter.

with a longitudinally folded nucleus and without conspicuous nucleoli are designated spindle A cells. Spindle B cells have a more ‘open’ nucleus and more prominent nucleoli. Round cells with abundant cytoplasm and prominent nucleoli are designated epithelioid. Tumors composed exclusively of spindle A cells may be classified as nevi. Tumors containing only spindle A and B cells are now classified as ‘spindle cell melanomas.’ Melanomas composed of a mixture of spindle and epithelioid cells are classified as being of the ‘mixed cell type.’ Tumors composed largely of epithelioid cells are classified as ‘epithelioid’ melanomas. Some melanomas are completely necrotic and are designated ‘necrotic melanomas.’

There is much interobserver variation in using the Callender classification. First, spindle B cells that are cut in cross-section may be mistaken for small epithelioid cells. Second, there is no consensus among pathologists as to the number of epithelioid cells required to

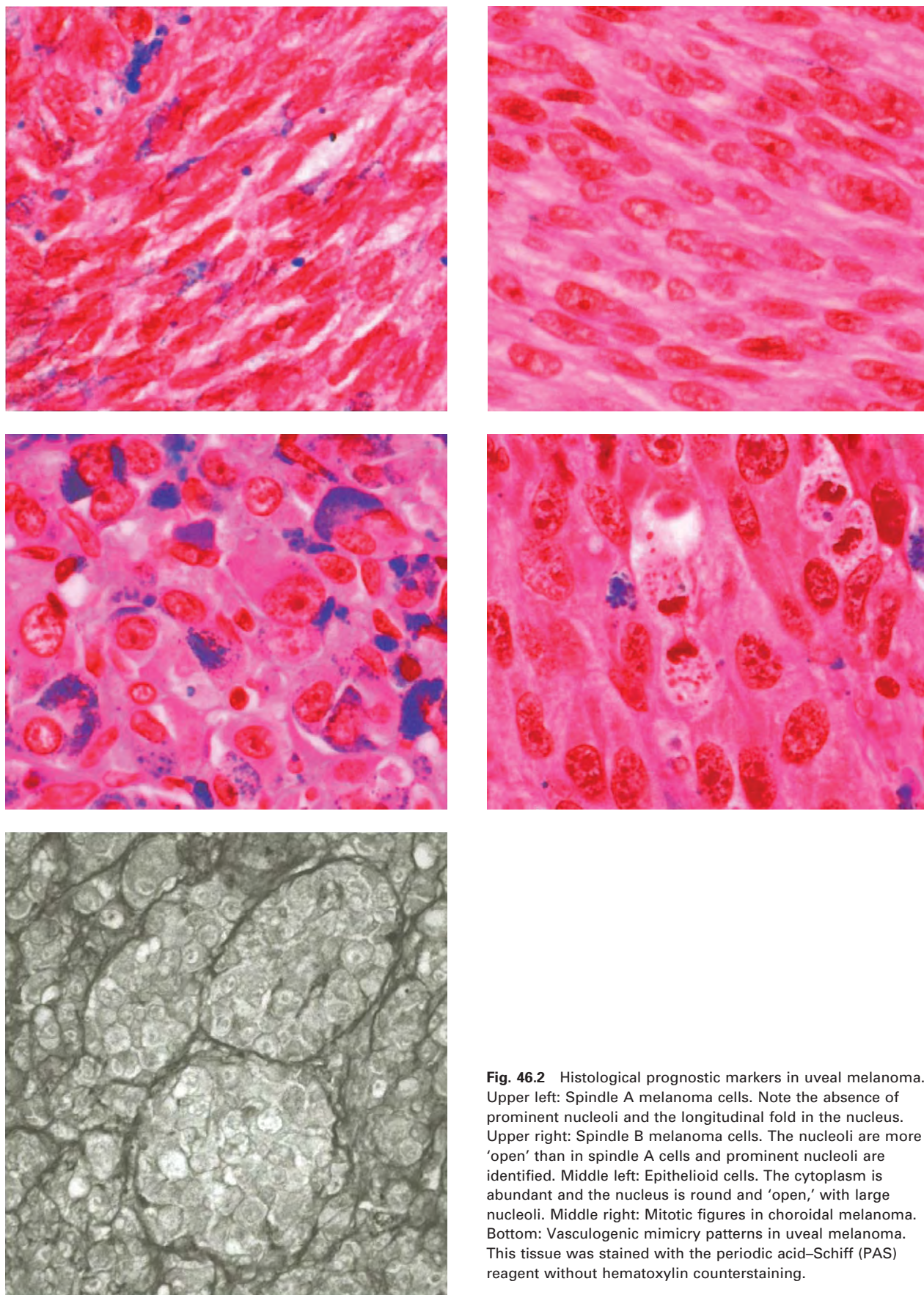
change a tumor from mixed to epithelioid. This problem has prompted some pathologists to measure the nucleolar diameter (mean of the 10 largest nucleoli) to assess malignant potential.<sup>11</sup> This cytomorphometric parameter, although prognostically sensitive, has not gained wide acceptance in routine practice. Many pathologists have therefore adapted a two-tiered classification system by simply reporting whether epithelioid cells are present or absent.<sup>12</sup>

A high number of mitotic figures in uveal melanoma has repeatedly been shown to be associated with adverse outcome. Conventionally, the number of mitoses per 40 high-power fields (hpf) is documented in pathology reports.<sup>13</sup> In many fields of surgical pathology mitotic counts have been replaced by proliferation indices, which are determined by calculating the percentage of cells that stain with proliferation markers such as Ki-67. A high proliferation index has been associated with an adverse outcome in uveal melanoma.<sup>14</sup>

In cutaneous melanoma, abundant tumor infiltrating lymphocytes are associated with a favorable outcome; however, in uveal melanoma the presence of more than 100 tumor-infiltrating lymphocytes per 20 hpf is associated with an adverse outcome.<sup>15</sup>

The histological detection of looping patterns that are positive on periodic acid–Schiff (PAS) staining is associated with an adverse outcome.<sup>12</sup> These PAS-positive structures contain a variety of extracellular matrix proteins, such as laminin, collagen IV, collagen VI, and fibronectin.<sup>16</sup> The looping patterns are formed by highly invasive uveal melanoma cells by a process known as ‘vasculogenic mimicry.’<sup>17</sup> These structures may function as an extravascular conduit for blood and plasma (the ‘fluid-conducting meshwork’<sup>18</sup>). Looping patterns seldom occupy the entire tumor and are typically found near the periphery.

Microvascular density (MVD) is measured by counting discrete points of staining using endothelial cell markers. Several studies indicate that MVD is associated with adverse outcome;<sup>19</sup> however, readers are cautioned that MVD may not equate to angiogenesis because highly invasive uveal melanoma cells tend to express endothelial cell markers. Simply counting discrete points staining for endothelial cell markers, therefore, would detect both blood vessels and highly invasive tumor cells.<sup>20</sup>



**Fig. 46.2** Histological prognostic markers in uveal melanoma. Upper left: Spindle A melanoma cells. Note the absence of prominent nucleoli and the longitudinal fold in the nucleus. Upper right: Spindle B melanoma cells. The nucleoli are more 'open' than in spindle A cells and prominent nucleoli are identified. Middle left: Epithelioid cells. The cytoplasm is abundant and the nucleus is round and 'open,' with large nucleoli. Middle right: Mitotic figures in choroidal melanoma. Bottom: Vasculogenic mimicry patterns in uveal melanoma. This tissue was stained with the periodic acid-Schiff (PAS) reagent without hematoxylin counterstaining.



## ANALYSIS OF CELLS EXTRACTED BY FINE NEEDLE ASPIRATION BIOPSY

Fine needle aspiration biopsy (FNAB) was introduced into the practice of ocular oncology to establish the diagnosis of choroidal tumors in rare cases where a clinical diagnosis was uncertain. Thus, FNAB can distinguish choroidal metastasis from melanoma with a high degree of accuracy.<sup>21</sup> Recently, some clinical investigators have begun to explore the prognostic value of FNAB.

At this point, it would be helpful for the reader to revisit the indications for FNAB elsewhere in the practice of medicine. Material is obtained during the procedure largely through the cutting action of the needle rather than 'aspiration.' To ensure representative sampling of a lesion (e.g. a breast mass, thyroid nodule, lymph node), the needle is inserted and removed at different angles by taking multiple passes through the area of interest.

When performing FNAB, it is important to know whether or not the relevant prognostic marker is distributed homogeneously throughout the tumor. If the marker of interest is inhomogeneous then only a positive result is significant, as a negative finding can be caused by a sampling error.

Many uveal melanomas are heterogeneous in the expression of markers and genes. In one tumor FNAB demonstrated only spindle cells, but when the serial sections of the enucleation specimen were examined the needle track was found to have missed a pocket of epithelioid cells.<sup>21</sup> In another study, cytomorphometric measurements of nucleoli in FNAB samples were significantly different from results obtained in the same tumors after enucleation.<sup>22</sup> Angiogenic vessels are typically not distributed uniformly throughout tumors: in assessing microvascular density the pathologist identifies 'hot spots' – discrete foci of increased vascular density. Thus, the expression of proangiogenic proteins in tumors is inhomogeneous.

There is now considerable interest in determining the karyotype of uveal melanomas. Non-random chromosomal abnormalities such as monosomy 3 and extra copies of chromosome 8 are associated with an adverse outcome.<sup>23</sup> It has recently been demonstrated that it is possible to identify monosomy 3 from FNAB specimens.<sup>24</sup> However, there are reports of cases of metastatic melanoma in patients with disomy 3. It is not known whether some patients with disomy 3 develop metastatic melanoma, or whether chromosome 3 abnormality was missed in some of the fatal cases.

Recently, results of gene expression arrays have been published which suggest that patients can be reliably stratified into risk categories according to the gene expression profile of their tumor.<sup>25,26</sup> These studies have yielded several unexpected associations. For example, both showed expression of the gene for osteopontin to be associated with a favorable outcome.<sup>25,26</sup> This is in marked contrast to most other cancers, in which osteopontin is associated with invasion and metastasis. Two conclusions are possible: that uveal melanoma is an exception to the 'rule' that osteopontin expression reflects a tumor with a highly invasive and metastatic phenotype; and that there may have been a systematic bias in tumor sampling, which resulted in a reversal of expected findings. Osteopontin is largely confined to the tumor periphery.<sup>27</sup> Thus, if samples were obtained from the center of a uveal melanoma, tumors for these gene expression studies might unintentionally result in an 'inversion of significance' for osteopontin. Indeed, high serum levels of osteopontin are associated with the development of hepatic metastases from uveal melanoma.<sup>27</sup>

With small uveal melanomas it is difficult to decide whether treatment should be administered immediately or whether it should be delayed until tumor growth is observed. If FNAB is performed and the tumor demonstrates features known to be associated with metastatic spread, then urgent treatment would be indicated in the hope of preventing metastasis. If no adverse features are found, however, it cannot be assumed that it is safe to delay treatment, because it is not known whether the tumor can transform into a more malignant type and whether metastatic spread can subsequently occur. If repeated FNAB is deemed necessary to obviate any risk of malignant transformation and sampling error, then the question arises as to how often this examination should be performed.

## PROGNOSTIC FACTORS BY NON-INVASIVE TESTING

The possible need to repeat FNAB procedures and the requirement to sample multiple areas of the tumor have stimulated interest in non-invasive techniques for prognostication.

As mentioned above, vasculogenic mimicry patterns in histological sections of uveal melanoma are associated with adverse outcome and with monosomy 3.<sup>28</sup> They also correlate with a dysregulated genotype,<sup>17</sup> and with a gene expression signature characteristic of tumors that metastasize.<sup>29</sup> Thus, if it were possible to image vasculogenic mimicry patterns clinically, the need for biopsy might be avoided.

It has been shown that vasculogenic mimicry patterns can be visualized by laser scanning confocal ophthalmoscopy after the injection of indocyanine green (ICG).<sup>30</sup> There is also evidence that such angiographic detection of these patterns predicts the growth of small choroidal melanocytic lesions. Another advantage of ICG angiography is that it studies the entire lesion, thereby detecting vasculogenic mimicry patterns even when these are present only focally. This approach is suitable for lesions in the posterior pole, but not those located more anteriorly. It has been shown that specialized ultrasonography can detect vasculogenic mimicry patterns in uveal melanomas with a relative sensitivity and specificity irrespective of the tumor's location in the eye.<sup>31</sup> Unfortunately, the equipment required to perform these examinations is not available commercially.

Ophthalmic oncologists have therefore turned their attention to the development of blood tests to detect biomarkers associated with tumor progression. Serum melanoma inhibitory activity has been associated with the development of metastatic melanoma in one series,<sup>32</sup> but this result was not duplicated in another study. Recently, raised serum osteopontin has been shown to correlate with hepatic metastases with high levels of sensitivity and specificity.<sup>27</sup>

It is possible that further efforts in the development of non-invasive tests and biomarkers will enable ophthalmologists and ophthalmic oncologists to separate patients at low risk for metastasis from those at high risk. Further studies will be needed to determine whether relatively indolent melanomas become more malignant if left untreated. The development of investigations predicting metastatic disease biomarkers linked to the molecular mechanisms favoring metastatic behavior may provide the basis for adjuvant systemic therapy.



## REFERENCES

1. Accuracy of diagnosis of choroidal melanomas in the Collaborative Ocular Melanoma Study COMS report no 1. *Arch Ophthalmol* 1990; 108: 1268–1273.
2. Shamma HF, Blodi FC. Prognostic factors in choroidal and ciliary body melanomas. *Arch Ophthalmol* 1977; 95: 63–69.
3. Kaiserman I, Anteby I, Chowers I et al. Post-brachytherapy initial tumour regression rate correlates with metastatic spread in posterior uveal melanoma. *Br J Ophthalmol* 2004; 88: 892–895.
4. Augsburger JJ, Gamel JW. Clinical prognostic factors in patients with posterior uveal malignant melanoma. *Cancer* 1990; 66: 1596–1600.
5. Char DH, Kroll S, Phillips TL. Uveal melanoma: Growth rate and prognosis. *Arch Ophthalmol* 1997; 115: 1014–1018.
6. Kaiserman I, Rosner M, Pe'er J. Forecasting the prognosis of choroidal melanoma with an artificial neural network. *Ophthalmology* 2005; 112: 1608–1611.
7. Folberg R, Salomao D, Grossniklaus HE et al. Recommendations for the reporting of tissues removed as part of the surgical treatment of common malignancies of the eye and its adnexa. The Association of Directors of Anatomic and Surgical Pathology. *Hum Pathol* 2003; 34: 114–118.
8. Gamel JW, McLean I, Greenberg RA et al. Objective assessment of the malignant potential of intraocular melanomas with standard microslides stained with hematoxylin–eosin. *Hum Pathol* 1985; 16: 689–692.
9. Callender GR. Malignant melanotic tumors of the eye: a study of histologic types in 111 cases. *Trans Am Acad Ophthalmol Otolaryngol* 1931; 36: 131–142.
10. McLean IW, Zimmerman LE, Evans RM. Reappraisal of Callender's spindle A type of malignant melanoma of choroid and ciliary body. *Am J Ophthalmol* 1978; 86: 557–564.
11. McLean IW, Sibug ME, Becker RL et al. Uveal melanoma: the importance of large nucleoli in predicting patient outcome – an automated image analysis study. *Cancer* 1997; 79: 982–988.
12. Folberg R, Rummelt V, Parys-Van Ginderdeuren R et al. The prognostic value of tumor blood vessel morphology in primary uveal melanoma. *Ophthalmology* 1993; 100: 1389–1398.
13. McLean IW, Foster WD, Zimmerman LE. Prognostic factors in small malignant melanomas of choroid and ciliary body. *Arch Ophthalmol* 1977; 95: 48–58.
14. Pe'er J, Gnessin H, Shargal Y et al. PC-10 immunostaining of proliferating cell nuclear antigen (PCNA) in posterior uveal melanoma. Enucleation versus enucleation postirradiation groups. *Ophthalmology* 1994; 101: 56–62.
15. de la Cruz PO Jr, Specht CS, McLean IW. Lymphocytic infiltration in uveal malignant melanoma. *Cancer* 1990; 65: 112–115.
16. Lin AY, Maniotis AJ, Valyi-Nagy K et al. Distinguishing fibrovascular septa from vasculogenic mimicry patterns. *Arch Pathol Lab Med* 2005; 129: 884–892.
17. Maniotis AJ, Folberg R, Hess A et al. Vascular channel formation by human melanoma cells in vivo and in vitro: vasculogenic mimicry. *Am J Pathol* 1999; 155: 739–752.
18. Clarijs R, Otte-Holler I, Ruiter DJ et al. Presence of a fluid-conducting meshwork in xenografted cutaneous and primary human uveal melanoma. *Invest Ophthalmol Vis Sci* 2002; 43: 912–918.
19. Foss AJ, Alexander RA, Jefferies LW et al. Microvessel count predicts survival in uveal melanoma. *Cancer Res* 1996; 56: 2900–2903.
20. Chen X, Maniotis AJ, Majumdar D et al. Uveal melanoma cell staining for CD34 and assessment of tumor vascularity. *Invest Ophthalmol Vis Sci* 2002; 43: 2533–2539.
21. Augsburger JJ, Shields JA, Folberg R et al. Fine needle aspiration biopsy in the diagnosis of intraocular cancer. Cytologic–histologic correlations. *Ophthalmology* 1985; 92: 39–49.
22. Char DH, Kroll SM, Stoloff A et al. Cytomorphometry of uveal melanoma. Comparison of fine needle aspiration biopsy samples with histologic sections. *Anal Quant Cytol Histol* 1991; 13: 293–299.
23. Gambrelle J, Labialle S, Dayan G et al. Toward monosomy 3 as the main prognosis factor of uveal melanoma: current cytogenetic data. *J Fr Ophtalmol* 2004; 27: 1061–1067.
24. Sisley K, Nichols C, Parsons MA et al. Clinical applications of chromosome analysis, from fine needle aspiration biopsies, of posterior uveal melanomas. *Eye* 1998; 12: 203–207.
25. Tschentscher F, Husing J, Holter T et al. Tumor classification based on gene expression profiling shows that uveal melanomas with and without monosomy 3 represent two distinct entities. *Cancer Res* 2003; 63: 2578–2584.
26. Onken MD, Worley LA, Ehlers JP et al. Gene expression profiling in uveal melanoma reveals two molecular classes and predicts metastatic death. *Cancer Res* 2004; 64: 7205–7209.
27. Kadkol SS, Lin AY, Barak V et al. Osteopontin expression and serum levels in metastatic uveal melanoma – a pilot study. *Invest Ophthalmol Vis Sci* 2006; 47: 802–806.
28. Scholes AGM, Damato BE, Nunn J et al. Monosomy 3 in uveal melanoma: Correlation with clinical and histologic predictors of survival. *Invest Ophthalmol Vis Sci* 2003; 44: 1008–1011.
29. Onken MD, Lin AY, Worley LA et al. Association between microarray gene expression signature and extravascular matrix patterns in primary uveal melanomas. *Am J Ophthalmol* 2005; 140: 748–749.
30. Mueller AJ, Bartsch DU, Folberg R et al. Imaging the microvasculature of choroidal melanomas with confocal indocyanine green scanning laser ophthalmoscopy. *Arch Ophthalmol* 1998; 116: 31–39.
31. Coleman DJ, Silverman RH, Rondeau MJ et al. Noninvasive in vivo detection of prognostic indicators for high-risk uveal melanoma: Ultrasound parameter imaging. *Ophthalmology* 2004; 111: 558–564.
32. Schaller UC, Bosserhoff AK, Neubauer AS et al. Melanoma inhibitory activity: a novel serum marker for uveal melanoma. *Melanoma Res* 2002; 12: 593–599.

# Uveal malignant melanoma: mortality

Bertil Damato and Azzam Taktak

## INTRODUCTION

Many patients with uveal melanoma die as a result of systemic spread, despite successful treatment of the primary tumor. This raises important and unsettling questions about how and in whom ocular treatment influences survival, if at all. Such questions cannot be fully answered without a proper understanding of the natural history of uveal melanoma, particularly in relation to the time of onset of metastatic spread. The lack of firm evidence on which to base patient care complicates decision-making with regard to matters such as the treatment of small melanocytic tumors of indeterminate malignancy and screening for metastatic disease.

Even though metastatic disease only rarely responds to treatment, many patients still wish to know their chances of survival. Those with a good prognosis are encouraged by their relatively good fortune, whereas patients with a limited life expectancy have the opportunity to sort out their affairs while they still feel well. Prognostication is also useful when a policy of screening for metastases is undertaken selectively, that is, when the probability of metastatic disease exceeds a predefined threshold. Mortality statistics are also required for the evaluation of any novel forms of systemic adjuvant therapy, for example allowing the required study sample size to be estimated.

Survival studies have many pitfalls, caused by selection bias, incomplete data, loss to follow-up, competing risks, mistaken diagnoses, and others. For all these reasons, this chapter not only reports on mortality from uveal melanoma but attempts to draw attention to some of the uncertainties that prevail. Because of the controversial nature of this subject, the personal views expressed in this chapter are not necessarily shared by others working in this field. Apart from encouraging due skepticism, this review will hopefully stimulate new ideas for future investigations.

## UVEAL MELANOMA MORTALITY

There is an extensive literature regarding mortality in patients with uveal melanoma.<sup>1,2</sup> The paper by Kujala, Mäkitie, and Kivelä from Finland regarding choroidal and ciliary body melanomas is particularly informative, first because it takes into account the impact of deaths that are unrelated to uveal melanoma, and second because it reports long-term prognosis.<sup>3</sup>

**Survival probability according to tumor size** The cumulative melanoma-related mortality rates 25 years after treatment of the primary tumor are approximately 18%, 52%, and 59% for small, medium, and large tumors, respectively (Fig. 47.1).<sup>3</sup> The survival


curves in the initial postoperative period become steeper with increasing tumor size, indicating shorter survival times in fatal cases. This can be explained by faster growth of the primary tumor and any metastases, as well as by lead-time bias (see below).

**Competing risks** In the Finnish study, the rates of melanoma-related mortality were lower than generally reported because the authors performed cumulative incidence analysis, which takes account of competing risk events (i.e. deaths unrelated to uveal melanoma).<sup>3</sup> In contrast, Kaplan–Meier analysis censors patients dying of unrelated causes, thereby exaggerating melanoma-related mortality (Fig. 47.2). It is interesting that this study showed age at primary treatment to be insignificant, thereby casting doubt on previous suggestions that old age increases the risk of metastatic disease.


**Lead-time bias** The increased mortality observed after treatment of large tumors may simply reflect the fact that these tumors and any metastases have been present for a relatively long time, so that disease is more advanced at the time of diagnosis and treatment. Such ‘lead-time bias’ must be taken into account especially when considering 5- and 10-year survival data in relation to time-dependent categories (e.g. tumor diameter). Because almost all melanoma-related mortality occurs within 20 years of ocular treatment, very long-term survival data are particularly valuable.

**Loss to follow-up** can cause bias in different ways. Melanoma-related mortality rates would be exaggerated if patients lost to follow-up subsequently contacted the oncology center for advice when they developed metastatic disease. Conversely, melanoma-related mortality might be underestimated if patients lost to follow-up stopped attending the center because of ill health, and if such disease was usually caused by metastasis.

**Erroneous death certification** In a study by Kujala and associates<sup>3</sup> about 10% of all autopsies discovered metastatic melanoma in patients who were thought to have died of unrelated disease. Even routine histology did not guarantee a correct diagnosis, because about 10% of biopsies originally diagnosed as unrelated forms of cancer were found on immunohistochemistry to be amelanotic melanomas. Errors caused by a misdiagnosed cause of death can be avoided by comparing all-cause mortality in the study sample with all-cause mortality in the general population, matched for age and gender and reported as a ratio (e.g. relative survival rate). For example, Bergman



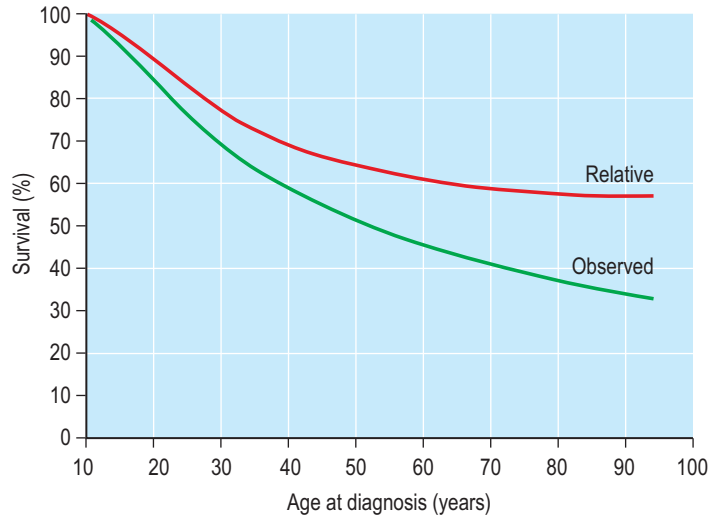
**Fig. 47.1** Cumulative incidence of death from uveal melanoma (thick lines) and from second malignancy (thin lines) according to largest basal tumor diameter at the time of treatment. (Reproduced with permission from Kujala E, Mäkitie T, Kivelä T. Very long-term prognosis of patients with malignant uveal melanoma. Invest Ophthalmol Vis Sci 2003; 44: 4651–4659.)



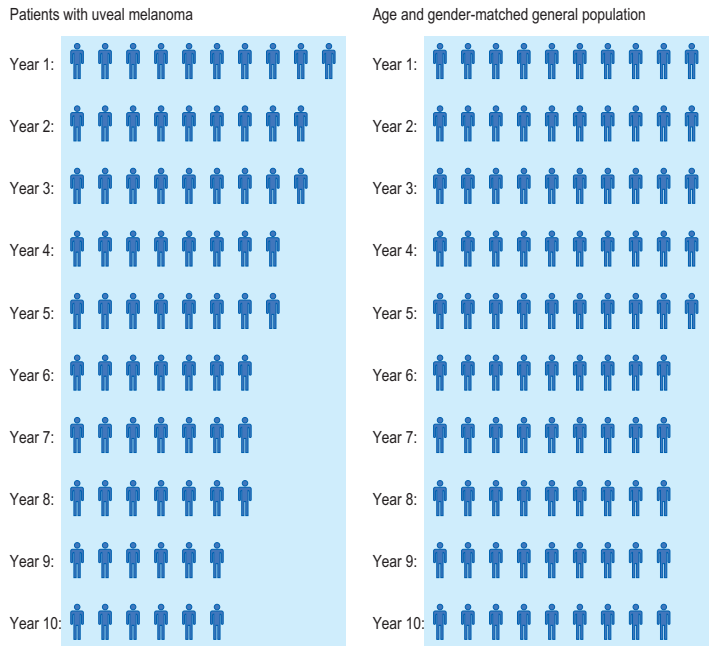
**Fig. 47.2** Kaplan–Meier estimate of metastatic death from uveal melanoma according to largest basal tumor diameter. (Reproduced with permission from Kujala E, Mäkitie T, Kivelä T. Very long-term prognosis of patients with malignant uveal melanoma. Invest Ophthalmol Vis Sci 2003; 44: 4651–4659.)

and associates<sup>4</sup> in Sweden reported relative survival rates in uveal melanoma patients (Fig. 47.3). Such an approach is applicable to uveal melanomas because of their rarity and their lack of association with other fatal conditions. Another advantage of using relative survival rate is that it adjusts for changes in overall life expectancy over extended periods.

We have developed a neural network for predicting all-cause mortality in patients with choroidal and ciliary body melanoma according



**Fig. 47.3** Observed and relative survival rates of patients with uveal melanoma treated in Sweden. (Reproduced with permission from Bergman L, Seregard S, Nilsson B et al. Uveal melanoma survival in Sweden from 1960 to 1998. Invest Ophthalmol Vis Sci 2003; 44: 3282–3287.)



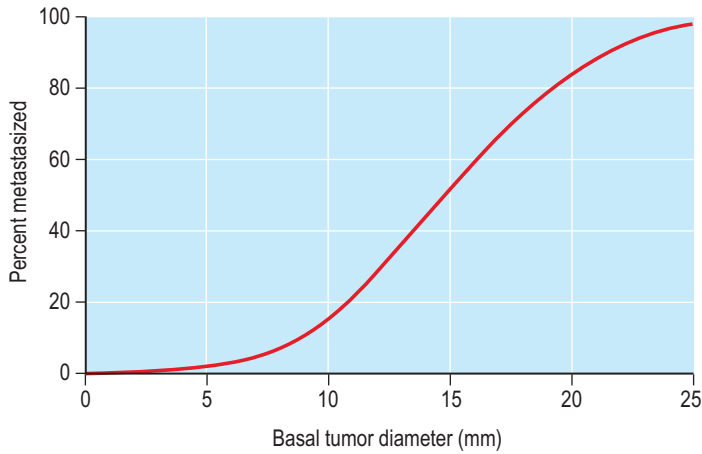
**Fig. 47.4** Left: a 40% all-cause mortality in a male patient with uveal melanoma, predicted by neural network according to age, gender, basal tumor diameter, and ciliary body involvement; and (right) a 10% all-cause mortality in the general population matched for age and gender.

to age, gender, basal tumor diameter, and ciliary body involvement (Taktak, Damato and Fisher, unpublished data). This program also presents the results in the form of a pictogram, to facilitate communication with patients (Fig. 47.4). There is a facility to revise the prognosis years after the initial treatment if the patient has survived the ‘danger period’, when most metastatic deaths occur.

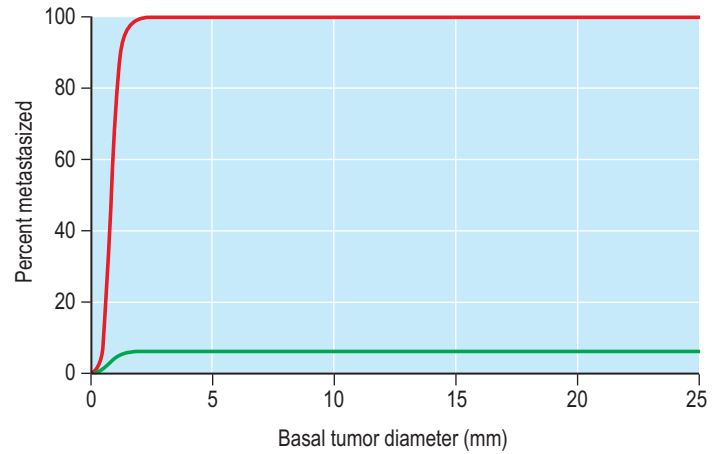
**ONSET OF METASTASIS**

**Late-onset hypothesis** The strong correlation between large tumor size at treatment and high mortality is the logical basis for the hypothesis that most metastatic spread commences after tumors grow large (Fig. 47.5). This view is linked to the belief that, over time, uveal

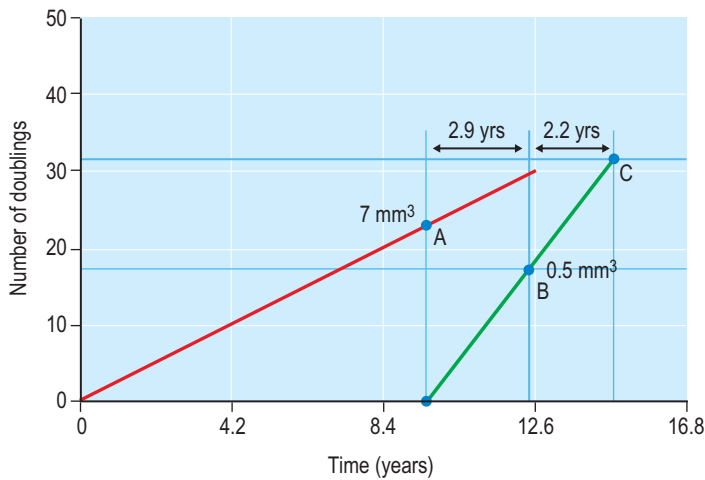




**Fig. 47.5** Schematic graph showing how the percentage of tumors that have metastasized before treatment might increase with basal tumor diameter. This model implies that all uveal melanomas tend to become more malignant and to metastasize, given time.



**Fig. 47.7** Schematic graph showing how high-grade uveal melanomas all metastasize early (red line) and how few, if any, low-grade tumors do (green line). According to this model, size essentially indicates only the duration of ocular tumor and any metastases. If the tumor has metastasized, size is inversely proportional to the time to metastatic death.

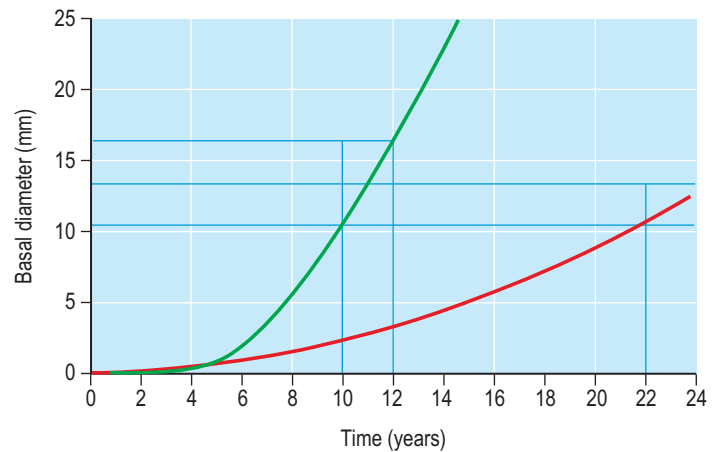


**Fig. 47.6** Estimated growth of primary tumor (red line) and metastasis (green line). Points A, B, and C represent the times of initial metastasis, ocular treatment, and detectable metastatic disease, respectively. Tumor doubling times suggest that the onset of metastatic spread is around 5 years before clinic metastases appear and 3.9 years before primary ocular treatment, when the uveal melanoma still has a volume of only 7 mm<sup>3</sup>. (Reproduced with permission from Eskelin S, Kivelä T. Reply: Tumor doubling times in metastatic malignant melanoma of the uvea: tumor progression before and after treatment. *Ophthalmology* 2001; 108: 830–831.)

melanomas tend to become progressively more undifferentiated and malignant, eventually metastasizing if not treated in time.

**Early-onset hypothesis** A rival hypothesis is that metastatic spread occurs before tumor growth, years before treatment (Fig. 47.6).<sup>5-7</sup> This model would suggest that large tumor size at the time of treatment merely reflects faster tumor growth and increased malignancy. There is growing evidence that uveal melanomas differentiate into low- and high-grade varieties at an early stage.<sup>8</sup> It is therefore possible that low-grade tumors remain small or grow large over many years, rarely or never metastasizing; high-grade tumors metastasize early and then rapidly grow large (Fig. 47.7).

Regular screening of the general population for eye disease is more likely to detect small, slow-growing, low-grade melanomas than



**Fig. 47.8** Schematic diagram correlating growth of high-grade melanomas (green line) and low-grade tumors (red line) with time. If a 10.5 mm tumor is missed on 2-yearly screening (e.g. by a community optometrist) then by the next scheduled assessment a high-grade melanoma will grow more than a low-grade tumor (i.e. by 6.5 mm and 2.5 mm respectively). Differences in growth rates may explain why high-grade melanomas are larger than low-grade ones at the time of detection and treatment. (NB. The curves in this diagram are speculative.)

small, high-grade tumors that grow rapidly. This is because the probability of detecting a tumor is proportional to the length of time during which it is detectable (Fig. 47.8). Such ‘length bias’ can give rise to misconceptions about the correlation between tumor size and mortality and may exaggerate the apparent benefits of screening and treatment.

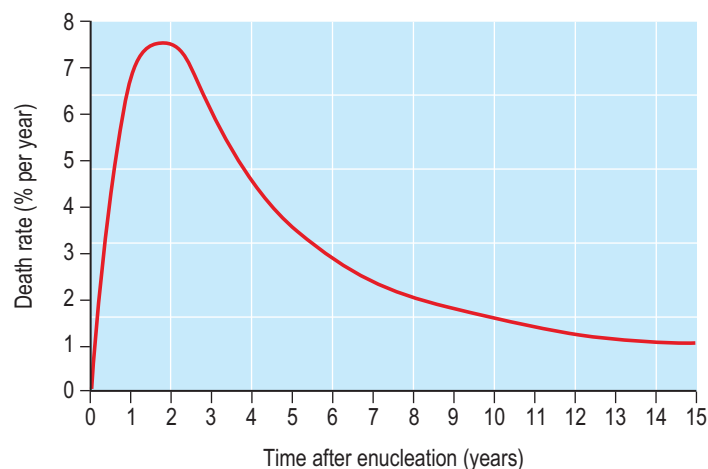
**IMPACT OF THERAPY ON MORTALITY**

The impact of ocular treatment on mortality from uveal melanoma is still speculative because there have been no randomized, prospective studies comparing treatment with no treatment. Therefore, treatment of large uveal melanomas is considered respectively life-saving or merely palliative, according to whether one believes that metastatic spread tends to start late or early. For example, if treatment of 15 mm

uveal melanomas is associated with a 50% survival probability, the late-onset metastasis hypothesis would imply that treatment has prevented metastatic spread in 50% of patients. Conversely, if mortality after treatment of a 15 mm tumor is 50%, the early-onset metastasis hypothesis would suggest that this is because only 50% of such tumors have any metastatic potential, these already metastasizing before presentation and treatment, with the remaining 50% of tumors probably never metastasizing even without treatment. Another important question is whether treatment of the ocular tumor after metastasis prolongs life by reducing hepatic tumor burden.

**Enucleation** In 1978, Zimmerman and colleagues<sup>9</sup> hypothesized that two-thirds of all fatalities occurring after enucleation could be attributed to the dissemination of tumor emboli at the time of surgery. This impression was based on the correct observation that the mortality rate rises abruptly following enucleation, reaching a peak of about 8% during the second postoperative year (Fig. 47.9).<sup>10</sup> The ‘Zimmerman hypothesis,’ as it came to be known, was challenged by Manschot<sup>5</sup> and others on the basis of tumor-doubling times, which suggested that metastatic death occurring in the first 7 postoperative years is nearly always the result of tumor dissemination before enucleation. Others have also disagreed with Zimmerman, on the basis of growth rates and mitotic index.<sup>11</sup>

**Pre-enucleation radiotherapy** Influenced by the Zimmerman hypothesis, the Collaborative Ocular Melanoma Study (COMS) in the USA performed a randomized, prospective multicenter study to determine whether pre-enucleation radiotherapy improved survival in patients with a large choroidal melanoma. No survival advantage attributable to the radiation was reported even in patients eligible for 10 years of follow-up.<sup>12</sup> As this study was limited to large tumors, systemic disease may already have been present in all patients whose tumor had any metastatic potential. Smaller tumors were excluded from this study, first for logistical reasons as it would have needed more patients and longer follow-up, and second for conceptual reasons, as metastatic spread was believed to commence after growth of the tumor to a large size in most patients (see above).



**Fig. 47.9** Peak in mortality after treatment of uveal melanoma. (Reproduced with permission from Zimmerman LE, McLean IW, Foster WD. Does enucleation of the eye containing a malignant melanoma prevent or accelerate the dissemination of tumour cells? *Br J Ophthalmol* 1978; 62: 420–425.)

A study in Rotterdam investigated the effect of pre-enucleation radiotherapy irrespective of tumor size and recently reported a significant improvement in survival after such therapy.<sup>13</sup> The validity of this result is questionable, however, because the patients were not randomized. The results of this study appear to be biased as the patients receiving pre-enucleation therapy were significantly younger than those who had enucleation alone (two-sample *t*-test,  $P = 0.006$ ).

**Radiotherapy** Several studies suggest that survival after radiotherapy is not significantly worse than after enucleation.<sup>14–16</sup> The largest is the randomized, prospective study undertaken by the COMS, which included 1317 patients with medium-sized choroidal melanomas.<sup>17</sup> In this study, the 5-year survival was reported to be 81% after enucleation and 82% after brachytherapy (log-rank test,  $P = 0.48$ ). The follow-up time may not yet be long enough to determine whether or not survival was influenced by choice of treatment, because all metastasis-related deaths in the first few postoperative years may be the result of dissemination of the tumor prior to treatment of the primary melanoma.

Non-randomized studies have reported higher mortality in patients who develop local tumor recurrence after radiotherapy.<sup>18–20</sup> It is uncertain whether the recurrent ocular tumors caused the metastatic disease or whether they merely reflected the increased malignancy of the primary tumor (i.e. at the time of initial ocular treatment). The COMS data are unlikely to answer this question because the number of recurrences after brachytherapy was not high enough to achieve statistical significance.

**Local resection** With trans-scleral local resection, predictive factors for survival are similar to those of enucleation (i.e. large basal tumor diameter and tumor cell type).<sup>21</sup> A study using historical controls suggested that mortality was not significantly different from that after enucleation; however, this was not a randomized, prospective study and so bias may have occurred.<sup>22</sup> According to the ‘early-onset metastasis’ hypothesis, local resection is unlikely to influence survival because it is generally reserved for large tumors, which have probably already spread from the eye by the time of surgery if they have any metastatic potential.

**Transpupillary thermotherapy (TTT)** is reserved for small choroidal melanomas, which because of their relatively early stage are the least likely to have metastasized before the treatment. It is in this group of patients, therefore, that recurrent tumor is most life threatening. One study has shown that primary TTT without adjunctive radiotherapy is associated with a 22% rate of local recurrence after 3 years.<sup>23</sup> Because of the lack of any randomized, prospective studies of TTT versus enucleation, it is not possible to determine whether survival is adversely influenced by the choice of TTT.

**Delayed treatment** The COMS performed a non-randomized observational study on patients with a small choroidal melanoma who were ineligible for the brachytherapy study and who were not immediately treated.<sup>24</sup> After 5 years, 31% of small tumors grew and the all-cause mortality was 6%. Unfortunately, follow-up was discontinued so that no long-term conclusions can be drawn from this investigation.

The COMS also reported 42 patients who fulfilled all criteria for enrolment in the brachytherapy versus enucleation study but who

chose to receive no treatment.<sup>25</sup> The 5-year all-cause mortality was greater in the untreated patients than in those treated by enucleation or radiotherapy, but the difference was not statistically significant. Possible explanations for this result include prevention of initial metastasis, cessation of ongoing metastasis, bias, and chance. Further studies are required to determine whether or not it is safe to defer treatment of small uveal melanomas until growth is observed.

According to the late-onset metastasis hypothesis, it would be safe to observe small melanomas until growth is documented. However, any possibility of early metastatic spread of high-grade melanomas should give rise to concern that delayed treatment of small melanomas might allow lethal tumor dissemination to occur, albeit in a small proportion of patients.

**Systemic therapy** Advances in the ocular treatment of uveal melanoma have not improved survival.<sup>26</sup> This realization is stimulating interest in systemic adjuvant therapy for the treatment of micrometastases.

## IRIS MELANOMA

Iris melanomas are rare, accounting for only about 3% of all uveal melanomas. A study including 169 consecutive patients with iris melanoma reported the actuarial rate of metastasis to be 5% at 10 years and 10% at 20 years.<sup>27</sup> Risk factors for increased mortality were identified as age at primary treatment, angle involvement, secondary glaucoma, extraocular extension, and prior surgical treatment before referral. The method of treatment (i.e. radiotherapy, enucleation, or local resection) was considered not to influence survival. The main limitation of this study was that despite the large sample size only nine patients developed metastatic disease. No firm conclusions can be drawn from this investigation, except perhaps that diffuse growth and seeding indicative of aggressive local disease may indicate a worse prognosis for survival. A Danish study provides further evidence that annular, or ring, spread is associated with increased mortality, but

again the number of deaths due to metastasis was small (eight patients).<sup>28</sup>

## CONCLUSIONS

The correlation between tumor size and mortality is still not fully explained, so that important treatment decisions depend largely on whether one believes that metastatic spread usually commences before or after tumor growth.

With large tumors, survival does not seem to be influenced by choice of treatment or by pre-enucleation radiotherapy. If one favors the 'late-onset metastasis' hypothesis, then all ocular forms of therapy are equally effective at preventing metastatic spread of large uveal melanomas from the eye. If one believes in the 'early-onset metastasis' hypothesis, then all ocular treatment is equally ineffective because all large melanomas with any metastatic potential have already disseminated by the time treatment is administered.

It is with small tumors that treatment deferral, pre-enucleation radiotherapy, and local tumor recurrence are most likely to influence survival. Studies undertaken with medium-sized and large tumors are probably of no relevance to small melanomas. Randomized studies of treatment versus no treatment of small uveal melanomas would seem to be indicated, but are prevented by logistical difficulties.<sup>29</sup> These problems might be overcome if it were possible to reliably identify the minority of small melanomas that have a significant metastatic potential.

From this review, it is obvious that studies on uveal melanoma are fraught with difficulties. Weighing risks against benefits in the face of uncertainty, while considering the patient's own utilities, or priorities, is a challenge. With recent advances in statistics and molecular biology one can expect new insights into the pathogenesis of metastatic disease from uveal melanoma and the impact of any treatment on survival.

## ACKNOWLEDGEMENT

The authors wish to thank J. Augsburger and W. Wackernagel for reviewing early drafts of the manuscript.

## REFERENCES

- Singh AD, Damato B, Howard P et al. Uveal melanoma: genetic aspects. *Ophthalmol Clin North Am* 2005; 18: 85–97, viii.
- Singh AD, Borden EC. Metastatic uveal melanoma. *Ophthalmol Clin North Am* 2005; 18: 143–150, ix.
- Kujala E, Makitie T, Kivela T. Very long-term prognosis of patients with malignant uveal melanoma. *Invest Ophthalmol Vis Sci* 2003; 44: 4651–4659.
- Bergman L, Seregard S, Nilsson B et al. Uveal melanoma survival in Sweden from 1960 to 1998. *Invest Ophthalmol Vis Sci* 2003; 44: 3282–3287.
- Manschot WA, Lee WR, van Strik R. Uveal melanoma: updated considerations on current management modalities. *Int Ophthalmol* 1995; 19: 203–209.
- Eskelin S, Pyrhonen S, Summanen P et al. Tumor doubling times in metastatic malignant melanoma of the uvea: tumor progression before and after treatment. *Ophthalmology* 2000; 107: 1443–1449.
- Singh AD. Uveal melanoma: implications of tumor doubling time. *Ophthalmology* 2001; 108: 829–831.
- Tschentscher F, Husing J, Holter T et al. Tumor classification based on gene expression profiling shows that uveal melanomas with and without monosomy 3 represent two distinct entities. *Cancer Res* 2003; 63: 2578–2584.
- Zimmerman LE, McLean IW, Foster WD. Does enucleation of the eye containing a malignant melanoma prevent or accelerate the dissemination of tumour cells? *Br J Ophthalmol* 1978; 62: 420–425.
- Singh AD, Rennie IG, Kivela T et al. The Zimmerman–McLean–Foster hypothesis: 25 years later. *Br J Ophthalmol* 2004; 88: 962–967.
- Gass JD. Comparison of uveal melanoma growth rates with mitotic index and mortality. *Arch Ophthalmol* 1985; 103: 924–931.
- Hawkins BS. The Collaborative Ocular Melanoma Study (COMS) randomized trial of pre-enucleation radiation of large choroidal melanoma: IV. Ten-year mortality findings and prognostic factors. COMS report number 24. *Am J Ophthalmol* 2004; 138: 936–951.
- Kilic E, Stijnen T, de Jong PT et al. Reduced melanoma-related mortality in uveal melanoma by preenucleation radiotherapy. *Arch Ophthalmol* 2005; 123: 1363–1367.
- Guthoff R, Frischmuth J, Jensen OA et al. Choroid melanoma. A retrospective randomized comparative study of ruthenium irradiation vs enucleation. *Klin Monatsbl Augenheilkd* 1992; 200: 257–261.
- Augsburger JJ, Schneider S, Freire J et al. Survival following enucleation versus plaque radiotherapy in statistically matched subgroups of patients with choroidal melanomas: results in patients treated between 1980 and 1987. *Graefes Arch Clin Exp Ophthalmol* 1999; 237: 558–567.
- Seddon JM, Gragoudas ES, Albert DM et al. Comparison of survival rates for patients with uveal melanoma after treatment with proton beam irradiation or enucleation. *Am J Ophthalmol* 1985; 99: 282–290.
- Diener-West M, Earle JD, Fine SL et al. The COMS randomized trial of iodine 125 brachytherapy for choroidal melanoma, III: initial mortality findings. COMS Report No. 18. *Arch Ophthalmol* 2001; 119: 969–982.
- Vrabec TR, Augsburger JJ, Gamel JW et al. Impact of local tumor relapse on patient survival after cobalt 60 plaque radiotherapy. *Ophthalmology* 1991; 98: 984–998.
- Egan KM, Ryan LM, Gragoudas ES. Survival implications of enucleation after definitive radiotherapy for choroidal melanoma: an example of regression on time-dependent covariates. *Arch Ophthalmol* 1998; 116: 366–370.
- Summanen P, Immonen I, Heikkonen J et al. Survival of patients and metastatic and local recurrent tumor growth in malignant melanoma of the uvea after ruthenium plaque radiotherapy. *Ophthalmic Surg* 1993; 24: 82–90.



21. Damato BE, Paul J, Foulds WS. Risk factors for metastatic uveal melanoma after trans-scleral local resection. *Br J Ophthalmol* 1996; 80: 109–116.
22. Foulds WS, Damato BE, Burton RL. Local resection versus enucleation in the management of choroidal melanoma. *Eye* 1987; 1: 676–679.
23. Shields CL, Shields JA, Perez N et al. Primary transpupillary thermotherapy for small choroidal melanoma in 256 consecutive cases: outcomes and limitations. *Ophthalmology* 2002; 109: 225–234.
24. Singh AD, Kivela T. The collaborative ocular melanoma study. *Ophthalmol Clin North Am* 2005; 18: 129–142, ix.
25. Straatsma BR, Diener-West M, Caldwell R et al. Mortality after deferral of treatment or no treatment for choroidal melanoma. *Am J Ophthalmol* 2003; 136: 47–54.
26. Singh AD, Topham A. Incidence of uveal melanoma in the United States: 1973–1997. *Ophthalmology* 2003; 110: 956–961.
27. Shields CL, Shields JA, Materin M et al. Iris melanoma: risk factors for metastasis in 169 consecutive patients. *Ophthalmology* 2001; 108: 172–178.
28. Jensen OA. Malignant melanoma of the iris. A 25-year analysis of Danish cases. *Eur J Ophthalmol* 1993; 3: 181–188.
29. Augsburger JJ. Is observation really appropriate for small choroidal melanomas? *Trans Am Ophthalmol Soc* 1993; 91: 147–168.

# Uveal malignant melanoma: metastasis

Arun D. Singh, Julie Bray and Ernest C. Borden

## INTRODUCTION

In general, the survival of patients with metastatic uveal melanoma is poor, with a median survival of less than 6 months.<sup>1</sup> Despite recent advances in management, the relative survival rate of uveal melanoma appears to have remained unchanged over the last 25 years.<sup>2</sup> In this chapter the pathogenesis, clinical features, and treatment of metastatic uveal melanoma are outlined.

## PATHOGENESIS

Cytogenetic studies have demonstrated that non-random alterations of monosomy 3 and additional copies of 8q independently predict worse outcome. These chromosomal changes not only determine which patient ultimately develops metastases, but also how rapidly metastases develop following treatment of the primary tumor.<sup>3</sup> Gene expression profiling of uveal melanoma is yielding important new insights into its pathogenesis, and there is correlation of gene expression pattern with cytogenetic changes,<sup>4</sup> improving prognostic accuracy.<sup>5</sup> The correlation between the loss of expression of HLA class I antigens and improved survival indicates that there is an ongoing NK cell-mediated surveillance of uveal melanoma tumor cells in the blood.<sup>6</sup>

## CLINICAL FEATURES

**Frequency of metastasis** Clinically evident metastatic disease at the time of initial presentation is detected in less than 1% of all patients.<sup>1</sup> Nevertheless, long-term follow-up of treated patients reveals metastases in 31% of cases in 5 years, 45% in 15 years, and almost 50% in 25 years (Fig. 48.1).<sup>7</sup> These findings suggest that subclinical metastasis is present in such cases at the time of primary treatment. The correlation of primary and metastatic uveal melanoma growth data suggests that metastasis commences when the primary tumor is still small.<sup>8</sup> At the time of diagnosis of the primary uveal melanoma, any metastases are too small to be clinically detected by currently available techniques (Fig. 48.2).<sup>8,9</sup> After 10 years of observation, more than 40% of patients with large uveal melanomas would have developed metastatic disease, whereas less than 20% of patients with medium or small primaries will develop metastases.

**Sites of metastasis** The liver is the predominant organ, being involved in 70–90% of cases with metastatic uveal melanoma.<sup>10–12</sup> Liver involvement also tends to be the first manifestation of metastatic disease.<sup>10</sup> In almost half of cases other organs, such as the lungs, bone, and skin, may be affected in addition to the liver. Lymph nodes and brain are uncommonly involved (Box 48.1).<sup>1,13</sup> Metastasis to the

fellow eye is extremely rare.<sup>14</sup> The extent of metastatic disease is greater than clinically suspected in cases that undergo autopsy.<sup>13</sup> In an atypical clinical scenario, the possibility of a coexistent second primary tumor should be considered.

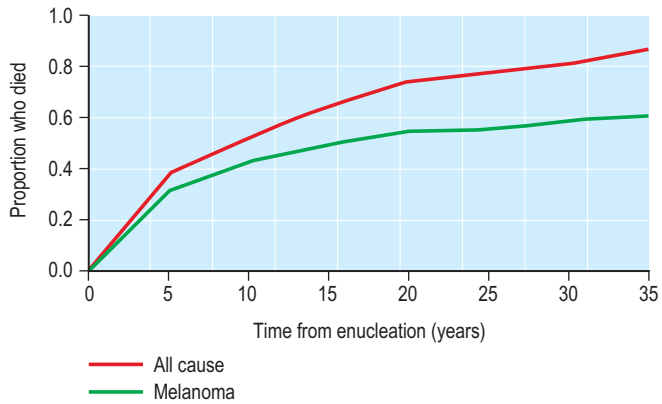
**Determinants of metastasis** Several clinical, histopathological, cytogenetic, and molecular genetic factors influence the frequency of metastasis and the interval between the diagnosis of the primary tumor and the onset of metastatic disease (see Chapter 46).<sup>15</sup>

**Signs and symptoms** Patients with metastases can present with a variety of symptoms based on organ involvement. About 60% are asymptomatic at the time of detection of their metastases.<sup>16</sup> General malaise, loss of appetite, and jaundice are some of the common symptoms. Hepatomegaly, abnormal liver function tests, and abnormal appearance of the liver on imaging studies are highly suspicious of metastasis. However, liver function tests can be normal in about one-third of cases in the presence of liver metastases.<sup>16</sup> Needle biopsy is usually performed to confirm the diagnosis (Fig. 48.3).

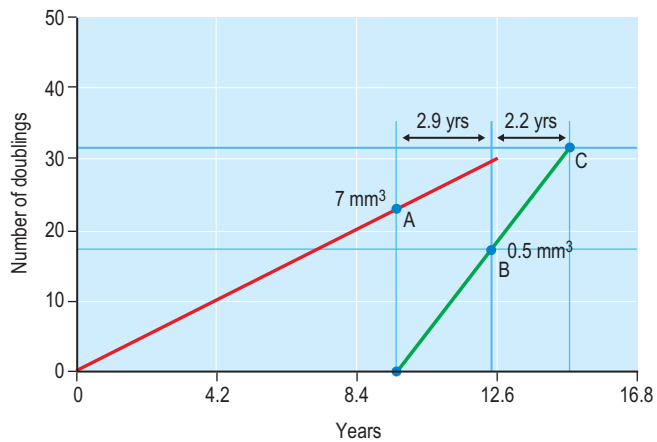
## DIAGNOSTIC EVALUATION

The role of systemic screening is controversial because of the lack of effective treatment for metastatic disease. Nevertheless, several screening protocols are widely used.<sup>17</sup> In the Collaborative Ocular Melanoma Study, patients with medium-sized and large choroidal melanoma were screened annually for metastasis by physical examination, liver function tests (LFTs), and chest X-ray.<sup>18</sup> Liver function tests include a panel of AST, ALT, alkaline phosphatase, and bilirubin. Any elevated LFT prompted a diagnostic evaluation (imaging test with or without biopsy) to confirm metastasis. The sensitivity and specificity of LFT were 14.7% and 92.3%, respectively. Sensitivity improved to only 19% for large tumors.<sup>1</sup> The positive predictive value was 45.7%, and negative predictive value was 71.0%. Of all the LFTs, alkaline phosphatase had the highest sensitivity. These findings indicate that abnormal LFT values correctly predict metastasis in only 50% of cases. Conversely, normal LFTs are unreliable, with around a 30% false negative rate. Chest X-rays were not useful because they were positive only in 3% of screened patients.<sup>1</sup>

There are data to suggest that screening solely by liver imaging, such as an ultrasonography performed every 6–12 months, may be adequate for detecting subclinical metastatic melanoma.<sup>16</sup> In a recent survey, significant differences in the methods used for screening metastatic uveal melanoma were observed between ocular oncologists in



**Fig. 48.1** Kaplan–Meier estimate of all-cause and melanoma-specific mortality. (Modified with permission from Kujala E, Mäkitie T, Kivelä T. Very long-term prognosis of patients with malignant uveal melanoma. *Invest Ophthalmol Vis Sci* 2003; 44: 4651–4659.)

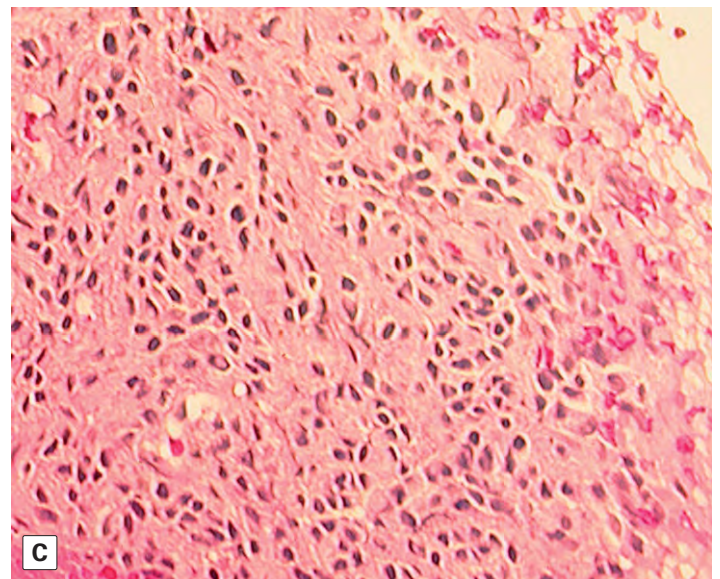
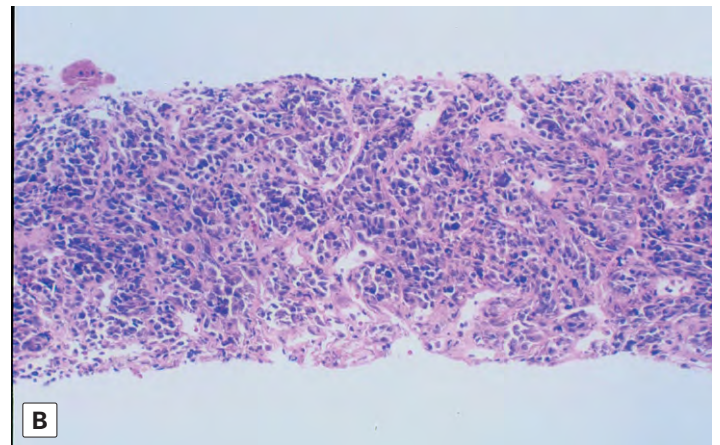
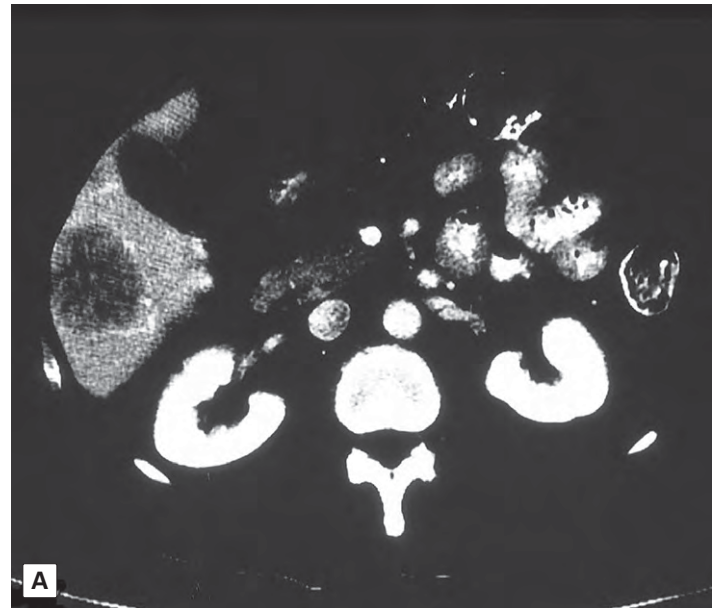


**Fig. 48.2** Inferred growth of primary (red line) and metastatic uveal melanoma (green line) based on tumor doubling times. It takes 2.2 years after the diagnosis of primary tumor (point B) for the metastases to be clinically detected, point C. At the time of metastasis (point A), the primary tumor is estimated to be 7 mm<sup>3</sup> and the metastases are subclinical. (Modified with permission from Eskelin S, Kivelä T. Tumor doubling times in metastatic malignant melanoma of the uvea: tumor progression before and after treatment. *Ophthalmology* 2001; 108: 830–831.)

#### BOX 48.1 Sites for Metastatic Uveal Melanoma

- Liver 93%
- Lungs 24%
- Bone 16%
- Skin 11%
- Lymph nodes 10%
- Brain 5%
- Fellow eye 0%

Multiple sites involved in about half the cases.  
In an atypical case consider a second primary tumor.



**Fig. 48.3** Computerized tomograph of the liver shows a focal area of metastasis in the right lobe of the liver (A). Fine needle aspiration biopsy of the liver (B). Metastatic uveal melanoma (C). (Hematoxylin & eosin  $\times$  400.)



North America and Europe.<sup>17</sup> Liver ultrasonography is used widely in Europe, whereas liver function tests and chest X-rays are preferred in North America.<sup>17</sup>

Even in adequately screened individuals, the survival seems to be no different whether the diagnosis is made on the basis of symptoms or by currently used screening methods (imaging, physical examination, hepatic panel).<sup>19</sup> Therefore, there is a need for better screening tests with improved sensitivity to detect early metastatic disease.<sup>1,17</sup> Current areas of research include the use of tumor-associated antigen melanoma inhibitory activity by ELISA assay as a serological tumor marker,<sup>20</sup> and the detection of circulating tumor cells by reverse transcriptase polymerase chain reaction.<sup>21</sup>

## TREATMENT OPTIONS

Several treatments have been tried for patients with metastatic uveal melanoma and these include chemotherapy, intra-arterial hepatic chemotherapy, chemoembolization, immunotherapy, surgery, and a combined approach (Box 48.2). Most published results are based on non-randomized, non-comparative case series of a small number of patients or phase I trials.<sup>22</sup>

**Chemotherapy** Various chemotherapeutic agents have been investigated for the treatment of metastatic uveal melanoma (Table 48.1). Initial promising reports with a combination of bleomycin, vincristine, lomustine, and dacarbazine (BOLD) with interferon- $\alpha_2$ <sup>23</sup> were subsequently proved overoptimistic in a larger number of patients.<sup>24</sup> Moreover, published data from the Eastern Cooperative Oncology Group suggest that liver metastasis from uveal melanoma has a lower response rate (10%) than metastasis from cutaneous melanoma (33%) when patients are treated with the ‘Dartmouth combination’ (dacarbazine, carmustine, cisplatin, and tamoxifen).<sup>12</sup> Using a novel approach based on ATP-based tumor chemosensitivity assay, encouraging preliminary results have been reported on 14 patients treated with a combination of treosulfan and gemcitabine, with a median survival of 14 months.<sup>25</sup>

**Intra-arterial hepatic chemotherapy** can be selectively delivered to liver tumors by infusion through a hepatic artery catheter, as

such tumors (both primary and secondary) obtain their blood supply from this artery, whereas normal liver tissue is mainly supplied by the portal circulation. Various drugs have been investigated and median survival times of 12–14 months have been reported (Table 48.2).<sup>22,26,27</sup>

**Chemoembolization** is used to achieve a prolonged and a high local concentration of chemotherapeutic agents such as cisplatin with polyvinyl sponge. Although an objective response in more than one-third of cases has been reported from the MD Anderson Cancer Center,<sup>11</sup> others could not reproduce these results.<sup>28</sup>

**Immunotherapy** There has been a uniform lack of benefit of immunotherapy with either methanol-extracted BCG, interleukin-2, or lymphokine-activated killer cells.<sup>22,29</sup>

**Surgery** Some of the longest median survival times in metastatic uveal melanoma patients have been obtained when patients were amenable to complete resection of the solitary metastasis in the liver<sup>30</sup> or other sites (Table 48.3).<sup>31</sup> Unfortunately, less than 10% of all patients with metastatic uveal melanoma have such a profile.<sup>31</sup> In addition, most patients undergoing resection of an apparently solitary tumor eventually develop additional hepatic or extrahepatic metastases.<sup>31</sup>

## Surgery and intra-arterial hepatic chemotherapy

When feasible, complete surgical excision of the hepatic metastasis followed by intra-arterial hepatic fotemustine and/or dacarbazine + cisplatin has been reported to prolong median survival to about 22 months.<sup>32</sup>

## PROGNOSIS

Initial metastasis to extrahepatic sites (lung, soft tissue, skin), age less than 60 years, female gender, and a longer interval from initial diagnosis to metastatic disease are associated with good prognosis.<sup>19</sup> However, survival with metastatic uveal melanoma is poor, with a median of less than 6 months.<sup>1</sup> Dacarbazine-based chemotherapy used for the treatment of metastatic cutaneous melanoma is ineffective in the treatment of metastatic uveal melanoma.<sup>11</sup> Total resection of the solitary metastasis in the liver or at other sites offers a distinct survival advantage.<sup>30,31</sup> However, the longest median survival is observed when it is possible to perform complete surgical excision of the hepatic metastasis, followed by intra-arterial hepatic fotemustine and/or dacarbazine + cisplatin.<sup>19,32</sup>

## FUTURE RESEARCH

Cytogenetic testing, FISH analysis, and gene expression profiling are offering improved prognostic accuracy.<sup>3,5</sup> It may be feasible to extend the possibilities of predictive testing to patients receiving various forms radiotherapy by performing needle aspiration biopsies. Gene profiling and proteomics should identify new targets for therapeutic interventions in a setting of multicenter, prospective randomized trials.

## ACKNOWLEDGEMENT

This chapter was modified with permission from Singh AD, Borden EC. Metastatic uveal melanoma. *Ophthalmol Clin North Am* 2005; 18: 143–145.

### BOX 48.2 Metastatic Uveal Melanoma

- Median survival is less than 6 months
- Dacarbazine-based chemotherapy is ineffective
- Total resection of the solitary metastasis offers a survival advantage
- Total resection of the hepatic metastasis followed by intra-arterial hepatic chemotherapy (where feasible) may prolong the median survival (22 months)
- Screening protocols, although generally recommended, are of questionable benefit
- Gene profiling and proteomics may offer new therapeutic targets

**Table 48.1 Chemotherapy for metastatic uveal melanoma**<sup>10,12,21–24</sup>

Author	Year	No. of patients	Chemotherapy	Median survival (months)	Response			Type of study
					CR	PR	%	
Einhorn	1974	25	Various	8.5	0	4	16	Retrospective
Rajpal	1983	7*	Various	4.5				Retrospective
Gragoudas	1991	61*	Various	3.8				Review
Pyrhonen	1992	4	BOLD + Interferon $\alpha$	–	0	2	50	Phase I
Kath	1993	14*	Various	9	0	0	0	Retrospective
Nathan	1994	16	Dartmouth	–	0	1	6	Prospective Uncontrolled
Bedekian	1995	143	Various	6	0	1	<1	Retrospective
Atzpodien#	1995	7	Dacarbazine + carboplatin or Dartmouth + interferon- $\alpha$ 2		–	–	–	Phase II
Albert	1996	51	Various	4.5	0	0	0	Review
Proebstle	1996	8	Dacarbazine + cisplatin + interferon- $\alpha$ 2b	–	0	1	12	Phase I
Nathan	1997	20	BOLD + interferon- $\alpha$ 2b	–	0	4	20	Prospective Uncontrolled
Flaherty	1998	64	Dacarbazine or csplatin	5	1	5	9	Prospective Uncontrolled
Pyrhonen	2002	20	BOLD + interferon- $\alpha$	12	0	3	15	Prospective Uncontrolled
Kivelä	2003	24	BOLD + interferon- $\alpha$ 2b	11	0	0	0	Prospective Uncontrolled
Pfohler	2003	14	Treosulfan + gemcitabine	14	1	3	29	Prospective Uncontrolled
Bedekian	2003	14	Temozolomide	?	0	0	0	Prospective Uncontrolled

\*Treated with chemotherapy alone.

# Not segregated from cutaneous melanoma.

CR, complete response; PR, partial response.

Dartmouth: dacarbazine + carmustine + cisplatin + tamoxifen.

BOLD: bleomycin, vincristine, lomustine, and dacarbazine.

ECOG: Eastern Cooperative Group.

**Table 48.2 Intrahepatic arterial chemotherapy for metastatic uveal melanoma**<sup>11,21,25,26</sup>

Author	Year	No. of patients	Chemotherapy	Median survival (months)	Response			Type of study
					CR	PR	%	
Cantore	1994	8	Carboplatin	15	0	3	38	Prospective Uncontrolled
Bedekian	1995	38	Various	–	0	2	5	Retrospective review
Leyvraz	1997	31	Fotemustine	14	4	8	40	Prospective Uncontrolled
Alexander	1998	7	TNF + melphalan		2	2	57	Prospective Uncontrolled
Egerer	2001	7	Fotemustine	24	0	2	29	Prospective Uncontrolled
Becker	2002	48	Fotemustine + Interleukin 2 + Interferon 2	19**	1	6	13	Prospective Uncontrolled

\*Isolated hyperthermic hepatic perfusion.

\*\*In patients demonstrating objective response. The median survival in non-responders was 13 months. CR, complete response; PR, partial response; TNF, tumor necrosis factor.

**Table 48.3 Surgical resection for metastatic uveal melanoma**<sup>10,21,29–31</sup>

Author	Year	No. of patients	Adjuvant treatment (months)	Median survival	Comments
Rajpal	1983	15	Chemotherapy	18.4	Retrospective
Fournier	1984	2	Chemotherapy	12 and 36	Case series
Salmon	1998	75	Intra-arterial hepatic chemotherapy	9 (overall)	Prospective Uncontrolled
			Dacarbazine or Cisplatin	22 (complete resection)	
Aoyama	2000	12	Chemotherapy Chemoembolization	27 (complete resection)	Prospective Uncontrolled

Single case reports excluded.

## REFERENCES

- Diener-West M, Reynolds SM, Agugliaro DJ et al. Screening for metastasis from choroidal melanoma: the Collaborative Ocular Melanoma Study Group Report 23. *J Clin Oncol* 2004; 22: 2438–2444.
- Singh AD, Topham A. Survival rate with uveal melanoma in the United States: 1973–1997. *Ophthalmology* 2003; 110: 962–965.
- Sisley K, Rennie IG, Parsons MA et al. Abnormalities of chromosome 3 and 8 in posterior uveal melanoma correlate with prognosis. *Genes Chromosomes Cancer* 1997; 19: 22–28.
- Tschentscher F, Prescher G, Horsman DE et al. Partial deletions of the long and short arm of chromosome 3 point to two tumor suppressor genes in uveal melanoma. *Cancer Res* 2001; 61: 3439–3442.
- Onken MD, Worley LA, Ehlers JP, Harbour JW. Gene expression profiling in uveal melanoma reveals two molecular classes and predicts metastatic death. *Cancer Res* 2004; 64: 7205–7209.
- Jager MH, Hurks MH, Levitskaya J, Kiessling R. HLA expression in uveal melanoma: there is no rule without some exception. *Hum Immunol* 2002; 63: 444–451.
- Kujala E, Makitie T, Kivelä T. Very long-term prognosis of patients with malignant uveal melanoma. *Invest Ophthalmol Vis Sci* 2003; 44: 4651–4659.
- Singh AD. Uveal melanoma: implications of tumor doubling time. *Ophthalmology* 2001; 108: 829–830.
- Eskelin S, Kivelä T. Reply: Tumor doubling times in metastatic malignant melanoma of the uvea: tumor progression before and after treatment. *Ophthalmology* 2001; 108: 830–831.
- Rajpal S, Moore R, Karakousis CP. Survival in metastatic ocular melanoma. *Cancer* 1983; 52: 334–336.
- Bedikian AY, Legha SS, Mavligit G et al. Treatment of uveal melanoma metastatic to the liver: a review of the MD Anderson Cancer Center experience and prognostic factors. *Cancer* 1995; 76: 1665–1670.
- Albert DM, Ryan LM, Borden EC. Metastatic ocular and cutaneous melanoma: a comparison of patient characteristics and prognosis. *Arch Ophthalmol* 1996; 114: 107–108.
- Group TCOMS. Assessment of metastatic disease status at death in 435 patients with large choroidal melanoma in the Collaborative Ocular Melanoma Study (COMS): COMS report no. 15. *Arch Ophthalmol* 2001; 119: 670–676.
- Singh AD, Shields JA, Shields CL, Sato T. Choroidal melanoma metastatic to the contralateral choroid. *Am J Ophthalmol* 2001; 132: 941–943.
- Singh AD, Shields CL, Shields JA. Prognostic factors in uveal melanoma. *Melanoma Res* 2001; 11: 1–9.
- Eskelin S, Kivelä T. Imaging to detect metastases from malignant uveal melanoma. *Arch Ophthalmol* 2002; 120: 676.
- Gombos DS, Van Quill KR, Uusitalo M, O'Brien JM. Geographic disparities in diagnostic screening for metastatic uveal melanoma. *Ophthalmology* 2004; 111: 2254–2258.
- Group COMS. COMS Manual of Procedures. Vol. AC. Springfield, VA: National Technical Information Service, 1995.
- Rietschel P, Panageas KS, Hanlon C et al. Variates of survival in metastatic uveal melanoma. *J Clin Oncol* 2005; 23: 8076–8080.



20. Reiniger IW, Schaller UC, Haritoglou C et al. 'Melanoma inhibitory activity' (MIA): a promising serological tumour marker in metastatic uveal melanoma. *Graefes Arch Clin Exp Ophthalmol* 2005; 243: 1161–1166.
21. Boldin I, Langmann G, Richtig E et al. Five-year results of prognostic value of tyrosinase in peripheral blood of uveal melanoma patients. *Melanoma Res* 2005; 15: 503–507.
22. Singh AD, Borden EC. Metastatic uveal melanoma. *Ophthalmol Clin North Am* 2005; 18: 143–150, ix.
23. Pyrhonen S. The treatment of metastatic uveal melanoma. *Eur J Cancer* 1998; 34(Suppl 3): S27–30.
24. Kivelä T, Suci S, Hansson J et al. Bleomycin, vincristine, lomustine and dacarbazine (BOLD) in combination with recombinant interferon alpha-2b for metastatic uveal melanoma. *Eur J Cancer* 2003; 39: 1115–1120.
25. Pfohler C, Cree IA, Ugurel S et al. Treosulfan and gemcitabine in metastatic uveal melanoma patients: results of a multicenter feasibility study. *Anticancer Drugs* 2003; 14: 337–340.
26. Leyvraz S, Spataro V, Bauer J et al. Treatment of ocular melanoma metastatic to the liver by hepatic arterial chemotherapy. *J Clin Oncol* 1997; 15: 2589–2595.
27. Becker JC, Terheyden P, Kampgen E et al. Treatment of disseminated ocular melanoma with sequential fotemustine, interferon alpha, and interleukin 2. *Br J Cancer* 2002; 87: 840–845.
28. Sato T, Nathan FE, Berd D et al. Lack of effect from chemoembolisation for liver metastasis from uveal melanoma [abstract]. *Proc Am Soc Clin Oncol* 1995; 14: 415.
29. Keilholz U, Scheibenbogen C, Brado M et al. Regional adoptive immunotherapy with interleukin-2 and lymphokine-activated killer (LAK) cells for liver metastases. *Eur J Cancer* 1994; 30A: 103–105.
30. Fournier GA, Albert DM, Arrigg CA et al. Resection of solitary metastasis. Approach to palliative treatment of hepatic involvement with choroidal melanoma. *Arch Ophthalmol* 1984; 102: 80–82.
31. Aoyama T, Mastrangelo MJ, Berd D et al. Protracted survival after resection of metastatic uveal melanoma. *Cancer* 2000; 89: 1561–1568.
32. Salmon RJ, Levy C, Plancher C et al. Treatment of liver metastases from uveal melanoma by combined surgery–chemotherapy. *Eur J Surg Oncol* 1998; 24: 127–130.

# Uveal vascular tumors

Arun D. Singh and Peter K. Kaiser

## INTRODUCTION

Uveal vascular tumors represent benign, hamartomatous disorders and are classified as hemangiomas. Although the iris and ciliary body can be involved, hemangiomas most frequently affect the choroid. Choroidal hemangioma can either be circumscribed or diffuse.<sup>1</sup> In general, uveal hemangioma may be confined to the globe or may be a manifestation of a widespread hemangiomatous disorder. In this chapter the clinical features, differential diagnosis, and treatment of iris, ciliary body, circumscribed choroidal, and diffuse choroidal hemangioma are outlined.

## IRIS HEMANGIOMA

Iris hemangioma is a rare benign vascular tumor of the iris stroma. Some have even questioned its existence.<sup>3–5</sup> However, there are few well documented cases with histopathologic<sup>6–10</sup> and immunohistochemical findings that are confirmatory of the diagnosis.<sup>11</sup>

**Clinical features** The majority of iris hemangiomas appear as an orange or red circumscribed mass that may have prominent feeder vessels,<sup>12</sup> a multiloculated cavernous appearance,<sup>13</sup> or simply be a single circumscribed mass.<sup>11</sup> Associated hyphema and secondary glaucoma may be present. There are two variants of iris hemangioma. One is limited to the iris without any ocular or systemic associations (Fig. 49.1).<sup>12</sup> The second may be associated with cavernous hemangioma of the CNS<sup>13</sup> or may occur in the setting of a lethal systemic disease known as diffuse neonatal hemangiomatosis (Fig. 49.2).<sup>6,8,9,11</sup> As the name implies, diffuse hemangiomatosis is characterized by multifocal cutaneous and visceral hemangioma that are usually evident at birth.<sup>8</sup> In addition to iris hemangioma, eyelid and conjunctival hemangiomas may also be present (Table 49.1).<sup>8</sup>

**Diagnostic evaluation** The diagnosis is suspected based on clinical findings and is supported by iris fluorescein angiography (Fig. 49.1).<sup>12</sup> Histopathologic findings include cavernous spaces filled with blood cells on light microscopy,<sup>6,9,11</sup> and immunopositivity to factor VIII and CD 34,<sup>11</sup> indicating endothelial cells, confirms the diagnosis (Fig. 49.3).

**Differential diagnosis** Iris melanoma, iris granuloma, juvenile xanthogranuloma of the iris, and iris neovascularization may mimic iris hemangioma.<sup>3</sup>

**Treatment** Supportive care, such as the management of associated glaucoma and amblyopia treatment, are usually needed in children.

Topical steroids can be used to induce tumor regression.<sup>8</sup> In progressive tumors, excision should be considered.<sup>11</sup>

**Prognosis** Hemangiomas of the iris and those present elsewhere have a tendency to undergo spontaneous regression, which can be hastened by the use of topical and systemic steroids.<sup>8</sup> Survival beyond the first year of life is rare in diffuse hemangiomatosis owing to congestive heart failure.<sup>8,9</sup>

## CILIARY BODY HEMANGIOMA

Only a few cases of well-documented ciliary body hemangioma have been published.<sup>3,14</sup> These tumors are mistaken for ciliary body melanomas and a definitive diagnosis is made on histopathologic evaluation following iridocyclectomy.<sup>14</sup> In the setting of diffuse neonatal hemangiomatosis,<sup>9</sup> ciliary body hemangioma can cause secondary glaucoma.<sup>15</sup>

## CIRCUMSCRIBED CHOROIDAL HEMANGIOMA

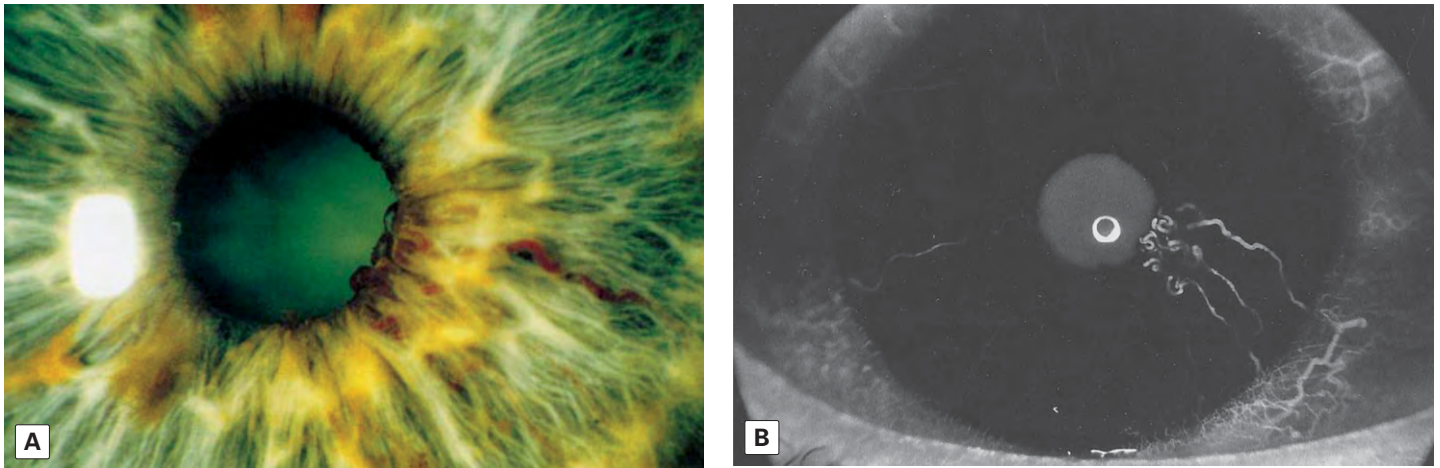
A circumscribed choroidal hemangioma is usually diagnosed between the second and fourth decades of life when it causes visual disturbances owing to the development of an exudative retinal detachment.<sup>16</sup> Circumscribed tumors occur sporadically, without any associated local or systemic anomalies. In contrast, a diffuse choroidal hemangioma is usually evident at birth and generally occurs as a part of neuro-oculocutaneous hemangiomatosis (Sturge–Weber syndrome).

## Clinical features

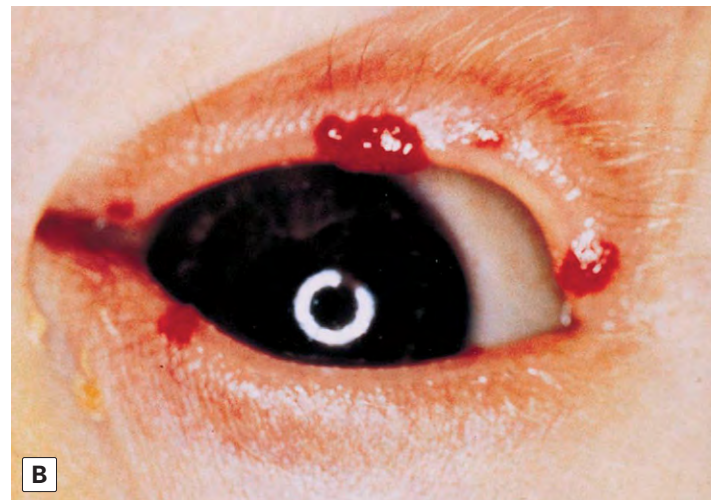
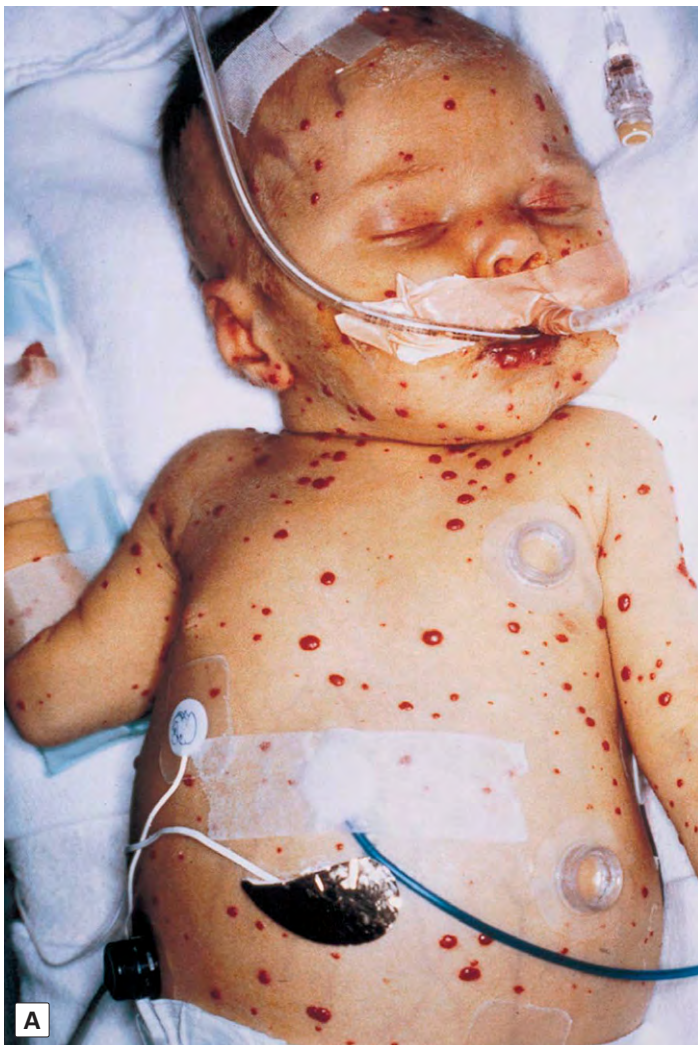**Symptoms** Although they are usually asymptomatic, the most common symptom of circumscribed choroidal hemangioma is visual disturbance, such as reduced vision, metamorphopsia, and photopsia.

**Signs** Ophthalmoscopically, a circumscribed choroidal hemangioma appears as an orange choroidal mass with margins that blend with the surrounding choroid (Fig. 49.4A). Circumscribed choroidal hemangiomas are usually located in the posterior pole and are no thicker than 6 mm.<sup>1</sup> Although they are vascular tumors, prominent intrinsic tumor vessels or feeder vessels are not seen ophthalmoscopically. Subretinal fluid from the tumor leading to an exudative retinal detachment is generally present in symptomatic cases (Box 49.1).

**Differential diagnosis** A circumscribed choroidal hemangioma can be misdiagnosed as an amelanotic choroidal lesion, such as an



**Fig. 49.1** Abnormal collection of iris vessels at the pupillary margin with prominent feeder vessel (A). Iris angiography confirms the vascular nature of the tumor (B). (Reproduced with permission from Giessler S, Tost F, Duncker GI. Vascular convolute of the iris. *Cavernous iris hemangioma*. *Ophthalmologie* 1999; 96: 752-753.)



**Fig. 49.2** Diffuse neonatal hemangiomatosis. Numerous cutaneous hemangiomas are distributed throughout the body (A). The right eye shows several eyelid hemangiomas (B). (Reproduced with permission from Chang CW, Rao NA, Stout JT. Histopathology of the eye in diffuse neonatal hemangiomatosis. *Am J Ophthalmol* 1998; 125: 868-870.)



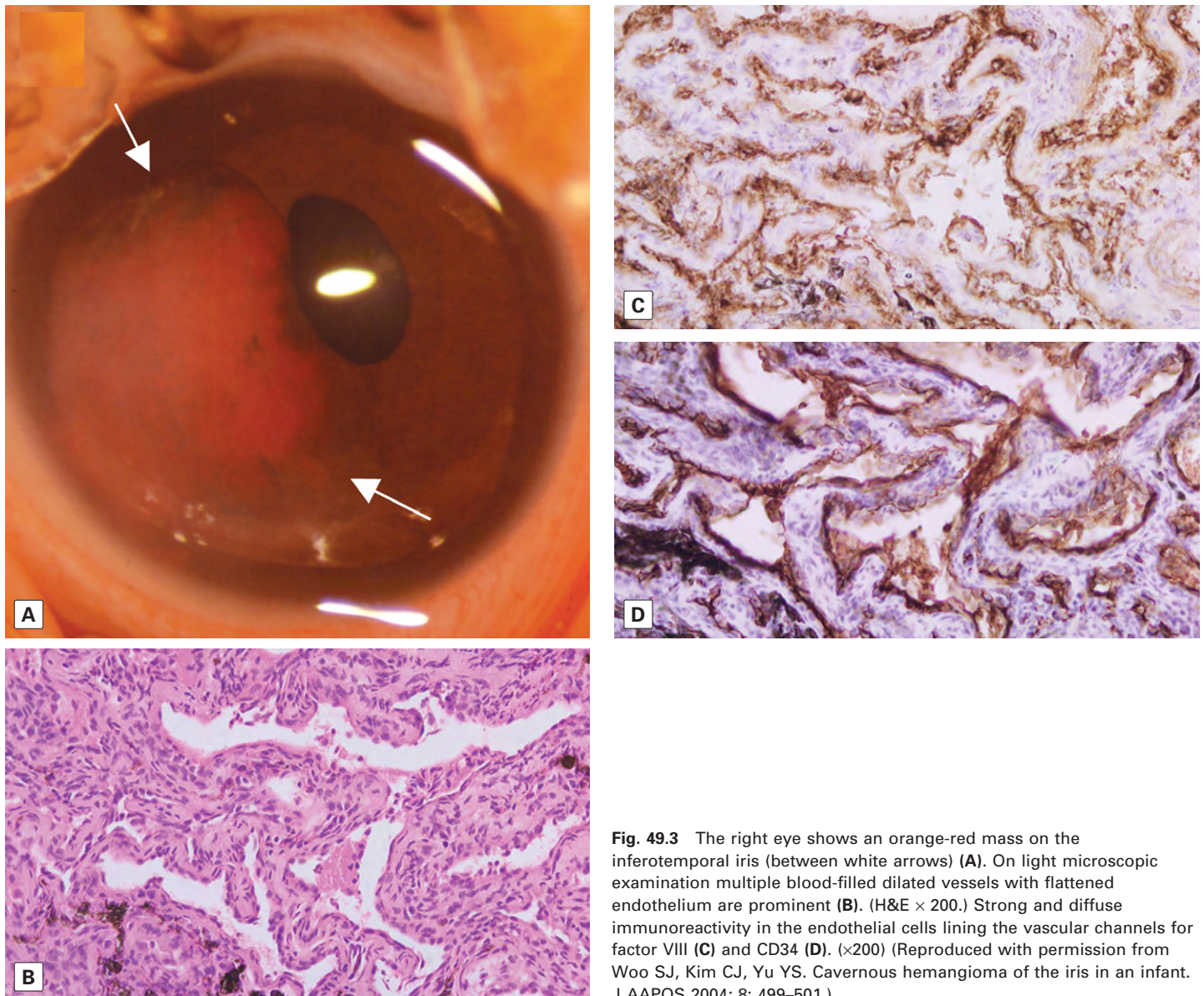
**Table 49.1 Summary of ocular manifestations of diffuse neonatal hemangiomatosis<sup>6</sup>**

Site	Abnormality	Frequency (%)
Iris	Hemangioma	75
Conjunctiva	Hemangioma	38
Eyelid	Hemangioma	25
Fundus	Abnormal vasculature	38
Angle	Secondary glaucoma	13
Neuro-ophthalmic	III and VI nerve palsy, cortical blindness	38

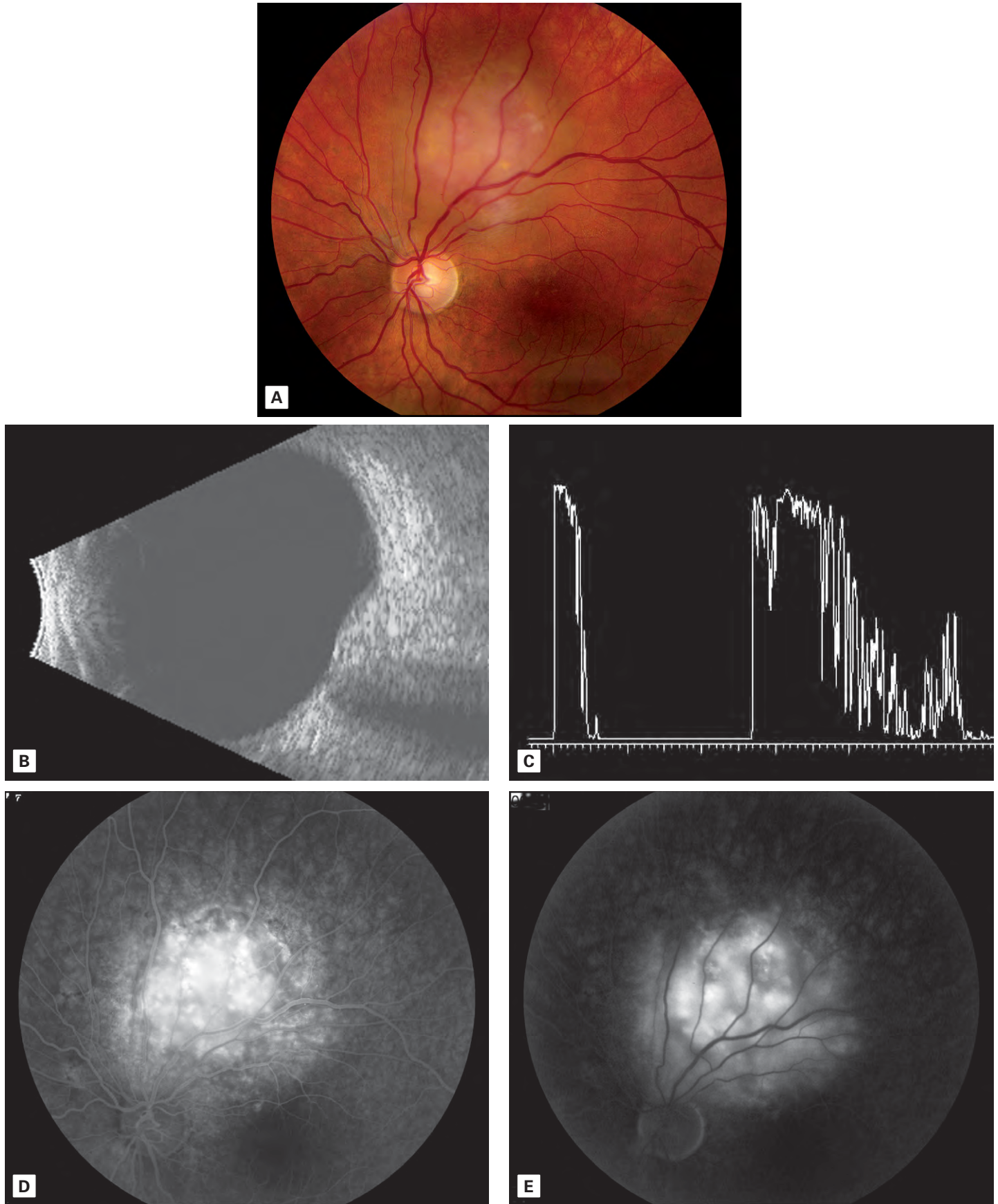
(Modified with permission from Naidoff MA, Kenyon KR, Green WR. Iris hemangioma and abnormal retinal vasculature in a case of diffuse congenital hemangiomatosis. *Am J Ophthalmol* 1971; 72: 633–644)

amelanotic choroidal malignant melanoma, choroidal metastasis, posterior scleritis, choroidal granuloma, or atypical central serous retinopathy (Table 49.2). Ultrasonographic findings of high internal reflectivity and angiographic evidence of very early hyperfluorescence strongly support a diagnosis of circumscribed choroidal hemangioma.

**Diagnostic evaluation** Ultrasonographic and angiographic studies with fluorescein and indocyanine green (ICG) dyes are helpful in establishing the correct diagnosis. On B-scan ultrasonography a hemangioma appears as a smooth-contoured, dome-shaped, choroidal mass that demonstrates high internal reflectivity on A-scan (Fig. 49.4B,C). Its choroidal origin is confirmed by angiographic studies. On fluorescein angiography the hemangioma appears as a hyperfluorescent mass with a fine lacy network of intrinsic vessels in the choroidal filling phase (early views). The hyperfluorescence increases through most of the phases of the angiogram, with variable amounts of late leakage (Fig. 49.4D,E). The intrinsic vascular pattern of a choroidal hemangioma is better observed with ICG angiography.<sup>17</sup> Within



**Fig. 49.3** The right eye shows an orange-red mass on the inferotemporal iris (between white arrows) (A). On light microscopic examination multiple blood-filled dilated vessels with flattened endothelium are prominent (B). (H&E  $\times 200$ .) Strong and diffuse immunoreactivity in the endothelial cells lining the vascular channels for factor VIII (C) and CD34 (D). ( $\times 200$ ) (Reproduced with permission from Woo SJ, Kim CJ, Yu YS. Cavernous hemangioma of the iris in an infant. *J AAPOS* 2004; 8: 499–501.)



**Fig. 49.4** Fundus photograph of the left eye showing a circumscribed choroidal hemangioma (A). On B-scan ultrasonography there is a smooth-contoured, dome-shaped choroidal mass (B) that demonstrates high internal reflectivity on A-scan (C). Fluorescein angiography shows early hyperfluorescence (53s) (D). The hyperfluorescence increases through most of the phases of the angiogram, with variable amounts of late leakage (10min) (E). Indocyanine green angiogram showing early hyperfluorescence (within 30 seconds) (F). In the late phase a 'washout' effect with reduction of the initial hyperfluorescence due to egress of dye from the hemangioma is observed (20 minutes) (G).



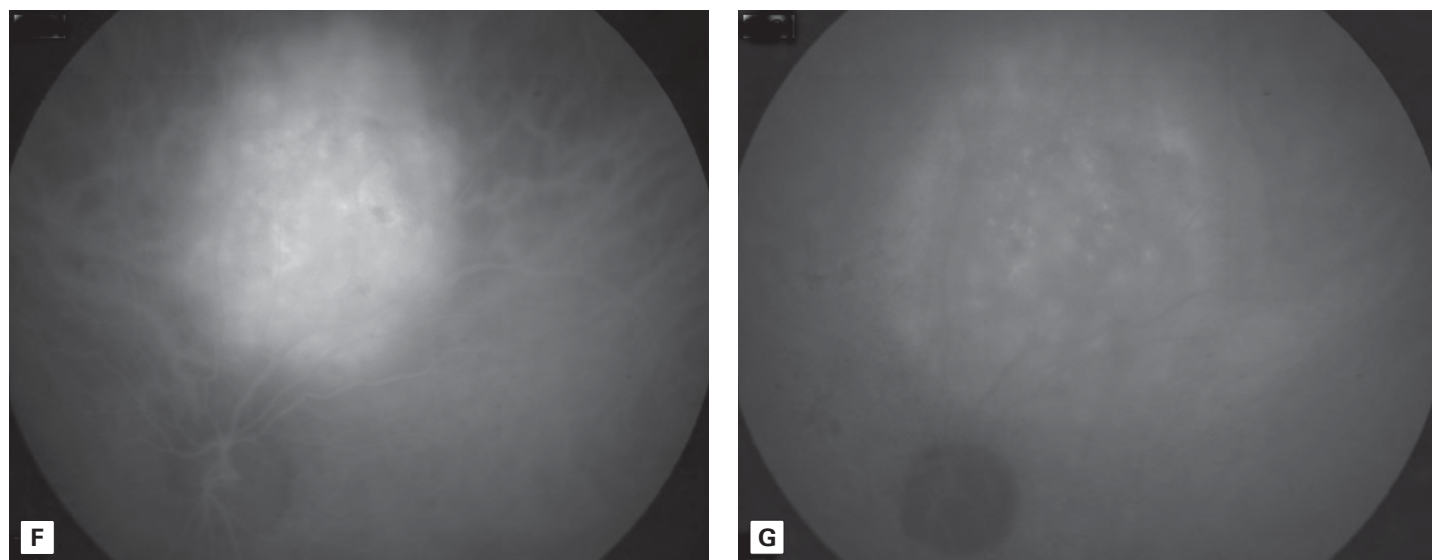


Fig. 49.4 continued

**BOX 49.1 Diagnostic Features of a Circumscribed Choroidal Hemangioma**

- Onset of symptoms between second and fourth decades of life
- Orange choroidal mass with indistinct margins
- Located in posterior pole
- May have associated subretinal fluid
- Usually not thicker than 6mm
- Ophthalmoscopic absence of intrinsic tumor vessels
- Absent feeder vessels
- Absent or minimal retinal hard exudates
- Very early hyperfluorescence on angiography
- High internal reflectivity on A-scan ultrasonography

**Table 49.2 Differential diagnosis of a circumscribed choroidal hemangioma**

Feature	Choroidal melanoma	Choroidal metastasis	Choroidal granuloma	Posterior scleritis	Choroidal hemangioma
Pain	–	–	–	+	–
Color	Brown Yellow (amelanotic)	Yellow	Yellow	Orange	Orange
Location	Anywhere	Anywhere	Anywhere	Posterior pole	Posterior pole
Number	Single	Multiple	Single or multiple	Single	Single
Intrinsic vessels	Visible	–	–	–	–
Subretinal fluid	+	+	+	+	+
Hard exudates	–	–	–	–	–
Vitreous cells	–	–	+	+/-	–
Fluorescein angiography	Early	Hypo	Hypo	Hypo	Hyper
	Late	Hyper	Hyper	Hyper	Hyper
ICG fluorescence	Late hyper	Late hyper	Late hyper	Late hyper	Early hyper
Ultrasonographic internal reflectivity	Low	Medium	High	High, Tenons lucency	High

Hypo, hypofluorescent; Hyper, hyperfluorescent; –, absent; +, present.



30 seconds of ICG dye injection, the intrinsic tumor vascular pattern is visualized. There is a rapid progression of hyperfluorescence, which peaks around 3–4 minutes (Fig. 49.4E). In the late phase of the ICG angiogram, a ‘washout’ effect with a reduction in the initial hyperfluorescence is observed due to egress of dye from the hemangioma (Fig. 49.4F). Optical coherence tomography can also be used to evaluate secondary retinal morphologic changes, such as shallow subretinal fluid or cystoid macular edema.

**Treatment** The decision to treat a circumscribed choroidal hemangioma should be individualized based on the extent of symptoms, loss of vision, and the potential for visual recovery. The aim of treatment is to induce sufficient tumor atrophy with resolution of subretinal fluid and tumor-induced foveal distortion without destroying the function of the overlying retina. Some asymptomatic cases can be observed. In cases where treatment is deemed necessary several options exist. Laser photocoagulation,<sup>16</sup> cryotherapy, radiotherapy, transpupillary thermotherapy,<sup>18</sup> and more recently photodynamic therapy with verteporfin (Visudyne, Novartis Ophthalmics, Basel, Switzerland),<sup>19</sup> have been reported to be efficacious.

**Observation** Asymptomatic circumscribed choroidal hemangiomas that are in an extramacular location and do not have surrounding subretinal fluid can be kept under observation.<sup>20</sup> In addition, subfoveal hemangiomas with long-standing cystoid macular edema may also be observed, because of the limited potential for visual recovery.<sup>20</sup>

**Laser photocoagulation** does not induce significant tumor regression but is able to induce the resolution of subretinal fluid (Table 49.2).<sup>2,5</sup> However, the recurrence of subretinal fluid necessitates additional treatment in up to 40% of cases.<sup>16</sup> The damage to the over-

lying retina can be minimized by using a diode laser because of a deeper penetration by the infrared wavelength.<sup>21</sup>

**Thermotherapy** In order to avoid the limitations of laser photocoagulation and complications of radiotherapy, transpupillary thermotherapy (TTT) has been used to treat choroidal hemangioma<sup>18</sup> Complete or partial regression of the hemangioma in more than 90% of cases, with a corresponding improvement of vision in the majority, can be expected.<sup>18</sup> However, visually significant complications such as cystoid macular edema,<sup>18</sup> preretinal fibrosis,<sup>18</sup> and retinal vascular occlusion can occur.<sup>22</sup> Therefore, TTT may not be suited for hemangioma located in the subfoveal or juxtapapillary regions.<sup>18</sup>

**Radiation treatment** for a circumscribed choroidal hemangioma can be delivered in several ways. In addition to lens-sparing external beam radiotherapy,<sup>23</sup> stereotactic radiotherapy,<sup>24</sup> plaque radiotherapy (cobalt-60, iodine-125, palladium-103),<sup>2,7</sup> and proton beam radiotherapy have been reported (Table 49.3).<sup>4,25</sup> In general, the total dosage used is about 20 Gy, given in 10 fractions for external beam radiotherapy, 25–50 Gy for plaque radiotherapy, and 16.4–20.0 Gy in four fractions for proton beam radiotherapy. Resolution of exudative retinal detachment, tumor regression, and an improvement of vision in the majority of cases treated by radiation therapy have been reported. The potential for radiation-related complications such as cataract, radiation optic neuropathy, and radiation retinopathy exists,<sup>26</sup> particularly for hemangioma in the juxtapapillary and macular regions. Stereotactic techniques, with improved precision, may be superior to other methods of radiation.<sup>24</sup> The technique of gamma knife radiosurgery has the advantage of delivering the total radiation dose in a single session.<sup>10</sup>

**Table 49.3 Photocoagulation treatment of circumscribed choroidal hemangioma<sup>2</sup>**

Light source	Author	Year	Cases	Outcome
Xenon	Shields	2001	10	Improved/stable vision (40%)
Argon	Duquesne	2002	17	Resolution of exudative RD (82%) Improved vision Recurrence (24%)
	Sun	1993	8	Resolution of exudative RD (100%) Tumor regression (100%) Improved vision
	Madreperla	1997	13	Resolution of exudative RD (46%) Improved/stable vision (31%)
	Shields Scott	2001 2004	86 23	Improved/stable vision (71%) Improved/stable vision (87%)
Krypton	Boucher	2000	2	Resolution of exudative RD (43%) Resolution of exudative RD (100%) Tumor regression (100%) Improved vision
Diode	Lanzetta	1995	2	Resolution of exudative RD (100%) Tumor regression (100%)

RD, retinal detachment.

**Photodynamic therapy** with verteporfin offers site-specific choroidal tumor destruction while sparing the overlying retina (Table 49.4).<sup>2,27</sup> Moreover, the procedure is performed in the office under topical anesthesia.

Verteporfin has a proven safety record from its use in the treatment of choroidal neovascularization. However, treatment variables, including the rapidity of verteporfin injection (bolus versus over 10 minutes as performed in the TAP study),<sup>28</sup> number of treatment sessions (1–5), laser power settings (50–100J/cm<sup>2</sup>), duration of exposure (83–186 s), and number of spots (one or more) have varied between investigators (Table 49.5). In general, tumor regression is

most dramatic following the first session of photodynamic therapy,<sup>29</sup> and is evident within 3 months (Fig. 49.5).<sup>30</sup> Additional photodynamic therapy may be considered after 3 months if the tumor or subretinal fluid persists,<sup>31</sup> however, increasing the number of treatment sessions may adversely affect the final visual acuity.<sup>32</sup>

Overall, photodynamic therapy is safe and effective with minimal complications. Nevertheless, delayed choroidal atrophy, perhaps due to over-treatment, may occur.<sup>19,29</sup> This can be minimized by avoiding treatment of the surrounding normal choroid,<sup>29</sup> and avoiding re-exposure to the previously treated portions of the tumor<sup>29,31</sup> by using

**Table 49.4 Radiation treatment of circumscribed choroidal hemangioma<sup>2</sup>**

Treatment	Technique/dose/fractions	Author	Year	Cases	Outcome
External beam radiotherapy	Lens sparing/20–24 Gy	Schilling	1997	36	Resolution of exudative RD (64%) Tumor stable Improved/stable vision (78%)
	Lens sparing/20–24 Gy	Ritland	2001	8	Resolution of exudative RD Tumor regression Improved vision
Stereotactic radiotherapy	20 Gy/10 fractions	Kivelä	2003	5	Resolution of exudative RD Tumor regression Improved vision
Proton beam radiotherapy	30 CGE 4 fractions	Hannouce	1997	13	Resolution of exudative RD Tumor regression Improved vision 8 eyes (62%)
	19.8 CGE 4 fractions	Lee	1998	3	Resolution of exudative RD (67%) Tumor regression Improved vision (34%) Radiation complications (67%)
	16.4–27.3 Gy (protons) 4 fractions	Zografos	1998	48	Resolution of exudative RD Tumor regression/improved vision Radiation complications (6%)
	20 CGE 4 fractions	Frau	2004	17	Resolution of exudative RD (100%) Tumor regression (100%) Improved vision (94%) Radiation complications (0%)
Gamma knife radiosurgery	18.4 Gy 1 fraction	Nam	2005	1	Resolution of exudative RD Tumor regression Improved vision
Plaque radiotherapy*	Cobalt-60	Zografos	1996	39	Resolution of exudative RD Tumor regression Improved vision Radiation complications (8%)
	Iodine-125 Ruthenium-106	Madreperla	1997	8	Resolution of exudative RD Tumor regression, Improved vision
	Iodine 125	Shields	2001	10	Improved/ stable vision (80%)
	Palladium 103	Aizman	2004	5	Resolution of exudative RD (100%) Tumor regression (100%) Improved vision (80%)

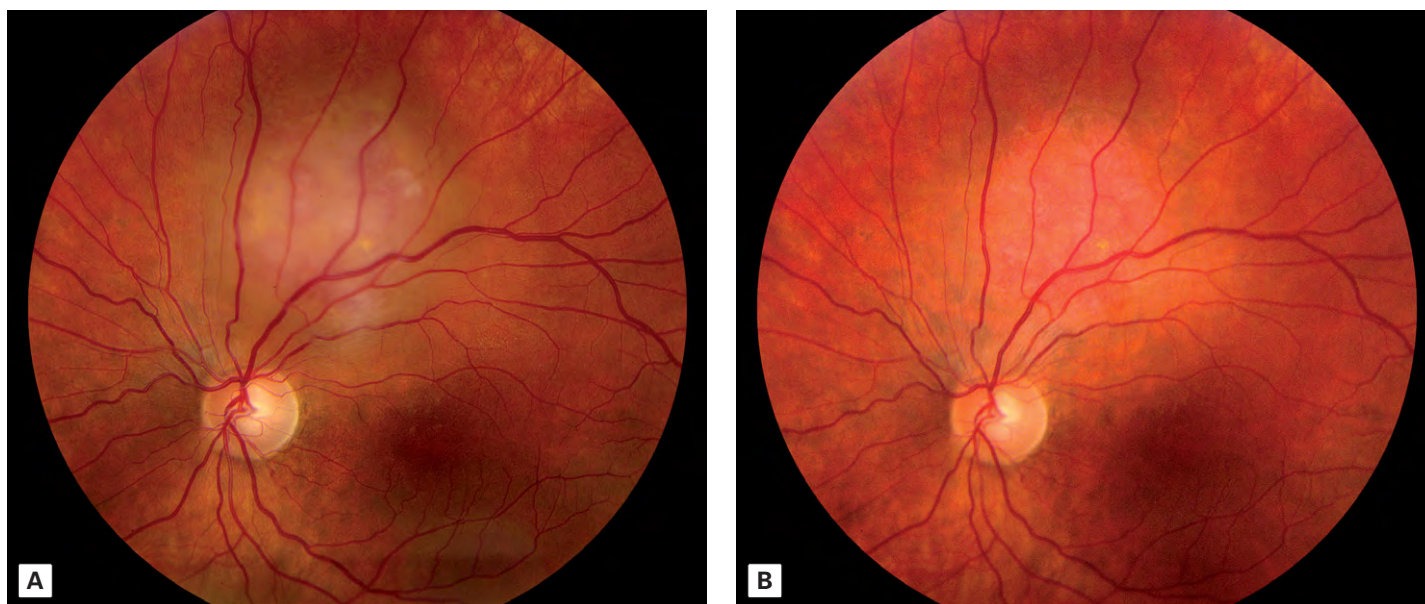
CGE, cobalt Gray equivalent; RD, retinal detachment.  
Only series with more than two cases included.

**Table 49.5** Published reports (excluding single case reports) of photodynamic therapy of circumscribed choroidal hemangioma.<sup>2</sup>

Author	Year	No. of eyes	Method of treatment			Results: Eyes (%)	
			Protocol	Spots	Sessions	Tumor regression	Vision improved or stable
Barbazetto	2000	2	Standard* 100 J/cm <sup>2</sup> 168s	≥1 overlapping	2–4	2 (100%)	2 (100%)
Madreperla	2001	3	Standard*	1	1	3 (100%)	3 (100%)
Landau	2002	8	Standard*	≥1 (?)	1–2	7 (88%)	7 (88%)
Robertson	2002	3	Standard*	≥1 Overlapping	1–2	3 (100%)	3 (100%)
Schmidt-Erfurth	2002	15	Bolus (1 min) 100 J/cm <sup>2</sup> 166s	1	1–4	15 (100%)	15 (100%)
Jurklies	2003	19	Bolus (2 min) 100 J/cm <sup>2</sup> 166s	≥1 non Overlapping	1–5	19 (100%)	18 (95%)
Verbraak	2003	13	Bolus (1 min) 50–100 J/cm <sup>2</sup> 83–166s	1	1–2	13 (100%)	13 (100%)
Porrini	2003	10	Standard* 75–100 J/cm <sup>2</sup> 125–186s	1	1–3	10 (100%)	10 (100%)
Singh	2004	10	Standard*	≥1 Overlapping	1–2	10 (100%)	8 (80%)

\*Laser application 10 minutes after completion of infusion.

Standard, standard PDT treatment as per published guidelines, with intravenous infusion of verteporfin over 10 minutes of 6 mg/m<sup>2</sup> followed by laser application (standard settings: power = 50 J/cm<sup>2</sup>, intensity = 600 mW/cm<sup>2</sup>, duration = 83s) 5 minutes after completion of infusion. (Modified with permission from Singh AD, Kaiser PK, Sears JE et al. Photodynamic therapy of circumscribed choroidal hemangioma. Br J Ophthalmol 2004; 88: 1414–1418)



**Fig. 49.5** Fundus appearance before treatment (A) and 6 weeks after photodynamic therapy with verteporfin showing regression of the hemangioma (B).



either a single spot or multiple non-overlapping spots.<sup>19</sup> Long-term observations on treated patients with follow-up of 5 years or more indicates the continued safety and efficacy of photodynamic therapy for circumscribed choroidal hemangioma.<sup>33,34</sup>

**Prognosis** Visual acuity may be compromised because of the presence of chronic subretinal fluid and cystoid macular edema. Moreover, treatment side effects may reduce vision, particularly if the hemangioma is located in the macula or in the papillomacular bundle. Hence the long-term visual prognosis is poor even in adequately treated patients.<sup>20</sup> With the increasing use of photodynamic therapy, it may be possible to achieve better long-term visual results.<sup>33,34</sup>

### DIFFUSE CHOROIDAL HEMANGIOMA

About half of patients with Sturge–Weber syndrome have a diffuse choroidal hemangioma.<sup>35</sup> It is usually unilateral and ipsilateral to the nevus flammeus, although other clinical variants have been reported.<sup>36</sup> Sturge–Weber syndrome is discussed in detail elsewhere (see Chapter 63).

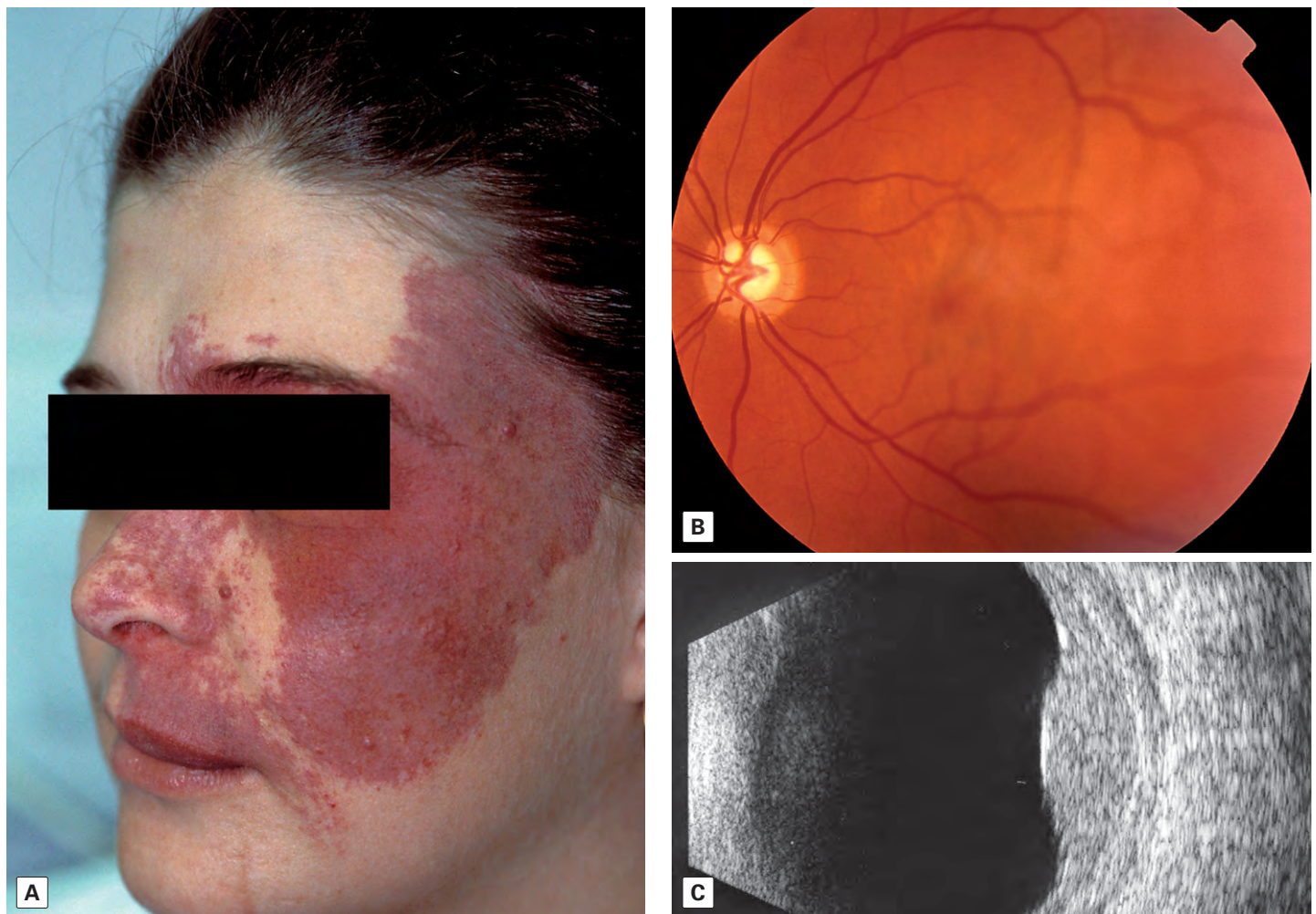
### Clinical features

**Symptoms** Diffuse choroidal hemangioma can lead to visual loss due to refractive errors, foveal distortion, and exudative retinal detachment.<sup>16</sup> Despite being present since birth, choroidal hemangioma may not cause exudative retinal detachment until adolescence.

**Signs** Choroidal hemangioma appears as an orange, diffuse choroidal thickening. The localized areas of excessive thickening simulating a circumscribed choroidal hemangioma may be seen within the diffuse hemangioma.<sup>37</sup> Associated exudative retinal detachment may also be present (Fig. 49.6A, B).

**Diagnostic evaluation** Ultrasonographic evaluation is most helpful as it shows diffuse thickening of the choroid (Fig. 49.6C).

**Differential diagnosis** In the setting of typical cutaneous and leptomeningeal angiomatosis the diagnosis of a diffuse choroidal hemangioma is evident.



**Fig. 49.6** External photograph showing hemangioma distribution typical of Sturge–Weber syndrome (A). Fundus photograph showing diffuse choroidal thickening with shallow subretinal fluid (B). Note glaucomatous cupping of the optic disc. B-scan ultrasonograph demonstrating a dome-shaped choroidal mass that blends with diffusely thickened choroid (C).

**Table 49.6 Treatment methods of diffuse choroidal hemangioma<sup>2</sup>**

Treatment	Technique/dose	Author	Year	Cases	Outcome
Radiotherapy	Lens sparing/* 12.5–20 Gy	Scott	1991	4	Resolution of exudative RD Focal cataract
	Lens sparing/20 Gy	Schilling	1997	15	Resolution of exudative RD Tumor regression in 5 cases Improved vision in 7 eyes
	Lens sparing/12–40 Gy	Madreperla	1997	5	Resolution of exudative RD Improved/stable vision in all cases
	Not stated/20 Gy	Gottlieb	1998	1	Resolution of exudative RD Tumor regression Improved vision
	Lens sparing/20–25 Gy	Ritland	2001	1	Resolution of exudative RD Tumor regression Improved vision
Proton beam radiotherapy	16.4–18.2 Gy 4 fractions	Zografos	1998	6	Resolution of exudative RD Tumor regression
Photodynamic therapy	Multispot	Anand	2003	1	Tumor regression Stable vision
	Multispot	Singh	2004	1	Resolution of exudative RD Tumor regression Improved vision
	Multispot	Bains	2004	1	Resolution of exudative RD Tumor regression Improved vision

RD, retinal detachment.

\*Lens-sparing technique used in only four eyes.

**Treatment** The decision to treat a diffuse choroidal hemangioma should be individualized based on the extent of symptoms, visual loss, and any potential for visual recovery.

**Observation** The aim of any treatment is to induce tumor atrophy, resolution of subretinal fluid, and minimize tumor-induced foveal distortion. Therefore, in asymptomatic cases, especially in the absence of an exudative retinal detachment, the hemangioma can be safely observed.

**Radiotherapy** Tumor regression and resolution of subretinal fluid can be induced with low-dose radiotherapy or proton beam irradiation (Table 49.6).<sup>2,25</sup> Schilling and associates<sup>23</sup> reported their results in 15 eyes treated by lens-sparing radiation (20 Gy, 10 fractions) with a mean follow-up of more than 5 years. Complete resolution of exudative retinal detachment in all cases, tumor regression in five cases, and improved vision in seven eyes was observed.

**Photodynamic therapy** for the treatment of diffuse choroidal hemangiomas has also been reported, with good short-term

results.<sup>38–40</sup> Compared to various forms of radiotherapy, photodynamic therapy has the advantage of avoiding radiation, ease of delivery, and minimal side effects. Long-term observations on a large number of treated patients are necessary to fully evaluate the efficacy of photodynamic therapy.

**Prognosis** Sturge–Weber syndrome, with its neural involvement, leads to seizures that can be intractable and is associated with developmental delay and behavioral problems. Ocular manifestations, including congenital glaucoma, generally require multiple surgical procedures. A diffuse choroidal hemangioma is usually associated with variable degree of visual loss from exudative retinal detachment.

#### ACKNOWLEDGEMENT

This chapter was modified in part with permission from Singh AD, Kaiser PK, Sears JE. Choroidal hemangioma. *Ophthalmol Clin North Am* 2005; 18: 151–161.

#### REFERENCES

1. Witschel H, Font RL. Hemangioma of the choroid. A clinicopathologic study of 71 cases and a review of the literature. *Surv Ophthalmol* 1976; 20: 415–431.
2. Singh AD, Kaiser PK, Sears JE. Choroidal hemangioma. *Ophthalmol Clin North Am* 2005; 18: 151–161.
3. Ferry AP. Hemangiomas of the iris and ciliary body. Do they exist? A search for a histologically proved case. *Int Ophthalmol Clin* 1972; 12: 177–194.
4. Frau E, Rumen F, Noel G et al. Low-dose proton beam therapy for circumscribed choroidal hemangiomas. *Arch Ophthalmol* 2004; 122: 1471–1475.

5. Scott IU, Gorskak J, Gass JD et al. Anatomic and visual acuity outcomes following thermal laser photocoagulation or photodynamic therapy for symptomatic circumscribed choroidal hemangioma with associated serous retinal detachment. *Ophthalm Surg Lasers Imag* 2004; 35: 281–291.
6. Naidoff MA, Kenyon KR, Green WR. Iris hemangioma and abnormal retinal vasculature in a case of diffuse congenital hemangiomatosis. *Am J Ophthalmol* 1971; 72: 633–644.
7. Aizman A, Finger PT, Shabto U et al. Palladium 103 (103Pd) plaque radiation therapy for circumscribed choroidal hemangioma with retinal detachment. *Arch Ophthalmol* 2004; 122: 1652–1656.
8. Haik BG, Clancy P, Ellsworth RM et al. Ocular manifestations in diffuse neonatal hemangiomatosis. *J Pediatr Ophthalmol Strabismus* 1983; 20: 101–105.
9. Chang CW, Rao NA, Stout JT. Histopathology of the eye in diffuse neonatal hemangiomatosis. *Am J Ophthalmol* 1998; 125: 868–870.
10. Nam TK, Lee JI, Kang SW. Gamma knife radiosurgery for circumscribed choroidal hemangioma. *Acta Neurochir (Wien)* 2005; 147: 651–654.
11. Woo SJ, Kim CJ, Yu YS. Cavernal hemangioma of the iris in an infant. *J Aapos* 2004; 8: 499–501.
12. Giessler S, Tost F, Duncker GI. Vascular convolute of the iris. Cavernal iris hemangioma. *Ophthalmologie* 1999; 96: 752–753.
13. Larson SA, Oetting TA. Presumed iris hemangioma associated with multiple central nervous system cavernous hemangiomas. *Arch Ophthalmol* 2002; 120: 984–985.
14. Isola VM. Hemangioma of the ciliary body: a case report and review of the literature. *Ophthalmologica* 1996; 210: 239–243.
15. Weiss MJ, Ernest JT. Diffuse congenital hemangiomatosis with infantile glaucoma. *Am J Ophthalmol* 1976; 81: 216–218.
16. Anand R, Augsburger JJ, Shields JA. Circumscribed choroidal hemangiomas. *Arch Ophthalmol* 1989; 107: 1338–1342.
17. Arevalo JF, Shields CL, Shields JA et al. Circumscribed choroidal hemangioma: characteristic features with indocyanine green videoangiography. *Ophthalmology* 2000; 107: 344–350.
18. Gunduz K. Transpupillary thermotherapy in the management of circumscribed choroidal hemangioma. *Surv Ophthalmol* 2004; 49: 316–327.
19. Singh AD, Kaiser PK, Sears JE et al. Photodynamic therapy of circumscribed choroidal haemangioma. *Br J Ophthalmol* 2004; 88: 1414–1418.
20. Shields CL, Honavar SG, Shields JA et al. Circumscribed choroidal hemangioma: clinical manifestations and factors predictive of visual outcome in 200 consecutive cases. *Ophthalmology* 2001; 108: 2237–2248.
21. Lanzetta P, Virgili G, Ferrari E, Menchini U. Diode laser photocoagulation of choroidal hemangioma. *Int Ophthalmol* 1995; 19: 239–247.
22. Kamal A, Watts AR, Rennie IG. Indocyanine green enhanced transpupillary thermotherapy of circumscribed choroidal hemangioma. *Eye* 2000; 14: 701–705.
23. Schilling H, Sauerwein W, Lommatzsch A. Long term results after low dose ocular irradiation for choroidal hemangioma. *Br J Ophthalmol* 1997; 81: 267–273.
24. Kivelä T, Tenhunen M, Joensuu T et al. Stereotactic radiotherapy of symptomatic circumscribed choroidal hemangiomas. *Ophthalmology* 2003; 110: 1977–1982.
25. Zografos L, Egger E, Bercher L et al. Proton beam irradiation of choroidal hemangiomas. *Am J Ophthalmol* 1998; 126: 261–268.
26. Zografos L, Bercher L, Chamot L et al. Cobalt-60 treatment of choroidal hemangiomas. *Am J Ophthalmol* 1996; 121: 190–199.
27. Schmidt-Erfurth U, Hassan T. Mechanism of action of photodynamic therapy with verteporfin for the treatment of age-related macular degeneration. *Surv Ophthalmol* 2000; 45: 195–213.
28. TAP Study Group. Photodynamic therapy of subfoveal choroidal neovascularization in age-related macular degeneration with verteporfin. One year results of 2 randomized clinical trials – TAP report. Treatment of age related macular degeneration with photodynamic therapy (TAP) Study Group. *Arch Ophthalmol* 1999; 117: 1329–1345.
29. Schmidt-Erfurth UM, Michels S, Kusserow C et al. Photodynamic therapy for symptomatic choroidal hemangioma: visual and anatomic results. *Ophthalmology* 2002; 109: 2284–2294.
30. Madreperla SA. Choroidal hemangioma treated with photodynamic therapy using verteporfin. *Arch Ophthalmol* 2001; 119: 1606–1610.
31. Porrini G, Giovannini A, Amato G et al. Photodynamic therapy of circumscribed choroidal hemangioma. *Ophthalmology* 2003; 110: 674–680.
32. Jurkles B, Anastassiou G, Ortmans S et al. Photodynamic therapy using verteporfin in circumscribed choroidal haemangioma. *Br J Ophthalmol* 2003; 87: 84–89.
33. Michels S, Michels R, Beckendorf A, Schmidt-Erfurth U. Photodynamic therapy for choroidal hemangioma. Long-term results. *Ophthalmologie* 2004; 101: 569–575.
34. Jurkles B, Bornfeld N. The role of photodynamic therapy in the treatment of symptomatic choroidal hemangioma. *Graefes Arch Clin Exp Ophthalmol* 2005; 243: 393–396.
35. Sullivan TJ, Clarke MP, Morin JD. The ocular manifestations of the Sturge–Weber syndrome. *J Pediatr Ophthalmol Strab* 1992; 29: 349–356.
36. Amirikia A, Scott IU, Murray TG. Bilateral diffuse choroidal hemangiomas with unilateral facial nevus flammeus in Sturge–Weber syndrome. *Am J Ophthalmol* 2000; 130: 362–364.
37. Scott IU, Alexandrakis G, Cordahi GJ, Murray TG. Diffuse and circumscribed choroidal hemangiomas in a patient with Sturge–Weber syndrome. *Arch Ophthalmol* 1999; 117: 406–407.
38. Anand R. Photodynamic therapy for diffuse choroidal hemangioma associated with Sturge–Weber syndrome. *Am J Ophthalmol* 2003; 136: 758–760.
39. Singh AD, Rundle PA, Vardy SJ, Rennie IG. Photodynamic therapy of choroidal hemangioma associated with Sturge–Weber syndrome. *Eye* 2004; 19: 365–367.
40. Bains HS, Cirino AC, Ticho BH, Jampol LM. Photodynamic therapy using verteporfin for a diffuse choroidal hemangioma in Sturge–Weber syndrome. *Retina* 2004; 24: 152–155.



# Uveal neural tumors

Arun D. Singh and Jonathan E. Sears

## INTRODUCTION

Neurofibroma and schwannoma (neurilemmoma) are two types of neural tumor having distinct clinical and histopathologic features. Neurofibroma is a benign tumor composed of Schwann cells, axons, and endoneurial fibroblasts. Schwannoma consists purely of a proliferation of Schwann cells (Table 50.1).<sup>1</sup> These tumors can occur sporadically or in association with neurofibromatosis type 1 or other genetic syndromes. In this chapter we review the spectrum of neural tumors of the uvea, emphasizing various uveal manifestations of neurofibromatosis type 1 (NF1).

## UVEAL NEUROFIBROMA

Neurofibromatosis type 1 can affect the uvea in several ways. Almost all patients develop Lisch nodules, which are melanocytic hamartomas of the iris, albeit not strictly neural in origin. Another abnormality that is almost universal is the presence of choroidal bright spots, which are believed to correspond to histologically observed ovoid bodies.<sup>2</sup> The spots are more frequent in the posterior pole and increase with age.<sup>3</sup> The choroidal spots are not seen on standard ophthalmoscopy or fluorescein angiography, but are visible with infrared scanning laser ophthalmoscopy (Fig. 50.1A) and appear as focal areas of choroidal hypofluorescence on indocyanine green angiography (Fig. 50.1B).<sup>2</sup> The relationship between choroidal bright spots and choroidal hamartoma also remains to be elucidated.<sup>4</sup>

Choroidal neurofibromas (solitary or diffuse)<sup>5-8</sup> and ganglioneuromas<sup>9</sup> are extremely unusual ophthalmic manifestations of NF1. Although, an association between NF1 and uveal melanoma has been reported,<sup>10</sup> such cases may represent a coincidental occurrence rather than a true association.<sup>11</sup>

**Etiology** The solitary type of neurofibroma is sporadic and not associated with NF1, whereas diffuse neurofibroma usually occurs in the setting of NF1.

**Pathology** The diffuse uveal neurofibroma causes irregular thickening of the choroid and ciliary body with relative sparing of the iris. The tumor is composed of bundles of Schwann cells, axons, ganglion cells, and fibroblasts (Fig. 50.2A).<sup>5,7</sup> Numerous melanocytes are also present.<sup>12</sup>

**Light microscopy** The neurofibroma is composed of spindle cells with small oval nuclei. Certain areas of the tumor demonstrate a peculiar onion-like lamellar arrangement of cells called ovoid bodies (Fig.

50.2B).<sup>5,12</sup> In one case, the predominance of ganglion cells within the tumor led to the diagnosis of ganglioneuroma.<sup>9</sup>

**Immunohistochemistry** Neurofibroma stains positively with the S-100 stain, similar to schwannoma (Table 50.2). The anti-neurofilament antibody stain demonstrates axons in neurofibroma but is negative in schwannoma.<sup>13</sup>

**Electron microscopy** of an ovoid body reveals a group of elongated cells arranged in a lamellar pattern.<sup>14</sup> These findings suggest that ovoid bodies represent thickened peripheral nerves from neoplastic proliferation of the Schwann cells around axons, rather than a sensory end organ.<sup>12,14</sup>

**Clinical features** A solitary uveal neurofibroma appears as a circumscribed amelanotic choroidal tumor.<sup>6</sup> Diffuse uveal neurofibroma can be associated with congenital glaucoma presenting as a classic triad of unilateral buphthalmos, homolateral eyelid plexiform neurofibroma, and homolateral facial hypertrophy (François syndrome) (Fig. 50.2C).<sup>7,8,15</sup> NF1 should be excluded in all such cases as not all the diagnostic features may be apparent on initial ophthalmic evaluation.<sup>8</sup>

There are only a few well documented case reports describing the fundus appearances of uveal neurofibroma<sup>16,17</sup> because the diagnosis is usually based on histopathology of the enucleated globe.<sup>5,7,8</sup> The uveal neurofibroma appears on ophthalmoscopy as multiple, pale-yellow nodular choroidal lesions or an ill defined choroidal thickening.<sup>16,17</sup>

**Diagnostic evaluation** The angiographic and ultrasonographic findings are non-specific and therefore not helpful in establishing the diagnosis of uveal neurofibroma. The presence of systemic signs of NF1 support the diagnosis of uveal neurofibroma.

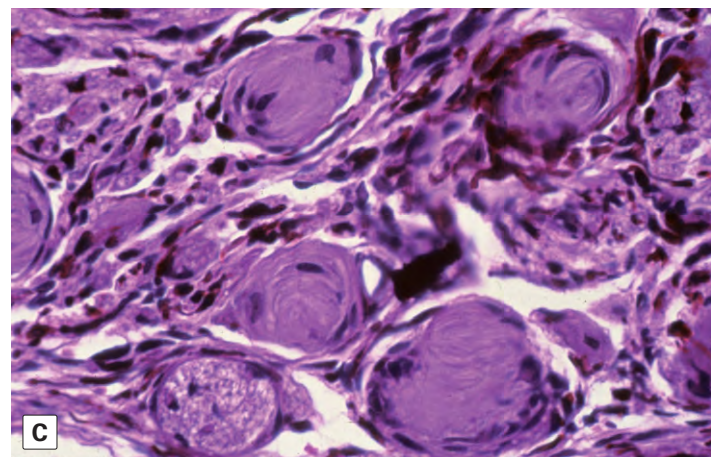
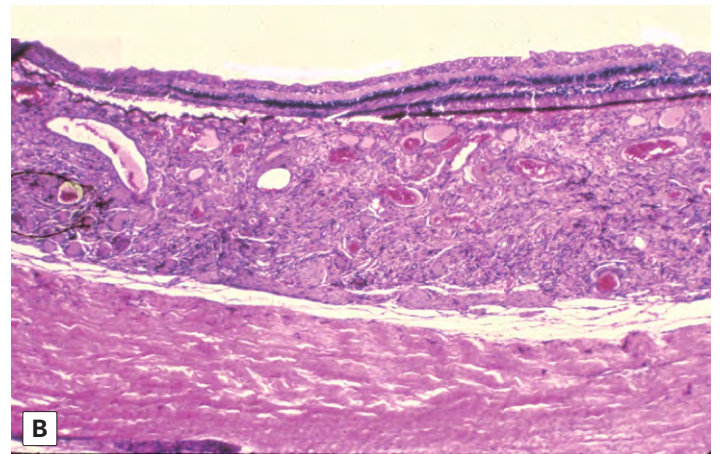
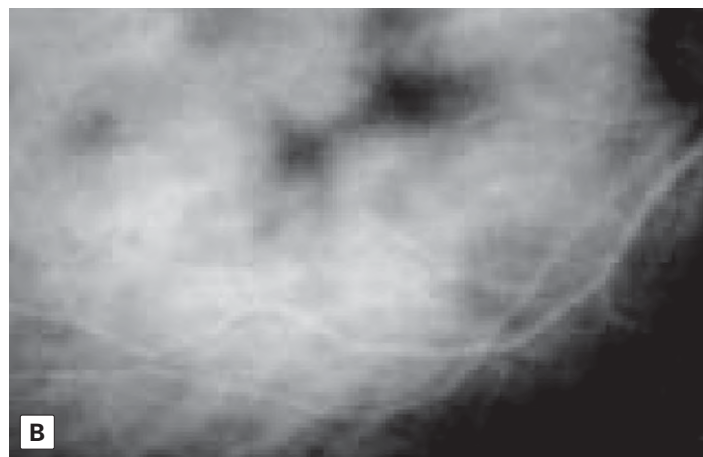
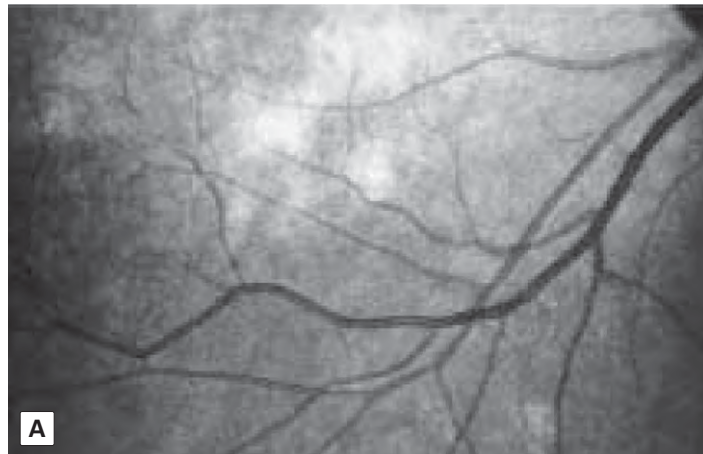
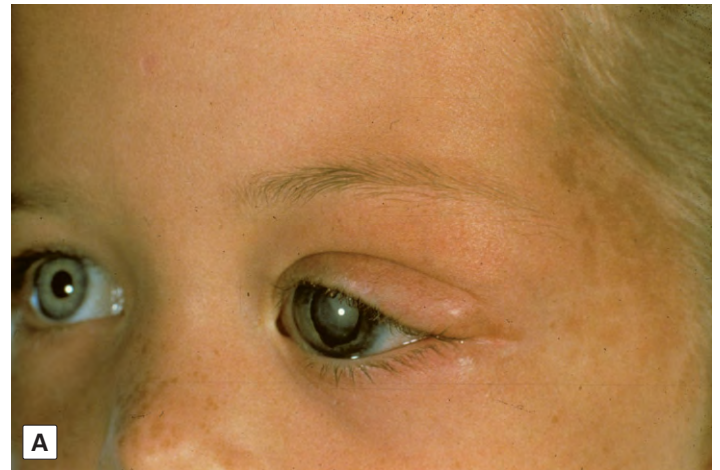**Differential diagnosis** Clinical differentiation from uveal metastases, uveal lymphoma, and amelanotic uveal melanoma is not always feasible. Uveal neurofibroma should always be included in the differential diagnosis of multifocal amelanotic choroidal tumor. Histopathologically, other spindle cell tumors such as schwannoma, leiomyoma, and fibrous histiocytoma should also be considered.

**Treatment** There is no effective treatment for uveal neurofibroma. For smaller tumors that are asymptomatic only observation is

**Table 50.1 Clinical differentiating features of schwannoma and neurofibroma**

Feature	Schwannoma	Neurofibroma
Location	Head and neck	Cutaneous nerves
Encapsulation	Present	Absent
Composition	Schwann cells	Schwann cells, axons, endoneurial fibroblasts
Growth pattern	Usually localized, plexiform (uncommon)	Localized, diffuse, plexiform
Association	Sporadic, NF2, NF1 (rare)	Sporadic, NF1
Malignant transformation	Rare	About 2% of NF1

(Modified from Weiss SW, Goldblum JR (eds) Enzinger and Weiss's Soft tissue tumors, 4th edn. St Louis, Mosby, 2003)



**Fig. 50.1** Fundus photograph taken with a confocal infrared scanning laser ophthalmoscope showing several bright patchy spots around the posterior pole (A). The bright spots appear as focal areas of choroidal hypofluorescence on the indocyanine angiography (B). (Reproduced with permission from Yasunari T, Shiraki K, Hattori H, Miki T. Frequency of choroidal abnormalities in neurofibromatosis type 1. *Lancet* 2000; 356: 988–992.)

**Fig. 50.2** Left eyelid neurofibroma, café au lait spot and buphthalmic globe (A). The choroid is thickened by diffuse neurofibroma (B). (Hematoxylin & eosin  $\times 100$ .) Ovoid bodies in choroidal neurofibroma (C). (Hematoxylin & eosin  $\times 400$ .) (Reproduced with permission from Brownstein S, Little JM. Ocular neurofibromatosis. *Ophthalmology* 1983; 90: 1595–1599.)

**Table 50.2 Immunohistochemical profile of tumors in the differential diagnosis of uveal schwannoma (spindle cell tumor). The immunoreactivity is expressed as a percentage of positive tumors**

Stain	Schwannoma (%)	Neurofibroma (%)	Leiomyoma (%)	Fibrous histiocytoma (%)	Melanoma (%)
S-100	100	88	80	3	97
HMB-45	10	28	5	0	86
Melan-A	0	45	0	0	86
Anti-neurofilament protein antibody	15	35	0	0	0
Desmin	0	0	80	8	1
Muscle-specific actin	0	5	93	50	10
Vimentin	100	100	88	99	96

(Data obtained from www.immunoquery.com)

recommended. The majority of cases eventually require enucleation because of progressive growth of the tumor or as a result of complications from buphthalmos.

**Prognosis** The ocular prognosis is guarded. Association with buphthalmos eventually leads to significant loss of vision.

### UVEAL SCHWANNOMA

Schwannoma is a slow-growing, benign tumor which tends to involve the head, neck, and extremities.<sup>1</sup> The spinal nerve roots, sympathetic, cervical, and vagus nerves are most commonly affected. Schwannoma can rarely arise from ciliary nerves within the uvea<sup>18</sup> or sclera,<sup>19</sup> presenting as an intraocular tumor. The terms neurilemmoma and neurinoma are synonyms but are not preferred because they do not identify the cell of origin.

**Etiology** Schwannoma usually occurs in isolation, only 10% of cases being associated with a multisystem disorder such as neurofibromatosis,<sup>18,20–22</sup> schwannomatosis,<sup>23</sup> multiple meningiomas,<sup>24</sup> and Carney's complex.<sup>24,25</sup>

**Pathology** The clinicopathologic variants include schwannoma with degenerative change (i.e. 'ancient schwannoma'), cellular schwannoma, plexiform schwannoma, epithelioid schwannoma, and melanotic schwannoma.<sup>26</sup> The majority of uveal schwannomas resemble those elsewhere in the body,<sup>13</sup> with single cases of melanotic<sup>27</sup> and plexiform schwannoma reported (Fig. 50.3A,B).<sup>28</sup>

**Light microscopy** The tumor is composed of spindle cells with bland nuclei and abundant eosinophilic cytoplasm. Certain areas demonstrate palisading (Antoni A pattern), whereas others may be myxoid (Antoni B pattern) (Fig. 50.3C). So-called Verocay bodies may develop, which consist of palisaded cells in which cytoplasmic processes are bordered on each side by clusters of nuclei.

**Immunohistochemistry** Schwannoma stains positively with the S-100 stain, in a similar fashion to neurofibroma and uveal melanoma.

The anti-neurofilament antibody stain demonstrates axons in neurofibroma but is negative in schwannoma and melanoma. Both neurofibroma and schwannoma are HMB45 negative, whereas uveal melanoma is usually positive (Table 50.2).<sup>13,29</sup>

**Electron microscopy** reveals spindle cells with interdigitating long, tapering processes of Schwann cells.<sup>28,29</sup> The presence of long-spaced collagen (Luse bodies) helps confirm the diagnosis of schwannoma (Fig. 50.3D).<sup>30</sup>

**Clinical features** A review of the clinical findings of a uveal schwannoma, based on features of about 20 published cases, reveals that they can arise in the ciliary body, the choroid, or diffusely in the whole uvea.<sup>13,28</sup> Typically, uveal schwannoma presents as a solitary amelanotic tumor,<sup>13</sup> but multifocal uveal involvement due to plexiform schwannoma has rarely been described.<sup>28</sup>

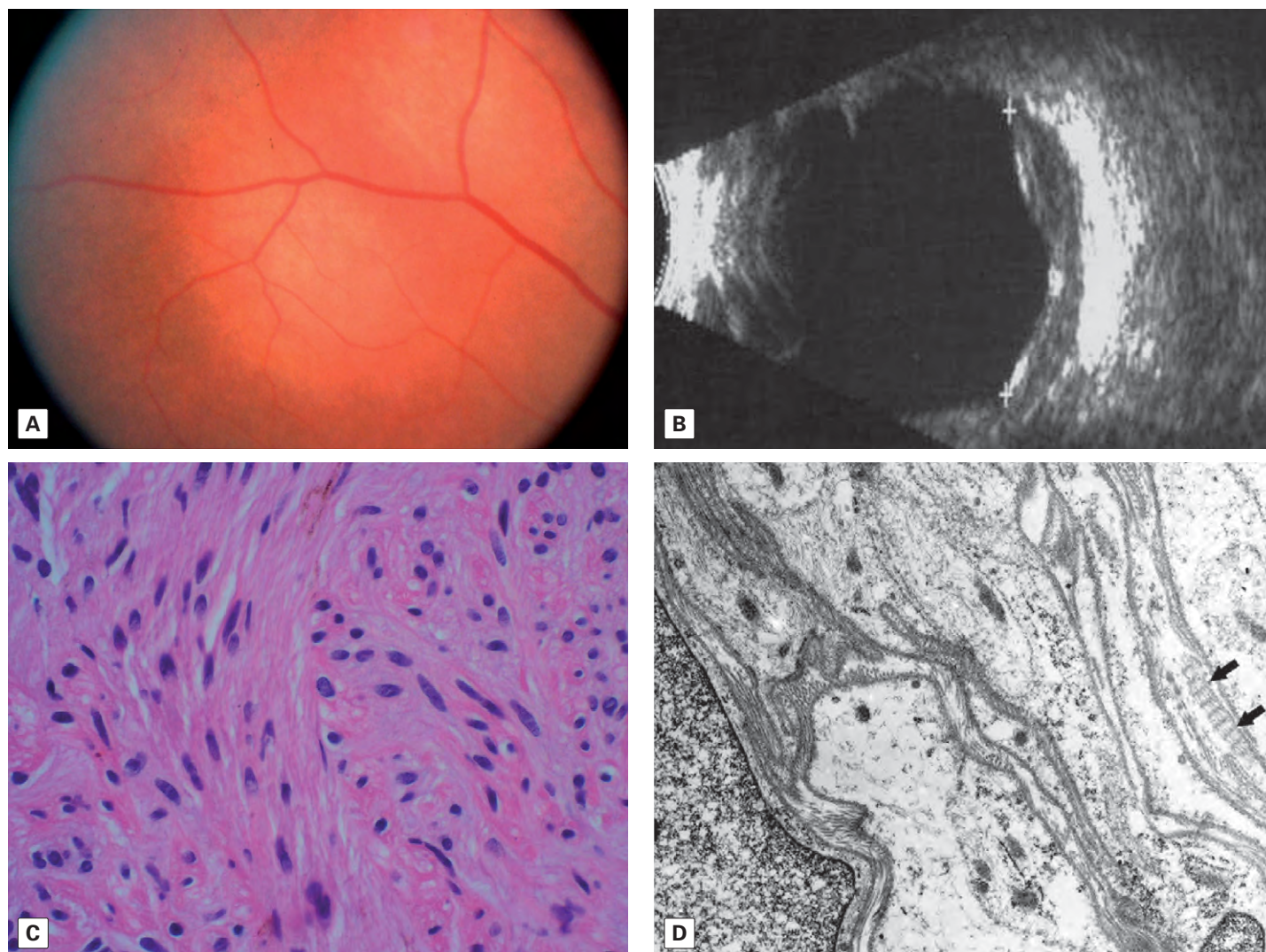
**Diagnostic evaluation** The ophthalmoscopic, angiographic, and ultrasonographic findings are not helpful in differentiating uveal schwannoma from melanoma.<sup>13</sup>

**Differential diagnosis** Differentiation from uveal melanoma and metastasis is not always feasible clinically.<sup>31</sup> However, uveal neural tumors should always be considered in the differential diagnosis of all amelanotic choroidal tumors. Histopathologically, other spindle cell tumors, such as neurofibroma, leiomyoma, and fibrous histiocytoma, should be considered.

**Treatment** For smaller tumors located anteriorly, resection may be feasible.<sup>32</sup> However, most cases are enucleated because they are mistaken for melanoma.

**Prognosis** The ocular prognosis is guarded. The tumors can show progressive growth,<sup>6</sup> with some cases reported to fill the entire globe.<sup>33</sup> As uveal schwannoma is a benign tumor there is no risk of metastasis.<sup>6</sup>





**Fig. 50.3** A 9-year-old white girl with iris and choroidal masses in her left eye. There was hyperpigmentation of the nasal iris and irregularity of the pupillary margin, with nasal pupillary margin cysts. Fundus photograph showing two raised amelanotic choroidal nodules in the superonasal quadrant (A). There is multifocal thickening of the choroid in the corresponding areas on B-scan ultrasonography (B). Photomicrograph of the iridectomy specimen reveals spindle-shaped cells with abundant eosinophilic cytoplasm and bland nuclei tending to palisade (C). (Hematoxylin & eosin  $\times 250$ .) Electron photomicrograph microscopy shows spindle cells with long-spaced collagen (Luse bodies, arrows) (D). (Reproduced with permission from Saavedra E, Singh AD, Sears JE, Ratliff NB. Plexiform pigmented schwannoma of the uvea. *Surv Ophthalmol* 2006; (in press).)

## REFERENCES

- Weiss SW, Goldblum JR (eds) *Enzinger and Weiss's Soft tissue tumors*, 4th edn. St Louis, Mosby, 2003.
- Yasunari T, Shiraki K, Hattori H, Miki T. Frequency of choroidal abnormalities in neurofibromatosis type 1. *Lancet* 2000; 356: 988–992.
- Nakamura S, Shiraki K, Yasunari T et al. Quantification and anatomic distribution of choroidal abnormalities in patients with type I neurofibromatosis. *Graefes Arch Clin Exp Ophthalmol* 2005; 243: 980–984.
- Lewis RA, Riccardi VM. Von Recklinghausen neurofibromatosis. Incidence of iris hamartomata. *Ophthalmology* 1981; 88: 348–354.
- Wolter JR, Gonzales-Sirit R, Mankin WJ. Neurofibromatosis of the choroid. *Am J Ophthalmol* 1962; 54: 217–225.
- Shields JA, Sanborn GE, Kurz GH, Augsburger JJ. Benign peripheral nerve tumor of the choroid: a clinicopathologic correlation and review of the literature. *Ophthalmology* 1981; 88: 1322–1329.
- Brownstein S, Little JM. Ocular neurofibromatosis. *Ophthalmology* 1983; 90: 1595–1599.
- Burke JP, Leitch RJ, Talbot JF, Parsons MA. Choroidal neurofibromatosis with congenital iris ectropion and buphthalmos: relationship and significance. *J Pediatr Ophthalmol Strabismus* 1991; 28: 265–267.
- Woog JJ, Albert DM, Craft J et al. Choroidal ganglioneuroma in neurofibromatosis. *Graefes Arch Clin Exp Ophthalmol* 1983; 220: 25–31.
- Specht CS, Smith TW. Uveal malignant melanoma and von Recklinghausen's neurofibromatosis. *Cancer* 1988; 62: 812–817.
- Honavar SG, Singh AD, Shields CL et al. Iris melanoma in a patient with neurofibromatosis. *Surv Ophthalmol* 2000; 45: 231–236.
- Wolter JR. Nerve fibrils in ovoid bodies. *Arch Ophthalmol* 1965; 73: 696–699.
- Fan JT, Campbell RJ, Robertson DM. A survey of intraocular schwannoma with a case report. *Can J Ophthalmol* 1995; 30: 37–41.
- Kurosawa A, Kurosawa H. Ovoid bodies in choroidal neurofibromatosis. *Arch Ophthalmol* 1982; 100: 1939–1941.
- François J, Katz C. Homolateral association of hydrophthalmia, plexiform neuroma of the upper lid and facial hemihypertrophy in Recklinghausen's disease. *Ophthalmologica* 1961; 142: 549–571.
- Savino PJ, Glaser JS, Luxenberg MN. Pulsating enophthalmos and choroidal hamartomas: two rare stigmata of neurofibromatosis. *Br J Ophthalmol* 1977; 61: 483–488.
- Klein RM, Glassman L. Neurofibromatosis of the choroid. *Am J Ophthalmol* 1985; 99: 367–368.
- François J. Schwannome intraoculaire. *Ann Ocul* 1947; 180: 542–546.
- Quintana M, Lee WR. Intrasccleral schwannoma. *Ophthalmologica* 1976; 173: 64–69.
- Reith JD, Goldblum JR. Multiple cutaneous plexiform schwannomas. Report of a case and review of the literature with particular reference to the association with

- types 1 and 2 neurofibromatosis and schwannomatosis. *Arch Pathol Lab Med* 1996; 120: 399–401.
21. Vannas S, Raitta C, Tarkkanen A. Neurilemmoma of the choroid in Recklinghausen's disease. *Acta Ophthalmol Suppl* 1974; 123: 126–133.
  22. Freedman SF, Elnor VM, Donev I et al. Intraocular neurilemmoma arising from the posterior ciliary nerve in neurofibromatosis. Pathologic findings. *Ophthalmology* 1988; 95: 1559–1564.
  23. MacCollin M, Willett C, Heinrich B et al. Familial schwannomatosis: Exclusion of the NF2 locus as the germline event. *Neurology* 2003; 60: 1968–1974.
  24. Antinheimo J, Sankila R, Carpen O et al. Population-based analysis of sporadic and type 2 neurofibromatosis-associated meningiomas and schwannomas. *Neurology* 2000; 54: 71–76.
  25. Carney JA. The Carney complex (myxomas, spotty pigmentation, endocrine overactivity, and schwannomas). *Dermatol Clin* 1995; 13: 19–26.
  26. Kurtkaya-Yapicier O, Scheithauer B, Woodruff JM. The pathobiologic spectrum of schwannomas. *Histol Histopathol* 2003; 18: 925–934.
  27. Shields JA, Font RL, Eagle RC Jr et al. Melanotic schwannoma of the choroid. Immunohistochemistry and electron microscopic observations. *Ophthalmology* 1994; 101: 843–849.
  28. Saavedra E, Singh AD, Sears JE, Ratliff NB. Plexiform pigmented schwannoma of the uvea. *Surv Ophthalmol* 2006 (in press).
  29. Matsuo T, Notohara K. Choroidal schwannoma: immunohistochemical and electron-microscopic study. *Ophthalmologica* 2000; 214: 156–160.
  30. Luse SA. Electron microscopic studies of brain tumors. *Neurology* 1960; 10: 881–905.
  31. Smith PA, Damato BE, Ko MK, Lyness RW. Anterior uveal neurilemmoma – a rare neoplasm simulating malignant melanoma. *Br J Ophthalmol* 1987; 71: 34–40.
  32. Kuchle M, Holbach L, Schlotzer-Schrehardt U, Naumann GO. Schwannoma of the ciliary body treated by block excision. *Br J Ophthalmol* 1994; 78: 397–400.
  33. Donovan BF. Neurilemmoma of the ciliary body. *AMA Arch Ophthalmol* 1956; 55: 672–675.

# Uveal osseous tumors

Arun D. Singh

## INTRODUCTION

Choroidal osteoma consists of cancellous bone and must be differentiated from calcium deposition (i.e. calcification), which can be dystrophic or metastatic.<sup>1</sup> Dystrophic calcification occurs in dead or degenerated tissues despite normal calcium metabolism. An example of this condition is sclerochoroidal calcification. In contrast, metastatic calcification involves normal tissues and is secondary to hypercalcemia (Table 51.1). In this chapter I review choroidal osteoma and sclerochoroidal calcification, emphasizing their differentiating features.

## CHOROIDAL OSTEOMA

In 1976, Reese<sup>2</sup> published the first case of choroidal osteoma, which was misdiagnosed as an ossifying choroidal hemangioma. The term 'choroidal osteoma' was coined by Gass<sup>3</sup> in 1978, when he described four healthy young women with characteristic ophthalmoscopic findings. Another term for this condition is 'osseous choristoma.'

**Etiology** These tumors are believed to be choristomatous in origin.<sup>3,4</sup> However, a few well-documented cases have occurred in the setting of ocular inflammation.<sup>5</sup> Familial cases with multisibling<sup>6</sup> and multi-generation involvement<sup>7</sup> have been reported, but most cases occur sporadically.<sup>4,8</sup> The role of hormonal and metabolic factors in the causation of choroidal osteoma remains speculative.

**Pathology** Choroidal osteoma is composed of interconnected bony trabeculae with large cavernous vascular spaces.<sup>9</sup> Numerous osteocytes, osteoblasts, and occasional osteoclasts are also present. The overlying retinal pigment epithelium shows areas of focal depigmentation with narrowing or loss of choriocapillaris.

**Clinical features** About 90% of cases are observed in females, presenting at a mean age of 21 years.<sup>10</sup> Rare cases in early childhood<sup>11</sup> and older adults have also been observed.<sup>12</sup> About 75% of cases are unilateral.<sup>10</sup> It is unusual for osteoma to develop in a previously unaffected eye.<sup>13</sup>

**Symptoms** Visual loss, metamorphopsia, and visual field defects are common symptoms. However, most patients are asymptomatic.<sup>8</sup>

**Signs** The ophthalmoscopic appearance of choroidal osteoma is characteristic.<sup>3</sup> The lesion is yellow-white in color, with varying

degrees of overlying RPE changes (Fig. 51.1A). The basal diameter varies from 2 to 22 mm and the tumor is usually flat or only minimally elevated (i.e. <2.5 mm).<sup>4</sup> The typical location is juxtapapillary or peripapillary, with some extension into the macular region. The tumor is round or oval in shape, with well defined wavy margins. Fine vascular tufts are visible on its surface and are distinct from secondary choroidal neovascularization, which manifests as exudation, hemorrhage, or subretinal fluid in the vicinity of the tumor.

**Course** About 40% of tumors grow, usually slowly.<sup>10</sup> Rapid enlargement of choroidal osteoma is exceptional.<sup>4,13</sup> Spontaneous reabsorption and decalcification can also occur.<sup>14</sup>

**Complications** Choroidal neovascularization is the major complication of choroidal osteoma and is expected to occur in about 50% of cases by 10 years.<sup>10</sup>

## Diagnostic evaluation (Box 51.1)

**Fluorescein angiography** Early patchy hyperfluorescence and late staining are characteristic angiographic features of choroidal osteoma (Fig. 51.1B). Fine vascular tufts are visible in the early phases of the angiogram.<sup>13</sup> Choroidal neovascularization appears as a lacy network with late leakage. Pinpoint areas of hyperfluorescence from retinal pigment epithelial dysfunction may also be observed.<sup>4</sup>

**Indocyanine angiography** Choroidal osteoma is hypofluorescent in the early phase and shows diffuse staining in the late phase. The tumor appears larger on the angiogram than on ophthalmoscopy.<sup>15</sup>

**Optical coherence tomography** reveals irregular plate-like high-signal intensity areas within the tumor and multiple tracks of high refractivity posterior to it.<sup>16</sup>

**Ultrasonography** provides characteristic signs and is therefore most helpful in establishing the diagnosis of choroidal osteoma. Both A- and B-scan show the anterior tumor surface to be highly reflective, with the B-scan also demonstrating orbital shadowing (Fig. 51.1C).<sup>3,4,8</sup>

**Computed tomography** demonstrates a dense, plaque-like opacity at the level of the choroid.<sup>3,4,8</sup> Quantitative tomographic techniques may be more sensitive in detecting subtle choroidal calcification.<sup>17</sup> CT scan may detect subclinical calcification in the fellow eye when ophthalmoscopy suggests that it is healthy.<sup>17</sup>



**Table 51.1 Causes of retinal, choroidal, and scleral calcification**

Category		Example		
Dystrophic	Degenerative		Sclerochoroidal calcification	
	Metaplastic		Phthisis bulbi	
	Neoplastic	Benign	Hamartoma Choristoma	Astrocytoma, retinocytoma Osteoma*
		Malignant		Retinoblastoma
Metabolic	Hypercalcemia	Hyperparathyroidism	Sclerochoroidal calcification	
		Bone destruction		
		Vitamin-D related disorders		
		Renal failure		
	Hypokalemic metabolic alkalosis	Barter syndrome Gitelman syndrome		

\*Choroidal osteoma represents bone formation and not a mere deposition of calcium salts.

**Magnetic resonance imaging** On high-resolution MRI with a surface coil, choroidal osteoma is hyperintense (bright) on T<sub>1</sub>-weighted images and hypointense (dark) on T<sub>2</sub>-weighted images. The tumor enhances with gadolinium-DPTA.<sup>18</sup>

**Differential diagnosis** The differential diagnosis of choroidal osteoma includes amelanotic melanoma, metastasis, hemangioma, primary choroidal lymphoma, and posterior scleritis (see Chapter 53). Intrascleral cartilage in patients with the organoid nevus syndrome may closely resemble choroidal osteoma.<sup>19,20</sup> Differentiation between choroidal osteoma and sclerochoroidal calcification is discussed in the next section.

Choroidal metastases appear as pale, white to yellow multiple lesions on ophthalmoscopy under a serous detachment, superficially resembling choroidal osteoma. Metastases are usually painless, and in most cases a previous history of cancer can be elicited. Ultrasonography usually demonstrates medium internal reflectivity without calcification. Fluorescein angiography reveals irregular widespread leakage in the late phase. Long-standing choroidal hemangioma can induce metaplastic calcification of the overlying pigment epithelium and mimic choroidal osteoma.<sup>2,9</sup> In such cases fluorescein angiography and indocyanine angiography will reveal early diffuse hyperfluorescence, whereas osteoma shows early patchy hyperfluorescence on fluorescein angiography and hypofluorescence on indocyanine angiography. Primary uveal lymphoma, unlike choroidal osteoma, shows low internal reflectivity on ultrasonography. In contrast to choroidal osteoma, posterior scleritis is often associated with autoimmune diseases and presents with pain, erythema, and either localized or diffuse thickening in the posterior segment. Further, posterior scleritis usually demonstrates high internal reflectivity with retrobulbar edema on ultrasonography.

**Treatment** Choroidal osteoma by itself is untreatable. However, its main complication of choroidal neovascularization may respond to photocoagulation, photodynamic therapy, and anti-angiogenic agents in a similar fashion to age-related disease.

**Observation** Asymptomatic cases without visually threatening complications may be observed.

**Laser photocoagulation** has limited efficacy (25%) because of lack of pigment in the tumor and atrophy of overlying retinal pigment epithelium.<sup>10</sup>

**Photodynamic therapy (PDT)** which is independent of the intrinsic pigmentation and has the advantage of sparing the overlying retina, may be superior to laser photocoagulation.<sup>21</sup> We have recently reported a case that was successfully treated with PDT (Fig. 51.1).<sup>22</sup>

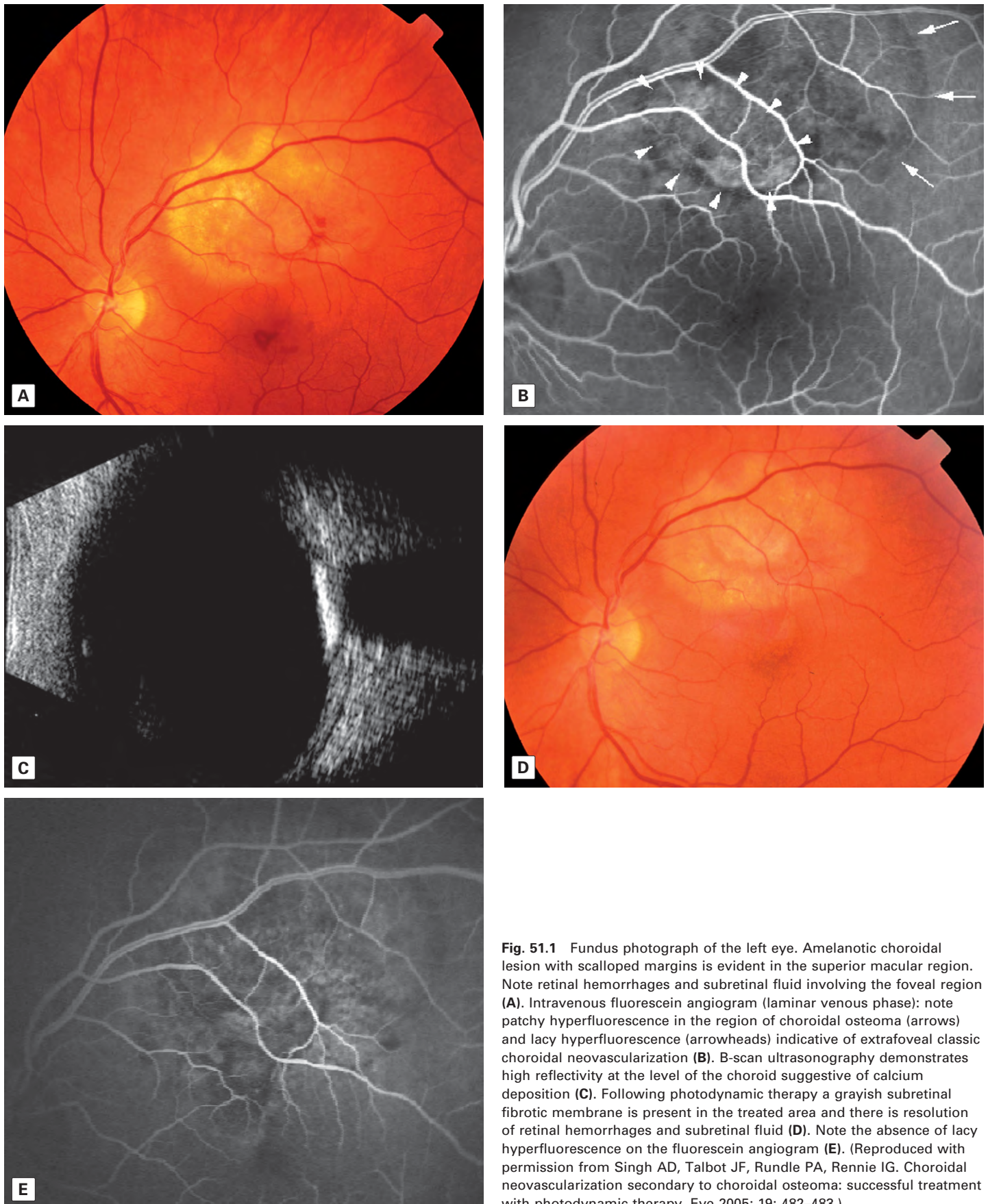
**Prognosis** After follow-up of 10 years or more, most eyes with choroidal osteoma have visual acuity of 20/200 or worse as a result of choroidal neovascularization or RPE degeneration at the fovea.<sup>10</sup>

## SCLEROCHOROIDAL CALCIFICATION

In 1982, Goldstein and Miller<sup>23</sup> described in detail the ophthalmoscopic, angiographic, and ultrasonographic features of sclerochoroidal calcification in a patient with hyperparathyroidism. The histopathologic features of sclerochoroidal calcification had been reported earlier by Wong<sup>24</sup> in a postmortem examination of both eyes of a patient with pseudohypoparathyroidism. Schachat<sup>25</sup> summarized the collective findings of 19 cases from several centers in the United States.

**Etiology** In most patients, sclerochoroidal calcification is apparently unrelated to any metabolic disease. In some of the early cases the clinical<sup>23</sup> and histopathological features<sup>24</sup> occurred in patients with calcium metabolic disorders, which include hyperparathyroidism,<sup>23,26,27</sup> hypervitaminosis D,<sup>28</sup> and hypokalemic metabolic alkalosis (Table 51.1).<sup>29,30</sup> In Schachat's series of 19 patients, calcium metabolism seemed to be normal in all but two patients.<sup>25</sup> Similarly in another series of 27 patients, metabolic abnormalities were detected in only seven.<sup>31</sup>

Hypokalemic metabolic alkalosis with hypomagnesemia has recently been recognized in association with sclerochoroidal calcification.<sup>29,30</sup> Barter syndrome (polyuria, polydipsia, failure to thrive, and



**Fig. 51.1** Fundus photograph of the left eye. Amelanotic choroidal lesion with scalloped margins is evident in the superior macular region. Note retinal hemorrhages and subretinal fluid involving the foveal region (A). Intravenous fluorescein angiogram (laminar venous phase): note patchy hyperfluorescence in the region of choroidal osteoma (arrows) and lacy hyperfluorescence (arrowheads) indicative of extrafoveal classic choroidal neovascularization (B). B-scan ultrasonography demonstrates high reflectivity at the level of the choroid suggestive of calcium deposition (C). Following photodynamic therapy a grayish subretinal fibrotic membrane is present in the treated area and there is resolution of retinal hemorrhages and subretinal fluid (D). Note the absence of lacy hyperfluorescence on the fluorescein angiogram (E). (Reproduced with permission from Singh AD, Talbot JF, Rundle PA, Rennie IG. Choroidal neovascularization secondary to choroidal osteoma: successful treatment with photodynamic therapy. *Eye* 2005; 19: 482–483.)

hypomagnesemia)<sup>29</sup> and Gitelman syndrome (muscle weakness, dermatitis, hypokalemia, and hypomagnesemia)<sup>30</sup> are autosomal recessive disorders of sodium chloride transport that should be considered in all patients with sclerochoroidal calcification.

**Pathology** The sclera is mainly affected, showing basophilic, amorphous, acellular calcium deposits.<sup>24,27</sup> The choroid is involved to a variable degree. There is atrophy of the retinal pigment epithelium, but the sensory retina is usually normal.

**Clinical features** Sclerochoroidal calcification is a disease of the elderly, detected at a mean age of 76 years.<sup>25,31</sup> Bilateral involvement occurs in about 85% of cases.<sup>25,31</sup>

**Symptoms** As a rule, patients are asymptomatic and the condition is detected on a routine examination.<sup>31</sup>

**Signs** Typically, nodular conglomerations of round, yellow-white lesions in the supero- and inferotemporal mid-periphery, beneath the major retinal vascular arcades are observed (Fig. 51.2A).<sup>25,31,32</sup> The lesions vary in basal diameter from 3 to 8 mm, and may either be elevated (up to 6 mm) or flat with overlying retinal pigment epithelial atrophy. Calcific deposits along the insertion of the medial or lateral rectus muscles (Cogan plaque) may be evident on external examination.

#### BOX 51.1 Features of Choroidal Osteoma

- Young healthy females with unilateral involvement
- Ophthalmoscopic appearance of a yellow-white choroidal mass, minimal elevation with a well defined scalloped margin, located in the juxtapapillary region
- Early patchy hyperfluorescence and late staining on fluorescein angiography
- Early hypofluorescence and late staining on indocyanine angiography
- Highly reflective choroidal plaque-like lesion with orbital shadowing on ultrasonography (B-scan)
- A dense plaque-like bony opacity at the level of the choroid is noted on CT scan

**Complications** Lack of complications and overall stability is the rule. In rare cases, secondary choroidal neovascularization may develop.<sup>33</sup>

**Diagnostic evaluation** (Box 51.2)

**Fluorescein angiography** typically shows autofluorescence, early hypofluorescence, progressive hyperfluorescence, and late staining.<sup>32</sup> Secondary choroidal neovascularization may be evident as a lacy vascular network in the early phases, with progressive leakage.<sup>33</sup>

**Ultrasonography** Detection of calcification with B-scan and A-scan ultrasonography is the most significant diagnostic test. Calcification appears as a highly reflective lesion at the sclerochoroidal level, with shadowing of the orbit (Fig. 51.2B).<sup>25</sup> The scan should be performed to visualize all quadrants of both eyes, including areas that appear ophthalmoscopically normal, as well as the unaffected normal eye, as calcification is commonly detected in apparently normal areas.<sup>32</sup>

**Computed tomography** Calcification can be confirmed by CT scan (Fig. 51.2C); however, this is more expensive and less convenient than ultrasonography. Some cases of sclerochoroidal calcification are detected when a scan is performed for unrelated reasons.

**Metabolic evaluation** Before labeling any case of sclerochoroidal calcification as idiopathic, it is essential to exclude systemic disease by appropriate enquiry, clinical examination, and metabolic tests.

**Differential diagnosis** Some might confuse sclerochoroidal calcification with other amelanotic lesions, such as choroidal metastasis and subpigment epithelial infiltrates of primary CNS-ocular lymphoma, and choroidal osteoma (Table 51.2). Choroidal osteoma is rare in elderly individuals, in whom the calcified lesion is more likely to be sclerochoroidal calcification.<sup>34</sup>

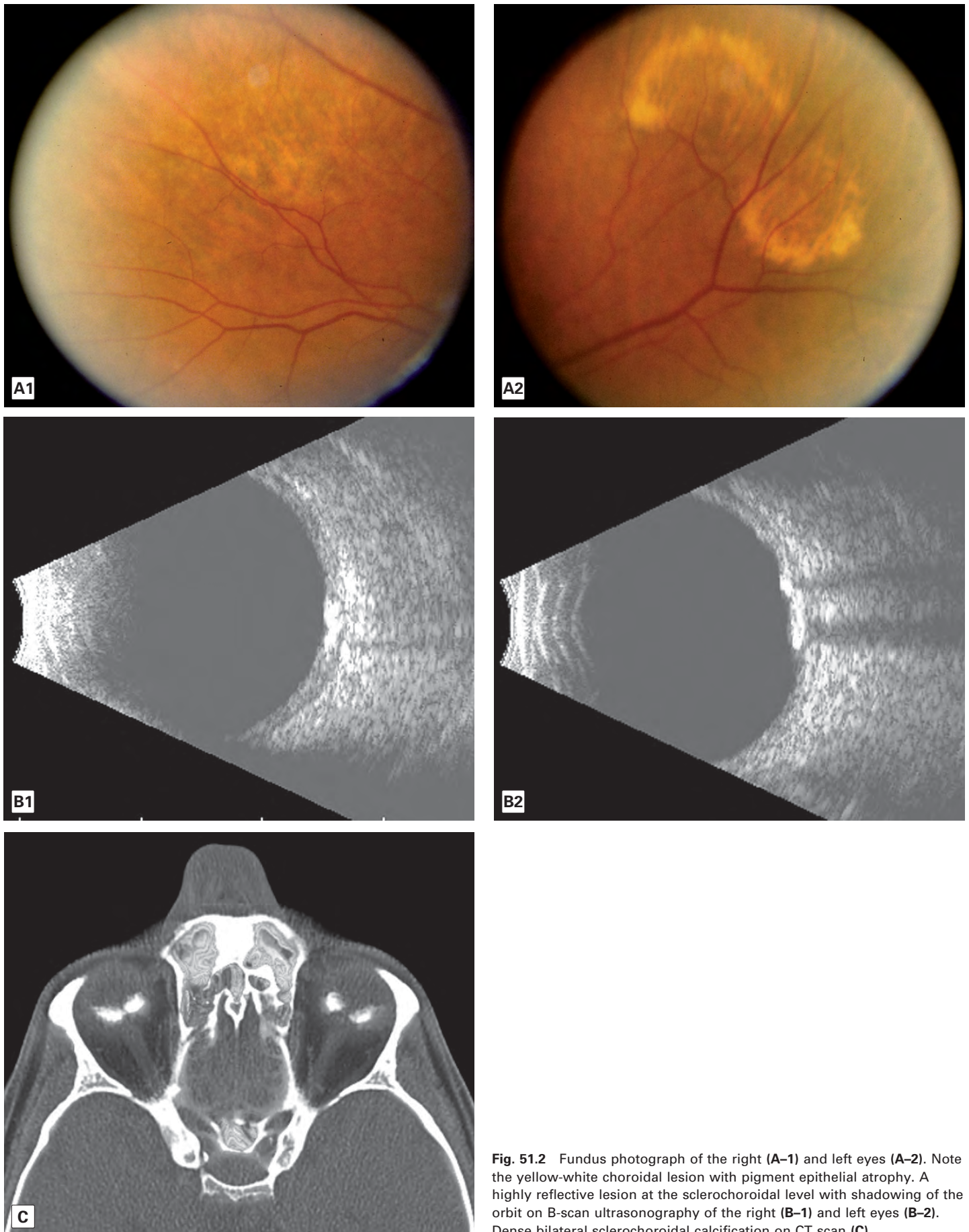
**Treatment** may be necessary for secondary choroidal neovascularization or for any underlying metabolic disorder.

**Prognosis** Overall the visual prognosis is excellent, as this condition is usually stable.

#### BOX 51.2 Features of Sclerochoroidal Calcification

- Elderly patients with bilateral involvement
- Ophthalmoscopic appearance of a yellow-white choroidal mass, minimal elevation with ill defined margins, and in the midperipheral location
- Early hypofluorescence, progressive hyperfluorescence, and late staining on fluorescein angiography
- Highly reflective sclerochoroidal plaque-like lesion with orbital shadowing on ultrasonography (B-scan)
- A dense plaque-like bony opacity at the sclerochoroidal level on CT scan
- Systemic association with disorders of calcium, vitamin D, and magnesium





**Fig. 51.2** Fundus photograph of the right (A-1) and left eyes (A-2). Note the yellow-white choroidal lesion with pigment epithelial atrophy. A highly reflective lesion at the sclerochoroidal level with shadowing of the orbit on B-scan ultrasonography of the right (B-1) and left eyes (B-2). Dense bilateral sclerochoroidal calcification on CT scan (C).

**Table 51.2 Differentiating features of choroidal osteoma and sclerochoroidal calcification**

	Feature	Choroidal osteoma	Sclerochoroidal calcification
Clinical	Age (mean)	21 years	76 years
	Sex	Female >> male	Male = female
	Bilaterality	75% Unilateral	85% Bilateral
	Progression	Frequent	Stable
Ophthalmoscopic	Location	Juxtapapillary	Mid-periphery
	Shape	Oval with scalloped margins	Round with ill-defined margins
	Size (diameter)	2–22 mm	3–8 mm
	Elevation	<2.5 mm	<6 mm
	Focality	Unifocal	Multifocal
	Neovascularization	Frequent	Rare
Diagnostic	Fluorescein angiography	Early patchy hyperfluorescence; late staining	Early hypofluorescence; late staining
	Ultrasonography	Calcification	Calcification
Pathology		Osseous choristoma	Degenerative/metastatic calcification
Systemic association		Absent	May be present

(Modified from Schachat AP, Robertson DM, Mieler WF et al. Sclerochoroidal calcification. *Arch Ophthalmol* 1992; 110: 196–199)

## REFERENCES

- Cotran RS, Kumar V, Collins T. Robbins' pathologic basis of disease, 6th edn. Philadelphia: WB Saunders, 1999; 43–45.
- Reese AB. Tumors of the eye. New York: Harper & Row, 1976; 266–267.
- Gass JD, Guerry RK, Jack RL, Harris G. Choroidal osteoma. *Arch Ophthalmol* 1978; 96: 428–435.
- Shields CL, Shields JA, Augsburger JJ. Choroidal osteoma. *Surv Ophthalmol* 1988; 33: 17–27.
- Katz RS, Gass JD. Multiple choroidal osteomas developing in association with recurrent orbital inflammatory pseudotumor. *Arch Ophthalmol* 1983; 101: 1724–1727.
- Noble KG. Bilateral choroidal osteoma in three siblings. *Am J Ophthalmol* 1990; 109: 656–660.
- Cunha SL. Osseous choristoma of the choroid. A familial disease. *Arch Ophthalmol* 1984; 102: 1052–1054.
- Kadmas EF, Weiter JJ. Choroidal osteoma. *Int Ophthalmol Clin* 1997; 37: 171–182.
- Williams AT, Font RL, Van Dyk HJ, Riekhof FT. Osseous choristoma of the choroid simulating a choroidal melanoma. Association with a positive 32P test. *Arch Ophthalmol* 1978; 96: 1874–1877.
- Aylward GW, Chang TS, Pautler SE, Gass JD. A long-term follow-up of choroidal osteoma. *Arch Ophthalmol* 1998; 116: 1337–1341.
- Kida Y, Shibuya Y, Oguni M et al. Choroidal osteoma in an infant. *Am J Ophthalmol* 1997; 124: 119–120.
- Baarsma GS, Craandijk A. Osteoma of the choroid. *Doc Ophthalmologica* 1981; 50: 205–212.
- Gass JD. New observations concerning choroidal osteomas. *Int Ophthalmol* 1979; 1: 71–84.
- Buettner H. Spontaneous involution of a choroidal osteoma. *Arch Ophthalmol* 1990; 108: 1517–1518.
- Yuzawa M, Kawamura A, Haruyama M, Matsui M. Indocyanine green video-angiographic findings in choroidal osteoma. *Eur J Ophthalmol* 1994; 4: 191–198.
- Ide T, Ohguro N, Hayashi A et al. Optical coherence tomography patterns of choroidal osteoma. *Am J Ophthalmol* 2000; 130: 131–134.
- Jokl DH, Tsai N, Kreps S. Detection of choroidal calcium by computed tomography scan quantitative computerized tomography: a clinically useful diagnostic tool. *Ophthalmology* 1999; 106: 1841–1846.
- DePotter P, Shields JA, Shields CL, Rao VM. Magnetic resonance imaging in choroidal osteoma. *Retina* 1991; 11: 221–223.
- Shields JA, Shields CL, Eagle RC Jr et al. Ocular manifestations of the organoid nevus syndrome. *Ophthalmology* 1997; 104: 549–557.
- Traboulsi EI, Zin A, Massicotte SJ et al. Posterior scleral choristoma in the organoid nevus syndrome (linear nevus sebaceus of Jadassohn). *Ophthalmology* 1999; 106: 2126–2130.
- Parodi MB, Da Pozzo S, Toto L et al. Photodynamic therapy for choroidal neovascularization associated with choroidal osteoma. *Retina* 2001; 21: 660–661.
- Singh AD, Talbot JF, Rundle PA, Rennie IG. Choroidal neovascularization secondary to choroidal osteoma: successful treatment with photodynamic therapy. *Eye* 2005; 19: 482–484.
- Goldstein BG, Miller J. Metastatic calcification of the choroid in a patient with primary hyperparathyroidism. *Retina* 1982; 2: 76–79.
- Wong S, Zakov ZN, Albert DM. Scleral and choroidal calcifications in a patient with pseudohypoparathyroidism. *Br J Ophthalmol* 1979; 63: 177–180.
- Schachat AP, Robertson DM, Mieler WF et al. Sclerochoroidal calcification. *Arch Ophthalmol* 1992; 110: 196–199.
- Berkow JW, Fine BS, Zimmerman LE. Unusual ocular calcification in hyperparathyroidism. *Am J Ophthalmol* 1968; 66: 812–824.
- Jensen OA. Ocular calcifications in primary hyperparathyroidism. Histochemical and ultrastructural study of a case. Comparison with ocular calcifications in idiopathic hypercalcaemia of infancy and in renal failure. *Acta Ophthalmol (Copenh)* 1975; 53: 173–186.
- Gartner S, Rubner K. Calcified scleral nodules in hypervitaminosis D. *Am J Ophthalmol* 1955; 39: 658–663.
- Marchini G, Tosi R, Parolini B et al. Choroidal calcification in Bartter syndrome. *Am J Ophthalmol* 1998; 126: 727–729.
- Bourcier T, Blain P, Massin P et al. Sclerochoroidal calcification associated with Gitelman syndrome. *Am J Ophthalmol* 1999; 128: 767–768.
- Honavar SG, Shields CL, Demirci H, Shields JA. Sclerochoroidal calcification: clinical manifestations and systemic associations. *Arch Ophthalmol* 2001; 119: 833–840.
- Shields JA, Shields CL. CME review: sclerochoroidal calcification: the 2001 Harold Gifford Lecture. *Retina* 2002; 22: 251–261.
- Leys A, Stalmans P, Blanckaert J. Sclerochoroidal calcification with choroidal neovascularization. *Arch Ophthalmol* 2000; 118: 854–857.
- Wiesner PD, Nofsinger K, Jackson WE. Choroidal osteoma: two case reports in elderly patients. *Ann Ophthalmol* 1987; 19: 19–23.

# Uveal myogenic, fibrous, and histiocytic tumors

Paul Rundle, Hardeep Singh Mudhar, M. Andrew Parsons and Ian G. Rennie

## INTRODUCTION

Primary uveal tumors exhibiting muscle differentiation are rare, but consist essentially of those with smooth muscle differentiation (leiomyomas and leiomyosarcomas) and those with striated muscle differentiation (rhabdomyosarcomas).<sup>1-3</sup>

Leiomyomas, on the other hand, are rare benign tumors arising from smooth muscle components of the uveal tract. The first well documented case was probably described by Blodi in 1950,<sup>4</sup> and since then the majority of publications have consisted either of single case reports or small series.<sup>5-8</sup> Their rarity and the fact that leiomyomas often strongly resemble malignancies such as uveal melanoma makes diagnosis difficult prior to treatment.

## PATHOGENESIS

Rhabdomyosarcomas elsewhere in the body commonly develop in tissues devoid of striated muscle, and in this situation are thought to arise from undifferentiated mesenchyme. This would also account for their development in iris tissue. A further possibility is of rhabdomyoblastic differentiation of a teratoid medulloepithelioma, thought to be the mechanism underlying the case of the ciliary body tumor alluded to above. All three cases presented in childhood and showed surprisingly slow growth compared to rhabdomyosarcomas elsewhere. In the cases of iris involvement glaucoma ultimately developed and the eyes were enucleated. No metastases have been reported.

Leiomyomas have a propensity to arise in the ciliary body (Fig. 52.1A,B), although rare cases of involvement of the posterior choroid<sup>9</sup> have been described. Interestingly, some authors have noted at the time of surgical resection that leiomyomas grow within the suprachoroidal space and that the overlying uveal stroma is uninvolved.<sup>5</sup> It is questionable whether the iris may be a site for leiomyoma. Although a number of cases have been described, the difficulty in distinguishing leiomyomas from the more common melanocytic tumors means that at least some of these reports were probably inaccurate.<sup>10</sup>

In 1977, Jakobiec<sup>11</sup> proposed that two variants of leiomyoma be recognized, reflecting their different origins. Muscle tissue of the uveal tract has two embryological sources. Vascular smooth muscle arises from true mesoderm and is thought to give rise to mesodermal leiomyomas. On the other hand, ciliary muscle is of neural crest origin and is thought to give rise to so-called mesectodermal leiomyomas showing features of both myogenic and neural tumors. Whether this distinction is of any clinical value is doubtful.

Overall, leiomyomas occur in a younger age group (third to fifth decades) than uveal melanomas, which have a mean age at presentation of 55 years.<sup>5</sup>

Interestingly, as with leiomyomas elsewhere in the body, uveal lesions are more common in females. In fact, in one review by Shields et al.,<sup>5</sup> only three out of 24 patients were males. This raises the possibility of a hormonal influence.

## CLINICAL FEATURES

**Symptoms** Uveal leiomyomas may be asymptomatic, being detected as an incidental finding during a routine eye examination. On the other hand, they may present with painless blurring of vision, astigmatism, or visual field defect resulting from cataract, lens subluxation, or serous detachment of the retina.

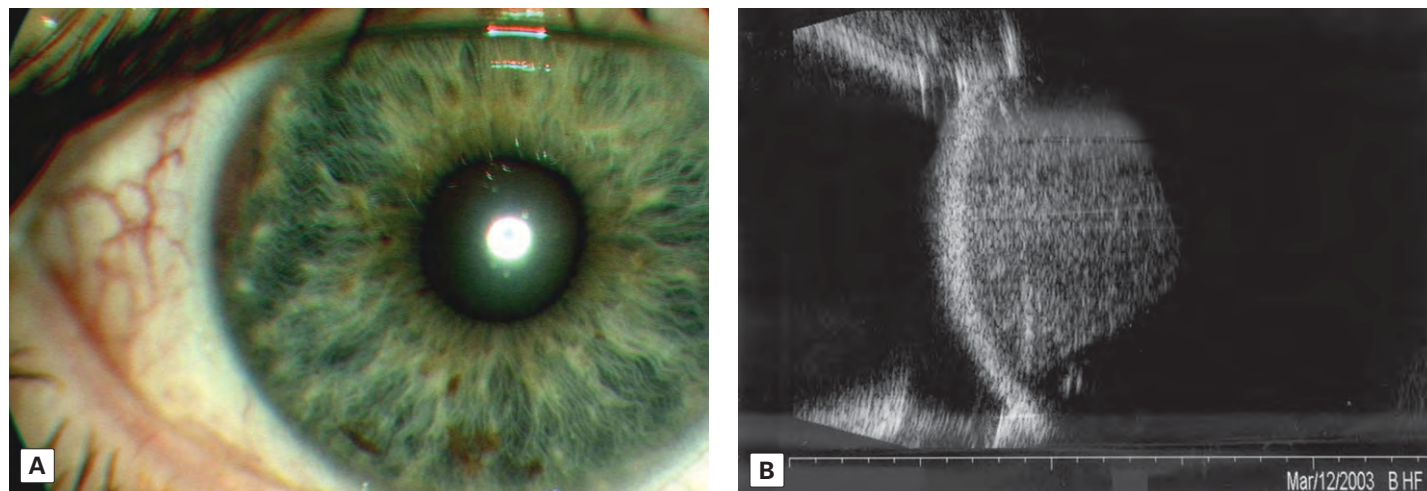
**Signs** Leiomyomas are solitary, usually well-circumscribed lesions affecting only one eye. Examination of the anterior segment may reveal dilated episcleral (sentinel) vessels in the quadrant overlying the uveal tumor (Fig. 52.1A). Leiomyomas are usually amelanotic in appearance and may show prominent intrinsic vessels, making them indistinguishable in some cases from collar-stud melanomas. One characteristic feature of leiomyomas is that they frequently transilluminate, in contrast to melanomas, which generally cast a shadow on transillumination of the globe. As has been said, enlarging lesions may produce pressure effects on adjacent structures, such as cataract, notching of the lens, or lens subluxation. Occasionally, leiomyomas may invade the anterior chamber angle<sup>6</sup> (Fig. 52.1A) or extend through the sclera.<sup>5,12</sup>

## DIAGNOSTIC EVALUATION

Making a firm diagnosis of uveal leiomyoma may be impossible without histology, although the presence of an amelanotic mass that transilluminates in a young (female) patient should certainly raise the possibility of this diagnosis. Unfortunately, there are no features that may be considered pathognomonic of leiomyoma. On ocular ultrasound, leiomyomas may show medium to low reflectivity, similar to uveal melanomas. As the majority of leiomyomas involve the ciliary body, it may be possible to demonstrate the suprauveal location of these tumors using high-frequency ultrasonography.

CT and MRI scans, despite demonstrating the presence of the tumor, cannot reliably distinguish leiomyomas from other intraocular masses.<sup>13</sup>





**Fig. 52.1** Pigmented ciliary body leiomyoma eroding through the iris root. Note the dilated episcleral vessels overlying the tumor (A). High-frequency ultrasound scan demonstrating the lesion (B).

Fluorescein and ICG angiography have little role to play, as these lesions may be difficult to visualize on angiography. In those cases where angiography is possible, the overlying choroid might be expected to be normal owing to the supra-uveal location of these tumors.

### SALIENT DIAGNOSTIC FINDINGS

**Macroscopic pathology** Leiomyomas that are present in the supraciliary space are usually well circumscribed, non-pigmented, and solid, with a gray/white color.<sup>5</sup> However, other leiomyomas have been documented to show an irregular outline, a reflection of an infiltrative growth pattern, and in some cases trans-scleral permeation.<sup>12,14</sup>

The only documented case of primary intraocular leiomyosarcoma displayed a crescentic, firm, gray-brown mass with a pushing border trans-scleral component, with overlying retinal detachment.<sup>15</sup> The documented cases of rhabdomyosarcomas were solid, with gray/white cut surfaces.<sup>1-3</sup>

**Microscopic pathology** Mesodermal and mesectodermal uveal leiomyomas are composed predominantly of spindle cells, with solid to vesicular, ovoid elongate nuclei with indistinct nucleoli, set in eosinophilic fibrillar cytoplasm (Fig. 52.2A). There is usually no or only a minimal degree of nuclear pleomorphism. Cell borders are usually indistinct.<sup>4,5,6,11</sup>

Nuclear pleomorphism and distinct nucleoli, coupled with non-aberrant mitotic activity, may be seen in uveal leiomyomas that show a propensity to infiltrate neighboring structures.<sup>14</sup> Mesectodermal leiomyomas often contain groups of polygonal tumor cells with distinct paranuclear indenting vacuoles, as are seen in typical extraocular leiomyomas. These polygonal cells have oval to round vesicular nuclei and indistinct basophilic nucleoli.<sup>11</sup>

The tumor cells are arranged as interlacing, randomly distributed fascicles, with little intervening collagen matrix.<sup>4-6,11</sup> The degree of

interstitial vascularity varies from tumor to tumor. Conventional leiomyomas have a sparse, delicate capillary vascular network, whereas some mesectodermal leiomyomas can be quite vascular.<sup>5</sup> The few cases of uveal angioleiomyoma documented contained prominent thick-walled vessels between the smooth muscle cells.<sup>4-6,11,12</sup>

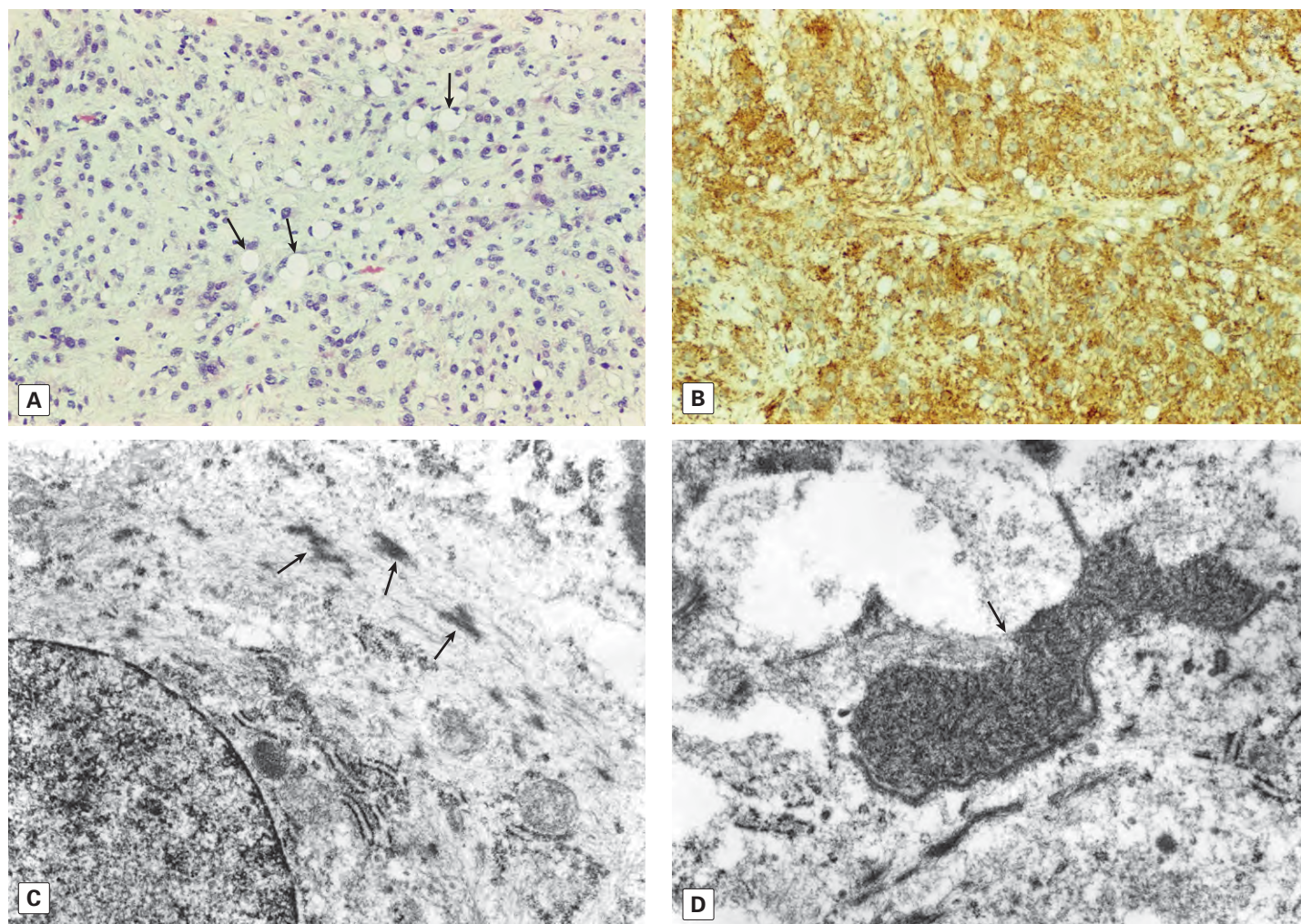
Tumor cellularity varies again from field to field: conventional leiomyomas tend to be more cellular than the mesectodermal subtype. The paucicellular, fibrillar nature of some areas of mesectodermal leiomyoma, coupled with focal palisading of the tumor cells, imparts a 'cerebral' or 'neural' appearance.<sup>5,6,11</sup> At higher power it is sometimes possible to observe brightly eosinophilic cytoplasmic densities in mesectodermal leiomyomas; these are skeinoid fibers (see Ultrastructure findings).<sup>16</sup> Occasionally, scattered melanocytes are seen between the smooth muscle cells; these may either be entrapped from the uvea, or represent focal melanocytic differentiation.<sup>4-6,11</sup>

The only documented case of a mesectodermal leiomyosarcoma of the uvea showed typical mesectodermal features, with hyperchromatic, moderately atypical nuclei having four to six mitotic figures per 10 unspecified high-power fields. It is debatable whether this case represents a true leiomyosarcoma, as trans-scleral infiltration by leiomyomas is well documented, a probable reflection of their natural history.<sup>5,15</sup>

The few documented cases of primary intraocular rhabdomyosarcoma have been of the embryonal subtype.<sup>1-3</sup> These are composed of a variable combination of undifferentiated, mitotically active spindled mesenchyme cells, with variable differentiation to typical eosinophilic strap cells. Strap cells can show cytoplasmic cross-striations if viewed at higher power.<sup>1-3</sup>

### IMMUNOHISTOCHEMICAL FINDINGS

Leiomyomas are strongly positive for smooth muscle actin<sup>5,6,9,10</sup> (Fig. 52.2B). They may be positive for desmin,<sup>5,6,9,10</sup> CD-56,<sup>17</sup> and hcal-desmon.<sup>17</sup> They are negative for S100, Melan-A, HMB45, cytokeratins, GFAP, CD-10, CD-34, Alk-1, and c-kit (personal observations).



**Fig. 52.2** Hematoxylin and eosin-stained section of a mesectodermal leiomyoma. Note oval to circular nuclei in spindle-shaped eosinophilic cytoplasm, with some paranuclear vacuolation (arrows) (A). Diffuse, strong cytoplasmic immunoreactivity with anti-smooth muscle actin (brown reaction product) (B). Transmission electron micrograph. The arrows point to smooth muscle actin fusiform, focal densities (C). Transmission electron micrograph. The arrow points to a skenoid fiber (D).

It is important to confirm a negative reaction with S-100, as this excludes melanoma and schwannoma, with which leiomyoma may be confused on light microscopy. Mesectodermal leiomyomas may be positive for CD-56, reconfirming the observation that the mesectodermal subtype is probably differentiating towards a neural crest phenotype. The negative reaction with cytokeratin excludes a spindle carcinoma or a cytokeratin-positive sarcoma. The negative reaction with CD34 and GFAP excludes a solitary fibrous tumor and a glial tumor, respectively, and a negative reaction with c-kit excludes a metastatic gastrointestinal stromal tumor (GIST) (personal observations).

We have observed one case of mesectodermal leiomyoma from a female that showed nuclear positivity for progesterone receptors (unpublished), whereas an identical tumor from a male was negative for hormone receptors. The presence of progesterone receptors in the female patient argues in favor of a hormone-driven etiopathogenesis. This may explain why most uveal leiomyomas occur in premenopausal women.<sup>5</sup>

The case reports on rhabdomyosarcoma did not employ immunohistochemical confirmation, but used electron microscopy.<sup>1-3</sup>

## ULTRASTRUCTURAL FINDINGS

Leiomyomas show cytoplasmic filaments with fusiform densities (Fig. 52.2C), confirming a smooth muscle phenotype. No z-banding is identified.<sup>18-20</sup>

Mesectodermal leiomyomas may show extracellular skenoid fibers, characterized by curvilinear collagenous fibrils (Fig. 52.2D). Skenoid fibers are often found in neurogenic spindle cell tumors. Their presence in this setting lends further weight to the theory of neural crest differentiation of mesectodermal leiomyomas.<sup>16</sup>

The few cases of primary uveal rhabdomyosarcoma have exhibited distinct cytoplasmic z-banding.<sup>1-3</sup>

## CYTOGENETIC ANALYSIS

We have had experience with performing cytogenetic analysis on two cases of mesectodermal leiomyoma. One was from a male and the other from a female. The former showed a 46XY pattern and the latter a 46XX pattern. No distinct cytogenetic aberrations were identified (unpublished data). Cytogenetic studies were not performed on the originally reported cases of primary uveal rhabdomyosarcoma.<sup>1-3</sup>



**DIFFERENTIAL DIAGNOSIS**

The most important differential diagnosis is of uveal melanoma; however, other possibilities include adenoma of the ciliary epithelium with smooth muscle elements; medulloepithelioma; schwannoma; metastatic lesions; cysts of the pigment epithelium/pars plana; and granulomata/intermediate uveitis.

**TREATMENT**

As leiomyomas of the uveal tract are benign in the histological sense, then in theory treatment could be conservative. They do, however, have a propensity to grow, and so require treatment to prevent local damage. Unfortunately, the diagnosis may only become apparent after the lesion – or indeed the eye – has been removed. In the case of leiomyomas, radiotherapy and chemotherapy have no role. The mainstay of treatment is surgical, and in general, if the diagnosis is suspected then such tumors can be readily excised by iridocyclectomy or cyclochoroidectomy, with the potential to retain excellent vision. Complications of local resection have been well described<sup>21</sup> and may be sight threatening, including hypotony, glaucoma, cataract, hemorrhage (hyphema or vitreous hemorrhage), retinal detachment, and endophthalmitis. Unfortunately, as the diagnosis may not be apparent prior to surgery, eyes may be enucleated under the erroneous impression that they harbor a melanoma rather than a leiomyoma. This raises the question of whether all such lesions should be biopsied prior to definitive treatment. This is probably unnecessary for a number of reasons. First, masquerading lesions such as leiomyomas are exceptionally rare and the frequency of enucleation for an erroneous diagnosis is very low.<sup>22</sup> Second, fine needle aspiration biopsy does not allow for a histological diagnosis and may not provide sufficient material for even a cytological diagnosis. Open-flap biopsy is a possibility but may render subsequent local resection impossible. The best alternative is to have a high index of suspicion that the lesion may be a leiomyoma and plan eye-retaining surgery wherever possible.

**FOLLOW-UP**

Occasionally the diagnosis of leiomyoma will come as a surprise to both the patient and the clinician. Obviously no metastatic screening will be necessary, and follow-up will depend on the type of surgery performed. If local resection has been performed then regular follow-up will be necessary to monitor the intraocular pressure, retinal status, and to check for cataract. If the eye has been enucleated then once the socket has healed and a prosthesis fitted the patient may be monitored or discharged at the clinician's discretion.

**PROGNOSIS**

Obviously, the life prognosis in the case of uveal leiomyoma is excellent. There has been no recorded case of metastatic ocular leiomyosarcoma of which the authors are aware. In cases treated by local resection the ocular prognosis is also good. There has only been one recorded case of recurrence of uveal leiomyoma, in a young patient whose initial treatment consisted of curettage alone. In that instance the patient suffered a massive tumor recurrence requiring enucleation.<sup>8</sup>

**LEIOMYOSARCOMA**

There is only one reported case of primary intraocular leiomyosarcoma.<sup>15</sup> Moreover, it is debatable whether this case represents a true leiomyosarcoma, as it may have been a leiomyoma with trans-scleral infiltration.<sup>5,15</sup>

**RHABDOMYOSARCOMA**

Ordinarily, striated muscle does not occur in the uveal tract; however, there have been at least three published reports of rhabdomyosarcoma of the iris and ciliary body.<sup>1,23</sup> All three cases presented in childhood and showed surprisingly slow growth compared to rhabdomyosarcoma elsewhere. No metastases were observed.<sup>1,2</sup>

**FIBROUS TUMORS**

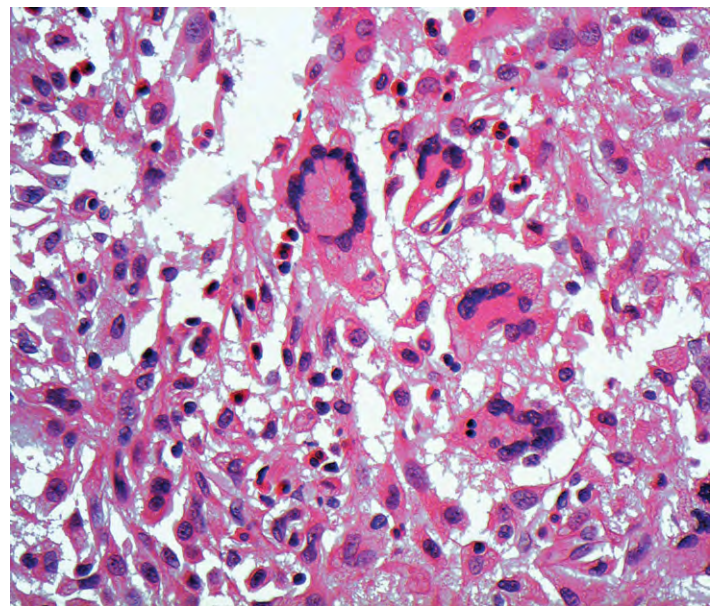
There are at least two reports describing fibrous histiocytoma of the choroid in adult females,<sup>23,24</sup> and a third describing a congenital fibrosarcoma metastatic to the choroid.<sup>25</sup>

**JUVENILE XANTHOGRANULOMA**

In general, juvenile xanthogranuloma (JXG) is a benign, self-limiting skin condition affecting young children.<sup>26</sup> Lesions typically consist of reddish papules involving the trunk, upper extremities, and face including the eyelids.<sup>26</sup>

Ocular involvement most commonly presents as a unilateral infiltration of the iris<sup>27</sup> although, rare cases of bilateral disease have been observed.<sup>28</sup> Ciliary body, choroidal, optic nerve involvement and orbital involvement have also been described.<sup>27,28,29</sup> Iris lesions are yellow in color and may be localized or diffuse.<sup>27</sup> Recurrent hyphema, uveitis, secondary glaucoma or iris heterochromia are common presenting features.<sup>27</sup> The diagnosis is easily confirmed by means of a skin biopsy, if cutaneous lesions are present. In cases with only iris involvement, an aqueous humor tap (paracentesis) may be diagnostic. In general, an iris biopsy should be avoided owing to the risk of hemorrhage.

**Pathology** The characteristic feature is the presence of Touton giant cells in which a peripheral wreath of nuclei encloses an area of eosinophilic cytoplasm (Figure 52.3). In contrast to Langerhans cell histiocytosis, cytoplasmic Birbeck granules are absent on electron microscopy.



**Fig. 52.3.** Light microscopic appearance of juvenile xanthogranuloma. Note the foamy cytoplasm of the histiocytic cells and the giant cells of Touton type (peripheral wreath of circumferentially disposed nuclei).



**Treatment and prognosis** JXG is a self-limiting condition. Symptomatic cases requiring treatment, usually respond to topical, periocular<sup>30</sup> or systemic steroids.<sup>31</sup> In cases unresponsive to steroids, low-dose radiotherapy (less than 500 cGy) may be used.<sup>32</sup>

### LANGERHANS CELL HISTIOCYTOSIS

Langerhans cell histiocytosis is a neoplastic proliferation of Langerhans cells and includes (in order of severity) eosinophilic granuloma, Hand-Schuller-Christian disease, and Letterer-Siwe disease. Uveal infiltration has rarely been reported at necropsy in severe systemic forms of the disease.<sup>33,34</sup> The Langerhans cells are usually accompanied by eosinophils, lymphocytes, and occasional neutrophils. Immunohisto-

chemistry demonstrates a CD1a and S100 positive phenotype.<sup>32</sup> The ultrastructural hallmark is the cytoplasmic Birbeck granule that is shaped like a tennis racket (Chapter 3A, Figure 3A.3).<sup>35</sup>

### SUMMARY

In any case of suspected amelanotic uveal melanoma, myogenic, fibrous and histiocytic tumors should be considered in the differential diagnosis. The correct diagnosis usually becomes apparent following enucleation or local resection. Little or no mitotic activity is observed in any of the reported specimens suggesting that radiotherapy would be of little benefit. In the absence of systemic involvement, however, the life prognosis should be excellent.

### REFERENCES

- Woyke S, Chwirot R. Rhabdomyosarcoma of the iris. Report of the first recorded case. *Br J Ophthalmol* 1972; 56: 60–64.
- Elsas FJ, Mroczek EC, Kelly DR, Sprecht CS. Primary rhabdomyosarcoma of the iris. *Arch Ophthalmol* 1991; 109: 982–984.
- Wilson ME, McClatchey SK, Zimmerman LE. Rhabdomyosarcoma of the ciliary body. *Ophthalmology* 1990; 97: 1484–1488.
- Blodi FC. Leiomyoma of the ciliary body. *Am J Ophthalmol* 1950; 33: 939–942.
- Shields JA, Shields CL, Eagle RC, De Potter P. Observations on seven cases of intraocular leiomyoma. The 1993 Byron Demorest Lecture. *Arch Ophthalmol* 1994; 112: 521–528.
- Biswas J, Krishna Kumar S, Gopal L, Bhende MP. Leiomyoma of the ciliary body extending to the anterior chamber: clinicopathologic and ultrasound biomicroscopic correlation. *Surv Ophthalmol* 2000; 44: 336–342.
- Schlotzer-Schrehardt U, Junemann A, Naumann G.O.H. Mitochondria-rich epithelioid leiomyoma of the ciliary body. *Arch Ophthalmol* 2002; 120: 77–82.
- Park SH, Lee J, Chae YS, Kim CH. Recurrent mesectodermal leiomyoma of the ciliary body: a case report. *J Korean Med Sci* 2003; 18: 614–617.
- Jeon YK, Cha HJ, Kim NR, Kim CJ, Chi JG. Leiomyoma in the posterior choroid: a case report. *J Korean Med Sci* 2002; 17: 429–433.
- Foss AJE, Pecorella I, Alexander RA, Hungerford JL, Garner A. Are most intraocular 'leiomyomas' really melanocytic lesions? *Ophthalmology* 1994; 101: 919–924.
- Jakobiec FA, Font RL, Tso MO, Zimmerman LE. Mesectodermal leiomyoma of the ciliary body: a tumor of presumed neural crest origin. *Cancer* 1977; 39: 2102–2113.
- Jakobiec FA, Witschel H, Zimmerman LE. Choroidal leiomyoma of vascular origin. *Am J Ophthalmol* 1976; 82: 205–212.
- Oh KJ, Kwon BJ, Han MH et al. MR imaging findings of uveal leiomyoma: three cases. *Am J Neuroradiol* 2005; 26: 100–103.
- Shields CL, Shields JA, Varenhorst MP. Trans-scleral leiomyoma. *Ophthalmology* 1991; 98: 84–97.
- Park SW, Kim HJ, Chin HS, Tae KS, Han JY. Mesectodermal leiomyoma of the ciliary body. *Am J Neuroradiol* 2003; 24: 1765–1768.
- Campbell RJ, Min KW, Bolling JP. Skenoid fibres in mesectodermal leiomyoma of the ciliary body. *Ultrastruct Pathol* 1997; 21: 559–567.
- Lai CT, Tai MC, Liang CM, Lee HS. Unusual uveal tract tumor: mesectodermal leiomyoma of the ciliary body. *Pathol Int* 2004; 54: 337–342.
- Meyer SL, Fine BS, Font RL, Zimmerman LE. Leiomyoma of the ciliary body. *Am J Ophthalmol* 1968; 66: 1061–1068.
- Croxatto JO, Malbran E. Unusual ciliary body tumor: mesectodermal leiomyoma. *Ophthalmology* 1982; 89: 1208–1212.
- Zimmerman LE, Font RL, Tso MOM, Fine BS. Application of electron microscopy to histopathological diagnosis. *Trans Am Acad Ophthalmol Otolaryngol* 1972; 76: 101–107.
- Char DH. Anterior uveal tumors. In: *Clinical ocular oncology*, 2nd edn. Philadelphia: Lippincott-Raven, 1997; 186–189.
- The Collaborative Ocular Melanoma Study Group. Accuracy of diagnosis of choroidal melanomas in the Collaborative Ocular Melanoma Study Group. COMS report no. 1. *Arch Ophthalmol* 1990; 108: 1268–1273.
- Croxatto JO, D'Alessandro C, Lombardi A. Benign fibrous tumor of the choroid. *Arch Ophthalmol* 1989; 107: 1793–1796.
- Lam DS, Chow LT, Gandhi SR, et al. Benign fibrous histiocytoma of the choroid. *Eye* 1998; 12: 208–211.
- Rootman J, Carvounis EP, Dolman CL, Dimmick JE. Congenital fibrosarcoma metastatic to the choroid. *Am J Ophthalmol* 1979; 87: 632–638.
- Lyons C, Rootman J. Histiocytic, haematopoietic and lymphoproliferative disorders. In: Taylor D and Hoyt C, eds. *Paediatric ophthalmology and Strabismus 3rd Edition*. Elsevier Saunders, Philadelphia, 2006; pp 344–353.
- Zimmerman LE. Ocular lesions of juvenile xanthogranuloma. Nevoxanthoedothelioma. *Am J Ophthalmol* 1965; 60: 1011–1035.
- Hadden OB. Bilateral juvenile xanthogranuloma of the iris. *Br J Ophthalmol* 1975; 59: 699–702.
- Wertz FD, Zimmerman LE, McKeown CA, et al. Juvenile xanthogranuloma of the optic nerve, disc, retina, and choroid. *Ophthalmology* 1982; 89: 1331–1335.
- Casteels I, Olver J, Malone M, Taylor D. Early treatment of juvenile xanthogranuloma of the iris with subconjunctival steroids. *Br J Ophthalmol* 1993; 77: 57–60.
- Gass JD. Management Of juvenile xanthogranuloma of the iris. *Arch Ophthalmol* 1964; 71: 344–347.
- Harley RD, Romayananda N, Chan GH. Juvenile xanthogranuloma. *J Pediatr Ophthalmol Strabismus* 1982; 19: 33–39.
- Mittelman D, Apple DJ, Goldberg MF. Ocular involvement in Letterer-Siwe disease. *Am J Ophthalmol* 1973; 75: 261–265.
- Rupp RH, Holloman KR. Histiocytosis X affecting the uveal tract. *Arch Ophthalmol* 1970; 84: 468–470.
- Kim IT, Lee SM. Choroidal Langerhans' cell histiocytosis. *Acta Ophthalmol Scand* 2000; 78: 97–100.

# Uveal lymphoproliferative tumors

Sarah E. Coupland

## INTRODUCTION

Lymphoid proliferations of the uvea can be divided into primary uveal tumors and secondary intraocular manifestations of systemic lymphoma. Although the exact frequency of the latter is not known, they are not unusual, particularly in leukemia, where intraocular (mainly choroidal) involvement may occur in as many as 80–90% of patients at some point in the course of the disease.<sup>1–4</sup> The primary uveal lymphoproliferative tumors can be further divided into primary choroidal lymphoma and primary iridal lymphoma.

## PRIMARY CHOROIDAL LYMPHOMA

Approximately 70 cases of primary lymphoproliferations of the choroid have been reported in the literature. They have been the subject of controversy since their original description in 1920<sup>5</sup> and are considered to be *primary* choroidal tumors, owing to the absence of systemic disease at the time of diagnosis and to their unilaterality in most patients.<sup>6</sup> Owing to the usual low-grade nature of these tumors, in the past they were erroneously termed ‘reactive lymphoid hyperplasia’ (RLH)<sup>7</sup> or ‘uveal pseudotumors’.<sup>8</sup> The confusion concerning their nomenclature was further compounded by inherent diagnostic difficulties due to the extranodal location of the primary lymphoproliferations of the choroid, and to their composition predominantly of small lymphocytes. The demonstration of monoclonality within the infiltrating lymphocytes indicated their malignant nature.<sup>6,9</sup> Jakobiec and co-workers recommended that the two terms should be abandoned and the term ‘uveal lymphoid neoplasia’ be adopted.<sup>6</sup> Subsequent investigations, using newer diagnostic methods, such as immunohistology following antigen retrieval, Southern blotting, and polymerase chain reaction for immunoglobulin gene rearrangements (IgH-PCR), have provided further evidence that the majority of these tumors represent low-grade B-cell lymphoma.<sup>10–14</sup> We have recently observed that primary choroidal lymphomas are most accurately subtyped as ‘extranodal marginal zone B-cell lymphomas’ (EMZL) of MALT type (WHO lymphoma classification), as these tumors demonstrate morphological, immunophenotypical, and clinical features similar to EMZL in other locations.<sup>12,15</sup>

**Etiology and pathogenesis** Extranodal marginal zone B-cell lymphomas are in general low-grade B-cell lymphomas, occur in a number of sites, and can be associated with infections (e.g. *Helicobacter pylori* in the stomach<sup>16</sup> and (reportedly) *Chlamydia psittacci* in ocular adnexal lymphomas.<sup>17</sup> Further, they can be associated with autoimmune disease (e.g. Sjögren’s syndrome, Hashimoto’s disease).

However, the etiology and pathogenesis of primary choroidal lymphomas remains unknown. Whether the patients with uveal lymphomas reported in the literature suffered from autoimmune diseases was not noted. Further studies are required to determine the predisposing factors for these tumors.

## Clinical features

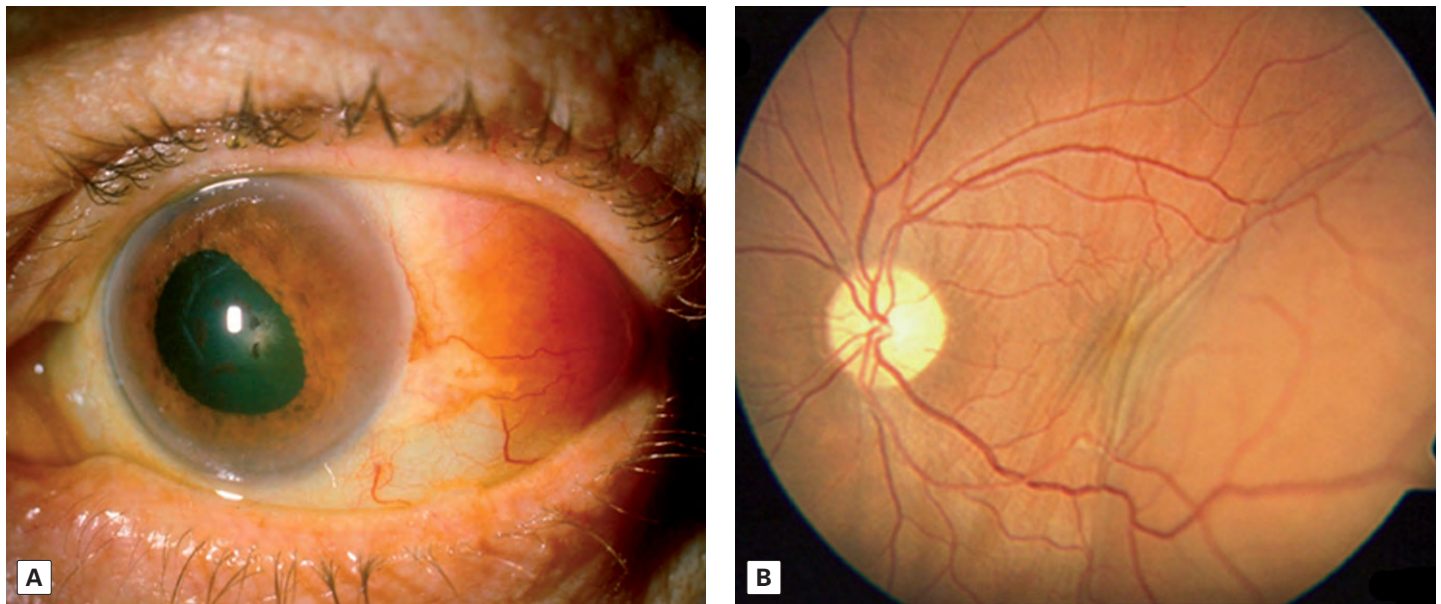
**Symptoms** Primary choroidal lymphoma usually occurs in men in their fifth decade. Typical presenting symptoms include recurrent episodes of blurred vision, painless loss of vision, and metamorphopsia due to secondary serous detachment of the macula.<sup>6,11,12</sup> Late forms of the disease are characterized by symptoms such as narrow-angle glaucoma and eye pain, total or subtotal retinal detachment, and visual acuity reduced to finger counting or worse.<sup>6,11,12</sup>

**Signs** The key early features of primary choroidal lymphoma include creamy choroidal infiltrates on fundus examination and low echogenicity on ophthalmic ultrasound (Fig. 53.1).<sup>6,9</sup> Ultimately, a diffuse thickening of the uveal tract and, in some cases, subconjunctival or episcleral extension can occur (Box 53.1).<sup>7,9,18,19</sup>

**Diagnostic evaluation** In most reported cases of primary choroidal EMZL the eyes were ultimately enucleated, either because of difficulties in determining the nature of the uveal mass clinically, or because of pain as a result of secondary glaucoma. Some authors performed biopsies of the episcleral tumor nodules,<sup>18,19</sup> and either aspirates or biopsies of the choroidal swelling<sup>13,20,21</sup> to establish the diagnosis (Fig. 53.2).

**Histology** The morphological, immunohistochemical, and molecular biological characteristics of primary choroidal lymphomas are similar to those of EMZL in other locations.<sup>16</sup>

**Morphology** Most primary uveal lymphomas demonstrate an expansion of centrocyte-like, monocytoid, and plasmacytoid tumor cells, with occasional blasts in the marginal zone surrounding reactive follicles (Fig. 53.2). The degree of plasmacellular differentiation can be extensive, with a large number of tumor cells with intranuclear collections of immunoglobulin (Dutcher bodies) (Fig. 53.2). Furthermore, in some tumors the neoplastic cells demonstrate ‘follicular colonization,’ a morphological feature commonly observed in EMZL. When arising in tissues associated with mucosa or epithelium, nests of EMZL tumor cells may infiltrate neighboring structures, forming



**Fig. 53.1** The clinical features of a primary choroidal lymphoma. (A) Yellow-orange episcleral and anterior choroidal mass. (Courtesy of Professor B. Damato.) (B) Fundus appearance of a choroidal mass and accompanying exudative retinal detachment. (Courtesy of Professor N. Bornfeld.)

### BOX 53.1 Primary Choroidal Lymphoma

- Prolonged benign course
- Thickened uveal tract with confluent or non-confluent one disc diameter creamy yellow lesions
- Depigmentation of the retinal pigment epithelium with loss of normal choroidal markings
- Anterior segment involvement in the form of fixed salmon-colored epibulbar masses with fine intrinsic vascularity
- **Fluorescein angiography:** early mottled or pinpoint areas of hyperfluorescence of the lesions and late staining at the level of the retinal pigment epithelium
- **Ultrasonography:** choroidal thickening with decreased echogenicity and extrascleral extension with an intact intervening scleral layer. Absence of scleral thickening or retrobulbar edema
- **Computed tomography:** thickening in the region of the mass without calcification, with a corresponding reduction in size of the vitreous cavity
- **Magnetic resonance imaging:** thickening in the region of the mass with a decrease in size of the vitreous cavity

'lymphoepithelial lesions,' a feature indicating the neoplastic nature of these lesions and aiding the differentiation between EMZL and RLH.<sup>13</sup> The malignant nature of the tumor can be supported morphologically by the presence of extrascleral extension and the 'uveal equivalent' of lymphoepithelial lesions (i.e. tumor cells infiltrating Bruch's membrane and the retinal epithelium (Fig. 53.2)).<sup>22</sup>

**Immunohistochemistry** Immunohistochemical studies demonstrate a dominance of B-lymphocytes with expression of B-cell antigens such as CD79a and CD20 (Fig. 53.2). Often the tumor cells display an aberrant expression of the T-cell antigen CD43,<sup>12,13</sup> as well

as monotypic expression of an Ig light and/or heavy chain (Fig. 53.2). The neoplastic cells are negative for CD23, CD5, CD10, BCL-6, and cyclin D1. The absence of expression of these markers is important for the differentiation of primary uveal EMZL from a secondary choroidal infiltration by other small cell B-cell lymphoproliferative disorders, such as B-cell lymphocytic leukemia (CD5+, CD23+, CD10-, BCL-6-, cyclin D1-), mantle cell lymphoma (CD5+, CD23-, CD10-, BCL-6-, cyclin D1+), and follicular lymphoma (CD5-, CD23-, CD10+, BCL-6+, cyclin D1-). The neoplastic plasmacytoid cells usually demonstrate a loss of plasma cell-related antigens compared to reactive plasma cells.<sup>12</sup>

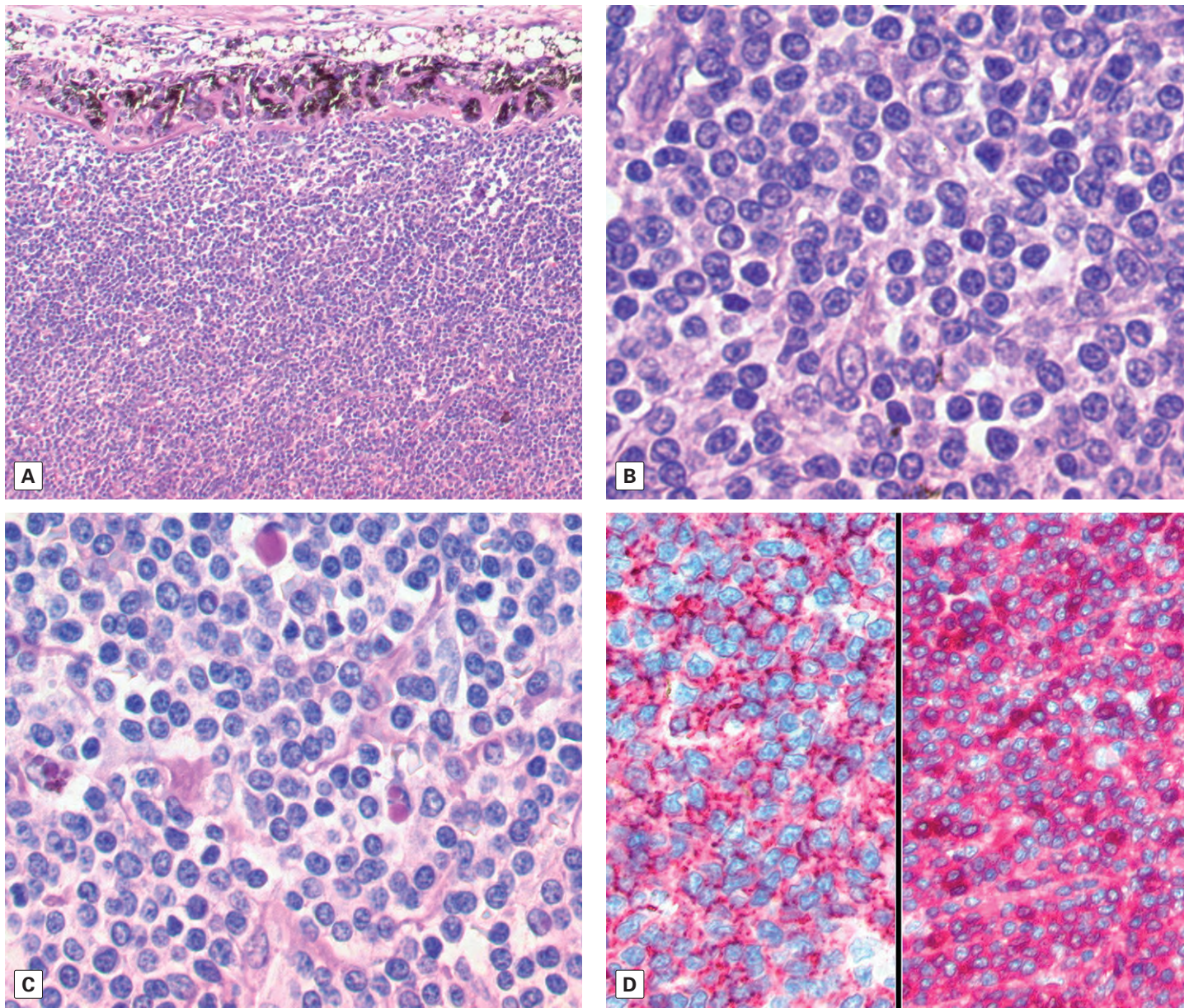
**Clonality analysis** Finally, the neoplastic nature of the B cells in EMZL can be further supported through clonality analysis, which demonstrates a monoclonal B-cell population using IgH-PCR and GeneScan (Fig. 53.3). Through a more detailed analysis of the DNA sequences of the variable (V) region of the immunoglobulin gene obtained from PCR it is possible to define the differentiation stage of the lymphoma cell – that is, whether the tumor cells arose from a pregerminal center cell, a germinal center cell, or a postgerminal center cell.<sup>23–25</sup> Very few molecular biological studies of primary choroidal lymphomas have been performed, mainly due to improper fixation of the enucleation specimens (e.g. glutaraldehyde fixation).<sup>11–13</sup> However, it appears that primary choroidal lymphomas arise from postgerminal center cells, similar to ocular adnexal EMZL.<sup>26</sup>

### DIFFERENTIAL DIAGNOSIS

The differential diagnosis of primary choroidal lymphoma includes diffuse uveal melanoma, uveal effusion syndrome, posterior scleritis,<sup>27,28</sup> and amelanotic choroidal tumors such as choroidal metastasis, choroidal hemangioma, and choroidal osteoma (Table 53.1). Conjunctival lymphoma and choroidal metastases from systemic lymphoma or leukemia should also be differentiated from primary choroidal lymphoma.

The clinical differentiation between primary choroidal lymphoma and diffuse malignant melanoma is difficult. Generally, malignant





**Fig. 53.2** (A) Primary choroidal lymphoma with infiltration and disruption of Bruch's membrane and the RPE; the overlying retina is gliotic. (Hematoxylin & eosin, original magnification  $\times 200$ .) (B) Small centrocyte-like and plasmacytoid cells with occasional blasts are evident. (Hematoxylin & eosin, original magnification  $\times 400$ .) The tumor cells exhibit plasmacellular differentiation with Dutcher bodies (C). (PAS stain, original magnification  $\times 400$ .) (D) In addition, the tumor cells are positive for B-cell antigen, CD20 (left panel; APAAP  $\times 400$  original magnification) and monotypic IgM (right panel; APAAP  $\times 400$  original magnification).

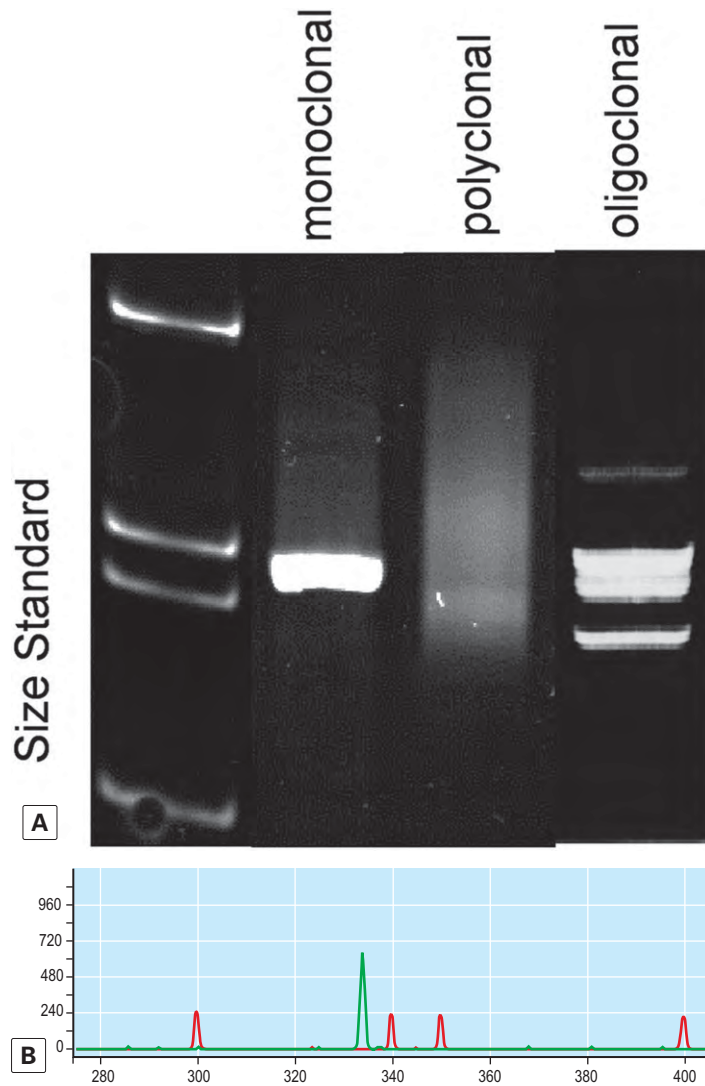
melanoma is pigmented and vascularized, causes disturbance of the retinal pigment epithelium, and grows at a faster rate than primary choroidal lymphoma.<sup>29</sup> Uveal effusion syndrome, characterized by serous detachment of the peripheral choroid, ciliary body, and retina, occurs in men in a similar age group to those developing primary choroidal lymphoma.<sup>30</sup> In contrast to the latter, uveal effusion syndrome is usually bilateral and may be associated with dilated episcleral vessels, vitreous cellular reaction, and 'leopard-spot' retinal pigment epithelial changes.<sup>30</sup> Fluorescein angiography demonstrates little, if any, leakage.<sup>31</sup>

In contrast to primary choroidal lymphoma, posterior scleritis occurs most often in women, and can be associated with autoimmune diseases and can present with pain, erythema, and either a localized or a diffuse thickening in the posterior segment.<sup>31,32</sup> Similar to primary

choroidal lymphoma, an exudative retinal detachment, choroidal folds as well as serous detachment of the choroid may be seen on funduscopy. Further, posterior scleritis can appear as a thickening of the sclera on computed tomography. It usually demonstrates high internal reflectivity on ultrasonography and retrobulbar edema, whereas primary choroidal lymphoma shows low internal reflectivity and is not usually associated with retrobulbar edema.<sup>31</sup>

Choroidal metastases may present with pale white to yellow multiple lesions on funduscopy under a serous detachment without involvement of the retina, superficially resembling primary uveal lymphoma.<sup>33,34</sup> Metastases are usually painless, and in most cases a previous history of cancer can be elicited.<sup>33</sup> Ultrasonography usually demonstrates medium internal reflectivity without retrobulbar edema.<sup>31</sup> Fluorescein angiography reveals irregular widespread leakage





**Fig. 53.3** Electrophoresis gel demonstrating monoclonal, polyclonal and oligoclonal bands (left to right) obtained by using polymerase chain reaction for immunoglobulin gene heavy chain rearrangements (A). The monoclonal band displays a monoclonal peak of 335 base pairs using the primer FR1 (B). (GeneScan). The red signals represent the internal size standard.

in the late phase. Choroidal hemangioma appears as an orange-red solitary mass with cystic degeneration of the overlying retina, or may be diffuse, as in the Sturge-Weber syndrome (see Chapter 49). Choroidal osteoma is a very rare benign ossifying tumor of the choroid that typically occurs in the peripapillary or macular region in young females. On funduscopy an orange-yellow lesion with well-defined scalloped borders is observed (see Chapter 51).

Primary choroidal lymphoma can usually be distinguished from primary malignant lymphoma of the conjunctiva. In the latter entity, the salmon patch lies in the lamina propria and is freely movable. This contrasts with the anterior epibulbar form of primary choroidal lymphoma, where the mass is fixed. The clinical and ultrasonographic appearances may be similar in both primary choroidal lymphoma and secondary uveal lymphomatous or leukemic infiltration. Ocular manifestations are rarely the first sign of disease in malignant lymphoma/leukemia, although the majority (80%) of patients will manifest some choroidal involvement during the course of their disease.<sup>1</sup> Intraocular biopsy or aspirates may be required to establish the diagnosis.<sup>35</sup>

## TREATMENT

It is essential to perform a complete staging investigation, including a complete blood count, serum protein electrophoresis, abdominal and chest CT scanning.<sup>1</sup> Through such staging investigations it is important to exclude the possibility of concurrent systemic disease, e.g. pulmonary EMZL, with secondary infiltration of the uvea. If no systemic disease is found, local treatment is appropriate. This includes excisional biopsy of any epibulbar mass, cryotherapy, and low-dose irradiation in divided doses.<sup>1</sup>

## PROGNOSIS

Primary choroidal lymphomas are less aggressive in their clinical course, with the overall survival of patients being very good.<sup>13</sup>

## PRIMARY IRIDAL LYMPHOMA

Primary iridal lymphomas are exceptionally rare, with approximately 10 cases having been reported in the literature.<sup>2,36-41</sup> We recently encountered primary iridal lymphoma in a 34-year-old patient who presented with uveitis of unclear origin, and ultimately a pseudohypopyon (Fig. 53.4). An anterior chamber tap and iris biopsy were performed, demonstrating a high-grade B-cell lymphoma (Fig. 53.4). No other systemic or cerebral lymphoma manifestation was detected within 6 months of the diagnosis of the iris lymphoma.

**Etiology and pathogenesis** Owing to the extreme rarity of the disease and the minimal amount of material available for diagnostic purposes, molecular biological investigations of primary intraocular lymphomas have not been reported to date.

## Clinical features

**Symptoms** The typical presenting symptoms of primary iridal lymphoma include a painful eye, photophobia, and sometimes decreased vision.<sup>36-41</sup>

**Signs** The clinical signs reported in the literature include uveitis of uncertain origin, nodular or diffuse iridal precipitates, iris discoloration with heterochromia and anisocoria, iridal swelling, and hyphema or pseudohypopyon.<sup>2,36-41</sup>

**Diagnostic evaluation** On ultrasound examination, ill-defined tumors of low-reflectivity can be observed.

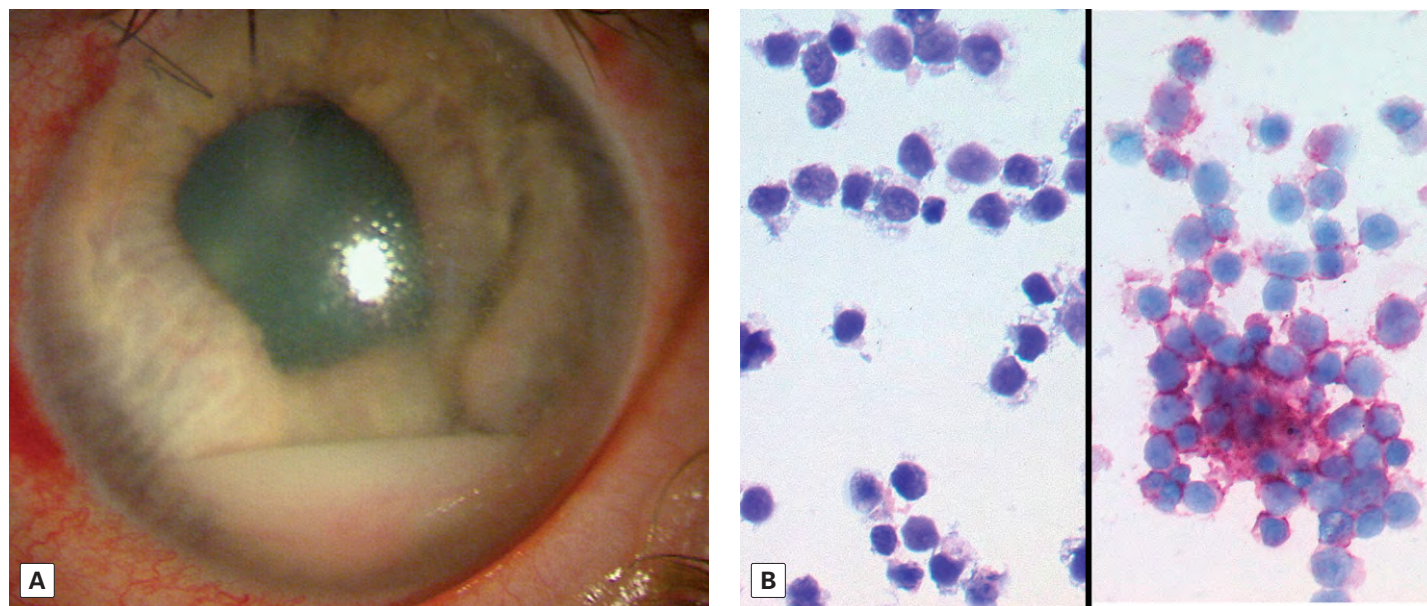
Paracentesis from the anterior chamber and/or iris biopsy with subsequent cytological and histological examination are the two methods employed that usually lead to the establishment of a definitive diagnosis.<sup>37-41</sup>

**Cytology and histology** All described primary iridal lymphomas consisted of sheets of large atypical lymphoid cells with evidence of apoptosis. On immunohistological examination the tumor cells demonstrated either a B- or a T-cell phenotype. The growth fraction of the neoplastic cells, as measured using the Ki-67 antigen, is usually large – approximately 70–90% – indicating that the degree of malignancy is high.

**Differential diagnosis** Manifestations of secondary lymphoma in the iris are more common than in the primary tumors. These can either be a secondary manifestation of a primary choroidal lymphoma, primary intraocular (retinal) lymphoma, or a systemic lymphoma. From our series of 13 cases, we have observed iridal infiltration in five (38%).<sup>12</sup> In a review of 163 patients with primary intraocular (retinal)

**Table 53.1 The differential diagnosis of primary choroidal lymphoma**

Features		Diagnosis				
		<i>Diffuse melanoma</i>	<i>Uveal effusion</i>	<i>Posterior scleritis</i>	<i>Choroidal metastasis</i>	<i>Choroidal lymphoma</i>
Symptoms	Pain	Absent	Absent	Present	Absent	Absent
External examination	Sentinel vessels	Present	Absent	Absent	Usually absent	Usually absent
	Other	Extrascleral extension	Normal	Scleritis	Transcleral metastasis	Salmon patch
Ophthalmoscopy	Mass	Choroidal	Absent	Scleral	Choroidal	Choroidal
	Shape	Diffuse	Dome	Dome	Variable	Variable
	Color	Usually pigmented	Normal choroid	Normal choroid	Yellow	Normal choroid or Yellow
	RPE	Mottled	Mottled	Normal	Mottled	Normal
	Retina	Exudative detachment	Exudative detachment	Exudative detachment	Exudative detachment	Exudative detachment
Ultrasonography	Internal reflectivity	Low	Absent	Medium-high	Medium-high	Low
	Associated findings	Extrascleral extension	Exudative detachment	Retrobulbar edema	Transcleral metastasis or Exudative detachment	Exudative detachment
IVFA	Late Leakage	Present	Absent	Present	Present	Present
Systemic association		Absent	Absent	Autoimmune disease	Carcinoma elsewhere	Absent



**Fig. 53.4** (A) Pseudohypopyon in a 34-year-old woman with primary iridal lymphoma. (B) Anterior chamber aspirate consisting of medium-sized atypical lymphocytes. (Left panel; MGG  $\times 400$  original magnification.) The neoplastic lymphocytes expressed the B-cell antigen CD79a. (Right panel; APAAP  $\times 400$  original magnification.) (Courtesy of Professor N. Bornfeld.)

lymphoma, secondary involvement of the iris was described only in five (3%) cases.<sup>37</sup> Secondary involvement of the iris associated with systemic non-Hodgkin's lymphoma (usually of B-cell type) or leukemia represents the most frequent iridal lymphoma manifestation.<sup>3</sup> Involvement of the iris by T-cell and T/NK-cell lymphoma has also been reported.<sup>26</sup>

Other differential diagnoses of primary iridal lymphoma include lymphoproliferative lesions associated with Epstein-Barr virus, human immunodeficiency virus (HIV) and immunosuppression,<sup>42,43</sup> metastatic carcinoma, amelanotic iris melanoma, juvenile xanthogranuloma, and inflammatory conditions such as endophthalmitis.<sup>44</sup>



## TREATMENT

On establishing the diagnosis of iridal lymphoma staging evaluations must be undertaken to exclude either a systemic non-Hodgkin's lymphoma or a primary central nervous system lymphoma with secondary iridal involvement. On the exclusion of further disease, low-dose irradiation or systemic chemotherapy is the treatment of choice.<sup>39</sup>

## PROGNOSIS

The prognosis of primary iridal lymphoma varies. Most patients develop either systemic or cerebral involvement.<sup>39</sup> In general, those who developed a cerebral or visceral manifestation did worse than those whose tumors disseminated to lymph nodes or the skin.<sup>36,37</sup>

## REFERENCES

1. Augsburger JJ, Greatrex KV. Intraocular lymphoma: clinical presentations, differential diagnosis and treatment. *Trans Am Acad Ophthalmol Otolaryngol* 1989; 41: 796–808.
2. Cooper EL, Riker JL. Malignant lymphoma of the uveal tract. *Am J Ophthalmol* 1951; 34: 1153–1158.
3. Kincaid ME, Green WR. Ocular and orbital involvement in leukemia. *Surv Ophthalmol* 1983; 27: 211–232.
4. Vogel MH, Font RL, Zimmerman LE, Levine RA. Reticulum cell sarcoma of the retina and uvea. Report of six cases and review of the literature. *Am J Ophthalmol* 1968; 66: 205–215.
5. Triebenstein O. Ein Beitrag zur Frage der aleukämischen Augenveränderungen. *Klin Monatsbl Augenheilkd* 1920; 64: 825–836.
6. Jakobiec FA, Sacks E, Kronish JW et al. Multifocal static creamy choroidal infiltrates. An early sign of lymphoid neoplasia. *Ophthalmology* 1987; 94: 397–406.
7. Ryan SJ, Zimmerman LE, King FM. Reactive lymphoid hyperplasia. An unusual form of intraocular pseudotumor. *Trans Am Acad Ophthalmol Otolaryngol* 1972; 76: 652–671.
8. Gass JD. Retinal detachment and narrow-angle glaucoma secondary to inflammatory pseudotumor of the uveal tract. *Am J Ophthalmol* 1967; 64(Suppl): 612–621.
9. Ciulla TA, Bains RA, Jakobiec FA et al. Uveal lymphoid neoplasia: a clinical-pathologic correlation and review of the early form. *Surv Ophthalmol* 1997; 41: 467–476.
10. Ben-Ezra D, Sahel JA, Harris NL et al. Uveal lymphoid infiltrates: immunohistochemical evidence for a lymphoid neoplasia. *Br J Ophthalmol* 1989; 73: 846–851.
11. Cockerham GC, Hidayat AA, Bijwaard KE, Sheng ZM. Re-evaluation of 'reactive lymphoid hyperplasia of the uvea': an immunohistochemical and molecular analysis of 10 cases. *Ophthalmology* 2000; 107: 151–158.
12. Coupland SE, Foss HD, Hidayat AA et al. Extranodal marginal zone B cell lymphomas of the uvea: an analysis of 13 cases. *J Pathol* 2002; 197: 333–340.
13. Coupland SE, Jousseaume A, Anastassiou G, Stein H. Diagnosis of a primary uveal extranodal marginal zone B-cell lymphoma by chorioretinal biopsy: case report. *Graefes Arch Clin Exp Ophthalmol* 2005; 243: 482–486.
14. Grossniklaus HE, Martin DF, Avery R et al. Uveal lymphoid infiltration. Report of four cases and clinicopathologic review. *Ophthalmology* 1998; 105: 1265–1273.
15. Jaffe ES, Harris NL, Stein H, Vardiman JW. World Health Organization classification of tumours. Tumours of haematopoietic and lymphoid tissues. Pathology and genetics. Lyon: IARC Press, 2001.
16. Isaacson PG, Du MQ. MALT lymphoma: from morphology to molecules. *Nat Rev Cancer* 2004; 4: 644–653.
17. Ferreri AJ, Guidoboni M, Ponzoni M et al. Evidence for an association between *Chlamydia psittaci* and ocular adnexal lymphomas. *J Natl Cancer Inst*. 2004; 21: 586–594.
18. Holz FG, Boehmer HV, Mechttersheimer G et al. Uveal non-Hodgkin's lymphoma with epibulbar extension simulating choroidal effusion syndrome. *Retina* 1999; 19: 343–346.
19. Chang TS, Byrne SF, Gass JD et al. Echographic findings in benign reactive lymphoid hyperplasia of the choroid. *Arch Ophthalmol* 1996; 114: 669–675.
20. Cheung MK, Martin DF, Chan CC et al. Diagnosis of reactive lymphoid hyperplasia by chorioretinal biopsy. *Am J Ophthalmol* 1994; 118: 457–462.
21. Gündüz K, Shields JA, Shields CL et al. Transscleral choroidal biopsy in the diagnosis of choroidal lymphoma. *Surv Ophthalmol* 1999; 43: 551–555.
22. Isaacson P, Wright DH. Malignant lymphoma of mucosa-associated lymphoid tissue: a distinctive type of B-cell lymphoma. *Cancer* 1983; 52: 1410–1416.
23. Berek C, Berger A, Apel M. Maturation of the immune response in germinal centers. *Cell* 1991; 67: 1121–1129.
24. Jacob J, Kelsøe G, Rajewsky K, Weiss U. Intracloacal generation of antibody mutants in germinal centres [see comments]. *Nature* 1991; 354: 389–392.
25. Kelsøe G. The germinal center: a crucible for lymphocyte selection. *Semin Immunol* 1996; 8: 179–184.
26. Coupland SE, Foss HD, Anagnostopoulos I et al. Immunoglobulin VH gene expression among extranodal marginal zone B-cell lymphomas of the ocular adnexa. *Invest Ophthalmol Vis Sci* 1999; 40: 555–562.
27. Hunyor AP, Harper CA, O'Day J, McKelvie PA. Ocular-central nervous system lymphoma mimicking posterior scleritis with exudative retinal detachment. *Ophthalmology* 2000; 107: 1955–1959.
28. Gaucher D, Bodaghi B, Charlotte F et al. Lymphome oculaire de type MALT simulant une sclérite ou une uvéite postérieure. *J Fr Ophtalmol* 2005; 28: 31–38.
29. Font RL, Spaulding A, Zimmerman L. Diffuse malignant melanoma of the uveal tract: a clinicopathological report of 54 cases. *Trans Am Acad Ophthalmol Otolaryngol* 1968; 72: 877–895.
30. Gass JD, Jallow S. Idiopathic serous detachment of the choroid, ciliary body and retina (uveal effusion syndrome). *Ophthalmology* 1982; 89: 1018–1032.
31. Benson WE. Posterior scleritis. *Surv Ophthalmol* 1988; 32: 297–316.
32. McCluskey PJ, Watson PG, Lightman S et al. Posterior scleritis: clinical features, systemic associations, and outcome in a large series of patients. *Ophthalmology* 1999; 106: 2380–2386.
33. Shields CL, Shields JA, Gross NE et al. Survey of 520 eyes with uveal metastases. *Ophthalmology* 1997; 104: 1265–1276.
34. Kreusel K-M, Bechrakis N, Wiegel T et al. Klinische Charakteristika der Aderhautmetastasierung. *Ophthalmologie* 2003; 100: 681–622.
35. Bechrakis NE, Foerster MH, Bornfeld N. Biopsy in indeterminate intraocular tumors. *Ophthalmology* 2002; 109: 235–242.
36. Coupland SE, Foss HD, Assaf C et al. T-cell and T/natural killer-cell lymphomas involving ocular and ocular adnexal tissues: a clinicopathologic, immunohistochemical, and molecular study of seven cases. *Ophthalmology* 1999; 106: 2109–2120.
37. Velez G, de Smet MD, Whitcup SM et al. Iris involvement in primary intraocular lymphoma: report of two cases and review of the literature. *Surv Ophthalmol* 2000; 44: 518–526.
38. Goldley SH, Stern GA, Oblon DJ et al. Immunophenotypic characterization of an unusual T-cell lymphoma presenting as anterior uveitis. A clinicopathologic case report. *Arch Ophthalmol* 1989; 107: 1349–1353.
39. Lobo A, Larkin G, Clark BJ et al. Pseudo-hypopyon as the presenting feature in B-cell and T-cell intraocular lymphoma. *Clin Exp Ophthalmol* 2003; 31: 155–158.
40. Yahalom C, Cohen Y, Averbukh E et al. Bilateral iridociliary T-cell lymphoma. *Arch Ophthalmol* 2002; 120: 204–207.
41. Yamada K, Hirata A, Kimura A, Tanihara H. A case of primary B-cell type non-Hodgkin lymphoma originating in the iris. *Am J Ophthalmol* 2003; 136: 380–382.
42. Brodsky MC, Casteel H, Barber LD et al. Bilateral iris tumors in an immunosuppressed child. *Surv Ophthalmol* 1991; 36: 217–222.
43. Mathur R, Lim W-K, Chan CC, Chee S-P. Reactive iris lymphoid proliferation presenting as the AIDS-defining event in an HIV patient with systemic lymphoma. *AIDS* 2004; 18: 2215–2216.
44. Green WR. Uveal tract. In: Spencer WH, ed. *Ophthalmic pathology: an atlas and textbook*, 3rd edn. Philadelphia: WB Saunders, 1986.

# Uveal metastatic tumors

Norbert Bornfeld

## INTRODUCTION

Historically, metastatic tumors to the uvea were considered to be rare<sup>1</sup> and most ophthalmologists would consider uveal melanoma to be the most common intraocular malignancy. Numerous studies in the last 30 years, however, have shown that cancer metastasis to the uvea is by far the most frequent intraocular tumor, and that often the ophthalmologist is the first physician to detect disseminating cancer because uveal metastasis is the first presenting symptom.

## INCIDENCE AND PREVALENCE

Autopsy studies have shown that ocular metastases occurs in 9.3% of all fatal cases of cancer.<sup>2</sup> Clinical series demonstrated that up to 38% of all patients with breast carcinoma who have ocular symptoms may have choroidal metastases.<sup>3</sup> More extensive clinical studies showed that choroidal metastasis occurs predominantly in patients in whom systemic metastases involve more than one organ system, resulting in a risk of developing ocular metastasis of approximately 11% in these patients.<sup>4</sup> Consequently, uveal metastasis is considered to be the most frequent intraocular malignancy, with an estimated annual incidence of 20 000 patients in the United States.

**Clinical features** Metastatic tumors may occur anywhere in the uvea, including the iris, ciliary body, and choroid. The vast majority of metastatic tumors, however, develop in the choroid, whereas metastases to the iris are relatively rare. Metastasizing breast cancer accounts for more than half of all patients with a clinical diagnosis of uveal metastasis,<sup>5</sup> and can even occur in men (Table 54.1).<sup>6</sup> In a quarter of all patients with choroidal metastases cancer of the lung is the underlying primary tumor. Other primary tumors, such as carcinoma tumor, cancer of the gastrointestinal tract, thyroid, prostate, cutaneous melanoma, and renal cell carcinoma, rarely metastasize to the uvea. Sarcomas only very exceptionally lead to uveal metastasis.

Choroidal metastases usually occur in a setting of a pre-existing primary tumor, e.g. in breast cancer.<sup>5</sup> It may also occur as the initial manifestation of a metastasizing primary tumor.<sup>7</sup> Choroidal metastases from an unknown or undetectable primary tumor is uncommon, although some authors have reported a frequency of one in five patients with uveal metastasis.<sup>8</sup> Evaluation of patients presenting with a choroidal metastasis as the first symptom most frequently detects bronchial carcinoma as the primary tumor.<sup>9</sup>

**Symptoms** Blurred vision, floaters and photopsia are the key symptoms of choroidal metastasis and are related to the intraocular mass itself as well as the associated exudative retinal detachment.

Large metastatic tumors of the ciliary body and the iris may obscure the optical axis and impair vision. Large untreated metastatic tumors eventually result in secondary glaucoma and loss of function. One-third of all patients have a visual acuity of less than 6/60 in the affected eye at the time of presentation.<sup>8</sup> In metastatic tumors to the iris, typical symptoms are related to secondary glaucoma, which is found in 38% of patients, and blurred vision caused by the tumor or associated hemorrhages in the anterior chamber.<sup>10</sup>

Uveal metastasis can be asymptomatic. Screening of patients with metastasizing breast cancer have shown that up to 11% of all patients had asymptomatic choroidal metastases,<sup>4,11</sup> emphasizing the need for screening those with identified risk factors for uveal metastasis (such as lung or brain metastasis).

## Signs

**Choroidal metastasis** Frequently, choroidal metastases are bilateral and multifocal (Box 54.1). At presentation up to one-quarter of all patients have metastatic tumors in both eyes.<sup>8</sup> Choroidal metastases are located preferentially at the posterior pole. The macula is involved in 42% of eyes.<sup>9</sup> Choroidal metastatic tumors may appear in three different forms:

- Flat, amelanotic tumor with indistinct margins (Fig. 54.1)
- Flat, pigmented tumor with indistinct margins (Fig. 54.2)
- Amelanotic dome-shaped tumor (Fig. 54.3).

Melanotic dome-shaped tumor as a result of uveal metastasis from cutaneous melanoma is clinically indistinguishable from primary choroidal melanoma (Fig. 54.4). The presence of widespread metastasis from cutaneous melanoma and rapid growth of intraocular tumor is usually evident.

**Iris and ciliary body metastasis** Typical signs of metastatic tumors to the iris include uni- or multifocal, non-pigmented, sometimes vascularized tumors with associated anterior chamber inflammation, hyphema, and pseudohypopyon (i.e. layering of tumor cells).<sup>10</sup> The tumor, which may be located in the chamber angle or on the surface of the iris, usually undergoes rapid growth (Fig. 54.5).

## DIAGNOSTIC EVALUATION

**Fluorescein and indocyanine angiography** may be helpful in distinguishing choroidal metastases from uveal melanoma. Typical angiographic characteristics are lack of early blockage, mottling of

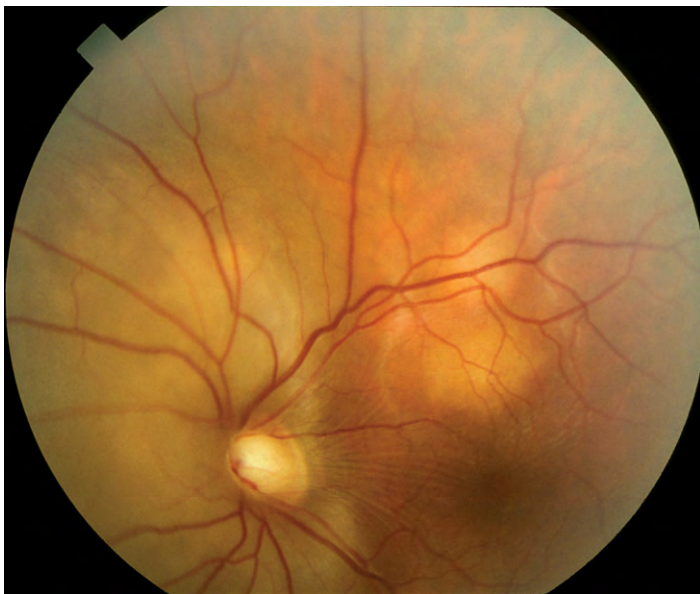**Table 54.1 Primary tumors that metastasize to the uvea**

Primary site	Frequency (%)
Breast carcinoma	47
Lung carcinoma	21
Gastrointestinal tract carcinoma	4
Renal cell carcinoma	2
Cutaneous melanoma	2
Prostate carcinoma	2
Other tumors	4
Unknown	18

Note that sarcoma only very exceptionally metastasizes to the uvea. (Modified with permission from Shields CL, Shields JA, Gross NE et al. Survey of 520 eyes with uveal metastases. *Ophthalmology* 1997; 104: 1265–1276)

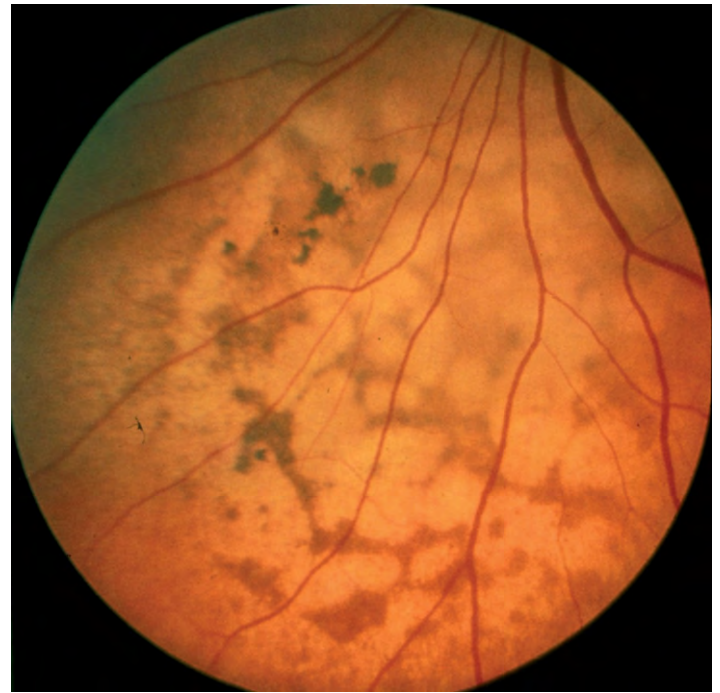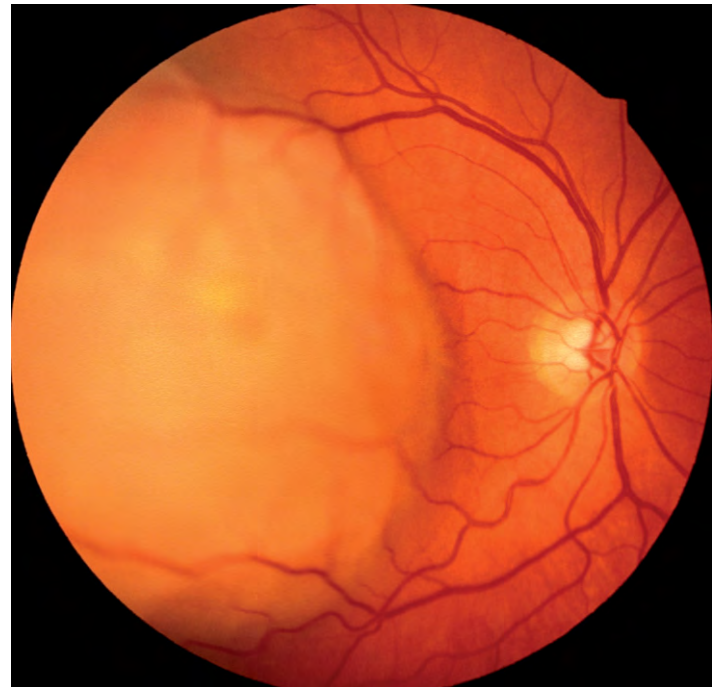**BOX 54.1 Features of Choroidal Metastasis**

- Uni- or multifocal yellow white tumors, mostly at the posterior pole
- Exudative retinal detachment
- No tumor vessels on fluorescein angiography
- Rapid growth if untreated

**Fig. 54.1** Multifocal choroidal metastases in a patient with disseminated breast cancer.

pigment on the surface of the tumor, lack of intrinsic tumor vessels, and late pooling of the dye (Fig. 54.6). In contrast, choroidal melanoma demonstrates early blockage, intrinsic tumor vessels, and late pooling of dye.

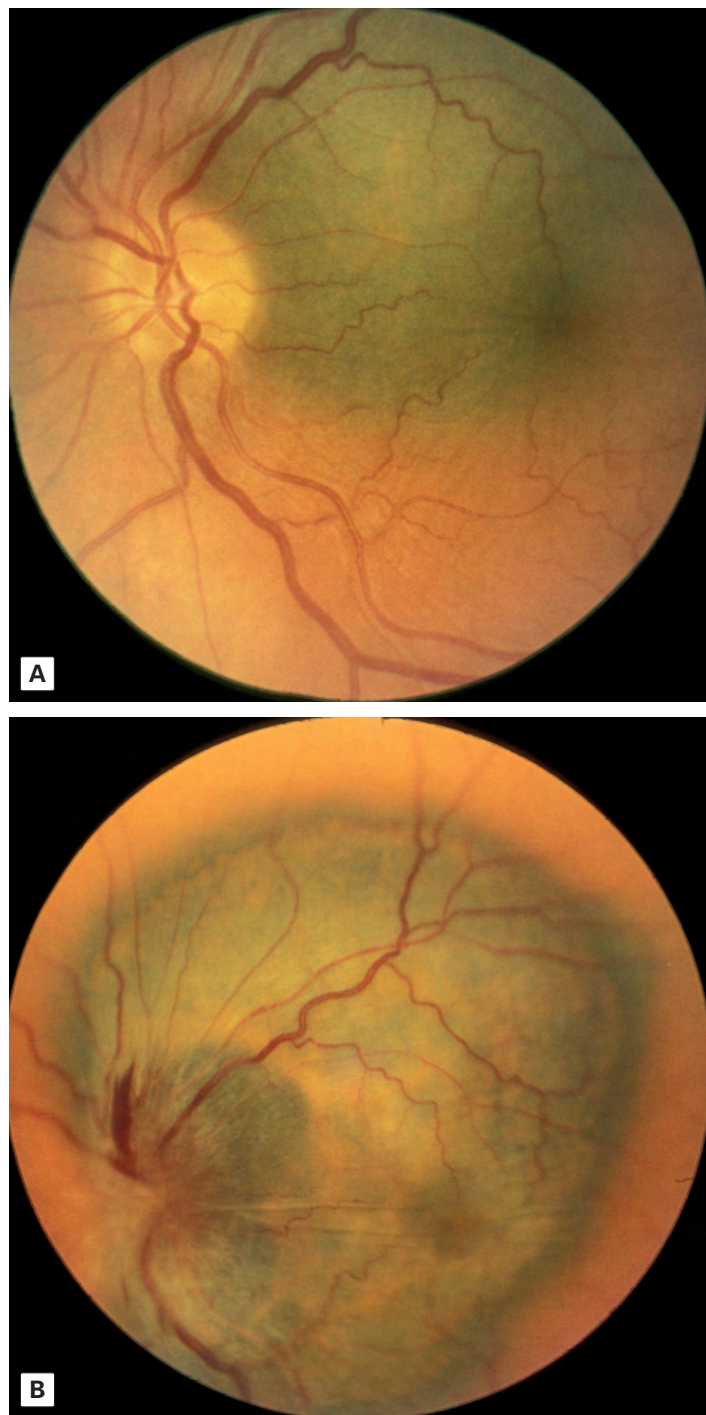
**Ultrasonography** is helpful in detecting the intraocular mass, particularly in cases where an extensive exudative retinal detachment is present. Metastatic lesions may have extremely variable reflectivity. Therefore, ultrasonography may not be diagnostic.<sup>9</sup>

**Fig. 54.2** Flat, pigmented metastatic tumor in the choroid with typical pigmentary pattern on the tumor surface.**Fig. 54.3** Amelanotic, dome-shaped metastatic tumor in the choroid in a patient with metastasizing cancer of the lung.

**Magnetic resonance imaging** In doubtful cases, magnetic resonance imaging may be helpful in detecting an intraocular mass but is not helpful in differentiating metastasis from other intraocular tumors, such as uveal melanoma.

**Biopsy** Intraocular biopsy of a suspected lesion is indicated when the diagnosis cannot be ascertained by other, less invasive procedures. Additionally, intraocular biopsy may be required when the primary tumor is undetectable on systemic evaluation. In such cases,

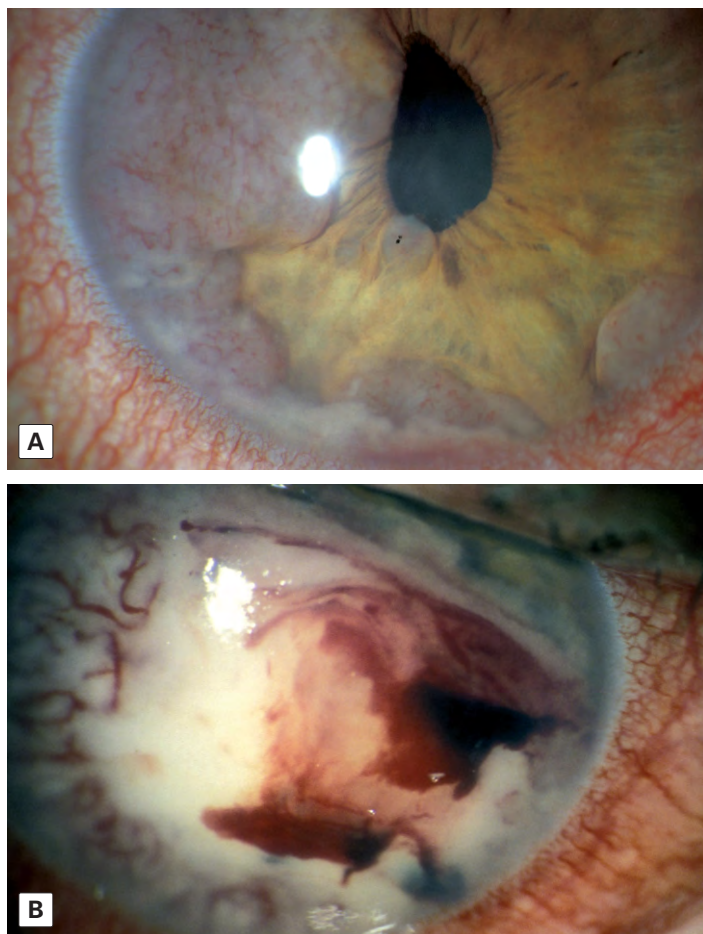




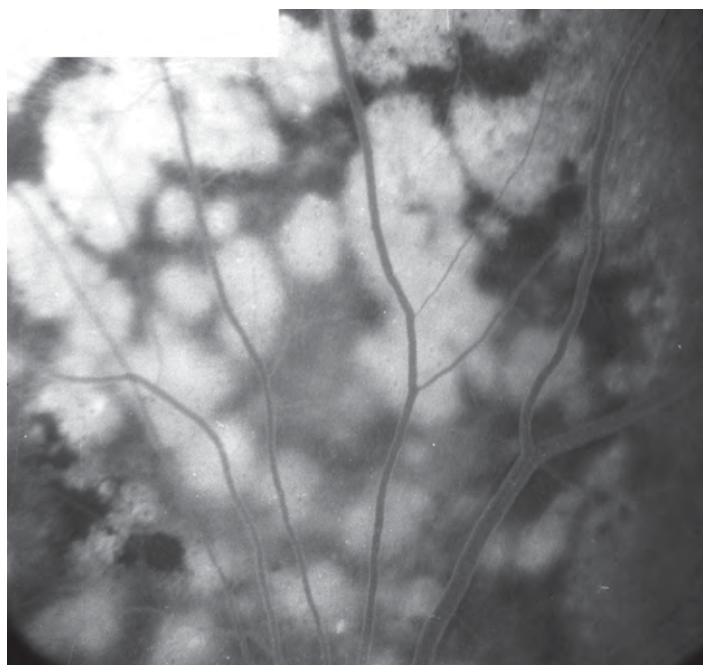
**Fig. 54.4** Melanotic, dome-shaped metastatic choroidal tumor from a primary cutaneous melanoma, which is ophthalmoscopically indistinguishable from a primary choroidal melanoma (A). Massive tumor growth 3 months later (B).

histopathological characterization of the intraocular metastasis can facilitate identification of the primary tumor.<sup>12</sup>

Despite concerns that intraocular biopsy of a malignant tumor may result in tumor seeding along the needle tract and also severe vitreoretinal complications, modern techniques are relatively safe and can be very useful in selected cases.<sup>13</sup> Several surgical techniques using either a trans-scleral or a transretinal approach permit the extraction of informative samples from a suspicious intraocular mass. Fine-needle



**Fig. 54.5** Iris metastases from a bronchial carcinoma (A). Three months later, massive tumor growth nearly fills the anterior chamber (B).



**Fig. 54.6** Fluorescein angiograph of a choroidal metastasis demonstrating characteristic early blockage and a mottled appearance.

aspiration biopsy (FNAB) is performed via a pars plana approach using a 25-gauge needle attached to a 10 mL syringe. FNAB of choroidal lesions can also be carried out by the direct trans-scleral approach. Alternative techniques include a three-port vitrectomy system with transretinal biopsy of the tumor using a 25G vitreous cutter or special forceps, resulting in specimens with preserved histological structure rather than single cells.

## DIFFERENTIAL DIAGNOSIS

The differential diagnosis of uveal metastasis includes all other intraocular tumors, and in particular amelanotic choroidal melanoma. Findings suggestive of a diagnosis of uveal melanoma rather than metastasis are: pigmentation, 'double circulation' (retinal vessels overlying clearly identifiable tumor vessels), unifocal location, mushroom shape, and slow tumor growth. None of these findings are pathognomonic; therefore, in doubtful cases a tumor biopsy may be necessary. Other tumors that can mimic a metastatic tumor to the choroid, such as leiomyoma, melanocytoma, and schwannoma, are exceedingly rare. Secondary infections in immunosuppressed individuals can cause infective chorioretinitis and endogenous endophthalmitis, which should also be considered in the differential diagnosis, especially when the clinical features are atypical.

## TREATMENT

The decision to treat metastasis is made in consultation with the oncologist and radiation oncologist. At the outset, systemic evaluation is performed to determine the extent of metastasis, particularly involvement of the brain, by appropriate imaging techniques, serum markers, and bone marrow biopsy (if indicated). The extent of metastatic disease may be classified as diffuse (i.e. widespread to several organs in addition to uvea), focal (i.e. confined to uvea), or local (i.e. a solitary focus in the uvea) (Fig. 54.7). If the metastatic disease is diffuse then the treatment options include chemotherapy, hormonal therapy (for hormone-dependent tumors), immune modulation, angiogenic inhibitors, and hospice care for the terminally ill. Radiotherapy is usually recommended for focal disease (confined to the uvea). The localized disease may be treated by plaque radiotherapy. Surgical treatment may be necessary for painful eyes with secondary glaucoma.

**Chemotherapy** There is an extensive discussion in the literature as to whether chemotherapy alone is sufficient to treat intraocular metastasis. There is, however, clear evidence that chemotherapy may lead to complete regression of choroidal metastases in disseminated breast cancer (Fig. 54.8).<sup>14</sup> Chemotherapy alone or in combination with radiotherapy may be considered on an individual basis.

**Radiotherapy** The efficacy of external beam radiotherapy in the treatment of choroidal metastases has been shown in several studies.

**External beam radiotherapy** The standard procedure makes use of asymmetric unilateral or bilateral fields generated by a linear accelerator, with a target volume dose of 35–40 Gy in 20 fractions. Using this approach visual acuity can be improved or stabilized in 86% of patients.<sup>15</sup> Immediate complications of external beam therapy, such as erythema and conjunctivitis, are usually mild and transient. As the overall survival rate is poor, late complications of radiotherapy, such as cataract, are not experienced by most patients.

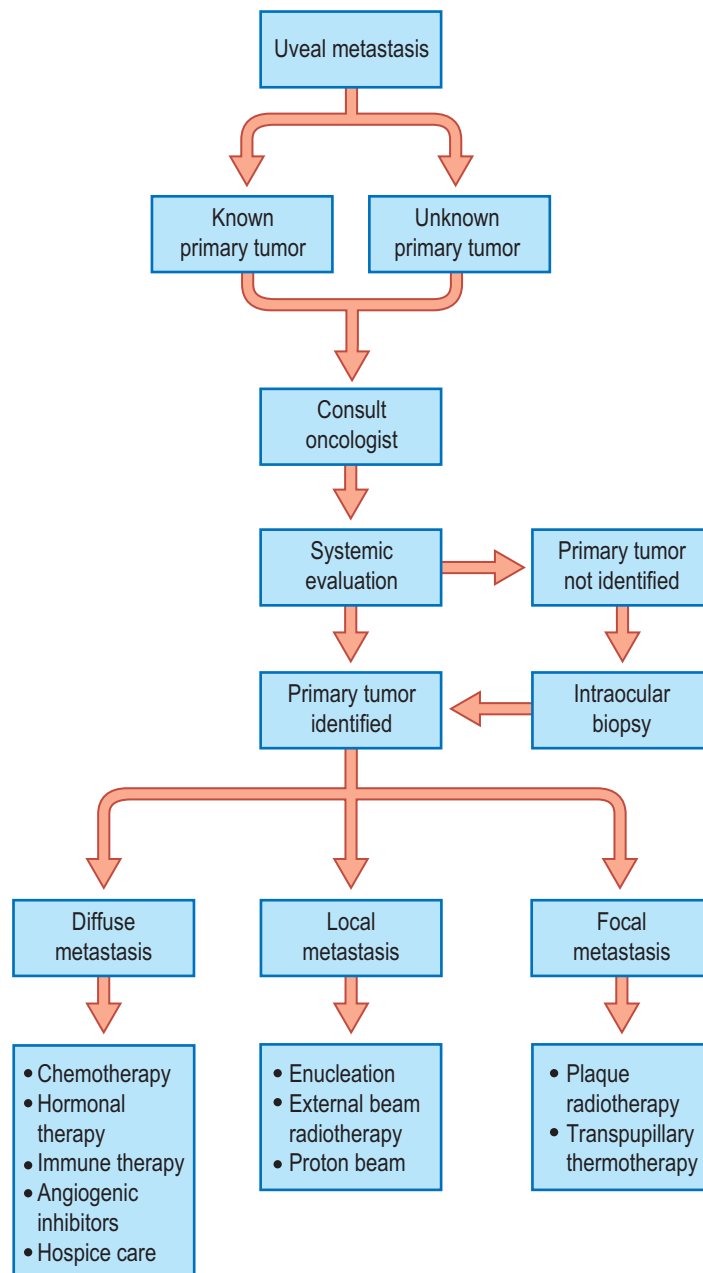


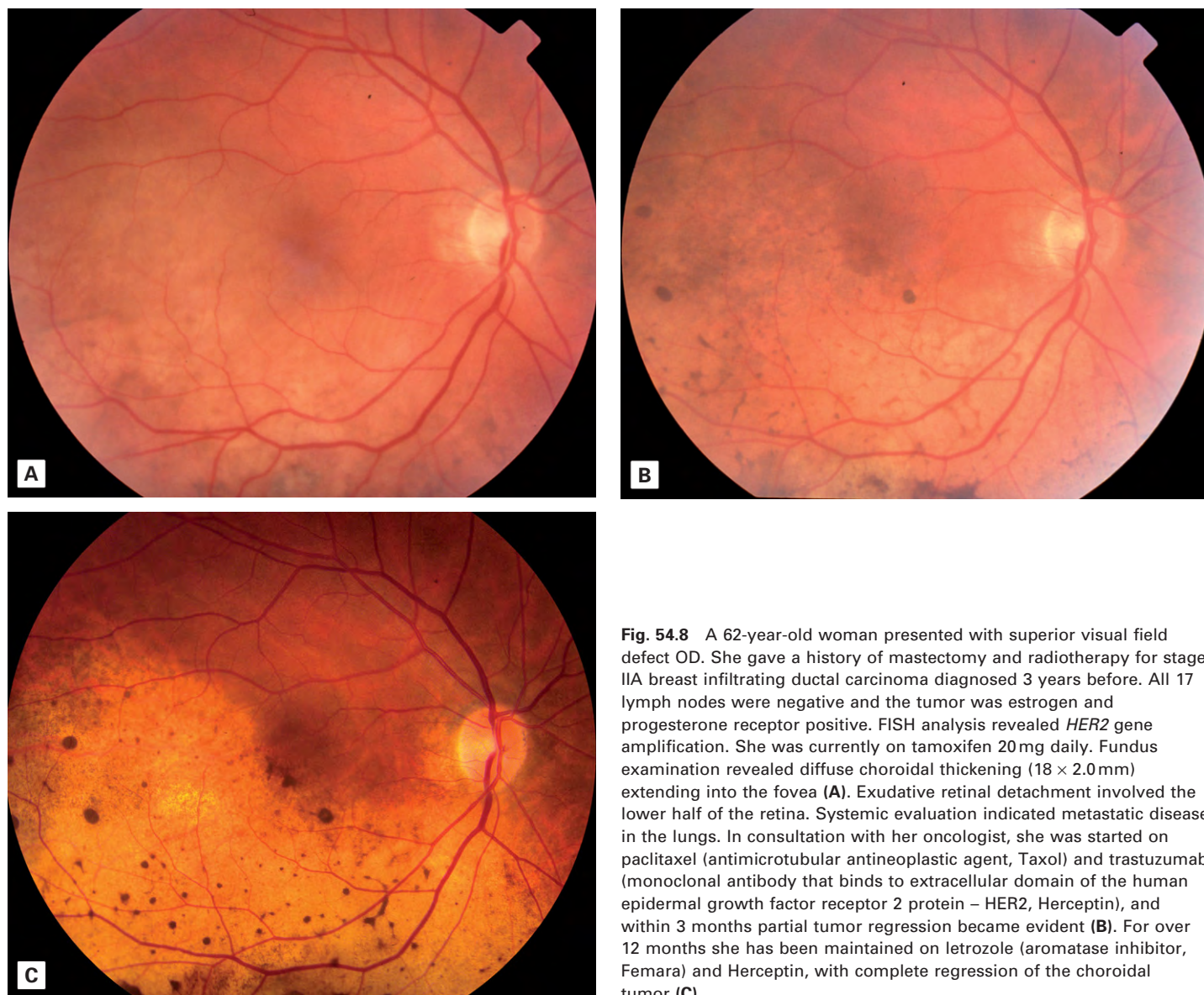
Fig. 54.7 Steps in management of uveal metastasis.

**Proton beam radiotherapy** Some authors have reported the treatment of metastatic tumors to the choroid with proton beam irradiation.<sup>16</sup> Although proton treatment is effective in treating choroidal metastases, there is no documented benefit over external beam radiotherapy to justify the excessive cost of proton treatment.

**Plaque radiotherapy** Selected solitary metastatic tumors to the choroid can be treated with a radioactive plaque,<sup>17,18</sup> which has the advantage of a shorter interval and a more target-oriented delivery than external beam radiotherapy. Consequently, brachytherapy of choroidal tumors is limited to unilateral solitary tumors.

**Thermotherapy** A few patients have been treated with transpupillary thermotherapy, with encouraging preliminary results.<sup>19</sup> Wide





**Fig. 54.8** A 62-year-old woman presented with superior visual field defect OD. She gave a history of mastectomy and radiotherapy for stage IIA breast infiltrating ductal carcinoma diagnosed 3 years before. All 17 lymph nodes were negative and the tumor was estrogen and progesterone receptor positive. FISH analysis revealed *HER2* gene amplification. She was currently on tamoxifen 20 mg daily. Fundus examination revealed diffuse choroidal thickening ( $18 \times 2.0$  mm) extending into the fovea (**A**). Exudative retinal detachment involved the lower half of the retina. Systemic evaluation indicated metastatic disease in the lungs. In consultation with her oncologist, she was started on paclitaxel (antimicrotubular antineoplastic agent, Taxol) and trastuzumab (monoclonal antibody that binds to extracellular domain of the human epidermal growth factor receptor 2 protein – HER2, Herceptin), and within 3 months partial tumor regression became evident (**B**). For over 12 months she has been maintained on letrozole (aromatase inhibitor, Femara) and Herceptin, with complete regression of the choroidal tumor (**C**).

safety margins are needed, as extensive invisible lateral extension may be present.

**Surgery** The only surgical approach is enucleation in advanced cases with loss of function and painful secondary glaucoma. In all other cases an eye salvaging treatment modality should be attempted to avoid enucleation, considering that the patient has a limited life expectancy.

## PROGNOSIS

Treatment of choroidal metastases with radiotherapy and/or systemic chemotherapy is very effective, preserving vision in most cases. The prognosis in terms of survival, however, is poor. Several studies have shown that the median survival of all patients with uveal metastasis is as little as 7 months.<sup>5,15,20</sup>

## REFERENCES

- Ferry AP. Metastatic carcinoma of the eye and ocular adnexa. *Int Ophthalmol Clin* 1967; 7: 615–658.
- Nelson CC, Hertzberg BS, Klintworth GK. A histopathologic study of 716 unselected eyes in patients with cancer at the time of death. *Am J Ophthalmol* 1983; 95: 788–793.
- Mewis L, Young SE. Breast carcinoma metastatic to the choroid. Analysis of 67 patients. *Ophthalmology* 1982; 89: 147–151.
- Wiegel T, Kreusel KM, Bornfeld N et al. Frequency of asymptomatic choroidal metastasis in patients with disseminated breast cancer: results of a prospective screening programme. *Br J Ophthalmol* 1998; 82: 1159–1161.
- Demirci H, Shields CL, Chao AN, Shields JA. Uveal metastasis from breast cancer in 264 patients. *Am J Ophthalmol* 2003; 136: 264–271.
- Kreusel KM, Heimann H, Wiegel T et al. Choroidal metastasis in men with metastatic breast cancer. *Am J Ophthalmol* 1999; 128: 253–255.
- Williams NJ, Leris AC, Kouriefs C et al. Choroidal metastasis – the initial presentation of breast carcinoma. *Eur J Surg Oncol* 2000; 26: 817–818.
- Shields CL, Shields JA, Gross NE et al. Survey of 520 eyes with uveal metastases. *Ophthalmology* 1997; 104: 1265–1276.
- Kreusel KM, Bechrakis N, Wiegel T et al. Klinische Charakteristika der Aderhautmetastasierung. *Ophthalmologie* 2003; 100: 618–622.



10. Shields JA, Shields CL, Kiratli H, de Potter P. Metastatic tumors to the iris in 40 patients. *Am J Ophthalmol* 1995; 119: 422–430.
11. Fenton S, Long V, Kennedy S, Curtin DM. Metastatic adenocarcinoma presenting as an isolated ciliary body tumour. *Eye* 1997; 11: 939–940.
12. Augsburger JJ. Diagnostic biopsy of selected intraocular tumors. *Am J Ophthalmol* 2005; 140: 1094–1095.
13. Bechrakis NE, Foerster MH, Bornfeld N. Biopsy in indeterminate intraocular tumors. *Ophthalmology* 2002; 109: 235–242.
14. Amer R, Pe'er J, Chowers I, Anteby I. Treatment options in the management of choroidal metastases. *Ophthalmologica* 2004; 218: 372–377.
15. Wiegel T, Bottke D, Kreusel KM et al. External beam radiotherapy of choroidal metastases – final results of a prospective study of the German Cancer Society (ARO 95–08). *Radiother Oncol* 2002; 64: 13–18.
16. Tsina EK, Lane AM, Zacks DN et al. Treatment of metastatic tumors of the choroid with proton beam irradiation. *Ophthalmology* 2005; 112: 337–343.
17. Lim JI, Petrovich Z. Radioactive plaque therapy for metastatic choroidal carcinoma. *Ophthalmology* 2000; 107: 1927–1931.
18. Shields CL, Shields JA, De Potter P et al. Plaque radiotherapy for the management of uveal metastasis. *Arch Ophthalmol* 1997; 115: 203–209.
19. Kiratli H, Bilgic S. Thermotherapy in the management of choroidal metastases. *Eur J Ophthalmol* 2004; 14: 423–429.
20. d'Abbadie I, Arriagada R, Spielmann M, Le MG. Choroid metastases: clinical features and treatments in 123 patients. *Cancer* 2003; 98: 1232–1238.

# Intraocular manifestations of proliferative hematopoietic disorders

Hayyam Kiratli

## INTRODUCTION

Hematopoietic disorders encompass a wide variety of neoplastic and non-neoplastic diseases of erythrocytes, leukocytes, and platelets, and their precursors. The World Health Organization classifies hematological malignancies according to cell lineage: myeloid, lymphoid, histiocytic/dendritic, and mast cells.<sup>1</sup> Many hematological neoplasms originate from early precursor cells and the genetic abnormality determines the stage of differentiation. This chapter will focus on the effects of myeloid hematological malignancies on intraocular tissues. Uveal lymphoproliferative tumors are discussed in Chapter 53.

## LEUKEMIAS

The leukemias are malignancies of myelogenous and lymphocytic leukocyte precursors, which develop in the bone marrow and are characterized by the spread of leukemic blast cells to the circulation, liver, spleen, and lymph nodes.<sup>2</sup> The current diagnosis and classification of leukemias are based on peripheral blood and bone marrow examinations using morphological criteria, immunophenotyping, cytochemical features, and detection of genetic abnormalities (Table 55.1). Traditionally, leukemias are grouped into acute and chronic forms and according to the predominant cellular phenotype. Acute leukemias have a rapid onset with signs of bone marrow failure and multiorgan involvement, whereas chronic leukemias have a relatively indolent course.<sup>2</sup> The orbit (including the eye) is the third most commonly affected extramedullary site, following leukemic involvement of the meninges and testes.

### Systemic features

**Acute myelogenous leukemia (AML)** evolves from a single mutant pluripotential cell, which has the capability to differentiate to erythroid, megakaryocytic, or granulocytic progenitors, the last being the predominant type in most cases.<sup>2</sup>

Most patients are older than 60 years; however, AML is the most common neonatal or congenital leukemia and constitutes 15–20% of childhood leukemias.<sup>3</sup> Risk factors include exposure to radiation and benzene; genetic diseases such as Down's syndrome, Fanconi's anemia and Bloom's syndrome; and previous treatment with cytotoxic agents.<sup>2</sup> Frequently associated chromosomal abnormalities are t(15;17) (q22;q12), t(8;21) (q22;q22), and inv(16) (p13;q22).<sup>4</sup>

The early clinical manifestations of the disease are pallor, fatigue, easy bruising, and mucosal bleeding, appearing when the malignant cell number is enough to suppress normal hematopoiesis.<sup>5</sup>

**Acute lymphoblastic leukemia (ALL)** originates from a single B- or T-lymphocyte progenitor cell. This is the most common malignancy diagnosed under the age of 15 years, and 75% of cases occur before the age of 6.<sup>2,3</sup> There is a bimodal distribution, the first peak occurring between the age of 2 and 5 years, with the incidence rising again after the age of 50.<sup>5</sup> Risk factors include Down's syndrome, ataxia–telangiectasia, prenatal exposure to ionizing radiation, and possibly late exposure to common infections.<sup>6</sup> Reciprocal translocation between chromosomes 9 and 22 [t(9;12) (q32;q11)] is the most frequent cytogenetic abnormality in adults, whereas t(12;21) abnormality is more common in children.<sup>5</sup> Current evidence indicates that most translocations leading to childhood leukemias (including TEL-AML1-positive ALL, hyperplod ALL, and T-lineage ALL) originate in utero.<sup>7</sup>

Common presenting symptoms and signs include fever, anemia-related complaints, bone pain (particularly in children), and petechiae.<sup>2</sup>

**Chronic myelogenous leukemia (CML)** results from malignant transformation of a single hematopoietic stem cell. The Philadelphia chromosome (22q-), formed by a reciprocal translocation between chromosomes 9 and 22, is present in 90% of cases. The mutations of the ABL gene on chromosome 9 and the BCR gene on chromosome 22 lead to the formation of the BCR-ABL fusion gene, which encodes a fusion protein p210, a key factor in the development of CML.<sup>8,9</sup>

Usually seen in the elderly, CML constitutes 15% of all leukemias and only 3% of childhood leukemias.<sup>2,8</sup> Exposure to very high doses of radiation may increase the incidence of CML.

Easy fatigability, abdominal discomfort, weight loss, and splenomegaly are the common presenting signs and symptoms. A number of patients are diagnosed coincidentally during routine examination.<sup>9</sup>

**Chronic lymphocytic leukemia (CLL)** results from the proliferation of mature-appearing CD5+ B lymphocytes. The most frequent cytogenetic abnormality is del 13q14-23.1. The disease represents 30% of all leukemias and 90% of patients are over 50 years of age.<sup>2</sup> CLL is often associated with acquired immunodeficiency, and autoimmune diseases such as hemolytic anemia and thrombocytopenic purpura are common.<sup>10</sup>

Most patients present with lymphadenopathy, hepatosplenomegaly, and mild symptoms. There is an increased rate of second cancers,

**Table 55.1 Classification of leukemias<sup>a</sup>**

Acute Myeloid Leukemia (AML)	AML with recurrent cytogenetic abnormalities
	AML with multilineage dysplasia
	AML with myelodysplastic syndrome; therapy related
	AML not otherwise categorized (FAB <sup>b</sup> : M1-M7)
Myelodysplastic/myeloproliferative diseases	Acute leukemia with ambiguous lineage
	Chronic myelomonocytic leukemia
	Atypical chronic myeloid leukemia
Chronic myeloproliferative leukemia	Juvenile myelomonocytic leukemia
	Chronic myelogenous leukemia (CML)
	Chronic neutrophilic leukemia
Precursor B- and T-cell leukemia	Chronic eosinophilic leukemia
	Precursor B-lymphoblastic leukemia (ALL: FAB: L1, L2)
	Precursor T-lymphoblastic leukemia (ALL: FAB: L1, L2)
Mature B-cell leukemia	Chronic lymphocytic leukemia (CLL)
	B-cell prolymphocytic leukemia
	Hairy cell leukemia
Mature T-cell and NK-cell leukemia	T-cell prolymphocytic leukemia
	T-cell large granular lymphocytic leukemia
	Aggressive NK-cell leukemia
Mastocytosis	Adult T-cell leukemia
	Mast cell leukemia

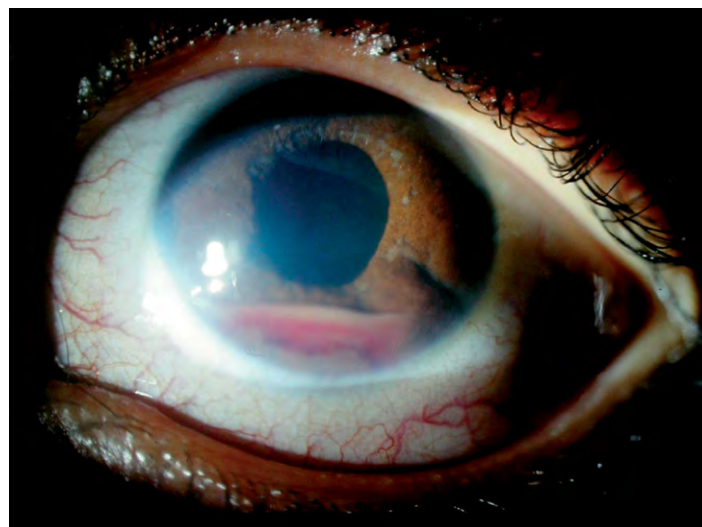
<sup>a</sup> based on World Health Organization (WHO) criteria.<sup>1</sup>

<sup>b</sup> French-American-British system of classification of leukemias.

which include melanoma, colorectal carcinoma, and multiple myeloma. A small subset of patients develops diffuse large cell lymphoma (i.e. Richter transformation), which then has a median survival of 4 months.<sup>11</sup>

**Ophthalmic features** Ocular involvement is reported in 32–92% of patients with leukemia (Box 55.1).<sup>12–15</sup> Nearly 50% of patients with ocular leukemia have concomitant central nervous system involvement. Isolated ocular leukemic infiltrations may also be the first clinical evidence of an extramedullary relapse in 30% of cases.<sup>16</sup> Leukemic blast cells adversely affect the normal physiology through the formation of extramedullary tumors in soft tissues (e.g. orbital granulocytic sarcoma), as well as by the release of procoagulants and fibrinolytic activators.<sup>12,13</sup> A high blast cell count may also cause microthrombi, leading to vascular occlusion. The release of toxic products and a high oxygen consumption by blast cells may further contribute to endothelial cell injury and microvascular invasion.<sup>2,13</sup> The intraocular structures may primarily be involved by direct infiltration of leukemic cells, or may be affected secondarily as a consequences of anemia, increased blood viscosity, thrombocytopenia, or immunosuppression.

**Symptoms** A significant number of patients, especially children, are asymptomatic when ocular leukemia is discovered. Blurred vision and acute loss of visual acuity are the most common complaints.<sup>12</sup>



**Fig. 55.1** Iris and anterior chamber involvement in a 5-year-old boy with ALL L2. There is diffuse irregular thickening of the iris and a pseudohypopyon mixed with hemorrhage.

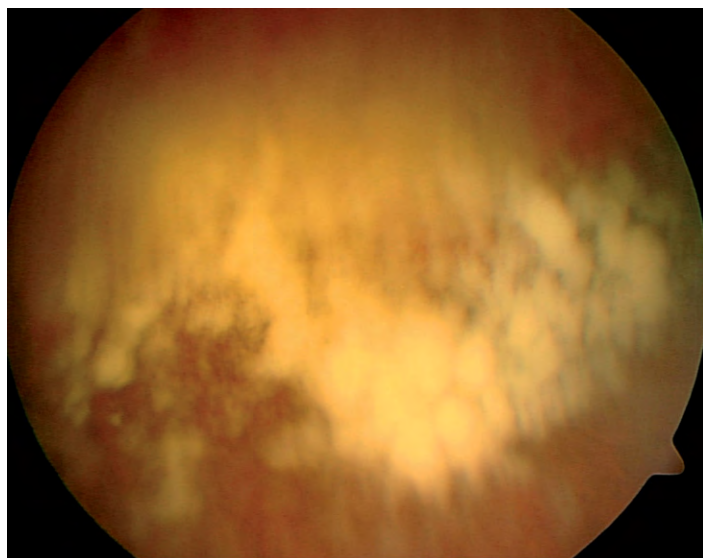
### Signs

**IRIS AND ANTERIOR CHAMBER** Infiltration of the iris and anterior chamber by leukemic cells is rare and most cases are encountered in children with ALL. Typically, the infiltrated heterochromic iris may show diffuse or nodular thickening, which is often associated with a gray-yellow pseudohypopyon with hemorrhage (Fig. 55.1).<sup>12,17</sup> Spontaneous hyphema may be the presenting sign in children with ALL, and anterior segment infiltration may be the initial and only sign of relapse.<sup>12</sup> Relapse in the anterior chamber tends to develop in the first 2 months after the completion of chemotherapy.<sup>18</sup> Infiltration of the trabecular meshwork is often associated with an elevated intraocular pressure.<sup>13,14,17</sup> Massive choroidal infiltration and hemorrhage may also cause acute angle closure glaucoma.<sup>13,14</sup> The lens and the zonular fibers are not directly involved, even in the presence of massive anterior segment disease.<sup>19</sup> Anterior segment necrosis is another rare ocular manifestation that tends to occur in CML. The differential diagnosis of anterior chamber and iris leukemia includes uveitis, especially in children.

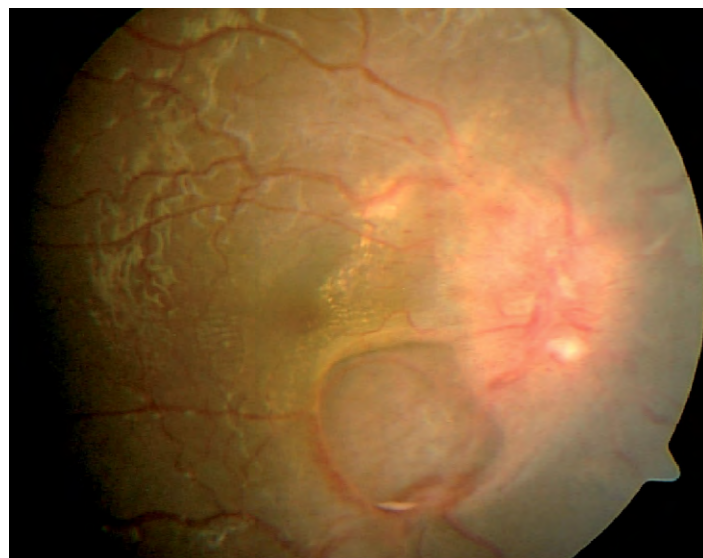**VITREOUS** Direct involvement of the vitreous by the leukemic process is exceedingly rare (Fig. 55.2).<sup>20</sup> The internal limiting membrane acts as an effective barrier, preventing blast cells from reaching the vitreous. Any leukemic cells in the vitreous are assumed to have infiltrated that part of the eye through the optic nerve head.<sup>13</sup> More often, the neoplastic cells incidentally accompany hemorrhage in the vitreous.<sup>19</sup> The differential diagnosis includes infectious endophthalmitis, especially in immunocompromised patients and those with a history of bone marrow transplantation (see below).

**Retina** Clinically, the retina is the most commonly affected intraocular structure.<sup>14</sup> In most cases this is in the form of leukemic retinopathy caused by anemia, hyperviscosity, and thrombocytopenia.<sup>21,22</sup> Such leukemic retinopathy is more often associated with adult acute leukemias and relapses.<sup>15,20</sup> White-centered hemorrhages occur frequently and are variably composed of platelet–fibrin aggregates, leukemic cells, debris, or septic emboli.<sup>13,23</sup> Cottonwool spots, caused by the occlusion of precapillary arterioles, may result from sludging of white blood cells as a result of hyperviscosity, direct occlusion by





**Fig. 55.2** Infiltration of the vitreous in a 15-year-old boy with AML M2.



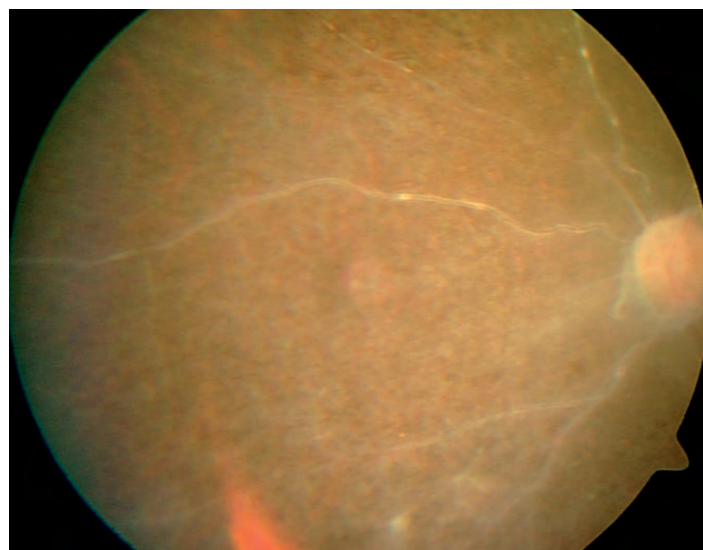
**Fig. 55.3** Serous retinal detachment with a subretinal 'hypopyon' in a 7-year-old girl with AML M4. There is also infiltration of the optic nerve head.

#### BOX 55.1 Ocular Features of Leukemia

- Leukemic infiltrates can develop in the iris and choroid
- Anemia, increased blood viscosity, thrombocytopenia, and immunosuppression can all cause ocular abnormalities
- Anterior chamber abnormalities include hyphema and glaucoma
- Retinal disease includes white-centered hemorrhages, cottonwool spots, microaneurysms, neovascularization, vascular sheathing, and serous retinal detachment
- Choroidal abnormalities include tumor formation and a leopard-skin appearance
- The optic nerve can be infiltrated or there may be swelling due to raised intracranial pressure

the leukemic cells, or occlusion by platelet–fibrin aggregates.<sup>14,15,22</sup> Although similar mechanisms usually underlie central retinal vein occlusions, recent evidence suggests that the risk of thrombosis may also be increased by the formation of anticardiolipin phospholipid autoantibodies against leukemic cells or their phospholipid antigens.<sup>24</sup> With regard to hematological parameters, thrombocytopenia has been linked to intraretinal hemorrhage, and an elevated white blood cell count has been related to intraretinal and white-centered hemorrhages.<sup>22</sup> Serous retinal detachment may occasionally be seen and is postulated to result from occlusion of the choriocapillaris, leading to ischemia of the retinal pigment epithelium and disruption of the intercellular tight junctions (Fig. 55.3).<sup>25</sup> Peripheral microaneurysms and neovascularization may be seen, especially in patients with CML and CLL.<sup>13,14</sup> Not infrequently, direct invasion of the retina is manifest in the form of yellow-white nodules or perivascular sheathing (Fig. 55.4).<sup>13,15,20</sup>

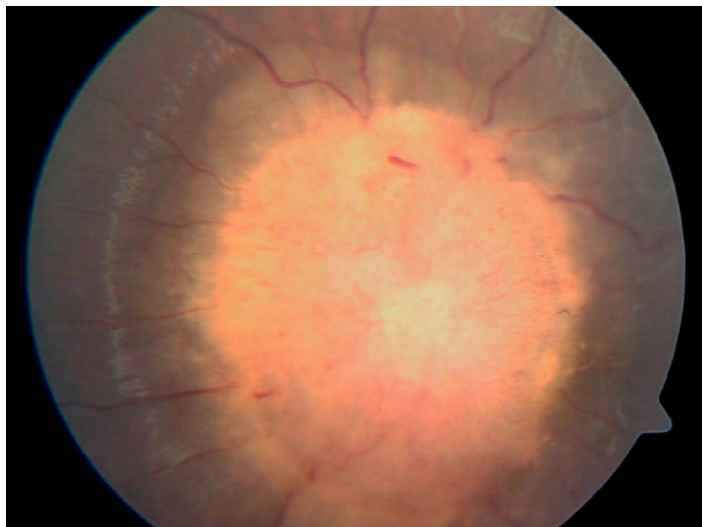
**CHOROID** Choroidal infiltration is the most frequent finding on histopathological examination, although it is rarely recognized clinically.<sup>12,15</sup> The choroid is thickened mainly by perivascular cellular infiltrations,



**Fig. 55.4** Perivascular sheathing in a 10-year-old boy with ALL L2.

which may be diffuse or patchy.<sup>14,19</sup> Solitary, large masses can be seen in patients with CML.<sup>14</sup> Blood flow through the choriocapillaris may be compromised and the overlying retinal pigment epithelium may become atrophic, hyperplastic, or hypertrophic, giving rise to a 'leopard skin' appearance clinically.<sup>14,15</sup> Fluorescein angiography may show numerous leakage points at the retinal pigment epithelium level. The differential diagnosis includes posterior scleritis, metastatic tumors, Vogt–Koyanagi–Harada disease, choroidal melanoma and fungal chorioretinitis.<sup>13,14</sup>

**OPTIC NERVE** Optic nerve involvement is an ominous sign because of a strong correlation with central nervous system (CNS) leukemia. It is found more commonly in children with ALL.<sup>12</sup> The optic nerve is affected by three different pathophysiological mechanisms: direct invasion of the optic nerve head by leukemic cells (Fig. 55.5), in which case the visual acuity is good unless there is any macular edema or hemorrhage; retrolaminar optic nerve infiltration, which may cause



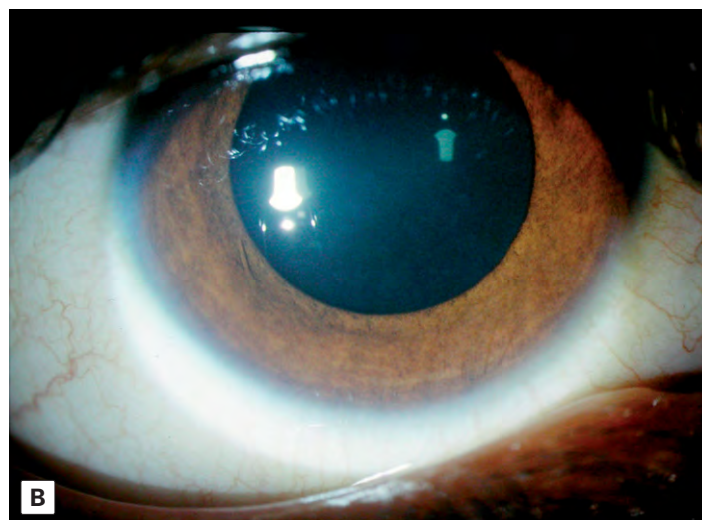
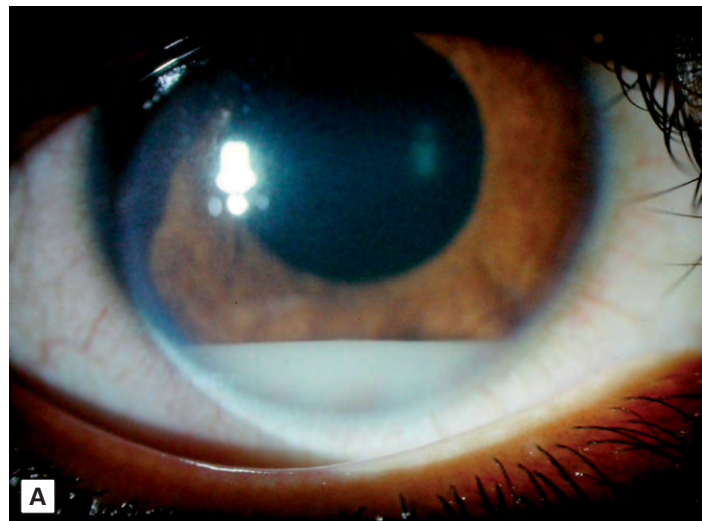
**Fig. 55.5** Massive optic nerve head infiltration in a 4-year-old boy with ALL L2. The patient also had central nervous system involvement.

devastating and permanent visual loss; and passive papilledema caused by increased intracranial pressure.<sup>13–15,19</sup>

**Treatment** The aims of treatment for any type of leukemia are to restore normal hematopoiesis, prevent the emergence of resistant leukemic clones, eradicate minimal residual disease, and provide effective prophylactic therapy to prevent recurrence from ‘sanctuary sites,’ most importantly in the CNS.<sup>3,5</sup>

**Systemic** In general, the treatment of acute leukemias is divided into induction, consolidation and intensification, and maintenance phases.<sup>2,5</sup> Autologous or allogeneic stem cell transplantation is widely used for selected patients with ALL and AML, with variable success.<sup>2</sup> A better understanding of the pathobiology of leukemias through molecular microdissection now enables more individualized and targeted therapeutic options to be implemented, and therefore great variations may exist in the treatment protocols of subtypes of ALL and AML.<sup>5,9</sup> The treatment of CLL and CML is palliative.<sup>2</sup> CNS disease is one of the most serious complications of leukemia and indicates a poor prognosis for survival.<sup>26</sup>

**Ophthalmic** involvement, particularly infiltration of the optic nerve, retina, and vitreous, implies CNS disease, which must be excluded.<sup>26</sup> If CNS leukemia is detected, high-dose intrathecal chemotherapy and craniospinal radiotherapy including the ocular structures are prescribed. When the optic nerve is involved a distinction between papilledema from increased intracranial pressure and direct cellular infiltration is urgently required, as prompt irradiation usually conserves vision in the latter condition whereas this will not be effective in the former.<sup>20</sup> The eye (particularly the anterior chamber) is regarded as a ‘pharmacological sanctuary’ where relapse is likely to occur even after apparently successful systemic chemotherapy or when the bone marrow is normal. Irradiation is therefore required to eradicate any viable neoplastic cells in the eye (Fig. 55.6).<sup>12,18</sup> Topical corticosteroids may temporarily reduce the tumor burden in



**Fig. 55.6** Leukemic pseudohypopyon in a 6-year-old boy with ALL (A). Same eye following external beam radiotherapy (B).

the anterior chamber, but recurrence rapidly occurs. Leukemic retinopathy does not necessitate direct treatment because most abnormalities regress when hematological parameters return to normal with systemic therapy.

**Prognosis** Event-free survival in children with ALL now exceeds 75%, whereas in adults the cure rate remains around 30%.<sup>2</sup> Children usually have the TEL-AML1 fusion gene and hyperdiploidy, which confer a favorable prognosis.<sup>7</sup> In contrast, most adult patients have the Philadelphia chromosome, MLL rearrangements and hypodiploidy, which are adverse prognostic indicators. In AML the cure rate is 35% in children, steadily decreasing with age and becoming very rare at the age of 80.<sup>5</sup> In CML, reported 8-year survival rates vary between 8% and 17%. Patients with CLL usually succumb to infections.<sup>9</sup>

Ocular involvement is a poor prognostic indicator, indicating a 5-year survival probability of 21% compared to 46% in the absence of ocular manifestations.<sup>26</sup> Children with acute leukemia rarely survive more than 28 months after the onset of ocular manifestations. The

average survival is 14 months following the diagnosis of optic nerve infiltration, 9 months after the detection of uveal infiltration, and only 8 months after the occurrence of retinal hemorrhages and other retinal vascular abnormalities. Patients with neuro-ophthalmological signs of CNS leukemia have a significantly worse prognosis.<sup>26</sup> Because aggressive chemotherapy and radiotherapy may be beneficial in these patients, routine ocular examination should be part of the evaluation of every patient with leukemia.

### POLYCYTHEMIA VERA RUBRA (VAQUEZ-OSLER DISEASE)

Polycythemia vera (PV) is a chronic myeloproliferative disorder that originates in a clonal hematopoietic stem cell.<sup>27</sup> There is uncontrolled production of erythroid, granulocytic, and megakaryocytic cells.

The disease has an insidious onset and the mean age at diagnosis is 60 years.<sup>27</sup> Most commonly, clinical disease is the result of thrombotic episodes, which include hepatic vein thrombosis, bleeding and bruising, and pruritus.<sup>2,27</sup> Ocular effects include transient visual obscurations, cyanotic fundus, dilatation and tortuosity of retinal vessels, intraretinal and vitreous hemorrhages, juxtafoveal retinal telangiectasis, and optic disc swelling and atrophy. Retinal arterial and venous occlusions are common.<sup>28</sup>

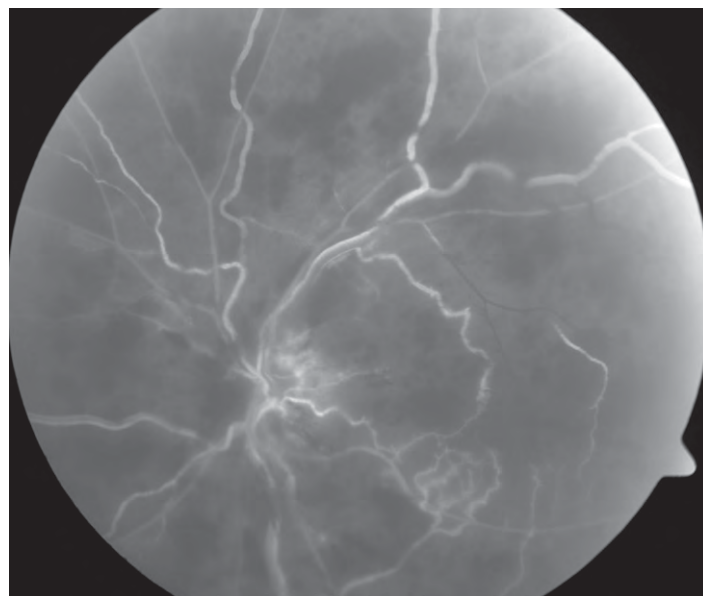
The treatment of PV consists of phlebotomy and myelosuppression by the use of hydroxyurea, busulfan, chlorambucil, and anagrelide. Thrombosis is the most common cause of death, the other major cause being the development of AML.<sup>2</sup>

### ESSENTIAL THROMBOCYTHEMIA

This is a myeloproliferative disorder arising from a multipotential hematopoietic stem cell. The disease affects patients between ages 50 and 70, most of whom are asymptomatic and discovered incidentally.<sup>2</sup>

Morbidity and mortality are usually caused by hemorrhage and thrombosis, including cerebrovascular accident. The most serious ocular manifestations are central retinal arterial and central retinal vein occlusion (Fig. 55.7), which can lead to neovascular glaucoma.<sup>29,30</sup>

Treatment aims to reduce the platelet count, preferably to below 600 000/mm<sup>3</sup>, achieved by using hydroxyurea, anagrelide, and interferon- $\alpha$ . Although essential thrombocythemia does not usually reduce life expectancy, some patients convert to AML, which has a dismal prognosis.<sup>2</sup>



**Fig. 55.7** A 75-year-old man with essential thrombocythemia and central retinal vein occlusion of the left eye. Late-phase fluorescein angiogram shows dilated and tortuous retinal veins and areas of retinal non-perfusion.

### GRAFT-VERSUS-HOST DISEASE

This is a particularly serious complication of hematopoietic stem cell transplantation that occurs when competent donor-derived T cells react with recipient tissue antigens.<sup>2</sup> The skin, liver, and gastrointestinal tract are most severely affected. Serious ocular complications can also occur, and include cicatricial lagophthalmos, keratoconjunctivitis sicca, pseudomembranous conjunctivitis, pathognomonic fibrotic tarsal conjunctival Arlt lines, corneal ulceration, and corneal melting.<sup>12</sup> Intraocular manifestations include cataract, bilateral optic disc edema, vitreous hemorrhage, retinal detachment, and cotton wool spots.<sup>20</sup> Endophthalmitis caused by *Aspergillus*, herpes zoster, cytomegalovirus, and *Toxoplasma* develops in 2% of cases.<sup>20</sup> Fungal endophthalmitis presents with vitritis, choroidal nodules, and white-centered hemorrhages mimicking leukemic infiltration.<sup>20</sup> In the absence of blast cells in the peripheral blood and CNS, an infectious process is more likely. The treatment of graft-versus-host disease involves immunosuppression by the use of cyclosporine, tacrolimus, or prednisolone.<sup>2</sup>

### REFERENCES

- Jaffe ES, Harris NL, Stein H, Vardiman JW (eds) World Health Organization classification of tumors. Pathology and genetics of tumors of haematopoietic and lymphoid tissues. Lyon: IARC Press; 2001: 76–117.
- Lichtman MA. Classification and clinical manifestations of the clonal myeloid disorders. In: Beutler E, Lichtman MA, Coller BS, Kipps TJ, Seligsohn U, eds. Williams hematology, 4th edn. New York: McGraw Hill, 2001; 1017–1028.
- Gürgey A, Yetgin S, Çetin M et al. Acute lymphoblastic leukemia in infants. Turk J Pediatr 2004; 46: 115–119.
- Kelly LM, Gilliland DG. Genetics of myeloid leukemias. Annu Rev Genomics Hum Genet 2002; 3: 179–198.
- Faderi S, Jeha S, Kantarjian HM. The biology and therapy of adult acute lymphoblastic leukemia. Cancer 2003; 98: 1337–1354.
- Greaves MF. Aetiology of acute leukaemia. Lancet 1997; 349: 344–349.
- Wiemels JL, Cazzaniga G, Daniotti M et al. Prenatal origin of acute lymphoblastic leukaemia in children. Lancet 1999; 354: 1499–1503.
- Melo JV. The molecular biology of chronic myeloid leukaemia. Leukemia 1996; 10: 751–756.
- Goldman JM, Melo JV. Chronic myeloid leukemia: advances in biology and new approaches to treatment. N Engl J Med 2003; 349: 1451–1464.
- Hamblin TJ, Oscier DG, Young BJ. Autoimmunity in chronic lymphocytic leukemia. J Clin Pathol 1986; 39: 713–716.
- Hattenbauer MG, Pach JM. Ocular lymphoma in a patient with chronic lymphocytic leukemia. Am J Ophthalmol 1996; 122: 266–268.
- Sharma T, Grewal J, Gupta S, Murray PI. Ophthalmic manifestations of acute leukaemias: the ophthalmologist's role. Eye 2004; 18: 663–672.
- Kinkaid MC, Green WR. Ocular and orbital involvement in leukemia. Surv Ophthalmol 1983; 27: 211–232.
- Rosenthal AR. Ocular manifestations of leukemia. A review. Ophthalmology 1983; 90: 899–905.
- Leonardy NJ, Rupani M, Dent G, Klintworth GK. Analysis of 135 autopsy eyes for ocular involvement in leukemia. Am J Ophthalmol 1990; 109: 436–444.
- Curto ML, Zingone A, Acquaviva A et al. Leukemic infiltration of the eye: results of therapy in a retrospective multicentric study. Med Pediatr Oncol 1989; 17: 134–137.
- Zakka KA, Yee RD, Shorr N et al. Leukemic iris infiltration. Am J Ophthalmol 1980; 89: 204–209.
- Maclean H, Clarke MP, Strong NP, Krenahan J, Ashraf S. Primary ocular relapse in acute lymphoblastic leukaemia. Eye 1996; 10: 719–722.



19. Allen RA, Straatsma BR. Ocular involvement in leukemia and allied disorders. *Arch Ophthalmol* 1961; 66: 490–508.
20. Gordon KB, Rugo HS, Duncan JL et al. Ocular manifestations of leukemia. Leukemic infiltration versus infectious process. *Ophthalmology* 2001; 108: 2293–2300.
21. Guyer DR, Schachat AP, Vitale S et al. Leukemic retinopathy. Relationship between fundus lesions and hematologic parameters at diagnosis. *Ophthalmology* 1989; 96: 860–864.
22. Reddy SC, Jackson N. Retinopathy in acute leukaemia at initial diagnosis: correlation of fundus lesions and haematological parameters. *Acta Ophthalmol Scand* 2004; 82: 81–85.
23. Schachat AP, Markowitz JA, Guyer DR et al. Ophthalmic manifestation of leukemia. *Arch Ophthalmol* 1989; 107: 697–700.
24. Al-Abdulla NA, Thompson JT, LaBorwit SE. Simultaneous bilateral central vein occlusion associated with anticardiolipin antibodies in leukemia. *Am J Ophthalmol* 2001; 132: 266–268.
25. Stewart MW, Gitter KA, Cohen G. Acute leukemia presenting as a unilateral exudative retinal detachment. *Retina* 1989; 9: 110–114.
26. Ohkoshi K, Tsiaras WG. Prognostic importance of ophthalmic manifestations in childhood leukemia. *Br J Ophthalmol* 1992; 76: 651–655.
27. Berlin NI, Wasserman LR. Polycythemia vera: a retrospective and reprise. *J Lab Clin Med* 1997; 130: 365–372.
28. Rothstein T. Bilateral central retinal vein closure as the initial manifestation of polycythemia. *Am J Ophthalmol* 1972; 74: 256–260.
29. Liu M, Lee AG, Rice L, Lambert HM. Bilateral retinal vascular occlusive disease in essential thrombocythemia. *Retina* 1999; 19: 563–564.
30. Yoshizumi MO, Townsend-Pico W. Essential thrombocythemia and central retinal vein occlusion with neovascular glaucoma. *Am J Ophthalmol* 1996; 121: 728–730.

# Intraocular biopsy

Devron H. Char

## INTRODUCTION

Intraocular biopsy was first credited to Hirschberg in 1868.<sup>1</sup> Early attempts with either a trephine or a large-bore needle often established the diagnosis, but made a sufficient ocular opening to result in tumor extension.<sup>1–9</sup> In contrast, with fine needle aspiration biopsies (FNAB) using a needle size of 25-gauge or smaller there has been no evidence of ocular or orbital tumor dissemination, although theoretic concerns have been raised.<sup>10,11</sup>

## INDICATIONS

The major indication for intraocular tumor biopsy is failure to establish a diagnosis non-invasively in a patient who requires therapy. A confusing clinical pattern, such as an amelanotic uveal tumor with a history of a prior carcinoma, media opacities with ultrasound demonstration of a choroidal mass, question of a uveitis versus intraocular lymphoma, or a patient unwilling to have a surgical procedure without cytopathologic confirmation of the diagnosis, are potential indications. Clinical diagnosis of an intraocular tumor can be difficult. The Collaborative Ocular Melanoma Study published >99% diagnostic accuracy in patients with large choroidal melanomas, but study inclusion criteria included only large obvious melanomas. Difficult diagnostic cases, such as those with media opacification, were excluded.<sup>12</sup> Establishing the diagnosis can be challenging in patients with opaque media, and those with an atypical pattern or a rare neoplasm.<sup>13</sup>

## TECHNIQUES

There are several different intraocular tumor biopsy techniques; they include vitrectomy, fine needle aspiration biopsy (trans-scleral or transvitreal), external scleral-based choroidal resection, and endorectal biopsy (Box 56.1).

**Vitrectomy** is usually performed to rule out an intraocular lymphoma, although occasionally it is also used to detect metastatic tumors to the vitreous. In one series, neoplasm was the reason for diagnostic vitrectomy in 58 of 405 consecutive cases.<sup>14</sup> We and others have previously reported on techniques to optimize the quality of vitreous cellular cytopathology.<sup>15</sup> In most centers, if a patient has moderate or severe vitreous cellularity a standard three-port vitrectomy is set up, but before using the vitrector a sample is obtained with a 20-gauge needle and immediately transported to the laboratory. Saving these specimens in RPMI (Roswell Park Memorial Institute medium) or newer preservation media can reduce cell degradation.

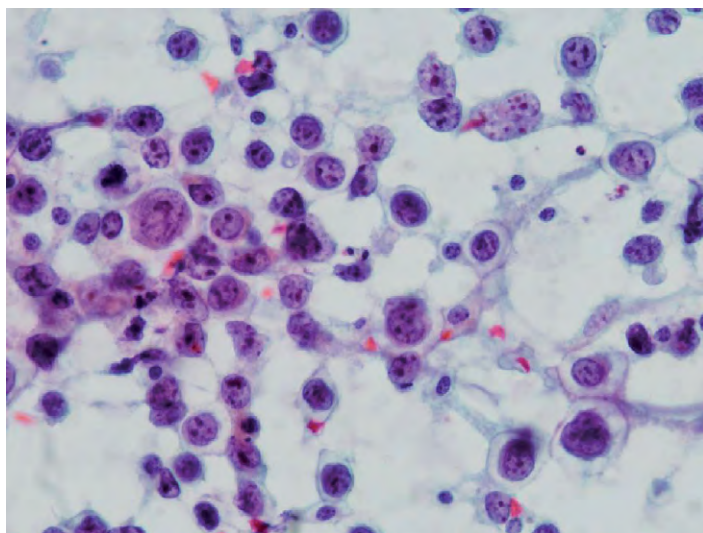
Specimens for morphological examination may be processed by several standard concentrating methods, including Millipore filtration, ThinPrep (Cytoc Corporation, Boxborough, MA, USA, and AutoCyte PREP (TriPath Imaging Inc., Burlington, NC, USA). Other workers have used cytospin preparations with good results. We have found these methods are superior to direct smears for examining cellular and nuclear detail. Material may be stained by either Papanicolaou or the May–Grünwald–Giemsa methods. Fresh materials for polymerase chain reaction (PCR) analysis are best delivered to the laboratory as soon as possible. The samples can be stored at  $-80^{\circ}\text{C}$ . Although uncommon, these samples may at times contain sufficient material for cell button preparation and immunohistochemical studies. If culture for organisms is required, transport media such as remel-supplemented tryptone soya broth (TSB) maybe used. Similarly, PCR for viral retinitis can be performed on 0.1 mL of undiluted vitreous fluid on dry ice.

We and others have previously reported that a significant minority of intraocular lymphomas could not be diagnosed cytopathologically on a single vitrectomy sample. In many cases sequential vitreous biopsies had to be performed to establish the diagnosis.<sup>16–18</sup> There are several confounding variables that can make cytopathologic diagnosis of intraocular lymphoma difficult: some of the lymphomas have a large admixture of normal inflammatory cells; the quality of cytopathology preparation and analysis is variable; and some intraocular lymphomas have a predilection for early vitreous involvement, whereas others remain subretinal or sub-RPE in location, which can make diagnosis extremely challenging. As a result of the sub-RPE or subretinal location, several groups have made the diagnosis in such unusual cases with a fine needle biopsy, a chorioretinal biopsy, or after enucleation.<sup>19,20</sup>

The ability to diagnose intraocular lymphoma cytologically is based on several criteria. The samples vary in their cell content, with most cases having 5–10 cells per high-power field (hpf). The neoplastic cells are incohesive and usually visualized as single cells. The vast majority of morphologically identifiable lymphomas are of the large cell high-grade type. The most striking cytologic feature of these high-grade lymphomas is the marked irregular nuclear outline (Fig. 56.1) occurring in cells that are large and have a high nuclear to cytoplasmic ratio. Nucleoli, although often prominent, may not be present in all cases. The chromatin material is coarse.<sup>16,21,22</sup> There may be an admixture of degenerating inflammatory cells. In our experience we have had a 90% diagnostic accuracy with a single vitreous biopsy. In 10% of cases a second vitreous biopsy, subretinal

**BOX 56.1 Techniques of Intraocular Biopsy**

- Vitrectomy
- Fine needle aspiration biopsy (trans-scleral or transretinal)
- Trans-scleral incisional tumor biopsy
- Endoretinal biopsy



**Fig. 56.1** B-cell lymphoma demonstrating large single cells with irregular nuclear shapes. (Papanicolaou stain  $\times 60$ .)

FNAB, or eye-wall resection biopsy was needed to establish the diagnosis.

Some centers have an error rate as high as 70% in patients suspected of having an intraocular lymphoma.<sup>23</sup> This high false negative rate with cytopathology has led to other analytical approaches.<sup>23</sup> An early approach was flow cytometry to stain for surface lymphocyte markers and assess monoclonality as a substitute for cytology to diagnose lymphoma. Unfortunately, only 70% of cases were correctly diagnosed in that manner, and subsequent data have shown that benign processes can also rarely be monoclonal.<sup>23</sup>

Molecular techniques have been used to help establish a diagnosis of intraocular lymphoma, predicated on a number of molecular alterations. It is uncertain to what extent these molecular techniques have improved our diagnostic accuracy. In some cases PCR assays to assess monoclonal proliferations or rearrangement of the immunoglobulin heavy chain have been diagnostic, as have elevations of either the interleukin-10 or the interleukin-10/interleukin-6 ratios. Unfortunately, false negatives have also occurred with these techniques.<sup>24-27</sup> Although abnormal vitreous cytokine levels (increased vitreous IL-10 or IL10/IL6  $>1.0$ ) are helpful, only if there is confirmatory cytopathology can a diagnosis of primary intraocular lymphoma be made.

Immunoglobulin gene rearrangements have also been used to diagnose primary ocular lymphoma.<sup>28-30</sup> Katai<sup>28</sup> and associates used PCR to assess whether the complementarity-determining region of the immunoglobulin heavy chain (CDR3) was useful as a means to detect lymphoma. Shen and colleagues<sup>29</sup> at the NEI have studied several different markers, including clonality of the IgH heavy chain rear-

angement, and a bcl-2 translocation, which is common in systemic lymphomas. Using a microdissection technique on eyes enucleated for intraocular lymphoma, they found that there was often both an aberrant third framework region of the IgH variable region gene, as well as a translocation between chromosomes 14 and 18, where the Bcl-2 gene is located.<sup>29</sup>

There are problems with molecular techniques as well. In enucleated eyes, unless microdissection was performed, false negative results occurred. White and colleagues<sup>30</sup> noted that in two of 14 cases DNA degradation did not allow amplification. Merle-Béral and colleagues<sup>31</sup> were able to make the diagnosis more commonly with cytology, and this was confirmed by increased IL-10 levels. When this group used PCR they found that in five cases they could not amplify the DNA because of degradation, and in seven cases no gene rearrangement was found.<sup>31</sup> Chan<sup>32</sup> has shown that bcl-2 translocations occurred in 15 of 20 primary ocular lymphomas that they studied. Gorochov and colleagues<sup>33</sup> studied six patients for polymorphism of the CDR3 region of the immunoglobulin heavy chain. In five of six lymphomas there was a dominant B-cell clone, but one lymphoma was polyclonal using this marker. A control patient's immune recovery uveitis vitreous specimen was also monoclonal.

The gold standard for primary intraocular lymphoma diagnosis remains vitreous cytopathology. The primary ophthalmic diagnostic technique (in addition to neuroimaging and CSF cytology) is vitreous biopsy. If that is negative and there are discrete subretinal lesions, a fine needle aspiration biopsy is performed. If this is not diagnostic in the operating room, we immediately perform a chorioretinal biopsy. In some centers only enucleation has yielded the correct diagnosis, although fortunately we have never required that option.

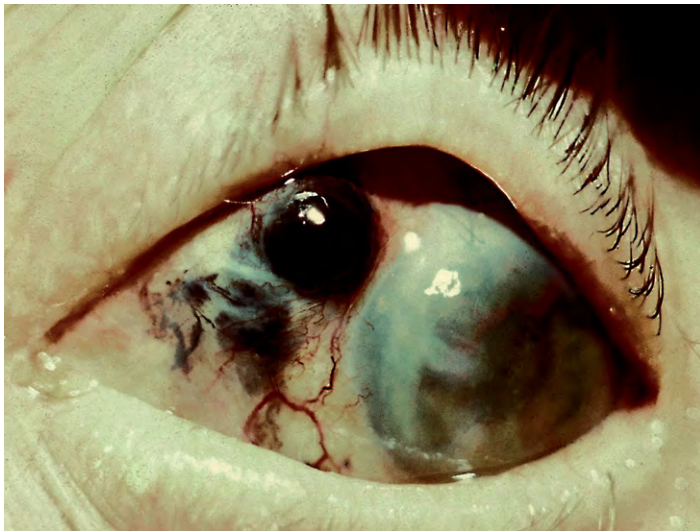Coupland and colleagues characterized 80 patients, of whom 12 were eventually diagnosed as having lymphoma and five were felt to be suspicious for neoplastic disease. Five of these cases required surgical approaches in addition to vitrectomy; three had chorioretinal biopsies, and two eyes were enucleated. Seven cases were initially diagnosed as reactive vitritis. All of these seven eyes were eventually diagnosed with lymphoma after other procedures. On chorioretinal biopsy most of these tumors were CD20, bcl-2, bcl-6, and MUM1 positive. Others have also noted the failure to diagnose a tumor with vitrectomy, and in such cases FNAB, chorioretinal biopsy, or enucleation is required.<sup>24,34-37</sup> T-cell lymphomas can also involve the vitreous, and these have been diagnosed.<sup>38,39</sup>

Several cases of metastatic tumors to the vitreous cavity have been diagnosed with a vitreous biopsy.<sup>40</sup> These include metastatic cutaneous melanoma, lung carcinoma, breast carcinoma, testicular germ cell carcinoma, and esophageal carcinomas.<sup>41-51</sup> In addition, several investigators have inadvertently performed vitrectomies on suspected retinoblastoma and discovered the tumor in that manner.<sup>21</sup>

Worryingly, we have seen a few patients who have had vitrectomies for unsuspected melanomas, with dire consequences (Fig. 56.2). Incorrect diagnoses based on cytopathologic analysis can occur, including the incorrect diagnosis of leukemia as a breast carcinoma.<sup>14,52</sup> A fungal endophthalmitis misdiagnosed as a lymphoma has also been described.<sup>53</sup>

**Fine needle aspiration biopsy** Transvitreal and trans-scleral fine needle aspiration biopsy has been used mainly to diagnose adult choroidal tumors. No evidence of tumor spread has been documented in eye or orbital fine needle biopsies.<sup>11</sup> We prefer the use of a 25-gauge needle for fine needle aspiration samples, which may be obtained with





**Fig. 56.2** Eye after vitrectomy with an unsuspected uveal melanoma.

or without the application of negative pressure. The optimal preparation is that of direct smears on glass slides. If the material is alcohol fixed a Papanicolaou stain is used. Air-dried samples are stained with the May–Grünwald–Giemsa method. There are occasions when one may need to use concentration methods, described above under vitrectomy.

If a cytopathologist is present in the operating room to immediately assess the adequacy of the sample, false negative biopsy results are reduced.<sup>54</sup> Performing analyses in this manner we have had a less than 3% true false negative rate, whereas other ophthalmic oncology units have had a higher incidence of false negative results.<sup>55,56</sup>

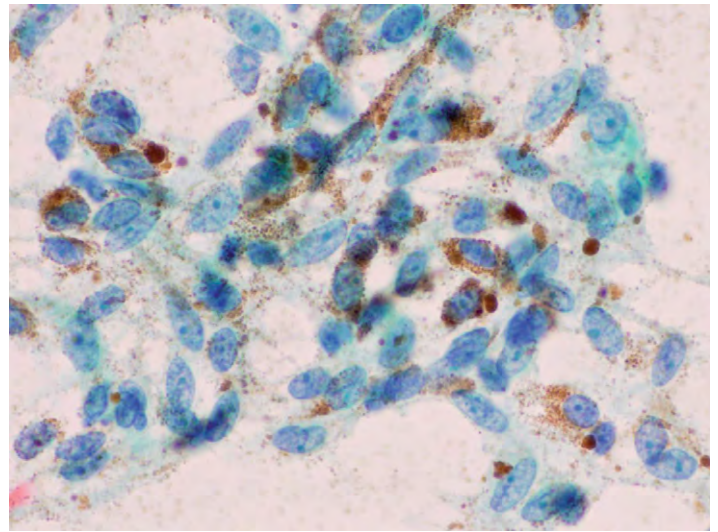
Tissue culture, immunostaining, and molecular studies can be performed on these samples.<sup>13,57,58</sup> We have observed no false positive diagnoses with fine needle biopsy, although there are a few reported cases in which metastatic carcinomas were mistaken for melanomas.<sup>59</sup> In addition, melanocytoma was incorrectly diagnosed as a melanoma in one series.<sup>60</sup>

The diagnosis is more difficult to establish in thin choroidal lesions. Cohen and colleagues quantified this problem and found that tumors <2 mm thick had a much lower incidence of FNAB diagnoses than those that were over 4 mm thick.<sup>61</sup> Similarly, Augsburg and colleagues noted a diagnostic accuracy of only 68% in small choroidal lesions.<sup>62</sup>

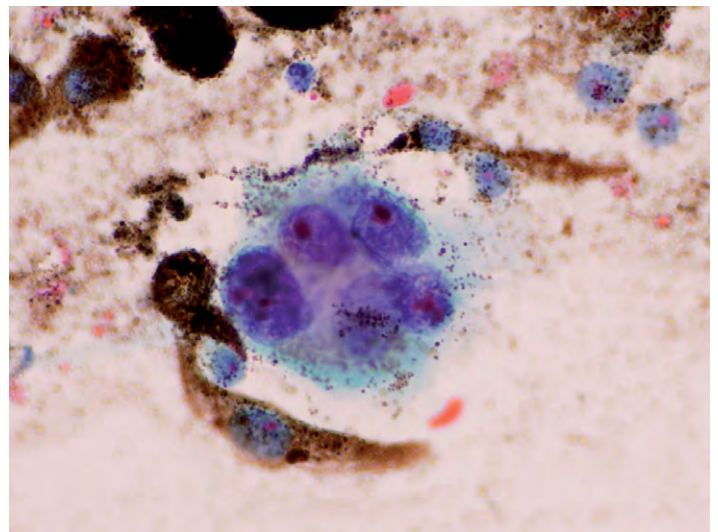
In addition to making the diagnosis of a uveal melanoma, we have been able to ascertain cell type with a high degree of accuracy (Figs 56.3–56.6).<sup>63</sup> In irradiated patients for whom enucleated specimens were not available, cytopathology added to our prognostic accuracy in a Cox model.<sup>64</sup>

Fine needle biopsy has also been used to make the diagnosis of a number of other solid tumors, including lymphoma and metastatic carcinoma.<sup>59,65</sup> In some cases ultrasound has also been used to guide needle placement in eyes with opaque media.<sup>66</sup>

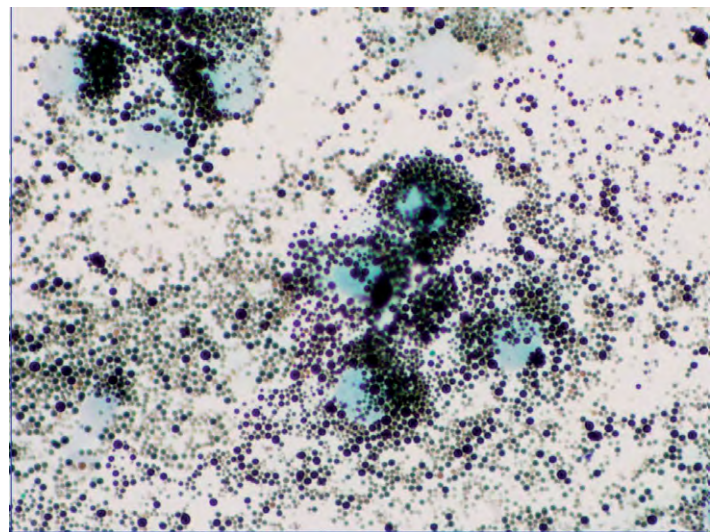
Fine needle biopsy data are also very helpful to establish the correct diagnosis and guide therapy in atypical cases. Figure 56.7A shows a patient with an enlarging lesion nasal to the optic disc with age-related macular degeneration. Clinically we felt this was an extramacular disciform lesion, but it continued to enlarge. On cytopathology (Fig. 56.7B) hemosiderin-laden macrophages were noted that established the correct diagnosis. Figure 56.8 shows an atypical ciliochoroidal tumor. Ultrasound and fluorescein angiographic features were not



**Fig. 56.3** Spindle B melanoma with fine dusty pigment. (Papanicolaou stain  $\times 60$ .)

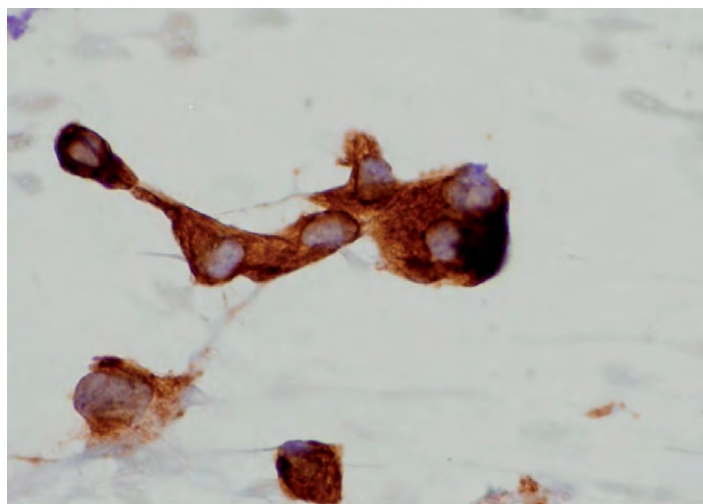


**Fig. 56.4** Epithelioid melanoma, note large nucleoli. (Papanicolaou stain  $\times 60$ .)

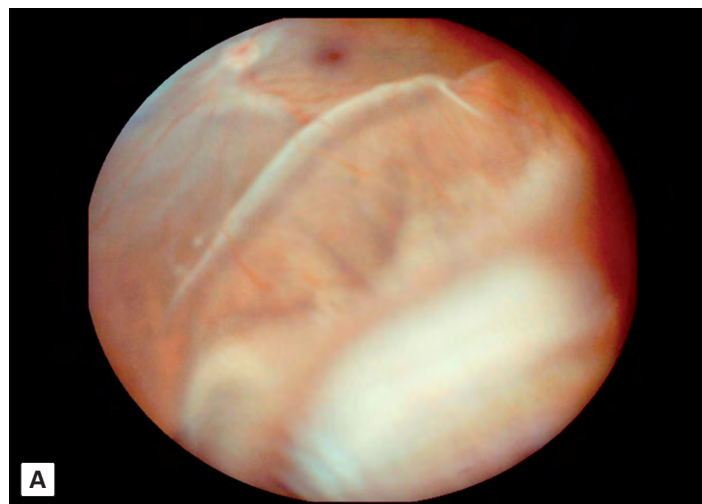


**Fig. 56.5** Melanocytoma with large uniform pigment granules. (Papanicolaou stain  $\times 60$ .)

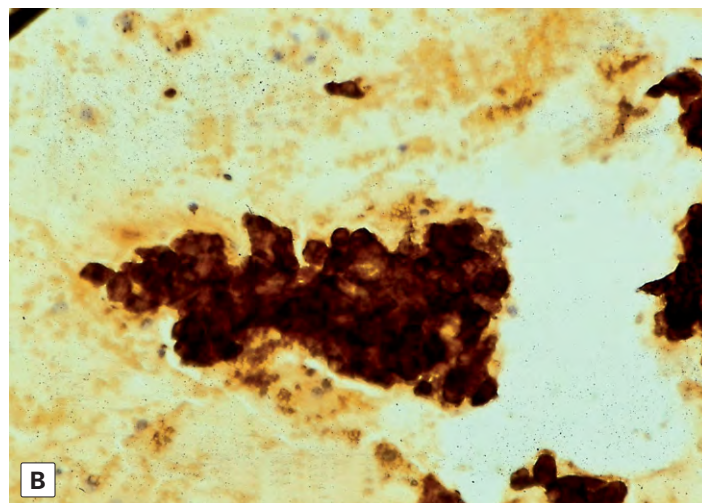




**Fig. 56.6** Metastatic breast carcinoma showing cohesive cell groups. (Immunohistochemical stain for keratin. AE 1/3  $\times 60$ .)

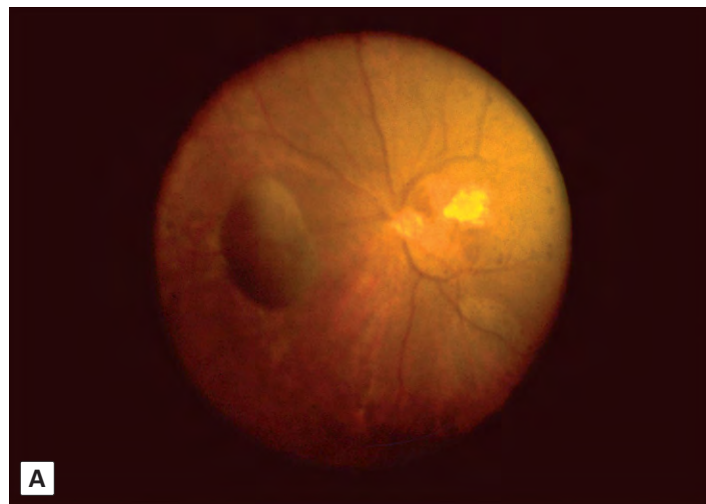

A

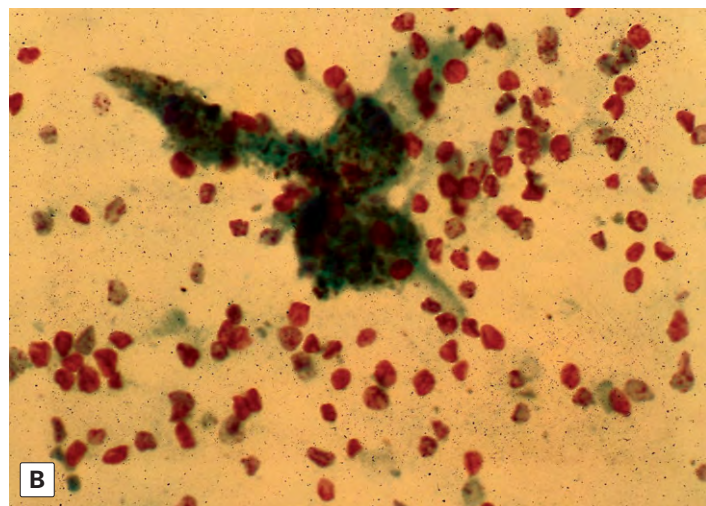


B

**Fig. 56.8** Atypical ciliochoroidal tumor. Neither FA nor ultrasonography was diagnostic (A). Keratin stain confirms the metastatic nature of this tumor. (60 $\times$ ) (B)



A



B

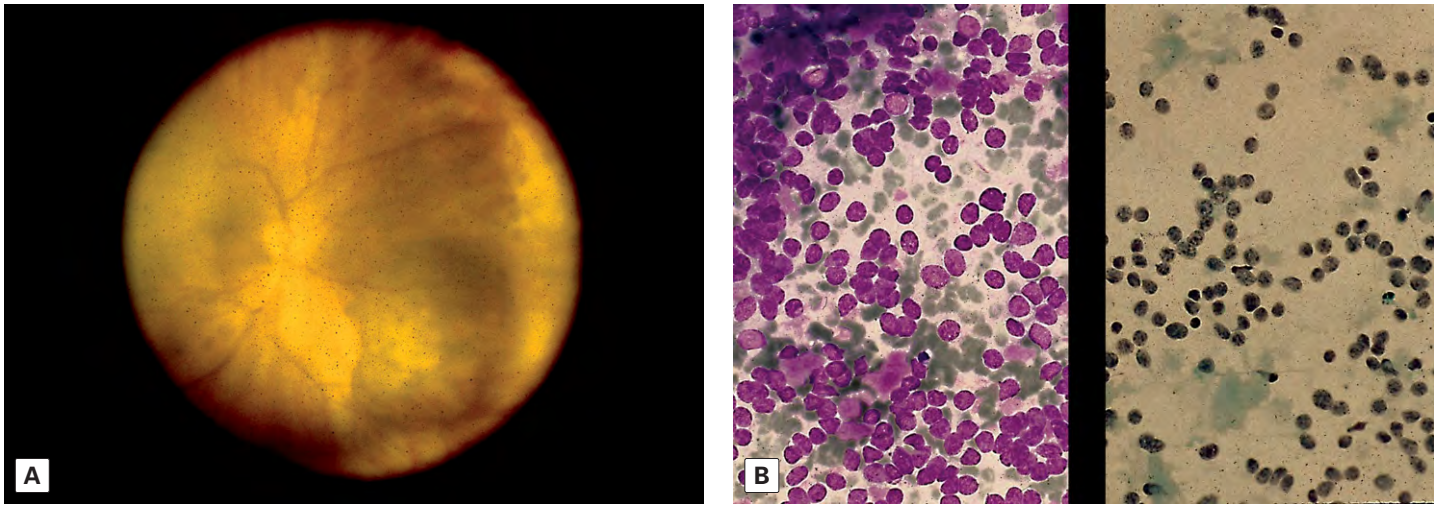
**Fig. 56.7** Enlarging, presumed extramacular disciform. The thickness of the lesion increased 2mm over a 6-week interval (A). Cytopathology shows hemosiderin-laden macrophages 60 $\times$  (B).

diagnostic, but the keratin staining demonstrated that this was a metastatic carcinoma (Fig. 56.8B). Figure 56.9A shows an atypical, lightly pigmented choroidal tumor. On FNAB this lesion is diagnostic of a carcinoid tumor (Fig. 56.9B) that required 30Gy to obliterate it completely. Figure 56.10A shows a large, pigmented peripapillary choroidal mass. FNAB showed very large pigment granules and bland cells (Fig. 56.10B); a diagnosis of melanocytoma was established. Ten years later the lesion, without treatment, is slightly smaller and the patient's vision remains excellent.

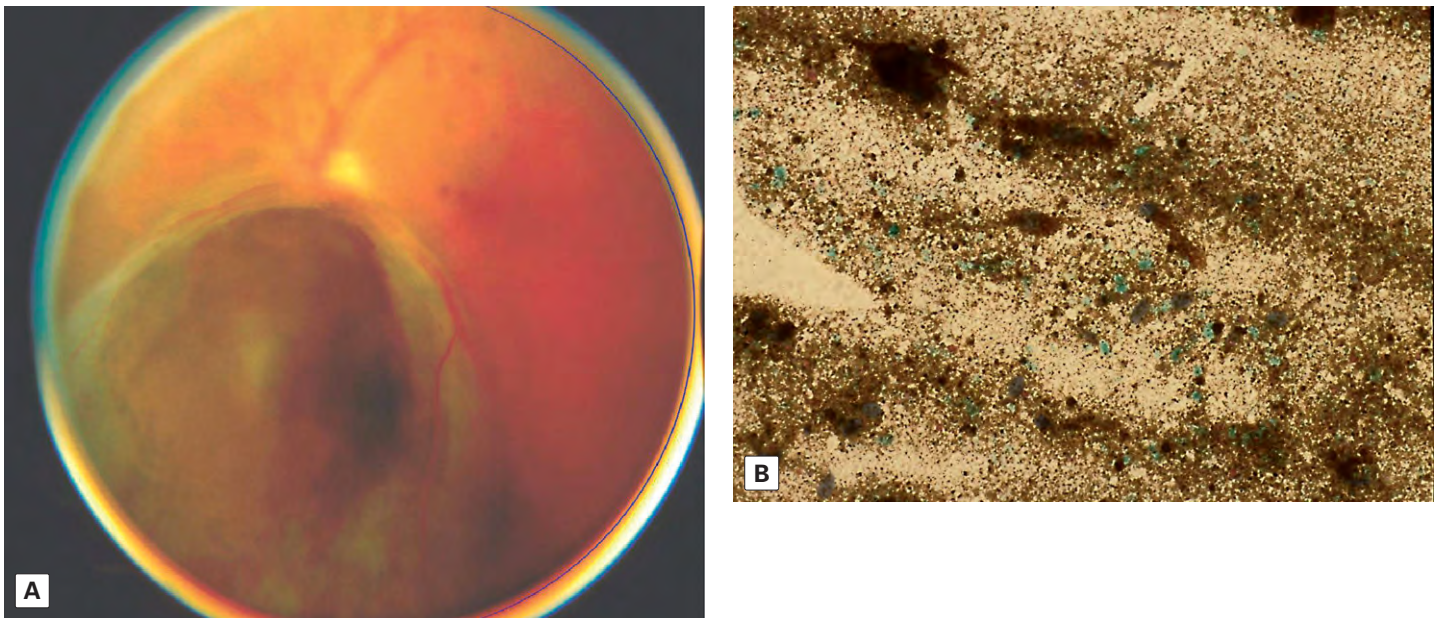
**External (scleral-based choroidal resection) biopsy** Rarely in our experience have we required an external approach to make the diagnosis of an intraocular tumor. We have observed cases of tumor spread when an intraocular vitrectomy-based procedure has been performed on a patient with an untreated uveal melanoma. Similarly, vitrectomy on an unsuspected retinoblastoma historically had a deleterious effect.<sup>67</sup>

We prefer a scleral flap and chorioretinal biopsy if the tumor involves the choroid or deep retinal layers.<sup>68</sup> The technique is well described elsewhere.<sup>68</sup> As shown in Figure 56.11, under hypotensive anesthesia we raise a 90% scleral flap around the area to be biopsied. If it is a deep lesion we do not incise the full thickness of the retina.

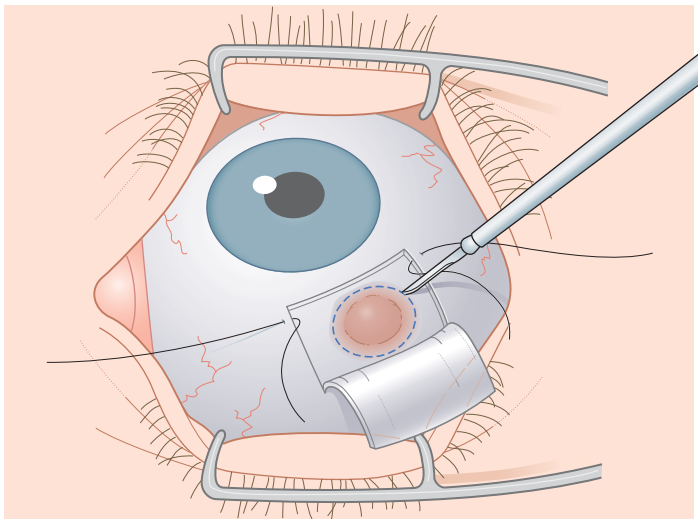




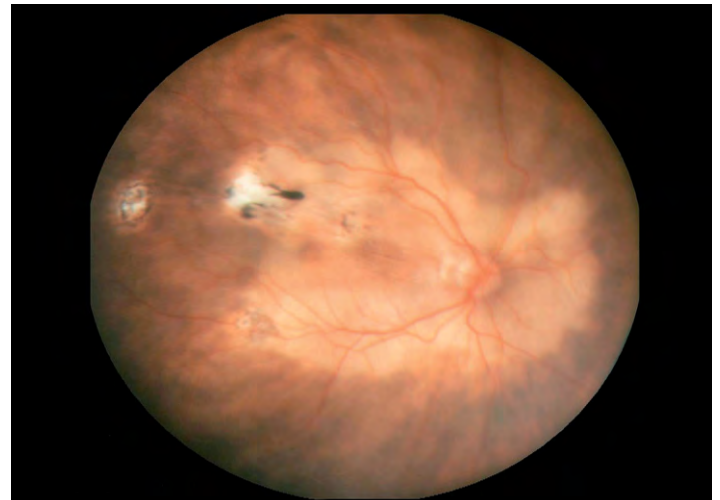
**Fig. 56.9** Slightly pigmented choroidal tumor. Both FA and ultrasonography are consistent with a medium-sized melanoma (A). FNAB identified a carcinoid tumor. (60×) (B)



**Fig. 56.10** Large peripapillary pigmented choroidal mass 9.0mm thick (A). FNAB showed melanocytoma with bland cells and very large pigment granules. (60×) (B)



**Fig. 56.11** Schematic ab externo eye-wall biopsy.



**Fig. 56.12** Intraocular lymphoma. This case had a negative vitrectomy and FNAB result. Diagnosis was obtained with eye-wall biopsy.



Figure 56.12 shows a post eye-wall biopsy patient in whom intraocular lymphoma was diagnosed after we were unable to establish the diagnosis with a vitreous biopsy.<sup>69–72</sup>

In a German study of 34 cases between 1994 and 1999, intraocular biopsies (11 iris and 23 posterior tumors) using a vitreous cutter were performed.<sup>73</sup> The technique used was a standard core vitrectomy: the intraocular pressure was raised and then tissue biopsied using a vitreous cutter with aspiration setting at 400 mmHg and a low cutting rate of 80/min. A Sato knife was used to incise the retina, and then the tumor was cut out and the intraocular pressure gradually lowered from 70 to 42 mmHg. The authors were able to establish a diagnosis in 97% of cases; however, they had one patient who developed intraocular recurrence 5 months after biopsy, and some vitreous hemorrhages occurred.

**Endoretinal biopsy** In patients who require an endoretinal biopsy for a diffuse process, it is easier to operate on a detached retina at the junction of the involved and uninvolved retina in the upper temporal quadrant (for easier gas/fluid retinal tamponade).<sup>74</sup> Johnston and colleagues used endocautery and then removed a 2 × 2 mm area of retina with vertical cutting scissors, grasped it with forceps, and did an air/fluid exchange and endolaser. Cataract can occur after this procedure, along with vitreous hemorrhage and retinal detachment.

We and others have demonstrated that a diagnosis of retinoblastoma can be made with a fine needle biopsy, but it is rarely indi-

cated.<sup>75,76</sup> Biopsy for suspected retinoblastoma should be limited only to cases with atypical presentations. The last patient to undergo biopsy for retinoblastoma in our center was an 18-year-old who had 20/50 vision, diffuse uveitis, and no obvious tumor.

## CONCLUSION

In selected cases of possible ocular tumors that require intervention but about which there is diagnostic uncertainty, fine needle aspiration biopsy is a useful technique. In our experience, we are able to obtain a definitive diagnosis in approximately 95% of cases. Rarely, especially in the intraocular lymphoma group if there is a predominantly subretinal neoplasm, either an eye-wall resection-based biopsy or an endoretinal biopsy is required.

In addition to establishing a correct diagnosis, these techniques can be used to improve our understanding of the biology of these tumors, as well as the prognosis. Genomic studies such as FISH and comparative genomic hybridization can be performed, looking for alterations on chromosomes 3 and 8 on fine needle biopsy specimens. Further, with microarray techniques it is possible to assess genes associated with poor prognosis in uveal melanoma. One of our original reasons for performing fine needle aspiration biopsies in uveal melanomas prior to charged particle or radioactive plaque irradiation was that we believed that newer systemic therapies would be available for patients with poor prognostic tumors. The obvious challenge is to develop treatments that will allow us to use this information and improve patient care.

## REFERENCES

- Jensen OA, Andersen SR. Late complications of biopsy in intraocular tumors. *Acta Ophthalmol (Copenh)* 1959; 37: 568–575.
- Meisner W. Zur Diagnose des Aderhautsarkoms. *Klin Monatsbl Augenheilkd* 1923; 70: 722–732.
- Popovic JM. Zur Diagnose des Aderhautsarkoms. *Klin Monatsbl Augenheilkd* 1931; 86: 816–819.
- Velhagen K. Ueber die diagnostische Punktion bei Verdacht auf Sarkom der Aderhaut. *Klin Monatsbl Augenheilkd* 1941; 107: 354–361.
- Sanders TE. Intraocular biopsy: an evaluation. *Am J Ophthalmol* 1953; 36: 1204–1220.
- Makley TA Jr. Biopsy of intraocular lesions. *Am J Ophthalmol* 1967; 64: 591–599.
- Long JC, Black WC, Danielson RW. Aspiration biopsy in intraocular tumors. *Arch Ophthalmol* 1953; 50: 303–310.
- Andersen SR. Biopsy in intraocular tumours: a preliminary report. *Acta Ophthalmol (Copenh)* 1954; 32: 645–657.
- Char DH. History of ocular oncology. *Ophthalmology* 1996; 103: S96–101.
- Karcioglu ZA, Gordon RA, Karcioğlu GL. Tumor seeding in ocular fine needle aspiration biopsy. *Ophthalmology* 1985; 92: 1763–1767.
- Glasgow BJ, Brown HH, Zargoza AM, Foos RY. Quantitation of tumor seeding from fine needle aspiration of ocular melanoma. *Am J Ophthalmol* 1988; 105: 538–546.
- Collaborative Ocular Melanoma Study. Accuracy of diagnosis of choroidal melanomas in the Collaborative Ocular Melanoma Study. COMS report no.1. *Arch Ophthalmol* 1990; 108: 1268–1273.
- Char DH. Tumors of the eye and ocular adnexa. New York: BC Decker, 2001; 199–224.
- Palexas GN, Green WR, Goldberg MF, Ding Y. Diagnostic pars plana vitrectomy report of a 21-year retrospective study. *Trans Am Ophthalmol Soc* 1995; 93: 281–308.
- Ljung B-M, Char DH, Miller TR, Deschenes J. Intraocular lymphoma. Cytologic diagnosis and the role of immunologic markers. *Acta Cytol* 1988; 32: 840–847.
- Char DH, Ljung BM, Miller TR, Phillips TL. Primary intraocular lymphoma (ocular reticulum cell sarcoma) diagnosis and management. *Ophthalmology* 1988; 95: 625–630.
- Char DH, Ljung B-M, Deschenes J, Miller TR. Intraocular lymphoma: immunological and cytological analysis. *Br J Ophthalmol* 1988; 72: 905–911.
- Whitcup SM, de Smet MD, Rubin BI et al. Intraocular lymphoma. Clinical and histopathologic diagnosis. *Ophthalmology* 1993; 100: 1399–1406.
- Ciulla TA, Pesavento RD, Yoo S. Subretinal aspiration biopsy of ocular lymphoma. *Am J Ophthalmol* 1997; 123: 420–422.
- Levy-Clarke GA, Byrnes GA, Buggage RR et al. Primary intraocular lymphoma diagnosed by fine needle aspiration biopsy of a subretinal lesion. *Retina* 2001; 21: 281–284.
- Decaussin M, Devouassoux-Shishe Boran M, Salle M et al. Cytological aspiration of intraocular retinoblastoma in an 11-year-old boy. *Diagn Cytopathol* 1998; 19: 190–193.
- Akpek EK, Ahmed I, Hochberg FH et al. Intraocular–central nervous system lymphoma. *Ophthalmology* 1999; 106: 1805–1810.
- Davis JL, Viciano AL, Ruiz P. Diagnosis of intraocular lymphoma by flow cytometry. *Am J Ophthalmol* 1997; 124: 362–372.
- Coupland SE, Bechrakis NE, Anastassiou G et al. Evaluation of vitrectomy specimens and chorioretinal biopsies in the diagnosis of primary intraocular lymphoma in patients with masquerade syndrome. *Graefes Arch Clin Exp Ophthalmol* 2003; 241: 860–870.
- Akpek EK, Maca SM, Christen WGG, Foster S. Elevated vitreous interleukin-10 level is not diagnostic of intraocular–central nervous system lymphoma. *Ophthalmology* 1999; 106: 2291–2295.
- Buggage RR, Velez G, Myers-Powell B et al. Primary intraocular lymphoma with a low interleukin 10 to interleukin 6 ratio and heterogeneous IgH gene rearrangement. *Arch Ophthalmol* 1999; 117: 1239–1242.
- Wolf LA, Reed GF, Buggage RR, Nussenblatt RB, Chan C-C. Vitreous cytokine levels. *Ophthalmology* 2003; 110: 1671–1672.
- Katai N, Kuroiwa S, Fujimori K, Yoshimura N. Diagnosis of intraocular lymphoma by polymerase chain reaction. *Graefes Arch Clin Exp Ophthalmol* 1997; 235: 431–436.
- Shen DF, Zhuang Z, LeHoang P et al. Utility of microdissection and polymerase chain reaction for the detection of immunoglobulin gene rearrangement and translocation in primary intraocular lymphoma. *Ophthalmology* 1998; 105: 1664–1669.
- White VA, Gascoyne RD, Paton KE. Use of the polymerase chain reaction to detect B- and T-cell gene rearrangements in vitreous specimens from patients with intraocular lymphoma. *Arch Ophthalmol* 1999; 117: 761–765.
- Merle-Béral H, Davi F, Cassoux N et al. Biological diagnosis of primary intraocular lymphoma. *Br J Haematol* 2004; 124: 469–473.
- Chan CC, Shen DF, Buggage RR. Immunopathology and molecular biology of primary intraocular lymphoma. In: Zierhut, Jager, Ksander, eds. *Immunology of ocular tumors*. Lisse: Swets Zeitlinger, 2002.
- Gorochov G, Parizot C, Bodaghi B et al. Characterization of vitreous B-cell infiltrates in patients with primary ocular lymphoma, using CDR3 size polymorphism analysis of antibody transcripts. *Invest Ophthalmol Vis Sci* 2003; 44: 5235–5241.
- Read RW, Zamir E, Rao NA. Neoplastic masquerade syndromes. *Surv Ophthalmol* 2002; 47: 81–124.
- Pavan PR, Oteiza EE, Margo CE. Ocular lymphoma diagnosed by internal subretinal pigment epithelium biopsy. *Arch Ophthalmol* 1995; 113: 1233–1234.
- Martin DF, Chan CC, de Smet MD et al. The role of chorioretinal biopsy in the management of posterior uveitis. *Ophthalmology* 1993; 100: 705–714.

37. Lafaut BA, Hanssens M, Verbraken H, De Laey JJ. Choroidretinal biopsy in the diagnosis of intraocular lymphoma: a case report. *Bull Soc Belge Ophthalmol* 1994; 252: 67–73.
38. Lois N, Hiscott PS, Nash J, Wong D. Immunophenotypic shift in a case of mycosis fungoides with vitreous invasion. *Arch Ophthalmol* 2000; 118: 1692–1694.
39. Williams GC, Holtz E, Lee AG, Font RL. T-cell lymphoproliferative disorder of vitreous associated with mycosis fungoides. *Arch Ophthalmol* 2000; 118: 278–280.
40. Char DH, Schwartz A, Miller TR, Abele JS. Ocular metastases from systemic melanoma. *Am J Ophthalmol* 1980; 90: 702–707.
41. Gündüz K, Shields JA, Shields CL, Eagle RC Jr. Cutaneous melanoma metastatic to the vitreous cavity. *Ophthalmology* 1998; 105: 600–605.
42. Robertson DM, Wilkinson CP, Murray JL, Gordy DD. Metastatic tumor to the retina and vitreous cavity from primary melanoma of the skin: treatment with systemic and subconjunctival chemotherapy. *Ophthalmology* 1981; 88: 1296–1301.
43. Shankar J, Damato BE, Hiscott P. Palliative vitrectomy for intraocular metastasis from cutaneous melanoma. *Eye* 2002; 16: 660–662.
44. Eide N, Syrdalen P. Intraocular metastasis from cutaneous malignant melanoma. *Acta Ophthalmol (Copenh)* 1990; 68: 102–106.
45. Spraul CW, Martin DF, Hagler WS, Grossniklaus HE. Cytology of metastatic cutaneous melanoma to the vitreous and retina. *Retina* 1996; 16: 328–332.
46. Soheilian M, Mirbabai F, Shahsavari M, Parvin M, Manieei F. Metastatic cutaneous melanoma to the vitreous cavity masquerading as intermediate uveitis. *Eur J Ophthalmol* 2002; 12: 324–327.
47. Gündüz K, Shields JA, Shields CL et al. Lung carcinoma metastatic to the vitreous cavity. *Retina* 1998; 18: 285–286.
48. Patel CK, Lam WC, Boerner S. Lung adenocarcinoma and malignant uveitis masquerade syndrome. *Ophthalmology* 2001; 108: 2151–2152.
49. Latkany P, Ciulla TA, Younger C, Gao H. Nonsmall cell lung adenocarcinoma metastatic to the vitreous without fundus lesions. *Ophthalmic Surg Lasers* 2000; 31: 155–156.
50. Mehriyar M, Jahadi SHR, Nader K, Kumar PV. Testicular germ cell tumor metastatic to the retina: vitreous fluid cytologic findings. *Acta Cytol* 2003; 47: 531–532.
51. Cangiarella JF, Suhlrad MJ, Cajigas A et al. Esophageal carcinoma metastatic to the retina. Diagnosis of a case by cytologic examination of intraocular vitreous washings. *Acta Cytol* 1996; 40: 995–998.
52. Piro P, Pappas HR, Erozan YS et al. Diagnostic vitrectomy in metastatic breast carcinoma in the vitreous. *Retina* 1982; 2: 182–188.
53. Davila RM, Miranda MC, Smith ME. Role of cytopathology in the diagnosis of ocular malignancies. *Acta Cytol* 1998; 48: 362–366.
54. Char DH, Kroll SM, Stoloff A et al. Cytopathology of uveal melanoma. Comparison of fine needle aspiration biopsy samples with histologic sections. *Anal Quant Cytol Histol* 1991; 13: 293–299.
55. Shields JA, Shields CL, Ehya H, Eagle RC Jr, De Potter P. Fine-needle aspiration biopsy of suspected intraocular tumors. The 1992 Urwick Lecture. *Ophthalmology* 1993; 100: 160–177.
56. Eide N, Syrdalen P, Walaas L, Hagmar B. Fine needle aspiration biopsy in selecting treatment for inconclusive intraocular disease. *Acta Ophthalmol Scand* 1999; 77: 448–452.
57. Schachat AP, Newsome DA, Miller E et al. Tissue culture of human choroidal melanoma cells obtained by fine-needle aspiration biopsy. *Graefes Arch Clin Exp Ophthalmol* 1986; 24: 407–413.
58. Pelosi G, Bonetti F, Colombari R, Bonzanini M, Iannucci A. Use of monoclonal antibody HMB-45 for detecting malignant melanoma cells in fine needle aspiration biopsy samples. *Acta Cytol* 1990; 34: 460–462.
59. Augsburger JJ. Fine needle aspiration biopsy of suspected metastatic cancers to the posterior uvea. *Trans Am Ophthalmol Soc* 1988; 86: 499–560.
60. Augsburger JJ, Shields JA, Folberg R et al. Fine needle aspiration biopsy in the diagnosis of intraocular cancer. Cytologic–histologic correlations. *Ophthalmology* 1985; 92: 39–49.
61. Cohen VML, Dinakaran S, Parsons MA, Rennie IG. Transvitreal fine needle aspiration biopsy: the influence of intraocular lesion size on diagnostic biopsy result. *Eye* 2001; 15: 143–147.
62. Augsburger JJ, Correa ZM, Schneider S et al. Diagnostic transvitreal fine-needle aspiration biopsy of melanocytic choroidal tumors in nevus versus melanoma category. *Trans Am Ophthalmol Soc* 2002; 100: 225–232.
63. Char DH, Miller TR, Ljung BM, Howes EL Jr, Stoloff A. Fine needle aspiration biopsy in uveal melanoma. *Acta Cytol* 1989; 33: 599–605.
64. Char DH, Miller TR. Accuracy of presumed melanoma diagnosis prior to alternative therapy. *Br J Ophthalmol* 1995; 79: 692–696.
65. Friedman SM, Margo CE, Stephenson JA. Choroidal metastasis from adenocarcinoma of the parotid gland. *Retina* 1999; 19: 457–459.
66. Jakobiec FA, Coleman DJ, Chattock A, Smith M. Ultrasonically guided needle biopsy and cytologic diagnosis of solid intraocular tumors. *Ophthalmology* 1979; 86: 1662–1681.
67. Shields CL, Honavar S, Shields JA, Demirci H, Meadows AT. Vitrectomy in eyes with unsuspected retinoblastoma. *Ophthalmology* 2000; 107: 2250–2255.
68. Char DH, Miller TR, Crawford JB. Uveal tumour resection. *Br J Ophthalmol* 2001; 85: 1213–1219.
69. Taylor D, Day S, Tiedemann K, Chessels J, Marshall WC, Constable IJ. Choroidretinal biopsy in a patient with leukaemia. *Br J Ophthalmol* 1981; 65: 489–493.
70. Rutzen AR, Ortega-Larrocea G, Dugel PU et al. Clinicopathologic study of retinal and choroidal biopsies in intraocular inflammation. *Am J Ophthalmol* 1995; 119: 597–611.
71. Gündüz K, Shields JA, Shields CL et al. Transscleral choroidal biopsy in the diagnosis of choroidal lymphoma. *Surv Ophthalmol* 1999; 43: 551–555.
72. Charteris D. Retinal biopsy. In: Hamilton AMP, Gregson R, Fish GE, eds. *Text atlas of the retina*. Boston: Butterworth–Heinemann, 1998.
73. Bechrakis NE, Foerster MH, Bornfeld N. Biopsy in indeterminate intraocular tumors. *Ophthalmology* 2002; 109: 235–242.
74. Johnston RL, Tufail A, Lightman S et al. Retinal and choroidal biopsies are helpful in unclear uveitis of suspected infectious or malignant origin. *Ophthalmology* 2004; 111: 522–528.
75. Char DH, Miller TR. Fine needle biopsy in retinoblastoma. *Am J Ophthalmol* 1984; 97: 686–690.
76. Das DK, Das J, Chachra KL, Natarajan R. Diagnosis of retinoblastoma by fine-needle aspiration and aqueous cytology. *Diagn Cytopathol* 1989; 5: 203–206.

# Retinal vascular tumors

Arun D. Singh, Paul A. Rundle and Ian Rennie

## INTRODUCTION

Retinal vascular tumors represent at least four distinct clinical entities, which include retinal capillary hemangioma, retinal cavernous hemangioma, retinal arteriovenous communications (Wyburn-Mason syndrome), and retinal vasoproliferative tumor. Retinal vascular tumors can also be considered as congenital (retinal cavernous hemangioma, retinal arteriovenous communications (Wyburn-Mason syndrome)), developmental (retinal capillary hemangioma), or acquired (retinal vasoproliferative tumor). Each of the subtypes has characteristic clinical features and an attempt should be made to differentiate them because of specific systemic associations, treatments, and prognoses associated with them. The clinical features and systemic associations of retinal vascular tumors are summarized in Table 57.1. Only a brief description of retinal capillary hemangioma and retinal arteriovenous communications (Wyburn-Mason syndrome) is included in this chapter as these topics are further discussed under Neuro-oculocutaneous syndromes (see Chapter 64).

## RETINAL CAPILLARY HEMANGIOMA

Although these retinal vascular tumors have been characterized as hemangioblastomas, various authors have recommended that the term capillary hemangioma rather than hemangioblastoma or hemangioendothelioma be used to describe them.<sup>1</sup> Retinal capillary hemangiomas can be further classified on the basis of their location within the retina (peripheral and juxtapapillary), morphology (endophytic, exophytic, and sessile), effects on the retina (exudative form and tractional form), and their relationship to von Hippel–Lindau (VHL) disease (with or without VHL disease).<sup>2</sup>

**Clinical features** Retinal capillary hemangiomas are multiple in about one-third of patients, and up to half the cases have bilateral involvement. The mean age at diagnosis of retinal capillary hemangioma in VHL disease is approximately 25 years.<sup>3</sup>

**Symptoms** Patients typically notice a progressive worsening of vision, which may be associated with photopsia. Many patients are asymptomatic and are detected on a routine examination or on screening evaluation because of a family history of VHL disease.<sup>4</sup>

**Signs** Ophthalmoscopically a retinal capillary hemangioma appears as a circumscribed, round retinal lesion with an orange-red color and prominent feeder vessels (Fig. 57.1). Intraretinal and subretinal exudation is often seen around the tumor or in the macula. The majority of

retinal capillary hemangiomas are located in the supero- and infero-temporal peripheral retina.<sup>5</sup> Prominent retinal vessels emerging from the optic disc are highly suggestive of a peripherally located retinal capillary hemangioma. In contrast, juxtapapillary retinal capillary hemangiomas are not associated with visible prominent feeder vessels.

**Diagnostic evaluation** The fundus findings of retinal capillary hemangioma are characteristic and the diagnosis can usually be made based solely on ophthalmoscopic examination. Fluorescein angiography is the most informative diagnostic tool because of the vascular nature of the tumor (Fig. 57.1).<sup>6</sup> Fluorescein angiography also helps in differentiating the feeder arteriole from the draining vein, and is therefore important for treatment planning (Box 57.1).

**Differential diagnosis** Some of the conditions that should be considered in the differential diagnosis include Coats' disease, macroaneurysm, and other forms of retinal vascular tumor.<sup>2</sup> Coats' disease is an idiopathic unilateral retinal vascular disease of young males which is characterized by retinal telangiectasia and retinal exudation.<sup>7</sup> The younger age of onset, unilateral involvement, predilection for males, and lack of systemic features are helpful differentiating features. Moreover, Coats' disease has prominent areas of retinal telangiectasia rather than distinct retinal vascular tumors.

Retinal macroaneurysm has many features that differentiate it from retinal capillary hemangioma.<sup>8</sup> In general, macroaneurysm is seen as a single lesion in the posterior pole in older individuals and is more likely to present with subretinal, intraretinal, or vitreous hemorrhage rather than retinal exudation. Most importantly, the feeder vessels are absent and careful fundus examination reveals that the macroaneurysm is centered on the retinal arteriole.

Important findings that differentiate a retinal capillary hemangioma from a vasoproliferative tumor is the absence of prominent feeder vessels in the latter, and its extreme peripheral location in the inferior retina.<sup>9</sup> Retinal capillary hemangioma is more commonly seen in the temporal quadrants of the mid-peripheral retina.<sup>2</sup> Unlike retinal capillary hemangioma, vasoproliferative tumors are non-familial and lack significant systemic associations.<sup>9</sup>

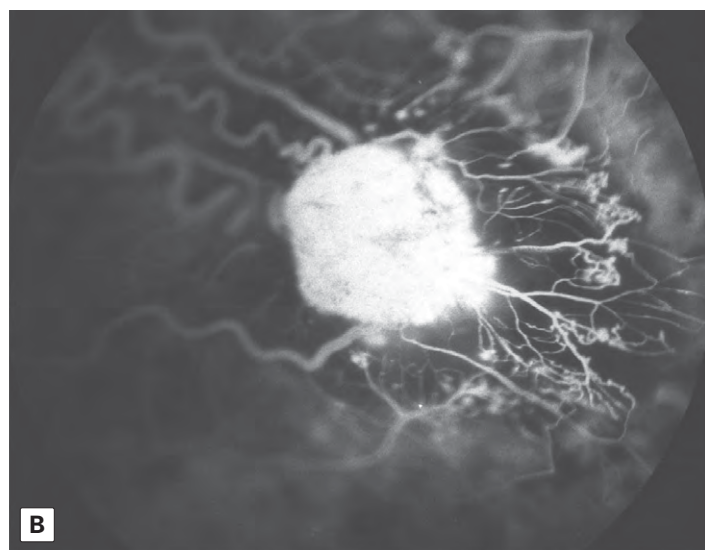
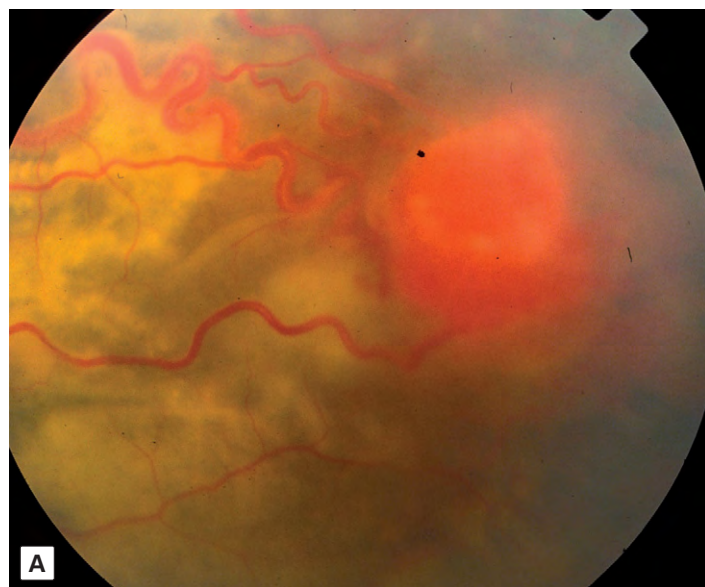
**Treatment** There are several methods of treating a retinal capillary hemangioma and the choice is determined by the size, location, and associated findings of subretinal fluid, retinal traction, and the visual



**Table 57.1** Diagnostic features of retinal vascular tumors

Type	Appearance	Location	Feeder vessels	Exudation	Systemic association
Capillary hemangioma	Round red mass	Juxtapapillary/peripheral	Prominent	Present	VHL disease
Cavernous hemangioma	Grape like clusters	Non-specific	Absent	Absent	CNS hemangioma
Arteriovenous malformations	Dilated/tortuous retinal vessels	Near the disc	Absent	Absent	Wyburn-Mason syndrome
Vasoproliferative tumor	Globular pale mass	Periphery	Absent	Present	Absent

VHL, von Hippel–Lindau disease.



**Fig. 57.1** Fundus photograph of a retinal capillary hemangioma. Prominent feeder vessels, retinal exudation, and subretinal fluid are present (A). Marked hyperfluorescence on fluorescein angiography is a characteristic finding (B). (Reproduced with permission from Bakri SJ, Sears JE, Singh AD. Transient closure of a retinal capillary hemangioma with verteporfin photodynamic therapy. *Retina* 2005; 25: 1103–1134.)

### BOX 57.1 Retinal Capillary Hemangioma

- Single or multiple, circumscribed, orange-red colored round retinal lesion
- Retinal exudation and or subretinal fluid surrounding the lesion which may extend into the macular region
- Prominent feeder vessels extending from the optic disc (absent in juxtapapillary variant)
- Prominent and early filling on fluorescein angiography, with late leakage

potential of the eye.<sup>10</sup> The treatment can be challenging owing to the presence of multiple tumors in both eyes and the potential for the development of new tumors.

**Observation** Careful observation in a reliable patient can be recommended if the retinal capillary hemangioma is very small (up to 500  $\mu\text{m}$ ), is not associated with exudation or subretinal fluid, and is not sight threatening.<sup>10</sup> Initial observation should always be considered in juxtapapillary retinal capillary hemangioma as they tend to remain stable.<sup>11</sup>

**Laser photocoagulation** applied over many sessions is effective (91–100%) in treating retinal capillary hemangioma that are up to 4.5 mm in size, but is most effective in tumors that are 1.5 mm or smaller.<sup>12</sup> Photocoagulation can be applied directly to the tumor, to the feeder artery, or to both.<sup>13</sup>

**Cryotherapy** is preferable to photocoagulation when the retinal capillary hemangioma is located anteriorly and is more than 3.0 mm in diameter.<sup>14</sup> Cryotherapy may also be preferred when there is moderate amount of subretinal fluid. The efficacy of cryotherapy is greater with smaller tumors (<1.5 mm).<sup>10</sup>

**Photodynamic therapy** More recently, photodynamic therapy has been reported to induce the occlusion of juxtapapillary<sup>11</sup> and peripheral retinal capillary hemangiomas.<sup>15,16</sup>

**Radiotherapy** Retinal capillary hemangioma that are larger than 4 mm show a poor response to cryotherapy and laser photocoagulation, and can be treated successfully with plaque radiotherapy.<sup>17</sup> Low-dose external beam radiotherapy is also an option in cases that do not respond to the usual treatment methods listed above.<sup>18</sup>

**Vitreoretinal procedures** Pars plana vitrectomy, retinal detachment repair, and other related procedures are usually required for larger retinal capillary hemangiomas that are complicated by rhegmatogenous or tractional retinal detachment.

**Association with von Hippel–Lindau disease** Retinal capillary hemangiomas can occur sporadically, or in association with VHL disease.<sup>19,20</sup> The association with VHL disease is discussed in detail elsewhere.

**Prognosis** The visual prognosis, even in adequately treated cases, is guarded.<sup>2</sup> Overall, more than 25% of affected patients show permanent visual loss and about 20% have vision of less than 20/100 in at least one eye.<sup>5</sup> However, the visual outcome is greatly dependent on the size, location, and number of retinal capillary hemangiomas, and the presence of exudative or tractional retinal detachment. As retinal capillary hemangiomas progressively enlarge, the visual outcome is much better in cases that are diagnosed and treated before the onset of symptoms.<sup>5</sup>

## CAVERNOUS HEMANGIOMA OF THE RETINA

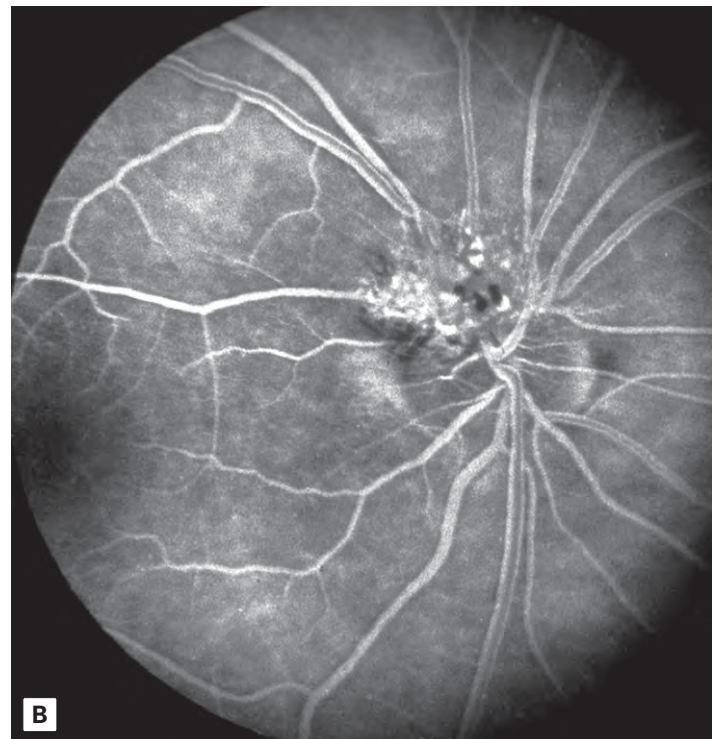
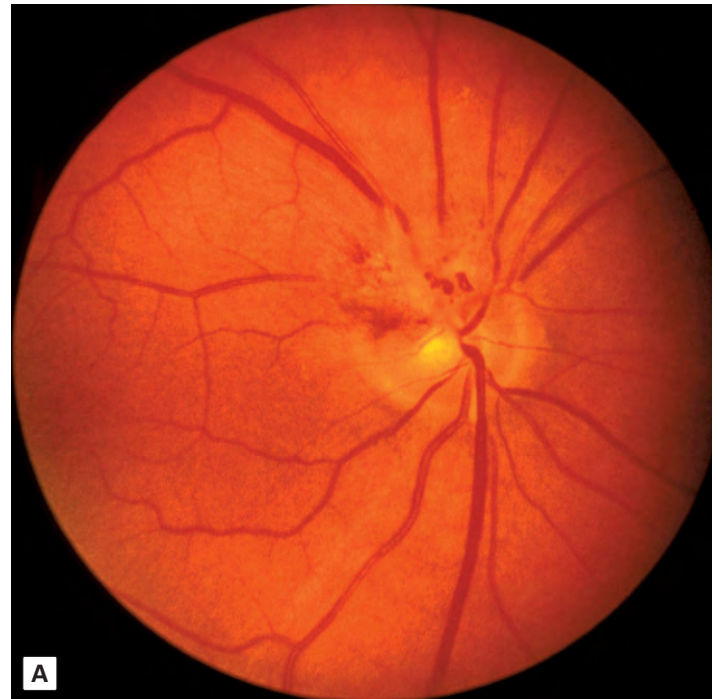
Cavernous hemangioma of the retina are composed of multiple, thin-walled dilated vascular channels with surface gliosis.<sup>21</sup> The walls are lined by non-fenestrated endothelium, which explains the lack of exudation.<sup>22</sup> Two forms of cavernous hemangioma of the retina are recognized: sporadic and syndromic.<sup>21</sup> It has been suggested that the cerebral cavernous malformation syndromes should be included with the neuro-oculocutaneous (phakomatoses) syndromes, but the association of cerebral and cutaneous hemangiomas is inconsistent.<sup>21</sup>

**Clinical features** Cavernous hemangiomas of the retina are believed to be a rare form of congenital hamartoma. The age of presentation in a series of nine patients ranged from 1 to 55 years.<sup>23</sup>

**Symptoms** Patients may be asymptomatic or may present with reduced vision due to a macular location of the hemangioma, macular fibrosis, or vitreous hemorrhage.

**Signs** Retinal lesions appear as grape-like clusters of blood-filled saccular spaces in the inner layers of the retina or on the surface of the optic disc (Fig. 57.2).<sup>21</sup> The size and location of the tumor are variable, but epiretinal membranes are usually present. There are no prominent feeder vessels, and there is a lack of subretinal or intraretinal exudation.

**Diagnostic evaluation** The ophthalmoscopic findings of cavernous hemangioma of the retina are characteristic. Fluorescein angiography is the most helpful diagnostic test in establishing the correct diagnosis. It demonstrates the retinal origin of the hemangioma with a low flow system and hence delayed filling in the venous phase (Fig. 57.2). The saccular dilatations in the hemangioma appear as fluorescent caps due to staining of supernatant plasma overlying collections of sedimented erythrocytes. Although cavernous hemangiomas are distributed randomly in the fundus, they tend to follow the course of a major vein; however, feeder vessels are not prominent. There is a characteristic absence of leakage (Box 57.2).



**Fig. 57.2** Fundus photograph of a peripapillary cavernous hemangioma of the retina. Note the absence of retinal exudation (A). On fluorescein angiography characteristic hyperfluorescent saccular dilatations are evident (B). (Reproduced with permission from Singh AD, Rundle PA, Rennie IG. Retinal vascular tumors. *Ophthalmol Clin North Am* 2005; 18: 167–176.)

**Differential diagnosis** Cavernous hemangioma of the retina should be differentiated from other vascular disorders, such as Coats' disease, retinal capillary hemangioma, retinal arteriovenous communications, and retinal vasoproliferative tumors. The presence of dilated feeder vessels and retinal exudation does not support the diagnosis of retinal cavernous hemangioma.



**BOX 57.2 Cavernous Hemangioma of the Retina**

- Retinal lesions appear as grape-like clusters of blood-filled saccular spaces in the inner layers of the retina or on the surface of the optic disc
- Overlying epiretinal membranes are usually present
- Absence of prominent feeder vessels
- Lack of subretinal fluid and intraretinal exudation
- May be associated with CNS hemangioma

**Treatment** In general, cavernous hemangiomas of the retina are non-progressive, may undergo spontaneous thrombosis, and rarely cause vitreous hemorrhage. No effective treatment is known or indeed required, although laser photocoagulation has been attempted in a few cases.<sup>21</sup>

**Association with CNS hemangioma** Cavernous hemangioma of the retina may be associated with cerebral cavernous malformations in the context of an autosomal dominant syndrome with high penetrance and variable expressivity.<sup>24,25</sup> The association between retinal and CNS hemangioma is discussed in detail elsewhere.

**Prognosis** The vast majority of cases of cavernous hemangioma of the retina remain asymptomatic, do not progress, and require no treatment. A small number of cases may have associated self-limiting vitreous hemorrhage. With time, cavernous hemangiomas of the retina undergo progressive thrombosis and often demonstrate an increase in surface gliosis. In contrast, cerebral cavernous hemangiomas may have serious consequences such as seizures, intracranial hemorrhages, and even death.<sup>24</sup>

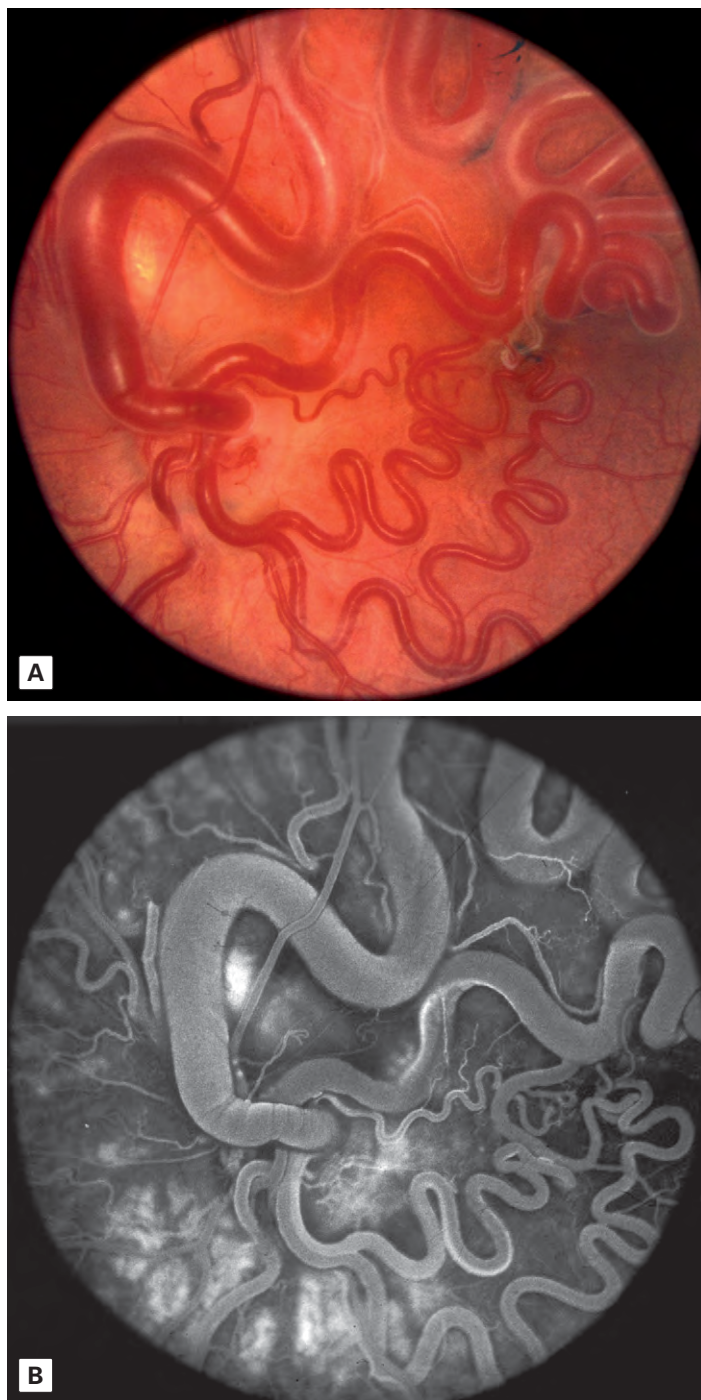
**WYBURN-MASON SYNDROME**

Wyburn-Mason syndrome is a rare sporadic disorder characterized by congenital arteriovenous malformations, principally of the retina and brain. Other involved tissues may include the skin, bones, kidneys, muscles, and gastrointestinal tract.<sup>26,27</sup>

**Clinical features** Although usually congenital in origin, the diagnosis of retinal arteriovenous malformations is most commonly made in later childhood.

**Symptoms** Patients with retinal arteriovenous malformations may be asymptomatic. These lesions are often detected as an incidental finding in an asymptomatic patient, or as a cause of visual impairment in an ‘amblyopic’ eye.

**Signs** Arteriovenous malformations are seen readily on ophthalmoscopy. They have been classified into three groups depending upon the severity of vascular malformation.<sup>28</sup> Those in group I have an abnormal capillary plexus between the major vessels of the arteriovenous malformation. Group II lack any intervening capillary between the artery and the vein. Group III are the most extensive malformations, with dilated and tortuous vessels and no apparent distinction between artery and vein (Fig. 59.3).



**Fig. 57.3** Fundus appearance of a typical retinal arteriovenous malformation (A). On fluorescein angiography arteries and veins appear undistinguishable (B).

**Diagnostic evaluation** The ophthalmoscopic findings of arteriovenous malformations of the retina are characteristic. Fluorescein angiography is the most helpful diagnostic test in establishing the correct diagnosis. It demonstrates abnormal arteriovenous connections and the presence or absence of intervening capillaries. In the most severe cases (grade III) arteries and veins cannot be differentiated even on angiography (Fig. 57.3). Abnormal retinal vasculature characteristically demonstrates an absence of leakage (Box 57.3).



**BOX 57.3 Wyburn-Mason Syndrome**

- Retinal arteriovenous malformations appear as abnormally dilated and tortuous retinal vessels
- Absence of prominent feeder vessels
- Lack of subretinal fluid and intraretinal exudation
- May be associated with intracranial arteriovenous malformations

**Differential diagnosis** Retinal arteriovenous communications should be differentiated from other vascular disorders listed above. The presence of dilated feeder vessels and retinal exudation goes against a diagnosis of retinal arteriovenous communication.

**Treatment of retinal arteriovenous communications** Retinal vascular malformations are usually not amenable to therapy.

**Association with intracranial arteriovenous malformations** The exact incidence of intracranial arteriovenous malformations in patients with retinal arteriovenous malformations is not known. This topic is discussed in detail elsewhere.

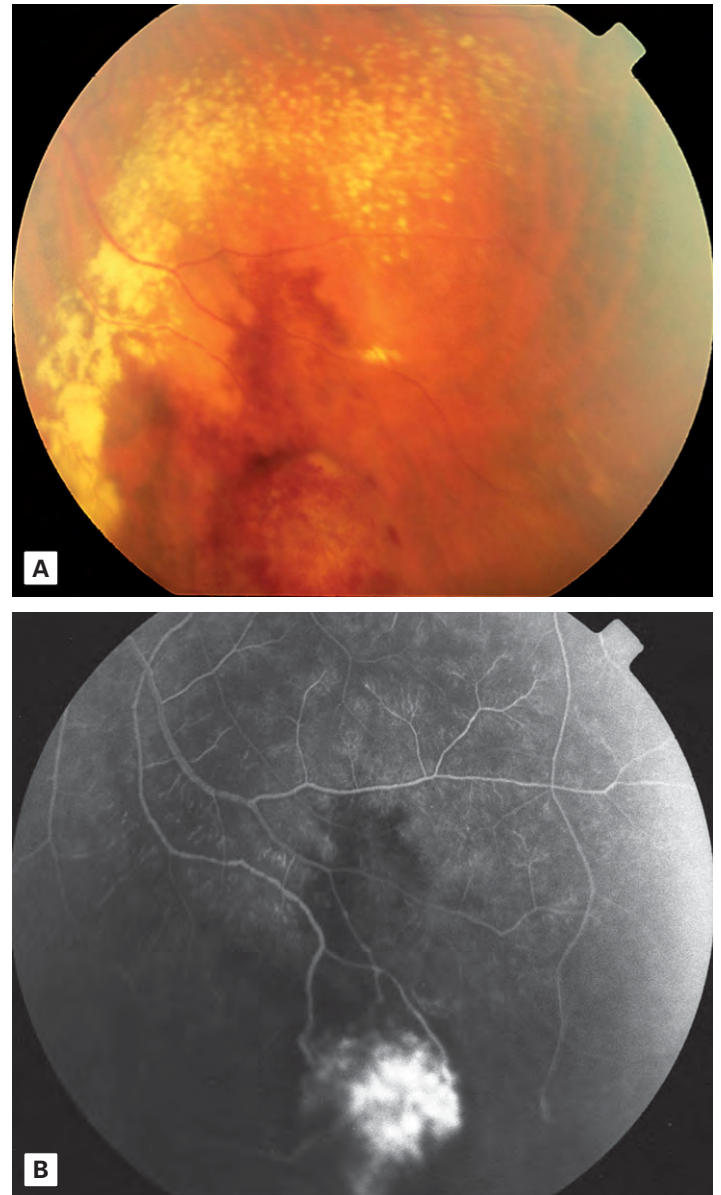
**Prognosis** Retinal vascular anomalies may alter in configuration over many years, exhibiting increasing tortuosity<sup>29</sup> and sometimes leading to vascular occlusions<sup>30</sup> and retinal ischemia, with the development of neovascular glaucoma. Patients with group III retinal arteriovenous malformations have a high risk of visual loss, either as a result of retinal decompensation or via direct compression of retinal nerve fibers or the optic nerve.<sup>31,32</sup>

**RETINAL VASOPROLIFERATIVE TUMOR**

Retinal vasoproliferative tumors are uncommon retinal lesions which have only been recognized as a distinct clinical entity since 1982, when Baines<sup>33</sup> reported the combination of peripheral telangiectatic nodules and posterior fibrocellular membranes in five patients. These lesions were initially termed ‘presumed acquired retinal hemangiomas’ to differentiate them from capillary hemangiomas.<sup>34</sup> The nomenclature in the literature has varied, but at present vasoproliferative retinal tumor is the generally accepted term.<sup>9</sup> The exact nature of these tumors remains uncertain, but histologically they are composed of a mixture of glial cells and a network of fine capillaries, with some larger dilated blood vessels.<sup>35</sup> Vasoproliferative retinal tumors may be primary (74%) or secondary to a pre-existing ocular disease (26%).<sup>9</sup>

**Clinical features** Vasoproliferative retinal tumors usually present in the third or fourth decade and both sexes are equally affected.<sup>9</sup> The majority of primary tumors are solitary (87%), in contrast to secondary tumors, where multiple lesions were found in 42% of cases.

**Symptoms** Reduced vision, photopsia, and metamorphopsia are common presenting symptoms. Some asymptomatic cases are diagnosed incidentally on ophthalmoscopic evaluation.



**Fig. 57.4** Fundus appearance of a vasoproliferative retinal tumor (A). Diffuse hyperfluorescence in the late phase of the fluorescein angiogram (B). (Reproduced with permission from Singh AD, Rundle PA, Rennie IG. Retinal vascular tumors. *Ophthalmol Clin North Am* 2005; 18: 167–176.)

**Signs** Vasoproliferative tumors appear as a globular yellowish-pink vascular mass in the peripheral retina (Fig. 57.4). The lesions lack the dilated, tortuous, feeder vessels typically seen in retinal capillary hemangioma, but retinal vessels of normal or near normal caliber may be seen entering the lesion posteriorly. Vasoproliferative retinal tumors have a predilection for the inferior retina. Subretinal exudation, which may be extensive, is common, occurring in over 80% of cases.<sup>9</sup> Exudative retinal detachment, retinal and vitreous hemorrhage, and vitreous cells are frequent associated findings. Retinal pigment epithelial hyperplasia adjacent to the vasoproliferative retinal tumor may be evident, especially in secondary tumors.<sup>9</sup> Macular fibrosis (31%) and edema (18%) may lead to visual loss (Box 57.4).

**Diagnostic evaluation** Ancillary investigations such as fluorescein angiography are of limited value because of the peripheral nature

**BOX 57.4 Retinal Vasoproliferative Tumor**

- Appears as a globular yellowish-pink vascular mass
- Inferior peripheral retinal location
- Absence of dilated, tortuous, feeder vessels
- Associated retinal exudation, subretinal fluid, and macular fibrosis
- Pre-existing ocular disease, such as intermediate uveitis, other inflammation or retinitis pigmentosa

of most lesions. In cases where angiography is possible the lesions typically fill rapidly in the early phase, with increasing hyperfluorescence and diffuse leakage in the late phases (Fig. 57.4). Telangiectatic and dilated vessels are frequently observed within the tumor mass. Ultrasonography confirms a raised solid lesion with high internal reflectivity on both A- and B-scans. Intraocular biopsy may be necessary to establish a diagnosis in difficult cases.<sup>36</sup>

**Differential diagnosis** Atypical lesions may be confused with retinal capillary hemangioma, eccentric choroidal neovascularization (disciform), or even amelanotic melanoma. The absence of distinct feeder vessels or a family history is of value in differentiating a vasoproliferative retinal tumor from a retinal capillary hemangioma. Careful examination of the tumor's vascular supply should confirm its retinal origin, in contrast to eccentric disciform tumors, which arise beneath the sensory retina. Similarly, choroidal hemangiomas are subretinal and rarely surrounded by any significant degree of exudate.

**Treatment of vasoproliferative tumors**

**Observation** Small peripheral vasoproliferative retinal tumors lacking significant exudate or maculopathy can be managed by periodic observation. If the lesion is symptomatic or associated with a significant amount of exudate or detachment, then treatment is warranted.

**Cryotherapy** Most vasoproliferative retinal tumors can be treated successfully with triple freeze-thaw transconjunctival cryotherapy, although repeated treatments may be required.<sup>9</sup>

**Other** treatment options include plaque brachytherapy,<sup>9,37</sup> laser photocoagulation,<sup>9</sup> and photodynamic therapy.<sup>38</sup>

**Association with vasoproliferative tumor** About 25% of all vasoproliferative tumors are secondary to a pre-existing congenital, inflammatory, vascular, traumatic, dystrophic, or degenerative ocular disease such as intermediate uveitis, retinitis pigmentosa, and ocular toxoplasmosis.<sup>9</sup> Rare occurrences in monozygotic twins,<sup>39</sup> Waardenburg's syndrome,<sup>40</sup> and a possible association with systemic hypertension and hyperlipidemia have been reported.<sup>9</sup>

**Prognosis** In a large series of 103 patients up to one-third were initially managed by observation.<sup>9</sup> However, even small peripherally located vasoproliferative tumors may be associated with a significant loss of vision. Advanced cases can progress to neovascular glaucoma, requiring enucleation.

**ACKNOWLEDGEMENT**

This chapter was modified and reproduced in part with permission from Singh AD, Rundle PA, Rennie IG. Retinal vascular tumors. *Ophthalmol Clin North Am* 2005; 18: 167–176.

**REFERENCES**

1. Grossniklaus HE, Thomas JW, Vigneswaran N, Jarrett WH 3rd. Retinal hemangioblastoma. A histologic, immunohistochemical, and ultrastructural evaluation. *Ophthalmology* 1992; 99: 140–145.
2. Singh AD, Shields CL, Shields JA. von Hippel–Lindau disease. *Surv Ophthalmol* 2001; 46: 117–142.
3. Maher ER, Yates JR, Harries R et al. Clinical features and natural history of von Hippel–Lindau disease. *Q J Med* 1990; 77: 1151–1163.
4. Moore AT, Maher ER, Rosen P, Gregor Z, Bird AC. Ophthalmological screening for von Hippel–Lindau disease. *Eye* 1991; 5: 723–728.
5. Webster AR, Maher ER, Moore AT. Clinical characteristics of ocular angiomas in von Hippel–Lindau disease and correlation with germline mutation. *Arch Ophthalmol* 1999; 117: 371–378.
6. Gass JDM, Braunstein R. Sessile and exophytic capillary angiomas of the juxtapapillary retina and optic nerve head. *Arch Ophthalmol* 1980; 98: 1790–1797.
7. Coats G. Forms of retinal diseases with massive exudation. *Roy Lond Ophthalmol Hosp Rep* 1908; 17: 440–525.
8. Rabb MF, Gagliano DA, Teske MP. Retinal arterial macroaneurysms. *Surv Ophthalmol* 1988; 33: 73–96.
9. Shields CL, Shields JA, Barrett J, De Potter P. Vasoproliferative tumors of the ocular fundus. Classification and clinical manifestations in 103 patients. *Arch Ophthalmol* 1995; 113: 615–623.
10. Singh AD, Nouri M, Shields CL, Shields JA, Perez N. Treatment of retinal capillary hemangioma. *Ophthalmology* 2002; 109: 1799–1806.
11. Schmidt-Erfurth UM, Kusserow C, Barbazetto IA, Laqua H. Benefits and complications of photodynamic therapy of papillary capillary hemangiomas. *Ophthalmology* 2002; 109: 1256–1266.
12. Schmidt D, Natt E, Neumann HP. Long-term results of laser treatment for retinal angiomas in von Hippel–Lindau disease. *Eur J Med Res* 2000; 5: 47–58.
13. Blodi CF, Russell SR, Pulido JS, Folk JC. Direct and feeder vessel photocoagulation of retinal angiomas with dye yellow laser. *Ophthalmology* 1990; 97: 791–797.
14. Welch RB. The recognition and treatment of early angiomas of retinae and use of cryosurgery as an adjunct to therapy. *Trans Am Ophthalmol Soc* 1970; 68: 367–424.
15. Atebara NH. Retinal capillary hemangioma treated with verteporfin photodynamic therapy. *Am J Ophthalmol* 2002; 134: 788–790.
16. Bakri SJ, Sears JE, Singh AD. Transient closure of a retinal capillary hemangioma with verteporfin photodynamic therapy. *Retina* 2005; 25: 1103–1134.
17. Kreusel KM, Bornfeld N, Lommatzsch A, Wessing A, Foerster MH. Ruthenium-106 brachytherapy for peripheral retinal capillary hemangiomas. *Ophthalmology* 1998; 105: 1386–1392.
18. Raja D, Benz MS, Murray TG, Escalona-Benz EM, Markoe A. Salvage external beam radiotherapy of retinal capillary hemangiomas secondary to von Hippel–Lindau disease: visual and anatomic outcomes. *Ophthalmology* 2004; 111: 150–153.
19. Maher ER, Webster AR, Moore AT. Clinical features and molecular genetics of von Hippel–Lindau disease. *Ophthalmol Genet* 1995; 16: 79–84.
20. Singh AD, Shields JA, Shields CL. Solitary retinal capillary hemangioma: hereditary (von Hippel–Lindau disease) or nonhereditary? *Arch Ophthalmol* 2001; 119: 232–234.
21. Gass JD. Cavernous hemangioma of the retina. A neuro-oculo-cutaneous syndrome. *Am J Ophthalmol* 1971; 71: 799–814.
22. Messmer E, Font RL, Laqua H, Hopping W, Naumann GO. Cavernous hemangioma of the retina. Immunohistochemical and ultrastructural observations. *Arch Ophthalmol* 1984; 102: 413–418.
23. Messmer E, Laqua H, Wessing A et al. Nine cases of cavernous hemangioma of the retina. *Am J Ophthalmol* 1983; 95: 383–390.
24. Dobyms WB, Michels VV, Groover RV et al. Familial cavernous malformations of the central nervous system and retina. *Ann Neurol* 1987; 21: 578–583.
25. Goldberg RE, Pheasant TR, Shields JA. Cavernous hemangioma of the retina. A four-generation pedigree with neurocutaneous manifestations and an example of bilateral retinal involvement. *Arch Ophthalmol* 1979; 97: 2321–2324.

26. Wyburn-Mason R. Arteriovenous aneurysm of midbrain and retina, facial nevi and mental changes. *Brain Dev* 1943; 66: 163–203.
27. Theron J, Newton TH, Hoyt WF. Unilateral retinocephalic vascular malformations. *Neuroradiology* 1974; 7: 185–196.
28. Archer DB, Deutman A, Ernest JT, Krill AE. Arteriovenous communications of the retina. *Am J Ophthalmol* 1973; 75: 224–241.
29. Augsburger JJ, Goldberg RE, Shields JA, Mulberger RD, Magargal LE. Changing appearance of retinal arteriovenous malformation. *Graefes Arch Klin Exp Ophthalmol* 1980; 215: 65–70.
30. Bech K, Jensen OA. On the frequency of coexisting racemose hemangiomas of the retina and brain. *Acta Psychiatr Scand* 1961; 36: 47–56.
31. Shah GK, Shields JA, Lanning RC. Branch retinal vein obstruction secondary to retinal arteriovenous communication. *Am J Ophthalmol* 1998; 126: 446–448.
32. Efron L, Zakov ZN, Tomsak RL. Neovascular glaucoma as a complication of the Wyburn-Mason syndrome. *J Clin Neuroophthalmol* 1985; 5: 95–98.
33. Baines PS, Hiscott PS, McLeod D. Posterior non-vascularized proliferative extraretinopathy and peripheral nodular retinal telangiectasis. *Trans Ophthalmol Soc UK* 1982; 102: 487–491.
34. Shields JA, Decker WL, Sanborn GE, Augsburger JJ, Goldberg RE. Presumed acquired retinal hemangiomas. *Ophthalmology* 1983; 90: 1292–1300.
35. Irvine F, O'Donnell N, Kemp E, Lee WR. Retinal vasoproliferative tumors: surgical management and histological findings. *Arch Ophthalmol* 2000; 118: 563–569.
36. Bechrakis NE, Foerster MH, Bornfeld N. Biopsy in indeterminate intraocular tumors. *Ophthalmology* 2002; 109: 235–242.
37. Heimann H, Bornfeld N, Vij O et al. Vasoproliferative tumours of the retina. *Br J Ophthalmol* 2000; 84: 1162–1169.
38. Barbezatto IA, Smith RT. Vasoproliferative tumor of the retina treated with PDT. *Retina* 2003; 23: 565–567.
39. Wachtlin J, Heimann H, Jandek C et al. Bilateral vasoproliferative retinal tumors with identical localization in a pair of monozygotic twins. *Arch Ophthalmol* 2002; 120: 860–862.
40. Rundle P, Shields JA, Shields CL, Singh AD, Peairs R. Vasoproliferative tumour of the ocular fundus associated with Waardenburg's syndrome. *Eye* 2000; 14: 105–106.



# Coats' disease

Thomas M. Aaberg Jr

## INTRODUCTION

In 1908, George Coats, curator of the Royal London Ophthalmic Hospital, described an ophthalmic disease which was typically unilateral, had a predilection for healthy males, and resulted in focal deposition of exudates within the fundus and 'peculiar' retinal vascular findings.<sup>1</sup> Four years later, Coats classified his cases of 'exudative retinitis' into three groups.<sup>2</sup> Group I manifested massive exudation but no discernible vascular abnormalities. Group II had marked vascular disease, intraretinal hemorrhage, and exudation. Group III presented with obvious arteriovenous malformations and exudation. Group III was later considered to be a retinal hemangioma. During this same time, Theodor Leber described a non-exudative retinal vascular degeneration characterized by 'multiple miliary aneurysms.'<sup>3</sup> Leber's multiple miliary aneurysms are now believed to represent an early stage of Coats' disease.<sup>3</sup> In this chapter we provide a comprehensive review of the pathogenesis, clinical findings, treatment options, and prognosis of Coats' disease.

**Etiology and pathogenesis** Histologic preparations of eyes affected by Coats' disease reveal irregular dilation, thickening, and hyalinization of retinal vessels (capillaries, arteries, and veins), attenuation of endothelial cells, and disorganized and necrotic vessel walls.<sup>1,4-7</sup> Large aneurysms (50–350 μm) seen after trypsin digestion frequently formed large sausage-like or beaded outpouchings.<sup>6</sup> Other findings include PAS-positive deposits in vessel walls and the outer retinal layer, and intraretinal and subretinal cysts, hemorrhage, cholesterol, and lymphocytic infiltrates (Fig. 58.1).

Unfortunately, the histologic findings have not led to the elucidation of the cause of Coats' disease. Polysaccharide deposition in the vessel lumen and retinal hypoxia have been suggested as pathogenetic mechanisms.<sup>8,9</sup> More recently attention has focused on somatic mutation of the NDP gene implicating norrin, a protein with an important role in retinal angiogenesis.<sup>10,11</sup> The CRB1 (crumbs homolog 1) gene has also been implicated.<sup>12</sup> Unfortunately, it is unclear whether the Coats'-like changes are secondary events or due to an independent genetic mutation.

**Clinical features** The most common presenting signs in an affected child are strabismus and leukocoria. About 25% of cases are detected by screening eye examination. There is a gender predilection for Coats' disease, which affects males eight times more often than females, and whereas the majority of cases are unilateral, bilateral disease has been reported in up to 10% of cases.<sup>13</sup> The majority of cases present before

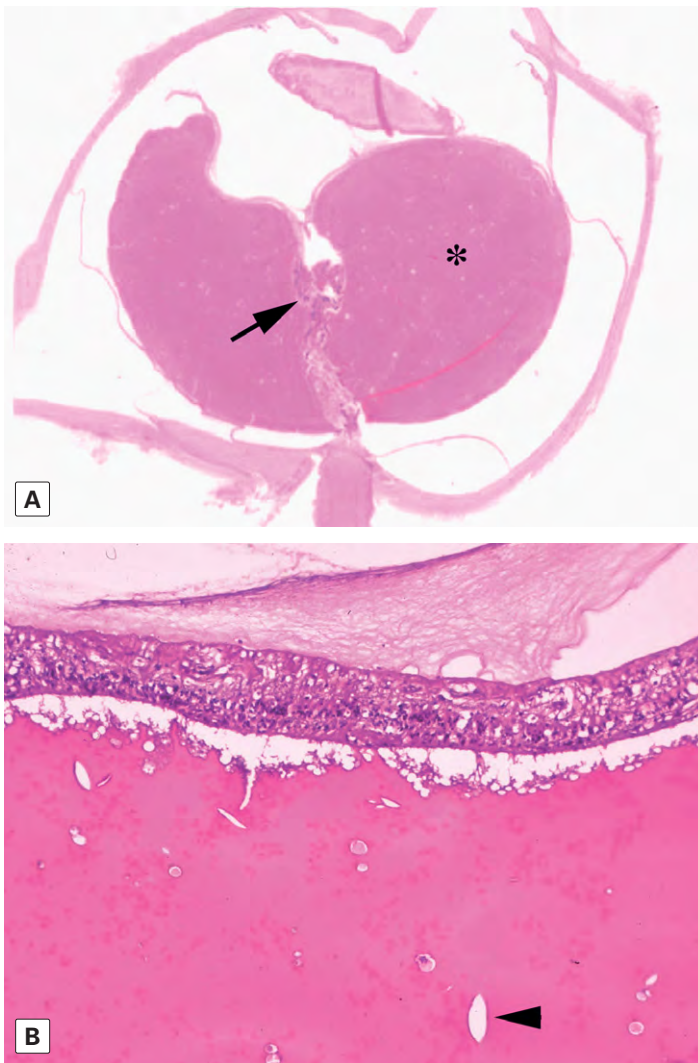
the second decade of life; however, there are reports of cases presenting within the first month of life and as late as the eighth decade.<sup>13-16</sup>

Clinical findings vary depending on the stage of the disease. Early in the disease process, vascular telangiectasia occurs focally within the retina, most often near or anterior to the equator (Fig. 58.2A).<sup>13,17</sup> The macula is involved in only 1% of these early cases.<sup>13</sup> The entire retinal vasculature (arteries, veins, and capillaries) appears to be affected. The caliber of the involved vessels varies as aneurysmal dilation and progressive telangiectasia occurs. The aneurysms may be saccular (sausage shaped), or bulbous (often described as having a 'light-bulb' appearance). As the disease progresses nearly all cases will develop intraretinal exudation and exudative retinal detachment. Intraretinal macrocysts develop in 10% of cases, most likely due to chronic retinal detachment.<sup>13,18</sup> The anterior segment changes, such as iris neovascularization, secondary glaucoma, and cataract, do not occur until late in the disease process.<sup>13,17</sup>

Extraocular associations have been reported with some cases of Coats' disease. It may be that these are simply coincidental, but they nevertheless warrant a mention. The most common association is with muscular dystrophy.<sup>19</sup> In a study of 64 patients affected with facioscapulohumeral muscular dystrophy, 48 (75%) had angiographic findings of retinal telangiectasia.<sup>19</sup> Concurrent CNS findings have also been reported, including central nervous system venous malformations<sup>20</sup> and cerebral calcifications.<sup>21</sup> Beyond these cases there exist only case reports of Coats' disease associated with a variety of syndromes, such as Turner syndrome,<sup>22</sup> Cornelia de Lange syndrome,<sup>23</sup> Hallermann-Streif syndrome,<sup>24</sup> and Osler-Weber-Rendu disease.<sup>8</sup>

**Diagnostic evaluation** In most cases Coats' disease can be diagnosed by clinical examination. However, fluorescein angiography is helpful both for diagnostic purposes and to assess the extent of the disease. Angiographic evaluation is particularly helpful in cases where the retinal telangiectasia is subtle or obscured by lipid exudation. Typical fluorescein angiographic findings include retinal telangiectasia, patchy areas of capillary dropout, and characteristic 'light-bulb' vascular aneurysm (Fig. 58.2B). Areas of capillary dropout are replaced with arteriovenous shunts. Fluorescein leaks from these incompetent vessels, resulting in cystoid macular changes or large areas of intra- and subretinal fluorescein collection.

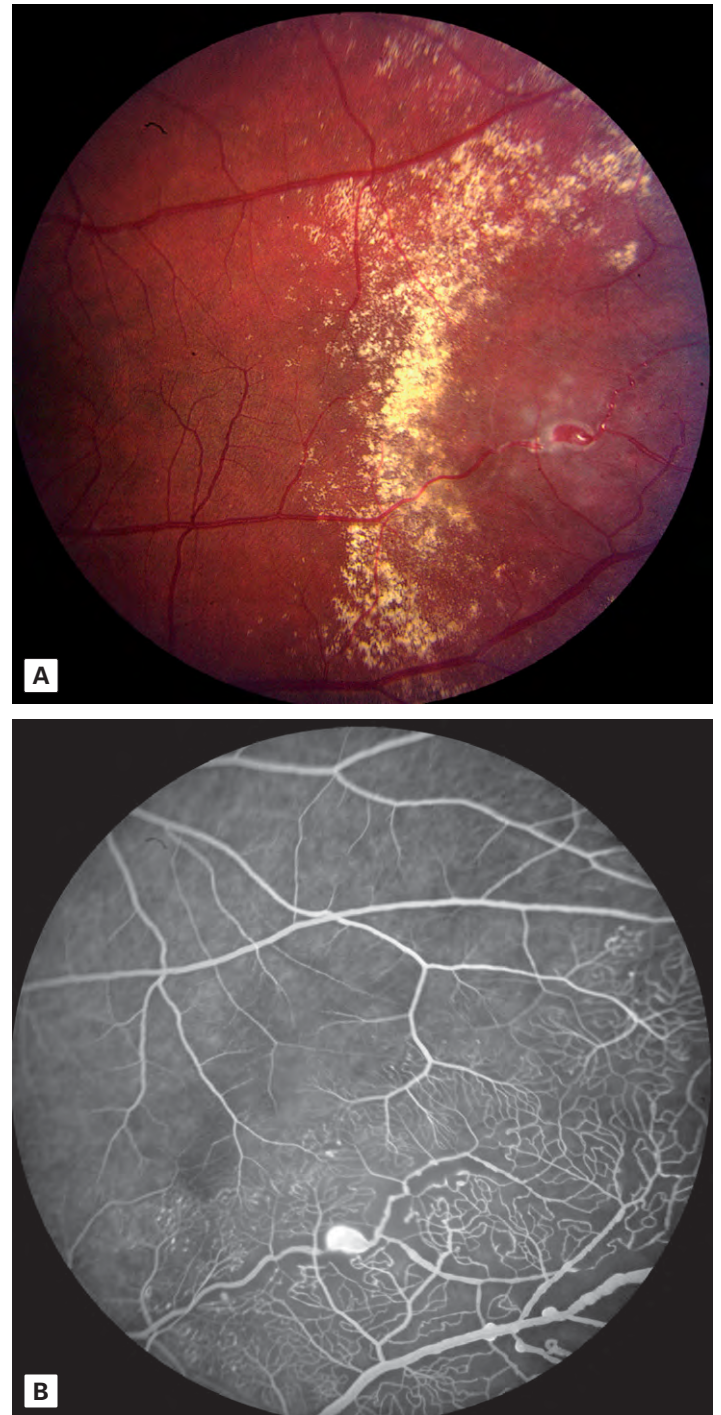
In more advanced cases of Coats' disease a total or near-total exudative detachment exists. Clinical or angiographic examination of the retinal vasculature may be difficult if not impossible. In such cases,



**Fig. 58.1** Enucleated eye with Coats' disease. Note the total exudative retinal detachment (arrow) and the subretinal exudate (asterisk) (Low-power, hematoxylin & eosin.) (A). Cystic degeneration, disorganization, and deposition of PAS-positive material in the outer retina. Cholesterol clefts are seen in the subretinal exudate (arrowhead). (High-power, hematoxylin & eosin.) (B).

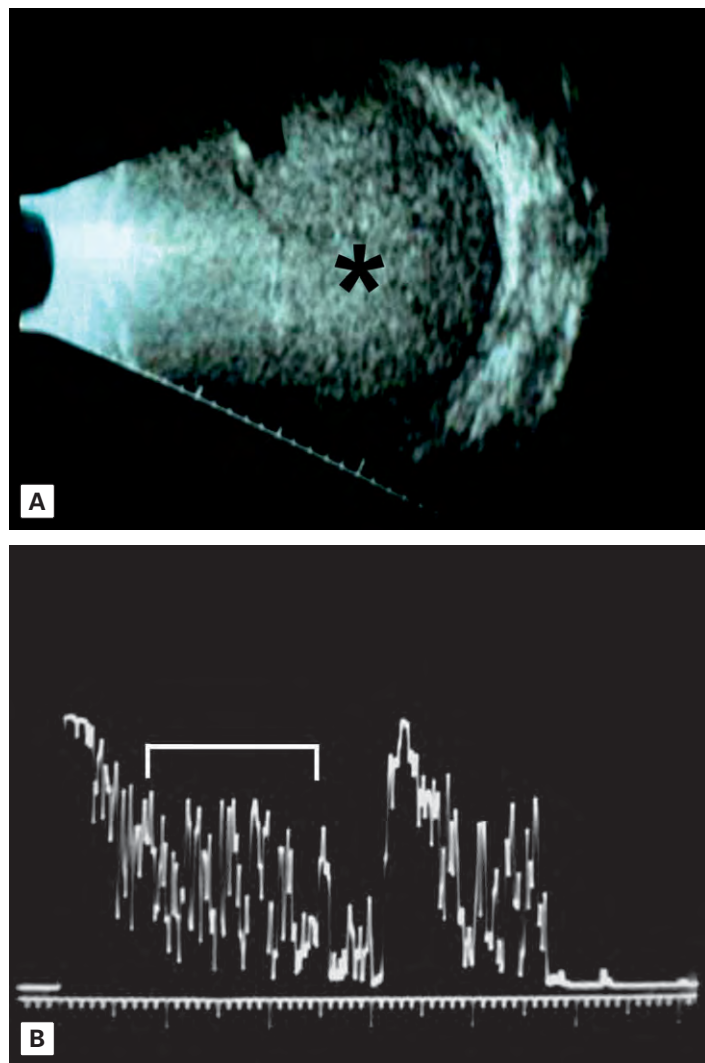
imaging with ocular ultrasonography, computerized tomography (CT), or magnetic resonance (MRI) may be necessary. The characteristic ultrasonographic findings include a relatively immobile, thickened, detached retina with homogeneous subretinal fluid and medium reflective echogenic clefts (Fig. 58.3). Highly reflective foci representing calcium deposition, frequently associated with retinoblastoma, are rarely seen in Coats' disease. When present, it usually represents osseous metaplasia of the retinal pigment epithelium in end-stage phthisical eyes.

CT can also detect calcium deposition, thereby facilitating the differentiation of retinoblastoma from Coats' disease. MRI cannot image bone or calcium, making this imaging modality somewhat sub-optimal. However, it does have superior contrast resolution. On  $T_1$ -weighted images the subretinal space is hyperintense.  $T_2$ -weighted images can be either hyper- or hypointense, depending on the extent of the retinal detachment and the composition of the exudate. After gadolinium contrast infusion the retina shows a well-delineated ribbon of enhancement.<sup>25</sup>



**Fig. 58.2** Fundus photograph of the left eye demonstrates the circinate lipid exudation surrounding retinal telangiectasia (A). Fluorescein angiography demonstrates the area of bulbous aneurysms, vascular telangiectasia, and areas of capillary non-perfusion (B).

Fine needle aspiration of the subretinal exudate demonstrates cholesterol crystals, lipid and pigment-laden macrophages, and the absence of tumor cells.<sup>26</sup> Fine needle aspiration biopsy (FNAB), although useful, should not be used routinely. Because retinoblastoma is a possible diagnosis, FNAB runs the risk of seeding the orbit with viable retinoblastoma cells. In non-seeing eyes with total retinal detachment and an uncertain diagnosis, enucleation should be preferred over FNAB.



**Fig. 58.3** Diagnostic ultrasonography of the eye in Fig. 58.1. Note the diffuse, homogeneous medium reflectivity of the posterior segment on B-scan (asterisk). The numerous echogenic clefts represent cholesterol crystals within the subretinal exudates (A). These crystals account for the medium reflective spikes seen on the A scan (bracket) (B).

**Differential diagnosis** The diagnosis of early stage Coats' disease is often straightforward. Foremost in the differential diagnosis is retinoblastoma, thereby making the stakes of an accurate diagnosis high (Table 58.1). Like Coats' disease, retinoblastoma most often presents with leukocoria and strabismus.<sup>27</sup> Exudative retinal detachments may be present in either condition. However, retinoblastoma typically presents at an earlier age, is more often bilateral (40% of cases), and 10% have a family history. Retinoblastomas are white to flesh-colored, in contrast to the yellow coloration of lipid seen in Coats' disease. Retinoblastoma tumors have an intrinsic vascular supply and often have associated calcium deposits. Small and even medium-sized tumors do not typically have associated lipid exudation, though serous retinal detachments will occur in exophytic tumors.

Vitreoretinal traction rarely occurs in Coats' disease. In contrast, it frequently occurs in many childhood vitreoretinopathies that are associated retinal telangiectasia, such as familial exudative vitreoretinopathy, retinopathy of prematurity, persistent hyperplastic primary vitreous, incontinentia pigmenti, Norrie's disease, and retinal capillary hemangioma (Table 58.2). For example, familial exudative vitreoretinopathy (FEVR) is a bilateral autosomal dominantly inherited vitreoretinal disease. These patients develop peripheral retinal telangiectasia and neovascularization, which may be associated with lipid exudation, shunt vessel formation, and aneurismal dilations much like Coats' disease. However, another manifestation of FEVR is abnormal vitreoretinal adhesions resulting in retinal traction. When significant traction occurs a falciform fold may develop from the disc to the involved peripheral retina, or the retina may tractionally detach. Retinopathy of prematurity (ROP), another bilateral vitreoretinal disease, will have a history of premature birth and a demarcation separating vascularized and avascular retina. Persistent hyperplastic primary vitreous (PHPV) is a congenital, typically unilateral malformation. The eyes are small and the anterior chamber is often shallow. Echography can often elucidate a stalk emanating from the disc or another posterior pole location and extending to the lens capsule. Incontinentia pigmenti will have typical dermatologic and dental findings characteristic of the disease.

Retinal capillary hemangioma may most closely represent Coats' disease. These cases have dilated tortuous arteries and veins, vascular

**Table 58.1** Coats' disease and retinoblastoma

		Coats' disease		Retinoblastoma
Feature	Demographic	Mean age at diagnosis	5 years	1.5 years
		Male	76%	50%
		Family history	0%	10%
	Ophthalmic	Unilateral	95%	60%
		Retinal vessels	Irregular dilatation with telangiectasia	Regular dilatation and tortuosity
		Retinal mass	Absent	Present
		Retinal exudation	Present	Absent
		Vitreous seeds	Absent	Present
	Diagnostic	USG	Retinal detachment	Retinal detachment with calcification
		CT scan	Calcification absent	Calcification present
MRI		Retinal detachment	Retinal detachment with enhancing mass	

USG, ultrasonography; CT, computed tomography; MRI, magnetic resonance imaging.

(Modified from Shields JA, Shields CL. Differentiation of Coats' disease and retinoblastoma. *J Pediatr Ophthalmol Strabismus* 2001; 38: 262-266)



**Table 58.2 Differential diagnosis of exudative retinopathy**

Entity	Demographics			Ophthalmoscopic findings			Inheritance	Systemic features
	Age	Sex	Laterality	Exudation	Traction	Other		
Coats' disease FEVR	5 years	M (75%)	Unilateral (95%)	+	-	Telangiectasia	Sporadic	Absent
	0-3 months	M (50%)	Bilateral	+	+	Peripheral retinal avascular zone	AD	Absent
		F (50%)						AR
Retinopathy of prematurity	Premature neonate	M (50%)	Bilateral	-	+	Neovascularization	Sporadic	Complications of premature birth
		F (50%)				Vitreous hemorrhage	Sporadic	
PHPV	0-5 years	M (50%)	Unilateral	-	+	Microphthalmia, cataract	Sporadic	Absent
		F (50%)				Shallow AC		
Incontinentia pigmenti	0-16 years	F (100%)	Bilateral	+	+	Vitreous stalk		
						Optic atrophy	XD	Skin rash
Norrie's disease	At Birth	M (50%)	Bilateral	+	+	Foveal hypoplasia		Hypodontia
						Retrolental mass	XR	Dystrophic nails
Retinal capillary hemangioma	25 years	M (50%)	Unilateral or bilateral	+	-	Capillary hemangioma	AD	Cognitive
		F (50%)						Sporadic
								Hearing loss
								VHL disease
								Sporadic

M, males; F, females; AC, anterior chamber; FEVR, familial exudative vitreoretinopathy; VHL, von Hippel-Lindau disease; PHPV, persistent hyperplastic primary vitreous; AD, autosomal dominant; AR, autosomal recessive; XR, X-linked recessive; XD, X-linked dominant.

shunts, and lipid exudation. Features that differentiate these vascular tumors from Coats' disease are the dilated tortuous feeding arteries and draining veins, the focal nodularity of the tumor, and the lack of telangiectasia.

**Treatment** The natural history is usually of a progressive disease. Although the rate of progression is variable, the majority of eyes will develop severe vision loss. Between 64% and 80% of eyes will become phthisical, and develop advanced glaucoma or retinal detachment.<sup>14</sup> Only rarely will the telangiectasia regress spontaneously.<sup>28</sup>

**Observation** can be considered in some cases with early-stage disease having little or no exudate, or in advanced non-seeing but comfortable eyes.

**Laser photocoagulation** The treatment should be initiated once progression is documented. The first line of treatment is laser photocoagulation and/or cryotherapy. The goal is to ablate the non-perfused retina and areas of telangiectasia. The entire area of retinal telangiectasia needs to be treated. The laser photocoagulation can only be performed in cases of absent or minimal exudative retinal detachment.

**Cryotherapy** Cases with a shallow exudative retinal detachment can be successfully treated with double freeze-thaw cryotherapy. Multiple treatment sessions every 3 months are usually necessary with either laser or cryotherapy.

**Surgical drainage** In advanced cases of Coats' disease where vision is still preserved but the retina is extensively detached, surgical drainage of the subretinal exudate can be considered. This is accomplished with a sclerotomy in the area of greatest exudation. Often more than one sclerotomy is required. If a significant amount of exudate must be drained, balanced saline solution is infused via either an anterior or a posterior chamber infusion cannula. A posterior chamber infusion cannula should only be placed if it can be safely passed through the pars plana without damaging the lens or retina and extends far enough that the tip does not end in the subretinal space. Once the subretinal exudate is drained, laser photocoagulation or cryotherapy is per-

formed. Some surgeons elect to encircle the eye with a scleral buckle to minimize tractional forces generated at the vitreous base.

**Vitreoretinal techniques** have also been used in cases with tractional detachment or epimacular membranes.<sup>29,30</sup>

**Supportive care** Protective eyewear must be stressed. These patients are often healthy, active young boys potentially predisposed to incurring injuries, and so every effort should be made to prevent injury to the unaffected eye without deterring normal daily or sporting activities. For bilateral cases, visual rehabilitation with low-vision aids and learning of the Braille alphabet may have to be recommended.

**Follow-up** Recurrence of disease in 7–10% of eyes up to a decade from the initial treatment has been reported.<sup>13,17,31</sup> Consequently, a lifetime of follow-up is necessary. Once stable, a patient should be seen every 6–12 months. Setting realistic expectations and providing a general timeline for follow-up care is essential.

**Prognosis** Overall, it can be expected that roughly 75% of patients will have an anatomic improvement or stabilization of the affected eye with treatment.<sup>31</sup> The remaining 25% will worsen or require enucleation. As expected, patients with early-stage disease fare far better than those with more advanced stages. In a series of 124 eyes (117 patients), 73% of patients with telangiectasia with or without extrafoveal lipid exudate had better than 20/200 vision, whereas only 26% who had partial or total exudative retinal detachments attained this level of vision.<sup>31</sup> The natural progression in advanced Coats' disease is toward the development of a blind, painful eye, or to a phthisical state.<sup>32</sup>

## CONCLUSIONS

A definitive therapy for Coats' disease will depend largely on a better understanding of its pathogenesis. Without an adequate animal model or an implicated gene, future developments will be hindered. Associations with other disease entities such as muscular dystrophy will hopefully lead to the etiologic gene. In the meantime our treatment of Coats' disease will need to concentrate on early detection and modulation of the affected retina via retinal ablation (laser and cryotherapy) or pharmacologic stabilization of exuding vessels.

## REFERENCES

- Coats G. Forms of retinal disease with massive exudation. *R Lond Ophthalm Hosp Rep* 1908; 17: 440–525.
- Coats G. Uber Retinitis exudativa (retinitis haemorrhagica externa). *Graefes Arch Ophthalmol* 1912; 81: 275–327.
- Leber TH. Uber eine durch Vorkommen multipler Miliaraneurysmen charakterisierte Form von Retinaldegeneration. *Graefes Arch Ophthalmol* 1912; 81: 1–14.
- Tripathi R, Ashton N. Electron microscopical study of Coat's disease. *Br J Ophthalmol* 1971; 55: 289–301.
- Farkas TG, Potts AM, Boone C. Some pathologic and biochemical aspects of Coats' disease. *Am J Ophthalmol* 1973; 75: 289–301.
- Egbert PR, Chan CC, Winter FC. Flat preparations of the retinal vessels in Coats' disease. *J Pediatr Ophthalmol* 1976; 13: 336–339.
- McGettrick PM, Loeffler KU. Bilateral Coats' disease in an infant (a clinical, angiographic, light and electron microscopic study). *Eye* 1987; 1: 136–145.
- Reese AB. Telangiectasis of the retina and Coats' disease. *Am J Ophthalmol* 1956; 42: 1–8.
- Wise GN. Coats' disease. *AMA Arch Ophthalmol* 1957; 58: 735–746.
- Black GC, Perveen R, Bonshek R et al. Coats' disease of the retina (unilateral retinal telangiectasis) caused by somatic mutation in the NDP gene: a role for norrin in retinal angiogenesis. *Hum Mol Genet* 1999; 8: 2031–2035.
- Berinstein DM, Hiraoka M, Trese MT, Shastry BS. Coats' disease and congenital retinoschisis in a single eye: a case report and DNA analysis. *Ophthalmologica* 2001; 215: 132–135.
- den Hollander AI, Heckenlively JR, van den Born LI et al. Leber congenital amaurosis and retinitis pigmentosa with Coats-like exudative vasculopathy are associated with mutations in the crumbs homologue 1 (*CRB1*) gene. *Am J Hum Genet* 2001; 69: 198–203.
- Shields JA, Shields CL, Honavar SG, Demirci H. Clinical variations and complications of Coats disease in 150 cases: the 2000 Sanford Gifford Memorial Lecture. *Am J Ophthalmol* 2001; 131: 561–571.
- Gomez Morales A. Coats' disease. Natural history and results of treatment. *Am J Ophthalmol* 1965; 60: 855–865.
- Woods AC, Duke JR. Coats's Disease. I. Review of the literature, diagnostic criteria, clinical findings, and plasma lipid studies. *Br J Ophthalmol* 1963; 47: 385–412.
- Smithen LM, Brown GC, Brucker AJ et al. Coats' disease diagnosed in adulthood. *Ophthalmology* 2005; 112: 1072–1078.
- Egerer I, Tasman W, Tomer TT. Coats disease. *Arch Ophthalmol* 1974; 92: 109–112.
- Chang MM, McLean IW, Merritt JC. Coats' disease: a study of 62 histologically confirmed cases. *J Pediatr Ophthalmol Strabismus* 1984; 21: 163–168.

19. Gurwin EB, Fitzsimons RB, Sehmi KS, Bird AC. Retinal telangiectasis in facioscapulohumeral muscular dystrophy with deafness. *Arch Ophthalmol* 1985; 103: 1695–1700.
20. Robitaille JM, Monsein L, Traboulsi EI. Coats' disease and central nervous system venous malformation. *Ophthalm Genet* 1996; 17: 215–218.
21. Goutieres F, Dollfus H, Becquet F, Dufier JL. Extensive brain calcification in two children with bilateral Coats' disease. *Neuropediatrics* 1999; 30: 19–21.
22. Cameron JD, Yanoff M, Frayer WC. Coats' disease and Turner's syndrome. *Am J Ophthalmol* 1974; 78: 852–854.
23. Folk JC, Genovese FN, Biglan AW. Coats' disease in a patient with Cornelia de Lange syndrome. *Am J Ophthalmol* 1981; 91: 607–610.
24. Newell SV, Hall BD, Anderson CW, Lim ES. Hallermann–Streiff syndrome with Coats disease. *J Pediatr Ophthalmol Strabismus* 1994; 31: 123–125.
25. De Potter P, Flanders AE, Shields JA et al. The role of fat-suppression technique and gadopentetate dimeglumine in magnetic resonance imaging evaluation of intraocular tumors and simulating lesions. *Arch Ophthalmol* 1994; 112: 340–348.
26. Haik BG, Koizumi J, Smith ME, Ellsworth RM. Fresh preparation of subretinal fluid aspirations in Coats' disease. *Am J Ophthalmol* 1985; 100: 327–328.
27. Shields JA, Shields CL. Differentiation of Coats' disease and retinoblastoma. *J Pediatr Ophthalmol Strabismus* 2001; 38: 262–266; quiz 302–263.
28. Deutsch TA, Rabb MF, Jampol LM. Spontaneous regression of retinal lesions in Coats' disease. *Can J Ophthalmol* 1982; 17: 169–172.
29. Yoshizumi MO, Kreiger AE, Lewis H et al. Vitrectomy techniques in late-stage Coats'-like exudative retinal detachment. *Doc Ophthalmol* 1995; 90: 387–394.
30. Schmidt-Erfurth U, Lucke K. Vitreoretinal surgery in advanced Coats' disease. *Ger J Ophthalmol* 1995; 4: 32–36.
31. Shields JA, Shields CL, Honavar SG et al. Classification and management of Coats disease: the 2000 Proctor Lecture. *Am J Ophthalmol* 2001; 131: 572–583.
32. Silodor SW, Augsburger JJ, Shields JA, Tasman W. Natural history and management of advanced Coats' disease. *Ophthalmic Surg* 1988; 19: 89–93.



# Retinal astrocytic tumors

Mehryar Taban, Mehran Taban and Arun D. Singh

## INTRODUCTION

Retinal astrocytic tumors represent two distinct types of benign retinal astrocytic tumor: astrocytic hamartoma and ‘acquired’ retinal astrocytoma. Retinal astrocytic hamartomas are more common and have a known association with tuberous sclerosis. ‘Acquired’ retinal astrocytomas are rare astrocytic tumors that develop at any age, have no family history, and are not associated with tuberous sclerosis or other systemic syndromes.

## RETINAL ASTROCYTIC HAMARTOMA

The astrocytic hamartoma of the retina and optic disc is a benign tumor that typically occurs in patients with tuberous sclerosis, although it can be seen in those with neurofibromatosis, retinitis pigmentosa, or as an isolated finding (see Chapter 63).<sup>1</sup> Astrocytic hamartoma can be the first clinical manifestation of tuberous sclerosis, and in its isolated form it may represent a forme fruste of tuberous sclerosis.<sup>2,3</sup>

**Pathogenesis and pathology** Undifferentiated glioneurocytes within the developing retina give rise to hamartoma due to mutations in the TSC1 and TSC2 genes, which respectively encode hamartin and tuberin.<sup>4</sup> Tuberin and hamartin are coexpressed in a wide variety of normal human tissues, including neurons and astrocytes.<sup>5</sup> Hamartin and tuberin interact with each other and influence common cellular pathways, and may play a role in cell growth regulation via the PDGF-signaling pathway.<sup>6,7</sup> Clinically, it has been noted that these lesions may show varying degrees of tumor vascularization, which is more evident angiographically than ophthalmoscopically. This observation has raised speculation that these tumors may have an angioblastic as well as an astrocytic origin, and thus the term angiogliomatous hamartoma has been used to describe such tumors.<sup>8</sup>

Gross examination of retinal astrocytic hamartomas reveals a white mass that may be calcified. Histologically, the typical non-calcified retinal astrocytic hamartoma is a lightly eosinophilic lesion consisting of elongated astrocytes with long processes and small oval nuclei. They arise from the retinal ganglion cell layer and later involve all layers.<sup>9</sup> The mitotic figures are extremely rare. The more calcified tumors show fossilization and peculiar round basophilic laminated structures resembling corpora aranacea.<sup>9</sup>

## Clinical features

**Symptoms** The patient with a retinal astrocytic hamartoma is often visually asymptomatic but can develop painless blurred vision, particularly if the tumor is located in the posterior pole. Often these tumors are detected as part of screening for tuberous sclerosis.

**Signs** Based on ophthalmoscopic appearance, three morphologic types of retinal astrocytic hamartoma are recognized: the more common subtle, flat, round, semitranslucent lesion; the large, elevated, nodular, and calcified mulberry lesion; and the mixed type of lesion possessing features of the other two, being calcified in the central portion and semitranslucent in the periphery (Fig. 59.1).<sup>10–12</sup> All three types may be seen in a given patient.

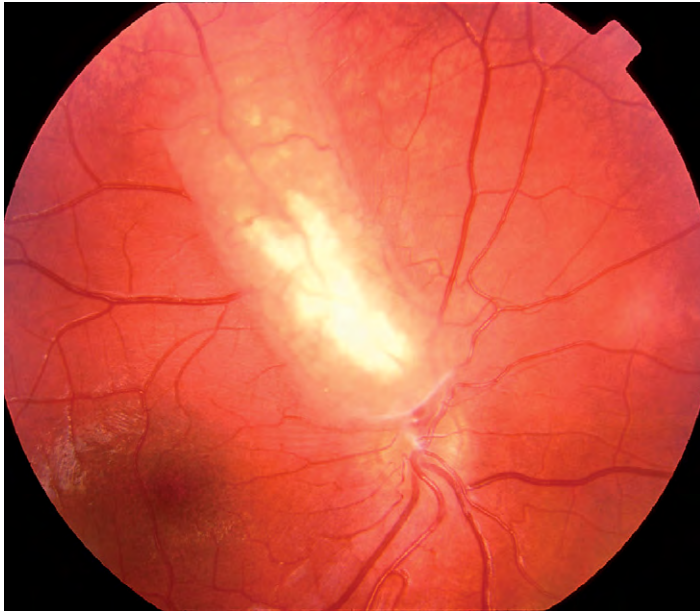
**Diagnostic evaluation** In the majority of cases the diagnosis of retinal astrocytic hamartoma can be made with indirect ophthalmoscopy and a physical evaluation looking for signs of tuberous sclerosis. However, fluorescein angiography, ultrasonography, and optical coherence tomography (OCT) can be useful ancillary studies. Fluorescein angiography of retinal astrocytic hamartoma shows a prominent superficial network of fine vessels in the arterial phase with leakage in the venous phase (Fig. 59.2A, B). Late angiograms show intense diffuse homogeneous staining of the mass.

Ultrasonography is not generally useful for small, non-calcified tumors. However, larger and calcified lesions can show characteristic features, including acoustic solidity and shadowing due to calcification within the mass on B-scan ultrasonography (Fig. 59.2C). A-scan ultrasonography shows a sharp anterior border, high internal reflectivity, and attenuation of orbital echoes posterior to the tumor.

OCT of retinal astrocytic hamartoma reveals full-thickness replacement of the retinal anatomic layers with the tumor and shadowing corresponding to the intralaminar calcification. It can be useful in ascertaining the reasons for visual loss (Box 59.1).<sup>13</sup>

**Differential diagnosis** Despite the characteristic ophthalmoscopic features listed above, certain entities can closely resemble astrocytic hamartoma. Retinoblastoma, retinocytoma, myelinated nerve fibers, massive gliosis of the retina, retinal capillary hemangioma, and optic disc drusen can be difficult to differentiate ophthalmoscopically from astrocytic hamartoma (Table 59.1).

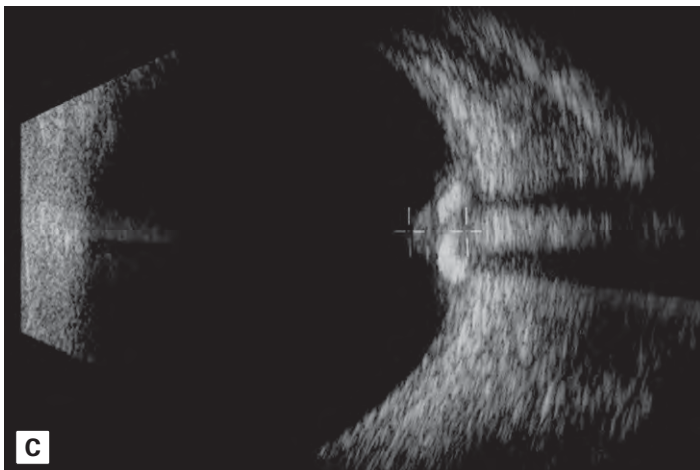
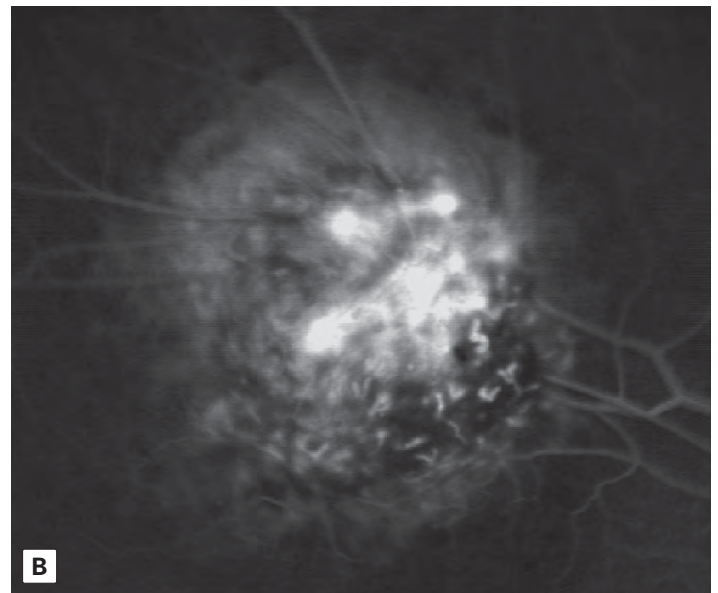
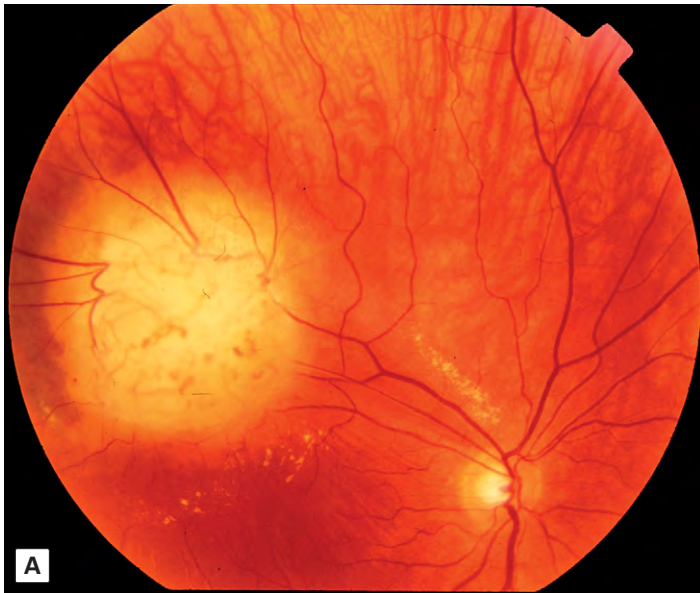Small retinoblastomas can be translucent, similar to astrocytic hamartomas, and both lack calcification when small. Calcification, when present, can demonstrate subtle differences, as it tends to be dull and chalky white in a retinoblastoma, whereas the calcification in an astrocytic hamartoma is a more glistening yellow, resembling fish eggs. In addition, dilated, tortuous retinal feeder vessels are more common with retinoblastoma. A larger retinoblastoma often



**Fig. 59.1** Fundus appearance of a typical retinal astrocytic hamartoma. Note central area of calcification and peripheral semitranslucent non-calcified region. (Reproduced with permission from Singh AD. Tuberosus sclerosis complex. In: Huang D, Kaiser PK, Lowder CY, Traboulsi ET, eds. Atlas of posterior segment imaging. Philadelphia: Mosby, 2005.)

### BOX 59.1 Retinal Astrocytic Hamartoma

- Single or multiple, circumscribed, semitranslucent round retinal lesion
- Single or multiple, large, elevated, nodular, and calcified mulberry lesion
- Absence of retinal exudation or subretinal fluid surrounding the lesion
- Absence of prominent feeder vessels extending from the optic disc
- Prominent network of fine retinal vessels on fluorescein angiography
- Lack of growth over short periods of observation (weeks to months)



**Fig. 59.2** Fundus appearance of calcified large astrocytic hamartoma. Note surrounding retinal exudation (A). Fluorescein angiogram (arteriovenous phase) reveals fine intrinsic vessels (B). B-scan ultrasonograph indicative of intrinsic calcification (C). (Reproduced with permission from Giles J, Singh AD, Rundle PA, Noe KP, Rennie IG. Retinal astrocytic hamartoma with exudation. *Eye* 2005; 19: 724–725.)

**Table 59.1 Differential diagnosis of astrocytic hamartoma**

Diagnosis	Appearance	Calcification	Feeder vessels	Exudation	RPE	Growth*	Association
Astrocytic hamartoma	Translucent or white mass	Present, yellow, spherical	Absent	Usually absent	Normal	Absent	Tuberous sclerosis
Retinoblastoma Retinocytoma	White mass	Present, white, chunky	Present	Absent	Normal Proliferation	Present	13 q deletion syndrome
			Absent	Absent		Absent	
Myelinated nerve fibers	White patch, no mass	Absent	Vessels obscured	Absent	Normal	Absent	None
Massive gliosis of retina	White mass	May be present	Absent	May be present	Atrophy and proliferation	Absent	None
Retinal capillary hemangioma	Round red mass	Absent	Prominent	Present	Normal	May be present	VHL disease
Optic disc drusen	White mass	Present	Absent	Absent	Normal	Absent	Retinitis pigmentosa

\*Short-term growth observed over weeks to months.  
RPE, retinal pigment epithelium; VHL, von Hippel–Lindau disease.

produces vitreous or subretinal seeding and exudative retinal detachment, which rarely occurs in astrocytic hamartoma. Fluorescein angiography may be helpful in making the correct diagnosis, as the feeder blood vessels are of normal caliber in astrocytic hamartoma, in contrast to retinoblastoma. In doubtful cases, close follow-up over several weeks will demonstrate stability in astrocytic hamartoma and growth in retinoblastoma.<sup>12,14</sup>

Retinocytoma, a benign counterpart of retinoblastoma, can also closely resemble astrocytic hamartoma because both lesions may be calcified. Surrounding retinal pigment epithelial alterations are a common finding in retinocytoma and are typically absent in astrocytic hamartoma, as they are situated superficially in the retina.

Myelinated nerve fibers sometimes can mimic a small astrocytic hamartoma. However, myelinated nerve fibers are usually located at or adjacent to the optic disc margin, show a more fibrillated margin, are flat without any elevation, and are not calcified.

Massive gliosis of the retina can be difficult to differentiate clinically from an astrocytic hamartoma, but a prior history of ocular inflammation or trauma and a more degenerated eye are important clues.

Some astrocytic hamartomas have prominent vascularity, which makes the differentiation from retinal capillary hemangioma difficult. However, a capillary hemangioma is usually red or pink (rather than white), has dilated tortuous retinal feeder vessels, is more likely to produce retinal exudation, and is non-calcified.

The similarity between optic disc drusen and optic disc astrocytic hamartoma can be so great that the term ‘giant drusen’ has been used to describe the calcified astrocytic hamartoma seen with tuberous sclerosis.<sup>15</sup> Although drusen of the optic disc show distinct calcification, they are usually bilateral and lie within the disc, whereas the calcified astrocytic hamartoma is characteristically unilateral, protrudes above the optic disc, and obscures the disc and retinal blood vessels.<sup>15</sup>

**Treatment** Even though the great majority of retinal astrocytic hamartomas are asymptomatic, non-progressive, and do not require

treatment, ocular examination should be performed on an annual basis for possible associated exudative retinal detachment that may extend into the fovea. In these cases, laser photocoagulation can be employed. A patient with retinal astrocytic hamartomas should also be followed for other manifestations of tuberous sclerosis.

**Association with tuberous sclerosis** The exact prevalence of retinal astrocytic hamartoma in tuberous sclerosis is not known. Approximately one-third to half of patients with tuberous sclerosis have retinal or optic nerve hamartoma, and in half of these the hamartoma occur bilaterally.<sup>11,16</sup> The association of astrocytic hamartoma with tuberous sclerosis is discussed fully in Chapter 63.

**Prognosis** Although most astrocytic hamartoma remain stable, some become calcified over time.<sup>12</sup> Additionally, new lesions may develop from previously normal-appearing retina.<sup>12</sup> There are also reports of spontaneous regression of retinal astrocytic hamartoma in patients with tuberous sclerosis.<sup>17</sup> In general, astrocytic hamartomas are silent, with an excellent visual prognosis. They are not known to undergo malignant transformation and have no tendency to metastasize. However, rarely they have been associated with degenerative necrosis, leading to vitreous seeding, vitreous or subretinal hemorrhage, and subretinal exudation or detachment.<sup>18</sup> There have even been reports of blind, painful eye due to total retinal detachment and secondary glaucoma.<sup>19</sup>

### ACQUIRED ASTROCYTOMA

‘Acquired’ retinal astrocytoma seem to develop at any age, have no family history, and are not associated with tuberous sclerosis or other systemic syndromes. The exact incidence is unknown, but a number of cases have been reported.<sup>20–24</sup> The true pathogenesis of acquired retinal astrocytoma is not known. It apparently arises from either typical retinal astrocytes or Muller cells. It may be a solitary intraocular counterpart of the astrocytoma that occurs in the brain, but in general, the acquired retinal astrocytoma does not seem to be as aggressive as the intracranial variety. For the most part, pathology, diagnostic



approach, management, and prognosis are similar to astrocytic hamartoma.<sup>20-23</sup> Acquired retinal astrocytoma begins as a white to fleshy pink intraretinal mass, usually in the posterior pole near the optic disc. It may show progressive growth, or even produce intraretinal and subretinal exudation, vitreous hemorrhage, and secondary retinal detachment.<sup>22,24</sup>

Because the diagnosis has not often been made clinically, the best management of acquired retinal astrocytoma is not well established. Many eyes have been enucleated because of suspected uveal melanoma or retinoblastoma, and this may continue to be the trend.<sup>24</sup> Radiotherapy may prove useful in rare cases where the diagnosis is established by a needle biopsy.

## REFERENCES

- DeBustros S, Miller NR, Finkelstein D et al. Bilateral astrocytic hamartomas of the optic nerve heads in retinitis pigmentosa. *Retina* 1983; 3: 21-23.
- Walsh MN, Koch FLP, Brunsting HA. Syndrome of tuberous sclerosis, retinal tumors and adenoma sebaceum: report of a case. *Mayo Clin Proc* 1938; 13: 155-160.
- Margo CE, Barletta JP, Staman JA. Giant cell astrocytoma of the retina in tuberous sclerosis. *Retina* 1993; 13: 155-159.
- Catania MG, Mischel PS, Vinters HV. Hamartin and tuberin interaction with the G2/M cyclin-dependent kinase CDK1 and its regulatory cyclins A and B. *J Neuropathol Exp Neurol* 2001; 60: 711-723.
- Johnson MW, Kerfoot C, Bushnell T et al. Hamartin and tuberin expression in human tissues. *Mod Pathol* 2001; 14: 202-210.
- van Slegtenhorst M, Nellist M, Nagelkerken B et al. Interaction between hamartin and tuberin, the TSC1 and TSC2 gene products. *Hum Mol Genet* 1998; 7: 1053-1057.
- Reneker LW, Overbeek PA. Lens-specific expression of PDGF-A in transgenic mice results in retinal astrocytic hamartomas. *Invest Ophthalmol Vis Sci* 1996; 37: 2455-2466.
- Barsky D, Wolter FR. The retinal lesion of tuberous sclerosis: An angiomatous hamartoma? *J Pediatr Ophthalmol* 1971; 8: 261-265.
- Walsh FB, Zimmerman LE. Clinicopathologic conference. *Am J Ophthalmol* 1956; 42: 737-747.
- Nyboer JH, Robertson DM, Gomez MR. Retinal lesions in tuberous sclerosis. *Arch Ophthalmol* 1976; 94: 1277-1280.
- Robertson DM. Ophthalmic manifestations of tuberous sclerosis. *Ann NY Acad Sci* 1991; 615: 17-25.
- Zimmer-Galler IE, Robertson DM. Long-term observation of retinal lesions in tuberous sclerosis. *Am J Ophthalmol* 1995; 119: 318-324.
- Shields CL, Materin MA, Shields JA. Review of optical coherence tomography for intraocular tumors. *Curr Opin Ophthalmol* 2005; 16: 141-154.
- Howard GM, Ellsworth RM. Differential diagnosis of retinoblastoma. A statistical survey of 500 children. I. Relative frequency of the lesions which simulate retinoblastoma. *Am J Ophthalmol* 1965; 60: 610-618.
- Reese AB. Relation of drusen of the optic nerve to tuberous sclerosis. *Arch Ophthalmol* 1940; 24: 187-205.
- Williams R, Taylor D. Tuberous sclerosis. *Surv Ophthalmol* 1985; 30: 143-154.
- Kiratli H, Bilgic S. Spontaneous regression of retinal astrocytic hamartoma in a patient with tuberous sclerosis. *Am J Ophthalmol* 2002; 133: 715-716.
- de Juan E Jr, Green WR, Gupta PK et al. Vitreous seeding by retinal astrocytic hamartoma in a patient with tuberous sclerosis. *Retina* 1984; 4: 100-102.
- Shields JA, Eagle RC, Shields CL et al. Aggressive retinal astrocytomas in 4 patients with tuberous sclerosis complex. *Arch Ophthalmol* 2005; 123: 856-863.
- Arnold AC, Hepler RS, Yee RW et al. Solitary retinal astrocytoma. *Surv Ophthalmol* 1985; 30: 173-181.
- Reeser FH, Aaberg TM, Van Horn DL. Astrocytic hamartoma of the retina not associated with tuberous sclerosis. *Am J Ophthalmol* 1978; 86: 688-698.
- Ramsay RC, Kinyoun JL, Hill CW et al. Retinal astrocytoma. *Am J Ophthalmol* 1979; 88: 32-36.
- Ulbricht TM, Fulling KH, Helveston EM. Astrocytic tumors of the retina. Differentiation of sporadic tumors from phakomatosis-associated tumors. *Arch Pathol Lab Med* 1984; 108: 160-163.
- Shields CL, Shields JA, Eagle RC Jr et al. Progressive enlargement of acquired retinal astrocytoma in 2 cases. *Ophthalmology* 2004; 111: 363-368.

# Tumors of the retinal pigment epithelium

Elias I. Traboulsi, Martin Heur and Arun D. Singh

## INTRODUCTION

Tumors of the retinal pigment epithelium (RPE) can be congenital or acquired. They may also be classified as reactive, hypertrophic, hamartomatous, and neoplastic (Table 60.1).<sup>1</sup> Those present at birth can be associated with systemic conditions such as familial adenomatous polyposis (FAP) or neurofibromatosis 2 (NF2). Acquired RPE tumors include benign and malignant lesions that are sometimes difficult to differentiate from choroidal neoplasms were it not for ancillary tests such as ultrasonography, optical coherence tomography, and fluorescein angiography. In this chapter we review the clinical features of congenital and acquired tumors of the RPE, and their systemic associations.

## CONGENITAL HYPERTROPHY OF THE RPE (CHRPE)

Congenital hypertrophy of the retinal pigment epithelium (CHRPE) is a round, darkly pigmented, flat lesion of the ocular fundus located at the level of the retinal pigment epithelium. In the older literature, CHRPE was classified as a benign melanoma of the retinal pigment epithelium.<sup>2</sup>

**Etiology and pathogenesis** CHRPE are isolated sporadic congenital lesions with no known underlying genetic basis.

**Pathology** Histopathologically, isolated CHRPE lesions consist of a layer of hypertrophied RPE cells containing excessive pigment granules.<sup>3</sup> The underlying choriocapillaris and choroid are normal. The photoreceptor layer overlying the abnormal RPE may be normal, or may be atrophic, causing a scotoma. The RPE cells contain granules of pigment that resemble melanin in the absence of lipofuscin, suggesting the inability of these RPE cells to perform their normal phagocytic function, leading perhaps to the associated photoreceptor degeneration.<sup>4</sup> In the areas of lacunae, RPE cells have reduced pigmentation or there may be dropout of RPE cells.<sup>3</sup> In these areas glial cells are present between Bruch's membrane and the RPE. The histopathology of CHRPE lesions has been studied in neonates, documenting the congenital nature of these lesions and their pigmentation pattern.<sup>5</sup>

## Clinical features

**Symptoms** Patients with CHRPE are generally asymptomatic unless the macula is involved.

**Signs** Ophthalmoscopically, CHRPE patches have round and sometimes scalloped edges, and are generally located in the fundus periph-

ery (Fig. 60.1). A peripapillary location is less common. The lesion is frequently surrounded by a hypopigmented halo and occasionally by a hyperpigmented ring.<sup>4</sup> Punched-out hypopigmented or depigmented lacunae may be present, and occasionally the whole CHRPE patch is depigmented and is referred to as an albinotic patch of the peripheral fundus.<sup>6</sup> The retina and retinal vessels overlying the CHRPE appear normal, except for occasional areas of focal intraretinal pigmentation. Atrophy of the outer and, sometimes, the inner retinal layers may be present, especially over larger lesions.<sup>4,7</sup> Rarely, neovascularization has been noted in association with capillary and large vessel obliteration.<sup>8</sup>

**Diagnostic evaluation** Visual field testing can map the scotoma associated with some CHRPE lesions. The scotoma is relative initially, but may become absolute if photoreceptor atrophy occurs. Electroretinographic (ERG) and electro-oculographic (EOG) studies are normal in patients with CHRPE, and in patients with familial adenomatous polyposis and multiple pigmented ocular fundus lesions (POFL).<sup>9</sup> Hypertrophied RPE cells block choroidal fluorescence on angiography and no leakage of dye is observed. The remainder of the normal-appearing fundus has a normal fluorescein angiographic pattern.

**Treatment** No treatment is necessary except for the very rare instance in which neovascularization develops at the edge of the CHRPE lesion.

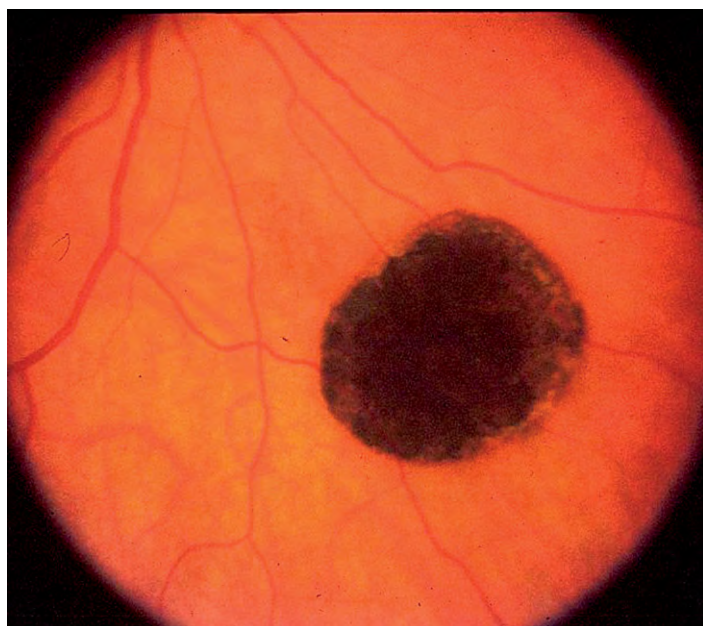**Prognosis** CHRPE is a benign lesion that does not enlarge significantly except in very rare instances.<sup>10</sup> The significance and pathogenesis of minimal growth, observed in almost 50% of cases, is unclear.<sup>11</sup> The development of nodules at the edge of CHRPE lesions, suggestive of RPE adenoma, has also been observed.<sup>12</sup>

## CONGENITAL GROUPED PIGMENTATION OF THE RPE

Multiple areas of circumscribed and flat retinal pigmentation arranged in clusters is described as congenital grouped pigmentation of the RPE.<sup>13</sup> The smaller lesions are located near the apex of the cluster closer to the posterior pole.<sup>13,14</sup> Such an appearance is suggestive of animal footprints – so-called bear tracks or animal tracks (Fig. 60.2).<sup>13,15</sup> In the majority of cases, involvement is unilateral (84%) and is limited to one sector.<sup>14</sup> In contrast to isolated patches of CHRPE, there are no depigmented lacunae or overlying photoreceptor abnormalities in grouped pigmentation of the retina.<sup>15</sup> However, in rare instances the

Table 60.1 Classification of RPE lesions				
Type	Subtype	Variants	Other terminology	Association
Reactive	Hyperplasia Metaplasia			Trauma Inflammation Toxicity
Hypertrophic	Solitary	Pigmented Non-pigmented	Retinal nevus Benign melanoma of RPE	None
	Grouped	Pigmented Non-pigmented	Bear tracks Polar bear tracks	None
	POFLs		Atypical CHRPE	Gardner syndrome Turcot syndrome
Hamartoma	RPE	Superficial Full-thickness With intrinsic vascularization	Congenital hamartoma	None
	RPE and retina		Combined hamartoma	Neurofibromatosis type 2
Neoplastic	Adenoma Adenocarcinoma			CHRPE (rare)

RPE, retinal pigment epithelium; CHRPE, congenital hypertrophy of retinal pigment epithelium; POFL, pigmented ocular fundus lesion.

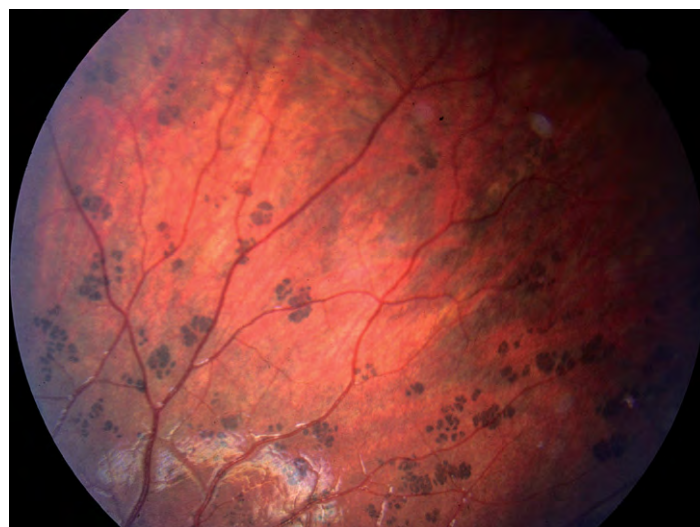


**Fig. 60.1** Solitary CHRPE. A sharply demarcated pigmented flat retinal lesion representing solitary CHRPE. The lighter area represents lacunae, which may enlarge slowly over many years.

lesions can lack pigmentation and appear albinotic (polar bear tracks).<sup>1</sup> Congenital grouped pigmentation of the RPE is not associated with FAP.<sup>13,16</sup>

**PIGMENTED OCULAR FUNDUS LESIONS**

Pigmented ocular fundus lesions (POFL) is a descriptive term that we have used to refer to fundus lesions observed in patients with FAP. It is preferred to use the term POFLs rather than CHRPE in FAP because the ‘garden’ variety of CHRPE described above is generally not associated with FAP,<sup>16</sup> there are distinct ophthalmoscopic features that distinguish CHRPE from lesions in FAP, and only some of the lesions have histopathologic characteristics compatible with CHRPE (Table 60.2).<sup>17</sup>



**Fig. 60.2** Multiple grouped pigmented lesions (grouped CHRPE) reminiscent of ‘bear tracks.’

**Etiology and pathogenesis** The presence of multiple POFLs is a highly specific (>90%) and sensitive (70–80%) marker for FAP.<sup>18</sup> Several hundred mutations have been described in the gene for FAP, designated APC (adenomatous polyposis coli), which maps to chromosome 5q21-q22.<sup>19</sup> Genotype–phenotype correlation has revealed that mutations in the first eight exons of the gene result in polyposis without POFLs, whereas mutations in exons 9–15 are associated with a POFL-positive phenotype.<sup>20,21</sup>

**Pathology** Histopathologic studies reveal diffuse RPE abnormalities in FAP, in addition to focal hyperpigmented lesions. RPE cells are hypertrophic and contain lipofuscin granules, multimembranous inclusions, and macromelanosomes.<sup>17</sup> POFLs may be divided histopathologically into four types: lesions consisting of a monolayer of hypertrophic RPE cells; lesions composed of a small mound of two to



**Table 60.2 Differentiating features of CHRPE and POFLs**

Feature	CHRPE	Grouped pigmentation	POFLs
Shape	Round	Variable	Oval
Depigmentation	Lacunae	Absent	Tail/lacunae
Size (basal diameter)	0.2–13 mm	Variable	0.15–4.5 mm
Laterality	Unilateral	Unilateral/ bilateral	Bilateral
Number	Solitary or grouped	Numerous	Four or more
Growth	Frequent but minimal	Unknown	Unknown
Malignant transformation	Rare	Never	Never
Histopathology (RPE changes)	Hypertrophy Hyperplasia	Hypertrophy	Hypertrophy Hyperplasia Hamartoma
Systemic association	None	None	Gardner syndrome, Turcot syndrome
RPE, retinal pigment epithelium; CHRPE, congenital hypertrophy of retinal pigment epithelium; POFL, pigmented ocular fundus lesion.			

three cell layers of RPE; thick lesions, seven to eight cell layers high composed of hyperplastic RPE cells; and darkly pigmented lesions that occupy the full thickness of the retina and resemble RPE adenoma (Fig. 60.3). Hence, POFLs in FAP are probably better thought of as adenomas or hamartomas of the RPE.

### Clinical features

**Symptoms** Patients with POFL are usually asymptomatic unless the macula is involved.

**Signs** POFLs are present at birth in about three-quarters of patients with polyposis. They have even been observed in a preterm infant who was examined in the neonatal intensive care unit for retinopathy of prematurity.<sup>22</sup> They do not seem to increase in size or number with age, but no such data have been published.

Ophthalmoscopy underestimates the number of lesions because clinicopathologic correlation has revealed that almost three times more lesions were present histopathologically than were counted pre-mortem (Fig. 60.3).<sup>17</sup> We recommend a three-mirror contact lens examination to document all lesions. POFLs can take one of a number of several configurations. Very small (<0.1 disc diameter, DD) round dark lesions are usually located in the peripheral fundus in the vicinity of vortex veins, whereas larger, more characteristic ovoid, tear-shaped or coffee bean-shaped lesions are located closer to the posterior pole (Fig. 60.3). Macular lesions have also been observed. Some POFLs have a hypopigmented halo and/or a posterior depigmented trail. It is often possible to note a diffuse fine stippling of RPE pigmentation in the peripheral fundus. There is a fair degree of intrafamilial consistency in the number of POFLs.

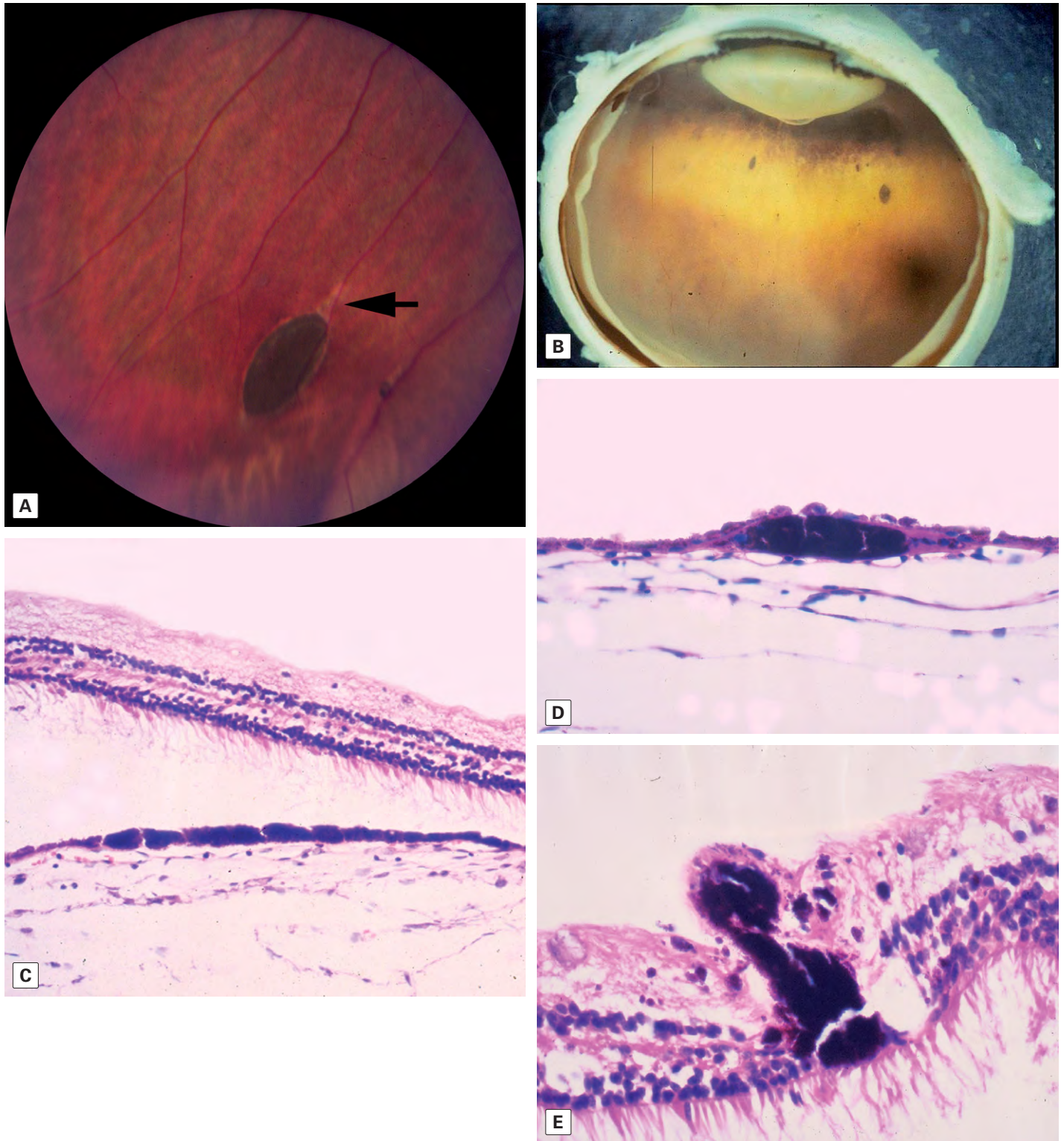
### Associations

**FAMILIAL ADENOMATOUS POLYPOSIS (GARDNER SYNDROME)** Familial adenomatous polyposis or Gardner syndrome is a rare autosomal dominant condition characterized by the development of hundreds of adenomatous colonic polyps.<sup>23</sup> Adenocarcinoma of the colon inevitably develops unless prophylactic colectomy is performed. Many patients develop extracolonic benign lesions such as sebaceous cysts, lipomas, fibromas, and osteomas. Osteomas are most commonly present in the skull and have also been reported in the orbit.<sup>24</sup> POFLs<sup>18</sup> and opaque jaw lesions<sup>25</sup> are the most common and most characteristic extracolonic manifestations of the disease. Extracolonic cancers can occur in the thyroid, adrenal glands, and liver.<sup>26</sup>

The presence of four or more POFLs is a highly sensitive (70–80%) and specific (>90%) clinical marker for FAP.<sup>18</sup> Sensitivity and specificity are increased slightly if opaque jaw lesions are present at the same time.<sup>25</sup> The presence of POFLs is especially helpful in families where several affected individuals have numerous POFLs because of the intrafamilial consistency of expression of the ocular trait. Patients at risk for the disease who have the ocular lesions develop colonic polyps.<sup>27</sup> The absence of POFLs, however, does not rule out the disease.

**TURCOT SYNDROME** Turcot syndrome is a variant of FAP in which patients develop brain tumors. Patients with Turcot syndrome may also have multiple POFLs.<sup>28</sup>

**MICROCEPHALY** CHRPE-like lesions have been described in three siblings (two boys and one girl) with autosomal recessive microcephaly and without associated systemic features of Gardner syndrome.<sup>29</sup>



**Fig. 60.3** POFLs in the right eye of a patient with Gardner syndrome (A). Two oval pigmented retinal lesions are evident. Note depigmentation along the posterior margin (arrow). Numerous peripheral small lesions are easily overlooked unless fundus examination is performed with a three-mirror contact lens (B). On histopathology POFL may appear as a hyperpigmented and hypertrophic RPE (C), many-layered thick RPE hamartoma (D), and even as nodular RPE adenoma (E). (Reproduced with permission from Traboulsi EI, Murphy SF, de la Cruz ZC et al. A clinicopathologic study of the eyes in familial adenomatous polyposis with extracolonic manifestations (Gardner's syndrome). *Am J Ophthalmol* 1990; 110: 550–561.)

**Diagnostic evaluation** Patients suspected of having FAP need detailed ocular examination to determine whether they show the ocular phenotype of the disease. If only one or two lesions are detected on ophthalmoscopy, three-mirror fundus examination may be necessary to find additional small lesions. ERG and EOG examinations are not necessary as they are normal. Patients suspected of having FAP should be evaluated by a gastroenterologist, and the appropriate medical and surgical interventions should be instituted according to current protocols. Prophylactic colectomy is frequently performed in teenagers with this disease. Mutation analysis of the gene and protein truncation assays are available commercially.

**Treatment** No treatment is necessary for POFLs. If orbital osteoma causes significant ocular problems, it may need surgical excision.

**Prognosis** The prognosis for vision is excellent. Early diagnosis of FAP results in good prognosis for life if appropriate therapeutic measures are instituted.

### SIMPLE HAMARTOMA OF THE RPE

Simple hamartomas of the RPE are very rare congenital lesions that were first described by Laqua in 1981.<sup>30</sup> The term RPE hamartoma was suggested by Gass,<sup>1</sup> who reported three architectural patterns: superficial retinal involvement, full-thickness retinal involvement and pre-retinal extension, and with intrinsic vascularization. Others have used the term congenital hamartoma of the RPE to describe these tumors.<sup>31</sup>

**Etiology and pathogenesis** These tumors are congenital, but no specific genetic etiology has been postulated or identified in any of the reported cases.

**Pathology** No clinicopathologic correlation of simple hamartoma of the RPE have been published.

#### Clinical features

**Symptoms** Patients with simple hamartoma of the RPE are generally asymptomatic unless the macula is involved, when they can have variable loss of vision.

**Signs** Simple hamartomas of the RPE appear as a discrete small (0.5–1.0 mm) black nodule and have a predilection for the macular area. They can be discovered in children, or later in life if vision is not affected. A feeding arteriole and draining venule may be apparent ophthalmoscopically, or observed on fluorescein angiography in all cases. A surrounding halo or associated retinal traction is present in the majority of patients.

**Diagnostic evaluation** The clinical features are characteristic. Ultrasonography shows a nodular echo-dense mass with high internal reflectivity. There is early non-fluorescence on early phases of the fluorescein angiogram, with some cases showing a central plaque of fluorescence and others only a ring of fluorescence at the edge of the lesions on late frames.

**Treatment** No specific therapy is indicated and none has been tried or deemed necessary, as vision is usually well preserved.

**Prognosis** There has been no documentation of growth in any of the reported cases, some of which have been observed for up to 15 years.

### ADENOMA AND ADENOCARCINOMA OF THE RPE

These are rare acquired tumors of the RPE. The differentiation between adenoma and adenocarcinoma can only be made on the basis of histopathologic findings because of similar clinical findings in both types of tumors.

**Etiology and pathogenesis** The etiology of RPE adenoma and adenocarcinoma remains elusive and no genetic factors have so far been identified.

**Pathology** Histopathologically, RPE adenoma is composed of proliferations of RPE cells. Tumors arising from the anterior portion of the RPE have vacuolated polygonal cells in a glandular or tubular configuration with vascularized connective tissue septae (Fig. 60.4). A prominent basement membrane is evident. Tumors demonstrating nuclear atypia and local invasiveness are classified as adenocarcinomas. However, RPE tumors including adenocarcinoma are not known to metastasize.

#### Clinical features

**Symptoms** Patients with adenoma may have varying visual symptoms, including vision loss, because of the macular involvement.

**Signs** Most RPE adenomas are located in the peripheral fundus, although rare juxtapapillary tumors have been reported.<sup>32</sup> In a series of 13 adult patients (age range 28–79 years) 10 were women and three were men; 10 were white and three were African-Americans.<sup>33</sup> All tumors were solitary, unilateral, and ranged from small (2 × 2 × 1 mm) to large in size (17 × 17 × 17 mm). The tumors were usually dark brown to black in color (Fig. 60.4). Prominent retinal feeder vessels were visualized in eight patients, five of whom had an exudative retinal detachment. Two patients had recurrent vitreous hemorrhage.<sup>32</sup> The presence of surrounding retinal hard exudates is an important diagnostic feature, as it is almost never associated with untreated choroidal melanoma.

**Diagnostic evaluation** Fluorescein angiography shows early hypofluorescence and late minimal hyperfluorescence of the tumor, without visibility of choroidal vessels. Ultrasonography typically demonstrates abrupt elevation of the tumor, and medium to high internal reflectivity and acoustic solidity. Despite clinical and diagnostic evaluation, it is not always possible to differentiate RPE adenoma and adenocarcinoma from choroidal melanoma (Table 60.3). In such cases, fine needle aspiration biopsy that discloses cells of pigment epithelial origin can be diagnostic.

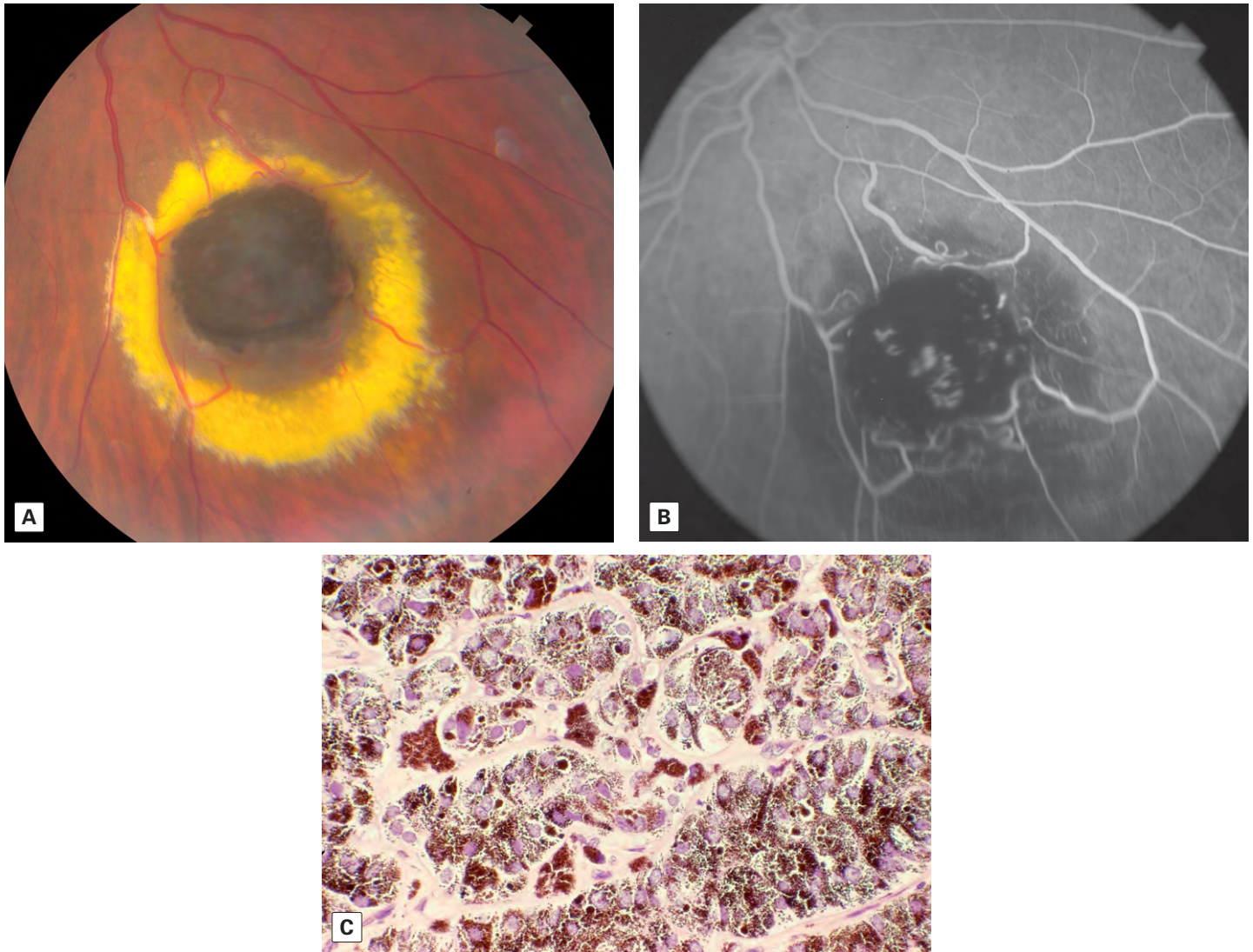
**Treatment** A variety of treatment modalities have been used depending on individual case characteristics, including observation, enucleation, local tumor resection, irradiation, and laser therapy.<sup>33</sup>

**Prognosis** The visual prognosis is variable. RPE adenoma can enlarge simulating a melanoma.<sup>32</sup>

### COMBINED HAMARTOMA OF THE RETINA AND RPE

Combined hamartoma of the retina and retinal pigment epithelium (CHR), a term first coined by Gass,<sup>34</sup> is a rare developmental disorder involving the retina and the retinal pigment epithelium.





**Fig. 60.4** RPE adenoma. A circumscribed, dark elevated nodular lesion involving the retina (A). The lesion is surrounded by a prominent rim of hard exudates. The tumor circulation is in connection with the retinal circulation (B). (Fluorescein angiogram in the venous phase.) The tumor is composed of pigment containing polygonal cells arranged in tubule-like groups with vascularized connective tissue septa and prominent basement membrane (C). (Hematoxylin & eosin,  $\times 100$ .) (Reproduced with permission from Singh AD. CHRPE and other pigmented RPE lesions. In: Huang D, Kaiser P, Lowder CY, Traboulsi EI, eds. Retinal imaging. Philadelphia: Elsevier, 2006; 519–523.)

**Etiology and pathogenesis** Hamartomas are benign proliferations of tissues that are normally present in the affected area. Although there is an association between CHR and NF2,<sup>35</sup> the mechanistic relationship between a disease with a predilection for tumors of the nerve sheath and tissues that do not contain myelinated axons remains to be elucidated. A diagnosis of CHR in infants supports the hypothesis that it is a congenital lesion, but there have also been reports of acquired cases of CHR. Ticho et al.<sup>36</sup> have reported the development of CHR in a 3-year old patient following parainfectious meningoencephalitis with optic neuritis.

**Pathology** CHR is usually composed of varying amounts of vascular, glial, and pigment epithelial components.

### Clinical features

**Symptoms** The most common presenting symptom of CHR is painless decrease in vision, usually due to direct involvement of the optic

disc, the papillomacular bundle, or the fovea.<sup>37</sup> Secondary causes of decreased vision include tractional distortion of the macula and epiretinal membrane formation.<sup>37</sup> Other presenting symptoms include strabismus, floaters, and leukocoria.<sup>37</sup>

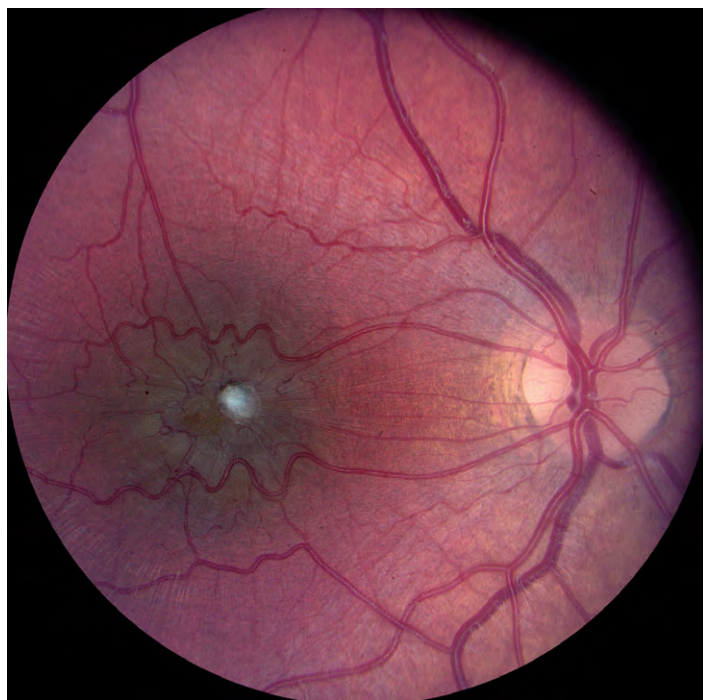**Signs** CHR is usually unilateral and can occur at the optic disc or elsewhere in the fundus (Fig. 60.5). The tumor is gray-black in color and typically has an epiretinal membrane that may cause retinal traction. The traction may be progressive, leading to a decline in vision. CHR does not undergo malignant transformation. Uncommon secondary effects include choroidal neovascularization, vitreous hemorrhage, retinoschisis, and the formation of a macular hole.<sup>38</sup>

**Association** Although most cases of CHR are isolated, there have been reports of associated systemic disorders. In his original report, Gass<sup>34</sup> noted that one of his patients had multiple café-au-lait spots, and there is another reported occurrence of CHR in NF1.<sup>39</sup> However,

**Table 60.3 Differentiating features of RPE adenoma and choroidal melanoma**

Feature		RPE adenoma/ adenocarcinoma	Choroidal melanoma
Shape		Dome	Dome or mushroom
Color		Black	Brown
Margins		Sharply demarcated	Undemarcated
Retinal feeder vessels		Present	Absent
Retinal exudation	Serous	Frequent	Frequent
	Lipid	Frequent	Almost never
Ancillary studies	Fluorescein angiography	Communication with retinal circulation	Intrinsic abnormal choroidal vasculature
	Ultrasonography	Medium to high reflectivity	Low to medium reflectivity
Behavior	Growth	Slow	Rapid
	Metastasis	Never	Frequent
Histopathology	Cells	Polygonal cells	Spindle or epithelioid cells
	Arrangement	Glandular	Fascicular or non-specific
	Basement membrane	Prominent	Absent
	Immunohistochemistry	Epithelial antigens	Melan-A HMB-45

RPE: Retinal pigment epithelium.



**Fig. 60.5** Combined hamartoma of the retina and RPE usually appears as a unilateral gray-black colored lesion with epiretinal membrane.

the most frequent association of CHR is observed with NF2.<sup>35,40</sup> Sporadic observations of CHR in several syndromes, such as branchio-oculofacial syndrome,<sup>41</sup> Gorlin's syndrome,<sup>42</sup> and ipsilateral Poland anomaly, have also been reported.<sup>43</sup>

**Diagnostic evaluation** CHR is important because it is often mistaken for malignancies such as retinoblastoma or choroidal melanoma, and there have been patients who were enucleated because of the suspicion of a malignant lesion. CHR can often be reliably diagnosed on indirect ophthalmoscopy. Ancillary studies such as fluorescein angiography are helpful in establishing the diagnosis. Angiographically, the lesion shows blockage of the choroidal fluorescence due to increased pigmentation of the retina pigment epithelium. Vascular tortuosity is prominent in the arterial phase, and progressive hyperfluorescence is evident in the late phase owing to leakage from the abnormal vessels.<sup>37</sup> Optical coherence tomography of CHR demonstrates a highly reflective lesion of the inner retina with obscuring of the underlying retinal architecture, which is useful in differentiating from a minimally elevated choroidal melanoma, which shows normal retinal architecture.<sup>44</sup> Although often isolated, patients diagnosed with CHR should undergo evaluation to exclude a systemic association, especially NF2.

**Treatment** Most CHR cause decreased vision because they involve the macula and peripapillary region and lead to retinal traction and distortion. CNV can be treated with laser or submacular surgery.

Vitreotomy and membrane peeling have been used in selected cases, with a modest visual improvement.<sup>45</sup> Peeling of the epiretinal membrane may not be possible in cases where the membrane is tightly adherent to the retina, and the role of vitrectomy and membrane peeling remains controversial in the management of vision loss in CHR.

**Prognosis** In a survey of the 60 cases examined by members of The Macula Society, 41 patients had adequate follow-up information.<sup>37</sup> Ten patients (24%) lost at least two lines of visual acuity and four (10%) had improved visual acuity following either amblyopia therapy or vitreous surgery for macular traction.<sup>37</sup>

## REFERENCES

- Gass JD. Focal congenital anomalies of the retinal pigment epithelium. *Eye* 1989; 3: 1–18.
- Jones IS, Reese AB. Benign melanomas of the retinal pigment epithelium. *Am J Ophthalmol* 1956; 42: 207–212.
- Parsons MA, Rennie IG, Rundle PA et al. Congenital hypertrophy of retinal pigment epithelium: a clinicopathological case report. *Br J Ophthalmol* 2005; 89: 920–921.
- Lloyd WC 3rd, Eagle RC Jr, Shields JA et al. Congenital hypertrophy of the retinal pigment epithelium. Electron microscopic and morphometric observations. *Ophthalmology* 1990; 97: 1052–1060.
- Champion R, Daicker BC. Congenital hypertrophy of the pigment epithelium: light microscopic and ultrastructural findings in young children. *Retina* 1989; 9: 44–48.
- Schlernitzauer DA, Green WR. Peripheral retinal albinotic spots. *Am J Ophthalmol* 1971; 72: 729–732.
- Buettner H. Congenital hypertrophy of the retinal pigment epithelium. *Am J Ophthalmol* 1975; 79: 177–189.
- Cleary PE, Gregor Z, Bird AC. Retinal vascular changes in congenital hypertrophy of the retinal pigment epithelium. *Br J Ophthalmol* 1976; 60: 499–503.
- Santos A, Morales L, Hernandez-Quintela E et al. Congenital hypertrophy of the retinal pigment epithelium associated with familial adenomatous polyposis. *Retina* 1994; 14: 6–9.
- Boldrey EE, Schwartz A. Enlargement of congenital hypertrophy of the retinal pigment epithelium. *Am J Ophthalmol* 1982; 94: 64–66.
- Shields CL, Mashayekhi A, Ho T et al. Solitary congenital hypertrophy of the retinal pigment epithelium: clinical features and frequency of enlargement in 330 patients. *Ophthalmology* 2003; 110: 1968–1976.
- Shields JA, Shields CL, Singh AD. Acquired tumors arising from congenital hypertrophy of the retinal pigment epithelium. *Arch Ophthalmol* 2000; 118: 637–641.
- Santos A, Humayun M, Traboulsi EI. Congenital abnormalities of the retinal pigment epithelium. In: Traboulsi EI, ed. *Genetic diseases of the eye*. New York: Oxford Press, 1998.
- Egerer I. Congenital grouped pigmentation of the retina. *Klin Monatsbl Augenheilkd* 1976; 168: 672–677.
- Shields JA, Tso MO. Congenital grouped pigmentation of the retina. Histopathologic description and report of a case. *Arch Ophthalmol* 1975; 93: 1153.
- Shields JA, Shields CL, Shah PG et al. Lack of association among typical congenital hypertrophy of the retinal pigment epithelium, adenomatous polyposis, and Gardner syndrome. *Ophthalmology* 1992; 99: 1709–1713.
- Traboulsi EI, Murphy SF, de la Cruz ZC et al. A clinicopathologic study of the eyes in familial adenomatous polyposis with extracolonic manifestations (Gardner's syndrome). *Am J Ophthalmol* 1990; 110: 550–561.
- Traboulsi EI, Krush AJ, Gardner EJ et al. Prevalence and importance of pigmented ocular fundus lesions in Gardner's syndrome. *N Engl J Med* 1987; 316: 661–667.
- Kinzler KW, Nilbert MC, Su LK et al. Identification of FAP locus genes from chromosome 5q21. *Science* 1991; 253: 661–665.
- Olschwang S, Turet A, Laurent-Puig P et al. Restriction of ocular fundus lesions to a specific subgroup of APC mutations in adenomatous polyposis coli patients. *Cell* 1993; 75: 959–968.
- Traboulsi EI, Apostolides J, Giardiello FM et al. Pigmented ocular fundus lesions and APC mutations in familial adenomatous polyposis. *Ophthalm Genet* 1996; 17: 167–174.
- Aiello LP, Traboulsi EI. Pigmented fundus lesions in a preterm infant with familial adenomatous polyposis. *Arch Ophthalmol* 1993; 111: 302–303.
- Gardner EJ. A genetic and clinical study of intestinal polyposis, a predisposing factor for carcinoma of the colon and rectum. *Am J Hum Genet* 1951; 3: 167–176.
- Whitson WE, Orcutt JC, Walkinshaw MD. Orbital osteoma in Gardner's syndrome. *Am J Ophthalmol* 1986; 101: 236–241.
- Giardiello FM, Offerhaus GJ, Traboulsi EI et al. Value of combined phenotypic markers in identifying inheritance of familial adenomatous polyposis. *Gut* 1991; 32: 1170–1174.
- Li FP, Thurber WA, Seddon J, Holmes GE. Hepatoblastoma in families with polyposis coli. *JAMA* 1987; 257: 2475–2477.
- Traboulsi EI, Maumenee IH, Krush AJ et al. Congenital hypertrophy of the retinal pigment epithelium predicts colorectal polyposis in Gardner's syndrome. *Arch Ophthalmol* 1990; 108: 525–526.
- Koot RW, Hulsebos TJ, van Overbeeke JJ. Polyposis coli, craniofacial exostosis and astrocytoma: the concomitant occurrence of the Gardner's and Turcot syndromes. *Surg Neurol* 1996; 45: 213–218.
- Sheriff SM, Hegab S. A syndrome of multiple fundal anomalies in siblings with microcephaly without mental retardation. *Ophthalmic Surg* 1988; 19: 353–355.
- Laqua H. Tumors and tumor-like lesions of the retinal pigment epithelium. *Ophthalmologica* 1981; 183: 34–38.
- Shields CL, Shields JA, Marr BP et al. Congenital simple hamartoma of the retinal pigment epithelium: a study of five cases. *Ophthalmology* 2003; 110: 1005–1011.
- Shields JA, Melki T, Shields CL et al. Epipapillary adenoma of retinal pigment epithelium. *Retina* 2001; 21: 76–78.
- Shields JA, Shields CL, Gunduz K, Eagle RC Jr. Neoplasms of the retinal pigment epithelium: the 1998 Albert Ruedemann Sr, Memorial Lecture, Part 2. *Arch Ophthalmol* 1999; 117: 601–608.
- Gass JD. An unusual hamartoma of the pigment epithelium and retina simulating choroidal melanoma and retinoblastoma. *Trans Am Ophthalmol Soc* 1973; 71: 171–183; discussions 184–175.
- Cotlier E. Café-au-lait spots of the fundus in neurofibromatosis. *Arch Ophthalmol* 1977; 95: 1990–1992.
- Ticho BH, Egel RT, Jampol LM. Acquired combined hamartoma of the retina and pigment epithelium following parainfectious meningoencephalitis with optic neuritis. *J Pediatr Ophthalmol Strabismus* 1998; 35: 116–118.
- Schachat AP, Shields JA, Fine SL et al. Combined hamartomas of the retina and retinal pigment epithelium. *Ophthalmology* 1984; 91: 1609–1615.
- Schachat AP, Glaser BM. Retinal hamartoma, acquired retinoschisis, and retinal hole. *Am J Ophthalmol* 1985; 99: 604–605.
- Tsai P, O'Brien JM. Combined hamartoma of the retina and retinal pigment epithelium as the presenting sign of neurofibromatosis-1. *Ophthalm Surg Lasers* 2000; 31: 145–147.
- Landau K, Dossetor FM, Hoyt WF, Muci-Mendoza R. Retinal hamartoma in neurofibromatosis 2. *Arch Ophthalmol* 1990; 108: 328–329.
- Demirci H, Shields CL, Shields JA. New ophthalmic manifestations of branchio-oculo-facial syndrome. *Am J Ophthalmol* 2005; 139: 362–364.
- De Potter P, Stanescu D, Caspers-Velu L, Hofmans A. Photo essay: combined hamartoma of the retina and retinal pigment epithelium in Gorlin syndrome. *Arch Ophthalmol* 2000; 118: 1004–1005.
- Stupp T, Pavlidis M, Bochner T, Thanos S. Poland anomaly associated with ipsilateral combined hamartoma of retina and retinal pigment epithelium. *Eye* 2004; 18: 550–552.
- Ting TD, McCuen BW 2nd, Fekrat S. Combined hamartoma of the retina and retinal pigment epithelium: optical coherence tomography. *Retina* 2002; 22: 98–101.
- Stallman JB. Visual improvement after pars plana vitrectomy and membrane peeling for vitreoretinal traction associated with combined hamartoma of the retina and retinal pigment epithelium. *Retina* 2002; 22: 101–104.



# Tumors of the ciliary pigment epithelium

Javier Elizalde, María de la Paz and Rafael I. Barraquer

## INTRODUCTION

Tumors arising from the ciliary epithelium are quite uncommon. The extremely low prevalence of these tumors often causes them to be mistaken for other, more common, iridociliary tumors such as melanoma or metastases. The location of these rare lesions growing behind the iris, the complexity in differentiating between benign and malignant tumors, their histologically remarkable cellular polymorphism, and the possibility of dealing with either a congenital or an acquired tumor, makes their diagnosis difficult.<sup>1</sup>

## ANATOMY

Histologically, the pars plana and the pars plicata of the ciliary body have two layers of overlying epithelial cells. The outer layer is the pigmented epithelium; it is continuous anteriorly with the sphincter and dilator muscles of the iris and posteriorly with the retinal pigment epithelium. The inner layer, adjacent to the vitreous cavity, is the non-pigmented epithelium. It is a cuboidal or low-columnar layer that lines the surface of the ciliary crests and extends posteriorly, becoming continuous with the sensory retina. The non-pigmented epithelium is responsible for the production of aqueous humor, and possibly of hyaluronic acid found within the vitreous gel.

## CLASSIFICATION

Based on Zimmerman's<sup>1</sup> histological classification, ciliary epithelium tumors may be grouped as congenital and acquired (Table 61.1).

## CONGENITAL TUMORS OF CILIARY EPITHELIUM

Congenital tumors of the ciliary epithelium arise from the primitive medullary epithelium, before its differentiation into its various adult derivatives. Thus, they tend to become clinically apparent in young children and have an embryonic appearance histologically.

**Glioneuroma** is perhaps the rarest tumor in the group, with only a few cases reported in the literature.<sup>2-5</sup> It is considered to be a choristomatous malformation developed from the anterior margin of the primitive optic cup<sup>8</sup> without an evident neoplastic potential.

**Clinical features** Glioneuroma appears as a slowly enlarging white or fleshy unilateral mass in the inferior aspect of the anterior chamber angle, often with involvement of the corneoscleral limbus. The tumor may be adherent to the corneal endothelium, displace the pupil, the lens, or induce a cataract.<sup>2,4,5</sup> Sometimes an associated ciliary body colobomatous defect may be present. The intraocular pressure may

also be elevated.<sup>2,5</sup> Glioneuroma is usually recognized at birth or shortly thereafter, although it has been diagnosed in a 21-year-old woman.<sup>2</sup>

**Pathology** Glioneuroma infiltrates the stroma of the iris and ciliary body, and may invade the choroid, the peripheral retina, and even extend into the extrascleral space.<sup>2,4,5</sup> Light microscopy reveals a well-differentiated neural tissue similar to brain, with eosinophilic fibrillary material, axonal processes, and glial cells within the matrix of the tumor.<sup>4</sup>

**Management** Because intraocular glioneuromas are rare, there is no clearly established treatment. Most recorded cases have been managed by enucleation of the involved eye. Occasionally glioneuromas have been removed by iridocyclectomy.<sup>2</sup> It also seems reasonable that the diagnosis could be established by a local biopsy in selected cases.

**Medulloepithelioma** Intraocular medulloepithelioma is a non-hereditary embryonal neoplasm that most often occurs in the ciliary body. Accordingly, it contains pure neuroepithelial structures (non-teratoid medulloepithelioma or diktioma), or more commonly, derivatives of the medullary epithelium, particularly cartilage, skeletal muscle, and brain tissue (teratoid medulloepithelioma or teratoneuroma).<sup>6,7</sup>

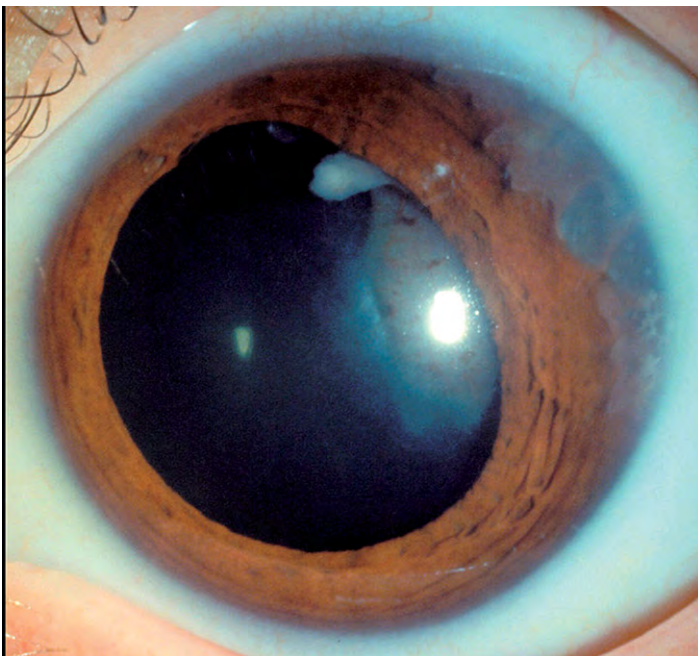
**Clinical features** Medulloepithelioma is typically a disease of childhood that becomes clinically apparent during the first decade of life, although some cases are asymptomatic for quite some time and manifest later on during adulthood.<sup>8</sup> The most relevant clinical signs and symptoms of medulloepithelioma are poor vision, pain, leukocoria, and the presence of an intraocular mass appearing behind the pupillary area (Box 61.1). The tumor is an irregular, variably sized white or gray translucent mass arising from the ciliary region (Fig. 61.1). It is frequently vascularized and comes in contact with the iris, and very seldom appears pigmented. One well known clinical feature that suggests the diagnosis of medulloepithelioma is the presence of cysts within the tumor.<sup>6,7,9</sup> Large cysts may break off from the tumor and float freely in the anterior chamber or into the vitreous cavity (Fig. 61.2). Iris neovascularization is a common and early finding in eyes with medulloepithelioma.<sup>7</sup> Children with neovascularization of the iris of unknown cause should be evaluated to exclude underlying medulloepithelioma.<sup>10</sup>

**Table 61.1 Classification of ciliary epithelium tumors**

Congenital	Gliomeuroma		
	Medulloepithelioma	Teratoid	Benign Malignant
		Non-teratoid	Benign Malignant
Acquired	Pseudoadenomatous hyperplasia	Reactive	
		Age-related (Fuchs' or coronal adenoma)	
	Adenoma Adenocarcinoma		

**BOX 61.1 Features of Medulloepithelioma**

- Manifests during the first decade of life
- Should be considered in the differential diagnosis of leukocoria
- White or gray translucent mass arising from the ciliary body
- Presence of cysts within the tumor, anterior chamber or vitreous cavity
- Iris neovascularization, lens coloboma, sectoral or total cataract
- Other findings include a cyclitic neoplastic membrane, uveitis, hyphema, retinal detachment, and vitreous hemorrhage



**Fig. 61.1** Medulloepithelioma of the ciliary body. Note translucent mass behind the iris and invading the anterior chamber through the iris root.

The presence of a sectoral or total cataract with or without subluxation is quite common. One of the earliest clinical manifestations may be a peculiar notch in the lens, producing a 'lens coloboma' in the quadrant of the tumor.<sup>6-11</sup> Other findings include a cyclitic neoplastic membrane, uveitis, hyphema, retinal detachment, vitreous hemorrhage, invasion of the optic nerve, and extraocular extension of the tumor.<sup>7</sup>

**Pathology** According to Zimmerman's classification, medulloepithelioma may be divided into non-teratoid and teratoid types, and either may have benign or malignant cytologic features.<sup>1,6,12</sup> The non-teratoid medulloepithelioma contains multilayered sheets of cords of poorly differentiated neuroepithelial cells that are histologically similar to the embryonic retina and ciliary epithelium. In contrast, the teratoid type demonstrates variable degrees of heteroplasia (hyaline cartilage, rhabdomyoblasts, undifferentiated mesenchymal cells resembling embryonal sarcoma, neuroglial tissue resembling brain, and ependymal structures).<sup>6-9</sup>

As most intraocular medulloepitheliomas do not demonstrate distant metastasis but do show variable degrees of local invasiveness, it may be difficult to classify them as benign or malignant. The histopathologic criteria of malignancy as defined by Broughton and Zimmerman are: areas composed of poorly differentiated neuroblastic cells, greater pleomorphic or mitotic activity, sarcomatous areas resembling a chondrosarcoma, rhabdomyosarcoma, or embryonal sarcoma, and invasion of the uvea, cornea, or sclera with or without extraocular invasion.<sup>6</sup>

**Management** Because most of these tumors are cytologically malignant, infiltrate the adjacent vitreous, and proliferate in delicate sheets which may not be evident intraoperatively, enucleation of the affected eye is usually advisable. In carefully selected small tumors (<3 clock hours), local removal by iridocyclectomy may be considered as an initial management option, although local recurrence is usual. Brachytherapy might be a good option in circumscribed tumors, with the stipulation of possible retreatment in case of recurrence.<sup>13,14</sup>

## ACQUIRED TUMORS OF THE CILIARY EPITHELIUM

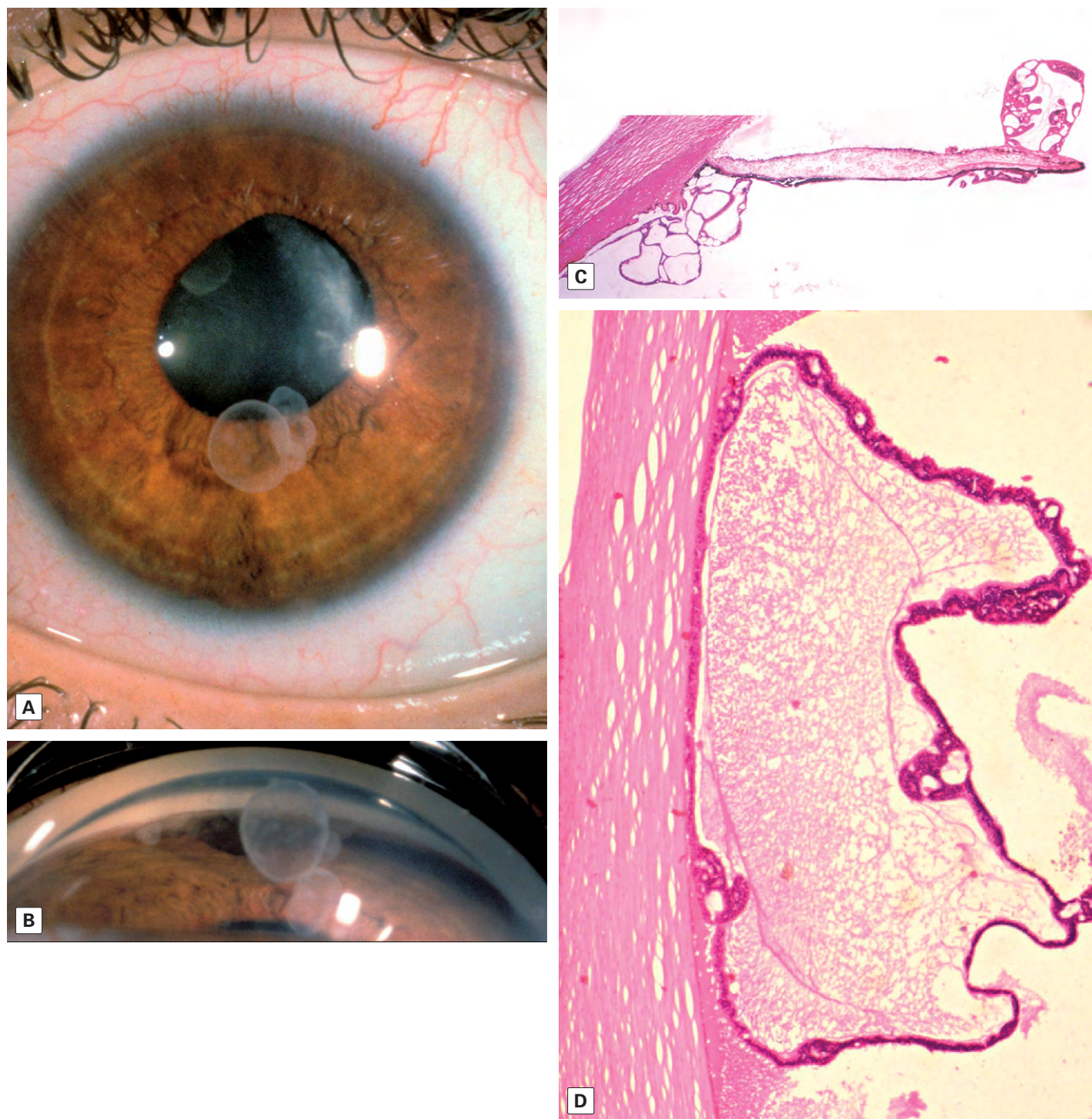
In contrast to the congenital tumors that arise from undifferentiated medullary epithelium, acquired tumors arise from fully differentiated ciliary epithelium and usually occur in older patients. They may take the form of reactive proliferations (pseudoadenomatous hyperplasia) or neoplastic proliferations (adenoma or adenocarcinoma).

### Pseudoadenomatous hyperplasia (reactive proliferation)

**Age-related hyperplasia (Fuchs' or coronal adenoma)** is an acquired lesion that seems to be age related, with increasing frequency in older patients and with little clinical significance.<sup>15</sup> It is commonly observed as an opaque white mass, usually confined to a ciliary process in eyes removed surgically or post mortem. Histologically, it is composed of irregular cords of cells of the non-pigmented ciliary epithelium. In rare instances, the tumor can erode into the anterior chamber, simulating an iris tumor.<sup>15,16</sup>

**Reactive hyperplasia** The non-pigmented ciliary epithelium contributes to the development of a cyclitic membrane, composed of a proliferation of benign cells from the non-pigmented ciliary





**Fig. 61.2** Anterior chamber cysts secondary to medulloepithelioma of the ciliary body (A). Multiple cysts within the anterior chamber and emerging through the pupil (gonioscopic photographs) (B). Histopathologic composite photograph showing a cyst adherent to the anterior border layer of the iris, another one behind the iris, and some cysts near the ciliary body (Hematoxylin & eosin  $\times 35$ .) (C). Photomicrograph showing an irregular cyst on the posterior surface of the corneal endothelium (Hematoxylin & eosin  $\times 75$ .) (D).

epithelium, connective tissue, and blood vessels. Clinically it is characterized by a dense retroretinal fibrovascular tissue that usually extends from the pars plicata on one side to the pars plicata on the other. It does not usually take the form of a distinct tumor, but rather occurs as a thickened sheet or membrane.<sup>17</sup> Reactive hyperplasia of the ciliary epithelium is usually seen in histopathologic specimens of traumatized or disorganized eyes, and may adopt a pseudotumor appearance.<sup>17</sup>

#### Adenoma and adenocarcinoma of the ciliary epithelium

True acquired neoplasms of the pigmented or non-pigmented ciliary epithelium are relatively rare. They may be benign (adenoma) or malignant (adenocarcinoma), and clinical differentiation between the two may often be impossible. Similar tumors arise from the pigment epithelium in the region of the iris<sup>18</sup> and from the retinal pigment epithelium.<sup>19</sup>



**Clinical features** Both adenoma and adenocarcinoma appear as a solid ciliary body mass presenting variable characteristics and simulating ciliary body melanoma. Tumors arising from the pigmented ciliary epithelium are usually deeply pigmented,<sup>20,21</sup> and those arising from the non-pigmented ciliary epithelium are amelanotic.<sup>22</sup> The clinical course is either asymptomatic or involves a painless visual loss. Adenoma and adenocarcinoma of the ciliary body have an irregular and sometimes multilobulated surface (Fig. 61.3).<sup>20–22</sup> The uveal melanoma tends to be more pigmented, with a smooth surface presenting as a mushroom-like growth pattern. Some cases may present with cellularity in the anterior chamber and with sentinel vessel in the overlying episclera, though this finding is more characteristic and evident in the case of uveal melanoma. Pigment dispersion in the vitreous is also seen more often with adenoma than with melanoma.<sup>23</sup> Adenoma of the non-pigmented ciliary epithelium may be associated with iris or disc neovascularization due to excessive production of vascular endothelial factor.<sup>24</sup> It is not uncommon to observe dyscoria and secondary cataract formation induced by tumor compression, and even secondary lens subluxation may occur. Unlike amelanotic melanoma, the appearance of lacunar tissue defects in the intrinsic structure of adenomas of the non-pigmented ciliary epithelium is quite characteristic, owing to the presence of cystic spaces that facilitate transillumination during exploration. Although there are no large series on record, most acquired tumors arising from the ciliary epithelium appear to have a relatively benign course. They may grow slowly and destroy the ocular structures, but they almost never metastasize or cause death. Relative differentiating features of adenoma and melanoma of the ciliary body are summarized in Table 61.2.

**Pathology** These tumors are composed of pigmented or non-pigmented cuboidal or columnar cells, usually arranged in cords or tubules (Fig. 61.3). The adenocarcinomas may be more invasive and show malignant features with cellular pleomorphism and loss of alveolar pattern.<sup>25–27</sup> Positivity of the tumor cells to vimentin confirms the non-pigmented ciliary epithelial origin.<sup>28</sup> In some cases immunopositivity with antibodies targeted to different cytokeratins may be also observed, though this pattern tends to be highly variable. Immunoreactivity to HMB-45, which is typical of melanoma, proves negative in these cases.<sup>28</sup>

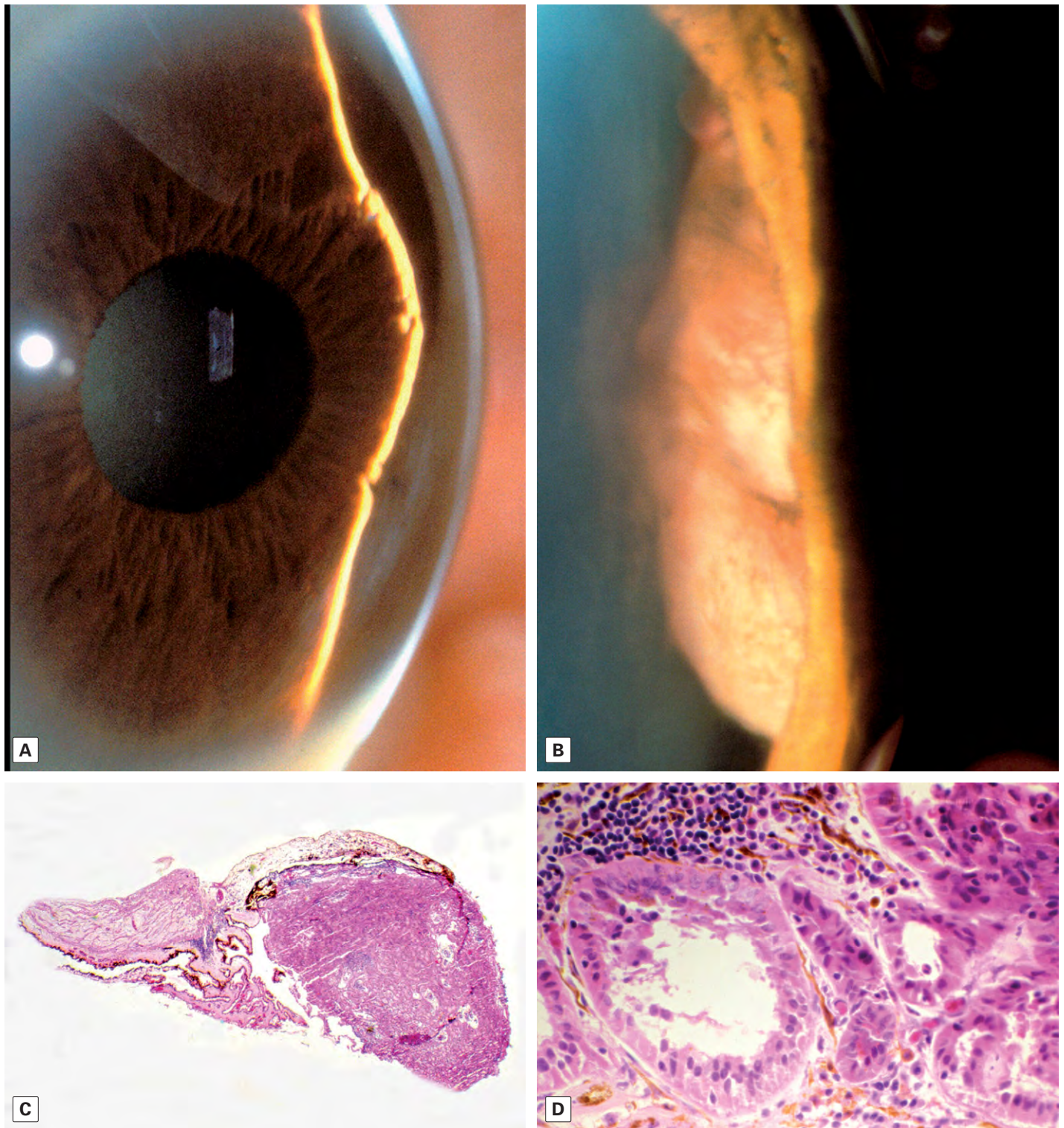
**Management** If the lesion is small, asymptomatic, and non-enlarging, simple periodic observation is the treatment of choice. As adenoma of the non-pigmented ciliary epithelium is a slow-growing tumor with benign cytological characteristics and usually presents with good vision, management with local resection via iridocyclectomy may be advised. This procedure also serves to confirm the histologic diagnosis. In the event of lens opacification the procedure may be combined with small-incision cataract surgery. If the clinical course shows evidence of growth, or if a biopsy specimen indicates malignancy, local excision or enucleation should be considered.<sup>25,26</sup>

## SUMMARY

Tumors arising from the ciliary epithelium are quite uncommon. Medulloepithelioma is typically a disease of childhood that becomes clinically apparent during the first decade of life. Medulloepithelioma should be considered in the differential diagnosis of leukocoria, especially if there is a gray translucent mass arising from the ciliary region with cysts, iris neovascularization, lens coloboma, or cataract.

**Table 61.2 Differentiating features of adenoma (adenocarcinoma) and melanoma of the ciliary body**

	Feature	Adenoma	Melanoma
Clinical	Shape	Irregular, multilobulated	Smooth dome, mushroom
	Color	Melanotic or amelanotic	Melanotic or amelanotic
	Sentinel vessels	Frequent	Infrequent
	Anterior chamber inflammation	Frequent	Infrequent
	Pigment dispersion in vitreous	Frequent	Infrequent
	Cyst/cavities	Frequent	Infrequent
	Growth	Slow	Rapid
Histopathological	Origin	Epithelial	Stromal
	Composition	Cuboidal or columnar cells	Spindle or epithelioid cells
	Pattern	Arranged in cords or tubules	Non specific
	Vimentin	Positive	Negative
Behavior	HMB 45	Negative	Positive
	Neoplasia	Usually benign, may be malignant	Always malignant
	Metastasis	Never	Frequent



**Fig. 61.3** Adenoma of the non-pigmented ciliary epithelium. Slit lamp photograph demonstrating an anterior displacement of the iris (**A**). A predominantly amelanotic nodular mass is located behind the iris (**B**). Histopathologic macroscopic photograph discloses a tumor of the non-pigmented epithelium extending from the anterior aspect of the ciliary processes and to the posterior surface of the iris, and also a tumor located in the ciliary body and the root of the iris. (Hematoxylin & eosin  $\times 35$ .) (**C**). Microscopic structure of the tumor composed of cuboidal and columnar cells with abundant eosinophilic cytoplasm and hyperchromatic nuclei. The tumor cells are arranged in tubular, papillary, and solid patterns. (Hematoxylin & eosin  $\times 75$ .) (**D**).

Acquired neoplasms of the pigmented or non-pigmented ciliary epithelium may be benign (adenoma) or malignant (adenocarcinoma), and clinical differentiation between the two may often be impossible. Both adenoma and adenocarcinoma appear as a solid

ciliary body mass simulating a ciliary body melanoma. These tumors may grow slowly and destroy the ocular structures, but they almost never metastasize or cause death. If clinically suspected, these tumors are best managed by local resection via iridocyclectomy.

## REFERENCES

- Zimmerman LE. The remarkable polymorphism of tumours of the ciliary epithelium. *Trans Aust Coll Ophthalmol* 1970; 2: 114–125.
- Addison DJ, Font RL. Gliomeuroma of iris and ciliary body. *Arch Ophthalmol* 1984; 102: 419–421.
- Kivela T, Kauniskangas L, Miettinen P, Tarkkanen A. Gliomeuroma associated with colobomatous dysplasia of the anterior uvea and retina. A case simulating medulloepithelioma. *Ophthalmology* 1989; 96: 1799–1808.
- Manz HJ, Rosen DA, Macklin RD, Willis WE. Neuroectodermal tumor of anterior lip of the optic cup. Gliomeuroma transitional to teratoid medulloepithelioma. *Arch Ophthalmol* 1973; 89: 382–386.
- Spencer WH, Jesberg DO. Gliomeuroma (choristomatous malformation of the optic cup margin). A report of two cases. *Arch Ophthalmol* 1973; 89: 387–391.
- Broughton WL, Zimmerman LE. A clinicopathologic study of 56 cases of intraocular medulloepitheliomas. *Am J Ophthalmol* 1978; 85: 407–418.
- Shields JA, Eagle RC Jr, Shields CL, Potter PD. Congenital neoplasms of the nonpigmented ciliary epithelium (medulloepithelioma). *Ophthalmology* 1996; 103: 1998–2006.
- Carrillo R, Streeten BW. Malignant teratoid medulloepithelioma in an adult. *Arch Ophthalmol* 1979; 97: 695–699.
- Green WR. Neuroepithelial tumors of the ciliary body. In: Spencer WH, ed. *Ophthalmic pathology: an atlas and textbook*. Philadelphia: WB Saunders, 1985.
- Singh A, Singh AD, Shields CL, Shields JA. Iris neovascularization in children as a manifestation of underlying medulloepithelioma. *J Pediatr Ophthalmol Strabismus* 2001; 38: 224–228.
- Brownstein S, Barsoum-Homsy M, Conway VH, et al. Non-teratoid medulloepithelioma of the ciliary body. *Ophthalmology* 1984; 91: 1118–1122.
- Zimmerman LE. Verhoeff's 'terato-neuroma.' A critical reappraisal in light of new observations and current concepts of embryonic tumors. The Fourth Frederick H. Verhoeff Lecture. *Am J Ophthalmol* 1971; 72: 1039–1057.
- Balmer A, Munier F, Uffer S et al. Medullo-epithelioma: presentation of 3 cases. *Klin Monatsbl Augenheilkd* 1996; 208: 377–380.
- Lumbroso L, Desjardins L, Coue O et al. Presumed bilateral medulloepithelioma. *Arch Ophthalmol* 2001; 119: 449–450.
- Bateman JB, Foos RY. Coronal adenomas. *Arch Ophthalmol* 1979; 97: 2379–2384.
- Zaidman GW, Johnson BL, Salamon SM, Mondino BJ. Fuchs' adenoma affecting the peripheral iris. *Arch Ophthalmol* 1983; 101: 771–773.
- Zografos L. Tumeurs et pseudotumeurs de l'épithelium pigmenté et non pigmenté. In: Zografos L, ed. *Tumeurs intraoculaires*. Paris: Société Française d'Ophtalmologie et Masson, 2002.
- Singh AD, Rundle PA, Longstaff S et al. Iris pigment epithelial adenoma: resection and repair. *Eye* 2005.
- Shields JA, Melki T, Shields CL et al. Epipapillary adenoma of retinal pigment epithelium. *Retina* 2001; 21: 76–78.
- Rennie IG, Faulkner MK, Parsons MA. Adenoma of the pigmented ciliary epithelium. *Br J Ophthalmol* 1994; 78: 484–485.
- Shields JA, Shields CL, Gunduz K, Eagle RC Jr. Adenoma of the ciliary body pigment epithelium: the 1998 Albert Ruedemann Sr Memorial Lecture, Part 1. *Arch Ophthalmol* 1999; 117: 592–597.
- Shields JA, Eagle RC Jr, Shields CL. Adenoma of nonpigmented ciliary epithelium with smooth muscle differentiation. *Arch Ophthalmol* 1999; 117: 117–119.
- Dinakaran S, Rundle PA, Parsons MA, Rennie IG. Adenoma of ciliary pigment epithelium: a case series. *Br J Ophthalmol* 2003; 87: 504–505.
- Suzuki J, Goto H, Usui M. Adenoma arising from nonpigmented ciliary epithelium concomitant with neovascularization of the optic disk and cystoid macular edema. *Am J Ophthalmol* 2005; 139: 188–190.
- Dryja TP, Albert DM, Horns D. Adenocarcinoma arising from the epithelium of the ciliary body. *Ophthalmology* 1981; 88: 1290–1292.
- Grossniklaus HE, Zimmerman LE, Kachmer ML. Pleomorphic adenocarcinoma of the ciliary body. Immunohistochemical and electron microscopic features. *Ophthalmology* 1990; 97: 763–768.
- Shields JA, Eagle RC Jr, Shields CL, De Potter P. Acquired neoplasms of the nonpigmented ciliary epithelium (adenoma and adenocarcinoma). *Ophthalmology* 1996; 103: 2007–2016.
- Loeffler KU, Seifert P, Spitznas M. Adenoma of the pigmented ciliary epithelium: ultrastructural and immunohistochemical findings. *Hum Pathol* 2000; 31: 882–887.



# Lymphoma of the retina and CNS

Arun D. Singh, Hilel Lewis, Andrew P. Schachat and David Peereboom

## INTRODUCTION

Primary lymphoma of the central nervous system (CNS) is now considered to be a variant of extranodal non-Hodgkin's lymphoma (NHL) that arises from specific sites such as the brain, spinal cord, meninges, or eyes, and is called primary CNS lymphoma (PCNSL).<sup>1</sup> Primary intraocular lymphoma (PCNSL-O) is a variant of PCNSL with predominantly ophthalmic involvement. Ophthalmic involvement with other forms of lymphoma is usually orbital, conjunctival or uveal, in contrast to vitreoretinal involvement in PCNSL-O.

## PATHOGENESIS

As CNS and the eyes lack lymphatics and lymph nodes, it is suspected that PCNSL arises from lymphocytes that normally traffic through the CNS, or from an abnormal clone of lymphocytes that home into the CNS.<sup>2</sup>

Congenital immunodeficiency and iatrogenic or acquired immunosuppression (AIDS) are risk factors for PCNSL.<sup>3</sup> Epstein–Barr virus infection of B lymphocytes in the absence of T-suppressor function (due to immunosuppression) leads to an uncontrolled lymphocytic proliferation. Rare cases of PCNSL may be secondary to human T-cell lymphotropic virus type 1 infection.<sup>4</sup> The vast majority of PCNSL are diffuse large B-cell lymphomas.<sup>1,5</sup> In contrast, PCNSL arising in T cells are composed of small lymphocytes.<sup>6</sup>

## CLINICAL FEATURES

Overall, PCNSL represents about 1–2% of all cases of lymphoma and only 5% of all primary CNS tumors.<sup>7</sup> The age-adjusted incidence of PCNSL is about 4.8 per million population.<sup>7</sup> There has been a threefold increase in the incidence of PCNSL in the United States over the last 25 years, which is partly explained on the basis of the rising incidence of AIDS.<sup>7</sup> The incidence of PCNSL-O is not known.

PCNSL is typically a disease of the elderly, with a mean age of about 60 years.<sup>8,9</sup> Intraocular involvement may precede, occur simultaneously, or follow the CNS disease. In general, intraocular involvement is the presenting feature in PCNSL-O and subsequent CNS involvement occurs in 56–85% of patients over a period of months to years.<sup>8,10,11</sup> Conversely, about 20% of patients with PCNSL have concurrent intraocular involvement.

## Symptoms

**Ophthalmic** The most frequent symptoms are of painless blurred vision, floaters, or both. Bilateral involvement occurs in up to 80% of cases.<sup>11</sup> Some patients are asymptomatic and are diagnosed only when

examined for suspected CNS involvement.<sup>11</sup> Owing to the non-specific nature of the ophthalmic manifestations, a diagnosis of PCNSL-O is difficult to make on clinical grounds alone, and a delay in diagnosis is common. A delay of up to 2 years between the initial presentation and histopathologic confirmation of PCNSL-O has been reported.<sup>10,12</sup>

**Central nervous system** The brain, spinal cord, and meninges, either separately or in various combinations, can be involved. Solitary involvement of the spinal cord is rarely seen. Personality changes are a common presenting feature because the frontal lobe is the most frequently involved region of the brain. Seizures are an uncommon feature.

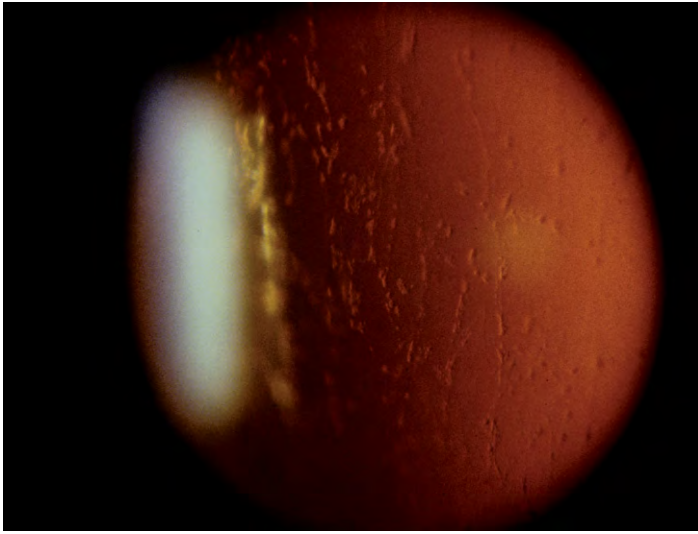
## Signs

**Ophthalmic** The anterior segment findings of keratic precipitates, aqueous cells, and aqueous flare are suggestive of inflammation and can be misleading.<sup>12</sup> The most common manifestations are of a posterior uveitis or vitritis (50%), combined anterior and posterior uveitis (22%), and chorioretinitis, or subretinal pigment epithelial infiltrates (18%).<sup>10</sup> The presence of clumps of cells in the vitreous is a common finding (Fig. 62.1). Multifocal or diffuse chorioretinal infiltrates may be seen with or without vitreous cells (Fig. 62.2A). Multifocal subretinal pigment epithelial infiltrates are considered to be pathognomonic (Box 62.1).<sup>13</sup> Rare findings include peripapillary choroidal mass, perivasculitis, retinal artery occlusion, and exudative retinal detachment.

**Central nervous system** Unlike PCNSL-O, PCNSL is a rapidly growing tumor and the diagnosis is frequently made within a few months of the onset of symptoms. The lesions in the CNS tend to be periventricular in location, thus allowing access to cerebrospinal fluid (CSF) and meninges. An associated meningeal involvement is present in approximately 40% of cases. Brain lesions can be multifocal, particularly in immunosuppressed individuals.

## DIAGNOSTIC EVALUATION

The relationship between intraocular involvement and CNS involvement is variable, with intraocular involvement preceding, occurring simultaneously with, or following the CNS manifestations. It is therefore imperative that all cases of PCNSL-O should be thoroughly evaluated to exclude CNS involvement at the initial diagnosis, and periodically thereafter. Conversely, periodic ophthalmic examinations should be part of the diagnostic evaluation and subsequent management of a patient diagnosed with PCNSL.



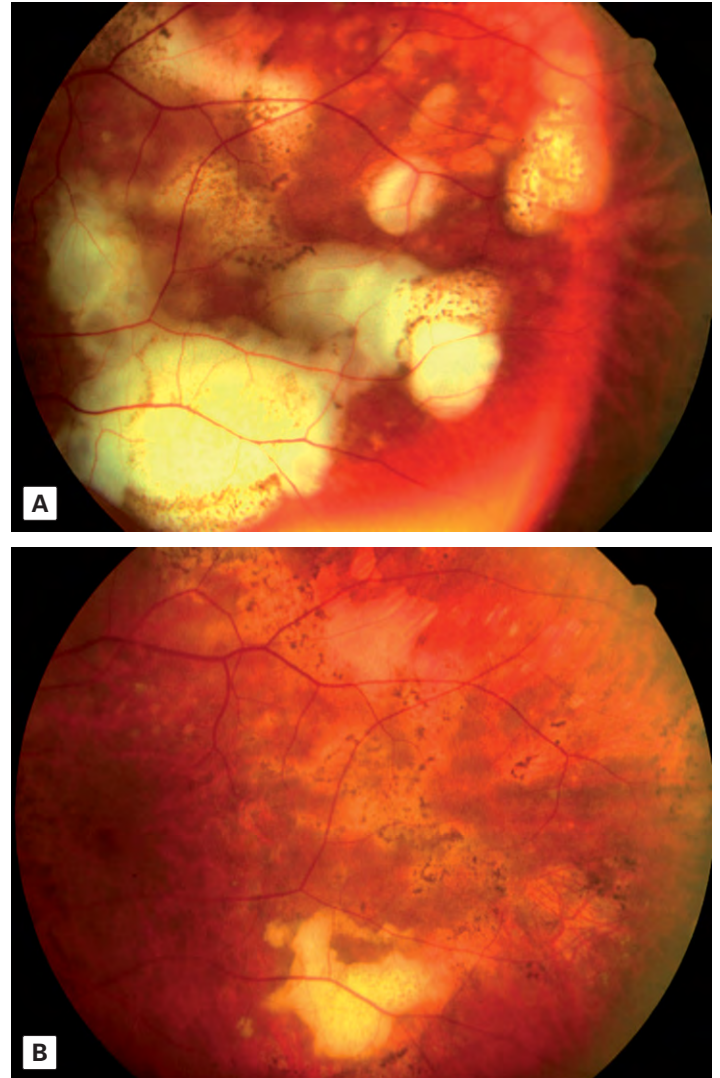
**Fig. 62.1** Slit lamp photograph (retroillumination) showing vitreous cellular infiltrate.

#### BOX 62.1 Diagnostic Findings of PCNSL-O

- Clumps of cells in the vitreous
- Multifocal or diffuse chorioretinal infiltrates with or without vitreous cells
- Multifocal subretinal pigment epithelial infiltrates are considered to be pathognomonic
- Rare findings include choroidal mass, perivasculitis, retinal artery occlusion, and exudative retinal detachment
- Keratitic precipitates, aqueous cells, aqueous flare, and cystoid macular edema are suggestive of inflammation

**Ophthalmic** As a result of the varied clinical features and the rare nature of the condition, a high index of suspicion is needed. Diagnostic vitrectomy should be considered in middle-aged or older patients with ‘idiopathic’ unilateral or bilateral recurrent uveitis, or uveitis that is unresponsive to steroids. Neoplastic cells can be identified by an experienced cytologist using an array of techniques, such as liquid-based cytology, cytospin, and cell block preparations stained with modified Papanicolaou, Giemsa, or standard hematoxylin and eosin stains (Fig. 62.3). Proper and rapid handling of vitreous samples is a must, as the neoplastic cells undergo rapid lysis. It is recommended that an undiluted vitreous sample of about 1 mL be collected prior to starting the infusion during vitrectomy. The sample is processed by liquid-based cytology as it preserves cellular details.<sup>14</sup>

The histologic and cytologic features of the tumor cells are characteristic: the tumor cells are large pleomorphic lymphocytes with scant cytoplasm. The nuclei may be round, oval, or indented, with con-



**Fig. 62.2** (A) Fundus photograph of the left eye demonstrating multiple creamy subretinal pigment epithelial deposits. (B) Regression of the retinal tumors following external beam radiotherapy (45 Gy). (Courtesy of S. Seregard, MD.) (Reproduced with permission from Singh AD, Lewis H, Schachat AP. Primary lymphoma of the central nervous system. *Ophthalmol Clin North Am* 2005; 18: 199–207.)

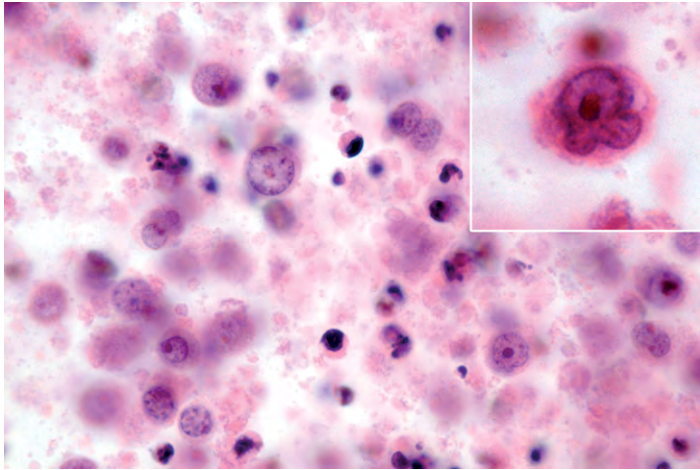
spicuous nuclear membranes, occasional fingerlike protrusions, and multiple, prominent, eccentrically located nucleoli (Fig. 62.3).

Owing to the limited number of cells available for evaluation, it is often difficult to reach a conclusive diagnosis based solely on cytopathological findings. In the presence of chorioretinal lesions, a chorioretinal or retinal biopsy may be required.<sup>5</sup> Ancillary histopathologic techniques include immunohistochemistry and flow cytometry to determine the immunophenotypes of lymphocytes, gene rearrangement studies by using polymerase chain reaction, and determination of interleukin levels (Fig. 62.4). Polymerase chain reaction-based tests are used to detect monoclonal proliferation of B lymphocytes, clonal heavy chain immunoglobulin gene rearrangement, *bcl-2* gene translocation, and T-cell gene rearrangements.<sup>5,15,16</sup>

Initial observation of elevated interleukin-10 in the vitreous led to the development of a diagnostic test wherein a greater than 1.0 ratio of interleukin-10 and interleukin-6 was considered an indicator of

PCNSL-O.<sup>17,18</sup> However, the clinical utility of determining the interleukin ratio is not clearly established, as cases of PCNSL-O with low interleukin ratios have also been reported.<sup>19</sup>

**Central nervous system** Craniospinal magnetic resonance imaging (MRI) with gadolinium is the diagnostic procedure of choice.



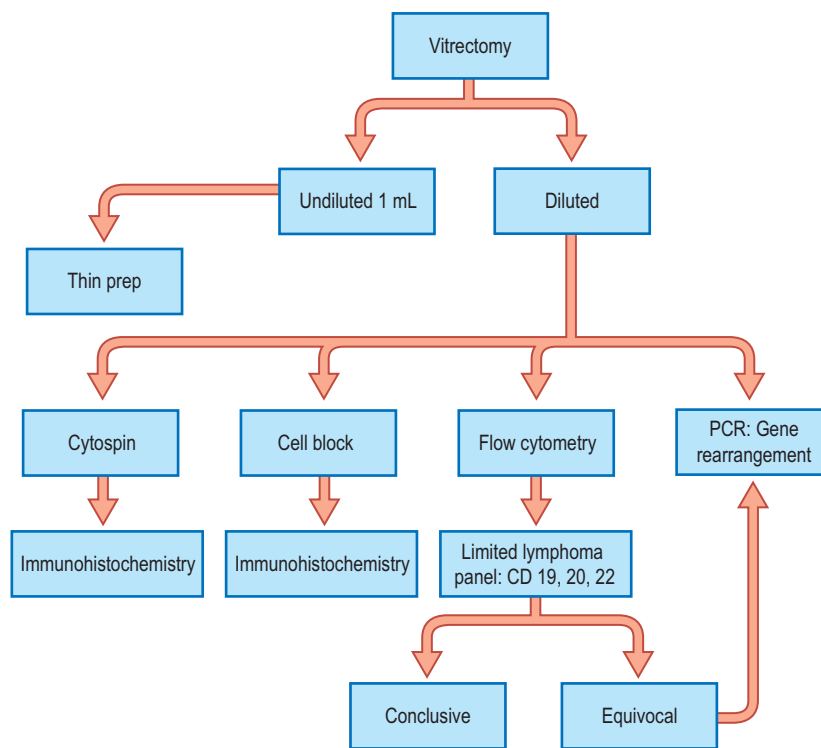
**Fig. 62.3** Vitrectomy sample containing large atypical lymphocytes, necrotic lymphoid cells, and nuclear debris. Inset shows characteristic nuclear membrane protrusions and a prominent nucleolus (main figure, Millipore filter, hematoxylin & eosin, original magnification  $\times 250$ .) (Courtesy of RC Eagle Jr, MD.) (Reproduced with permission from Singh AD, Lewis H, Schachat AP. Primary lymphoma of the central nervous system. *Ophthalmol Clin North Am* 2005; 18: 199–207.)

Cranial lesions appear as multiple isointense nodules on T<sub>1</sub>-MRI, and demonstrate characteristic dense and diffuse contrast enhancement (Fig. 62.5). Meningeal enhancement with gadolinium is indicative of meningeal involvement. Many centers also perform CT scans of the chest, abdomen, and pelvis to exclude systemic involvement or a systemic origin of the CNS involvement.

The presence of malignant lymphocytes in the CSF is confirmatory for the diagnosis of PCNSL. The CSF shows lymphocytic pleocytosis, raised protein concentration, and normal or low glucose concentrations. Visceral involvement is rare at the initial diagnosis but not uncommon in the terminal stages.

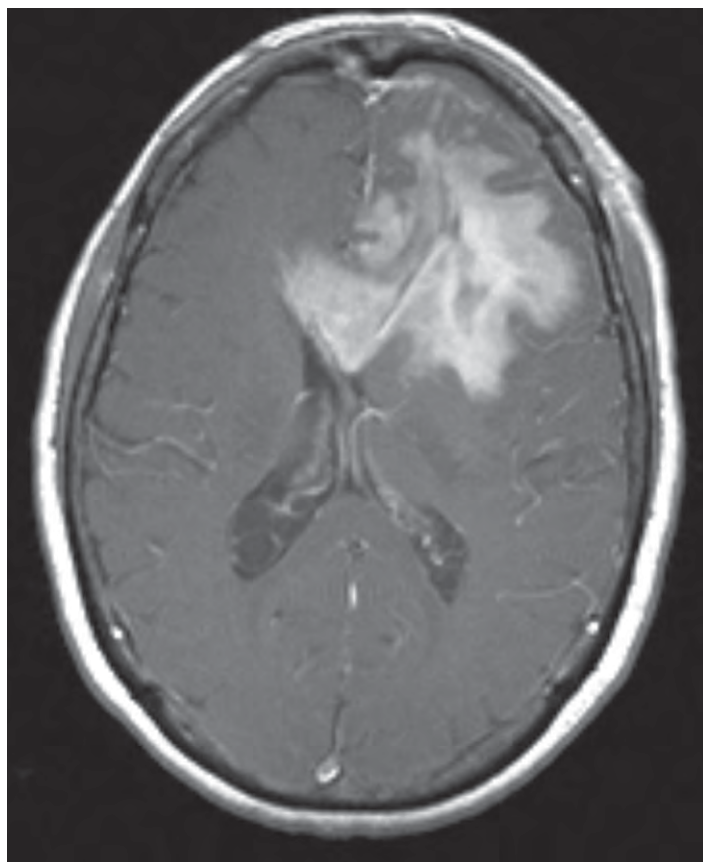
## DIFFERENTIAL DIAGNOSIS

In general, all causes of chronic posterior uveitis, such as syphilis, sarcoidosis, and tuberculosis, should be considered in the differential diagnosis. Infiltrative choroidal lesions such as metastatic tumors and amelanotic melanomas can also mimic PCNSL-O. HIV infection predisposes to both opportunistic infections and PCNSL-O, therefore in an immunosuppressed patient disseminated choroiditis due to *Nocardia* chorioretinitis and *Pneumocystis* choroiditis should be excluded. When the retina and the vitreous are involved, consideration must be given to entities such as viral or fungal retinitis, acute retinal necrosis syndrome, and toxoplasmosis. Multifocal subepithelial lesions of PCNSL-O should be differentiated from diffuse unilateral subacute neuroretinitis, birdshot retinochoroidopathy, multifocal choroiditis, multiple evanescent white-dot syndrome, and punctate inner choroidopathy. When perivascular infiltrates are present, ocular sarcoidosis and retinal vasculitides must be considered. Patients with



**Fig. 62.4** Schema for analysis of vitreous samples for suspected lymphoma. Initial undiluted vitreous specimen (about 1 mL) is processed by ThinPrep for liquid-based cytology because it preserves the cellular details. The diluted vitreous sample is divided into four portions for cytospin, cell block, and flow cytometry. Gene rearrangement studies are performed if the flow cytometry results are equivocal. (Derived from Rishi K, Font RL, Chevez-Barrios P. Diagnostic yield of liquid-based cytology, immunophenotyping and molecular techniques in lymphomas and other entities in vitrectomy specimens. *Invest Ophthalmol Vis Sci* 2004; 45: 1072.)





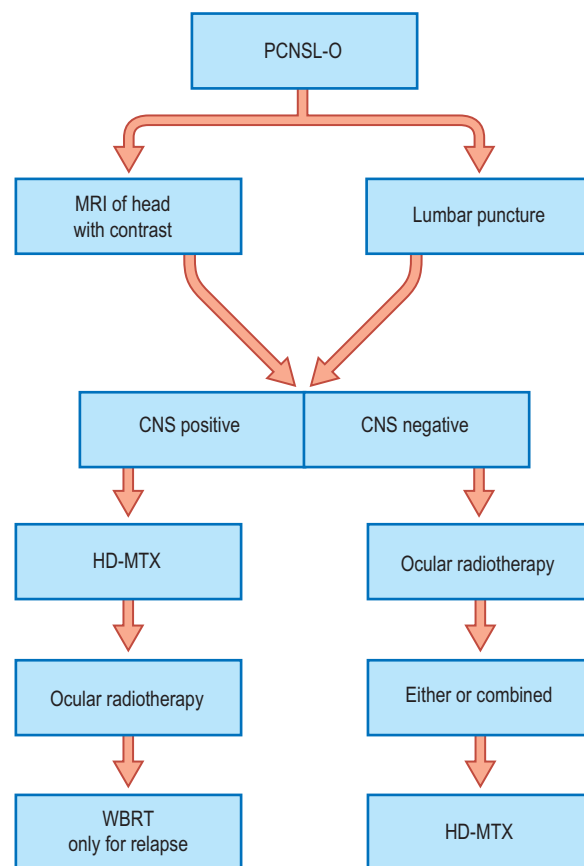
**Fig. 62.5** T<sub>1</sub>-weighted MRI scan of the brain with gadolinium, showing a diffusely enhancing area in the left frontal lobe. (Reproduced with permission from Singh AD, Lewis H, Schachat AP. Primary lymphoma of the central nervous system. *Ophthalmol Clin North Am* 2005; 18: 199–207.)

systemic lymphomas not arising in the CNS who develop retinal infiltrates are more likely to have a superimposed viral or fungal retinitis rather than an intraocular lymphoma.<sup>20</sup>

## TREATMENT

As PCNSL is very sensitive to corticosteroids, treatment should be withheld in suspected cases until a tissue diagnosis is obtained. The treatment of PCNSL is still evolving and some of the guiding principles are discussed below. A schema outlining our current approach of management is shown in Figure 62.6.

**Ophthalmic** Management of PCNSL-O should be undertaken with the guidance of an oncologist who has expertise in lymphoma. As a high percentage of patients with PCNSL-O eventually develop CNS involvement, the aim of treatment must be to eradicate the ocular disease and prevent subsequent CNS involvement. Traditional therapy with ocular radiation (40 Gy in divided doses) controls ocular involvement in the majority of cases,<sup>21</sup> but most progress to develop CNS disease (Fig. 62.2).<sup>11</sup> Irradiation of both eyes (because of the high incidence of bilaterality) should be strongly considered for patients with proven PCNSL-O. Because radiation therapy to the brain may have significant side effects, its use for prophylaxis in patients without proven CNS involvement is not advisable. Instead, high-dose methotrexate (8 g/m<sup>2</sup>) in combination with intrathecal methotrexate and other agents may be considered.<sup>22,23</sup> Systemic therapy by itself,



**Fig. 62.6** Schema outlining our current approach of management of patients with PCNSL-O. HD-MTX, high-dose methotrexate; WBRT, whole-brain radiation therapy.

however, may not be sufficient for treatment of PCNSL-O, even though high-dose methotrexate achieves therapeutic concentrations in the aqueous and vitreous (Table 62.1).<sup>24</sup>

Intravitreal methotrexate as an initial treatment, or for those with recurrence following ocular radiation therapy, has been investigated in a small number of patients with encouraging results (Table 62.1).<sup>25</sup> In a recent report on 16 patients, intravitreal methotrexate (400 µg/0.1 mL) was given over a period of 1 year according to a standard induction–consolidation–maintenance regimen.<sup>26</sup> All patients showed initial tumor control after a maximum of 12 methotrexate injections, but three relapsed. The median follow-up was 18.5 months (range 6–35 months). Complications included cataract (73%), corneal epitheliopathy (58%), maculopathy (42%), and vitreous hemorrhage (8%). No patient had irreversible loss of vision. Primary treatment with intravitreal methotrexate in patients with of PCNSL-O remains investigational.

**Central nervous system** Until recently, whole-brain radiotherapy was the mainstay of treatment, which improved the median survival from 4 months to about 12–18 months in untreated patients.<sup>27</sup> In 1992, trials using a combination of methotrexate-based chemotherapy and radiotherapy first reported an improved median survival of about 40 months.<sup>27</sup> However, the combination of whole-brain radiotherapy and chemotherapy is associated with a significant risk of neurotoxicity in older people.<sup>28</sup> Therefore, chemotherapy alone is the

**Table 62.1 Chemotherapy for treatment of intraocular lymphoma (PCNSL-O)**

Author	Year	Cases/Eyes	Treatment method			Response	Side effects
			Indication	Route	Agent		
Fishburne	1997	47 Eyes	Recurrent	Intravitreal with BBB	MTX 400µg	100%	Visual loss 15%
Sandor	1998	14		Intravenous and intrathecal	MTX, thiotepa, vincristine, cytarabine	79%	Recurrence 71% Neurotoxicity 14%
Soussain	2001	22	Refractory/Recurrent	Intravenous	Multiagent chemotherapy with stem-cell rescue	75%	Recurrence 10% Neurotoxicity 35%
Smith	2002	16/ 26 Eyes	Initial	Intravitreal	MTX 400µg	100%	Recurrence 12% Cataract 73% Epitheliopathy 58% Maculopathy 42% Vitreous hem 8% Optic atrophy 4% Endophthalmitis 4%
Batchelor	2003	9	Initial	Intravenous	MTX High dose	78%	Recurrence 40%

BBB, blood-brain barrier disruption with mannitol; MTX, methotrexate.  
Excluding single case reports.  
(Modified with permission from Singh AD, Lewis H, Schachat AP. Primary lymphoma of the central nervous system. *Ophthalmol Clin North Am* 2005; 18: 199–207)

initial treatment of choice in such patients (60 years and over).<sup>27</sup> Such an approach for younger individuals is currently under investigation, but radiotherapy is rarely used as initial treatment.

As the blood-brain barrier is a limiting factor that restricts drug entry into the CNS, various strategies to circumvent it have been developed. These include the use of high doses, intrathecal drug delivery, intraventricular drug delivery by a reservoir, and temporary disruption of the blood-brain barrier with mannitol infusion.<sup>27</sup> Preliminary data suggest that a median survival of about 50 months, which is comparable to that achieved with a combination of radiation therapy and chemotherapy, can be achieved by chemotherapy alone.<sup>29</sup> However, the treatment of PCNSL is still evolving and is currently being investigated within a framework of international multidisciplinary collaborative studies.<sup>30</sup>

## PROGNOSIS

Most patients with PCNSL die within 2 years of diagnosis as a result of progressive or recurrent CNS disease.<sup>8,10,21</sup> Age less than 60 years at diagnosis and high initial performance status are well recognized favorable prognostic factors in PCNSL.<sup>31</sup> Involvement of the brain stem and meninges implies an unfavorable prognosis.<sup>31</sup> Expression of p53, c-Myc, or Bcl-6 also suggests a poor prognosis.<sup>32</sup> The presence or absence of retinal involvement in the setting of existing CNS disease is not a prognostic factor that influences survival.<sup>31</sup>

## ACKNOWLEDGEMENT

This chapter was modified with permission from Singh AD, Lewis H, Schachat AP. Primary lymphoma of the central nervous system. *Ophthalmol Clin North Am* 2005; 18: 199–207.

## REFERENCES

- Hochberg FH, Miller DC. Primary central nervous system lymphoma. *J Neurosurg* 1988; 68: 835–853.
- DeAngelis LM. Primary central nervous system lymphoma. *Curr Opin Neurol* 1999; 12: 687–691.
- Newell ME, Hoy JF, Cooper SG et al. Human immunodeficiency virus-related primary central nervous system lymphoma: factors influencing survival in 111 patients. *Cancer* 2004; 100: 2627–2636.
- Marshall AG, Pawson R, Thom M et al. HTLV-I associated primary CNS T-cell lymphoma. *J Neurol Sci* 1998; 158: 226–231.
- Coupland SE, Bechrakis NE, Anastassiou G et al. Evaluation of vitrectomy specimens and chorioretinal biopsies in the diagnosis of primary intraocular lymphoma in patients with Masquerade syndrome. *Graefes Arch Clin Exp Ophthalmol* 2003; 241: 860–870.
- Choi JS, Nam DH, Ko YH et al. Primary central nervous system lymphoma in Korea: comparison of B- and T-cell lymphomas. *Am J Surg Pathol* 2003; 27: 919–928.
- Olson JE, Janney CA, Rao RD et al. The continuing increase in the incidence of primary central nervous system non-Hodgkin lymphoma: a surveillance, epidemiology, and end results analysis. *Cancer* 2002; 95: 1504–1510.
- Char DH, Ljung BM, Miller T, Phillips T. Primary intraocular lymphoma (ocular reticulum cell sarcoma) diagnosis and management. *Ophthalmology* 1988; 95: 625–630.
- Whitcup SM, de Smet MD, Rubin BI et al. Intraocular lymphoma. Clinical and histopathologic diagnosis. *Ophthalmology* 1993; 100: 1399–1406.
- Freeman LN, Schachat AP, Knox DL et al. Clinical features, laboratory investigations, and survival in ocular reticulum cell sarcoma. *Ophthalmology* 1987; 94: 1631–1639.
- Peterson K, Gordon KB, Heinemann MH, DeAngelis LM. The clinical spectrum of ocular lymphoma. *Cancer* 1993; 72: 843–849.
- Akpek EK, Ahmed I, Hochberg FH et al. Intraocular-central nervous system lymphoma: clinical features, diagnosis, and outcomes. *Ophthalmology* 1999; 106: 1805–1810.

13. Gass JD, Sever RJ, Grizzard WS et al. Multifocal pigment epithelial detachments by reticulum cell sarcoma. A characteristic fundusoscopic picture. *Retina* 1984; 4: 135–143.
14. Rishi K, Font RL, Chevez-Barrios P. Diagnostic yield of liquid-based cytology, immunophenotyping and molecular techniques in lymphomas and other entities in vitrectomy specimens. *Invest Ophthalmol Vis Sci* 2004; 45: 1072.
15. Shen DF, Zhuang Z, LeHoang P et al. Utility of microdissection and polymerase chain reaction for the detection of immunoglobulin gene rearrangement and translocation in primary intraocular lymphoma. *Ophthalmology* 1998; 105: 1664–1669.
16. White VA, Gascoyne RD, Paton KE. Use of the polymerase chain reaction to detect B- and T-cell gene rearrangements in vitreous specimens from patients with intraocular lymphoma. *Arch Ophthalmol* 1999; 117: 761–765.
17. Chan CC, Whitcup SM, Solomon D, Nussenblatt RB. Interleukin-10 in the vitreous of patients with primary intraocular lymphoma. *Am J Ophthalmol* 1995; 120: 671–673.
18. Buggage RR, Whitcup SM, Nussenblatt RB, Chan CC. Using interleukin 10 to interleukin 6 ratio to distinguish primary intraocular lymphoma and uveitis. *Invest Ophthalmol Vis Sci* 1999; 40: 2462–2463.
19. Akpek EK, Foster CS. Primary intraocular lymphoma with a low interleukin 10 to interleukin 6 ratio and heterogeneous IgH gene arrangement. *Arch Ophthalmol* 2000; 118: 731–732.
20. Schanzer MC, Font RL, O'Malley RE. Primary ocular malignant lymphoma associated with the acquired immune deficiency syndrome. *Ophthalmology* 1991; 98: 88–91.
21. Margolis L, Fraser R, Lichter A, Char DH. The role of radiation therapy in the management of ocular reticulum cell sarcoma. *Cancer* 1980; 45: 688–692.
22. Sandor V, Stark-Vancs V, Pearson D et al. Phase II trial of chemotherapy alone for primary CNS and intraocular lymphoma. *J Clin Oncol* 1998; 16: 3000–3006.
23. Hormigo A, DeAngelis LM. Primary ocular lymphoma: clinical features, diagnosis, and treatment. *Clin Lymphoma* 2003; 4: 22–29.
24. Batchelor TT, Kolak G, Ciordia R et al. High-dose methotrexate for intraocular lymphoma. *Clin Cancer Res* 2003; 9: 711–715.
25. Singh AD, Lewis H, Schachat AP. Primary lymphoma of the central nervous system. *Ophthalmol Clin North Am* 2005; 18: 199–207, x.
26. Smith JR, Rosenbaum JT, Wilson DJ et al. Role of intravitreal methotrexate in the management of primary central nervous system lymphoma with ocular involvement. *Ophthalmology* 2002; 109: 1709–1716.
27. DeAngelis LM, Hormigo A. Treatment of primary central nervous system lymphoma. *Semin Oncol* 2004; 31: 684–692.
28. Correa DD, DeAngelis LM, Shi W et al. Cognitive functions in survivors of primary central nervous system lymphoma. *Neurology* 2004; 62: 548–555.
29. Pels H, Schmidt-Wolf IG, Glasmacher A et al. Primary central nervous system lymphoma: results of a pilot and phase II study of systemic and intraventricular chemotherapy with deferred radiotherapy. *J Clin Oncol* 2003; 21: 4489–4495.
30. Ferreri AJ, Abrey LE, Blay JY et al. Summary statement on primary central nervous system lymphomas from the Eighth International Conference on Malignant Lymphoma, Lugano, Switzerland, 12–15 June 2002. *J Clin Oncol* 2003; 21: 2407–2414.
31. Blay JY, Conroy T, Chevreau C et al. High-dose methotrexate for the treatment of primary cerebral lymphomas: analysis of survival and late neurologic toxicity in a retrospective series. *J Clin Oncol* 1998; 16: 864–871.
32. Chang CC, Kampalath B, Schultz C et al. Expression of p53, c-Myc, or Bcl-6 suggests a poor prognosis in primary central nervous system diffuse large B-cell lymphoma among immunocompetent individuals. *Arch Pathol Lab Med* 2003; 127: 208–212.



# Ocular paraneoplastic diseases

Rishi P. Singh and Arun D. Singh

## INTRODUCTION

Paraneoplastic disorders are defined as syndromes in which the end organ effect is not a direct consequence of the mass or of distant metastasis. Instead, an autoimmune response to the primary tumor causes end-organ disorder and dysfunction. The temporal relationship of paraneoplastic illnesses can occur before, at the time of diagnosis, and even after the identification of the primary malignancy, and in rare cases the primary may never be discovered.

Ocular paraneoplastic diseases include a wide range of clinical manifestations, ranging from color deficiencies to complete blindness. Their diagnosis is complicated by the fact that cancers can by themselves cause remote ocular effects due to toxicity from antineoplastic agents, nutritional deficiencies, and direct opportunistic infections. This chapter summarizes the salient features of cancer-associated retinopathy (CAR), melanoma-associated retinopathy (MAR), bilateral diffuse uveal melanocytic proliferation (BDUMP), paraneoplastic optic neuropathy, and opsoclonus manifesting as paraneoplastic ocular disease (Table 63.1).

## CANCER-ASSOCIATED RETINOPATHY

Cancer-associated retinopathy was first described in 1981 during the Walsh society meeting and was postulated to have an autoimmune cause, given the patients' response to corticosteroids.<sup>1</sup> CAR is most commonly associated with small cell carcinoma of the lung, followed by gynecological and breast carcinomas. It is less commonly found in patients with non-small cell carcinoma of the lung, laryngeal, bladder, lymphoma, and prostate cancer.<sup>2</sup>

**Etiology and pathogenesis** Research studies have identified various autoantibodies that cross-react with retinal antigens. The substrates for antibody formation include recoverin, heat shock cognate protein (HSC70), and others that are thought to be tumor antigens with cross-reactivity toward retinal proteins.<sup>3-5</sup> Recoverin plays a role in light and dark adaptation by regulating rhodopsin phosphorylation and dephosphorylation in a calcium-dependent manner.<sup>6</sup> CAR affects both rod and cone function late in the disease. Rod dysfunction manifests with night vision, prolonged dark adaptation, and mid-peripheral visual scotomas. Cone dysfunction causes color perception abnormalities and central and ceco-central scotomas.

## Clinical features

**Symptoms** Cancer-associated retinopathy is characterized by painless progressive visual loss over weeks to months. In a retrospective

review, severe deterioration in vision (less than 20/200) was found in 47% of all patients.<sup>7</sup> Initial complaints are of dimming of vision and positive visual phenomena, such as shimmering lights.

**Signs** Early in the course, the eye may appear to be entirely normal. Anterior segment findings have rarely been reported in cases of CAR, except for iritis. Posterior segment findings predominate and include narrowing of the retinal vessels, chorioretinal atrophy, and optic nerve atrophy. Vitritis, peripheblitis, and arteriolar sheathing occur later in the disease course.<sup>5</sup>

**Diagnostic evaluation** Assessment of retinal functions using Goldmann or Humphrey visual fields, Farnsworth color assessments, and electroretinography (ERG) is important for establishing the diagnosis (Fig. 63.1). Visual field testing can manifest various defects, such as central, paracentral, or arcuate/ring scotomas, and generalized field depression. However, the most common finding is a constriction within the central 20° of visual fields.<sup>7</sup> Electroretinographic studies are helpful both in the confirmation of the diagnosis and when the clinical findings are subtle. The classic pattern is of suppressed photopic and scotopic responses.<sup>8</sup>

It is also possible to obtain serum assays for several antiretinal antibodies, such as anti-recoverin antibodies and anti-enolase antibodies from commercial laboratories.<sup>3,9</sup> Relatively low titers of anti-recoverin antibodies (<1 : 1000) can be found in the serum of an estimated 10% of asymptomatic cancer patients prior to systemic chemotherapy, and also in patients with non-cancer-related retinopathy.<sup>5,10</sup>

**Differential diagnosis** CAR must be distinguished from other non-paraneoplastic autoimmune retinopathies, including MAR and paraneoplastic optic neuropathies. Furthermore, infiltration by the primary carcinoma or anterior ischemic disease must be ruled out. Anterior visual pathways may also be affected by chemotherapeutic agents such as vincristine.

**Treatment** When present, the visual improvement after treatment for CAR is generally modest and often transient. The rise of antibodies to retinal antigens is a useful indication that steroid therapy should be started, as this precedes visual loss.<sup>11</sup> Immunomodulatory drugs have shown variable success in patients with CAR. Intravenous high-dose methylprednisone and, less commonly, oral steroids have shown benefit in reversing the visual changes seen early in the illness. Once photoreceptor degeneration has begun, steroid use only stabilizes

**Table 63.1 Paraneoplastic retinopathies**

Feature	CAR	MAR	BDUMP
Symptoms	Bilateral visual loss Positive visual phenomenon Nyctalopia	Near normal acuities Normal color vision Normal central visual fields	Severe visual loss Cutaneous/mucosal focal melanocytic proliferation
Fundus examination	Vessel attenuation, chorioretinal atrophy, optic atrophy	Majority have normal appearance. Few have vascular attenuation, RPE changes, and vitreous cells	Multiple elevated uveal melanocytic tumors Exudative retinal detachment
Visual field	Central/paracentral scotoma	Paracentral scotoma	Central/paracentral scotomas
ERG findings	Depressed scotopic and photopic response	'Negative' ERG	Depressed scotopic and photopic response
Associated malignancy	Lung carcinoma (small cell) Gynecological carcinoma Breast carcinoma	Cutaneous melanoma	Small cell carcinoma and others
Antibodies	Anti-recoverin Anti-enolase Anti-65-kDA Heat shock cognate protein 70	Rod bipolar 'on' cells	Not known
Prognosis	Progression to severe visual loss	Progression to severe visual loss	Progression to severe visual loss

CAR, cancer-associated retinopathy; MAR, melanoma-associated retinopathy; BDUMP, bilateral diffuse uveal melanocytic proliferation.

vision. Small case series have evaluated the use of intravenous immunoglobulin G and found success in stabilizing or slightly improving visual results.<sup>12</sup> The benefit of plasmapheresis alone remains to be established. The use of chemotherapy, radiotherapy, and local excision of the primary tumor has shown no effect on CAR.<sup>2</sup>

**Prognosis** The visual prognosis with CAR is generally very poor.

### MELANOMA-ASSOCIATED RETINOPATHY

Melanoma-associated retinopathy (MAR) was not recognized as a distinct clinical entity until Berson<sup>13</sup> in 1988 showed that this night blindness was a paraneoplastic phenomenon. Unlike CAR, which can occur before or after the diagnosis of the underlying malignancy, MAR typically occurs after diagnosis, when metastatic disease is present. In a review of the cases of MAR published in the literature, only two patients presented prior to the diagnosis and six before metastasis.<sup>2</sup>

**Etiology and pathogenesis** As with CAR, patients with MAR have antibodies toward tumor antigens that cross-react with antigens on retinal cells.<sup>14</sup> Circulating immunoglobulin-G antibodies directed toward human rod bipolar cells are usually present.<sup>15</sup> However, these circulating antibodies are not specific to MAR. Recent studies have shown that the rod antibodies found in MAR are directed preferentially towards the 'on' bipolar cells.<sup>16</sup> This selective damage of bipolar and Mueller cells produces a negative-appearing scotopic response termed the 'negative ERG.'<sup>8</sup>

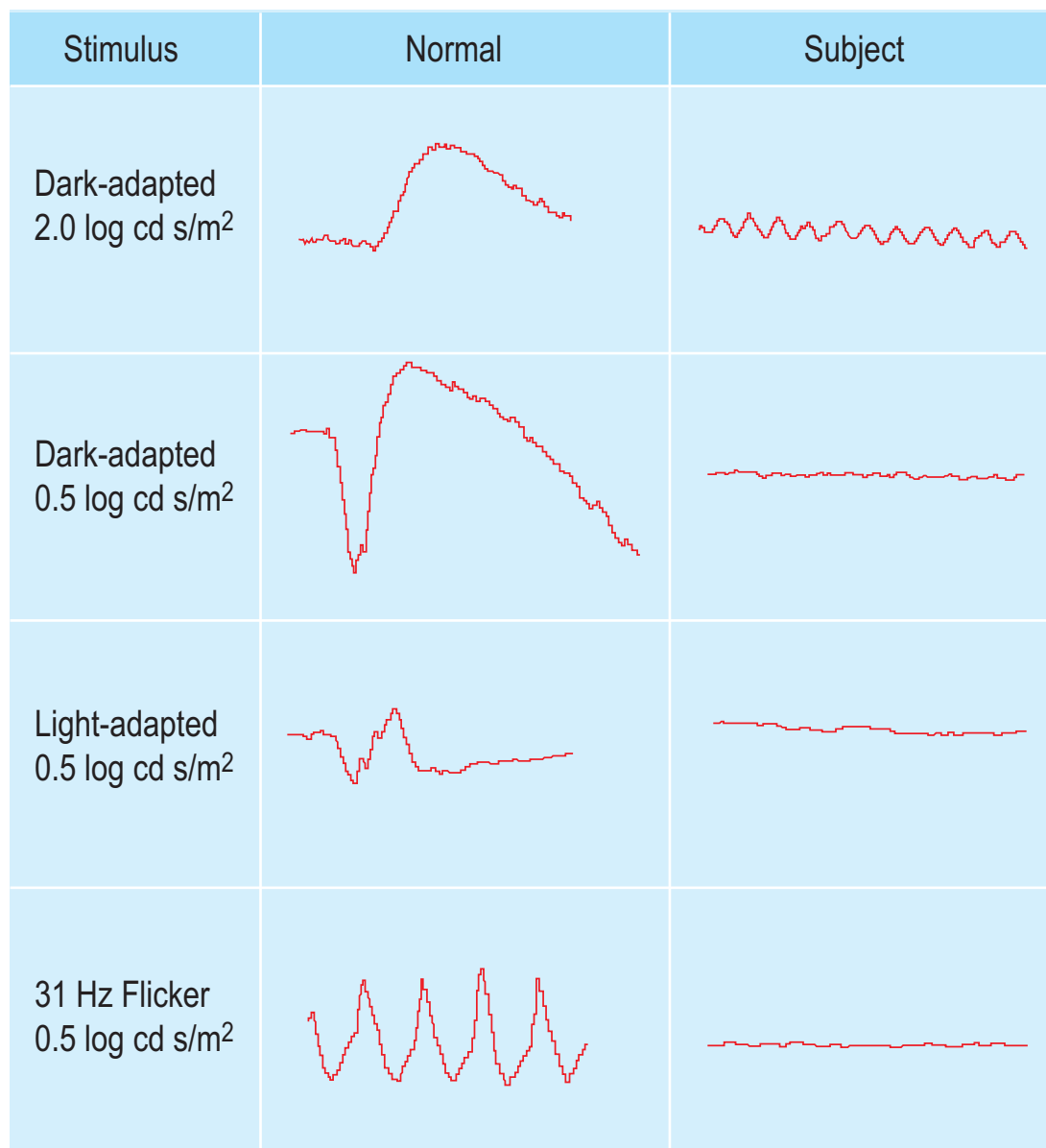
**Clinical features** The vast majority of patients with MAR are male, most often with an established diagnosis of cutaneous melanoma.<sup>17</sup> It also has been reported in a case of choroidal melanoma.<sup>18</sup>

**Symptoms** The clinical features of MAR are similar to those seen in other paraneoplastic retinopathies. Patients typically report shimmering, flickering photopsias, peripheral scotomas, acute-onset night blindness, and slowly progressive visual loss.<sup>17,19</sup> Subclinical MAR as detected by electroretinography, perimetry, and nyctometry appears to be more common than previously suspected in patients with cutaneous melanoma.<sup>20</sup>

**Signs** Patients typically have near normal visual acuity, color vision, and central visual fields, unlike CAR patients, who manifest more severe deficits at presentation.<sup>19</sup> Few patients manifest fundus changes. In a series of 34 patients with proven MAR 44% had normal findings on presentation, 30% had vascular attenuation, and 28% had RPE changes. Vitreous cells were present in 30%, and 23% had optic disc pallor.<sup>19,21</sup>

**Diagnostic evaluation** As with other paraneoplastic retinopathies the initial diagnostic evaluation should consist of Goldmann or Humphrey visual fields, Farnsworth color assessments, and ERG. Visual field testing can reveal mid-peripheral defects or peripheral field depressions. MAR manifests ERG abnormalities, including absent or reduced b-waves even after dark adaptation with preserved a-waves.<sup>17</sup> A positive history of cutaneous malignant melanoma and circulating immunoglobulin (Ig)-G antibodies directed toward human rod bipolar cells establishes the diagnosis (Fig. 63.2). Many commercial laboratories can readily assay serum sample for these antibodies. However, these circulating antibodies are not specific to MAR.

**Differential diagnosis** MAR must be differentiated from congenital stationary night blindness (CSNB), vincristine toxicity, juvenile



**Fig. 63.1** A 67-year-old man with a known history of lung cancer presented with halos in both eyes. Electroretinograms recorded from a normal control subject and from the patient. Responses recorded from the two eyes of the patient were averaged together. Extinguished ERG responses in the patient were suggestive of cancer-associated retinopathy. (Courtesy of Neal Peachey, PhD).

retinoschisis, and non-ischemic central retinal vein occlusion.<sup>22</sup> Although eye history and examination can help distinguish some of these entities, ancillary testing with ERG and serum antibody testing establish the diagnosis. CSNB can be distinguished from MAR on ERG, as blue cones are typically spared in CSNB.

**Treatment** The key to management is early detection, because MAR causes irreversible destruction of bipolar and Mueller cells. The treatment is similar to that for CAR. Isolated case reports document the benefits of cytoreduction of the primary tumor by radiation, intravenous immunoglobulin infusion, and plasmapheresis in combination with steroids.<sup>19,23</sup> Given the sporadic nature of MAR, insufficient data on new modalities are available to permit comment on the reported responses. A meta-analysis of the literature found that in MAR only 4% had visual improvement or an improvement in fundus changes

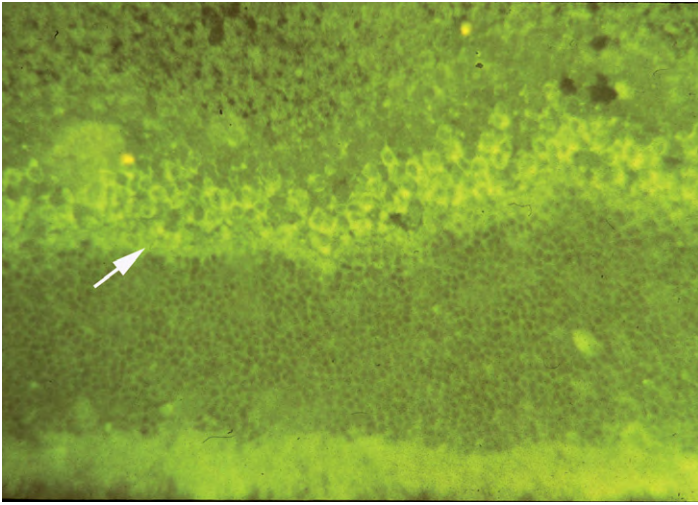
after treatment.<sup>2</sup> Modalities currently under investigation include aggressive management of the primary tumor in addition to immunosuppressive therapy.

**Prognosis** Visual loss in MAR is progressive owing to the decline in retinal dysfunction seen late in the course of the disease. In a review of 34 patients with MAR there was a significant decline in acuity, with only 10 patients having visual acuity better than 20/60.<sup>19</sup>

### **BILATERAL DIFFUSE UVEAL MELANOCYTIC PROLIFERATION (PARANEOPLASTIC MELANOCYTIC PROLIFERATION)**

Bilateral diffuse uveal melanocytic proliferation (BDUMP) is a rare but recognized paraneoplastic disorder that causes bilateral painless visual loss in patients with systemic carcinomas. Since the original





**Fig. 63.2** A 64-year-old man presented with photopsia, difficulty with night vision, and reduced peripheral visual field in both eyes of 3 months' duration. He had been recently diagnosed with malignant melanoma of the maxillary sinus. The corrected visual acuity was 20/20 in both eyes. Results of the anterior segment and fundus examination were normal in both eyes. An electroretinogram showed marked reduction in the b-wave amplitude under scotopic testing conditions to a bright flash. Indirect immunofluorescence was performed on cryosections of unfixed human retina using serum and IgG from the patient. Fluorescein isothiocyanate-labeled antihuman IgG and IgM were used as secondary antibodies. A weak but specific labeling of bipolar cells was observed (arrow). The patient's visual status remained stable for the next 12 months, when he died from metastatic disease. (Reproduced with permission from Singh AD, Milam AH, Shields CL et al. Melanoma-associated retinopathy. *Am J Ophthalmol* 1995; 119: 369-370.)

description by Machermer<sup>24</sup> and Barr,<sup>25</sup> about 22 cases have been published.<sup>26</sup> In the majority of cases the primary carcinoma is unknown at presentation. The primary tumor can arise from numerous sites, but gynecological neoplasms, including those of the ovary, cervix, and uterus, predominate. Other sites, including lung, colon, pancreas, gallbladder, breast, and esophagus, have been reported.<sup>2</sup>

**Etiology and pathogenesis** The exact pathogenesis of BDUMP is not known. It is believed that production of hormonal or other oncogenic stimulus by the primary carcinoma causes activation and proliferation of pre-existing nevus cells within the uveal tract, mucosal membranes, and skin. Biopsy of the lesion shows melanocytic infiltration composed predominately of benign nevus cells with few mitotic figures in the uvea and the skin (Fig. 63.3).<sup>27</sup> As the proliferation of melanocytes is not limited to the uvea, paraneoplastic melanocytic proliferation may be a better descriptive term.<sup>27</sup>

**Clinical features** The mean age at diagnosis is 63 years, with a preponderance of women affected.

**Symptoms** In half of the reported cases the ocular symptoms manifest before the diagnosis of an underlying malignancy. Patients typically manifest severe progressive visual loss over months to years. Central and paracentral scotomas have been reported. In addition, cutaneous and/or mucosal focal melanocytic proliferation has also been observed in five cases of documented BDUMP syndrome

(Fig. 63.3).<sup>27</sup> Mucosal involvement was widespread, with pigmentation in the oral mucosa and lips, penis, and rectum.<sup>27</sup> Similarly, the acquired cutaneous pigmentation appeared to be site non-specific, with head, neck, shoulder, and vulval involvement.<sup>26</sup>

**Signs** Gass<sup>28</sup> established the five cardinal signs associated with the diagnosis of BDUMP: the typical fundus pattern consists of multiple elevated red round patches at the level of the retinal pigment epithelium; a multifocal pattern of early hyperfluorescence corresponding to the patches; pigmented and non-pigmented uveal melanocytic tumors and diffuse thickening of the uvea; coexistent exudative retinal detachment; and the rapid development of cataracts (Fig. 63.3). Other slit lamp findings may include dilated episcleral vessels, shallow anterior chamber, iridodonesis, and cells in the anterior chamber and vitreous.

**Diagnostic evaluation** As with other paraneoplastic ocular disorders the initial diagnostic evaluation should consist of Goldmann or Humphrey visual fields, ERG, and color assessments. ERG studies performed in patients with BDUMP found flat or markedly reduced cone and rod responses. However, the angiographic findings are specific to BDUMP, and consist of early hyperfluorescence due to focal destruction of the pigment epithelium and sparing of the choriocapillaris. In late frames, there is marked choroidal hyperfluorescence with patches of hypofluorescence.<sup>28</sup>

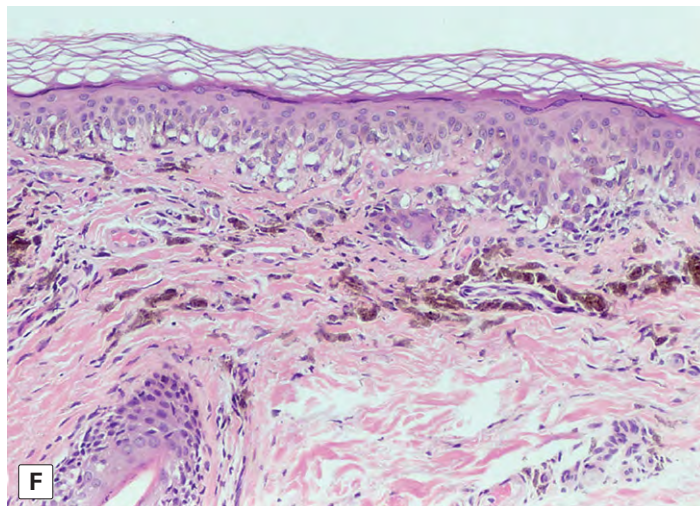
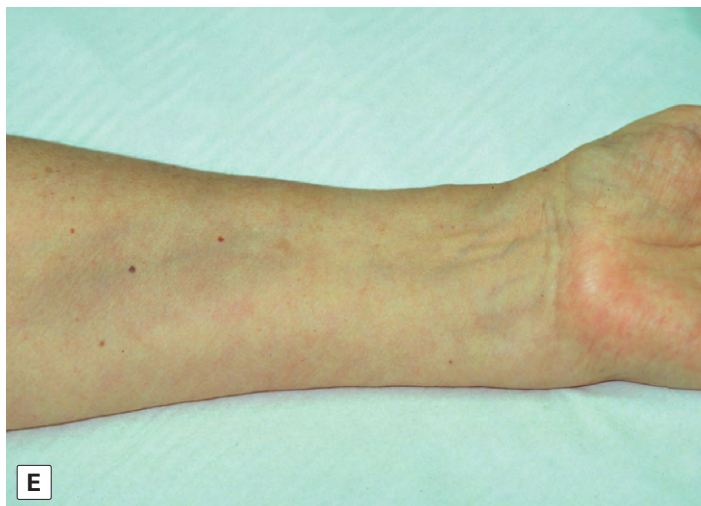
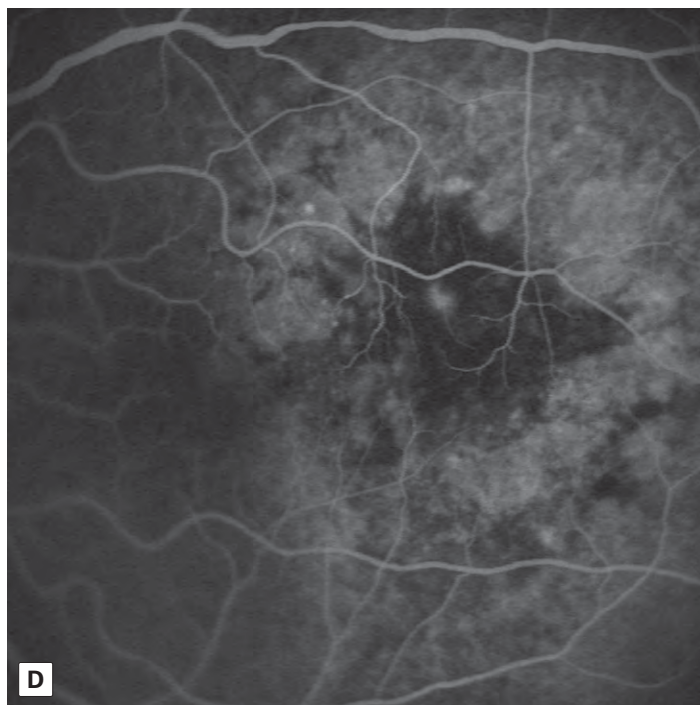
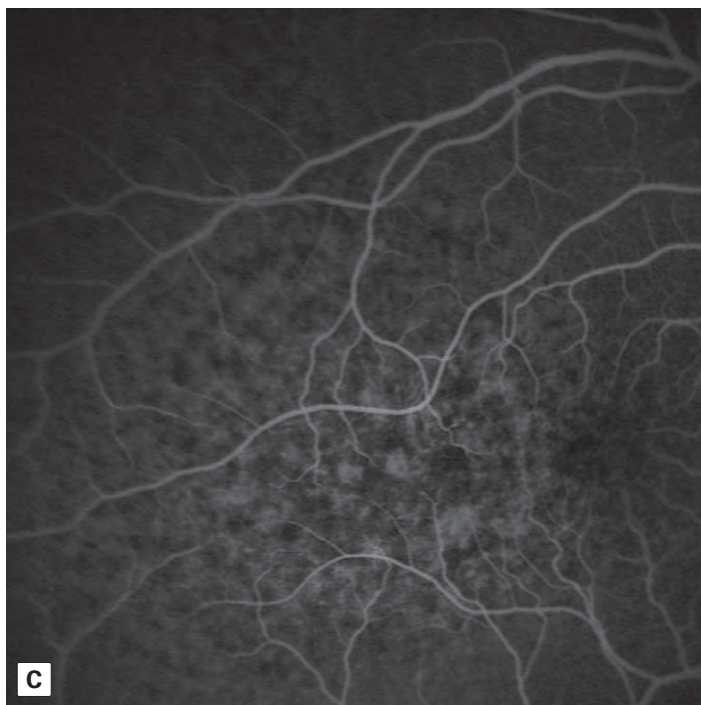
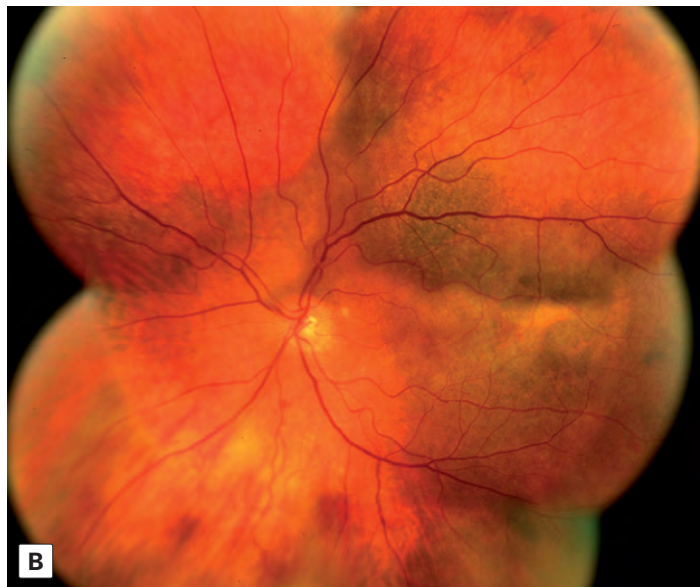
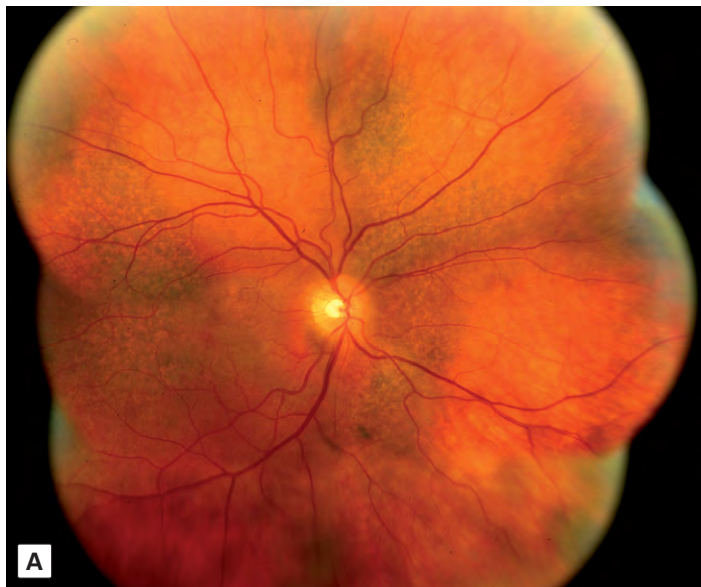**Differential diagnosis** BDUMP should be distinguished from other inflammatory or neoplastic disorders that cause multifocal or diffuse cellular infiltration of the choroid. These can be separated into two categories, based on the presence or absence of pigmented choroidal tumors. Idiopathic uveal effusion syndrome, large cell lymphoma, metastatic carcinoma, leukemia, multifocal and diffuse choroiditis, posterior scleritis, and benign reactive lymphocytic hyperplasia can mimic BDUMP prior to the presence of multifocal pigmented choroidal tumors. Metastatic melanoma to the uvea and multiple choroidal nevi can resemble multifocal pigmented choroidal tumors observed in BDUMP syndrome.

**Treatment** No treatment has been shown to prevent severe visual loss in patients with BDUMP. The use of corticosteroids and ocular external radiotherapy do not prevent the progression of the disease.<sup>29</sup> Vitrectomy, silicone oil injection, and panretinal photocoagulation have all failed to prevent the retinal detachments seen in the late stages of BDUMP.<sup>28</sup>

**Prognosis** Because BDUMP can be the first manifestation of an occult carcinoma, early diagnosis is key to improving the patient's prognosis for therapy and survival. However, the presence of BDUMP has been reported to lead to death from the occult carcinoma within 12–24 months. There have been no reported cases of metastasis from the choroidal lesions found in BDUMP.<sup>26</sup>

## PARANEOPLASTIC OPTIC NEUROPATHIES

Paraneoplastic optic neuropathies occur within the clinical spectrum of cerebellar and brainstem paraneoplastic disorders. These optic neuropathies have been reported in Hodgkin's and non-Hodgkin's lymphoma, neuroblastoma, bronchial carcinoma, nasopharyngeal carcinoma, small cell lung carcinoma and others.





**Fig. 63.3** A 56-year-old woman presented with progressive deteriorating vision in both eyes for the last 6 months. The onset of visual symptoms coincided with the diagnosis of large cell carcinoma of the lung. She was not known to have metastases and was receiving chemotherapy. The corrected visual acuity was 20/40 in the right eye and 20/60 in the left. Anterior segment examination was unremarkable. On ophthalmoscopic examination the choroid was diffusely thickened in both eyes (**A**, right eye; **B**, left eye). The choroid was also markedly hypermelanotic with scattered areas of orange pigmentation. The choroidal thickening was confirmed by B-scan ultrasonography. Fluorescein angiographic studies showed hypofluorescence corresponding to the distribution of the orange pigment and multifocal patchy hyperfluorescence in the right eye (**C**). The angiographic findings were similar but more pronounced in the left eye (**D**). Over the last few months the patient had noticed new-onset pigmented lesions on her forearms and thighs (**E**). Histopathologic evaluation of one of the cutaneous lesions showed confluent proliferation of cytologically atypical melanocytes in the basal layers of the epidermis with focal extension into the mid-epidermis (**F**). Her visual status worsened over the next 6 months, when she died from metastatic disease. (Reproduced with permission from Singh AD, Rundle PA, Slater DN et al. Uveal and cutaneous involvement in paraneoplastic melanocytic proliferation. *Arch Ophthalmol* 2003; 121: 1637–1640.)

## Etiology and pathogenesis

### Clinical features

**SYMPTOMS** Neurologic symptoms may precede or follow the ocular manifestations of the syndrome. Patients present with unilateral, subacute, painless visual loss that progresses over weeks to months to involve both eyes. Additional ophthalmic symptoms may include blurred vision, tunnel vision, and spots or flashes. More recently, signs of retinitis and vitreal inflammation have been recognized in a significant proportion of these patients. In addition, patients can present with neurological findings of encephalomyeloradiculopathy, which can include mental status, cranial nerve, motor, autonomic, and movement disorders.<sup>30</sup>

**SIGNS** In the majority of patients the optic nerves appear normal, but optic disc edema may be observed. With treatment of the underlying disorder, the disc edema can resolve but the optic nerve dysfunction continues.

**Diagnostic evaluation** CSF analysis often shows mild to moderate lymphocytosis and elevated protein levels but no evidence of malignant cells. The ERG results are typically normal. Testing for CAR antibody is negative, and although antibodies have been identified in this illness it is unclear whether they represent an immune response to the cancer and may not cause the ocular symptoms.

**Differential diagnosis** Paraneoplastic optic neuropathy should be distinguished from the other previously mentioned paraneoplastic retinopathies, acute ischemic optic neuropathy, and infiltration of the optic nerve by metastatic or primary tumor.

**Treatment** of the underlying malignancy with excision, radiation, chemotherapy, and the use of corticosteroids improves visual acuity and visual field defects.<sup>2</sup>

**Prognosis** The prognosis for paraneoplastic optic neuropathy is good. Almost complete visual recovery frequently follows successful treatment of the underlying cancer.<sup>31–33</sup>

## OPSOCLONUS

Opsoclonus is part of a larger group of ocular disorders caused by paraneoplastic cerebellar degeneration. Ocular findings often are abnormal, including horizontal or vertical nystagmus, dysconjugate gaze, ocular dysmetria, and opsoclonus. The clinical picture is referred to as ‘dancing eyes’ because of the rapid ocular movements.<sup>34</sup> Lung cancer is the most common malignancy reported with opsoclonus, but it has also been described in association with tumors of the breast, ovary, and uterus.<sup>34</sup> Unlike with CAR and MAR, antibodies do not appear to cause the cerebellar damage. Rather, ‘killer T cells,’ or cytotoxic CD8+ T lymphocytes, are the most likely mediator of neuronal injury.<sup>35</sup> Assays for antibodies such as anti-RI, anti-Yu, and anti-Ho are useful for establishing the diagnosis.<sup>36</sup> Opsoclonus is sensitive to the treatment of the underlying malignancy, corticosteroids, and the infusion of intravenous Ig-G.<sup>37</sup>

## SUMMARY

Paraneoplastic ocular disorders can present with a multitude of ocular symptoms having overlapping characteristics. Ancillary testing with ERG and commercially available assays for suspected antibodies elicited by the primary tumor have proved quite useful. The correct and early identification of the occult malignancy through ocular examination leads to earlier therapeutic interventions and a better prognosis. Future therapies will focus on the potential benefits of new immunomodulatory medications in treating the paraneoplastic condition and on tumor surveillance through serial antibody evaluations.

## REFERENCES

1. Sawyer RA, Selhorst JB, Zimmerman LE, Hoyt WF. Blindness caused by photoreceptor degeneration as a remote effect of cancer. *Am J Ophthalmol* 1976; 81: 606–613.
2. Chan JW. Paraneoplastic retinopathies and optic neuropathies. *Surv Ophthalmol* 2003; 48: 12–38.
3. Thirkill CE, Keltner JL, Tyler NK, Roth AM. Antibody reactions with retina and cancer-associated antigens in 10 patients with cancer-associated retinopathy. *Arch Ophthalmol* 1993; 111: 931–937.
4. Chant SM, Heckenlively J, Meyers-Elliott RH. Autoimmunity in hereditary retinal degeneration. I. Basic studies. *Br J Ophthalmol* 1985; 69: 19–24.
5. Adamus G, Machnicki M, Seigel GM. Apoptotic retinal cell death induced by antirecoverin autoantibodies of cancer-associated retinopathy. *Invest Ophthalmol Vis Sci* 1997; 38: 283–291.
6. Ohguro H, Rudnicka-Nawrot M, Buczylo J et al. Structural and enzymatic aspects of rhodopsin phosphorylation. *J Biol Chem* 1996; 271: 5215–5224.
7. Ohguro H, Yokoi Y, Ohguro I et al. Clinical and immunologic aspects of cancer-associated retinopathy. *Am J Ophthalmol* 2004; 137: 1117–1119.
8. Scholl HP, Zrenner E. Electrophysiology in the investigation of acquired retinal disorders. *Surv Ophthalmol* 2000; 45: 29–47.



9. Dot C, Guigay J, Adamus G. Anti-alpha-enolase antibodies in cancer-associated retinopathy with small cell carcinoma of the lung. *Am J Ophthalmol* 2005; 139: 746–747.
10. Whitcup SM, Vistica BP, Milam AH et al. Recoverin-associated retinopathy: a clinically and immunologically distinctive disease. *Am J Ophthalmol* 1998; 126: 230–237.
11. Keltner JL, Thirkill CE, Tyler NK, Roth AM. Management and monitoring of cancer-associated retinopathy. *Arch Ophthalmol* 1992; 110: 48–53.
12. Guy J, Aptsiauri N. Treatment of paraneoplastic visual loss with intravenous immunoglobulin: report of 3 cases. *Arch Ophthalmol* 1999; 117: 471–477.
13. Berson EL, Lessell S. Paraneoplastic night blindness with malignant melanoma. *Am J Ophthalmol* 1988; 106: 307–311.
14. Singh AD, Milam AH, Shields CL et al. Melanoma-associated retinopathy. *Am J Ophthalmol* 1995; 119: 369–370.
15. Weinstein JM, Kelman SE, Bresnick GH, Kornguth SE. Paraneoplastic retinopathy associated with antiretinal bipolar cell antibodies in cutaneous malignant melanoma. *Ophthalmology* 1994; 101: 1236–1243.
16. Milam AH, Saari JC, Jacobson SG et al. Autoantibodies against retinal bipolar cells in cutaneous melanoma-associated retinopathy. *Invest Ophthalmol Vis Sci* 1993; 34: 91–100.
17. Kim RY, Retsas S, Fitzke FW et al. Cutaneous melanoma-associated retinopathy. *Ophthalmology* 1994; 101: 1837–1843.
18. Zacks DN, Pinnolis MK, Berson EL, Gragoudas ES. Melanoma-associated retinopathy and recurrent exudative retinal detachments in a patient with choroidal melanoma. *Am J Ophthalmol* 2001; 132: 578–581.
19. Keltner JL, Thirkill CE, Yip PT. Clinical and immunologic characteristics of melanoma-associated retinopathy syndrome: eleven new cases and a review of 51 previously published cases. *J Neuroophthalmol* 2001; 21: 173–187.
20. Pfohler C, Haus A, Palmowski A et al. Melanoma-associated retinopathy: high frequency of subclinical findings in patients with melanoma. *Br J Dermatol* 2003; 149: 74–78.
21. Borkowski LM, Grover S, Fishman GA, Jampol LM. Retinal findings in melanoma-associated retinopathy. *Am J Ophthalmol* 2001; 132: 273–275.
22. Ripps H, Carr RE, Siegel IM, Greenstein VC. Functional abnormalities in vincristine-induced night blindness. *Invest Ophthalmol Vis Sci* 1984; 25: 787–794.
23. Jacobzone C, Cochard-Marianowski C, Kupfer I et al. Corticosteroid treatment for melanoma-associated retinopathy: effect on visual acuity and electrophysiologic findings. *Arch Dermatol* 2004; 140: 1258–1261.
24. Machemer R. [On the pathogenesis of the flat malignant melanoma]. *Klin Monatsbl Augenheilkd* 1966; 148: 641–652.
25. Barr CC, Zimmerman LE, Curtin VT, Font RL. Bilateral diffuse melanocytic uveal tumors associated with systemic malignant neoplasms. A recently recognized syndrome. *Arch Ophthalmol* 1982; 100: 249–255.
26. O'Neal KD, Butnor KJ, Perkinson KR, Proia AD. Bilateral diffuse uveal melanocytic proliferation associated with pancreatic carcinoma: a case report and literature review of this paraneoplastic syndrome. *Surv Ophthalmol* 2003; 48: 613–625.
27. Singh AD, Rundle PA, Slater DN et al. Uveal and cutaneous involvement in paraneoplastic melanocytic proliferation. *Arch Ophthalmol* 2003; 121: 1637–1640.
28. Gass JD, Gieser RG, Wilkinson CP et al. Bilateral diffuse uveal melanocytic proliferation in patients with occult carcinoma. *Arch Ophthalmol* 1990; 108: 527–533.
29. Ritland JS, Eide N, Tausjo J. Bilateral diffuse uveal melanocytic proliferation and uterine cancer. A case report. *Acta Ophthalmol Scand* 2000; 78: 366–368.
30. Cross SA, Salomao DR, Parisi JE et al. Paraneoplastic autoimmune optic neuritis with retinitis defined by CRMP-5-IgG. *Ann Neurol* 2003; 54: 38–50.
31. Waterston JA, Gilligan BS. Paraneoplastic optic neuritis and external ophthalmoplegia. *Aust NZ J Med* 1986; 16: 703–704.
32. Luiz JE, Lee AG, Keltner JL et al. Paraneoplastic optic neuropathy and autoantibody production in small-cell carcinoma of the lung. *J Neuroophthalmol* 1998; 18: 178–181.
33. de la Sayette V, Bertran F, Honnorat J et al. Paraneoplastic cerebellar syndrome and optic neuritis with anti-CV2 antibodies: clinical response to excision of the primary tumor. *Arch Neurol* 1998; 55: 405–408.
34. Digre KB. Opsoclonus in adults. Report of three cases and review of the literature. *Arch Neurol* 1986; 43: 1165–1175.
35. Pittock SJ, Kryzer TJ, Lennon VA. Paraneoplastic antibodies coexist and predict cancer, not neurological syndrome. *Ann Neurol* 2004; 56: 715–719.
36. Luque FA, Furneaux HM, Ferziger R et al. Anti-Ri: an antibody associated with paraneoplastic opsoclonus and breast cancer. *Ann Neurol* 1991; 29: 241–251.
37. Jongen JL, Moll WJ, Sillevs Smitt PA et al. Anti-Ri positive opsoclonus–myoclonus–ataxia in ovarian duct cancer. *J Neurol* 1998; 245: 691–692.

# Neuro-oculocutaneous syndromes (phakomatoses)

Arun D. Singh, Elias Traboulsi and Lynn Schoenfield

## INTRODUCTION

The term phakomatoses is derived from the Greek word *phakos*, which means ‘birth mark.’ In 1923, Van der Hoeve grouped together von Hippel–Lindau disease, tuberous sclerosis, and neurofibromatosis and called them phakomatoses, because of their presence at birth, autosomal dominant inheritance, and the involvement of multiple systems in all three syndromes.<sup>1</sup> Subsequently encephalofacial angiomatosis (Sturge–Weber syndrome) was added, although there have been no instances of clear-cut inheritance of this condition. Other common features of the phakomatoses include a predominance of neural and ocular involvement, with variable cutaneous and visceral manifestations (Table 64.1). Wyburn-Mason syndrome, retinal cavernous hemangioma, and ataxia–telangiectasia have also been grouped with the phakomatoses and are included in this chapter. Phakomatosis pigmentovascularis and neurocutaneous melanosis are briefly described.

The characteristic systemic manifestations of the phakomatoses are due to the development of hamartomas, which are benign tumors arising from tissues normally present in a specific organ (Box 64.1). Patients who have any of the phakomatosis group of disorders are also predisposed to cancer and have a reduced lifespan. Advances in molecular genetics have led to the identification of genes responsible for von Hippel–Lindau disease, tuberous sclerosis, and neurofibromatosis, and have allowed molecular genetic diagnosis (Table 64.2).

## NEUROFIBROMATOSIS 1 (NF1)

Several distinct forms of neurofibromatosis have now been recognized.<sup>2</sup> The most frequent type is neurofibromatosis type 1 (von Recklinghausen’s disease),<sup>3</sup> followed by neurofibromatosis type 2 (also called central neurofibromatosis). Other rare types include multiple meningiomatosis, spinal schwannomatosis, and segmental neurofibromatosis.<sup>2,4</sup>

**Genetic aspects** NF1 is an autosomal dominant disorder caused by mutations of the *NF1* gene on chromosome 17q11.2.<sup>5</sup> The penetrance of *NF1* mutations is usually complete (100%).<sup>6</sup> About 50% of all index cases are due to new mutations and the majority (90%) of new mutations are paternal in origin.<sup>7</sup> A wide variety of *NF1* mutations have been described without any genotype–phenotype correlation.<sup>8</sup> The large size of the gene makes screening the whole gene for mutations difficult. A combination of techniques, such as heteroduplex analysis, fluorescent in situ hybridization (FISH), and protein truncation assays result in a high mutation detection rate (95%).<sup>9</sup>

**Pathogenesis** The *NF1* gene codes for neurofibromin,<sup>5</sup> a cytoplasmic GTPase-activating protein that negatively regulates the ras oncoprotein.<sup>10</sup> Recent studies have demonstrated that loss of *NF1* function in neurofibromas is limited to Schwann cells, indicating that these are the cells of origin of neurofibromas in *NF1*.<sup>11</sup>

**Clinical features** *NF1* is one of the most common genetic disorders, with protean manifestations involving neural tissues.<sup>2</sup> The disease has a prevalence of about 1/3000, with equal distribution in various ethnic groups.<sup>12</sup> The National Institutes of Health Consensus Development Conference has suggested clinical criteria diagnostic for *NF1* (Table 64.3).<sup>13</sup> Significant ocular findings in *NF1* are summarized in Table 64.4.<sup>14,15</sup>

**Café au lait spots** Large areas of flat cutaneous hyperpigmentation are the most frequent and earliest findings and occur in more than 99% of individuals with *NF1* (Fig. 64.1A). They are present at birth and increase in number and size during childhood. Other forms of hyperpigmentation occur as axillary and intertriginous freckling.

**Neurofibroma** Neurofibroma is the hallmark finding of *NF1*. Neurofibromas tend to be multiple and develop towards the end of the first decade of life. They appear as discrete soft tumors on the face, hands, and trunk (Fig. 64.1B). Based on their appearance and the extent of tissue involvement, neurofibromas can be classified as cutaneous, subcutaneous, nodular plexiform, and diffuse plexiform.

**Lisch nodules** The presence of melanocytic hamartomas on the iris, known eponymously as Lisch nodules, is highly characteristic of *NF1*.<sup>16,17</sup> Lisch nodules are typically multiple, tan-colored, and best detected with the slit lamp on the anterior surface of the iris (Fig. 64.1C). The prevalence gradually increases from birth to about 50% at 5 years, 75% at 15 years, and more than 90% of adults.<sup>14,18</sup>

### Box 64.1 The Characteristic Features of Phakomatoses

- Neuro-oculocutaneous syndrome
- Systemic hamartomatoses
- Familial predisposition to cancer
- Autosomal dominant inheritance (few exceptions)

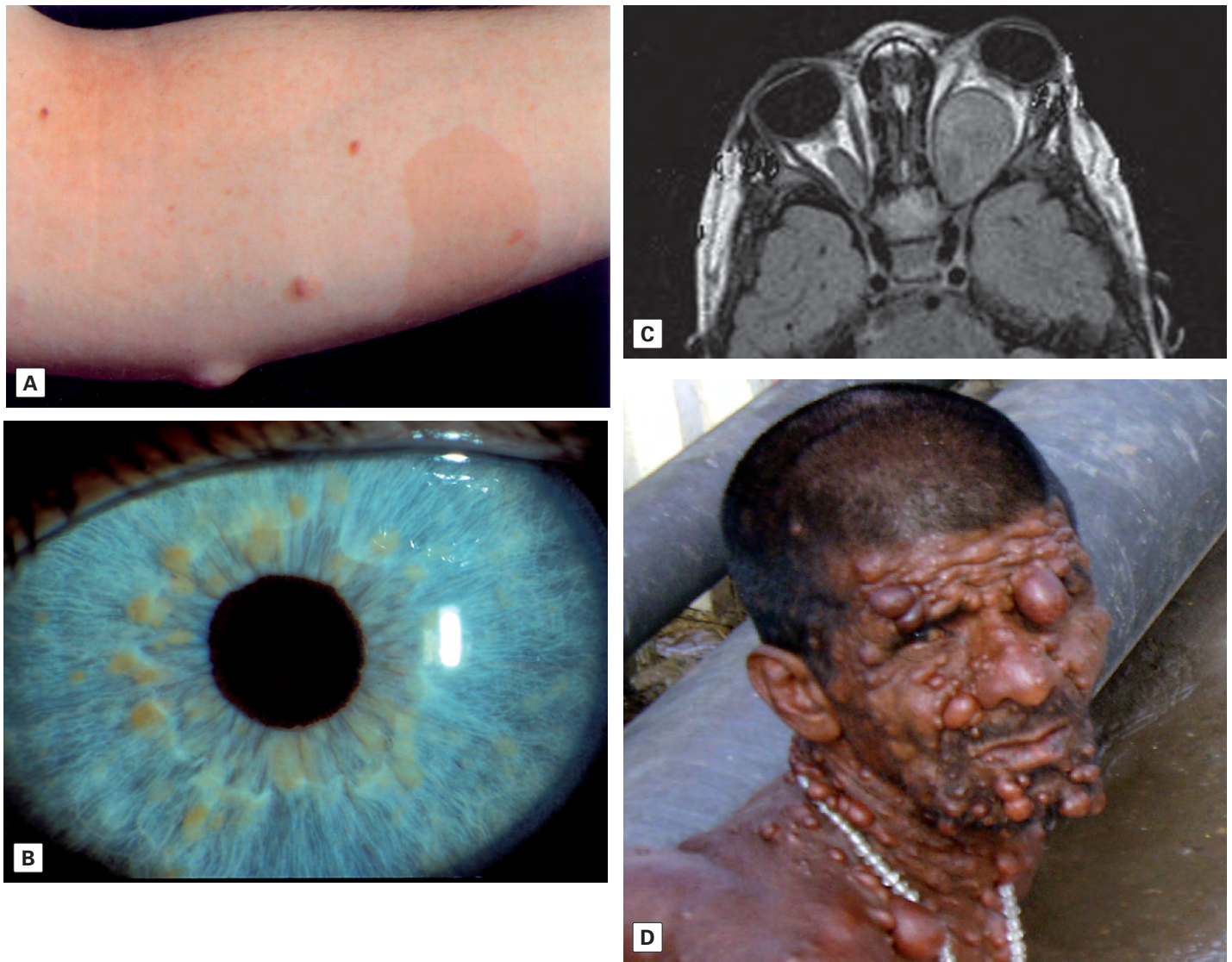
Table 64.1 Organ system involvement in various phakomatoses				
Disorder	Clinical features			
	Neurological	Ocular	Cutaneous	Visceral
Neurofibromatosis 1	Present	Present	Present	Absent
Neurofibromatosis 2	Present	Absent	Absent	Absent
Von Hippel–Lindau disease	Present	Present	Absent	Present
Tuberous sclerosis complex (I)	Present	Present	Present	Present
Tuberous sclerosis complex (II)	Present	Present	Present	Present
Sturge–Weber syndrome	Present	Present	Present	Absent
Wyburn–Mason syndrome	Present	Present	Absent	Absent
Retinal cavernous hemangioma	Present	Present	Absent	Absent
Sebaceous nevus syndrome	Present	Present	Present	Absent
Ataxia–telangiectasia	Present	Present	Present	Present
Neurocutaneous melanosis	Present	Variable	Present	Absent
Phakomatosis pigmentovascularis	Variable	Variable	Present	Absent

Table 64.2 Inheritance pattern of various phakomatoses					
Disorder	Inheritance	Genetic locus	Gene	Protein	Function
Neurofibromatosis 1	Autosomal dominant	17q11	NF1	Neurofibromin	Inhibits <i>ras</i> activity
Neurofibromatosis 2	Autosomal dominant	22q12	NF2	Merlin/ Schwannomin	Links cytoskeletal proteins and cell membrane
Von Hippel–Lindau disease	Autosomal dominant	3p25	VHL	pVHL	Inhibits mRNA elongation
Tuberous sclerosis complex (I)	Autosomal dominant	9q34	TSC1	Hamartin	Regulates vesicular movement
Tuberous sclerosis complex (II)	Autosomal dominant	16p13	TSC2	Tuberin	Inhibits GTP binding proteins
Sturge–Weber syndrome	Sporadic	–	–	–	–
Wyburn–Mason syndrome	Sporadic	–	–	–	–
Retinal cavernous hemangioma	Autosomal dominant	3q, 7p, 7q	–	–	–
Sebaceous nevus syndrome	Sporadic	–	–	–	–
Ataxia–telangiectasia	Autosomal recessive	11q22	ATM	ATM protein	Protein kinase
Neurocutaneous melanosis	Sporadic	–	–	–	–
Phakomatosis pigmentovascularis	Sporadic	–	–	–	–

Table 64.3 Criteria for the clinical diagnosis of NF1	
The presence of any two or more of the following is diagnostic	
Café-au-lait spots (6 or more)	>5mm in diameter in prepubertal individuals >15mm diameter in postpubertal individuals
Neurofibroma	Any type: 2 or more or Plexiform: 1 or more
Axillary and inguinal freckles	
Optic nerve glioma	1 or more
Lisch nodules	2 or more
A distinctive osseous lesion	Sphenoid wing dysplasia or Congenital bowing or thinning of long bone cortex, with or without pseudoarthrosis
First degree relative with NF 1	
National Institute of Health Consensus Development Conference Arch Neurol 1988; 45: 575–578	

Table 64.4 Ophthalmic manifestations of NF1		
Location	Lesion	Frequency (%)
Eyelid	Nodular neurofibroma	18
	Plexiform neurofibroma	5
	Café-au-lait spots	3
Conjunctiva	Neurofibroma	5
Cornea	Prominent corneal nerves	6–22
	Posterior embryotoxon	3–5
Angle	Congenital glaucoma	50
Uvea	Lisch nodules	70–92
	Choroidal hamartoma	51
	Choroidal nevus	3–5
Optic nerve	Pilocytic astrocytoma	2–12
	Optic disc drusen	1
Modified from Lewis RA, Riccardi VM. Von Recklinghausen neurofibromatosis. Incidence of iris hamartomata. Ophthalmology 1981; 88: 348–354		





**Fig. 64.1** Common manifestations of NF1. Café-au-lait spots (A). Multiple Lisch nodules (B). Magnetic resonance image of optic nerve glioma (C). Multiple neurofibromas (D).

*Optic nerve glioma* is a pilocytic hamartoma of the anterior visual pathways. Other more posterior gliomas represent more aggressive variants.<sup>19</sup> Gliomas occur in about 15% of patients with NF1 (Fig. 64.1D).<sup>20</sup> Isolated optic nerve gliomas are usually unilateral, whereas bilateral involvement is believed to be pathognomonic of NF1.<sup>21</sup>

**Diagnostic evaluation** The NIH consensus criteria are useful in establishing the diagnosis of NF1 in adults as well as in young children. MRI is particularly helpful in establishing the diagnosis of optic nerve glioma. Characteristic ‘bright lesions’ on MRI studies are present in about 15% of patients with NF1. The high-signal  $T_2$  lesions are present in the cerebral hemispheres, brain stem, and cerebellum. These lesions evolve over time and occur more commonly in children.<sup>22</sup>

**Treatment** Once the diagnosis of NF1 is made, patients need detailed counseling regarding the prognosis, genetics, and psychological aspects of the disease. First-degree relatives should also be evaluated. Resectable neural tumors should be treated as in the general population. For malignant tumors, excision, chemotherapy, and/or

radiotherapy may be indicated. The management of optic nerve glioma remains controversial. Therapeutic indication and outcomes with various forms of treatment, including observation, chemotherapy, excision, and radiotherapy, are discussed in detail elsewhere (see Chapter 92).

**Prognosis** Some patients with NF1 have mental retardation, learning difficulties, and other behavioral problems.<sup>23</sup> Moreover, the likelihood of additional system manifestations increases with age. Although the majority of tumors in NF1 are benign, their location in the CNS can lead to significant morbidity. The risk of developing malignant tumors, particularly of the peripheral nerve sheath, is about 5%, and there is also an increased risk of early death.<sup>24</sup>

### NEUROFIBROMATOSIS TYPE 2 (NF2)

NF2 is also called ‘central NF’ because the majority of its manifestations are related to central nervous system involvement. Unlike NF1, cutaneous findings are not a predominant feature of NF2. In contrast to neurofibromas, which are hallmarks of NF1, schwannomas are the characteristic tumors of NF2 (Table 64.5).

**Table 64.5** Criteria for the diagnosis of NF2

Presence of any ONE of the following	Features	
Bilateral vestibular schwannoma		
First-degree relative with NF2	PLUS	Unilateral vestibular schwannoma <30 year
First-degree relative with NF 2	PLUS	Any 2 of the following: meningioma, glioma, schwannoma, juvenile posterior subcapsular lenticular opacities/juvenile cortical cataract

National Institute of Health Consensus Development Conference. Neurofibromatosis: Conference Statement. Arch Neurol 1988; 45: 575–578

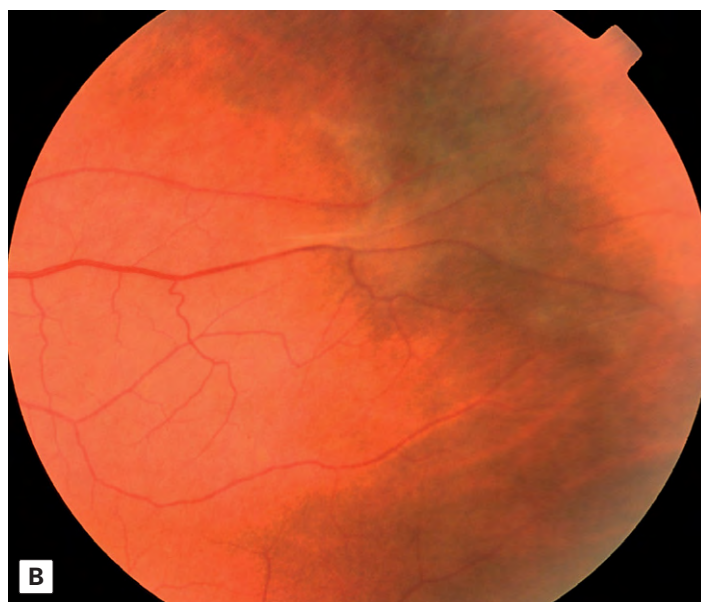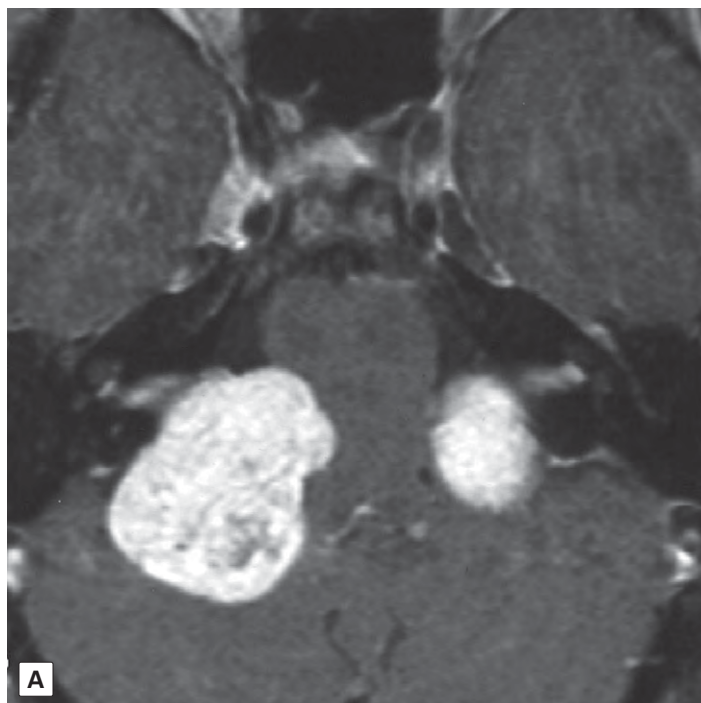
**Genetic aspects** The inheritance pattern is of autosomal dominance with complete penetrance. There is some evidence to suggest that maternally inherited cases have an earlier onset than paternally inherited ones (18 years vs 25 years).<sup>25</sup> About 50% of cases represent new mutations.<sup>25</sup> There is some evidence for genotype–phenotype correlation because patients with truncating NF2 mutations are usually associated with severe phenotypes, whereas those with single codon alterations have mild NF2.<sup>26,27</sup> The NF2 gene was mapped to chromosome 22q12.<sup>28</sup> It encodes a 587 amino acid protein known as merlin or schwannomin.

**Pathogenesis** Disruption of merlin-dependent links of membrane proteins to the cytoskeleton leads to tumor formation.<sup>29</sup>

**Clinical features** The prevalence of NF2 is 1 in 33 000–40 000;<sup>25</sup> 1% of patients with meningioma and 3% of patients with schwannoma have NF2.<sup>30</sup> Bilateral vestibular schwannomas (VS) are diagnostic of NF2 (Fig. 64.2A). Ocular abnormalities are present in more than two-thirds of cases and include cataracts, retinal hamartomas, and ocular motility disorders.<sup>31</sup> The ocular features manifest in childhood and adolescence and are therefore extremely useful in the early diagnosis of NF2.<sup>32</sup>

**Vestibular schwannoma** The mean age at onset is less than 25 years and clinical presentation beyond the age of 55 is unusual. Symptoms are most commonly due to VS rather than to ocular involvement. Deafness with or without tinnitus is most common. Seizures, vertigo, and numbness are less common. Blindness occurs as a presenting symptom in only 1% of cases.<sup>33</sup>

**Ophthalmic findings** The ocular manifestations of NF2 include posterior subcapsular cataracts, combined hamartoma of the retina and RPE, and epiretinal membranes (Box 64.2).<sup>34–36</sup> Combined hamartoma of the sensory retina and retinal pigment epithelium is described as a thickened retina with infoldings of the outer layers, gliosis, and associated disorganized proliferation of blood vessels and retinal pigment epithelium.<sup>37</sup> Children with VS are usually asymptomatic, and ocular findings are therefore of diagnostic significance. In a clinical study of 49 patients with NF2 and their offspring, posterior subcapsular/capsular, cortical, or mixed lens opacities were the most common ocular abnormalities, and were present in 67% of patients (Fig. 64.2B).<sup>32</sup>



**Fig. 64.2** (A) Bilateral vestibular schwannoma on gadolinium-enhanced MRI is diagnostic of NF2. (B) Fundus photograph of a combined hamartoma of the retina and retinal pigment epithelium.

#### Box 64.2 The Ocular Abnormalities in NF2

- Cataracts: posterior subcapsular, capsular, cortical, mixed
- Retinal hamartoma
- Epiretinal membrane
- Ocular motility disorders



Retinal hamartomas are less common than lens opacities and occur in about 20% of cases.<sup>31</sup>

**Diagnostic evaluation** Patients suspected to have NF2 are usually screened by neurologic, ophthalmic, and neuro-otologic testing. Magnetic resonance imaging (contrast-enhanced, multiplanar T<sub>1</sub>-weighted sequences) is a cost-effective first-line investigation in the detection of VS.<sup>38</sup>

**Treatment** The management of VS involves complex decision making and choosing among various options that include observation, stereotactic radiotherapy, and surgical resection.<sup>39</sup>

**Prognosis** The majority (90%) of patients with NF2 present with bilateral VS. The risk of developing a contralateral tumor in the absence of a family history or other features of NF2 in patients with sporadic unilateral VS is low.<sup>40</sup>

## VON HIPPEL–LINDAU DISEASE

Eugen von Hippel, a German ophthalmologist, coined the term angiomatosis retinae in 1904.<sup>41</sup> Arvid Lindau, a Swedish pathologist, established a relationship between cerebellar and retinal hemangioblastomas.<sup>42</sup> It was not until 1964 that Melmon and Rosen established the clinical spectrum of ‘von Hippel–Lindau’ disease (VHL) when they reported cases of ‘von Hippel’s disease’ and ‘Lindau’s disease’ with overlapping manifestations.<sup>43</sup> Since then several investigators have studied the natural history of the disease and developed screening protocols.<sup>44–46</sup>

**Genetic aspects** VHL disease follows an autosomal dominant mode of inheritance with age-dependent penetrance.<sup>44</sup> Following the identification of the VHL gene on chromosome 3p25–26 in 1993, genetic testing with very high detection rates (99%) has become commercially available.<sup>47,48</sup> Because of significant social and ethical issues associated with genetic testing, patients considering such testing for VHL disease should undergo detailed counseling.<sup>49</sup>

**Pathogenesis** The VHL gene encodes a 213 amino acid protein that binds with other proteins called elongin B, elongin C, and Cul 2, and forms a complex that targets hypoxia-inducible factors for degradation.<sup>50</sup> In the absence of pVHL there is excessive production of vascular endothelial growth factor. Using tissue microdissection techniques and PCR, it is now believed that the true neoplastic component (i.e. the cells with allelic deletion at the VHL gene locus) are the foamy stromal cells within the capillary hemangioma.<sup>51</sup>

**Clinical features** The incidence of VHL disease is 1 in 40 000 to 1 in 54 000 live births. It is estimated that there are approximately 7000 patients with the disease in the United States.<sup>52</sup> VHL disease is a multisystem disorder with a predilection for the retina and central nervous system (CNS). Significant clinical manifestations of VHL disease are included in the diagnostic criteria (Table 64.6). Retinal capillary hemangiomas (RCH) occur in less than 75% of cases, CNS hemangiomas in more than 50% of cases, renal carcinomas in less than 50% of cases, and pheochromocytomas in less than 25%.<sup>44</sup> The cumulative probability of manifesting RCH, CNS hemangioma, and renal cell carcinoma increases with age (Fig. 64.3A).<sup>44</sup>

There seems to be a correlation between the clinical features and the type of VHL gene mutation (genotype–phenotype correlation), which has led to a new classification of VHL disease (Table 64.7).<sup>53,54</sup>

**Table 64.6 Diagnostic criteria for VHL disease**

Family history*	Required feature
	<i>Any one of the following</i>
Positive	One or more retinal capillary hemangiomas One or more CNS hemangiomas One or more visceral lesions**
Negative	Two or more retinal capillary hemangiomas Two or more CNS hemangiomas One retinal hemangioma with a visceral lesion One CNS hemangioma with a visceral lesion

\*Family history of retinal hemangioma, CNS hemangioma, or visceral lesion.  
\*\*Visceral lesions include renal cysts, renal carcinoma, pheochromocytoma, pancreatic cysts, islet cell tumors, epididymal cystadenoma, endolymphatic sac tumor, adnexal papillary cystadenoma of probable mesonephric origin.

There does not appear to be a specific type of germline mutation that correlates with presence of RCH.<sup>55</sup>

**Retinal capillary hemangioma (RCH)** is one of the most common manifestations of VHL disease.<sup>56</sup> Therefore, an ophthalmologist is frequently involved in the care of these patients. The clinical features of VHL disease are discussed elsewhere (see Chapter 57). The prevalence of underlying VHL disease in patients with solitary or multiple RCH is reported to be 20–58%.<sup>57</sup> The presence of multiple RCH (two or more), other manifestations of VHL disease, or a positive family history indicate the presence of underlying VHL disease.

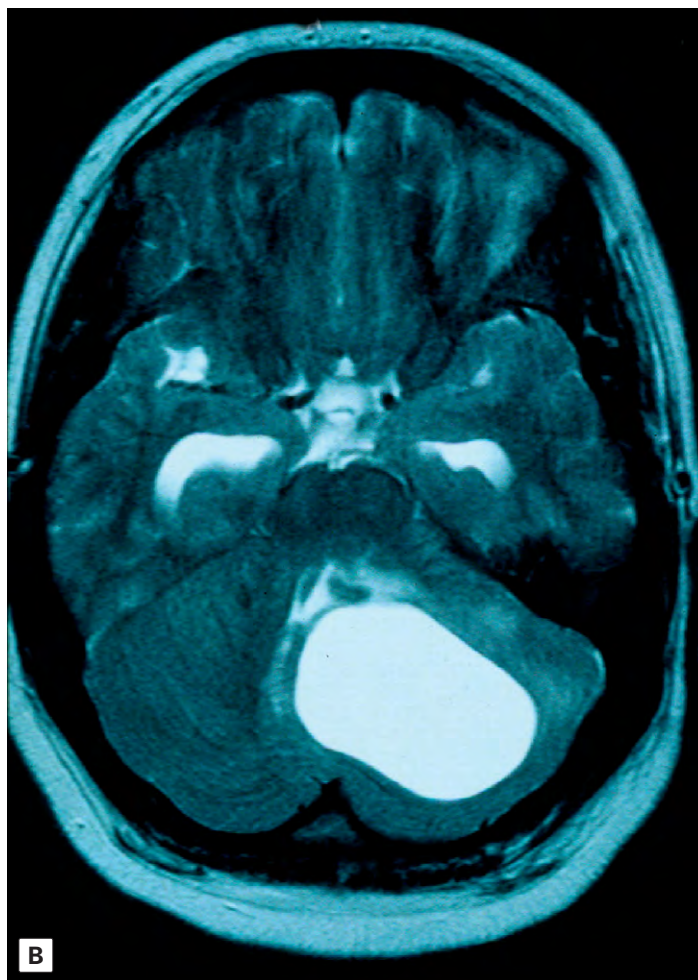
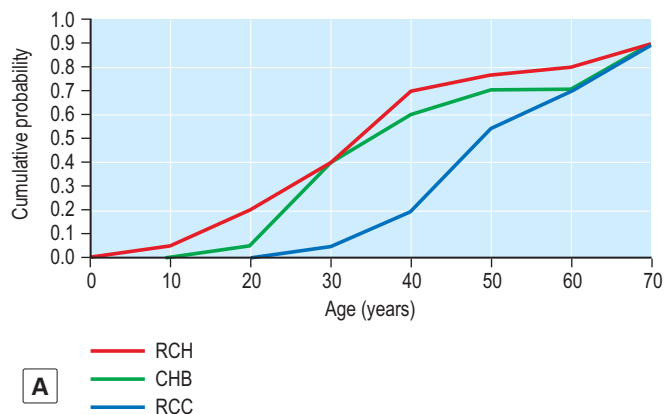
**Central nervous system hemangioma** Commonly involved sites include the cerebellum (75%) and spinal cord (15%).<sup>44</sup> The CNS hemangiomas associated with VHL disease tend to be multiple and occur at a younger age than in sporadic cases. Headache is the most frequent initial symptom of cerebellar hemangioma, and pain is the most common symptom of spinal cord hemangioma (Fig. 64.3B).<sup>58</sup>

**Renal cell carcinoma** is the leading cause of mortality in VHL disease.<sup>44</sup> Renal cell carcinomas in VHL disease are bilateral in 93% of cases; they are multiple, associated with renal cysts, and occur at a younger age (5% by age 30, and more than 40% by age 60) than in sporadic cases.

**Pheochromocytoma** When pheochromocytoma (rare benign tumors of the adrenal medulla) is associated with VHL disease they tend to be multiple and bilateral.<sup>59</sup> The absence (type I) or presence (type II) of pheochromocytoma forms the basis of the National Cancer Institute classification of VHL disease (Table 64.7). Pheochromocytoma produces elevated serum levels of catecholamines (norepinephrine and epinephrine) that lead to symptoms such as palpitations, headaches, and sweating, sometimes simulating anxiety attacks.

**Other cancers** Pancreatic tumors and cystadenoma of the epididymis occur less commonly. Endolymphatic sac tumor, present in 11% of patients, is a recently recognized feature of VHL disease.<sup>60</sup>





**Fig. 64.3** Cumulative probability of developing retinal capillary hemangioma (RCH), cerebellar hemangioma (CHB), and renal cell carcinoma (RCC) in von Hippel-Lindau disease (A). (Adapted from Maher ER, Yates JRW, Harries R et al. Clinical features and natural history of von Hippel-Lindau disease. *QJ Med* 1990; 77: 1151-1163). MRI scan (T<sub>2</sub>-weighted) of a cerebellar hemangioma appearing as a cystic lesion (B).

**Table 64.7 National Cancer Institute classification of VHL disease**

Type	Clinical features				Mutation
	<i>CNS hemangioma</i>	<i>RCH</i>	<i>RCC</i>	<i>Pheochromocytoma</i>	
I	Present	Present	Present	Absent	Deletions Insertion Nonsense
IIA	Present	Present	Absent	Present	Missense
IIB	Present	Present	Present	Present	
IIC	Absent	Absent	Absent	Present	

CNS, central nervous system; RCH, retinal capillary hemangioma; RCC, renal cell carcinoma.

**Diagnostic evaluation** The retinal findings of RCH are usually typical and the diagnosis can usually be made based on ophthalmoscopic examination and fluorescein angiography. Gadolinium-enhanced magnetic resonance imaging is the diagnostic method of choice for CNS hemangioma.<sup>58</sup> Asymptomatic renal, adrenal, and other organ involvement can be detected by enhanced computed tomography<sup>46</sup> and 24-hour urinary biochemical excretion tests. Patients with, or at risk for, VHL disease should be screened as per National Institutes of Health screening protocols (Table 64.8).

**Treatment** The decision to treat RCH and various methods of management are discussed elsewhere (see Chapter 57). Details of treatment of other organ involvement are beyond the scope of this chapter.

**Prognosis** The manifestations and complications of RCH even in adequately treated cases are visually significant. More than 25% of patients with RCH show permanent visual loss (vision <20/40 in one or both eyes).<sup>55</sup> VHL disease is associated with significant morbidity from CNS hemangioma or renal cell carcinoma. In addition, there is

**Table 64.8 National Institutes of Health (USA) screening protocols for patients with VHL disease**

Investigation	Age (years)	Frequency
Urinary catecholamine	From age 2	Every year
Ophthalmoscopy	From age 1	Every year
Enhanced MRI brain and spine	11–60	Every 2 years
	61 and above	Every 3–5 years
Abdominal USG	11–20	Every year
Abdominal CT	From age 21	Every 1–2 years

CT, computed tomography; MRI, magnetic resonance imaging; USG: ultrasonography.

significant mortality from renal cell carcinoma, which is the leading cause of death in VHL disease.<sup>44</sup> The life expectancy of patients with VHL disease may be improved by early detection and treatment of the various tumors using surveillance protocols.<sup>46</sup>

### TUBEROUS SCLEROSIS COMPLEX

The name tuberous sclerosis was suggested by a French physician, Desiré Magloire Bourneville (1840–1909), who dedicated his life to the study of mentally abnormal and epileptic children. In 1880 he described a patient with seizures, hemiplegia, mental subnormality, and renal tumors. He based the term tuberous sclerosis on the neuropathologic observations of multiple potato-like (tubers) lesions in the brain.<sup>61</sup>

**Genetic aspects** Tuberous sclerosis complex (TSC) includes two genetic diseases (TSC1 and TSC2) with autosomal dominant inheritance and high penetrance (95%).<sup>62</sup> Two-thirds of cases are sporadic and are thought to represent new mutations. The genes responsible for TSC, TSC1 (chromosome 9q34)<sup>63</sup> and TSC2,<sup>64</sup> have now been identified. The mutation detection rate is about 80% using a combination of molecular genetic techniques.<sup>65</sup>

**Pathogenesis** Tuberous sclerosis is associated with mutations in the TSC1 and TSC2 genes, which respectively encode hamartin and tuberin. Hamartin and tuberin interact with each other and influence a common cellular pathway.<sup>66</sup> These findings provide the basis for identical clinicopathologic manifestations of TSC1 and TSC2 that result when either of these proteins is inactivated.

**Clinical features** The incidence of TSC is 1 in 10 000.<sup>62</sup> What may appear to be a higher incidence in recent years is due to the diagnosis of patients having milder phenotypes with the advent of sophisticated imaging techniques.<sup>67</sup> Tuberous sclerosis is characterized by hamartomas in various organs. The hamartomas in the brain (astrocytoma and ependymoma) lead to childhood seizures and mental retardation. The skin manifestations (facial angiofibromas, subungual fibromas, hypomelanotic macules, and shagreen patches) are mainly of diagnostic significance. The ocular involvement is limited to the retina. Visceral hamartomas most commonly involve the lungs, kidney, and heart.<sup>62</sup> The classic triad of epilepsy, mental retardation, and adenoma sebaceum is present in only one-third of cases.<sup>68</sup>

In general, the clinical manifestations of TSC1 and TSC2 are similar except that TSC1 represents a milder phenotype with a reduced risk of mental retardation compared to TSC2.<sup>69</sup> Other findings of TSC1, such as seizures, renal involvement, facial angiofibroma, and retinal hamartomas, are also less frequent or less severe than in TSC2.<sup>70</sup>

**Retinal astrocytic hamartoma** Approximately one-third to one-half of patients with TSC have retinal or optic nerve hamartomas, which occur bilaterally in half of these patients.<sup>71</sup> Clinical features of retinal astrocytic hamartoma are discussed in detail elsewhere (see Chapter 59).

**Brain and neurologic manifestations** Epilepsy, mental retardation, and behavioral problems are the most significant clinical manifestations that cause most of the morbidity associated with TSC. As is evident from the revised diagnostic criteria, neurologic manifestations are not necessary for a diagnosis. Epilepsy may present as infantile spasms. About 50% of TSC patients are mildly to profoundly mentally retarded. The severity of neurologic disease directly correlates with the extent and number of cortical tubers detected on MRI (Fig. 64.4A).<sup>72</sup>

**Skin manifestations** of TSC are mainly of diagnostic significance (Fig. 64.6C). The hypomelanotic macules are the most frequent and the earliest finding of TSC and occur in up to 97% of children (Fig. 64.4B).<sup>73</sup> They are best visualized with Wood's lamp (UV light). Fibrous plaque appears as reddish-orange patches on the forehead. Facial angiofibromas are not present at birth and appear usually by age 5. Subungual fibromas appear later in life.<sup>74</sup>

**Visceral manifestations** of TSC include pulmonary lymphangiomyomatosis,<sup>74</sup> renal angiomyolipoma,<sup>75</sup> and cardiac rhabdomyoma (Fig. 64.4C).<sup>76</sup>

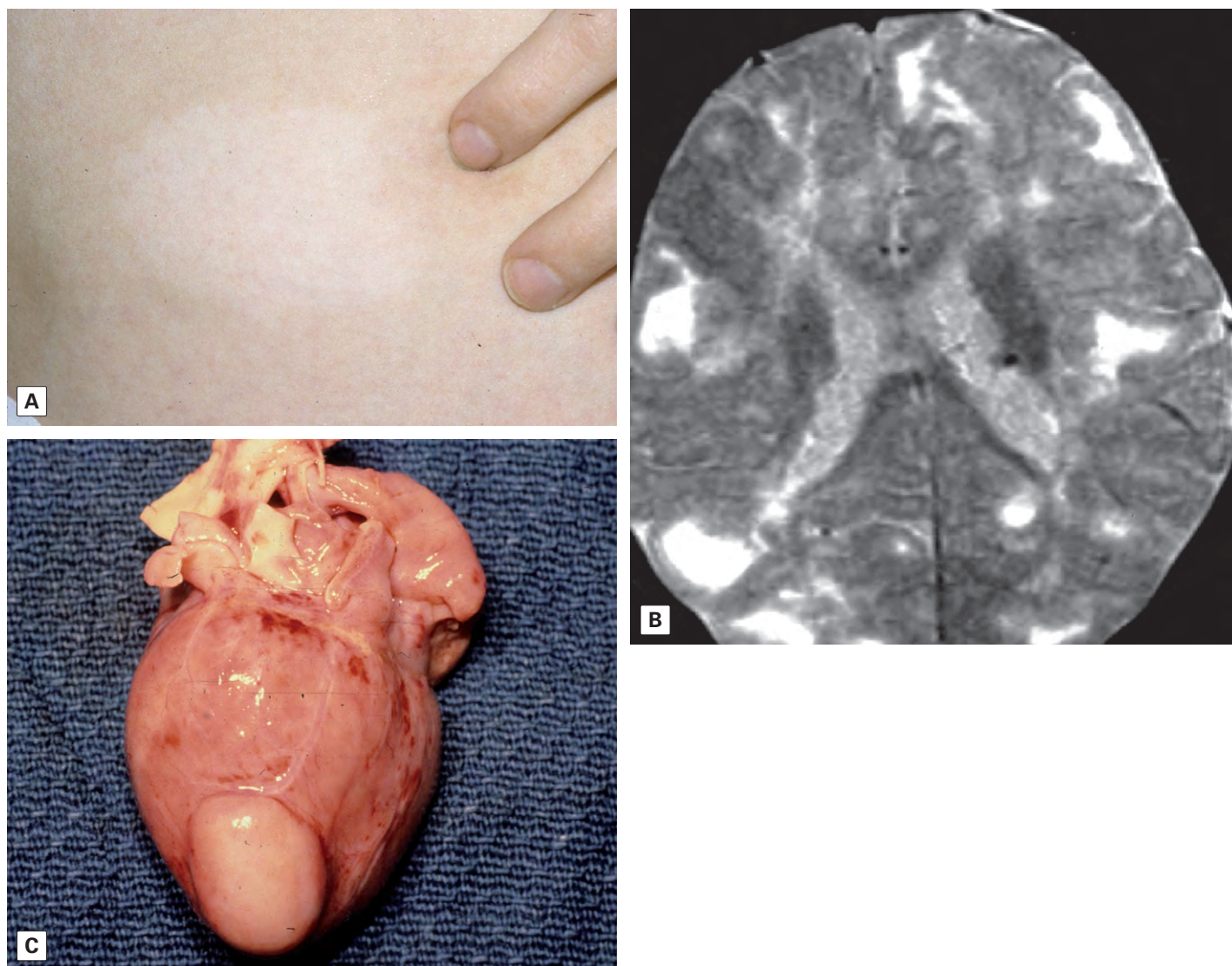
**Diagnostic evaluation** The diagnosis of TSC is essentially clinical, based on diagnostic criteria (Table 64.9).<sup>77</sup> Imaging studies such as MRI of the brain and CT scans of the abdomen are important to detect CNS and visceral involvement.<sup>78</sup>

**Treatment** of TSC depends on the location and the extent of organ involvement. Retinal astrocytic hamartomas usually need only periodic evaluation by ophthalmoscopy and fundus photography.

**Prognosis** Retinal astrocytic hamartomas are generally stable, with slow growth over several years or new calcification in some cases.<sup>71</sup> TSC leads to significant morbidity, mainly due to neurological and visceral involvement. The majority (85%) of patients with TSC-related mental retardation require supervision for daily living. In general, patients with TSC have reduced survival compared to the general population. The common causes of mortality are renal disease, brain tumors, and status epilepticus. Patients with TSC need lifelong follow-up for the early detection of potentially life-threatening complications.<sup>78</sup>

### STURGE-WEBER SYNDROME

In 1879, Sturge described a syndrome characterized by a facial hemangioma, ipsilateral buphthalmos, and contralateral seizures.<sup>79</sup> In 1922 Weber described radiological evidence of cortical calcification second-



**Fig. 64.4** Common manifestations of TSC. The hypomelanotic macules ('ash-leaf' sign) (A). Subcortical tubers on T<sub>2</sub>-weighted axial MR image of the brain appear as multiple subcortical high signal intensity areas (B). Cardiac rhabdomyoma (C). (Reproduced with permission from Seki I, Singh AD, Longo S. Pathological case of the month: congenital cardiac rhabdomyoma. *Arch Pediatr Adolesc Med* 1996; 150: 877–888.)

ary to leptomenigeal hemangioma causing hemiplegia.<sup>80</sup> As both descriptions applied to the same entity, the triad of leptomenigeal hemangioma, choroidal hemangioma, and cutaneous hemangioma has been called Sturge–Weber syndrome (SWS). In the absence of CNS involvement patients should only be given a diagnosis of port-wine stain or facial angioma to avoid the stigmata associated with a diagnosis of Sturges–Weber syndrome.

**Genetic aspects** Unlike other phakomatoses, Sturge–Weber syndrome is not inherited.

**Pathogenesis** The predominant manifestation is a diffuse hemangioma in the leptomeninges, choroid, and facial skin. The other term for this disorder, encephalofacial hemangiomatosis, emphasizes only the non-ocular manifestations.

**Clinical features** Infantile glaucoma and diffuse choroidal hemangioma may be associated with some visual loss. Sturge–Weber syndrome, with its neural involvement, leads to intractable seizures, developmental delay, and behavioral problems (Table 64.10). The cutaneous manifestations of nevus flammeus, although most evident, are mainly of diagnostic significance.

**Glaucoma** is the most frequent manifestation of SWS and occurs in about 70% of cases.<sup>81</sup> Various pathogenetic mechanisms, such as angle maldevelopment or raised episcleral venous pressure, can lead to glaucoma,<sup>82</sup> which is usually diagnosed within the first 2 years of life. The incidence is higher if the eyelids are involved with nevus flammeus.<sup>83</sup>

**Diffuse choroidal hemangioma** About half the patients with SWS have a diffuse choroidal hemangioma.<sup>81</sup> This is usually unilateral



Table 64.9 Revised diagnostic criteria for tuberous sclerosis complex	
Definite diagnosis	Two major features
Probable diagnosis	One major feature plus two minor features
Possible diagnosis	One major feature plus one minor feature
	One major feature
	Two minor features
Major features	Minor features
Facial angiofibroma or forehead plaque	Multiple dental enamel pits
Ungual/periungual fibroma	Hamartomatous rectal polyps
Hypomelanotic macules (3 or more)	Bone cysts
Shagreen patch	Cerebral white matter migration lines
Multiple retinal hamartomas	Gingival fibromas
Cortical tuber	Nonrenal hamartoma
Subependymal nodule	Retinal achromic patch
Subependymal giant cell astrocytoma	'Confetti' skin lesions
Cardiac rhabdomyoma (1 or more)	Multiple renal cysts
Lymphangiomyomatosis	
Renal angiomyolipoma	
(Roach ES, Gomez MR, Northrup H. Tuberous Sclerosis Complex Consensus Conference: revised clinical diagnostic criteria. J Child Neurol 1998; 13: 624-628)	

Table 64.10 Sturge-Weber syndrome	
Organ system	Clinical features
Central nervous system	Leptomeningeal angiomatosis* Cortical atrophy Seizures Developmental delay Behavioral problems
Eye and adnexa	Nevus flammeus Prominent episcleral vessels Glaucoma Diffuse choroidal hemangioma*
Cutaneous	Nevus flammeus*
*Any two of three features essential for diagnosis.	

and ipsilateral to the nevus flammeus. The clinical features of choroidal hemangioma are discussed in detail elsewhere (see Chapter 49).

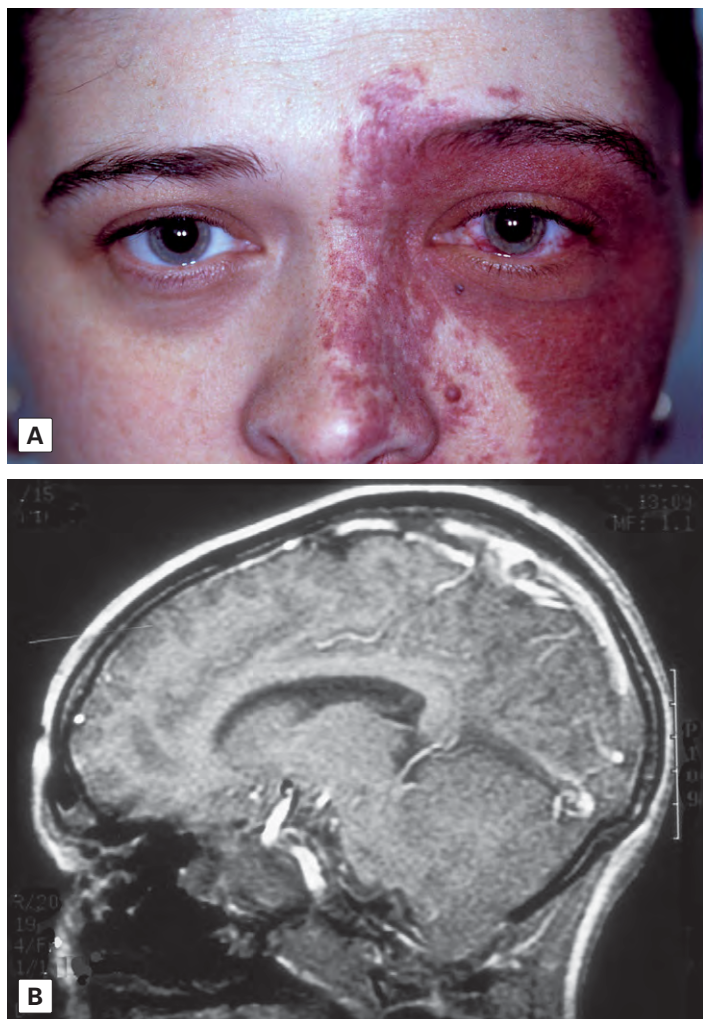
**Leptomeningeal hemangiomatosis** Leptomeningeal hemangiomatosis is ipsilateral to the cutaneous involvement. This can lead to a seizure disorder owing to the effects on underlying cerebral cortex. Seizures are present in about 80% of patients with SWS, with onset during the first year of life.<sup>84</sup> There is a correlation between early onset of seizures and the likelihood of developmental delay and behavioral problems.<sup>85</sup>

**Nevus flammeus** The cutaneous hemangioma is also called nevus flammeus or port-wine stain (Fig. 64.5A). In general, only about 10% of all nevus flammeus cases are associated with SWS.<sup>86</sup> SWS only occurs in patients who have involvement in the region of V1 or V2 distribution of the trigeminal nerve.<sup>86</sup> Bilateral port-wine stains have a higher likelihood of being associated with SWS than unilateral lesions. Conversely, leptomeningeal and ocular involvement in SWS is always associated with port-wine stain involving the eyelids, the upper more often than the lower.<sup>86</sup>

**Diagnostic evaluation** Contrast-enhanced MRI is most suited for detecting cerebral atrophy and leptomeningeal angiomatous malformations (Fig. 64.5B).<sup>87</sup> If the MRI is normal, CT scanning should be used to detect intracranial calcifications.

**Treatment** Medical therapy of glaucoma is effective in some cases,<sup>83</sup> but the majority eventually require multiple trabeculectomies, combined trabeculectomy with trabeculectomy,<sup>88</sup> or even drainage implants.<sup>89</sup> The choroidal hemangioma can be treated with low-dose standard radiotherapy or proton beam radiotherapy.<sup>90,91</sup> The treatment of choroidal hemangioma is discussed in detail elsewhere (see Chapter 49). The seizures are generally controlled with medication, but intractable cases require surgical resection of the leptomeningeal angiomatosis and underlying cerebral cortex.<sup>92</sup>

**Prognosis** Only limited information is available about the long-term prognosis of patients with SWS. Mental retardation, behavioral and social problems are more common in older children. Overall, about 40% of patients with SWS are self-sufficient and about 50% get married.<sup>84</sup>



**Fig. 64.5** (A) Typical facial distribution of cutaneous hemangioma. (B) Leptomeningeal hemangioma in Sturge–Weber syndrome.

### WYBURN-MASON SYNDROME

In 1943 Wyburn–Mason described several cases of racemose hemangiomas of the retina and brain and established an association between these malformations.<sup>93</sup> Some authors refer to this entity as Bonnet–Dechaumme–Blanc syndrome.<sup>94</sup> Unlike other phakomatoses, there is no cutaneous involvement in Wyburn–Mason syndrome.

**Genetic aspects** Wyburn–Mason syndrome is a non-hereditary sporadic disorder.

**Pathogenesis** The pathogenesis of the vascular abnormalities in Wyburn–Mason syndrome is not understood.

**Clinical features** The clinical findings are usually congenital in origin but the diagnosis is usually made later in childhood, as there are no prominent external features (Table 64.11). A review of published cases indicates that the incidence of intracranial arteriovenous malformations in patients with retinal arteriovenous malformations is 30%.<sup>95</sup> Conversely, only about 8% of cases with intracranial arteriovenous malformations have retinal arteriovenous malformations.<sup>95</sup>

**Retinal arteriovenous malformation** The ophthalmoscopic appearance of the retinal arteriovenous malformation is striking, with

**Table 64.11** Wyburn–Mason syndrome

Organ system	Clinical features
Central nervous system	Racemose hemangioma
Retina	Racemose hemangioma
Orbit	Racemose hemangioma

dilated and tortuous retinal vessels extending from the optic disc to the retinal periphery. Similar arteriovenous malformations within the orbit, with or without retinal changes in the setting of WMS, have also been reported.<sup>96</sup> The clinical features of retinal arteriovenous malformations are described in detail elsewhere (see Chapter 57).

**Intracranial arteriovenous malformation** in the chiasmal region can lead to neuro-ophthalmic manifestations.<sup>97</sup> Patients present in their second or third decade with signs and symptoms of acute cerebral or subarachnoid hemorrhage, such as severe headache, nuchal rigidity, and loss of consciousness.

**Diagnostic evaluation** The diagnosis of retinal arteriovenous malformation is essentially clinical, but fluorescein angiographic studies can be utilized to document the vascular pattern. The intracranial arteriovenous malformation is best detected by MRI or arteriography (Fig. 64.6).

**Treatment** The retinal vascular malformations are usually not amenable to therapy. Unlike the intracranial arteriovenous malformations, which have a tendency to bleed, the retinal arteriovenous malformation does not bleed. If neovascular glaucoma occurs, symptomatic treatment can be offered. Because of their location in the midbrain, intracranial arteriovenous malformations are usually inoperable. Embolization may be effective in some cases.

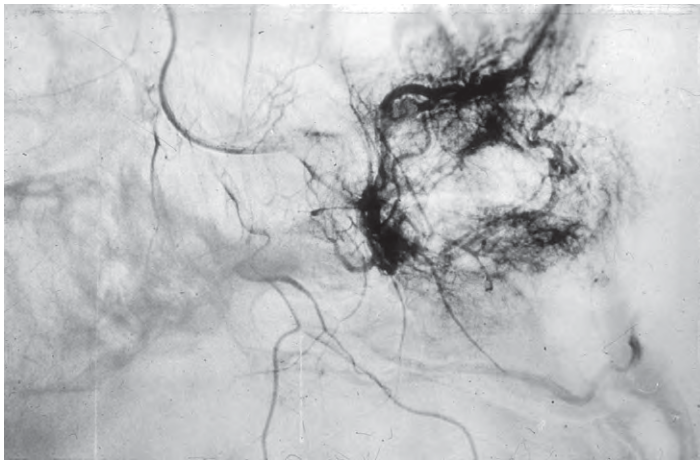
**Prognosis** The retinal vascular anomalies may sometimes lead to vascular occlusions<sup>98</sup> and retinal ischemia, with the development of neovascular glaucoma.<sup>99</sup> Hemorrhages from midbrain hemangiomas can be fatal.

### RETINAL CAVERNOUS HEMANGIOMA

Retinal cavernous hemangioma is a rare benign vascular tumor. Clinically, two forms are recognized: sporadic and syndromic.<sup>100</sup> Retinal cavernous hemangiomas can be associated with cerebral cavernous malformations as an autosomal dominant syndrome with high penetrance and variable expressivity.<sup>101,102</sup> It has been suggested that the cerebral cavernous malformation syndromes should be included with the neuro-oculocutaneous (phakomatoses) syndromes, but the association of cerebral and cutaneous hemangiomas is inconsistent.<sup>100</sup>

**Genetic aspects** Familial cavernous hemangioma has been linked to three loci on chromosomes 3q, 7p, and 7q.<sup>103,104</sup>

**Pathogenesis** Cavernous hemangiomas are considered to be congenital hamartomas composed of dilated multiple thin-walled dilated vascular channels and surface gliosis.<sup>100</sup> The walls are lined with normal-appearing endothelium, which explains the lack of exudation.<sup>105</sup>



**Fig. 64.6** The intracranial arteriovenous malformation seen on arteriography.

**Clinical features** All patients diagnosed with a retinal cavernous hemangioma should undergo detailed neuroimaging studies even if they are asymptomatic because of their possible association with cerebral hemangioma.<sup>106</sup> The diagnosis of familial cerebral cavernous malformations requires histopathologic or imaging documentation of cavernous hemangiomas in at least two family members.

**Retinal cavernous hemangioma** Retinal lesions appear as grape-like clusters of blood-filled saccular spaces. The clinical features are described in detail in Chapter 57.

**Central nervous system cavernous hemangioma** may involve any part of the central nervous system, but supratentorial regions are more frequently involved than infratentorial ones.<sup>107</sup> The tumors can occasionally involve the spinal cord. Seizures, hemorrhage, or progressive focal neurologic deficits are common manifestations.

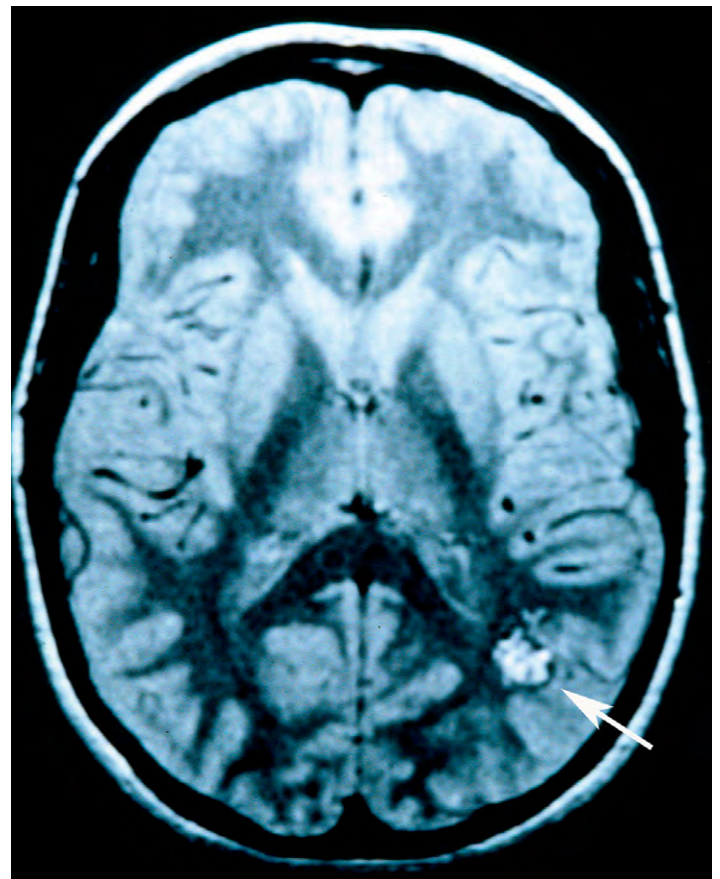
**Diagnostic evaluation** The ophthalmoscopic features and fluorescein angiographic findings of retinal cavernous hemangioma are characteristic (see Chapter 57). Cavernous hemangiomas of the CNS are best visualized by MRI, which shows a central enhancing core and a dark ring from previous hemorrhages (Fig. 64.7). Because these lesions are venous in origin, they not readily detected by angiography.

**Treatment** No effective treatment is known, although laser photocoagulation has been attempted in a few cases.<sup>100</sup> Intracranial cavernous hemangioma can be treated by observation, surgical excision, or gamma-knife radiosurgery depending on location and other considerations.<sup>108</sup>

**Prognosis** In general, retinal cavernous hemangiomas are non-progressive. Spontaneous thrombosis and vitreous hemorrhage are rare complications.<sup>100</sup> Cavernous hemangiomas of the CNS carry an annual risk of 0.25–5% for a clinically significant hemorrhage.<sup>108</sup>

## NEVUS SEBACEUS SYNDROME

Nevus sebaceus syndrome (of Jadassohn),<sup>109</sup> also known as Chimmelpenning–Feuerstein–Mims syndrome,<sup>110,111</sup> is a distinct clinical



**Fig. 64.7** Cortical cavernous hemangioma of the CNS appears on MRI as a central enhancing core surrounded by a dark ring from previous hemorrhages (arrow).

disorder within the spectrum of epidermal nevus syndrome (of Solomon)<sup>112</sup> characterized by cutaneous sebaceous nevus and extracutaneous manifestations.<sup>113</sup>

**Genetic aspects** Nevus sebaceus syndrome is a sporadic disease.



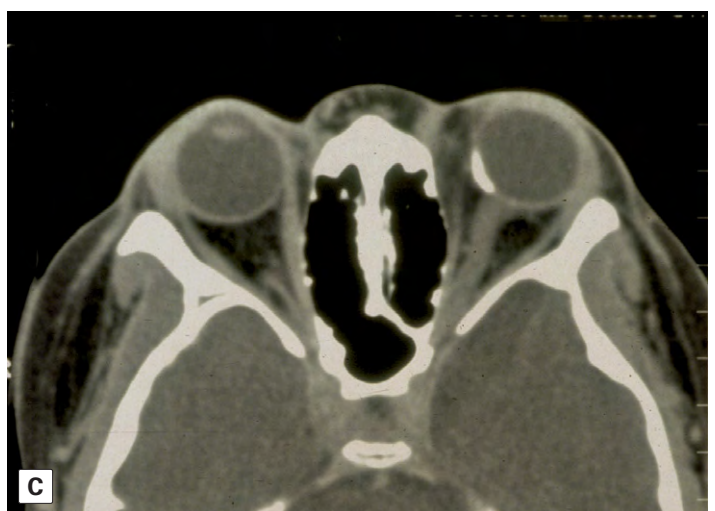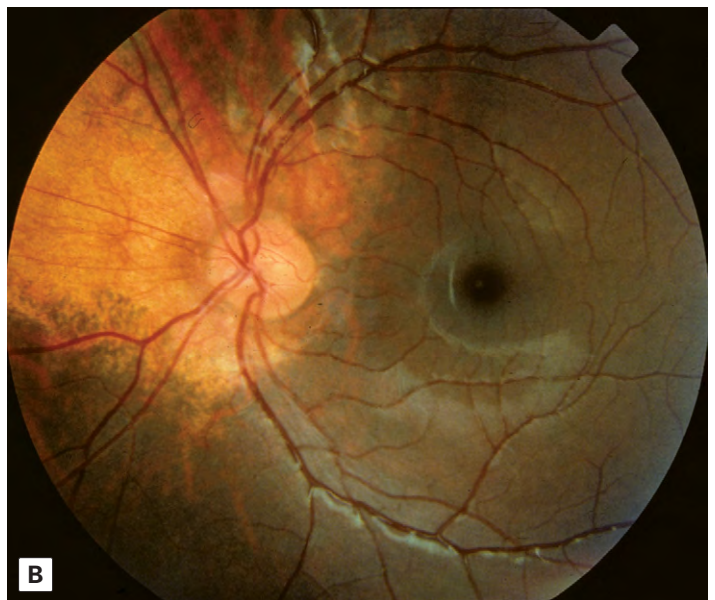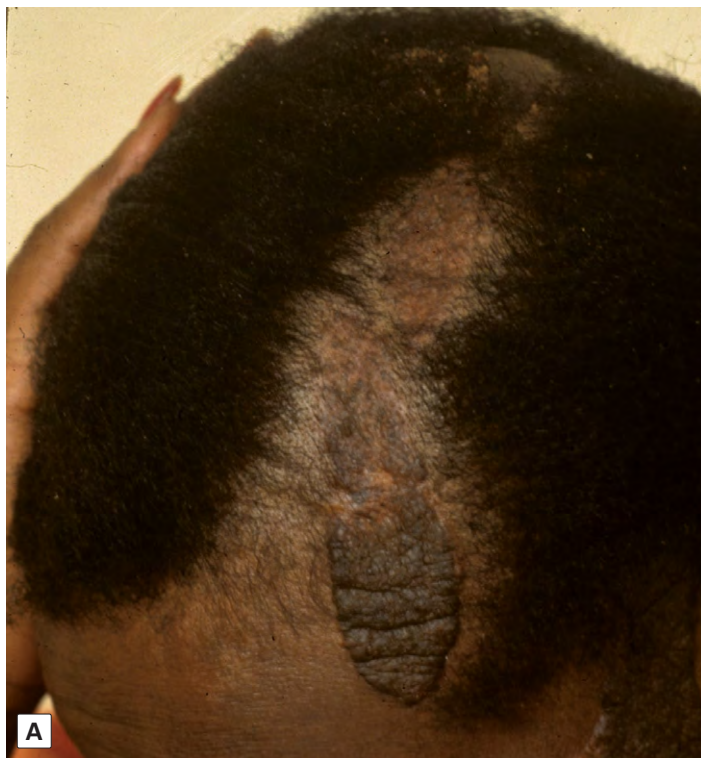**Pathogenesis** The term sebaceous nevus is used to emphasize the epidermal and adnexal composition (sebaceous glands, sweat glands, and hair follicles) of cutaneous hamartomas (organoid nevus) and to differentiate them from typical melanocytic nevi.<sup>114,115</sup>

**Clinical features** In addition to prominent cutaneous involvement, neural and ocular manifestations are common in nevus sebaceus syndrome (Table 64.12).

**Cutaneous** lesions are most commonly found on the head and neck region and appear as irregular linear lesions with alopecia (Fig. 64.8A). Three stages of age-dependent evolution of the organoid nevus have been described.<sup>116</sup> During infancy the skin appears atrophic due to underdevelopment of sebaceous glands. During the second stage, observed during puberty, there is overdevelopment of sebaceous glands, which appear clinically as hypertrophic and papillomatous. In

**Table 64.12 Sebaceous nevus syndrome**

Organ	Feature
Neural	Seizures, mental retardation, structural brain defects
Ocular	Conjunctiva/corneal/episclera choristoma Lid coloboma Chorioretinal coloboma Optic nerve coloboma, pit, hypoplasia Intrascleral cartilage/bone
Cutaneous	Midline linear nevus, alopecia, sebaceous lobules, basal/squamous cell carcinoma



**Fig. 64.8** Characteristic manifestations of sebaceous nevus syndrome. Facial and scalp involvement with sebaceous nevus (A). Yellowish-orange scleral choristoma of the superonasal quadrant (B). CT scan of bone density shows a nasal plaque-like lesion in the left globe (C). (Reproduced with permission from Traboulsi EI, Zin A, Massicotte SJ et al. Posterior scleral choristoma in the organoid nevus syndrome (linear nevus sebaceus of Jadassohn). *Ophthalmology* 1999; 106: 2126–2130.)

adulthood, there is tendency to form benign and malignant skin tumors such as sebaceous adenoma and basal cell carcinoma within the area of the organoid nevus.<sup>117</sup>

**Ophthalmic** involvement is observed in about 40% of cases, with epibulbar choristomas and coloboma being the most common.<sup>118</sup> The limbal choristomas can be simple or complex, and are usually dermoid or lipodermoid in nature (Fig. 64.8B).<sup>119,120</sup> Ophthalmoscopic examination can reveal coloboma, disc anomalies, or features suggestive of intrascleral cartilage (Fig. 64.8C).<sup>121</sup> Intrascleral calcification due to ossification of cartilage can also be observed.<sup>121,122</sup> Several other less frequent ophthalmic anomalies observed as part of nevus sebaceus syndrome have also been reported.<sup>121,122</sup>

**Neurological** Mental retardation and seizures are the most frequent neurological manifestations of nevus sebaceus syndrome.

**Other manifestations** Skeletal abnormalities, cardiovascular defects, and genitourinary defects are occasionally observed, indicating the multisystem nature of nevus sebaceus syndrome.<sup>113</sup>

**Diagnostic evaluation** The diagnosis is based essentially on clinical findings supported by appropriate imaging studies, such as MRI of the brain. Ophthalmic manifestations of intrascleral cartilage/ossification can be demonstrated by ultrasonography or CT. Cutaneous biopsy may prove the organoid nature of the nevus with the presence of adnexal components. Other diagnostic studies should be ordered based on suspicion of specific organ involvement.

**Treatment** Eyelid and episcleral choristomas can be excised and attempts to maximize vision may include corneal grafting, refraction, and amblyopia management.<sup>123</sup> The organoid nevus should be removed for cosmetic correction and to prevent the risk of malignant transformation observed in later stages of life.<sup>124</sup>

**Prognosis** The visual prognosis is usually guarded in the presence of limbal choristoma, chorioretinal coloboma, and optic disc anomalies. Morbidity associated with nevus sebaceus syndrome is due to neurological manifestations of mental retardation and seizure. The risk of malignant transformation of the organoid nevus is about 20% in the long term.<sup>117</sup>

**ATAXIA–TELANGIECTASIA**

In 1941 Madame Louis-Bar described a young boy with progressive cerebellar ataxia and oculocutaneous telangiectasia.<sup>125</sup> The term ataxia telangiectasia was proposed by Boder and Sedgwick in 1958, when they described seven cases of familial progressive cerebellar ataxia with oculocutaneous telangiectasia and sinopulmonary infections.<sup>126</sup> Other features such as lymphoreticular malignancy and immune dysfunction were not reported until later.<sup>127</sup>

**Genetic aspects** Ataxia telangiectasia (AT) follows an autosomal recessive pattern of inheritance. A gene that causes AT was identified on chromosome 11q22–23.<sup>128</sup>

**Pathogenesis** A region of the ATM gene that is homologous to phosphoinositid-3 kinases mediates cell growth signals. A second region homologous to RAD3 and MEC1 regulates the cell cycle, explaining the diverse manifestations of AT.<sup>129</sup>

**Clinical features** The incidence of AT is about 3 per million live births. The minimum frequency of AT gene mutations in the US white population is estimated to be 0.0017.<sup>130</sup> Although AT is included by some within the phakomatoses, it has only a limited similarity to other disorders in this group because it lacks dominant inheritance and a tendency for systemic hamartomatosis.

Ataxia telangiectasia is a childhood neurodegenerative disorder with neural, ocular, and cutaneous manifestations associated with immune dysfunction. In addition to some of the features outlined below, premature aging, chromosomal instability, and hypersensitivity to ionizing radiation are also important aspects of this disorder (Table 64.13).<sup>131</sup>

**Cerebellar ataxia** Progressive cerebellar ataxia in early childhood is the hallmark of AT and is present in all cases.<sup>132</sup> The majority of patients present with truncal ataxia by age 2, and almost all develop this neurologic sign before the age of 6. Other associated neurologic findings include chorea–athetosis, dysarthria, facial hypotonia, and ocular motility disorders. The combination of oculomotor apraxia with cerebellar ocular motor abnormalities is highly suggestive of AT.<sup>133</sup>

**Telangiectasia** have a later onset than ataxia, and usually develop by age 6 years; they may be absent in some cases. The telangiectasia involves the bulbar conjunctiva and the skin of the arms, neck, and shoulder regions.

**Other manifestations** Other significant manifestations of AT are dysplasia of the thymus gland, recurrent pulmonary infections, susceptibility to neoplasia, endocrine abnormalities, and progeric changes.<sup>134</sup> Lymphoma or leukemia develop in early adulthood in about 15% of cases, representing a 1000-fold greater incidence than in the general population.<sup>135</sup>

**Diagnostic evaluation** The diagnosis of AT is essentially based on clinical findings. The laboratory markers include elevated serum  $\alpha$ -fetoprotein after 2 years of age, elevated plasma carcinoembryonic antigen, and low serum antibody levels (IgA, IgG-2, and IgE). In vitro studies on lymphocytes show spontaneous chromosome breaks and rearrangements; and cultured fibroblasts show increased sensitivity to ionizing radiation. It is now possible to identify disease-causing mutations in more than 80% of patients with AT.<sup>136</sup>

Clinical features	Laboratory features
Progressive cerebellar ataxia	Elevated serum $\alpha$ -fetoprotein after 2 years of age
Oculocutaneous telangiectasia	Elevated plasma carcinoembryonic antigen
Hypotonic facies	Low serum antibody levels (IgA, IgG-2, IgE)
Oculomotor apraxia	Spontaneous chromosome breaks and rearrangements (in vitro studies)
Dysplasia of the thymus gland	Increased sensitivity to ionizing radiation
Recurrent pulmonary infections	
Susceptibility to neoplasia	
Endocrine abnormalities	
Progeric changes	

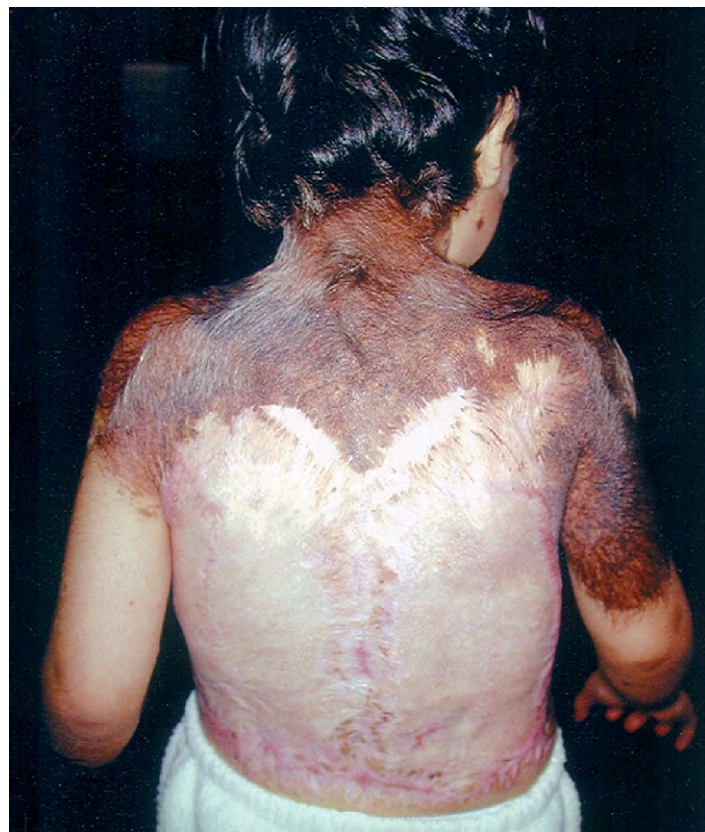

**Treatment** AT patients are susceptible to recurrent sinopulmonary infections because of immune dysfunction, for which they need appropriate long-term care. AT-associated malignancies such as lymphoma and leukemia require modified chemotherapy and radiotherapy dosages because of hypersensitivity to radiation- and chemotherapy-induced DNA damage.<sup>134,137</sup>

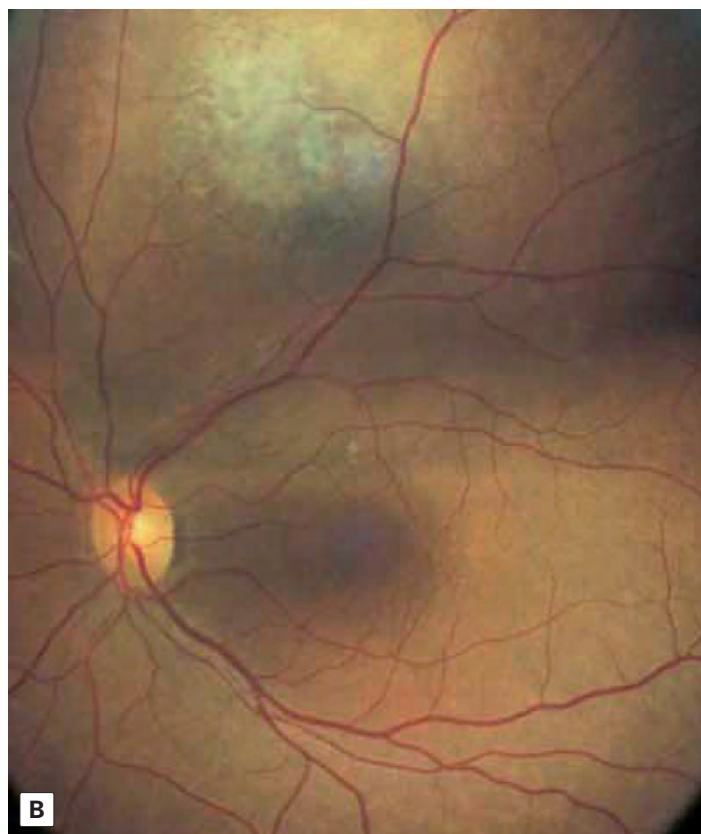
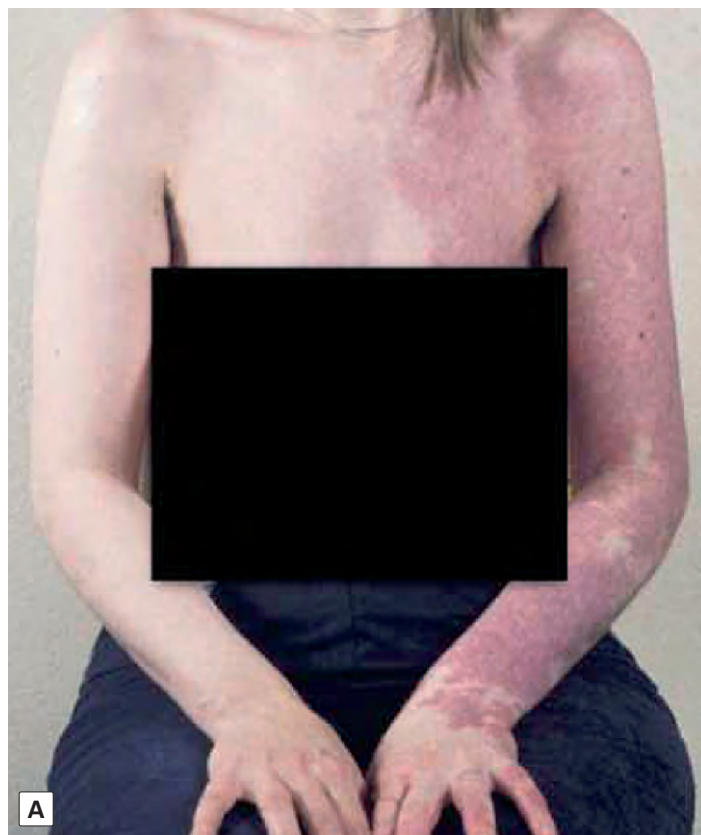**Prognosis** AT is a progressive disease with a poor prognosis.<sup>138</sup> About one-third of patients die by the age of 15, and survival beyond 30 is very unusual.<sup>139</sup>

### NEUROCUTANEOUS MELANOSIS

Neurocutaneous melanosis (NCM) is a non-familial phakomatosis characterized by multiple and large congenital cutaneous nevi in association with meningeal melanosis or melanoma (Fig. 64.9).<sup>140</sup> Rare cases with ocular abnormalities such as uveal coloboma-like lesions have been reported.<sup>141</sup>



**Fig. 64.9** Large cutaneous melanocytic nevi of the trunk in a patient with neurocutaneous melanosis. (Reproduced with permission from Kiratli H, Sahin A. Fundus features of a case of neurocutaneous melanosis. *Ophthalm Genet* 2004; 25: 271–276.)



**Fig. 64.10** Extensive nevus flammeus with a midline separation on the thorax and abdomen (A). Fundus photograph showing choroidal hyperpigmentation (ocular melanocytosis) and choroidal melanoma (B). (Reproduced with permission from Tran HV, Zografos L. Primary choroidal melanoma in phakomatosis pigmentovascularis IIa. *Ophthalmology* 2005; 112: 1232–1235.)



**PHAKOMATOSIS PIGMENTOVASCULARIS**

Ota,<sup>142</sup> in 1947, described cases with a combination of vascular and melanocytic nevi in the Japanese population (phakomatosis pigmentovascularis, PPV). Five types of PPV are known, with recent attempts to reclassify them into only three subtypes.<sup>143</sup> Systemic associations

with Sturge–Weber syndrome and Klippel–Trenaunay–Weber syndrome can occur. Ocular involvement can vary from congenital glaucoma, iris mammillations, oculo(dermal) melanocystis, and even choroidal melanoma (Fig. 64.10).<sup>144</sup>

**REFERENCES**

1. Van der Hoeve J. The Doyme Memorial Lecture. Eye symptoms in phakomatosis. *Trans Ophthalmol Soc UK* 1932; 52: 380–401.
2. Riccardi VM. Neurofibromatosis: phenotype, natural history, and pathogenesis, 2nd edn. Baltimore: Johns Hopkins University Press, 1992.
3. von Recklinghausen F. Ueber die multiplen Fibrome der Haut und ihre Beziehung zu den multiplen Neuromen. Berlin: August Hirschwald, 1882.
4. Ruggieri M. The different forms of neurofibromatosis. *Childs Nervous System* 1999; 15: 295–308.
5. Gutmann DH. Recent insights into neurofibromatosis type 1: clear genetic progress. *Arch Neurol* 1998; 55: 778–780.
6. Huson SM, Compston DA, Clark P, Harper PS. A genetic study of von Recklinghausen neurofibromatosis in south east Wales. I. Prevalence, fitness, mutation rate, and effect of parental transmission on severity. *J Med Genet* 1989; 26: 704–711.
7. Jadayel D, Fain P, Upadhyaya M et al. Paternal origin of new mutations in von Recklinghausen neurofibromatosis. *Nature* 1990; 343: 558–559.
8. Kayes LM, Burke W, Riccardi VM et al. Deletions spanning the neurofibromatosis 1 gene: identification and phenotype of five patients. *Am J Hum Genet* 1994; 54.
9. Messiaen LM, Callens T, Mortier G et al. Exhaustive mutation analysis of the NF1 gene allows identification of 95% of mutations and reveals high frequency of unusual splicing defects. *Hum Mutat* 2000; 15: 541–555.
10. Cichowski K, Jacks T. NF1 tumor suppressor gene function: narrowing the GAP. *Cell* 2001; 104: 593–604.
11. Kluwe L, Friedrich R, Mautner VF. Loss of NF 1 allele in Schwann cells but not in fibroblasts derived from an NF1-associated neurofibroma. *Genes Chromosomes Cancer* 1999; 24: 283–285.
12. Friedman JM. Epidemiology of neurofibromatosis type 1. *Am J Med Genet* 1999; 89: 1–6.
13. Conference NloHCD. Neurofibromatosis: Conference Statement. *Arch Neurol* 1988; 45: 575–578.
14. Lewis RA, Riccardi VM. Von Recklinghausen neurofibromatosis. Incidence of iris hamartomata. *Ophthalmology* 1981; 88: 348–354.
15. Destro M, D'Amico DJ, Gragoudas ES. Retinal manifestations of neurofibromatosis. *Arch Ophthalmol* 1991; 109: 662–666.
16. Lisch K. Ueber Beteiligung der Augen, insbesondere das Vorkommen von Irisknoten bei der Neurofibromatose (Recklinghausen). *Z Augenheilkd* 1937; 93.
17. Singh AD, Karl Lisch, MD: Remembered. July 24, 1907–February 5, 1999. *Ophthalmol Genet* 2000; 21: 129–131.
18. Ragge NK, Falk RE, Cohen WE, Murphree AL. Images of Lisch nodules across the spectrum. *Eye* 1993; 7: 95–101.
19. Ragge NK. Clinical and genetic patterns of neurofibromatosis 1 and 2. *Br J Ophthalmol* 1993; 77: 662–672.
20. Lewis RA, Gerson LP, Axelson KA et al. von Recklinghausen neurofibromatosis. II. Incidence of optic gliomata. *Ophthalmology* 1984; 91: 929–935.
21. Imes RK, Hoyt WF. Magnetic resonance imaging signs of optic nerve gliomas in neurofibromatosis 1. *Am J Ophthalmol* 1991; 111: 729–734.
22. DeBella K, Poskitt K, Szudek J, Friedman JM. Use of 'unidentified bright objects' on MRI for diagnosis of neurofibromatosis 1 in children. *Neurology* 2000; 54: 1646–1651.
23. Johnson NS, Saal HM, Lovell AM, Schorry EK. Social and emotional problems in children with neurofibromatosis type 1: evidence and proposed interventions. *J Pediatr* 1999; 134: 767–772.
24. Poyhonen M, Niemela S, Herva R. Risk of malignancy and death in neurofibromatosis. *Arch Pathol Lab Med* 1997; 121: 139–143.
25. Evans DG, Huson SM, Donnai D et al. A genetic study of type 2 neurofibromatosis in the United Kingdom. I. Prevalence, mutation rate, fitness, and confirmation of maternal transmission effect on severity. *J Med Genet* 1992; 29: 841–846.
26. Evans DG, Trueman L, Wallace A et al. Genotype/phenotype correlations in type 2 neurofibromatosis (NF2): evidence for more severe disease associated with truncating mutations. *J Med Genet* 1998; 35: 450–455.
27. Rutledge MH, Andermann AA, Phelan CM et al. Type of mutation in the neurofibromatosis type 2 gene (NF2) frequently determines severity of disease. *Am J Hum Genet* 1996; 59: 331–342.
28. Trofatter JA, MacCollin MM, Rutter JL et al. A novel moesin-, ezrin-, radixin-like gene is a candidate for the neurofibromatosis 2 tumor suppressor. *Cell* 1993; 72: 791–800.
29. Hovens CM, Kaye AH. The tumour suppressor protein NF2/merlin: the puzzle continues. *J Clin Neurosci* 2001; 8: 4–7.
30. Antinheimo J, Sankila R, Carpen O et al. Population-based analysis of sporadic and type 2 neurofibromatosis-associated meningiomas and schwannomas. *Neurology* 2000; 54: 71–76.
31. Ragge NK, Baser ME, Klein J et al. Ocular abnormalities in neurofibromatosis 2. *Am J Ophthalmol* 1995; 120: 634–641.
32. Bouzas EA, Freidlin V, Parry DM et al. Lens opacities in neurofibromatosis 2: further significant correlations. *Br J Ophthalmol* 1993; 77: 354–357.
33. Evans DG, Huson SM, Donnai D et al. A clinical study of type 2 neurofibromatosis. *Q J Med* 1992; 84: 603–618.
34. Kaye LD, Rothner AD, Beauchamp GR et al. Ocular findings associated with neurofibromatosis type II. *Ophthalmology* 1992; 99: 1424–1429.
35. Landau K, Yasargil GM. Ocular fundus in neurofibromatosis type 2. *Br J Ophthalmol* 1993; 77: 646–649.
36. Meyers SM, Gutman FA, Kaye LD, Rothner AD. Retinal changes associated with neurofibromatosis 2. *Trans Am Ophthalmol Soc* 1995; 93: 245–252; discussion 252–247.
37. Font RL, Moura RA, Shetlar DJ et al. Combined hamartoma of sensory retina and retinal pigment epithelium. *Retina* 1989; 9: 302–311.
38. Saeed SR, Woolford TJ, Ramsden RT, Lye RH. Magnetic resonance imaging: a cost-effective first line investigation in the detection of vestibular schwannomas. *Br J Neurosurg* 1995; 9: 497–503.
39. Bance M, Ramsden RT. Management of neurofibromatosis type 2. *ENT J* 1999; 78: 91–94, 96.
40. Evans DG, Lye R, Neary W et al. Probability of bilateral disease in people presenting with a unilateral vestibular schwannoma. *J Neurol Neurosurg Psychiatry* 1999; 66: 764–767.
41. Von Hippel E. Uber eine sehr self seltene Erkrankung der Netzhaut. Graefes *Arch Ophthalmol* 1904; 59: 83–106.
42. Lindau A. Studien ber Kleinbirncysten Bau. Pathogenese und Beziehungen zur Angiomatosis Retinae. *Acta Pathol Microbiol Scand* 1926; 3 (Suppl 1): 1–28.
43. Melmon KL, Rosen SW. Lindau's disease. *Am J Med* 1964; 36: 595–617.
44. Maher ER, Yates JR, Harries R et al. Clinical features and natural history of von Hippel–Lindau disease. *Q J Med* 1990; 77: 1151–1163.
45. Moore AT, Maher ER, Rosen P et al. Ophthalmological screening for von Hippel–Lindau disease. *Eye* 1991; 5: 723–728.
46. Choyke PL, Glenn GM, Walther MM et al. von Hippel–Lindau disease: genetic, clinical, and imaging features. *Radiology* 1995; 194: 629–642.
47. Stolle C, Glenn G, Zbar B et al. Improved detection of germline mutations in the von Hippel–Lindau disease tumor suppressor gene. *Hum Mutat* 1998; 12: 417–423.
48. Singh AD, Ahmad NN, Shields CL, Shields JA. Solitary retinal capillary hemangioma: lack of genetic evidence for von Hippel–Lindau disease. *Ophthalmol Genet* 2002; 23: 21–27.
49. Research NACFHG. Statement on use of DNA testing for presymptomatic identification of cancer risk. *JAMA* 1994; 271: 785.
50. Kaelin WG, Iliopoulos O, Lonergan KM, Ohh M. Functions of the von Hippel–Lindau tumour suppressor protein. *J Intern Med* 1998; 243: 535–539.
51. Chan CC, Vortmeyer AO, Chew EY et al. VHL gene deletion and enhanced VEGF gene expression detected in the stromal cells of retinal angioma. *Arch Ophthalmol* 1999; 117: 625–630.
52. Maher ER, Kaelin WG Jr. von Hippel–Lindau disease. *Medicine* 1997; 76: 381–391.
53. Chen F, Slife L, Kishida T et al. Genotype–phenotype correlation in von Hippel–Lindau disease: identification of a mutation associated with VHL type 2A. *J Med Genet* 1996; 33: 716–717.
54. Zbar B, Kishida T, Chen F et al. Germline mutations in the Von Hippel–Lindau disease (VHL) gene in families from North America, Europe, and Japan. *Hum Mutat* 1996; 8: 348–357.
55. Webster AR, Maher ER, Bird AC et al. A clinical and molecular genetic analysis of solitary ocular angioma. *Ophthalmology* 1999; 106: 623–629.
56. Singh AD, Shields CL, Shields JA. von Hippel–Lindau disease. *Surv Ophthalmol* 2001; 46: 117–142.
57. Singh A, Shields J, Shields C. Solitary retinal capillary hemangioma: hereditary (von Hippel–Lindau disease) or nonhereditary? *Arch Ophthalmol* 2001; 119: 232–234.
58. Filling-Katz MR, Choyke PL, Oldfield E et al. Central nervous system involvement in Von Hippel–Lindau disease. *Neurology* 1991; 41: 41–46.
59. Richard S, Chavveau D, Chretien Y et al. Renal lesions and pheochromocytoma in Von Hippel–Lindau disease. *Adv Nephrol* 1994; 23: 1–27.
60. Megerian CA, McKenna M, J, Nuss RC et al. Endolymphatic sac tumors: histopathologic confirmation, clinical characterization, and implication in Von Hippel–Lindau disease. *Laryngoscope* 1995; 105: 801–808.

61. Gomez MR. History of the tuberous sclerosis complex. *Brain Dev* 1995; 17: 55–57.
62. Kwiatkowski DJ, Short MP. Tuberous sclerosis. *Arch Dermatol* 1994; 130: 348–354.
63. van Slechtenhorst M, de Hoogt R, Hermans C et al. Identification of the tuberous sclerosis gene TSC1 on chromosome 9q34. *Science* 1997; 277: 805–808.
64. Anonymous. Identification and characterization of the tuberous sclerosis gene on chromosome 16. The European Chromosome 16 Tuberous Sclerosis Consortium. *Cell* 1993; 75: 1305–1315.
65. Jones AC, Shyamsundar MM, Thomas MW et al. Comprehensive mutation analysis of TSC1 and TSC2 and phenotypic correlations in 150 families with tuberous sclerosis. *Am J Hum Genet* 1999; 64: 1305–1315.
66. Catania MG, Mischel PS, Vinters HV. Hamartin and tuberin interaction with the G2/M cyclin-dependent kinase CDK1 and its regulatory cyclins A and B. *J Neuropathol Exp Neurol* 2001; 60: 711–723.
67. Shepherd CW, Beard CM, Gomez MR et al. Tuberous sclerosis complex in Olmsted County, Minnesota, 1950–1989. *Arch Neurol* 1991; 48: 400–401.
68. Webb DW, Fryer AE, Osborne JP. On the incidence of fits and mental retardation in tuberous sclerosis. *J Med Genet* 1991; 28: 395–397.
69. Jones AC, Daniells CE, Snell RG et al. Molecular genetic and phenotypic analysis reveals differences between TSC1 and TSC2 associated familial and sporadic tuberous sclerosis. *Hum Mol Genet* 1997; 6: 2155–2161.
70. Dabora SL, Jozwiak S, Franz DN et al. Mutational analysis in a cohort of 224 tuberous sclerosis patients indicates increased severity of TSC2, compared with TSC1, disease in multiple organs. *Am J Hum Genet* 2001; 68: 64–80.
71. Robertson DM. Ophthalmic manifestations of tuberous sclerosis. *Ann NY Acad Sci* 1991; 615: 17–25.
72. Goodman M, Lamm SH, Engel A et al. Cortical tuber count: a biomarker indicating neurologic severity of tuberous sclerosis complex. *J Child Neurol* 1997; 12: 85–90.
73. Jozwiak S, Schwartz RA, Janniger CK et al. Skin lesions in children with tuberous sclerosis complex: their prevalence, natural course, and diagnostic significance. *Int J Dermatol* 1998; 37: 911–917.
74. Webb DW, Clarke A, Fryer A, Osborne JP. The cutaneous features of tuberous sclerosis: a population study. *Br J Dermatol* 1996; 135: 1–5.
75. van Baal JG, Fleury P, Brummelkamp WH. Tuberous sclerosis and the relation with renal angiomyolipoma. A genetic study on the clinical aspects. *Clin Genet* 1989; 35: 167–173.
76. Seki I, Singh AD, Longo S. Pathological case of the month: congenital cardiac rhabdomyoma. *Arch Pediatr Adol Med* 1996; 150.
77. Roach ES, Gomez MR, Northrup H. Tuberous sclerosis complex consensus conference: revised clinical diagnostic criteria. *J Child Neurol* 1998; 13: 624–628.
78. Roach ES, DiMario FJ, Kandt RS, Northrup H. Tuberous Sclerosis Consensus Conference: recommendations for diagnostic evaluation. National Tuberous Sclerosis Association. *J Child Neurol* 1999; 14: 401–407.
79. Sturge WA. A case of partial epilepsy apparently due to lesion of one of the vasomotor centers of the brain. *Trans Clin Soc Lond* 1879; 12: 162–167.
80. Weber FP. Right-sided hemihypertrophy resulting from right-sided congenital spastic hemiplegia with a morbid condition of the left side of the brain revealed by radiogram. *J Neurol Psychopathol* 1922; 37: 301–311.
81. Sullivan TJ, Clarke MP, Morin JD. The ocular manifestations of the Sturge–Weber syndrome. *J Pediatr Ophthalmol Strab* 1992; 29: 349–356.
82. Phelps CD. The pathogenesis of glaucoma in Sturge–Weber syndrome. *Ophthalmology* 1978; 85: 276–286.
83. van Emelen C, Goethals M, Dralands L, Casteels I. Treatment of glaucoma in children with Sturge–Weber syndrome. *J Pediatr Ophthalmol Strabismus* 2000; 37: 29–34.
84. Sujansky E, Conradi S. Outcome of Sturge–Weber syndrome in 52 adults. *Am J Med Genet* 1995; 57: 35–45.
85. Kramer U, Kahana E, Shorer Z, Ben-Zeev B. Outcome of infants with unilateral Sturge–Weber syndrome and early onset seizures. *Develop Med Child Neurol* 2000; 42: 756–759.
86. Tallman B, Tan OT, Morelli JG et al. Location of port-wine stains and the likelihood of ophthalmic and/or central nervous system complications. *Pediatrics* 1991; 87: 323–327.
87. Marti-Bonmati L, Menor F, Poyatos C, Cortina H. Diagnosis of Sturge–Weber syndrome: comparison of the efficacy of CT and MR imaging in 14 cases. *AJR. Am J Roentgenol* 1992; 158: 867–871.
88. Mandal AK. Primary combined trabeculotomy–trabeculectomy for early-onset glaucoma in Sturge–Weber syndrome. *Ophthalmology* 1999; 106: 1621–1627.
89. Budenz DL, Sakamoto D, Eliezer R et al. Two-staged Baerveldt glaucoma implant for childhood glaucoma associated with Sturge–Weber syndrome. *Ophthalmology* 2000; 107: 2105–2110.
90. Schilling H, Sauerwein W, Lommatzsch A et al. Long-term results after low dose ocular irradiation for choroidal haemangiomas. *Br J Ophthalmol* 1997; 81: 267–273.
91. Zografos L, Egger E, Bercher L et al. Proton beam irradiation of choroidal hemangiomas. *Am J Ophthalmol* 1998; 126: 261–268.
92. Arzimanoglou AA, Andermann F, Aicardi J et al. Sturge–Weber syndrome: indications and results of surgery in 20 patients. *Neurology* 2000; 55: 1472–1479.
93. Wyburn-Mason R. Arteriovenous aneurysm of midbrain and retina, facial nevi and mental changes. *Brain Dev* 1943; 66: 163–203.
94. Muthukumar N, Sundaralingam MP. Retinocephalic vascular malformation: case report. *Br J Neurosurg* 1998; 12: 458–460.
95. Theron J, Newton TH, Hoyt WF. Unilateral retinocephalic vascular malformations. *Neuroradiology* 1974; 7: 185.
96. Ponce FA, Han PP, Spetzler RF et al. Associated arteriovenous malformation of the orbit and brain: a case of Wyburn-Mason syndrome without retinal involvement. Case report. *J Neurosurg* 2001; 95: 346–349.
97. Hopen G, Smith JL, Hoff JT, Quencer R. The Wyburn-Mason syndrome. Concomitant chiasmal and fundus vascular malformations. *J Clin Neuro-Ophthalmol* 1983; 3: 53–62.
98. Shah GK, Shields JA, Lanning RC. Branch retinal vein obstruction secondary to retinal arteriovenous communication. *Am J Ophthalmol* 1998; 126: 446–448.
99. Efron L, Zakov ZN, Tomsak RL. Neovascular glaucoma as a complication of the Wyburn-Mason syndrome. *J Clin Neuro-Ophthalmol* 1985; 5: 95–98.
100. Gass JD. Cavemous hemangioma of the retina. A neuro-oculo-cutaneous syndrome. *Am J Ophthalmol* 1971; 71: 799–814.
101. Dobyns WB, Michels VV, Groover RV et al. Familial cavernous malformations of the central nervous system and retina. *Ann Neurol* 1987; 21: 578–583.
102. Goldberg RE, Pheasant TR, Shields JA. Cavemous hemangioma of the retina. A four-generation pedigree with neurocutaneous manifestations and an example of bilateral retinal involvement. *Arch Ophthalmol* 1979; 97: 2321–2324.
103. Davenport WJ, Siegel AM, Dichgans J et al. CCM1 gene mutations in families segregating cerebral cavernous malformations. *Neurology* 2001; 56: 540–543.
104. Couteux SL, Brezin AP, Fontaine B et al. A novel KRIT1/CCM1 truncating mutation in a patient with cerebral and retinal cavernous angiomas. *Arch Ophthalmol* 2002; 120: 217–218.
105. Messmer E, Font RL, Laqua H et al. Cavemous hemangioma of the retina. Immunohistochemical and ultrastructural observations. *Arch Ophthalmol* 1984; 102: 413–418.
106. Dellemlin PL, Vanneste JA. Cavemous angiomatosis of the central nervous system: usefulness of screening the family. *Acta Neurol Scand* 1993; 88: 259–263.
107. Siegel AM. Familial cavernous angioma: an unknown, known disease. *Acta Neurol Scand* 1998; 98: 369–371.
108. Raychaudhuri R, Batjer HH, Awad IA. Intracranial cavernous angioma: a practical review of clinical and biological aspects. *Surg Neurol* 2005; 63: 319–328.
109. Jadassohn J. Bemerkungen zur Histologie der systematisirten Naevi und über ‘Talgdrusen-Naevi.’ *Arch Dermatol Syphilis* 1885; 33: 355–394.
110. Schimmelpenninck GW. Clinical contribution to symptomatology of phacomatosis. *Fortschr Geb Rontgenstr Nuklearmed* 1957; 87: 716–720.
111. Feuerstein RC, Mims LC. Linear nevus sebaceus with convulsions and mental retardation. *Am J Dis Child* 1962; 104: 675–679.
112. Solomon LM, Fretzin DF, Dewald RL. The epidermal nevus syndrome. *Arch Dermatol* 1968; 97: 273–285.
113. Vujevich JJ, Mancini AJ. The epidermal nevus syndromes: multisystem disorders. *J Am Acad Dermatol* 2004; 50: 957–961.
114. Solomon LM, Esterly NB. Epidermal and other congenital organoid nevi. *Curr Probl Pediatr* 1975; 6: 1–56.
115. Sugarman JL. Epidermal nevus syndromes. *Semin Cutan Med Surg* 2004; 23: 145–157.
116. Mehregan AH, Pinkus H. Life history of organoid nevi. Special reference to nevus sebaceus of Jadassohn. *Arch Dermatol* 1965; 91: 574–588.
117. Domingo J, Helwig EB. Malignant neoplasms associated with nevus sebaceus of Jadassohn. *J Am Acad Dermatol* 1979; 1: 545–556.
118. Grebe TA, Rimsza ME, Richter SF et al. Further delineation of the epidermal nevus syndrome: two cases with new findings and literature review. *Am J Med Genet* 1993; 47: 24–30.
119. Pe’er J, Ilisar M. Epibulbar complex choristoma associated with nevus sebaceus. *Arch Ophthalmol* 1995; 113: 1301–1304.
120. Duncan JL, Golabi M, Fredrick DR et al. Complex limbal choristomas in linear nevus sebaceus syndrome. *Ophthalmology* 1998; 105: 1459–1465.
121. Shields JA, Shields CL, Eagle RC Jr et al. Ocular manifestations of the organoid nevus syndrome. *Ophthalmology* 1997; 104: 549–557.
122. Traboulsi EI, Zin A, Massicotte SJ et al. Posterior scleral choristoma in the organoid nevus syndrome (linear nevus sebaceus of Jadassohn). *Ophthalmology* 1999; 106: 2126–2130.
123. Wagner RS, Facciani JM. Organoid nevus syndrome: manifestations and management. *J Pediatr Ophthalmol Strabismus* 2003; 40: 137–141.
124. Margulis A, Bauer BS, Corcoran JF. Surgical management of the cutaneous manifestations of linear nevus sebaceus syndrome. *Plast Reconstr Surg* 2003; 111: 1043–1050.
125. Louis-Bar D. Sur un syndrome progressif comprenant des telangiectasies capillaires cutanées et conjonctivales symétriques, à disposition naevoïde et des troubles cérébelleux. *Clin Neurol* 1941; 4: 32.
126. Boder E, Sedgwick RP. Ataxia–telangiectasia: a familial syndrome of progressive cerebellar ataxia, oculocutaneous telangiectasia and frequent pulmonary infections. *Pediatrics* 1958; 21: 526–554.
127. Boder E. Ataxia–telangiectasia: some historic, clinical and pathologic observations. *Birth Defects: Original Article Series* 1975; 11: 255–270.
128. Savitsky K, Bar-Shira A, Gilad S et al. A single ataxia telangiectasia gene with a product similar to PI-3 kinase. *Science* 1995; 268: 1749–1753.
129. Kastan MB. Ataxia–telangiectasia – broad implications for a rare disorder. *N Engl J Med* 1995; 333: 662–663.
130. Swift M, Chase CL, Morrell D. Cancer predisposition of ataxia–telangiectasia heterozygotes. *Cancer Genet Cytogenet* 1990; 46: 21–27.
131. Boder E. Ataxia–telangiectasia: an overview. *Kroc Foundation Series* 1985; 19: 1–63.
132. Bunday S. Clinical and genetic features of ataxia–telangiectasia. *Int J Rad Biol* 1994; 66: S23–29.

133. Stell R, Bronstein AM, Plant GT, Harding AE. Ataxia telangiectasia: a reappraisal of the ocular motor features and their value in the diagnosis of atypical cases. *Movement Disorders* 1989; 4: 320–329.
134. Gatti RA. Ataxia–telangiectasia. *Dermatol Clin* 1995; 13: 1–6.
135. Taylor AM, Metcalfe JA, Thick J, Mak YF. Leukemia and lymphoma in ataxia telangiectasia. *Blood* 1996; 87: 423–438.
136. Laake K, Jansen L, Hahnemann JM et al. Characterization of ATM mutations in 41 Nordic families with ataxia telangiectasia. *Hum Mutat* 2000; 16: 232–246.
137. Seidemann K, Henze G, Beck JD et al. Non-Hodgkin's lymphoma in pediatric patients with chromosomal breakage syndromes (AT and NBS): experience from the BFM trials. *Ann Oncol* 2000; 11: 141–145.
138. Woods CG, Taylor AM. Ataxia telangiectasia in the British Isles: the clinical and laboratory features of 70 affected individuals. *Q J Med* 1992; 82: 169–179.
139. Ersoy F, Berkel AI, Sanal O, Oktay H. Twenty-year follow-up of 160 patients with ataxia–telangiectasia. *Turk J Pediatr* 1991; 33: 205–215.
140. Makkar HS, Frieden IJ. Neurocutaneous melanosis. *Semin Cutan Med Surg* 2004; 23: 138–144.
141. Kiratli H, Sahin A. Fundus features of a case of neurocutaneous melanosis. *Ophthalm Genet* 2004; 25: 271–276.
142. Ota M, Kawamura T, Ito N. Phacomatosis pigmentovascularis Ota. *Jpn J Dermatol* 1947; 52: 1–3.
143. Happle R. Phacomatosis pigmentovascularis revisited and reclassified. *Arch Dermatol* 2005; 141: 385–388.
144. Tran HV, Zografos L. Primary choroidal melanoma in phacomatosis pigmentovascularis Ila. *Ophthalmology* 2005; 112: 1232–1235.



# Retinoblastoma and cancer genetics

Alfred G. Knudson, Jr.

## INTRODUCTION

For the pediatrician-in-training of more than 50 years ago, retinoblastoma was a rare curiosity, of interest because of its embryonal origin, sometimes hereditary predisposition, and frequent lethality. Now it is conspicuous in the world of oncology, paradigmatic in genetics, and highly curable. The explanation for these shifts is intimately related to the virtual founding of two fields of medicine and science, namely pediatric oncology and cancer genetics. Here I discuss a personal view of these developments from the point of view of cancer genetics.

## EVIDENCE FOR THE ROLE OF GENETICS IN THE ORIGIN OF CANCER

**Early evidence** Although a heritable predisposition to cancer has long been known, the first specific proposal for a role of genetics in the origin of cancer was set forth by Boveri<sup>1</sup> in his heuristic volume of 1914. Impressed by the finding of von Hansemann of aberrant mitoses in cancer cells,<sup>2</sup> Boveri proposed that some chromosomes might stimulate cell division and that others might inhibit it, anticipating the much later discovery of oncogenes and tumor suppressor genes. When Muller<sup>3</sup> later discovered that ionizing radiation could induce mutation of genes he proposed, knowing that such radiation is carcinogenic, that specific gene mutations initiate a process whose later progress entailed spontaneous mutations in other genes until some requisite number of mutations was reached, thus explaining the typical latent periods of radiogenic cancer.<sup>4</sup> Nordling<sup>5</sup> first proposed that the number of such 'hits' might be six for colon cancer. This conclusion provided a satisfying theory, but no means for discovery of specific mutations. Such cancers were clearly too complicated at that time, with contemporaneous tools.

**Cytogenetic evidence** An encouraging discovery was that by Nowell and Hungerford of the Philadelphia chromosome, Ph1, in chronic myelocytic leukemia cells with no other visible cytogenetic abnormality.<sup>6</sup> Could such a single genetic defect be characterized? The answer at that time was no; the ability to localize a gene had not been discovered. Nevertheless, the finding suggested that the number of hits to some cancers might be small.

**Number of events as evidence** If an induced hit could be the first on the path to cancer, so could an inherited hit, such as is found with a dominantly inherited predisposition to specific cancers. There should not be 'one-hit' hereditary cancer because cancer would be too common in a corresponding non-hereditary form. One might expect,

then, that the smallest number of hits would be two, the second being somatic. If two hits were sufficient then the resulting cancer might occur in very early life. This possibility caused my attention to be focused on retinoblastoma, which in its heritable form can be found even in newborn babies. One hit was clearly insufficient, for all retinoblasts would form tumors, yet the mean number of tumors observed was approximately three.<sup>7</sup> Non-hereditary tumors, although rare, would occur following two hits, because a clone of somatically mutant retinoblasts could give rise to a cell with a second hit that would create a single tumor. Such tumors should on average occur later than those arising in genetically predisposed persons, as is indeed the case.

**Implications for the nature of the gene(s) mutated** Such a scenario had important implications for the nature of the gene(s) mutated. The two hits could occur in one copy of each of two separate genes, i.e. in co-dominant fashion, or in both alleles of a single gene, in recessive fashion. The first scenario would support Boveri's notion of a genetic change that stimulated cell division; the second would support his notion of loss of a suppressor of cell division. At that time there was no means of discriminating between these alternatives. However, in an analysis of fusion of cancer cells with normal cells, Harris and Klein<sup>8</sup> found that the fusion product was not cancerous until it lost one or more chromosomes, from which they concluded that cancer, at least in some cases, involved loss of a tumor suppressor. I favored the latter possibility and suggested that the gene might code for a cell surface protein involved in signal transduction,<sup>9</sup> whereas Comings<sup>10</sup> proposed that it might encode a nuclear protein that inhibits the activation of what we now call a proto-oncogene, a prediction very close to what was later found.

With the recessive mechanism, the second event could be one of several kinds, including mutation, loss by deletion, loss of a whole chromosome, or mitotic recombination.<sup>11</sup> A search for these could be undertaken if the locations of the inherited and second hits were known. The location of the inherited mutation was revealed by a few cases of congenital deletions in band q14 of chromosome 13.<sup>12,13</sup>

## ROLE OF OPHTHALMOLOGISTS IN THE DISCOVERY OF THE *RB1* GENE

Three ophthalmologists, Linn Murphree, Brenda Gallie, and Thaddeus Dryja, were important participants in the discovery of the *RB1* gene as the first tumor suppressor gene. Robert Sparkes,<sup>14</sup> together with Murphree and others, discovered a close linkage between *RB1* and the esterase D gene (*EsD*). In persons heterozygous for a variant allele or

for hemizyosity of the normal allele of *E2F* these investigators and their colleagues were able to show allele loss in some tumors, supporting the recessive hypothesis.<sup>15,16</sup> Then all of them joined with Webster Cavenee, who had discovered multiple polymorphic markers (restriction fragment length polymorphisms or RFLPs) on chromosome 13, to demonstrate the predicted multiple mechanisms of the second events in support of recessiveness.<sup>17</sup> These tools and findings were then employed by Friend et al.<sup>18</sup> to use a DNA marker to clone the *RB1* gene.

The cloning of *RB1* was almost immediately followed by the cloning of other dominantly heritable cancer genes, including *WT1*, *NF1*, and *APC*. In virtually every case a two-hit tumor was demonstrated, in keeping with recessiveness, making retinoblastoma a model for many tumors. However, in most cases these tumors are benign, and further genetic changes are necessary for malignancy, as anticipated by Muller and Nordling. Now there are some 40–50 hereditary cancers that follow the model of two hits established for retinoblastoma.

### THE *RB1* GENE AND ITS IMPORTANCE FOR CANCER BIOLOGY

The *RB1* gene has an importance for cancer biology far beyond expectation. It was soon discovered that its encoded protein interacts with

an *E2F* transcription factor to regulate the cell cycle.<sup>19–23</sup> Indeed, the *Rb* protein is a major regulator of the cell cycle in all dividing cells, an observation that raises the question ‘Why is *RB1* a retinoblastoma gene?’ Of course, we now know, thanks to high cure rates and long-term follow-up of survivors, that it is not only a retinoblastoma gene. In fact, most cancers seem to be mutant for *RB1* or for genes closely related to it metabolically. This phenomenon has been exploited by ‘smart’ DNA tumor viruses, including simian virus 40, human papillomavirus, and some adenoviruses, each of which produces a protein that inactivates *Rb* protein.

The critical importance of *RB1* is also demonstrated by the effect of homozygosity for inactivating mutations. In mice the homozygous state is lethal to the developing embryo, with multiple defects, especially in the brain. Of further interest is the fact that homozygosity for most tumor suppressor genes associated with hereditary cancer results in fetal lethality. If we did not know these genes for their predisposition to cancer in the heterozygous mutant state, we would know them as recessive developmentally lethal genes, thereby proving the long-suspected relationship between cancer and development.

### REFERENCES

1. Boveri T. Zur frage der entstehung maligner tumoren. Jena: Gustav Fischer, 1914; English translation: Boveri M. The origin of malignant tumors. Baltimore: Williams & Wilkins, 1929.
2. von Hansemann D. Über asymmetrische Zellteilung in Epithelkrebsen und deren biologische Bedeutung. Virchow's Arch Path Anat 1890; 119: 299–326.
3. Muller HJ. Artificial transmutation of the gene. Science 1927; 46: 84–87.
4. Muller HJ. Radiation damage to the genetic material. Sci Progr 1951; 7: 93–165, 481–493.
5. Nordling CE. A new theory on the cancer-inducing mechanism. Br J Cancer 1953; 6: 68–72.
6. Nowell PC, Hungerford DA. A minute chromosome in human chronic granulocytic leukemia. Science 1960; 132: 1497.
7. Knudson AG. Mutation and cancer: statistical study of retinoblastoma. Proc Natl Acad Sci USA 1971; 68: 820–823.
8. Harris H, Miller OJ, Klein G et al. Suppression of malignancy by cell fusion. Nature 1969; 223: 363–368.
9. Knudson AG. Mutation and human cancer. Adv Cancer Res 1973; 17: 317–352.
10. Comings DE. A general theory of carcinogenesis. Proc Natl Acad Sci USA 1973; 70: 3324–3328.
11. Knudson AG. Retinoblastoma: a prototypic hereditary neoplasm. Semin Oncol 1978; 5: 57–60.
12. Francke U, Kung F. Sporadic bilateral retinoblastoma and 13q- chromosomal deletion. Med Pediatr Oncol 1976; 2: 379–385.
13. Knudson AG Jr, Meadows AT, Nichols WW et al. Chromosomal deletion and retinoblastoma. N Engl J Med 1976; 295: 1120–1123.
14. Sparkes RS, Sparkes MC, Wilson MG et al. Regional assignment of genes for human esterase D and retinoblastoma to chromosome band 13q14. Science 1980; 208: 1042–1044.
15. Benedict WF, Murphree AL, Banerjee A et al. Patient with 13 chromosome deletion: evidence that the retinoblastoma gene is a recessive cancer gene. Science 1983; 219: 973–975.
16. Godbout R, Dryja TP, Squire J et al. Somatic inactivation of genes on chromosome 13 is a common event in retinoblastoma. Nature 1983; 304: 451–453.
17. Cavenee WK, Dryja TP, Phillips RA et al. Expression of recessive alleles by chromosomal mechanisms in retinoblastoma. Nature 1983; 305: 779–784.
18. Friend SH, Bernards R, Rogelj S et al. A human DNA segment with properties of the gene that predisposes to retinoblastoma and osteosarcoma. Nature 1986; 323: 643–646.
19. Bagchi S, Weinmann R, Raychaudhuri P. The retinoblastoma protein copurifies with *E2F-1*, an *E1A*-regulated inhibitor of the transcription factor *E2F*. Cell 1991; 65: 1063–1072.
20. Chellappan SP, Hiebert S, Mudryj M et al. The *E2F* transcription factor is a cellular target for the *RB* protein. Cell 1991; 65: 1053–1061.
21. Helin K, Lees JA, Vidal M et al. A cDNA encoding a pRB-binding protein with properties of the transcription factor *E2F*. Cell 1992; 70: 337–350.
22. Kaelin WG, Krek W, Sellers WR et al. Expression cloning of a cDNA encoding a retinoblastoma-binding protein with *E2F*-like properties. Cell 1992; 70: 351–364.
23. Shirodkar S, Ewen M, DeCaprio JA et al. The transcription factor *E2F* interacts with the retinoblastoma product and a p107-cyclin A complex in a cell cycle-regulated manner. Cell 1992; 68: 157–166.

# Cellular and genetic events in retinoblastoma tumorigenesis

Michael A. Dyer and J. William Harbour

## INTRODUCTION

Tumorigenesis is a multistep process that involves sequential genetic alterations.<sup>1</sup> Preneoplastic cells must overcome their dependence on extrinsic mitogenic signals, evade apoptosis, prevent degradation of life-span limiting telomeres, recruit vasculature, and acquire invasive properties to become malignant tumor cells.<sup>1</sup>

## RETINOBLASTOMA TUMORIGENESIS: KNUDSON'S TWO-HIT HYPOTHESIS

Despite its relative rarity, retinoblastoma has been at the heart of many of the landmark discoveries that have advanced our understanding of the cellular events in tumorigenesis over the past several decades (See Chapter 65). By studying the inheritance pattern of retinoblastoma, Knudson proposed a 'two-hit' model to explain how a mutant 'tumor suppressor' gene could be inherited as a dominant trait in which inactivation of the second, normal allele occurred in a susceptible somatic tissue such as the developing retina.<sup>2</sup> The Knudson hypothesis was confirmed by the cloning of the RB1 gene from retinoblastomas in 1986 by a team headed by Weinberg and Dryja.<sup>3</sup> As predicted by Knudson, one copy of the RB1 gene, located on chromosome 13q14, is mutated in the germline of susceptible individuals, whereas both copies of the gene are disrupted in the retinal tumors. Surprisingly, RB1 mutations subsequently were found in many other tumors unrelated to retinoblastoma, such as lung and breast cancer,<sup>4,5</sup> and the RB1 protein is inactivated in the vast majority of all human cancers,<sup>6</sup> indicating that the Rb pathway is broadly important as a tumor suppressor.

## MOUSE MODELS OF RETINOBLASTOMA

The first genetically-engineered animal model of spontaneous retinoblastoma was a transgenic mouse line in which the oncogenic T antigen from the SV40 virus was expressed in the retina.<sup>7</sup> T antigen inhibits the Rb protein, providing an explanation for the retinal tumors, but it also inhibits the other Rb family members p107 and p130, as well as the p53 tumor suppressor and many other proteins. Therefore, this model was not ideal for studying the molecular genetics of retinoblastoma as it occurs in humans. Intriguingly, when a similar transgenic mouse line was developed in which Rb was inhibited by E7, a viral oncoprotein encoded by human papillomavirus that does not inhibit p53, retinoblastomas did not develop unless the mice were bred into a p53-null background.<sup>8</sup> In an attempt to reconcile these observations, some investigators postulated that p53 or another anti-apoptotic gene must be mutated in human retinoblastoma. A

recent study has shown that the p53 pathway is suppressed in retinoblastoma by genetic amplification of MDMX and MDM2<sup>9</sup> and that retinoblastoma does not arise from an intrinsically death resistant cell as previously believed.<sup>10</sup>

In the search for a more accurate genetic model of retinoblastoma, several groups generated mice in which one copy of the Rb1 gene was nonfunctional, thereby replicating the situation with patients with heritable retinoblastoma.<sup>11–13</sup> Surprisingly, these mice developed pituitary tumors but none developed retinoblastoma. The first clue to solving this apparent inconsistency between human and mouse retinoblastoma was provided by workers in the Berns laboratory who showed that deletion of Rb1 in the mouse retina leads to retinal tumors if the Rb family member p107 was also deleted.<sup>14</sup> Subsequent work confirmed these findings and showed that loss of Rb1 in the mouse (but not humans) is compensated by up-regulation of p107,<sup>15</sup> thus explaining the apparent contradiction between mouse and human susceptibility to retinoblastoma. These findings led to the generation of the first true knockout mouse model of retinoblastoma<sup>16</sup>, which was confirmed and extended by two other groups.<sup>10,17</sup> These new genetic models of retinoblastoma are yielding important new insights into retinoblastoma biology, and may lead to novel treatments.<sup>9,18</sup>

## CELL OF ORIGIN

The cell of origin of retinoblastoma has been the subject of intense debate for many years.<sup>19</sup> This concept is important for understanding why selected cells are susceptible to transformation when RB1 is lost, how the initiating genetic mutation leads to clonal tumor expansion, and which cell types should be targeted for targeted molecular therapy.<sup>20,21</sup>

**Why cell of origin is important** If retinoblastoma arises from a specific cell type during a restricted period of retinal development, then understanding of the regulatory pathways may provide highly directed targets for molecular therapy. For example, a small molecule inhibitor of the Hedgehog pathway recently was shown to prevent medulloblastoma progression in a mouse model.<sup>22</sup>

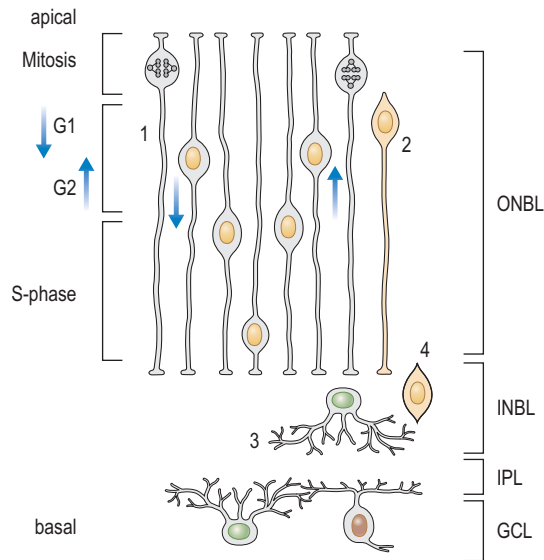
**Four possible cells of origin** There are at least four possible cells of origin for retinoblastoma: (1) retinal stem cell, (2) differentiated neuron or glial cell, (3) retinal progenitor cell or (4) a newly postmitotic cell committed or biased toward a particular retinal fate (Fig. 66.1).<sup>16</sup>

**Retinal stem cell** Recent studies have suggested that there is no retinal stem cell in either the human or mouse neural retina.<sup>23,24</sup>



**Differentiated neuron or glial cell** It is unlikely that a fully differentiated retinal neuron or glial cell gives rise to retinoblastoma, since the susceptibility to retinoblastoma is generally limited to a small window of time in embryonic development and early infancy, prior to cell cycle exit and terminal differentiation in the developing retina.

**Retinal progenitor cell** Therefore, the most likely candidates for the cell of origin are a retinal progenitor cell or a newly postmitotic cell in the developing retina.<sup>19</sup> The evidence for a retinal progenitor

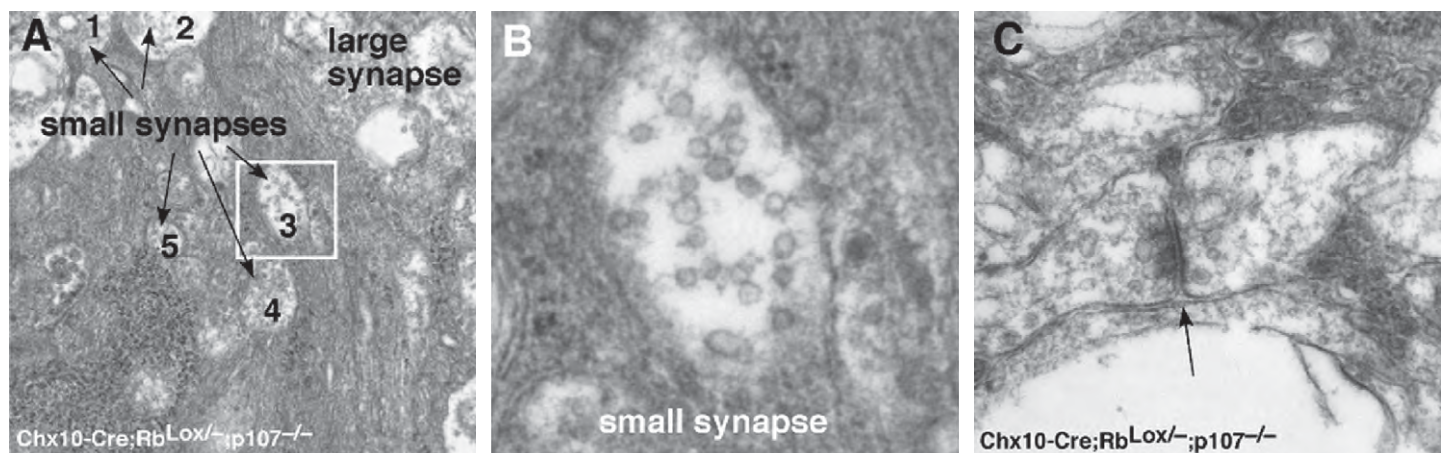


**Fig. 66.1** Retinoblastoma: cell of origin. Retinoblastoma could arise from four different cell populations. The first potential cell of origin is a proliferating retinal progenitor cell.<sup>1</sup> Multipotent retinal progenitor cells undergo interkinetic nuclear migration as they transition through the cell cycle. Rb inactivation is believed to occur during DNA replication; however, it is not necessarily required to prevent deregulated proliferation. It is expected that the tumors arising from this cell would express progenitor cell markers and possibly differentiation markers. The second possibility is a newly postmitotic cell<sup>2</sup> that is committed to a particular cell fate but fails to complete the differentiation program. It is expected that the tumors arising from this cell would express markers characteristic of this committed cell type. An extension of this hypothesis is the possibility that a more mature differentiated retinal cell<sup>3</sup> gives rise to retinoblastoma by re-entering the cell cycle. Stem cells have been identified in the ciliary marginal zone (CMZ) of the retina but not the neural retina.

cell as the retinoblastoma cell of origin comes from several experiments using genetic studies in mice. First, conditional inactivation of Rb1 and p107 in newly postmitotic rod photoreceptors (~80% of the cells in the mouse retina) did not result in retinoblastoma,<sup>25</sup> but when Rb1 and p107 were inactivated in proliferating retinal progenitor cells using three different independent approaches, retinoblastomas developed in all three models.<sup>10,16,17</sup> Further evidence that a retinal progenitor cell can give rise to retinoblastoma in mice came from studies using replication incompetent retroviral vectors. Expression in the retina of the adenoviral E1A oncogene, which inhibits Rb family members, using a retroviral vector that can only infect proliferating cells caused deregulated proliferation in retinal progenitor cells.<sup>15,16</sup> Individual infected retinal progenitor cells expressing the E1A oncogene formed clonal focal retinal hyperplastic lesions, and simultaneous elimination of p53 led to formation of frank retinoblastoma.<sup>15,16</sup> In a recent study, acute Rb1 inactivation in p107 deficient retinas, showed that retinal progenitor cells were more likely to undergo ectopic cell division than newly postmitotic cells.<sup>26</sup>

**Newly postmitotic cell** One approach that is often used to identify cancer cell of origin is to analyze differentiation markers. The main assumption of this approach is that the normal cell type that expresses a given protein may be the cell of origin for a cancer in which that protein is expressed.

**ANALYSIS OF DIFFERENTIATION MARKERS** Retinoblastoma has been shown to express photoreceptor-specific genes, which initially suggested photoreceptors as the cell of origin.<sup>27</sup> However, further analysis has shown that human retinoblastoma samples express a variety of other cell-specific markers.<sup>28</sup> These indeterminate results reflect the difficulty in the differentiation marker approach to cell of origin studies; tumor cells that express different markers could have arisen from different cell types, or they may simply have arisen from the same multipotent progenitor cell at a different point in maturation. Further, gene expression changes in retinoblastoma, which is a developmental regulator, may reflect a nonspecific, deregulated developmental program initiated by the loss of RB1. In mice, the picture is more straightforward. Retinoblastomas from knockout mice described above, express markers of retinal progenitor cells and amacrine cells, results supported by electron microscopic observations (Dyer and Johnson, personal observation) (Fig. 66.2). However, these results



**Fig. 66.2** Electron microscopic analysis of mouse retinoblastoma. Abundant structures that have all the hallmarks of amacrine or horizontal cell synapses are found in knockout mouse tumors. This image includes five small synapses and one large one (A). (Magnification  $\times 36600$ .) Higher magnification of one of the small synapses in (A) showing synaptic vesicles (B). At  $\times 110000$  magnification the postsynaptic density is visible (C).

must be interpreted cautiously since even the knockout mouse models are not genetically identical to human retinoblastoma.

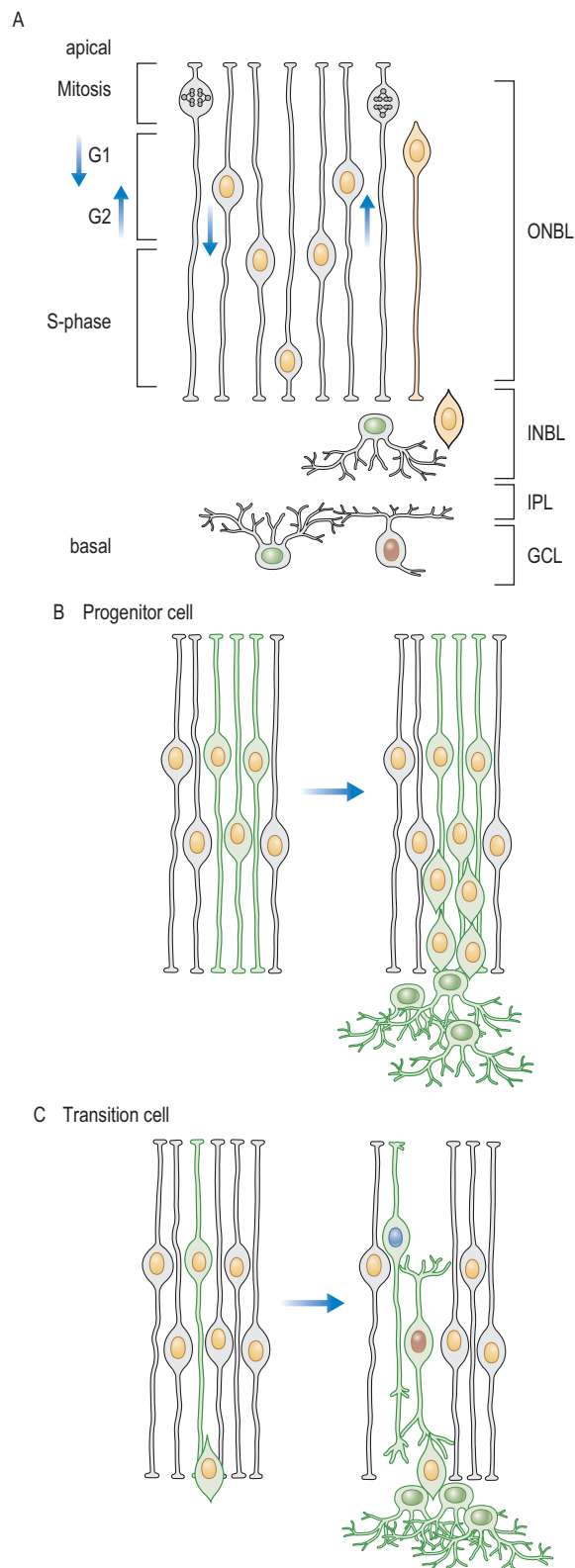
**SUPPORTING EVIDENCE** The evidence for a newly postmitotic cell as the retinoblastoma cell of origin also relies upon marker expression. The expression of amacrine cell markers in mouse retinoblastoma may indicate that a newly postmitotic cell committed to the amacrine cell fate is the cell that is susceptible to loss of *Rb1* and *p107*. The strongest evidence for a postmitotic cell of origin comes from the position of ectopically dividing cells in the apical-basal organization of the developing retina.<sup>19</sup> Normally, DNA synthesis (S-phase) occurs in retinal precursor cells on the basal surface of the retina, M-phase occurs on the apical surface, and the G1 and G2 phases occur during the transition from apical to basal surface.<sup>29</sup> The fact that *Rb1/p107*-deficient retinas exhibit an absence of mitoses at the apical surface and an increase in S-phase cells in the differentiating regions of the retina suggests that a newly postmitotic cell may give rise to retinoblastoma.<sup>19</sup> These results must be interpreted in light of the fact that the genetic manipulations in these mice result in widespread disruption of normal retinal lamination, perturbing the normal position of retinal progenitor cells and newly postmitotic cells within the developing retina. While we have narrowed our focus on retinal progenitor cells and newly postmitotic cells as the possible retinoblastoma cells of origin (Fig. 66.3), additional studies are required to definitively determine the cell of origin of retinoblastoma (Fig. 66.4).

## EVENTS IN RETINOBLASTOMA PROGRESSION

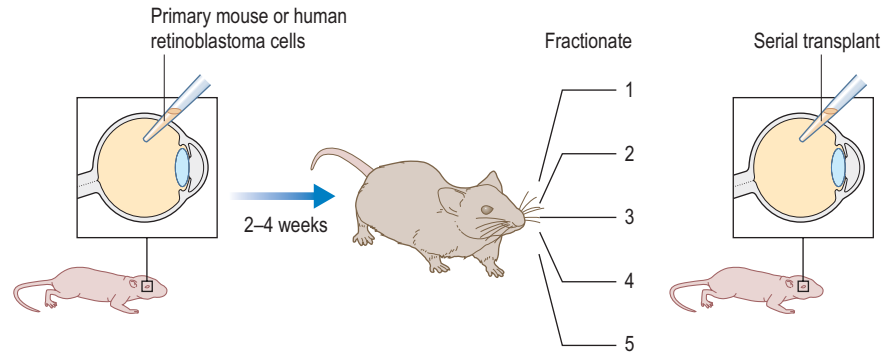
While the initiating genetic event in retinoblastoma – biallelic inactivation of the *RB1* gene – is well established, until recently, little was known about the subsequent genetic events that contribute to retinoblastoma formation and progression.<sup>9</sup>

**Circumventing apoptosis** Until recently, a major unexplained question is why loss of *RB1* does not trigger an apoptotic response that eliminates nascent retinoblastoma cells before clonal expansion occurs.<sup>9</sup> In most cancers, there are mutations in the *p53* tumor suppressor or other members of the *p53* pathway that explain the acquired resistance to apoptosis.<sup>6</sup> Further, in mouse models of retinoblastoma, tumor development is greatly enhanced when *p53* is inactivated (Fig. 66.5).<sup>8,30</sup> However, there is no evidence that *p53* is frequently mutated in human retinoblastoma.<sup>31</sup> Further, *p53* can be activated in retinoblastomas, suggesting that the protein is functional.<sup>32</sup> New research have shown that amplification of the *MDMX* and *MDM2* genes suppress the *p53* pathway in human retinoblastoma<sup>9</sup> and that these tumor do not arise from intrinsically death resistant cells as previously believed.<sup>10</sup>

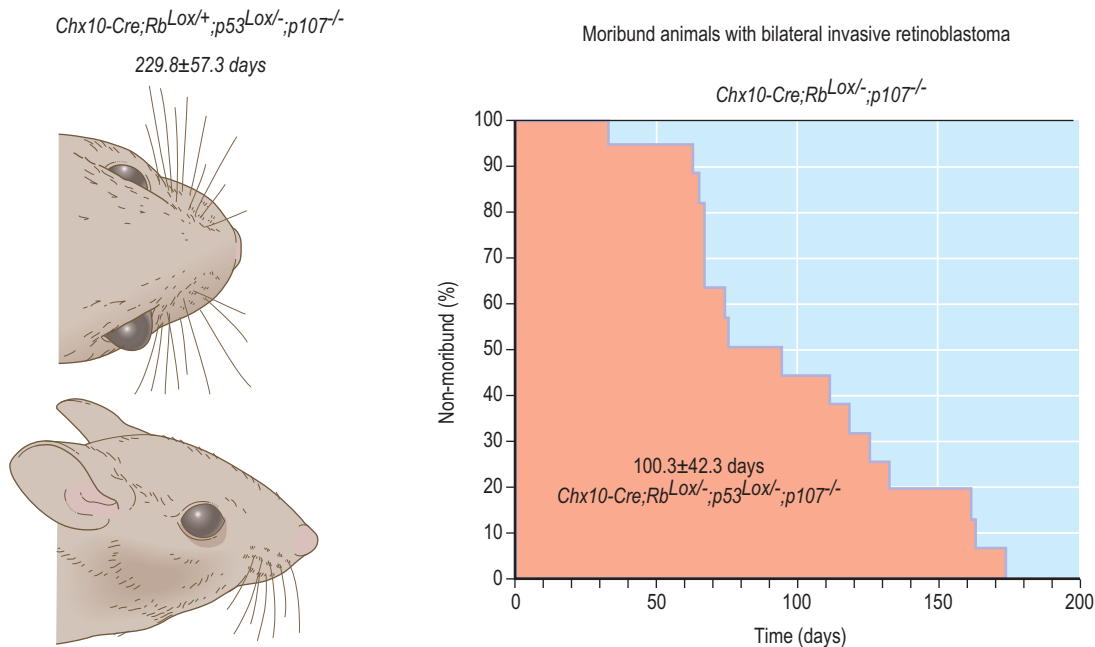
**Is retinoblastoma a unique exception?** It has been well established by Weinberg, Vogelstein and many others, that most tumors sustain genetic lesions in their *Rb* and *p53* pathways.<sup>1,33</sup> However, correlational studies on murine retinoblastoma<sup>10</sup> led to the hypothesis that retinoblastoma was the unique exception to this important principle in cancer genetics. Specifically, Bremner and colleagues proposed that retinoblastoma arises from an intrinsically death resistant cell that did not need to bypass the *ARF/MDM2/MDMX/p53* tumor suppressor pathway.<sup>19</sup> A comprehensive analysis of human retinoblastomas has found that the *p53* pathway is inactivated in human retinoblastomas by the amplification of the *MDMX* and *MDM2* genes and that these genetic changes suppress the *p53* oncogenic stress response allowing *RB1*-deficient retinoblasts to clonally expand.<sup>9</sup>



**Fig. 66.3** Clonal analysis of early stage retinoblastoma. Retinal progenitor cells proliferate in the outer neuroblastic layer and generate postmitotic transition cells (yellow) that migrate to their appropriate layer and differentiate (A). If a progenitor cell is the cell of origin for retinoblastoma then the emerging clones will be homogeneous and contain proliferating cells and amacrine cells (B). If a transition cell is the cell of origin then clones will contain amacrine cells but also normal bipolar cells (purple) and Müller glia generated from unaffected progenitor cells (C).



**Fig. 66.4** Serial transplant of fractionated human or mouse retinoblastoma. To determine whether retinoblastoma grows by a stem cell mechanism, primary human or mouse tumors will be fractionated by FACS sorting for stem cell markers and other cell surface proteins found to be localized to restricted subsets of tumor cells. These purified cell populations will then be injected into the vitreous of newborn rats and allowed to expand for 2–4 weeks. Immunosuppression is not required because rats are immunonaive for the first 24 hours after birth. If a particular fraction of the primary tumor can reconstitute retinoblastoma using the orthotopic xenograft approach, the tumor will be isolated, fractionated, and a serial transplant carried out.



**Fig. 66.5** Importance of p53 pathway in mouse retinoblastoma. Mice lacking Rb and p107 in the developing retina rarely develop aggressive invasive retinoblastoma and become moribund. However, when p53 is also inactivated, 100% of animals develop bilateral invasive retinoblastoma by 180 days and become moribund. Interestingly, similar mice with one wild-type allele of Rb have the same disease presentation but it takes longer (229 compared to 100.3 days).

### CLINICAL IMPLICATIONS

With the identification of the target for chemotherapy (MDMX and MDM2), researchers have been able to specifically activate p53 induced cell death in retinoblastoma cells with a small molecule inhibitor (nutlin-3a) of the MDMX-p53 and MDM2-p53 interaction.<sup>9</sup> By combining nutlin-3a with a topoisomerase inhibitor (topotecan) that induces a p53 DNA damage response, synergistic killing of retinoblastoma cells with MDMX amplifications was achieved.<sup>9</sup> In addition, by administering nutlin-3 and topotecan to the eye with subconjunctival

injections, the intraocular concentrations were sufficient to block MDMX and MDM2 from interacting with p53 that led to synergistic killing of retinoblastoma cells.<sup>18</sup> More importantly, this local delivery of targeted chemotherapy bypassed all of the toxicity associated with systemic administration of broad spectrum chemotherapy (etoposide, carboplatin, vincristin) that is widely used to treat retinoblastoma. Taken together, these data show how rapidly advances in treatment can be made when basic research in developmental neurobiology is combined with cancer genetics.



## REFERENCES

1. Hahn WC, Weinberg RA. Modelling the molecular circuitry of cancer. *Nat Rev Cancer* 2002; 2: 331–341.
2. Knudson A. Mutation and Cancer: statistical study of retinoblastoma. *PNAS* 1971; 68: 820–823.
3. Friend SH, Bernards R, Rogelj S, et al. A human DNA segment with properties of the gene that predisposes to retinoblastoma and osteosarcoma. *Nature* 1986; 323: 643–646.
4. Harbour JW, Lai SL, Whang-Peng J, Gazdar AF, Minna JD, Kaye FJ. Abnormalities in structure and expression of the human retinoblastoma gene in SCLC. *Science* 1988; 241: 353–357.
5. Lee EY, To H, Shew JY, Bookstein R, Scully P, Lee WH. Inactivation of the retinoblastoma susceptibility gene in human breast cancers. *Science* 1988; 241: 218–221.
6. Sherr CJ, McCormick F. The RB and p53 pathways in cancer. *Cancer Cell* 2002; 2: 103–112.
7. Windle JJ, Albert DM, O'Brien JM, et al. Retinoblastoma in transgenic mice. *Nature* 1990; 343: 665–669.
8. Howes KA, Ransom N, Papermaster DS, Lasudry JG, Albert DM, Windle JJ. Apoptosis or retinoblastoma: alternative fates of photoreceptors expressing the HPV-16 E7 gene in the presence or absence of p53. *Genes Dev* 1994; 8: 1300–1310.
9. Laurie NA, Donovan SL, Shih C-S, et al. Inactivation of the p53 Pathway in Retinoblastoma. *Nature* 2006; in press.
10. Chen D, Livne-Bar I, Vanderluit JL, Slack RS, Agochiya M, Bremner R. Cell-specific effects of RB or RB/p107 loss on retinal development implicate an intrinsically death-resistant cell-of-origin in retinoblastoma. *Cancer Cell* 2004; 5: 539–551.
11. Clarke AR, Maandag ER, van Roon M, et al. Requirement for a functional Rb-1 gene in murine development. *Nature* 1992; 359: 328–330.
12. Jacks T, Fazeli A, Schmitt EM, Bronson RT, Goodell MA, Weinberg RA. Effects of an Rb mutation in the mouse. *Nature* 1992; 359: 295–300.
13. Lee EY, Chang CY, Hu N, et al. Mice deficient for Rb are nonviable and show defects in neurogenesis and haematopoiesis. *Nature* 1992; 359: 288–294.
14. Robanus-Maandag E, Dekker M, van der Valk M, et al. p107 is a suppressor of retinoblastoma development in pRb-deficient mice. *Genes Dev* 1998; 12: 1599–1609.
15. Zhang J, Gray J, Wu L, et al. Rb regulates proliferation and rod photoreceptor development in the mouse retina. *Nat Genet* 2004; 36: 351–360.
16. Zhang J, Schweers B, Dyer MA. The first knockout mouse model of retinoblastoma. *Cell Cycle* 2004; 3: 952–959.
17. MacPherson D, Sage J, Kim T, Ho D, McLaughlin ME, Jacks T. Cell type-specific effects of Rb deletion in the murine retina. *Genes Dev* 2004; 18: 1681–1694.
18. Laurie NA, Gray JK, Zhang J, et al. Topotecan combination chemotherapy in two new rodent models of retinoblastoma. *Clin Cancer Res* 2005; 11: 7569–7578.
19. Dyer MA, Bremner R. The search for the retinoblastoma cell of origin. *Nat Rev Cancer* 2005; 5: 91–101.
20. Pardal R, Clarke MF, Morrison SJ. Applying the principles of stem-cell biology to cancer. *Nat Rev Cancer* 2003; 3: 895–902.
21. Lapidot T, Sirard C, Vormoor J, et al. A cell initiating human acute myeloid leukaemia after transplantation into SCID mice. *Nature* 1994; 367: 645–648.
22. Romer JT, Kimura H, Magdaleno S, et al. Suppression of the Shh pathway using a small molecule inhibitor eliminates medulloblastoma in Ptc1+/-, p53-/- mice. *Cancer Cell* 2004; 6: 229–240.
23. Coles BL, Angenieux B, Inoue T, et al. Facile isolation and the characterization of human retinal stem cells. *Proc Natl Acad Sci USA* 2004; 101: 15772–15777.
24. Tropepe V, Coles BL, Chiasson BJ, et al. Retinal stem cells in the adult mammalian eye. *Science* 2000; 287: 2032–2036.
25. Vooijs M, te Riele H, van der Valk M, Berns A. Tumor formation in mice with somatic inactivation of the retinoblastoma gene in interphotoreceptor retinal binding protein-expressing cells. *Oncogene* 2002; 21: 4635–4645.
26. Donovan S, Schweers B, Martins R, Johnson D, Dyer MA. Compensation by tumor suppressor genes during retinal development in mice and humans. *BMC Biol* 2006; 4: 14.
27. Nork TM, Schwartz TL, Doshi HM, Millecchia LL. Retinoblastoma. Cell of origin. *Arch Ophthalmol* 1995; 113: 791–802.
28. DiCiommo D, Gallie BL, Bremner R. Retinoblastoma: the disease, gene and protein provide critical leads to understand cancer. *Semin Cancer Biol* 2000; 10: 255–269.
29. Dyer MA, Cepko CL. Regulating proliferation during retinal development. *Nat Rev Neurosci* 2001; 2: 333–342.
30. Dyer MA, Rodriguez-Galindo C, Wilson MW. Use of preclinical models to improve treatment of retinoblastoma. *PLoS Med* 2005; 2: e332.
31. Kato MV, Shimizu T, Ishizaki K, et al. Loss of heterozygosity on chromosome 17 and mutation of the p53 gene in retinoblastoma. *Cancer Lett* 1996; 106: 75–82.
32. Nork TM, Poulsen GL, Millecchia LL, Jantz RG, Nickells RW. p53 regulates apoptosis in human retinoblastoma. *Arch Ophthalmol* 1997; 115: 213–219.
33. Vogelstein B, Kinzler KW. Cancer genes and the pathways they control. *Nat Med* 2004; 10: 789–799.

# Geographic and environmental factors

Greta R. Bunin and Manuela Orjuela

## INTRODUCTION

Retinoblastoma is the paradigm for the two-hit model of carcinogenesis.<sup>1</sup> From a genetic standpoint three forms may be considered: familial, sporadic heritable, and non-heritable (Fig. 67.1). In the discussion that follows, we use the proportions of retinoblastomas of each form seen in industrialized countries. In developing countries, non-heritable retinoblastoma accounts for a larger proportion.

**Familial retinoblastoma** Ten percent of children with retinoblastoma inherit an *RB1* gene mutation from a parent. In this circumstance the condition is referred to as familial retinoblastoma. Every cell in the body of these children contains an *RB1* gene mutation – the ‘first hit.’<sup>2</sup> The mutation to the other copy of the *RB1* gene, the ‘second hit,’ occurs in a retinal cell some time after conception. The inherited gene mutation is highly penetrant and nearly all (about 95%) of such children develop retinoblastoma.

**Sporadic heritable retinoblastoma** Another 30% of children with retinoblastoma also harbor an *RB1* mutation in all of their cells and are at the same risk for developing retinoblastoma as children who inherit a mutation. However, these children do not have a parent with the mutation. Rather, their *RB1* mutation occurred as a new germline mutation. Although these children did not inherit the gene from an affected parent, they will be able to pass the mutation on to their own children. This is called sporadic heritable retinoblastoma.

**Non-heritable retinoblastoma** The remaining 60% of retinoblastoma patients have non-heritable disease. Their retinoblastoma develops as the result of two somatic *RB1* mutations that occur in a single cell some time after conception.

## INCIDENCE RATES

**Unilateral and bilateral retinoblastoma** The vast majority of children with familial or sporadic heritable retinoblastoma develop bilateral disease, but 10–15% have unilateral disease.<sup>3</sup> All non-heritable retinoblastomas are unilateral. Incidence rates would be most informative if they were available for the three subtypes of retinoblastoma. However, they are generally available only for retinoblastoma overall, with rates by laterality available only for selected countries. As explained above, bilateral retinoblastoma includes most instances of familial and sporadic heritable disease, whereas the vast majority of unilateral disease is non-heritable retinoblastoma. Therefore, bilateral rates can be interpreted as reflecting the incidence of heritable retino-

blastoma (familial and sporadic heritable combined) and unilateral rates as reflecting non-heritable disease. In the only report of international variation in incidence by laterality, the incidence of unilateral disease was observed to vary markedly, much more so than bilateral disease.<sup>4</sup>

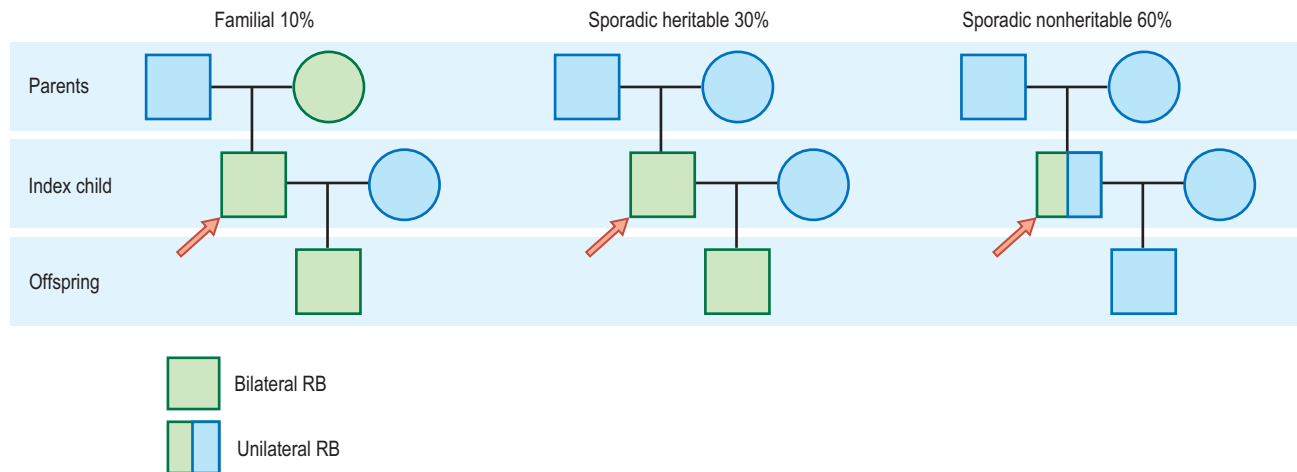
**Expression of incidence rates** Because 95% of cases are diagnosed under the age of 5 years, incidence rates are better expressed as ‘per million children 0–4 years of age,’ than as ‘per million children 0–14 years of age,’ as is common for other childhood cancers. In the discussion that follows we present rates for children aged 0–4 years whenever the data are available.

## GEOGRAPHIC VARIATION IN INCIDENCE

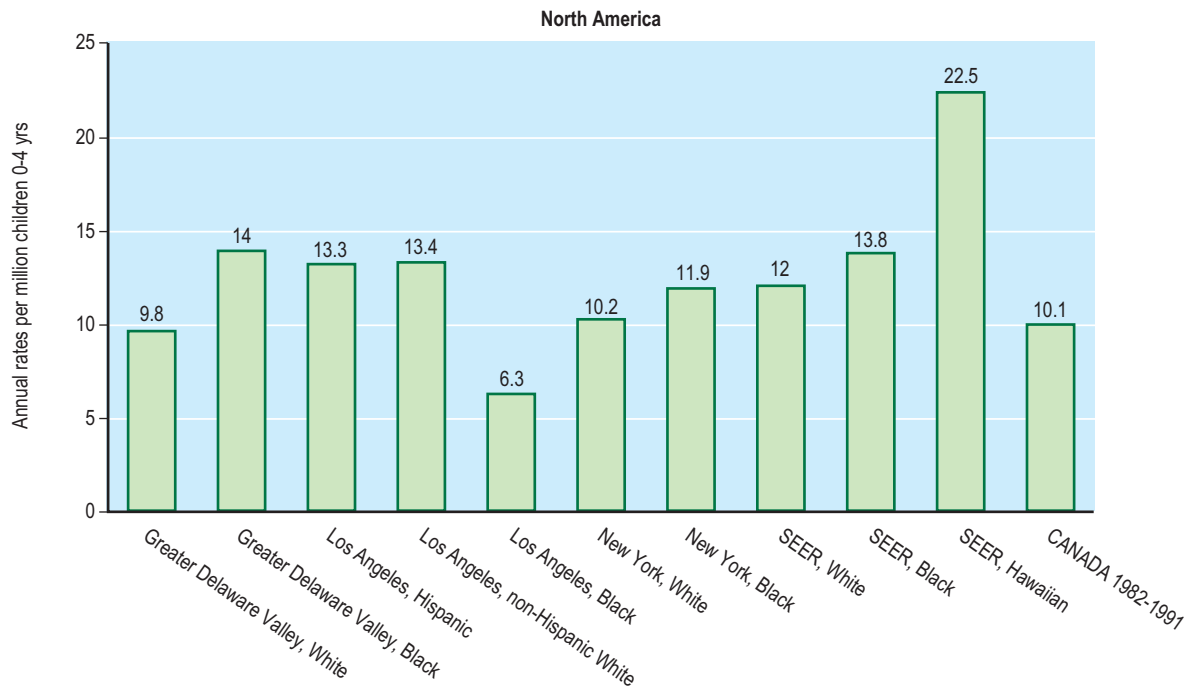
Variations in incidence among countries, regions, and ethnic groups or over time can provide clues to etiology. Environmental (defined here as non-genetic) factors are implicated in cancers that show a great variation in incidence.

The rates of retinoblastoma vary about 50-fold across continents,<sup>5</sup> a degree of variability higher than that for several adult cancers, namely stomach, colon, cervical and pancreatic cancer, and lower than that for lung and esophageal cancer, among others. The incidence in North America and much of Europe is relatively uniform, is somewhat higher in Central and South America, and varies more widely in Asia and Africa.<sup>5</sup> Overall, the rates are higher in less industrialized than in more industrialized countries. In addition, there are enormous variations within certain countries. The data suggest variation by economic development, with higher rates in poorer regions of countries such as Brazil and Mexico.<sup>6</sup> Clearly, the differences in incidence rates may be due to other factors, such as ethnic origin, genetic susceptibility, and cultural and behavioral practices. A closer examination of the differences in incidence may identify specific risk factors for the development of retinoblastoma.

**North America** The incidence of retinoblastoma in the United States did not change significantly between 1975 and 1995.<sup>7</sup> Annual rates by race/ethnicity and region generally range from 10 to 14 per million children aged 0–4 years (Fig. 67.2). Incidence rates were generally higher for African-Americans than for their white neighbors.<sup>5</sup> For African-Americans in Los Angeles the incidence was lower and for native Hawaiians was higher, but these rates are based on small numbers of affected children and are therefore imprecise.<sup>5</sup>



**Fig. 67.1** Three genetic forms of retinoblastoma. The vast majority of familial and sporadic heritable retinoblastomas are bilateral. However, 10–15% are unilateral. Arrow indicates the index child or proband, with the indicated form of retinoblastoma. Males are indicated as squares and females as circles. A horizontal line connects the mother and father and a vertical line connects parents and offspring. The sex of the affected individuals is shown, although it is not relevant. Changing the sex of each affected individual would not change the accuracy of this figure.



**Fig. 67.2** Incidence of retinoblastoma in North America in children aged 0–4 years. Data derived from Parkin DM, Kramarova E, Draper GJ et al. International incidence of childhood cancer. Lyon, France: International Agency for Research on Cancer, 1998.

**Europe** In Europe there is some variability in incidence (data not shown). Most countries have incidences in the range of 6–12 per million per year in children aged 0–4. However, there are a few notable exceptions. Bulgaria has a very low incidence (3.4 per million per year), whereas the province of Valencia in Spain (but not other regions in Spain) has the highest incidence in the whole of Europe, followed by Norway, Denmark, and Scotland (but not England and Wales).<sup>5</sup> Although many of the registries have small numbers of cases, these differences within Europe are intriguing and do not appear to follow an easily discernible pattern.

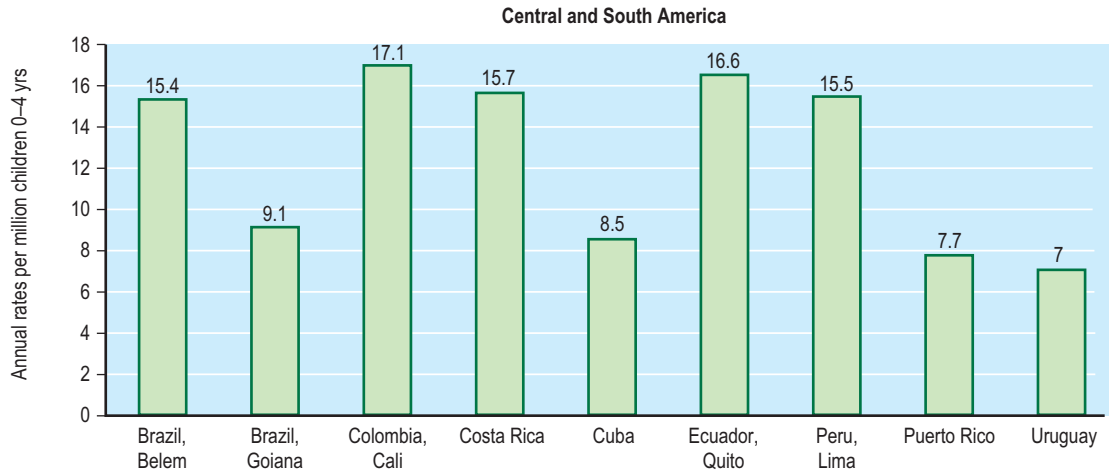
**Central and South America** Population-based registries do not exist for all countries in Central and South America, and for some countries rates are only available within selected cities (Fig. 67.3).

However, even with these limitations there appear to be two groups in Central and South America, those regions with an incidence under 9.5 per million per year in children aged 0–4, and those with an incidence higher than 15 per million per year.<sup>5</sup>

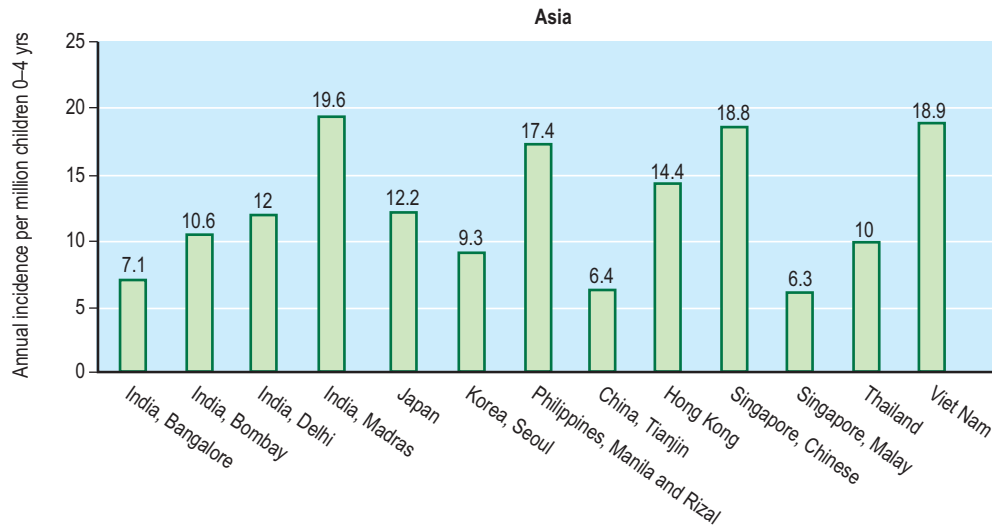
**Asia** Incidence also varies greatly in Asia (Fig. 67.4).<sup>5</sup> The highest rate is found in Madras (Chennai), India, whereas rates in the rest of India are much lower. The lowest incidence in Asia is found among Malays in Singapore, whereas Chinese in Singapore have the third highest rates in the continent. Notably, Chinese living in China have the second lowest incidence in the region.

**Africa** In Africa, where there are few population-based registries, incidence is also quite variable (Fig. 67.5).<sup>5</sup> In sub-Saharan Africa the

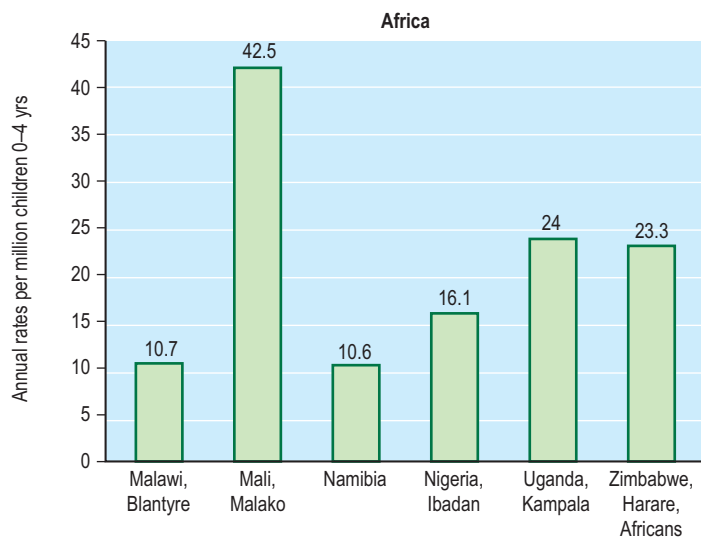




**Fig. 67.3** Incidence of retinoblastoma in Central and South America in children aged 0-4 years. Data derived from Parkin DM, Kramarova E, Draper GJ et al. International incidence of childhood cancer. Lyon, France: International Agency for Research on Cancer, 1998.



**Fig. 67.4** Incidence of retinoblastoma in Asia in children aged 0-4 years. Data derived from Parkin DM, Kramarova E, Draper GJ et al. International incidence of childhood cancer. Lyon, France: International Agency for Research on Cancer, 1998.



**Fig. 67.5** Incidence of retinoblastoma in Africa in children aged 0-4 years. Data derived from Parkin DM, Kramarova E, Draper GJ et al. International incidence of childhood cancer. Lyon, France: International Agency for Research on Cancer, 1998.

incidence is much higher than in North Africa. In the Middle East (including Israel) and North Africa the incidence is low and fairly uniform, ranging from 1.4 to 5.2 per million per year in children aged 0–4. However, even within the higher rates of sub-Saharan Africa there is wide variability, with the highest rates in West Africa, and generally lower rates in the central and southern regions of the continent. It is noteworthy that the highest rate worldwide is in Bamako, Mali, one of the least economically developed urban centers in Africa.

**Oceania** The incidence rate in Australia is similar to that in the United States and Canada (Fig. 67.6).<sup>5</sup> The incidence in New Zealand, although higher than that in Australia, is similar in Maori and non-Maori populations.

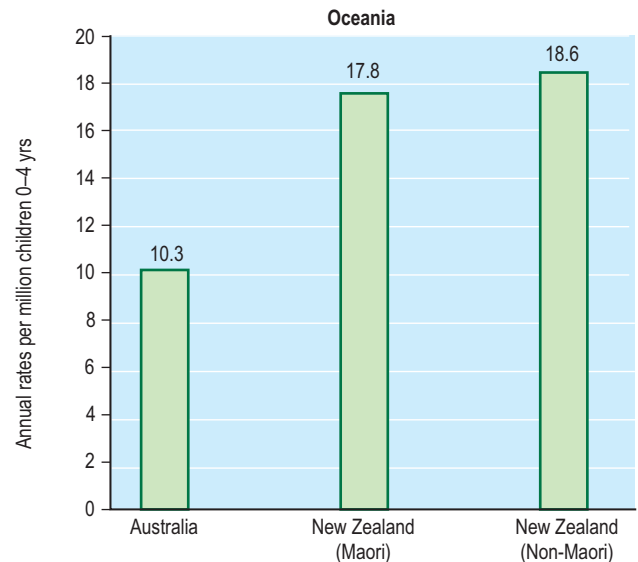
### INCIDENCE BY SEX

Males and females in most countries of the world have similar incidence rates.<sup>5</sup> Interestingly, in almost every Central and South American country, girls have an elevated incidence compared to their male counterparts (Fig. 67.7).

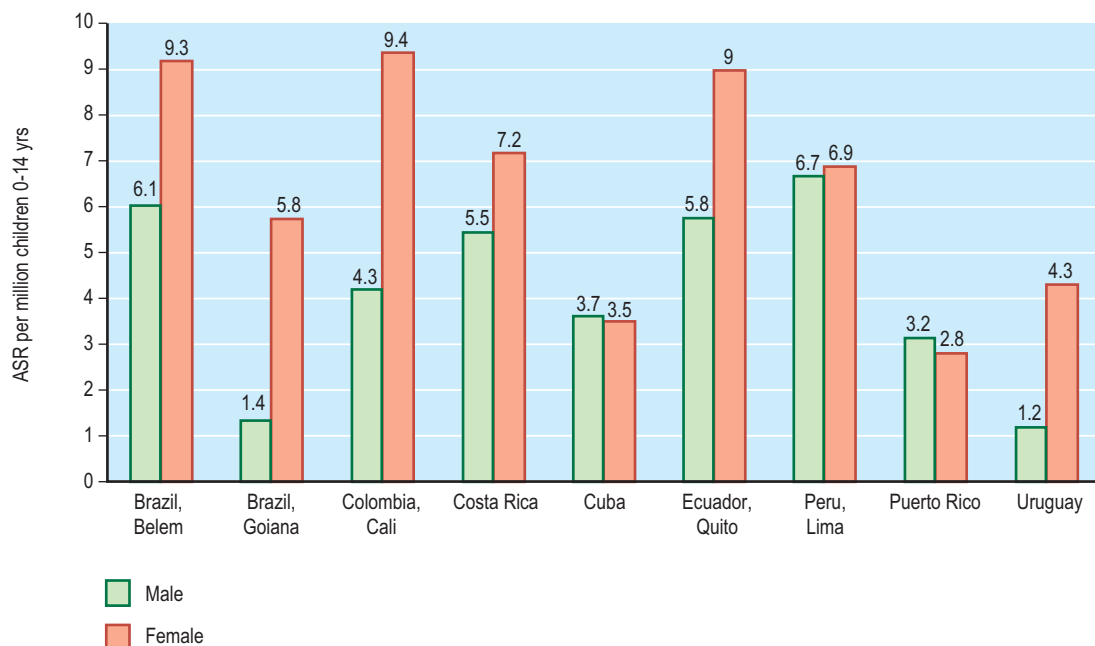
### ENVIRONMENTAL AND BEHAVIORAL RISK FACTORS

To summarize the extent of variation, it is useful to consider the areas with the highest incidence worldwide.<sup>5</sup> The highest incidence of retinoblastoma is noted in Mali (Bamako), followed by (in descending order) Uganda (Kampala); Zimbabwe (African ancestry); Hawaii (native Hawaiians); India (Chennai); Vietnam (Hanoi), the Chinese population of Singapore; New Zealand (essentially equal rates among non-Maoris and Maoris); Spain (Valencia); the Philippines; Colombia (Cali); Ecuador (Quito); Nigeria (Ibadan); Costa Rica; Peru (Lima); Norway; Brazil (Belem); and Denmark (Table 67.1). All of these populations have annual incidences above 15 cases per million children aged 0–4 years. Some global differences are particularly intriguing

or paradoxical, given expected similarities in ethnicity and presumed shared environmental exposures: for example, that Australia and New Zealand have very different rates which cannot be explained by ethnic differences; that one province in Spain has rates much higher than the rest of Europe, higher even than Spain's former colonies (i.e. the Philippines, Latin America), many of whom also have high rates; that some Scandinavian countries (but not Sweden) have rates equivalent to those of Northern Brazil (where a large proportion of the population is of African not European ancestry); that the Chinese in



**Fig. 67.6** Incidence of retinoblastoma in Oceania in children aged 0–4 years. Data derived from Parkin DM, Kramarova E, Draper GJ et al. International incidence of childhood cancer. Lyon, France: International Agency for Research on Cancer, 1998.



**Fig. 67.7** Comparison of age standardized rates (ASR) for retinoblastoma for boys and girls aged 0–14 years in Latin America. Data derived from Parkin DM, Kramarova E, Draper GJ et al. International incidence of childhood cancer. Lyon, France: International Agency for Research on Cancer, 1998.

**Table 67.1 Regions with a high incidence of retinoblastoma**

Country (registry/ethnicity)	Incidence*
Mali (Bamako)	42.5
Uganda (Kampala)	24.0
Zimbabwe (African ancestry)	23.3
Hawaii (native Hawaiians)	22.5
India (Chennai)	19.6
Vietnam (Hanoi)	18.9
Singapore (Chinese)	18.8
New Zealand (non-Maori)	18.6
New Zealand (Maori)	17.8
Spain (Valencia)	17.8
Philippines	17.4
Colombia (Cali)	17.1
Ecuador (Quito)	16.6
Nigeria (Ibadan)	16.1
Costa Rica	15.7
Peru (Lima)	15.5
Norway	15.4
Brazil (Belem)	15.4
Denmark	15.3

\*Annual incidence per million children aged 0–4 years.

Singapore have a much higher rate than Malays in Singapore, or Chinese in China or Hong Kong. There is no clear pattern, but there is a suggestion that environmental factors may play a role, though genetic susceptibility to particular environmental and behavioral risk factors may explain some of the differences.

### ETIOLOGICAL FACTORS FOR SPORADIC HERITABLE RETINOBLASTOMA

Sporadic heritable retinoblastoma results from a new germline mutation, which in over 90% of patients is of paternal origin.<sup>8,9</sup> Because the germline mutation is new, it occurs before the child is conceived. Based on these two facts, the search for genetic and non-genetic risk factors for sporadic heritable retinoblastoma should focus on the father's genes and his exposures before the child's conception.<sup>10</sup> It would be reasonable to hypothesize preconception exposure to mutagens, variants of metabolizing genes that prolong the duration or increase the level of a mutagen in the body, and variants of DNA repair genes that result in less efficient repair of DNA damage as possible risk factors.

Only a few epidemiologic studies have investigated possible risk factors for new germline mutations. Moreover, such studies have been limited in scope, mostly focusing on paternal age. The cohort studies of children of cancer survivors and of atomic bomb survivors have limited power to detect anything but large effects.

**Advanced paternal age** A number of studies have examined paternal age in relation to sporadic heritable retinoblastoma, with a wide range of results.<sup>11–14</sup> In the largest, most methodologically sound studies the observed paternal age difference between those with retinoblastoma and the general population was about 1 year. This is much

smaller than the difference of 4–10 years observed in achondroplasia<sup>15,16</sup> and the 2–5 years observed for Apert's syndrome,<sup>17,18</sup> genetic conditions for which a paternal age effect is well established. Increased risk with greater paternal age has been explained by the fact that the stem cells that give rise to sperm are continuously dividing. Thus, the stem cells of an older man are more likely than those of a younger man to have sustained a mutation arising from an error during DNA replication.<sup>19</sup> The number of cell divisions between stem cell and mature sperm is estimated to be 197 at age 20, 427 at age 30, and 772 at age 45.<sup>20</sup> Although the explanation about the increasing number of cell divisions at older ages might be expected to apply to all conditions due to a new germline mutation, for reasons unknown a paternal age effect is observed in only some of these conditions.

Overall, the evidence for a paternal age effect on sporadic heritable retinoblastoma is not convincing. Data on possible other risk factors are almost non-existent. In a study with 67 patients and the same number of controls, employment of the father in metal manufacturing industries prior to the child's conception was significantly associated with the disease.<sup>21</sup> Elevated but non-significant risks were observed for other exposures of the father's: smoking; diagnostic X-rays with gonadal exposure prior to the child's conception;<sup>22</sup> and occupational exposure to welding fumes.<sup>21</sup>

**Germline mutagens in animals** It is well established that exposure to some substances increases the frequency of germline mutations in animals. Toxicologists have developed methods for testing effects on germline mutation, although only a small number of chemicals have been tested compared to the number tested for carcinogenicity. Agents that induce mutation in male germ cells include radiation and commonly used chemotherapeutic agents such as cyclophosphamide.<sup>10</sup>

**Cancer survivors** have been studied, as they are often treated with radiation and/or mutagenic drugs. Altogether, perhaps 4000–5000 offspring of cancer survivors have been studied, and no strong evidence of a higher incidence of conditions thought to be the result of germline mutations has been observed.<sup>23–25</sup> However, the strength of the negative data is less than it first appears. Because most new germline mutations appear to occur on the father's gene, we would expect any effect to be much stronger in the children of male rather than female survivors. Therefore, studies should focus on males, or at least analyze the offspring of males and females separately. In addition, many of the cancer survivors studied may not have received highly mutagenic therapy, such as radiation exposure to the gonads. Therefore, the number of male survivors with exposure to possible germline mutagens that have been studied is perhaps too small to observe an effect.

**Studies of atomic bomb survivors** The survivors of the atomic bombings in Japan have also been studied for evidence of new germline mutations. This cohort experienced very high exposure to a known germline mutagen, ionizing radiation. The study of thousands of pregnancies in exposed individuals has found no increased risk of a variety of outcomes possibly related to germline mutation.<sup>26</sup> Many scientists believe that as the extraordinary exposure to the atomic bombs did not result in a detectable effect on the children born to survivors, no ordinary exposure is likely to induce an increase in new germline mutations. However, despite the large size of the cohort, its statistical power to detect an increase in the few conditions known to



be caused by new germline mutations is low. For example, sporadic heritable retinoblastoma occurs in about 1 in 60 000 births. In addition, congenital anomalies and genetic conditions were not studied in those conceived in the first 18 months after the bombings, and an early excess in those conditions would have been missed. Thus, the evidence from the atomic bomb survivors does not entirely rule out an effect of radiation on new germline mutations, such as those resulting in sporadic heritable retinoblastoma.

### ETIOLOGICAL FACTORS FOR NON-HERITABLE RETINOBLASTOMA

Non-heritable retinoblastoma occurs as a result of somatic mutation. The child does not have a germline *RB1* mutation; rather, both copies of the *RB1* gene are inactivated in a single developing retinal cell. As the mutations are somatic, they must occur after the child's conception, during either gestation or early postnatal life. Therefore, the search for risk factors should focus on exposures of the mother that would affect the child in utero and of the child after birth. The data on such possible risk factors for non-heritable retinoblastoma are very limited. Most of the findings have not yet been replicated and cannot be considered conclusive. Rather, the studies provide clues to be pursued by replication and extension of the original findings.

**Environmental exposure** The mother's use of insect or garden sprays during pregnancy, diagnostic X-ray with direct fetal exposure, and father's employment as a welder, machinist, or related metal worker have been associated with an increased risk of non-heritable retinoblastoma.<sup>22,27</sup>

### Maternal diet and/or vitamin intake during pregnancy

The limited evidence suggests a role for diet and/or use of multi-vitamin supplements during pregnancy. In a case-control study in central Mexico, lower intake of vegetables and fruits during pregnancy was associated with increased risk of retinoblastoma in the child.<sup>28</sup> Another study found that multivitamin use in the first trimester appeared to decrease the risk of (non-heritable) retinoblastoma in the child. These findings suggest that gestational intake of one or more nutrients may influence risk. Folate and lutein/zeaxanthine have been suggested as possibly protective, as they are necessary for DNA methylation, synthesis, and/or retinal function.<sup>28</sup>

**In vitro fertilization (IVF)** A study in The Netherlands estimated that children born after in vitro fertilization (IVF) had a 5–7-fold increased risk of retinoblastoma;<sup>29</sup> results were not reported by form of retinoblastoma. However, studies in birth cohorts of children born after IVF in the UK, Denmark, and Australia observed no increase in the incidence of retinoblastoma.<sup>30–32</sup>

**Maternal infection with human papillomavirus** Some viral proteins bind to and inactivate the retinoblastoma protein that is coded for by *RB1*, and thus it is hypothesized that these viruses may contribute to the development of retinoblastoma. One such viral protein is the human papillomavirus (HPV) protein, E7. In support of the viral hypothesis, DNA sequences from oncogenic HPV subtypes were detected in approximately one-third of retinoblastoma tumors studied in central Mexico.<sup>33</sup> In southern Brazil and northern Mexico, oncogenic HPV sequences were seen in similar proportions of retinoblastoma tumors.<sup>34,35</sup> The oncogenic HPV subtypes found – 16, 18, 31, 33, 35, and 51 – are causally associated with cervical cancer. Detection of HPV sequences in Central and South American tumor samples is particularly intriguing, given the finding that the use of barrier methods of contraception around the time of conception was associated with lower risk of having a child with retinoblastoma.<sup>22</sup>

### SUMMARY

Although the molecular etiology of retinoblastoma is well understood, our knowledge of the role of exposure in both parents and child is very limited. The international variation in incidence suggests that non-genetic risk factors for the development of retinoblastoma may exist. The findings of the few studies that have investigated possible risk factors provide clues for further research. Based on our molecular understanding of the disease, we can identify the critical period (before rather than after conception) and the family member in which the critical event occurred (father, mother, or child) for sporadic heritable and non-heritable retinoblastoma. Epidemiological studies should be designed that recognize the distinction between the three forms of retinoblastoma and investigate events that surround the critical period in the individuals at risk. Such studies will improve our knowledge of possible risk factors and could lead to the prevention of retinoblastoma.

### REFERENCES

1. Knudson AG. Mutation and cancer: statistical study of retinoblastoma. *PNAS* 1971; 68: 820–823.
2. Friend SH, Bernards R, Rogelji S et al. A human DNA segment with properties of the gene that predisposes to retinoblastoma and osteosarcoma. *Nature* 1986; 323: 643–646.
3. Richter S, Vandezande K, Chen N et al. Sensitive and efficient detection of *RB1* gene mutations enhances care for families with retinoblastoma. *Am J Hum Genet* 2003; 72: 253–269.
4. Stiller CA, Parkin DM. Geographic and ethnic variations in the incidence of childhood cancer. *Br Med Bull* 1996; 52: 682–703.
5. Parkin DM, Kramarova E, Draper GJ et al. International incidence of childhood cancer. Lyon, France: International Agency for Research on Cancer, 1998.
6. Bravo-Ortiz J, Mendoza-Sanchez H, Fajardo Guttierrez A. Algunas características epidemiológicas del retinoblastoma en niños residentes del Distrito Federal. *Boletín Médico del Hospital Infantil de México* 1996; 53: 234–239.
7. Ries LAG, Smith MA, Gurney JG et al. Cancer incidence and survival among children and adolescents: United States SEER Program 1975–1995. NIH Pub. No. 99–4649 ed. Bethesda, Maryland: National Cancer Institute, 1999.
8. Kato MV, Ishizaki K, Shimizu T et al. Parental origin of germ-line and somatic mutations in the retinoblastoma gene. *Hum Genet* 1994; 94: 31–38.
9. Dryja TP, Mukai S, Rapaport JM, Yandell DW. Parental origin of mutations of the retinoblastoma gene. *Nature* 1989; 339: 556–558.
10. Allen JW, Ehling UH, Moore MM, Lewis SE. Germline specific factors in chemical mutagenesis. *Mutat Res* 1995; 330: 219–231.
11. Pellie C, Briard M-L, Feingold J, Freza J. Parental age in retinoblastoma. *Humangenetik* 1973; 20: 59–62.
12. Moll AC, Imhof SM, Kuik J et al. High parental age is associated with sporadic hereditary retinoblastoma: the Dutch Retinoblastoma Register 1862–1994. *Hum Genet* 1996; 98: 109–112.
13. Matsunaga E, Minoda K, Sasaki MS. Parental age and seasonal variation in the births of children with sporadic retinoblastoma: a mutation-epidemiologic study. *Hum Genet* 1990; 84: 155–158.
14. Czeizel A, Gardonyi J. Retinoblastoma in Hungary, 1960–1968. *Humangenetik* 1974; 22: 153–158.
15. Orioli IM, Castilla EE, Scarano G, Mastroiacovo P. Effect of paternal age in achondroplasia, thanatophoric dysplasia, and osteogenesis imperfecta. *Am J Med Genet* 1995; 59: 209–217.

16. Morch ET. Chondrodystrophic dwarfs in Denmark. Copenhagen, Denmark: Ejnar Munksgaard, 1941.
17. Moloney DM, Slaney SF, Oldridge M et al. Exclusive paternal origin of new mutations in Apert Syndrome. *Nature Genet* 1996; 13: 48–53.
18. Blank CE. Apert's syndrome (a type of acrocephalosyndactyly) – observations on a British series of thirty nine cases. *Ann Hum Genet* 1960; 24: 151–164.
19. Vogel F, Rathenberg R. Spontaneous mutation in man. *Adv Hum Genet* 1975; 5: 223–318.
20. Woodall AA, Ames BN. Nutritional prevention of DNA damage to sperm and consequent risk reduction in birth defects and cancer in offspring. In: Bendich A, Deckelbaum RJ, eds. *Preventive nutrition. The comprehensive guide for health professionals*. Totowa, NJ: Humana Press, 1997; 373–385.
21. Bunin G, Petrakova A, Meadows A et al. Occupations of parents of children with retinoblastoma: a report from the Children's Cancer Study Group. *Cancer Res* 1990; 50: 7129–7133.
22. Bunin GR, Meadows AT, Emanuel BS et al. Pre- and post-conception factors associated with heritable and non-heritable retinoblastoma. *Cancer Res* 1989; 49: 5730–5735.
23. Hawkins MM. Is there evidence of a therapy-related increase in germ cell mutation among childhood cancer survivors? *J Natl Cancer Inst* 1991; 83: 1643–1650.
24. Li FP, Fine W, Jaffe N, Holmes GE, Holmes FF. Offspring of patients treated for cancer in childhood. *J Natl Cancer Inst* 1979; 62: 1193–1197.
25. Senturia YD, Peckham CS, Peckham MJ. Children fathered by men treated for testicular cancer. *Lancet* 1985; 2: 766–769.
26. Olshan AF, Ananth CV, Savitz DA. Intrauterine growth retardation as an endpoint in mutation epidemiology: an evaluation based on paternal age. *Mutat Res* 1995; 344: 89–94.
27. Bunin GR, Nass CC, Kramer S, Meadows AT. Parental occupation and Wilms' tumor: results of a case-control study. *Cancer Res* 1989; 49: 725–729.
28. Orjuela MA, Titievsky L, Liu X et al. Fruit and vegetable intake during pregnancy and risk for development of sporadic retinoblastoma. *Cancer Epidemiol Biomarkers Prev* 2005; 14: 1433–1440.
29. Moll AC, Imhof SM, Cruysberg JR et al. Incidence of retinoblastoma in children born after in-vitro fertilization. *Lancet* 2003; 361: 309–310.
30. Bradbury BD, Jick H. In vitro fertilization and childhood retinoblastoma. *Br J Clin Pharmacol* 2004; 58: 209–11.
31. Lidegaard O, Pinborg A, Andersen AN. Imprinting diseases and IVF: Danish National IVF cohort study. *Hum Reprod* 2005; 20: 950–954.
32. Bruinsma F, Venn A, Lancaster P, Speirs A, Healy D. Incidence of cancer in children born after in-vitro fertilization. *Hum Reprod* 2000; 15: 604–607.
33. Orjuela M, Ponce Castaneda V, Ridaura C et al. Presence of human papilloma virus in tumor tissue from children with retinoblastoma: an alternative mechanism for tumor development. *Clin Cancer Res* 2000; 6: 4010–4016.
34. Montoya-Fuentes H, de la Paz Ramirez-Munoz M, Villar-Calvo V et al. Identification of DNA sequences and viral proteins of 6 human papillomavirus types in retinoblastoma tissue. *Anticancer Res* 2003; 23: 2853–2862.
35. Palazzi MA, Yunes JA, Cardinalli IA et al. Detection of oncogenic human papillomavirus in sporadic retinoblastoma. *Acta Ophthalmol Scand* 2003; 81: 396–398.

# Retinoblastoma: an international perspective

Guillermo L. Chantada and Carlos Leal-Leal

## INTRODUCTION

Retinoblastoma represents a challenge in developing countries. Whereas in affluent societies more than 90% of affected children survive, many fewer children living in developing nations outlive this disease. In this chapter we review some aspects of retinoblastoma management, such as incidence, delayed diagnosis, barriers to optimal treatment, and poor survival in developing countries (Box 68.1).

## INCIDENCE

In the previous chapter (Chapter 67), Bunin and Orjuela introduced evidence that the incidence of non-heritable retinoblastoma may be higher in some developing countries, especially among the poorer populations. The highest incidence of retinoblastoma has been reported in tropical Brazil and Namibia.<sup>1,2</sup> Retinoblastoma was also found to be more frequent in the native population from Alaska.<sup>3</sup> As reliable data on cancer incidence in many developing countries are usually lacking, these findings should be confirmed in larger, properly designed, population-based studies.

There is no sound explanation for this probable increased incidence. These authors suggest that variations in incidence may be due to environmental factors. Orjuela et al.<sup>4</sup> detected sequences of the human papillomavirus (HPV) in enucleation specimens from patients with retinoblastoma in Mexico. Even though a direct effect on human retinoblastoma tumorigenesis is still to be proven, this finding is provocative, as HPV infection is more common in many areas of the world where retinoblastoma is presumed to be more prevalent. Further study will shed light on this intriguing finding. Low intake of fruits and vegetables during pregnancy also correlates with a higher risk of having a child with sporadic non-heritable retinoblastoma in Mexico.<sup>5</sup>

## CLINICAL FEATURES

**Presenting signs of retinoblastoma** vary depending where in the world the affected child lives (Fig. 68.1). Strabismus, a presenting sign in 20% of children in the United States, is not recognized as a presenting sign in central Africa.<sup>6,7</sup> Proptosis due to orbital extension of retinoblastoma, which is rarely a presenting sign of retinoblastoma in the United States, is the second most common sign in the Congo.<sup>6,7</sup> In a Brazilian study, patients who presented with strabismus had a longer delay between the onset of signs and diagnosis than did those who presented with leukocoria, suggesting that the pediatrician's index of suspicion for retinoblastoma is low for patients with strabismus.<sup>8</sup> In addition, patients with proptosis had a shorter lag time

between onset of symptoms and diagnosis. This may reflect the fact that long-standing leukocoria in a child may have been unnoticed by parents and physicians until orbital extension occurred.<sup>8</sup>

An intermediate situation is observed in countries such as Mexico, Argentina, and some parts of India, where leukocoria is the most common presenting sign. Moreover, overt extraocular disease is relatively uncommon, but patients still present with advanced intraocular disease as evidenced by choroidal or optic nerve invasion.<sup>8-11</sup>

**Extraocular retinoblastoma at presentation** There is evidence that retinoblastoma presents more frequently with extraocular dissemination in developing countries (Fig. 68.2). Delayed diagnosis is implicated as a major factor leading to extraocular dissemination and subsequent metastasis. In a Brazilian cohort with metastatic disease, the lag time between onset of symptoms and diagnosis was 10 months,<sup>8</sup> compared to about 6 months in all cases.<sup>12</sup>

## DELAYED DIAGNOSIS

Delayed diagnosis is a complex phenomenon in which several patient- and physician-related factors and socioeconomic factors play a role.

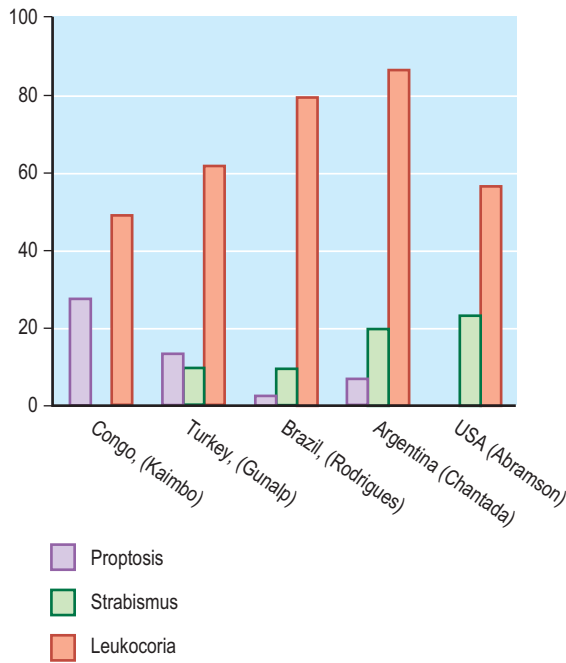
**Patient-related factors** include the lack of symptoms of retinoblastoma in young children, who are unable to express visual disturbances, together with the lack of awareness of the general population that ocular abnormalities such as strabismus and leukocoria may be signs of cancer.

**Physician-related factors** Invariably, parents or other family members are the first to notice the visual abnormality. Pediatricians are frequently the first physicians to evaluate the affected child. It is rare for the pediatrician to detect leukocoria because of limited ophthalmic examination with undilated pupil. Therefore, they rarely recognize the significance of the parents' complaints. As a result, many patients are not diagnosed or referred to an ophthalmologist on the first visit to the pediatrician.<sup>12</sup> In a large cohort from Mexico, a INCTR (The International Network for Cancer Treatment and Research [www.inctr.org])-funded study confirmed that in up to 10% of cases the diagnosis of retinoblastoma was suspected but parents were not adequately informed (Fig. 68.3).<sup>13</sup> All these factors add critical weeks or months to the delay in diagnosis of retinoblastoma (Fig. 68.4).



**BOX 68.1 Retinoblastoma in Developing Countries**

- Incidence may be higher
- Advanced intraocular disease at presentation
- Extraocular disease at presentation
- Delayed diagnosis
- Existence of several barriers to optimal delivery of care
- Poor survival rate
- International collaborative efforts are necessary to improve the survival



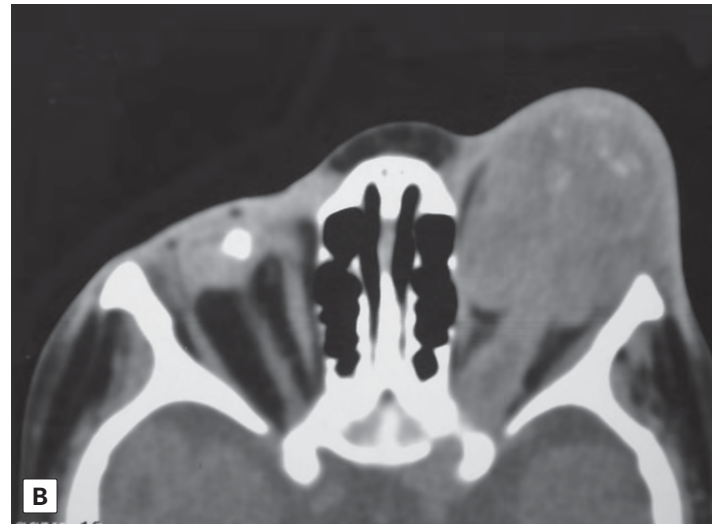
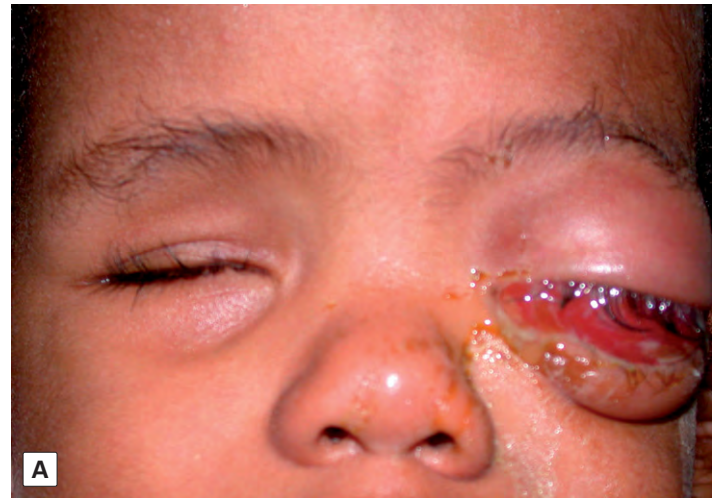**Fig. 68.1** Comparison of presenting signs of patients with retinoblastoma in different countries.

**Socioeconomic factors** Studies from Latin America, Asia, and Africa demonstrate that socioeconomic factors such as parental education, lack of health insurance, and living in villages remote from large cities are significant risk factors for systemic dissemination of disease.<sup>8,12,13</sup> Unfortunately, there is a direct correlation between advanced retinoblastoma and poverty.<sup>14</sup>

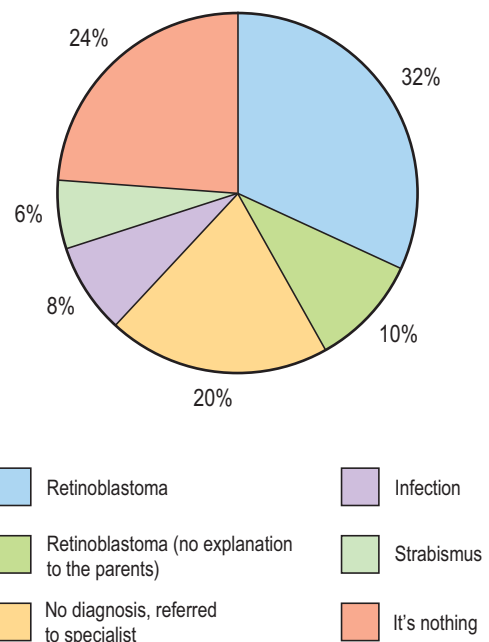
**SURVIVAL**

**Survival with retinoblastoma is lower in developing countries** Survival rates lower than 50% have been reported in some Latin American and African countries. As more than 80% of the world’s children live in developing countries, globally there may be more children dying of retinoblastoma than surviving.

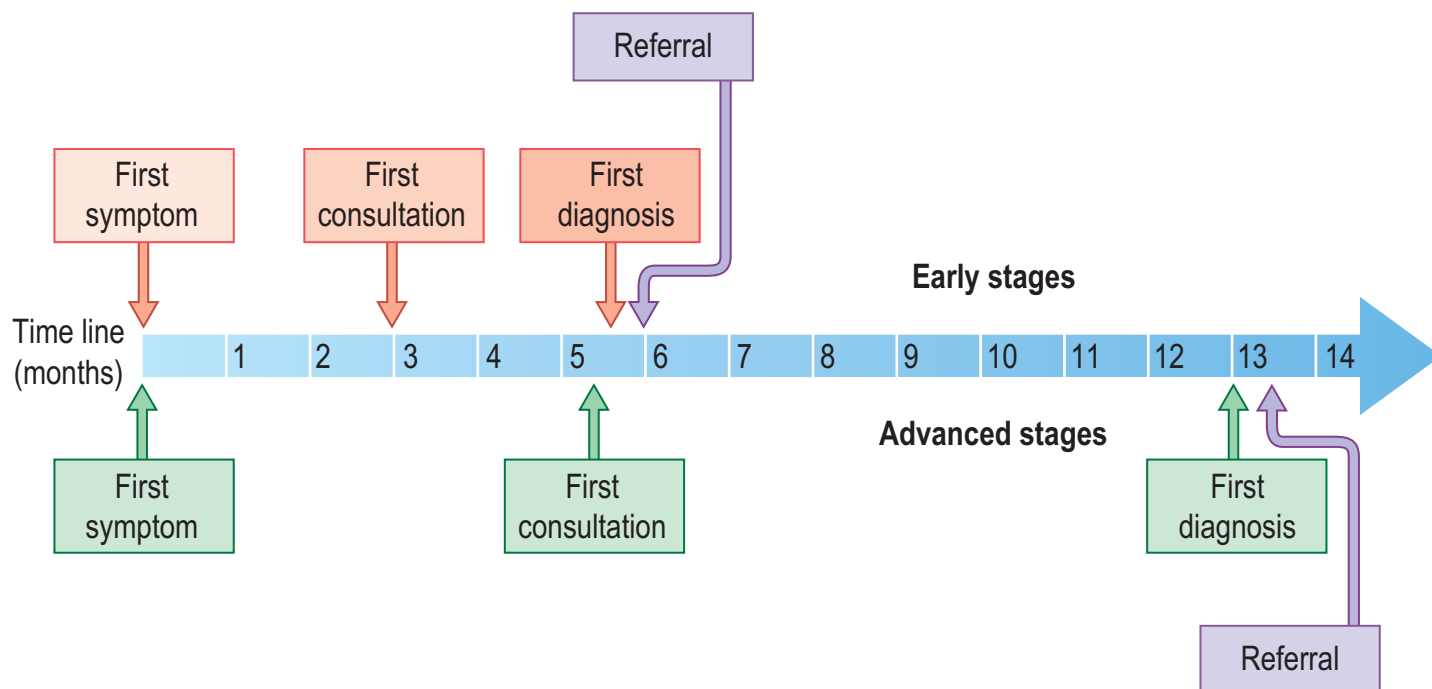
**Steps to improve survival** An improvement in the survival of retinoblastoma patients in developing countries should not depend on better treatment for extraocular disease. Rather, early detection and diagnosis, with a consequent reduction in systemic dissemination, is expected to improve the overall survival rate. A coordinated multi-step approach involving public education, professional education,



**Fig. 68.2** Patient with bilateral retinoblastoma and overt extraocular extension OS (A) which is confirmed by computed tomography (B).



**Fig. 68.3** Action taken by the pediatrician or ophthalmologist after the first consultation of a patient with retinoblastoma in Mexico.



**Fig. 68.4** Schematic representation of the diagnostic pathway of children with retinoblastoma in Mexico according to the disease extension.

screening, and socioeconomic development is necessary. To be effective, resources must also be aimed at reducing the probability of treatment refusal.

**Public education programs** In order to address this public health problem, some developing countries have embarked on public education programs about the signs and symptoms associated with retinoblastoma. One of the earliest and most important programs of this kind was developed in Brazil. To increase awareness of leukocoria as a presenting sign, the program targeted the general population through TV advertising, billboards, and pamphlets distributed at vaccination centers and pediatricians' offices. The TV advertising program that involved popular TV stars has been translated into many languages and disseminated to other developing countries ([www.tucca.org.br](http://www.tucca.org.br)).

**Professional education programs** An educational program to increase awareness of retinoblastoma among primary care physicians, especially those working in rural areas, has been established. In addition, more detailed information about retinoblastoma has been inserted into the medical school curriculum. These programs are expensive and their effectiveness in reducing the number of deaths from retinoblastoma remains to be proven.

**Screening for retinoblastoma** Retinoblastoma may be an ideal candidate for screening (Box 68.2). Because children with a family history of retinoblastoma have for many years been screened by dilated examination under anesthesia, the natural history of the intraocular disease is well known (Chapter 69). There is an established relationship between early diagnosis and enhanced prognosis for eye salvage and patient survival. Additionally, retinoblastoma presents in a narrow age range, constituting a well-defined target population to be screened. Because retinoblastoma occurs at an age when routine visits to the pediatrician are more common, these practitioners should probably

#### BOX 68.2 Screening for Retinoblastoma

- Natural history of the intraocular disease is well known
- Presentation in a narrow age range, constituting a well-defined target population
- Retinoblastoma occurs at an age when routine visits to the pediatrician are more common
- Programs that involve pediatricians in the screening should be developed
- Relationship between early diagnosis and enhanced prognosis for eye salvage and patient survival

be involved in the screening. However, the perfect test for screening and a proper program are still to be developed.

**UNITED STATES** Researchers in Los Angeles suggested a screening program for retinoblastoma based on the detection of an abnormal red reflex following pupil dilation during pediatric well-child care. This approach is currently being used in a number of large pediatric practices in the Los Angeles area, but has not been widely adopted. In The Netherlands, nearly all children undergo examination by a pediatric ophthalmologist in their first year of life to screen for retinoblastoma and other eye conditions. In the 1980s, New York-based investigators tried to detect differences in the composition of the tears of affected patients, but even though the tears of retinoblastoma patients had higher levels of uric acid and LDH, it proved difficult to establish a reliable cut-off value.<sup>15</sup>

**ARGENTINA** Screening for retinoblastoma is rare in developing countries, even when patients are known to be at risk. The extent of the

problem is demonstrated by the fact that among individuals at known risk for retinoblastoma – relatives and offspring of affected individuals – the diagnosis is made relatively late. Of 27 patients with a positive family history of retinoblastoma diagnosed and treated in Buenos Aires, only seven were able to be managed without enucleation. Three of the 27 underwent bilateral enucleation and one died of metastatic disease due to advanced extraocular extension at diagnosis.

**LIMITATIONS** Costly screening programs cannot be justified in countries with other pressing problems, such as poor water hygiene, lack of universal vaccination, malaria, or other high-prevalence and high-mortality diseases. Therefore, for any screening program to be useful and practical in developing countries, it should be affordable, accessible, culturally acceptable, and be a part of routine visits to pediatricians or general practitioners.

**Minimizing treatment refusal** Families refuse or withdraw treatment in as many as 30% of children diagnosed with retinoblastoma in parts of Central America (Luna S, personal communication). Refusal of enucleation is the major cause of treatment withdrawal and attests to many cultural and religious barriers to the effective treatment of retinoblastoma in indigenous populations in the developing world. Socioeconomic factors also play a large role. Because families frequently must travel long distances to receive medical care for retinoblastoma, following diagnosis and treatment recommendations many choose to return home, where the child dies. The lack of financial resources to support the family during a stay in the referral center, as would be required for an extended course of chemoreduction, is a common cause of treatment refusal. Also, there are other family members at home who must be cared for. Therefore, treatment programs must take all of these factors into consideration.

Measures to reduce treatment withdrawal and early detection of familial cases are probably the most cost-effective measures that can be taken in many developing countries where treatment programs are well established. A recent study from India demonstrated that it might be cost-effective to offer DNA-based testing, especially when there are many at-risk individuals in large families.<sup>16</sup>

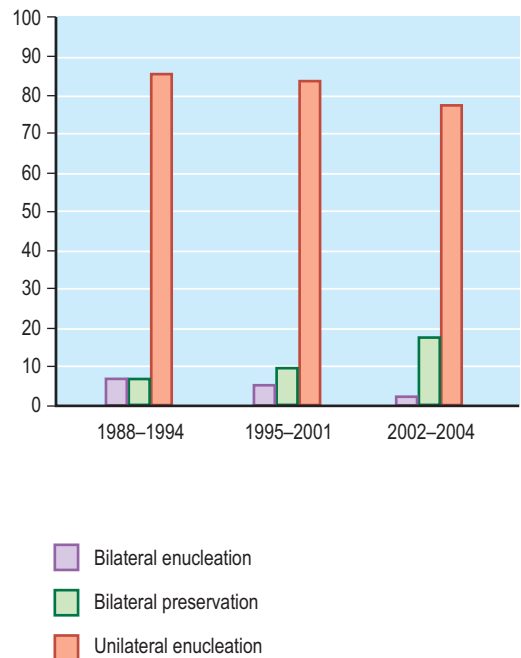
**Socioeconomic development** leading to the increased availability of high-quality healthcare may be the only sustainable way to reduce late diagnosis and ultimately the death rate from retinoblastoma.

## TREATMENT CHALLENGES IN DEVELOPING COUNTRIES

Because extraocular retinoblastoma is a rare event in developed countries, there are only limited data on the treatment. Only a few prospective trials of the treatment of systemic retinoblastoma from developed countries have been reported.<sup>1,9,10,17,18</sup>

**Lack of a uniformly used staging system** Because of the lack of a uniformly used staging for extraocular disease, comparison of outcomes among the series cited in the paragraph above is impossible. However, these studies led a large international group of pediatric oncologists to develop a staging system for retinoblastoma (Chapter 69).<sup>19</sup>

**Primary systemic chemotherapy with focal consolidation in developing countries** The use of systemic chemotherapy



**Fig. 68.5** Eye preservation in 322 consecutive patients in three different time periods. A chemoreduction protocol was started in 1995.

and local consolidation has allowed for an increased eye preservation rate while avoiding the frequent use of external beam radiation therapy in developed countries.<sup>20</sup>

**Special challenges** However, the need for expensive equipment, frequent visits to the hospital, and strict follow-up are some of the factors that limit the use of such treatments in the developing countries. In Buenos Aires, an unanticipated problem associated with the introduction of the chemoreduction program was the dramatic increase in patient burden on the medical system. Because of all of these difficulties, local resources should be carefully evaluated before starting a chemoreduction program in developing countries.

**Published results from developing countries** There is a recognized need to reduce the number of bilaterally enucleated patients in countries with poor facilities and few job opportunities for handicapped individuals. Therefore, in spite of the difficulties outlined above, chemoreduction programs have been established in some developing countries, with initial success. The results from programs in Argentina<sup>20</sup> and Turkey<sup>21</sup> have been published, indicating that chemoreduction significantly reduces the number of enucleated eyes (Fig. 68.5). Moreover, there is unpublished evidence that the results in other countries are similar. A chemotherapy protocol tailored to disease extension, eliminating etoposide and limiting the number of chemotherapy cycles in patients with less advanced disease was used in Buenos Aires. The use of periocular chemotherapy may be a cost-effective alternative in developing countries for some eyes requiring radiotherapy.

## DEVELOPMENTS THAT PROVIDE HOPE FOR THE FUTURE

**Creation of cooperative groups** Cooperative groups for the treatment of childhood cancer are difficult to establish in developing countries because of limited financial support and infrastructure. Recently, the Children's Oncology Group in North America has



launched clinical trial protocols that provide the framework for international applications (Chapter 81). In addition, cooperative groups for the treatment of retinoblastoma have been created in Mexico, Brazil, India, and Central America. These developments should provide evidence-based treatment guidelines that will benefit children from developing countries.

**International collaborative efforts** Collaborative efforts between retinoblastoma centers in the northern and southern hemispheres have proved successful in improving outcomes in pediatric oncology.<sup>22</sup> Transfer of knowledge and resources is the main purpose of these programs, the first of which included cooperation between New York City institutions, sponsored by the Fund for Ophthalmic Knowledge, and Buenos Aires, Argentina. This cooperation included donations of teaching material, participation in common research studies, and financial support for laboratory research. The International Network for Cancer Treatment and Research ([www.inctr.org](http://www.inctr.org)) created a retinoblastoma group involving researchers from many different countries. Its ambitious program aims to develop a common treatment protocol for participating institutions. An outreach program of the St Jude Children Research Center ([www.stjude.org](http://www.stjude.org)) supports the treatment of retinoblastoma in Central America based on internet transmission of RetCam images, as well as an active teaching program. Other programs include cooperation between national groups (Children's Oncology Group and India) and hospitals (Chil-

drens Hospital Los Angeles and Mexico City; Institut Curie, Paris and Algeria).

**Efforts in developing countries** The SLAOP (Latin American Society of Pediatric Oncology) is currently designing a registry of retinoblastoma in each of the Latin American countries. This tool will provide a wealth of new data about this disease. New drug (ifosfamide, idarubicin, topotecan, irinotecan) testing has also been actively pursued in developing countries.<sup>1,9,23</sup>

## SUMMARY

Retinoblastoma presents unique challenges to treating physicians in developing countries. The burden of caring for 80% of the world's retinoblastoma cases falls to individuals and national healthcare systems with limited resources where caring for children with extraocular disease is relatively common. Retinoblastoma specialists from developing countries have taken the lead in creating a new international staging system for extraocular retinoblastoma. Understanding the cause(s) of non-heritable or environmental retinoblastoma will probably take place in countries outside North America and Europe. The need for the cost containment will lead to more effective and less expensive approaches. Initiatives that lead to early diagnosis and improve the quality of medical care of retinoblastoma patients in developing countries will be a valuable contribution to the rest of the world.

## REFERENCES

1. Antoneli CB, Steinhorst F, de Cassia Braga Ribeiro K et al. Extraocular retinoblastoma: a 13-year experience. *Cancer* 2003; 98: 1292–1298.
2. Wessels G, Hesselting PB. Incidence and frequency rates of childhood cancer in Namibia. *S Afr Med J* 1997; 87: 885–889.
3. Lanier AP, Holck P, Ehrsam Day G, Key C. Childhood cancer among Alaska Natives. *Pediatrics* 2003; 112: 396e.
4. Orjuela M, Castaneda VP, Ridaura C et al. Presence of human papilloma virus in tumor tissue from children with retinoblastoma: an alternative mechanism for tumor development. *Clin Cancer Res* 2000; 6: 4010–4016.
5. Orjuela MA, Titievsky L, Liu X et al. Fruit and vegetable intake during pregnancy and risk for development of sporadic retinoblastoma. *Cancer Epidemiol Biomarkers Prev* 2005; 14: 1433–1440.
6. Abramson DH, Frank CM, Susman M et al. Presenting signs of retinoblastoma. *J Pediatr* 1998; 132: 505–508.
7. Kaimbo WK, Mvitu MM, Missotten L. Presenting signs of retinoblastoma in Congolese patients. *Bull Soc Belge Ophtalmol* 2002; 283: 37–41.
8. Rodrigues E, Latorre MR, de Camargo B. Delayed diagnosis in retinoblastoma. *J Pediatr (Rio de Janeiro)* 2004; 80: 511–516.
9. Leal-Leal C, Flores-Rojo M, Medina-Sanson A et al. A multicentre report from the Mexican Retinoblastoma Group. *Br J Ophthalmol* 2004; 88: 1074–1077.
10. Chantada G, Fandino A, Davila MT et al. Results of a prospective study for the treatment of retinoblastoma. *Cancer* 2004; 100: 834–842.
11. Yeole BB, Advani S. Retinoblastoma: An Epidemiological Appraisal with Reference to a Population in Mumbai, India. *Asian Pac J Cancer Prev* 2002; 3: 17–21.
12. Chantada G, Fandino A, Manzitti J, Urrutia L, Schwartzman E. Late diagnosis of retinoblastoma in a developing country. *Arch Dis Child* 1999; 80: 171–174.
13. Leal-Leal C, Grupo Mexicano de Retinoblastoma. INCTR newsletter 2003; 4: 3.
14. Carlos LL, Roberto RL, Victor TG, Carlos HG, Eduardo LP. Risk of dying of retinoblastoma in Mexican children. *Med Pediatr Oncol* 2002; 38: 211–213.
15. Mendelsohn ME, Abramson DH, Senft S, Servodidio CA, Gamache PH. Uric acid in the aqueous humor and tears of retinoblastoma patients. *J AAPOS* 1998; 2: 369–371.
16. Joseph B, Shanmugam MP, Srinivasan MK, Kumaramanickavel G. Retinoblastoma: Genetic testing versus conventional clinical screening in India. *Mol Diagn* 2004; 8: 237–243.
17. Howarth C, Meyer D, Hustu HO et al. Stage-related combined modality treatment of retinoblastoma. Results of a prospective study. *Cancer* 1980; 45: 851–858.
18. Schwartzman E, Chantada G, Fandiño A et al. Results of a stage-based protocol for the treatment of retinoblastoma. *J Clin Oncol* 1996; 14: 1532–1536.
19. Chantada G, Doz F, Antoneli CB et al. A proposal for an international retinoblastoma staging system. *Pediatr Blood Cancer* 2005 Dec 15; [Epub ahead of print]
20. Chantada GL, Fandino AC, Raslawski EC et al. Experience with chemoreduction and focal therapy for intraocular retinoblastoma in a developing country. *Pediatr Blood Cancer* 2005; 44: 455–460.
21. Gunduz K, Gunalp I, Yalcindag N et al. Causes of chemoreduction failure in retinoblastoma and analysis of associated factors leading to eventual treatment with external beam radiotherapy and enucleation. *Ophthalmology* 2004; 111: 1917–1924.
22. Ribeiro RC, Pui CH. Saving the children – improving childhood cancer treatment in developing countries. *N Engl J Med* 2005; 352: 2158–2160.
23. Chantada GL, Fandino A, Mato G, Casak S. Phase II window of idarubicin in children with extraocular retinoblastoma. *J Clin Oncol* 1996; 14: 1532–1536.

# Staging and grouping of retinoblastoma

A. Linn Murphree and Guillermo Chantada

## INTRODUCTION

A commonly used tumor classification is essential in order to plan initial treatment, determine prognosis, assess treatment response, compare outcomes, and plan clinical trials.<sup>1</sup> Berman<sup>2</sup> maintains that for tumor classifications to be successful, they must reflect clinical reality and must be changed as information is accrued. Almost never does the staging of the tumor rest solely with the subspecialty surgeon: rather, it usually results from interaction between pathologists and oncologists. In almost all solid childhood malignancies except retinoblastoma, survival of the patient is the sole end point against which to assess treatment efficacy and side effects.

## UNIQUE ASPECTS OF RETINOBLASTOMA

Retinoblastoma is unique among childhood malignancies for several reasons:

- There are two legitimate end points against which outcome is measured: salvage of useful vision and survival of the patient.
- Rarely is a tissue specimen available to assist with the initial diagnosis and classification of the intraocular disease.
- The care of eye disease is so restricted to the ophthalmologist that the pediatric oncologist and pathologist, without help from the ophthalmologist, are unable to assess, classify, or treat the eye tumor.
- As a result, a single staging system similar to those for other solid childhood malignancies was never widely adopted.

## REESE–ELLSWORTH CLASSIFICATION

In the 1960s Reese and Ellsworth<sup>3,4</sup> proposed a preoperative grouping system (Table 69.1). These authors developed their group classification as a way to assist treating ophthalmologists in assessing the likelihood of salvaging the eye. This system was used for decades. However, in the early 1990s primary radiotherapy, the treatment modality on which the Reese–Ellsworth grouping system was based, was in large part supplanted by systemic chemotherapy. Reese–Ellsworth no longer reflected current clinical reality, the essential requirement for a successful classification, according to Fleming.<sup>1</sup>

The historical absence of a staging system also reflects the low incidence of extraocular disease in developed countries. Until relatively recently, the fact that extraocular disease is still a clinical issue in developing countries was largely overlooked in publications about retinoblastoma from the northern hemisphere. An international perspective on retinoblastoma is presented in Chapter 68.

## FIRST INTERNATIONAL CLASSIFICATION OF RETINOBLASTOMA

In this chapter we present the first international classification system for retinoblastoma. It consists of both preoperative grouping to help the ophthalmologist assess the risk of the disease and its treatment to the child's eye(s) and vision, and a staging schema for assessment of the risk the disease poses to the child's life and wellbeing (Table 69.2). The organization and content of both the grouping and the staging were developed with unprecedented international cooperation between oncologists and ophthalmologists who treat this disease. The fact that four new cooperative group clinical trials, the first in almost 40 years, have recently opened to assess the management of retinoblastoma (Chapter 81) gives some testimony to the role of reality-based tumor classification systems. All of the four new clinical trials use the International Grouping and Staging of Retinoblastoma described in this chapter.

## STAGING THE PATIENT

**Background** Retinoblastoma differs from other pediatric neoplasms in never having had a widely accepted classification system that encompasses the entire spectrum of the disease. The clinical scenario of a patient being treated for intraocular disease where survival is not in significant jeopardy is completely different from the case with metastatic disease in which there is a life-threatening extraocular disease.

The absence of a widely accepted staging system made it extremely difficult to design studies or to compare the outcomes from published studies that evaluated disease extension, risk factors for metastatic disease, and/or response to therapy.

**Other staging systems** There are at least five published reports that included a staging classification, but none of these has been widely adopted.<sup>5–9</sup>

**St Jude's Hospital Staging and TNM System** Some classifications, like the St Jude's and the TNM systems, embraced the whole spectrum of retinoblastoma and included ophthalmologic data, but were seldom used by ophthalmologists, who preferred the Reese–Ellsworth group classification that had been in use since the 1960s.<sup>3,4</sup>

**Childrens' Cooperative Group Classification (CCG)** Other classifications, such as the CCG, considered only extraocular disease,

**Table 69.1 Reese–Ellsworth classification**

Group	Subgroup	Descriptor	Prognosis
Group I	Ia	Solitary tumor <4DD at or behind the equator	Very favorable
	Ib	Multiple tumors, none > 4DD, all at or behind the equator	
Group II	IIa	Solitary tumor, 4 to 10DD, all at or behind the equator	Favorable
	IIb	Multiple tumors, 4 to 10DD, behind the equator	
Group III	IIIa	Any lesion anterior to the equator	Doubtful
	IIIb	Solitary tumors larger than 10DD behind the equator	
Group IV	IVa	Multiple tumors, some larger than 10DD	Unfavorable
	IVb	Any lesion extending anteriorly to the ora serrata	
Group V	Va	Massive tumors involving over half the retina	Very unfavorable
	Vb	Vitreous seeding	

**Table 69.2 Staging and grouping in the international retinoblastoma classification**

Aspect	Staging	Grouping
Focus	Patient and tumor	Eye
Primary specialist	Oncologist and pathologist	Ocular oncologist
Relation to tumor excision/biopsy	Clinical staging (preoperative)	Preoperative
	Pathologic staging (postoperative)	
Outcome measure	Survival of the patient	Survival of the eye/vision
Information required	Has one eye been enucleated?	Results of the grouping EUA
	Is tumor confined to the eye?	Is there tumor in one or both eyes?
	Is there microscopic orbital disease?	Is the tumor confined to the retina?
	Has the tumor grossly invaded regional structures?	Is significant retinal detachment present?
	Have metastases occurred?	Are vitreous and/or subretinal seeding present?
	Number of metastatic foci?	Has/have the functional and/or structural integrity of the eye(s) been destroyed?
	Is there CNS disease?	
Sources of information	Medical record, including all diagnostic imaging studies and the tumor pathology report	Functional vision, ophthalmic examination, ocular ultrasound (CT rarely necessary)
Designator	Roman numerals	Capital letters A–E
Subgroups	Yes	No
Used in COG clinical trials	Yes	Yes
Time from study entry to: disease recurrence requiring off-protocol therapy or loss to follow-up	Event-free survival (EFS)	Event-free ocular survival (EFOS)

omitting important pathological features such as choroidal or post-laminar optic nerve invasion.<sup>7</sup>

**Grabowski–Abramson Classification** The Grabowski–Abramson classification, later modified by Abramson, was also used by some groups.<sup>8</sup> In that classification, patients with CNS invasion were categorized as Stage III and those with systemic metastases as Stage IV. The current clinical experience is that patients with Grabowski–Abramson Stage III are seldom curable, whereas those with Stage IV can often be rescued with high-dose chemotherapy and bone marrow salvage.

**International Retinoblastoma Classification: Staging System<sup>10</sup>** At the International Symposium on Retinoblastoma held in Paris in May 2003, a committee of retinoblastoma experts from

large centers worldwide drafted yet another staging system. Investigators from centers in South and North America, Europe, and South Africa edited this draft into a consensus document. This staging system was designed to be used in conjunction with the new intraocular grouping system that was also under development at the same time. This staging system combines clinical and pathologic staging and has a single end point – survival of the patient with retinoblastoma. Patients are classified according to extent of disease, including the presence of microscopic or overt extraocular extension and metastatic extension (Table 69.3). Roman numerals are used for stage assignment.

**Stage 0** In order to be consistent with staging systems for other pediatric solid malignancies, patients in whom neither eye has been enucleated are assigned to Stage 0.



**Table 69.3 Staging system for patients in international retinoblastoma classification**

Stage	Substage	Descriptor	Comments
Stage 0		Intraocular tumor only	No evidence of regional or metastatic disease; patient may not have had an enucleation
Stage I		Tumor completely removed by enucleation	Retinoblastoma may be present in the non-enucleated eye. High-risk pathology may be present within the enucleated specimen
Stage II		Residual orbital tumor	Microscopic tumor present in the optic nerve at the site of surgical resection (cut end of nerve)
Stage III	a. Overt orbital extension b. Preauricular or cervical lymph node extension	Overt regional disease	Orbital or node involvement diagnosed clinically or by neuroimaging
Stage IV	a. Hematogenous metastasis without CNS disease b. CNS disease	1. Single lesion 2. Multiple lesions  1. Prechiasmatic lesion 2. CNS mass 3. Leptomeningeal disease	Metastatic Disease

**Stage I** Patients who have had at least one enucleation, with pathologic evidence of complete excision of the tumor, are placed in Stage I.

**Stage II** is used to describe patients whose enucleated eye shows tumor at the cut end of the optic nerve and residual microscopic tumor remaining in the orbit.

**Stage III** contains patients with gross clinical evidence of orbital disease or regional lymph node involvement.

**Stage IV** is reserved for patients with metastatic disease. The presence or absence of CNS involvement is highly significant in terms of survival.

**Possible future improvements** This proposal considers histopathology features found in enucleated eyes (Stages I and II). However, because evaluation of the invasion of the ocular coats, such as the extent of choroidal or scleral invasion, may be interpreted subjectively, there is currently an international effort under way to standardize these factors in order to allow for more accurate reproducibility.

## GROUPING THE EYE DISEASE

**Background** The arguments supporting the creation of a new group classification of intraocular retinoblastoma were published in early 2005.<sup>11</sup> The effort to create a new group classification began more than 10 years before that publication. In 1994, more than 50 international retinoblastoma specialists met and discussed the classification issue for a full day during the World Congress of Ophthalmology held in Toronto.

In 2003, Murphree presented a draft of his ABC classification at the International Retinoblastoma Symposium in Paris. There was input with recommended modifications. Following that meeting, Brenda

Gallie (Toronto, Canada) set up a website that allowed retinoblastoma centers from around the world to test the validity of the ABC classification. Using protocols approved by each institution's institutional review board, more than 20 centers on six continents retrospectively grouped more than 2000 of their patient's eyes using the ABC system. Treatment and outcome data were recorded. A summary of the data from that effort was the subject of Murphree's Ellsworth Lecture at the 2005 Retinoblastoma Symposium at Whistler, British Columbia. In that lecture, the author suggested that future classifications of retinoblastoma should no longer carry an individual's name, as an expression of respect to the many contributors. This set the stage for the combination of grouping and staging into one International Classification of Retinoblastoma.

## International Retinoblastoma Classification: Grouping System

Eyes are classified according to the extent of disease and dissemination of intraocular tumor (Table 69.4). The grouping is based on the natural history of this eye disease as well as the probability of salvaging the eye(s). Each group may contain elements of preceding groups, but is defined by the most advanced tumor in the eye.

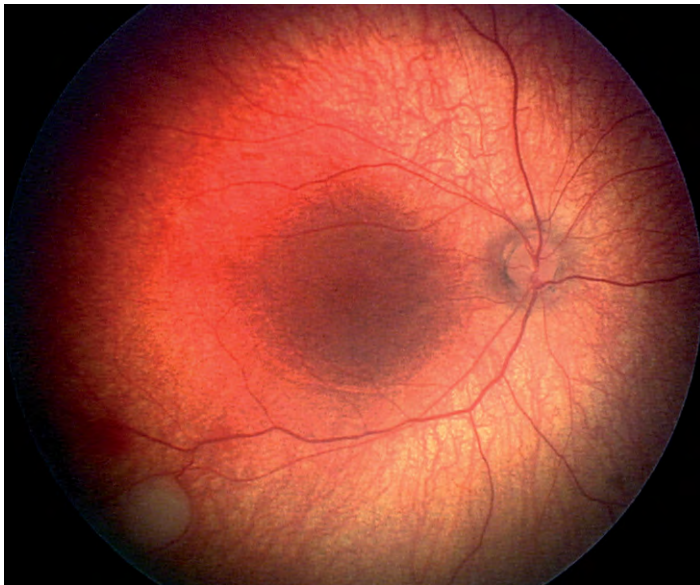
The predominating factor that determines the risk of losing the eye is the extent of intraocular tumor dissemination. In this group classification, tumor dissemination into the subretinal fluid and vitreous space is considered to have an equally adverse effect on the likelihood of salvaging the eye. Vitreous dissemination can be appreciated clinically as vitreous seeding. Subretinal fluid must be assumed to contain tumor cells or clumps of cells even when they cannot be detected clinically. More advanced subretinal seeding presents as subretinal plaques or masses.

**Group A** If no intraocular tumor dissemination is present at diagnosis, the eye falls into either Group A or Group B (Fig. 69.1). The

**Table 69.4 Grouping system for eyes in international retinoblastoma classification**

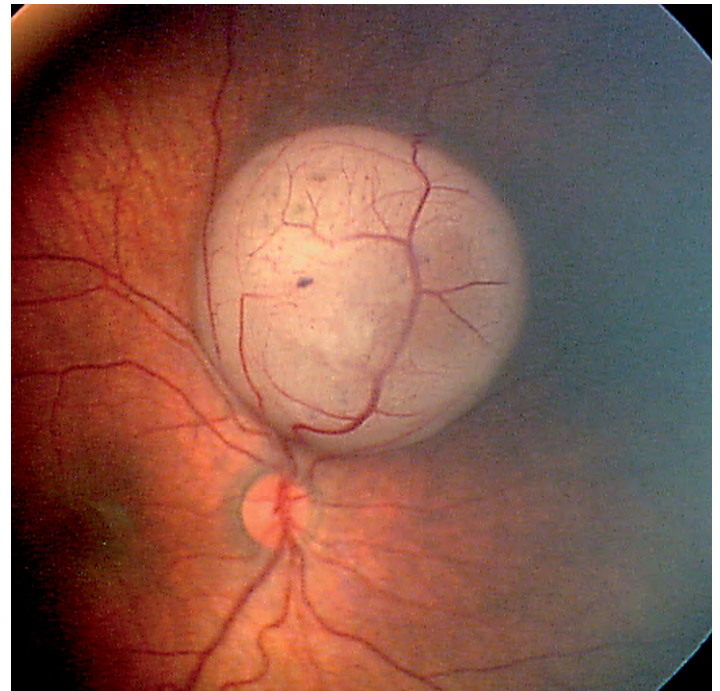
Group	Descriptor
Group A	Small <sup>1</sup> round tumor(s) located away from the fovea <sup>2</sup> and disc <sup>3</sup>
Group B	All eyes without tumor dissemination <sup>4</sup> not in Group A <sup>5</sup>
Group C	Local <sup>6</sup> tumor dissemination
Group D	Diffuse <sup>7</sup> tumor dissemination
Group E	Unsalvageable eyes <sup>8</sup>

<sup>1</sup>No tumor may be larger than 3mm in any diameter (base or height). No vitreous seeding allowed.  
<sup>2</sup>Tumor(s) must be 2DD (3mm) or more from the fovea.  
<sup>3</sup>Tumor(s) must be 1 DD (1.5mm) or more from the optic disc.  
<sup>4</sup>Tumor dissemination is defined to include both vitreous seeding and the presence of subretinal fluid even if subretinal seeding is not clinically apparent. A cuff of subretinal fluid extending no more than 5mm from the base of the tumor is allowed in Group B. No vitreous seeding of any extent is allowed.  
<sup>5</sup>Tumors may be of any size, shape or location. Current or RPE evidence of previous detachment of 1 quadrant or less is allowed.  
<sup>6</sup>Vitreous or subretinal seeding may extend no more than 3mm from tumor  
<sup>7</sup>Vitreous seeding may be large, diffuse and/or 'greasy.' Avascular masses of tumor may be present in the vitreous. Subretinal dissemination may consist of fine seeds, large avascular plaques on the underside of the detached retina, or extensive subretinal masses (exophytic disease).  
<sup>8</sup>See Box 69.1 for features that confer Group E status.



**Fig. 69.1** Group A retinoblastoma. Small round tumor(s) located away from the fovea and disc. No tumor may be larger than 3 mm in any diameter (base or height). Tumor(s) must be 2 DD (3mm) or more from the fovea and must be 1 DD (1.5mm) or more from the optic disc. No vitreous seeding is allowed. (Reproduced with permission from Murphree AL. Intraocular retinoblastoma: the case for a new group classification. *Ophthalmol Clin North Am* 2005; 18: 41–53.)

prognosis for both is excellent. In Group A tumors are still small and retain their original round configuration. Loss of central vision from direct tumor destruction or laser consolidation during treatment is minimized in Group A by restricting the tumor to locations greater than 2 DD (3mm) from the fovea and 1 DD (1.5mm) from the optic disc.



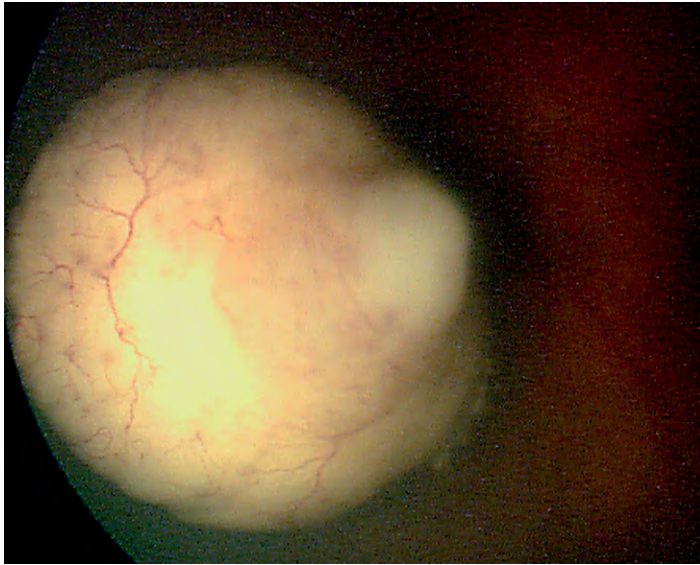
**Fig. 69.2** Group B retinoblastoma. All eyes without tumor dissemination not in Group A. Cuff of subretinal fluid extending no more than 5 mm from the base of the tumor is allowed. Tumors may be of any size, shape or location, but vitreous seeding of any extent is not allowed. (Reproduced with permission from Murphree AL. Intraocular retinoblastoma: the case for a new group classification. *Ophthalmol Clin North Am* 2005; 18: 41–53.)

**Group B** contains all eyes that have passed through Group A but have not yet developed vitreous seeding or significant subretinal fluid (Fig. 69.2). The tumors in Group B are still discrete but tend to be larger. As tumors expand, gain of function mutations occur, causing these masses to assume an irregular or nodular configuration – the pre-seeding phase. Tumors in Group B need not respect the location restrictions of Group A. Almost all reasonably sized tumors are associated with a cuff of subretinal fluid. Group B eyes are allowed to have such a cuff of subretinal fluid that at no point extends further than 5 mm from the base of the tumor.

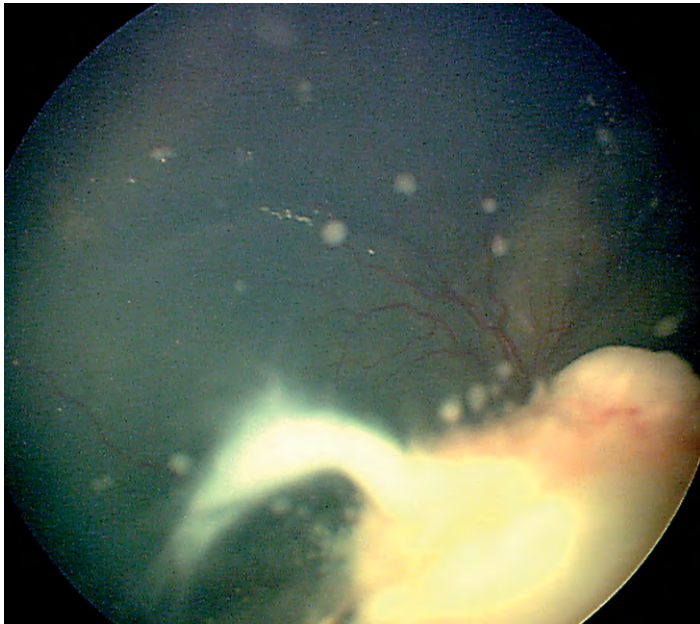
**Group C** eyes have passed through the natural history of the disease represented by Groups A and B (Fig. 69.3). In the next phase of tumor progression, focal vitreous or subretinal seeding begins. Presumably, one or more clones of tumor cells on the surface of the tumor, usually in one of the nodular prominences, achieves anchorage independence. Anchorage independence mutations confer the ability of tumor cells to survive without being anchored to the main tumor mass. Early seeds are fine and localized, not having had sufficient time to expand in volume by adjusting to the new, relatively more hypoxic micro-environment of the vitreous or subretinal fluid. Group C includes eyes with evidence of very early dissemination that is located near the originating site. Subretinal fluid of less than one quadrant is allowed in Group C.

**Group D** eyes display greater dissemination of intraocular tumor than allowed in Group C (Fig. 69.4). Subretinal fluid involves more than one quadrant of the retina. Total retinal detachment may be present. Subretinal masses, or exophytic disease, may be present, but



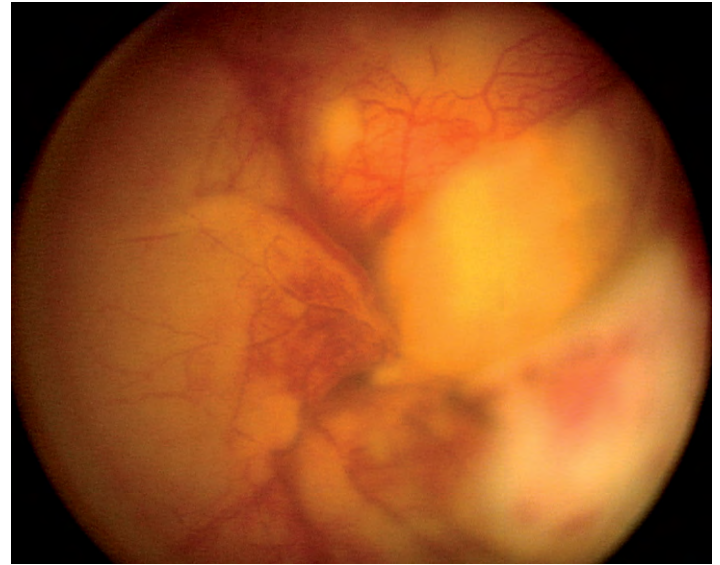


**Fig. 69.3** Group C retinoblastoma. Local tumor dissemination. Vitreous or subretinal seeding may extend no more than 3 mm from tumor. Current or RPE evidence of previous detachment of one quadrant or less is allowed. Note the 'nipple' that is the likely source of the vitreous seeding. (Reproduced with permission from Murphree AL. Intraocular retinoblastoma: the case for a new group classification. *Ophthalmol Clin North Am* 2005; 18: 41–53.)



**Fig. 69.4** Group D retinoblastoma. Diffuse tumor dissemination. Vitreous seeding may be large diffuse and/or 'greasy.' Avascular masses of tumor may be present in the vitreous. Subretinal dissemination may consist of fine seeds or large avascular plaques on the underside of the detached retina or extensive subretinal masses (exophytic disease). (Reproduced with permission from Murphree AL. Intraocular retinoblastoma: the case for a new group classification. *Ophthalmol Clin North Am* 2005; 18: 41–53.)

the subretinal tumor may also appear as fine white dots or thin geographic avascular plaques on the underside of the detached retina. The vitreous seeding is no longer confined to the vicinity of the tumor. It may be massive and/or diffuse. Avascular tumor masses probably represent a further stage of progression of malignancy in which mutations have conferred upon tumor cells the ability to be independent of a blood supply.



**Fig. 69.5** Group E retinoblastoma. Unsalvageable eyes include those displaying any one or more of the following features: neovascular glaucoma, massive intraocular hemorrhage, bloodstained cornea, massive tumor necrosis associated with aseptic orbital cellulites, phthisis or pre-phthisis, tumor anterior to anterior vitreous face, anterior segment tumor, tumor touching the lens, or diffuse infiltrating retinoblastoma. (Reproduced with permission from Murphree AL. Intraocular retinoblastoma: the case for a new group classification. *Ophthalmol Clin North Am* 2005; 18: 41–53.)

#### BOX 69.1 Clinical Features that Confer Group E Status

- Neovascular glaucoma
- Massive intraocular hemorrhage
- Blood-stained cornea
- Massive tumor necrosis associated with aseptic orbital cellulitis
- Phthisis or pre-phthisis
- Tumor anterior to anterior vitreous face
- Anterior segment tumor
- Tumor touching the lens
- Diffuse infiltrating retinoblastoma

**Group E** eyes include any or all of the tumor features present in the earlier groups (Fig. 69.5). These eyes are distinguished by showing certain ominous features or effects of the intraocular tumor (Box 69.1) that have significantly and irreversibly compromised the physical and/or structural integrity of the eye.

#### Possible future improvements

**Improved prediction of vision salvage probability in each group** In developing the grouping described here as part of the new International Classification of Retinoblastoma, a major consideration was that it be kept simple by avoiding subgrouping. In addition, there were no data supporting the value or rationale of subgrouping. Except for Group A, the likelihood of salvaging vision in each group is not addressed. Any attempt to include those modifiers would have complicated the grouping immensely. Currently there is a pilot effort



**Table 69.5 Application of the international retinoblastoma classification**

Clinical scenario	International classification		Comments
	Staging	Grouping	
Previously untreated; no clinical or imaging evidence of extraocular disease; no family history RE Group D, LE Group E	Stage 0	Right eye Group D Left eye Group E	Stage 0 conveys that neither eye has been enucleated. After enucleation, this patient's disease will be Stage I if there is no microscopic residual tumor. High-risk pathology would not make this Stage II
Left eye previously enucleated; unilateral sporadic, Group E, left eye; tumor at cut end of nerve but no imaging evidence of tumor mass in the orbit	Stage II	Right eye Left eye Group E (enucleated)	This patient has Stage II retinoblastoma because there is proven microscopic residual disease beyond the surgical margin
Metastatic Rb to bones, bone marrow but no CNS involvement; Unilateral sporadic, Group D right eye, enucleated.	Stage IVa	Right eye Group D (enucleated) Left eye	
Bilateral sporadic retinoblastoma, right eye Group C, left eye Group E, enucleated; received adjuvant chemotherapy for tumor posterior to lamina cribosa but not to cut end	Stage I	Right eye Group C Left eye Group E (enucleated)	This patient has Stage I retinoblastoma. Following enucleation, the pathologic finding of high-risk pathology does not imply residual microscopic orbital tumor required for Stage II

under way to determine whether a simple subgroup overlay might be an effective tool to predict vision salvage. Similar to the location restrictions imposed for Group A, the vision salvage predictor tool might assist in initial treatment decisions, such as whether or not attempts at salvage with the known side effects are appropriate in the case of a unilateral Group C eye.

**Allowing intraocular grouping to change in case of disease progression** Currently there is no provision in the grouping schema for the group assignment of an eye to change. However, consideration is being given to a concept referred to as event-free ocular survival (EFOS). Such a term would be analogous to the term 'event-free survival' (EFS), commonly used in clinical trials to define the time from study entry until an 'event' such as disease progression, tumor relapse, second malignancy, death, or last contact occurs. Event-free ocular survival (EFOS) could define the time from study entry until an ocular 'event,' such as disease progression that cannot be controlled by local consolidation or last visit, occurs. Once an EFOS has occurred, a revised group assignment to reflect the current status of the ocular disease might be considered. Further study is required.

## CLINICAL APPLICATION OF INTERNATIONAL RETINOBLASTOMA CLASSIFICATION

Because staging is a relatively new concept to ophthalmologists treating retinoblastoma, we suggest one simple approach (Table 69.5): to couple staging and grouping in all cases.

## SUMMARY

This chapter presents the new Staging and Grouping Schema for the International Classification of Retinoblastoma. The common use of both staging and grouping in all patients will give pediatric oncologists and ophthalmologists who treat retinoblastoma a powerful new tool to generate a roadmap for initial therapy.<sup>11</sup> It will provide clinicians with an assessment of the likely prognosis for salvage of the child and his or her eye(s) before treatment begins. It will allow prediction of treatment morbidity. The international retinoblastoma classification also creates the environment for successful clinical trials, four of which are already under way (See Chapter 81). Finally, and perhaps most importantly, it will allow medical professionals, government officials, and parents from any country to focus on minimizing loss of life and vision from retinoblastoma.

## REFERENCES

- Fleming I. Staging of pediatric cancers: problems in the development of a national system. *Semin Surg Oncol* 1992; 8: 94–97.
- Berman JJ. Tumor classification: molecular analysis meets Aristotle. *BMC Cancer* 2004; 4: 10.
- Reese A, Ellsworth R. The evaluation and current concept of retinoblastoma therapy. *Trans Am Acad Ophthalmol Otolaryngol* 1963; 67: 164–172.
- Ellsworth RM. The practical management of retinoblastoma. *Trans Am Ophthalmol Soc* 1969; 67: 462–534.
- Pratt CB, Fontanesi J, Lu X, et al. Proposal for a new staging scheme for intraocular and extraocular retinoblastoma based on an analysis of 103 globes. *Oncologist* 1997; 2: 1–5.
- American Joint Committee on Cancer. *Retinoblastoma*, 6th edn. *Cancer Staging Manual*, ed. 2002, New York: Springer Verlag.
- Wolff J, Boesel C, Ellsworth R. Extraocular retinoblastoma. *Childrens Cancer Study Group Protocol CCSG 962*, 1978.
- Grabowski E, Abramson DH. Intraocular and extraocular retinoblastoma. *Hematol Oncol Clin North Am* 1978; 1: 721–735.
- Stannard C, Sealy R, Hering E, et al. Postenucleation orbits in retinoblastoma: treatment with <sup>125</sup>I brachytherapy. *Int J Radiat Oncol Biol Phys* 2002; 54: 1446–1454.
- Chantada G, Doz F, Antonelli CB, et al. A proposal for an international retinoblastoma staging system. *Pediatr Blood Cancer* 2005. Epub.
- Murphree AL. Intraocular retinoblastoma: the case for a new group classification. *Ophthalmol Clin North Am* 2005; 18: 41–53.

# Heritable retinoblastoma: the RB1 cancer predisposition syndrome

A. Linn Murphree and Arun D. Singh

## INTRODUCTION

A group of signs and symptoms that, when taken together, are characteristic of a specific genetic disease or disorder defines a genetic syndrome. An RB1 mutation in the germline causes a lifelong predisposition to many different forms of cancer.<sup>1</sup> Although retinoblastoma is found in one or both eyes of 95% of patients with a germline RB1 mutation, this eye tumor alone does not define the syndrome. Because precise terminology is essential for consistently superior clinical care, an argument can be made to group all phenotypes that can be broadly defined as heritable retinoblastoma under a single term: the RB1 cancer predisposition syndrome. The only feature that every member of the syndrome shares is a mutation in RB1 that is heritable (capable of being passed on to offspring).<sup>1</sup> The occurrence, timing, and nature of spontaneous genetic events that occur long after the predisposing mutation determines the clinical manifestation (phenotype) of this syndrome.

## BACKGROUND

The use of the term ‘cancer syndrome’ to refer to the presence of a genetic predisposition to cancer is firmly established in the literature.<sup>2</sup> Although Knudson<sup>3</sup> did not use this specific term in 1975, he pointed out that the genetic predisposition to cancer, or a ‘prezygotic group,’ could be found in many childhood cancers. In that same paper he defined the tumor suppressor model in retinoblastoma. Figure 70.1 is an updated illustration of that concept. Subsequently, Knudson maintained that there were as many as 50 human cancer genes and that mutations in any of them could predispose to one or a few specific cancers.<sup>4</sup> Although most solid childhood cancers occur in heritable forms, just as Knudson predicted, they are rarely recognized as cancer syndromes. A partial list of the better-known human cancer syndromes, together with their manifestations, is given in Table 70.1 (Chapters 22 and 30). The case is made in this chapter that heritable retinoblastoma should be among the widely recognized human cancer syndromes.

## TERMINOLOGY

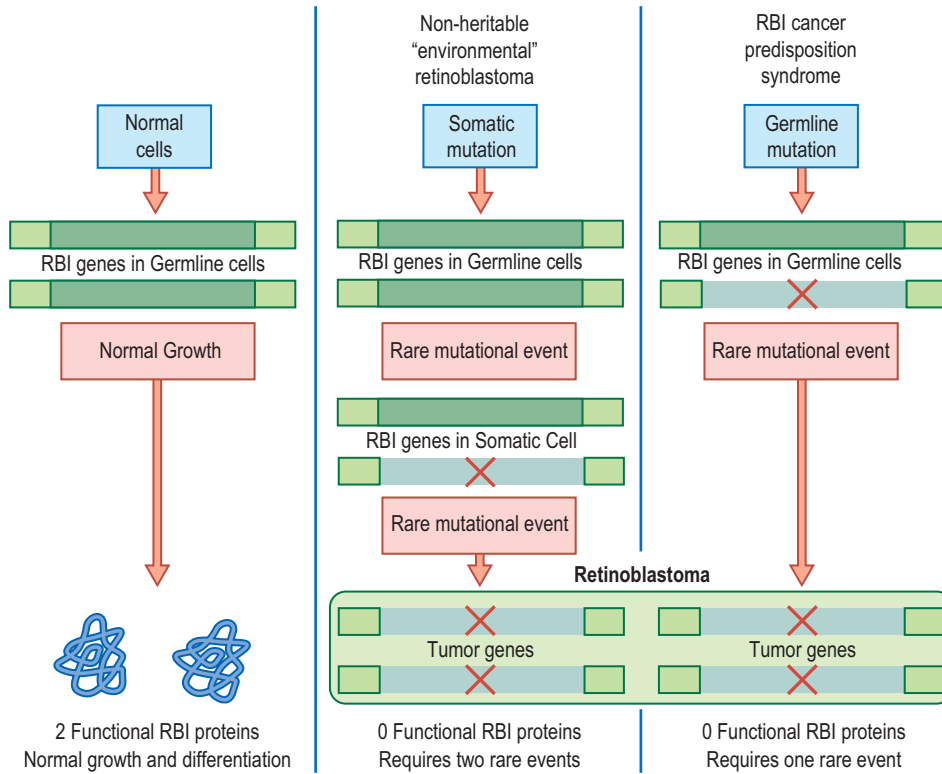
A complete understanding of the nuances surrounding retinoblastoma is essential for recognizing the key clinical issues at hand, for selecting the most appropriate treatment, and for providing timely and accurate genetic counseling. Terms commonly used in the literature to refer to the group of patients genetically predisposed to retinoblastoma include ‘bilateral,’ ‘hereditary,’ ‘heritable,’ and ‘familial’ (Table 70.2). None of these terms is always accurate or precise when referring to the group as a whole. At least 15% of all unilateral retinoblastoma cases carry an

RB1 germline mutation (Fig. 70.2). Fully two-thirds of all patients with RB1 germline mutations did not inherit the mutant allele from a parent (Chapter 67). Most are the result of endogenous germline mutations in RB1. Although these endogenously derived new or ‘founder’ RB1 mutations are not inherited, they are heritable (capable of being transmitted to offspring).

## RB1 CANCER PREDISPOSITION SYNDROME

**Phenotype** Compared to the single phenotype (unifocal unilateral retinoblastoma) seen in non-heritable retinoblastoma, more than 10 clinical phenotypes may result from a germline RB1 mutation (Table 70.3). Not all patients with a genetic predisposition to retinoblastoma develop tumors in both eyes, or even in one eye. Each does, however, share a 50% probability of passing the predisposition-to-cancer trait to each of their children. Each of the families of those children deserves to know that their children may be at risk. They should also know that their growing children should be watched carefully for unexplained ‘bumps, lumps, or sore spots’ that do not resolve spontaneously within 2 weeks. Such findings may be early signs of osteosarcoma or soft tissue sarcoma. They should avoid sunburn (increases risk for melanoma) and second-hand tobacco smoke (increases risk for carcinoma of the lung and bladder in the fourth and fifth decades of life). Clinical clues to the presence of the RB1 cancer predisposition cancer syndrome include all familial cases (parent, grandparent, child, or sibling with retinoblastoma), bilateral retinoblastoma, trilateral retinoblastoma (Chapter 72), 13q deletion syndrome (Chapter 73), and the presence or a positive family history of non-ocular malignant neoplasms (Box 70.1) (Chapter 71).

**Genotype** A variety of genetic changes at RB1 predisposes to retinoblastoma and other cancers in the RB1 cancer predisposition syndrome. About 20% of the changes are deletions larger than 1 kb; 30% consist of small deletions or insertions; and about 45% are point mutations. Mutations have been found in 25 of the 27 coding exons and in promoter elements.<sup>1</sup> More than 930 RB1 mutations published by 2005 were gathered into a searchable database by Valverde and colleagues.<sup>5</sup> Their meta-analysis revealed that the retinoblastoma protein is most commonly inactivated by deletions and nonsense mutations. In contrast, most genetic diseases are caused by missense mutations. Almost 40% of RB1 gene mutations are recurrent and occur in 16 hot spots, and include 12 nonsense, two missense, and three splicing mutations. The remainder of the mutations are scattered along RB1, but are most



**Fig. 70.1** This tumor suppressor model demonstrates that the *RB1* cancer syndrome patient has one inactive *RB1* allele in the germline and in all somatic cells. A single rare, second event is all that is required for reduction to homozygosity at the *RB1* locus and for retinoblastoma to be created in a retinoblast. Additional mutations may be required for non-ocular cancer to arise. The two rare mutational events occur in somatic cells. For retinoblastoma to appear, both alleles in a single retinoblast must be inactivated. Environmental pressure would be expected to have an impact on non-heritable retinoblastoma.

Table 70.1 Some human cancer predisposition syndromes				
Name	Alternative nomenclature	Gene designation	Defining cancer	Associated cancers
<b><i>RB1</i> Cancer predisposition syndrome</b>	Bilateral retinoblastoma Hereditary retinoblastoma Heritable retinoblastoma Familial retinoblastoma	Retinoblastoma gene ( <i>RB1</i> )	Retinoblastoma	Osteosarcoma Melanoma Fibrosarcoma Chondrosarcoma Leiomyosarcoma Renal, bladder or lung carcinoma (Adult onset) Rhabdomyosarcoma Pancreatic cancer Malignant fibrous histiocytoma Ewing's sarcoma Carcinoma of the tongue Medulloblastoma
<b>Lynch syndrome</b>	Hereditary non-polyposis colorectal carcinoma	DNA replication repair genes ( <i>MSH2, MLH1, MSH6, PMS2</i> )	Colorectal cancer	Female genital tract cancer Stomach cancer Brain tumors Breast cancer Cancer of urological system Small intestine cancer Skin cancer Prostate cancer
<b>Hereditary breast cancer syndrome</b>	Familial breast cancer Hereditary breast-ovarian cancer	Familial breast cancer genes ( <i>BRCA1, BRCA2</i> )	Breast cancer	Ovarian cancer Uterine serous papillary carcinoma
<b>Li-Fraumeni syndrome</b>		p-53 gene ( <i>TP53, CHEK-2</i> )	Osteosarcoma	Soft tissue sarcoma Breast cancer Brain tumors Adrenocortical carcinoma Leukemia



Table 70.2 Terms currently used to define genetic predisposition to retinoblastoma			
Terminology			RB1 Cancer predisposition syndrome
Laterality	Inheritance	Family history	
Bilateral	Inherited from a parent	+	+
	Negative family history	-	+
Unilateral <sup>1</sup>	Inherited from a parent	+	+
	Negative family history	-	+
	Non-heritable <sup>2</sup>	-	-

<sup>1</sup>15–20% of unilateral patients have an RB1 germline mutation; 80–85% do not.  
<sup>2</sup>A diagnosis of non-heritable unilateral Rb can only be made with certainty if the RB1 gene test is normal.



**Fig. 70.2** The mother in this photograph was diagnosed at age 2 with unilateral retinoblastoma and treated in another country. She was told that she had the non-heritable form of retinoblastoma. Her child was not expected to be at risk for the disease and was not examined until age 18 months. The child had advanced retinoblastoma in each eye that had severely compromised vision. Suspecting each newly diagnosed unilateral retinoblastoma patient to have the RB1 cancer predisposition syndrome would have prevented this tragedy.

Table 70.3 Phenotypes of non-heritable retinoblastoma and the RB1 cancer predisposition syndrome					
Genotype	Phenotype				
	Family history of Rb	13 q deletion	Unilateral/bilateral	Retinoblastoma/retinocytoma	Risk for Rb associated non-ocular malignancy* and for having affected children
Non-heritable retinoblastoma	-	-	U	Unifocal Rb	-
RB1 Cancer predisposition syndrome	-	-	B	Rb	+
	-	-	U	Rb	+
	+	-	B	Rb	+
	+	-	U	Rb	+
	- / +	+	B	Rb	+
		+	U	Rb	+
	Parent and child with Rb	-	No ocular tumor		+
	Parent or child with Rb	-	No ocular tumor		+
	-	-	No ocular tumor		+
	-	-	Only retinocytoma		+
Parent or child with Rb	-	Only retinocytoma		+	
Low-penetrance Rb	-	No ocular tumor or Rb or retinocytoma		+	(May be low)

\*Associated non-ocular malignancies include osteosarcoma, melanoma, fibrosarcoma, chondrosarcoma, leiomyosarcoma, malignant fibrous histiocytoma, Ewing's sarcoma, renal cancer, bladder cancer, lung cancer, rhabdomyosarcoma, pancreatic cancer, carcinoma of the tongue, medulloblastoma.  
 RB or Rb, retinoblastoma.

**BOX 70.1 Clinical Clues to the Presence of RB1 Cancer Predisposition Syndrome**

- Family history of retinoblastoma (parent, grandparent, child, or sibling)
- Bilateral retinoblastoma
- Trilateral retinoblastoma
- 13q deletion syndrome
- Second malignant neoplasm

common in exons 9, 10, 14, 18, 20, and 23. There is some clustering by country of origin, suggesting the involvement of a predisposing ethnic background.

**Genotype–phenotype correlation** A significant association between late age at diagnosis and the presence of splicing mutations has been observed, suggesting a delayed-onset phenotype.<sup>5</sup> In addition, the mutations reported in low-penetrance retinoblastoma families tend to cluster into three groups: promoter mutations resulting in low expression of normal Rb protein; mutations involving non-essential sequence motifs that result in a partial inactivation of Rb protein function; and splicing mutations leading to a reduction of normal mRNA splicing or to alternative splicing.<sup>5,6</sup>

**Special clinical variants**

**'Pseudo' unilateral retinoblastoma** At presentation bilateral retinoblastoma can be asymmetric to such an extent that only one eye harbors a retinoblastoma at diagnosis.<sup>7</sup> Over time, the other eye manifests with a small tumor that is detected during one of the examinations under anesthesia.<sup>8</sup> The likelihood of such a scenario is particularly high when the age at diagnosis is less than 3 months.<sup>9</sup> The simple presence of unilateral sporadic retinoblastoma cannot be interpreted as indicating that the child has the non-heritable form of retinoblastoma (see Fig. 70.2).

**'Pseudo' bilateral retinoblastoma** Rare 'pseudo' (iatrogenic) bilateral retinoblastoma may arise when the initial diagnosing ophthalmologist has had little experience in recognizing early retinoblastoma. During examination under anesthesia, infants and small children often are found to have, in the otherwise normal second eye, white 'dots' in the peripheral retina that are part of the peripheral meridional complex. If such an ambiguous peripheral white dot is detected in one eye and the other eye has advanced retinoblastoma, the ophthalmologist may feel pressure to treat such a 'lesion' with cryotherapy, 'just in case it might be retinoblastoma.' Such a move is a major error of judgment. A child that has unilateral disease is now inadvertently and inappropriately converted to 'pseudo-bilateral' status. Subsequently, genetic counselors may assume that the child has heritable retinoblastoma, unless the RB1 gene status is determined. The correct way to deal with these small white lesions is to repeat the examination in 3–4 weeks. If the 'lesion' was retinoblastoma it would have enlarged, but still be small enough to treat with local modalities alone. Color is another clue that is helpful in distinguishing these bright, white peripheral dots from retinoblastoma. Early intraretinal retinoblastoma is virtually transparent before it recruits a blood supply. It would never be bright or chalky-white in color.

**'Pseudo' Low-penetrance retinoblastoma** In rare families, mutations in RB1 lead to only partial rather than complete inactivation of pRB. Such families manifest with a large number of unaffected carriers or with retinocytoma, and are termed low-penetrance retinoblastoma.<sup>6,8,10</sup> It is possible that two remotely related individuals in a large family may manifest retinoblastoma due to two unrelated mutations, simulating low-penetrance retinoblastoma.<sup>11</sup>

**Genetic testing (DNA analysis of the RB1 mutation)** The enormous variability in the phenotype of RB1 cancer predisposition syndrome implies that every new retinoblastoma patient, regardless of laterality, age at diagnosis, or lack of a family history, should be considered to have the RB1 cancer predisposition syndrome (Table 70.3).<sup>12</sup> Each patient with the RB1 cancer syndrome has a high risk (95%) of being diagnosed with retinoblastoma in at least one eye in the first 5 years of life. Each has a lifelong predisposition to fatal non-ocular cancer that is 19 times greater than if the germline RB1 mutation were not present.<sup>13</sup>

In an ideal world all newly diagnosed retinoblastoma patients would have RB1 gene testing as part of the initial evaluation. Blood tests for RB1 DNA analysis should be as routine as ordering a chromosome analysis or FISH for detection of 13q14 deletion. Unfortunately, because of the cost of RB1 testing, that is not currently the practice in most clinical settings (Chapter 73). Our cost–benefit analysis of RB1 testing in unilateral retinoblastoma patients indicates that insurers would actually save a great deal of money through the elimination of expensive surveillance examinations under anesthesia in the unilateral patient. Kaiser Permanente Medical Group in Southern California is now routinely approving RB1 testing in unilateral patients. Our agreement with Kaiser is that if the RB1 testing is negative (and the risk of being a carrier of the germline mutation is reduced from 15–20% to about 1%) then we will examine these children in the office with posterior pole examinations and B-scan ultrasonography for peripheral retinal examination and eliminate the expensive EUAs that have been routine in the past.

California Children's Service (CCS) – the state agency that funds the care of all low-income patients with the diagnosis of retinoblastoma in California – has also agreed that it would be cost-effective for the State to routinely pay for RB1 gene testing in patients with unilateral disease. Implementation of that program is pending.

Details about the laboratories performing RB1 mutation analyses, the preparation and shipping of specimens are discussed in detail in Chapter 73. A reliable online site for information is [www.genetests.org](http://www.genetests.org). If the patient to be tested is bilaterally affected or has a clear family history, blood may be the only specimen required. If the patient has unilateral disease and no family history, some laboratories will not accept the specimen. Retinoblastoma Solutions (Toronto, Canada) will accept blood only in such cases, but prefers to have both a blood sample and retinoblastoma tumor tissue (fresh frozen). The difficulties of interpreting RB1 genetic tests are discussed elsewhere (Chapter 73).

**DIFFICULTIES CAUSED BY IMPRECISE TERMINOLOGY**

**Incidence of retinoblastoma** Virtually all of the reports defining the incidence of retinoblastoma in the last 30 years, except for one series,<sup>14</sup> report the incidence by lumping the heritable form with the non-heritable form. This lumping of diseases with different etiologies (genetic vs environmental) has obscured the fact that 'non-heritable' retinoblastoma may have a higher incidence among less affluent

populations, suggesting an association with poor living conditions and perhaps an infectious etiology.<sup>14</sup> This statement, taken from the 1996 paper of Stiller and Parkin,<sup>14</sup> is attracting a great deal of attention 10 years later (Chapter 67). The fact that such a fundamentally important feature of retinoblastoma (that unilateral non-heritable disease has a much higher incidence among economically disadvantaged populations) was unrecognized for 30 years suggests the problems associated with the use of imprecise language in defining a rare disease.

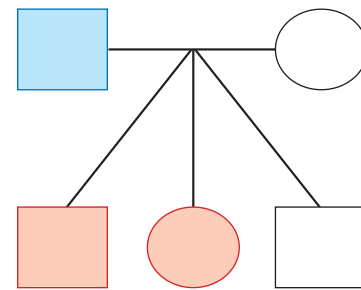
**Risk of second malignant neoplasms in unilateral retinoblastoma** Another example of the difficulties caused by imprecise use of language is demonstrated by the contamination of the 'non-hereditary' group of patients in the large series being followed for the incidence of non-ocular cancer with the RB1 cancer syndrome patients and unilateral disease.<sup>13</sup> This small level of data contamination is insignificant when large numbers of patients are involved, as in this study, but in smaller series it could pose a problem.

### CLINICAL MANAGEMENT

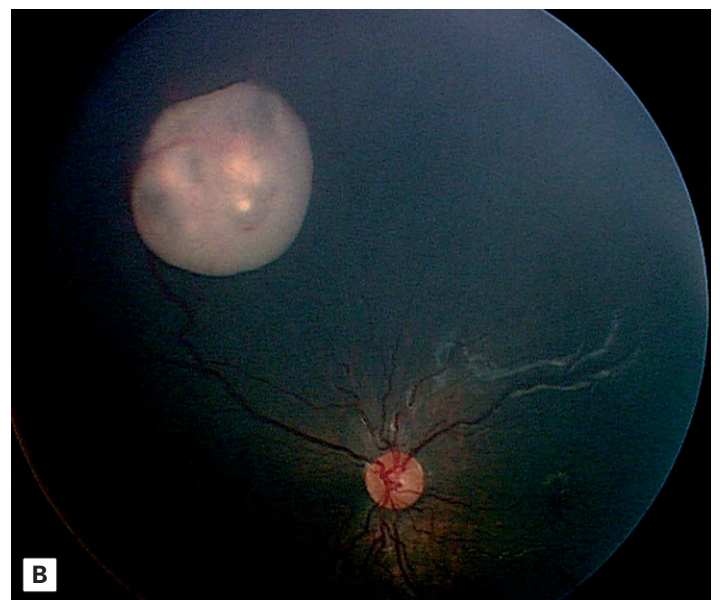
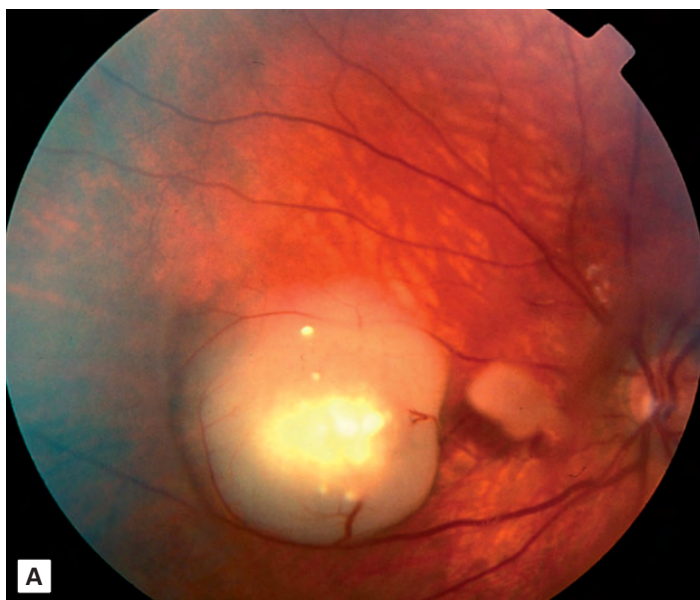
**First-degree relatives** Parents and siblings of the affected child should have a dilated examination of the retina looking for evidence of retinocytoma in family members older than 5 years, and for retinoblastoma in the younger family members (Fig. 70.3). Retinocytoma is usually diagnosed in parents when they are examined concurrently with the diagnosis of retinoblastoma in their child (Fig. 70.4).<sup>15</sup> Retinocytoma may also be present in children (under 5 years), in the same eye as active retinoblastoma or as the only lesion in the eye (Chapter 80). These lesions are confirmed as retinocytoma when they do not respond to either systemic chemotherapy or external beam radiotherapy.<sup>16</sup> Retinocytomas can be treated with laser photocoagulation using the same parameters as those described for post-chemotherapy consolidation in Chapter 75 in order to prevent the possibility of these lesions transforming into active retinoblastoma in the second or third decades of life.

**Treatment of unilateral retinoblastoma** In our Retinoblastoma Center at Children's Hospital Los Angeles, enucleation is strongly recommended for patients with unilateral retinoblastoma when the tumor presents with either local or diffuse intraocular tumor dissemination (Groups C, D, or E). Only extraordinary circumstances (such as the absence of vision in the uninvolved eye) would lead us to treat such a patient with brachytherapy (Group C) or systemic chemotherapy for unilateral Group D eyes.

**Radiation treatment** If there is advanced disease in the better eye we make every effort to delay the use of external beam radiotherapy until the child is as far past the first birthday as possible (Chapter 76). If the data suggesting a decreased incidence of radiogenic sarcoma with delayed radiation (after 1 year of age) are confirmed,<sup>17</sup> then the additive effect of the RB1 germline mutation and radiation in the etiology of non-ocular cancer can be potentially mitigated (Chapter 71).



**Fig. 70.4** Two of the triplets in this pedigree developed bilateral retinoblastoma (red). Fundus evaluation of the father led to the diagnosis of a retinocytoma (blue). (Reproduced with permission from Singh AD, Santos CM, Shields CL, Shields JA, Eagle RC Jr. Observations on 17 patients with retinocytoma. *Arch Ophthalmol* 2000; 118: 199–205.)



**Fig. 70.3** Retinocytoma in an adult (A). There is no family history of retinoblastoma. Note vitreous seeding. The lack of classically described RPE hyper- and hypopigmentation around the lesion is unusual in an adult. Early 'presumed' retinocytoma in a 18-month-old child (B). Active retinoblastoma and another retinocytoma were present in the fellow eye. The diagnosis of early 'presumed' retinocytoma was made on the basis of the complete failure of this lesion to respond to systemic chemotherapy.



**SUMMARY**

The patient with the germline *RB1* mutation has a lifelong predisposition to cancer that can be transmitted to his or her offspring. The clinical assumption that a sporadic, unilaterally affected patient does not have the syndrome is not only incorrect but also dangerous. The *RB1* cancer predisposition syndrome is very different from non-heritable retinoblastoma. If two patients, one with the *RB1* cancer predisposition syndrome and one with non-heritable retinoblastoma, each had a solitary retinoblastoma in only one eye, the tumors and the two patients would be indistinguishable by clinical examination, by ultrasound, MRI, pathology, or clinical response to treatment. However, the two

tumors would have a different etiology. The identification of the *RB1* cancer predisposition syndrome patient would have significant implications for the affected child and his or her family.

Non-heritable retinoblastoma is a diagnosis of exclusion and can only be made with certainty if *RB1* gene testing is negative. It is imperative that ophthalmologists navigate this paradigm shift in the approach to each newly diagnosed retinoblastoma. The new assumption must be that each newly diagnosed retinoblastoma patient, regardless of age at diagnosis, laterality, or lack of a positive family history, has the *RB1* cancer predisposition syndrome until that diagnosis is actively disproved.

**REFERENCES**

- Lohmann DR. Retinoblastoma. Atlas Genet Cytogenet Oncol Haematol. URL: <http://AtlasGeneticsOncology.org/Kpooones/RbkprID10031.Ltml> 1998.
- Gruber SB. New developments in Lynch syndrome (hereditary nonpolyposis colorectal cancer) and mismatch repair gene testing. Gastroenterology 2006; 130: 577–587.
- Knudson AG Jr. The genetics of childhood cancer. Cancer 1975; 35: 1022–1026.
- Knudson AG Jr. Nakahara memorial lecture. Hereditary cancer, oncogenes, and anti-oncogenes. Princess Takamatsu Symposium 1989; 20: 15–29.
- Valverde JR, Alonso J, Palacios I, Pestana A. *RB1* gene mutation update, a meta-analysis based on 932 reported mutations available in a searchable database. BMC Genet 2005; 6: 53.
- Lohmann DR, Brandt B, Hopping W, Passarge E, Horsthemke B. Distinct *RB1* gene mutations with low penetrance in hereditary retinoblastoma. Hum Genet 1994; 94: 349–354.
- Rubinfeld M, Abramson DH, Ellsworth RM, Kitchin FD. Unilateral vs. bilateral retinoblastoma. Correlations between age at diagnosis and stage of ocular disease. Ophthalmology 1986; 93: 1016–1019.
- Lee TC, Hayashi NI, Dunkel IJ et al. New retinoblastoma tumor formation in children initially treated with systemic carboplatin. Ophthalmology 2003; 110: 1989–1994; discussion 1994–1985.
- Abramson DH, Greenfield DS, Ellsworth RM. Bilateral retinoblastoma. Correlations between age at diagnosis and time course for new intraocular tumors. Ophthalmic Paediatr Genet 1992; 13: 1–7.
- Dryja TP, Rapaport J, McGee TL, Nork TM, Schwartz TL. Molecular etiology of low-penetrance retinoblastoma in two pedigrees. Am J Hum Genet 1993; 52: 1122–1128.
- Munier FL, Wang MX, Spence MA et al. Pseudo low penetrance in retinoblastoma. Fortuitous familial aggregation of sporadic cases caused by independently derived mutations in two large pedigrees. Arch Ophthalmol 1993; 111: 1507–1511.
- Brichard B, Heusterspreute M, De Potter P et al. Unilateral retinoblastoma, lack of familial history and older age does not exclude germline *RB1* gene mutation. Eur J Cancer 2006; 42: 65–72.
- Kleinerman RA, Tucker MA, Tarone RE et al. Risk of new cancers after radiotherapy in long-term survivors of retinoblastoma: an extended follow-up. J Clin Oncol 2005; 23: 2272–2279.
- Stillier CA, Parkin DM. Geographic and ethnic variations in the incidence of childhood cancer. Br Med Bull 1996; 52: 682–703.
- Singh AD, Santos CM, Shields CL, Shields JA, Eagle RC Jr. Observations on 17 patients with retinocytoma. Arch Ophthalmol 2000; 118: 199–205.
- Singh AD, Shields CL, Shields JA. Lack of response to chemoreduction in presumed well differentiated retinoblastoma. J Pediatr Ophthalmol Strabismus 2002; 39: 107–109.
- Abramson DH, Frank CM. Second nonocular tumors in survivors of bilateral retinoblastoma: a possible age effect on radiation-related risk. Ophthalmology 1998; 105: 573–579; discussion 579–580.

# Non-ocular tumors

Cari E. Lyle, Carlos Rodriguez-Galindo and Matthew W. Wilson

## INTRODUCTION

Retinoblastoma must be seen as more than an intraocular cancer representing a prototypical hereditary cancer in humans. Children with an RB1 germline mutation who survive heritable retinoblastoma (all familial cases, all bilateral cases, and about 15% of unilateral cases) are at an exceptionally high risk for developing and dying from subsequent primary tumors, particularly osteosarcomas and soft tissue sarcomas. The most feared non-ocular tumor is the intracranial primitive neuroectodermal tumor that arises in the pineal gland, the pinealoblastoma (Chapter 72). Those patients with heritable retinoblastoma who survive through childhood without developing trilateral retinoblastoma are still at increased risk for developing a variety of second non-ocular malignancies (Chapter 70).

## PATHOGENESIS

**Genetic susceptibility** Although non-heritable retinoblastoma makes up the vast majority of cases of this disease, it is those patients with the heritable form who are far more likely to develop second non-ocular malignancies (Fig. 71.1A). The high rate of subsequent cancers in heritable retinoblastoma is attributed to the presence of germline mutations in the retinoblastoma tumor suppressor gene, RB1. The protein encoded by RB1, p105 Rb, functions in multiple cellular processes, including proliferation, DNA replication, DNA repair, and cell-cycle checkpoint control. p105 Rb and the proteins that interact with it appear to play a role in many other cancers. Mutations in RB1 or altered expression of p105 Rb have been found in many sarcomas, small cell lung cancers, bladder cancer, primary breast tumors, and glioblastomas.

**Effects of radiation therapy** It is unknown what factors definitively predispose patients to second malignancies, and there are obviously many factors yet to be understood. However, in addition to increasing the incidence of non-ocular tumors, radiation therapy also influences the age of onset, location, and type of non-ocular cancer (Fig. 71.1B). For many years it was assumed that second non-ocular tumors in heritable retinoblastoma patients were a direct consequence of the radiation dosing: lower doses of radiation were then employed, but these malignancies continued to occur. This is discussed further in Chapter 76.

**Three subsets of patients** Further study of these patients who continued to develop second non-ocular tumors after dose reduction revealed three distinct subsets, the first being those who had received

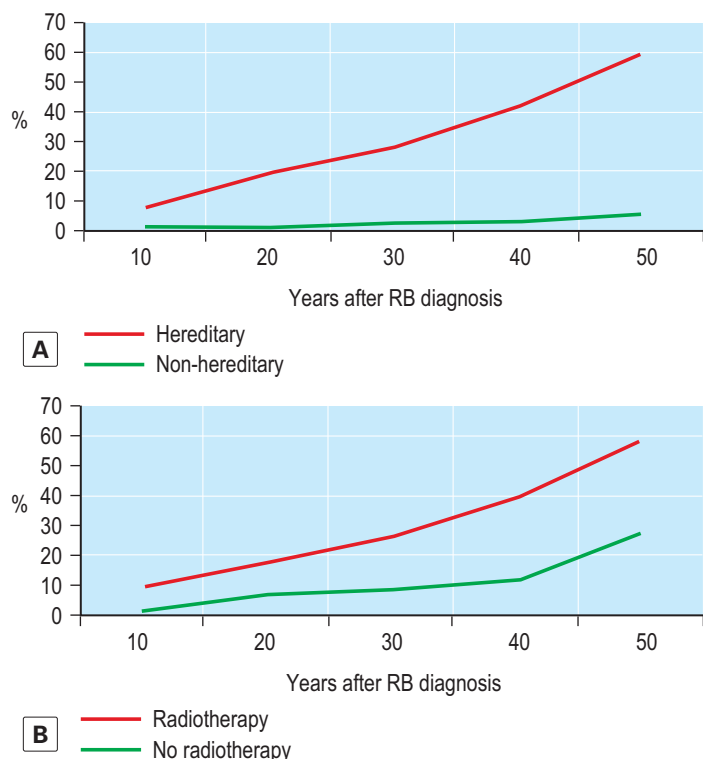
radiation to the orbits but developed second malignancies remote from the radiation field. The second subset of patients developed second tumors in the head and neck area mimicking radiation-induced malignancies, but these patients had not received prior radiation therapy. Lastly, there was a subset of patients who had large doses of radiation who developed later malignancies within the field of radiation.<sup>1,2</sup>

**Timing of the radiation therapy** also appears important. Receiving radiation treatment in the first year of life may place the patient at a greater risk of second tumors within the field of radiation than if the radiation is delayed until 1 year of age. This remains controversial, based on what is defined as being within the radiation field. If considering those tumors located strictly within the radiation field, there appears to be no effect on age at onset of the second malignancies. However, if the definition is expanded to tumors within the head and neck area, including the thyroid, pineal gland, and brain, there appears to be a significant age-related risk; therefore radiation should be delayed until 1 year of age or avoided if at all possible.<sup>1,3-7</sup>

**Increased incidence** There is a relationship between previous radiation therapy and the development of a second malignancy which is neither linear nor definite. External beam radiation therapy increases the risk of developing second non-ocular malignancies in patients with heritable retinoblastoma.<sup>3-5</sup> This risk is not observed in patients with non-heritable retinoblastoma.<sup>8,9</sup>

**Age of onset** of non-ocular tumors is variable, and increases in incidence with age. In essence, the longer a retinoblastoma patient survives, the higher the risk of developing a non-ocular tumor. Osteosarcomas usually develop during the growth-spurt years, not significantly differently from the normal population.<sup>6-8</sup> However, studies suggest that there may be a bimodal distribution between the ages of 5 and 7 years, and then a second incidence peak in the early teenage years, whereas sporadic osteosarcomas tend to occur in the later teenage years.<sup>8</sup>

**Location** of non-ocular tumors is variable, and obviously corresponds with the cell of origin of the tumor. Osteosarcomas are the most common and tend to occur predominantly in the field of radiation, although there are many reports of these sarcomas developing remote from the radiation, again discouraging the assumption that such tumors are strictly a consequence of radiation therapy



**Fig. 71.1** Cumulative incidence of second malignancy following diagnosis of retinoblastoma in patients with hereditary and non hereditary retinoblastoma (**A**) and in the hereditary retinoblastoma with and without radiation treatment (**B**). (Data derived from Wong FL, Boice JD, Abramson DH et al. Cancer incidence after retinoblastoma. Radiation dose and sarcoma risk. JAMA 1997; 278: 1262–1267.)

(Fig. 71. 2). Overall, about 70% of the tumors occur in the head and neck region.<sup>3,8</sup>

### TYPES OF SECOND MALIGNANCY

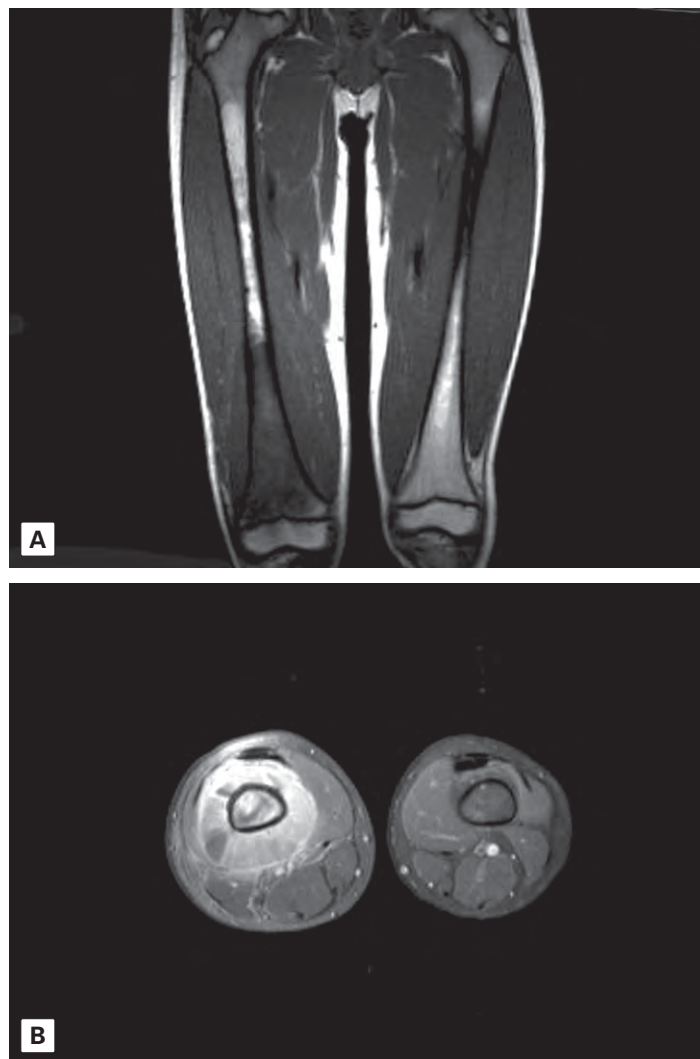Two major types of second malignancy are observed in patients with childhood cancers: radiation-associated solid non-hematopoietic tumors, and alkylating agent- and topoisomerase-II inhibitor-related acute myeloid leukemia and myelodysplastic syndrome.

#### Radiation-associated solid non-hematopoietic tumors

Most patients with retinoblastoma develop solid non-hematopoietic tumors. Osteosarcomas, both inside and outside the radiation field, make up a third of second malignancies; soft tissue sarcomas and melanomas are the next most common. Although hematopoietic tumors are a dreaded consequence of other childhood cancers treated with alkylating agents, there are few reports in the retinoblastoma literature documenting hematopoietic second malignancies.

#### Alkylating agent and topoisomerase-II inhibitor-related acute myeloid leukemia and myelodysplastic syndrome

Retinoblastoma is a chemosensitive tumor; cytoreduction combined with intensive focal therapies is a desirable regimen to avoid radiation. However, because of the feared development of a secondary leukemia or myelodysplastic syndrome, multi-agent chemotherapy regimens avoiding the use of alkylating agents are recommended at St. Jude's Children's Research Hospital, Memphis, Tennessee, United States.<sup>10</sup> Likewise, some centers have avoided the use of etoposide to diminish the risk of secondary acute myelogenous leukemias.



**Fig. 71.2** A 7-year-old boy treated for bilateral retinoblastoma during the first year of life who presented with right thigh pain and swelling. A coronal T<sub>1</sub>-weighted (**A**) and transverse plane (**B**) MRI shows a mass arising from the right distal femur. Biopsy confirmed a primitive neuroectodermal tumor.

### INCIDENCE

In the United States, more retinoblastoma patients die of non-ocular cancers than from the initial eye tumor. Reports of the cumulative incidence of second cancers in patients with germline RB1 mutations vary, but it is believed to be approximately 1% per year of life. The 5-year incidence is about 5%, increasing to almost 50% at 50 years of age, although a more recent study estimates a considerably lower risk (see Chapter 76).<sup>8,9,11,12</sup> Kleinerman et al.<sup>13</sup> compared subsequent cancer risk in 963 heritable retinoblastoma patients and 638 non-heritable retinoblastoma patients and found a threefold greater risk of developing second cancers in the heritable patients. The heritable patients had a cumulative risk of 36% of developing a new cancer 50 years after diagnosis.

### CLINICAL FEATURES

A wide variety of neoplasms have been described in survivors of retinoblastoma. Not only are these patients at risk for second non-ocular



tumors, there is a lifelong risk for the development of additional third, fourth, and fifth non-ocular cancers.<sup>3,8,14</sup> As mentioned earlier, the most common second malignancy is osteosarcoma, which accounts for approximately one-third of cases.<sup>8</sup> Soft tissue sarcomas and melanomas are second in frequency, accounting for 20–25% of the cases. Hematopoietic tumors such as non-Hodgkin's lymphoma and leukemia, and sebaceous gland carcinomas of the eyelid have also been reported.

In recent years it has become apparent that patients with heritable retinoblastoma are also at risk of developing epithelial cancers late in adulthood.<sup>5</sup> Of these, lung cancer appears to be the most common, followed by bladder cancer.<sup>5,15</sup> This is not surprising, as somatic mutations of the RB1 gene are known to contribute to the development of lung cancer.<sup>15,16</sup> Finally, an interesting observation is the increased incidence of lipomas in survivors of hereditary retinoblastoma. The incidence of a second neoplasm appears to be higher in those patients with lipomas, suggesting that the presence of lipoma could be a clinical marker of susceptibility to second neoplasms.<sup>17</sup>

## TREATMENT

Despite the incidence of second malignancies, little has been written addressing the outcome and treatment of patients found to develop non-ocular malignancies. These tumors tend to be more aggressive than their 'de novo' counterparts, although it is not known whether this is related to their genetic susceptibility or due to damage resulting from irradiation or alkylating agents.<sup>1</sup> The treatment of the different types of non-ocular tumors is highly variable, depending on the tumor's cell of origin as well as its location and extent. Radical resection, often combined with preoperative chemotherapy, is the treatment modality of choice. Avoidance of further radiation to potentially radiation-induced second malignancies is desirable where possible.<sup>11,12,18</sup>

## PREVENTION

Delay of radiation therapy should be a goal when designing treatment for children with heritable retinoblastoma. Studies show that the therapeutic strategy of chemoreduction and aggressive focal treatments can successfully delay the use of radiation therapy for at least 6 or 7 months (median age 21 months).<sup>4,10,19</sup> In addition to theoretically decreasing the risk of second cancers, delaying radiation therapy may also allow more complete facial and orbital growth, thus reducing the degree of midfacial deformity.<sup>2,21,22</sup> However, with a multidisciplinary approach the dose of radiation needed for disease control may also be reduced. Avoidance of other mutagens, such as sun (UV) exposure, cigarette smoking, and (when possible) multi-agent chemotherapy, is recommended.

## SCREENING

Screening children for second malignancies is a lifelong process, as the risk for these tumors increases with age. The most important aspect of screening starts with educating the family on the lifelong risks of this disease and common signs of non-ocular cancers. As mentioned, it has been suggested that an increased number of lipomas may be a marker for the development of second malignancies; patients and physicians should be alert to this, as half of the lipomas reported were noted prior to the development of the second malignancy.<sup>17</sup> Perhaps similar markers will be identified in the future that will further aid the screening process.

As part of the initial evaluation, MRI scanning of the head is performed to exclude the presence of a pinealoblastoma. Subsequent screening for central nervous system tumors varies between institutions, with some favoring repeat MRIs as frequently as every 6 months, whereas others defer screening. Instead, these centers alert the parents to the signs and symptoms of central nervous system tumors and obtain imaging when indicated.

## PROGNOSIS

The morbidity and mortality of patients with non-ocular tumors are high. In one study,<sup>18</sup> more than 65% of patients with second non-ocular tumors died before an additional malignancy developed; however, of those who survived, 40% developed a third non-ocular tumor. Most of the patients who developed third non-ocular cancers received radiation therapy as part of their retinoblastoma therapy, and the majority had received it prior to 1 year of age. The types of cancers constituting the third and additional non-ocular tumors are similar to second tumors, with soft tissue tumors in the head constituting one-third of the third tumors, skin cancers being the next most common.<sup>18</sup> Ultimately, most bilateral retinoblastoma patients will have multiple cancers that will shorten their life expectancy.

## SUMMARY

More patients with retinoblastoma will die from second non-ocular malignancies than from their original disease. There is a lifetime risk of the development of these second non-ocular tumors, and patients must be educated on the fact that they are never truly 'cured.' Patients with the heritable germline form of retinoblastoma, the RB1 cancer predisposition syndrome are at markedly increased risk for the development of these tumors compared to the non-heritable form. Radiation also appears to increase the risk of developing second non-ocular tumors and must therefore be avoided when possible. The prognosis for patients with second non-ocular malignancies is grim, and highlights the importance of counseling patients with the heritable form of the disease.

## REFERENCES

- Abramson DH, Frank CM. Second nonocular tumors in survivors of bilateral retinoblastoma. A possible age effect on radiation-related risk. *Ophthalmology* 1998; 105: 573–580.
- Moll AC, Imhof SM, Schouten-Van Meeteren AY et al. Second primary tumors in hereditary retinoblastoma: a register-based study, 1945–1997: is there an age effect on radiation-related risk? *Ophthalmology* 2001; 108: 1109–1114.
- Fletcher O, Easton D, Anderson K et al. Lifetime risks of common cancers among retinoblastoma survivors. *J Natl Cancer Inst* 2004; 96: 357–363.
- Wong FL, Boice JD, Abramson DH et al. Cancer incidence after retinoblastoma. Radiation dose and sarcoma risk. *JAMA* 1997; 278: 1262–1267.
- Eng G, Li FP, Abramson DH et al. Mortality from second tumors among long-term survivors of retinoblastoma. *J Natl Cancer Inst* 1993; 85: 1121–1128.
- Abramson DH. Second nonocular cancers in retinoblastoma: a unified hypothesis. The Franceschetti Lecture. *Ophthalm Genet* 1999; 99: 193–204.
- Abramson DH. Retinoblastoma in the 20th Century: Past success and future challenges. The Weisenfeld Lecture. *Invest Ophthalmol Vis Sci* 2005; 46: 2684–2691.
- Chauveinc L, Mosseri V, Quintana E et al. Osteosarcoma following retinoblastoma: age at onset and latency period. *Ophthalm Genet* 2001; 22: 77–88.
- Mohney BG, Robertson DM, Schomberg PJ, Hodge DO. Second nonocular tumors in survivors of heritable retinoblastoma and prior radiation therapy. *Am J Ophthalmol* 1998; 126: 269–277.
- Rodriguez-Galindo C, Wilson MW, Haik BG et al. Treatment of intraocular retinoblastoma with vincristine and carboplatin. *J Clin Oncol* 2003; 21: 2019–2025.

11. Dunkel IJ, Gerald WL, Rosenfield NS et al. Outcome of patients with a history of bilateral retinoblastoma treated for a second malignancy: The Memorial Sloan-Kettering experience. *Med Pediatr Oncol* 1998; 30: 59–62.
12. Fontanesi J, Parham DM, Pratt C, Meyer D. Second malignant neoplasms in children with retinoblastoma: the St. Jude Children's Research Hospital experience. *Ophthalm Genet* 1996; 16: 105–108.
13. Kleinerman RA, Tucker MA, Tarone RE et al. Risk of new cancers after radiotherapy in long-term survivors of retinoblastoma: An extended follow up. *J Clin Oncol* 2005; 23: 2272–2279.
14. Abramson DH, Melson MR, Dunkel IJ, Frank CM. Third (fourth and fifth) nonocular tumors in survivors of retinoblastoma. *Ophthalmology* 2001; 108: 1868–1876.
15. Kleinerman RA, Tarone RE, Abramson DH et al. Hereditary retinoblastoma and risk of lung cancer. *J Natl Cancer Inst* 2000; 92: 2037–2039.
16. Harbour JW, Lai SL, Whang-Peng J et al. Abnormalities in structure and expression of the human retinoblastoma gene in SCLC. *Science* 1988; 241: 353–357.
17. Li FP, Abramson DH, Tarone RE et al. Hereditary retinoblastoma, lipoma, and second primary cancers. *J Natl Cancer Inst* 1997; 89: 83–84.
18. Aerts I, Pacquement H, Doz F et al. Outcome of second malignancies after retinoblastoma: a retrospective analysis of 25 patients treated at the Institut Curie. *Eur J Cancer* 2004; 40: 1522–1529.
19. Shields CL, Honavar SG, Meadows AT et al. Chemoreduction plus focal therapy for retinoblastoma: Factors predictive of need for treatment with external beam radiotherapy or enucleation. *Am J Ophthalmol* 2002; 133: 657–664.
20. Abramson DH, Beaverson KL, Chang ST, Dunkel IJ, McCormick B. Outcome following initial external beam radiotherapy in patients with Reese-Ellsworth group Vb retinoblastoma. *Arch Ophthalmol*. 2004; 122: 1316–13s23.
21. Yue NC, Benson ML. The hourglass deformity as a consequence of orbital irradiation for bilateral retinoblastoma. *Pediatr Radiol* 1996; 26: 421–423.
22. Merchant TE, Gould CJ, Hilton NE et al. Ocular preservation after 36 Gy external beam radiation therapy for retinoblastoma. *J Pediatr Hematol Oncol* 2002; 24: 246–249.

# Trilateral retinoblastoma

Cari E. Lyle, Carlos Rodriguez-Galindo and Matthew W. Wilson

## INTRODUCTION

As discussed in Chapter 71, children who survive heritable retinoblastoma are at an exceptionally high risk for developing and dying from subsequent primary tumors, particularly osteosarcomas and soft tissue sarcomas. The most feared non-ocular tumor is the intracranial primitive neuroectodermal tumor that arises in the pineal gland, the pinealoblastoma. Trilateral retinoblastoma refers to the association of bilateral retinoblastoma with an asynchronous intracranial tumor.<sup>1–3</sup> The connection between retinoblastoma and these intracranial tumors was first recognized in the 1970s and reported by Jakobiec et al.<sup>4</sup> in two patients. In 1980, Bader et al.<sup>5</sup> reported a series of 10 children with bilateral retinoblastoma who developed malignancy in the pineal gland. In lower animals, the pineal gland functions as a photoreceptor organ and is commonly referred to as the ‘third eye.’ The term trilateral retinoblastoma was first coined by Bader et al. because of the common embryologic origin of both the pineal gland and the retina.

## NATURE OF THE MIDLINE INTRACRANIAL TUMORS

The tumors that constitute trilateral retinoblastoma are primitive neuroectodermal tumors exhibiting varying degrees of neuronal or photoreceptor differentiation, suggesting an origin from the germinal layer of primitive cells.<sup>6</sup> The majority of these tumors are pineoblastomas, but in 20–25% of cases are suprasellar or parasellar. In most cases they resemble undifferentiated retinoblastomas, with the more frequent formation of Homer Wright rosettes.

Although trilateral retinoblastoma was classically defined in patients with bilateral retinoblastoma who developed an intracranial tumor, there are case reports of patients with unilateral retinoblastoma who have developed a pineoblastoma, suprasellar, or parasellar tumor.<sup>7–11</sup> There are also reports of siblings of patients with retinoblastoma who developed intracranial malignancies of primitive neuroectodermal origin without having clinical evidence of an intraocular tumor.<sup>7</sup> In these cases, the midline intracranial malignancies appear to represent a focus of multicentric tumorigenesis in patients with the RB1 cancer predisposition syndrome, who failed to develop retinoblastoma in one or both eyes. Patients with unilateral retinoblastoma who develop an intracranial tumor are more likely to develop a suprasellar tumor than a pineal gland one.<sup>12</sup> However, there does not appear to be a specific genetic mutation in these patients that is unique to traditional trilateral retinoblastoma. It is presumed that these patients all have a germline mutation, although this has not been confirmed by gene mutational analysis in all reported cases reported.

## INCIDENCE OF TRILATERAL RETINOBLASTOMA

The incidence of trilateral retinoblastoma is approximately 3% for all patients with retinoblastoma, and is estimated at around 5–6% for patients with bilateral retinoblastoma; the incidence may be as high as 10–15% in patients with familial retinoblastoma.<sup>3,13</sup> In recent years, with the more widespread use of chemoreduction treatments for patients with bilateral retinoblastoma, the incidence of trilateral retinoblastoma has decreased dramatically. Some feel that patients with the genetic form of retinoblastoma who receive chemotherapy for their intraocular disease are protected against pinealoblastoma.<sup>14,15</sup> The chemotherapeutic agents typically used for the treatment of bilateral retinoblastoma are also effective in the treatment of primitive neuroectodermal neoplasms of the central nervous system in children, which are the type of neoplasm that constitute trilateral retinoblastoma. A common treatment strategy for the management of retinoblastoma is a triple-agent regimen of carboplatin, vincristine, and etoposide, administered generally for six cycles.<sup>14</sup> An alternative explanation is that the primary use of chemotherapy has reduced the use of external beam radiotherapy and its subsequent oncogenic effects in patients with the heritable form of the disease.

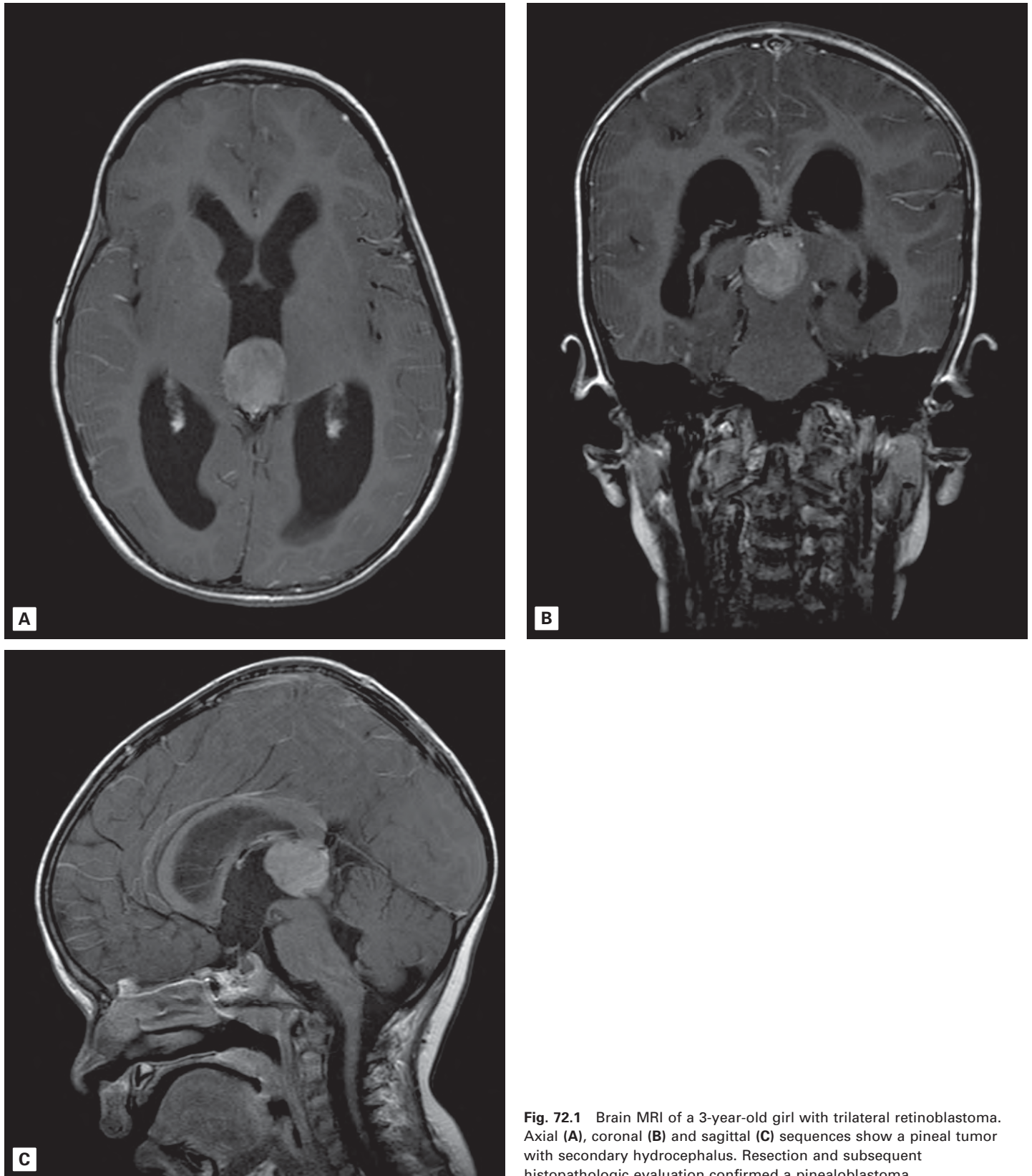
## AGE AT DIAGNOSIS

The median age at diagnosis of trilateral retinoblastoma is reported variously as 23–48 months,<sup>1–3,13</sup> and the interval between the diagnosis of bilateral retinoblastoma and the diagnosis of the brain tumor is usually more than 20 months.<sup>1,12</sup> Not surprisingly, patients with trilateral retinoblastoma were usually diagnosed with their initial disease by 6–8 months of age, which is slightly earlier than the average age at diagnosis for bilateral retinoblastoma.<sup>12</sup> Perhaps this indicates a more clinically and biologically aggressive disease. Suprasellar tumors are usually diagnosed much earlier than pinealoblastomas, on average 1 month after the diagnosis of retinoblastoma.<sup>12</sup> In 15–20% of cases the detection of the intracranial tumor occurs before the diagnosis of retinoblastoma.<sup>2</sup> These intracranial tumors are often discovered incidentally after signs or symptoms of increased intracranial pressure develop, prompting imaging studies of the brain. The most common presenting symptoms of these intracranial tumors are lethargy, anorexia, vomiting, and gait disturbances.<sup>3</sup>

## SCREENING FOR TRILATERAL RETINOBLASTOMA

The children at highest risk for developing trilateral retinoblastoma are those with bilateral disease and a family history of retinoblastoma. Almost half of trilateral patients have a positive family history of





**Fig. 72.1** Brain MRI of a 3-year-old girl with trilateral retinoblastoma. Axial (A), coronal (B) and sagittal (C) sequences show a pineal tumor with secondary hydrocephalus. Resection and subsequent histopathologic evaluation confirmed a pinealoblastoma.

retinoblastoma.<sup>1</sup> Because of the poor prognosis of trilateral retinoblastoma, screening the midline lesions with neuroimaging is a common practice, although the screening recommendations are somewhat controversial. There is almost universal agreement that MRI of the brain and orbits at diagnosis is helpful to rule out the concurrent presence of intraocular and intracranial neoplasms. The controversy arises as to

how often subsequent neuroimaging should occur and when should it be discontinued.

One-quarter of the cases in the literature were found during screening.<sup>1</sup> Given the short interval between the diagnosis of retinoblastoma and the occurrence of trilateral retinoblastoma, routine screening might detect the majority of cases within 2 years.<sup>1</sup> Although it is not

clear whether early diagnosis can affect survival,<sup>16</sup> many centers perform neuroimaging every 6 months until the child is 5 years of age.<sup>1,2,17</sup> More recently, the preference has been the use of magnetic resonance imaging (MRI) rather than computed tomography (CT) to avoid unnecessary radiation exposure (Fig. 72.1).

## PROGNOSIS

The prognosis for trilateral retinoblastoma is dismal: patients usually die of disseminated neuroaxis disease in less than 9 months.<sup>1,12,13</sup> In the United States, trilateral retinoblastoma was the principal cause of death from retinoblastoma during the first decade of life.<sup>3</sup> The average survival time after diagnosis of trilateral retinoblastoma is 6 months, regardless of the location of the intracranial tumor. Patients who were asymptomatic at the time of diagnosis of intracranial disease had a better overall survival than those who were symptomatic.

## TREATMENT

The rare survivors are usually those diagnosed during neuroimaging and treated with intensive chemotherapy with or without craniospinal

irradiation.<sup>1</sup> Pinealoblastoma occurring in non-retinoblastoma patients is also associated with a poor prognosis. However, with an appropriate aggressive multimodal approach these patients can be cured. Pinealoblastoma is a chemosensitive neoplasm and appears to have a steep dose–response curve for alkylating agents. Studies in older patients with primary pinealoblastoma have recently shown that treatment with complete resection and intensive alkylator- and cisplatin-based therapy, followed by craniospinal irradiation (36 Gy with boost to pineal gland to 59 Gy), and consolidation with high-dose chemotherapy and autologous stem cell rescue, may produce survival in more than two-thirds of cases.<sup>18</sup> It is therefore possible that similar treatment guidelines could be used for trilateral retinoblastoma. One must, however, consider the serious long-term toxicities of such doses of radiation in the very young child. Current strategies are directed toward avoiding irradiation using intensive chemotherapy followed by consolidation with autologous stem cell rescue, an approach similar to those being used in the treatment of brain tumors in infants.

## REFERENCES

1. Kivelä T. Trilateral retinoblastoma: a meta-analysis of hereditary retinoblastoma associated with primary ectopic intracranial retinoblastoma. *J Clin Oncol* 1999; 17: 1829–1837.
2. Amoaku WMK, Willshaw HE, Parkes SE, Shah KJ, Mann JR. Trilateral retinoblastoma: A report of five patients. *Cancer* 1996; 78: 858–863.
3. Blach LE, McCormick B, Abramson DH, Ellsworth RM. Trilateral retinoblastoma – incidence and outcome: decade of experience. *Int J Radiat Oncol Biol Phys* 1994; 29: 729–733.
4. Jakobiec FA, Tso MO, Zimmerman LE, Danis P. Retinoblastoma and intracranial malignancy. *Cancer* 1977; 39: 2048–2058.
5. Bader JL, Meadows AT, Zimmerman LE, Champion LA, Voule PA. Trilateral retinoblastoma. *Lancet* 1980; 2: 582–583.
6. Marcus DM, Brooks SE, Leff G et al. Trilateral retinoblastoma: insights into histogenesis and management. *Surv Ophthalmol* 1998; 43: 59–70.
7. DePotter P, Shields CL, Shields JA. Clinical variations of trilateral retinoblastoma: a report of 13 cases. *J Pediatr Ophthalmol Strabismus*. 1994; 31: 26–31.
8. Bullitt E, Crain BJ. Retinoblastoma as a possible primary intracranial tumor. *Neurosurgery* 1981; 9: 706–709.
9. Stannard C, Knight BK, Sealy R. Pineal malignant neoplasm in association with hereditary retinoblastoma. *Br J Ophthalmol* 1985; 69: 749–753.
10. Whittle IR, McClellan K, Martin FJ, Johnston IH. Concurrent pineoblastoma and unilateral retinoblastoma: a forme fruste of trilateral retinoblastoma. *Neurosurgery* 1985; 17: 500–505.
11. Kingston JE, Plowman PN, Hungerford JL. Ectopic intracranial retinoblastoma in childhood. *Br J Ophthalmol* 1985; 107: 742–748.
12. Paulino AC. Trilateral retinoblastoma: Is the location of the intracranial tumor important? *Cancer* 1999; 86: 135–141.
13. Holladay DA, Holladay A, Montebello JF, Redmond KP. Clinical presentation, treatment, and outcome of trilateral retinoblastoma. *Cancer* 1991; 67: 710–715.
14. Shields CL, Meadows AT, Shields JA, Carvalho C, Smith AF. Chemoreduction for retinoblastoma may prevent intracranial neuroblastic malignancy (trilateral retinoblastoma). *Arch Ophthalmol* 2001; 119: 1269–1272.
15. Rodriguez-Galindo C, Wilson MW, Haik BG et al. Treatment of intraocular retinoblastoma with vincristine and carboplatin. *J Clin Oncol* 2003; 21: 2019–2025.
16. Moll AC, Imhof SMS, Schouten-van Meeteren AYN, and Boers M. Trilateral retinoblastoma: Is the location of the intracranial tumor important? [Letter to the Editor] *Cancer* 2000; 88: 965–966.
17. Singh AD, Shields CL, Shields JA. New insights into trilateral retinoblastoma. *Cancer* 1999; 86: 3–5.
18. Gururangan S, McLaughlin C, Quinn J et al. High-dose chemotherapy with autologous stem-cell rescue in children and adults with newly diagnosed pineoblastomas. *J Clin Oncol* 2003; 21: 2187–2191.

# Retinoblastoma: genetic testing and counseling

## PART A: GENETIC TESTING AND COUNSELING

Robin D. Clark and Nancy C. Mansfield

### INTRODUCTION

Genetic counseling for retinoblastoma is simple at first glance, but complex in practice. The appearance of simplicity, in part, lies in the fact that there is only one gene involved, *RB1*. The fact that all patients with bilateral retinoblastoma have a germline mutation in *RB1* reinforces that perception. However, for those with unilateral retinoblastoma, genetic counseling is less straightforward as only about 15–20% will have a germline mutation. Although most patients are young children whose parents have specific concerns, genetic counselors must also be prepared to counsel adult Rb survivors who are at risk for second non-ocular cancers. Mosaicism and low penetrance mutations may make risk assessments difficult. The optimum surveillance strategy for second primary cancers in retinoblastoma survivors has not been developed, so it is difficult to offer guidance to mutation carriers who want to manage their cancer risk. Finally, pregnant patients whose fetuses are at risk for retinoblastoma pose a challenge for the geneticist as *RB1* gene testing must be completed within a narrow timeframe.

In some centers, a genetics professional works with the retinoblastoma team. In other settings, the treating ophthalmologist must communicate genetic information to the patient without special training in the field. Further, if there are no mental health professionals on the retinoblastoma team, often the treating physician may be called upon to deal with the emotional fallout that results from the complex genetic information the family is given. The impact of genetic counseling and testing reaches across generations and even into the future, as it affects reproductive decisions regarding future children. The purpose of this chapter is to help the professional providing genetic counseling, whether experienced or otherwise, to be successful when counseling a family with this disease.

### BACKGROUND

**Who is the patient in genetic counseling?** It may be helpful to redefine the concept of the patient in the context of genetic counseling. The patient with retinoblastoma comes with a family, and for the geneticist or medical professional providing the counseling, that family is the patient. The genetic counseling ‘patient’ in fact consists of three persons: two parents and a child or a potential child. Often, depending on the family, the patient list can include siblings, the

extended family, and their offspring. When speaking with the parents of an affected child, the child and parents must be thought of together: ‘what helps one, helps all, and conversely, what hurts one, will hurt all.’ This point of view gives the geneticist a unique perspective that is different from others on the retinoblastoma team.

**Who should be referred for genetic counseling?** Individuals with bilateral retinoblastoma may be more likely to be referred for genetic counseling because they all have a germline mutation. Because individuals with bilateral retinoblastoma have a 50% chance of passing their *RB1* gene mutation to their offspring, these patients often seek genetic counseling during their reproductive years. It is always best to start the counseling and testing process prior to conceiving a pregnancy. When a mutation has been detected in the affected parent, counseling should cover more than the option of prenatal diagnosis with amniocentesis or chorionic villous sampling. Patients should also be made aware of other reproductive strategies that lower the risk for retinoblastoma in their offspring. These include adoption, in vitro fertilization with donor egg or sperm and embryo selection using preimplantation diagnosis for the *RB1* mutation. Termination of an affected pregnancy is an option but it should not be used as the deciding factor in choosing or rejecting prenatal diagnosis. For those who choose to continue an affected pregnancy, detailed ultrasound imaging of the fetal eye may allow early detection of an intraocular mass. Visualization of a fetal retinoblastoma tumor may prompt the decision to deliver preterm as early intervention may salvage vision in the affected eye. Those who choose not to have prenatal diagnosis may choose to have *RB1* gene analysis performed immediately after birth. However, these at-risk babies should have their eyes dilated and examined by a qualified ophthalmologist before leaving the hospital and at short intervals, every 2–3 weeks until their mutation status is known.

Individuals with unilateral retinoblastoma have more to gain from genetic counseling and yet are less likely to be referred because the genetic impact of their diagnosis is not appreciated from the pedigree. A common mistake in counseling is to minimize the risk for a germline mutation in the individual with sporadic unilateral retinoblastoma. These patients are often advised that the chance of an *RB1* germline mutation is so low that testing is not warranted. In fact, a germline mutation is found in about 15% or 1 in 8 of sporadic unilateral retino-



blastoma patients. By comparison, this risk is much higher than the likelihood of finding a chromosome abnormality in a pregnant 40-year-old woman, who will be offered an invasive procedure, amniocentesis. Likewise, the risk is higher than it is for a chromosome anomaly in an individual with mental retardation, who will be routinely offered chromosome analysis. Retinoblastoma patients, especially those with a unilateral tumor, may be discouraged from RB1 gene testing because DNA studies are very expensive and the yield is low. The potential problems, such as non-informative results if a tumor sample is not available, or the chance of undetected mosaicism, may be given as further justification for not offering RB1 gene analysis. However, when a germline mutation is detected, all aspects of care – treatment, prognosis for second tumors and reproductive counseling – are affected. Conversely, individuals with sporadic unilateral retinoblastoma who do not have a germline mutation will need fewer examinations under anesthesia and less intense monitoring for retinoblastoma in the unaffected eye. In our center, and in many retinoblastoma centers in Canada and Europe, individuals with sporadic unilateral retinoblastoma are being routinely tested for RB1 germline mutations, even in the absence of a sample of tumor DNA.

### INTEGRATING GENETIC SERVICES INTO THE RETINOBLASTOMA TEAM

Genetic information is valuable to all members of the team. The well-integrated team incorporates family and genetic information into their regular protocols. For example, with low penetrance mutations in mind, the ophthalmologist would routinely examine the parents and siblings of a retinoblastoma patient to check for retinocytoma/retinoma. When possible, radiation therapy would be avoided until RB1 gene analysis is complete. The ophthalmologist would routinely freeze a tumor sample from the affected enucleated eye to make it available for future RB1 gene testing. The ocular pathologist, who might prefer an intact sample, would agree to ‘share’ the tumor for the purpose of optimizing genetic analysis of the tumor. When the RB1 genetic analysis is complete, the ophthalmologist would modify the management plan accordingly, perhaps by performing office examinations with ultrasound instead of examinations under anesthesia after the likelihood of an RB1 germline mutation has been substantially reduced. Perhaps the best sign that the team understands the importance of genetic testing is that patients and their families are referred for genetic counseling long before the next pregnancy is under way.

### THE ROLE OF THE GENETIC COUNSELOR

The role of the genetics professional is twofold. First, the counselor must assess risk and communicate this complex information to the patient and guide the family through the genetic testing process when they choose to go forward. The second part of the job, which is equally challenging, is to communicate the genetic information to the other members of the team and help structure a personalized plan for treatment and long-term management. To be effective in both aspects of the job requires familiarity with this rare disorder and integration into the retinoblastoma team. Not surprisingly, this can be more difficult than it might initially seem.

Retinoblastoma is rare and, because of this, few geneticists outside pediatric cancer centers have counseled more than an occasional family with this disorder. In some situations, the treating ophthalmologist fills this role. The geneticist is at a disadvantage because of inexperience with retinoblastoma, whereas the ophthalmologist is at a disadvantage because of lack of knowledge about the limitations of genetic

testing and counseling. Commonly, but not optimally, a pregnancy inspires the initial referral for genetic counseling for a parent of an affected child or in an adult retinoblastoma survivor. In this situation, genetic counseling may take place in the context of a prenatal diagnosis clinic and the focus may be inappropriately limited to reproductive issues. For instance, a patient might be told that it is not worth pursuing RB1 mutation analysis because the results would not be back in time to make a diagnosis in the current pregnancy. However, the implications of RB1 gene testing are much broader and deserve a comprehensive approach. The consequences of having a germline RB1 mutation are lifelong and serious. For these reasons, it is better to start the genetic counseling process prior to a pregnancy. Optimally, a genetic counselor who is both familiar with the disease and affiliated with a comprehensive retinoblastoma team should provide comprehensive counseling.

### THE GENETIC COUNSELING AND TESTING PROCESS

#### Available DNA testing options and interpreting results

It is beyond the scope of this chapter to review the molecular genetics of heritable retinoblastoma. Over 500 germline mutations have been found in the RB1 gene in association with retinoblastoma, and new mutations are still being described. For the great majority of these, no phenotype genotype correlations have been established. Several recent reviews are recommended.<sup>1,2</sup>

For a comparison of the commercial testing laboratories, the tests they perform, including detection rates, and their individual requirements for DNA specimens, please consult [www.genetests.org](http://www.genetests.org). From the home page click on the Laboratory Directory tab at the top and search all laboratories for retinoblastoma. Dramatic technical improvements have taken place recently, increasing the ability of reference laboratories to detect germline mutations. To get the broadest search for the laboratories that do RB1 gene testing and comparative information about the depth of testing do not restrict the search by location. Contact the laboratory before sending a sample, and familiarize yourself with their testing methods, their detection rate, the turnaround time, their billing requirements, and the level of support they provide throughout the testing process. Generally, it is best to choose a laboratory that does not rely solely on one testing technique, for example gene sequencing. The highest detection rate is achieved by using gene sequencing with a variety of other techniques to detect various types of mutations, deletions, rearrangements, methylation errors, and mosaicism.

#### Preparing the family/patient for genetic counseling

Preparation, both for the clinician/counselor and for the family of a retinoblastoma survivor, can improve the genetic counseling experience for all concerned. Experience has shown that without adequate preparation, clinicians and counselors may not address critical issues and families may misinterpret and mistrust genetic information.

The first step in preparing families is to give them a picture of the multidisciplinary retinoblastoma team, introducing the team members and describing the roles they play. The team includes the pediatric ophthalmologist, pediatric oncologist, as well as pediatric nurse practitioners, often an oculist, and a social worker. A comprehensive team also includes genetic professionals: counselors and clinical geneticists as well as molecular geneticists who work in the laboratory. If these roles, and how they integrate with one another, are explained early in the process of diagnosis and treatment, genetic counseling will

become a normal and expected part of the family's experience. Without this broad view, genetic counseling can become one more frightening and unexpected event that families experience sometimes long after they believe the anxiety of a childhood cancer is behind them. Under these circumstances, genetic counseling is difficult and less effective for all concerned.

It is also useful to emphasize the protocols that the family will encounter with each specialist. This gives the family a 'road map' of care and the expectation of what the experience will entail. When viewed from a broader perspective, parents can see where their child is in the 'big picture' and there often are fewer surprises. Instead of increasing anxiety, this approach, especially when adopted from the outset and presented with care and concern, may in fact decrease it. The parents see the terrain ahead and work with the clinicians who guide them through unfamiliar territory.

**Preparing the genetic counselor** The truth is that, in spite of its apparent genetic simplicity, retinoblastoma is a complex disorder for the genetic counseling professional. For those who need to gain expertise quickly, the review of retinoblastoma available at [www.genetests.org](http://www.genetests.org) is up to date, comprehensive, and clear.

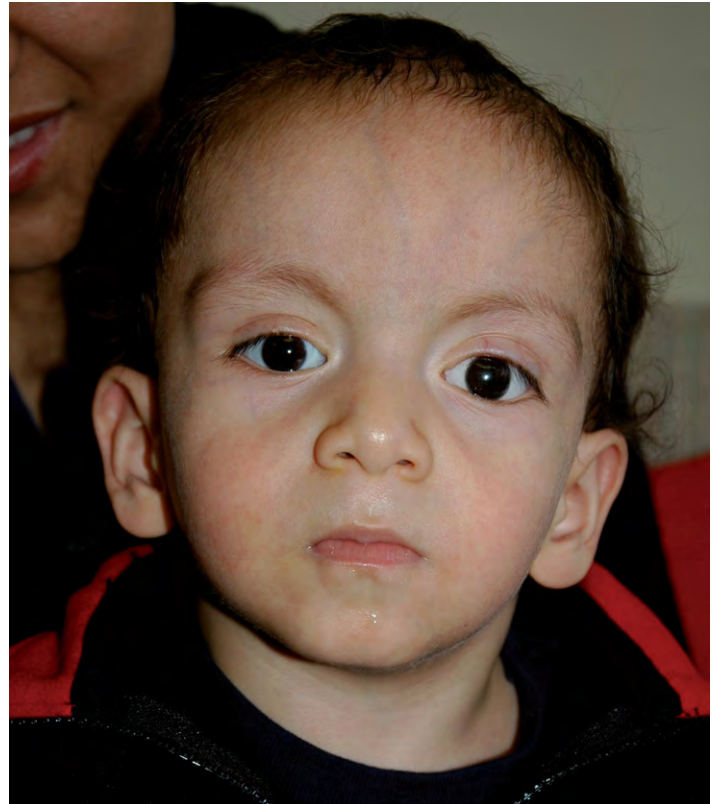**The pedigree or family history** The family history, documented in a three-or-more-generations pedigree, is the fundamental working tool for the geneticist. As a graphic representation of the family history, it neatly summarizes information that would otherwise be scattered throughout the chart. The patient's age at the time of onset of the tumor should be recorded for retinoblastoma and all cancers, the laterality of the tumor should be documented, and the ages of the parents noted. The pedigree should be referred to at each visit and updated regularly. It is incomplete until parents and siblings have had eye examinations to rule out retinocytoma/retinoma. It is modified with test results. If the disease in the proband advances from unilateral to bilateral retinoblastoma, or when there is a positive family history of retinoblastoma in previous generations, the implications for subsequent generations are clear at a glance. Finally, retinoblastoma patients with low vision or blindness may have visually impaired spouses. This should be documented in the pedigree in detail and genetic counseling should address both retinoblastoma and risks associated with other genetic ophthalmic disorders in the spouse's family.

## CONFOUNDING FACTORS

Many confounding factors can complicate what may seem to be a simple pedigree or an apparently non-familial case. When these scenarios are understood, the counselor will be better prepared to avoid these common pitfalls.

**Chromosome 13q14 deletions** Deletion of chromosome 13q14, the site of the *RB1* gene, and neighboring regions on the long arm of chromosome 13 can lead to mental retardation and retinoblastoma. The size of the deletions varies and the phenotype is also variable; however, as yet, the correlation between the size of the deletion and the severity of the clinical phenotype has not been established. Some individuals with small deletions of this area are developmentally normal. In children with a deletion involving chromosome 13q14, developmental delay or mental retardation may be appreciated before retinoblastoma is diagnosed (Fig. 73A.1).

Children with 13q14 deletions may develop retinoblastoma at a somewhat later age, and often only one tumor. One may speculate that



**Fig. 73A.1** This boy was referred to a pediatric neurologist for hypotonia before his retinoblastoma was diagnosed. He has a chromosome 13q deletion visible on routine banding. He has an ocular prosthesis following enucleation of his left eye for retinoblastoma. He also has developmental delay and mild facial dysmorphism: a broad forehead with frontal bossing, arched eyebrows, hypertelorism, small mouth.

when the 'first hit' is a large deletion, gene conversion, a common pathway for the 'second hit' in retinoblastoma, may lead to premature cell death instead of cancer. Paradoxically, by reducing cell viability with the 'second hit,' large deletions can act as low-penetrance deletions.

In our center, all children have high-resolution chromosome analysis and fluorescence in situ hybridization (FISH) for 13q14 as part of their initial evaluation to rule out both microscopic and submicroscopic deletions.<sup>3</sup> When a chromosome deletion is discovered in a child, the parents should also undergo chromosome analysis with FISH for 13q14 to rule out a heritable chromosome anomaly.

**Mosaicism** Mosaicism, in which the *RB1* mutation is present in some but not all cells of the affected child, is common in the first affected member of a family with retinoblastoma.<sup>4-10</sup> Mosaics for *RB1* germline mutations often have unilateral retinoblastoma and later onset, and lack a family history of the disease. However, mosaicism has also been seen in patients with bilateral retinoblastoma and in unaffected parents of affected children. There is no technique that will reliably detect all cases of mosaicism. Gene sequencing may miss mosaicism when less than 20% of cells have a mutation. Even when more than one tissue is studied, mosaicism can never be completely ruled out. When a child with unilateral sporadic retinoblastoma has normal *RB1* gene test results, the chance of a germline mutation is never zero. There is always a small residual risk for undetected mosaicism. The counseling session should include a discussion of the possibility of low-level germline mosaicism.



**Fig. 73A.2** The mother in this photograph had unilateral retinoblastoma. After her daughter was diagnosed with bilateral retinoblastoma, the mother was found to be mosaic for the germline mutation in *RB1* that caused the daughter's disease. This family illustrates the point that when retinoblastoma is caused by a new sporadic mutation, the founder individual may be mosaic for the *RB1* mutation (i.e. it can occur at some point after conception and the first cell division). When searching for the mutation in a two-generation family, the second generation should always be tested first, if possible. Also this family confirms comments in the text that a negative DNA test for a germline mutation in a unilateral patients may fail to detect low-level mosaicism.

The genetic counselor can anticipate mosaicism in a multigeneration retinoblastoma family when the first affected individual, the 'founder,' has unilateral retinoblastoma or a late-onset tumor yet their affected offspring have bilateral, early-onset retinoblastoma. In a retinoblastoma family with two or more affected generations, including a parent and child, it is always best to start the testing process in the child from the second affected generation. This avoids the possibility of a false negative result due to undetected mosaicism in the first affected member of the family. Mosaicism, when it occurs, is limited to the first affected member of the pedigree. Mosaicism is not hereditary. The affected child of a mosaic individual inherits the deleterious mutation and is not mosaic. Such a family is illustrated in Figure 73A.2. The mother had unilateral retinoblastoma and normal *RB1* gene analysis, whereas her daughter, with bilateral retinoblastoma, had a detectable *RB1* mutation. Later the same mutation was demonstrated in the mother's blood using a specific technique for that mutation: PCR with an allele-specific oligonucleotide probe. This family also shows the value of testing more than one individual in a family when a germline mutation is expected.

### Low-penetrance mutations and variable expressivity

Low-penetrance mutations, often due to missense mutations in *RB1* that do not truncate the protein product, and variable expressivity are well documented in the retinoblastoma literature.<sup>11-13</sup> We stress the need for parental dilated eye examinations before genetic counseling so that any retinocytoma/retinoma (Chapter 80) that may be present but previously unknown is documented prior to counseling. Parents who are unaffected and healthy can share the same *RB1* germline mutation with their affected child. The counselor may also be led astray by so-called 'pseudo low penetrance' families. This term refers to two

affected relatives in a large pedigree, giving the appearance of familial retinoblastoma when in fact, the tumors arose from independent and unrelated *RB1* mutations.<sup>14</sup>

**Family history of other early-onset cancers** Family history is often positive for early-onset cancers of different types. Otherwise healthy parents and grandparents of isolated retinoblastoma patients may have rare or multiple cancers, suggesting the possibility of other cancer-predisposing genetic disorders in the family. This can complicate genetic counseling for the family of a child with sporadic unilateral retinoblastoma. In the face of normal *RB1* mutation analysis, the genetic counselor might modify the risk for subsequent cancers based on the family history of other cancers. We have observed early-onset melanoma in the unaffected daughter of a mother with retinoblastoma who died of gastric cancer. In contrast, we have also observed early-onset melanoma in the otherwise normal mother of a boy with isolated sporadic retinoblastoma whose *RB1* mutation analysis was normal. In both of these families, cancer surveillance and high-risk follow-up were recommended.

**Evolving phenotypes and changing pedigrees** Evolving phenotypes and changing pedigrees sometimes make it necessary to revise risks and re-counsel families. After counseling a patient with unilateral sporadic retinoblastoma, the counselor may have to revise their risk assessment after the discovery of a second affected individual in the family or a second tumor in the proband. This is a special concern when counseling the parents of a young infant with a unilateral tumor.

**Mental retardation** All children with retinoblastoma should be monitored for age-appropriate developmental milestones. However, mental retardation in children with retinoblastoma is not always due to a deletion of chromosome 13q14. Those who are developmentally delayed deserve a prompt and thorough evaluation. Diagnosis can be delayed when the team attributes developmental delay to a 13q deletion but fails to obtain chromosome analysis and fluorescence in situ hybridization studies. We have seen a child with retinoblastoma and autistic features who had Fragile X syndrome. Other patients have mental retardation of unknown cause without a clear causal link to their retinoblastoma.

**Congenital anomalies** are common in patients with retinoblastoma. In our clinic, we have seen retinoblastoma patients with clubfoot, dextrocardia, ear anomalies, etc. It is unclear whether there are more than the expected number of congenital anomalies among children with retinoblastoma because there have been no studies. However, in our center, more than the expected 3% of affected children have congenital anomalies. Although this could be due to ascertainment bias, it also raises questions about common environmental or genetic/epigenetic causation for retinoblastoma and birth defects. In either case, the presence of other anomalies further complicates the genetic counseling process. A complete genetic assessment is important for any child with retinoblastoma and unexpected findings or developmental delay.

### THE ISOLATED CASE OF UNILATERAL RETINOBLASTOMA

It is the isolated case of unilateral retinoblastoma (URb) that is most problematic for the genetic counselor. The lack of a family history and



an older age at onset of unilateral sporadic retinoblastoma does not exclude a germline *RB1* mutation.<sup>15</sup> We recently found a germline *RB1* mutation in a child with unilateral sporadic retinoblastoma who was diagnosed at age 5. Although most children with unilateral retinoblastoma will not have heritable retinoblastoma, a significant minority will have a germline mutation in the *RB1* gene. URb children and their families may benefit the most from genetic counseling, as some of these children receive more intervention than they need and others receive too little. For now, when a germline *RB1* mutation is diagnosed, we can only modify surveillance and advise about reproductive risks. Reducing the morbidity and mortality associated with retinoblastoma is an important goal of genetic counseling. Eventually, we hope to have effective strategies to reduce cancer risk in individuals who carry *RB1* germline mutations. We hope that all children with unilateral sporadic retinoblastoma will be able to undergo *RB1* testing to determine their germline mutation status.

### THE LIMITS OF TECHNOLOGY AND FALSE NEGATIVE RESULTS

The limits of technology need to be reviewed in detail with the family prior to gene testing as part of the informed consent process. The possibility of undetectable mutations, false positive and false negative results should be discussed before DNA testing.

**Mutation detection** When direct DNA testing shows an abnormal result, the family can be counseled accordingly. However, normal results should always be interpreted with caution, as sensitivity for mutation detection is not 100%. The technical limitations of gene sequencing analysis contribute to this lack of sensitivity because this

method does not reliably detect large deletions or low-level mosaicism. Patients also need to be aware of the possibility of false negative results. This refers to the situation in which *RB1* gene analysis in blood appears to be negative but a cryptic mutation is in fact present. This situation can usually be avoided if the tumor tissue is tested at the same time as the blood sample. As all retinoblastoma tumors will contain two *RB1* gene mutations, by starting the testing process with a tumor sample, the sensitivity of the technique to detect the mutations in question can be determined. When DNA testing on tumor tissue does not reveal both mutations, it is evident that the same mutation would probably not be detectable in blood. This cannot be discerned when only blood is studied. For this reason, in all unilateral retinoblastoma cases treated with enucleation, fresh tumor tissue should be frozen so that it is available for gene analysis later. Even in the best laboratories, using a variety of DNA techniques, *RB1* gene analysis yields a detection rate of about 90% (Table 73A.1). With this in mind, the chance of misinterpreting an undetected *RB1* mutation as a normal result (false negative) should be discussed whenever blood alone is studied.

**Linkage analysis** is an indirect form of DNA testing in which the actual mutation is not detected but nearby DNA markers, some of which may be within the *RB1* gene itself, can be tracked through affected relatives. Linkage analysis can be misleading when the proband with retinoblastoma is mosaic for a germline *RB1* mutation. Linkage analysis is less reliable (reduced specificity, more false positives) when the pedigree is small, with only two affected generations. Under these circumstances, linkage analysis should not be used prenatally because of the chance of a false positive diagnosis.

**Table 73A.1 Retinoblastoma gene testing techniques: limitations and detection rates**

Technique		Limitations	Detection rate (%)
Cytogenetic analysis	Chromosome analysis	Limited to detection of chromosome 13 translocations, rearrangements, and very large deletions Should be done in conjunction with FISH for 13q14	5
	FISH for 13q14	Limited to detection of large <i>RB1</i> gene deletions Should be done in conjunction with chromosome analysis	
Direct DNA analysis	<i>RB1</i> gene sequence analysis	Limited to detection of small sequence variations Detects small deletions, insertions, point mutations Does not reliably detect mosaicism or splice site changes deep within introns	70
	<i>RB1</i> quantitative multiplex PCR	Limited to detection of deletions and gene rearrangements	20
	<i>RB1</i> allele-specific PCR	Limited to cases in which familial mutation is known and mosaicism is suspected	
	Methylation of <i>RB1</i> promoter	Limited to non-hereditary, sporadic unilateral retinoblastoma	11
Indirect DNA analysis	Linkage analysis	Limited to multigenerational families Mosaicism in proband can lead to false positive result for unaffected offspring	

*RB1*, retinoblastoma gene; FISH, fluorescence in situ hybridization; PCR, polymerase chain reaction.

## THE FUTURE OF DNA TESTING FOR RETINOBLASTOMA

We have discussed germline mutation testing, but there is a parallel body of work on genetic analysis of the tumor itself. Germline mutations are found in the *RB1* gene in body tissues outside the tumor, but there are a variety of other gene mutations and chromosome changes found in the tumor itself. Specific chromosome changes in addition to those found on chromosome 13, such as +6p, +1q and -16, have been recognized in retinoblastoma tumors since the early 1980s.<sup>16,17</sup> Recent reports suggest that DNA analysis in these and other chromosome regions may shed light on the progression of malignancy events in retinoblastoma.<sup>18-21</sup> These findings may have clinical relevance in the future. Of similar potential clinical interest is the finding that loss of specific metastasis suppressor genes (MSGs) have been associated with a much higher risk for metastatic growth in other human cancers.<sup>22-24</sup>

## SUMMARY

The genetics of retinoblastoma is complex and unique. Genetic counseling and *RB1* gene testing has value for patients, both those with unilateral and those with bilateral retinoblastoma. This information is also valuable for the other members of the retinoblastoma team, who can manage patients whose *RB1* status has been clarified more effectively. The genetic counseling process is improved when both patients and physicians are prepared and both thoroughly understand the benefits and limitations of the molecular technology and the cancer surveillance strategies that are currently available. Even when the facts are mastered, genetic counseling for retinoblastoma is further complicated by the psychological and emotional aspects of this disorder. Geneticists, ophthalmologists, psychologists, social workers, and other mental health professionals work best when they work together to help families grapple with the lifelong implications of the information they have been given.

## REFERENCES

- Albrecht P, Ansperger-Rescher B, Schuler A et al. Spectrum of gross deletions and insertions in the *rb1* gene in patients with retinoblastoma and association with phenotypic expression. *Hum Mutat* 2005; 26: 437-445.
- Lohmann DR, Gallie BL. Retinoblastoma: Revisiting the model prototype of inherited cancer. *Am J Med Genet C Semin Med Genet* 2004; 129: 23-28.
- Kallioniemi A, Kallioniemi OP, Waldman FM et al. Detection of retinoblastoma gene copy number in metaphase chromosomes and interphase nuclei by fluorescence in situ hybridization. *Cytogenet Cell Genet* 1992; 60: 190-193.
- Dudin G, Nasr A, Traboulsi E et al. Hereditary retinoblastoma and 13q-mosaicism. *Cytogenet Cell Genet* 1984; 38: 235-237.
- Greger V, Passarge E, Horsthemke B. Somatic mosaicism in a patient with bilateral retinoblastoma. *Am J Hum Genet* 1990; 46: 1187-1193.
- Kivela T, Tuppurainen K, Riikonen P et al. Retinoblastoma associated with chromosomal 13q14 deletion mosaicism. *Ophthalmology* 2003; 110: 1983-1988.
- Munier FL, Thonney F, Girardet A et al. Evidence of somatic and germinal mosaicism in pseudo-low-penetrant hereditary retinoblastoma, by constitutional and single-sperm mutation analysis. *Am J Hum Genet* 1998; 63: 1903-1908.
- Ribeiro MC, Andrade JA, Erwenne CM et al. Bilateral retinoblastoma associated with 13q- mosaicism. Possible manifestation of a germinal mutation. *Cancer Genet Cytogenet* 1988; 32: 169-175.
- Sippel KC, Fraioli RE, Smith GD et al. Frequency of somatic and germ-line mosaicism in retinoblastoma: Implications for genetic counseling. *Am J Hum Genet* 1998; 62: 610-619.
- Van Esch H, Aerssens P, Fryns JP. The importance of excluding 13q deletion mosaicism in the diagnosis of retinoblastoma associated with dysmorphic features. *Genet Couns* 2005; 16: 91-93.
- Dalmon V, Surace E, Giliberto F et al. Detection of germline mutations in argentine retinoblastoma patients: Low and full penetrance retinoblastoma caused by the same germline truncating mutation. *J Biochem Mol Biol* 2004; 37: 246-253.
- Huang Q, Dryja TP, Yandell DW. [Distinct Rb gene point mutations in families showing low penetrance of hereditary retinoblastoma.] *Zhonghua Yi Xue Yi Chuan Xue Za Zhi* 1998; 15: 139-142.
- Lohmann DR, Brandt B, Hopping W et al. Distinct *RB1* gene mutations with low penetrance in hereditary retinoblastoma. *Hum Genet* 1994; 94: 349-354.
- Munier FL, Wang MX, Spence MA et al. Pseudo low penetrance in retinoblastoma. Fortuitous familial aggregation of sporadic cases caused by independently derived mutations in two large pedigrees. *Arch Ophthalmol* 1993; 111: 1507-1511.
- Brichard B, Heusterspreute M, De Potter P et al. Unilateral retinoblastoma, lack of familial history and older age does not exclude germline *RB1* gene mutation. *Eur J Cancer* 2006; 42: 65-72.
- Squire J, Gallie BL, Phillips RA. A detailed analysis of chromosomal changes in heritable and non-heritable retinoblastoma. *Hum Genet* 1985; 70: 291-301.
- Gardner HA, Gallie BL, Knight LA et al. Multiple karyotypic changes in retinoblastoma tumor cells: Presence of normal chromosome no. 13 in most tumors. *Cancer Genet Cytogenet* 1982; 6: 201-211.
- Grasemann C, Gratiás S, Stephan H et al. Gains and overexpression identify *dek* and *e2f3* as targets of chromosome 6p gains in retinoblastoma. *Oncogene* 2005; 24: 6441-6449.
- Gratiás S, Schuler A, Hitpass LK et al. Genomic gains on chromosome 1q in retinoblastoma: Consequences on gene expression and association with clinical manifestation. *Int J Cancer* 2005; 116: 555-563.
- Marchong MN, Chen D, Corson TW et al. Minimal 16q genomic loss implicates cadherin-11 in retinoblastoma. *Mol Cancer Res* 2004; 2: 495-503.
- Orlic M, Spencer CE, Wang L et al. Expression analysis of 6p22 genomic gain in retinoblastoma. *Genes Chromosomes Cancer* 2006; 45: 72-82.
- Berger JC, Vander Griend DJ, Robinson VL et al. Metastasis suppressor genes: From gene identification to protein function and regulation. *Cancer Biol Ther* 2005; 4: 805-812.
- Kauffman EC, Robinson VL, Stadler WM et al. Metastasis suppression: The evolving role of metastasis suppressor genes for regulating cancer cell growth at the secondary site. *J Urol* 2003; 169: 1122-1133.
- Keller ET. Metastasis suppressor genes: A role for raf kinase inhibitor protein (rkp). *Anticancer Drugs* 2004; 15: 663-669.

**PART B: RETINOBLASTOMA: FAMILY COUNSELING**

Nancy C. Mansfield and Robin D. Clark

**INTRODUCTION**

General concepts relating to the counseling of patients with cancer are discussed in Chapter 11. This chapter deals with specific aspects of counseling patients and families with retinoblastoma.

**BACKGROUND**

The counselor should understand the special significance that retinoblastoma has, not only for the affected child or adult survivor, but for the entire family. The loss of an eye is a blow that has unique physical, personal, psychological, and social consequences. The extended family of the affected person will see this individual differently for the rest of their life. It helps to appreciate the impact of this diagnosis as well as to understand the unique context of the ‘eye.’ From biblical times to the present, the eye has been a potent image that expressed profound meanings. In both eastern and western cultures, many idioms demonstrate this phenomenon: ‘a person of vision;’ ‘a visionary;’ ‘seeing is believing;’ ‘out of sight, out of mind;’ ‘a sight for sore eyes;’ ‘love at first sight;’ ‘the eye is the window to the soul’ – all these connote positive feelings about the ability to see well. The converse is equally important (‘he is very short-sighted;’ ‘hindsight is 20/20;’ ‘blind as a bat’).

**THE FAMILY/PATIENT’S REACTION TO THE DIAGNOSIS**

A diagnosis of retinoblastoma can bring with it layers of grief for the family. Often, just when a family begins to feel that they may be through with the worst phase, perhaps when the affected eye has been enucleated or when chemotherapy comes to an end, genetic counseling is recommended. For families whose child has retinoblastoma, genetic counseling and molecular testing can be unexpectedly stressful. Issues of fault and blame may arise as parents struggle with the implications of test results. This is especially true in a child with unilateral retinoblastoma who receives a diagnosis of heritable retinoblastoma after an RB1 germline mutation is found. Parents sometimes decline to have themselves tested because of the stress.

Although genetic counseling has many benefits for all concerned, this may not be appreciated by families coping with the implications of a germline mutation. From the perspective of the already anxious family, the results of genetic testing may have an even greater impact than the original diagnosis.

**Emotional reactions** Reactions to the counseling itself, and eventually to the DNA test results, often cause family members to experience one or more common feelings (Box 73B.1). These responses are all coping mechanisms that many of us use at one time or another to allow us to handle difficult situations. It is normal for parents to experience one or more of these reactions. The successful counselor will anticipate these responses and help families find ways to cope effectively.

**Expectations** We have found that families usually enter into the process of genetic testing with a positive attitude and with the belief or expectation that nothing significant will be found: the problem started with the child and will end with the child. Even after coun-

**BOX 73B.1 Common Emotional Reactions**

Denial	Intellectualization	Anger
Depression	Guilt	Blaming
Shock	Helplessness	Anxiety
Worry	Flat affect	Doubt over results
Negation of the information	Unwillingness to follow through with recommended tests	Questioning every piece of information

seling, few families realize when they begin the testing process that the entire family may be faced with testing, or that they may be burdened with the knowledge that they in fact carry a germline mutation. In these cases, parents may be unprepared for their feelings of being ‘responsible’ for their child’s condition.

**Coping reactions** Because the genetic aspects of retinoblastoma raise new areas of concern, couples often feel that they have to cope with yet another ‘abnormality.’ Understanding how a couple may react to genetic information can be useful for the genetic counselor. Not all coping mechanisms are counterproductive, and many can help a family process difficult information. For some individuals, denial buys time in which to process the information they have been given. They can slowly absorb the results and ask questions, and move on when they are ready. For others, excessive worry over the information causes increased anxiety, already heightened because of the original diagnosis. Worry often expresses itself as anger, which in effect blocks other emotions. The feeling of anger overrides most other feelings. Unfortunately, anger can alienate couples from one another and cause feelings of mistrust toward the professionals trying to give information. As with any diagnosis or disability in a child, guilt is always present. Parents uniformly feel that they have somehow caused the problem, even when it is properly explained and framed in a context that they can understand. Often, time helps to alleviate this guilt, but sometimes a mental health professional is crucial to the individual who gets ‘stuck’ with this feeling and blames him- or herself for the problem.

**ANXIETY ABOUT HAVING MORE CHILDREN**

The ability to reproduce effectively goes to the core of our view of ourselves. Most couples want to have a family. If, for any reason, this coupling produces a child with a problem such as retinoblastoma, the parent can also feel that they are somehow defective or abnormal. This feeling can interfere with all coping tools used by individuals to carry out everyday activities. When this happens, emotional help is needed to assist them in recovering their self-esteem. If a social worker is not available, often a caring nurse can help. Sometimes the treating physician or geneticist will be called upon to try to assist the family in regaining some sense of normalcy in their daily life.



**BOX 73B.2 Situations to Avoid for Effective Communication with Patients**

- Do not be in a rush
- Take your time to listen, and ask whether the patients have questions that you can answer
- Do not take telephone calls or respond to pagers during the appointment
- Do not invite students, residents, or fellows into the room with a family
- Do not judge the intelligence of a patient and/or family based on the questions they ask or the lack of questions
- Do not give bad news over the phone if it can be avoided
- Do not use medical jargon
- Do not use dictation as a method of giving information, thereby allowing the family to listen as a way of giving results
- Do not assume that the reaction of a family or patient is pathological
- Do not use phrases such as ‘it could be worse,’ or other pat responses
- If you are uncomfortable, do not hide your own feelings. Say, ‘I am sorry to be giving this news as I know it is not what you expected’
- Do not ask for a bill to be paid after giving difficult news
- Do not allow your staff to be harsh or judgmental with a family

**HOW TO GIVE BAD NEWS**

Arguably there is no right way to give bad news, but it seems that there are many wrong ways (Box 73B.2). Most of us are uncomfortable when we give bad news, and few feel that we do this part of our job particularly well. In these difficult situations it may be easy to rationalize doing it quickly, but taking more time is always preferable. Box 73B.3 offers tips, many suggested by retinoblastoma patients themselves, to help us communicate effectively with patients.

**SUMMARY**

Even when the facts and information are absorbed by the family, genetic counseling for retinoblastoma is complicated by the psycho-

**BOX 73B.3 How to Communicate Effectively with Patients When Delivering Bad News**

- Allow enough time: often an hour or more is needed
- Arrange for a face-to-face appointment. This is not to be done over the phone
- Follow the ‘Golden Rule’ and treat others as you would wish to be treated
- Demonstrate kindness, respect, dignity, acceptance, and validation
- Sit down when speaking
- If giving bad news, say, ‘you are sorry to report . . .’
- Offer tissues or a glass of water when patients are upset
- Explain information clearly, concisely, and slowly
- Make a drawing or create a list to reinforce your points
- Have information repeated back to you to be sure you were understood
- Plan to give information more than once
- If in a teaching institution, involve your students either before or after seeing the family
- Set up a follow-up appointment to go over the information and answer questions
- Assume that much of the information will not be absorbed owing to anxiety
- Accept the reaction of families even if you are surprised by their feelings
- If necessary, offer referrals for support
- Offer your assistance in the future when the need arises
- Teach kindness to your staff, as they are your representatives
- Expect the unexpected: we cannot predict reactions even from the most resourceful individuals

logical and emotional aspects of this disorder. Geneticists, ophthalmologists, psychologists, social workers, and other mental health professionals work best when they work together to help families grapple with the lifelong implications of the information they have been given.

# Chemotherapy for retinoblastoma: an overview

Rima F. Jubran, Judith G. Villablanca and Anna T. Meadows

## INTRODUCTION

The management of patients with intraocular retinoblastoma has changed dramatically in the past 15 years with the introduction of primary systemic chemotherapy. Before 1990, systemic chemotherapy had been used to treat patients with extraocular disease, with less than optimal results.<sup>1</sup> In the early 1990s several investigators from North America and Great Britain began using systemic agents to treat intraocular retinoblastoma (CEV regimen, comprising carboplatin, etoposide, and vincristine) that had been found to be successful in the treatment of central nervous system neoplasms. Other indications for chemotherapy in a patient with retinoblastoma include prophylaxis against metastasis following enucleation in the presence of histopathologic high-risk features, extraocular retinoblastoma with local and/or regional spread, metastatic retinoblastoma with or without CNS involvement, and trilateral retinoblastoma (Box 74.1).

## RESPONSE TO SYSTEMIC CEV CHEMOTHERAPY COMBINED WITH LOCAL THERAPY

Good responses were noted when these agents were combined with local ophthalmic therapy (Chapter 75). The intention was to reduce the volume of intraocular tumor with systemic chemotherapy so as to allow better tumor kill with local laser photocoagulation and cryotherapy (Fig. 74.1).

**Response in eyes with early disease** This approach was very successful in eyes with Reese–Ellsworth Stage I–III tumors (International Group A and Group B) using either six courses of low-dose or three courses of high-dose CEV (Table 74.1).<sup>5,6</sup>

**Response in eyes with advanced disease** Although eyes with subretinal or vitreous seeds responded initially, the tumors usually recurred within 9 months of diagnosis.<sup>5,7</sup> This spurred the idea that increasing the doses of the CEV regimen (high-dose CEV, Table 74.1) and adding subtenon or periocular carboplatin delivered locally might achieve higher drug concentrations in the vitreous, where blood supply was poor, and would improve the outcomes of patients with Reese–Ellsworth Group IV–V eyes (International Group C and D eyes). Preliminary studies with high-dose CEV and subtenon carboplatin have indeed resulted in improved ocular salvage rates.<sup>8,9</sup> However, toxicities reported with this therapy include periorbital fat atrophy associated with mild to moderate cosmetic changes and consequent limitation of extraocular movements.<sup>10</sup> Rare cases of optic atrophy, associated with

concomitant use of cryotherapy and cumulative effect of edema within the orbit, have also been reported.<sup>8</sup>

## OTHER SYSTEMIC CHEMOTHERAPY REGIMENS

A variety of other systemic chemotherapy combinations have been used in the past decade. They include carboplatin alone, carboplatin with vincristine, and carboplatin, etoposide/tenoposide, and vincristine.<sup>11–13</sup> In addition, there have been reports of investigators using ifosfamide, doxorubicin, and vincristine as well as cyclophosphamide.<sup>14,15</sup> Furthermore, some have added cyclosporin to the regimens in an effort to reduce presumed chemotherapy resistance.<sup>16</sup> Although all these combinations have been reported, the most widely used regimen is the combination of systemic carboplatin, etoposide, and vincristine.

## DETERMINING OPTIMAL CHEMOTHERAPY REGIMENS

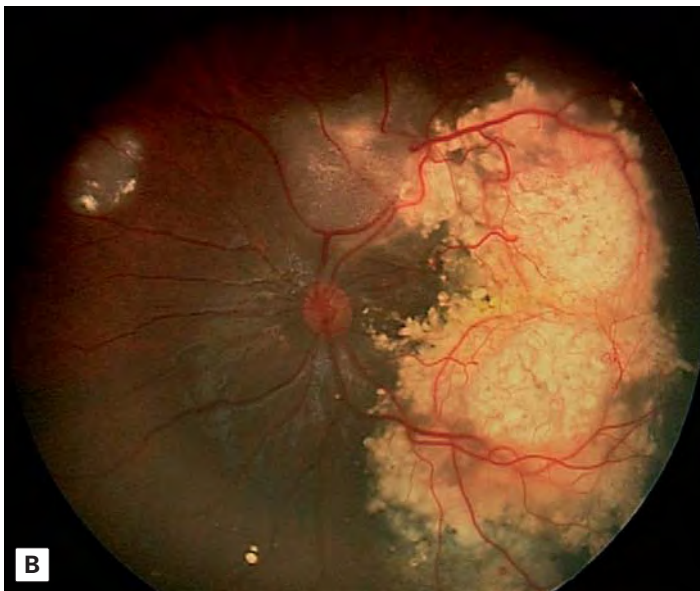
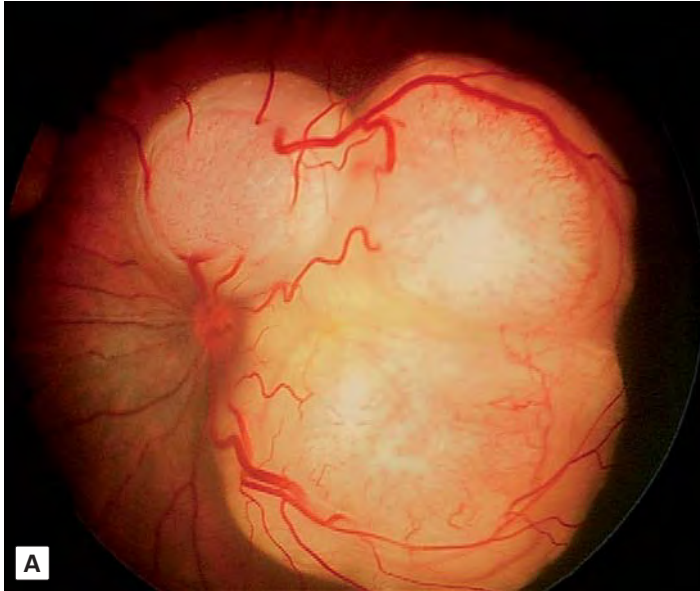
Many questions remain to determine the optimal chemotherapy regimen for intraocular retinoblastoma. Some of these questions are being addressed in Childrens Oncology Group (COG) clinical trials beginning in 2006 (Chapter 81). For Group B eyes, which have a very high rate of success with CEV, questions are focused on reduction of therapy to minimize morbidity. These aims include the deletion of etoposide, and a possible reduction in the number of courses of therapy. For Group C/D eyes, improving the ocular salvage rate is the major goal. For these patients, high-dose CEV with subtenon carboplatin will be tested in larger numbers to confirm the encouraging results from pilot studies. Future studies may add consolidation with low-dose irradiation to the globe for patients identified as more likely to fail chemotherapy alone. Novel regimens for patients failing CEV are also needed. Possible approaches could include anti-angiogenic agents, other agents delivered locally using improved delivery systems (Chapter 83), and novel chemotherapeutic agents with different mechanisms of action from CEV. The initiation of retinoblastoma cell lines to perform in vitro modeling may provide insights to develop future therapies.

## THE NEED TO REVISE THE RETINOBLASTOMA CLASSIFICATION

The Reese–Ellsworth (R–E) classification system, developed in the era of radiotherapy as the primary treatment modality, fails to reliably predict outcome with chemotherapy. Interpretation of many published series utilizing chemotherapy has been difficult, as they group

**BOX 74.1 Indications for Chemotherapy**

- Intraocular retinoblastoma
- Prophylaxis against metastasis following enucleation in the presence of histopathologic high-risk features
- Extraocular retinoblastoma with local and/or regional spread
- Metastatic retinoblastoma with or without CNS involvement
- Trilateral retinoblastoma



**Fig. 74.1** Pretreatment Group B retinoblastoma (A). Note reduction in tumor volume 3 weeks after the administration of the first cycle of carboplatin, etoposide, vincristine (B). Focal consolidation may start at this time (concurrently with the second cycle of chemotherapy) or at the beginning of the third cycle. The goal of local consolidation is to treat the entire residual lesion with laser photocoagulation to assure that all tumor cells not killed by the chemotherapy will be eradicated. At least three sessions in which the residual lesion is completely covered by laser burns is recommended (Chapter 75).

multiple R-E stages that have very different prognoses with current therapy. In order to test current therapy approaches that include chemotherapy in a homogeneous population of eyes, the International Classification System for Intraocular retinoblastoma was developed (Chapter 69).<sup>17</sup> Several national intraocular retinoblastoma trials using this new classification system for eligibility with central review of staging at diagnosis and response to therapy via Retcam images have been approved (Chapter 81).

**CHEMOTHERAPY AGENTS**

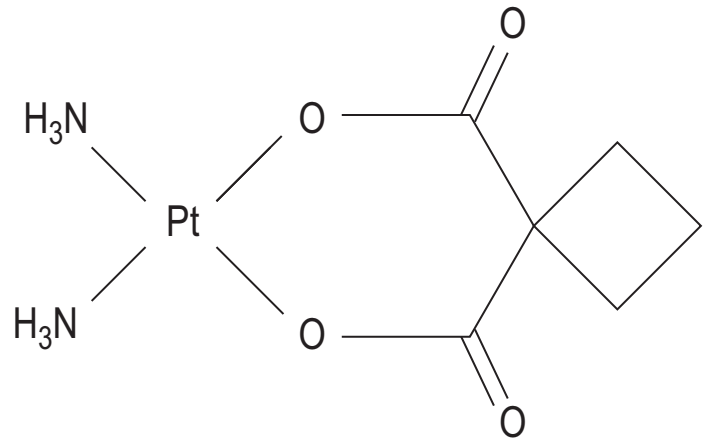
The details of chemotherapy are outside the scope of this chapter but a brief review of general principles is provided in Section 1.

**Carboplatin** is a member of a family of cytotoxic compounds based on elemental platinum (Fig. 74.2). It acts by interrupting DNA replication and disrupting cell division by forming cross-links with DNA.<sup>18</sup> Its serum decay pattern is triphasic, with initial, middle, and terminal half-lives of 12–24 minutes, 1.3–1.7 hours, and 22–40 hours, respectively. Approximately 90% is excreted in the urine within 24 hours. Common toxicities associated with carboplatin are myelosuppression (most notably thrombocytopenia), nausea and vomiting, renal and ototoxicity.<sup>19</sup> Renal and ototoxicity are dose related and to date have not been seen with doses used for intraocular retinoblastoma. Some patients have reported a metallic taste in the mouth, and rarely patients develop electrolyte disturbances or a peripheral neuropathy.

**Etoposide** is an epipodophyllotoxin and acts as a topoisomerase II inhibitor (Fig. 74.3). It blocks the enzyme by stabilizing DNA cleavage

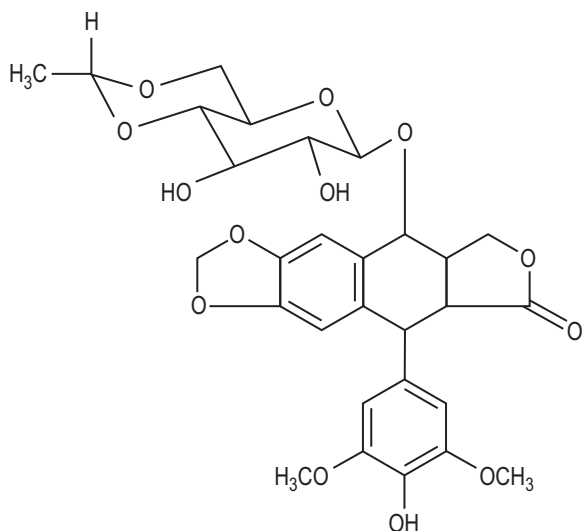
**Table 74.1 Low- and high-dose treatment regimens**

Drug	Dose	
	Low	High
Carboplatin	18.6 mg/kg	26–28 mg/kg
Etoposide	10 mg/kg	10–12 mg/kg
Vincristine	0.05 mg/kg	0.05 mg/kg
Course repeated every 21–28 days		



**Fig. 74.2** The chemical structure of carboplatin. A DNA alkylating agent, carboplatin stops tumor growth by cross-linking guanine nucleobases in DNA double helix strands, rendering them unable to uncoil and separate for replication.





**Fig. 74.3** The chemical structure of etoposide. An inhibitor of the nuclear enzyme topoisomerase II, etoposide is essential for DNA replication. Topoisomerase II is required to remove normally occurring knots and tangles in the genetic material.

complexes and preventing its catalytic activity.<sup>20</sup> After an intravenous dose, the terminal half-life of etoposide, in patients with normal renal function, is 6–8 hours. Approximately 40% of administered etoposide is excreted unchanged in the urine. The remainder is metabolized in the liver. Ninety-six percent of etoposide is bound to albumin in plasma.<sup>21</sup> Common toxicities include nausea and vomiting, alopecia, stomatitis, bone marrow suppression, and fatigue. Hypotension (related to rate of infusion) and hypersensitivity rarely occur with this agent.<sup>22</sup>

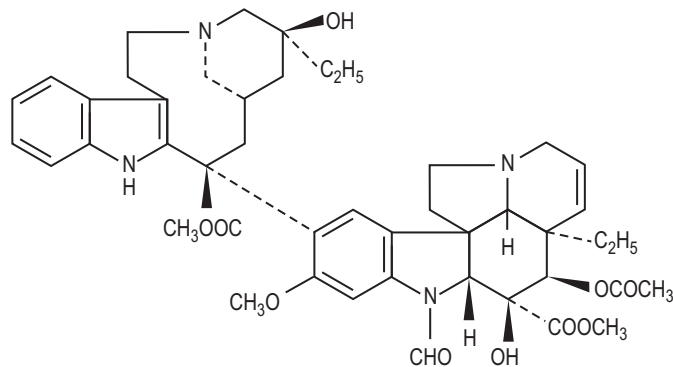
Etoposide-induced secondary malignancy occurs in approximately 2–4% of exposed patients. There are no statistical differences in the pharmacokinetics between patients who develop secondary acute myeloblastic leukemia (AML) and those who do not. It has been shown that the cumulative dose and schedule of etoposide administration may be factors in the development of AML.<sup>23,24</sup>

**Vincristine** is an alkaloid isolated from *Vinca rosea* (periwinkle) (Fig. 74.4). It binds to tubulin, disrupting microtubules and inducing metaphase arrest.<sup>25</sup> Its serum decay pattern is triphasic, with initial, middle, and terminal half-lives of 5 minutes, 1.3 hours, and more than 24 hours, respectively. It is excreted in the bile and feces. It is a potent vesicant. Common toxicities include alopecia, constipation, jaw and abdominal pain, blurred vision, ptosis, diplopia, clumsiness, and peripheral neuropathy.<sup>26</sup>

### CEV TOXICITY

Whereas the regimens containing these three drugs have been largely well tolerated, the long-term toxicity of chemotherapy, particularly in the setting of patients with a cancer-predisposing condition, is still not fully known.

**Common expected toxicity** In the short term, toxicity related to systemic chemotherapy has been minimal.<sup>5,6,9,11–13</sup> Expected myelosuppression is the most common toxicity, with blood product transfusion and uncomplicated febrile neutropenic hospital admissions as the result. The addition of granulocyte-stimulating factor has shortened the period of neutropenia and consequently improved the toxicity profile of chemotherapy regimens. Some investigators have reported feeding



**Fig. 74.4** The chemical structure of vincristine. Vincristine is an inhibitor of microtubule formation and a disruptor of mitotic spindle formation.

problems and gastrointestinal disturbance during therapy, but these are largely transient and resolve with the cessation of chemotherapy.<sup>5</sup>

**Uncommon serious toxicity** One rare but serious and important toxicity associated with the etoposide component of CEV systemic chemotherapy is the development of myelodysplastic syndrome or secondary acute myeloid leukemia. SEER data analysis shows that the incidence of AML or MDS is 1–2% in patients who have received a cumulative dose of 4000/m<sup>2</sup> of etoposide.<sup>23,24</sup> There have been very few reports of myelodysplastic syndrome or secondary acute myeloid leukemia in patients treated with systemic chemotherapy for intraocular retinoblastoma. This may be due to the lower cumulative doses of etoposide used in these patients compared to the pediatric oncology population at large. Patients with retinoblastoma do not have an increased risk of secondary leukemia compared to other children treated for cancer with the same agents.

## PROPHYLAXIS FOR PATIENTS WITH HIGH RISK HISTOPATHOLOGY

**High-risk features** The definition of high-risk pathology in an enucleated eye remains unclear (Chapter 77). Common criteria include ‘massive’ choroidal invasion, involvement of tumor past the lamina cribrosa, and tumor invading into the sclera. However, anterior chamber involvement and iris invasion have also been included in some reports.<sup>27–29</sup>

**Drug regimen** The management of patients with high-risk features has varied from close observation to, more commonly, treatment with six courses of the low-dose CEV regimen. Recent chemoprophylaxis studies have had encouraging results. Honavar et al.<sup>27</sup> described 80 patients with unilateral sporadic retinoblastoma who had high-risk pathologic features post enucleation. Two of 46 patients who received adjuvant chemotherapy developed metastatic disease, compared to eight of 34 patients who did not receive chemotherapy. Uusitalo et al.<sup>28</sup> reported on 129 patients with unilateral disease treated at University of California, San Francisco, and the University of Miami. Eleven patients with post-laminar involvement or tumor at the cut end of the optic nerve were treated with chemotherapy. None of those patients developed metastatic disease. This has spurred the Children’s Oncology Group to propose a uniform treatment protocol for patients with high-risk pathology to better understand the role of each of these features and the outcome of patients (Chapter 81).

## THERAPEUTIC APPROACHES TO EXTRAOCULAR RETINOBLASTOMA

The treatment of extraocular retinoblastoma is discussed in more detail in Chapters 78 (Orbital retinoblastoma) and 79 (Metastatic retinoblastoma). Survival of patients with retinoblastoma depends on the extent of the disease. In the United States, where the majority of patients have intraocular disease, overall survival is reported to be 90%.<sup>30</sup> In contrast, extraocular retinoblastoma is associated with a very poor outcome. Prognostic variables have not been well defined, although several reports suggest that central nervous system (CNS) involvement is associated with the highest risk of death.<sup>30</sup> The optimal therapeutic approach for metastatic retinoblastoma has not been determined, but occasional reports suggest a better outcome after high-dose chemotherapy and hematopoietic stem cell transplant.<sup>31</sup>

Extraocular retinoblastoma can be divided into four categories: regional extraocular disease (optic nerve involvement at the cut end of an affected enucleated eye, orbital or periauricular involvement); distant metastatic retinoblastoma without CNS involvement; with CNS involvement (Chapter 79); and trilateral retinoblastoma (Chapter 72). The historical event-free survival rate at 1 year for patients with orbital disease is 40%, 20% for patients with metastatic disease, and 0–5% for CNS-positive patients.<sup>32</sup>

**Regional extraocular disease (Chapters 78 and 79)** Traditionally, patients with orbital disease have been treated with surgery with or without irradiation and have fared poorly. The addition of conventional-dose chemotherapy to the treatment regimen has improved survival considerably. Recent reports confirm that conventional chemotherapy and external beam irradiation can cure patients with regional extraocular disease (orbital and/or preauricular disease or optic nerve margin positivity). Investigators in Argentina treated 15 patients with orbital or periauricular nodal disease using chemotherapy (cyclophosphamide, doxorubicin and vincristine or vincristine, idarubicin, cyclophosphamide, carboplatin and etoposide). This was followed by external beam irradiation (45Gy) up to the chiasm in patients with orbital disease and to the involved nodes in patients with preauricular lymphadenopathy. They reported a 5-year event-free survival of 84%.<sup>32</sup> Chantada et al.<sup>32</sup> reported on 12 patients with optic nerve involvement treated with the above regimens and orbital irradiation. All were event-free survivors. Investigators in Brazil treated 61 patients with regional extraocular disease using chemotherapy and external beam radiation of 40–50Gy to the orbit. Triple intrathecal chemotherapy was also administered. Therapy was successful in 20/32 patients with orbital disease and 22/29 with optic margin positivity.<sup>33</sup>

**Metastatic retinoblastoma without CNS involvement (Chapter 79)** Historically, patients with metastatic retinoblastoma were treated with conventional doses of chemotherapy and radiation, and despite some reports of long-term survival the majority of the evidence pointed to a grim prognosis. This was also recently confirmed by the Argentine and Brazilian investigators referred to above, with reports of 0/26 and 1/14 survivors, respectively, with distant metastatic disease.<sup>34,35</sup> Namouni et al.<sup>34</sup> reported the results of 25 patients with metastatic retinoblastoma treated with high-dose carboplatin, etoposide, and cyclophosphamide followed by autologous stem cell rescue (ASCR). Five of 11 patients (45%) without CNS metastasis at diagnosis were event-free survivors at 11–70 months after high-dose chemotherapy. Dunkel et al.<sup>39</sup> reported on four patients with meta-

static retinoblastoma without CNS involvement treated with high-dose carboplatin, thiotepa, and etoposide with ASCR after complete response to conventional doses of chemotherapy. All four were event-free survivors from 46 to 80 months after diagnosis. In 2003, investigators in New York reported on four patients treated with intensive chemotherapy with ASCR followed by radiation therapy to bony metastases. Two patients are long-term survivors.<sup>31</sup> Jubran et al.,<sup>35</sup> at Children's Hospital Los Angeles, included two patients with metastatic disease not including the CNS in a report of patients with extraocular retinoblastoma. Both died after high-dose chemotherapy and ASCR, one of disease recurrence and the other of a secondary Ewing's sarcoma.<sup>35</sup> Most recently, Matsubara et al.<sup>36</sup> from Japan reported on five patients with metastatic retinoblastoma treated with conventional-dose chemotherapy and irradiation to bulky sites followed by high-dose chemotherapy with a variety of chemotherapy combinations and ASCR. The three patients without CNS involvement are long-term survivors with no evidence of disease at 113, 107, and 38 months, respectively, from the time of transplant.<sup>36</sup>

The overall experiences suggest that high-dose chemotherapy with ASCR is associated with improved survival for patients with metastatic retinoblastoma not involving the CNS. The optimal high-dose chemotherapy combination remains to be determined; however, the inclusion of thiotepa may reduce the risk of CNS recurrence owing to the excellent penetration of the agent into the CNS.

## Metastatic retinoblastoma with CNS involvement (Chapter 79)

There are fewer data on survivors of retinoblastoma with CNS metastatic disease or patients with pineal involvement (trilateral retinoblastoma). Antoneli et al.<sup>33</sup> described seven patients with CNS disease at the time of diagnosis, none of whom survived despite treatment with chemotherapy and irradiation of the whole brain and spine to 36Gy. Chantada et al.<sup>32</sup> reported on 21 patients with CNS metastatic disease who were treated with conventional-dose chemotherapy and irradiation: 24Gy to the brain and 18Gy to the spine. None of those patients survived.<sup>32</sup>

## Trilateral retinoblastoma (Chapter 72)

In the literature trilateral retinoblastoma occurs in 4% of patients and is diagnosed more commonly in patients with bilateral disease, although all patients who carry the germline mutation are at risk.<sup>37</sup> Amoaku et al.<sup>38</sup> reported no cure in five patients with trilateral retinoblastoma, including three treated with chemotherapy plus or minus radiation therapy. Jubran et al.<sup>35</sup> included four patients with CNS involvement and three with trilateral disease. The one patient who survived (trilateral retinoblastoma) was treated with complete resection of the pineal tumor followed by chemotherapy and high-dose chemotherapy and acute stem cell rescue (ASCR). Dunkel et al.<sup>39</sup> reported 14 patients with CNS involvement: five of nine patients with trilateral retinoblastoma survived, compared to two of five patients with CNS metastases, suggesting that trilateral patients may have a better outcome than originally thought if they are treated aggressively with chemotherapy and stem cell rescue.

Although the data to support high-dose chemotherapy and ASCR for patients with CNS involvement are not strong, the poor prognosis and the young age at diagnosis justify intensive chemotherapy. Because the optimal regimens are not known, large international collaborative studies are needed to improve the outcomes of patients with metastatic retinoblastoma. The Children's Oncology Group is planning an international study to address this problem (Chapter 81).

## REFERENCES

- White L. Chemotherapy in retinoblastoma: current status and future directions. *Am J Pediatr Hematol Oncol* 1991; 13: 189–201.
- Kingston JE, Hungerford JL, Madreperla SA et al. Results of combined chemotherapy and radiotherapy for advanced intraocular retinoblastoma. *Arch Ophthalmol* 1996; 114: 1339–1343.
- Shields CL, De Potter P, Himelstein BP et al. Chemoreduction in the initial management of intraocular retinoblastoma. *Arch Ophthalmol* 1996; 114: 1330–1338.
- Murphree AL, Villablanca JG, Deegan III WF et al. Chemotherapy plus local treatment in the management of intraocular retinoblastoma. *Arch Ophthalmol* 1996; 114: 1348–1356.
- Freidman DL, Himelstein B, Shields CL et al. Chemoreduction and local ophthalmic therapy for intraocular retinoblastoma. *J Clinical Oncol* 2000; 22: 12–17.
- Jubran RF, Murphree AL, Villablanca JG. ‘High dose’ CEV and local ophthalmic therapy for group B intraocular retinoblastoma. *Proceedings 12th International Symposium on Retinoblastoma*, 2005.
- Shields CL, Honavar SG, Meadows AT et al. Chemoreduction plus focal therapy for retinoblastoma: Factors predictive of need for treatment with external beam radiotherapy or enucleation. *Am J Ophthalmol* 2002; 133: 657–664.
- Abramson DH, Frank CM, Dunkel IJ. A phase I/II study of subconjunctival carboplatin for intraocular retinoblastoma. *Ophthalmology* 1999; 106: 1947–1950.
- Villablanca JG, Jubran RF, Murphree AL. Phase I study of subtenon carboplatin with systemic high dose carboplatin/etoposide/vincristine for group C, D and E intraocular retinoblastoma. *Proceedings 12th International Symposium on Retinoblastoma*, 2005.
- Mulvihill A, Budning A, Jay V et al. Ocular motility changes after subtenon carboplatin chemotherapy for retinoblastoma. *Arch Ophthalmol* 2003; 121: 1120–1124.
- Rodriguez-Gallindo C, Wilson MW, Haik BG et al. Treatment of intraocular retinoblastoma with vincristine and carboplatin. *J Clinical Oncol* 2003; 21: 2019–2025.
- Abramson DH, Beaverson KL, Lee, TC et al. Single agent (carboplatin) chemoreduction for Reese–Ellsworth groups I–III. *Proceedings 12th International Symposium on Retinoblastoma*, 2005.
- Chan HSL, Heon E, Budning A et al. Improvement in the cure rate of intraocular retinoblastoma without significantly increasing toxicity with higher dose carboplatin–teniposide in a cyclosporine multidrug reversal regimen. *Proceedings 10th International Symposium on Retinoblastoma*, 2002.
- Landsdale P, Berry DH, Holcomb TM et al. Chemotherapeutic trials in patients with metastatic retinoblastoma. *Cancer Chemother Rep* 1968; 52: 631–634.
- Pratt CB, Crom DB, Howarth C. The use of chemotherapy for extraocular retinoblastoma. *Med Pediatr Oncol* 1985; 13: 330–333.
- Chan HS, DeBoer G, Thiessen JJ et al. Combining cyclosporine with chemotherapy controls intraocular retinoblastoma without requiring radiation. *Clin Cancer Res* 1996; 2: 1499–1508.
- Murphree AL. Intraocular retinoblastoma: The case for a new group classification. *Ophthalmol Clin North Am* 2005; 18: 41–53.
- Blommaert FA, van Dijk-Knijnenburg HC, Dijt FJ et al. Formation of DNA adducts by the anticancer drug carboplatin: different nucleotide sequence preferences in vitro and in cells. *Biochemistry* 1995; 34: 8474–8489.
- Reed E. Cisplatin and analogs. In: Chabner BA, Longo DL, eds. *Cancer chemotherapy principles and practice*. Philadelphia: JB Lippincott, 2001; 447–465.
- Prommier Y. DNA topoisomerase II inhibitors. In Teicher BA, ed. *Cancer therapeutics: experimental and clinical agents*. Totowa, NJ: Humana Press, 1997; 153.
- Smyth RL, Pfeffer M, Scalzo A et al. Bioavailability and pharmacokinetics of etoposide. *Semin Oncol* 1985; 12: 48.
- Pommer YG, Goldwasser F, Strumberg D. Topoisomerase II inhibitors: Epipodophyllotoxins, acridines, ellipticines and bisdioxopiperazines. In: Chabner BA, Longo DL, eds. *Cancer chemotherapy principles and practice*. Philadelphia: JB Lippincott, 2001; 538–578.
- Curtis RE, Boice JD Jr, Stovall M et al. Risk of leukemia after chemotherapy and radiation treatment for breast cancer. *N Engl J Med* 1992; 326: 1745.
- Smith MA, Rubinstein L, Anderson JR et al. Secondary leukemia or myelodysplastic syndrome after treatment with epipodophyllotoxins. *J Clin Oncol* 1999; 17: 567.
- Correia JJ. Effects of antimetabolic agents on tubulin–nucleotide interactions. *Pharmacol Ther* 1991; 52: 127.
- Rowinsky EK, Donehower RC. Antimicrotubule agents. In: Chabner BA, Longo DL, eds. *Cancer chemotherapy principles and practice*. Philadelphia: JB Lippincott, 2001; 329–372.
- Honavar SG, Singh AD, Shields CL et al. Postenucleation adjuvant therapy in high-risk retinoblastoma. *Arch Ophthalmol* 2002; 120: 923–931.
- Uusitalo MS, Van Quill KR, Scott IU et al. Evaluation of chemoprophylaxis in patients with unilateral retinoblastoma with high-risk features on histopathologic examination. *Arch Ophthalmol* 2001; 119: 41–48.
- Chantada GL, Dunkel IJ, deDavila MTG et al. Retinoblastoma patients with high risk ocular pathological features: who needs adjuvant therapy? *Br J Ophthalmol* 2004; 88: 1069–1073.
- Donaldson SS, Egbert PR, Newsham I et al. Retinoblastoma. In: Pizzo PA, Poplack DG, eds. *Principles and practice of pediatric oncology*, 4th edn. Philadelphia: Lippincott-Raven, 2002; 825–846.
- Dunkel IJ, Aledo A, Kerman N et al. Successful treatment of metastatic retinoblastoma. *Cancer* 2000; 89: 2117–2121.
- Chantada G, Fadino A, Casak et al. Treatment of overt extraocular retinoblastoma. *Med Pediatr Oncol* 2003; 40: 158–161.
- Antonelli CBG, Steinhilber F, Ribeiro KCB et al. Extraocular retinoblastoma: A 13 year experience. *Cancer* 2003; 98: 1292–1298.
- Namouni F, Doz F, Tanguy ML et al. High dose chemotherapy with carboplatin, etoposide, and cyclophosphamide followed by haematopoietic stem cell rescue in patients with high risk retinoblastoma: a SFOP and SFGM study. *Eur J Cancer* 1997; 33: 2368–2375.
- Jubran RF, Erdreich-Epstein A, Butturini A et al. Approaches to treatment of extraocular retinoblastoma. *Childrens Hospital Los Angeles experience*. *J Pediatr Hematol Oncol* 2004; 26: 31–34.
- Matsubara H, Makimoto A, Higa T et al. A multidisciplinary treatment strategy that includes high dose chemotherapy for metastatic retinoblastoma without CNS involvement. *Bone Marrow Transplant* 2005; 35: 763–766.
- DePotter P, Shields CL, Shields JA et al. Clinical variations of trilateral retinoblastoma. *J Pediatric Ophthalmol Strabismus* 1994; 31: 26–31.
- Amouku WMK, Willshaw HE, Parkes SE et al. Trilateral retinoblastoma. A report of five patients. *Cancer* 1996; 78: 858–863.
- Dunkel IJ, Jubran R, Chan HSL et al. Intensive chemotherapy for central nervous system (CNS) retinoblastoma. *Proceedings 12th International Symposium on Retinoblastoma*, 2005.



# Local therapy, brachytherapy, and enucleation

A. Linn Murphree

## INTRODUCTION

The two most common surgical procedures used as part of the treatment of intraocular retinoblastoma are local therapy, either primary or for consolidation following systemic chemotherapy, and enucleation. In this chapter general guidelines are provided to assist an ophthalmic surgeon who is relatively new to the treatment of retinoblastoma. This chapter might also be of help to those ophthalmologists who would like to compare their current approach with the principles and approaches used by other surgeons. Radioactive plaque therapy of retinoblastoma is also discussed.

## TERMINOLOGY

**Local treatment** Before primary systemic chemotherapy was introduced as treatment for intraocular retinoblastoma in the early 1990s all intraocular retinoblastoma therapy, including photocoagulation, thermotherapy, chemothermotherapy, cryotherapy, brachytherapy, and external beam radiotherapy, could be considered local treatment (Table 75.1). External beam radiotherapy of retinoblastoma is discussed in Chapter 76.

**Local primary treatment** Primary treatment refers to local treatment employed as the sole therapy for very small tumors (Group A).

**Chemoreduction or neoadjuvant chemotherapy** The term chemoreduction is used to describe induction of tumor shrinkage as the function of primary systemic chemotherapy, implying the need for a subsequent consolidation treatment.

**Consolidation treatment** In today's treatment environment, local treatment is applied more frequently following primary systemic chemotherapy or chemoreduction. The term consolidation, as used in oncology, is a therapy that is used in tandem with primary therapy to 'mop up' or eliminate the tumor cells that were resistant to, or were not inactivated by, the primary therapy. In most other childhood tumors, consolidation involves switching treatment modalities entirely, or at least changing to different agents and/or doses of the primary modality. In the case of intraocular retinoblastoma, local consolidation consists of direct laser photocoagulation, hyperthermia, thermochemotherapy, thermotherapy, or cryotherapy. Brachytherapy is not routinely used for focal consolidation because of the very high risk of aggressive radiation retinopathy.

**Photocoagulation** Described by Meyer-Swickerath in 1949,<sup>1</sup> photocoagulation involves heating the tumor to temperatures above 65°C (Chapter 7).

**Hyperthermia** Hyperthermia implies raising the tumor temperature to 42–45°C. Hyperthermia can be induced by laser, microwave, ultrasound, and a localized current field or ferromagnetic thermoseeds (Chapter 40).

**Thermochemotherapy** The combined use of heat in the hyperthermia range (42–45°C; sub-photocoagulation level) and chemotherapy is referred to as thermochemotherapy.<sup>2</sup>

**Thermotherapy** During thermotherapy, the tumor is heated to a temperature of 60–65°C for longer periods. In 1994, Oosterhuis and co-workers introduced thermotherapy by means of an infrared diode laser (transpupillary thermotherapy – TTT).<sup>3</sup> Increased depth of tumor necrosis is achieved with TTT compared to photocoagulation, and, unlike hyperthermia, the cytotoxic effects of TTT are irreversible (Chapter 40).

## LOCAL PRIMARY TREATMENT

Group A eyes with small intraretinal lesions away from critical structures are candidates for local primary therapy, such as direct laser photocoagulation or cryotherapy (Chapter 69). The indications for brachytherapy are discussed below. Lesions in all part of the fundus can be treated primarily with the techniques described below for local consolidation following systemic chemotherapy. Tumor foci that have not been treated with systemic chemotherapy may be more fragile and sensitive to intense energy density from the laser. For this reason, small spot size, high power, and prolonged burn duration, all of which contribute to increased power density, should be used with caution to avoid sudden mechanical tumor disruption and dissemination (Chapter 7).

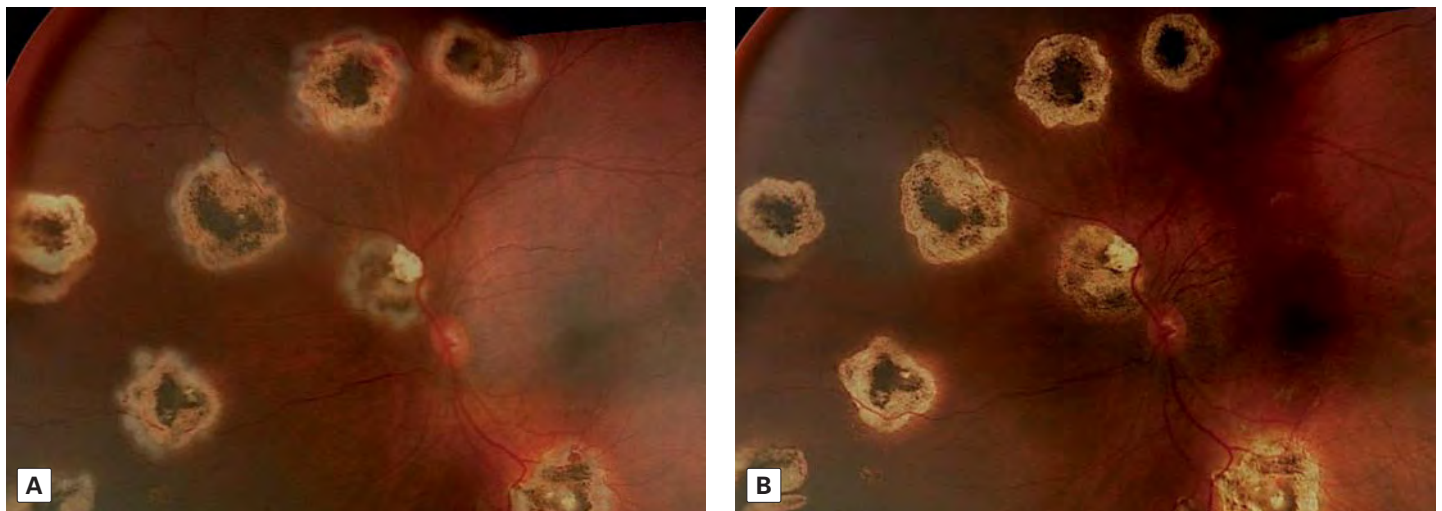## LOCAL CONSOLIDATION TREATMENT

### Photocoagulation with argon green laser (532 nm)

**Background** The argon 532 nm (green) laser is useful in most situations for local consolidation after at least one cycle of systemic chemotherapy. As with other uses of retinal photocoagulation, local consolidation should not be attempted if the retina containing the lesion is detached. The argon's midrange visible (532 nm) wavelength is more readily absorbed in the non-pigmented retinoblastoma tissue

**Table 75.1 Local treatment of retinoblastoma**

Treatment	Indication	Complications
Photocoagulation	Primary treatment, consolidation treatment, and for tumor recurrence  Tumors not more than 3 mm in diameter, with no evidence of seeding, and located posterior to the equator	Tumor seeding into vitreous Retinal fibrosis and traction Retinal vascular occlusion
Thermotherapy	Primary treatment, consolidation treatment, and for tumor recurrence  Tumors not more than 3 mm in diameter, with no evidence of seeding, and located posterior to the equator	Iris atrophy, focal cataracts Tumor seeding into vitreous Retinal fibrosis and traction Retinal vascular occlusion
Thermochemotherapy	Consolidation treatment. Tumors not more than 12 mm in diameter with no evidence of seeding, and located posterior to the equator	Iris atrophy, focal cataracts Tumor seeding into vitreous transient retinal detachment, diffuse choroidal atrophy
Cryotherapy	Primary treatment, consolidation treatment, and for tumor recurrence  Tumors not more than 3 mm in diameter with no evidence of seeding, and located anterior to the equator 'Cutting cryo' for posterior tumors	Large area of retinal atrophy, transient retinal detachment, retinal hole, retinal detachment
Brachytherapy	Primary treatment, residual tumor following photocoagulation/thermotherapy thermochemotherapy/cryotherapy, and for tumor recurrence  Tumor less than 15 mm in diameter Presence of diffuse vitreous seeding is contraindication	Radiation retinopathy, radiation optic neuropathy



**Fig. 75.1** Image taken immediately after the third consolidation laser photocoagulation (A). Each lesion was covered with laser burns. Note the distinct gentle white burn at the lesion edge. There is differential energy uptake. Three weeks later, all lesions are flat with no clinical evidence of active disease (B). We recommend three complete coverage of lesions like these at 3–4 week intervals.

than the longer (810 nm) wavelength. Its only disadvantage is the small spot size. Care must be taken not to increase the power density in the small spot. Tumor disruption may occur in a small spot if the power from the laser exceeds 700–800 mW for more than 0.3–0.4 seconds.

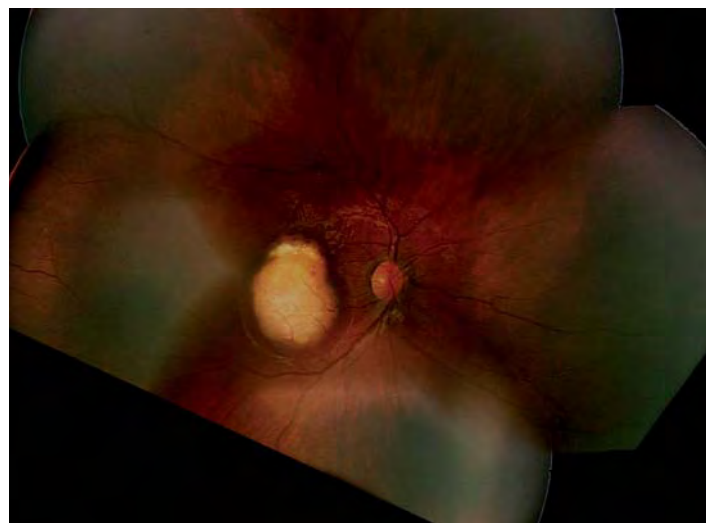
**Technique** The 532 nm laser is available as a table-top solid-state laser with an indirect delivery system that works best for transpupillary applications during examination under anesthesia. The desirable end point for the ophthalmologist is a gentle white spot generated at the boundary between normal retina and tumor edge (Fig. 75.1). The

power is initially set at between 250 and 350 mW for 0.3–0.5 seconds. Burns are placed at the edge of the lesion, half-on and half-off the tumor. The power and/or burn duration is slowly increased until a clear reaction is achieved. Punctate hemorrhage in the treatment spots is a sign that the power density is high. The intensity of the treatment (increasing power out of the fiber or burn duration) should not exceed the levels at which the hemorrhage appeared.

Once the appropriate power level is set, the edge of the tumor is treated with overlapping burns to establish its perimeter. Subsequently the entire lesion should be treated with burns having the same overlap. In the central, thicker portions of the tumor, the whitening reaction following treatment may not be present. Neither power nor burn duration should be increased. The burn is occurring on the underside of the tumor nearest the Retinal pigment epithelium (RPE).

**Frequency of treatment** Typically the treatment is repeated every 3–4 weeks immediately before the next cycle of chemotherapy. A 2–4-week interval can be adopted if the systemic chemotherapy has been completed. Edge recurrence may appear if the laser consolidation is insufficient or significantly delayed (Fig. 75.2).

**Mechanism of action** When photocoagulation is used on retinoblastoma lesions and the patient subsequently receives planned systemic chemotherapy including carboplatin within 24 hours, two tumor-destroying mechanisms may come into play. The first and the most important is the direct tumor cell kill generated by the temperatures in excess of 70°C within the treatment spot. The second mechanism occurs in the ‘donut’ or ring of tissue extending for several millimeters outside the spot. Heat radiating out from the central spot



**Fig. 75.2** Edge regrowth 8 weeks after the last laser treatment that almost covers the original flat chorioretinal scar. This child missed one follow-up EUA.

increases the temperature to the thermochemotherapy threshold of 45°C. In this region there is a synergism with the carboplatin, assuming an adequate level of carboplatin is achieved in the tumor.

**Recommendations** In Los Angeles, our treatment protocol requires that each lesion, except those composed entirely of type I regression (calcium), be treated completely with laser on at least three occasions 2–3 weeks apart. A flat chorioretinal scar that has received laser consolidation only once cannot, in our experience, be considered sterilized.

### Photocoagulation with diode laser (810 nm)

**Background** The 810 nm diode laser is most effective when there is intact RPE beneath the tumor. The indirect ophthalmoscope delivery system offers a spot size of 0.5 mm. This provides safety and convenience. Safety comes from the reduced likelihood of concentrated power intensity in a small spot creating explosive disruption of the tumor. The larger spot size compared to argon laser saves treatment time, thereby conferring convenience.

**Technique** The delivery technique is similar to that with argon laser photocoagulation. The entire tumor is treated with overlap of the spots similar to that described above for the argon 532 nm laser. The initial power settings with the diode laser, especially when the large spot is used, are somewhat higher than for the argon laser (Table 75.2). We generally select an initial setting of 400–500 mW and 0.5–1.0 seconds. The power and duration will vary for each patient because of the degree of pigmentation underlying the lesion. As with the argon laser, both power and burn duration can be increased incrementally until the appropriate end point is reached.

**Frequency of treatment** The treatment is repeated every 3–4 weeks immediately before the next cycle of chemotherapy. A 2–4-week interval can be adopted if the systemic chemotherapy has been completed.

**Mechanism of action** The most important effect is the direct heat-mediated tumor cell kill. The diode laser is most effective when intact RPE is present beneath the tumor to be treated. If the RPE has been destroyed, most of the 810 nm wavelength energy passes into the orbit without being absorbed by the retinoblastoma (see discussion under TTT below).

**Recommendation** If only one laser is available for use in delivering local therapy to retinoblastoma, the 532 nm laser is probably the most versatile.

**Transpupillary thermotherapy (TTT)** is a direct tumor cell killing system that couples large spot size (2–3 mm) and long burn

**Table 75.2** Instruments and settings commonly used for local laser consolidation

Instrument	Wavelength (nm)	Largest spot size (μm)	Maximum recommended power (mW)	Usual power (mW)	Usual burn duration(s)
Argon laser	532	50	600	300–400	0.3–0.5
Diode laser	810	500	800	500–700	0.5–9



duration (1 minute) with low power settings, applied to achieve the end point of gentle whitening in the treatment spot (Chapter 40). The infrared diode laser (810 nm) is effective in killing choroidal melanoma cells because pigmentation in the tumor allows absorption of the laser energy. The long-term efficacy of this approach is under question (Chapter 40). Transpupillary thermotherapy is difficult to adapt to the treatment of retinoblastoma because of lack of pigmentation in the tumor. Initially, intact RPE will absorb the laser energy and generate heat to affect the tumor. However, once the RPE is no longer intact under the retinoblastoma, relatively little of the delivered energy will be absorbed by the tumor.<sup>4,5</sup> Moreover, TTT is used as primary therapy and not in combination with chemotherapy.

### Thermochemotherapy

**Background** The 810 nm diode laser was initially adapted as a source of hyperthermia for the treatment of small discrete retinoblastoma tumors. This initial use of the infrared diode laser relied on hyperthermia (42–45°C) to provide synergistic tumor killing with platinum-based chemotherapy, carboplatin. This combined use of chemotherapy and heat in the sub-photocoagulation range was referred to as thermochemotherapy.<sup>2,6</sup>

**Technique** The 810 nm diode laser is available as a tabletop model. The laser indirect ophthalmoscope delivery system is used most commonly for retinoblastoma. Occasionally the diode is still used with an operating microscope delivery system and a contact lens. Thermochemotherapy requires a long spot time (5–10 minutes).<sup>2</sup>

**Mechanism of action** The hyperthermia delivered was analogous to other applications of hyperthermia that were in fairly wide use in the early 1990s to enhance the effect of radiotherapy or systemic chemotherapy. The goal of hyperthermia was not direct kill of the tumor cells, but rather the enhancement of the alkalyting effect of the carboplatin.

**Frequency of treatment** The treatment was repeated every 3–4 weeks immediately before the next cycle of chemotherapy.

**Recommendations** Thermochemotherapy is effective, but unfortunately time-consuming. As a result, this approach is rarely used today.

### TRANS-SCLERAL CRYOTHERAPY

**Background** The indications for cryotherapy are similar to those for laser thermotherapy, but cryotherapy is more suitable for anterior tumors.<sup>7</sup> At least 70% of carefully selected tumors can be treated with cryotherapy.<sup>8</sup>

**Technique** Cryotherapy has particular value if there is a small peripheral lesion with a focal site that may have shed tumor cells into the vitreous. For tumors located posterior to the equator, a small conjunctival incision in the fornix located between the rectus muscles may be necessary to advance the curved cryoprobe posteriorly ('cutting' cryotherapy). The position of the cryoprobe tip is verified by indirect ophthalmoscopy using the standard techniques of scleral indentation. Once the tip is centered on the tumor, freezing is begun. Any iceball used to freeze a tumor should incorporate all of the vitreous near the lesion that may contain the local tumor cell clumps or 'seeds.' Triple freeze-thaw cycles are generally applied. The number of sites treated

with cryotherapy at one sitting should be limited to two or three because of the likelihood of creating a secondary serous retinal detachment with more extensive treatment. Cryotherapy tends to destroy a relatively large amount of peripheral retina (Fig. 75.3). Complications of cryotherapy can include retinal breaks that may be associated with retinal detachment. Cryotherapy is contraindicated for the treatment of more than one quadrant of disease at the ora serrata. The need for extensive therapy often arises when retinal detachment is present at diagnosis, settles with systemic chemotherapy, and then satellite tumors appear 3–4 months after the completion of chemotherapy. Cryotherapy is rarely the treatment of choice with such diffuse disease.

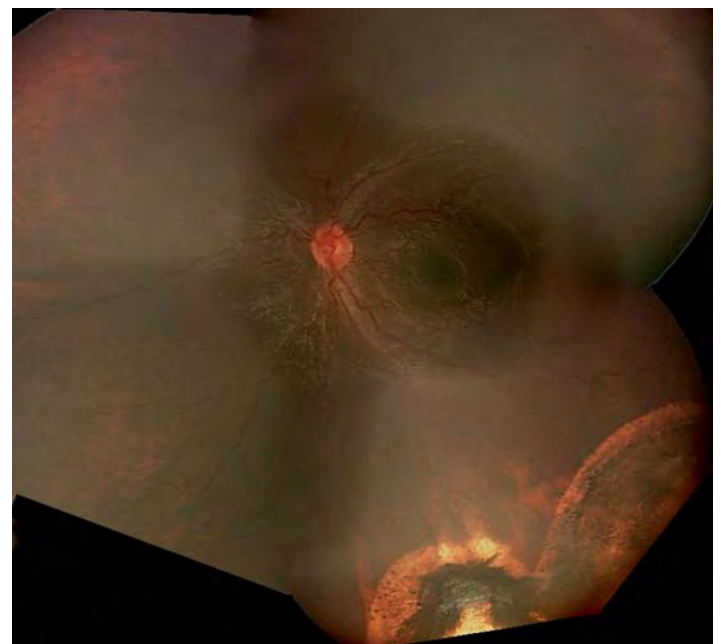
**Mechanism of action** Cryotherapy is a local destructive modality that kills tumor cells mechanically via ice crystal disruption of the cell membranes (Chapter 6).

**Frequency of treatment** The treatment is repeated every 3–4 weeks. A flat chorioretinal scar is an acceptable end point.

**Recommendations** Cryotherapy is suitable for anteriorly located Group A tumors. Excessive cryotherapy should be avoided.

### BRACHYTHERAPY

**Background** Brachytherapy (Greek 'brachy,' or short distance) refers to the implantation of radioactive material within or close to the tumor (Chapters 8 and 41). Moore<sup>9</sup> first used brachytherapy for uveal melanoma in 1930 by inserting radon-222 seeds into the tumor. This technique was later modified by Stallard,<sup>12</sup> when he introduced cobalt-60 radioactive plaques sutured to the surface of the episclera.<sup>10,11</sup> In the United States, iodine-125 is the preferred radioactive source.<sup>12</sup> The radiation from iodine seeds can be shielded by the gold carrier material



**Fig. 75.3** Two cryotherapy scars in the inferotemporal periphery. Note extensive destruction of the peripheral retina.

of the plaque and by a thin lead shield that is used over the eye during the time the plaque is in place. In Europe, ruthenium-106 is commonly used as a radioactive source for episcleral brachytherapy.<sup>13</sup> Ruthenium offers some advantages over iodine: improved calculation of dose distribution for clinical planning<sup>14</sup> has ushered in the routine use of ruthenium for retinoblastoma and choroidal melanoma at University of South California and Children's Hospital Los Angeles. Ruthenium has a longer half-life of 6 months compared to iodine.<sup>15</sup> Iodine-125 and ruthenium-106 isotopes are the most common source of radiation currently used in brachytherapy for retinoblastoma.<sup>15,16</sup> Other less frequently used radionuclides are palladium-103, gold (aurum)-198, iridium-192, and strontium-90 (Chapter 41).

**Technique** The principles of brachytherapy (Chapter 8) and plaque design (Chapter 41) are discussed in other sections of the book. The standard apical dose of 45Gy is usually prescribed for retinoblastoma,<sup>17</sup> although lower doses to the apex of the tumor may be just as effective. A detailed discussion of plaque planning is beyond the scope of this chapter, but relevant details are available elsewhere.<sup>18</sup> The surgical technique of plaque application is similar to that used for uveal melanoma (Chapter 41).

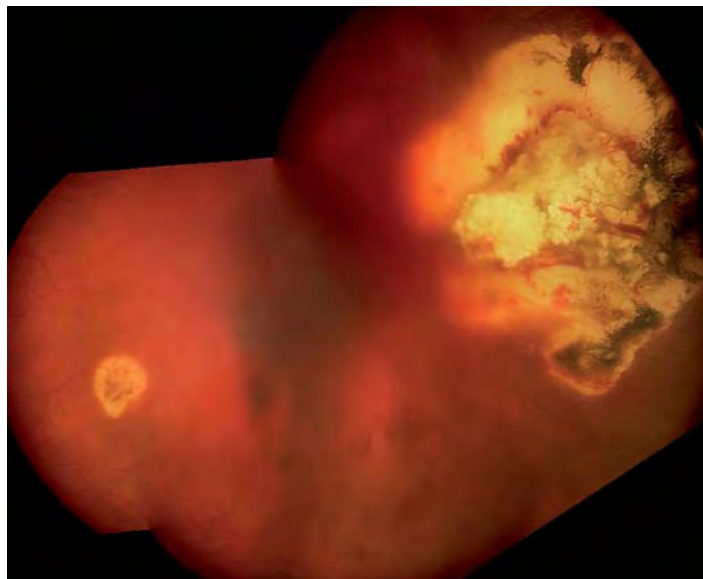
**Mechanism of action** Tissue absorption of ionizing radiation causes DNA damage, loss of reproductive capacity, and cell death. Retinoblastoma with a large proportion of dividing cells is more radiosensitive than uveal melanoma. Because of the dose gradient in episcleral plaque radiotherapy, the most severe effects are seen at the tumor base, where the dose of radiation is the highest. There may be a partial solution to this problem, however. Astrahan and colleagues<sup>19</sup> recently described a simple concept of shielding each iodine-125 source by creating deeper slots in the gold carrier, thereby increasing individual source columnation. Their 'slotted' plaque reduces the delivered scleral dose by as much as 50% without reducing the dose to the apex.

**Frequency of treatment** Plaque radiotherapy is usually applied only once. The treatment effects are noticeable within 4 weeks. The tumor regresses completely with only residual calcification. Failure of a lesion to respond to brachytherapy may indicate that it was a 'presumed' early retinocytoma.

**Recommendations** Brachytherapy is rarely considered for routine focal consolidation because of the very high risk of aggressive radiation retinopathy (Fig. 75.4). Instead, it is useful for either the primary treatment of an isolated Group B tumor at or anterior to the equator, or for the treatment of edge recurrences that are too large or extensive for laser or cryotherapy alone (Fig. 75.5).

## ENUCLEATION

Enucleation procedure is not only the oldest surgical procedure used to treat intraocular retinoblastoma but is also one of the best choices for advanced disease present in only one eye. If an ocular 'event' such as diffuse subretinal satellite tumors occurs, then enucleation may be the treatment of choice (Fig. 75.6). Some of the principles and techniques of enucleation are discussed elsewhere (Chapter 98). This chapter focuses on specific issues related to enucleation for retinoblastoma, including some 'surgical pearls' that in the author's experience have been shown to be very effective.

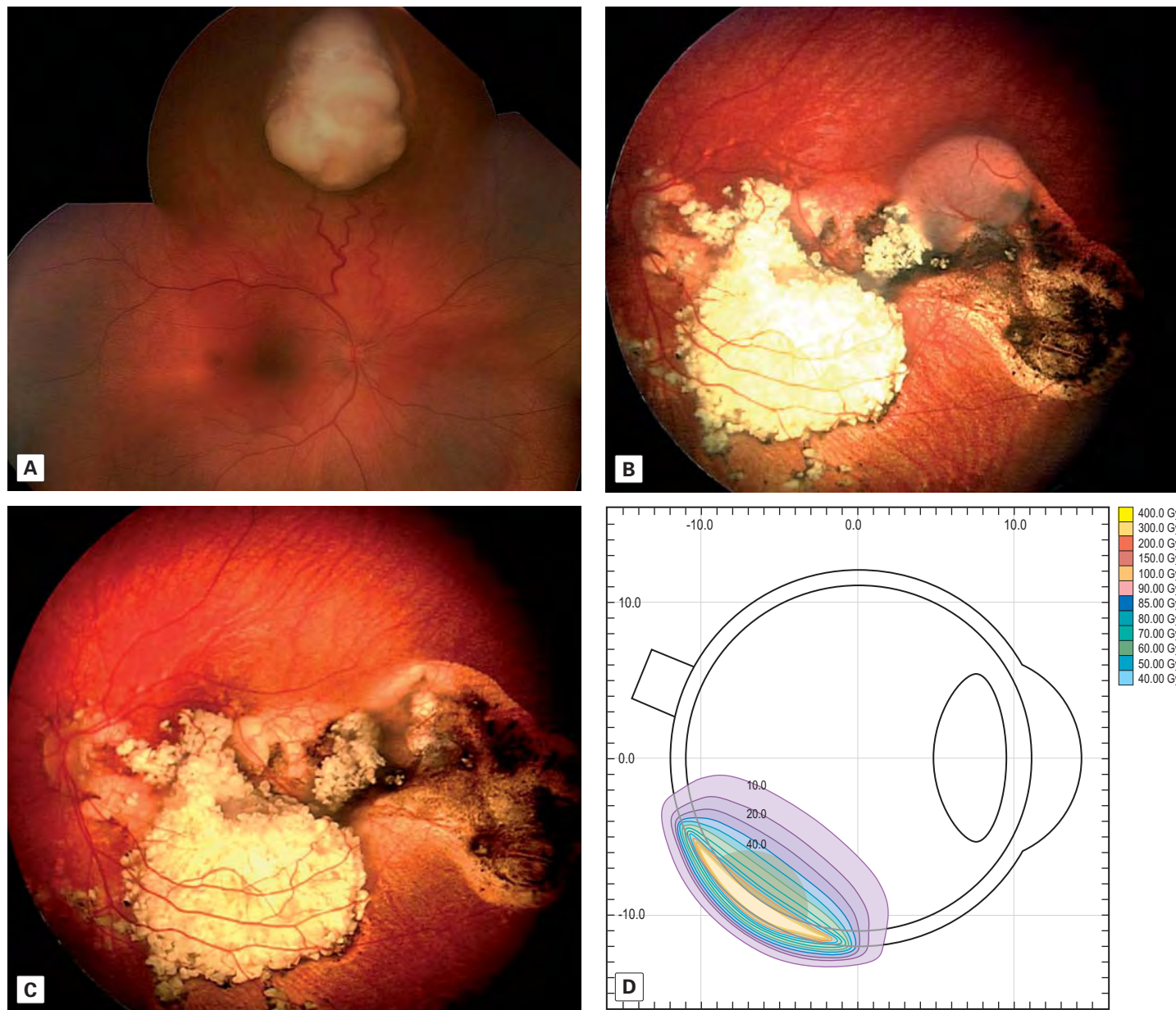


**Fig. 75.4** Radiation retinopathy in the nasal periphery following primary brachytherapy. Recurrent vitreous seeding required external beam radiation therapy. This vitreous hemorrhage began about 6 months after completion of the external beam radiation therapy.

**Meticulous intraoperative hemostasis (MIH)** Meticulous intraoperative hemostasis from the beginning of the procedure allows the surgery to be precise and controlled. It assures the absence of postoperative ecchymosis and orbital edema. It facilitates the obtaining of a long section of optic nerve. It assists in the insertion of a large implant and achieving a good cosmetic outcome (Box 75.1).

**Long optic nerve stump** Certain surgical steps can facilitate obtaining about a 15 mm long optic nerve stump in all cases of retinoblastoma (Chapter 78).<sup>20</sup> An artery clamp (a large Allis clamp happens to be the width of the rectus insertion) can be used to exert gentle traction. My personal experience is that the gentle traction applied to the 4–6 mm lateral rectus stump 'lengthens' the nerve in the orbit exposed to the scissors. A straight Mayo scissor, or a 15° curved enucleation scissor, may be used if the tip is kept in contact with the nasal orbital wall. The scissor is introduced from the medial aspect and the tips are passed blindly through the posterior Tenon's to touch bone. The optic nerve is palpated ('strummed') with the closed tips of the scissors while maintaining gentle traction on the lateral rectus stump. The scissor tip is moved posteriorly and nasally and the nerve is transected with one bold cut. With good hemostasis, blunt dissection of the remaining connective tissue can be carefully performed with a 4 × 4 gauze under direct visualization. The absence of significant bleeding allows time to avoid a second unnecessary transection of the optic nerve. This maneuver generally provides at least a 15 mm long optic nerve stump. Extreme care should be taken to avoid accidental perforation of the globe. After enucleation the length of the optic nerve stump should be measured and documented. The globe and optic nerve must also be inspected for extraocular extension of the tumor.

**Attention to surgical closure and prevention of implant extrusion** Exposure of the surgical implant postoperatively is a surgical complication that can be prevented by diligent attention to surgical detail. There are many equally good techniques. After attaching the

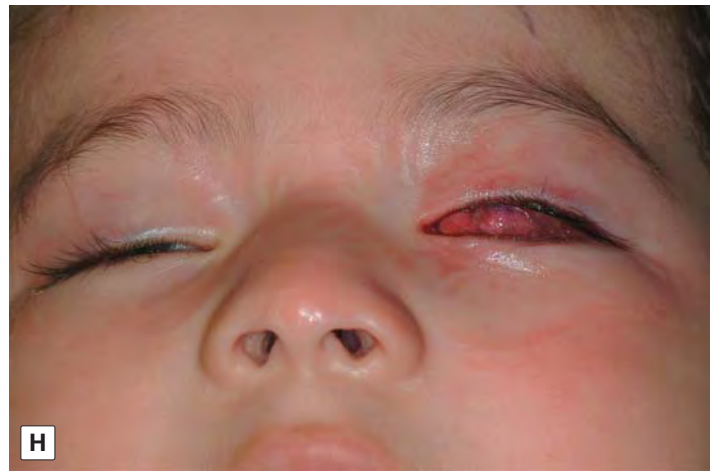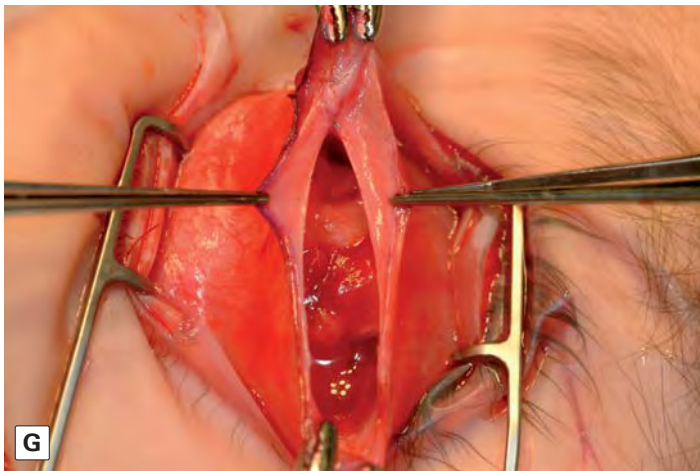
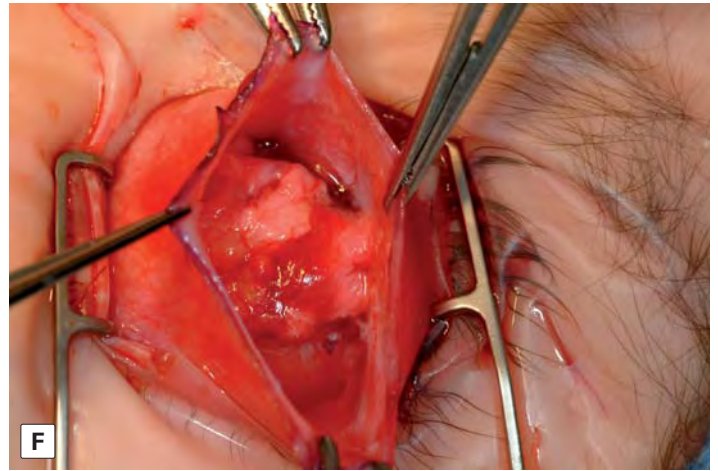
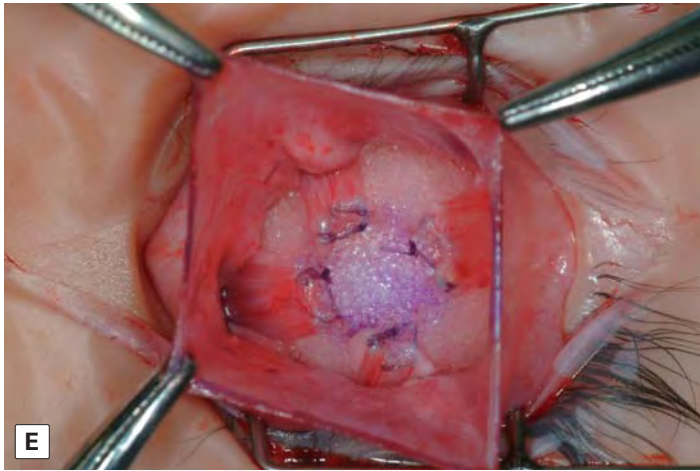
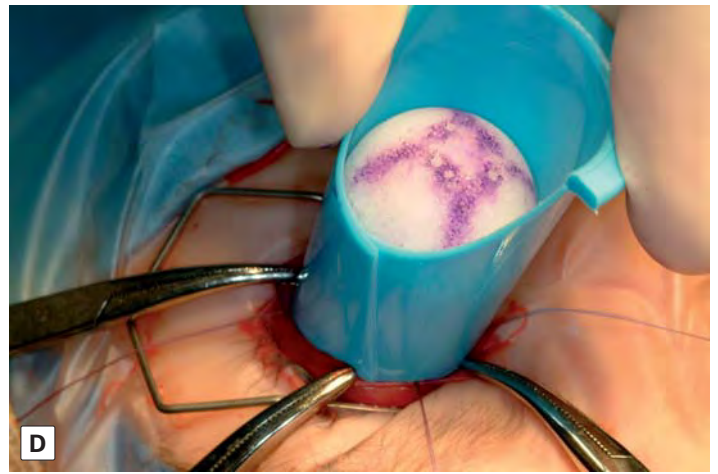
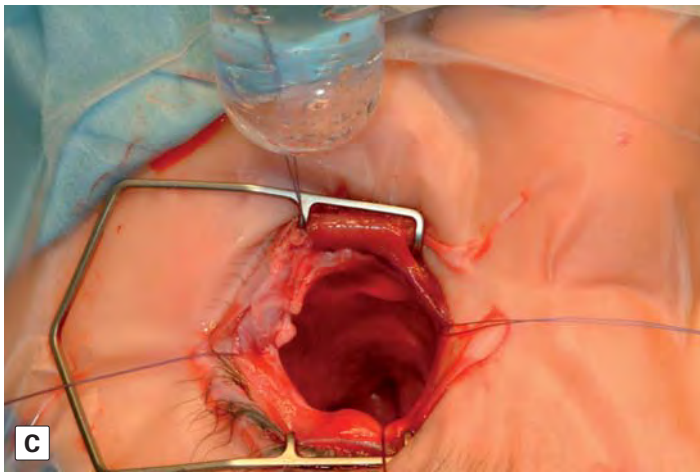
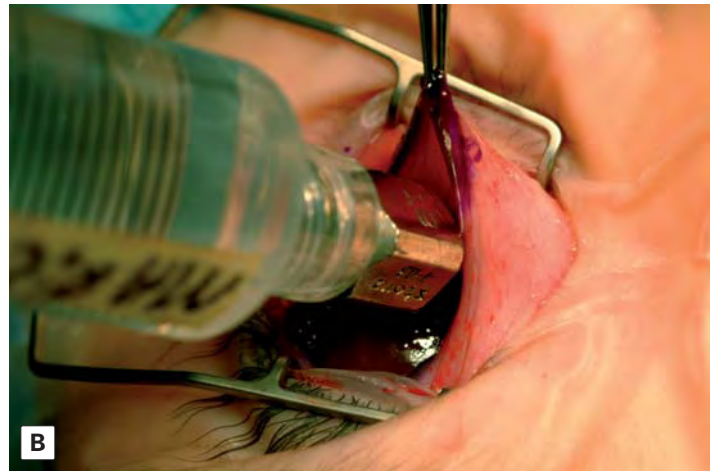
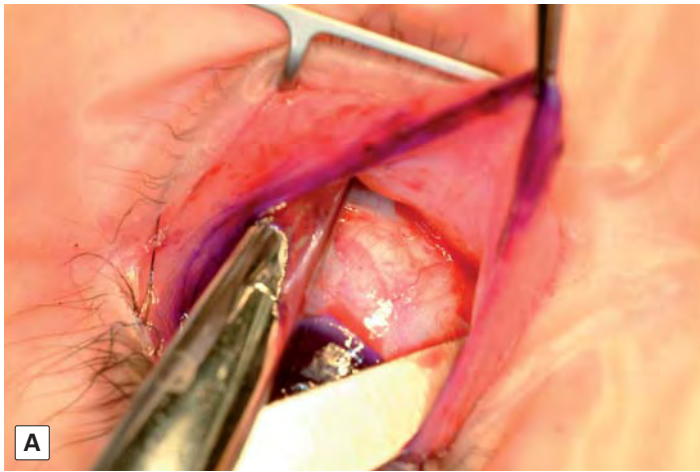


**Fig. 75.5** A Group C eye with solitary peripheral tumor that is a candidate for brachytherapy (A). A 12-month-old child with bilateral retinoblastoma treated with chemoreduction and consolidation. Note tumor recurrence within the chorioretinal scar from previous cryotherapy in the left eye (B). There was tumor regression within 4 weeks of brachytherapy (C). A 16 mm round ruthenium-106 plaque (apical dose 38.70 Gy, total duration 32 hours) was used for plaque radiotherapy (D).

rectus muscles to the implant of choice, we pack fat and connective tissue (autologous orbital fat graft-AOFG) harvested from the back of the enucleated globe over the anterior surface of the implant. We then close the anterior Tenon’s capsule with horizontal mattress sutures 4–5 mm posterior to the conjunctival edge using 5/0 Vicryl for good position and maintenance of the upper and lower culs-de-sac. Multiple vertical interrupted 5/0 sutures strengthen the initial anterior Tenon suture line. The AOFG serves as a ‘mechanical buffer’ or ‘cushion’ between the rough surface and overlying Tenons and may contribute to the prevention of implant exposure.

**Harvest of fresh tumor for *RB1* testing or other research uses** During the 10-minute pause for hemostasis after removal of the globe and after removal of the excess fat and connective tissue for later use in the closure, with the permission of the ocular pathologist the optic nerve can be removed from the eye and submitted separately. An 8.5–9.0 mm corneal trephine can be used to gently open a round ‘window’ in the wall of the globe. Forceps and scissors are then used to remove a sample of the tumor. Bisecting the globe is also an excellent way of harvesting fresh tumor. Some pathologists may want to perform this harvesting themselves in the operating room.





**Fig. 75.6** Key steps in the successful enucleation of a Group E eye. Immediately after the peritomy, the Tenon's capsule is being spread widely and deeply between the rectus muscles with a curved Stephens' scissor (A). 2 mL of a 1:1 mixture of short- and long-acting local anesthesia is deposited in the retrobulbar space using an irrigating cannula (B). Dry orbit immediately after removing the iced saline-filled test tube that had provided gentle pressure to the apex for 10 minutes (C). 20mm conical SST Medpor implant being inserted into the orbit (D). The predrilled holes and orientation for the rectus muscles are indicated by a skin marker. The four rectus muscles are attached to the predrilled implant (E). The previously harvested retrobulbar fat and connective tissue is placed over the exposed surface of the implant to provide a 'cushion' between suture knots and Tenon's closure to assist in preventing postoperative implant extrusion (F). The first horizontal mattress suture (5/0 Vicryl) has been tied (G). Three to four more mattress sutures will be used to approximate the tissues. Six to eight vertical interrupted sutures across the horizontal mattress sutures will provide strength to the Tenon's closure. The appearance of the child immediately after the drape has been removed following the removal of the left eye (H). Note the lack of ecchymosis or lid edema. A simple patch will be used only for the first 24 hours.

### BOX 75.1 Procedure for Meticulous Intraoperative Hemostasis (MIH) during Enucleation

- Irrigate 2 mL of local anesthesia containing epinephrine into the retrobulbar space after spreading Tenon's capsule widely and before isolating the muscles
- Irrigate an additional 6–8 mL of the local anesthesia mixture into the retrobulbar space after complete removal of all six muscles from the globe
- Globe will proptose. Intraocular pressure will be very high
- Wait 10 minutes by the clock (may prepare the implant during this time)
- Immediately before severing the nerve and removing the globe, fill a plastic test tube with sterile iced saline (slush). Do not wrap in gauze. After removing the eye, introduce the test tube to apply firm pressure at the apex of the orbit
- Maintain gentle pressure for 10 minutes by the clock. Fresh tumor may be harvested for tumor DNA for *RB1* gene testing during this time
- Gently remove test tube. Orbit will be dry
- At end of the procedure a simple patch is used for 24 hours only

The local anesthesia consists of 10 mL of a 1:1 mixture of 1% lidocaine with epinephrine (1:200 000) and long-acting local anesthetic containing epinephrine (1:200 000). Hyaluronidase may be added to the mixture.

### Prevention of postoperative nausea and vomiting (PONV)

Careful attention to the prevention of PONV reduces the chance that there will be orbital hemorrhage in the postoperative period. At a minimum, intravenous steroids along with a 24-hour dose of ondansetron (Zofran) or similar agent is given intravenously during surgery. Postoperative pain is controlled for 4 hours by the long-acting local anesthetic given prior to cutting the optic nerve. The child receives alternating appropriate doses of liquid Lortab or similar (Tylenol with codeine or hydrocodone) with liquid ibuprofen so that analgesic is given every 3 hours for the first 3–4 days. It is not uncommon to find that, if the analgesics are discontinued too early, nausea and vomiting can make its first appearance on the second or third postoperative day. We have found that multiagent prophylaxis for PONV should include agents that specifically target motion sickness, such as Dramamine taken at least 30 minutes before the child is transported home from the outpatient surgery.

## REFERENCES

1. Meyer Schwickerath G, Vogel MH. Malignant melanoma of the choroid treated with photocoagulation. A 10-year follow-up. *Mod Probl Ophthalmol* 1974; 12: 544–549.
2. Murphree AL, Villablanca JG, Deegan WF 3rd et al. Chemotherapy plus local treatment in the management of intraocular retinoblastoma. *Arch Ophthalmol* 1996; 114: 1348–1356.
3. Oosterhuis JA, Journée-de Korver JG, Kakebeeke-Kemme HM et al. Transpupillary thermotherapy in choroidal melanoma. *Arch Ophthalmol* 1995; 113: 315–321.
4. Abramson DH, Scheffer AC. Transpupillary thermotherapy as initial treatment for small intraocular retinoblastoma: technique and predictors of success. *Ophthalmology* 2004; 111: 984–991.
5. Shields CL, Santos MC, Diniz W et al. Thermotherapy for retinoblastoma. *Arch Ophthalmol* 1999; 117: 885–893.
6. Schueler AO, Jurklics C, Heimann H et al. Thermochemotherapy in hereditary retinoblastoma. *Br J Ophthalmol* 2003; 87: 90–95.
7. Lincoff H, McLean J, Long R. The cryosurgical treatment of intraocular tumors. *Am J Ophthalmol* 1967; 63: 389–399.
8. Abramson DH, Ellsworth RM, Rozakis GW. Cryotherapy for retinoblastoma. *Arch Ophthalmol* 1982; 100: 1253–1256.
9. Moore RF. Choroidal sarcoma treated by the intraocular insertion of radon seeds. *Br J Ophthalmol* 1930; 14: 145–152.
10. Stallard HB. Radiotherapy of malignant intra-ocular neoplasm. *Br J Ophthalmol* 1948; 32: 618–639.
11. Stallard HB. The conservative treatment of retinoblastoma. *Trans Ophthalmol Soc UK* 1962; 82: 473–534.
12. Sealy R, le Roux PLM, Ropley F et al. The treatment of ophthalmic tumors with low-energy sources. *Br J Radiol* 1976; 49: 551–554.
13. Lommatzsch PK. Treatment of choroidal melanomas with <sup>106</sup>Ru/<sup>106</sup>Rh beta-ray applicators. *Surv Ophthalmol* 1974; 19: 85–100.
14. Astrahan MA. A patch source model for treatment planning of ruthenium ophthalmic applicators. *Med Phys* 2003; 30: 1219–1228.
15. Schueler AO, Fluhs D, Anastassion G et al. beta-Ray brachytherapy with (106)Ru plaques for retinoblastoma. *Int J Radiat Oncol Biol Phys* 2006; 65: 1212–1221.
16. Hernandez JC, Brady LW, Shields CL, Shields JA, DePotter P. Conservative treatment of retinoblastoma. The use of plaque brachytherapy. *Am J Clin Oncol* 1993; 16: 397–401.
17. Shields CL, Shields JA, Cater J et al. Plaque radiotherapy for retinoblastoma: Long term tumor control and treatment complications in 208 tumors. *Ophthalmology* 2001; 108: 2116–2121.
18. <http://radonc.usc.edu/USCRadonc/Downloadable/PS5/UserGuide/BEBIGPlaquesMenu.html>.
19. Astrahan MA, Luxton G, Pu Q, Petrovich Z. Conformal episcleral plaque therapy. *Int J Radiat Oncol Biol Phys* 1997; 39: 505–519.
20. Moshfeghi DM, Moshfeghi AA, Finger PT. Enucleation. *Surv Ophthalmol* 2000; 44: 277–301.



# Teletherapy: indications, risks, and new delivery options

Thomas E. Merchant

## INTRODUCTION

In the treatment of retinoblastoma, radiation therapy provides the benchmark for the evaluation of tumor control, for eye preservation, and for side effects. Its role has recently been diminished by the haunting prospect of long-term side effects and a move toward chemotherapy combined with local ophthalmic therapy.<sup>1</sup> This chapter will discuss teletherapy, its indications, risks, and new delivery approaches. Chapter 75 provides more detail about brachytherapy in the treatment of intraocular retinoblastoma.

## EFFICACY

Radiation therapy, in its many forms, is a highly effective non-surgical treatment for retinoblastoma, but its effectiveness must be balanced against its potential side effects, because of the patients' young age and genetic susceptibility to further malignancy.

**Globe preservation** Radiation therapy has an excellent track record in preserving the eye. In patients with Reese–Ellsworth Group I–II disease, tumor control rates measured at 5 years are in excess of 95%. In patients with more advanced disease (Reese–Ellsworth Groups III–IV) 5-year control rates reduce to approximately 50%, owing partly to the greater tumor burden and the intraocular extent of disease.<sup>2</sup> Patients with Reese–Ellsworth Group Vb disease have 5-year eye-preservation rates of approximately 53%.<sup>3</sup> Poor tumor control in advanced cases is often attributed to vitreous seeding.

**Visual acuity** Although data on visual acuity are relatively limited, most patients are reported to have good visual acuity (20/20–20/40) after radiation therapy; the rest have at least some prospect of functional vision (20/50–20/400).<sup>4,5</sup> Final visual acuity and field are affected by tumor location, which often depends on the patient's age at the time of diagnosis: younger patients are more likely to have tumors in the macula (Fig. 76.1).<sup>6</sup>

## SIDE EFFECTS AND SECONDARY MALIGNANCIES

The side effects of radiation therapy have framed current clinical trials to include the avoidance of radiation therapy for patients with retinoblastoma. These side effects include ophthalmic complications, such as retinal detachment, vitreous hemorrhage, cataract formation, and glaucoma; somatic complications, such as orbital hypoplasia; and the most daunting of all, the second malignant neoplasm (Fig. 76.2).

**Risk of second malignant neoplasms** The risk of second malignant neoplasms is highest among patients with the germline

mutation of the retinoblastoma gene (RB1). They may occur without the use of radiation therapy, but radiation-induced tumors are the most frequent, and bone and soft tissue sarcomas are the most common. Radiation-induced sarcomas are the secondary malignancies that cause the most deaths, and more patients die from second malignant neoplasms than from retinoblastoma itself.

*The 1914–1984 New York/Boston Patient Series* A report published in 1997 had a chilling effect on the use of radiation therapy in patients with retinoblastoma.<sup>7</sup> The report covered a 70-year experience (1914–1984) of treating 1604 patients with bilateral retinoblastoma. The 50-year cumulative incidence of second malignant neoplasms in irradiated patients was 51% (1% per year) for patients with bilateral disease, but only 5% for patients with unilateral disease (Fig. 76.3). The data clearly showed that radiation-induced tumors are the leading cause of death among long-term survivors. This article is the one most often quoted by parents whose child is referred to a radiation oncologist. It might seem irrational, on the basis of these results, to irradiate a child with retinoblastoma – the radiation oncologist is often put in a difficult position when the family is confronted with the news that external beam irradiation is the only option for ocular preservation.

*The incidence of radiogenic tumors is smaller in other series* Moll et al.<sup>8</sup> reviewed 11 series reporting on malignancy induction, each including more than 50 patients and published between 1966 and 1995: only four were without selection bias. The 11 series included 35 second primary tumors, and three of the larger series showed cumulative incidences of second malignancy of 8% at 18 years, 16% at 20 years, and 19% at 35 years (Fig. 76.3). The same group published an analysis of data from the Netherlands Cancer Registry<sup>9</sup> which included 639 patients diagnosed between 1945 and 1994: 241 had hereditary tumors, and more than 80% were followed for more than 10 years. The cumulative incidence of a histologically confirmed second malignant neoplasm in patients with hereditary tumors was 3.7% at 10 years and only 17.7% at 35 years. Curiously, seven of the 28 second malignant neoplasms in the data from the Netherlands Cancer Registry were melanoma. One might conclude that the lower incidence of second malignant neoplasms in this report than in the 1997 report<sup>7</sup> was due to the unique patient population, which included central referral for an entire country, as well as the definition and types of second malignant neoplasms.



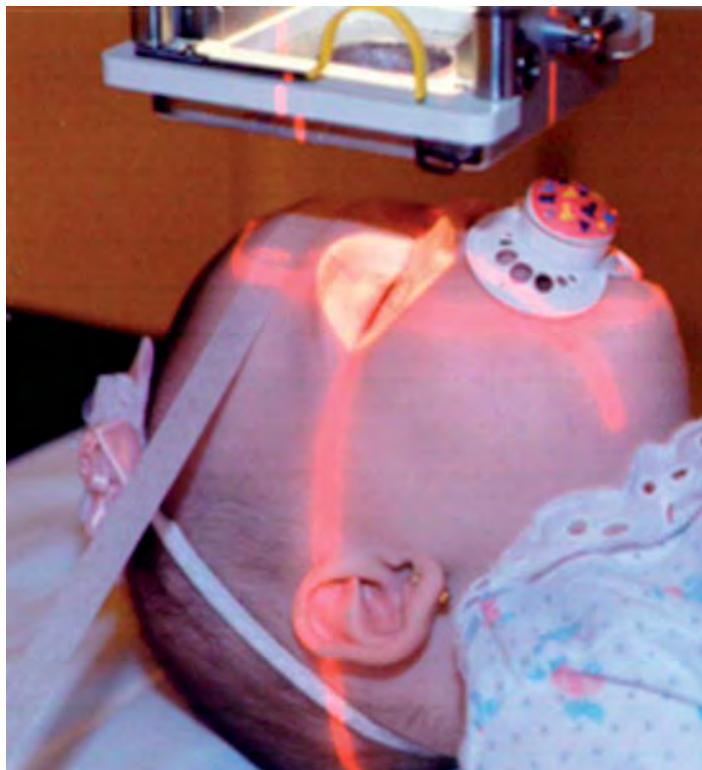

Fig. 76.1 A child receiving external beam radiation therapy.

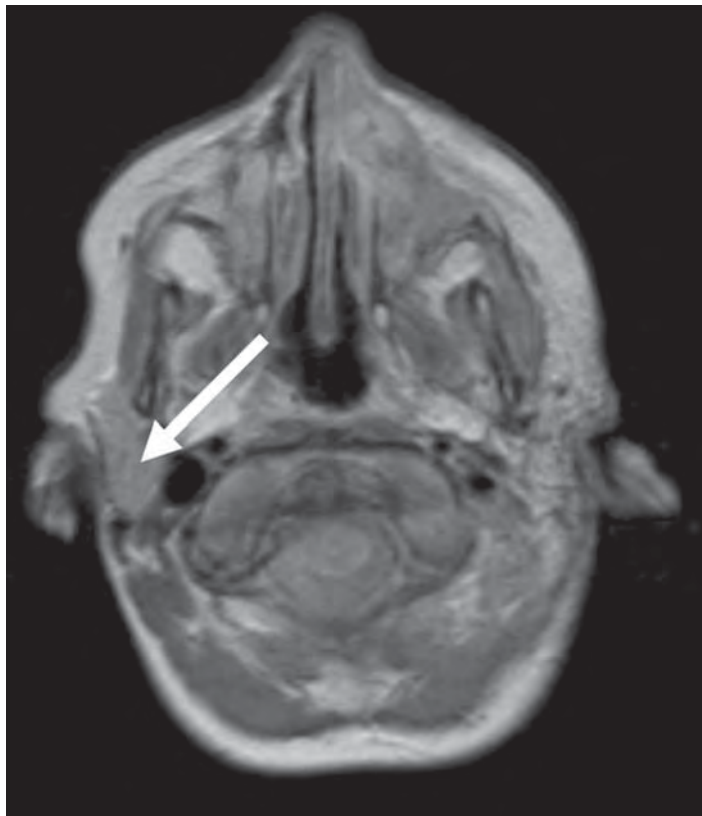


Fig. 76.2 Coronal magnetic resonance image showing a secondary malignancy (sarcoma indicated by arrow) in a patient treated for retinoblastoma.

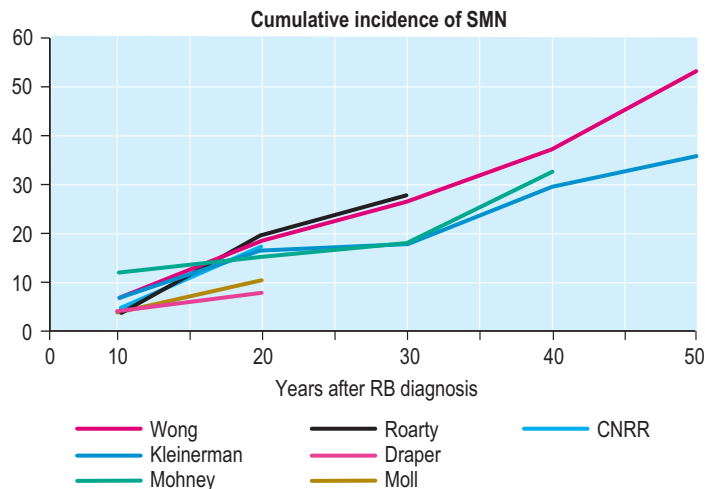


Fig. 76.3 Cumulative incidence of second malignant neoplasms reported in various studies identified by the author. Data derived from Moll AC, Imhof SM, Schouten-Van Meeteren AY et al. Second primary tumors in hereditary retinoblastoma: a register-based study, 1945–1997: is there an age effect on radiation-related risk? *Ophthalmology* 2001; 108: 1109–1114; and Kleinerman RA, Tucker MA, Tarone RE et al. Risk of new cancers after radiotherapy in long-term survivors of retinoblastoma: an extended follow-up. *J Clin Oncol* 2005; 23: 2272–2279.

**A 2005 update on the 1914–1984 New York/Boston Patient Series** A recent report by Kleinerman et al.<sup>10</sup> provided an update on some of the 1601 previously studied retinoblastoma survivors through the year 2000. The analysis included nearly 1000 irradiated or non-irradiated tumors in patients with heritable retinoblastoma. The standardized incidence ratio (ratio of observed to expected cancers) was 22 in the irradiated group and 7 in the non-irradiated group, a three-fold difference. The cumulative incidence of new cancers at 50 years was 38% among those irradiated and 21% in those not irradiated (Fig. 76.3). Sufficient data were available to determine the risks of malignancy induction after orthovoltage irradiation (32.9%) and modern megavoltage irradiation (26.3%); this finding provided some indication that the use of newer radiation therapy modalities might reduce the risk of secondary malignancy. In this series, tissues calculated to receive a cumulative dose of more than 0.4 Gy were considered at risk of radiation-induced malignancy. This definition augmented the risk of various tumors, from pinealoblastoma to breast cancer. Although the authors justified their inclusion criteria on the basis of atom-bomb survivor data, the small number of events leading to the increased risk (three cases of breast cancer) and the lack of potentially influential clinical variables leave these results open to debate among radiation oncologists. At face value, these results indicate that all external beam radiation modalities will result in an excess of secondary malignancies, and that the use of any diagnostic X-ray procedure in the clinical assessment of patients with retinoblastoma should cease.

**Patient age at radiation appears to be important** In 1998, Abramson et al.<sup>11</sup> determined that the risk of a second malignancy was smaller for patients older than 12 months than for patients younger than 12 months when they received radiation therapy. The risk of secondary malignancies in patients irradiated when older than 12 months was equal to that in patients who did not receive radiation therapy. Therefore, delaying radiation therapy until the patient is older than 1 year appears to reduce the risk of a second malignancy. This information has played a prominent role in clinical decision-making. Similar

findings were observed by Moll et al.,<sup>12</sup> who reviewed the Dutch Registry of 1945–1997, which included 263 patients with heritable retinoblastoma. In that series the cumulative incidence of second malignancy at age 25 was 22% in patients who were younger than 12 months at the time of irradiation, and only 3% in those irradiated after age 12 months. The infield tumor induction rate was 11% in the younger patients and 3% in the older ones, but this difference was not statistically significant. The ‘infield’ evaluation is meant to specify the location of the event within the irradiated volume determined by detailed review of radiation portals or two- or three-dimensional dosimetry. The authors concluded that the similarity of the infield failure rates suggested that factors other than radiation therapy are involved in the induction of malignancy in younger patients, and that the estimation of the risk of second malignancy depends on how the second malignancy is defined, how carefully the irradiated volume is analyzed, and how the statistical analysis treats pineoblastoma. In that study, pineoblastoma was not defined as a secondary malignancy.

### REDUCING SIDE EFFECTS FROM RADIATION THERAPY

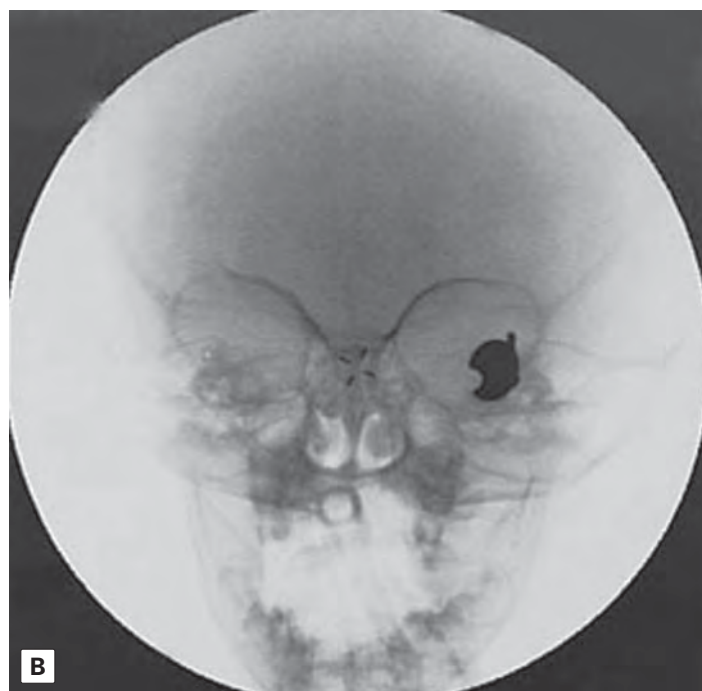
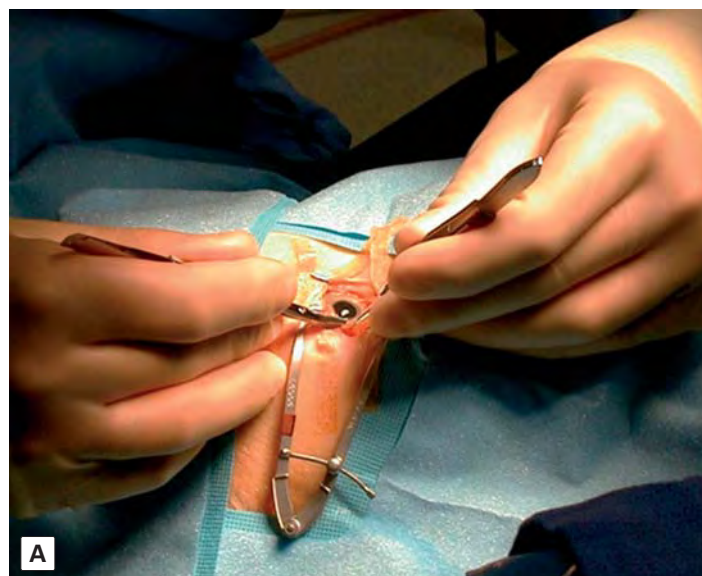
A number of measures may be taken to reduce the likelihood of second malignant neoplasms and radiation-related treatment effects in children with retinoblastoma: (1) delay radiation therapy until the patient is 12 months old; (2) reduce the total dose of radiation; (3) use episcleral plaque brachytherapy; and (4) apply new external beam treatment methods and modalities, including conformal radiation therapy, intensity-modulated radiation therapy, and proton beam radiation therapy (Box 76.1).

**Delay radiation** The fact that delaying radiation until after the age of 12 months reduced the risk of second malignant neoplasms<sup>11</sup> provides hope that teletherapy may still have a major therapeutic role in eyes with advanced disease that have had their tumor load reduced but not eliminated by primary chemotherapy. It is now common practice in some retinoblastoma centers to use systemic chemotherapy in patients with bilateral advanced disease diagnosed before 1 year of age, delaying radiation until after the first birthday.

**Lower the radiation dose** The standard dose for irradiation is 45 Gy. One of the largest studies to show the feasibility of low-dose irradiation included 49 eyes in 38 patients treated with 36 Gy between 1978 and 1998.<sup>13</sup> At a median follow-up of 88 months, rates of tumor control in patients who had undergone low-dose irradiation therapy were equivalent to those attained with higher doses in other series. The estimated 10-year ocular preservation rate was  $82\% \pm 6\%$ . The 5-year ocular preservation rate for patients with Reese–Ellsworth Group I or II tumors was  $95\% \pm 4\%$ , and for patients with Reese–

Ellsworth Group III or IV tumors,  $66\% \pm 11\%$ . Ocular preservation rates after external beam irradiation at various doses indicate that low-dose external beam irradiation may be an option for selected patients. Although the use of low-dose external beam irradiation in a cooperative group trial has been discussed, no such study is currently in progress.

**Use episcleral plaque brachytherapy** Episcleral plaque brachytherapy has the advantages that it is highly focal, allows irradiation of normal tissue to be limited, and has a high rate of lesion control. Its disadvantages include its lack of wide availability or applicability as a treatment technique. Also, there are relatively few eyes with single isolated tumors in which brachytherapy is appropriate. It



**Fig. 76.4** Application of a notched episcleral iodine-125 plaque for brachytherapy (A). The corresponding X-ray image showing the episcleral plaque, abutting the optic nerve (B).

#### BOX 76.1 Measures to Reduce Radiation-related Treatment Effects in Children with Retinoblastoma

- Delay radiation therapy until the patient is 12 months old
- Reduce the total dose of radiation
- Use episcleral plaque brachytherapy (if applicable)
- Consider new external beam treatment methods, including conformal radiation therapy, intensity-modulated radiation therapy, and proton beam radiation therapy

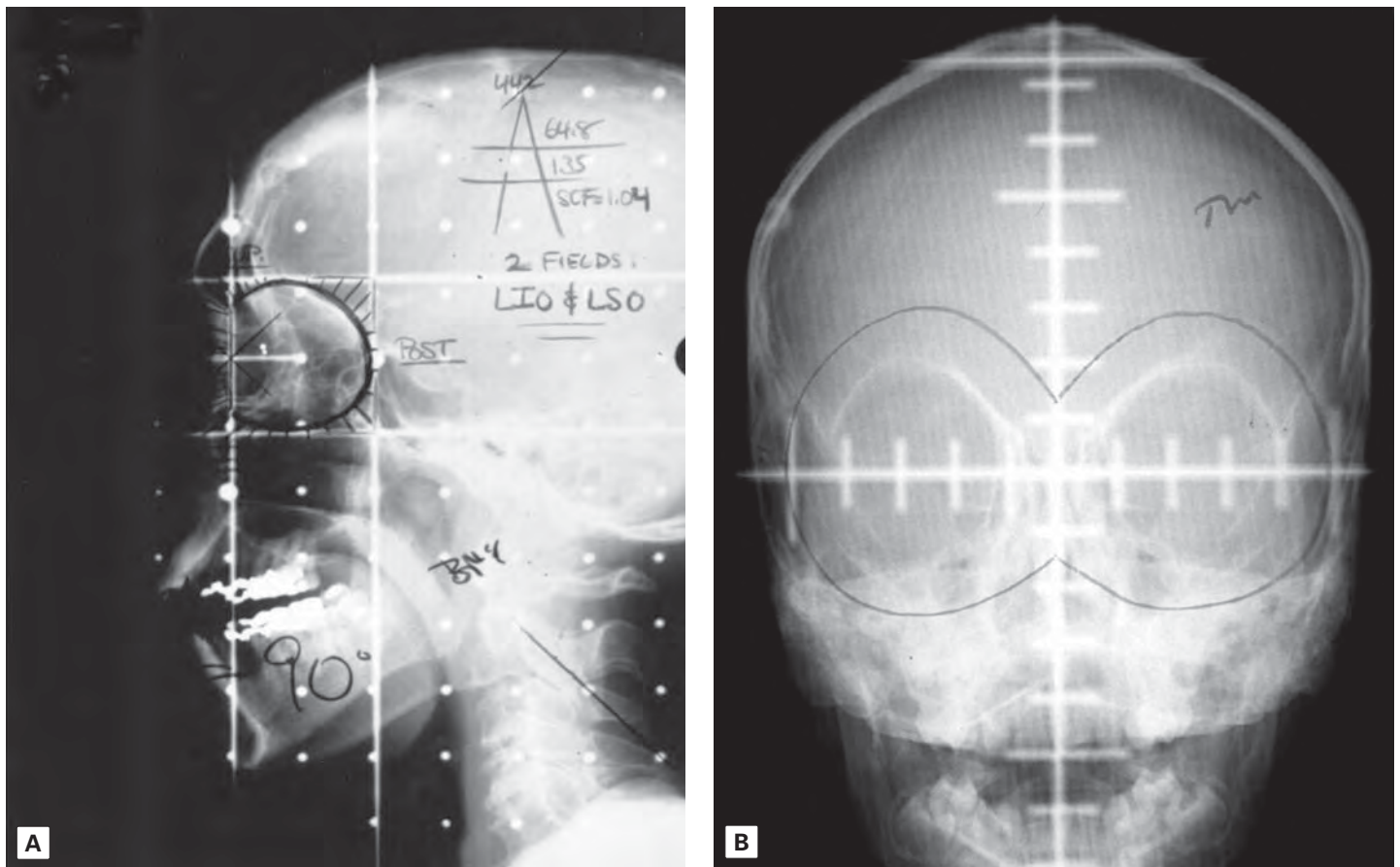
requires extensive operator experience and in some instances produces significant adverse effects in the retina (Fig. 76.4). A standard dose is 40 Gy to the apex at 40–50 cGy/hour and may require inpatient admission. Common sources include iodine-125, but other sources have been investigated. In the largest reported series from Philadelphia, tumor control rates in excess of 86% were achieved in 102 cases.<sup>14</sup> The St Jude series included a relatively small number of cases and a lesion control rate of 96%.<sup>15</sup> Response to episcleral plaque brachytherapy is seen rapidly and in some cases during the brief course of application.

**Use new radiation treatment techniques** A discussion of all the radiation techniques and of all the measures taken to spare the lens and minimize irradiation of normal tissue is beyond the scope of this chapter. Indeed, given that a substantial number of patients are diagnosed with vitreous seeding (Reese–Ellsworth Vb) and require whole eye irradiation after chemotherapy, it may be less important to reduce the total dose of radiation, spare the lens, or use a more focal radiation delivery technique.<sup>16,17</sup> Nevertheless, the more commonly used new techniques are discussed below.

**Conformal and intensity-modulated radiation therapy (IMRT)** Most clinicians are familiar with the D-shaped fields used to treat unilateral or bilateral disease, with the isocenter placed 2–3 mm

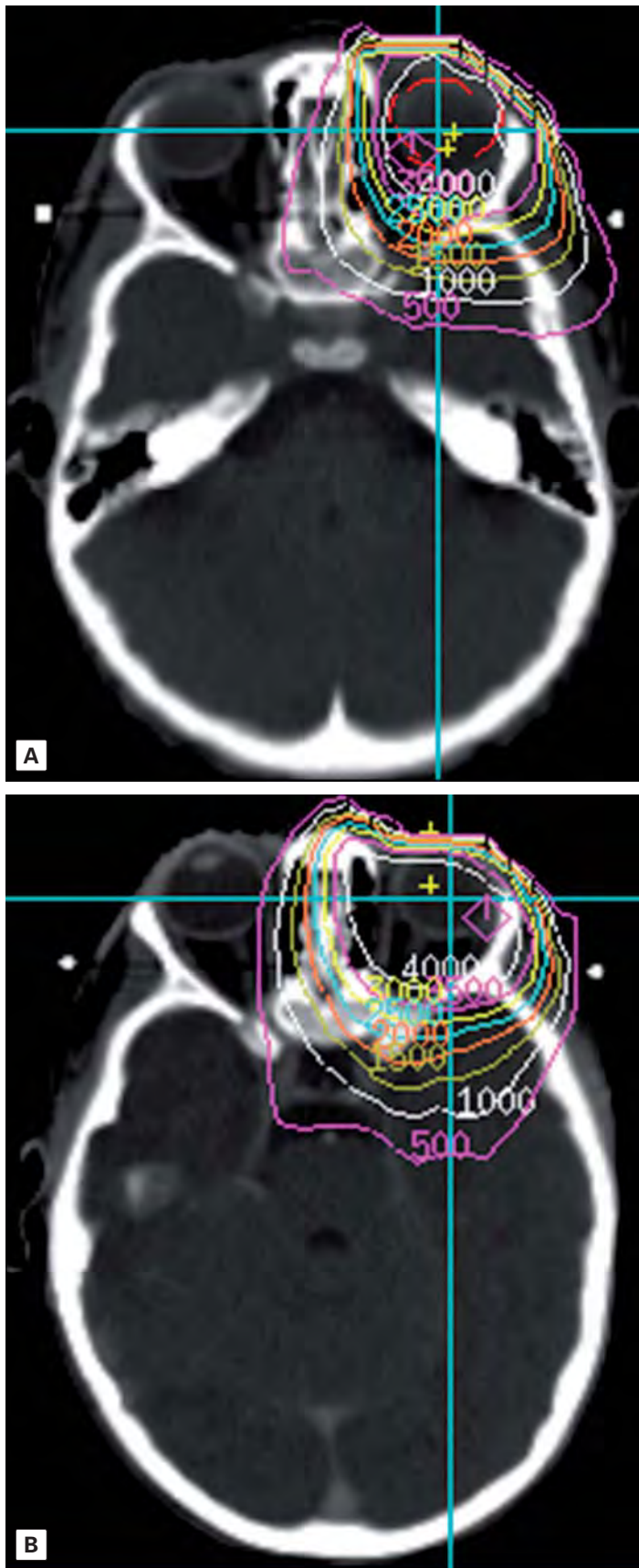
behind the lens at the level of the surgical limbus (Fig. 76.5A). Less familiar are the unilateral or bilateral electron fields used for en face treatment (Fig. 76.5B). With the advent of three-dimensional radiation therapy, a variety of methods have been used to treat retinoblastoma, including intensity-modulated radiation therapy (IMRT). Various methods may be compared on a dosimetry basis by comparing dose–volume histograms for normal tissue, assuming adequate coverage of the targeted volume. Although each method may be used to achieve conformity (i.e. shaping the radiation field so that the highest doses are focused centrally on the targeted volume), each method has different characteristics in terms of normal tissue irradiation (Fig. 76.6). A recent report by Krasin et al.<sup>18</sup> demonstrated the advantages of IMRT over three-dimensional conformal radiation therapy and conventional two-dimensional irradiation in terms of the dose delivered to normal tissue structures (Fig. 76.7). Although for most techniques increasing the conformity of the highest doses results in a relatively sharp decline in the dose–volume curve at the higher doses, this gain comes at the expense of increasing the volume of normal tissue that receives the lowest doses. Consider the dose to the bony orbit, a common site of secondary malignancies: even optimally applied IMRT will result in 50% of the orbit receiving 50% of the prescribed dose.

**Proton beam radiation therapy** Although proton beam radiation therapy has been available for decades, only recently have protons

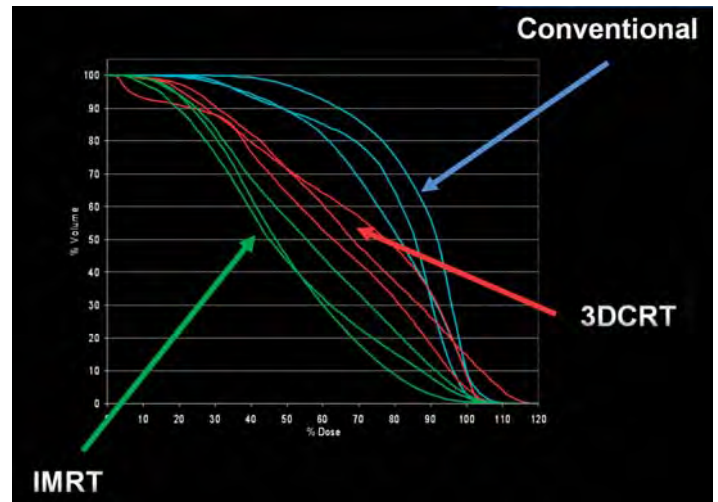


**Fig. 76.5** The D-shaped field used in photon beam radiation therapy (A). An en face bilateral electron field (B).

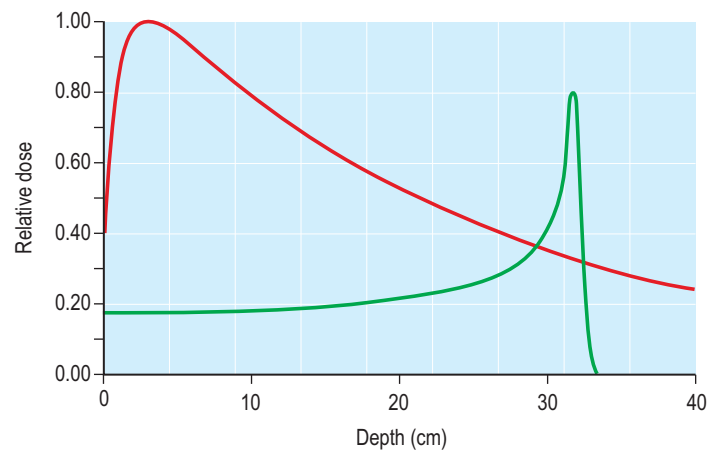




**Fig. 76.6** Comparison of electron (A) and photon (B) dosimetry on axial CT images. Decreasing radiation doses are indicated by the curves delimiting the volumes surrounding the target volume.

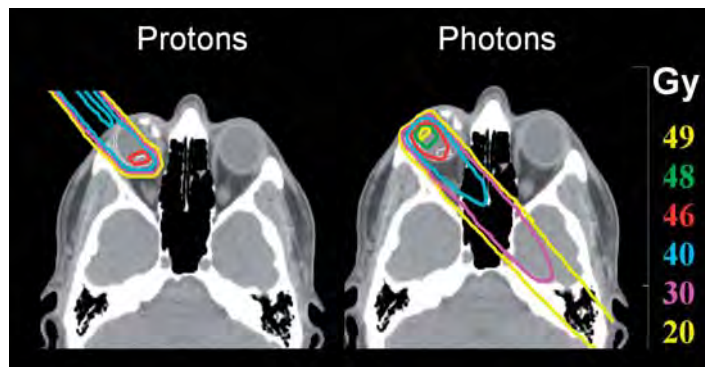


**Fig. 76.7** Relationship between irradiated volume and dose of radiation to the orbit to compare the dosimetric characteristics of conventional, conformal (3DCRT), and intensity-modulated radiation therapy.



**Fig. 76.8** The relationship between dose and depth of penetration of the beam for protons (green curve) and photons (red curve). The sharpness of the Bragg peak for the proton beam illustrates the potential tissue-sparing capacity of the proton beam.

shown promise as external beams that can deliver a precise dose to the target yet minimize the dose to normal tissues. A proton beam has exquisite stopping power in tissue and produces essentially no lateral scatter, whereas photon beams traversing the tissue slowly lose energy and deposit decreasing doses of radiation along the path through the tissue (Fig. 76.8). Where the photon beam enters the tissue it deposits most of its dose superficially, then continues to deposit dose gradually until it exits the patient. The proton beam, with its sharp Bragg peak (Fig. 76.8), can penetrate deeply and deposit all of its dose in the targeted volume, leaving no exit trail. The proton beam can be modulated to achieve a more widely spread Bragg peak and used to irradiate the tumor or target uniformly at a particular depth. Comparing photons or X-rays with protons, it is easy to see that proton beam irradiation can be used to control tumors at any depth without the entrance and exit doses associated with photon beam irradiation that are largely responsible for the complications we see in patients given radiation therapy for retinoblastoma.



**Fig. 76.9** Comparison of single-beam proton and photon irradiation. (Courtesy of EB Hug, MD.)

The advantages of protons over photons in reducing doses to normal tissue (lens, lacrimal gland, bony orbit, and soft tissues) have been demonstrated during irradiation of tumors in various sites in the retina (Fig. 76.9).<sup>19</sup> One study showed that for tumors located in the nasal retina, central retina, or temporal retina, irradiation of normal tissue can be avoided by using beam positioning and eye positioning techniques. This finding opens up the possibility of selective retinal irradiation by using an external beam. Enhancements that allow fine-beam (pencil-beam) scanning and new methods of achieving

stereotaxy (including image guidance and robotics) will enable very precise proton beam treatment of the retina in patients with retinoblastoma. Given plans to increase the availability of proton beam radiation therapy in the United States, the relatively small number of cases (based on current trends) that will require radiation therapy, and the obvious dosimetric advantages in these high-risk patients, proton beam radiation therapy will become the standard modality for external beam irradiation of retinoblastoma.

## CURRENT RECOMMENDATIONS

Our recommendations for patients with newly diagnosed retinoblastoma include 36 Gy for Reese–Ellsworth Group I or II disease and standard dose irradiation (45 Gy) for more advanced (Reese–Ellsworth Group III–V) disease. For patients whose disease progresses after chemotherapy, our bias is to irradiate with standard doses (outside a protocol) and to use episcleral plaque brachytherapy when possible. We recommend defining the clinical target volume as the optic globe and the treatment planning target volume as the optic globe with a 3–5 mm margin. Lens sparing can be accomplished on an individual basis when no evidence of vitreous or subretinal seeding is apparent. Additional individualized techniques include using a conventional split beam to spare the lens and using electrons, conformal irradiation, IMRT, and, soon to be widely available, proton beam radiation therapy.

## REFERENCES

- Wilson MW, Rodriguez-Galindo C, Haik BG et al. Multiagent chemotherapy as neoadjuvant treatment for multifocal intraocular retinoblastoma. *Ophthalmology* 2001; 108: 2106–2114; discussion 2114–2115.
- Blach LE, McCormick B, Abramson DH. External beam radiation therapy and retinoblastoma: long-term results in the comparison of two techniques. *Int J Radiat Oncol Biol Phys* 1996; 35: 45–51.
- Abramson DH, Beaverson KL, Chang ST et al. Outcome following initial external beam radiotherapy in patients with Reese–Ellsworth group Vb retinoblastoma. *Arch Ophthalmol* 2004; 122: 1316–1323.
- Egbert PR, Donaldson SS, Moazed K, Rosenthal AR. Visual results and ocular complications following radiotherapy for retinoblastoma. *Arch Ophthalmol* 1978; 96: 1826–1830.
- Hall LS, Ceisler E, Abramson DH. Visual outcomes in children with bilateral retinoblastoma. *J AAPOS* 1999; 3: 138–142.
- Brinkert AW, Moll AC, Jager MJ et al. Distribution of tumors in the retina in hereditary retinoblastoma patients. *Ophthalm Genet* 1998; 19: 63–67.
- Wong FL, Boice JD Jr, Abramson DH et al. Cancer incidence after retinoblastoma. Radiation dose and sarcoma risk. *JAMA* 1997; 278: 1262–1267.
- Moll AC, Imhof SM, Bouter LM, Tan KE. Second primary tumors in patients with retinoblastoma. A review of the literature. *Ophthalm Genet* 1997; 18: 27–34.
- Moll AC, Imhof SM, Bouter LM et al. Second primary tumors in patients with hereditary retinoblastoma: a register-based follow-up study, 1945–1994. *Int J Cancer* 1996; 67: 515–519.
- Kleinerman RA, Tucker MA, Tarone RE et al. Risk of new cancers after radiotherapy in long-term survivors of retinoblastoma: an extended follow-up. *J Clin Oncol* 2005; 23: 2272–2279.
- Abramson DH, Frank CM. Second nonocular tumors in survivors of bilateral retinoblastoma: a possible age effect on radiation-related risk. *Ophthalmology* 1998; 105: 573–579; discussion 579–580.
- Moll AC, Imhof SM, Schouten-Van Meeteren AY et al. Second primary tumors in hereditary retinoblastoma: a register-based study, 1945–1997: is there an age effect on radiation-related risk? *Ophthalmology* 2001; 108: 1109–1114.
- Merchant TE, Gould CJ, Hilton NE et al. Ocular preservation after 36 Gy external beam radiation therapy for retinoblastoma. *J Pediatr Hematol Oncol* 2002; 24: 246–249.
- Shields CL, Shields JA, Cater J et al. Plaque radiotherapy for retinoblastoma: long-term tumor control and treatment complications in 208 tumors. *Ophthalmology* 2001; 108: 2116–2121.
- Merchant TE, Gould CJ, Wilson MW et al. Episcleral plaque brachytherapy for retinoblastoma. *Pediatr Blood Cancer* 2004; 43: 134–139.
- Blach LE, McCormick B, Abramson DH, Ellsworth RM. Trilateral retinoblastoma – incidence and outcome: a decade of experience. *Int J Radiat Oncol Biol Phys* 1994; 29: 729–733.
- Rodriguez-Galindo C, Wilson MW, Haik BG et al. Treatment of intraocular retinoblastoma with vincristine and carboplatin. *J Clin Oncol* 2003; 21: 2019–2025.
- Krasin MJ, Crawford BT, Zhu Y et al. Intensity-modulated radiation therapy for children with intraocular retinoblastoma: potential sparing of the bony orbit. *Clin Oncol (Roy Coll Radiol)* 2004; 16: 215–222.
- Krengli M, Hug EB, Adams JA et al. Proton radiation therapy for retinoblastoma: comparison of various intraocular tumor locations and beam arrangements. *Int J Radiat Oncol Biol Phys* 2005; 61: 583–593.

# Histopathologic features and prognostic factors

Patricia Chévez-Barrios, Ralph C. Eagle and Eduardo F. Marback

## INTRODUCTION

Retinoblastoma is a tumor that arises from the neuroblastic cells that comprise the nuclear layers of the retina.<sup>1-4</sup> Grossly, the tumor is classified by its pattern of growth into endophytic, exophytic, mixed, diffuse infiltrative, and necrotic variants.

**Endophytic growth pattern** Endophytic tumors grow from the retina into the vitreous cavity and disperse small pieces of tumor into the vitreous called vitreous seeds (Fig. 77.1A).

**Exophytic growth pattern** The exophytic tumor grows towards the choroid into the subretinal space, detaching the retina and forming subretinal tumor seeds, which are prone to choroidal invasion (Fig. 77.1B).

**Mixed growth pattern** The mixed growth pattern is the most common and displays both endophytic and exophytic patterns (Fig. 77.1C).

**Diffuse infiltrative pattern** Another growth pattern of clinical importance is the diffuse infiltrative type, which typically presents in older children. Diffuse tumors infiltrate the retina without forming an obvious retinal mass, and often invade the anterior segment forming a pseudohypopyon of tumor cells. This pattern has prognostic importance because it can be mistaken clinically for an inflammatory process.<sup>2</sup> Often the diagnosis is made by cytologic assessment of the anterior chamber material or a vitrectomy specimen.<sup>1-3</sup>

**Necrotic retinoblastoma** Finally, an extensively necrotic retinoblastoma can present clinically as an inflammatory process that mimics orbital cellulitis with chemosis and proptosis.<sup>1,5,6</sup> Histopathologically, such cases show total tumor necrosis associated with intraocular tissue necrosis. This type carries an increased incidence of poor prognostic factors for metastasis (see below).

## HISTOPATHOLOGIC FEATURES

The characteristic histopathologic findings in retinoblastoma include a tumor that replaces the retina with medium-sized cells that have a high nuclear:cytoplasmic ratio, marked apoptotic and mitotic activity, and foci of necrosis with calcification (Fig. 77.2A, B). The areas of necrosis typically surround vessels that are cuffed by a layer of viable cells measuring 90–100 μm in radius (Fig. 77.2C). The active turnover of the tumor often releases DNA from the cells, which forms basophilic

deposits around vessels and on basement membranes. Most of the tumor grows as sheets or large foci of undifferentiated cells (Fig. 77.3A);<sup>1-4</sup> however, sometimes there are areas of tumor differentiation evident as rosettes and fleurettes. The most differentiated tumors exhibit actual photoreceptor differentiation that is evident as bouquet-like aggregates of cells called fleurettes, which lack mitoses or necrosis (Fig. 77.3B). A tumor composed solely of fleurettes is designated a retinocytoma or retinoma – the benign counterpart of retinoblastoma (See Chapter 80).<sup>1-3</sup> Rosettes represent varying degrees of retinal differentiation. Flexner–Wintersteiner rosettes comprise a ring of nuclei surrounding an empty lumen analogous to the subretinal space. The cells are joined by intercellular attachments similar to those found between photoreceptors (Fig. 77.3C). Primitive Homer Wright rosettes are formed by a rim of nuclei with a center filled by tangles of cytoplasmic filaments (Fig. 77.3D). These rosettes also occur in neuroblastomas and other tumors. Both types may contain mitotic figures.

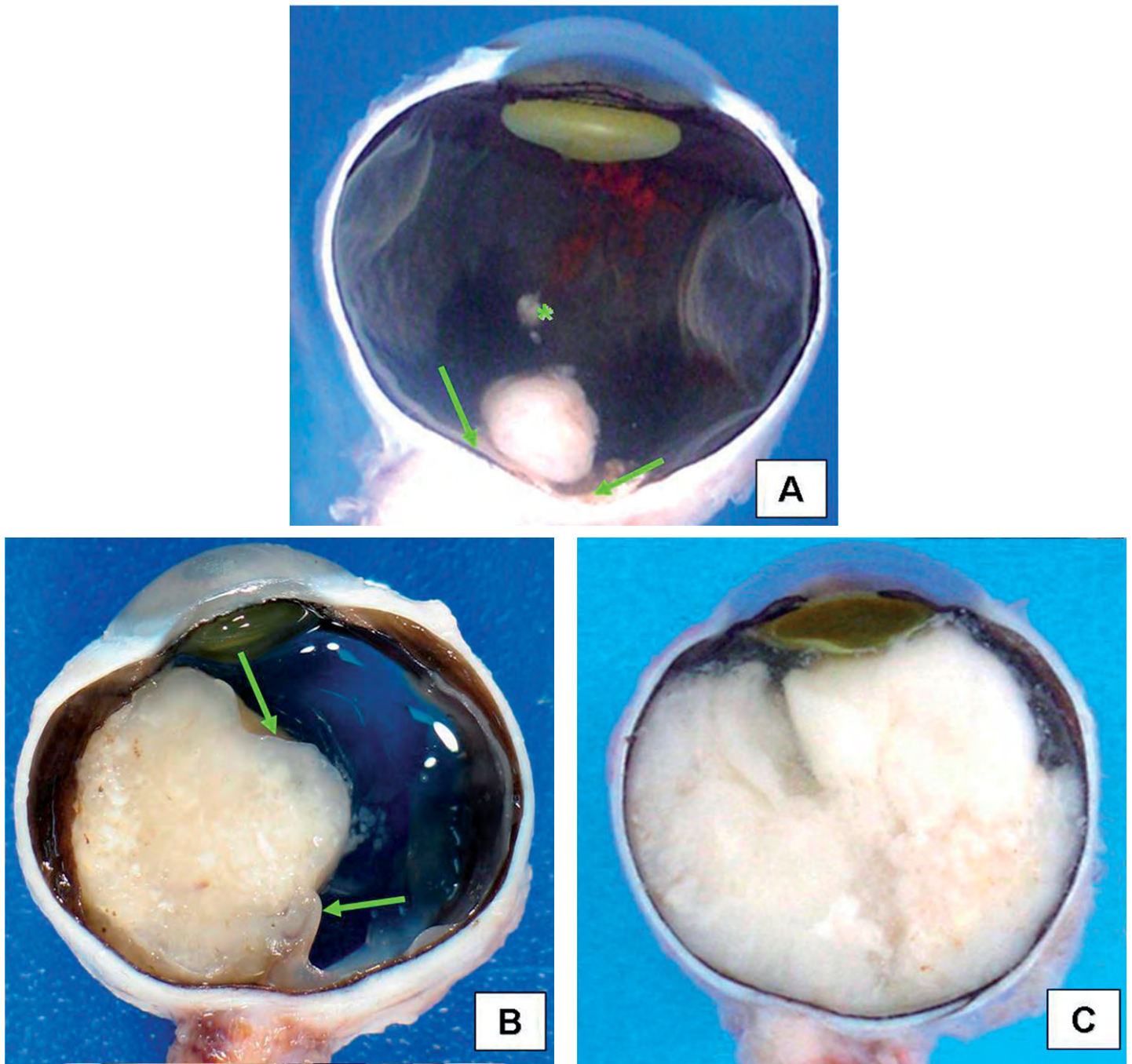
## ROUTES OF SPREAD OUTSIDE THE EYE

If left untreated, retinoblastoma usually fills the eye and completely destroys the internal architecture of the globe. The tumor tends to spread locally by invading the optic nerve and choroid; then hematogenously, and by lymphatics once it reaches the extraocular structures such as conjunctiva and eyelids.

**Optic nerve invasion** The most common route of spread is by invasion through the optic nerve (Fig. 77.4). Once in the nerve, tumor spreads directly along it towards the optic chiasm, or infiltrates through the pia into the subarachnoid space. After reaching the subarachnoid space, retinoblastoma cells may disperse in the cerebrospinal fluid (CSF), and then invade the brain and the spine. Retinoblastoma cells in the subarachnoid space may reach the optic nerve of the opposite eye through the chiasm, and this can occur without detectable presence of tumor cells at the surgical margin of the optic nerve.<sup>2,3,7-11</sup>

**Choroidal invasion** The second major route of spread involves massive involvement of the choroid (Fig. 77.5), followed by extension into the orbit via either scleral emissarial canals (channels within the sclera where ciliary vessels, nerves, and vortex veins enter or exit the eye), or by direct invasion through the sclera.<sup>1,2,9,11-15</sup> Extraocular extension generally occurs if intraocular tumors are left untreated (Fig. 77.6A). Extraocular extension dramatically increases the chances of hematogenous and lymphatic spread.<sup>2,3</sup>





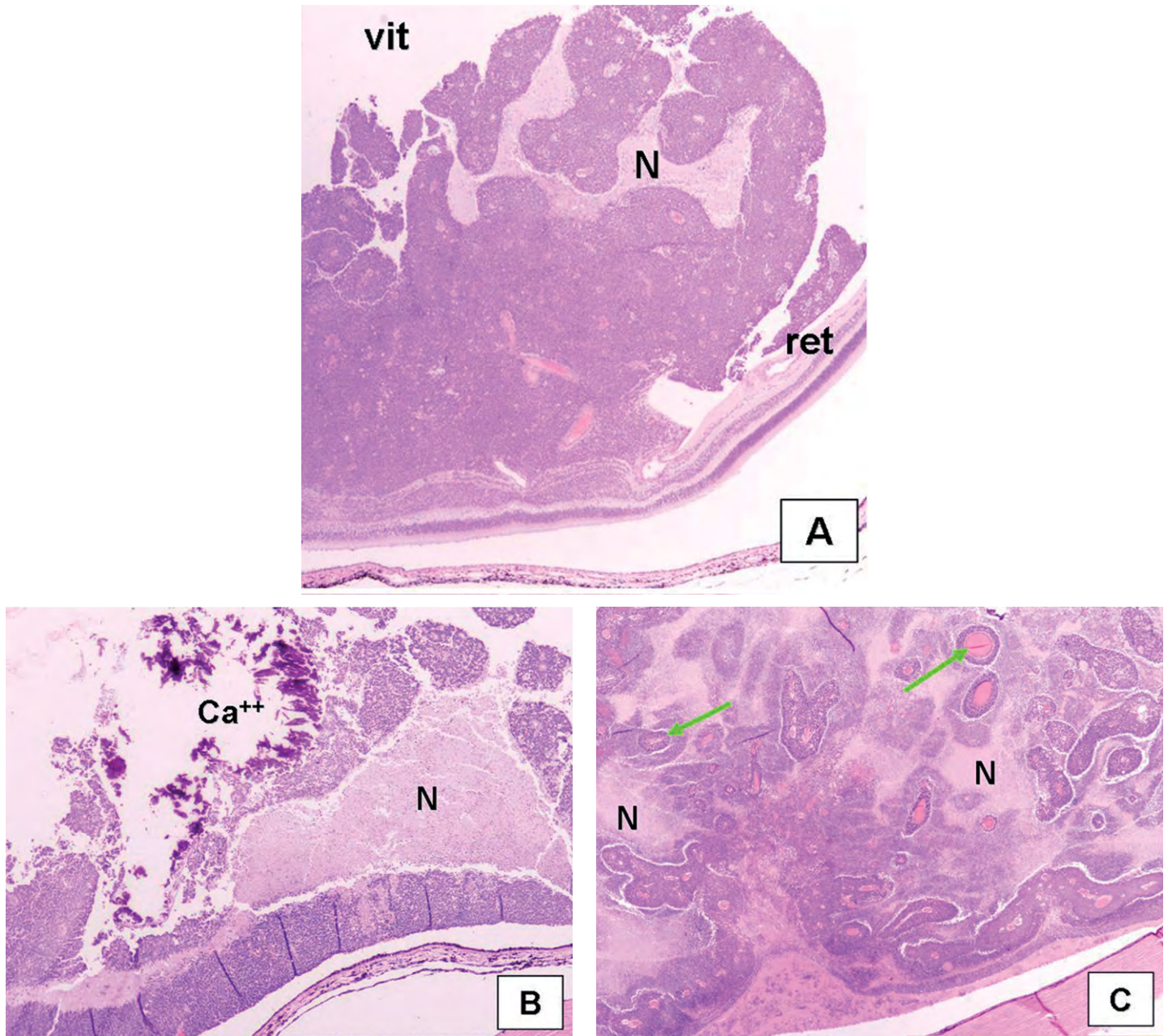
**Fig. 77.1** Patterns of tumor growth. Endophytic growth pattern with tumor arising from retina (arrows) and invading into the vitreous (A). Notice the formation of vitreous seeds (\*), which are small pieces of tumor floating in the vitreous. Exophytic growth pattern with tumor arising from retina (arrows) and invading into the subretinal space (B). Mixed growth pattern is a combination of endophytic and exophytic where the retina is mostly replaced by tumor (C).

**Hematogenous dissemination** Metastatic spread can occur by direct infiltration, either through the optic nerve into the brain or through the choroid into the orbit soft tissues and bones. Hematogenous dissemination may induce metastasis even when other types of invasion have not been found. Widespread metastasis presents most frequently in lung, bone, and brain.<sup>1,2,16</sup>

**Lymphatic dissemination** Metastasis via lymphatic dissemination can occur when tumors spread anteriorly into the conjunctiva and eyelids or extend into extraocular tissues. Lymphatic vessels and

lymphoid tissue are absent in the orbit and intraocular tissues. In the ocular region, only conjunctiva and skin have lymphatic channels. Tumors must first reach these areas to permeate the lymphatic vessels and then spread into regional lymph nodes.<sup>1,2,16</sup>

Histologically, retinoblastoma metastases appear less differentiated than intraocular tumors. Rosettes are rarely encountered and fleurettes have never been described. When a focus of very well-differentiated tumor is found outside the orbit, the differential diagnosis must include primary primitive neuroectodermal tumor (PNET).<sup>1,2</sup>



**Fig. 77.2** Retinoblastoma is composed of small blue cells and arises from the retina (ret); the tumor cell alternates with geographic areas of necrosis (N) and invades the vitreous (vit) (A). (Original magnification  $\times 2$ .) Higher magnification shows necrosis (N) and calcifications ( $\text{Ca}^{++}$ ) (B). (Original magnification  $\times 4$ .) Viable tumor cells form cuffs surrounding the vessels (arrows) and they are surrounded by necrosis (N) (C). (Original magnification  $\times 4$ .)

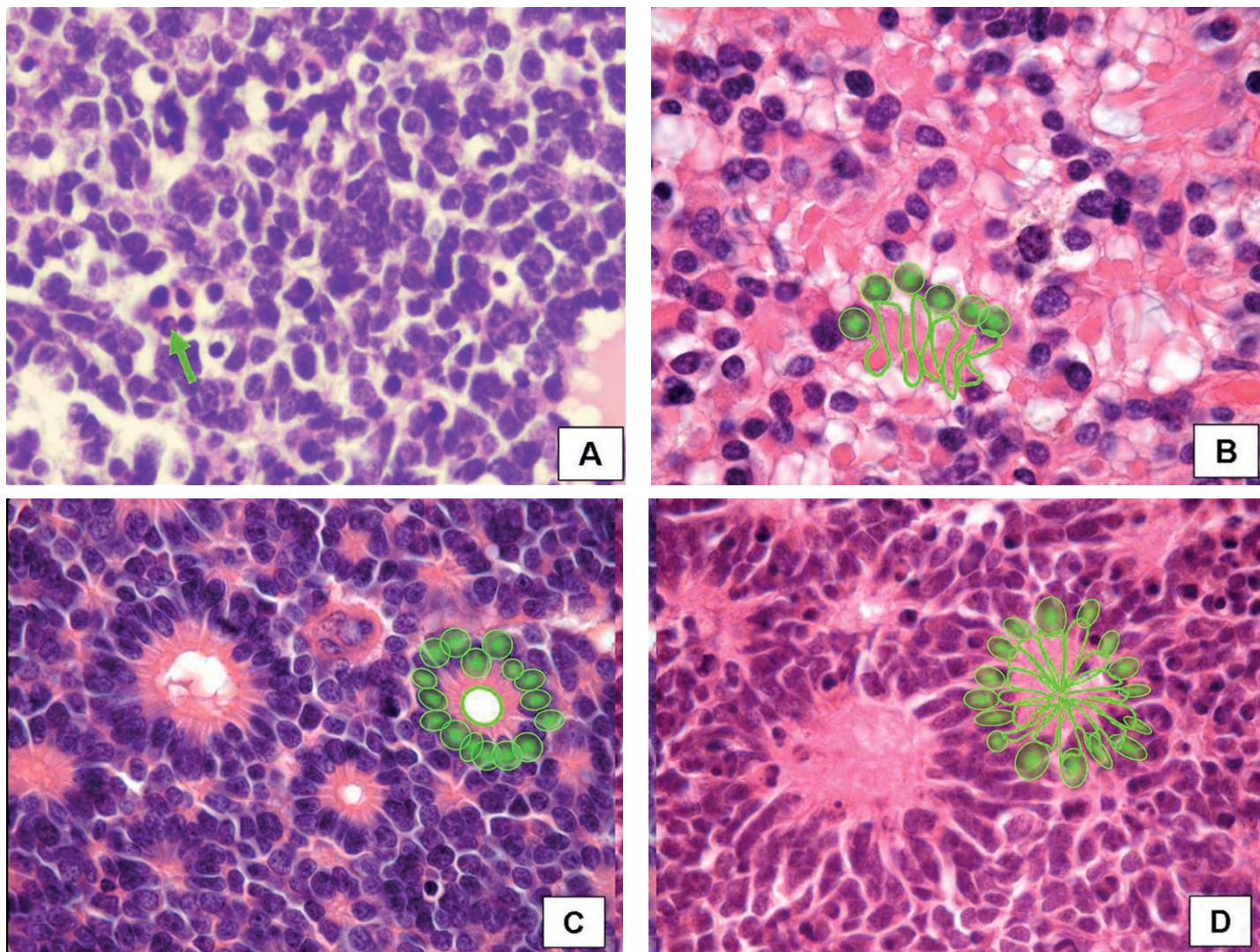
### HISTOPATHOLOGIC FACTORS THAT MAY BE USEFUL IN DETERMINING PROGNOSIS

Metastatic disease is still associated with a poor prognosis.<sup>11–19</sup> Most clinical findings are not useful in predicting the occurrence of metastasis in children with retinoblastoma, although histopathologic data provide a fair estimate of its risk. Multivariate statistical analysis has suggested the correlation of certain histopathologic findings and prognostic risk factors (Table 77.1).<sup>17,19,20</sup> The most important prognostic indicators for the development of metastasis are the presence of tumor in the optic nerve posterior to the lamina cribrosa, tumor at the site of surgical transection, and extrascleral extension of tumor into the orbit (Fig. 77.4).<sup>7–12,20</sup> Other factors associated with probable risk for metastatic behavior, especially in conjunction with the major factors

cited above, are tumor invasion into the anterior chamber (Fig. 77.6B), large tumor size with vitreous seeding, neovascularization of the iris, and glaucoma (Table 77.2).<sup>12–21</sup>

**Tumor invasion into the optic nerve** The extent of tumor invasion in the optic nerve correlates with prognosis. In several published series<sup>7–12,20</sup> superficial invasion of the optic disc was associated with a mortality rate (10%) similar to that seen when the optic nerve is not involved. The presence of tumor up to the lamina cribrosa is associated with a mortality rate of 29% (Fig. 77.4). This rises to 42% when tumor is found posterior to the lamina cribrosa, and the presence of tumor at the transected surgical margin is associated with a mortality of 80%.<sup>7–12,20,21</sup> The importance of obtaining a long segment





**Fig. 77.3** Undifferentiated tumors show sheets of small and medium-sized cells with scanty cytoplasm and hyperchromatic nuclei (A). Apoptosis is frequently seen (arrow). Fleurettes are composed of cells that closely resemble photoreceptors, and are so named because they group in a fashion similar to an arrangement of flowers (B). Flexner–Wintersteiner rosettes are tumor cells forming a round structure with a clear center rimmed by a membrane like the outer limiting membrane in the retina (C). Homer Wright rosettes have a lumen filled by cytoplasmic prolongations of the tumor cells (D). (Original magnification  $\times 40$ .)

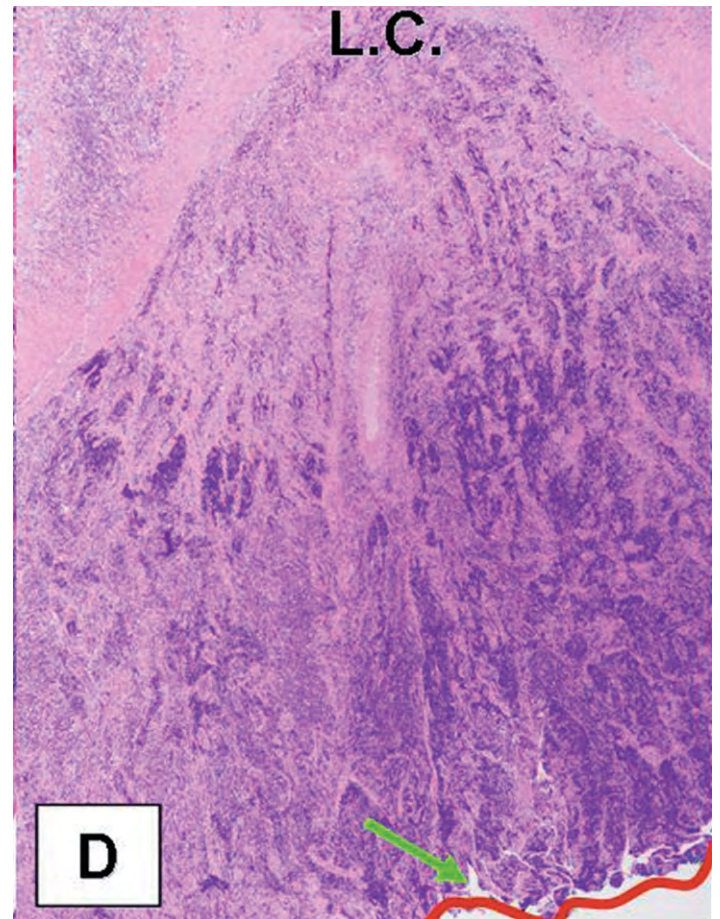
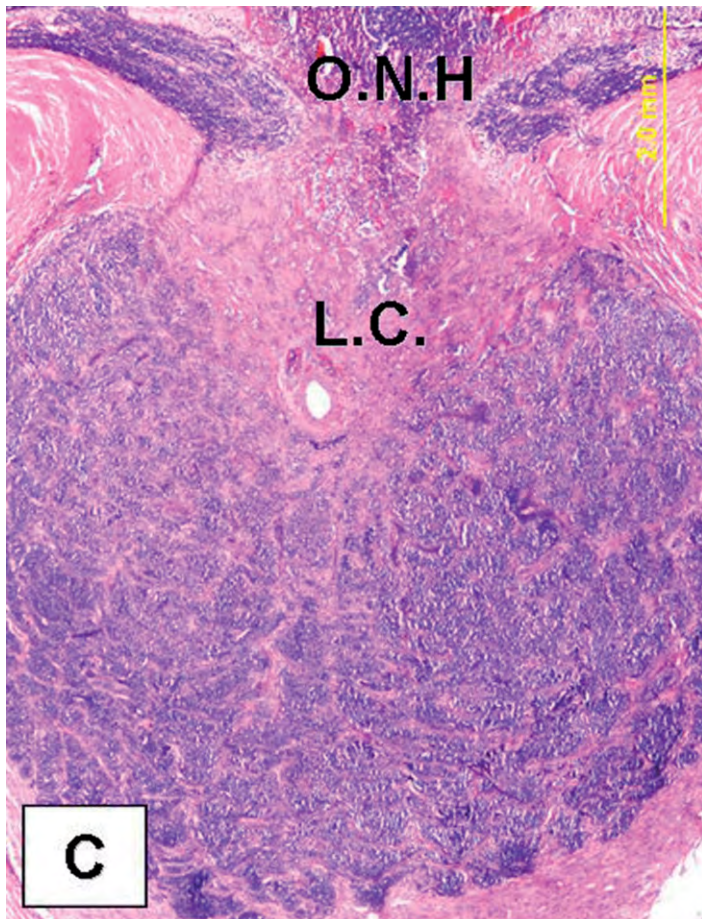
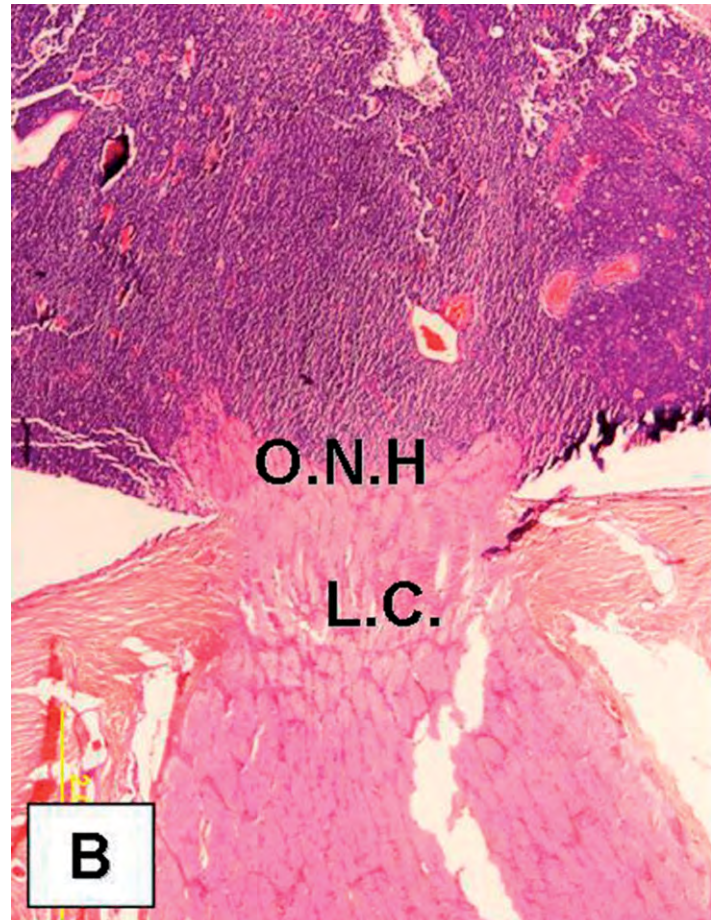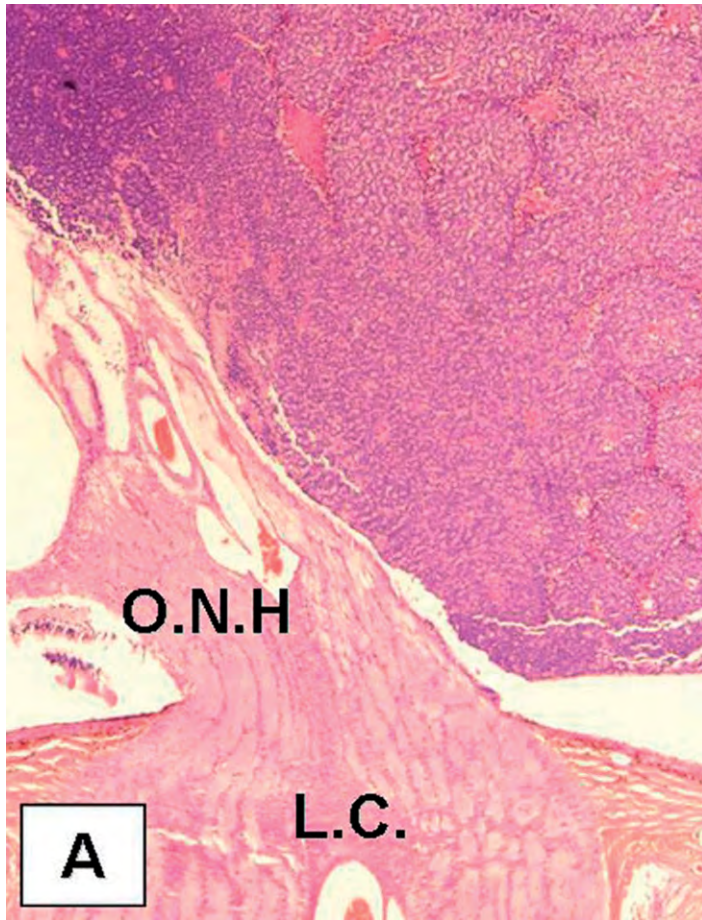
of optic nerve at the time of enucleation is emphasized by these results. Specific studies related to the length of the optic nerve stump alone suggest that patients with an optic nerve stump measuring  $<5$  mm in the enucleated eye have a worse prognosis than those having  $>5$  mm stumps. However, other series found no correlation between the length of the optic nerve stump and metastatic events.<sup>13</sup>

The location of retinoblastoma in the different portions of the optic nerve has been shown to be important: the closer to the brain and the surgical margin the worse the prognosis for metastasis.<sup>7–13</sup> However, the amount of tumor present and the coexistence of choroidal involvement also appear to have a prognostic value. More precise measurement of the invading tumor into the nerve, together with the location, may be needed. Limitations for exact measurement include the plane of section and the number of sections examined. However, results may

become comparable if pathologists adopt a standardized protocol for ocular dissection and tissue submission, sectioning, and examination. Even though the results may not be exact measurements of the actual amount of tumor present, they may be representative of the biological process in each case.

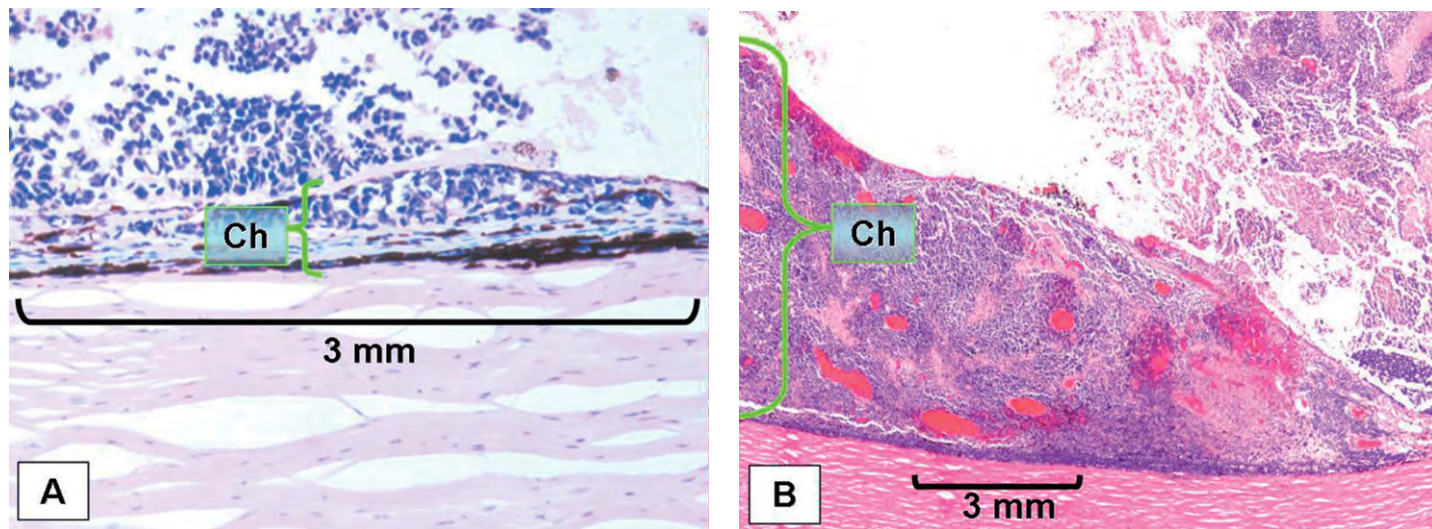
**Tumor invasion into the choroid** Conventionally, tumor invasion of the choroid has been described as massive or focal without commonly agreed definitions of the degree of invasion that constitutes each descriptor. Using this imprecise terminology, however, massive – but not focal – invasion of the choroid by tumor increases the possibility for hematogenous spread, either via the choroidal vessels or, more frequently, by extension through the sclera into the orbital tissues (Fig. 77.6A).<sup>6–12</sup>



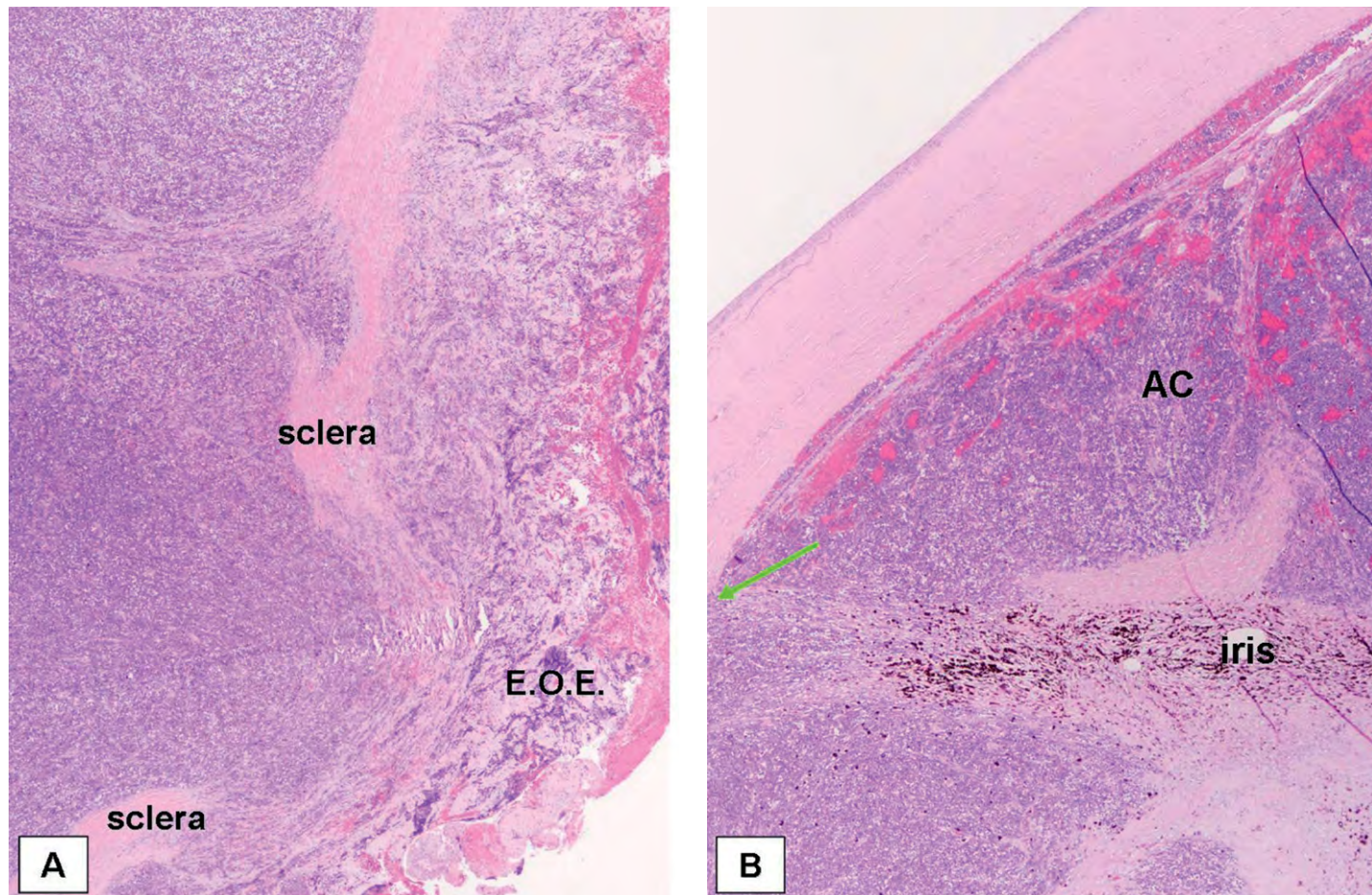




**Fig. 77.4** Retinoblastoma invasion at different levels of the optic nerve. Note that the tumor is filling the vitreous cavity and replacing the retina adjacent to the optic nerve head (ONH) but the entire optic nerve is free of tumor (A). Tumor has infiltrated the optic nerve head but does not reach the lamina cribrosa (LC) (B). Tumor has invaded through the lamina cribrosa into the posterior (orbital portion) of the optic nerve but without reaching the margin of resection (C). Tumor massively invades the optic nerve up to the level of the surgical margin (line and arrow) (D). (Original magnification  $\times 4$ .)



**Fig. 77.5** Retinoblastoma invasion of choroid (Ch). Focal invasion of the choroid by tumor that does not expand more than approximately 3mm in maximum diameter and which is not seen grossly (A). (Original magnification  $\times 10$ .) Massive choroidal invasion is seen grossly and expands beyond 3mm in maximum diameter. Compare the thickness of choroid between focal and massive invasion (B). (Original magnification  $\times 4$ .)



**Fig. 77.6** Extraocular extension of retinoblastoma and anterior segment invasion. Extraocular extension (EOE) of tumor through the sclera into the orbital tissue (A). (Original magnification  $\times 4$ .) Massive involvement of the anterior chamber (AC) by tumor with effacement of iris and invasion of the trabeculum and chamber angle structures (arrow) (B). (Original magnification  $\times 4$ .)



**Table 77.1 Conventional histopathologic poor prognostic factors for metastasis in retinoblastoma**

Risk factor	Extent
Orbital invasion	Present
Optic nerve invasion	Retrolaminar invasion At line of transection
Scleral and extrascleral invasion	Present
Choroidal invasion	Massive
Anterior segment involvement	Present

**Table 77.2 Probable histopathologic poor prognostic factors for metastasis in retinoblastoma**

Risk factor	Extent
Extensive necrosis of tumor and intraocular tissues	Present
Tumor angiogenesis	Relative vascular area >3.9%
Large tumor with vitreous seeds	Present
Neovascularization of iris	Present
Glaucoma	Present

The significance of choroidal involvement and its effect on survival outcome remains controversial. In the literature, some degree of choroidal invasion has been reported in 12–62% of eyes enucleated for retinoblastoma.<sup>12,19,22–24</sup> However, the lack of a broadly accepted grading system and the intrinsic subjectivity of the evaluation contribute to further confusion. Some authors divide choroidal invasion into focal and massive, defining focal invasion as Bruch's membrane disruption by no more than three microscopic clusters of tumor cells, and massive as any invasion greater than focal.<sup>12</sup>

Others divide choroidal invasion into *not massive* and *massive*, with *not massive* consisting of involvement of no more than one-quarter of the choroid.<sup>23</sup> Another paper classified choroidal invasion as minor or major, defining minor as the absence of choroidal thickening by the tumor. However, the authors were inclined to ignore this distinction, as they found no statistical difference in prognosis between the two groups.<sup>19</sup> A similar strategy of grading choroidal invasion as merely present or absent has been used in many other publications, gathering together a very heterogeneous group of tumors and results.<sup>13,16,17,24</sup> Some studies found that choroidal invasion is an isolated risk factor for disease, with widely ranging mortality rates from 11% to 81%.<sup>12,19,24</sup> Others find that choroidal invasion is linked to a worse prognosis only when associated with optic nerve invasion.<sup>8,9,17</sup>

**Scleral and extrascleral extension** The reported occurrence of scleral infiltration (1–8%),<sup>12,17,19</sup> and extrascleral extension (2–13%),<sup>12,17,19</sup> varies widely, even in series reported from developed countries. It is now generally agreed that infiltration and extrascleral extension are the risk factors that are predictive of metastasis.<sup>12,17,19,25</sup>

The degree of tumor vascularization has been shown to correlate with risk for metastatic disease in other human cancers.<sup>26,27</sup>

**Tumor at surgical margins and in the orbit** The optic nerve is the most important surgical margin for prognosis in eyes with retinoblastoma because the predilection of this tumor to spread primarily through the optic nerve. If the tumor is present at the cut end of the optic nerve, retinoblastoma tumor cells are left in the orbit (Fig. 77.4D). Once the orbital soft tissues are invaded, the tumor spreads directly into the orbital bones, through the sinuses into the nasopharynx, or via the various openings into the cranium. In cases of extraocular extension of tumor before enucleation, the soft tissues of the orbit represent additional surgical margins.<sup>1,2</sup> Currently, most ophthalmic oncologists would administer pre-enucleation chemotherapy if extraocular extension is suspected, in order to decrease the tumor burden and to target the extraocular extension. In these cases, evaluation of orbital soft tissue margins to access the presence of residual tumor is of prognostic importance.

Recurrence of retinoblastoma in the orbital tissues after enucleation is almost always the result of tumor cells that were left untreated in the orbit. This may result from subclinical orbital involvement that escapes histopathologic recognition, but most frequently it is a consequence of incomplete removal of the orbital tumor or invasion of the optic nerve beyond the plane of surgical transection.<sup>1</sup> With extensive orbital involvement and metastatic disease, especially with CNS involvement, the mortality rate ranges from 68% to 100%.<sup>1,2</sup> It is thought that extraocular extension may present approximately 6 months after the initial presentation of symptoms. Extraocular extension dramatically increases the possibilities of hematogenous dissemination and creates tumor access to conjunctival lymphatics, with subsequent lymph node metastasis.<sup>1</sup>

**Anterior segment involvement** There are only few reports dealing with extension of retinoblastoma into the iris, ciliary body, anterior chamber, trabeculum, and cornea (Fig. 77.6B). One of the limiting factors is the frequency of coexistence of large tumors and other histopathologic risk factors that are associated with anterior chamber involvement. There is a need to address these findings objectively (measuring) in the same way that the other factors are recorded and reported to begin obtaining meaningful data. Clinically it has been suggested that iris neovascularization and a high intraocular pressure are predictors of choroidal as well as optic nerve invasion.<sup>10,28</sup>

**Size and tumor characteristics** (growth pattern and degree of differentiation) have received different degrees of importance as prognostic factors in the literature. Some have given these factors heavy weight as prognosticators for metastatic disease, and others dismiss them as unimportant by themselves. Again, the coexistence of other prognostic factors confounds the data. Another important factor is the presence of widespread necrosis of intraocular tissues in combination with extensive necrosis of the tumor (Table 77.2).<sup>5,6,29</sup> In a comparative study of enucleated eyes of children with and without extensive necrosis of tumor and intraocular tissues, those displaying extensive necrosis of tumor and intraocular structures were statistically significantly associated with the presence of high-risk histopathologic features such as tumor invasion into the optic nerve, tumor beyond the lamina cribrosa, and choroidal invasion.<sup>29</sup> In addition, in the same



study, although without reaching statistical significance, two of the children (2/11) with extensive necrosis died of cerebral metastasis despite the absence of extraocular extension of the tumor at enucleation. Only one of the two patients had post-laminar optic nerve invasion without involvement of the cut end; the other had optic head invasion only. Both patients had choroidal invasion on histological examination. In contrast, none of the patients (0/32) without extensive necrosis died of metastatic retinoblastoma, and these children showed less frequently the presence of high-risk histopathologic features.<sup>29</sup>

### LIMITATIONS OF PUBLISHED STUDIES

There are several case series that address different histopathologic features that may predict metastatic behavior.<sup>4–21</sup> Recurring limiting aspects that prohibit definite conclusions from the data in these series include small number of patients, inconsistent treatment regimens, tissue handling, and presence of confounding variables. They do, however, provide clues to the potential strategies that may be explored in the future.

#### Limited patient numbers and inconsistent treatment

The limitations of most reports include small size of the series and the different treatments that each group utilized for the patients with similar histopathologic findings. Retinoblastoma is a rare disease, thus most studies on prognostic factors are small retrospective series. The study patients had been treated at different time points that ranged from a decade to more than 50 years.<sup>4–21</sup> Hence the series are too heterogeneous in number and quality to accurately evaluate representative histopathologic material, pattern of diagnosis and treatment during different decades, and the reliability of follow-up information.

**Tissue handling** Controversies arise over the important issue of tissue handling. For example, how many histologic sections and levels of the enucleated eye are representative for accurate interpretation, and how practical would this number be? Can we trust the histopathologic results obtained from the examination of two or three sections through the thickest portion of the tumor, if it is well known that another plane of section may disclose previously undetected ‘massive’ choroidal involvement or even intrascleral extension in an eye where initial sections show ‘focal’ choroidal invasion or no choroidal involvement at all? But, would it be feasible and practical in routine patient care to section the entire tumor in all enucleated eyes with retinoblastoma? To our knowledge, no study has yet addressed these questions.

**Confounding variables** Adding to the confusion is the fact that choroidal invasion often is present in eyes with advanced intraocular disease, and thus is very commonly associated with other possible risk factors, such as invasion of the optic nerve, sclera, and anterior chamber.

### STRATEGIES FOR THE FUTURE

There are some indirect ways to measure increased metastatic potential.<sup>26,27,30</sup> As our knowledge of tumor behavior and the metastatic process increases, it will become evident that the extent of ocular structure invasion is only one of several possible parameters that are useful in identifying patients at risk for disease dissemination. Murine models of retinoblastoma using human xenografts in the

vitreous that mimic both metastatic and non-metastatic disease<sup>31</sup> have revealed that certain retinoblastoma cell lines have metastatic potential from the beginning, in contrast to other cell lines that invade locally without distant metastasis. These findings suggest that the metastatic potential of some tumors is present in the genetic makeup of the cells.

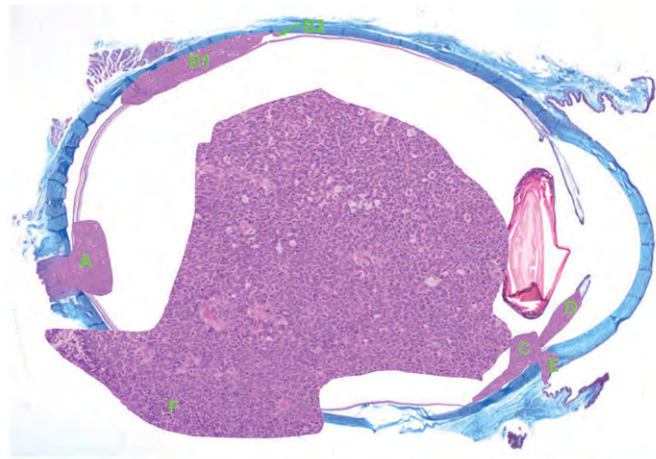
Other parameters should also be addressed, as it is known that for a tumor to metastasize it is not sufficient to have a few tumor cells gain access to the lymphatic or blood circulation. For these cells to implant and proliferate, they must have the capacity to evade the immune system, adhere to a vessel wall, degrade the extracellular matrix, recruit a vascular supply, and adapt to the new environment.<sup>22,30,32–34</sup> Neoplastic tumors undergo a process of natural selection. Those tumors with clones of cells that have achieved the capacities (mutations) required to metastasize have the capacity for disease dissemination.<sup>22,30,32–34</sup>

**Extent of angiogenesis in retinoblastoma tumors** One parameter that has already been tested in retinoblastoma and shown to be a better prognostic factor than invasion of the ocular coats is the tumor’s relative vascular area or angiogenic capacity.<sup>22,31,32</sup> In a pilot study of patients with unilateral retinoblastoma treated solely by enucleation, Marback and colleagues<sup>22</sup> found that a tumor’s relative vascular area  $\geq 3.9\%$  was a better predictor of disease dissemination than either choroidal or optic nerve invasion (see Table 77.2).

#### Applying therapy targeted to cellular pathways in the metastatic process

As tumor biology and its environment are more fully understood, cellular pathways that contribute to the development of metastatic behavior are being defined.<sup>31,32</sup> These features have been studied recently and have potential for manipulating targeted therapies. To support the importance of these factors there are few publications that note patients who have no known histopathologic risk factors for metastasis but who developed metastatic disease. Khelifaoui<sup>12</sup> reported three patients with disease dissemination and no known risk features other than prelaminar optic nerve and focal choroidal invasion; Shields et al.<sup>28</sup> examined 30 microscopic sections from two patients with metastases without any detectable choroidal or optic nerve involvement; Marback<sup>22</sup> and Mackay<sup>16</sup> reported two cases each where orbital and central nervous system spread developed in the absence of choroidal or optic nerve invasion.

**A Cooperative Group Clinical Trial** As a significant response to the challenge of improving the quality of data related to histologic risk factors in retinoblastoma, The Children’s Oncology Group (<https://childrensoncologygroup.org>) has opened a multicenter protocol (ARET0332 A Study of Unilateral Retinoblastoma With and Without Histopathologic High-Risk Features and the Role of Adjuvant Chemotherapy. A Groupwide Phase III Study) where eyes with unilateral retinoblastoma enucleated at participating institutions will be reviewed by three ocular pathologists (two are authors of this chapter) using a standardized methodology (See Chapter 81). The main objectives will be to prospectively determine the incidence of candidate high-risk features such as choroidal involvement, optic nerve invasion, and scleral and anterior segment involvement (Fig. 77.7) in patients with unilateral retinoblastoma who had undergone enucleation, and to treat the patients having well-defined high-risk features with uniform therapy.<sup>35,36</sup>



**Fig. 77.7** Schematic representation of histopathological variables studied in the Children's Oncology Group Trial. Invasion into the optic nerve (**A**); choroid – massive (**B1**) and focal (**B2**); ciliary body (**C**); iris (**D**); trabeculum and anterior segment structures (**E**); and extrascleral extension (**F**).

## REFERENCES

- McLean IW, Burnier M, Zimmerman L, Jakobiec F. Tumors of the retina. In: McLean IW, Burnier MN, Zimmerman LE et al., eds. Atlas of tumor pathology. Tumors of the eye and ocular adnexa. Washington, DC: Armed Forces Institute of Pathology, 1994; s 100–135.
- Hurwitz RL, Chévez-Barrios P, Chintagumpala M, Shields C, Shields J. Retinoblastoma. In: Pizzo PA, Poplack D, eds. Principles and practice of pediatric oncology, 5th edn. Philadelphia: Lippincott-Raven, 2006; 825–846.
- Sang DN, Albert DM. Retinoblastoma: clinical and histopathologic features. *Hum Pathol* 1982; 13: 133–147.
- Augsburger JJ, Oehlschlager U, Manzitti JE. Multinational clinical and pathologic registry of retinoblastoma. Retinoblastoma International Collaborative Study Report 2. *Graefes Arch Clin Exp Ophthalmol* 1995; 233: 469–475.
- Andersen SR, Jensen OA. Retinoblastoma with necrosis of central retinal artery and vein and partial spontaneous regression. *Acta Ophthalmol* 1974; 52: 183–193.
- Mullaney PB, Karciglu ZA, Huaman AM, al-Mesfer S. Retinoblastoma associated orbital cellulitis. *Br J Ophthalmol* 1998; 82: 517–521.
- Spencer WH. Optic nerve extension of intraocular neoplasms. *Am J Ophthalmol* 1975; 80: 465–471.
- Magrann I, Abramson DH, Ellsworth RM. Optic nerve involvement in retinoblastoma. *Ophthalmology* 1989; 96: 217–222.
- Stannard C, Lipper S, Sealy R, Sevel D. Retinoblastoma: correlation of invasion of the optic nerve and choroid with prognosis and metastases. *Br J Ophthalmol* 1979; 63: 560–570.
- Shields CL, Shields JA, Baez K, Cater JR, De Potter P. Optic nerve invasion of retinoblastoma. Metastatic potential and clinical risk factors. *Cancer* 1994; 73: 692–698.
- Rubin CM, Robison LL, Camerson JD et al. Intraocular retinoblastoma Group V: an analysis of prognostic factors. *J Clin Oncol* 1985; 3: 680–685.
- Khelfaoui F, Validire P, Auperin A et al. Histopathologic risk factors in retinoblastoma: a retrospective study of 172 patients treated in a single institution. *Cancer* 1996; 77: 1206–1213.
- Chantada GL, de Davila MT, Fandino A et al. Retinoblastoma with low risk for extraocular relapse. *Ophthalm Genet* 1999; 20: 133–140.
- Erwenne CM, Franco EL. Age and lateness of referral as determinants of extraocular retinoblastoma. *Ophthalmic Paediatr Genet* 1989; 10: 179–184.
- Rootman J, Ellsworth RM, Hofbauer J, Kitchen D. Orbital extension of retinoblastoma: a clinicopathological study. *Can J Ophthalmol* 1978; 13: 72–80.
- MacKay CJ, Abramson DH, Ellsworth RM. Metastatic patterns of retinoblastoma. *Arch Ophthalmol* 1984; 102: 391–396.
- Kopelman JE, McLean IW, Rosenberg SH. Multivariate analysis of risk factors for metastasis in retinoblastoma treated by enucleation. *Ophthalmology* 1987; 94: 371–377.
- de Buen S, Gonzalez-Almaraz G, Cruz-Perez R. [Retinoblastoma. Considerations on its biological behavior]. *Gac Med Mex* 1974; 108: 177–186.
- Messmer EP, Heinrich T, Hopping W et al. Risk factors for metastases in patients with retinoblastoma. *Ophthalmology* 1991; 98: 136–141.
- Karciglu ZA, al-Mesfer SA, Abboud E, Jabak MH, Mullaney PB. Workup for metastatic retinoblastoma. A review of 261 patients. *Ophthalmology* 1997; 104: 307–312.
- Tosi P, Cintonino M, Toti P et al. Histopathological evaluation for the prognosis of retinoblastoma. *Ophthalmic Paediatr Genet* 1989; 10: 173–177.
- Marback EF, Arias VE, Paranhos A Jr et al. Tumour angiogenesis as a prognostic factor for disease dissemination in retinoblastoma. *Br J Ophthalmol* 2003; 87: 1224–1228.
- Uusitalo MS, Van Quill KR, Scott IU et al. Evaluation of chemoprophylaxis in patients with unilateral retinoblastoma with high-risk features on histopathologic examination. *Arch Ophthalmol* 2001; 119: 41–48.
- Redler LD, Ellsworth RM. Prognostic importance of choroidal invasion in retinoblastoma. *Arch Ophthalmol* 1973; 90: 294–296.
- Singh AD, Shields CL, Shields JA. Prognostic factors in retinoblastoma. *J Pediatr Ophthalmol Strabismus* 2000; 37: 134–141.
- Romani AA, Borghetti AF, Del Rio P, Sianesi M, Soliani P. The risk of developing metastatic disease in colorectal cancer is related to CD105-positive vessel count. *J Surg Oncol* 2006; 93: 446–455.
- Stefansson IM, Salvesen HB, Akslen LA. Vascular proliferation is important for clinical progress of endometrial cancer. *Cancer Res* 2006; 66: 3303–3309.
- Shields CL, Shields JA, Baez KA, Cater J, De Potter PV. Choroidal invasion of retinoblastoma: metastatic potential and clinical risk factors. *Br J Ophthalmol* 1993; 77: 544–548.
- Chong EM, Coffee RE, Chintagumpala M et al. Extensively necrotic retinoblastoma is associated with high-risk prognostic factors. *Arch Pathol Lab Med* 2006; (in press).
- Ellis LM, Fidler IJ. Angiogenesis and metastasis. *Eur J Cancer* 1996; 32A: 2451–2460.
- Chevez-Barrios P, Hurwitz MY, Louie K et al. Metastatic and nonmetastatic models of retinoblastoma. *Am J Pathol* 2000; 157: 1405–1412.
- Burnier MN, McLean IW, Zimmerman LE, Rosenberg SH. Retinoblastoma. The relationship of proliferating cells to blood vessels. *Invest Ophthalmol Vis Sci* 1990; 31: 2037–2040.
- O'Byrne KJ, Dalglish AG, Browning MJ, Steward WP, Harris AL. The relationship between angiogenesis and the immune response in carcinogenesis and the progression of malignant disease. *Eur J Cancer* 2000; 36: 151–169.
- Yokota J. Tumor progression and metastasis. *Carcinogenesis* 2000; 21: 497–503.
- Honavar SG, Singh AD, Shields CL et al. Does post-enucleation prophylactic chemotherapy in high risk retinoblastoma prevent metastasis? *Invest Ophthalmol Vis Sci* 2000; 41: S953.
- Mustafa MM, Jamshed A, Khafaga Y et al. Adjuvant chemotherapy with vincristine, doxorubicin, and cyclophosphamide in the treatment of postenucleation high risk retinoblastoma. *J Pediatr Hematol Oncol* 1999; 21: 364–369.

## CONCLUSIONS

Perhaps the question of which child with an enucleated eye containing retinoblastoma is at risk for disease dissemination will be best answered when we begin to understand other indicators of tumor behavior, and when we use these indicators in combination with the traditional prognostic factors (Table 77.1). Animal models, and histopathological and collaborative clinical trials, will certainly facilitate the understanding of these factors and ultimately allow the use of targeted therapies to prevent metastasis and death from retinoblastoma.

# Orbital retinoblastoma

Santosh G. Honavar

## INTRODUCTION

The systemic prognosis of retinoblastoma has dramatically improved in the last few decades due to earlier diagnosis and better management protocols.<sup>1</sup> The 5-year survival rates of 88%, 91%, and 93% have been reported from developed countries such as the United Kingdom,<sup>2</sup> Japan,<sup>3</sup> and the United States, respectively.<sup>1,4</sup> However, the mortality is still high in the developing nations.<sup>5,6</sup> Presentation for medical attention at advanced stages of disease because of compounding social and economic factors is believed to be the main cause for poor survival.<sup>3</sup> One of the major contributors to mortality is orbital retinoblastoma.<sup>7-9</sup> This chapter provides an update on the current concepts in the management of orbital retinoblastoma.

## INCIDENCE

Orbital retinoblastoma is rare in developed countries. Ellsworth<sup>10</sup> observed a steady decline in the incidence of orbital retinoblastoma in his large series of 1160 patients collected over 50 years. The overall incidence was 8.2% in the period 1925–1959 and 7.6% between 1959 and 1974.<sup>10</sup> Later, authors from the same center reported that 6.3% (11 of 175) of patients presented with primary orbital retinoblastoma between 1980 and 1986.<sup>11</sup> The histopathologic evidence of scleral invasion, extrascleral extension, and optic nerve infiltration, although variable, is about 2%.<sup>12</sup>

Orbital retinoblastoma is relatively more common in the developing countries. In a recent large multicenter study from Mexico, 18% of 500 patients presented with an orbital retinoblastoma.<sup>13</sup> A Taiwanese group reported that 36% (42 of 116) of their patients presented with orbital retinoblastoma.<sup>14</sup> The incidence is higher (40%, 19 of 43) in Nepal, with proptosis being the most common clinical manifestation of retinoblastoma.<sup>15</sup>

## CLINICAL MANIFESTATIONS

There are several clinical presentations of orbital retinoblastoma.

**Primary orbital retinoblastoma** refers to a clinically or radiologically detected orbital extension of an intraocular retinoblastoma at the initial presentation, with or without proptosis or a fungating mass (Fig. 78.1). Silent proptosis without significant orbital and periocular inflammation in a patient with manifest intraocular tumor is the characteristic presentation. Proptosis with inflammation generally indicates reactive sterile orbital cellulitis secondary to intraocular tumor necrosis. The other manifestations include a palpable orbital mass or an eyelid swelling. An exuberant fungating orbital mass, a dramatic mani-

festation of orbital retinoblastoma, is rarely seen. Such patients need orbital imaging, preferably with magnetic resonance techniques.

**Secondary orbital retinoblastoma** Orbital recurrence following uncomplicated enucleation for intraocular retinoblastoma is termed secondary orbital retinoblastoma (Fig. 78.2). Orbital recurrence of retinoblastoma may present as an orbital mass several weeks to years after the primary surgery. Unexplained displacement, bulging, or extrusion of a previously well-fitting conformer or prosthesis is an ominous finding suggestive of orbital recurrence. A vascular conjunctival nodule may also be a feature of orbital retinoblastoma.

**Accidental orbital retinoblastoma** Inadvertent perforation, fine needle aspiration biopsy, or intraocular surgery in an eye with unsuspected intraocular retinoblastoma should be considered as accidental orbital retinoblastoma and managed as such (Fig. 78.3).

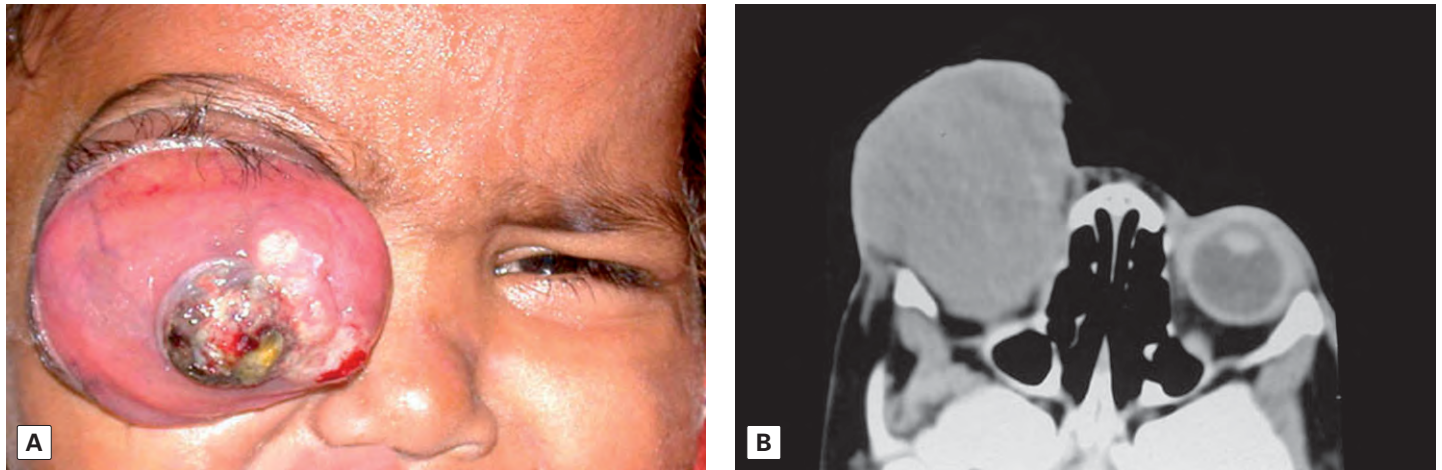
**Overt orbital retinoblastoma** Previously unrecognized extrascleral or optic nerve extension discovered during enucleation qualifies as overt orbital retinoblastoma (Fig. 78.4). A pale pink to cherry-red episcleral nodule, generally in a juxtapapillary location or at the site of vortex veins, may be visualized during enucleation. An enlarged and inelastic optic nerve with or without nodular optic nerve sheath is a clinical indicator of optic nerve extension of retinoblastoma that should be recognized during enucleation.

**Microscopic orbital retinoblastoma** In several instances, orbital extension of retinoblastoma may not be clinically evident and may only be microscopic. Full-thickness scleral infiltration, extrascleral extension, and invasion of the optic nerve on histopathologic evaluation of an eye enucleated for intraocular retinoblastoma are unequivocal features of orbital retinoblastoma (Fig. 78.5). Tumor cells in choroidal and scleral emissaria and optic nerve sheath indicate possible orbital extension, mandating further serial sections and detailed histopathologic analysis.

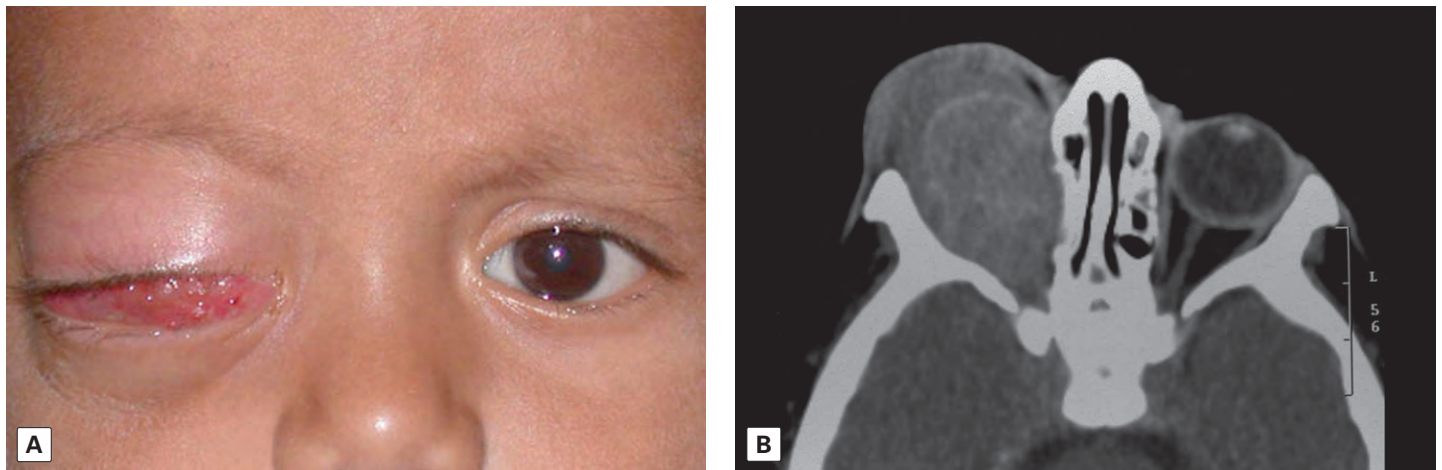
## DIAGNOSTIC EVALUATION

A thorough clinical evaluation paying attention to the subtle signs of orbital retinoblastoma is necessary. Magnetic resonance imaging (preferably) or CT scan of the orbit and brain in axial and coronal orientations with 2-mm slice thickness helps confirm the presence of orbital retinoblastoma and determine its extent. Systemic evaluation, including a detailed physical examination, palpation of the regional





**Fig. 78.1** Primary orbital retinoblastoma. Orbital extension of an intraocular retinoblastoma at the initial clinical presentation, manifesting as massive proptosis (A). CT scan confirmed an orbital mass (B).



**Fig. 78.2** Secondary orbital retinoblastoma. Orbital recurrence of retinoblastoma 6 months after enucleation for intraocular retinoblastoma in the right eye (A). CT scan showing an orbital mass (B).

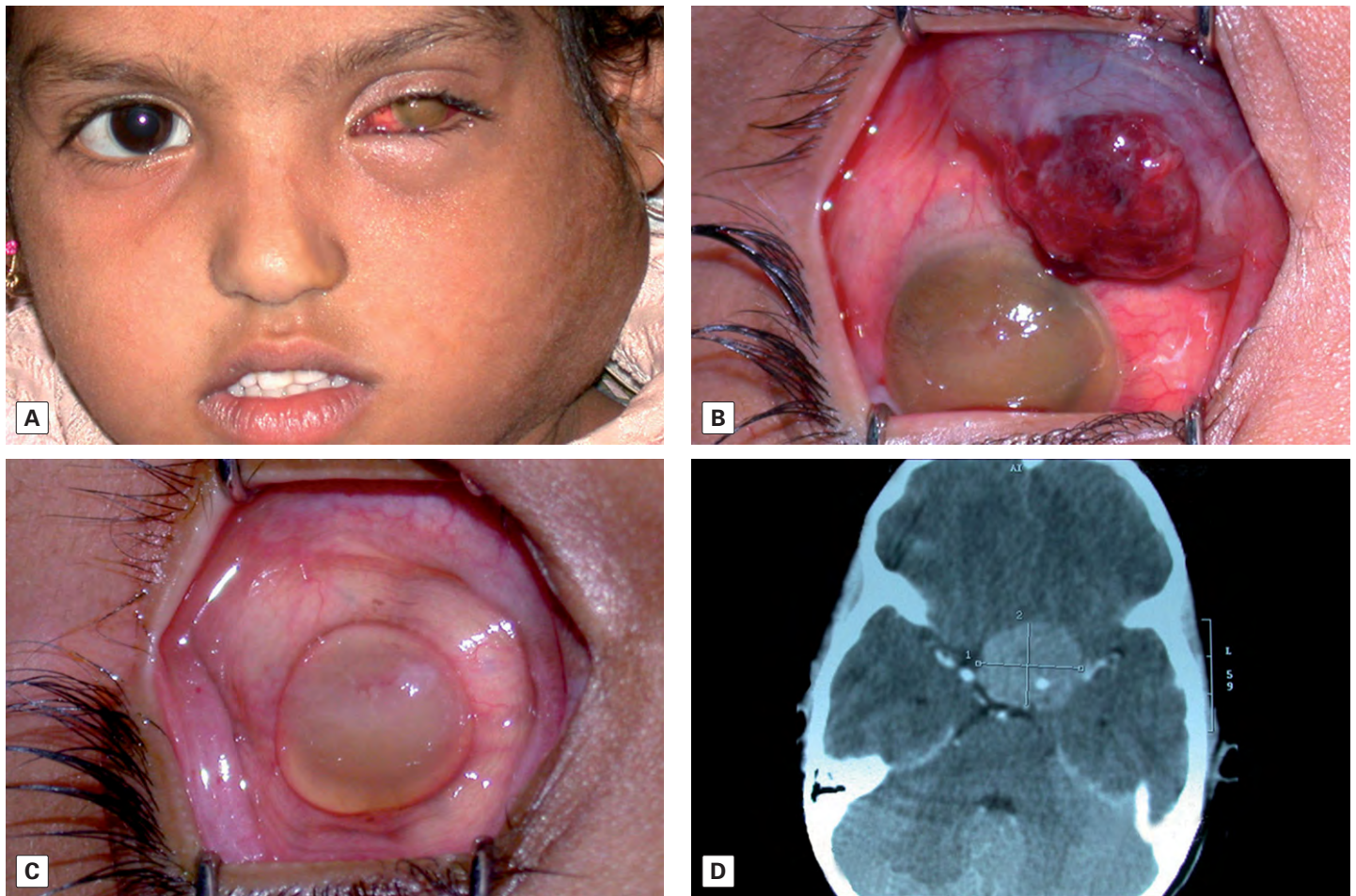
lymph nodes, and fine needle aspiration biopsy if involved, imaging of the orbit and brain, chest X-ray, ultrasonography of the abdomen, bone marrow biopsy, and cerebrospinal fluid cytology are necessary to stage the disease. Technetium-99 bone scan and positron-emission tomography coupled with CT may be useful in the early detection of subclinical systemic metastases.<sup>16,17</sup> Orbital biopsy is rarely required, and should be considered specifically when a child presents with an orbital mass following enucleation or evisceration where the primary histopathology is unavailable.

## MANAGEMENT

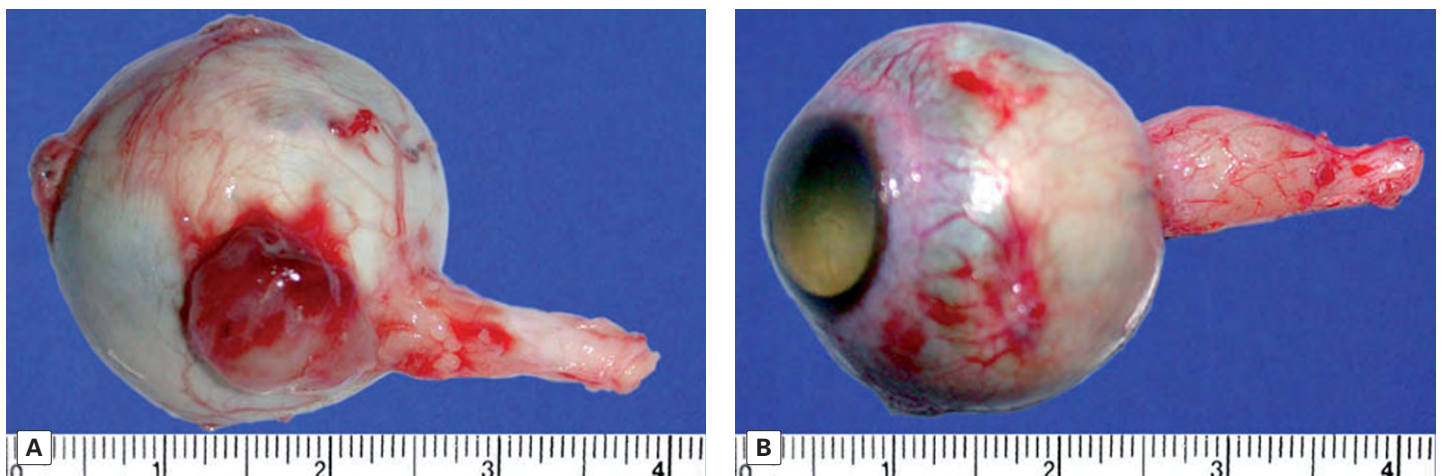
**Primary orbital retinoblastoma** has been managed in the past with orbital exenteration, chemotherapy, or external beam radiotherapy in isolation or in sequential combination with variable results.<sup>18–23</sup> It is well known that local treatments have a limited effect on the course of this advanced disease. Orbital exenteration alone is unlikely to achieve complete surgical clearance and preclude secondary relapses; external beam radiotherapy does not generally prevent systemic metastasis; and chemotherapy alone may not eradicate residual orbital disease.<sup>21,22</sup> Therefore, a combination therapy is considered to be more effective. In a case series of five children, Goble and associates<sup>21</sup> dem-

onstrated long-term survival with local surgical excision, orbital radiotherapy, and systemic chemotherapy. We have developed a treatment protocol (Table 78.1) comprising of initial triple-drug (vincristine, etoposide, carboplatin) high-dose chemotherapy (three to six cycles) followed by surgery (enucleation, extended enucleation or orbital exenteration as appropriate), orbital radiotherapy, and an additional 12-cycle standard dose chemotherapy (Table 78.2).<sup>24</sup> There was concern about the long-term carcinogenic effects of high-dose etoposide as it is known to cause leukemia. Considering that these patients had an otherwise extremely poor prognosis for survival, such risks may be acceptable in selected cases.

In six carefully selected cases without intracranial extension or systemic metastasis, there was dramatic resolution of orbital involvement. All the involved eyes became phthisical after three cycles of high-dose chemotherapy. No clinically apparent orbital tumor was found during enucleation. All patients completed the treatment protocol of orbital external beam radiotherapy and additional 12-cycle standard chemotherapy. All were free of local recurrence or systemic metastasis at a mean follow-up of 36 months (range 12–102 months) and achieved an acceptable cosmetic outcome (Fig. 78.6).<sup>24</sup>

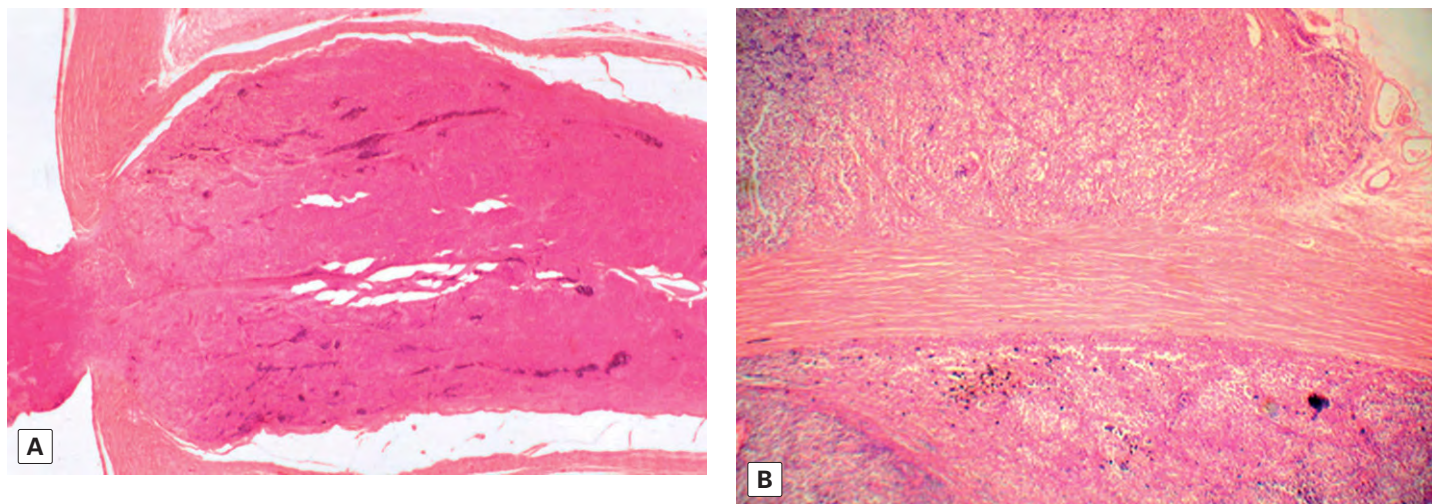


**Fig. 78.3** Accidental orbital retinoblastoma. Cervical lymphadenopathy 6 months after hyphema drainage in an eye with unsuspected retinoblastoma (A). Note vascular conjunctival mass (B). Although the conjunctival mass resolved with high-dose chemotherapy (C), the child succumbed to intracranial metastasis (D).



**Fig. 78.4** Overt orbital retinoblastoma. Previously unrecognized extrascleral mass (A) and optic nerve extension (B) discovered during enucleation.





**Fig. 78.5** Microscopic orbital retinoblastoma. Histopathologic evaluation of an eye enucleated for intraocular retinoblastoma. Invasion of the optic nerve to the level of transection (A) and extrascleral extension (B).

**Table 78.1 Suggested protocol for primary orbital retinoblastoma**

<b>Baseline investigations</b>		
CT scan or magnetic resonance imaging		
Bone marrow biopsy		
Cerebrospinal fluid cytology		
<b>Treatment</b>		
Initial chemotherapy		High-dose triple-drug chemotherapy for 3–6 cycles (every 3 weeks)
Surgery	Enucleation	Assessment of orbital tumor by imaging after completion of third cycle After completion of third cycle if the orbital tumor is resolved Additional 3 cycles of chemotherapy After completion of sixth cycle if the orbital tumor is resolved
	Exenteration	After completion of sixth cycle if the orbital tumor is present
External beam radiation		45–50 Gy (fractionated) to the orbit
Subsequent chemotherapy		Continuation high-dose chemotherapy for 12 cycles
<b>Follow-up investigations</b>		
Imaging at 12, 18, 24, and 36 months		
Bone marrow biopsy and cerebrospinal fluid cytology at 6, 12, 18, 24, and 36 months		

Our treatment protocol should be considered experimental at present. Further studies are necessary to evaluate whether fewer treatment cycles are equally effective. There are also serious concerns about the long-term carcinogenic effects of high-dose chemotherapy.

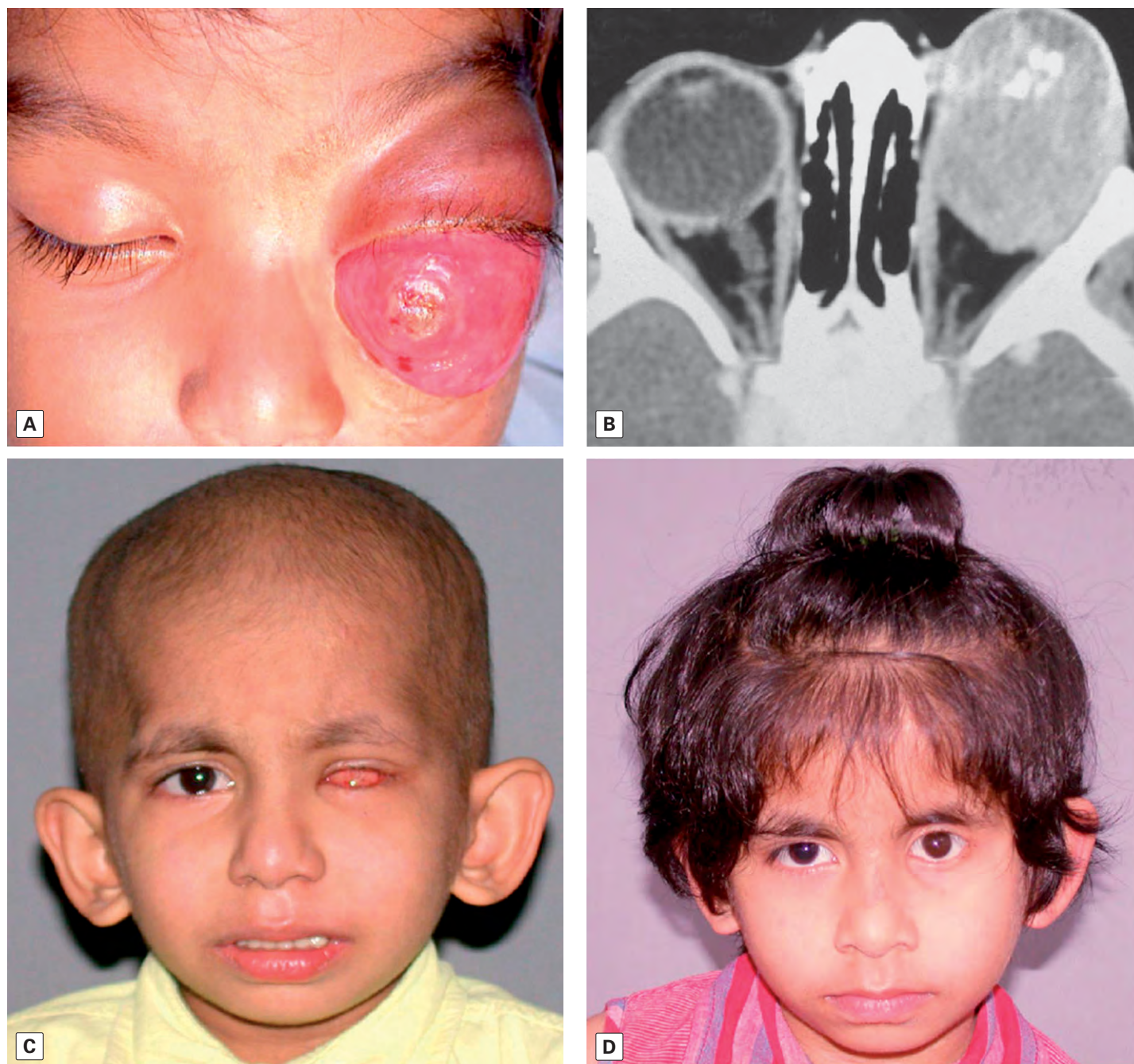
**Table 78.2 Chemotherapy drugs, dose (mg/kg body weight) and schedule for orbital retinoblastoma**

Drugs	Standard dose		High dose	
	Day 1	Day 2	Day 1	Day 2
Vincristine	0.05		0.025	
Etoposide	5.0	5.0	12.0	12.0
Carboplatin	18.6		28.0	

**Secondary orbital retinoblastoma** Our treatment protocol outlined for primary orbital retinoblastoma is currently under evaluation for secondary orbital retinoblastoma and early results have been very encouraging. Surgical intervention in such cases may be limited to excision of the residual orbital mass or an orbital exenteration, depending on the extent of the residual tumor after the initial three to six cycles of high-dose chemotherapy.

**Accidental orbital retinoblastoma** All eyes that have undergone intraocular surgery for unsuspected retinoblastoma should be





**Fig. 78.6** Outcome in a case of primary orbital retinoblastoma. A 2-year-old child with primary orbital retinoblastoma in the left eye (A). CT scan showing massive orbital tumor (B). Following three cycles of neoadjuvant chemotherapy, enucleation, orbital external beam radiotherapy, and an additional nine cycles of chemotherapy, the orbital tumor is completely resolved (C). Three years later, the child is free of local and systemic recurrence and has an acceptable cosmetic appearance (D).

promptly enucleated.<sup>25</sup> The conjunctiva overlying the ports with about 4 mm clear margin should be included en-bloc with enucleation. Random orbital biopsy may be also obtained, but there are no data to support its utility. If immediate enucleation is not logistically possible, then the vitrectomy ports or the surgical incision should be subjected to triple freeze–thaw cryotherapy and enucleation should be performed at the earliest possible opportunity. Histopathologic evaluation of such eyes may include specific analysis of the sites of sclerotomy ports or the cataract wound for tumor cells.

The surgeon should be careful not to accidentally perforate the eye during enucleation. Many surgeons prefer to avoid applying traction

sutures at the insertion of extraocular muscles to minimize the risk of accidental perforation. Instead, a hemostat applied to the medial or lateral rectus muscle stump, or a cryoprobe applied at the limbus provides adequate traction. Eyes manifesting tumor necrosis with aseptic orbital cellulitis pose a specific risk for accidental perforation. Surgery in such eyes is best performed when the inflammation is resolved. A brief course of preoperative oral and topical steroids helps control inflammation.

All patients with accidental orbital retinoblastoma after histopathologic confirmation (if applicable) undergo baseline systemic evaluation to rule out metastasis. Orbital external beam radiotherapy

(fractionated 45–50 Gy) and 12 cycles of high-dose chemotherapy is recommended.<sup>25</sup>

**Overt orbital retinoblastoma** If an extraocular extension is visualized macroscopically during enucleation, special precautions are taken to excise it completely along with the eyeball, preferably together with the layer of Tenon's capsule intact in the involved area.<sup>24</sup> Moreover, steps should be taken to obtain about a 15 mm long optic nerve stump in all cases of advanced retinoblastoma (Chapter 75).<sup>24</sup> In case the optic nerve is thickened and inelastic and is suspected to be involved, and the optic nerve stump is small (<10 mm), it may be best to explore the orbit and attempt to obtain an additional length of optic nerve. This difficult maneuver is made easier by hemostasis, good magnification, and direct illumination. Placement of a biointegrated implant such as hydroxyapatite or porous polyethylene is generally avoided if orbital extension is suspected.<sup>24</sup> Although most implants structurally tolerate radiotherapy well, implant vascularization may be compromised by radiotherapy, thus increasing the risk of implant exposure.

All patients with overt orbital retinoblastoma after histopathologic confirmation undergo baseline systemic evaluation to rule out metastasis. Orbital external beam radiotherapy (fractionated 45–50 Gy) and 12 cycles of high-dose chemotherapy is recommended.

**Microscopic orbital retinoblastoma** The management protocol for patients with microscopic extension of retinoblastoma up to the level of optic nerve transection, scleral infiltration, and extrascleral extension detected on histopathologic evaluation of the enucleated

specimen includes orbital external beam radiotherapy (fractionated 45–50 Gy) and 12 cycles of high-dose chemotherapy.<sup>12,25</sup>

## PROGNOSIS

Orbital retinoblastoma has traditionally carried a poor prognosis, with mortality rates ranging from 25 to 100%.<sup>19–21,26</sup> The presence of orbital invasion was associated with a 10–27-fold higher risk of systemic metastasis compared to cases without orbital invasion.<sup>5</sup> In addition to our observations, several authors have reported improved survival when surgery (usually exenteration) was combined with chemotherapy.<sup>10,18,22,26</sup> Compared to the previously reported survival rates, our current protocol has provided better survival in a limited number of selected patients. However, longer follow-up of the larger numbers of treated patients is mandatory before a definite recommendation about sequential combination of high-dose chemotherapy, followed by surgery, external beam radiotherapy, and extended chemotherapy can be made.<sup>24</sup>

## PROGNOSTIC FACTORS

The identification of frequency and significance of high-risk histopathologic factors that can reliably predict orbital recurrence of retinoblastoma and subsequent systemic metastasis is vital when selecting patients for adjuvant therapy (Chapter 77).<sup>5,9,12</sup> It is generally agreed that invasion of the optic nerve to transection, scleral infiltration, and extrascleral extension are the risk factors that are predictive of orbital recurrence.<sup>5,9</sup> The outcome of adjuvant therapy in minimizing the risk of systemic metastasis and ultimate survival in patients with various histopathologic risk factors is summarized in Table 78.3.<sup>24</sup>

**Table 78.3 Adjuvant chemotherapy for prevention of metastasis in retinoblastoma: survey of the published literature**

First author	Year	Study design	Control group	Selection criteria	Treated cases*	Regimen	Metastasis number (%)	Conclusion
Howarth	1980	Prospective	No	CHR, ON-RL, ON-TR, ESE	14	VC	1 (7%)	Effective
Wolff	1981	Prospective**	Yes	Unilateral RE-Group V	41	VC	6 (12%)	Equivocal
Keith	1989	Retrospective	No	ON-RL, ON-TR, ESE	26	VC	1 (4%)	Effective
Zelter	1991	Retrospective	No	CHR, ON-RL, ON-TR, ESE	24	VAC	8 (33%)	Equivocal
Hungerford	1993	Retrospective	No	CHR, ON-RL	11	NA	0	Effective
Khelfaoui	1996	Retrospective	Yes	Variable	75	Variable	4 (6%)	Effective
Schwartzman	1996	Prospective	No	ON-RL, ON-TR, ESE	29	VAC	4 (14%)	Effective
Namouni	1997	Retrospective	No	ON-TR, ESE	6	VCCp	1 (17%)	Effective
Mustafa	1999	Retrospective	No	CHR, ON-RL, ON-TR, ESE	27	VAC	5 (19%)	Ineffective
Uusitalo	2001	Retrospective	Yes	ON-RL, ON-TR	11	Variable	1 (9%)	Effective
Honavar	2002	Retrospective	Yes	AC, CB, CHR, ON-L, ON-RL, ON-TS, SCL, ECE	46	VAC or VCpE	2 (4%)	Effective

Note: The number of patients and overall results in some of the studies may be different from the data compiled in the table because only relevant and comparable data are tabulated.

\*Those who received adjuvant chemotherapy.

\*\*Randomized.

n, number of patients who received adjuvant chemotherapy; RE, Reese–Ellsworth; NA, information not available; AC, anterior chamber seeding; iris, iris infiltration; CB, ciliary body infiltration; CHR, massive choroidal infiltration; ON-L, invasion of optic nerve lamina cribrosa; ON-RL, retrolaminar optic nerve invasion; ON-TS, invasion of optic nerve transection; SCL, scleral infiltration; ESE, extrascleral extension; V, vincristine; C, cyclophosphamide; A, adriamycin; Cp, carboplatin; E, etoposide.

(Reproduced with permission from Honavar SG, Singh AD. Management of advanced retinoblastoma. *Ophthalmol Clin North Am* 2005; 18: 65–73)

## CONCLUSIONS

Orbital retinoblastoma encompasses the spectrum of primary clinical manifestation (primary), orbital recurrence following enucleation (secondary), inadvertent perforation or intraocular surgery in an eye with unsuspected retinoblastoma (accidental), intraoperative discovery of extraocular or optic nerve extension (overt) and scleral, extra-scleral and optic nerve transection involvement with tumor cells on histopathology (microscopic). Although each clinical situation is unique, with a gross variation in tumor load, the current preferred

management is multimodal, with a combination of initial high-dose chemotherapy, surgery, external beam radiotherapy, and prolonged chemotherapy for 12 cycles. The proposed Children's Oncology Group trial may help formulate a relatively more effective and a standard strategy for the management of orbital retinoblastoma.

This work was supported by the Hyderabad Eye Research Foundation, Hyderabad, India, and SightSavers International, London, United Kingdom.

## REFERENCES

- Young J, Smith MA, Roffers SD et al. Retinoblastoma. In: Ries LA, Smith MA, Gurney JG et al., eds. Cancer incidence and survival among children and adolescents: United States SEER Program 1975–1995. Bethesda, MD: National Cancer Institute, SEER Program. NIH Pub. No. 99–4649, 1999.
- Sanders BM, Draper GJ, Kingston JE. Retinoblastoma in Great Britain 1969–80: incidence, treatment, and survival. *Br J Ophthalmol* 1988; 72: 576–583.
- Anonymous. Survival rate and risk factors for patients with retinoblastoma in Japan. The Committee for the National Registry of Retinoblastoma. *Jpn J Ophthalmol* 1992; 36: 121–131.
- Abramson DH, Niksarli K, Ellsworth RM, Servodidio CA. Changing trends in the management of retinoblastoma: 1951–1965 vs 1966–1980. *J Pediatr Ophthalmol Strabismus* 1994; 31: 32–37.
- Singh AD, Shields CL, Shields JA. Prognostic factors in retinoblastoma. *J Pediatr Ophthalmol Strabismus* 2000; 37: 134–141.
- Ajaiyeoba IA, Akang EE, Campbell OB et al. Retinoblastomas in Ibadan: treatment and prognosis. *West Africa J Med* 1993; 12: 223–227.
- Stannard C, Lipper S, Sealy R, Sevel D. Retinoblastoma: correlation of invasion of the optic nerve and choroid with prognosis and metastases. *Br J Ophthalmol* 1979; 63: 560–570.
- Hungerford J. Factors influencing metastasis in retinoblastoma. *Br J Ophthalmol* 1993; 77: 541.
- Finger PT, Harbour JW, Karcioğlu ZA. Risk factors for metastasis in retinoblastoma. *Surv Ophthalmol* 2002; 47: 1–16.
- Ellsworth RM. Orbital retinoblastoma. *Trans Am Ophthalmol Soc* 1974; 72: 79–88.
- Grabowski EF, Abramson DH. Intraocular and extraocular retinoblastoma. *Hematol Oncol Clin North Am* 1987; 1: 721–735.
- Honavar SG, Singh AD, Shields CL et al. Post-enucleation prophylactic chemotherapy in high-risk retinoblastoma. *Arch Ophthalmol* 2002; 120: 923–931.
- Leal-Leal C, Flores-Rojo M, Medina-Sanson A et al. A multicentre report from the Mexican Retinoblastoma Group. *Br J Ophthalmol* 2004; 88: 1074–1077.
- Kao LY, Su WW, Lin YW. Retinoblastoma in Taiwan: survival and clinical characteristics 1978–2000. *Jpn J Ophthalmol* 2002; 46: 577–580.
- Badhu B, Sah SP, Thakur SK et al. Clinical presentation of retinoblastoma in Eastern Nepal. *Clin Exp Ophthalmol* 2005; 33: 386–389.
- Kiratli PO, Kiratli H, Ercan MT. Visualization of orbital retinoblastoma with technetium-99m (V) dimercaptosuccinic acid. *Ann Nucl Med* 1998; 12: 157–159.
- Moll AC, Hoekstra OS, Imhof SM et al. Fluorine-18 fluorodeoxyglucose positron emission tomography (PET) to detect vital retinoblastoma in the eye: preliminary experience. *Ophthalm Genet* 2004; 25: 31–35.
- Rootman J, Ellsworth RM, Hofbauer J, Kitchen D. Orbital extension of retinoblastoma: a clinicopathological study. *Can J Ophthalmol* 1978; 13: 72–80.
- Pratt CB, Crom DB, Howarth C. The use of chemotherapy in extraocular retinoblastoma. *Med and Pediatr Oncol* 1985; 13: 330–333.
- Kiratli H, Bilgic S, Ozerdem U. Management of massive orbital involvement of intraocular retinoblastoma. *Ophthalmology* 1998; 105: 322–326.
- Goble RR, McKenzie J, Kingston JE et al. Orbital recurrence of retinoblastoma successfully treated by combined therapy. *Br J Ophthalmol* 1990; 74: 97–98.
- Doz F, Khelifaoui F, Mosseri V et al. The role of chemotherapy in orbital involvement of retinoblastoma. The experience of a single institution with 33 patients. *Cancer* 1994; 74: 722–732.
- Antoneli CB, Steinhorst F, de Cassia Braga Ribeiro K et al. Extraocular retinoblastoma: a 13-year experience. *Cancer* 2003; 98: 1292–1298.
- Honavar SG, Singh AD. Management of advanced retinoblastoma. *Ophthalmol Clin North Am* 2005; 18: 65–73.
- Shields CL, Honavar S, Shields JA et al. Vitrectomy in eyes with unsuspected retinoblastoma. *Ophthalmology* 2000; 107: 2250–2255.
- Hungerford J, Kingston J, Plowman N. Orbital recurrence of retinoblastoma. *Ophthalm Pediatr Genet* 1987; 8: 63–68.



# Metastatic retinoblastoma

Ira J. Dunkel and Guillermo L. Chantada

## INTRODUCTION

Patients with extraocular retinoblastoma have historically had a poor prognosis, but recently significant improvements in survival have been reported. In this chapter we will review data indicating that the majority of patients with regional extraocular disease can be successfully treated with conventional chemotherapy and external beam radiation therapy, and that patients with distant metastatic disease appear to benefit from the addition of high-dose chemotherapy with stem cell rescue.

## CLINICAL FEATURES

The presenting signs and symptoms of metastatic retinoblastoma are quite variable and depend on the site or sites of involvement. Reasonably common sites of extraocular disease include the orbit, preauricular lymph nodes, bones, bone marrow, liver, and central nervous system. In patients who have previously undergone enucleation, orbital recurrences often present with the parental observation that the prosthesis is no longer fitting well. More extensive orbital disease may present as a visible mass. Bone disease may present with pain, and bone marrow disease may present with abnormally low blood counts, but often disease at those sites and liver disease may be asymptomatic and discovered only during the extent of disease evaluation. Central nervous system disease can occur as optic nerve disease tracking posteriorly into the brain, or as diffuse leptomeningeal involvement. Again, signs and symptoms are variable, depending on the locations involved and the degree of involvement, but may include headache, irritability, emesis, and/or focal neurological signs.

## DIAGNOSTIC EVALUATION

Patients suspected to have extraocular retinoblastoma need extensive evaluation investigating the sites described above (Table 79.1). In anticipation of aggressive chemotherapy, baseline laboratory work should be performed (Table 79.2).

## DIFFERENTIAL DIAGNOSIS

Although theoretically a broad differential diagnosis exists for the findings associated with extraocular retinoblastoma, in the appropriate context (patient with a history of intraocular retinoblastoma) it is usually fairly obvious whether or not a patient has extraocular retinoblastoma. However, bone and bone marrow disease should be differentiated from secondary neoplasms, as secondary leukemia and other small round blue cell tumors may occur in patients with heritable retinoblastoma, and differential diagnosis may be difficult. Occasionally

orbital masses can develop and be suspected to represent orbital retinoblastoma, but instead be due to granulomas or other causes.<sup>1</sup>

## TREATMENT AND PROGNOSIS

**Regional extraocular (orbital) retinoblastoma** In this section we will summarize data indicating that patients with regional extraocular (orbital) retinoblastoma can be cured with an appropriately intensive treatment that includes systemic chemotherapy and external beam radiation therapy.

**Isolated orbital retinoblastoma** Patients with isolated orbital retinoblastoma had fared poorly when treated with surgery and/or radiation therapy,<sup>2</sup> but their prognosis improved considerably when conventional chemotherapy was added to the treatment regimen, with 1-year event-free survival of 40% following treatment with a variety of chemotherapy agents.<sup>3,4</sup> The management of orbital retinoblastoma is discussed in detail elsewhere (Chapter 78).

**Regional extraocular retinoblastoma** Recent publications confirm that patients with regional extraocular disease (orbital and/or preauricular disease, optic nerve margin positivity) may be cured with conventional chemotherapy and external beam radiation therapy. Investigators in Argentina treated 15 patients with orbital or preauricular nodal disease using two consecutive protocols. Chemotherapy included vincristine, doxorubicin, and cyclophosphamide (local protocol 87), or vincristine, idarubicin, cyclophosphamide, carboplatin, and etoposide (local protocol 94). The external beam radiation therapy dose was 4500 cGy, administered up to the chiasm for patients with orbital disease and to the involved nodes in patients with preauricular adenopathy. The group achieved a 5-year event-free survival of 84%.<sup>5</sup> The Argentine and New York groups also reported the results of 12 patients with optic nerve margin positivity treated with the chemotherapy regimens above and orbital radiation therapy (4000–4500 cGy). All 12 were event-free survivors.<sup>6</sup>

Similarly, investigators in Brazil reported the results of two consecutive protocols. Chemotherapy included vincristine, doxorubicin, cyclophosphamide, cisplatin, and teniposide (1987–1991), or ifosfamide, etoposide, cisplatin, and teniposide (1992–2000). The external beam radiation therapy dose was 4000–5000 cGy to the orbit. Triple intrathecal therapy was also administered. Their therapy was successful in 20 of 32 patients (63%) with orbital disease and 22 of 29 (76%) with optic nerve margin positivity.<sup>7</sup>

**Table 79.1 Systemic work-up for suspected metastatic disease**

Organ/system	Tests
Central nervous system	Brain and orbit MRI with and without contrast Lumbar puncture for CSF cytology Spine MRI with and without contrast (if CNS disease is present or appropriate focal neurological signs are present)
Visceral organs	Abdominal CT with IV contrast
Bone and bone marrow	Bone scan Bone marrow aspirate and biopsy

**Table 79.2 Laboratory Work-up for Suspected Metastatic Disease**

Complete blood count with differential
Liver function studies
Estimate of glomerular filtration rate via either timed urine collection for creatinine clearance or nuclear medicine renal function study
Audiogram
LDH determination may also be useful to provide an estimate of the total body tumor burden

**Distant metastatic retinoblastoma without CNS involvement**

In this section we will summarize data indicating that patients with distant metastatic retinoblastoma have a poor prognosis when treated with conventional therapy, but may be cured when therapy is intensified to include high-dose chemotherapy with autologous stem cell rescue (ASCR). Most of the experience involves patients with metastatic disease that does not involve the central nervous system.

**Conventional dose chemotherapy plus radiation therapy**

Older publications from several centers reported the results of trials utilizing conventional dose chemotherapy and radiation therapy for metastatic extraocular disease, most using vincristine, doxorubicin, cyclophosphamide, cisplatin, and etoposide. Despite occasional reports of long-term event-free survival,<sup>8,9</sup> the bulk of the evidence suggested that the prognosis remained grim with such an approach.<sup>10–12</sup> Recent publications confirm the dismal prognosis. The Argentinian investigators (using the regimens discussed above) noted that all 26 patients with distant metastases died.<sup>5</sup> Similarly, the Brazilian investigators noted that treatment with their regimens (discussed above) led to survival of only 1 of 14 patients (7%) with distant metastases.<sup>7</sup>

**High-dose chemotherapy with ASCR** Individual case reports had suggested that the use of high-dose chemotherapy with ASCR might be beneficial for patients with metastatic retinoblastoma,<sup>13,14</sup> and subsequently investigators for the Institut Curie reported the results of 25 patients with high-risk retinoblastoma treated with high-dose carboplatin, etoposide, and cyclophosphamide followed by

ASCR.<sup>15</sup> Five of eight patients with metastases not involving the CNS were event-free survivors 11–70 months after high-dose chemotherapy. Three had central nervous system relapses and died of disease 10–20 months after the therapy. Three other patients had disease that progressed during induction with conventional induction chemotherapy and never received high-dose chemotherapy. In total, then, five of 11 patients (45%) with metastatic disease not initially involving the central nervous system were event-free survivors.

Memorial Sloan–Kettering Cancer Center (New York, USA) investigators reported the results of four patients with metastatic retinoblastoma not involving the CNS. All had bone marrow metastases and/or bone, liver, and orbital disease. They all responded to an induction regimen using vincristine, a platinum agent, cyclophosphamide, and etoposide (plus doxorubicin in one case) and were then treated with a high-dose carboplatin, thiotepa, and etoposide with ASCR regimen.<sup>16</sup> All four patients were event-free survivors from 46 to 80 months after the diagnosis of metastatic disease. Updated data from New York reveal that seven of 10 patients with metastatic retinoblastoma not involving the CNS were event-free survivors at a median of 84 months.<sup>17</sup> Two relapsed in the CNS at 7 and 10 months after the diagnosis of metastatic disease (prior to high-dose chemotherapy). These two failures were associated with treatment delays due to fungal infection (one patient) and insurance denial (one patient), and both later died of tumor progression. One patient relapsed in the CNS 16 months after the diagnosis of metastatic disease and later died of progressive tumor. The remaining seven were failure free and alive at 16–130 months after the diagnosis of metastatic disease.

Subsequently, other groups have published small series and the overall results appear promising. German investigators treated five patients, three of whom had distant metastatic disease not involving the CNS, with a regimen very similar to that used in New York.<sup>18</sup> None of those three patients received radiation therapy and were event-free survivors at 24, 69, and 124 months from diagnosis of metastatic disease.

St Jude's Hospital (Memphis, Tennessee, USA) investigators reported four patients treated with intensive therapy, including high-dose chemotherapy with stem cell rescue, but their regimens (carboplatin–etoposide, busulfan–cyclophosphamide–melphalan, cyclophosphamide–etoposide, cyclophosphamide–topotecan) did not include thiotepa.<sup>19</sup> Radiation therapy was used for bone metastases. Two of the four patients were long-term survivors.

Children's Hospital Los Angeles (California, USA) investigators included two patients with metastatic disease not involving the CNS in their report regarding patients with extraocular disease.<sup>20</sup> One patient with orbital, bone, and bone marrow disease received high-dose cyclophosphamide, thiotepa, and etoposide with stem cell rescue, but died of disease at 10 months. Another patient had an isolated bone metastasis and received high-dose carboplatin, etoposide, and melphalan with stem cell rescue, but died at 23 months due to a secondary Ewing's sarcoma.

Most recently, a Japanese report included three patients with bone and/or bone marrow disease treated with intensive therapy, including high-dose melphalan-based chemotherapy with ASCR.<sup>21</sup> One of the three patients received radiation therapy. All three were event-free survivors at 38, 107, and 113 months.

**Summary of outcomes for non-CNS metastatic disease**

Overall experience suggests that the addition of high-dose chemotherapy with ASCR is associated with improved survival for patients

with metastatic retinoblastoma not involving the CNS. The inclusion of thiotepa in the regimen may be associated with a lower risk of CNS recurrence (the most likely site of failure) owing to the excellent CNS penetration of that agent.

**Distant metastatic disease with CNS involvement** Fewer data are available regarding the prognosis of patients with metastatic retinoblastoma involving the central nervous system disease treated with high-dose chemotherapy and ASCR. The French Society of Paediatric Oncology (SFOP) experience included four patients with CNS metastases who received high-dose carboplatin, etoposide, and cyclophosphamide with stem cell rescue. Three died of CNS disease, and one was free of disease at 63 months.<sup>15</sup> The CHLA report included four patients with CNS disease, none of whom survived.<sup>20</sup> None received high-dose chemotherapy, but it is unclear whether any had been treated with the intention to include high-dose chemotherapy in the regimen even though none ultimately received such therapy. The

Japanese report included two patients with CNS disease.<sup>21</sup> Both died of disease.

## FUTURE RESEARCH

The Children's Oncology Group has proposed a study of multimodality therapy for extraocular retinoblastoma (COG ARET 0321) and hopes that other cooperative groups or major centers around the world will participate (see Chapter 81). In this study, patients with regional extraocular retinoblastoma (orbital disease, regional nodal disease, and/or optic nerve margin positivity) will receive aggressive conventional chemotherapy and involved-field external beam radiation therapy. Those with distant metastatic disease (as well as those with trilateral retinoblastoma) will receive aggressive conventional induction chemotherapy, have autologous stem cells harvested, receive high-dose carboplatin, thiotepa, and etoposide with ASCR, and then (depending on response to induction) will be considered for involved-field external beam radiation therapy.

## REFERENCES

1. Abramson DH, Andracchi S. Orbital avitene granuloma formation after enucleation for intraocular retinoblastoma. *Am J Ophthalmol* 1997; 123: 567–569.
2. Hungerford J, Kingston J, Plowman N. Orbital recurrence of retinoblastoma. *Ophthalm Pediatr Genet* 1987; 8: 63–68.
3. Goble RR, McKenzie J, Kingston JE et al. Orbital recurrence of retinoblastoma successfully treated by combined therapy. *Br J Ophthalmol* 1990; 74: 97–98.
4. Doz F, Khelifaoui F, Mosseri V et al. The role of chemotherapy in orbital involvement of retinoblastoma: the experience of a single institution with 33 patients. *Cancer* 1994; 74: 722–732.
5. Chantada G, Fandino A, Casak S et al. Treatment of overt extraocular retinoblastoma. *Med Pediatr Oncol* 2003; 40: 158–161.
6. Chantada GL, Dunkel IJ, de Dávila MTG et al. Retinoblastoma patients with high risk ocular pathological features: Who needs adjuvant therapy? *Br J Ophthalmol* 2004; 88: 1069–1073.
7. Antoneli CBG, Steinhorst F, Ribeiro KCB et al. Extraocular retinoblastoma: A 13-year experience. *Cancer* 2003; 98: 1292–1298.
8. Grabowski EF, Abramson DH. Intraocular and extraocular retinoblastoma. *Hematol Oncol Clin North Am* 1987; 1: 721–735.
9. Pratt CB, Fontanesi J, Chenaille P et al. Chemotherapy for extraocular retinoblastoma. *Pediatr Hematol Oncol* 1994; 11: 301–309.
10. Kingston JE, Hungerford JL, Plowman PN. Chemotherapy in metastatic retinoblastoma. *Ophthalm Paediatr Genet* 1987; 8: 69–72.
11. Zelter M, Damel A, Gonzalez G et al. A prospective study on the treatment of retinoblastoma in 72 patients. *Cancer* 1991; 68: 1685–1690.
12. Schwartzman E, Chantada G, Fandino A et al. Results of a stage-based protocol for the treatment of retinoblastoma. *J Clin Oncol* 1996; 14: 1532–1536.
13. Saleh RA, Gross S, Cassano W et al. Metastatic retinoblastoma successfully treated with immunomagnetic purged autologous bone marrow transplantation. *Cancer* 1988; 62: 2301–2303.
14. Saarinen UM, Sariola H, Hovi L. Recurrent disseminated retinoblastoma treated by high-dose chemotherapy, total body irradiation, and autologous bone marrow rescue. *Am J Pediatr Hematol Oncol* 1991; 13: 315–319.
15. Namouni F, Doz F, Tanguy ML et al. High-dose chemotherapy with carboplatin, etoposide and cyclophosphamide followed by a haematopoietic stem cell rescue in patients with high-risk retinoblastoma: a SFOP and SFGM study. *Eur J Cancer* 1997; 33: 2368–2375.
16. Dunkel IJ, Aledo A, Kernan NA et al. Successful treatment of metastatic retinoblastoma. *Cancer* 2000; 89: 2117–2121.
17. Dunkel IJ, Aledo A, Finlay JL et al. Intensive multimodality therapy for metastatic retinoblastoma. *Pediatr Blood Cancer* 2004; 43: 378.
18. Kremens B, Wieland R, Reinhard H et al. High-dose chemotherapy with autologous stem cell rescue in children with retinoblastoma. *Bone Marrow Transplant* 2003; 31: 281–284.
19. Rodriguez-Galindo C, Wilson MW, Haik BG et al. Treatment of metastatic retinoblastoma. *Ophthalmology* 2003; 110: 1237–1240.
20. Jubran RF, Erdreich-Epstein A, Buturini A et al. Approaches to treatment for extraocular retinoblastoma. Children's Hospital Los Angeles experience. *J Pediatr Hematol Oncol* 2004; 26: 31–34.
21. Matsubara H, Makimoto A, Higa T et al. A multidisciplinary treatment strategy that includes high-dose chemotherapy for metastatic retinoblastoma without CNS involvement. *Bone Marrow Transplant* 2005; 35: 763–766.



# Retinocytoma or retinoma

Arun D. Singh, Aubin Balmer and Francis Munier

## INTRODUCTION

There are several lines of evidence that suggest the existence of a benign variant of retinoblastoma.<sup>1-3</sup> The ophthalmoscopic appearance of certain retinal tumors closely resembles that of a successfully treated retinoblastoma. These tumors were called retinoma.<sup>4</sup> Histopathologic studies have demonstrated that these tumors are composed of well-differentiated, benign-appearing mature retinal cells with a characteristic absence of mitoses and necrosis.<sup>5</sup> Based on the nomenclature used to classify pineal body tumors (benign, pineocytoma; malignant, pineoblastoma) an alternate term retinocytoma, has been used to describe these tumors. Other less frequently used terminology includes spontaneously regressed retinoblastoma, spontaneously arrested retinoblastoma, and retinoblastoma group 0.<sup>6-8</sup> Although retinocytoma has in the past been referred to as spontaneously regressed retinoblastoma, there are no convincing cases in the literature wherein spontaneous regression of retinoblastoma was documented. Overall, retinocytoma or retinoma are the preferred terminology because they imply more specifically a benign tumor arising from a retinal cell.<sup>3,4</sup>

## ETIOLOGY AND PATHOGENESIS

Retinocytoma is considered to be benign manifestation of RB1 gene mutation.<sup>2,4,7,9</sup> Several theoretical mechanisms have been proposed to explain the development of retinocytoma. Hypothetically, retinocytoma could arise if the second hit (M2) occurs at a later stage of cell maturation, when the precursor cell has limited mitotic capability and is unable to accumulate additional mutations (M3+).<sup>10</sup> Retinocytoma could also be a manifestation of low-penetrance retinoblastoma (M1 variation).<sup>11-14</sup> In families expressing a low penetrance of retinoblastoma, many gene carriers are either unaffected or affected unilaterally owing to RB1 gene mutations that code for a partially functional retinoblastoma protein.<sup>15,16</sup> In the presence of a partially functional retinoblastoma protein, transformation of the precursor cell into retinoblastoma is blocked leading instead to the formation of a retinocytoma.<sup>14,16-18</sup>

## CLINICAL FEATURES

The incidence of retinocytoma in the general population is not known. The proportion of retinocytoma among the population with retinoblastoma has ranged from 2% to 10%.<sup>1,4</sup> This incidence presumably is an underestimate, reflecting bias, as a diagnosis of retinocytoma is more likely to be made in those with a family history of retinoblastoma.

**Symptoms** The majority (60%) of patients with retinocytoma are asymptomatic, and the diagnosis is made either on routine eye examination or when retinoblastoma is diagnosed in another family member, prompting an eye examination.<sup>3,4</sup> Leukocoria, a common initial feature of retinoblastoma, is not a presenting feature of retinocytoma.<sup>3</sup>

**Signs** The ophthalmoscopic appearance of retinocytoma resembles the spectrum of retinoblastoma regression patterns observed after irradiation (Box 80.1).<sup>19</sup> A translucent retinal mass (88%), calcification (63%), retinal pigment epithelial alteration (54%), and chorioretinal atrophy (54%) are four diagnostic ophthalmoscopic features of retinocytoma (Fig. 80.1).<sup>1,3,4</sup> Any one of these may be present in all cases. However, the majority (80%) of cases have at least two, with only 10% of cases having all four.<sup>3</sup> Retinocytoma diagnosed during the treatment of retinoblastoma because of minimal or complete lack of response to systemic chemotherapy or radiotherapy uniformly lacks the surrounding chorioretinal atrophy commonly seen in adult patients found to have retinocytomas. They frequently, however, have the grayish appearance of type II regression prior to any treatment.

The areas of chorioretinal atrophy closely resemble retinoblastoma regression after irradiation, suggesting tumor regression. Photographic regression of retinocytoma with increasing chorioretinal atrophy over prolonged follow-up has been observed.<sup>3,20</sup> The mechanisms of tumor regression in retinocytoma are unknown but might involve apoptosis<sup>21</sup> rather than ischemia or immune-mediated necrosis.<sup>22</sup> Calcification is not limited to the retinal mass and may be observed as seeding in the vitreous.<sup>23</sup> Intratumoral cysts, a feature of presumed well-differentiated retinoblastoma, is sometimes observed in retinocytoma.<sup>24,25</sup>

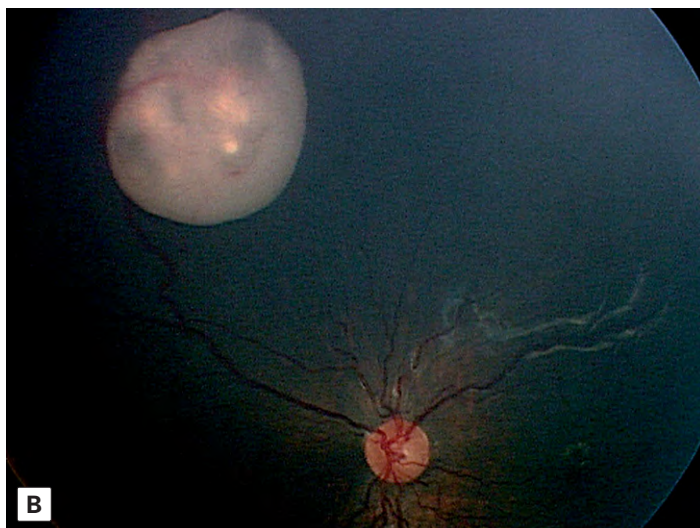
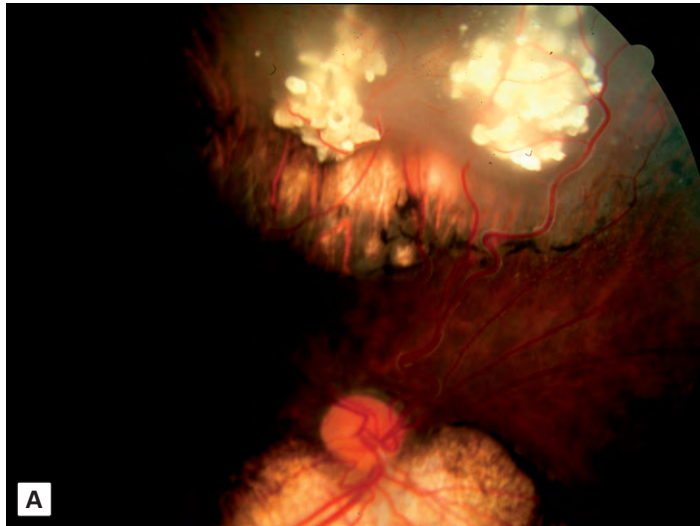
**Risk of second malignant neoplasms** A review of large published series of patients with retinocytoma suggests that second malignant neoplasms are rare in such patients.<sup>1,4,8,26</sup> It is possible that mechanisms that play a protective role in inducing retinocytoma also protect the extraocular cells from the development of second malignant neoplasms.<sup>18,27</sup>

## RELATIONSHIP WITH RETINOBLASTOMA

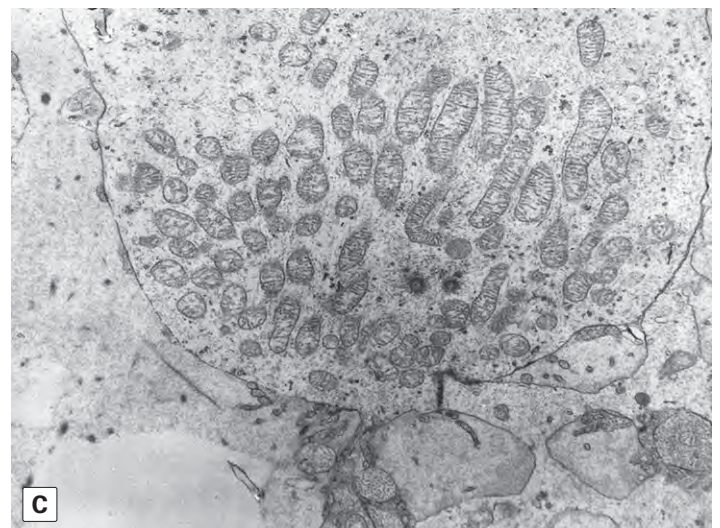
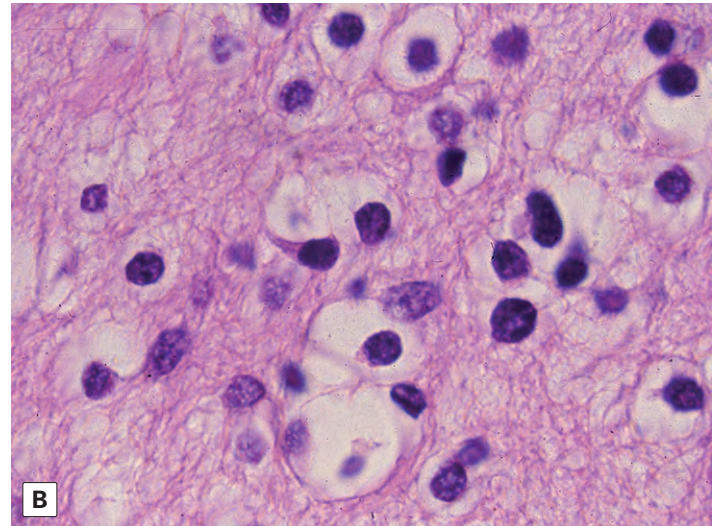
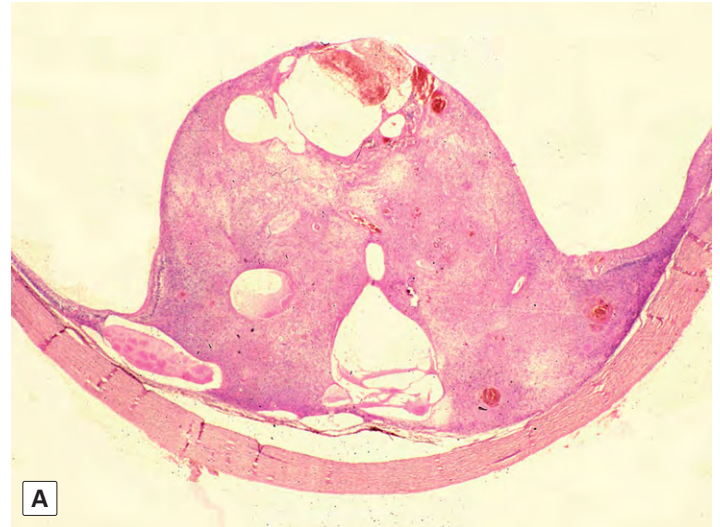
Retinocytoma is considered to be a benign counterpart of retinoblastoma (Fig. 80.2).<sup>2,4,7,9</sup> The majority are diagnosed when the parents of a child who has retinoblastoma are examined.<sup>1,4,8</sup> The examination of first-degree relatives, especially parents, when a new case of retinoblastoma is diagnosed is extremely important as it has major implications for genetic counseling.<sup>28</sup> The occurrences of retinoblastoma

**BOX 80.1 Retinocytoma**

- Retinocytoma is a benign manifestation of *RB1* gene mutation
- The ophthalmoscopic appearance resembles the spectrum of retinoblastoma regression patterns observed after irradiation
- Presence of a translucent grayish retinal mass, calcification, retinal pigment epithelial alteration, and chorioretinal atrophy with or without associated staphyloma are diagnostic features
- Retinocytoma is not associated with retinal exudation or prominent feeder vessels
- Retinocytoma lacks growth over short periods of observation (weeks to months)
- Retinocytoma can undergo malignant transformation into retinoblastoma



**Fig. 80.1** The ophthalmoscopic appearance of retinocytoma. Note translucent grayish retinal mass, calcification, retinal pigment epithelial alteration and chorioretinal atrophy (A). Chorioretinal atrophy may not be present in the early stages (B).



**Fig. 80.2** Histopathology of retinocytoma. Macroscopic view showing pseudocystic appearance (A). On light microscopy the tumor is composed of benign cells (B). Note photoreceptor differentiation on electronmicrophotograph (C).

**Table 80.1 Differential diagnosis of retinocytoma**

Feature	Retinoblastoma	Retinocytoma	Astrocytic hamartoma	Myelinated nerve fibers
Calcification	White, chunky	White, chunky	Yellow, spherical	Absent
Chorioretinal atrophy	Absent	Present in older patients but absent in early retinocytoma	Absent	Absent
RPE changes	Present	Present	Absent	Absent
Feeder vessels	Present	Absent (except sclerosed and tortuous)	Absent	Vessels obscured
Exudation	Absent	Absent	May be present	Absent
Growth*	Present	Absent	Absent	Absent
Association	13q deletion syndrome	13q deletion syndrome	Tuberous sclerosis	None

\*Short-term growth observed over weeks to months.  
RPE, retinal pigment epithelium.

and retinocytoma are not mutually exclusive. Retinoblastoma and retinocytoma have been reported in the same family.<sup>1,4,8</sup> Retinoblastoma and retinocytoma can coexist as two separate tumors in the same eye,<sup>23</sup> or between two eyes of the same patient.<sup>1,4</sup> Lastly, malignant transformation of retinocytoma is well known,<sup>29</sup> and perhaps such occurrences account for cases of retinoblastoma in adults.<sup>30,31</sup>

Another scenario when a diagnosis of retinocytoma can be retrospectively considered is when there is minimal initial response to chemotherapy in tumors presumed to be retinoblastoma. Moreover, the residual tumor fails to grow when all treatment has been discontinued. It is postulated that lack of response to chemotherapy is indicative of extreme differentiation (retinocytoma) rather than chemoresistance by an aggressive tumor.<sup>32</sup>

### DIAGNOSTIC EVALUATION

In the majority of cases the diagnosis of retinocytoma can be made with indirect ophthalmoscopy. However, fluorescein angiography, ultrasonography, and optical coherence tomography (OCT) can be useful ancillary studies.

**Fluorescein angiography** of retinocytoma shows a prominent superficial network of fine vessels in the arterial phase with leakage in the venous phase. Late angiograms show intense diffuse homogeneous staining of the mass.

**Ultrasonography** is useful to demonstrate calcified lesions that show characteristic features, including acoustic solidity and shadowing due to calcification within the mass on B-scan ultrasonography. A-scan ultrasonography shows a sharp anterior border, high internal reflectivity, and attenuation of orbital echoes posterior to the tumor.

**Optical coherence tomography** of retinal astrocytic hamartoma reveals full-thickness replacement of the retinal anatomic layers with the tumor, and shadowing corresponding to the intralaminar calcification. It can be useful in ascertaining areas of chorioretinal atrophy.

### DIFFERENTIAL DIAGNOSIS

Despite the characteristic ophthalmoscopic features of retinocytoma outlined above, certain entities can closely resemble retinocytoma. Retinoblastoma, astrocytic hamartoma, and myelinated nerve fibers can be difficult to differentiate ophthalmoscopically from retinocytoma (Table 80.1).

**Retinoblastoma** From a clinical standpoint it is of the utmost importance to differentiate retinocytoma from retinoblastoma. The retinoblastoma is diagnosed prior to age 5 years and retinocytoma is usually diagnosed in adults. Although calcification is seen in both tumors, areas of chorioretinal atrophy and associated retinal pigment epithelial changes are uncommon in untreated retinoblastoma. In addition, dilated, tortuous retinal feeder vessels are a feature of retinoblastoma rather than retinocytoma. Despite these differences, it may be impossible to differentiate a small retinoblastoma from retinocytoma. Characteristically, retinoblastoma will show growth within 4–6 weeks, whereas retinocytoma will appear unchanged. In cases of doubt, it may be more prudent to treat a small tumor as a retinoblastoma rather than observe for growth, especially if treatment is not expected to lead to significant visual loss.

**Astrocytic hamartoma** a benign retinal tumor, can also closely resemble retinocytoma because both lesions may be calcified. Calcification, when present, can demonstrate subtle differences, as it tends to be dull and chalky white in a retinocytoma, whereas in an astrocytic hamartoma it is more glistening yellow, resembling fish eggs. Surrounding retinal pigment epithelial alterations, a common finding in retinocytoma, is typically absent in astrocytic hamartomas as they are situated superficially in the retina. Although uncommon, the presence of hard exudation supports the diagnosis of astrocytic hamartoma rather than retinocytoma.<sup>33</sup>

**Myelinated nerve fibers** sometimes can mimic a retinocytoma. However, myelinated nerve fibers are usually located at or adjacent to the optic disc margin, show a more fibrillated margin, are flat without any elevation, and are not calcified.



**TREATMENT**

The vast majority of patients with retinocytoma are asymptomatic, non-progressive, and do not require treatment; ocular examination should be performed on an annual basis for possible risk of malignant transformation. Genetic counseling related to the risk of retinoblastoma in offspring should be offered. Genetic testing for RB1 mutations should also be considered.

**REFERENCES**

- Balmer A, Munier F, Gailloud C. Retinoma. Case studies. *Ophthalm Paediatr Genet* 1991; 12: 131–137.
- Balmer A, Munier F, Gailloud C. Retinoma and phthisis bulbi: benign expression of retinoblastoma. *Klin Monatsbl Augenheilkd* 1992; 200: 436–439.
- Singh AD, Santos CM, Shields CL et al. Observations on 17 patients with retinocytoma. *Arch Ophthalmol* 2000; 118: 199–205.
- Gallie BL, Ellsworth RM, Abramson DH, Phillips RA. Retinoma: spontaneous regression of retinoblastoma or benign manifestation of the mutation? *Br J Cancer* 1982; 45: 513–521.
- Margo C, Hidayat A, Kopelman J, Zimmerman LE. Retinocytoma. A benign variant of retinoblastoma. *Arch Ophthalmol* 1983; 101: 1519–1531.
- Aaby AA, Price RL, Zakov ZN. Spontaneously regressing retinoblastomas, retinoma, or retinoblastoma group 0. *Am J Ophthalmol* 1983; 96: 315–320.
- Abramson DH. Retinoma, retinocytoma, and the retinoblastoma gene. *Arch Ophthalmol* 1983; 101: 1517–1518.
- Lommatzsch PK, Zimmermann W, Lommatzsch R. Spontaneous growth inhibition in retinoblastoma. *Klin Monatsbl Augenheilkd* 1993; 202: 218–223.
- Gallie BL, Phillips RA, Ellsworth RM, Abramson DH. Significance of retinoma and phthisis bulbi for retinoblastoma. *Ophthalmology* 1982; 89: 1393–1399.
- Gallie BL, Dunn JM, Chan HS et al. The genetics of retinoblastoma. Relevance to the patient. *Pediatr Clin North Am* 1991; 38: 299–315.
- Dryja TP, Rapaport J, McGee TL et al. Molecular etiology of low-penetrance retinoblastoma in two pedigrees. *Am J Hum Genet* 1993; 52: 1122–1128.
- Kratzke RA, Otterson GA, Hogg A et al. Partial inactivation of the RB product in a family with incomplete penetrance of familial retinoblastoma and benign retinal tumors. *Oncogene* 1994; 9: 1321–1326.
- Schubert EL, Strong LC, Hansen MF. A splicing mutation in RB1 in low penetrance retinoblastoma. *Hum Genet* 1997; 100: 557–563.
- Harbour JW. Molecular basis of low-penetrance retinoblastoma. *Arch Ophthalmol* 2001; 119: 1699–1704.
- Macklin MT. A study of retinoblastoma in Ohio. *Am J Hum Genet* 1960; 12: 1–43.
- Lohmann DR, Brandt B, Hopping W et al. Distinct RB1 gene mutations with low penetrance in hereditary retinoblastoma. *Hum Genet* 1994; 94: 349–354.
- Otterson GA, Chen W, Coxon AB et al. Incomplete penetrance of familial retinoblastoma linked to germ-line mutations that result in partial loss of RB function. *Proc Natl Acad Sci USA* 1997; 94: 12036–12040.
- Sakai T, Ohtani N, McGee TL et al. Oncogenic germ-line mutations in Sp1 and ATF sites in the human retinoblastoma gene. *Nature* 1991; 353: 83–86.
- Singh AD, Garway-Heath D, Love S et al. Relationship of regression pattern to recurrence in retinoblastoma. *Br J Ophthalmol* 1993; 77: 12–16.
- Lam A, Shields CL, Manquez ME, Shields JA. Progressive resorption of a presumed spontaneously regressed retinoblastoma over 20 years. *Retina* 2005; 25: 230–231.
- Nork TM, Poulsen GL, Millicchia LL et al. p53 regulates apoptosis in human retinoblastoma. *Arch Ophthalmol* 1997; 115: 213–219.
- Papac RJ. Spontaneous regression of cancer. *Cancer Treat Rev* 1996; 22: 395–423.
- Lueder GT, Heon E, Gallie BL. Retinoma associated with vitreous seeding. *Am J Ophthalmol* 1995; 119: 522–523.
- Morris WE, LaPiana FG. Spontaneous regression of bilateral multifocal retinoblastoma with preservation of normal visual acuity. *Ann Ophthalmol* 1974; 6: 1192–1194.
- Mashayekhi A, Shields CL, Eagle RC Jr, Shields JA. Cavitory changes in retinoblastoma: relationship to chemoresistance. *Ophthalmology* 2005; 112: 1145–1150.
- Moll AC, Imhof SM, Bouter LM, Tan KE. Second primary tumors in patients with retinoblastoma. A review of the literature. *Ophthalm Genet* 1997; 18: 27–34.
- Bremner R, Du DC, Connolly-Wilson MJ et al. Deletion of RB exons 24 and 25 causes low-penetrance retinoblastoma. *Am J Hum Genet* 1997; 61: 556–570.
- Onadim Z, Hykin PG, Hungerford JL, Cowell JK. Genetic counselling in retinoblastoma: importance of ocular fundus examination of first degree relatives and linkage analysis. *Br J Ophthalmol* 1991; 75: 147–150.
- Eagle RC Jr, Shields JA, Donoso L, Milner RS. Malignant transformation of spontaneously regressed retinoblastoma, retinoma/retinocytoma variant. *Ophthalmology* 1989; 96: 1389–1395.
- Rychener RO. Retinoblastoma in the adult. *Trans Am Ophthalmol Soc* 1948; 46: 318–326.
- Takahashi T, Tamura S, Inoue M et al. Retinoblastoma in a 26-year-old adult. *Ophthalmology* 1983; 90: 179–183.
- Singh AD, Shields CL, Shields JA. Lack of response to chemoreduction in presumed well differentiated retinoblastoma. *J Pediatr Ophthalmol Strabismus* 2002; 39: 107–109.
- Giles J, Singh AD, Rundle PA et al. Retinal astrocytic hamartoma with exudation. *Eye* 2005; 19: 724–725.

**PROGNOSIS**

Most retinocytomas remain stable, with few cases showing regression, which is clinically insignificant. Malignant transformation into retinoblastoma may entail chemotherapy, radiotherapy, or even enucleation, depending on the extent of the disease.

# Children's Oncology Group (COG) Trials for Retinoblastoma

Anna T. Meadows, Murali Chintagumpala, Ira J. Dunkel, Debra Friedman, Julie A. Stoner and Judith G. Villablanca

## INTRODUCTION

During the last decade, retinoblastoma, a tumor that occurs in only 3% of children with cancer, has been the subject of extensive molecular biologic research.<sup>1</sup> However, apart from a short period in the 1970s, retinoblastoma has not been studied by any of the pediatric cooperative groups. Three recent developments offer compelling reasons to initiate clinical and biologic studies of this rare pediatric neoplasm.

## LARGER ROLE FOR PEDIATRIC ONCOLOGY

In the early 1990s pediatric oncologists began to assume a major role in the treatment of children with retinoblastoma when it was found that certain chemotherapeutic agents could successfully reduce the bulk of intraocular tumor (Fig. 81.1), permitting ophthalmologists to avoid enucleation and preserve vision in at least one eye in the majority of children with bilateral disease.<sup>2-4</sup>

## ESTABLISHMENT OF THE CHILDREN'S ONCOLOGY GROUP (COG)

The establishment of the Children's Oncology Group (COG) in 2001 from the four existing pediatric cooperative groups brought together the major institutions treating children with cancer in the United States, Canada, and several other countries. As the majority of the 350 children with this diagnosis annually in North America were receiving treatment at only six or eight institutions, it was quite feasible to begin discussions with these investigators to develop research protocols.

## MAJOR BIOLOGIC QUESTIONS ABOUT THE RB1 PATHWAY

Finally, since the cloning of RB1, the first tumor suppressor gene to be cloned, the RB pathway has been shown to be critical in the cell cycle of normal and neoplastic cells, but more questions remain concerning its mechanisms.<sup>5</sup>

## FORMATION OF A COG COMMITTEE ON RETINOBLASTOMA

A committee consisting of ophthalmic surgeons and pediatric oncologists was formed within the Children's Oncology Group; they later enlisted radiation oncologists, pathologists, statisticians, epidemiologists, and basic scientists in an effort to pursue questions regarding this tumor that required a critical mass of patients and an infrastructure within which to conduct clinical trials and basic research.

The initial aims of this committee were to: identify all retinoblastoma patients in North American in order to monitor incidence, extent

of disease, management and outcome; to test the reliability and validity of the International Classification of Eye Tumors<sup>6</sup> in this context; to centralize tumor samples and conduct more consistent screening for RB1 mutations, as well as to study potential etiological agents, most notably candidate viruses implicated in sporadic retinoblastoma; to conduct studies for specific subgroups of retinoblastoma, in particular for those with high-risk features identified in enucleated unilateral disease using standardized chemotherapy and those with metastatic and intracranial disease with an aim to apply standard therapy plus stem cell transplantation, and improve survival; and to adjust therapy depending on grouping by the International Classification with an aim to increase survival, and reduce the need for external beam irradiation and enucleation wherever possible, that is, to preserve vision and reduce long-term sequelae.

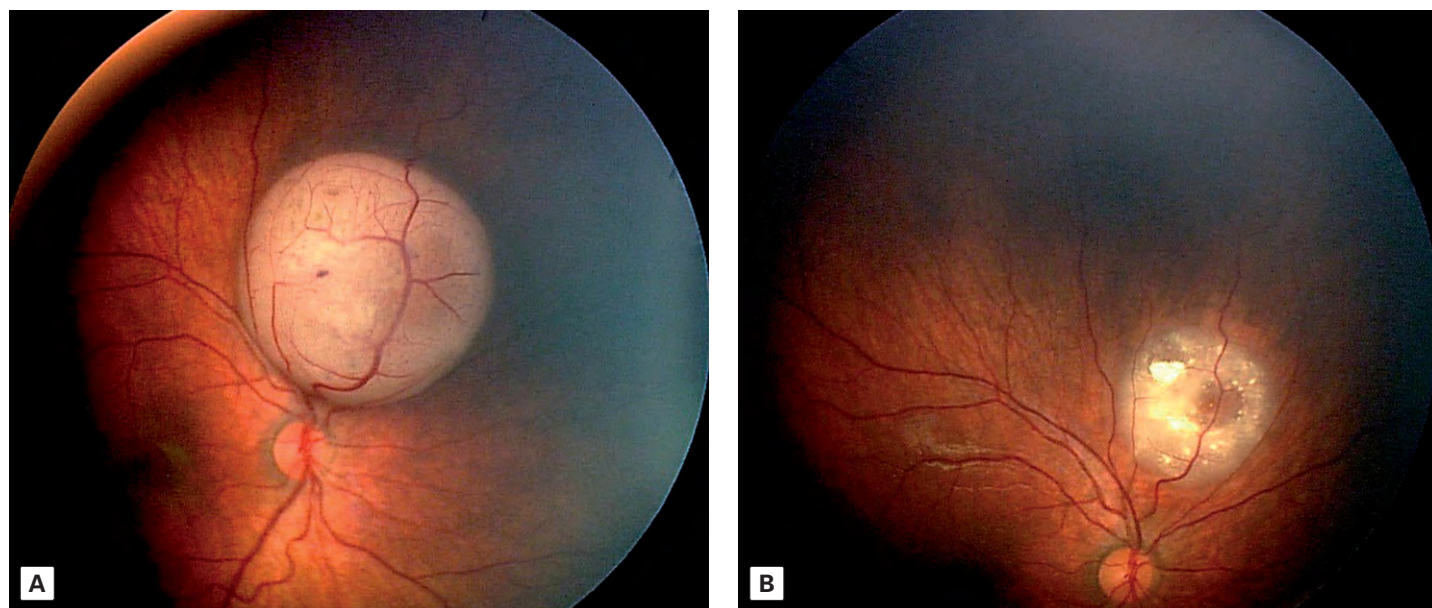
## FOUR COG RETINOBLASTOMA PROTOCOLS

During the 4 years of its existence, the committee met to deliberate the methods by which these questions might be practically addressed. Four distinct protocols emerged, each dealing with a subset of retinoblastoma patients with specific aims, methods, statistical analyses, and expectations regarding outcome. The protocols are listed in Table 81.1. Their aims, background, study methods, and statistical considerations are summarized below.

### COG ARET 0332 A Study of Unilateral Retinoblastoma with and without Histopathologic High-Risk Features and the Role of Adjuvant Chemotherapy (The Histopathologic Risk Factors Protocol)

**Aims** To prospectively determine the prevalence of high-risk histopathologic features such as choroidal involvement, optic nerve invasion, scleral and anterior segment involvement in patients with unilateral retinoblastomas who had undergone enucleation and to estimate the event-free survival (extraocular or metastatic disease) and survival of patients with unilateral retinoblastoma with and without high-risk features.

**Background** Patients with metastatic retinoblastoma have a very poor outcome.<sup>7</sup> Several studies have identified risk factors that might be associated with the development of metastatic disease, including post-laminar optic nerve involvement, choroidal invasion, scleral and anterior segment involvement.<sup>8-10</sup> Tumor cells in the optic nerve posterior to the lamina cribrosa also confer a poorer prognosis despite not affecting mortality.



**Fig. 81.1** Group B retinoblastoma superonasal to the optic nerve at staging examination under anesthesia and prior to treatment (A). After the first cycle of CEV systemic chemotherapy (2 days of drug infusion with 3 weeks of recovery). Note a dramatic reduction in tumor volume (B). This tumor now exhibits regression features of both calcification and 'fish-flesh'-like changes labeled type III regression. Focal laser consolidation (see Chapter 75) could be begun concurrently with the beginning of cycle 2 or cycle 3. In the Group B COG protocol laser treatment is begun at the beginning of cycle 3. The goal of laser consolidation is to completely cover the residual tumor with overlapping laser burns on at least three separate occasions.

**Table 81.1** The Children's Oncology Group retinoblastoma protocols

COG Protocol # ARET-	Protocol		Participants	Investigators
	Short name	Full name		
0332	Histopathologic risk factors	A Study of Unilateral Rb with and without Histopathologic High-Risk Features and the Role of Adjuvant Chemotherapy	Group-wide	Chintagumpala, Chevez-Barrios, Eagle, Albert, O'Brien
0331	Group B	Trial of Systemic Neoadjuvant Chemotherapy for Group B Intraocular Retinoblastoma	Limited institution	Friedman, Murphree
0231	Group C/D	A Single Arm Trial of Systemic and Subtenon Chemotherapy for Groups C and D Intraocular Retinoblastoma	Limited institution	Villablanca, C. Shields
0321	Extraocular disease	A Trial of Intensive Multi-Modality Therapy for Extraocular Retinoblastoma	Group-wide	Dunkel, Abramson

Although 'massive' involvement of the choroid is considered a poor risk factor recent data suggest that choroidal involvement alone does not have a negative effect on outcome, but when associated with optic nerve involvement seems to have an adverse influence on the outcome. There are fewer studies addressing scleral and anterior segment involvement.

The presence of the above risk factors, either singly or in various combinations, had prompted previous investigators to use chemotherapy as prophylaxis. Recent studies by Uusitalo et al. and Honavar et al.<sup>11,12</sup> have shown that chemoprophylaxis is effective in reducing the occurrence of metastases in patients with retrolaminar optic nerve invasion and massive choroid invasion. The data from these studies are confounded by different criteria for the initiation of chemoprophylaxis, and the different chemotherapy regimens used.

There clearly is a need for a prospective study with clearly defined and universally accepted criteria for initiation of post-enucleation chemotherapy to prevent metastases and to improve patient survival.<sup>13</sup> In

addition, the chemotherapy regimen prescribed should be consistent across centers. Such a study could provide a foundation for future studies by providing an estimate of the outcome associated with a uniform post-enucleation chemotherapy regimen for patients with uniformly defined histopathologic risk factors, and by providing an estimate of the outcome associated with enucleation alone for patients without the defined histopathologic risk factors requiring chemotherapy. More importantly, for the first time we will be able to gather information about the true prevalence of such high-risk histopathologic features present in the majority of the patients with unilateral retinoblastoma diagnosed in North America.

**Study methods** Patients with the high-risk features listed in Table 81.2 will receive chemotherapy consisting of six cycles of standard dose carboplatin, vincristine, and etoposide (see Chapter 74) given once every 4 weeks (Table 81.2). All other patients will be treated with enucleation alone.



**Table 81.2 High-risk histopathologic features in an enucleated eye that qualify for adjuvant chemotherapy under COG ARET-0332**

Feature	Details
Massive choroidal invasion	Posterior uveal invasion grades IIC and IID (as defined in pathology guidelines of the protocol)
Any posterior uveal invasion <i>with</i> any optic nerve involvement (optic nerve head, pre- and post-lamina cribrosa)	Both posterior uveal invasion <i>and</i> optic nerve involvement are required
Optic nerve involvement posterior to the lamina cribrosa is an independent finding	

**Statistical considerations** Patients with at least one high-risk feature for which adjuvant therapy is indicated will be non-randomly assigned to receive a single-arm adjuvant therapy regimen. All other patients will be treated with enucleation alone. All patients will be followed for the development of metastasis, extraocular disease, MDS/secondary leukemia, and death. The event-free survival distribution will be compared to historical series according to treatment arm (adjuvant therapy or enucleation alone).<sup>14,15</sup> The prevalence of each histopathologic feature of interest will be estimated among all patients.

### COG ARET 0331: Trial of Systemic Neoadjuvant Chemotherapy for Group B Intraocular Retinoblastoma (the Group B Protocol)

**Aims** Using a backbone of neoadjuvant two-agent (vincristine/carboplatin) systemic chemotherapy (chemoreduction), together with local ophthalmic therapy, the primary aim of this trial is to estimate the event-free survival rate at 2 years. An event is defined as additional chemotherapy, enucleation, external beam radiotherapy (EBRT), or death from any cause. A secondary aim is to estimate the response rate to vincristine and carboplatin after an initial single cycle of chemoreduction prior to implementing standardized local ophthalmic therapy, and to correlate this with event-free survival.

**Background** The standard therapies to treat retinoblastoma – enucleation and EBRT – are associated with significant morbidity.<sup>16–18</sup> The prevalence of second malignancies following the hereditary form of retinoblastoma remains higher than for any other pediatric malignancy, an effect worsened by the use of external beam radiation therapy.<sup>18,19</sup> To avoid the associated morbidities of these therapies, and to utilize the now standardized local ophthalmic therapies in a greater number of patients, research has been directed towards chemoreduction – using chemotherapy to reduce tumor volume in order to increase the efficacy of local therapies. In single institutional studies, small Group B tumors have been shown to respond to vincristine, carboplatin, and etoposide, and also to carboplatin and vincristine.<sup>20</sup> It is important to demonstrate that etoposide can be omitted from the treatment of these tumors as it increases the risk of infectious complications, and possibly of secondary leukemia.<sup>21</sup>

**Study methods** A total of six cycles of chemotherapy with standard dose vincristine and carboplatin (see Chapter 74) is planned. Response

to chemotherapy will be determined following the first cycle of vincristine and carboplatin (Fig. 81.1). Local ophthalmic therapy will be delivered before the second to sixth cycles as clinically indicated. Patients whose disease remains stable will continue on therapy; those who develop progressive disease at any time will be treated at the investigator's discretion.

**Statistical considerations** The single-arm trial will compare event-free survival following six cycles of two-drug therapy with the event-free survival expected under the standard of triple-drug therapy.<sup>2</sup> An event is defined as the need for non-protocol therapy, including any systemic chemotherapy other than or in addition to vincristine and carboplatin as defined in the protocol; enucleation; external beam radiation; or death from any cause. The primary end point will be assessed at the patient level. For patients with bilateral disease, the need for non-protocol therapy of either eye will be defined as a failure at the patient level.

### COG ARET 0231: A Single Arm Trial of Systemic and Subtenon Chemotherapy for Groups C and D Intraocular Retinoblastoma (the Group C/D Protocol)

**Aims** The primary aim is to determine the event-free survival (EFS) at 12 months for eyes with Group D intraocular retinoblastoma treated with systemic high-dose carboplatin/etoposide/vincristine (CEV), sub-Tenon carboplatin, and local ophthalmic therapy. An event is defined for each eye individually as the need for non-protocol chemotherapy, enucleation, or external beam radiation; or death. Secondary aims include determination of the event-free survival at 12 months for Group C eyes treated with this regimen; and to describe the toxicities, patterns of failure, and predictors of failure from findings at the diagnostic eye examination and the response status at the end of therapy.

**Background** Enucleation and/or external beam radiotherapy are effective therapies for retinoblastoma, but have significant side effects.<sup>16–18</sup> The success of chemotherapy for intraocular retinoblastoma is dependent on the size and location of the tumor. Several studies have found that eyes with vitreous seeding or very large tumors (R–E Group V) treated with chemotherapy only have a higher failure rate,<sup>2,22–24</sup> with approximately 60% of Group C and 30% of Group D eyes treated successfully without external beam radiation and/or enucleation. In a small pilot study, the addition of escalating doses of sub-Tenon carboplatin to higher doses of systemic CEV (carboplatin 26 mg/kg, etoposide 12 mg/kg, and vincristine 0.05 mg/kg) chemotherapy achieved a 66% EFS in Group C eyes, and 58% in Group D eyes, with a median follow-up of 24 months.<sup>25</sup> Sub-Tenon carboplatin has been well tolerated in this pilot and a previous report, with toxicity limited to transient periorbital edema, and rare optic nerve atrophy in eyes that also received laser photocoagulation and/or cryotherapy.<sup>25,26</sup>

**Study methods** Children with newly diagnosed bilateral retinoblastoma with at least one Group C or D eye will receive intravenous high-dose carboplatin, etoposide, and vincristine for six courses, with sub-Tenon carboplatin given on the day before or the first day of courses 2–4. Local ophthalmic therapy will be given as clinically indicated, starting with the third course of CEV, and may include cryotherapy, laser, and/or radioactive plaque. Cryotherapy will not be given at the same time as sub-Tenon carboplatin, to avoid toxicity. An event will be defined as the need for any non-protocol chemotherapy,

**Table 81.3 Three extraocular retinoblastoma stratification groups for COG ARET-0321**

Stage	Inclusion criteria	Exclusion criteria
Stage 2 or 3	Orbital disease (including microscopic trans-scleral invasion seen on enucleation pathology), optic nerve margin (+), and/or regional nodal disease	No other sites of metastases
Stage 4a	Overt distant metastatic disease (such as bone, bone marrow, and/or liver)	No detectable CNS involvement
Stage 4b	Overt CNS involvement (brain parenchyma, leptomeninges, CSF cytology). Patients with trilateral retinoblastoma will be included	Extradural/dural disease, but without parenchymal or leptomeningeal disease should not be included and will be considered to be stage 4a

external beam radiotherapy, and/or enucleation of a Group C/D eye; or death. New retinal tumors and/or edge recurrences of previous retinal tumors that can be treated successfully by laser, cryotherapy, and/or plaque only will not be considered protocol failures. A central review of Retcam images will be performed by three ophthalmologists at diagnosis to confirm eye group, and after chemotherapy courses 3 and 6 to confirm response.

**Statistical considerations** Patients with at least one Group C eye or one Group D eye will be non-randomly assigned to receive systemic high-dose carboplatin/etoposide/vincristine (CEV) (see Chapter 74), sub-Tenon carboplatin, and local ophthalmic therapy. The primary aim of the study is to compare the eye-level, 1-year failure-free survival probability under the proposed therapy to fixed historical control values, using lower doses of CEV without sub-Tenon carboplatin, separately for Group D and Group C eyes.<sup>2</sup> For the primary analysis, a failure will be defined as the need for non-protocol chemotherapy, external beam radiotherapy, or enucleation for each Group C or D eye. A death, second malignancy, or metastatic disease will count as a failure of both eyes for a bilateral patient. An eye-level primary analysis will allow us to distinguish between a Group C eye failure and a Group D eye failure for a bilateral Group C/Group D patient (noting that Group D eyes and Group C eyes may respond differently to the proposed therapy).

### COG ARET 0321: A Trial of Intensive Multi-Modality Therapy for Extraocular Retinoblastoma (the Extraocular Disease Protocol)

**Aims** Patients with extraocular retinoblastoma will be stratified into three groups (Table 81.3). We will aim to estimate the proportion in each group who achieve long-term event-free survival after aggressive multimodality therapy, to estimate the response rate to the induction phase of the regimen, and to evaluate the toxicities associated with this regimen.

**Background** Patients with extraocular retinoblastoma have historically fared much worse than those with intraocular disease, but recently significant improvements in survival have been reported in small series. This protocol will seek to confirm that the majority of patients with regional extraocular disease can be successfully treated with conventional chemotherapy and external beam radiation therapy,<sup>27,28</sup> and that patients with distant metastatic disease will benefit from the addition of high-dose chemotherapy with stem cell rescue.<sup>29–34</sup>

**Study methods** Patients will receive four cycles of induction chemotherapy consisting of vincristine, cisplatin, cyclophosphamide, and etoposide. Autologous hematopoietic stem cells will be harvested after clearance of bone marrow disease. Patients with regional extraocular disease (stratum stages 2 and 3) will then receive external beam radiation therapy. Those with distant metastatic (stratum stage 4a) or central nervous system (stratum stage 4b) disease will receive consolidative high-dose carboplatin, thiopeta, and etoposide chemotherapy followed by autologous stem cell rescue, and will then be considered for external beam radiation therapy (depending on response to induction chemotherapy).

**Statistical considerations** The study involves a non-randomized assignment of patients with CNS-negative and CNS-positive distant metastases to receive a treatment regimen involving induction chemotherapy, stem cell harvesting, external beam radiation therapy, and consolidation therapy (high-dose chemotherapy with stem cell rescue). Patients with orbital, regional nodal disease and/or optic nerve margin tumor, but no other sites of metastases (stratum stages 2 and 3), will be non-randomly assigned to receive the same treatment regimen without consolidation therapy. Observed event-free survival distributions will be compared to fixed, historical distributions separately for each stratum.<sup>27,35–36</sup> An event is defined as relapse, second malignancy, or death from any cause.

## REFERENCES

- Dyer MA, Bremner R. The search for the retinoblastoma cell of origin. *Nat Rev Cancer* 2005; 5: 91–101.
- Friedman DL, Himelstein B, Shields CL et al. Chemoreduction and local ophthalmic therapy for intraocular retinoblastoma. *J Clin Oncol* 2000; 18: 12–17.
- Murphree AL, Villablanca JG, Deegan WF 3rd et al. Chemotherapy plus local treatment in the management of intraocular retinoblastoma. *Arch Ophthalmol* 1996; 114: 1348–1356.
- Shields CL, Honavar SG, Meadows AT et al. Chemoreduction plus focal therapy for retinoblastoma: factors predictive of need for treatment with external beam radiotherapy or enucleation. *Am J Ophthalmol* 2002; 133: 657–664.
- Knudson AG. Retinoblastoma and cancer genetics Chapter 65.
- Murphree AL. Intraocular retinoblastoma: the case for a new group classification. *Ophthalmol Clin North Am* 2005; 18: 41–53.
- Schvartzman E, Chantada G, Fandino A et al. Results of a stage-based protocol for the treatment of retinoblastoma. *J Clin Oncol* 1996; 14: 1532–1536.
- Messmer EP, Heinrich T, Hopping W et al. Risk factors for metastases in patients with retinoblastoma. *Ophthalmology* 1991; 98: 136–141.
- Khelfaoui F, Validire P, Auperin A et al. Histopathologic risk factors in retinoblastoma: a retrospective study of 172 patients treated in a single institution. *Cancer* 1996; 77: 1206–1213.

10. Shields CL, Shields JA, Baez KA et al. Choroidal invasion of retinoblastoma: metastatic potential and clinical risk factors. *Br J Ophthalmol* 1993; 77: 544–548.
11. Uusitalo MS, Van Quill KR, Scott IU et al. Evaluation of chemoprophylaxis in patients with unilateral retinoblastoma with high-risk features on histopathologic examination. *Arch Ophthalmol* 2001; 119: 41–48.
12. Honavar SG, Singh AD, Shields CL et al. Postenucleation adjuvant therapy in high-risk retinoblastoma. *Arch Ophthalmol* 2002; 120: 923–931.
13. Chantada GL, Dunkel IJ, de Davila MT et al. Retinoblastoma patients with high risk ocular pathological features: who needs adjuvant therapy? *Br J Ophthalmol* 2004; 88: 1069–1073.
14. Woolson RF. Rank tests and a one-sample logrank test for comparing observed survival data to a standard population. *Biometrics* 1981; 37: 687–696.
15. Jennison C, Turnbull, B.W. Group sequential methods with application to clinical trials. Boca Raton, FL: Chapman & Hall/CRC Press, 2000.
16. Anteby I, Ramu N, Gradstein L et al. Ocular and orbital complications following the treatment of retinoblastoma. *Eur J Ophthalmol* 1998; 8: 106–111.
17. Kaste SC, Chen G, Fontanesi J et al. Orbital development in long-term survivors of retinoblastoma. *J Clin Oncol* 1997; 15: 1183–1189.
18. Kleinerman RA, Tucker MA, Tarone RE et al. Risk of new cancers after radiotherapy in long-term survivors of retinoblastoma: an extended follow-up. *J Clin Oncol* 2005; 23: 2272–2279.
19. Fletcher O, Easton D, Anderson K et al. Lifetime risks of common cancers among retinoblastoma survivors. *J Natl Cancer Inst* 2004; 96: 357–363.
20. Rodríguez-Galindo C, Wilson MW, Haik BG et al. Treatment of intraocular retinoblastoma with vincristine and carboplatin. *J Clin Oncol* 2003; 21: 2019–2025.
21. Smith MA, Rubinstein L, Anderson JR et al. Secondary leukemia or myelodysplastic syndrome after treatment with epipodophyllotoxins. *J Clin Oncol* 1999; 17: 569–577.
22. Gallie BL, Budning A, DeBoer G et al. Chemotherapy with focal therapy can cure intraocular retinoblastoma without radiotherapy. *Arch Ophthalmol* 1996; 114: 1321–1328.
23. Chan HSL, Heon, E., Budning, A. et al. Improvement of the cure rate of intraocular retinoblastoma without significantly increasing toxicity with higher dose carboplatin–teniposide in a cyclosporine multidrug reversal regimen. Proceedings 10th International Symposium on Retinoblastoma, 2001.
24. Villablanca JG, Atchaneeyasakul, L, Murphree, A.L. Clinical outcome of Group V eyes treated with cyclosporin A/carboplatin/etoposide/vincristine. Proceedings 10th International Symposium on Retinoblastoma, 2001.
25. Villablanca JG, Jubran RF, Murphree LA. Phase I study of subtenon carboplatin with systemic high dose carboplatin/etoposide/vincristine for eyes with disseminated intraocular retinoblastoma. Proceedings 10th International Symposium on Retinoblastoma, 2001.
26. Abramson DH, Frank CM, Dunkel IJ. A phase I/II study of subconjunctival carboplatin for intraocular retinoblastoma. *Ophthalmology* 1999; 106: 1947–1950.
27. Chantada G, Fandino A, Casak S et al. Treatment of overt extraocular retinoblastoma. *Med Pediatr Oncol* 2003; 40: 15–161.
28. Antoneli CB, Steinhorst F, de Cassia Braga Ribeiro K et al. Extraocular retinoblastoma: a 13-year experience. *Cancer* 2003; 98: 1292–1298.
29. Namouni F, Doz F, Tanguy ML et al. High-dose chemotherapy with carboplatin, etoposide and cyclophosphamide followed by a haematopoietic stem cell rescue in patients with high-risk retinoblastoma: a SFOP and SFGM study. *Eur J Cancer* 1997; 33: 2368–2375.
30. Dunkel IJ, Aledo A, Kernan NA et al. Successful treatment of metastatic retinoblastoma. *Cancer* 2000; 89: 2117–2121.
31. Kremens B, Wieland R, Reinhard H et al. High-dose chemotherapy with autologous stem cell rescue in children with retinoblastoma. *Bone Marrow Transplant* 2003; 31: 281–284.
32. Rodríguez-Galindo C, Wilson MW, Haik BG et al. Treatment of metastatic retinoblastoma. *Ophthalmology* 2003; 110: 1237–1240.
33. Jubran RF, Erdreich-Epstein A, Butturini A et al. Approaches to treatment for extraocular retinoblastoma: Children’s Hospital Los Angeles experience. *J Pediatr Hematol Oncol* 2004; 26: 31–34.
34. Matsubara H, Makimoto A, Higa T et al. A multidisciplinary treatment strategy that includes high-dose chemotherapy for metastatic retinoblastoma without CNS involvement. *Bone Marrow Transplant* 2005; 35: 763–766.
35. Doz F, Khelfaoui F, Mosseri V et al. The role of chemotherapy in orbital involvement of retinoblastoma: the experience of a single institution with 33 patients. *Cancer* 1994; 74: 722–732.
36. Kivela T. Trilateral retinoblastoma: a meta-analysis of hereditary retinoblastoma associated with primary ectopic intracranial retinoblastoma. *J Clin Oncol* 1999; 17: 1829–1837.



# Retinoblastoma: at risk pregnancies

Lisa Paquette and David A. Miller

## INTRODUCTION

Recent advances in imaging technology have enabled evaluation of the fetus to become more accessible and the information obtained exquisitely more detailed. Specifically, fetal magnetic resonance imaging (MRI) and fetal ultrasound, including three-dimensional ultrasound, are being increasingly used for prenatal diagnosis (Table 82.1). This chapter will provide a review of fetal ultrasound and fetal MRI, care of the pregnant woman and her fetus/newborn with possible retinoblastoma, and how retinoblastoma may be detected prenatally and proper management strategies designed. Interestingly, there have only been two case reports of retinoblastoma being diagnosed in utero, and both were massive extraocular tumors found on fetal ultrasound.<sup>1,2</sup> Exploring the fetal eye is a new frontier but may have a future important role in the routine management of this disease.

## FETAL ULTRASOUND

**Background** Since 1958 fetal ultrasound has become so much a part of the routine examination that 90–100% of pregnant women in some countries will have at least one ultrasound scan.<sup>3,4</sup> In 2001, approximately 67% of pregnant women in the United States had an ultrasound.<sup>3</sup> After more than 30 years of experience, there have been no reports of prenatal ultrasound causing fetal harm.<sup>3</sup> There are two approaches to the ultrasonographic examination of a fetus, both B-mode techniques: transvaginal and transabdominal. Cardiac motion can be detected by transvaginal ultrasound as early as 6 weeks of gestation (when the embryo is about 5 mm in length) and by transabdominal ultrasound 1 week later.<sup>3</sup> Transvaginal ultrasound is rarely used for evaluation of the fetus after the first trimester, as by that time it has outgrown the superior bounds of the pelvis.

**Standard uses of fetal ultrasound** The most common uses for prenatal ultrasound are to confirm the expected date of delivery and to screen for anomalies. A standard ultrasonographic examination of the fetus during the second and third trimester evaluates the placenta, amniotic fluid, maternal pelvis, and fetus (including heart motion, brain structures, estimated fetal weight, abdominal organs, spine, extremities, and estimated gestational age).

**Specialized uses of fetal ultrasound** A specialized examination is a more detailed anatomic examination performed when an anomaly is suspected. Additional uses of prenatal ultrasound include fetal echocardiography, Doppler, and a biophysical profile, the latter two assessing fetal well-being.<sup>3</sup> Standard values have been established

to evaluate blood flow in maternal uterine arteries, and in fetal umbilical and middle cerebral arteries. A biophysical profile is employed in high-risk pregnancies to help predict fetal survival. These examinations are only used when abnormalities of the pregnancy/fetus are suspected.

**Transabdominal 3D ultrasound** was first reported in 1989 for reconstructing fetal body regions of special interest (Fig. 82.1).<sup>5</sup> Now it is being used to evaluate cleft lip and cleft palate, as well as brain, kidney, and ear development. It allows for estimating the volume of organs, and often provides greater multidimensional detail when anomalies are suspected.<sup>6–14</sup> Limitations of 3D ultrasound are that the quality will be significantly diminished if there is low amniotic fluid volume, or if the position of the fetus does not adequately reveal the body region of interest, subtle differences in soft tissue detail are difficult to appreciate, and the field of view is relatively small.<sup>3,15,16</sup>

**Specialized ultrasound of the fetal eye** As of the end of 2005, there are no reports of transabdominal 3D ultrasound being used for ocular evaluation. Figures from our institution help illustrate the fetal ultrasound imaging capabilities of the normal and abnormal eye (Fig. 82.2). Microphthalmia can be identified on a thorough specialized transabdominal B-mode or 3D ultrasound by lack of identification of the lens. A 1 mm tumor on the retina may be visible by 20 weeks' gestation (Fig. 82.2).

## FETAL MAGNETIC RESONANCE IMAGING

**Background** The use of fetal magnetic resonance imaging (MRI) was first reported in 1988, but fetal motion artifact limited useful information.<sup>17</sup> In the ensuing years, faster imaging sequences have been developed that can essentially eliminate fetal motion artifact, one of the most common causes of poor image quality. Specifically, the mother lies in a supine or lateral decubitus position in the MRI scanner for approximately 30 minutes. No oral or IV contrast is given, nor are any sedatives or paralytics needed to keep the fetus still. It is preferable that the mother has fasted for 4 hours prior to the examination so that the fetus is less active and the mother's stomach is mostly empty while recumbent.

**Safety** There have been no reports of adverse outcomes due to human fetal exposure to MRI, although it is generally recommended to avoid MRI during the period of organogenesis (the first trimester)

and to avoid gadolinium contrast, as it readily crosses the placenta.<sup>18–21</sup> The Safety Committee of the Society of Imaging states that MRI can be used for pregnant patients if results from other non-ionizing studies (i.e. ultrasound) are inadequate and a procedure requiring ionizing radiation would be required (i.e. CT, X-ray).<sup>21</sup> Because of the expense

and limited accessibility of MRI, ultrasound remains the first tool to evaluate the fetus.

**Uses of fetal MRI** Fetal MRI is employed to better define an abnormality (in order for delivery management, pregnancy termination, fetal intervention, and postnatal management decisions to be made) and to help find associated anomalies once one anomaly has been diagnosed (Fig. 82.3). It is especially useful in cases in which the amniotic fluid volume is too low, the maternal habitus is too great, or the fetal position obscures the area of interest.<sup>15,20</sup> Fetal MRI is often a useful complement to ultrasound as it allows for better tissue differentiation and can display a larger field of view.<sup>21</sup>

Many disciplines (urology, pediatric surgery, neurosurgery, cardiothoracic surgery, perinatology, neonatology) are using fetal MRI results to aid in developing case-specific treatment plans for many prenatally diagnosed conditions (sacroccygeal teratoma, congenital diaphragmatic hernia, twin–twin transfusion syndrome, myelomeningocele, neck and chest masses, hydrocephalus, and renal and genitourinary anomalies). The evaluation of central nervous system and thoracic lesions has been aided greatly by fetal MRI, adding information and changing counseling and management in up to 50% of cases.<sup>15,20</sup> Abdominal, genitourinary, and neck abnormalities are also being better elucidated by fetal MRI.<sup>20</sup> Contraindications to fetal MRI include a pregnant patient with a pacemaker or metallic implants of any kind.<sup>22</sup>

**Use of fetal MRI to evaluate the developing eye** There is not a single published report in the English literature related to the anatomy of the fetal eye on MRI examination. It seems plausible that a small retinal tumor may be detected in utero, as a new MRI coil has allowed postnatal identification of tumors >1.8 mm.<sup>23</sup> Some images from our institution may help illustrate what capabilities exist for the ophthalmic applications of fetal MRI (Fig. 82.4).

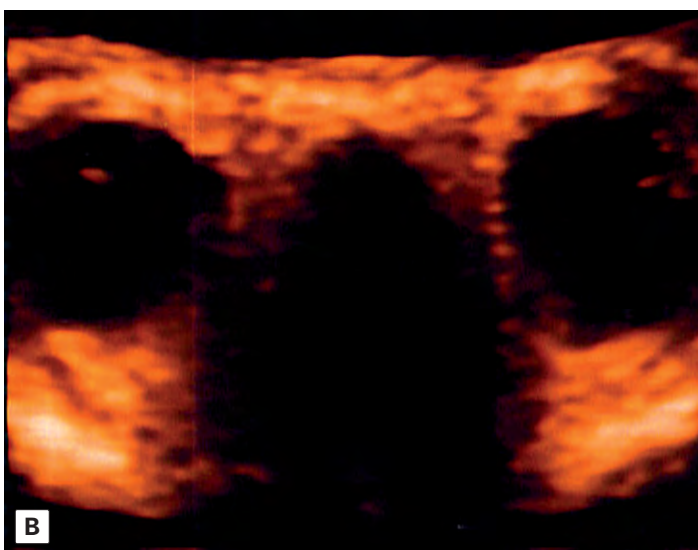
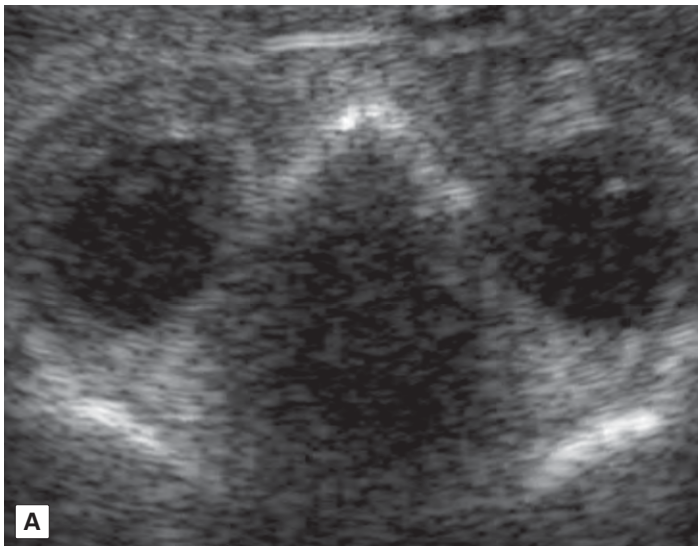
## CARE OF THE PREGNANT WOMAN AND HER FETUS/NEWBORN WITH POSSIBLE RETINOBLASTOMA

**Routine prenatal care** Mothers identified to be at risk of having a fetus with retinoblastoma, or who have been found to carry a fetus with ultrasound or fetal MRI evidence of retinoblastoma, should receive routine prenatal care as early in the pregnancy as possible. This would involve, for the uncomplicated pregnancy, being examined every 4 weeks until 28 weeks of gestation, then every 2–3 weeks until 36 weeks of gestation, then every week until delivery at term (>37 weeks of gestation). Examinations include fetal heart rate evaluation, maternal blood pressure measurement, maternal urinalysis, maternal weight measurement, fundal height measurement, psychosocial evaluation, and later in pregnancy obtaining the history of recent and consistent fetal movement. Although the American Academy of Pediatrics and American College of Obstetricians and Gynecologists do not recommend routine prenatal ultrasonography, it is our preference and California's reimbursement practice to have at least one ultrasound early in the pregnancy to assist with accurate gestational age assessment, and one in the second trimester (approximately 18–20 weeks of gestation) to evaluate fetal anatomy.

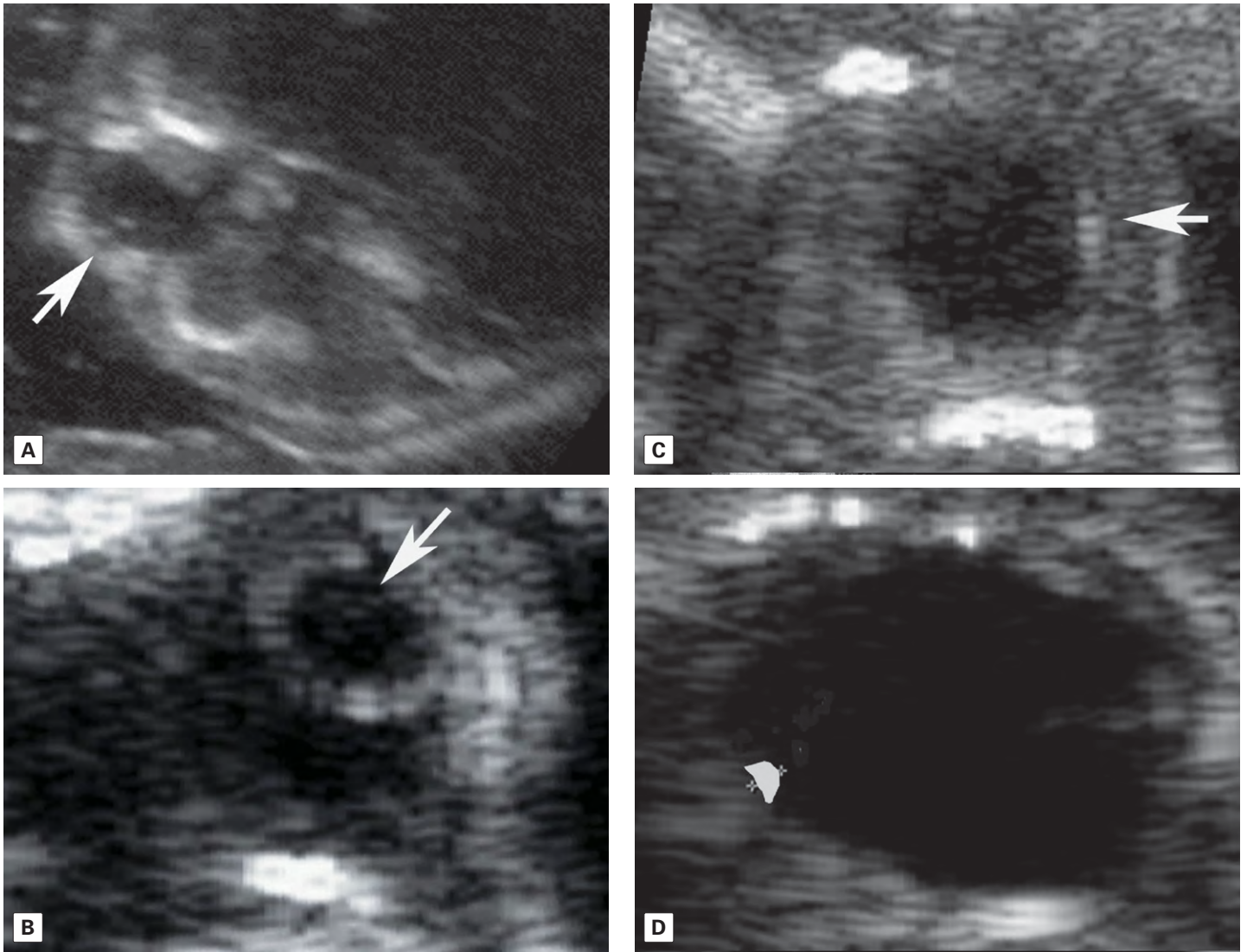
**The Childrens Hospital Los Angeles protocol for specialized retinoblastoma prenatal care** Because it is not known how early in gestation retinoblastoma can be identified, we are conducting a study in which ultrasound is done every 2 weeks and

**Table 82.1 Glossary of commonly used terms**

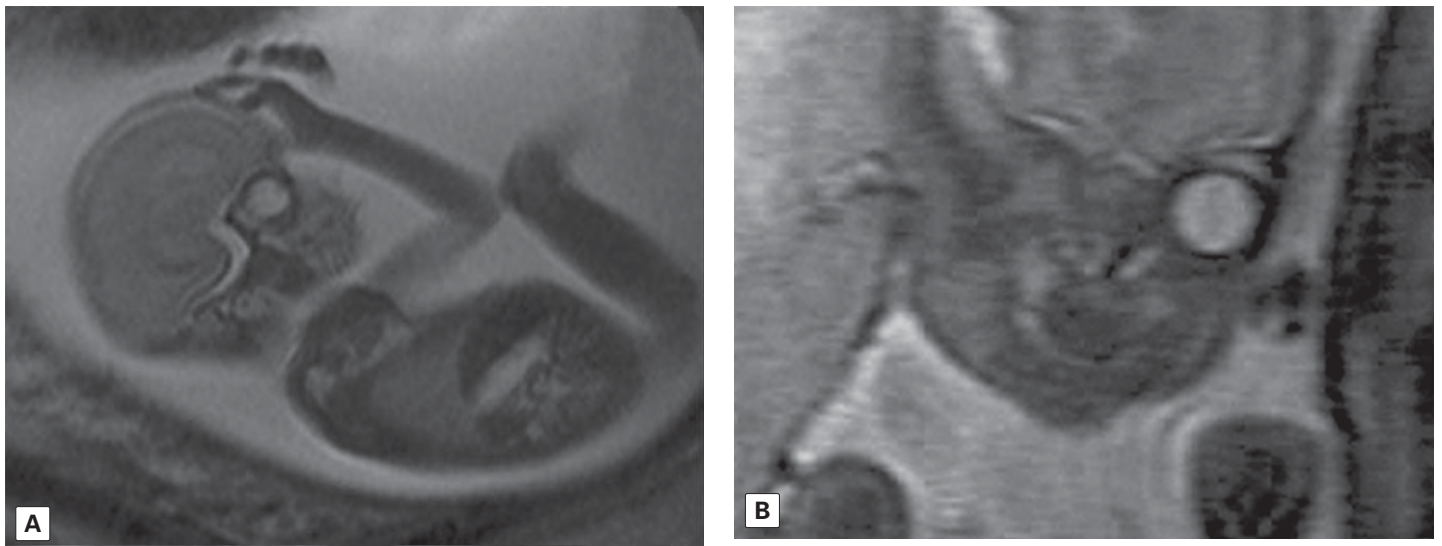
Term	Meaning
Prenatal	Prior to birth
Antenatal	Used interchangeably with prenatal
Postnatal	After birth
Gestational age	Age of fetus in weeks, estimated from last menstrual period, giving a total of 40 weeks to be completed
Term gestation	Gestational age >37 weeks
Fetus	Technically, an embryo develops into a fetus at 12 weeks of gestation, although these terms are often interchangeably used
Fundal height	Measurement of the uterus from maternal pubic symphysis to the top of the uterus



**Fig. 82.1** Fetal transabdominal ultrasound at 20 weeks gestation. Coronal view of orbits (A). Appearance on a 3D ultrasound (B).

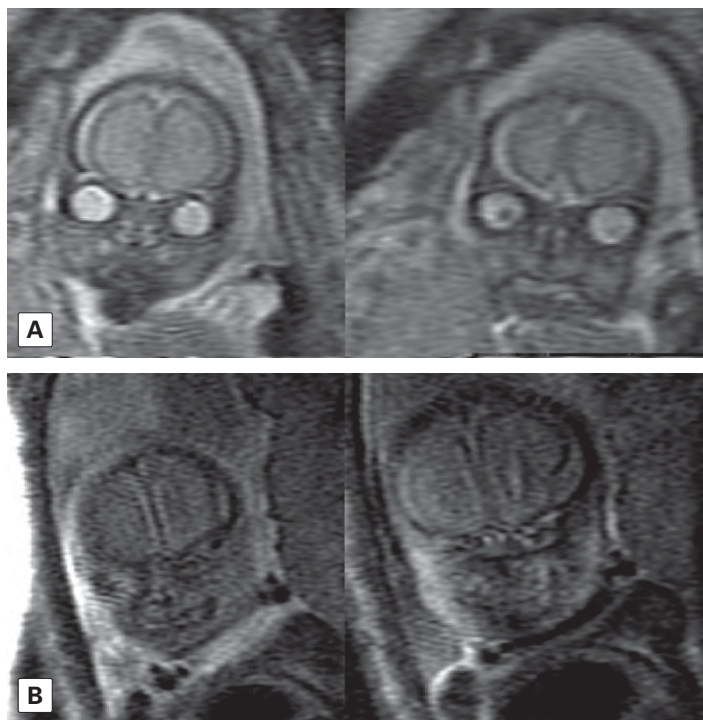


**Fig. 82.2** Fetal transabdominal ultrasound at 20 weeks gestation. Arrow indicates right eye (A). To the right of the arrow is the nose. At higher magnification circle-shaped normal lens (arrow) is visible (B). Sagittal view of the eye with right side of picture corresponding to the anterior aspect of the eye (C). Lens is clearly visible (arrow). Gray drawing represents hypothetical appearance of a 1 mm retinoblastoma (D).



**Fig. 82.3** Fetal magnetic resonance imaging (A). Easy visualization of the eyeball (B).





**Fig. 82.4** Fetal magnetic resonance imaging. Normal appearance (A). Patient with microphthalmia (B).

MRI is performed every 4 weeks, starting at 20 weeks of gestation in women whose fetus is at risk for this disease. In addition to medical management, the mother will most likely benefit from psychosocial interventions (Chapter 73). The presence of retinoblastoma in the fetus at this time does not alter the delivery management. Obstetric decisions should be made based on the standard of care for both mother and fetus. Perhaps, in time, it will be learned that fetal retinoblastoma can indeed be diagnosed in utero, and some families may find the benefit of starting treatment for the retinoblastoma sooner to be greater than the risk of a scheduled premature delivery at 34–35 weeks of gestation (3–4 weeks early). If this is considered, fetal lung maturity documentation is recommended prior to delivery in order to lessen the complications of preterm delivery. It is particularly impor-

tant that the mother's care provider (obstetrician, family practitioner, midwife) is aware of the possible retinoblastoma in the fetus and relays this information promptly to the newborn's physician.

**Care of the fetus and neonate with retinoblastoma** Unfortunately, if retinoblastoma is diagnosed in utero, there is currently no action that can be taken until the baby is born.

As noted above, we have an IRB-approved pilot study to validate the use of 3D ultrasound and MRI to evaluate fetal eyes. The next step may be to pursue early (34–35 weeks of gestation) safe delivery so that treatment of prenatally documented intraocular disease can begin as early as possible. Our center's experience has suggested a greater frequency of congenital anomalies in patients with retinoblastoma. Therefore, a thorough physical examination should be performed by the baby's physician (Chapter 73). It is likely that the newborn with retinoblastoma will appear well, in which case there is no reason to separate mother and baby. The mother should be allowed to breastfeed if she desires, unless she is receiving chemotherapy herself (which would be very unlikely). Again, it is imperative that good communication exists among the healthcare team in order for the neonate to be examined by an ophthalmologist for retinoblastoma within the first days of life, preferably prior to discharge home. The presence of retinoblastoma in the newborn is not a contraindication to routine neonatal care (immunizations, newborn screening, etc.). Theoretically, if there has been significant intracranial extension, seizures, apnea, syndrome of inappropriate antidiuretic hormone secretion, and hypertension could arise. The management of these conditions would not differ from that of other neonates with centrally derived homeostasis abnormalities, but the ocular oncologist should be involved immediately. It is worth emphasizing again that support for the entire family should have begun prior to delivery, and should continue as the diagnostic and possible treatment steps are taken.

## SUMMARY

The diagnosis of retinoblastoma in utero is expected to become a reality as the techniques available with fetal ultrasound and MRI are applied to the at-risk fetus. The exact role that prenatal detection of retinoblastoma will play in the clinical management of this disease is still to be determined.

## ACKNOWLEDGEMENTS

We are grateful to Dr A. Panigrahy for providing the MR images.

## REFERENCES

- Maat-Kievit JA, Oepkes D, Hartwig NG et al. A large retinoblastoma detected in a fetus at 21 weeks of gestation. *Prenat Diagn* 1993; 13: 377–384.
- Salim A, Wiknjosastro GH, Danukusumo D et al. Fetal retinoblastoma. *L Ultrasound Med* 1998; 17: 717–720.
- Cunningham FG, Leveno KJ, Bloom SJ et al, eds. *Williams obstetrics*, 22nd edn. New York: McGraw Hill, 2005.
- Callen PW. *Ultrasonography in obstetrics and gynecology*, 3rd edn. Philadelphia: WB Saunders, 1994.
- Baba K, Satoh K, Sakamoto S et al. Development of an ultrasonic system for three-dimensional reconstruction of the fetus. *J Perinat Med* 1989; 17: 19–24.
- Gentile M, Volpe P, Cariola F. Prenatal diagnosis of chromosome 4 mosaicism: prognostic role of cytogenetic, molecular, and ultrasound/MRI characterization. *Am J Med Genet A* 2005; 136: 66–70.
- Chang CH, Chang FM, Yu CH et al. Fetal ear assessment and prenatal detection of aneuploidy by the quantitative three-dimensional ultrasonography. *Ultrasound Med Biol* 2000; 26: 743–749.
- Chang CH, Yu CH, Chang FM et al. The assessment of normal fetal brain volume by 3D ultrasound. *Ultrasound Med Biol* 2003; 29: 1267–1272.
- Chang CH, Yu CH, Chang FM et al. The assessment of normal fetal liver volume by three-dimensional ultrasound. *Ultrasound Med Biol* 2003; 29: 1123–1129.
- Chang CH, Yu CH, Ko HC et al. Quantitative three-dimensional power Doppler sonography for assessment of the fetal renal blood flow in normal gestation. *Ultrasound Med Biol* 2003; 29: 929–933.
- Chang CH, Yu CH, Ko HC et al. Prenatal assessment of normal fetal humerus volume by three-dimensional ultrasound. *Ultrasound Med Biol* 2003; 29: 1675–1680.
- Chang LW, Chang FM, Chang CH et al. Prenatal diagnosis of fetal multicystic dysplastic kidney with two-dimensional and three-dimensional ultrasound. *Ultrasound Med Biol* 2002; 28: 853–858.
- Kang L, Chang CH, Yu CH et al. Prenatal depiction of cystic hygroma using three-dimensional ultrasound. *Ultrasound Med Biol* 2002; 28: 719–723.
- Hata T, Yanagihara T, Matsumoto M et al. Three-dimensional sonographic features of hydrops fetalis. *Gynecol Obstet Invest* 1999; 48: 172–175.
- Russell SA. Cranial abnormalities. In: Twining P, McHugo J, Pilling D et al., eds. *Textbook of fetal abnormalities*. Edinburgh: Churchill Livingstone, 2000.
- Joe BN, Coakley FV. MR imaging before fetal surgery: Contribution to management. In: Levine D, ed. *Atlas of fetal MRI*. London: Taylor and Francis, 2005.

17. Mattison DR, Kay HH, Miller RK et al. Magnetic resonance imaging: A noninvasive tool for fetal and placental physiology. *Biol Reprod* 1988; 39: 39–49.
18. Kok RD, de Vries MM, Heerschap A et al. Absence of harmful effects of magnetic resonance exposure at 1.5 T *in utero* during the third trimester of pregnancy: a follow-up study. *MRI* 2004; 22: 851–854.
19. Coakley FV, Glenn OA, Qayyum A et al. Fetal MRI: A developing technique for the developing patient. *AJR* 2004; 182: 243–252.
20. Sandrasegaran K, Lall C, Aisen AA et al. Fast fetal magnetic resonance imaging. *J Comput Assist Tomogr* 2005; 29: 487–498.
21. Levine D. Safety of MR imaging in pregnancy. In: Levine D, ed. *Atlas of fetal MRI*. London: Taylor and Francis, 2005.
22. Kumar S, O'Brien A. Recent developments in fetal medicine. *Br Med J* 2004; 328: 1002–1006.
23. Schueler AO, Hosten N, Bechrakis NE et al. High resolution magnetic resonance imaging of retinoblastoma. *Br J Ophthalmol* 2003; 87: 330–335.

# Future directions

A. Linn Murphree

## A GLOBAL SURVEY OF WHERE WE ARE

Before we can take a look at the future in the diagnosis, management, and prevention of retinoblastoma, it is important to make a cold, dispassionate global survey of where we are now (late 2006) in the management of this disease. The results are not encouraging. In spite of the fact that *RB1* was the first human cancer gene to be cloned, in the 20 years since that momentous event we have made distressingly little, if any, progress in improving treatment as a result of 'having the gene.' We are, however, able to define the *RB1* mutation, but even that significant achievement remains prohibitively costly and time-consuming to the extent that it is not yet a routine part of patient care even in the developed world. At a much more basic level, we know almost nothing about the etiology of the non-heritable form of retinoblastoma, which probably accounts for 80% of cases of this disease worldwide.

Countries of the developed world, including North America, Europe, Russia, Japan, Australia, and New Zealand, are the source of probably 90% of the papers published on retinoblastoma each year, but are home to only about 5% of the world's estimated 20 000 retinoblastoma cases. Toxic, non-specific systemic chemotherapy given without regard for cost (Box 83.1) is presented to physicians in developing countries as the treatment of choice. However, there is little evidence that salvage of vision and the eye with retinoblastoma in 2006 is much better than it was in 1986, when external beam radiotherapy, another toxic, non-specific and expensive treatment, was the treatment of choice according to some 'first world' authors. We do know that we are doing emotional and psychic harm. We are creating bona fide cases of post-traumatic stress in children undergoing repeated chemotherapy and the 30 or 40 anesthetics that are part of the current treatment for intraocular disease.

**Late diagnosis** Even among the approximately 5% (1000 patients) of the world's retinoblastoma patients who will be diagnosed and treated in the developed countries in 2006, 75% will present with advanced intraocular disease (Groups C–E). That, too, is essentially unchanged in the last 30 years in the developed world. The problem of late or delayed diagnosis is even worse in developing countries with large populations of economically disadvantaged people. Lack of access to medical facilities, lack of education about the need for early medical attention, and cultural resistance to enucleation continue to contribute to an epidemic of extraocular disease at diagnosis.

**Social and environmental causes of non-heritable retinoblastoma** The authors of Chapter 67 presented the evidence

for a major role of poor living conditions and maternal infections as causal events in the etiology of non-heritable (environmental) retinoblastoma. This evidence and other basic science evidence suggest that the factors causing the somatic mutations required for the development of environmental retinoblastoma take place while the child is in utero. Maternal diets deficient in fruit and vegetables and maternal infection with the human papillomavirus (HPV) have both been implicated as causal agents (Chapter 67).

## High birth rate and high retinoblastoma incidence rate in developing countries

The birth rate in most of the countries in the developed world is no longer sufficient to maintain the current population. In contrast to a fertility rate of less than two (the number of children per average mother) in developed countries, in some countries of Africa the fertility rate is as high as six (Fig. 83.1). Almost 90% of the world's births occur in economically underdeveloped countries. When that is combined with an incidence rate four times higher than in developed countries, the estimate of 20 000 cases of retinoblastoma worldwide is easier to understand.

**Systemic chemotherapy** The adoption of primary systemic chemotherapy (neoadjuvant chemotherapy or chemoreduction) for the treatment of intraocular retinoblastoma can hardly be considered a great leap forward. Systemic chemotherapy is a non-specific, sledgehammer approach to treating intraocular disease. It is dosed by the child's body weight. The two eyes weigh a combined total less than 15 g; for a 10 kg (10 000 g) child, the dose of chemotherapy given for the 9985 g of body weight that does not include the eyes contributes solely to systemic toxicity. For the sake of this argument the assumption is that the chemotherapy is solely for treating intraocular disease and not for the prevention of micrometastatic disease.

The 3–4-week cycle of chemotherapy administration is not used because this dosing regimen has been shown to be the most effective in controlling the intraocular tumor: it is used to allow the body, specifically the bone marrow, time to recover from the toxic effects of the chemotherapy. It is not important to know what the best drug delivery regimen would be for intraocular tumor control, as the limiting factor is systemic toxicity.

One valuable principle introduced by the use of systemic chemotherapy has been the concept of multimodality therapy for the control of cancer. Ophthalmologists had contributed to retinoblastoma being treated with a single modality combined with observation. The fact that retinoblastoma is exquisitely available for observation has,



historically, been a negative factor in the adoption of principles of cancer therapy that are universally accepted in other disciplines.

**External beam radiotherapy** The solution to the problems of systemic chemotherapy are unlikely to be solved by turning back the clock for two decades and widely reintroducing primary radiation therapy for the management of retinoblastoma. Technological advances have been made in this field, with more precise control of the beam through better collimation and tighter isodose curves. One possible downside to these newly introduced techniques is that a larger field of normal tissue may receive low-dose radiation. There is no evidence that this might not be a factor in the induction of non-ocular malignancies. Radiation is a non-specific, toxic and expensive modality that, like systemic chemotherapy, will probably have a supporting role to play in the future management of intraocular retinoblastoma.

### BOX 83.1 Cost of Chemotherapy for Retinoblastoma

- Six cycles (5 months) of systemic chemotherapy (carboplatin, etoposide, and vincristine) administered as an outpatient in an American pediatric cancer center costs approximately \$200,000
- This includes the pretreatment work-up, the placing of a central line, and two hospitalizations of 1 week each for sepsis
- It does not include the cost of six to eight EUAs during the time of treatment, nor the cost of local consolidation therapy
- It also does not include the cost of maintaining the family at the treatment center, or the loss of wages and income of the family

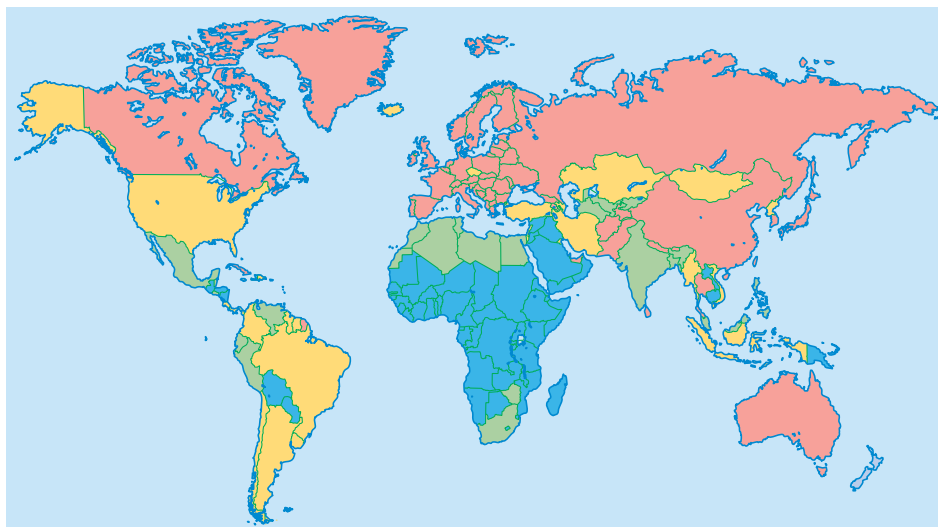
**Enucleation** Enucleation is an excellent, efficient, and cost effective treatment for intraocular retinoblastoma, especially for unilateral disease. Publications from retinoblastoma centers in developed countries have implied that enucleation can be avoided by the use of systemic chemotherapy. If an eye has little chance of vision and advanced intraocular disease (disseminated tumor) is present, the expense and toxicity of systemic chemotherapy argues strongly against its use.

### A LOOK TO THE FUTURE

A strategic assessment of future needs resulted in the identification of the following six strategic goals:

1. The introduction of programs to insure early detection of intraocular disease in all parts of the world.
2. The elimination of maternal diet deficiencies through dietary supplements and endemic human papillomavirus infection through the creation of a vaccine.
3. The creation of more specific, targeted and local administration strategies for multimodality therapy of intraocular disease.
4. The adoption of a common and universally used stage and group classification.
5. The development of inexpensive, automated RB1 gene testing.
6. The development of a rational targeted approach to the prevention and treatment of metastatic disease.
7. Progress is being made toward some of these goals.

**Goal 1: Introduce programs to educate the general population and primary care providers about the early signs of intraocular retinoblastoma** Programs targeting the reduction in the number of cases with delayed diagnosis are proving effective in mid-developed countries such as Mexico, Brazil, and Argentina.



**Fig. 83.1** World map illustrating world fertility rates (children per family) for 1997. Countries in red have a fertility rate less than 2. The long-term impact is a declining population. Spain has the world's lowest fertility rate, at 1.12. Countries in yellow have a stable population. Population in green countries is growing, with a fertility rate between 3 and 4. Countries in blue have a fertility rate over 4 and a rapidly growing population. (Data source: United Nations Department of Economic and Social Affairs, Population Division. Abortion policies: a global review, 2001). Map from The Pregnant Pause website: <http://www.pregnantpause.org/numbers/fertility.htm>.

In both Mexico and Brazil, public service television announcements and public billboards have made the general population aware that a white glow in one or both eyes may be a sign of cancer. Both countries have websites dedicated to education of the general population as well as primary care physicians on ways to screen for and detect intraocular retinoblastoma before it has spread out of the eye. At a recent World Ophthalmology Congress in São Paulo, evidence was presented that there has been a decrease in late diagnoses, probably as a direct result of these programs. Similar programs could be cloned to developing countries in Africa and southern Asia.

**Goal 2: Eliminate maternal diet deficiency and papillomavirus infections** If the view of this problem were from the offices of a UN public health officer, the first target that could be reasonably accomplished is the elimination of maternal diet deficiency on a scale similar to the elimination of vitamin A deficiency in Indonesia several decades ago. This goal makes the assumption that the preliminary data supporting a role for both maternal diet deficiency and human papillomavirus infection in the etiology of the non-heritable form of retinoblastoma is confirmed. If these data are confirmed, a program of distribution of prenatal vitamins and an effective vaccine against human papillomavirus infection should have a dramatic impact on the disproportionately high incidence of environmental retinoblastoma, especially in Africa and Southeast Asia.

**Goal 3: Develop targeted, locally delivered, less toxic, and less expensive therapeutic approaches to intraocular disease** There are sufficient data to conclude that non-specific systemically administered therapy such as systemic chemotherapy is only an interim solution. While systemic chemotherapy for one or two cycles may be necessary to reduce the size of a large intraocular lesion, experimental therapeutics targeting the pathways involving the inactivation of the RB1 gene product and associated peptides are beginning to appear. These targeted, locally administered therapeutic approaches hold promise for less toxic and less expensive therapy.

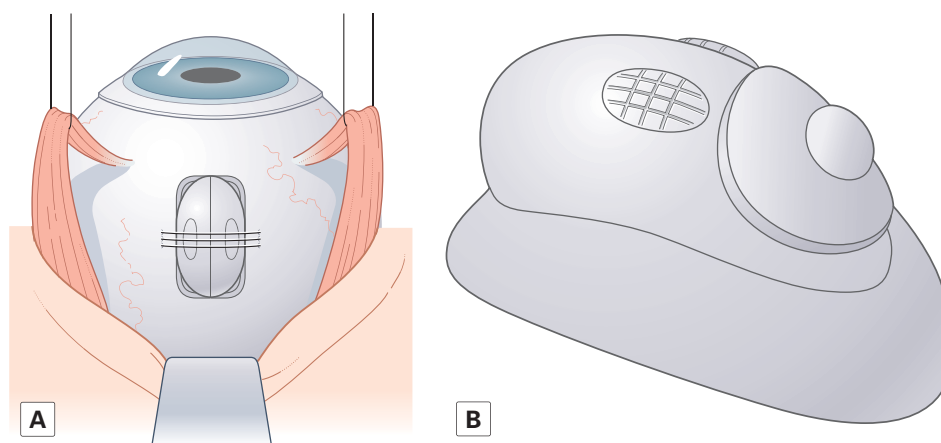
Local delivery of therapeutic agents to the retina and posterior vitreous is currently a goal in the management of AMD and other disorders. Numerous authors have described systems to accomplish trans-scleral delivery of therapeutic agents to the interior of the eye.<sup>1-12</sup> Agents as

large as PEDF and ovalbumin appear to cross the sclera in a passive way.<sup>1</sup> Local delivery of effective but systemically toxic agents might bring otherwise good agents back into clinical use.

Most eyes are lost to retinoblastoma because of dissemination of the tumor into the vitreous and subretinal space. There is a great need to consistently achieve therapeutic levels of therapeutic agents on a regimen that is not limited by systemic toxicity. The chemotherapeutic agents currently used (carboplatin, etoposide, and vincristine) are small molecules and should enter the eye easily in an appropriate trans-scleral delivery system. Carvalho and colleagues<sup>13</sup> have described a promising closed trans-scleral delivery system that consists of a small, impermeable refillable silicone reservoir that can be firmly attached to the episclera with minimally invasive conjunctival surgery (Fig. 83.2). Once in place the reservoir can be filled and refilled as often as necessary by simple transconjunctival injections. These authors have demonstrated the superiority of this trans-scleral protected delivery system in delivering agents to the posterior vitreous and retina when directly compared to agent delivery via subTenon injection.<sup>13</sup> In addition, much less delivered agent gains access to the plasma. As many as four of the reservoirs can be attached to the episclera of a single eye, allowing the concurrent delivery of multimodality therapy. The simplicity of the placement and recharging of the reservoir, the sustained delivery of high levels of agent to the vitreous and the posterior retina, and the potential for an inexpensive route for delivering tumor-targeted biotherapies makes this type of trans-scleral delivery very promising.

The large body of data evaluating systems associated with surgery to place drug reservoirs inside the eye is not considered in this chapter. It is possible that very small needles, such as 32 gauge, may be used to safely deposit therapeutic agents inside the eye. The practical problem with injection is the expense and the level of expertise required. Both factors make this approach unlikely to be widely adopted in the treatment of retinoblastoma, especially in countries with developing economies where improved therapeutic approaches are most needed.

**Goal 4: Adoption of a universally used stage and group classification** As discussed in Chapter 69, there has been a broad international movement to adopt the International Stage and Group Classification. Four COG retinoblastoma protocols based on this



**Fig. 83.2** Schematic of the eye (not to scale) that shows the positioning of the episcleral reservoir (A). This image shows a rigid reservoir held in place by scleral sutures. The most current version of the reservoir is made of flexible silicone. Indenting the reservoir creates a suction that securely attaches the implant to the sclera. Tissue adhesive can also be used to assist in maintaining its position. A higher magnification of the implant (B). The round soft refill port can be palpated through the overlying conjunctiva for refilling of the reservoir with a small 30 gauge needle.

classification are open and recruiting patients. The use of a common language will greatly facilitate the comparison of outcomes across populations.

**Goal 5: Development of an automated, inexpensive screening examination for RB1 mutations** The universal availability of quick and inexpensive screening for RB1 mutations in the germline would transform the clinical care of retinoblastoma. The NIH Office of Rare Diseases (ORD) was established by statute in the Rare Diseases Act of 2002. Its goal is to stimulate and coordinate research on rare disease and to support research to respond to the needs of patients with a rare disease. The effort to develop automated and inexpensive screening for RB1 mutations could be a joint effort by the ORD and other governmental and non-governmental agencies.

**Goal 6: Employing metastasis suppressor genes to prevent metastases** The largest problem facing physicians who care for patients from disadvantaged populations with retinoblastoma

is the late presentation with extraocular and metastatic disease. The paradigm pursued to treat metastatic disease in developed countries (massive chemotherapy, radiation, and bone marrow rescue) is unlikely to be transferable to those locales where resources are severely limited. A different approach is therefore needed for patients at high risk for metastatic disease in those environments. During the last 5 years researchers have described a class of genes called metastasis genes and metastasis suppressor genes.<sup>14–23</sup> These genes affect the ability of cancer cells to establish growth foci in locations distant from the primary cancer but do not affect the primary tumor itself. In prostate cancer, for example, there is evidence that the presence of tumor cells at distant sites is not an uncommon finding. Data in that tumor suggest that growth of the tumor cells at the distant site, however, is very inefficient.<sup>23</sup> The exploitation of these genes and pathways to block growth at distant sites hold promise for precisely targeted therapy, especially among populations unable to support the massive non-specific, resource-intensive therapy commonly employed in developed countries.

## REFERENCES

- Amaral J, Fariss RN, Campas MM et al. Transscleral-RPE permeability of PEDF and ovalbumin proteins: implications for subconjunctival protein delivery. *Invest Ophthalmol Vis Sci* 2005; 46: 4383–4392.
- Ambati J, Adamis AP. Transscleral drug delivery to the retina and choroid. *Prog Retin Eye Res* 2002; 21: 145–151.
- Ambati J, Gragoudas ES, Miller JW et al. Transscleral delivery of bioactive protein to the choroid and retina. *Invest Ophthalmol Vis Sci* 2000; 41: 1186–1191.
- Cruysberg LP, Franklin AJ, Sanders J et al. Effective transscleral delivery of two retinal anti-angiogenic molecules: carboxyamido-triazole (CAI) and 2-methoxyestradiol (2ME2). *Retina* 2005; 25: 1022–1031.
- Cruysberg LP, Nuijts RM, Gilbert JA et al. In vitro sustained human transscleral drug delivery of fluorescein-labeled dexamethasone and methotrexate with fibrin sealant. *Curr Eye Res* 2005; 30: 653–660.
- Geroski DH, Edelhauser HF. Transscleral drug delivery for posterior segment disease. *Adv Drug Del Rev* 2001; 52: 37–48.
- Hauber FA, Scherer WJ. Influence of total energy delivery on success rate after contact diode laser transscleral cyclophotocoagulation: a retrospective case review and meta-analysis. *J Glaucoma* 2002; 11: 329–333.
- Lam TT, Fu J, Chu R et al. Intravitreal delivery of ganciclovir in rabbits by transscleral iontophoresis. *J Ocul Pharmacol* 1994; 10: 571–575.
- Li SK, Jeong EK, Hastings MS. Magnetic resonance imaging study of current and ion delivery into the eye during transscleral and transcorneal iontophoresis. *Invest Ophthalmol Vis Sci* 2004; 45: 1224–1231.
- Myles ME, Neumann DM, Hill JM. Recent progress in ocular drug delivery for posterior segment disease: emphasis on transscleral iontophoresis. *Adv Drug Del Rev* 2005; 57: 2063–2079.
- Okabe K, Kimura H, Okabe J et al. Effect of benzalkonium chloride on transscleral drug delivery. *Invest Ophthalmol Vis Sci* 2005; 46: 703–708.
- Robinson MR, Lee SS, Kim H et al. A rabbit model for assessing the ocular barriers to the transscleral delivery of triamcinolone acetonide. *Exp Eye Res* 2006; 82: 479–487.
- Carvalho R, Krause ML, Murphree AL et al. Delivery from episcleral exoplants. *Invest Ophthalmol Vis Sci* 2006; (In press).
- Zhang G, He B, Weber GF. Growth factor signaling induces metastasis genes in transformed cells: molecular connection between Akt kinase and osteopontin in breast cancer. *Mol Cell Biol* 2003; 23: 6507–6519.
- Weber GF. The metastasis gene osteopontin: a candidate target for cancer therapy. *Biochim Biophys Acta* 2001; 1552: 61–85.
- Wang J, Levenson AS, Satcher RL Jr. Identification of a unique set of genes altered during cell-cell contact in an in vitro model of prostate cancer bone metastasis. *Int J Mol Med* 2006; 17: 849–856.
- Hartl M, Karagiannidis AI, Bister K. Cooperative cell transformation by Myc/Mil(Raf) involves induction of AP-1 and activation of genes implicated in cell motility and metastasis. *Oncogene* 2006; 25: 4043–4055.
- Yu Y, Davicioni E, Triche TJ, Merlino G. The homeoprotein six1 transcriptionally activates multiple protumorigenic genes but requires ezrin to promote metastasis. *Cancer Res* 2006; 66: 1982–1989.
- Fu WN, Shang C, Huang DF et al. Average 12.9 chromosome imbalances coupling with 15 differential expression genes possibly involved in the carcinogenesis, progression and metastasis of supraglottic laryngeal squamous cell cancer. *Zhonghua Yi Xue Yi Chuan Xue Za Zhi* 2006; 23: 7–11.
- Okaji Y, Tsuno NH, Kitayama J et al. Effects of down-regulating the Id genes in human colorectal cancer cells on early steps of haematogenous metastasis. *Eur J Cancer* 2006; 42: 668–673.
- Berger JC, Vander Griend DJ, Robinson VL et al. Metastasis suppressor genes: from gene identification to protein function and regulation. *Cancer Biol Ther* 2005; 4.
- Keller ET. Metastasis suppressor genes: a role for raf kinase inhibitor protein (RKIP). *Anticancer Drugs* 2004; 15: 663–669.
- Kauffman EC, Robinson VL, Stadler WM et al. Metastasis suppression: the evolving role of metastasis suppressor genes for regulating cancer cell growth at the secondary site. *J Urol* 2003; 169: 1122–1133.



# Examination techniques

Mehryar Taban and Julian D. Perry

## INTRODUCTION

The evaluation of a patient with suspected orbital neoplasia begins with a detailed history, and is followed by a physical examination so as to exclude simulating lesions. Special orbital and paranasal sinus examination techniques can help establish tumor location, infer histopathology, and direct further studies.

## HISTORY

The history aids in establishing a probable diagnosis and in guiding the initial work-up and therapy. Important historical elements will be discussed in Chapter 88.

## EXAMINATION

### Visual inspection

**External examination** The examiner should inspect the patient visually for symmetry of periocular structures, such as the brows, eyelids, canthi, and surrounding soft tissues. Visual inspection should include observation for obvious globe deviation.

**Pupils** All patients with suspected orbital disease should undergo the swinging flashlight test to determine the presence or absence of an afferent pupillary defect. Optic nerve function is further characterized by testing of visual acuity, color plates, and confrontational fields. The efferent pupillary pathway should be tested as well. Anisocoria should be recorded as worse in light (parasympathetic defect) or in dark (sympathetic defect), and pharmacologic testing can be performed. Tumors of the lateral orbit may impair ciliary body function to produce a parasympathetic defect, whereas cavernous sinus or superior orbital fissure tumors may result in sympathetic dysfunction.

**Extraocular motility** Ductions and versions are tested in each patient. The cover–uncover test is performed in each cardinal position to measure any phoria or tropia. Patients with suspected restrictive disease may undergo forced duction testing. Classically, after a drop of topical anesthetic is placed, a cotton-tipped applicator soaked in cocaine 10% solution is applied to the muscle away from the direction of gaze limitation for approximately 1 minute. The anesthetized muscle is then grasped firmly with toothed forceps and rotated toward the direction of gaze limitation. Resistance indicates a restrictive disorder. Fields of single vision and double vision can be mapped using a penlight or a kinetic perimeter. Infiltrative orbital tumors may result in restriction, whereas space-occupying tumors may cause paresis.

**Eyelid position and function** Eyelid position is characterized by the marginal reflex distances (MRD). The MRD<sub>1</sub> represents the distance from the center of the upper eyelid margin to the corneal light reflex in millimeters. The MRD<sub>2</sub> represents the distance from the center of the lower eyelid margin to the corneal light reflex. Levator function is measured as the extent of upper eyelid excursion from downgaze to upgaze with the brows fixated. If present, scleral show is measured from each limbus to the corresponding eyelid margin with the eye in the primary position. Upper eyelid ptosis may imply either mechanical involvement of the levator muscle or palsy, whereas eyelid retraction suggests a thyroid or CNS disorder.

The upper eyelid should be everted to inspect the palpebral lobe of the lacrimal gland, especially in the presence of superotemporal fullness. Lymphoma can result in a salmon-colored conjunctival mass that is only visible on inspection of the fornix.

**Globe position** The Hertel exophthalmometer quantifies the anterior protrusion of the eye by measuring the distance in millimeters from the lateral orbital rim to the front surface of the cornea. The Luedde exophthalmometer measures globe protrusion unilaterally from the lateral orbital rim. It consists of a prism bar with millimeter markers on one surface and a view of the corneal surface on the other. The Naugle exophthalmometer measures anterior globe position relative to the superior and inferior orbital rims. This method provides accurate assessment for patients with lateral rim fractures or defects. Horizontal and vertical globe displacement is measured in millimeters from the central pupil to vertical midline and horizontal canthal line, respectively. The McCoy Facial Trisquare (Paget Instrument Co., Kansas City, MO) provides quick and accurate measurements when viewed superimposed over the face (Fig. 84.1).

**Palpation** The examiner should palpate any abnormal areas for tenderness or a mass, assess the degree of resistance to retropulsion of each globe, and check for local adenopathy.

**Resistance to globe retropulsion** The examiner places both forefingers over the anterior portion of the globe with the eyelids closed and gently pushes posteriorly on the globe. The degree of resistance is recorded on a relative scale. Orbital mass lesions often produce increased resistance to manual globe retrodisplacement.

**Slit lamp examination** The slit lamp examination typically focuses on the corneal surface and the posterior pole in patients with

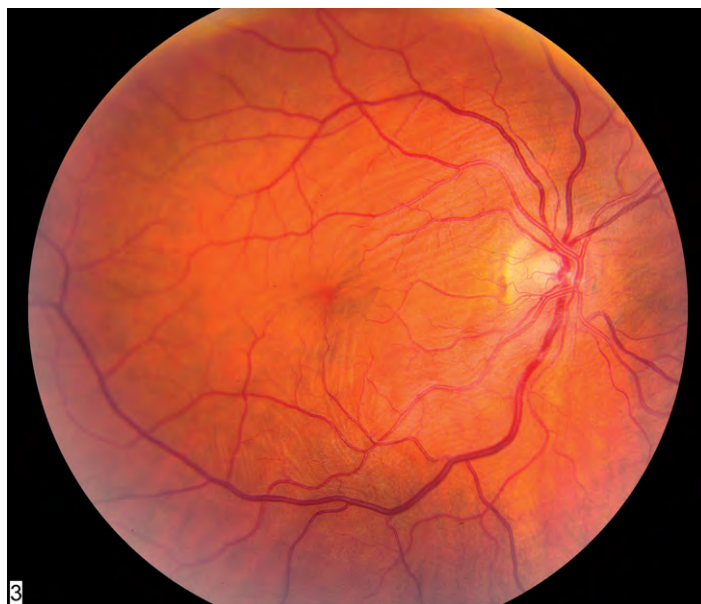

**Fig. 84.1** Types of exophthalmometer. Hertel (A); Naugle (B). Note that the Naugle instrument rests on the forehead and cheek, whereas the Hertel rests in the lateral canthus.

a suspected orbital neoplasm. The corneal surface is evaluated for signs of exposure, and the posterior pole is evaluated for signs of ocular or optic nerve compression or congestion.

**Fundus examination** Orbital mass lesions may result in choroidal folds, optic disc edema, pallor, or shunt vessels (Fig. 84.2).

**Cranial nerves V and VII** Sensation to light touch in each dermatome of the trigeminal nerve is tested using a tissue, including testing of the corneal blink reflex. Each motor branch of the facial nerve is evaluated. Bell's phenomenon testing is performed in all patients with lagophthalmos.



**Fig. 84.2** Slit lamp photograph demonstrates choroidal folds caused from an intraconal cavernous hemangioma.

**Lacrimal system** Secretory function is measured with Schirmer's test. Excretory function is determined by irrigation with or without Jone's test.

**Nasal endoscopy** Intranasal examination using a 0° 4-mm endoscope can detect intranasal disease causing secondary orbital or lacrimal signs.

## SUMMARY

Each step of the examination aids in disease localization and characterization to ultimately help formulate a treatment plan.

# Imaging techniques

Patrick De Potter

## INTRODUCTION

Ultrasonography, color Doppler imaging, CT and MR imaging are the most important imaging tools for the clinician in the field of orbital oncology. Catheter diagnostic angiography has a limited role in the diagnostic approach to orbit lesions, except for evaluating vascular abnormalities suggesting the diagnosis of carotid cavernous fistula. The role of positron emission tomography with [2-18F] fluoro-2-deoxy-D-glucose (FDG) in evaluation of orbital tumors is limited because FDG accumulates in extraocular muscles in proportion to their contractile activities and decreases lesion conspicuity in regions with high physiological tracer uptake.

## TECHNIQUES OF ORBITAL IMAGING

**Ultrasonography** is a non-invasive simple, fast, and economical imaging technique that allows easy detection of an orbital lesion before any decision can be made as to whether further evaluation with CT or MRI is necessary. However, it is limited by the requirement for skilled operators and because penetration of the deeper regions of the orbit at energy levels acceptable for the retina cannot be achieved (Table 85.1).

Although A- and B-mode orbital ultrasonography may provide good information about the acoustic inner texture of an orbital lesion, it is difficult to differentiate normal from abnormal tissues and it remains a semi-quantitative approach for tissue characterization (reflectivity and sound attenuation). Dynamic or real-time information represents one of the advantages of ultrasonography over CT and MRI. The relationships of a pathologic process to the normal anatomic structures can be easily shown by evaluating the same section with different gaze directions, particularly in cases of intraconal lesions. Extension to the orbital walls, especially when associated with erosion or destruction of bone, however, is better appreciated by CT. There are no studies of the relationship between reflectivity and histopathology in the orbit, but most orbital lesions display less coarse and heterogeneous structures with lower reflectivity than the normal orbital tissues (Fig. 85.1).<sup>1,2</sup>

**Color Doppler Imaging (CDI)** has proved to be effective in the display of the normal orbital and intraocular vasculature, tumor vascularization, and echographic differentiation of tumors from subretinal hemorrhage.<sup>3</sup> In patients with carotid-cavernous fistula or dural cavernous arteriovenous malformations, CDI clearly demonstrates the dilated, arterialized superior ophthalmic vein with high-velocity blood flow towards the transducer.<sup>4</sup> In addition, CDI may be able to

differentiate meningioma from glioma of the optic nerve. It may also be effective in confirming the diagnosis of orbital varices by showing the dynamic changes throughout inspiration and expiration.<sup>5</sup>

**Computed Tomography** The basis of computed tomography (CT) is the measurement of different tissue absorption values (Hounsfield units) of a given tissue to neighboring structures, following exposure to X-rays.

**Conventional CT** provides excellent details of the eye, orbital soft tissues, and bony orbit, and has an established role in the evaluation of orbital trauma and orbital diseases (Box 85.1). However, there are several drawbacks, including relatively long exposure times and increased radiation exposure (approximately 75 mGy of radiation). Although reconstructions in the sagittal and coronal planes can be obtained from conventional CT data, these images are of poor quality under practical conditions (Table 85.2).

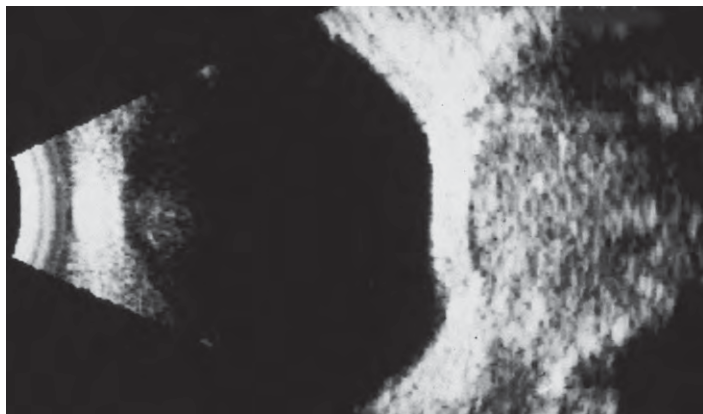
**Helical CT** studies have evolved to a spiral (helical) technique with multiple detectors or a rotating detector system. Helical CT, also known as spiral or volume acquisition CT, acquires data in a continuous fashion. With the use of image-reconstruction algorithms, multiple very thin-sectioned and multiplanar computer-reformatted images can be produced that are superior to those obtained from standard incremental axial CT images. By producing planar and three-dimensional reformations with less motion artifact than conventional CT, helical CT provides useful information in almost any plane. If bony involvement is clinically suspected, bone algorithm reconstruction (bone window) should be used (Fig. 85.2).<sup>6-8</sup> In addition, acquisition time is reduced, a great advantage with children and unstable patients.<sup>6-8</sup>

**Three-dimensional (3D) CT** a computerized post-processing technique, allows a unique topographic overview of selected anatomic or pathologic structures that have been isolated (a process called segmentation) from the image tissue volume.<sup>9</sup> For 3D CT imaging of the head and orbits, scanning technique with either 1.5-mm contiguous slices or 1-mm slices at 1.5-mm slice incrementation is recommended. Owing to partial volume averaging, the thin medial wall, the orbital floor, and the anterior wall of the maxillary sinuses are not visualized, causing artificial holes often referred as pseudoforamina. Special processing techniques and sophisticated edge detection algorithms may be used to avoid these imaging artifacts. Low-contrast tissue segmenta-



**Table 85.1 Acoustic tissue properties in various orbital diseases<sup>1,2</sup>**

Tissue/disease	Acoustic properties		
	Reflectivity at tissue sensitivity	Attenuation	Associated features
Normal orbital fat	Very high (95–100%)	Medium	Multiple interfaces
Orbital inflammation	High (60–95%)	High	
Neurofibroma		Medium to high	
Schwannoma			Low reflectivity areas indicate mucoid spaces
Cavernous hemangioma			Phleboliths
Hemangiopericytoma			
Hematoma – abscess (acute)	Medium (40–60%)	Low	
Lymphangioma		Low	Cystic spaces
Optic nerve glioma		High or medium	
Optic nerve sheath meningioma		High or medium	
Mucocele	Low (5–40%)	Low	
Dermoid			High and low reflectivity areas (fine hair, cartilaginous remnants)
Hematoma – abscess (chronic)			
Lymphoma			Homogeneous at high sensitivity
Malignant tumor	Variable	Variable	

**Fig. 85.1** B-scan ultrasound of cavernous hemangioma displays a well-defined oval echogenic lesion deforming the globe.**BOX 85.1 Indications of Orbital CT**

- Evaluation of patient with proptosis with suspicion of osseous, fibro-osseous, fibrous lesions
- Evaluation of patient with clinical diagnosis of lacrimal gland lesion
- Evaluation of orbital trauma
- Detection of calcification
- Contraindication for MRI (claustrophobia, metallic implants, allergy to contrast agent)

tion as in tumor–muscle or tumor–neural tissue interfaces requires visual identification and manual separation.<sup>9</sup> Three-dimensional imaging of the orbit is a perfect technique to illustrate a wide variety of teratogenic (particularly craniofacial dysplasia and synostosis), pathogenic, traumatic, and iatrogenic orbital abnormalities and

to comprehend the extent and location of the pathology in order to plan the surgical approach and facilitate comparison between pre- and postoperative changes (Fig. 85.2). CT, although excellent for bony detail of the lacrimal drainage system, provides limited soft tissue detail compared to MRI and suffers from image degradation in out-of-plane images.

**Magnetic resonance imaging (MRI)** is based on a physical phenomenon called the nuclear magnetic resonance effect on the atomic nuclei, primarily hydrogen atoms of water molecules in human tissues. MR images of patients are obtained by inducing electromagnetic signals from the magnetic dipole movements of <sup>1</sup>H nuclei and then converting those signals into cross-sectional images.

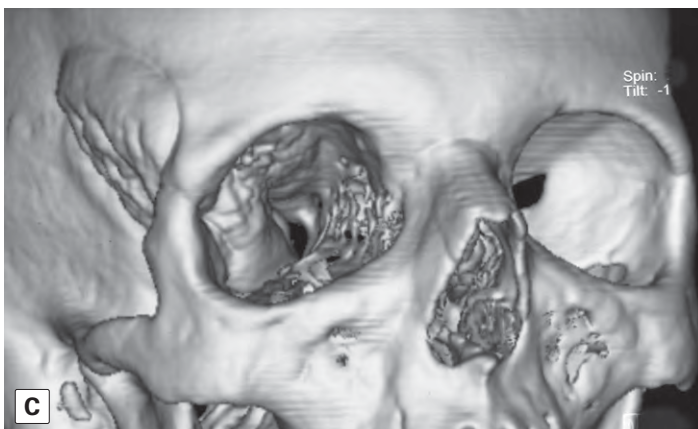
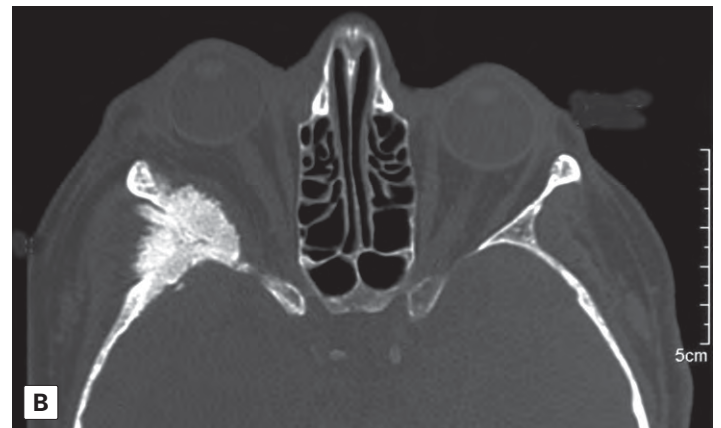
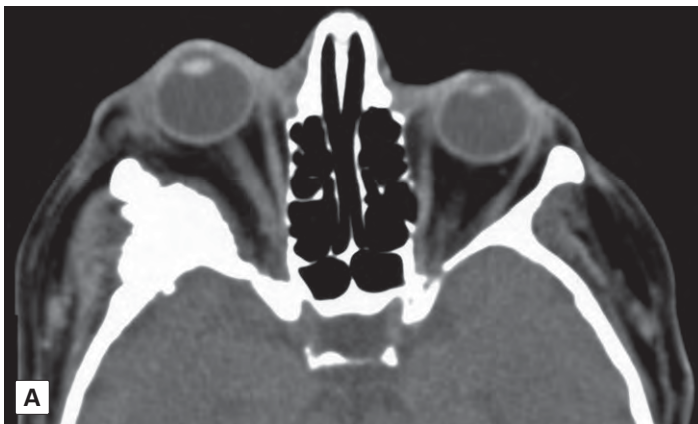Although CT and MRI studies are complementary, MRI provides superior soft tissue contrast. Its multiplanar capability with outstanding tissue contrast and the absence of ionizing radiation make MRI an especially suitable technique for imaging orbital structures (Box 85.2).<sup>7,10,11</sup> Moreover, the superficial location of the eye and eyelids permits the use of surface coils, which improve the display of anatomic details. Current MRI is often performed using 1.5 Tesla units of magnetic strength. The overall scan time can be shortened by fast spin-echo sequences. Fat suppression techniques are used to eliminate the extremely strong bright signal intensity from orbital fat, which may overwhelm high signal intensities of enhancing surrounding lesions.

**INTERPRETATION OF IMAGING STUDIES**

Interpretation of imaging studies is facilitated by evaluating radiological characteristics such as anatomic location, radiological characteristics, including anatomic location, appearance, content, post-contrast enhancement features, and bone characteristics.<sup>7,10–15</sup>

**Location** CT provides similar information to MRI on the location and extent of a lesion in the anterior orbital space, the globe, the intraconal–extraconal space, orbital fat, extraocular muscles, cavernous

Table 85.2 Comparison of various imaging techniques		
Technique	Comparison	
	Advantages	Disadvantages
Ultrasonography	Inexpensive Tissue characterization Dynamic information Evaluation of anterior orbital lesions	Requirement for skilled operator
Computerized tomography	Availability Short examination time	Ionizing radiation Allergic reaction with contrast agents Artifacts: High density foreign body Positioning Partial voluming Beam-hardening
Magnetic resonance imaging	High soft tissue contrast Large imaging depth No ionizing radiation Paramagnetic effects by: Methemoglobin Protein Melanin Gadopentate dimeglumine	Slow acquisition Claustrophobia Obesity Missile and thermal injuries Artifacts: Motion Wrap around Bioinhomogeneity Chemical shifts Partial volume Flow or pulsation



**Fig. 85.2** Axial CT images of a right sphenoid wing meningioma. Helical CT scan showing a right hyperostotic sphenoid wing (A), bone windows (B), and three-dimensional scan (C).

**BOX 85.2 Indications of Orbital MRI**

- Location and extent of orbital lesion
- Evaluation of orbital, intracanalicular, and prechiasmal optic pathways
- Evaluation of patient with proptosis (hemorrhagic, neoplastic, fibrosclerotic, mucinoid/cystic degeneration)
- Evaluation of patient with progressive bluish lid swelling (capillary hemangioma versus lymphangioma)
- Evaluation of tumor response after radiotherapy or chemotherapy
- Evaluation of anophthalmic socket when orbital tumor recurrence is suspected
- Orbital trauma when ferromagnetic material is excluded
- Identification of fibrovascular ingrowth within biocompatible implant

sinus, and temporal fossa. CT remains the imaging modality of choice in the evaluation of lesions located in the lacrimal gland fossa, the paranasal sinuses, and the adjacent bony orbit. Owing to the superior soft tissue contrast resolution of MRI, it is the study of choice for lesions infiltrating the optic nerve, optic nerve sheath, and orbital apex.

**Appearance** An orbital lesion may be described as having a regular (round or oval) or irregular (infiltrative) configuration. Its margin characteristics may be well circumscribed or diffuse.

**Content** Information on the content of the lesion (cystic or solid; homogeneous or heterogeneous) can be obtained by both CT and MR imaging techniques. Both techniques also detect the presence of fluid–fluid or fluid–air levels. When lesion density is higher than that of the vitreous, CT images identify the lesion as solid. As wide range of tissue densities on CT scans or signal intensities on MR images relate to the internal architecture and the presence of proteinaceous or blood products, it is not always possible to differentiate a solid from a cystic orbital lesion. MRI images identify tissue compounds such as melanin, methemoglobin, deoxyhemoglobin, ferritin, and proteinaceous material. Punctate or conglomerate increased densities on CT scans or foci of signal void on MRI may be seen in trauma, vascular tumors, optic nerve sheath tumors (meningioma), epithelial lacrimal gland tumors, and malignant osseous tumors (osteosarcoma). In general, MR images provide more information about the content of the lesion and than do CT images. However, CT is best suited for the detection of calcification.

**Contrast enhancement** The pattern of contrast enhancement (present or absent; homogeneous or heterogeneous) of orbital lesions guides in forming a differential diagnosis. The enhancement characteristics of an orbital lesion are best identified on fat-suppressed post-contrast T<sub>1</sub>-weighted images. No enhancement is documented in hemorrhagic processes, dense scar tissue, fluid collections, or necrotic portions of a tumor. Minimal contrast enhancement suggests a chronic or sclerosing orbital inflammation, tissue fibrosis, or post-therapeutic scar tissue. Moderate to marked contrast enhancement is usually

noticed in solid tumors as well as in acute inflammatory orbital lesions. Linear enhancement surrounding a non-enhancing well-delineated lesion suggests the cystic nature of the lesion. A well-defined linear or void signal within an enhancing lesion may suggest air, high-flow blood vessels (artery or vein), fragments of cortical bone, or foreign body. Gadolinium-enhanced MRI has proved to be the best-suited imaging modality for assessing the progression of fibrovascularization tissue into porous orbital implants (hydroxyapatite and porous polyethylene).

**Bone characteristics** Bone changes induced by an orbital lesion include cortical bony indentation and molding, bone erosion, bone lysis, bone infiltration, and hyperostosis. The destruction of cortical bone is seen on CT as a loss of the highly dense cortical bone and on MRI as a discontinuity of the linear signal void produced by normal cortical bone. CT with bone windows or 3D CT is almost always preferred to assess orbital disorders suspected to affect the bony orbit.

**Bone molding** by a well-circumscribed orbital mass suggests a congenital lesion (dermoid cyst, lymphangioma) or a slowly growing benign tumor (cavernous hemangioma, neurofibroma, neurilemmoma, or benign lacrimal gland tumor).

**Bone erosion** is usually seen with more aggressive inflammatory lesions, primary tumors, and secondary tumors.

**Bone lysis** is observed in very aggressive primary tumors, secondary malignant tumors, and inflammatory lesions (idiopathic orbital inflammation, eosinophilic granuloma).

**Bone infiltration** by the tumor is best seen on CT with bone algorithm reconstruction and identified on MRI as a discontinuity of cortical signal void and loss of high signal intensity of the fat in the bone marrow.

**Hyperostosis** is observed with benign osseous tumors (meningioma), malignant bone tumors (osteosarcoma), and metastatic tumors such as from prostate carcinoma. In general, osseous spiculation and inhomogeneous density are findings suggestive of a malignant tumor.

**RADIOLOGICAL DIFFERENTIAL DIAGNOSIS**

Orbital tumors can be classified into one of seven radiological patterns (well-circumscribed solid, ill-defined solid, circumscribed cystic, enlarged optic nerve, enlarged lacrimal gland, enlarged extraocular muscles, and anomalies of the bony orbit) to obtain a reliable differential diagnosis (Box 85.3).

**Well-circumscribed solid orbital tumors** The most frequent well-circumscribed orbital tumors are cavernous hemangioma, neurilemmoma, neurofibroma, fibrous histiocytoma, and hemangiopericytoma.<sup>10–15</sup> These tumors usually present as a well-defined, oval to round intraconal orbital mass on MRI (Table 85.3).

Cavernous hemangioma shows increasing homogeneous enhancement on delayed images owing to the pooling of the contrast material within the tumor. Tumor enhancement and delineation are best evaluated on Gd-DTPA-enhanced T<sub>1</sub>-weighted images using fat suppression techniques (frequency-selective presaturation). Heterogeneity in the



tumor signal may be related to the presence of calcified phleboliths, which produce a signal void on  $T_1$ - and  $T_2$ -weighted images. Neurilemmoma (schwannoma), neurofibroma, fibrous histiocytoma, and hemangiopericytoma may conceivably have identical non-enhancing MR characteristics to less common well-circumscribed orbital lesions, such as lymphoproliferative disorder, metastasis from skin melanoma or carcinoid tumor, capillary hemangioma, orbital varix, and rhabdomyosarcoma (Fig. 85.3).

**Ill-defined solid orbital tumors** The radiological differential diagnosis of common solid ill-defined orbital lesions in children includes capillary hemangioma, lymphangioma, plexiform neurofibroma, idiopathic orbital inflammation, and metastasis.<sup>10–16</sup> In adults idiopathic orbital inflammation, metastasis, primary orbital tumor, and lymphoproliferative disorder are more frequent causes.

### BOX 85.3 Radiological Patterns of Orbital Tumors

- Well-circumscribed solid tumor
- Ill-defined solid tumor
- Circumscribed cystic tumor
- Enlarged optic nerve
- Enlarged lacrimal gland
- Enlarged extraocular muscles
- Anomalies of the bony orbit

There are no specific CT features of ill-defined orbital lesions, but CT provides clues as to the malignant nature or chronic behavior of an orbital mass if bone changes (molding, erosion, lysis, and hyperostosis) are identified on bone windows scans. Radiolucent areas within the tumor may suggest necrotic change.

The increased signal of an inflammatory process is related to its acute stage and its high concentration of free water (Table 85.4). By studying  $T_2$  relaxation times it may be possible to differentiate muscle enlargement caused by inflammatory edema from an infiltrative process. Malignant tumors and occasionally inflammatory lesions may produce bony changes that appear as disruption of the regular signal void of the adjacent cortical bone or as a loss of the high signal of the marrow fat.

Minimal and heterogeneous enhancement is usually observed in the sclerosing type of orbital inflammation, and marked enhancement is observed in the acute type, making their radiological differentiation easier. However, MRI does not provide sufficient histologic tissue specificity to allow reliable differentiation between idiopathic orbital pseudotumor, benign reactive lymphoid hyperplasia, atypical lymphoid hyperplasia, and lymphoma.

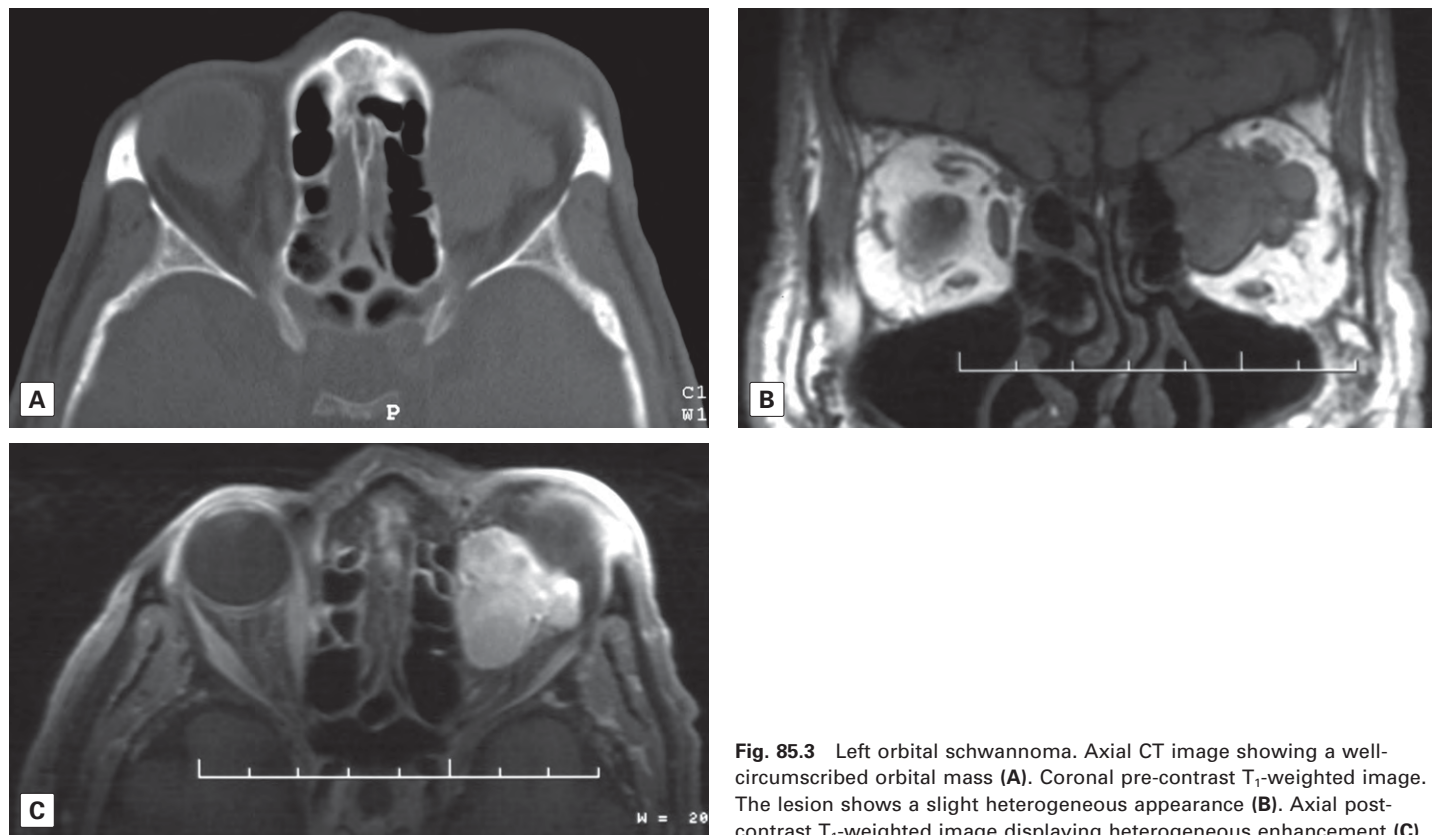
**Well-circumscribed cystic lesions** The differential diagnosis of cystic orbital lesions includes dermoid cyst, colobomatous cyst, teratoma, meningoencephalocele, lymphangioma, acquired inclusion cyst, chronic hematic cyst (cholesterol granuloma), mucocele, subperiosteal hematoma, and parasitic cyst.<sup>10–15,17</sup>

Orbital CT offers excellent information regarding the cystic features of the lesion, as its density is similar to that of the vitreous. However, cystic lesions with higher density (high content of protein, keratinaceous material, blood products) may simulate a solid well-

**Table 85.3 MRI features of well-circumscribed orbital tumors**

Tumor	Lesion appearance Signal intensity*		Degree of enhancement with Gd-DTPA
	$T_1$ -WI	$T_2$ -WI	
Cavernous hemangioma	Homo	Hetero/homo (late)	Homo
	Iso/hyper	Iso/hypo	+++
Neurilemmoma	Hetero	Hetero	Hetero
	Iso/hyper	Iso/hypo	+ /+++
Neurofibroma	Hetero	Hetero	Hetero
	Iso/hyper	Iso/hypo	+ /+++
Fibrous histiocytoma	Hetero	Hetero	Hetero
	Hyper/hypo	Hyper/hypo	++++
Hemangiopericytoma	Homo	Homo	Hetero
	Iso/hyper	Iso/hypo	++++
Orbital varix	Homo/hetero	Homo/hetero	Homo/hetero
	Iso/hyper	Iso/hypo	++++
Thrombosed varix	Hetero	Hetero	Hetero
	Iso/hyper	Iso/hypo	- /+
Orbital metastasis (skin melanoma, carcinoid)	Homo	Homo	Homo
	Iso/hyper	Iso/hypo	+ /+++

\*With respect to vitreous.  
Iso, isointense; Hyper, hyperintense; Hypo, hypointense; Homo, homogeneous; Hetero, heterogeneous.



**Fig. 85.3** Left orbital schwannoma. Axial CT image showing a well-circumscribed orbital mass (A). Coronal pre-contrast T<sub>1</sub>-weighted image. The lesion shows a slight heterogeneous appearance (B). Axial post-contrast T<sub>1</sub>-weighted image displaying heterogeneous enhancement (C).

**Table 85.4** MRI features of ill-defined orbital tumors

Tumor	Lesion appearance Signal intensity*		Degree of enhancement with Gd-DTPA
	T <sub>1</sub> -WI	T <sub>2</sub> -WI	
Orbital metastasis	Homo/hetero Hyper/hypo+/+++	Homo/hetero Iso/hypo	Homo/hetero + /+++
Capillary hemangioma	Homo/hetero Iso/hyper	Homo/hetero Iso/hypo	Homo/hetero +++
Lymphoid proliferative disorder	Homo Hyper	Homo Hypo	Homo +++
Primary orbital tumor	Homo/hetero Hyper	Homo/hetero Hypo	Homo/hetero + /+++
Acute idiopathic inflammation	Homo Iso/hyper	Homo Iso/hypo	Homo +++
Chronic idiopathic inflammation (sclerosing type)	Homo Iso/hyper	Homo Hypo	Homo/hetero - /+

\*With respect to vitreous.  
Iso, isointense; Hyper, hyperintense; Hypo, hypointense; Homo, homogeneous;  
Hetero, heterogeneous.

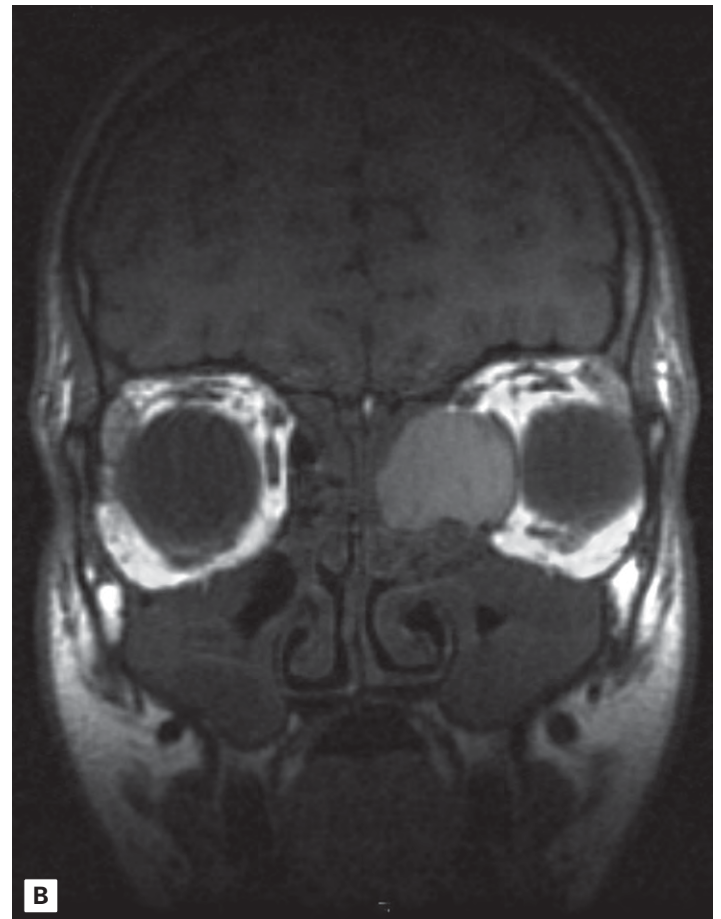
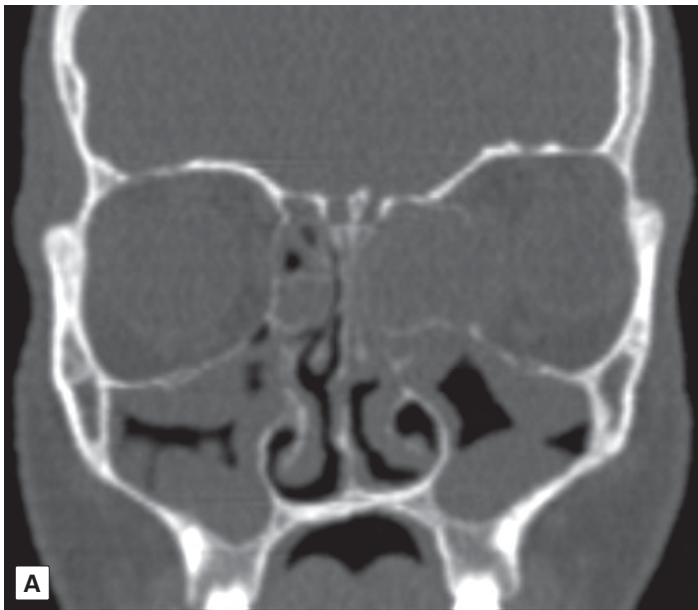circumscribed orbital tumor. MRI studies are more specific than CT in identifying tissue components within the cystic mass, as well as the linear enhancement of the capsule surrounding the non-enhancing lumen of the cyst.

On MRI, the cystic lesions appear as well-defined, round to oval, with variable signal intensities depending on the composition of their

content (Table 85.5). Dermoid cyst may have a characteristic dumb-bell configuration. A fat–fluid level is characteristically seen in dermoid cyst. A fluid–fluid level is suggestive of subacute hemorrhagic lymphangioma or hemorrhagic cyst, with the superior aspect of the cyst containing the methemoglobin released from the lysed erythrocytes and the dependent portion containing the settled cellular

Table 85.5 MRI features of cystic orbital lesions			
Tumor	Lesion appearance Signal intensity*		Degree of enhancement with Gd-DTPA
	<i>T</i> <sub>1</sub> -WI	<i>T</i> <sub>2</sub> -WI	
Dermoid cyst	Hetero	Hetero	Lumen –
	Iso/hyper	Iso/hypo	Capsule, septa +
Epithelial cyst	Homo	Homo	Lumen –
	Iso/hyper	Iso/hypo	Capsule, septa +
Mucocele	Homo	Homo	Lumen –
	Iso/hyper	Iso/hypo/hyper	Capsule, septa +
Hemorrhagic cyst/lymphangioma	Hetero	Hetero	Lumen –
	Iso/hyper	Iso/hypo/hyper	Capsule, septa +

\*With respect to vitreous.  
Iso, isointense; Hyper, hyperintense; Hypo, hypointense; Homo, homogeneous;  
Hetero, heterogeneous.



**Fig. 85.4** Left ethmoidal mucocele with bilateral pansinusitis. Coronal CT with bone window suggesting the rupture of the medial orbital wall (A). Coronal pre-contrast *T*<sub>1</sub>-weighted image. The cystic lumen shows high signal intensity owing to the high proteinaceous content (B).

elements of the hemorrhage with intracellular methemoglobin. The increasing concentration of proteinaceous secretions in a mucocele produces a higher signal intensity of the lesion (Fig. 85.4).

**Enlarged optic nerve** The differential diagnosis of an enlarged optic nerve includes juvenile pilocytic astrocytoma, malignant glioma,

secondary spread from intraocular tumor (retinoblastoma, uveal melanoma, melanocytoma), CNS lymphoma, systemic metastatic disease, and optic neuritis.<sup>10–15,18</sup> In all these diseases the optic nerve may assume a tubular, fusiform, lobular configuration. The differential diagnosis of an enlarged optic nerve sheath includes meningioma, meningeal spread of tumor, meningitis, arachnoidal cyst, hemorrhage,



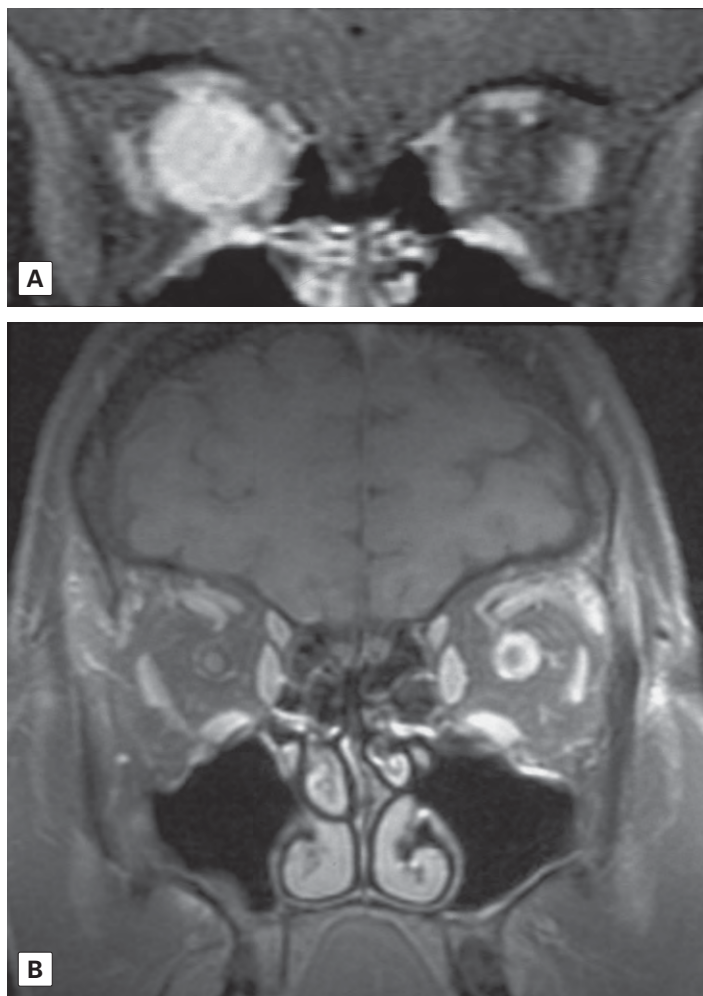
and CSF expansion, as seen with idiopathic intracranial hypertension or orbital apex compression.

The pattern of enhancement of the enlarged optic nerve allows differentiation between an optic nerve lesion and an optic nerve sheath lesion. In optic nerve lesions the enhancement is within the optic nerve, whereas the enhancement is eccentric surrounding a hypointense optic nerve. The characteristic kinking and buckling of the enlarged optic nerve is highly suggestive of juvenile pilocytic astrocytoma (optic nerve glioma). On pre-contrast  $T_1$ -weighted images juvenile pilocytic astrocytoma (JPA) appears isointense with respect to the cerebral gray matter (Fig. 85.5). The tumor may be surrounded by reactive arachnoid hyperplasia, which shows a slightly hypointense signal. On  $T_2$ -weighted images fusiform JPA demonstrates relatively high signal intensity, whereas large lobulated tumors tend to show a more heterogeneous signal. The peripheral hyperintense portion (perineural arachnoid gliomatosis or arachnoidal hyperplasia, or CSF accumulation) surrounds a central linear core of lower signal intensity (compact proliferation of glial cells). On post-contrast studies JPA shows variable enhancement, which can be traced through the optic canal to the chiasm and optic tracts when it involves the intracranial portion of the optic nerve. The non-enhancing peripheral portion of the tumor, which is hyperintense on  $T_2$ -weighted images, probably

represents arachnoidal hyperplasia or an ectatic subarachnoid space around the optic nerve. The perineural arachnoid gliomatosis shows enhancement. Involvement of the optic nerve with retinoblastoma or melanoma cells, lymphoproliferative tissue, and metastatic process are best detected on post-contrast MR studies. In these cases, the pattern of enhancement within the optic nerve may be localized or diffuse.

The intensity pattern of optic nerve sheath meningioma on pre-contrast MRI studies is variable and the tumor may appear iso-, hypo- or hyperintense with respect to the optic nerve on  $T_1$ - and  $T_2$ -weighted images. On post-contrast films the tumor shows marked enhancement, which characteristically take a rim or eccentric pattern surrounding the non-enhancing optic nerve. A small intracanalicular or intracranial extension of the tumor is best identified on post-contrast  $T_1$ -weighted images with fat-suppression techniques. Calcification shows a low signal intensity on  $T_1$ - and  $T_2$ -weighted images without enhancement with Gd-DTPA.

On CT, the tubular or globular enlargement seen with an optic nerve sheath meningioma is non-specific. Tram-tracking, sign in which the denser and thicker optic nerve sheath outlines a central lucency representing the residual optic nerve, is characteristic but not specific to optic nerve sheath meningioma.



**Fig. 85.5** Enlarged optic nerve on coronal post-contrast  $T_1$ -weighted images. Enhancing pattern of juvenile pilocytic astrocytoma within the right optic nerve (A). Rim-like enhancing left optic nerve sheath meningioma (B).

**Enlarged lacrimal gland** Lacrimal gland lesions may be classified as non-epithelial or epithelial. Non-epithelial lesions include inflammation and lymphoid tumors, whereas epithelial lesions include dacryops, pleomorphic adenoma, and malignant epithelial tumors (adenoid cystic carcinoma).<sup>10–15</sup>

Orbital CT is more specific than MRI in the detection of calcification within the enlarged lacrimal gland and in the evaluation of bone destruction in the lacrimal gland fossa. On MRI, among the non-epithelial lesions of the lacrimal gland the inflammatory process (dacryoadenitis) usually appears more ill-defined than a lymphoid infiltrate, which can mold to the globe (Table 85.6). Epithelial tumors of the lacrimal gland usually present as a well-circumscribed mass in the lacrimal gland fossa and produce scalloping of the frontal bone. Adenoid cystic carcinoma may have an irregular, relatively well-defined or infiltrative pattern, with possible evidence of bone destruction.

Calcification within the enlarged lacrimal gland is highly suggestive of adenoid cystic carcinoma and appears as hypointense areas on  $T_1$ - and  $T_2$ -weighted images without enhancement on post-contrast scans.

**Enlarged extraocular muscles** The extraocular muscles can be enlarged by infectious, inflammatory, neoplastic, vascular, and degenerative processes (Table 85.7). Such involvement is usually best seen on post-contrast coronal CT and MR images.<sup>13–16</sup> In thyroid-associated orbitopathy the belly of the extraocular muscles is expanded, and unlike in idiopathic myositis, the tendinous attachment to the globe is usually spared.<sup>19</sup> Neoplastic infiltration (rhabdomyosarcoma, metastasis, lymphoma) may involve the extraocular muscle focally or diffusely, with occasional sparing of the inserting tendon. Tumor necrosis may produce heterogeneous signal intensities. Focal or multifocal nodularity of the extraocular muscle(s) is highly suggestive of metastatic disease (Fig. 85.6).<sup>13–16</sup>

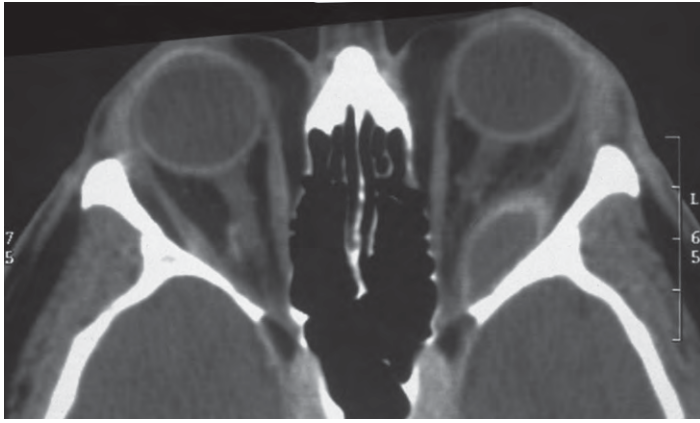
**Anomalies of bony orbit** CT remains the imaging modality of choice for the evaluation of bone abnormalities (scalloping, deformity,

Table 85.6 MRI features of lacrimal gland lesions			
Tumor	Lesion appearance Signal intensity*		Degree of enhancement with Gd-DTPA
	<i>T<sub>1</sub>-WI</i>	<i>T<sub>2</sub>-WI</i>	
Dacryops	Homo	Homo	–
	Iso/hyper	Iso/hypo	
Lymphoid proliferative disorder	Homo	Homo	Homo
	Hyper	Hypo	+ /+++
Acute idiopathic inflammation (dacryoadenitis)	Homo	Homo	Homo
	Iso/hyper	Iso/hypo	+++
Chronic idiopathic inflammation (sclerosing type)	Homo	Homo	Homo/hetero
	Iso/hyper	Hypo	– /+
Pleomorphic adenoma (benign mixed tumor)	Homo	Homo	Homo
	Iso/hyper	Iso/hypo	+++
Adenoid cystic carcinoma	Homo/hetero	Homo/hetero	Homo/hetero
	hyper	Hypo	+ /+++

\*With respect to vitreous.  
Iso, iso-intense; Hyper, hyperintense; Hypo, hypointense; Homo, homogeneous;  
Hetero, heterogeneous.

Table 85.7 MRI features of enlarged extraocular muscles				
Entity/tumor	Extent of involvement	Lesion appearance Signal intensity*		Degree of enhancement with Gd-DTPA
		<i>T<sub>1</sub>-WI</i>	<i>T<sub>2</sub>-WI</i>	
Thyroid orbitopathy	Uni/bilateral	Homo	Homo	Homo
	Single/multiple Tendon (+)	Hyper	Iso/hypo	+ /+++
Idiopathic myositis	Uni/bilateral	Homo	Homo	Homo
	Single/multiple Tendon (+)	Hyper	Iso/hypo	+ /+++
Rhabdomyosarcoma	Unilateral	Homo/hetero	Homo/hetero	Homo/hetero
	Single/multiple Tendon (+/-)	Iso/hyper	iso/hypo	
Metastasis	Uni/bilateral	Homo/hyper	Homo/hetero	Homo/hetero
	Single/multiple Tendon (+/-)	Hyper	hypo	– /+++
Lymphoma	Uni/bilateral	Homo	Homo	Homo
	Single/multiple Tendon (+/-)	Hyper	Hypo	+++
Carotid-cavernous fistula	Unilateral	Homo	Homo	Homo
	Multiple Tendon (–)	Hyper	Hypo	+++

\*With respect to vitreous.  
Iso, iso-intense; Hyper, hyperintense; Hypo, hypointense; Homo, homogeneous; Hetero, heterogeneous.



**Fig. 85.6** Focal enlargement of the left lateral rectus muscle by metastatic carcinoid from the lung. The necrotic tumor does not enhance.

hyperostosis, expansion, and bone marrow invasion) as well as osseous, fibro-osseous, and fibrous tumors.<sup>10–15,20</sup> The fact that cortical bone has a signal void permits bone to be demarcated from adjacent tissues on MR imaging. Good contrast is therefore available between bone and orbital fat, muscle, and brain. However, cortical bone may not be clearly defined when it lies adjacent to structures in which signal is not generated, such as air, rapidly flowing blood, dura, or calcification.

Osteosarcoma appears as an ill-defined mass with a heterogeneous, hyperintense signal with respect to the vitreous and gray matter on  $T_1$ -weighted scans. On  $T_2$ -weighted images, the tumor has a heterogeneous lower signal intensity. After Gd-DTPA injection, osteogenic sarcoma demonstrates heterogeneous enhancement. Replacement of the cortical bone and fat marrow as well as orbital and cranial extension are best identified on post-contrast fat-suppressed  $T_1$ -weighted images. CT scans demonstrate an irregular, invasive, and destructive tumor with lytic and sclerotic changes associated with focal areas of calcification.

Fibrous dysplasia displays a sclerotic, homogeneous, dense, ground-glass appearance on CT, but alternate areas of lucency and increased density can also be identified. On MR imaging fibrous dysplasia shows very low signal intensity on  $T_1$ - and  $T_2$ -weighted images.

Aneurysmal bone cysts of the orbit appear as multicystic, loculated masses associated with bone destruction and possible extension to the adjacent sinuses. These tumors have heterogeneous signal intensities and fluid–fluid levels, reflecting the various stages of evolution of the hemorrhagic content. Orbital CT scans show irregular expansion and destruction of bone associated with a mildly enhancing loculated cystic mass.

The major role of MRI in the evaluation of secondary orbital tumors from the paranasal sinuses is to delineate the extent of the infiltrative tumor process within the orbit, the sinuses, and the brain. These malignant tumors are fairly cellular and usually show a low signal intensity on  $T_1$ -weighted images and increased signal on  $T_2$ -weighted images with respect to orbital fat.

## SUMMARY

Ultrasonography, color Doppler, CT and MRI are the most important imaging tools for the clinician in the field of orbital oncology. Although orbital ultrasonography may provide good information about the acoustic inner texture of an orbital lesion, it is difficult to differentiate normal from abnormal tissues. CT provides excellent detail of the eye, orbital soft tissues, and bony orbit, and has an established role in the evaluation of orbital trauma and orbital diseases. Although CT and MR studies are complementary, MRI provides superior soft tissue contrast. Interpretation of imaging studies is facilitated by evaluating radiological characteristics such as anatomic location, appearance, content, post-contrast enhancement features, and bone characteristics. Moreover, orbital tumors can be classified into one of seven radiological patterns (well-circumscribed solid, ill-defined solid, circumscribed cystic, enlarged optic nerve, enlarged lacrimal gland, enlarged extraocular muscles and anomalies of the bony orbit) to obtain a reliable differential diagnosis.

## REFERENCES

- Berges O, Bilaniuk LT. Orbital ultrasonography: ocular and orbital pathology. In: Newton TH, Bilaniuk LT, eds. *Radiology of the eye and orbit*. New York: Raven Press, 1990; Chapter 7.
- Nasr AM, Abou Chacra G. Ultrasonography in orbital differential diagnosis. In: Karcioğlu ZA, ed. *Orbital tumors, diagnosis and treatment*. New York: Springer Verlag, 2005; 73–83.
- Lieb WE. Color Doppler imaging of the eye and orbit. *Radiol Clin North Am* 1998; 36: 1059–1071.
- Karam EZ, Destarac L, Hedges TR, Heggerick PA. Abnormal ophthalmic veins: differential diagnosis and management using color Doppler imaging. *Neuro-Ophthalmology* 1999; 22: 87–96.
- Jacquemin C, Bosley T, Mullaney P. Orbital color Doppler imaging of optic nerve tumors. *Int Ophthalmol* 1999; 23: 11–15.
- Rhea JT, Rao PM, Novelline RA. Helical CT and three-dimensional CT of facial and orbital injury. *Radiol Clin North Am* 1999; 37: 489–513.
- Rosel P. The basics of orbital imaging. In: Karcioğlu ZA, ed. *Orbital tumors, diagnosis and treatment*. New York: Springer Verlag, 2005; 84–93.
- Klevansky A. The efficacy of multiplanar reconstructions of helical CT of the paranasal sinuses. *Am J Roentgenol* 1999; 173: 493–495.
- Zonneveld FW, Vaandrager JM, van der Meulen JHC, Koornneef L. Three-dimensional imaging of congenital disorders involving the orbit. *Radiol Clin North Am* 1998; 36: 1261–1279.
- De Potter P, Shields JA, Shields CL. *MRI of the eye and orbit*. Philadelphia: Lippincott Raven, 1995.
- Wichmann W. Magnetic resonance imaging (MRI). In: Muller-Forell S, ed. *Imaging of orbital and visual pathway pathology*. Berlin: Springer Verlag, 2002; 18–23.
- De Potter. Imaging in orbital differential diagnosis. In: Karcioğlu ZA, ed. *Orbital tumors, diagnosis and treatment*. New York: Springer Verlag, 2005; 94–103.
- Ben Simon GJ, Annunziata CC, Fink J et al. Rethinking orbital imaging. Establishing guidelines for interpreting orbital imaging studies and evaluating their predictive value in patients with orbital tumors. *Ophthalmology* 2005; 112: 2196–2207.
- Bilaniuk LT, Zimmerman RA, Newton TH. Magnetic resonance imaging: orbital pathology. In: Newton TH, Bilaniuk LT, ed. *Radiology of the eye and orbit*. New York: Raven Press, 1990; Chapter 5.
- Char DH, Unsöld R, Sobel DF, Salvolini U, Newton TH. Computed tomography: Ocular and orbital pathology. In: Newton TH, Bilaniuk LT, ed. *Radiology of the eye and orbit*. New York: Raven Press, 1990; Chapter 9.
- Lacey B, Chang W, Rootman J. Nonthyroid causes of extraocular muscle disease. *Surv Ophthalmol* 1999; 44: 187–213.
- Bond JB, Haik BG, Taveras JL et al. Magnetic resonance imaging of orbital lymphangioma with and without gadolinium contrast enhancement. *Ophthalmology* 1992; 99: 1318–1324.
- Saeed P, Rootman J, Nugent R et al. Optic nerve sheath meningiomas. *Ophthalmology* 2003; 110: 2019–2030.
- Ben Simon GJ, Syed HM, Douglas R, McCann JD, Goldberg RA. Extraocular muscle enlargement with tendon involvement in thyroid-associated orbitopathy. *Am J Ophthalmol* 2004; 137: 1145–1147.
- Weinig BM, Mafee MF, Ghosh L. Fibro-osseous, osseous, and cartilaginous lesions of the orbit and paraorbital region. Correlative clinicopathologic and radiographic features, including the diagnostic role of CT and MR imaging. *Radiol Clin North Am* 1998; 36: 1241–1259.



# Classification of orbital tumors

Mehran Taban and Julian D. Perry

## INTRODUCTION

Orbital tumors represent approximately 0.1% of all tumors and approximately 18% of all orbital diseases. Neoplasms of the orbit may be primary, secondary (infiltration from adjacent structure), or metastatic (from distant structures). Orbital neoplasia can be divided into three histologic categories: benign, benign but locally aggressive, and malignant.

Various classification schemes have been used to classify and describe orbital tumors, based on tumor location, histology, demographics, imaging characteristics, clinical behavior, and histologic behavior. This chapter aims to classify orbital tumors on clinical grounds so as to provide a practical approach to the differential diagnosis of an orbital tumor.

## DIFFERENTIAL DIAGNOSIS OF ORBITAL TUMORS

Many masquerading processes, including infectious and inflammatory diseases, can resemble an orbital tumor. Most can be excluded based on a combination of demographic, clinical, and imaging characteristics (Table 86.1).

## CLINICOPATHOLOGICAL CLASSIFICATION OF ORBITAL TUMORS

**Cystic lesions** Dermoid cyst is the most common cystic lesion of the orbit.<sup>1</sup> It is a congenital lesion that forms from epithelial cells that are trapped beneath the surface epithelium during embryogenesis. It often occurs near the orbital rim superotemporally at the zygomatico-frontal suture, but it can occur at other bony sutures or in deeper orbital tissues. Other orbital cystic lesions include colobomatous cyst, congenital cystic eye, meningocele, and teratoma (Table 86.2).

**Vascular tumors** are divided into no-flow (type 1), low-flow (type 2), and high-flow (type 3) lesions. Treatment is based on flow characteristics. Cavernous hemangioma and capillary hemangioma are hamartomas (Table 86.3).

**Myogenic tumors** represents the most common myogenic orbital tumor and the most common primary orbital malignant neoplasia of childhood. It accounts for 4% of all biopsied orbital masses in children.<sup>1</sup> Rhabdomyosarcoma is believed to arise from primitive orbital mesenchymal elements.

**Lipomatous and myxomatous tumors** Lipoma is a benign tumor of adipose tissue that rarely occurs in the orbit. Dermolipoma

is a benign congenital lesion that often occurs as part of Goldenhar's syndrome. Liposarcoma, the most common soft tissue sarcoma in adults, has widespread distribution but occurs only occasionally in the orbit.

**Primary melanocytic tumors** of the orbit include melanoma, melanocytic hamartoma, and melanotic neuroectodermal tumor of infancy. Accounting for less than 1% of primary orbital neoplasms, primary orbital melanoma arises from native orbital melanocytes that are located along ciliary nerves, optic nerve leptomeninges, and scleral emissary vessels. One half of primary orbital melanomas are associated with pigmentary disorders, including nevus of Ota, ocular melanocytosis, and blue nevi.<sup>2</sup>

**Lacrimal gland tumors** Approximately half of all lacrimal gland tumors represent epithelial proliferations, and the remainder represent inflammatory or lymphoproliferative lesions. Of the epithelial proliferations, roughly half are pleomorphic adenomas (benign mixed tumors) and the remainder are malignant carcinomas, which include adenoid cystic carcinoma, malignant mixed cell tumor, and muco-epidermoid carcinoma. Non-epithelial lacrimal gland tumors consist of ductal cyst, lymphoma, and plasmacytoma (Table 86.4).

**Lacrimal sac tumors** Epithelial tumors are the most common neoplasms of the lacrimal sac.<sup>3</sup> The most common malignant and benign epithelial tumors are squamous cell carcinoma and papilloma, respectively.<sup>3</sup> Malignant tumors outnumber benign tumors.<sup>3</sup>

**Lymphoproliferative tumors** Lymphoid and leukemic tumors represent a common group of orbital neoplasms. Chapter 95 discusses the classification and management of these tumors.

**Peripheral nerve tumors** arising in the orbit include neurilemmoma (schwannoma), neurofibroma, alveolar soft-part sarcoma, granular cell tumor, amputation neuroma, and malignant peripheral nerve sheath tumor. Theoretically, these tumors can arise from branches of the orbital cranial nerves, sympathetic and parasympathetic fibers, and the ciliary ganglion, but most seem to arise from the ophthalmic division of the trigeminal nerve. The vast majority of orbital peripheral nerve sheath tumors are benign: only a few well-documented cases of malignant peripheral nerve sheath tumors have been reported.<sup>4</sup>

**Table 86.1 Orbital tumors: simulating lesions**

Category	Subtype
Infectious	Acute bacterial orbital cellulitis Invasive fungal infection Mycobacterial infection
Inflammatory	Idiopathic orbital inflammation Dysthyroid orbitopathy Systemic vasculitides
Other	Amyloidosis

**Table 86.2 Orbital cystic lesions**

Category	Subtype
Epithelial	Dermoid cyst Conjunctival epithelial cyst Ductal cyst of the lacrimal gland
Bone	Mucocele Aneurysmal bone cyst
Ocular	Colobomatous cyst Congenital cystic eye
Central nervous system	Meningocele Meningoencephalocele Optic nerve sheath cyst
Parasitic	Hydatid cyst

**Table 86.3 Orbital vascular tumors**

Category	Subtype	
More common	Capillary hemangioma	Cavernous hemangioma
	Hemangiopericytoma	Lymphangioma (type 1)
	Varix (type 2)	Arteriovenous malformation (type 3)
Less common	Angiosarcoma	Hemangioendothelioma
	Hemangiosarcoma	Kaposi's sarcoma
	Kimura's disease	Vascular leiomyoma/leiomyosarcoma

**Table 86.4 Tumors of the lacrimal gland**

Types	Subtypes
Benign	Pleomorphic adenoma Myoepithelioma
Malignant	Adenoid cystic carcinoma Malignant mixed tumor (carcinoma arising within pleomorphic adenoma) Mucoepidermoid carcinoma Adenocarcinoma
Lymphoproliferative	

**Optic nerve, meningeal, and other neural tumors** Optic nerve and meningeal tumors consist mainly of optic nerve glioma, malignant optic nerve astrocytoma, and meningioma. Optic nerve glioma presents in childhood with progressive visual loss and axial proptosis. Neurofibromatosis (NF) affects children in up to 50% of cases. Conversely, only a small percentage of patients with NF have optic nerve glioma. Meningioma represents a benign neoplasm arising from the arachnoid layer of the meninges. Other neural tissue tumors include primitive neuroectodermal tumor, primary orbital neuroblastoma, and primary orbital carcinoid.

**Fibrohistiocytic tumors** These mass lesions, composed mainly of fibroblastic cells, can be clinically and histologically similar. Examples include fibroma, fibrosarcoma, and fibrous histiocytoma.

**Histiocytic tumors** Proliferative disorders of histiocytes comprise a spectrum of disease ranging from a solitary inflammatory lesion to widely disseminated lesions that may exhibit malignant behavior. Variants include Langerhans' cell histiocytosis, juvenile xanthogranuloma, Erdheim–Chester disease, sinus histiocytosis, and multinucleate cell angiohistiocytoma. Langerhans' cell histiocytosis consists of three disorders formerly referred to as eosinophilic granuloma, Hand–Schuller–Christian disease, and Letterer–Siwe disease. Eosinophilic granuloma generally occurs in the orbital region as a solitary lesion of bone.

**Primary bone tumors** of the orbit are a heterogeneous group of conditions that constitute only about 1% of all orbital tumors.

**Benign fibro-osseous tumors** Osteomas are benign proliferations of bony tissue that occur most commonly in the sinuses, skull, and facial bones. Orbital involvement is usually a result of invasion from adjacent sinuses and occurs most frequently in the ethmoidal, fronto-ethmoidal, and frontal regions. Fibrous dysplasia is a benign proliferation of fibrous tissue and woven bone, which has been described in three forms: monostotic, polyostotic, and McCune–Albright syndrome; the latter consists of a triad of polyostotic fibrous dysplasia, sexual precocity, and cutaneous pigmentation occurring largely in prepubescent girls. The majority of cases with orbital involvement have monostotic fibrous dysplasia, with the frontal bone followed by the sphenoid and ethmoid being the bones most commonly affected. The disease presents with long-standing facial asymmetry, proptosis, and globe displacement. Slow growth often continues into adult life.

**Benign cartilaginous tumors** This rare group of tumors includes chondroma, osteochondroma, enchondroma, and fibrochondroma.

**Reactive bone lesions** include cholesterol granuloma, aneurysmal bone cyst, giant cell granuloma, and brown tumor of hyperparathyroidism. Cholesterol granuloma represents a foreign body reaction to cholesterol deposition following the breakdown of blood products. More commonly seen in the middle ear and temporal bone, it can rarely occur in the orbit, almost exclusively in the superolateral frontal bones.

**Malignant tumors** Osteosarcoma is the most common primary bone malignant tumor; however, orbital involvement is rare and the lesion usually has a maxillary focus. Most arise de novo, but some are

secondary to Paget's disease, fibrous dysplasia, or radiotherapy. Patients with familial retinoblastoma can develop osteosarcoma, even without a history of radiation. Multiple myeloma and solitary plasmacytoma may involve the orbital bone. These lesions typically present with subacute pain and proptosis in a patient over 50 years of age. Most frequently occurring in the tongue and subcutaneous tissues, granular cell tumors may rarely involve the orbit, extraocular cell muscles, periorbita, and lacrimal sac.<sup>5</sup> Grossly, the lesions are well-encapsulated tumors composed of round to oval-shaped cells with granular eosinophilic cytoplasm.

**Miscellaneous bone tumors** Orbital intraosseous hemangioma presents as a slowly evolving painful mass. Malignant vascular tumor of orbital bone is also rare. Other neoplasms, including intramedullary lipoma, intraosseous myxoma, and cartilaginous hamartoma can rarely affect the orbital bones.

**Metastatic tumors** spread to the orbit hematogenously, as there are no significant lymphatics in the orbit. Metastatic orbital lesions account for approximately 2–12% of orbital neoplasms, depending on the age of the patient.<sup>6</sup> Nearly all systemic malignancies have been reported to metastasize to the orbit.

**Metastatic orbital tumors in adults** are most often carcinomas of epithelial origin.<sup>6</sup> Breast cancer accounts for 42% of all metastatic lesions, followed by lung (11%), unknown primary (11%), prostate (8.3%), melanoma (5.2%), gastrointestinal tract (4.4%), and kidney (3.2%).<sup>6</sup> In general, more indolent cancers are diagnosed prior to orbital metastasis, whereas early orbital metastasis occurs in patients with more aggressive cancers. Orbital metastasis is the presenting sign of a systemic cancer in about 42% of cases.<sup>6</sup> Average survival after a diagnosis of orbital metastasis is approximately 9 months.<sup>6,7</sup> Patients with orbital metastases frequently complain of diplopia, ptosis, proptosis, eyelid swelling, pain, and vision loss. Metastatic breast carcinoma may cause enophthalmos owing to its scirrhous histologic nature.<sup>8</sup>

**Metastatic orbital tumors in children** are more likely to arise from embryonal neural tumors, such as neuroblastoma and sarcomas.

Metastatic neuroblastoma is second only to primary rhabdomyosarcoma as the most frequent orbital malignancy of childhood.<sup>9</sup> Such patients present with rapidly developing exophthalmos and eyelid ecchymoses. Isolated primary orbital neuroblastoma is exceedingly rare.<sup>10</sup> Other childhood tumors that metastasize to the orbit include Wilms' tumor, Ewing's tumor, and medulloblastoma.<sup>9</sup>

**Secondary orbital tumors** Orbital tissues may be invaded by tumors arising from adjacent sites, such as the eyelids (squamous cell carcinoma), conjunctiva (melanoma), lacrimal sac (adenoid cystic carcinoma), globe (retinoblastoma), paranasal sinuses (squamous cell carcinoma), nasopharynx (esthesioneuroblastoma), and brain (glioblastoma).<sup>11,12</sup>

## IMAGING CLASSIFICATION OF ORBITAL TUMORS

Orbital tumors can be differentiated based on imaging characteristics, notably well-circumscribed relative poorly circumscribed lesions.

**Well-circumscribed tumors** In general, benign orbital tumor presents as a well-circumscribed lesion, including cavernous hemangioma, fibrous histiocytoma, hemangiopericytoma, lipoma, neurilemmoma, pleomorphic adenoma, and others. A notable exception is diffuse (plexiform) neurofibroma, which appears as a poorly circumscribed lesion.

**Poorly circumscribed tumors** include adenoid cystic carcinoma, fibrosarcoma, lymphoma, pleomorphic adenocarcinoma, primary orbital melanoma, and most metastatic tumors. However, malignant orbital tumors can also be circumscribed. Examples include mesenchymal chondrosarcoma, optic nerve glioma, optic nerve meningioma, and rhabdomyosarcoma.

## SUMMARY

Orbital tumors represent a heterogeneous group of neoplasms with varying classification schemes devised to provide a framework for clinical evaluation. A combination of imaging, clinical, and demographic data may be used to narrow the differential diagnosis and to determine the appropriate evaluation and treatment.

## REFERENCES

- Shields JA, Bakewell B, Augsburger JJ, Donoso LA, Bernardino V. Space-occupying orbital masses in children. A review of 250 consecutive biopsies. *Ophthalmology* 1986; 93: 379–384.
- Jakobiec FA, Ellsworth R, Tannenbaum M. Primary orbital melanoma. *Am J Ophthalmol* 1974; 78: 24–39.
- Stefanyszyn MA, Hidayat AA, Pe'er JJ, Flanagan JC. Lacrimal sac tumors. *Ophthalm Plast Reconstr Surg* 1994; 10: 169–184.
- Jakobiec FA, Font RL, Zimmerman LE. Malignant peripheral nerve sheath tumors of the orbit: a clinicopathologic study of eight cases. *Trans Am Ophthalmol Soc* 1985; 83: 332–366.
- Jaeger MJ, Green WR, Miller NR, Harris GJ. Granular cell tumor of the orbit and ocular adnexae. *Surv Ophthalmol* 1987; 31: 417–423.
- Goldberg RA, Rootman J, Cline RA. Tumors metastatic to the orbit: a changing picture. *Surv Ophthalmol* 1990; 35: 1–24.
- Freedman MI, Folk JC. Metastatic tumors to the eye and orbit. Patient survival and clinical characteristics. *Arch Ophthalmol* 1987; 105: 1215–1219.
- Cline RA, Rootman J. Enophthalmos: a clinical review. *Ophthalmology* 1984; 91: 229–237.
- Albert DM, Rubenstein RA, Scheie HG. Tumor metastasis to the eye. II. Clinical study in infants and children. *Am J Ophthalmol* 1967; 63: 727–732.
- Jakobiec FA, Klepach GL, Crissman JD, Spoor TC. Primary differentiated neuroblastoma of the orbit. *Ophthalmology* 1987; 94: 255–266.
- Reifler DM, Hornblass A. Squamous cell carcinoma of the eyelid. *Surv Ophthalmol* 1986; 30: 349–365.
- Howard GR, Nerad JA, Carter KD, Whitaker DC. Clinical characteristics associated with orbital invasion of cutaneous basal cell and squamous cell tumors of the eyelid. *Am J Ophthalmol* 1992; 113: 123–133.



# Evaluation of a child with orbital tumor

Paul L. Proffer, Jill A. Foster and Julian D. Perry

## INTRODUCTION

The medical adage that ‘children are not just little adults’ is particularly true regarding the evaluation of a child with a suspected orbital tumor. Common etiologies of orbital tumors differ significantly between children and adults. For example, rhabdomyosarcoma, one of the most common primary pediatric orbital malignancies, rarely occurs in adults.

The potential morbidity – and in some cases mortality – of pediatric orbital neoplasia requires an understanding of common findings and presentations to direct the evaluation. The history, physical examination, and diagnostic studies will limit the differential diagnosis, which determines the initial surgical therapy.

## HISTORY

As with adults, the history begins with a description of the symptoms, severity, onset, and rate of progression. However, obtaining a detailed history in the pediatric patient presents unique challenges. The direct history depends upon the age, maturity, and verbal skills of the child. In many cases the bulk of the history requires input from the family. The evaluator should remember that a child may deny, forget, or embellish important historical facts that can confound the evaluation of an orbital tumor. For example, a child injured with a stick or toy may not disclose the cause, and a history of otherwise insignificant periocular trauma may obscure the work-up of true orbital neoplasia. Preverbal children cannot clearly communicate subjective findings such as pain, hypesthesia, diplopia, or diminished visual acuity. In these cases the evaluator uses non-verbal clues and physical findings to focus the examination and develop the differential diagnosis.

**Presenting symptoms and complaints** As with adults, pediatric orbital neoplasia presents with a wide spectrum of symptoms, but many may be under-reported in the non-verbal child. Tumor location and histology determine the presenting symptoms, which can be divided into sensory, motor, and structural or functional.

**Rate of onset** Pediatric orbital malignancies, such as rhabdomyosarcoma, often present with a subacute rate of onset that can be confused with orbital inflammation or trauma. Orbital lymphangioma may produce sudden findings due to intralesional bleeding. Benign tumors, such as dermoid cysts, capillary hemangiomas, and gliomas often present with slowly advancing symptoms.

**Past medical history** The past medical history importantly relates to several pediatric orbital tumors. For example, proptosis that occurs

predictably in conjunction with viral illness may indicate an underlying lymphangioma. Most patients with granulocytic sarcoma have a history of systemic leukemia. Patients with lymphangioma may have airway or palatal lesions, and these may increase during episodes of viral illness. Large capillary hemangiomas are associated with Kasabach–Merritt syndrome and visceral lesions. Orbital neuroblastoma is most often metastatic from the thorax. Diseases that may simulate an orbital neoplasm in children may be associated with underlying medical conditions. For example, orbital cellulitis often occurs in the context of underlying sinusitis.

## EXAMINATION

A systematic evaluation that includes a detailed history, physical examination and attention to ‘Krohel’s 6 Ps’, allows the examiner to narrow the differential diagnosis (Box 87.1).<sup>1</sup>

Asking the parent to hold or feed an infant often facilitates the physical examination. Through observation alone, the evaluator may gather important information regarding skin coloration, eyelid and globe position, external periocular soft tissue changes, ocular motility, and vision. The examination should include observation of any changes of globe position with crying.

Patient cooperation may limit the ability to perform a complete physical examination in the office. Some children require sedation or general anesthesia to complete the physical examination. Some surgeons prefer the use of chloral hydrate or ketamine in a monitored clinical setting, whereas others prefer monitored anesthesia in the operating room setting.

Communication with the pediatrician regarding suspected etiologies helps to determine the need for additional systemic evaluation. Systemic work-up may include serologic testing, genetic studies, or imaging studies.

**Complete eye examination** Orbital tumors can affect sensory visual function by producing compressive or glaucomatous optic neuropathy, refractive errors, or keratopathy. Any cause of visual dysfunction in the pediatric group may produce amblyopia. Detailed visual assessment can help localize an orbital tumor and determine the need for amblyopia therapy. In children, assessment requires a cycloplegic refraction. Eyelid position and papillary testing should be evaluated prior to placing drops for dilation.

Versions, ductions, and strabismus measurements should be noted. In older children, color plates may help to better characterize optic nerve function, especially if the examiner is considering an underlying

glioma. Evaluation of stereopsis may help distinguish a long-standing tropia from strabismus due to a new orbital process.

A standard or portable slit lamp allows for the most detailed anterior segment evaluation. However, a penlight with or without a 20D lens for magnification may be used. Conditions such as lymphangioma or capillary hemangioma often present with anterior segment findings. Posterior pole examination follows, and may reveal findings such as choroidal folds due to an orbital mass effect, optic disc pallor due to a glioma or other tumor compression, or orbital invasion from a primary ocular tumor.

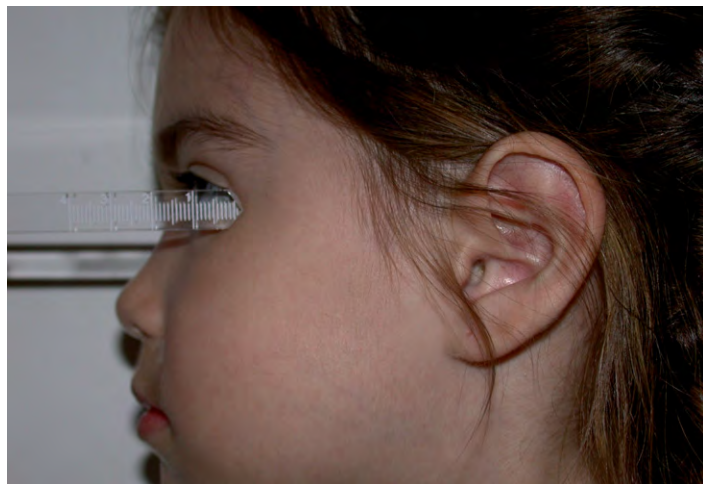### Orbital examination

**Globe displacement** The examiner assesses globe position qualitatively with the child in the chin-up position. Although an exophthalmometer may provide an objective measure, patient cooperation may limit its accuracy. The Luedde device is particularly valuable for evaluation of globe position in children, who often find it less intimidating because it is smaller and placed on the side (Fig. 87.1). The Luedde instrument offers accurate measurements with the patient in the supine position and can be used during an examination under anesthesia.

**Palpation** yields information regarding tumor location, size, and shape. A dermoid cyst may feel fluctuant, an orbital lymphangioma may have a ‘bag of worms’ consistency, and capillary hemangiomas often blanch with palpation. Malignancy may produce a high degree of resistance to globe retropulsion.

#### BOX 87.1 The 6 Ps of the Orbital Examination

- Proptosis
- Palpation
- Pulsation
- Periorbital changes
- Pain
- Progression



**Fig. 87.1** Luedde exophthalmometer for examination of a child with proptosis.

**Pulsation** Although rare, pulsations may occur with certain tumors in children, such as absence of the sphenoid wing in the setting of neurofibromatosis.

**Periorbital changes** The overlying tissues may show visible signs to suggest the etiology of an orbital neoplastic process. Neuroblastoma often presents with periorbital ecchymoses. Plexiform neurofibroma often presents with an S-shaped upper eyelid deformity with characteristic skin changes. Lymphangiomas and capillary hemangiomas can be visible through the conjunctiva. Rhabdomyosarcoma often presents with periorbital inflammatory signs.

**Head and neck examination** Examination of the sinuses, nasopharynx, and adjacent lymphatic drainage areas often helps to limit the differential diagnosis.

### LABORATORY EVALUATION

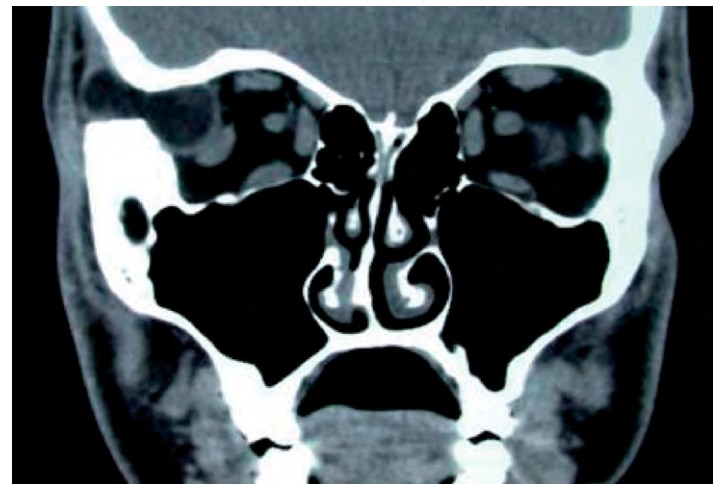
Laboratory analysis augments the information gained from the history and physical examination and further narrows the differential diagnosis. Metastatic neuroblastoma often results in high levels of urine homovanillic acid and vanillylmandelic acid. Peripheral blood smears may be useful in the evaluation of suspected granulocytic carcinoma with orbital presentation.

### DIAGNOSTIC IMAGING

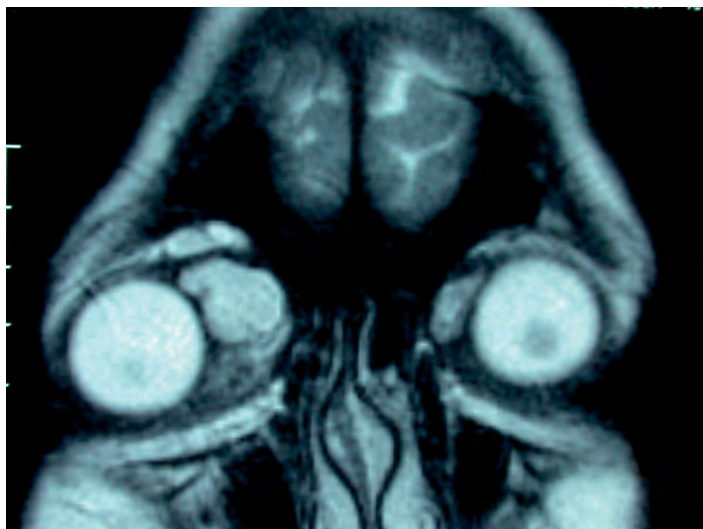
The evaluation of some pediatric orbital tumors, such as dermoid cyst and capillary hemangioma, may not require orbital imaging. In most cases, however, imaging is essential to solidify the diagnosis, clarify the extent of the disease, and determine the surgical approach.

CT and MR imaging studies represent the mainstay of current techniques. Orbital ultrasound may be of value in determining the size of an orbital lesion or to assess the homogeneity or flow characteristics of a lesion. CT provides the best views of bone (Fig. 87.2) and MRI is better for evaluating soft tissue pathology and blood flow (Fig. 87.3).

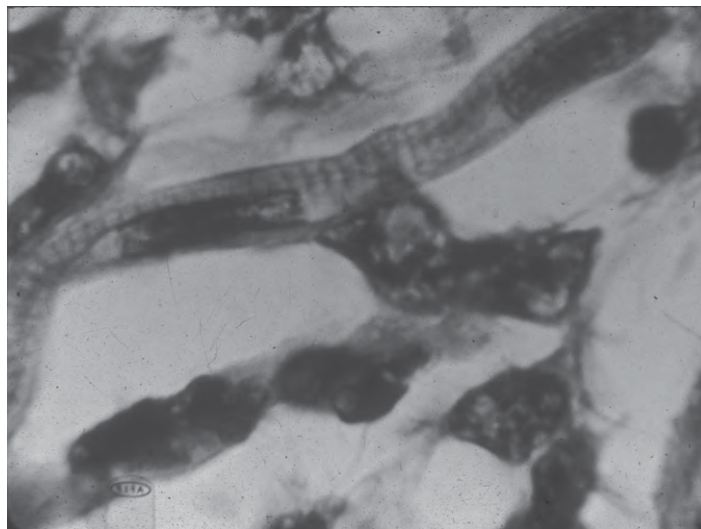
Orbital ultrasonography may be helpful to evaluate an orbital vascular process. A capillary hemangioma with medium to high internal reflectivity may be differentiated from a solid tumor with low reflectivity.<sup>2</sup> Ultrasonography may also help guide fine needle aspiration biopsy.



**Fig. 87.2** CT scan shows bony changes associated with an orbital dermoid.



**Fig. 87.3** MRI of an orbital lymphangioma.



**Fig. 87.4** Spindle-shaped cells containing striations in an embryonal rhabdomyosarcoma. (Hematoxylin & eosin.)

**Table 87.1 Presenting features of orbital tumors in children**

Category	Entity	Common symptoms and signs
Inflammatory	Ruptured dermoid	Acute onset, pain, proptosis
Congenital	Plexiform neurofibroma	Pulsating proptosis (absent sphenoid wing); painless, slow progression
	Dermoid	Proptosis with orbital lesions; painless, slow progression
	Teratoma	Progressive severe proptosis
Vascular	Capillary hemangioma	Slow progression, pain and pulsation rare; blanches with palpation; proptosis if posterior
	Lymphangioma	Painless proptosis but pain with intralesional bleed or upper respiratory infection; conjunctival involvement may aid in diagnosis
Benign	Optic nerve glioma	Axial proptosis, slow progression; Usually painless
Malignant	Rhabdomyosarcoma	Rapid onset painless proptosis; discoloration of overlying skin
Metastasis	Leukemia (chloroma)	Unilateral or bilateral painless proptosis; rapid progression,
	Neuroblastoma	Abrupt progressive proptosis; eyelid ecchymoses

## BIOPSY

Confirmation of the diagnosis may require surgery. Surgical goals and planning are determined prior to surgery. Equipment and personnel are secured preoperatively for frozen section microscopy, microbiological studies, permanent biopsy specimens, ancillary testing, or other concomitant procedures that may be performed while the child is under anesthesia, such as bone marrow biopsy or venous port placement.

Suspected rhabdomyosarcoma often requires biopsy to establish the diagnosis (Fig. 87.4). Further chapters discuss specific surgical approaches, goals, and treatments.

The differential diagnosis determines the possible outcomes of frozen section results and the appropriate extent of surgical excision. An adequate specimen should anticipate the possibility of needing tissue for further testing, including microbiological testing, cell marker studies, or electron microscopy. Marking sutures aid in specimen orientation.



**SUMMARY**

A detailed knowledge of specific pediatric orbital disorders and their common presentations provides the framework for evaluation and treatment of orbital tumors in children. Typical presenting features of

common tumors are summarized in Table 87.1. However, signs and symptoms of each tumor are not entirely specific, and the surgeon must be prepared to consider atypical presentations.

**REFERENCES**

1. Krohel GB, Stewart WB, Chavis RM. Orbital disease. A practical approach. New York: Grune & Stratton; 1981: 9–20.
2. Byrne SF, Green RL. Ultrasound of the eye and orbit, 2nd edn. St Louis: Mosby, 2002; 350–351.

# Evaluation of an adult with orbital tumor

Benson Chen, Julian D. Perry and Jill A. Foster

## INTRODUCTION

The evaluation of an adult with a suspected orbital tumor begins with a detailed history and physical examination. Comparison to children, adults often present with a more complex history due to comorbidities, but they often provide finer historical details. Although most patients require imaging and a tissue diagnosis, the history and examination help to determine the type and sequence of diagnostic studies and surgery.<sup>1</sup>

## HISTORY

The history begins with a description of the symptoms, severity, onset, and rate of progression. A targeted review of systems reveals additional clues to the etiology.

**Presenting symptoms and complaints** Orbital neoplasia presents with a wide spectrum of symptoms,<sup>2</sup> which may be categorized as sensory, motor, structural, or functional in nature. Tumor location and histology determine the presenting symptoms. These include hypesthesia, pain, and visual changes. Pain is often produced by malignancy. Some tumors, such as adenoid cystic carcinoma of the lacrimal gland, demonstrate perineural invasion to produce pain. Visual changes can result from optic nerve compression, choroidal folds, change in axial length, induced astigmatism, or exposure keratopathy.

Motor symptoms include diplopia and blepharoptosis. Diplopia may result from extraocular muscle nerve paresis, mass effect on the globe or extraocular muscles, or restriction.

Structural symptoms include changes in facial symmetry, globe displacement, as well as a visible or palpable mass. Functional symptoms may be due to dry eye, exposure keratopathy, hypersecretion of tears, or decreased lacrimal outflow (Box 88.1).

**Rate of onset** and progression help characterize the pathology. Acute symptoms progressing over hours to days imply a hemorrhagic, infectious, or inflammatory process, all of which can be associated with orbital neoplasia. Lymphangioma can result in acute hemorrhage, lymphomas and metastases can produce periorbital inflammatory signs, and tumors of the lacrimal drainage system may result in acute dacryocystitis. Indolent or slowly progressing changes over weeks to months may also suggest of a neoplastic etiology. Cavernous hemangioma often produces only slowly progressive axial proptosis. Meningioma often produces mild, slowly progressive proptosis in the setting of visual changes (Table 88.1).

**Past medical history** In adults, past medical history and concomitant systemic disease play a significant role in the evaluation of orbital disease. The past history helps to differentiate diseases that may simulate an orbital neoplasm from a true orbital tumor. Simulating etiologies include endocrine disease (thyroid related orbitopathy), autoimmune/granulomatous disease (sarcoidosis, Wegener's granulomatosis), infections (TB, HIV-associated diseases, invasive fungal infections), sinus disease (allergy, epistaxis, sinusitis, mucocele), vascular (carotid-cavernous or dural-cavernous fistula), and previous trauma or surgery.

Many of the most common orbital tumors carry systemic associations that can aid in diagnosis. Mucocele occurs in the setting of chronic sinusitis. Dermolipoma often occurs in patients with Goldenhar's syndrome. Patients with neurofibromatosis may develop optic nerve or chiasmal glioma. Fibrous dysplasia (polyostotic, the less common orbital form) is associated with Albright's syndrome. Most women presenting with metastatic orbital breast cancer already have an established diagnosis of primary disease. Patients in the immunocompromised state can develop lymphoma and other orbital tumors.

Conversely, certain orbital neoplasms require a systemic work-up to search for and treat known associated disease. Capillary hemangioma is associated with Kasabach-Merritt syndrome and visceral hemangiomas. Lymphangioma is associated with upper airway and palate lesions. Patients with these lesions may require a systemic work-up or follow to search for multiorgan involvement. Similarly, patients with Langerhans' cell histiocytosis, and orbital lymphoma and other primary orbital malignancies require systemic work-up to search for concurrent systemic disease.

Detailed inquiry should also include social history and medications, as this information may elucidate further past medical history not initially provided by the patient.

## EXAMINATION

The physical examination of an adult with suspected orbital neoplasia consists of three aspects: complete eye examination, orbital examination, and head and neck evaluation. Specific examination techniques are discussed in Chapter 84.

**Complete eye examination** Human eyes develop within the finite space defined by the bony orbital walls. The eye is ensheathed by organized layers of connective tissue and padded by orbital fat. A thorough eye examination may reveal the earliest clues to a progressing orbital lesion.

Anterior mass lesions, for example, can induce corneal astigmatic refractive error, whereas intraconal lesions may induce a hyperopic shift. New deficits in color or contrast vision, pupillary light reflex, and visual field testing may result from a tumor compressing the optic nerve. Orbital neoplasia may cause ocular motility dysfunction, either paralytic or restrictive. Slit lamp examination can define the etiology of a red eye as scleritis with orbital inflammation,<sup>3</sup> episcleral venous tortuosity from arteriovenous shunting, or secondary to exposure keratopathy. Elevated intraocular pressure may occur as result of any orbital process that disrupts venous outflow, such as sphenoidal meningioma, or from any tumor that compresses the globe or reduces globe compliance.

Dilated funduscopy may help to significantly limit the differential diagnosis, and is performed on all patients with a suspected orbital tumor. Orbital mass lesions may result in choroidal folds, with a resultant decrease in visual acuity. The optic nerve may appear edematous, pale, or normal when affected by orbital neoplasia. Optociliary shunt vessels suggest the presence of a long-standing optic nerve tumor, such as a meningioma. Venous congestion may occur with any process that limits venous outflow. Concurrent intraocular disease may occur in the setting of orbital lymphoma, which significantly affects prognosis and treatment. Funduscopy can also detect orbital invasion of a primary intraocular malignancy (Table 88.2).

**Orbital examination** Krohel, Stewart and Chavis<sup>2</sup> described four parts of the orbital examination: measurement of proptosis and globe displacement, palpation of the anterior orbits, detection of orbital pulsation, and examination of the periorbital region for changes.

**Globe displacement** Proptosis is one of the most obvious and important manifestations of orbital neoplasia, although it is non-

specific and may arise from many non-neoplastic diseases as well. Proptosis can point to the location of a mass. Retrobulbar lesions, such as cavernous hemangioma, glioma, meningioma, and metastases, cause axial proptosis. Lesions outside the muscle cone cause non-axial proptosis: the inciting orbital tumor produces globe displacement away from the lesion. For example, a lacrimal fossa mass will cause downward and medial globe displacement along with proptosis.

Several orbital tumors may cause bilateral proptosis, including lymphoma, leukemia, amyloidosis, glioma, metastatic tumors, and neuroblastoma. Orbital neoplasia can produce retrodisplacement of the globe rather than proptosis. Classically, sclerosing tumors, such as metastatic breast carcinoma, lead to enophthalmos.

The examiner should exercise caution in interpreting absolute exophthalmometry measurements. Whereas absolute measurements less than 21 mm are generally normal for Caucasians, higher levels are common for African-Americans (23 mm) and lower levels for Asians (18.7 mm).<sup>4,5</sup> The normal range for males exceeds that of females by about 1–1.5 mm, depending on race. An asymmetry of more than 2 mm between the two eyes of a given patient is abnormal. Old photographs of the patient and family members can help define normal congenital variations. Chapter 84 discusses examination techniques using the Hertel exophthalmometer and other devices that quantify globe position (Table 88.3).

Pseudoproptosis represents globe prominence without an underlying increase in orbital contents, and may be caused by an enlarged globe (myopia), asymmetric orbital size, asymmetric palpebral fissures (lid retraction or contralateral blepharoptosis), and contralateral enophthalmos.

**Palpation** Although it is most revealing for anterior orbital processes, palpation still yields critical information that guides evaluation. Palpation provides information regarding tumor location, size, and shape. If palpation shows the presence of a lacrimal fossa lesion, CT imaging may be warranted, whereas palpation of a superior orbital lesion may warrant MR imaging. Palpation also provides valuable information regarding the density and texture of a tumor, as well as the degree of tissue infiltration. Anteriorly located cystic lesions, such as a dermoid cyst or a mucocele, may appear fluctuant. Arteriovenous malformations may have a ‘bag of worms’ consistency. Lymphomas may feel rubbery. Tenderness to palpation provides information regarding the underlying etiology.

The degree of resistance to retropulsion should be recorded. Higher degrees of resistance in the setting of an orbital tumor should alert the examiner to the possibility of coexisting optic neuropathy. Metastatic

#### BOX 88.1 Common Presenting Symptoms of Orbital Disease

- Sensory: orbital pain, changes in vision, numbness or tingling
- Motor: diplopia, ptosis
- Structural: changes in facial symmetry, globe displacement, visible or palpable mass
- Functional: dry eyes or tearing

**Table 88.1 Onset of orbital tumors in adults**

Congenital	Acute	Subacute	Chronic (months)	Chronic (years)
Dermoid	Lymphangioma	Lymphoproliferative	Cavernous hemangioma	Cavernous hemangioma
Epidermoid	Lymphoproliferative	Metastatic lesions	Lymphoproliferative	Lacrimal gland neoplasia
	Metastatic lesions		Metastatic lesions	Lymphoproliferative
	Secondary tumors		Optic nerve meningioma	Metastatic lesions
			Secondary tumors	Optic nerve glioma
				Optic nerve meningioma
				Secondary tumors
				Vascular neoplasia



**Table 88.2 Clinical findings of common orbital neoplasms**

Clinical finding	Etiology
Salmon-colored cul-de-sac mass	Lymphoma
Eyelid ecchymoses	Neuroblastoma, leukemia, capillary hemangioma
Prominent temple with pulsations	Sphenoid wing meningioma
Optociliary shunt vessels	Meningioma (or glioma)
Frozen globe	Metastases
Gaze-evoked amaurosis	Orbital apex tumors

**Table 88.3 Normal Hertel exophthalmometry values**

	Male mean	Normal limit	Female mean	Normal limit
Asian	13.9	18.6	13.9	18.6
Caucasian	16.5	21.7	15.4	20.1
African-American	18.5	24.7	17.8	23.0

lesions often produce a high degree of resistance to globe retro-pulsion.

**Pulsation** Although rare, a pulsatile orbit represents an important physical finding. Pulsation may occur with an underlying arterial vascular lesion. The orbital soft tissues may also transmit cerebral pulsations through a disruption of the posterior orbital bones (absence of the sphenoid wing in the setting of neurofibromatosis). Applanation tonometry and exophthalmometry may demonstrate pulsatile changes. Auscultation of the orbit may occasionally reveal an audible bruit.

**Periorbital changes** The overlying periorbital region may yield visible information to suggest a non-neoplastic etiology. Eyelid retraction represents the most common ocular finding in Graves' disease, and in the presence of bilateral proptosis it requires no further diagnostic evaluation.<sup>2</sup> Eyelid or periorbital edema may result from venous outflow obstruction and/or inflammation. Warmth and deep red erythema in the febrile patient may represent an infection, whereas well-delineated pink edema may represent underlying inflammatory disease. Conversely, some orbital tumors show classic periorbital changes. Lymphoma can cause a salmon-colored fleshy conjunctival lesion within the fornix. Neuroblastoma often produces ecchymoses. Lymphangioma and capillary hemangioma often demonstrate a classic conjunctival or cutaneous appearance.

**Head and neck examination** Examination of the sinuses and nasopharynx may detect the primary source of contiguous disease when sinus neoplasia invades the orbit. The examiner should palpate for preauricular, submandibular, and supraclavicular adenopathy during the evaluation of a suspected orbital tumor.

### LABORATORY EVALUATION

Laboratory analysis can augment information gained from the clinical evaluation. Serologic testing can often support a non-neoplastic

**Table 88.4 Benign versus malignant orbital tumors**

	Benign tumors	Malignant tumors
Duration of symptoms	Long (years)	Short (months)
Pain	None	Present
Vision impairment	Little	Present
Motility impairment	Little	Present
Degree of exophthalmos	Minor	Marked
Imaging findings	Circumscribed mass Bone intact	Infiltrative mass Bone eroded

etiology in the setting of equivocal physical findings. Thyroid function and antibody testing can provide further evidence for Graves' disease.<sup>6</sup> cANCA titers may reflect underlying Wegner's granulomatosis. Angiotensin-converting enzyme, serum lysozyme elevation, and chest imaging can help to confirm sarcoidosis. Other serologic tests can support the clinical diagnosis of specific orbital tumors. Carcino-embryonic antigen is a non-specific tumor marker that may be elevated in the setting of orbital metastases from colorectal or bronchogenic carcinoma. Prostate-specific antigen may be elevated in the setting of metastatic prostate cancer. Metastatic neuroblastoma often results in high levels of urine homovanillic acid and vanillylmandelic acid.

### DIAGNOSTIC IMAGING

Most patients with suspected orbital neoplasia require orbital imaging to further elucidate the etiology of the orbital mass. Prior to the advent of CT and MR imaging, plain-film radiography was used to evaluate patients with orbital disease. Orbital exploration was often required to characterize orbital lesions and carried significant morbidity. CT and MRI techniques can define the lesion in terms of location, contour or surface features, infiltrative effects, relationship to and effect on adjacent structures, and changes with treatment.

CT imaging allows for visualization of the orbital bones and can show bone destruction in cases of orbital malignancy. CT often provides the most information in cases of suspected lacrimal gland disease. Contrast enhancement improves the resolution of internal characteristics. MR imaging achieves better resolution for most other orbital tumors, including posterior orbital lesions involving the apex, canal, optic nerve, and cavernous sinus. MR angiography and venography further characterize orbital vascular lesions.

Ultrasonography represents a non-invasive, rapid, and inexpensive way to characterize anterior orbital lesions without exposure to radiation. Dacryoscintigraphy and dacryocystography can characterize the location and the functional impact of lacrimal drainage system neoplasms.

The history, physical examination, laboratory tests, and imaging studies will narrow the differential diagnosis to determine the surgical approach and goals (Table 88.4).

### BIOPSY

Diagnosis of an orbital tumor ultimately requires confirmatory histology. Although the location of the lesion largely dictates the approach, certain tumors must be approached with caution, whereas others may be biopsied with less invasive techniques. Some tumors require complete excision, whereas others require only biopsy to establish a tissue diagnosis for medical therapy.

In the case of a lacrimal fossa tumor, the clinician must retain high suspicion for a benign mixed tumor. This slow-growing, painless, encapsulated lesion can produce orbital seeding and recurrence, or malignant degeneration after incomplete resection. A rapidly growing, painful lacrimal fossa lesion that erodes bone may represent an adenoid cystic carcinoma. Biopsy of this lesion will allow for diagnosis and subsequent treatment. When evaluating a superior orbital lesion for biopsy, the clinician should consider the possibility of an encephalocele with orbital roof disruption. Mucocoeles extending from the frontal sinus often have characteristic imaging findings and may require sinus drainage and ablation. When evaluating inferior orbital lesions, the surgeon should consider secondary extensions from the maxillary sinus.

Fine-needle aspiration offers an alternative to surgery for selected tumors. It should be reserved for solid infiltrative tumors, and is contraindicated for suspected vascular, cystic, or circumscribed tumors. The technique may be indicated in patients with orbital lesions who cannot tolerate a more extensive procedure, or in the setting of an

**Table 88.5 Surgical decisions for orbital tumors**

Biopsy specimen	Complete excision intact
Malignancy suspected	Benignity suspected
Infiltrative appearance	Encapsulated appearance
Solid consistency	Cystic or solid mass
Complex surgical approach	Accessible surgical approach

otherwise non-resectable orbital lesion. Chapter 99 discusses the principles of orbital surgery (Table 88.5).

## CONCLUSION

A systematic approach to the evaluation of the adult with suspected orbital neoplasia allows the clinician to efficiently diagnose and treat orbital tumors.

## REFERENCES

- Burde RM, Savino PJ, Trobe JD. Proptosis and adnexal masses. In: Burde RM, Savino PJ, Trobe JD. *Clinical decisions in neuro-ophthalmology*, 2nd edn. St Louis: Mosby, 1992; 379–416.
- Krohel GB, Stewart WB, Chavis RM. *Orbital disease: a practical approach*. New York: Grune & Stratton, 1981.
- Leone CR. Painful orbital swelling. In: van Heuven WAJ, Zwaan J. *Decision making in ophthalmology*. St. Louis: Mosby, 2000; 88–89.
- Migliori ME, Gladstone GJ. Determination of the normal range of exophthalmometric values for black and white adults. *Am J Ophthalmol* 1984; 98: 438–442.
- Tsai CC, Kau HC, Kao SC, Hsu WM. Exophthalmos of patients with Graves' disease in Chinese of Taiwan. *Eye* 2006; 20: 569–573.
- Bartley GB, Gorman CA. Diagnostic criteria for Graves' ophthalmopathy. *Am J Ophthalmol* 1995; 119: 792–795.

# Non-specific orbital inflammation

Roberta E. Gausas, Kimberly P. Cockerham and Madhura Tamhankar

## INTRODUCTION

Orbital inflammatory disease encompasses a broad category of disorders that conceptually can be divided into specific and non-specific inflammations, i.e. those that have an identifiable cause and those that do not. Non-specific orbital inflammation (NSOI) is defined as a benign inflammatory process of the orbit characterized by a polymorphous lymphoid infiltrate with varying degrees of fibrosis, without a known local or systemic cause.<sup>1</sup> The diagnosis is arrived at after all specific causes of inflammation have been eliminated.

The terminology used to describe this disorder has evolved over time, from 'orbital pseudotumor' to 'idiopathic orbital inflammatory syndrome' to 'non-specific orbital inflammation.' Recognition of this entity dates from the late 1800s and early 1900s, when several authors reported patients with presumed tumors of the orbit who were either noted to improve unexpectedly or who, upon surgical exploration of the orbit, proved histopathologically to have benign inflammation rather than malignancy. In 1930, Birch-Hirschfeld<sup>2</sup> described a series of 30 such patients and coined the term orbital pseudotumor. The clinical description of a benign process masquerading as a malignant one was appropriate for that era, and the term soon became entrenched in medical literature. However, medical understanding has advanced significantly, with breakthroughs in imaging, immunopathology, and molecular techniques, allowing for increasing diagnostic specificity. The underlying pathophysiologic characteristics of disease cannot be understood by their clinical characteristics alone.<sup>3</sup> Non-specific orbital inflammation (NSOI) is a more accurate and modern reflection of our current understanding of this disease process.

## PATHOGENESIS

The pathogenesis of NSOI remains controversial, although it is generally believed to be an immune-mediated process. Several lines of evidence point in this direction. NSOI is associated with a number of systemic immunologic disorders, including Crohn's disease, systemic lupus erythematosus, rheumatoid arthritis, diabetes mellitus, myasthenia gravis, and ankylosing spondylitis. An immune-mediated etiology is also strongly suggested by the observation that NSOI typically has a rapid and favorable response to systemic corticosteroid treatment, as well as other immunosuppressive agents such as cyclophosphamide, methotrexate and ciclosporin, indicating a cell-mediated component. An autoimmune process has also been suggested wherein circulating autoantibodies against eye muscle antigens are present in patients with orbital myositis.<sup>4</sup>

Other theories have been proposed as well, including post-infectious post-traumatic etiologies.<sup>5</sup> NSOI has been associated with several infectious processes, such as upper respiratory infections and flu-like viral illness in both adult and pediatric studies. Trauma may occasionally precede the onset of symptoms in NSOI, especially in children, and some authors have hypothesized that the trauma-induced localized increase in vascular permeability leads to the release of circulating antigenic substances into the traumatized orbital tissues and thereby incites the inflammatory cascade.<sup>6</sup>

## CLINICAL FEATURES

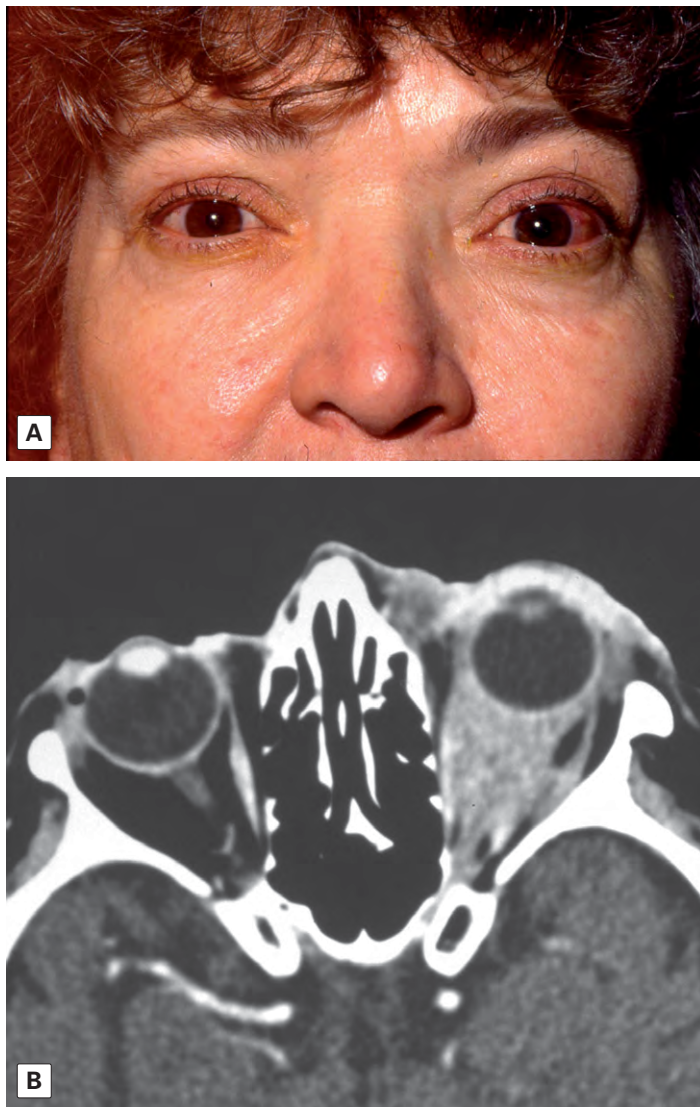There is no definite gender or racial predilection for this disorder, although a 2:1 female preponderance has been noted for orbital myositis and posterior scleritis.<sup>7</sup> The disease usually occurs in adults, but may also rarely affect children. NSOI in children differs from the adult presentation in a number of ways. Bilateral manifestation is much more common, as well as uveitis, elevated ESR, and eosinophilia.<sup>6</sup> Uveitis in particular, when present, appears to portend a poor outcome in children with NSOI.<sup>8</sup>

The symptoms and clinical findings in NSOI may vary widely, but are dictated by the degree and anatomic location of the inflammation. Anatomically, NSOI tends to occur in five orbital locations or patterns, the most common of which, in order of occurrence, are the extraocular muscles, lacrimal glands, anterior, apical, or diffuse orbital inflammation.<sup>9</sup> Inflammation localized to a specific anatomical site may acquire its own name, such as dacryoadenitis; inflammation localized to the lacrimal gland, or myositis; inflammation localized to one or more extraocular muscles.

**Symptoms** Non-specific orbital inflammation may be acute (within hours or days), subacute (days to weeks), or chronic (weeks to months) in onset. The most typical presentation is of acute-onset pain, redness, eyelid swelling, chemosis, and proptosis. In atypical cases, pain may be absent.<sup>10</sup> Chronic NSOI presents with a mass effect, inflammation and/or infiltration, resulting in variable deficits in function or vision.<sup>11</sup>

**Signs** The clinical findings vary based on the anatomic pattern of the inflammation. In addition to pain and lid swelling, diffuse inflammation of the globe can manifest as uveitis, papillitis, and exudative retinal detachment (Fig. 89.1).<sup>12</sup> Lacrimal gland and anterior inflammations may present with swollen, erythematous periorbital tissues, S-shaped lid deformity, and chemosis (Fig. 89.2). Although the



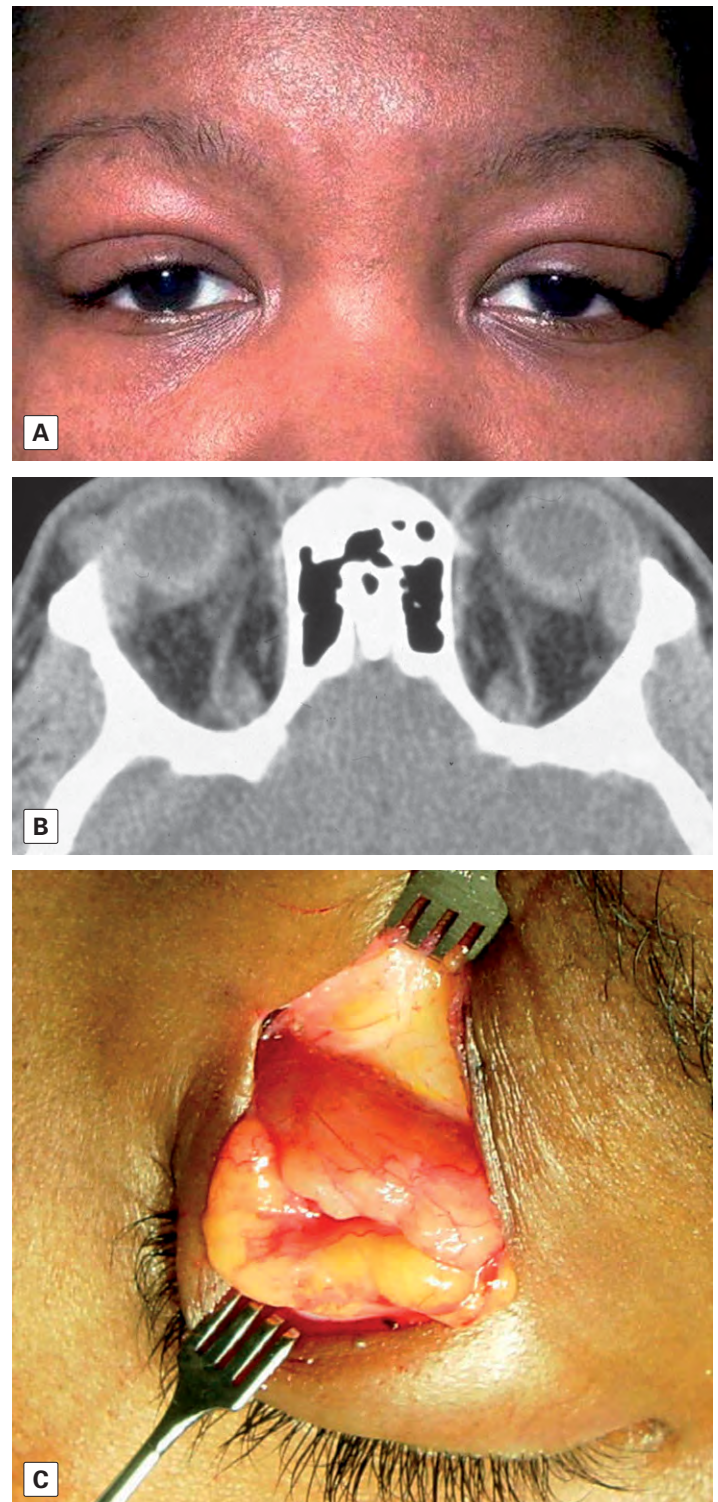


**Fig. 89.1** Diffuse orbital inflammation. Patient with painful proptosis and limited motility of left eye (A). Orbital CT reveals periocular and retrobulbar involvement of multiple tissues (B).

swelling may be dramatic, vision is often spared. In contrast, apical inflammation may appear quiet anteriorly, but present with proptosis and visual loss.

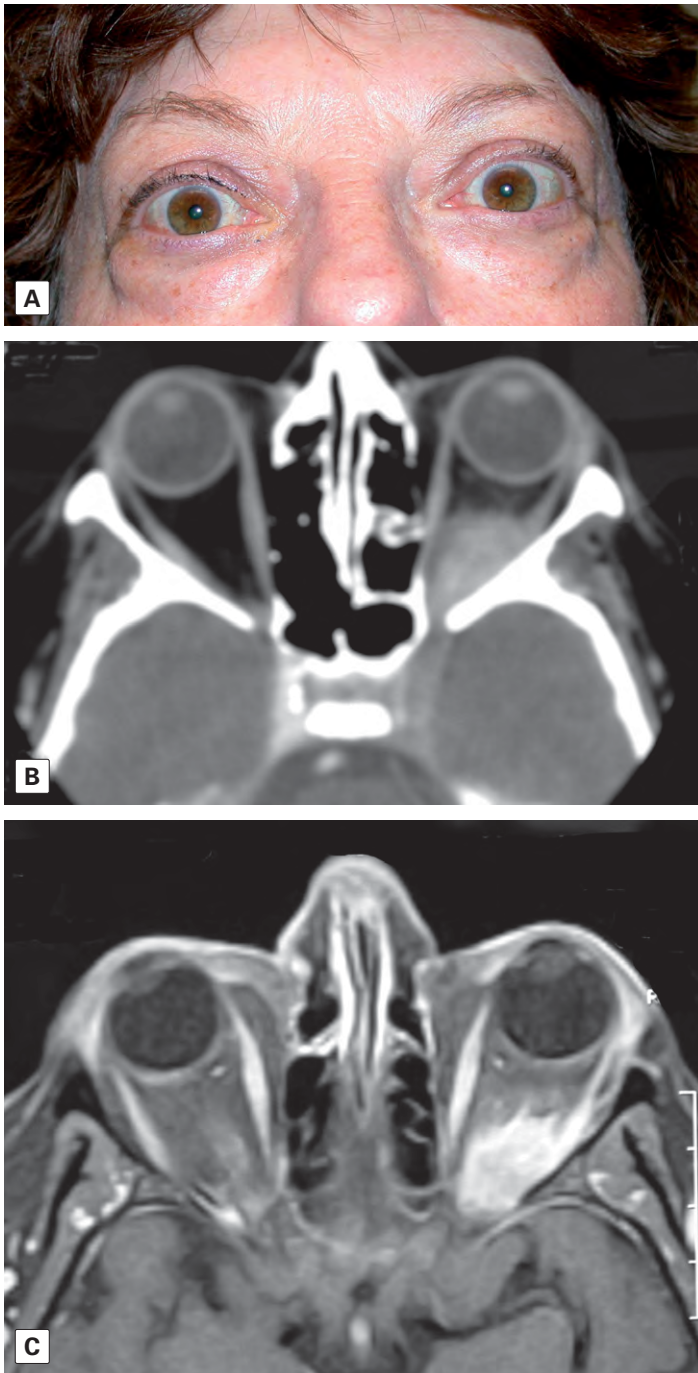
**Variants** Four clinical and pathological variants of NSOI deserve special mention: orbital myositis, orbital apex syndrome, sclerosing inflammation, and granulomatous inflammation.

**Orbital myositis** consists of inflammation involving one or more extraocular muscles in one or both orbits. Diplopia and pain exacerbated by eye movement are the presenting signs. Examination may reveal restriction of motility and positive forced ductions. Classically, orbital myositis is distinguished from thyroid-related orbitopathy, the most common cause of muscle enlargement, by tendon involvement. On imaging studies, myositis is characterized by thickening not only of the extraocular muscle belly, but also of the tendon. In contrast, thickening of the muscle tendon is not seen in thyroid-associated orbitopathy. Cases of myositis without tendon involvement, however, have been reported.<sup>13</sup>



**Fig. 89.2** Inflammation of the lacrimal gland. Patient with painful, bilateral periorbital swelling associated with S-shaped lateral lid deformity and preserved vision and motility (A). Orbital CT reveals homogenous enlargement of both lacrimal glands (B). Transcutaneous approach allows biopsy of the enlarged lacrimal gland (C).

**Orbital apex syndrome** Inflammation in the posterior orbit may present with findings of an orbital apex syndrome, which includes ophthalmoplegia, optic neuropathy, and proptosis (Fig. 89.3). Imaging reveals a diffuse, infiltrative lesion. Diagnostic considerations in such cases include a neoplasm, such as lymphoma, or an infectious orbital cellulitis, such as aspergillosis.<sup>14</sup>



**Fig. 89.3** Apical orbital inflammation. Patient with painful proptosis and optic neuropathy. Although the periorbital area and anterior segment are quiet (A), neuroimaging reveals an infiltrating lesion involving the orbital apex on a CT scan (B) and MRI (C).

**Sclerosing inflammation** A distinct sclerosing form of orbital inflammation has been identified which is characterized by dense fibrous replacement.<sup>15</sup> Long believed to represent the chronic end stage of the disease, it is now thought to represent a distinct clinicopathologic entity. This sclerosing form has been shown to be histologically similar to other fibroproliferative disorders, such as multifocal fibrosclerosis, a systemic disseminated fibrosing process that includes Riedel's thyroiditis, mediastinal fibrosis, sclerosing cholangitis, and fibrosis of the parotid gland, lacrimal gland and lung.<sup>16,17</sup> It has been suggested that fibrosis formation in these disorders is mediated

### BOX 89.1 Orbital Inflammation: Diagnostic Steps

- Contrast-enhanced magnetic resonance imaging with fat suppression
- Hematologic work-up
  - Complete blood count
  - Serum electrolytes
  - Sedimentation rate
  - Antinuclear antibody
  - Anti-ds DNA
  - Antineutrophil cytoplasmic antibody
  - Angiotensin-converting enzyme level
  - Rapid plasma reagin
- Biopsy (if indicated)

by the aberrant production of fibrogenic cytokines, such as platelet-derived growth factor (PDGF) and transforming growth factor- $\beta$  (TGF- $\beta$ ), which ultimately results in permanent alterations in tissue structure.<sup>18</sup>

**Granulomatous inflammation** Another distinct form displays granulomatous inflammation similar to sarcoidosis but is not associated with systemic sarcoidosis.<sup>19</sup>

### DIAGNOSTIC EVALUATION (BOX 89.1)

**Imaging** Although high-resolution orbital computerized tomography (CT) may demonstrate variable enhancement after administration of iodinated contrast material, contrast-enhanced magnetic resonance imaging (MRI) with fat suppression is the imaging study with the highest yield and should be performed when available. Subtle edema of the retrobulbar fat is often one of the earliest changes seen in NSOI. Orbital MRI typically shows a reticular pattern of orbital fat that is isointense to muscle in both T<sub>1</sub>- and T<sub>2</sub>-weighted images. In contrast, orbital cellulitis will be hyperintense to muscle in T<sub>2</sub>.<sup>20</sup>

Through neuroimaging, myositis can be distinguished from thyroid-associated orbitopathy, a specific orbital inflammation. Both demonstrate thickening of the muscle belly, but classically only myositis shows thickening of the tendon insertion as well. Bony change or destruction is rare in NSOI, but has been reported in cases with extra-orbital extension through the superior or inferior orbital fissure.<sup>21</sup>

### Laboratory testing

**Hematology** The diagnostic evaluation of a patient with suspected orbital inflammation should include a full hematologic work-up, with complete blood count (CBC), electrolytes, sedimentation rate, antinuclear antibody (ANA), anti-ds DNA, antineutrophil cytoplasmic antibody (ANCA), angiotensin-converting enzyme (ACE) level, and rapid plasma reagin (RPR).<sup>22</sup>

**Biopsy** The role of orbital biopsy in the management of NSOI is controversial. Although many authors have long advocated empiric steroid treatment while reserving orbital biopsy for atypical, non-steroid-responsive or recalcitrant cases of presumed orbital



inflammation, others advise biopsy before initiating treatment.<sup>23</sup> Although some consider a positive response to empiric corticosteroid treatment both therapeutic and diagnostic, empiric treatment may lead to some delayed and/or missed diagnoses.<sup>24</sup> Biopsy, on the other hand, allows definition of specific disease, identification of systemic implications, and more directed therapeutic treatment plans. In one study, 50% of biopsied inflammatory lacrimal gland lesions were associated with systemic disease, including Wegener's granulomatosis, sclerosing inflammation, Sjögren's syndrome, sarcoidal reactions, and autoimmune disease.<sup>25</sup> Given the low morbidity of the procedure and the high incidence of systemic disease involving the lacrimal gland, biopsy is recommended for isolated inflammation of the lacrimal gland (Fig. 89.2).<sup>12</sup>

Many advocate that almost all infiltrative lesions should be biopsied, except for two clinical scenarios, orbital myositis and orbital apex syndrome. In these situations, characteristic clinical and radiographic findings may strongly support the presumed diagnosis and the risk of biopsy must be weighed against the risk of a missed diagnosis. However, recurrent or non-responsive orbital myositis and orbital apex syndrome warrant orbital biopsy.

**Histopathology** in the acute phase of NSOI typically reveals a diffuse polymorphous infiltrate composed of mature lymphocytes, plasma cells, macrophages, eosinophils, and polymorphonuclear leukocytes. Vasculitis of small arteries may occasionally be found.<sup>1</sup> In the subacute and chronic phases, an increasing amount of fibrovascular stroma is seen.

**Immunohistochemistry** Recently proliferating cell nuclear antigen (PCNA), an immunohistochemical marker abundant in actively proliferating cells, has been proposed as an aid in differentiating between NSOI and lymphoproliferative diseases. In one study, PCNA activity was markedly increased in high-grade lymphoma compared to that in low-grade lymphoma and the non-specific inflammatory group.<sup>26</sup>

## DIFFERENTIAL DIAGNOSIS

NSOI is a diagnosis of exclusion, to be made only after all other specific causes of orbital inflammation have been eliminated (Table 89.1). Navigating through the differential diagnosis of diseases that can cause or simulate orbital inflammation is challenging; however, adhering to a methodical history and examination will help facilitate the process.

**Thyroid-associated orbitopathy (TAO)** is the most common specific inflammation of the orbit. It differs from NSOI in its clinical features, which include a lack of pain, the presence of eyelid retraction, the pattern of muscle involvement, and sparing of the extraocular muscle tendons on imaging. Eyelid retraction with lagophthalmos is characteristic of TAO, whereas mechanical ptosis typifies NSOI. Laboratory evaluation should include TSH, T<sub>4</sub>, and TSI (thyroid-stimulating immunoglobulin).<sup>5</sup>

**Wegener's granulomatosis** may present in a limited form, consisting of orbital inflammation but lacking airway or renal manifestations, called limited Wegener's.<sup>27</sup> These patients typically present with tearing due to nasolacrimal duct obstruction, sinusitis, and bone destruction. Laboratory evaluation should include cANCA, pANCA, BUN and creatinine, urine analysis, and CT scan of the chest.

**Table 89.1 Differential diagnosis of orbital inflammation**

Categories	Subtypes	
Thyroid-associated orbitopathy		
Infections	Bacterial	Spread from sinusitis
		Tuberculosis
		Syphilis
	Fungal	Mucormycosis
		Aspergillosis
	Parasitic	Echinococcosis
		Cysticercosis
Vasculitis	Wegener's granulomatosis	
	Polyarteritis nodosa	
	Hypersensitivity angiitis	
	Systemic lupus erythematosus	
	Giant cell arteritis	
Granulomatous inflammation	Sarcoidosis	
	Xanthogranulomatous	
	Foreign body granuloma	
	Erdheim-Chester disease	
	Sjögren's syndrome	
Non-inflammatory disorders	Lymphoid disorder	
	Dural-cavernous sinus arteriovenous fistula	
	Retained orbital foreign body	
Non-specific orbital inflammation (by exclusion)		

**Sarcoidosis** is a specific inflammatory syndrome of unknown etiology that may cause orbital inflammation in the form of insidious bilateral lacrimal gland enlargement without overlying eyelid erythema/edema. NSOI is typically unilateral, whereas sarcoidosis often presents bilaterally, and anterior uveitis and periphlebitis may precede orbital involvement. Gallium scan can show increased uptake at the sites of active sarcoid granulomata in the lacrimal glands and/or parotid glands. Laboratory abnormalities include an elevated angiotensin-converting enzyme (29%), calcium (7%) and lysozyme (29%), a CD4/CD8 ratio (80%), and an anergic reaction to skin sensitivity testing (43%).<sup>5</sup>

## TREATMENT

As the pathogenesis of NSOI remains unknown, management is directed toward the common consequence of the inflammatory cascade: tissue inflammation and destruction.

**Steroids** High-dose oral corticosteroids are commonly employed as the initial anti-inflammatory agent. The recommended starting dose for prednisone is 1 mg/kg/day, with a maximum adult dose of 60–80 mg/day. The recommended taper is 10 mg/day every 1–2 weeks. Typically the response is quick, with resolution of pain and proptosis within 24–48 hours after onset of the treatment. However, there are serious shortcomings to steroid therapy. Weight gain, mood swings, insomnia, and gastric upset are common, even with short-term therapy. Incomplete resolution of the condition, steroid dependence, and steroid intolerance are some of the other drawbacks associated with the use of steroids.<sup>28,29</sup>



**Steroid-sparing agents** Avoiding steroid-associated complications via alternative therapies is often desirable. Alternative therapeutic options include antimetabolites, such as methotrexate (15–25 mg/week), azathioprine, mycophenolate mofetil, and leflunomide; T-cell inhibitors ciclosporin and tacrolimus, and alkylating agents cyclophosphamide and chlorambucil. A multidisciplinary approach that utilizes the expertise of rheumatologists and/or oncologists is beneficial in organizing such treatment plans.<sup>5</sup>

**Radiation** External beam radiation has been used in the treatment of orbital inflammation with an efficacy of 50–80%. Careful patient selection, coordination with an experienced radiation therapist, and treatment planning are essential to maximize efficacy and minimize side effects. Doses of 10 Gy or less have been associated with an increased risk of recurrence. Ten to 30% of patients receiving radiation experience enhanced orbital inflammation that can be relieved by a short course of oral corticosteroids. Permanent dry eyes, optic neuropathy, or symptomatic retinopathy are rare side

effects that are seldom seen with appropriate fractionated delivery of less than 30 Gy. The risk of secondary tumors is higher in the young, and retinal ischemic complications are more prevalent in diabetic patients.<sup>5</sup>

**Surgery** Although incisional biopsy may play an important role in establishing a correct diagnosis, the treatment of NSOI is generally medical. Occasionally, surgical resection or debulking may be an effective alternative to medical and radiation therapy for localized lesions. For the most severe cases of orbital inflammation in which there is irretrievable loss of vision and uncontrollable pain, exenteration may be considered.

## PROGNOSIS

Although rapid resolution of pain and recovery of vision with steroid treatment is the common clinical course, the risk of recurrence ranges from 37% to 55%.<sup>28–30</sup> NSOI has not been shown to be a precursor for the development of lymphoma.

## REFERENCES

1. Kennerdell JS, Dresner SC. The non-specific orbital inflammatory syndromes. *Surv Ophthalmol* 1984; 29: 93–103.
2. Birch-Hirschfeld. *Handbuch der Gesamten Augenheilkunde*. Berlin: Julius Springer, 1930; 251.
3. Rootman J. Why 'orbital pseudotumour' is no longer a useful concept. *Br J Ophthalmol* 1998; 82: 339–340.
4. Atabay C, Tyutyunikov A, Scalise D et al. Serum antibodies reactive with eye muscle membrane antigens are detected in patients with non-specific orbital inflammation. *Ophthalmology* 1995; 102: 145–153.
5. Cockerham KP, Hong SH, Browne EE. Orbital inflammation. *Curr Neurol Neurosci Rep* 2003; 3: 401–409.
6. Mottow-Lippa L, Jakobiec FA, Smith M. Idiopathic inflammatory orbital pseudotumor in childhood. II. Results of diagnostic tests and biopsies. *Ophthalmology* 1981; 88: 565–574.
7. McCluskey PJ, Watson PG, Lightman S et al. Posterior scleritis: clinical features, systemic associations, and outcome in a large series of patients. *Ophthalmology* 1999; 106: 2380–2386.
8. Bloom JN, Graviss ER, Byrne BJ. Orbital pseudotumor in the differential diagnosis of pediatric uveitis. *J Pediatr Ophthalmol Strabismus* 1992; 29: 59–63.
9. Rootman J. Inflammatory diseases of the orbit. *Highlights. J Fr Ophtalmol* 2001; 24: 155–161.
10. Mahr MA, Salomao DR, Garrity JA. Inflammatory orbital pseudotumor with extension beyond the orbit. *Am J Ophthalmol* 2004; 138: 396–400.
11. Mombaerts I, Goldschmeding R, Schlingemann RO, Koornneef L. What is orbital pseudotumor? *Surv Ophthalmol* 1996; 41: 66–78.
12. Rootman J, Nugent R. The classification and management of acute orbital pseudotumors. *Ophthalmology* 1982; 89: 1040–1048.
13. Patrinely JR, Osborn AG, Anderson RL, Whiting AS. Computed tomographic features of nonthyroid extraocular muscle enlargement. *Ophthalmology* 1989; 96: 1038–1047.
14. Burde RM, Gittinger JW Jr, Keltner JL, Miller NR. Double vision, visual loss, and an enhancing orbital apex. *Surv Ophthalmol* 1988; 33: 55–61.
15. Weissler MC, Miller E, Fortune MA. Sclerosing orbital pseudotumor: a unique clinicopathologic entity. *Ann Otol Rhinol Laryngol* 1989; 98: 496–501.
16. Rootman J, McCarthy M, White V, Harris G, Kennerdell J. Idiopathic sclerosing inflammation of the orbit. A distinct clinicopathologic entity. *Ophthalmology* 1994; 101: 570–584.
17. McCarthy JM, White VA, Harris G et al. Idiopathic sclerosing inflammation of the orbit: immunohistologic analysis and comparison with retroperitoneal fibrosis. *Mod Pathol* 1993; 6: 581–587.
18. Kovacs EJ, DiPietro LA. Fibrogenic cytokines and connective tissue production. *FASEB J* 1994; 8: 854–861.
19. Raskin EM, McCormick SA, Maher EA, Della Rocca RC. Granulomatous idiopathic orbital inflammation. *Ophthalm Plast Reconstr Surg* 1995; 11: 131–135.
20. Uehara F, Ohba N. Diagnostic imaging in patients with orbital cellulitis and inflammatory pseudotumor. *Int Ophthalmol Clin* 2002; 42: 133–142.
21. Zborowska B, Ghabrial R, Selva D, McCluskey P. Idiopathic orbital inflammation with extraorbital extension: case series and review. *Eye* 2006; 20: 107–113.
22. Jacobs DA, Galetta SL. Orbital inflammatory disease. *Curr Treat Options Neurol* 2002; 4: 289–295.
23. Mauriello JA Jr, Flanagan JC. Pseudotumor and lymphoid tumor: distinct clinicopathologic entities. *Surv Ophthalmol* 1989; 34: 142–148.
24. Papalkar D, Sharma S, Francis IC et al. A rapidly fatal case of T-cell lymphoma presenting as idiopathic orbital inflammation. *Orbit* 2005; 24: 131–133.
25. Rootman J. Orbital disease: present status and future challenges. Boca Raton, FL: Taylor and Francis, 2005; 1–13.
26. Mauriello JA Jr, Piacentini M, Pokorny KS et al. The role of proliferating cell nuclear antigen (PCNA) in differentiating idiopathic orbital inflammatory disease and lymphoid proliferations. *Ophthalm Plast Reconstr Surg* 1997; 13: 26–30.
27. Perry SR, Rootman J, White VA. The clinical and pathologic constellation of Wegener granulomatosis of the orbit. *Ophthalmology* 1997; 104: 683–694.
28. Mombaerts I, Schlingemann RO, Goldschmeding R, Koornneef L. Are systemic corticosteroids useful in the management of orbital pseudotumors? *Ophthalmology* 1996; 103: 521–528.
29. Yuen SJ, Rubin PA. Idiopathic orbital inflammation: distribution, clinical features, and treatment outcome. *Arch Ophthalmol* 2003; 121: 491–499.
30. Maalouf T, Trouchaud-Michaud C, Angioi-Duprez K, George JL. What has become of our idiopathic inflammatory pseudo-tumors of the orbit? *Orbit* 1999; 18: 157–166.

# Vascular orbital tumors

Benson Chen MD and Julian D. Perry MD

## INTRODUCTION

Confusing terminology and a lack of consensus regarding classification has historically hindered clinical management of vascular orbital lesions. In 1999, The Orbital Society created a new classification of vascular lesions based on hemodynamic behavior. This new system guides management and prevents high-risk and unnecessary surgical intervention.<sup>1</sup> Infantile capillary hemangioma and cavernous hemangioma are thought to represent hamartomas, although some overlap exists. This chapter will discuss how distinction at the cellular level affects management options.

## VASCULAR MALFORMATIONS

Malformations result from errors in vascular development during the retiform stage of embryogenesis, at approximately day 48 of fetal development, and may occur as part of numerous congenital syndromes, including Sturge–Weber, Osler–Weber–Rendu, Wyburn–Mason, Klippel–Trenaunay and blue rubber bleb nevus (BLEB) syndrome. Lesions grow commensurately with age and never involute spontaneously. They are comprised of ectatic venous, arteriovenous, or lymphatic vessels lined with flat endothelial cells.

The Orbital Society's hemodynamic classification divides vascular malformations into three categories by flow characteristics: no-flow (type 1), venous-flow (type 2), and arterial flow (type 3). Each type of lesion poses significantly different challenges in management.

**No-flow (type 1) vascular malformations** These vascular malformations consist of hemodynamically isolated lymphatic or combined lymphatic and venous channels. Historically classified as hamartomas or lymphangiomas, lymphatic malformations typify this class of hemodynamic behavior. Lymphatic malformations consist of thin-walled ectatic channels lined with flat endothelium without evidence of smooth muscle. The channels contain serous fluid and lymphocytes surrounded by evidence of old hemorrhage and cholesterol clefts.

**Clinical features** No-flow malformations account for 3% of all orbital tumors. Over half of these lesions are diagnosed at birth (59%), with the rest typically presenting within the first few years of life. Unilateral proptosis or swelling occurs as the primary symptom in 76% of patients.<sup>2</sup> The edema classically exacerbates with respiratory infections and with prolonged recumbent positioning. Other presentations include spontaneous bleeding, orbital infection, ptosis, and strabismus. The spontaneous hemorrhage that typifies this malformation creates blood-filled 'chocolate' cysts. Spontaneous

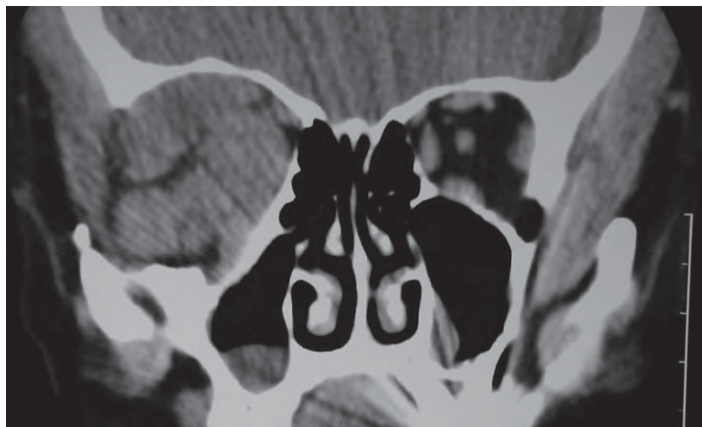hemorrhage frequently results in complications, including permanent vision loss.

**Diagnostic evaluation** Imaging studies show no evidence of venous or arterial flow (Fig. 90.1). Gadolinium-enhanced MRI optimally delineates the cystic compartments of these lesions, which can be intraconal, extraconal, or both. Old and new hemorrhages appear as fluid levels. Angiography reveals displaced normal veins around the lesions without filling. Direct injection of contrast using image guidance techniques and fluoroscopy confirm hemodynamic isolation without evidence of venous outflow channels.

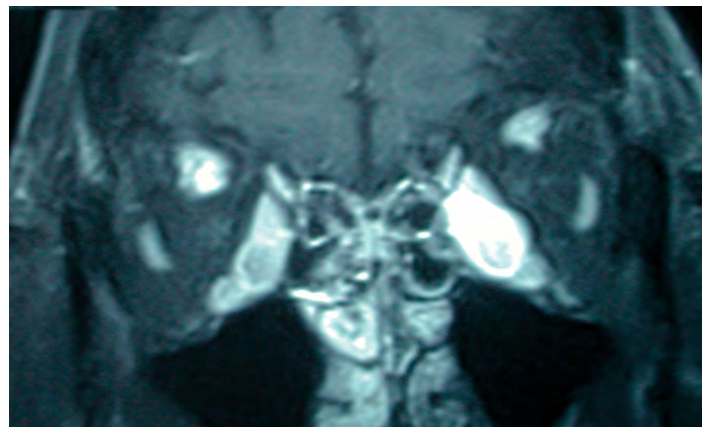**Treatment** often involves a multidisciplinary team, including an interventional radiologist and an orbital surgeon. Treatment remains risky, controversial, and only marginally effective, but common techniques include surgical debulking and sclerotherapy. Direct sclerotherapy through the eyelids uses stereotactic image-guided needle placement into the targeted cystic malformation. After confirmation of correct needle placement and lack of venous drainage channels using contrast fluoroscopy, sclerosing agent is injected to denude the luminal endothelium. Aspiration of the sclerosing agent collapses the cyst, permitting subsequent fibrosis to seal the malformation permanently. Effective agents include hypertonic saline, ethyl alcohol, sodium tetradecyl sulphate, ethanolamine oleate, and OK-432, but no comparisons exist.<sup>3</sup> Treatments appear successful in maintaining long-term closure.

Although technological improvements in the precision of guidance will eventually permit the treatment of smaller cysts, symptomatic microcysts often require surgical evacuation and excision. Other indications for surgical excision include symptomatic microcysts too small for sclerotherapy, and macrocysts that have failed sclerotherapy. Acute hemorrhage causing compressive optic neuropathy requires emergency surgical decompression or cyst evacuation.

The surgical approach to extraconal lesions depends primarily on their location. Removal of intraconal lesions carries a significant risk owing to neurovascular adhesions. These should be debulked only when absolutely necessary. Although complete excision can provide a cure, frequent extension through soft tissue planes makes complete excision impossible without violating orbital structure and function. The thin-walled lesions often rupture and collapse during surgery, hindering visibility. Injection of intraluminal fibrin sealant prior to excision may improve visibility and hemostasis.<sup>4</sup> After partial cyst excision, vaporization of remaining tissue with CO<sub>2</sub> laser may improve hemostasis and reduce recurrences.



**Fig. 90.1** Coronal CT imaging study shows lobulated appearance of lymphangioma (type 1 vascular lesion). Note surgical absence of the lateral wall.



**Fig. 90.2** Coronal Gd-DTPA-enhanced MRI shows bilateral contrast-enhancing lesions consistent with type 2 vascular lesions.

**Venous-flow (type 2) vascular malformations** Type 2 vascular malformations consist of venous and mixed venous/lymphatic channels that communicate with the venous system. Increased venous pressure may or may not cause distention, depending on the extent of the communication. Histopathology of venous malformation reveals large, thin-walled vessels. These channels are lined with flat endothelium with evidence of smooth muscle within fibrous stroma.

**Clinical features** The Orbital Society divides type 2 venous flow malformations into three subclasses: non-distensible venous, distensible venous, and distensible combined venous and lymphatic malformations. Non-distensible venous malformations behave clinically similar to type 1 lymphatic malformations, with frequent episodes of spontaneous thrombosis and hemorrhage. Doppler and contrast imaging show evidence of venous flow. Management of lesions with significant venous communication requires significantly greater caution because of the higher risk of venous thrombosis and bleeding.

Distensible venous malformations have a larger direct communication with the venous system and typically exhibit higher flow. These lesions less frequently exhibit spontaneous thrombosis and hemorrhage.

Distensible combined venous and lymphatic malformations possess both type 1 and 2 flow characteristics. The impact of any venous flow characteristics on clinical management emphasizes the type 2 classification of these combined malformations.

**Diagnostic evaluation** Color Doppler and directional ultrasound detect venous flow. CT and MRI reveal diffuse contrast enhancing lesions (Fig. 90.2). CT imaging can show distensibility, bony hypertrophy or intraosseous extension. MR imaging best delineates these lesions and may reveal fluid levels within combined malformations. MR angiography detects the venous flow through distensible lesions but is less successful at detecting slow flow in non-distensible lesions. Low-speed venous flow occasionally requires direct invasive fluoroscopy or CT angiography.

**Treatment** Surgical management for venous malformations in the orbit is notoriously difficult. Intralesional Nd:YAG laser, delivered by

optical fiber, has been recommended as a less invasive technique.<sup>5</sup> Other treatment modalities, including irradiation, electrocoagulation, cryotherapy, and compression, may be used alone or preoperatively to reduce bleeding complications. Recent advances in guidance technology have reduced the risks of sclerotherapy, which provides a relatively safe, less invasive treatment for symptomatic venous malformations. Sclerotherapy for venous malformations requires detailed pre-procedural evaluation by the interventional radiologist. Unlike isolated cystic lymphoid malformations, sclerotherapy of venous communicating lesions carries a significantly greater potential for severe bleeding complications. Inadvertent sclerosis of the ophthalmic vein and cavernous sinus results in immediate thrombosis, orbital compartment syndrome, and vision loss. Percutaneous image guidance methods can be used alone or in combination. X-ray fluoroscopy is frequently combined with duplex ultrasound. New methods include CT image fusion and frameless stereotactic guidance in combination with X-ray fluoroscopic monitoring of the injection. Any sclerosing agent extending toward vital venous drainage pathways must be prevented.<sup>6,7</sup>

Sclerotherapy works best with smaller caliber vessels and early treatment may offer greater success. Patients receive post-procedural intravenous steroids to prevent excessive inflammatory edema and an orbital compartment syndrome. Larger lesions often recanalize, and require multiple sessions every 3–6 weeks. Resistant lesions may ultimately require surgical treatment.<sup>8,9</sup>

**Surgery** Surgical excision of venous malformations carries a high risk of severe complications, including nerve damage, bleeding, inadvertent ophthalmic vein and cavernous sinus thrombosis, orbital compartment syndrome, and vision loss. These lesions often encase critical neuromuscular structures, making complete dissection difficult and recurrence rates high. Excellent exposure and visualization of the orbital apex achieved through a transcranial approach is often required.

Certain precautions can minimize the risk of severe intraoperative bleeding. In addition to sclerotherapy, embolization with fibrin sealant prior to excision may significantly reduce flow. Maintaining normothermia, hypotension, and elevation of the surgical field above the level of the heart further reduces the risk. Matched blood and platelet donor products should be available.



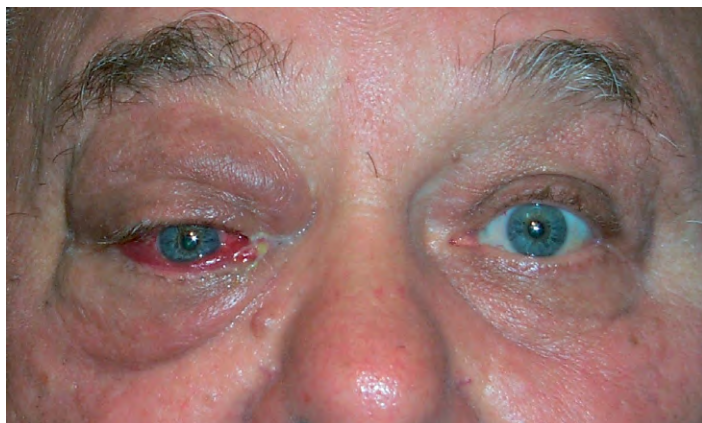**Arterial-flow (type 3) vascular malformations** Orbital arteriovenous malformations (AVM, type 3) display arterial-flow hemodynamics characterized by antegrade shunting of blood into the venous system. This congenital malformation begins as a slowly enlarging communication between carotid artery branches and orbital veins. Without intervening capillary beds, this low resistance nidus recruits multiple arteries and drains through multiple dilated veins. Often, both internal and external carotid branches act as feeder vessels. Histologically, the muscularis layer of the involved arteries and veins appears abnormal.

**Clinical features** AVMs typically present in children with progressive swelling, proptosis, redness, and pain. A bruit may be audible and proptosis is characteristically pulsatile. Painful swelling occurs on Valsalva maneuver and symptoms may be worse in the morning and improve during the day. Prolonged ocular ischemia may cause glaucoma and vision loss via progressive venous hypertension or diminished peak retinal arterial pressure from shunting. Venous hypertension may cause arterIALIZATION of conjunctival vessels (Fig. 90.3).

Although the nidus grows slowly, acute aggravation of symptoms may occur after spontaneous orbital hemorrhage. This presentation may mimic an acquired arteriovenous shunt. The older demography and angiographic characteristics help to distinguish acquired shunts from congenital malformations.

**Diagnostic evaluation** Directional ultrasound and color Doppler imaging show antegrade arterialized flow through dilated venous drainage channels. Angiography remains the standard for diagnosis and evaluates the internal and external carotid arterial systems, as well as the orbital venous system (Fig. 90.4).

**Treatment** Surgery alone risks bleeding and exsanguination. Preoperative endovascular embolization and gluing of the nidus significantly reduces the risks of ligation and debulking surgery. This technique employs a venous approach to avoid inadvertent embolization of critical ocular vessels. Provocative lidocaine testing can confirm radiologic positioning of the catheter distal to the central retinal artery (CRA) and posterior ciliary arteries. Owing to the rapid development of a collateral circulation and inflammation, excision is generally performed within 24–48 hours after embolization. Incomplete excision may result in rapid recurrence through recruitment of collateral vessels (Table 90.1).<sup>10–12</sup>

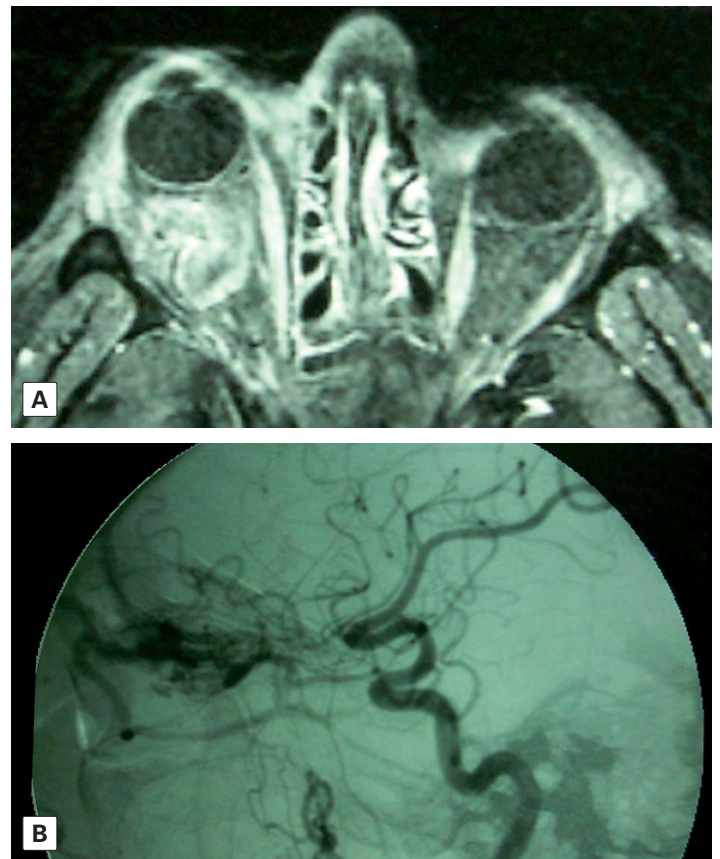


**Fig. 90.3** External photograph demonstrates severe arterIALIZATION and proptosis of the right eye in a patient with a type 3 orbital vascular lesion.

## INFANTILE CAPILLARY HEMANGIOMA

In 1982, Mulliken and Glowacki<sup>13</sup> proposed a classification of vascular anomalies by cellular activity, separating actively proliferating hemangioma from inactive congenital vascular malformation. Infantile capillary hemangioma represents the most common vascular tumor in children. Lined by plump propagating endothelial cells, capillary hemangioma consists of hamartomatous capillaries hemodynamically connected to normal vascular channels. An increased incidence in females, a hormonal responsive growth pattern, and immunohistochemical markers suggest a placental origin of this benign tumor.

**Clinical features** Orbital infantile capillary hemangioma typically presents within the first few months of life, with progressive unilateral swelling and proptosis, frequently with a visible dark blue anterior orbital component. Superficial extensions of lesions typically blanch on compression. Parents may report expansion of the lesions with crying. Large lesions may affect vision by causing astigmatism, corneal exposure, optic neuropathy, or amblyopia and may require therapy. Although considered a sporadic condition, a familial form may be under-reported and a family history should be obtained. Multiple hemangiomas should alert the clinician to systemic syndromes involving anomalies of the heart and intracranial posterior fossa. Hemangiomas associated with the Kasbach–Merritt syndrome carry high mortality due to platelet sequestration coagulopathy and high-output heart failure. Hemangiomas involving the nasopharynx may cause airway obstruction.<sup>14–17</sup>



**Fig. 90.4** MRI of orbital AVM shows enhancing lesion with flow voids (A). Angiography demonstrates communication with the internal and external carotid arteries (B).

**Table 90.1** Diagnostic features of orbital vascular lesions

Type	Flow	Imaging		Treatment
		Doppler US Angiography	CT MRI	
Lymphangioma (type I)	No flow	No flow	No enhancement Fluid levels	Debulking
Varix (type II)	Venous flow	Venous flow	Contrast enhancement Flow voids	Sclerotherapy, ligation and excision
AV malformation (type III)	Arterial flow	Arterial flow	Contrast enhancement Flow voids	Embolization then debulking

AV, arteriovenous; US, ultrasound; CT, computed tomography; MRI, magnetic resonance imaging.

**Table 90.2** Diagnostic features of infantile capillary hemangioma

Clinical	Imaging			Treatment
	US	Angiography	CT MRI	
Presentation (<age 1 year) Spontaneous involution (age 4–7 years) Superficial component red Deep component blue Expansion with crying	Irregular lesion with low internal reflectivity	Early blush with late staining	No bone involvement Contrast enhancement with late staining	Observation, laser, steroids

**Diagnostic evaluation** These lesions are characterized hemodynamically by dilated inflow and outflow channels on imaging. Ultrasound reveals an irregular lesion with low internal reflectivity. In the proliferative phase, CT and MRI reveal a lobulated, well-circumscribed, enhancing lesion without orbital bone involvement. MRI scanning shows hypointensity to fat on T<sub>1</sub>-weighted images and hyperintensity to fat on T<sub>2</sub>-weighted images. Angiography shows early blushing with late lobular parenchymal staining. Urine analysis may detect elevated levels of basic fibroblast growth factor (bFGF) and metalloproteinase (MMP) during active enlargement of infantile capillary hemangioma. These markers can monitor for involution or treatment progress (Table 90.2).<sup>18</sup>

**Treatment** These lesions exhibit a rapid growth phase over the first few months, followed by a gradual involutional phase and regression over 4–7 years. Most infantile capillary hemangiomas benefit from conservative observation because of a high rate of spontaneous involution. Life-threatening, visually impairing, and disfiguring lesions require treatment. Although superficial lesions respond well to a variety of treatments, including argon, YAG, and pulsed dye laser, and immunomodulating topical creams, deeper lesions often require steroids or surgical management.<sup>19,20</sup>

Localized intralesional steroid injection often induces the involutional phase and hastens regression. Molecular studies revealing similarities to wound healing may help explain the responsiveness to steroids.<sup>21</sup> Although a variety of steroid formulations have been effective, comparisons of their efficacy are unavailable. Many surgeons use a mixture of triamcinolone and betamethasone, with good success.<sup>22</sup> Injection into orbital lesions carries the serious risk of retinal arterial embolization and blindness. Slow injection under low pressure may

prevent retrograde arterial flow and minimize this complication.<sup>23</sup> Simultaneous dilated funduscopy during injection may detect emboli to allow for immediate discontinuation of the infusion. Ultrasound needle guidance can help monitor for retrograde flow.<sup>22,24</sup> Other complications include adrenal suppression, skin depigmentation, orbital fat necrosis, and localized calcification.<sup>25</sup> Posterior subtenon steroid infusion may reduce such systemic risks.<sup>26</sup> Systemic steroids (3 mg/kg/day for at least 6 weeks) can induce regression in life-threatening lesions causing glottic compression or high-output heart failure. Unresponsive lesions may benefit from interferon- $\alpha_{2a}$ .<sup>27</sup>

## CAVERNOUS HEMANGIOMA

Cavernous hemangioma, the most common benign orbital tumor in adults, is characterized as a hamartoma, but these lesions may behave as low-flow arterial side vascular malformations. Recent cases showing the coexistence of cavernous hemangioma with venous malformations has raised the possibility that these hamartomas share pathogenesis with vascular malformations.<sup>28,29</sup>

Cavernous hemangiomas consist of an encapsulated network of large-lumen channels connected to the normal arterial and venous system by small inflow and outflow channels. The endothelium appears flattened and stains positively for Factor VIII-related antigen. The channel walls contain multiple layers of spindle cells that stain positive for smooth muscle actin. Recent evidence of progesterone receptors within these spindle cells may help explain the increased incidence in women and the aggravation of symptoms during pregnancy.<sup>30</sup>

### Clinical features

**Symptoms** Cavernous hemangioma typically presents in a middle-aged adult with slowly progressive, painless proptosis. Vision may be

diminished due to compressive optic neuropathy or an induced hyperopic shift. Some patients complain of diplopia.

**Signs** Examination reveals signs of compressive optic neuropathy, axial proptosis, strabismus, choroidal folds, or disc edema. It is not infrequent for cavernous hemangioma to be detected incidentally when imaging studies of the brain are performed for unrelated symptoms.

**Diagnostic evaluation** CT scanning typically reveals a well-circumscribed, multiloculated, intraconal mass. Lesions appear hypo- or isointense on T<sub>1</sub>-weighted images and hyperintense on T<sub>2</sub>-weighted images (Fig. 90.5). Early images on angiography may show slow patchy enhancement, whereas later stages typically show more homogeneous pooling. Imaging may detect intracranial or cavernous sinus extension. Technetium-99m-labeled red blood cell scintigraphy can confirm the diagnosis, showing the combination of large blood volume with low flow.<sup>31</sup>

**Differential diagnosis** of cavernous hemangiomas includes all etiologies for slowly progressing axial proptosis: meningiomas, lymphangioma, hemangiopericytoma, and schwannoma.

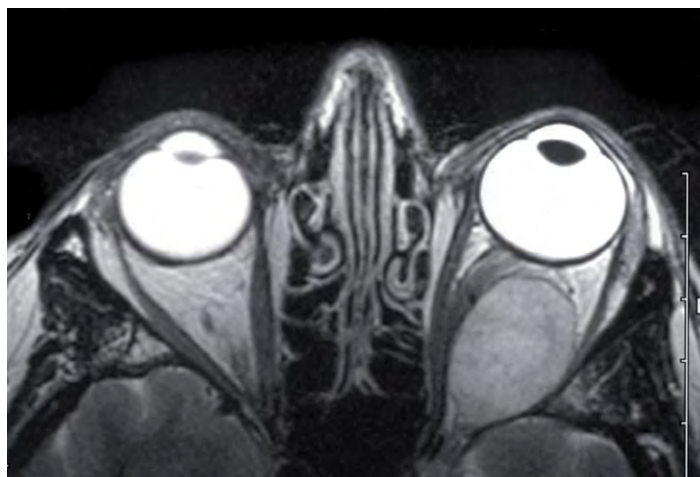
**Treatment** Patients without significant symptoms can be followed to detect evidence of progression. Many lesions stabilize and never require surgery, but patients must understand the urgency for immediate evaluation with symptoms of progression.

Surgical indications for symptomatic patients include proptosis, diplopia, compressive optic neuropathy, and gaze-evoked amaurosis. Lateral orbitotomy remains the standard approach to most intraconal cavernous hemangiomas, which typically lie lateral to the optic nerve.<sup>32</sup> Intraconal lesions located adjacent to the globe can be accessed using a transconjunctival approach. Hemangiomas may be decompressed prior to excision, or removed en bloc with temporary muscle disinsertion and use of a cryoprobe.<sup>33,34</sup> Apical tumors or larger lesions located superior to the optic nerve may require better exposure via a transcranial approach.

**Prognosis** Excisional surgery should result in a cure for symptomatic lesions.

## HEMANGIOPERICYTOMA

Hemangiopericytomas are characterized by a spectrum of pericyte proliferation. Histopathology often shows a mixed pattern of ovoid cells and sinusoidal space formations, creating the classic 'staghorn' vascular pattern. Varying levels of cellular atypia underlie the less benign nature of this lesion, implying malignant transformation or metastasis.



**Fig. 90.5** MRI of cavernous hemangioma. The lesion is circumscribed and appears hyperintense on T<sub>2</sub>-weighted images.

**Clinical features** Hemangiopericytoma typically presents in middle-aged adults as slowly progressing unilateral proptosis, often with pain and vision loss. Other signs and symptoms depend on tumor location. Frequent intracranial extension and invasion into sinus cavities may produce associated symptoms.

**Diagnostic evaluation** On MRI, T<sub>1</sub>-weighted images reveal a well-defined hypointense mass. T<sub>2</sub>-weighted studies show less definition. CT imaging often detects bony changes around these contrast-enhancing lesions. Angiography typically reveals early tumor blush with rapid washout of contrast. Diagnosis of this lesion requires histologic confirmation.

**Differential diagnosis** for hemangiopericytoma includes meningioma, lymphangioma, cavernous hemangioma, and schwannoma.

**Treatment** Although the majority of these lesions are benign, the high rate of malignant transformation and recurrent disease mandates aggressive en bloc excision with wide margins. Adjunctive radiation therapy may be of benefit, although owing to the rarity of this tumor there is no conclusive evidence supporting any such benefit.<sup>35,36</sup>

**Prognosis** The spectrum of aggressiveness of a particular lesion is difficult to predict, as even more histologically benign lesions may result in clinically invasive disease or malignant transformation. The elusive nature of this entity warrants aggressive surgery and often adjuvant therapy.

## REFERENCES

- Harris GJ. Orbital vascular malformations: a consensus statement on terminology and its clinical implications. Orbital Society. *Am J Ophthalmol* 1999; 127: 453–455.
- Greene AK, Burrows PE, Smith L, Mulliken JB. Periorbital lymphatic malformation: clinical course and management in 42 patients. *Plast Reconstruct Surg* 2005; 115: 22–30.
- Hall N, Ade-Ajai N, Pierro A et al. Is intralesional injection of OK-432 effective in the treatment of lymphangioma in children? *Surgery* 2003; 133: 238–242.
- Boulos PR, Harissi-Dagher M, Kavalec C, Hardy I, Codere F. Intralesional injection of Tisseel fibrin glue for resection of lymphangiomas and other thin-walled orbital cysts. *Ophthalm Plast Reconstruct Surg* 2005; 21: 171–176.
- Werner JA, Dunne AA, Folz BJ et al. Current concepts in the classification, diagnosis and treatment of hemangiomas and vascular malformations of the head and neck. *Eur Arch Otorhinolaryngol* 2001; 258: 141–149.
- Ernemann U, Westendorff C, Troitzsch D et al. Navigation-assisted sclerotherapy of orbital veno-lymphatic malformation: a new guidance technique for percutaneous



- treatment of low-flow vascular malformations. *Am J Neuroradiol* 2004; 25: 1792–1795.
7. Hayashi N, Masumoto T, Okubo T et al. Hemangiomas in the face and extremities: MR-guided sclerotherapy—optimization with monitoring of signal intensity changes in vivo. *Radiology* 2003; 226: 567–572.
  8. De Lorimier AA. Sclerotherapy for venous malformations. *J Pediatr Surg* 1995; 30: 188–193.
  9. Lee CH, Chen SG. Direct percutaneous ethanol sclerotherapy for treatment of a recurrent venous malformation in the periorbital region. *Aust NZ J Surg* 2004; 74: 1126–1127.
  10. Goldberg RA, Garcia GH, Duckwiler GR. Combined embolization and surgical treatment of arteriovenous malformation of the orbit. *Am J Ophthalmol* 1993; 116: 17–25.
  11. Hayes BH, Shore JW, Westfall CT, Harris GJ. Management of orbital and periorbital arteriovenous malformations. *Ophthalm Surg* 1995; 26: 145–152.
  12. Lee BB, Do YS, Yakes W et al. Management of arteriovenous malformations: a multidisciplinary approach. *J Vasc Surg* 2004; 39: 590–600.
  13. Mulliken JB, Glowacki J. Hemangiomas and vascular malformations in infants and children: a classification based on endothelial characteristics. *Plast Reconstruct Surg* 1982; 69: 412–422.
  14. Coats DK, Paysse EA, Levy ML. PHACE: a neurocutaneous syndrome with important ophthalmologic implications: case report and literature review. *Ophthalmology* 1999; 106: 1739–1741.
  15. Walter JW, Blei F, Anderson JL et al. Genetic mapping of a novel familial form of infantile hemangioma. *Am J Med Genet* 1999; 82: 77–83.
  16. Shields CL, Shields JA, Minzter R et al. Cutaneous capillary hemangiomas of the eyelid, scalp, and digits in premature triplets. *Am J Ophthalmol* 2000; 129: 528–531.
  17. Drolet BA, Esterly NB, Frieden IJ. Hemangiomas in children. *N Engl J Med* 1999; 341: 173–181.
  18. Marler JJ, Fishman SJ, Kilroy SM et al. Increased expression of urinary matrix metalloproteinases parallels the extent and activity of vascular anomalies. *Pediatrics* 2005; 116: 38–45.
  19. Berman B, Poochareon VN, Villa AM. Novel dermatologic uses of the immune response modifier imiquimod 5% cream. *Skin Therapy Lett* 2002; 7: 1–10.
  20. Clymer MA, Fortune DS, Reinisch L et al. Interstitial Nd:YAG photocoagulation for vascular malformations and hemangiomas in childhood. *Arch Otolaryngol Head Neck Surg* 1998; 124: 431–436.
  21. North PE, Waner M, Mizeraki A, Mihm MC. GLUT 1: A newly discovered immunohistochemical marker for juvenile hemangiomas. *Hum Pathol* 2000; 31: 11–22.
  22. Neumann D, Isenberg SJ, Rosenbaum AL, Goldberg RA, Jotterand VH. Ultrasonographically guided injection of corticosteroids for the treatment of retroseptal capillary hemangiomas in infants. *J AAPOS* 1997; 1: 34–40.
  23. Egbert JE, Paul S, Engel WK, Summers CG. High injection pressure during intralesional injection of corticosteroids into capillary hemangiomas. *Arch Ophthalmol*. 2001; 119: 677–683.
  24. Egbert JE, Schwartz GS, Walsh AW. Diagnosis and treatment of an ophthalmic artery occlusion during an intralesional injection of corticosteroid into an eyelid capillary hemangioma. *Am J Ophthalmol* 1996; 121: 638–642.
  25. Goyal R, Watts P, Lane CM, Beck L, Gregory JW. Adrenal suppression and failure to thrive after steroid injections for periocular hemangioma. *Ophthalmology* 2004; 111: 389–395.
  26. Coats DK, O'Neil JW, Paysse EA et al. SubTenon's infusion of steroids for treatment of orbital hemangiomas. *Ophthalmology* 2003; 110: 1255–1259.
  27. Ezekowitz RA, Mulliken JB, Folkman J. Interferon alfa-2a therapy for life-threatening hemangiomas of infancy. *N Engl J Med* 1992; 326: 1456–1463.
  28. Kodama T, Tane N, Ohira A, Matsuoka Y, Maruyama R. Concomitant cavernous hemangioma and venous angioma of the orbit. *Jpn J Ophthalmol* 2004; 48: 415–417.
  29. Gelal F, Feran H, Rezanko T, Vidinli BD. Giant cavernous angioma of the temporal lobe: a case report and review of the literature. *Acta Radiol* 2005; 46: 310–313.
  30. Di Tommaso L, Scarpellini F, Salvi F, Ragazzini T, Foschini MP. Progesterone receptor expression in orbital cavernous hemangiomas. *Virchows Arch* 2000; 436: 284–288.
  31. Gdal-On M, Israel O. Cryoextraction of orbital hemangiomas diagnosed by Tc-99m-labeled red blood cells. *Vision Res* 1995; 35: 169.
  32. McNab AA, Wright JE. Cavernous haemangiomas of the orbit. *Aust NZ J Ophthalmol* 1989; 17: 337–345.
  33. Goldberg RA, Garcia GH, Duckwiler GR. Combined embolization and surgical treatment of arteriovenous malformation of the orbit. *Am J Ophthalmol* 1993; 116: 17–25.
  34. Kiratli H, Bulur B, Bilgic S. Transconjunctival approach for retrobulbar intraconal orbital cavernous hemangiomas. Orbital surgeon's perspective. *Surg Neurol* 2005; 64: 71–74.
  35. Karciglu ZA, Nasr AM, Haik BG. Orbital hemangiopericytoma: clinical and morphologic features. *Am J Ophthalmol* 1997; 124: 661–672.
  36. Croxatto JO, Font RL. Hemangiopericytoma of the orbit: a clinicopathologic study of 30 cases. *Hum Pathol* 1982; 13: 210–218.

# Benign tumors of the orbit

Bhupendra C. K. Patel

## INTRODUCTION

Benign orbital tumors represent a broad spectrum of tumors (Chapter 86). In addition, orbital inflammation and infection may clinically simulate an orbital neoplasm (Chapter 89). In a recent survey of 1264 consecutive patients with suspected orbital tumor referred to an ophthalmic oncology center, 64% of the lesions were benign.<sup>1</sup>

Benign orbital tumors may be congenital or, more frequently, acquired. Benign tumors are more commonly of vascular (Chapter 90), neural (Chapter 92), meningeal, fibrocytic, and osseous origin. Benign tumors may also arise from the lacrimal gland (Chapter 93) and lacrimal sac (Chapter 94). The detail of clinical examination (Chapter 84), clinical evaluation (Chapters 87 and 88), and imaging techniques (Chapter 85) supplement the contents of this chapter. Benign orbital tumors not covered under other chapters are reviewed herein.

## DERMOID AND EPIDERMOID CYSTS

Dermoids cysts are the most common orbital cysts, representing up to 5% of all orbital tumors.<sup>1</sup> Epidermoid cysts have a single layer of keratinized or non-keratinized epithelium without evidence of adnexal structures. Most epidermoid cysts are traumatic in origin.<sup>2</sup> Dermoids, on the other hand, are choristomas with adnexal structures such as hair, sebaceous glands, and lipid. They arise from ectodermal nests pinched off at suture lines. Clinically, dermoid and epidermoid cysts may present very similarly and so are now usually differentiated by location: superficial or deep. Histopathology of dermoids may show hair, keratin, sebaceous glands, macrophages, lipid globules, multinucleated giant cells, and calcium.

**Clinical features** Most dermoid cysts present in infancy with a well-defined, round periorbital mass. Approximately 60% of all dermoids arise superotemporally from the frontozygomatic suture; 25% arise superomedially from the frontolacrimal suture (Fig. 91.1).<sup>3</sup> Others may arise from frontoethmoidal sutures and in the deep temporal fossa.<sup>4</sup> A few may arise from the sphenozygomatic suture.

The cysts are usually less than 2 cm in diameter and cause little ocular displacement. They are smooth, firm, non-tender and non-fluctuant. Many are not intraorbital, but sit on the frontozygomatic suture or just behind the orbital rim. Mild lateral upper eyelid ptosis is often seen. Deeper dermoids may be seen along the medial and lateral orbital walls. These deeper dermoids remodel bone over many years. They may cause extraorbital expansion of the cyst into the temporal fossa or into the intracranial cavity.<sup>5</sup> Such patients may present

with proptosis on mastication.<sup>6</sup> Deeper cysts often present later, in the third or fourth decade. Other presentations of deep cysts include proptosis and displacement of the eye opposite to the site of the cyst. Most patients will not have diplopia or visual problems as the cysts are of long duration.<sup>7</sup>

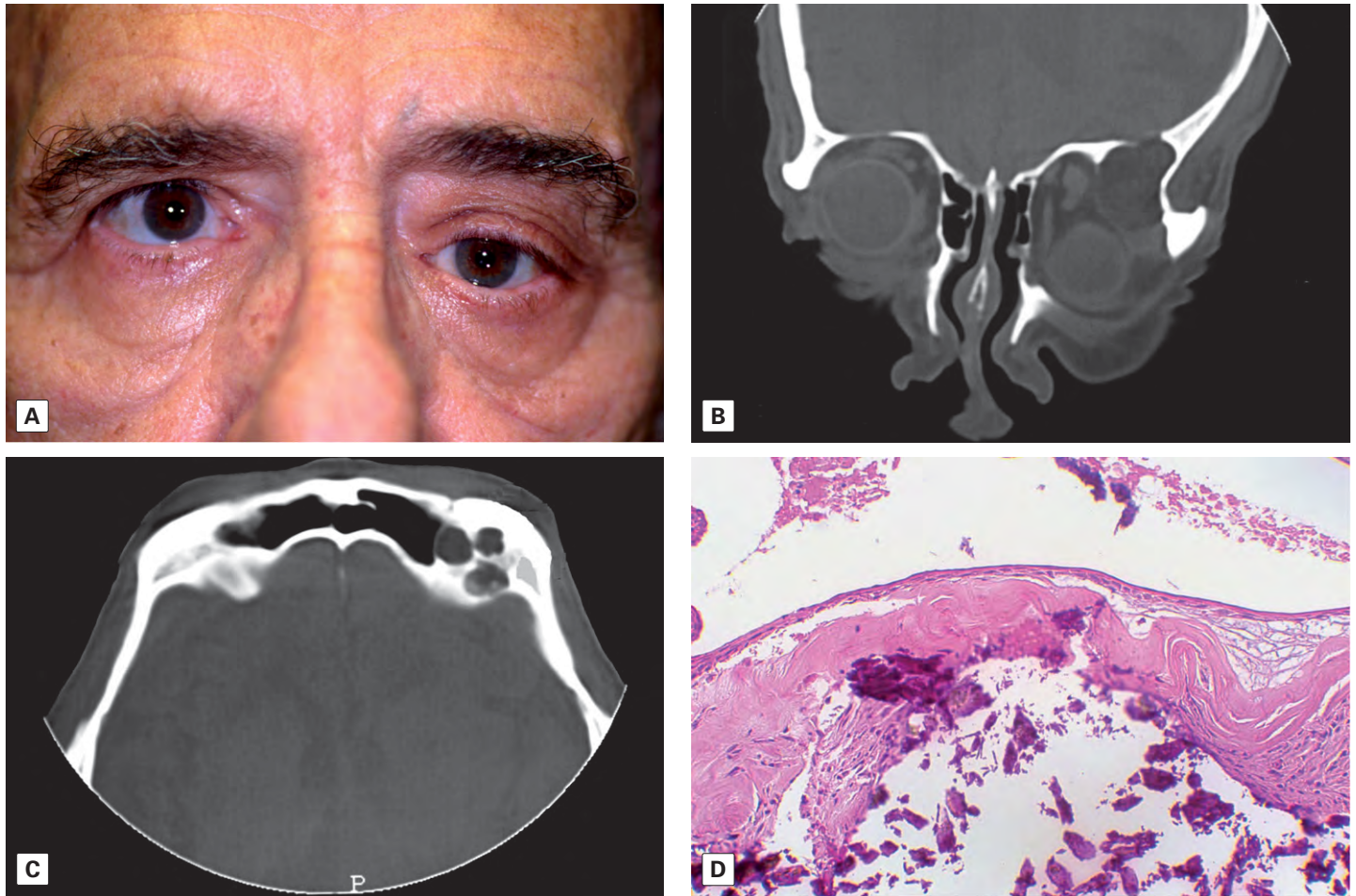
Patients may present with discomfort because of leakage. Asymptomatic leakage of lipid and keratin may lead to inflammation and adherence of the dermoid cyst to neighboring structures. Intermittent lid swelling with localized redness and pain may be seen. Chronic inflammation may be seen even in asymptomatic patients. Ruptured dermoids may present with a fistula to the skin.<sup>8</sup>

**Differential diagnosis** Superomedial lesions may be confused with retention cysts and orbitofrontal mucoceles. Medial dermoids must be differentiated from encephaloceles. Deep midline intranasal dermoid cysts may present like discharging lacrimal sac mucoceles in children. Unlike mucoceles, the dermoids present with a central cutaneous dimple.

Deep superotemporal dermoids should be differentiated from lacrimal gland tumors radiographically, as dermoids often are isodense to fat, and produce bony changes only in proximity to the frontozygomatic suture. Ultrasound may help confirm the cystic nature of the dermoid, although debris within the cyst may make the distinction difficult.

**Diagnostic evaluation** On CT scans the majority of orbital dermoids have some adjacent bony changes, which are rounded and well defined (Fig. 91.1). A well-defined wall is seen with a center of fat density. Some will show calcification and fluid levels. In the presence of a previous rupture the margins may be irregular. The presence of a tunnel, channel, or cleft through the adjacent wall is noted in as many as a third of cases.<sup>9</sup> Many patients have a blind pit or cleft in the bone. Irregular bony margins suggest rupture with granulomatous distribution of the adjacent bone. Posterior masses may show bony pressure effects. Ultrasonography may be used for an anterior cyst.

**Treatment** The surgical aim is to remove the dermoid completely. Dermoids presenting in childhood are removed soon after presentation to avoid traumatic rupture. Most can be safely removed via an anterior or anterolateral orbitotomy. An upper eyelid skin crease approach with appropriate distraction of the incision can be used for removal of most superolateral dermoids. The cryoprobe may be used to provide traction during the dissection around the wall. While the plane of



**Fig. 91.1** Dermoid cyst. A 75-year-old man presented with left proptosis and hypoglobus with double vision of several months duration (A). CT scan demonstrated thinning of the superotemporal orbital wall (B) (coronal view) and a cystic lesion (C) (axial view). The cyst wall is lined with stratified epithelium and there is keratin within the lumen (D).

dissection is easier to follow if the cyst is intact, sometimes, especially with large cysts, decompression is necessary to allow complete excision. If an inadvertent rupture of the cyst should occur, the area should be irrigated with an antibiotic solution and the contents and lining should be meticulously removed.

Deeper superotemporal and inferotemporal cysts can be accessed via a lateral orbitotomy with removal of the lateral orbital wall.<sup>10</sup> A transfrontal craniotomy approach is used when cysts extend intracranially and for cysts at the apex of the orbit. Dumb-bell tumors with extension into the temporal fossa are removed first from the orbit. The temporal component and the bony canal are subsequently removed. The bony tunnel should be cored out to remove the connecting stalk in dumb-bell tumors.

### MUCOCELE

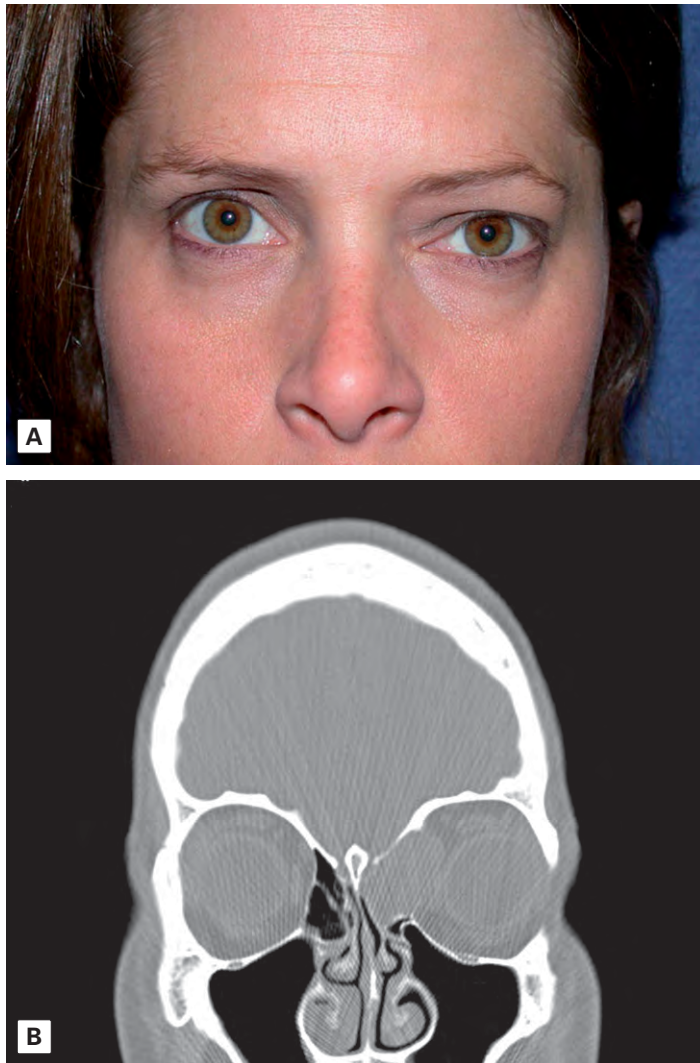
Mucoceleles occur mostly in adults; 60% affect the frontal sinus, 30% occur in the ethmoid sinus, and 10% occur in the maxillary sinus. They develop secondary to an obstruction of the ostium of the affected sinus. Mucoceleles may result from facial fractures, nasal or sinus surgery, paranasal osteomas, chronic polyposis, or congenital

abnormalities.<sup>11</sup> Mucoceleles in childhood suggest underlying cystic fibrosis.

**Clinical features** Obstruction of the normal sinus ostia will create entrapment of the secretory epithelium, the accumulation of mucus, pressure on the surrounding bony structures, thinning of the bony walls, and extension through the wall into the adjacent orbit, nasopharynx, or cranial cavity.<sup>12</sup> Mucocelele may develop slowly with subacute exacerbations mimicking orbital cellulitis. Extension of the mucocelele into the orbit will result in proptosis or other globe displacement, ptosis, a palpable superonasal mass, diplopia, headache, orbital pain, or visual impairment (Fig. 91.2). Orbital apex involvement may lead to orbital apex syndrome, with deep orbital pain, headache, and visual impairment.

**Frontoethmoid mucocelele** Clinical features are dependent on the location of the sinus involved. Frontoethmoid mucocelele may present with superomedial fullness, inferolateral displacement, epiphora, hypertelorism, or fistula.<sup>13</sup> Hypertelorism, seen more often in bilateral mucoceleles, may be associated with cystic fibrosis.





**Fig. 91.2** Frontal mucocoele. A 38-year-old woman with a 2-week history of left periorbital pain and diplopia on upgaze (A). CT scan demonstrating left frontal mucocoele with opacification of the frontal sinus and erosion of the superomedial orbital wall (B). The orbital component is well defined and rounded. The orbital structures are displaced inferiorly and laterally.

*Sphenoid and posterior ethmoid sinus mucocoele* may cause visual changes and proptosis.

*Maxillary mucocoele* usually causes proptosis, but may cause enophthalmos secondary to erosion of the floor of the orbit.<sup>14</sup>

**Diagnostic evaluation** CT scans show a well-defined homogenous mass isodense with brain. Cystic contents completely fill the enlarged sinus and displace, rather than destroy, the bony margins (Fig. 91.2). The bone thins and the mucocoele becomes part of the orbit.

**Treatment** involves complete surgical removal of the lining and re-establishment of normal drainage or obliteration of the sinus. The optimal obliteration technique remains controversial. Methods include the use of muscle, fat, and alloplastic materials. Repair of the bony defect is rarely required. Displacement of the globe often improves after effective treatment.<sup>15</sup>

### CHOLESTEROL GRANULOMA

The nomenclature for cholesterol granuloma has changed from previous terms, including hematic cyst, hematoma, hematocele, chocolate cyst, blood cyst, subperiosteal hemorrhage, and orbital cholesteatoma. A cholesterol granuloma is not a true cyst, as it lacks an epithelial lining.

Cholesterol granulomas are seen mostly in men in the superotemporal orbital wall and sometimes in the zygoma. Although factors causing elevated venous pressure, blood clotting diseases, and other causes have been invoked, it is now recognized that most cholesterol granulomas are caused by previous trauma.<sup>16</sup> Hematogenous debris accumulation creates an osmotic gradient with resultant absorption of fluid and increased volume. An anticoagulant effect caused by high concentrations of fibrinogen degradation products may also result in recurrent hemorrhage.

**Clinical features** The patient usually presents with a superolateral mass developing over weeks to years, causing inferior globe displacement, proptosis, and limited upgaze with diplopia. The patient may rarely have blurred vision. Headache or pain in the region of the mass may also occur.

**Diagnostic evaluation** CT scans reveal a well-defined, non-enhancing osteolytic lesion with bone erosion and sometimes intralésional bone fragments. The mass is usually homogeneous and isodense with the brain.<sup>17</sup> The smooth margins contrast with the moth-eaten appearance seen with malignant tumors such as plasma cell myeloma. These lesions do not transgress the frontozygomatic suture. The differential diagnosis includes dermoid cyst and lacrimal gland carcinoma.

**Treatment** Surgical evacuation of the lesion via a percutaneous approach is usually curative. There is usually a yellow-brown viscous material within the cavity containing friable tissue and loose bone. The bone itself may be yellow. The fluid is altered blood in various stages of degeneration and organization. Bone wax may be used to control oozing that occurs from the bony lining. Occasionally, a drain may be necessary at the end of the procedure. It is not necessary to pack the cavity. Recurrence is rare.

### ORBITAL CEPHALOCELE

Cephaloceles are protrusions of brain tissue through bony defects. An encephalocele is a protrusion of the parenchymal brain. A meningocele has protrusion of dura, whereas a mixture of brain and meninges is a meningoencephalocele. All cephaloceles retain some attachment to the brain by a cord or stalk of tissue. These are often associated with other congenital facial anomalies involving the midline structures.

**Clinical features** Cephaloceles may be anterior, basal, or posterior.

*Anterior cephalocele* is the most common, presenting as a paranasal mass located at the nasofrontal–orbital junction. The lesion may be soft or firm and is usually painless.

*Basal cephalocele* is associated with a defect in the cribriform plate and presents with a midline mass. The patient may have a broad nasal root, hypertelorism, and inferolateral globe displacement. The basal

cephalocele may be confused with a mucocele and may also present as bilateral nasolacrimal duct obstructions.<sup>18</sup>

**Posterior cephalocele** Posterior orbital cephalocele is less common; they herniate through a foramen or a dehiscence in the sphenoid bone and may present with pulsatile proptosis, optic nerve atrophy, and strabismus.<sup>19</sup>

**Diagnostic evaluation** CT scans show a homogeneous lesion, isodense with the brain. Dermoid and teratoma show more fluid content. Mucocele is usually present below the medial canthal tendon, whereas cephalocele is located above the tendon.

**Treatment** involves excision of the extracranial extension and stalk and repair of the dural and bony defect. Surgical repair involves a combined craniofacial and neurosurgical approach with correction of other facial deformities.<sup>20</sup>

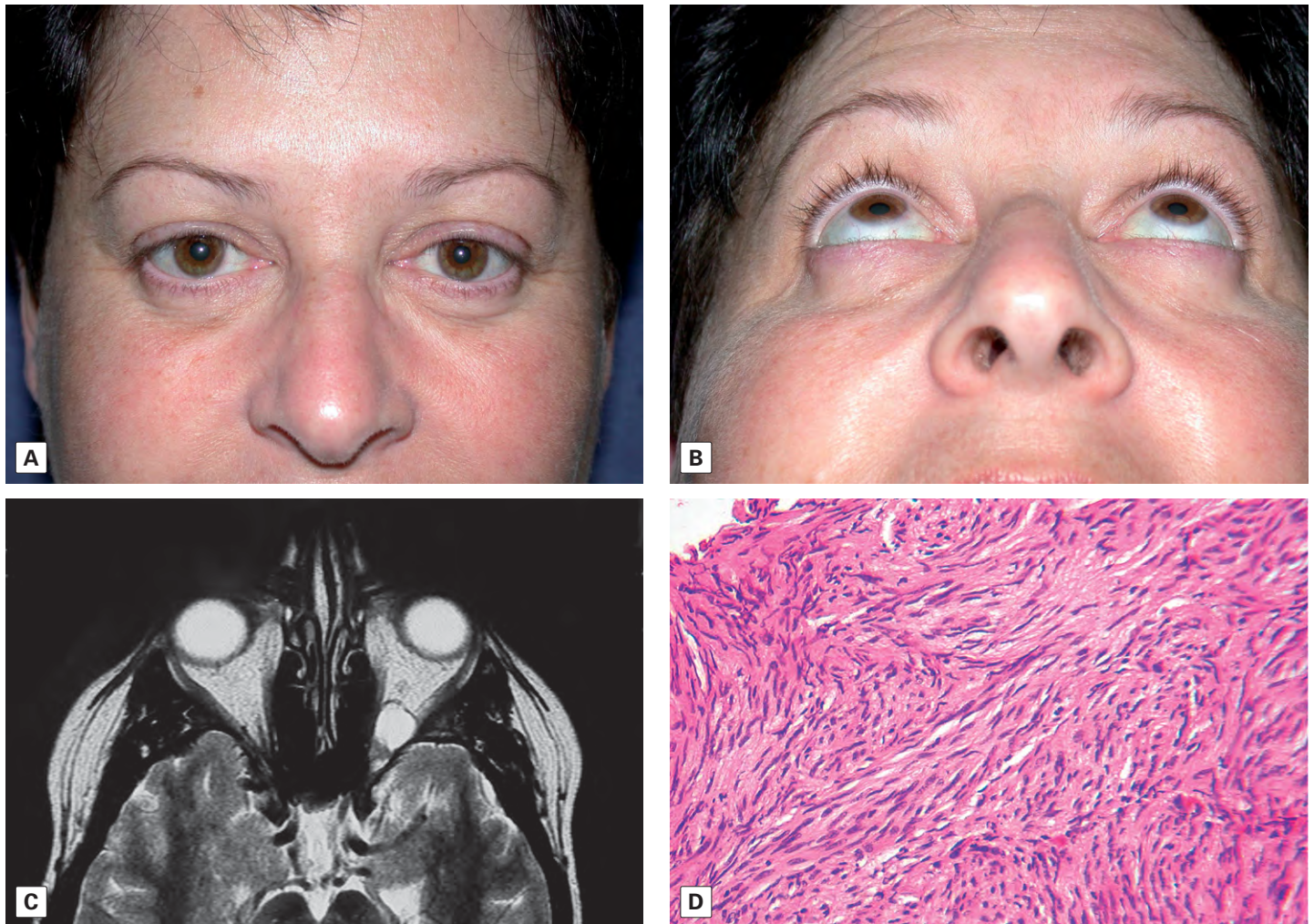
### NEUROFIBROMA AND NEURILEMMOMA (SCHWANNOMA)

Neurofibromas are twice as common as schwannomas in the orbit, and together constitute 4% of all orbital tumors. Isolated, solitary

neurofibromas, usually present in middle age and in 90% of instances are unassociated with neurofibromatosis. Plexiform neurofibromas may involve any of the cranial, sympathetic, and parasympathetic nerves in the orbit. Schwannomas are well-defined, encapsulated, slowly growing tumors that develop as eccentric growths from peripheral nerves. They are usually solitary and may also be associated with neurofibromatosis.

**Clinical features** Most neurofibromas and neurilemmomas manifest as a solitary mass, frequently in the upper quadrants. They are solid, isolated, circumscribed, slow-growing masses leading to displacement and local expansion of the orbit with associated anesthesia, paresthesia, and hypesthesia.<sup>21,22</sup> In more superficial locations, the tortuous enlarged nerves produce a characteristic 'bag of worms' feel and the overlying skin may be thickened (elephantiasis neuromatosa). When intraconal, the tumor presents with proptosis, lid swelling, posterior indentation of the globe, and diplopia in extremes of gaze (Fig. 91.3). Apical tumors may extend through the superior and inferior orbital fissure. Defects in the greater wing of sphenoid may be seen.

**Diagnostic evaluation** Neurofibroma and neurilemmoma are homogenous, well-circumscribed tumors with a density similar to



**Fig. 91.3** Schwannoma. A 51-year-old woman presents with left blurred vision, hypoglobus (A), and proptosis (B). MRI (T<sub>2</sub>-weighted image) shows a well-circumscribed apical superior orbital mass hyperintense to fat (C). Note spindle-shaped nuclei in a whirling or fascicular pattern within eosinophilic glassy cytoplasm (D). (H & E, original magnification × 200.)



brain on CT scans with contrast enhancement. CT scans demonstrate bony expansion and may show superior orbital fissure expansion.<sup>23</sup> MRI shows isointensity to vitreous on T<sub>1</sub>-accentuated images and hypointensity to vitreous on T<sub>2</sub>-weighted sequences (Fig. 91.3).

**Differential diagnosis** of neurofibroma includes all causes for slowly progressing axial proptosis: meningioma, lymphangioma, fibrous histiocytoma, hemangiopericytoma, and cavernous hemangioma. On MRI the lesion is indistinguishable from cavernous hemangioma, fibrous histiocytoma, and hemangiopericytoma.

**Treatment** Although solitary orbital neurofibroma and neurilemmoma may be easily excised, the involved nerve is necessarily sacrificed. Therefore, care should be taken to identify the involved nerve as a sensory rather than a motor nerve. Solitary neurofibroma and neurilemmoma are seen during surgery as well-defined, firm, circumscribed, rubbery, gray masses with little vascularity. Plexiform neurofibroma is vascular and diffusely intertwined with normal tissues. Complete surgical resection is rarely possible. When indicated, resection of plexiform neurofibroma is best approached through transfrontal craniotomy. Bleeding is always a problem. Repair of bony defects is necessary in the presence of pulsating proptosis. Complications can include bleeding, hematoma, cerebral edema, recurrence of pulsating proptosis, and secondary socket and orbital deformities.

## MENINGIOMA

Meningiomas constitute 20% of adult and 2% of childhood intracranial tumors. Primary meningioma affects a younger age group, arises within the orbit, and may arise from the optic nerve sheath or the orbital surface of the sphenoid bone. The secondary type extends into the orbit from an intracranial source. These secondary tumors arise from the sphenoid ridge, the basofrontal region, the suprasellar area, the olfactory groove, and the paranasal sinuses.<sup>24</sup> Most adult meningiomas are seen in the fifth decade, with females being affected 75% of the time. Previous ionizing radiation and neurofibromatosis type 2 are predisposing factors. Only primary optic nerve sheath meningiomas are discussed in chapter.

**Clinical features** Patients may present with proptosis, decreased visual acuity, disc pallor, eyelid edema, disturbance of ocular motility, headaches or orbital pain, and seizures (Fig. 91.4). Chemosis is often seen. Some patients will have 'boggy edema' of the eyelids. The more medial sphenoidal ridge tumors cause cranial nerve palsies, visual deficits, and venous obstructive signs. Proptosis is less prevalent in secondary meningiomas. A mass may be palpable in the temporal fossa when meningiomas of the greater wing of the sphenoid bone expand laterally. Occasional bilateral meningiomas have been reported. Visual field testing as well as CT or MRI may help to judge progression of the tumor.

**Diagnostic evaluation** CT and MRI are both useful imaging modalities.<sup>25</sup> CT often shows hyperostosis, and calcification is seen in 25% of cases (Fig. 91.4). MRI shows a hyperintense lesion against the isointense brain on T<sub>1</sub>-weighted sequences, allowing delineation of intracranial meningiomas, especially when gadolinium enhancement is used.

**Treatment** It is believed that meningioma in patients younger than 20 years are more aggressive and require earlier surgical intervention.

Observation is warranted in older patients and where vision is not at risk.

Major indications for surgery are disfiguring or severe proptosis, temporal fullness, orbital congestion, and impaired vision.<sup>26</sup> Aggressive excision or debulking of sphenoid wing tumors may allow improved cosmesis, alleviate compressive symptoms, and postpone visual loss.<sup>27</sup> Most patients undergoing surgical resection of sphenoidal ridge meningioma develop recurrences over several years, requiring further surgery. Recurrence, residual, and cavernous sinus disease may be treated with radiotherapy.<sup>28</sup> Stereotactic radiosurgical techniques allow more accurate delivery of radiation (Chapter 8).

## TERATOMA

Teratoma, formerly called teratoid cyst or teratoid tumor, is a tumor composed of tissues derived from more than one germ layer and usually from all three. They are rare tumors, usually seen at birth or in the neonatal period. Rarely, they may be seen in adolescents and adults.<sup>29</sup>

**Clinical features** A typical teratoma presents as a rapidly bulging eye with marked orbital distortion in an infant. The mass may be soft or solid. The tumor enlarges rapidly and may present with marked orbital and facial changes. The persistent enlargement of this neoplasm is attributed to mucus secretion from the embryonic intestinal tissue. Whereas malignant teratomas are seen, most are benign.<sup>30,31</sup>

**Diagnostic evaluation** The differential diagnosis includes orbital hemangioma, lymphangioma, rhabdomyosarcoma, retinoblastoma, metastatic tumors (neuroblastoma and leukemia), microphthalmos with cyst, congenital cystic eyeball, unilateral congenital glaucoma, cephalocele, and plexiform neurofibroma (Table 91.1). CT shows orbital enlargement with focal calcification in the lumen of the tumor. Erosion of the greater wing of sphenoid bone may be seen. The definitive diagnosis of an orbital teratoma is made by histopathology, which shows gut-like structures, the sine qua non for diagnosis of a teratoma.

**Treatment** Although vision preservation is rare, surgery should remove the tumor but retain the eye if possible to encourage orbito-facial development. In more severe tumors, enucleation is necessary. Recurrent teratomas may undergo malignant degeneration. Therefore, close follow-up is necessary.

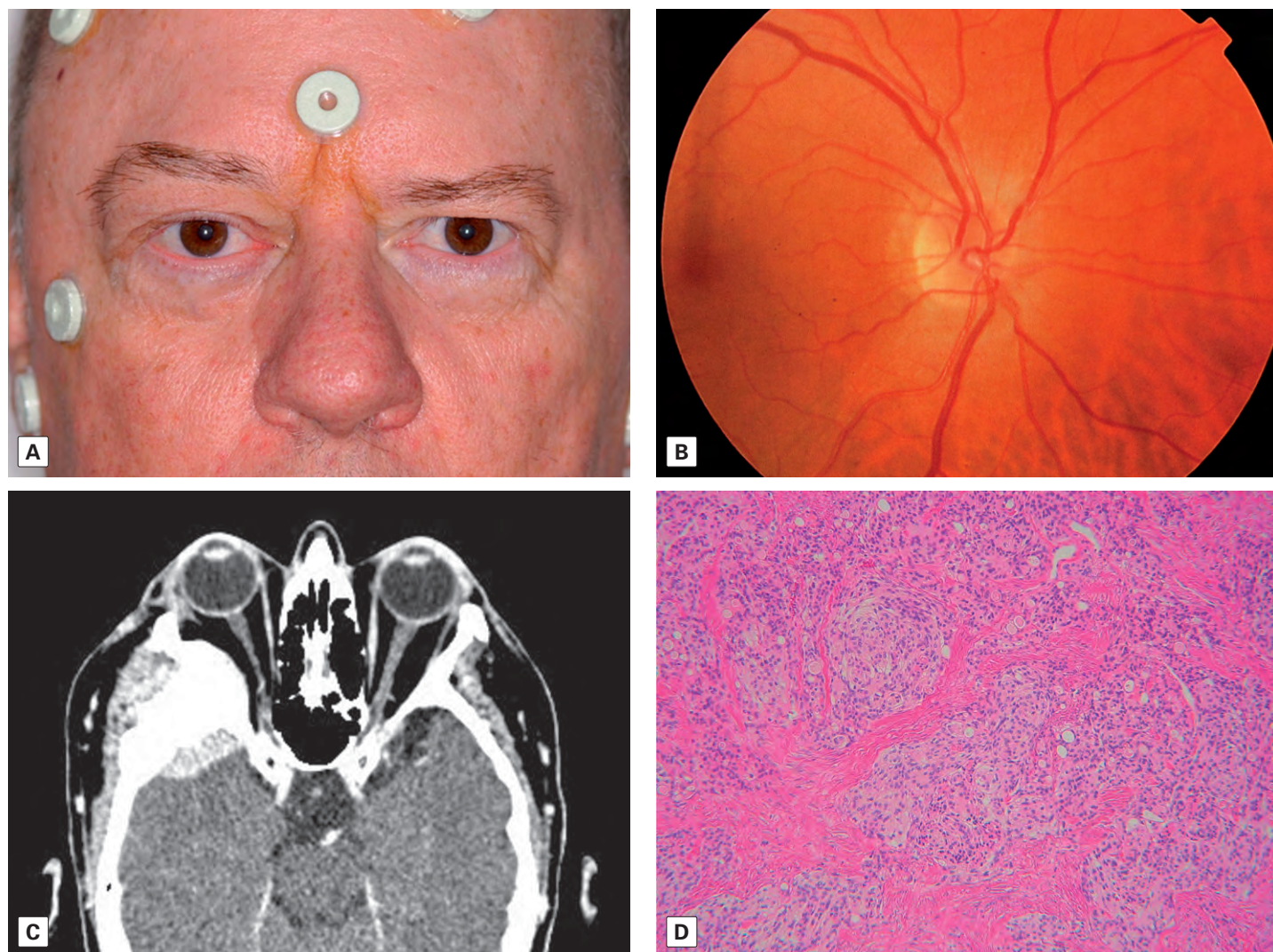
## FIBROUS HISTIOCYTOMA

Fibrous histiocytoma is the most common mesenchymal orbital tumor in adults, seen most commonly in the middle-aged. They may be benign, locally aggressive or malignant (Chapter 28). Fibrous histiocytoma is defined as a proliferating, complex admixture of fibroblasts and histiocyte-like cells of biphasic nature in a fibrous or collagenous matrix of varying proportions, associated with minor contents of lymphocytes, macrophages, capillaries, lipid, and reticulin.<sup>32</sup>

**Clinical features** These tumors, presenting most commonly with an upper nasal quadrant mass, are seen mostly in middle age. They are slow-growing, relatively firm masses. Patients present with proptosis, a mass effect, decreased vision, double vision, pain, eyelid swelling, and ptosis.

**Diagnostic evaluation** CT scans show a well-defined, irregular mass of uniform density. Bony erosion and enlargement of the orbit





**Fig. 91.4** Sphenoidal wing meningioma invading orbit. A 58-year-old man presented with a bump on the temple, decreased vision, and right-sided headaches (A). Right optic disc was edematous (B). CT scan demonstrated a right sphenoidal wing hyperostosis with a well-defined and homogenous soft tissue mass extending into the orbit (C). Histopathology shows parallel interlacing bundles of elongated cells. Whorled meningothelial cells are also present (D).

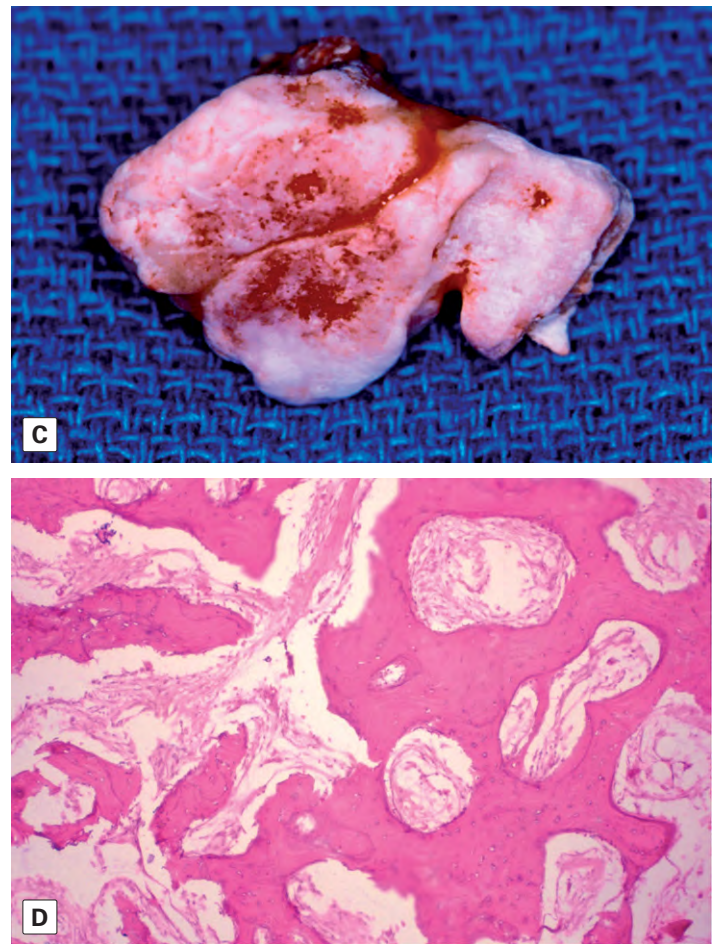
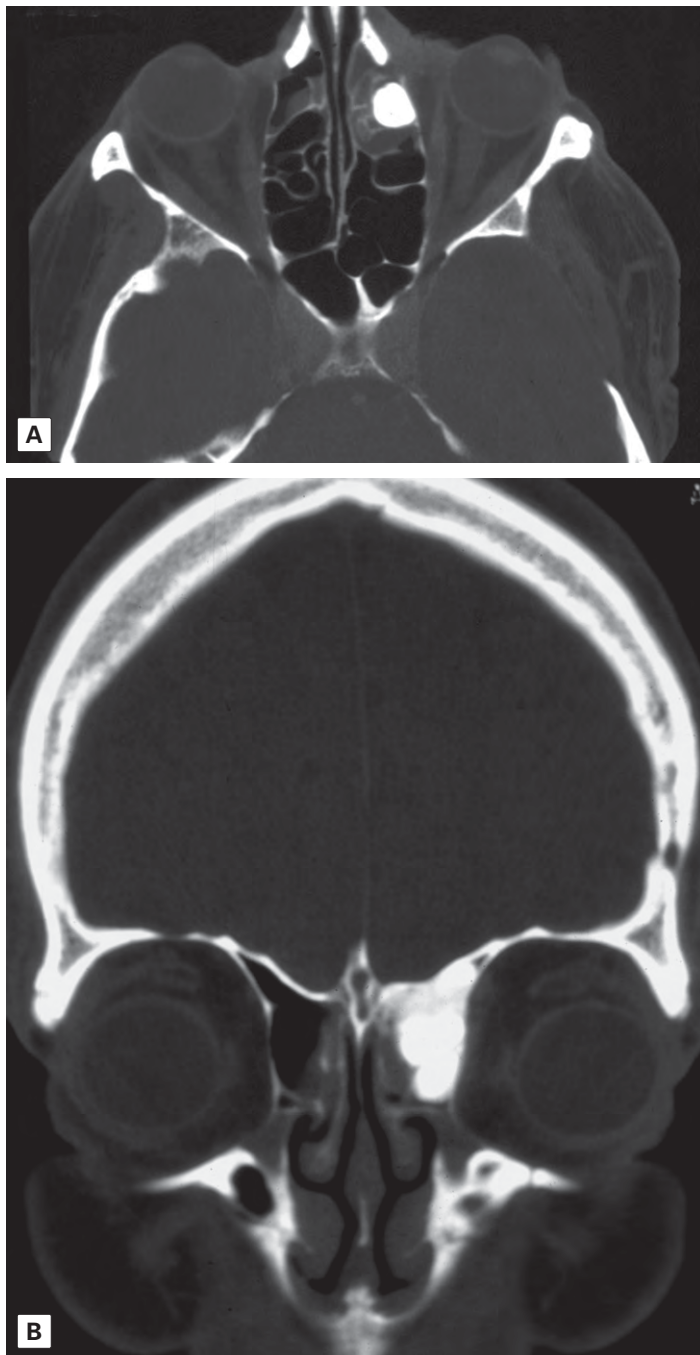
**Table 91.1** The differential diagnosis of orbital teratoma

Category	Subcategory	Diagnosis
Congenital anomaly of the globe		Congenital cystic eyeball Microphthalmos with cyst Congenital glaucoma
Congenital anomaly of the orbit		Cephalocele
Orbital tumor	Primary	Hemangioma
		Lymphangioma
		Rhabdomyosarcoma
		Plexiform neurofibroma
		Retinoblastoma
	Secondary	Neuroblastoma
Metastatic	Leukemia	

are seen with recurrent or malignant tumors. Ultrasound shows a well-defined mass with a smooth round or oval contour. Cystic cavities may be identified within the tumor.

**Differential diagnosis** Superotemporal tumors may mimic a lacrimal gland tumor. The CT appearance of the tumor may resemble neurofibroma, schwannoma, or cavernous hemangioma. Histopathologically, benign fibrous histiocytoma must be differentiated from the locally aggressive and malignant variant.<sup>33</sup>

**Treatment** Surgical excision via an orbitotomy is indicated. Complete excision is recommended, as incomplete resection of the tumor results in a high rate of recurrence. Grossly, the tumor appears as a lobulated, well-circumscribed, firm, grayish white to yellow-tan mass. Histopathology shows cartwheel bundles of elongated fibroblasts with spindle-shaped, uniformly staining nuclei set in a dense fibrous stroma. The majority of tumors fall in the benign or intermediate group. However, aggressive tumors may spread locally some years after initial diagnosis. Malignant change may occur (Chapter 96).



**Fig. 91.5** Osteoma. CT scan showing a well-circumscribed radiodense mass in the medial wall of the left orbit (A, axial view) (B, coronal view). Typical appearance of the resected osteoma (C). Osteoma is composed of compact bone devoid of fibrovascular stroma (D).



**OSTEOMA**

Primary osteomas, although rare, are the most common bony tumor of the orbit. They are well-defined benign tumors of bone. Most are seen in the superonasal orbit and arise secondarily from the frontal sinus, ethmoidal sinus, and junctions.<sup>34</sup>

**Clinical features** Osteoma is essentially an overgrowth of bone and present as rock-hard mass without pain. Most are solitary and asymptomatic (Fig. 91.5). However, larger lesions may cause proptosis and globe displacement. The patient may present with headaches. Chronic sinusitis or mucocele may result in frontal or frontoethmoid lesions. Frontal sinus osteoma presents with proptosis and downward displacement of the eye; ethmoidal osteomas produce a more lateral shift of the eye. Gardner's syndrome is an autosomal dominant familial polyposis of the large bowel associated with osteoma of the skull or jaws and epidermal and sebaceous cysts of the subcutaneous tissues (Chapter 60).<sup>35</sup> Some osteomas present with gaze-induced visual loss.

**Diagnostic evaluation** CT scans show a sharply circumscribed, very dense, rounded or lobulated mass arising from bone (Fig. 91.5). Fibrous osteomas have a low-density, ground-glass appearance similar to that of fibrous dysplasia or ossifying fibroma. The adjacent paranasal sinus may be opacified from secondary drainage obstruction.

**Treatment** If osteoma is symptomless, it may be followed.<sup>36</sup> Resection is indicated when secondary complications arise. A sphenoidal mass is resected endoscopically to prevent encroachment on the optic canal.<sup>37</sup> Recurrence is rare. Histologically, osteoma may be classified as compact, cancellous, or fibrous.

**FIBROUS DYSPLASIA**

Fibrous dysplasia is a benign developmental disorder characterized by proliferation of fibrous tissue. It is a hamartomatous malformation thought to be an arrest of bone maturation at the woven bone stage. The fibrous tissue replaces and distorts medullary bones. Three forms have been described: monostotic, polyostotic, and McCune–Albright syndrome.

**Monostotic fibrous dysplasia** usually involves one bone around the orbit. The monostotic type accounts for 80% of cases. The frontal bone is most frequently affected, followed by the sphenoid and ethmoid.<sup>38</sup>

**Polyostotic fibrous dysplasia** involves multiple bones.

**McCune–Albright syndrome** is a constellation of polyostotic fibrous dysplasia, sexual precocity, and cutaneous pigmentation.<sup>39</sup>

**Clinical features** Although fibrous dysplasia progresses slowly, sudden exacerbation of disfigurement may be seen over weeks. Symptoms depend on the anatomic site of the affected bone, the number of bones affected, the rate and duration of tumor growth, and the soft tissues compressed, displaced, or distorted. Anterior tumors affecting the frontal, ethmoid, or maxillary bones displace the globe in the direction opposite to the involved bone. Unilateral progressive proptosis and globe displacement sometimes occurs, with limitation of ocular movement and diplopia. Nasolacrimal duct obstruction may be seen. Patients may also present with persistent headaches or discomfort

and compression at the orbital apex, with involvement of nerves III, IV, and VI and visual loss.<sup>40</sup> The optic chiasm may also be affected.

Secondary sphenoid sinus mucoceles may occur with sudden loss of vision because of compression of the optic nerve. Patients may develop an intrasphenoidal hemorrhage or a secondary aneurysmal bone cyst, both of which can cause compression of the optic nerve. Slow compression of the optic canal or at the chiasm may also result in chronic visual loss. Malignant transformation (in less than 1% of cases) to osteogenic sarcoma, fibrosarcoma, or chondrosarcoma may occur if prior radiotherapy has been administered.<sup>41</sup>

**Diagnostic evaluation** CT scans show increased bone thickness. Increased fibrous content makes the bone look more lucent and it may show a cystic appearance; a more prominent osseous component gives a ground-glass or sclerotic character. Mixed patterns of alternating sclerosis and radiolucency are often seen. The orbital contour is narrowed and adjacent sinuses are replaced with dense bone.

**Differential diagnosis** includes hyperostotic meningioma, which will show an associated enhancing soft tissue component (best visualized on MRI). Other conditions to be considered include Paget's disease and cystic bone lesions, such as Langerhans' cell histiocytosis.

**Treatment** There has been much debate about whether surgical intervention before the patient is symptomatic is useful. As the complications of major craniofacial surgical intervention are significant, surgery is only indicated for gross deformity, functional deficits, pain, or sarcomatous transformation. In the presence of optic canal compression, resection and reconstruction is indicated.

**ANEURYSMAL BONE CYST**

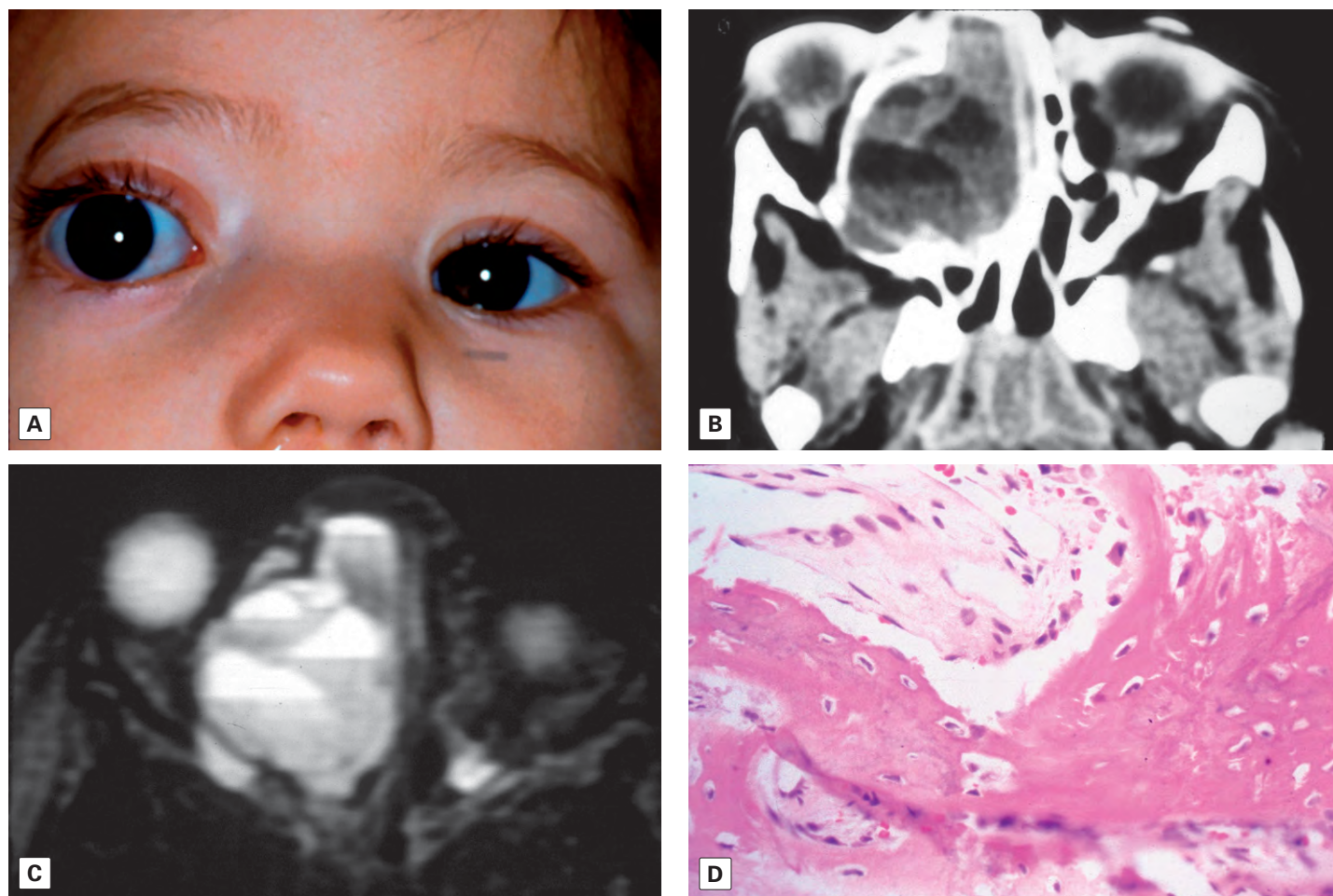
Aneurysmal bone cyst is a reactive lesion of bone. Aneurysmal bone cyst may arise in the orbit secondary to trauma or as a result of local vascular disturbance. In 30% of cases the cyst is associated with an underlying bone lesion, such as fibrous dysplasia, non-ossifying fibroma, or giant cell tumor.<sup>42</sup> The orbital roof is most commonly involved.

**Clinical features** Patients present with proptosis, displacement of the globe, and diplopia secondary to cranial nerve palsy (Fig. 91.6). There may be pain and local swelling. The patient may present with refractive changes. Compressive optic neuropathy and visual loss are rare.

**Diagnostic evaluation** CT scans show an irregular lytic bone lesion with cortical destruction (Fig. 91.6). A fluid level may be seen within the cavities due to hemorrhage with settled blood products. The margins of the tumor may show calcification. MRI scans show a multicystic mass with associated bone destruction. Fluid-filled levels may be seen with varying levels of signal intensity, depending on the state of the blood within the cyst.<sup>43</sup>

**Treatment** Complete surgical curettage is usually curative and the prognosis is usually excellent. Visual compromise is very rare. Radiation, used in the past, is inadvisable because of the potential risk of radiation-induced sarcoma.





**Fig. 91.6** Aneurysmal bone cyst. An 11-month-old child with a 3-week history of right proptosis and nasal obstruction (A). CT scan shows expansile lytic mass (B). MRI with contrast shows fluid levels with heterogenous signal intensity. Fresh blood is hyperintense on  $T_2$ -weighted images (C). Trabeculated bone with cavernous spaces filled with thick fibrous septa, blood, and cellular areas (D).

## REFERENCES

- Shields JA, Shields CL, Scartozzi R. Survey of 1264 patients with orbital tumors and simulating lesions: The 2002 Montgomery Lecture, part 1. *Ophthalmology* 2004; 111: 997–1008.
- Shields JA, Kaden IH, Eagle RC Jr, Shields CL. Orbital dermoid cysts: clinicopathologic correlations, classification and management. *Ophthalm Plast Reconstr Surg* 1997; 13: 265–276.
- Bonavolonta G, Tranfa G, de Conciliis C, Strianese D. Dermoid cysts: 16-year survey. *Ophthalm Plast Reconstr Surg* 1995; 11: 187–192.
- Meyer DR, Lessner AM, Yeatts RP, Linberg JV. Primary temporal fossa dermoid cysts. Characterization and surgical management. *Ophthalmology* 2000; 106: 342–349.
- Perry JD, Tuthill R. Simultaneous ipsilateral temporal fossa and orbital dermoid cysts. *Am J Ophthalmol* 2003; 135: 413–415.
- Emerick GT, Shields CL, Shields JA et al. Chewing-induced visual impairment from a dumbbell dermoid cyst. *Ophthalm Plast Reconstr Surg* 1997; 13: 57–61.
- Sherman RP, Rootman J, Lapointe JS. Orbital dermoids: clinical presentation and management. *Br J Ophthalmol* 1984; 68: 642–652.
- Wells TS, Harris GJ. Orbital dermoid cyst and sinus tract presenting with acute infection. *Ophthalm Plast Reconstr Surg* 2004; 20: 465–467.
- Sathananthan N, Moseley IF, Rose GE, Wright JE. The frequency and clinical significance of bone involvement in outer canthus dermoid cysts. *Br J Ophthalmol* 2003; 77: 789–794.
- Yuen HK, Chong YH, Chan SK et al. Modified lateral orbitotomy for intact removal of orbital dumbbell dermoid cyst. *Ophthalm Plast Reconstr Surg* 2004; 20: 327–329.
- Illiff CE. Mucocele in the orbit. *Arch Ophthalmol* 1973; 89: 392–395.
- Delfini R, Missori P, Iannetti G et al. Mucoceles of the paranasal sinuses with intracranial and intraorbital extension: report of 28 cases. *Neurosurgery* 1993; 32: 901–906.
- Lund VJ, Rolfe ME. Ophthalmic considerations in fronto-ethmoidal mucoceles. *J Laryngol Otol* 1989; 103: 667–669.
- Garber PF, Abramson AL, Stallman PT, Wasserman PG. Globe ptosis secondary to maxillary sinus mucocele. *Ophthalm Plast Reconstr Surg* 1995; 11: 254–260.
- Benninger MS, Marks S. The endoscopic management of sphenoid and ethmoid mucoceles with orbital and intranasal extension. *Rhinology* 1995; 33: 157–161.
- McNab AA, Wright GE. Orbitofrontal cholesterol granuloma. *Ophthalmology* 1990; 97: 28–32.
- Hill CA, Moseley IF. Imaging of orbitofrontal cholesterol granuloma. *Clin Radiol* 1992; 46: 237–242.
- Bagheri A, Naghibzakeri J, Yazdani S. Cerebrospinal fluid leakage during dacryocystorhinostomy in a patient with meningoencephalocele. *Eur J Ophthalmol* 2005; 15: 500–503.
- Strandberg B. Cephalocele of posterior part of orbit. General survey, with report of case. *Arch Ophthalmol* 1949; 42: 254–265.

20. Songur E, Mutluer S, Gurler T et al. Management of frontoethmoidal (sincipital) encephalocele. *J Craniofac Surg* 1999; 10: 135–139.
21. Rose GE, Wright JE. Isolated peripheral nerve sheath tumours of the orbit. *Eye* 1991; 5: 668–673.
22. Rootman J, Goldberg C, Robertson W. Primary orbital schwannomas. *Br J Ophthalmol* 1982; 66: 194–204.
23. Dervin JE, Beaconsfield M, Wright JE, Moseley IF. CT findings in orbital tumors of nerve sheath origin. *Clin Radiol* 1989; 40: 475–479.
24. Honeybul S, Neil-Dwyer G, Lang DA, Evans BT, Ellison DW. Sphenoid wing meningioma en plaque: a clinical review. *Acta Neurochir (Wien)* 2001; 143: 749–757.
25. Ehlers N, Malmros R. The suprasellar meningioma. A review of the literature and presentation of a series of 31 cases. *Acta Ophthalmol Suppl* 1973; 121: 1–74.
26. Shrivastava RK, Sen C, Costantino PD, Della Rocca R. Sphenoorbital meningiomas: surgical limitations and lessons learned in their long-term management. *J Neurosurg* 2005; 103: 491–497.
27. Sandalcioglu IE, Gasser T, Mohr C, Stolke D, Wiedemayer H. Spheno-orbital meningiomas: interdisciplinary surgical approach, resectability and long-term results. *J Craniomaxillofac Surg* 2005; 33: 260–266.
28. Peele KA, Kennerdell JS, Maroon JC et al. The role of postoperative irradiation in the management of sphenoid wing meningiomas. A preliminary report. *Ophthalmology* 1996; 103: 1761–1767.
29. Mamalis N, Garland PE, Argyle JC, Apple DJ. Congenital orbital teratoma: a review and report of two cases. *Surv Ophthalmol* 1985; 30: 41–46.
30. Gnanaraj L, Skibell BC, Coret-Simon J et al. Massive congenital orbital teratoma. *Ophthalm Plast Reconstr Surg* 2005; 21: 445–447.
31. Mahesh L, Krishnakumar S, Subramanian N, Babu K, Biswas J. Malignant teratoma of the orbit: a clinicopathological study of a case. *Orbit* 2003; 22: 305–309.
32. Jacobiec FA, Howard GM, Jones IS, Tannenbaum M. Fibrous histiocytomas of the orbit. *Am J Ophthalmol* 1974; 77: 333–345.
33. Font RL, Hidayat AA. Fibrous histiocytoma of the orbit. A clinicopathologic study of 150 cases. *Hum Pathol* 1982; 13: 199–209.
34. Grove AS Jr. Osteoma of the orbit. *Ophthalmic Surg* 1978; 9: 23–39.
35. McNab AA. Orbital osteoma in Gardner's syndrome. *Aust NZ J Ophthalmol* 1998; 26: 169–170.
36. Ciappetta P, Delfini R, Iannetti G et al. Surgical strategies in the treatment of symptomatic osteomas of the orbital walls. *Neurosurgery* 1992; 31: 628–635.
37. Naraghi M, Kashfi A. Endonasal endoscopic resection of ethmoido-orbital osteoma compressing the optic nerve. *Am J Otolaryngol* 2003; 24: 408–412.
38. Bibby K, McFadzean R. Fibrous dysplasia of the orbit. *Br J Ophthalmol* 1994; 78: 266–270.
39. Albright F, Butler AM, Hampton AO, Smith P. Syndrome characterized by osteitis fibrosa disseminata, areas of pigmentation and endocrine dysfunction with precocious puberty in females. *N Engl J Med* 1937; 216: 727–746.
40. Osguthorpe JD, Gudeman SK. Orbital complications of fibrous dysplasia. *Otolaryngol Head Neck Surg* 1987; 97: 403–405.
41. Yabut SM, Kenan S, Sissons HA. Malignant transformation of fibrous dysplasia. A case report and review of the literature. *Clin Orthop* 1988; 228: 281–289.
42. Lucarelli MJ, Bilyk JR, Shore JW et al. Aneurysmal bone cyst of the orbit associated with fibrous dysplasia. *Plast Reconstr Surg* 1995; 96: 440–445.
43. Patel BC, Sabir DI, Flaharty PM, Anderson RL. Aneurysmal bone cyst of the orbit and ethmoid sinus. *Arch Ophthalmol* 1993; 111: 586–587.

# Tumors of the optic nerve

Jonathan J. Dutton

## INTRODUCTION

Primary tumors of the optic nerve include optic gliomas and optic sheath meningiomas. Both are relatively rare lesions that result in significant visual morbidity. Together they account for less than 4% of all orbital tumors. There has been controversy about the natural history and appropriate management of these lesions, resulting from small sample sizes and short follow-up periods. Other tumors, such as gangliogliomas and primary lymphomas, have also been described, but are extremely rare (Table 92.1).

## ANTERIOR VISUAL PATHWAY GLIOMA

Optic pathway gliomas (OPG) are uncommon benign lesions classified as pilocytic astrocytomas. They represent 1.5–4% of all orbital tumors and 50–55% of all primary optic nerve tumors.<sup>1,2</sup>

### Clinical features

**Age distribution** Gliomas have been described in patients from birth to 79 years of age. However, 71% of cases occur in children in the first decade of life and 90% within the first two decades. The overall mean age at presentation is 8.5 years for all optic gliomas.

**Sex distribution** for all optic pathway gliomas shows approximately equal numbers of males and females. For gliomas confined to the optic nerve, 65% occur in females, compared to 35% for males. For tumors involving the optic chiasm there is no sex predilection.

**Location** About 20–25% of optic gliomas are confined to the optic nerve alone, but in three-quarters of cases the chiasm is involved.<sup>3,4</sup> Of the tumors that involve the chiasm, 40% extend into the adjacent hypothalamus or third ventricle. Although some authors have suggested that patients with neurofibromatosis show a higher incidence of pure optic nerve lesions, larger series fail to confirm this.

**Association with neurofibromatosis type 1** The reported incidence of neurofibromatosis type 1 (NF1) among patients with optic gliomas varies from 10% to 70%, with an overall incidence of 29%.<sup>1</sup> Although some reports have shown no difference in the course and prognosis of optic pathway gliomas with and without NF1,<sup>3,5</sup> others have suggested a more indolent course and a better prognosis in patients with OPG and NF1.<sup>6,7</sup> When associated with NF1 the glioma may present at a somewhat later age and show progression for a long time, justifying regular ophthalmological monitoring of this population over a long period.<sup>8</sup>

**Signs and symptoms** of optic pathway gliomas depend principally on the location of the tumor. Regardless of location, 85% of patients lose some vision, with about 25% retaining good vision between 20/20 and 20/40. About 60% of patients show vision of 20/300 or worse.

Proptosis is a presenting sign in 95% of all patients with optic nerve gliomas (Fig. 92.1). With gliomas of the optic chiasm proptosis is much less common, seen in fewer than 20% of patients, and all with concomitant intraorbital involvement. Limitation of ocular motility is seen infrequently with optic gliomas. It is reported in 30% of intra-orbital lesions and 20% of gliomas involving the chiasm. Pain and headache are present in up to 30% of patients with chiasmal tumors. Other rare symptoms seen with CNS invasion include nystagmus, seizures, hypothalamic signs, and hydrocephalus. On fundoscopic examination 60% of patients demonstrate some degree of optic atrophy. Disc edema, primarily associated with intraorbital gliomas, is seen in half of such cases. With chiasmal tumors disc edema is noted in only 20% of patients, and in these the tumor is usually contiguous with the intraorbital optic nerve (Box 92.1).

**Diagnostic evaluation** Imaging studies reveal that enlargement of the optic canal can be demonstrated in up to 80% of patients with a glioma involving the optic nerves. Enlargement and J-shaped excavation of the sella turcica may be associated with chiasmal gliomas, but is reported in only 25% of patients.

**Computed tomography (CT)** imaging typically demonstrates enlargement of the optic nerve or chiasm. Contrast enhancement ranges from imperceptible to moderate, but generally is less than with sheath meningiomas. Typical optic gliomas show a well-outlined fusiform swelling of the optic nerve (Fig. 92.2), but occasionally they may be more rounded or diffuse. Calcification occurs only occasionally.

**Magnetic resonance imaging (MRI)** has proved superior to CT for evaluation of chiasmal, hypothalamic, and optic tract lesions. Gliomas demonstrate normal to slightly prolonged T<sub>1</sub> relaxation times, which image isointense to slightly hypointense compared to normal optic nerve. The T<sub>2</sub> relaxation time is prolonged, giving a hyperintense image on T<sub>2</sub>-weighted sequences.

**Histopathology** Although optic gliomas were formerly believed to be congenital non-neoplastic hamartomas with self-limiting growth,



their histologic features, rates of growth, and a clear tendency to invade the leptomeninges show that these tumors are true neoplasms that have the ability to invade locally.

Optic gliomas arise from supporting astrocytes of the optic nerve. Most are classified as benign pilocytic astrocytomas in which proliferating neoplastic astrocytic cells predominate. Proliferating astrocytes may extend through the pia mater into the arachnoid and subarachnoid space, where they provoke an exuberant reactive proliferation of fibrovascular tissue and meningotheial cells. This so-called arachnoidal hyperplasia may extend beyond the limits of the tumor itself,

simulating tumor extension. Enlargement of optic gliomas may occur as a result of proliferation of neoplastic cells, reactive arachnoidal proliferation, or an accumulation of extracellular, PAS-positive mucosubstance secreted by the astrocytes.

**Treatment options** Anterior visual pathway gliomas are neoplasms with the potential to spread into contiguous areas of the optic nerve, chiasm, and adjacent brain. They appear at an early age, grow slowly for a few years, and vision generally stabilizes in most cases. However, indolent growth can be seen in up to 40% of cases. Although the best treatment options are still evolving, an algorithm for the management of patients with optic pathway gliomas is suggested in Figure 92.3. As with most medical decisions, treatment must be individualized based on patient symptoms, findings, and clinical course.

**Observation** Long-term survival shows a good prognosis even in patients followed conservatively without intervention.<sup>9-12</sup> After an initial period of deterioration, vision tends to stabilize in nearly 80% of cases. There is little difference in visual outcome or survival in patients undergoing treatment versus observation alone.<sup>3</sup> However, significant progression of tumor can occur in some patients despite clinically stable visual acuity for many years.

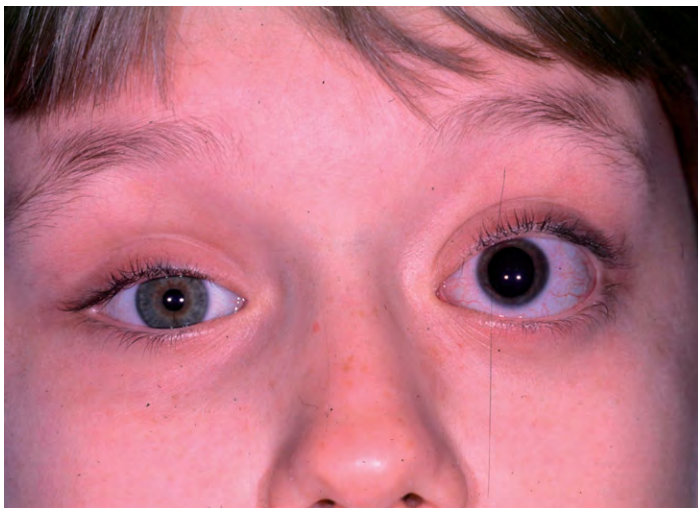**Surgery** Until recently, surgery was considered the treatment of choice for optic nerve gliomas. Today most authorities limit the indications for surgery to resectable tumors involving the orbital or

**Table 92.1 Differential diagnosis of orbital inflammation**

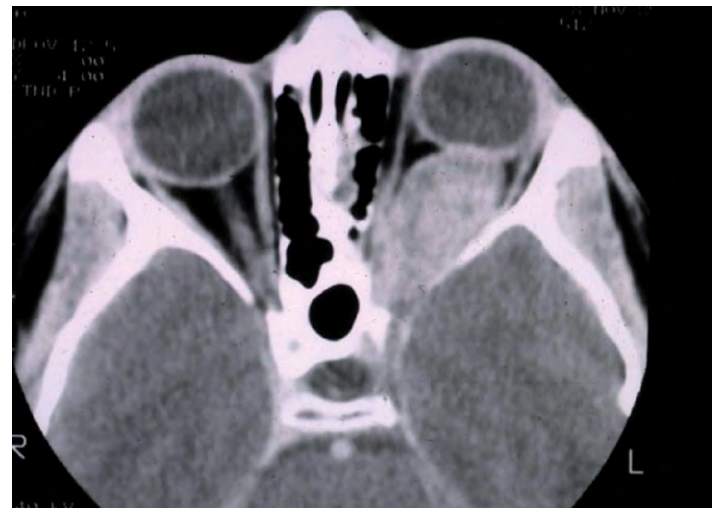
Categories	Subtypes	
<b>Thyroid-associated orbitopathy</b>		
Infections	Bacterial	Spread from sinusitis
		Tuberculosis
		Syphilis
	Fungal	Mucormycosis
		Aspergillosis
	Parasitic	Echinococcosis
	Cysticercosis	
Vasculitis	Wegener's granulomatosis	
	Polyarteritis nodosa	
	Hypersensitivity angiitis	
	Systemic lupus erythematosus	
	Giant cell arteritis	
Granulomatous inflammation	Sarcoidosis	
	Xanthogranulomatous	
	Foreign body granuloma	
	Erdheim-Chester disease	
	Sjogren's syndrome	
	Non-inflammatory disorders	Lymphoid disorder
Dural-cavernous sinus arteriovenous fistula		
Retained orbital foreign body		
Non-specific orbital inflammation (by exclusion)		

#### BOX 92.1 Benign Optic Glioma

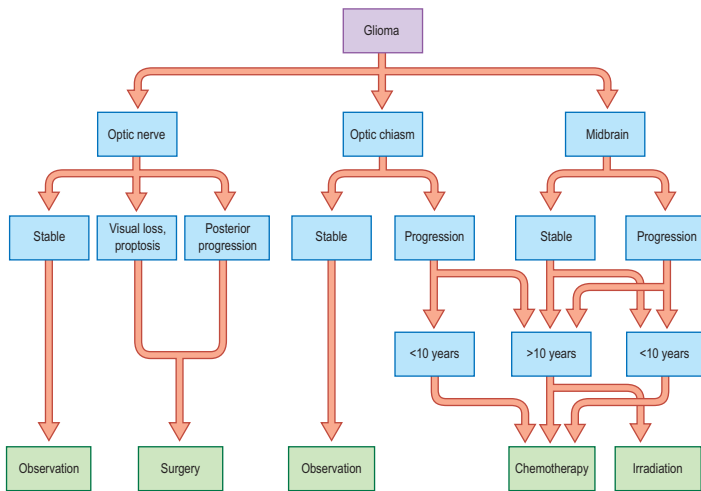
- Early visual loss 88%
- Optic disc swelling 35%
- Optic disc atrophy 59%
- Proptosis, orbital tumors 94%; chiasmal tumors 22%
- Nystagmus 24%
- Hypothalamic signs 26%
- Increased intracranial pressure 27%



**Fig. 92.1** External photograph of a child with a left orbital optic nerve glioma showing axial proptosis.



**Fig. 92.2** Axial CT scan shows a fusiform glioma of the left optic nerve.



**Fig. 92.3** Proposed management algorithm for treatment of anterior visual pathway glioma.

intracranial optic nerves, or for direct inspection or biopsy of the chiasm. Once vision is lost, surgery can be beneficial for severe proptosis or orbital pain. Where vision is present, surgical intervention carries a very significant risk of visual morbidity and mortality.

**Radiotherapy** The role of radiotherapy has been a subject of debate for decades. Some studies have failed to show any benefit of radiotherapy on long-term survival, visual acuity, or both.<sup>3</sup> However, other studies showed improvement or stability in visual acuity after treatment, and better progression-free survival interval.<sup>13</sup> Overall, the data suggest a possible benefit. Any potential benefit must also be tempered by the adverse effects of radiotherapy on the central nervous system in younger children.

**Chemotherapy** Several reports have suggested a role for chemotherapy in the management of optic pathway gliomas. Most studies show stabilization of vision and/or tumor regression in 50–65% of treated patients.<sup>14–16</sup> Although this is not much better than for tumors observed conservatively, chemotherapy may be useful for young children with progressive lesions in order to delay the potential complications of radiotherapy.

**Prognosis** A review of the literature shows that for all patients with optic pathway gliomas in all locations and with all forms of treatment, including observation, tumor recurrence or progression occurs in 38% of cases.<sup>3</sup> The overall tumor-related mortality is 36% with a mean follow-up of 11 years. However, with longer follow-up intervals of 25–30 years, the prognosis for survival may be considerably worse. The outlook for vision is actually rather good. About 55% of patients retain stable vision or show some improvement. Only 45% show progressive loss of vision.

**Glioma confined to the optic nerve** For gliomas initially confined to the optic nerve and treated conservatively or incompletely excised, recurrence or progression is seen in 17%. The mortality rate is 12%, typically from intracranial extension. The prognosis for vision, however, is good, with over 90% remaining stable over many years. With optic nerve tumors treated by complete surgical excision or partial excision plus radiotherapy, the mortality rate drops to zero. The same is true for tumors that progress but remain confined to the optic

nerve. Obviously, the prognosis for vision in such cases is poor after surgery.

**Gliomas with extension to the chiasm** Gliomas that extend to the chiasm but that do not invade the adjacent hypothalamus or third ventricle show results similar to those for untreated optic nerve tumors. Chiasmal gliomas left untreated or that are partially excised show a mortality rate of 17% over a mean follow-up period of 10 years. As with optic nerve tumors, death resulted from extension into the hypothalamus or third ventricle. Recurrence or progression of tumor after partial excision is seen in 64% of cases. Visual prognosis in this group is good, with 80% remaining stable. In patients with chiasmal tumors radiotherapy may delay progression to some extent. Mortality in this group is 22%, and recurrence or progression of tumor is seen in 43% of cases. Prognosis for vision is similar to that of untreated patients, with 68% remaining stable or demonstrating a slight improvement.

**Gliomas with extension to the chiasm and hypothalamus** In patients with chiasmal tumors plus hypothalamic or third ventricle involvement at the time of presentation, the prognosis for life is markedly reduced. The mortality rate is 50% or more over 15 years. For patients who received radiotherapy, recurrence or progression is noted in 52%, but the mortality rate is somewhat better, at 43%.

## MALIGNANT OPTIC NERVE GLIOMA

In 1973 Hoyt et al.<sup>17</sup> described five cases of optic pathway glioma in adults which had an aggressive behavior and a uniformly fatal outcome. To date more than 40 additional cases have been added to the literature, all confirming the original concept of the disease.

### Clinical features

**Age distribution** Malignant optic pathway gliomas have been seen in patients from 6 to 79 years old, but occur most commonly in middle age. The mean age at presentation is 48 years.

**Sex distribution** This disease has a distinct sexual predilection, with 65% occurring in males and 35% in females.

**Location** In all described cases the chiasm is the major site of origin. In all cases except one, the disease is bilateral with both optic nerves also involved. In only 23% of cases does the tumor extend to the intra-orbital portion of the nerve. In nearly half of patients the tumor extends posterior to the optic tracts, hypothalamus, or temporal lobe.<sup>3</sup>

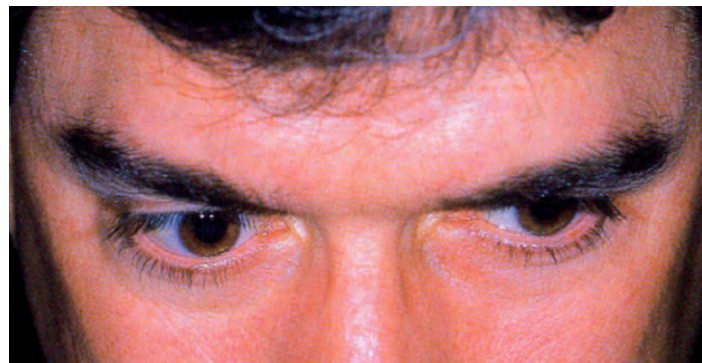**Signs and symptoms** All patients present with rapidly progressive loss of vision, first in one and then in the second eye. Blindness typically results in a matter of months. Optic disc edema is seen in most patients, and, if they survive long enough, optic atrophy results. Orbital signs are uncommon, as most tumors are confined to the intracranial compartment. Proptosis and ophthalmoplegia are seen in only 20–25% of cases (Box 92.2).

**Diagnostic evaluation** Enlargement of the chiasm on imaging is the most common finding, seen in 80% of cases. One or both optic nerves may also be involved along their intracranial portions.

**Histopathology** shows malignant astrocytes with subpial extension along the optic pathways and invasion into the optic chiasm and nerve, and into the adjacent areas of the brain.

**BOX 92.2 Malignant Optic Glioma**

- Very rapid loss of vision to blindness over weeks to months
- Optic disc swelling 43%
- Optic disc atrophy 31%
- Proptosis 23%
- Ophthalmoplegia 19%
- Other neurologic signs 35%



**Fig. 92.4** External photograph of a patient with a right orbital optic nerve sheath meningioma demonstrating proptosis.

**Treatment** To date no treatment has proved effective in slowing the progression of this disease. Neither surgery nor radiotherapy up to 60 Gy has significantly altered the prognosis.<sup>18</sup>

**Prognosis** for vision is dismal, with all patients progressing to profound visual loss within months of initial presentation. The prognosis for life is equally dismal, with a nearly 100% mortality rate. The mean survival rate is typically less than 1 year.

### OPTIC NERVE SHEATH MENINGIOMA

Meningiomas are the second most common brain neoplasms after gliomas. They represent 15–20% of all intracranial tumors in adults, and 2% of intracranial tumors in children. Although most orbital meningiomas are extensions from intracranial sites, primary orbital meningiomas are well documented and account for 1.3% of all meningiomas.

#### Clinical features

**Age distribution** Despite several reports of orbital meningiomas occurring with high frequency in young individuals, most series confirm that this is a disease primarily of middle age. On imaging studies meningiomas may be confused with arachnoid proliferation associated with optic gliomas in young patients. The mean age for presentation of optic sheath meningioma is 41 years, and only 4% of patients are under 20.<sup>19,20</sup>

**Sex distribution** It has long been recognized that meningiomas occur more frequently in females. When large series are examined the ratio has tended to equalize, but there does appear to be a slight female preponderance of approximately 60%.

**Laterality** A slight predilection for the right optic nerve has been reported in several studies. Others have not confirmed these findings. However, when larger series are examined 52% of sheath meningiomas occurred in the right optic nerve, 42% in the left, and 6% were bilateral.<sup>19</sup> Interestingly, among bilateral cases 60% are canalicular meningiomas, compared to all sheath meningiomas together, where canalicular tumors account for only 8%.

**Sites of origin** For optic sheath meningiomas 94% are unilateral and 6% bilateral. In about 8% of cases the meningioma is confined to the optic canal. Among these canalicular tumors there is a significant propensity toward bilaterality, 65% being unilateral and 35% bilateral.

About 4% of optic sheath meningiomas show focal tumor invasion of the optic disc, sclera, choroid, and retina. Tumor may enter the globe along penetrating vascular channels. Dutton<sup>19</sup> noted that 18 of 475 cases of primary orbital meningioma arose ectopic to the optic nerve sheath. The exact etiology of such lesions remains uncertain, and it is possible that in some cases they represent other lesions mistaken for meningiomas.

**Association with neurofibromatosis type 1** The incidence of NF1 in patients with sheath meningiomas is unclear because most studies in the past failed to mention the occurrence. Of the studies that specifically examined for NF, 9% of patients were affected. This is considerably lower than the 29% association with optic gliomas, but still significantly higher than the 0.3–0.5% incidence of NF in the general population.

**Signs and symptoms** The most frequent presenting symptom of optic sheath meningioma is loss of vision, seen in 97% of cases. In about 45% visual acuity is 20/20 to 20/40, and in only 25% is it counting fingers or worse. Visual loss usually takes place over several years. In bilateral cases visual loss in the two eyes may be separated in time by 2–30 years. Visual field defects are noted in 83% of patients. Most commonly these include peripheral constriction; central, centrocecal, and paracentral scotomas; altitudinal defects; and increased size of the blind spot.

Proptosis is found on initial examination in 65% of patients. It is seen less frequently in patients with canalicular lesions, as they typically have significant visual loss while the tumor is still very small (Fig. 92.4; Box 92.3). Limitation of ocular motility is variable but may be seen in more than half of patients. Upgaze is commonly severely impaired, possibly because of stiffening of the optic nerve from the relatively firm tumor.

Chronic disc edema is an early finding in 50% of patients. Optic atrophy, which may be subtle, is a somewhat later finding, noted in two-thirds of cases at presentation. Both edema and atrophy may be seen together, and overall 98% of patients will show one or the other of these two findings. The association between optic sheath meningiomas and optociliary shunt vessels has long been considered a key finding suggestive of optic sheath meningiomas. However, chronic disc edema and congestion of the central retinal vein usually precedes the first appearance of shunts by several years, and the shunts usually disappear as optic atrophy becomes complete. In fact, optociliary shunt



vessels are relatively infrequent with sheath meningiomas, being seen in only 30% of reported cases. Because shunts tend to appear some years after symptoms begin and involute as optic atrophy is complete, this probably does not indicate their true incidence.

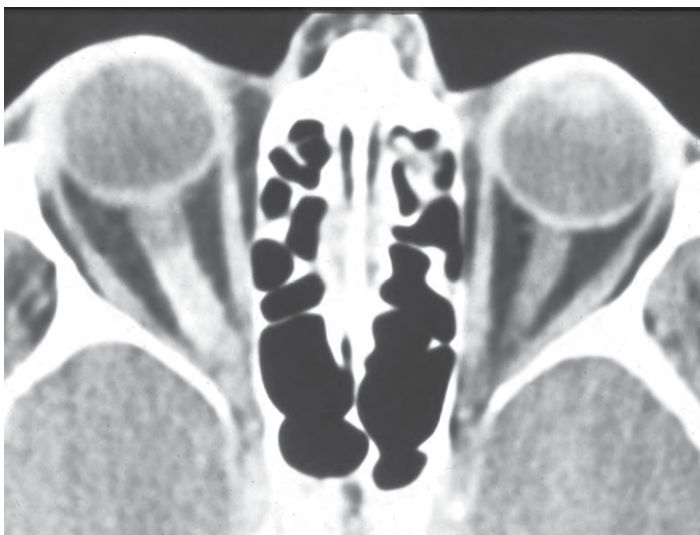### Diagnostic evaluation

**Computed tomography** Plain orbital radiographs and tomography through the optic canals demonstrate enlargement of the optic foramen in less than 30% of cases. CT scanning demonstrates enlargement of the optic nerve in 97% of examinations. The most common pattern is diffuse tubular enlargement, but a globular or fusiform shape may also be seen. Tram-tracking, a radiographic sign in which the denser and thickened optic nerve sheath outlines a central lucency representing the residual optic nerve, is a characteristic of sheath meningioma (Fig. 92.5). Contrast studies generally show moderate to marked enhancement. Calcification, an important finding, may help differentiate meningiomas from optic gliomas. It is seen in 20–50% of patients.

**Magnetic resonance imaging** shows a thickening of the nerve and sheath contrasted against orbital fat, and there is increased signal intensity compared to normal nerve on both the  $T_1$ - and  $T_2$ -weighted sequences.

#### BOX 92.3 Optic Nerve Sheath Meningioma

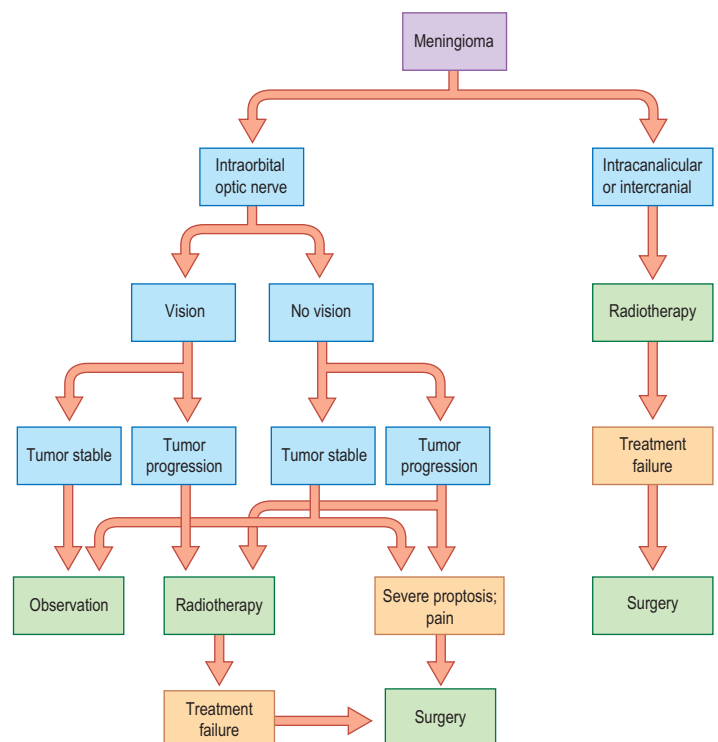
- Slowly progressive visual loss 96%
- Optic disc swelling 48%
- Optic disc atrophy 49%
- Proptosis 59%
- Decreased ocular motility 47%
- Optociliary shunt vessels 30%
- Increased intracranial pressure 27%



**Fig. 92.5** Axial CT scan shows a tubular optic nerve sheath meningioma with tram-tracking. The involved sheath enhances brightly, with the uninvolved optic nerve centrally.

**Histopathology** Optic meningiomas arise from meningeothelial cap cells of the arachnoid villi that lie along the intraorbital optic nerve. Two histologic patterns are seen. In the meningeothelial or syncytial pattern, polygonal cells are arranged in sheets separated by vascular trabeculae. In the transitional pattern, spindle-shaped or oval cells are arranged in a concentric whorl formation. Psammoma bodies are seen more commonly in the transitional pattern and contain the calcifications noted on radiologic studies. Meningioma typically remains indolent over many years. As the tumor grows within the subarachnoid space, it commonly encircles the optic nerve. Compression results in obstruction to axoplasmic flow, disc edema, dilatation of optociliary shunt channels, and eventually demyelination and optic atrophy. Tumor cells may also invade through the dura and into surrounding orbital tissues. Although they do invade along the intracranial optic nerve to the chiasm, meningiomas do not invade the brain.

**Treatment** The most appropriate therapy for optic sheath meningiomas has been a matter of some controversy. For sheath meningiomas that extend to the intracanalicular or intracranial portions of the optic nerve, the decision regarding treatment becomes less complex. The major rationale for treatment is the perceived risk of spread to the contralateral optic nerve. The actual risk of tumor spread from one optic nerve to the other remains unknown, but based on the high incidence of bilaterality with canalicular tumors and on documented unilateral tumors with progressive posterior extension, it may be very real. Because vision in such cases will eventually be lost, treatment to prevent possible extension to the contralateral side is justified. In most cases radiotherapy may slow or halt tumor progression. However, in cases of treatment failure, surgical excision should be considered. Newer treatment options have gained considerable support over the past decade and these are changing the approach to management. A proposed treatment algorithm is shown in Figure 92.6.



**Fig. 92.6** Proposed management algorithm for treatment of optic nerve sheath meningioma.

**Observation** For meningiomas confined to the intraorbital optic nerve, when vision remains and symptoms and radiographic findings are stable, observation without treatment is appropriate. The only possible exceptions that justify surgery are small anterior tumors and cases in young children, where biopsy for diagnosis may be indicated. Progressive visual loss is expected in most cases, but some patients may remain stable for many years. The prognosis for life is excellent, and there have been no tumor-related deaths reported for this disease.

**Surgery** Some have considered radical surgery necessary to prevent intracranial extension. This may be possible for some small anterior orbital lesions<sup>21</sup> or even with some posterior tumors,<sup>22</sup> but in general the morbidity is high and loss of vision is a very common sequela. Once blindness results, surgical extirpation may be necessary for relief of disfiguring proptosis, orbital pain, or intraocular complications. Incomplete excision has been associated with diffuse orbital invasion and intracranial spread to the chiasm. The risk of such spread outweighs the potential benefit of attempted resection. Attempts to decompress the optic nerve by opening the dural sheath have proved disappointing, and have resulted in massive orbital invasion requiring exenteration following surgical decompression.

**Radiotherapy** For lesions that show progression by worsening symptoms or radiographic findings, radiotherapy would be an appropriate option. In the past radiotherapy was considered ineffective; however, more recent reports using newer techniques suggest that in appropriate doses radiotherapy can be effective.<sup>23</sup> Fractionated stereotactic radiotherapy may offer a promising refinement with fewer complications.<sup>24</sup> The optimum total dose appears to be in the range of 50–55 Gy. Stability or improvement of vision has been reported in 50–95% of cases.<sup>25–27</sup> Similar results are being reported with the use of three-dimensional conformal fractionated radiation.<sup>27,28</sup> Complications of radiotherapy are reported in up to 15% of cases, and include new visual field defects, central retinal artery occlusion, and encephalopathy.

**Prognosis** Patients with optic sheath meningiomas have an excellent prognosis for life. There are few, if any, documented cases of tumor-related death. The prognosis for vision, however, is poor. Without treatment, in most patients visual loss progresses slowly but inexorably to blindness in the affected eye. However, in some cases a spontaneous improvement in vision or visual field has been reported.<sup>28</sup> Surgery offers little additional benefit and in most cases accelerates the process of visual loss. Rarely, a small anteriorly situated tumor may be excised with preservation or improvement of vision. Radiotherapy may stabilize or improve visual symptoms in some cases.

## REFERENCES

- Dutton JJ, Byrne SF, Proia AD. Diagnostic atlas of orbital diseases. Philadelphia: WB Saunders, 2000.
- Shields JA, Shields CL, Scartozzi R. Survey of 1264 patients with orbital tumors and simulating lesions: The 2002 Montgomery Lecture, part I. *Ophthalmology* 2004; 111: 997–1008.
- Gayre GS, Scott IU, Feuer W, Saunders TG, Siatkowski RM. Long-term visual outcome in patients with anterior visual pathway gliomas. *J Neuro-Ophthalmol* 2001; 2: 1–7.
- Czyzyk E, Jozwiak S, Roszkowski M, Schwartz RA. Optic pathway gliomas in children with and without neurofibromatosis 1. *J Child Neurol* 2003; 18: 471–478.
- Singhal S, Birch JM, Kerr B, Lashford L, Evans DG. Neurofibromatosis type 1 and sporadic gliomas. *Arch Dis Child* 2002; 87: 65–70.
- Thiagalingam S, Flaherty M, Billson F, North K. Neurofibromatosis type 1 and optic pathway gliomas: follow-up of 54 patients. *Ophthalmology* 2004; 111: 568–577.
- Glaser JS, Hoyt WF, Corbett J. Visual morbidity with chiasmal glioma. Long-term studies of visual fields in untreated and irradiated cases. *Arch Ophthalmol* 1971; 85: 3–12.
- Hoyt WF, Bagdassarian SA. Optic gliomas of childhood: Natural history and rationale for conservative management. *Br J Ophthalmol* 1969; 53: 793–798.
- Tow SL, Chandela S, Miller NR, Avellino AM. Long-term outcome in children with gliomas of the anterior visual pathway. *Pediatr Neurol* 2003; 28: 262–270.
- Mikaeloff Y, Chaix Y, Grill J et al. Optic pathway gliomas in neurofibromatosis type 1. Longitudinal study of 30 cases in two multidisciplinary practices. *Arch Pediatr* 2002; 9: 797–804.
- Khafaga Y, Hassounah M, Kandil A et al. Optic gliomas: a retrospective analysis of 50 cases. *Int J Radiat Oncol Biol Phys* 2003; 56: 807–812.
- Aquino VM, Fort DW, Kamen BA. Carboplatin for the treatment of children with newly diagnosed optic chiasm gliomas: a phase II study. *J Neuro-oncol* 1999; 41: 255–259.
- Silva MM, Goldman S, Keating G et al. Optic pathway hypothalamic gliomas in children under three years of age: the role of chemotherapy. *Pediatr Neurosurg* 2000; 33: 151–158.
- Kato T, Sawamura Y, Tada M et al. Cisplatin/vincristine chemotherapy for hypothalamic/visual pathway astrocytomas in young children. *J Neuro-oncol* 1998; 37: 263–270.
- Hoyt WF, Meshel LG, Lessell S et al. Malignant optic glioma of adulthood. *Brain* 1973; 96: 121–132.
- Dario A, Iadini A, Cerati M, Marra A. Malignant optic glioma of adulthood. Case report and review of the literature. *Acta Neurol Scand* 1999; 100: 350–353.
- Dutton JJ. Optic nerve sheath meningiomas. *Surv Ophthalmol* 1992; 37: 167–183.
- Saeed P, Rootman J, Nugent RA et al. Optic nerve sheath meningiomas. *Ophthalmology* 2003; 110: 2019–2030.
- Yuceer N, Erdogan A, Ziya H. Primary optic nerve sheath meningiomas. Report of seven cases (clinical neuroradiological, pathological and surgical considerations in seven cases). *J Neurosurg Sci* 1994; 38: 155–159.
- Cristante L. Surgical treatment of meningiomas of the orbit and optic canal: a retrospective study with particular attention to the visual outcome. *Acta Neurol (Wien)* 1994; 126: 27–32.
- Radhakrishnan S, Lee MS. Optic nerve sheath meningiomas. *Curr Treat Options Neurol* 2005; 7: 51–55.
- Richards JC, Roden D, Harper CS. Management of sight-threatening optic nerve sheath meningioma with fractionated stereotactic radiotherapy. *Clin Exp Ophthalmol* 2005; 33: 137–141.
- Baumert BG, Villa S, Studer G et al. Early improvements in vision after fractionated stereotactic radiotherapy for primary optic nerve sheath meningioma. *Radiother Oncol* 2004; 72: 169–174.
- Becker G, Jeremic B, Pitz S et al. Stereotactic fractionated radiotherapy in patients with optic nerve sheath meningioma. *Int J Radiat Oncol Biol Phys* 2002; 54: 1422–1429.
- Andrews DW, Faroozan R, Yang BP et al. Fractionated stereotactic radiotherapy for the treatment of optic nerve sheath meningiomas: preliminary observations of 33 optic nerves in 30 patients with historical comparison to observations with or without prior surgery. *Neurosurgery* 2002; 51: 890–902.
- Narayan S, Cornblath WT, Sandler HM, Elnor V, Hayman JA. Preliminary visual outcomes after three-dimensional conformal radiation therapy for optic nerve sheath meningioma. *Int J Radiat Oncol Biol Phys* 2003; 56: 537–543.
- Carasco JR, Penne RB. Optic nerve sheath meningiomas and advanced treatment options. *Curr Opin Ophthalmol* 2004; 15: 406–410.
- Eagan RA, Lessell S. A contribution to the natural history of optic nerve sheath meningiomas. *Arch Ophthalmol* 2002; 120: 1505–1508.

# Tumors of the lacrimal gland

Omar M. Durrani and Geoffrey E. Rose

## INTRODUCTION

Lacrimal gland tumors account for about 9–15% of all orbital tumors and represent a particularly difficult group with respect to diagnosis and management.<sup>1</sup> Diseases such as dacryoadenitis, sarcoidosis, Wegener's granulomatosis, and other inflammatory or infiltrative conditions account for over 60% of lacrimal gland masses and may present with signs and symptoms similar to neoplastic lesions, making it impossible to reach a firm clinical diagnosis.<sup>2</sup> Inflammatory lesions typically present with acute or subacute symptoms that can include a painful, tender swelling in the lacrimal gland area, an S-shaped deformity of the upper lid, and conjunctival redness and injection (Fig. 93.1). Lymphomas tend to have a chronic course with a painless displacement of the globe, although some patients can present with inflammatory features that are associated with a worse prognosis.<sup>3</sup>

Benign or malignant tumors may have similar presentation and enter the differential diagnosis for most lacrimal gland masses. Most primary tumors of the lacrimal gland are epithelial in origin, with about half being benign. In addition to a thorough history and clinical examination, radiological imaging plays a key role in establishing an appropriate plan for treatment.

## EPIDEMIOLOGY

Pleomorphic adenomas account for almost all benign tumors of the lacrimal gland (Table 93.1).<sup>4–6</sup> Adenoid cystic carcinoma is the most common (76%) malignant epithelial tumor.<sup>7</sup> Carcinoma arising in pre-existing pleomorphic adenoma (malignant mixed tumor) is the second most common malignancy of the lacrimal gland.<sup>8,9</sup> Mucoepidermoid carcinoma accounts for about 2% of epithelial tumors, whereas primary adenocarcinomas and squamous carcinomas are exceedingly rare. Lymphoma accounts for about 10–14% of all lacrimal gland masses and may be part of a systemic disease.<sup>1,2</sup> Tumors metastatic to the lacrimal gland are uncommon and tend to follow the course of the primary lesion, most being fast growing and associated with a poor prognosis.

## CLINICAL FEATURES

Pleomorphic adenomas present from childhood to old age, with a peak incidence in middle age.<sup>4,5</sup> Some reported series show a male preponderance<sup>4,5</sup> or an equal sex incidence.<sup>6</sup> Malignant epithelial tumors present at a similar age to pleomorphic adenomas and have a peak incidence in the fourth decade, but do not have a sex bias.<sup>7</sup>

**Symptoms** Patients with lacrimal gland tumors typically present with upper lid swelling or a mass, but other features depend on the

size, location, and nature of the lesion. Tumors in the palpebral lobe are rarer than orbital lobe tumors and, because of their anterior location, tend to present earlier with a palpable upper lid mass or an alteration in lid contour.<sup>10</sup> Patients with pleomorphic adenomas generally have a slowly progressive mass (without signs of inflammation) that has been present for over a year, or have a facial asymmetry noted by friends (Fig. 93.2). Larger tumors may also cause limitation of eye movement, with diplopia, or visual disturbances due to distortion of the globe by the firm tumor mass, with or without choroidal folds.<sup>6,7</sup>

Pain occurs rarely with pleomorphic adenoma or lacrimal lymphoma, but primary malignant tumors of the lacrimal gland are characterized by a short history and persistent pain. Lacrimal gland carcinoma tends to spread backwards along the lateral orbital wall, displacing the lateral rectus inferomedially with microscopic invasion of the orbital fat and a propensity to perineural spread. Late in the disease it tends to breach orbital periosteum, with spread to the bone and temporalis fossa, or extend through the superior orbital fissure to the middle cranial fossa.

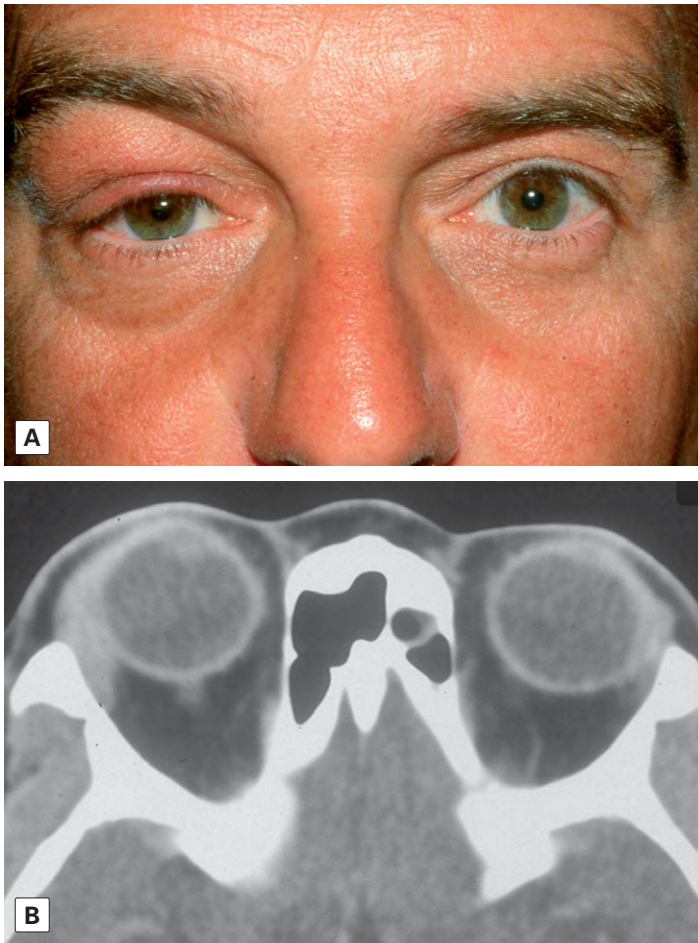
**Signs** A mobile, hard mass in the lateral aspect of the upper lid or a prominence of the palpebral lobe in the upper conjunctival fornix is found on examination. Orbital lobe tumors are characterized by progressive inferomedial globe displacement and relatively little proptosis.

Involvement of cranial nerves at the superior orbital fissure or in the cavernous sinus causes episcleral congestion, ptosis, diplopia, and periorbital sensory disturbance. A combination of persistent pain and sensory disturbance in the presence of a lacrimal gland mass is highly suggestive of a malignant lesion. The rate of growth, although much faster than that of benign tumors, varies between tumors: adenocarcinomas progress rapidly, whereas well-differentiated mucoepidermoid carcinomas have a relatively slow course;<sup>7</sup> the relentless growth of adenoid cystic carcinoma varies from slow to rapidly progressive. Lacrimal gland metastases tend to follow the course of the parent tumor, whereas lymphoma in this region may be primary orbital or part of a systemic disease. Progression of lacrimal gland lymphoma is very variable, although most follow a relatively indolent course.<sup>11</sup>

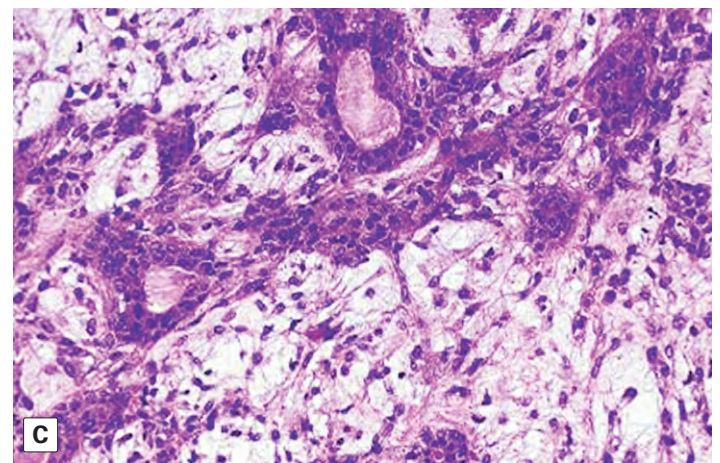
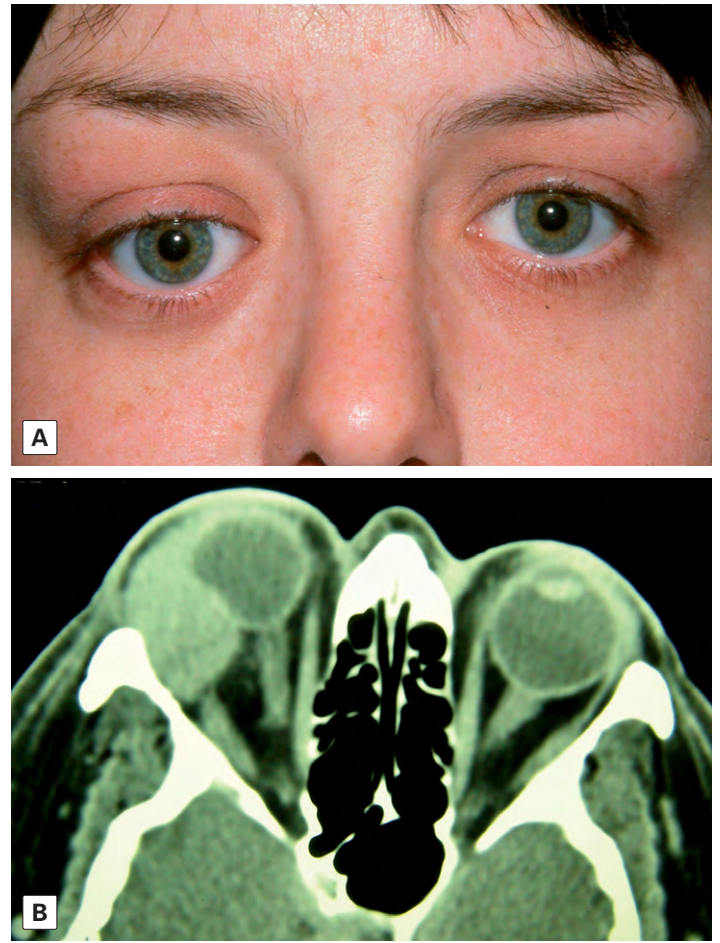
## DIAGNOSTIC EVALUATION

High-resolution computed tomography (CT), the primary imaging technique for orbital diseases, is valuable in the differentiation of lacrimal gland masses, and multislice scanners have markedly reduced





**Fig. 93.1** S-shaped deformity of the right upper lid caused by subacute dacryoadenitis (A). CT scan showing left lacrimal gland enlargement with molding around the globe (B).



**Fig. 93.2** Facial asymmetry due to pleomorphic adenoma of the right lacrimal gland (A). CT scan showing marked enlargement of the right lacrimal gland with molding around the globe (B). Epithelial cells centrally with eosinophilic cytoplasm and myoepithelial cells surrounding ducts showing clear lumen (C). (Hematoxylin & eosin.)

**Table 93.1 Primary lacrimal gland neoplasia<sup>12,19,25,27</sup>**

Types	Nomenclature
Benign tumors	Pleomorphic adenoma Myoepithelioma*
Malignant tumors	Adenoid cystic carcinoma Malignant mixed tumor (carcinoma arising within pleomorphic adenoma) Mucoepidermoid carcinoma Adenocarcinoma*

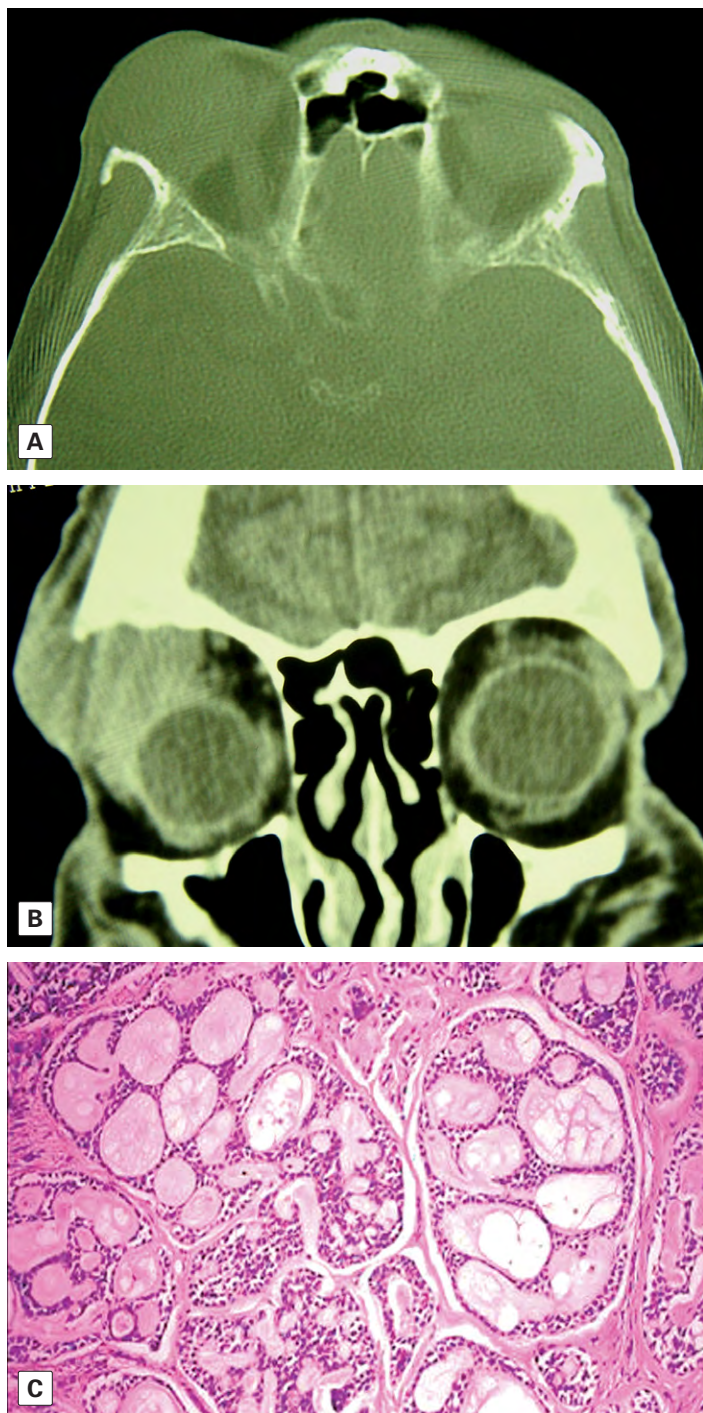\*Rare.

the acquisition time for orbital scans. Because bone changes are poorly shown on MR images this modality is not as useful as CT in establishing the diagnosis of lacrimal gland lesions.<sup>12</sup>

**Benign tumors** Pleomorphic adenomas appear as well-defined, sometimes nodular and non-homogeneous lesions that show moderate enhancement with intravenous contrast (Fig. 93.2). Palpebral lobe tumors lie anterior to the orbital rim, whereas expansion of the lacrimal fossa with preservation of intact cortical bone is seen in most cases of orbital lobe adenoma. Discrete calcification may also be present in a minority of cases, and indentation of the globe is common with larger tumors.

**Malignant tumors** are less defined, with infiltration into surrounding tissues, and bone invasion into the fossa is common (Fig. 93.3). Calcification occurs in about one-third of carcinomas, but is diffuse compared to pleomorphic adenomas; lymphomas and metastases are only rarely calcified. In contrast to the hard pleomorphic adenomas that flatten the globe, rapidly growing and softer lesions (such as carcinoma and lymphoma) tend to mold to its surface.





**Fig. 93.3** Adenoid cystic carcinoma of the right lacrimal gland with destruction of the lateral orbital wall bone (bone window, **A**). Soft tissue invasion of the right temporalis fossa through lateral wall defect (**B**). Typical cribriform appearance (**C**). (Hematoxylin & eosin.)

## **PATHOLOGY**

As pleomorphic adenomas and adenoid cystic carcinomas account for most lacrimal gland tumors, only their features will be discussed; details of other tumors can be found in various texts.<sup>9,13</sup>

**Pleomorphic adenoma** is typically solitary, lobulated, firm, grayish-white masses and microscopic examination shows sheets, cords, or masses of epithelial cells that are of ductal origin (see Fig.

93.2C). Metaplasia of the epithelium gives rise to myxoid and pseudocartilaginous areas, giving it a ‘pleomorphic’ appearance. Microscopic extension of the tumor occurs into the pseudocapsule of compressed neighboring tissues, and probably accounts for recurrence where the resection margin is insufficient.

**Adenoid cystic carcinoma** is gray-white, somewhat soft lesions that may be difficult to define during surgical resection, and microscopic examination shows small hyperchromatic, basophilic cells with varying amounts of stroma (Fig. 93.3C). Five patterns have been described: cribriform (most common), tubular, solid (basaloid), sclerosing and comedocarcinomatous. The basaloid pattern is the least common but associated with the most aggressive behavior.<sup>7</sup>

## **DIFFERENTIAL DIAGNOSIS**

Acute onset of a painful, swollen, and tender lacrimal gland is likely to be inflammatory or infectious in origin (bacterial or viral) rather than neoplastic. A lacrimal gland swelling that persists for more than a few weeks and does not respond to anti-inflammatory agents or antibiotics should be investigated with orbital CT scan and, if appropriate, biopsy should be performed as the inflammation may be related to an underlying carcinoma.

Differentiation of pleomorphic adenoma from primary malignancy is essential for an appropriate surgical plan, as pleomorphic adenoma requires intact excision whereas malignancy necessitates incisional biopsy. Based on the duration of symptoms and the presence of pain, Rose and Wright<sup>6</sup> proposed a clinical scoring system to help differentiate between a pleomorphic adenoma and other lesions (Table 93.2).<sup>14</sup> Painless lesions of over 10 months’ duration were typically pleomorphic adenomas – although the differential diagnosis included lymphoma, sarcoidosis, and chronic mild dacryoadenitis – whereas malignant tumors have a shorter history relative to their size, as well as persistent pain and paresthesia.<sup>6,9</sup>

With the advent of high-resolution multislice scanners, CT has become a major determinant in the practical management of lacrimal masses. A well-circumscribed tumor should be treated like a pleomorphic adenoma, with intact excision; in contrast, incisional biopsy should be carried out if the mass molds to the globe or there is radiologic evidence of bone invasion or intraorbital extension. A diagnosis of malignant transformation within a pleomorphic adenoma (malignant mixed tumor) should be considered when a patient with long-standing symptoms develops a sudden and dramatic acceleration of symptoms, especially if accompanied by recent onset of pain.<sup>15</sup>

## **TREATMENT**

**Pleomorphic adenoma** should be excised intact with a cuff of normal tissue, and handling with sharp instruments should be avoided. Palpebral lobe tumors are readily resected through an upper lid skin crease incision, although some may be accessible through the upper conjunctival fornix.<sup>6</sup> Orbital lobe tumors can be approached through a skin crease incision, which can be extended into the lateral canthal rhytides to allow a lateral osteotomy. Malleable retractors are used to manipulate the tumor as it is mobilized on an island of intact periosteum, and a buffer of normal tissue should always be maintained around the tumor. When intraoperative spillage of cells occurs, or if the periosteum is completely attenuated by the tumor, the breach should be treated by strict surgical isolation followed by thorough cautery and lavage of the operative field. Cyanoacrylate glue may be

**Table 93.2 Management plan for masses within the lacrimal gland**

Characteristics		Score	
		-1	+1
Clinical	Duration of acute symptoms	<10 months	>10 months
	Persistent pain	Present	Absent
Radiologic (Features on thin-slice CT images)	Sensory loss	Present	Absent
	Well defined mass	Present	Absent
	Molding of mass to globe or along lateral orbital wall	Present	Absent
	Tumor calcification	Present	Absent
	Invasion of bone	Present	Absent
	Duration of symptoms in relation to tumor size	Present	Absent
Therapeutic recommendation	Total score	Probable diagnosis	Type of biopsy
	-8 to +2	Carcinoma	Incisional
	-6 to +2	Malignant mixed tumor	Incisional or excisional
	+3 to +8	Pleomorphic adenoma	Total excision <i>without</i> prior biopsy
(Adapted from Rose GE, Wright JE. Pleomorphic adenoma of the lacrimal gland. Br J Ophthalmol 1992; 76: 395-400)			

applied to minor capsular breaches during surgery. Excision of the orbital lobe alone, with preservation of palpebral lobe, reduces the incidence of dry eye and secondary corneal disease.<sup>6</sup>

If a pleomorphic adenoma has been inadvertently biopsied – which is distinctly rare with contemporary imaging – the biopsy tract and the tumor should be meticulously excised as recurrence of pleomorphic adenoma is typically infiltrative and may otherwise necessitate extensive tissue resection or exenteration.<sup>16-18</sup>

**Adenoid cystic carcinoma** Tumors that are clinically and radiologically localized to the orbit should be debulked and given of the order of 55 Gy external beam irradiation or implant brachytherapy.<sup>19</sup> Surgical resection, when followed by external beam radiation, may delay the growth or recurrence of tumor: the median disease-free interval following this is 3 years, and the median survival rate is 10 years.<sup>19-21</sup> The areas irradiated should include the superolateral soft tissues of the orbit, lacrimal fossa, lateral orbital wall, and the orbital apex to include the superior orbital fissure as well as the anterior cavernous sinus. Brachytherapy with locally implanted radioactive plaques or seeds may also be effective in controlling the recurrence of lacrimal gland carcinoma.<sup>19</sup> Chemotherapy does not have a recognized role in the treatment of adenoid cystic carcinoma, although a report of two patients who received a combination cisplatin and doxorubicin intra-arterially, followed by surgical resection and external beam irradiation (55–60 Gy), both showed radiologic evidence of tumor shrinkage preoperatively and prolonged recurrence-free intervals (7–9 years) in both patients.<sup>22</sup>

**Malignant mixed tumor** (malignant transformation within pleomorphic adenoma) is treated with local excision followed by irradiation. Primary adenocarcinoma of the lacrimal gland is very rare and progresses rapidly to involve other orbital tissues, the temporalis fossa, and the cranium. Exenteration followed by radiotherapy is the recommended treatment.<sup>7,23</sup>

**Metastatic tumor** of the lacrimal gland carries a poor prognosis and treatment – generally palliative – reflects that of the primary tumor. Treatment consists of orbital irradiation and, where there is systemic disease, chemotherapy.<sup>24</sup>

## PROGNOSIS

**Pleomorphic adenoma** Malignant transformation of pleomorphic adenoma, as evidenced by an acceleration of previously stable or slowly progressive symptoms, is estimated to occur in about 10–20% of cases after 20 years, especially after incomplete excision.<sup>9,25</sup>

**Adenoid cystic carcinoma** The prognosis for primary epithelial carcinomas of the lacrimal gland is guarded and depends on the cell type: adenoid cystic carcinomas (the most common variant) are characterized by local recurrence, followed by metastasis. Perineural spread is thought to be responsible for intracranial spread and recurrence after resection. The median disease-free period is reported to be about 18 months to 3 years after resection, and the average survival is about 5



years.<sup>7,21,25</sup> Cure of this tumor may be impossible, and late recurrence has been reported up to 24 years after presentation, thus confounding the assessment of therapeutic outcome.<sup>9</sup>

**Malignant mixed tumor** Exenteration followed by radiotherapy has a less than 3-year survival rate in most patients.<sup>7,23</sup>

**Metastatic tumor** The prognosis for lacrimal gland lymphoma depends on several factors: systemic dissemination is more likely in patients with orbital or lacrimal gland involvement as well as patients with prior systemic disease. Patients with ophthalmic symptoms for more than a year are less likely to have systemic dissemination.<sup>3</sup> Histologic classification of infiltrating cells also has an impact on morbidity:

the 5-year mortality rate varies from 12% for marginal zone lymphoma to 53% with diffuse large B-cell lymphoma.

## SUMMARY

High-resolution CT scanning has improved the ability to differentiate between pleomorphic adenoma and other lacrimal gland masses, but the prognosis for lacrimal gland carcinoma remains bad despite advances in the diagnosis and treatment of other malignancies. Orbital irradiation after debulking of lacrimal malignancies seems to give the best disease-free interval, whereas intra-arterial chemotherapy administered before surgery needs further investigation. Cranio-orbital resection does not appear to prolong life, probably because of the propensity of adenoid cystic carcinoma to perineural spread or micrometastasis.

## REFERENCES

- Shields JA, Shields CL, Scartozzi R. Survey of 1264 patients with orbital tumors and simulating lesions: The 2002 Montgomery Lecture, part 1. *Ophthalmology* 2004; 111: 997–1008.
- Shields CL, Shields JA, Eagle RC, Rathmell JP. Clinicopathologic review of 142 cases of lacrimal gland lesions. *Ophthalmology* 1989; 96: 431–435.
- Jenkins C, Rose GE, Bunce C et al. Clinical features associated with survival of patients with lymphoma of the ocular adnexa. *Eye* 2003; 17: 809–820.
- Cates CA, Manners RM, Rose GE. Pleomorphic adenoma of the lacrimal gland in a 10 year old girl. *Br J Ophthalmol* 2002; 86: 249–250.
- Mercado GJ, Gunduz K, Shields CL et al. Pleomorphic adenoma of the lacrimal gland in a teenager. *Arch Ophthalmol* 1998; 116: 962–963.
- Rose GE, Wright JE. Pleomorphic adenoma of the lacrimal gland. *Br J Ophthalmol* 1992; 76: 395–400.
- Wright JE, Rose GE, Garner A. Primary malignant neoplasms of the lacrimal gland. *Br J Ophthalmol* 1992; 76: 401–407.
- Gamel JW, Font RL. Adenoid cystic carcinoma of the lacrimal gland: the clinical significance of a basaloid histologic pattern. *Hum Pathol* 1982; 13: 219–225.
- Rootman J, White V, Hind A. Tumors of the lacrimal gland. In: Rootman J, ed. *Disease of the orbit. A multidisciplinary approach*, 2nd edn. Philadelphia: Lippincott Williams & Wilkins, 2003.
- Vangveeravong S, Katz SE, Rootman J, White V. Tumors arising in the palpebral lobe of the lacrimal gland. *Ophthalmology* 1996; 103: 1606–1612.
- Bardenstein DS. Ocular adnexal lymphoma: classification, clinical disease, and molecular biology. *Ophthalmol Clin North Am* 2005; 18: 187–197.
- Aviv RI, Miszkil K. Orbital imaging: Part 2. Intraorbital pathology. *Clin Radiol* 2005; 60: 288–307.
- Yanoff M, Fine BS. *Ocular pathology*, 5th ed. New York: Mosby, 2005.
- Wright JE, Stewart WB, Krohel GB. Clinical presentation and management of lacrimal gland tumours. *Br J Ophthalmol* 1979; 63: 600–606.
- Perzin KH, Jakobiec FA, Livolsi VA, Desjardins L. Lacrimal gland malignant mixed tumors (carcinomas arising in benign mixed tumors): a clinicopathologic study. *Cancer* 1980; 45: 2593–2606.
- Font RL, Gamel JW. Epithelial tumors of the lacrimal gland: An analysis of 265 cases. In: Jakobiec FA, ed. *Ocular and adnexal tumors*. Birmingham, AL: Aesculapius, 1978.
- Ni C, Kuo PK, Dryja TP. Histopathological classification of 272 primary epithelial tumors of the lacrimal gland. *Chin Med J (Engl)* 1992; 105: 481–485.
- Rose GE, Wright JE. Exenteration for benign orbital disease. *Br J Ophthalmol* 1994; 78: 14–18.
- Shields JA, Shields CL, Freire JE et al. Plaque radiotherapy for selected orbital malignancies: preliminary observations: the 2002 Montgomery Lecture, part 2. *Ophthalm Plast Reconstr Surg* 2003; 19: 91–95.
- Brada M, Henk JM. Radiotherapy for lacrimal gland tumors. *Radiother Oncol* 1987; 175–183.
- Esmaili B, Ahmadi MA, Youssef A et al. Outcomes in patients with adenoid cystic carcinoma of the lacrimal gland. *Ophthalm Plast Reconstr Surg* 2004; 20: 22–26.
- Meldrum ML, Tse DT, Benedetto P. Neoadjuvant intracarotid chemotherapy for treatment of advanced adenocystic carcinoma of the lacrimal gland. *Arch Ophthalmol* 1998; 116: 315–321.
- Heaps RS, Miller NR, Albert DM et al. Primary adenocarcinoma of the lacrimal gland. A retrospective study. *Ophthalmology* 1993; 100: 1856–1860.
- Jenkins C, Rose GE, Bunce C et al. Histological features of ocular adnexal lymphoma (REAL classification) and their association with patient morbidity and survival. *Br J Ophthalmol* 2000; 84: 907–913.
- Font RL, Smith SL, Bryan RG. Malignant epithelial tumors of the lacrimal gland: a clinicopathologic study of 21 cases. *Arch Ophthalmol* 1998; 116: 613–616.

# Tumors of the lacrimal sac

Jacob Pe'er

## INTRODUCTION

Tumors of the lacrimal drainage system, especially the lacrimal sac, are rare, and since the first publications reporting such tumors by Spratt, Duke-Elder, Radnot and Gall, and others,<sup>1-7</sup> only about 500 cases have been reported in the medical literature in the last 110 years; about five new cases are reported per year worldwide. Despite their rarity, physicians should be aware of the clinical features of lacrimal sac tumors as many of them masquerade as a chronic inflammatory process.

## CLINICAL FEATURES

Lacrimal sac tumors are usually diagnosed in adults, with average age in the 50s, benign tumors being diagnosed about a decade earlier than malignant ones;<sup>1-9</sup> however, tumors in the lacrimal sac have also been reported in children and infants.<sup>9-11</sup> Although in a series from China, men were more commonly affected,<sup>8</sup> in most series there was no significant difference in the incidence between males and females.<sup>1-7,9</sup> Overall, 50–90% of tumors of the lacrimal sac are malignant, and about 75% of these are epithelial in origin.<sup>1-9</sup>

**Symptoms** of dacryostenosis and/or dacryocystitis due to complete or partial obstruction of the drainage system are common.<sup>8,9,12</sup> Patients suffer from chronic epiphora and many have a history of chronic dacryocystitis, with redness, swelling, and purulent discharge. Because of the similarity of symptoms, lacrimal sac tumors are often found inadvertently at the time of dacryocystorhinostomy (DCR) for presumed dacryostenosis. This is the reason that DCR specimens should always be submitted for pathologic evaluation.<sup>13</sup>

**Signs** The main sign of lacrimal sac tumor is a mass in the area of the lacrimal sac (Fig. 94.1); the appearance of a mass above the medial canthal tendon level is most characteristic. In benign tumors the mass is elastic in consistency with distinct margins, and is freely movable under the skin. On the other hand, most malignant tumors appear firm in consistency, are non-compressible, and are fixed to the underlying tissue. Fistulous tracts may be present. Bleeding from the puncta, either spontaneously or on applying pressure to the lacrimal sac, or bleeding from the nose (epistaxis) or a dark bloody nasal discharge are found in some patients, mainly those with epithelial tumors.<sup>9</sup> Some patients with malignant tumors complain of pain.<sup>7</sup>

In advanced cases of malignant tumors ulceration over the mass can be seen, with involvement of the preauricular, submandibular, and cervical lymph nodes. In some cases, regional lymph node involve-

ment appears before the primary tumor is discovered. With significant tumor growth and involvement of the orbit, proptosis and limitation of ocular motility may develop. Destruction of the face, nose, ethmoid and maxillary sinuses, and palate, as well as intracranial extension, are rarely observed.<sup>2</sup>

## DIAGNOSTIC EVALUATION

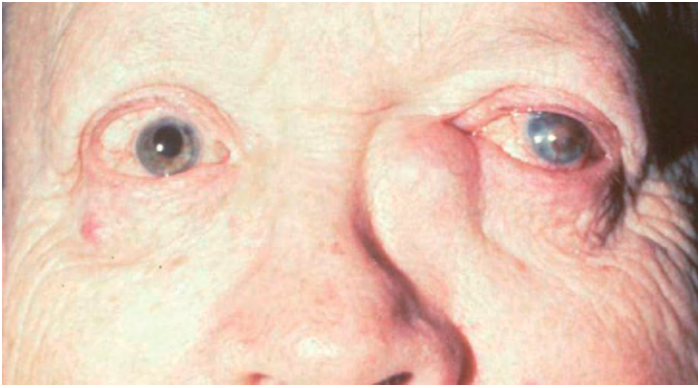
**Imaging studies** are important in the evaluation of a lacrimal sac tumor.<sup>2,3,8,9,12</sup> CT shows a solid mass over the lacrimal sac area, may display dilatation of the lacrimal fossa and/or bony erosion or destruction of the lacrimal fossa, and, in advanced cases, invasion into neighboring structures (Fig. 94.2). Ultrasound scanning can also be used, and some experts have found magnetic resonance imaging (MRI) to be superior to CT for imaging of the lacrimal sac, as it provides better tumor definition and determination of the cystic or solid nature of the mass.<sup>11</sup> Dacryocystography (DCG) may reveal a filling defect of the sac lumen or a distended sac with uneven or mottled contrast media, or a delay in draining of the contrast material (Fig. 94.3). Where the tumor is benign or in the early stages the lacrimal drainage system may be patent, so that negative results do not rule out a tumor.

**Histopathology of DCR specimen** In one series of 377 DCR specimens,<sup>13</sup> lacrimal sac neoplasms resulting in chronic lacrimal drainage obstruction occurred in 4.6% of cases; in 2.1% they were not suspected before surgery. Therefore, in every case of a mass in the lacrimal sac area that causes obstruction, a lacrimal sac tumor should be suspected. Inflammatory response in this area does not rule out the diagnosis of a tumor. In such patients a history of bloodstained tears or epistaxis should increase the suspicion.

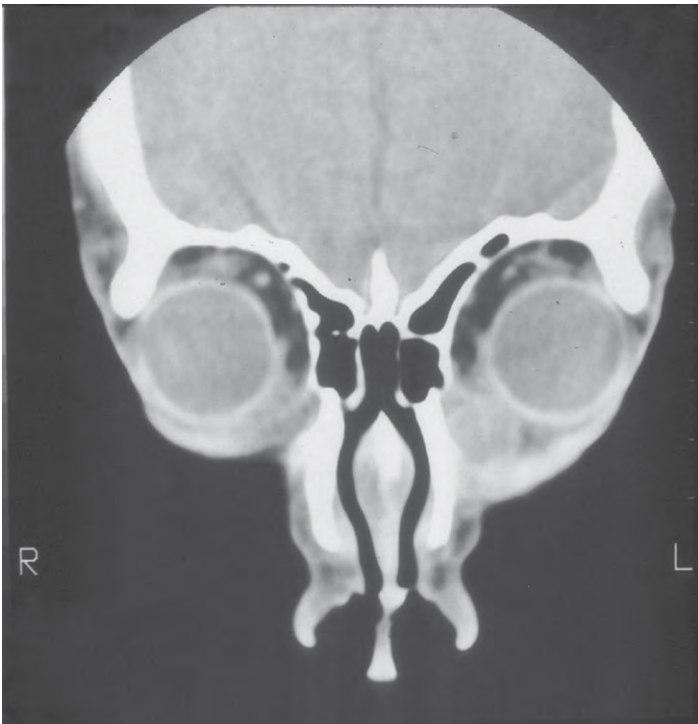**Biopsy** The final diagnosis can be ascertained only by histopathological examination, for which excisional biopsy is preferred. If the entire tumor cannot be removed, deep incisional biopsy is essential as the tumor periphery may show only an inflammatory response, leading to misdiagnosis and misinterpretation of inflammatory pseudotumor. When a patient with suspected lacrimal sac tumor has involvement of the nasal cavity, biopsy via the nasal route is possible.

## DIFFERENTIAL DIAGNOSIS

As most patients with lacrimal sac tumors present with symptoms and signs of dacryocystitis, obviously the main differential diagnosis is from acute or chronic dacryocystitis and, indeed, lacrimal sac tumors are often found at the time of DCR for presumed dacryostenosis,



**Fig. 94.1** A man with a transitional cell carcinoma of the lacrimal sac of the left eye presenting with a mass that reaches a level above the medial canthal tendon. (Courtesy of Mary A. Stefanyzyn, MD)

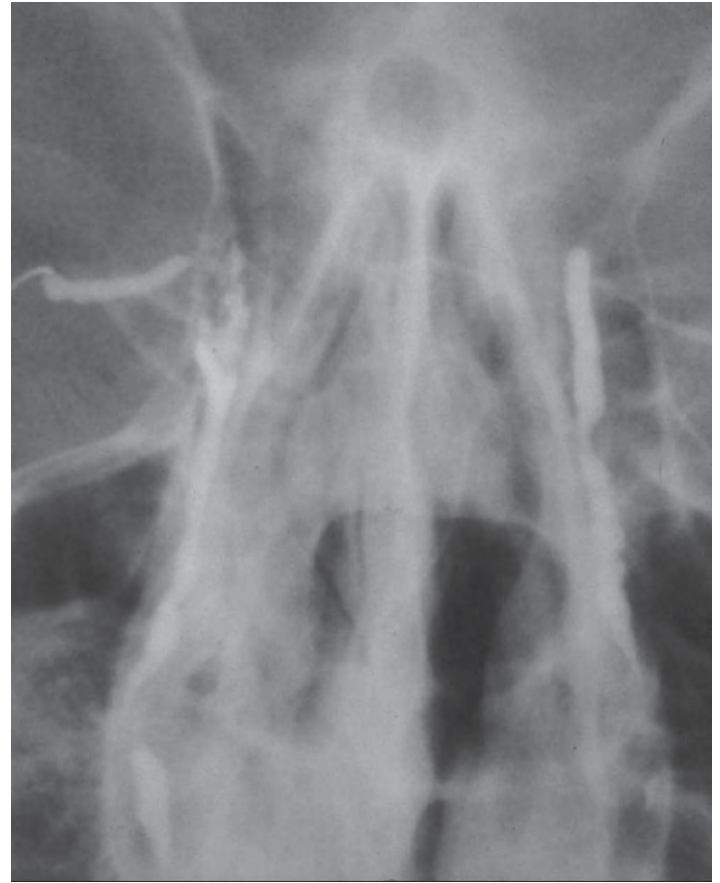

**Fig. 94.2** A CT scan shows a mass over the left lacrimal sac area. (Courtesy of Mary A. Stefanyzyn, MD)

mostly due to dacryocystitis. Inflammatory pseudotumors of the lacrimal sac, such as granulomas or granulation tissue, or an infective process due to tuberculosis or fungus, should also be included in the differential diagnosis.

### HISTOPATHOLOGICAL CLASSIFICATION

The canaliculus is lined by non-keratinized stratified squamous epithelium and the lacrimal sac and nasolacrimal duct are lined by stratified columnar (transitional) epithelium containing mucous glands. The origin of most benign and malignant epithelial tumors is in the epithelial lining of the lacrimal sac, and the tumor can therefore be either squamous or transitional in type.<sup>5,7,9</sup> Lacrimal sac tumors are divided into two major groups: the epithelial tumors, which account for about 75% of reported cases, and the non-epithelial tumors, which account for the remaining 25% (Tables 94.1 and 94.2).<sup>8,9,13-16</sup>



**Fig. 94.3** Dacryocystogram reveals a mottled defect in the right lacrimal sac compared to the smooth outline of the left lacrimal sac. (Courtesy of Mary A. Stefanyzyn, MD)

### Epithelial tumors

*Papilloma* may exhibit an exophytic growth pattern, growing towards the sac lumen, or an inverted pattern, growing towards the stroma. The latter, more than the former, tends to be invasive, recur, and undergo malignant change. Marked inflammation is often seen in the stroma of the papilloma.

*Squamous and transitional cell carcinoma* Squamous cell carcinoma may range from a well-differentiated tumor with keratin pearls and intercellular bridges to a poorly differentiated one. Transitional cell carcinoma may show a papillary pattern, and be composed of cylindrical epithelial cells (Fig. 94.4). Goblet cells may be seen. Both types of carcinoma invade the lacrimal sac wall and produce a hard mass.

*Other epithelial tumors* Most other benign and malignant epithelial tumors of the lacrimal sac arise from the mixed glands (serous and mucous) in the lacrimal sac as well as in the wall of the nasolacrimal duct.<sup>14</sup> The common benign tumors in this group are oncocytoma and pleomorphic adenoma and, among the malignant tumors, oncocytic adenocarcinoma and adenoid cystic carcinoma.

*Non-epithelial tumors* constitute about 25% of lacrimal sac tumors; of these, about half are mesenchymal, one-quarter lymphoproliferative, and one-quarter melanoma. Only a few neural tumors

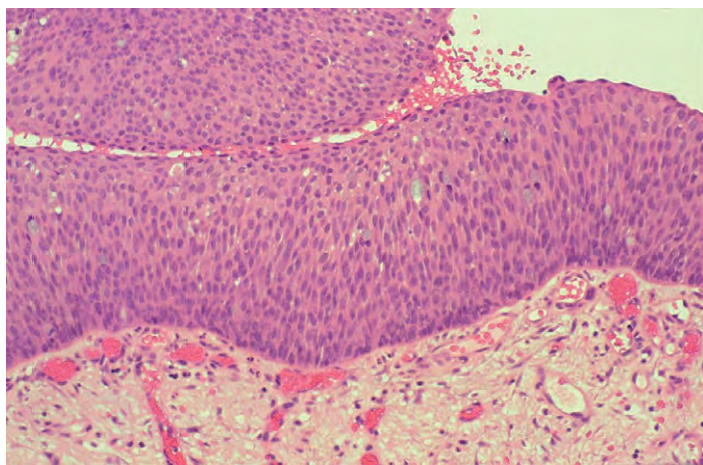


**Table 94.1 Histopathological classification of epithelial tumors of the lacrimal sac**

Category		Subtype	
Benign	Papilloma	Squamous papilloma	Transitional cell papilloma
		Mixed cell papilloma	Papilloma unspecified
	Oncocytoma		
	Mucocele	Pleomorphic adenoma (mixed tumor)	Cylindroma
Malignant	Papilloma with carcinoma		
	Carcinoma	Squamous cell carcinoma	Transitional cell carcinoma
		Mixed squamous/transitional carcinoma	Oncocytic adenocarcinoma
		Mucoepidermoid carcinoma	Adenoid cystic carcinoma
		Adenocarcinoma	Adenocarcinoma ex-pleomorphic adenoma
Eccrine adenocarcinoma		Undifferentiated carcinoma	
Secondary tumors			

**Table 94.2 Histopathological classification of non-epithelial tumors of the lacrimal sac**

Category		Subtype	
Mesenchymal–fibrous tissue	Benign	Fibrous histiocytoma	Lipoma
		Juvenile xanthogranuloma	
Mesenchymal–vascular	Benign	Malignant fibrous histiocytoma	
		Capillary hemangioma	Cavernous hemangioma
		Hemangiopericytoma	Angiofibroma
		Hemangioendothelioma	Glomus tumor
	Malignant	Kaposi's sarcoma	
Melanocytic	Benign	Nevi	
	Malignant	Melanoma	
Lymphoproliferative	Benign reactive lymphoid hyperplasia	Malignant lymphoma	
	Leukemic infiltrate (granulocytic sarcoma)	Plasmacytoma	
Neural	Neurofibroma	Neurilemmoma (schwannoma)	
Inflammatory pseudotumors			
Secondary tumors			

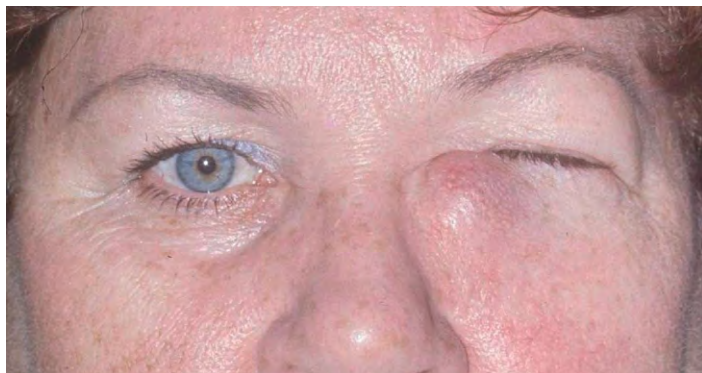

**Fig. 94.4** Histological picture of transitional cell carcinoma of the lacrimal sac, showing cylindrical epithelial cells. Some goblet cells are seen among the epithelial cells. (Hematoxylin & eosin, original magnification  $\times 40$ ). (Courtesy of Mary A. Stefanyszyn, MD)

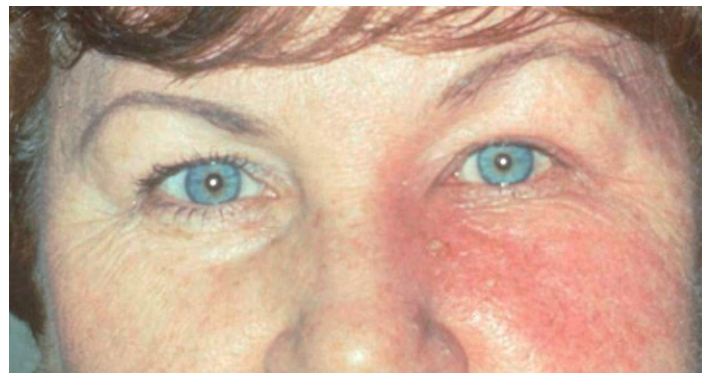have been reported.<sup>15</sup> The mesenchymal tumors appear at a relatively young age, compared to other groups of lacrimal sac tumors.

**Mesenchymal tumors** Fibrous histiocytoma is increasingly recognized as a common mesenchymal tumor of the lacrimal sac. Most fibrous histiocytomas of the lacrimal sac are benign and some are locally aggressive. Malignant fibrous histiocytoma of the lacrimal sac has not been reported. Among the very rare vascular tumors of the lacrimal sac, the most common reported is hemangiopericytoma, which histologically shows a vascular pattern of sinusoidal spaces, among which are solid areas of spindle-shaped cells. Even benign-appearing lesions have the potential to metastasize.

**Lymphoproliferative tumors** It appears that most lymphomas of the lacrimal sac are of the non-Hodgkin's B-cell type.<sup>10–12,17</sup> Leukemic infiltrates in the lacrimal drainage system are probably more frequent than reported.<sup>10</sup>



**Fig. 94.5** A woman with squamous cell carcinoma of the left lacrimal sac presenting with an irreducible hard mass and a history of chronic dacryocystitis. (Courtesy of Mary A. Stefanyshyn, MD)



**Fig. 94.6** The same woman as in Figure 94.5 following extensive surgical resection of the tumor and postoperative radiation, soon after completing the radiation treatment. Tumor is not seen, but redness, dryness and scaling skin are evident. (Courtesy of Mary A. Stefanyshyn, MD)

**Melanoma** of the lacrimal sac, like melanomas of other mucous membranes, has a poor prognosis and is probably the most malignant tumor of the lacrimal sac.<sup>15</sup>

**Other non-epithelial tumors** Neural tumors of the lacrimal sac are extremely rare. They originate from adjacent neural elements and invade the lacrimal sac wall. Two neurilemmomas and two neurofibromas have been reported so far.

**Secondary tumors** of the lacrimal sac may originate either from adjacent structures such as the nose, paranasal sinuses, orbit, conjunctiva, and skin, or as metastases, although the latter are rarely confined to the lacrimal sac alone.

## TREATMENT

The treatment of lacrimal sac tumors depends on the histological type, malignancy, and the extent of invasion through the lacrimal sac to adjacent tissue.<sup>2,8-12</sup> The treatment of choice is complete surgical removal. When epithelial and mesenchymal tumors are confined to the lacrimal sac, dacryocystectomy is performed. This usually suffices for benign tumors. En-bloc excision of the tumor with the periosteum of the fossa and supplemental external irradiation can be added if the tumor is malignant. Deep incisional biopsy, with or without frozen section, is performed when the mass is clinically suspected to be malignant or observed by imaging to extend beyond the lacrimal fossa. In some cases, biopsy can be taken through nasal endoscopy.

Extension of tumors, mainly premalignant and malignant, down the nasolacrimal duct accounts for recurrences and failure of therapy; therefore, lateral rhinostomy, which offers a greater chance of cure, should be performed. Extensive surgical excision of the canaliculi and nasolacrimal duct, together with the sac, may be needed in certain cases. When the tumor extends beyond the lacrimal drainage system to adjacent tissue, radical surgery, including exenteration of the orbital tissue, paranasal sinus resection, and cervical lymph node dissection, is needed. Postoperative radiotherapy is recommended for malignant epithelial tumors, with a suggested dose of approximately 60 Gy. Recurrent lesions may be treated with further surgery or radiotherapy (Figs 94.5, 94.6).

## PROGNOSIS

The outcome in cases of lacrimal sac tumor depends on the stage at the time of diagnosis, the histopathological features of the tumor, growth pattern, and the appropriateness of treatment. Ni and colleagues<sup>8</sup> offered four stages for the evolution of lacrimal sac tumors: stage 1, in which there are symptoms and signs but no definite tumor mass is seen or palpable; stage 2, in which obvious tumor formation is confined to the sac; stage 3, in which the tumor extends beyond the lacrimal sac to adjacent structures such as the orbit or paranasal sinuses; and stage 4, which is marked by evident metastases.

Malignant tumors of the lacrimal sac display three types of growth:<sup>8</sup> along the surface of the epithelium; protruding toward the lumen as papillary growth; and infiltrating the wall of the sac as solid cell nests. There are three main modes of tumor spread:<sup>8</sup> direct extension is the most common, to adjacent structures such as the orbit, nasolacrimal duct, paranasal sinuses and the skull; lymphatic metastases mainly to the submandibular, preauricular and cervical glands; and remote, most probably hematogenous spread, the most common site being to the lung.

Benign papillomas of the lacrimal sac have a tendency to recur, especially those with an inverted pattern, with a 10–40% recurrence rate.<sup>12</sup> Most papillomas that recur do not reveal malignant changes.<sup>7</sup> Low-grade carcinomas have variable cure rates depending on the extent of the disease and the treatment. The recurrence rate of invasive squamous cell and transitional cell carcinoma appears to be about 50%, with up to 50% of those being fatal, although some series have reported a much better outcome.

Recurrence and mortality rates for non-epithelial lacrimal sac tumors vary.<sup>9,12,15</sup> Benign fibrous histiocytoma has a good prognosis if completely excised, but the malignant potential of hemangiopericytoma can be unpredictable. Lymphoid lesions respond to radiotherapy and chemotherapy and have a variable prognosis, depending on the extent of the disease and the type of tumor. The most dismal prognosis is that of malignant melanoma, which is often fatal in a short period of time despite aggressive treatment.

## REFERENCES

1. Spratt CN. Primary carcinoma of the lacrimal sac. *Arch Ophthalmol* 1937; 18: 267–273.
2. Duke-Elder S. Diseases of the lacrimal passages – tumours and pseudotumours. In: Duke-Elder S. *Textbook of ophthalmology*, vol. 13, pt. II. St Louis: CV Mosby; 1974: 735–759.
3. Jones IS. Tumors of the lacrimal sac. *Am J Ophthalmol* 1956; 42: 561–566.
4. Radnot M, Gall J. Tumoren des Traensackes. *Ophthalmologica* 1966; 151: 1–22.
5. Harry J, Ashton N. The pathology of tumours of the lacrimal sac. *Trans Ophthalmol Soc UK* 1968; 88: 19–35.
6. Schenck NL, Ogura JH, Pratt LL. Cancer of the lacrimal sac. *Ann Otol Rhinol Laryngol* 1973; 82: 153–161.
7. Ryan SJ, Font RL. Primary epithelial neoplasms of the lacrimal sac. *Am J Ophthalmol* 1973; 76: 73–88.
8. Ni C, D’Amico DJ, Fan CQ, Kuo PK. Tumors of the lacrimal sac: A clinicopathological analysis of 82 cases. *Int Ophthalmol Clin* 1982; 22: 121–140.
9. Stefanyshyn MA, Hidayat AA, Pe’er JJ, Flanagan JC. Lacrimal sac tumors. *Ophthalm Plast Reconstr Surg* 1994; 10: 169–184.
10. Yip CC, Bartley GB, Habermann JM, Garrity JA. Involvement of the lacrimal drainage system by leukemia and lymphoma. *Ophthalm Plast Reconstr Surg* 2002; 18: 242–246.
11. Scheffler AC, Shields CL, Shields JA et al. Lacrimal sac lymphoma in a child. *Arch Ophthalmol* 2003; 121: 1330–1333.
12. Parmar D, Rose GE. Management of lacrimal sac tumours. *Eye* 2003; 17: 599–606.
13. Anderson NG, Wojno TH, Grossniklaus HE. Clinicopathologic findings from lacrimal sac biopsy specimens obtained during dacryocystorhinostomy. *Ophthalm Plast Reconstr Surg* 2003; 19: 173–176.
14. Pe’er J, Hidayat AA, Ihsar M, Landau L, Stefanyshyn MA. Glandular tumors of the lacrimal sac. Their histologic patterns and possible origins. *Ophthalmology* 1996; 103: 1601–1605.
15. Pe’er JJ, Stefanyshyn M, Hidayat AA. Nonepithelial tumors of the lacrimal sac. *Am J Ophthalmol* 1994; 118: 650–658.
16. Campbell RJ, Sobin LH. Tumours of the lacrimal drainage system. *Histological typing of tumours of the eye and its adnexa*, 2nd edn. World Health Organization International Histological Classification of Tumors. Berlin: Springer; 1998: 25–26.
17. Sjo LD, Ralfkiaer E, Juhl BR et al. Primary lymphoma of the lacrimal sac: an EORTC ophthalmic oncology task force study. *Br J Ophthalmol* 2006; 90: 1004–1009.



# Orbital and adnexal lymphoma

David S. Bardenstein

## INTRODUCTION

Ocular adnexal lymphoma (OAL) represents the malignant end of the spectrum of ocular adnexal lymphoproliferative disease and has reactive lymphoid hyperplasia (RLH) and RLH with atypia as its benign and intermediate forms, respectively. The importance of OAL in ophthalmology is based on the fact that it represents the most common group of orbital tumefactions in most series; the incidence is felt to be increasing, although the exact basis for this is unknown; and the orbital disease can be part of systemic lymphoma. OAL is a localized form (orbit, lacrimal gland, lids, and conjunctiva) of systemic lymphoma, and many of the advances in understanding OAL were initially demonstrated in systemic lymphoma (Box 95.1).

## EPIDEMIOLOGICAL ASPECTS

Historic data suggest that OAL comprises 6–8% of orbital tumors and 10–15% of adnexal lesions.<sup>1–4</sup> The incidence of OAL among systemic lymphoma is not known. OAL affects both genders, with a slight female predilection. It affects most ethnic groups, although there is significant geographic variation among systemic lymphoma, with the white population in the United States showing the highest incidence. The overall incidence of systemic lymphoma is increasing, but no corresponding information exists for OAL.<sup>5</sup>

OAL can affect the conjunctiva, eyelid, and orbit/lacrimal gland as well as the nasolacrimal drainage system. The reported frequencies of involvement in these sites are the conjunctiva 20–33%, orbit/lacrimal gland 46–74%, and eyelid 5–20%.<sup>6,7</sup> Estimates of involvement of multiple adnexal sites range from 10% to 20%. However, distinction between these sites can be difficult and combined involvement may be underreported.<sup>8,9</sup> Bilaterality is reported in 10–20% of cases. Recent studies have shown a higher incidence of OAL, presumably due to the ability of new methods and classifications to distinguish previously ambiguous cases.

## ETIOLOGY AND PATHOGENESIS: B-CELL BIOLOGY AND LYMPHOMAGENESIS

The greatest advances in our understanding of lymphoma pathogenesis and etiology as well as classification derive from the refined immunophenotypic (IPA) characterization of lymphocyte surface markers combined with concurrent advances in understanding of the molecular genetics of lymphocyte biology. This has resulted in a mechanistic hypothesis for lymphomagenesis that connects specific lymphoma types to different precursor cells and genetic events. In a manner different from other tumors, lymphoma classification, diagnosis, patho-

genesis are intertwined with the immunopathology and molecular biology.

The relationship between stages of lymphocyte development and their associated lymphoma types, which are based on immunophenotypic analysis, are shown in Table 95.1. Tumors arise from germinal center cells (follicular lymphoma), mantle cells (mantle cell lymphoma), or memory B cells (extranodal marginal zone lymphoma), all of which have undergone antigen exposure. From a molecular genetic standpoint, during the normal process of lymphocyte maturation mistakes occur in which an antigen receptor gene region is juxtaposed to an oncogene region, resulting in deregulation of the oncogene region. Less often a novel oncogenic protein is formed by the fusion of two other genes. Chromosomal translocations underlying these alterations are well described in up to 90% of systemic lymphomas.<sup>10,11</sup> Limited data suggest that these translocations are less common in OAL.<sup>12,13</sup>

The underlying concept that many lymphomas develop as a result of mistakes occurring during normal lymphocyte response to infection or inflammation is referred to as the infection/inflammation/mutation (IMM) model of lymphomagenesis. This has been corroborated in two ways. One is the recognized association of lymphoma with chronic antigen stimulation and infection, immune suppression, and autoimmune disease.<sup>14</sup> More powerful is the prototypic example of gastric extranodal marginal zone lymphoma/MALT lymphoma, in which an organ without endogenous lymphoid tissue develops lymphoma in response to chronic *Helicobacter pylori* infection. With the recent understanding that most OAL are also extranodal marginal zone lymphoma/MALT lymphomas, studies have appeared that show evidence of DNA from infectious agents, including *Clostridium psittaci* and *H. pylori* in OAL.<sup>15,16</sup>

In addition to its therapeutic implications, perhaps the most important consequence of the IMM model is that it explains why the ocular adnexa, which has little if any endogenous lymphoid tissue, has lymphoma as its most common neoplasia. Similar mechanisms may occur in RLH. Based on the relative infrequency of OAL, there may be other factors required for lymphomagenesis.

## CLASSIFICATION

Lymphoma classification can be confusing as multiple criteria are used in different contexts. OAL is a localized form of lymphoma which has only been well integrated into the overall schema of lymphoproliferative disease since the last two systems of classification (the Revised European American Lymphoma classification, 1994<sup>17</sup> and the WHO

classification, 2001<sup>18</sup>). OAL can be divided by type and site(s) of involvement. OAL is termed solitary if it is the only site involved, secondary when contiguous sites are involved, and systemic if remote sites are involved. General principles of systemic lymphoma staging apply to OAL.

### BOX 95.1 Ocular Adnexal Lymphoma

- OAL consists primarily of five types of lymphoma, the most common of which is extranodal marginal zone type (EMZT)
- The diagnosis depends on pathology, immunophenotypic analysis, and molecular genetics studies
- Updated lymphoma classifications allow excellent diagnostic accuracy
- Treatment of local disease consists of radiation and other local modalities with good local control but a variable long-term prognosis
- Low-grade tumors with systemic involvement are treated by observation or local methods
- Chemotherapy is used for high-grade disease with systemic involvement
- Infection and chronic inflammation may play a role in lymphomagenesis, and new treatment modalities may be directed at them

The vast majority of OAL are of the non-Hodgkin's B-cell type. Despite the extensive numbers of systemic lymphoma subtypes, most OAL belong to one of five subtypes (Table 95.2):<sup>7,9,19–27</sup> extranodal marginal zone (EMZL or MALT lymphoma), follicular lymphoma (FL); diffuse large B-cell lymphoma (DLBCL); mantle cell lymphoma (MCL); and lymphoplasmacytic lymphoma (LPL). In all series most OAL are the EMZL type.

OAL is solitary in 60–80% of cases at the time of presentation.<sup>19,21,24,27</sup> The rate of progression to systemic involvement can only be accurately identified using current criteria, as misclassification was so high before use of the WHO classification.

### CLINICAL FEATURES

**Symptoms** Subjective complaints in OAL include lacrimal gland, orbital, conjunctival mass or apparent eyelid mass, exophthalmos, pain, or diplopia, but many lesions are asymptomatic. If the lacrimal glands are involved, dry eye symptoms may occur.

**Signs** OAL have site-specific presentations that affect how the diagnosis is made. In the conjunctiva the lesions typically have a salmon or flesh-pink color (Fig. 95.1A). Clinical appearance does not allow a distinction between benign and malignant lymphoproliferative disease. In the orbit, lacrimal gland, and eyelid the lymphoma presents as an unseen mass which, if palpable, is typically very firm. Mobility is variable depending on its attachments to other structures. Diplopia occurs infrequently owing to the typically slow development of these masses.

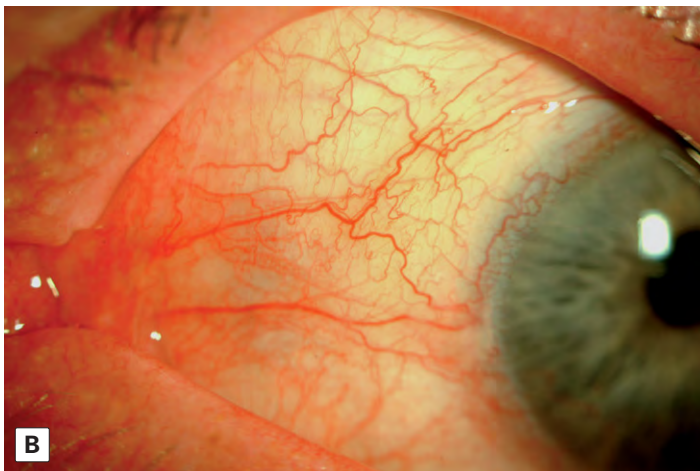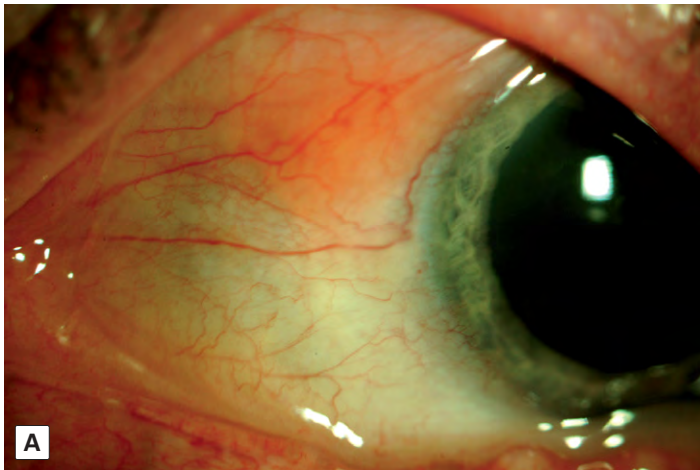
**Table 95.1 Immunophenotypic expression of ocular adnexal lymphoma**

Type	Precursor cell	CD3	CD5	CD10	CD20	CD23	CD43	CD79	Bcl-2	Bcl-6	Cyclin D1
EMZL	Memory B-cell	–	–	–	+	–	+	+	–	–	–
FL	Centrocyte	–	–	+	+	+/-	–		+	+	–
MCL	Mantle cell	–	+	–	+				–		+
LPL	Memory B-cell	–	+	–	+	+					
DLBCL	Centroblast	–	–	+	+			+			

EMZL, extranodal marginal zone lymphoma; FL, follicular lymphoma; MCL, mantle cell lymphoma; LPL, lymphoplasmacytic lymphoma; DLBCL, diffuse large B-cell lymphoma.

**Table 95.2 Distribution of various types of ocular adnexal lymphoma**

Author	Year	Patients	EMZL (%)	Follicular (%)	Mantle zone (%)	Lymphoplasmacytic (%)	Diffuse large B-cell (%)	Plasmacytoma (%)	T cell
White	1995	43	Not done						
Nakata	1999	44	77	–	4	2	14	–	–
Jenkins	2000	192	54	11	2	24	8		<1
McKelvie	2001	70	63	17	3		11		1
Shields	2001	117	Not done						
Mannami	2001	43	86	–	2	–	12	–	
Bhatia	2001	47	17	53			26		
Coupland	2003	230	59	12	3	4	13	4	3
Fung	2003	98	57	18	4		7		
Sharara	2003	17	47	12	18	6	18	–	
Cho	2003	57	98		2				
Total		958	17–98	11–53	2–18	4–24	7–26	4	1



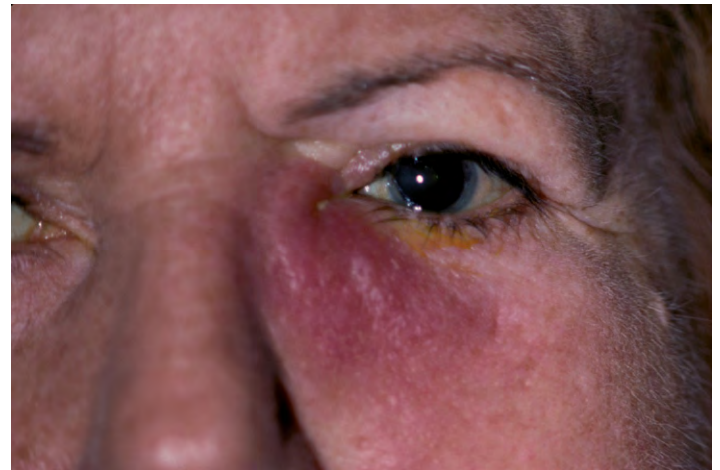
**Fig. 95.1** Conjunctival lymphoma with typical salmon color and diffuse margins (A). After radiation treatment there is complete resolution of the mass (B).

Exophthalmos and decreased retrobulbar of the globe may be the only clinical signs. Secondary ptosis may also occur. Involvement of the nasolacrimal drainage system can occur (Fig. 95.2). In rare cases, compression or invasion of the optic nerve can lead to vision loss. During orbital biopsy OAL appears as a white to pink mass, reflecting its leukocytic and vascular characteristics.

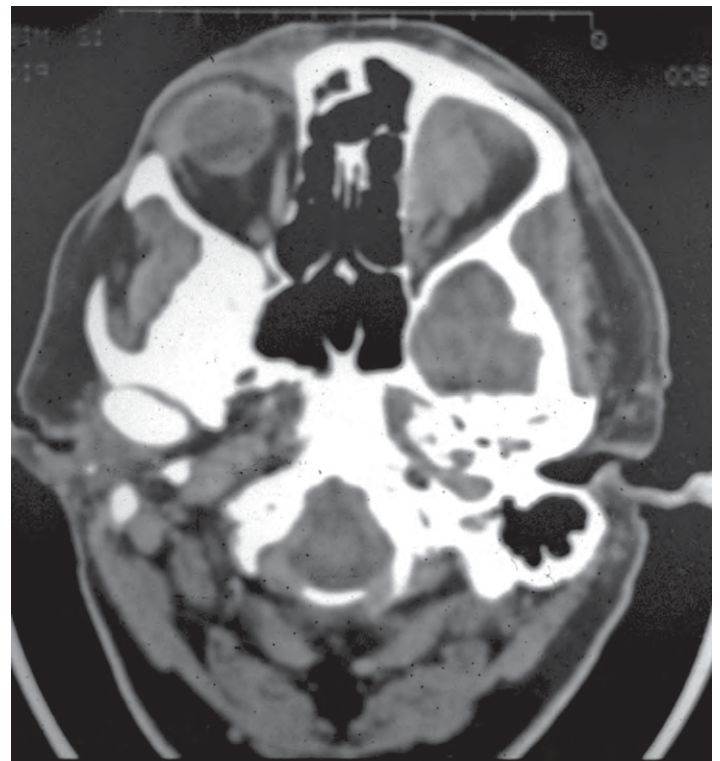
### DIAGNOSTIC EVALUATION

Evaluation of OAL involves characterization of the lesion and staging. If the lymphoid nature of the lesion is clear from the clinical features, these can be performed concurrently. Otherwise, staging follows characterization. Lesions should be obtained by open biopsy to allow sufficient material for multiple special studies that are employed: pathology, lymphocyte immunophenotypical analysis, and molecular genetic studies to identify gene rearrangements indicative of clonality and/or translocations.

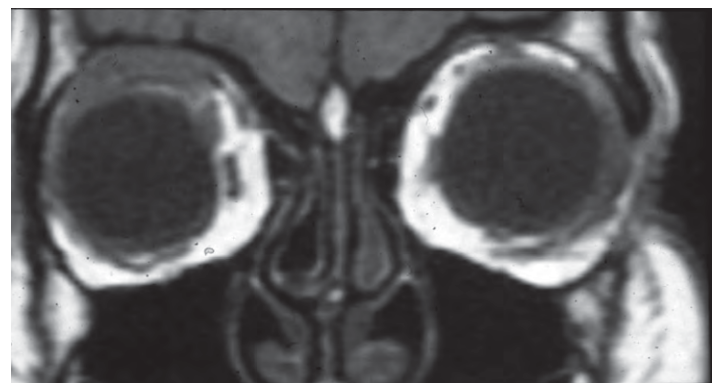
**Imaging studies** of the orbit play an important role in OAL but are performed at different times, depending on the presentation. With conjunctival disease, the lesion is frequently biopsied first and imaging of the orbit follows to assess orbital involvement. With orbital and lid disease, the orbit is usually imaged to optimize the biopsy process. Contrast-enhanced CT and MRI scans of the orbits will show enhancing lesions, which can be discrete or diffuse (Figs 95.3 and 95.4). Lymphoid lesions typically mold to structures such as the globe or



**Fig. 95.2** Clinical view of lymphoma involving the nasolacrimal sac region.



**Fig. 95.3** Axial CT scan of patient in Figure 95.2, showing a superior orbital mass with irregular margins that molds to the orbital wall.



**Fig. 95.4** Coronal MRI scan (T<sub>1</sub>-weighted image) demonstrating bilateral orbital involvement.



bony orbit. Imaging will show orbital lesions in up to 50% of lesions where they were clinically unsuspected.<sup>8</sup> Paranasal sinus involvement is not uncommon.

**Staging procedures** Because OAL can coexist with lymphoma in other sites, after OAL is classified, staging is performed. This includes a thorough physical examination by a physician familiar with the manifestations of lymphoma. Invasive staging has been replaced by the use of high-resolution contrast-enhanced imaging techniques: CT of the chest, abdomen and pelvis, and MRI of the head. Imaging of the neck is performed if cervical nodes are palpated or suspected to be enlarged. Laboratory evaluation includes a full blood count, hepatic enzymes, serum lactate dehydrogenase (LDH), and bone marrow aspiration and biopsy.

Although not typically performed by the ophthalmologist, an understanding of the staging process is important for multidisciplinary management of OAL. A modified version of the Ann Arbor Classification is still used. Tumor types are divided into indolent or high grade based on their expected clinical behavior. Indolent tumors (EMZL, FL, LPL) are divided into two stages, whereas high-grade lesions (DLBCL, MZL) are divided into three (Table 95.3). The majority of OAL is low grade and stage IE. Bilateral OAL is considered to be stage IE. Analysis of these data can be challenging because of the use of different criteria, but overall rates for initial staging are 60–80% for IE, 4–25% for IIE and 16–18% for stages III and IV combined.<sup>7,20,23</sup> Studies using criteria for extraorbital disease showed stage III/IV rates of 22–36% at diagnosis.<sup>19,24,28</sup>

## DIFFERENTIAL DIAGNOSIS

The clinical and imaging differential diagnosis of OAL is extensive, owing to the paucity of specific features. It includes benign lymphoproliferative lesions, epithelial tumors, melanocytic tumors, inflammatory lesions, infectious lesions, and lacrimal gland lesions of the conjunctiva. In the orbit and lid any mass, including metastases, dacryoadenitis, inflammations, and other benign and malignant tumors, must be considered.

## PATHOLOGIC FEATURES

Pathologic analysis can identify obvious lymphomas but cannot reliably differentiate lymphoma types (Fig. 95.5). Recent data have shown that using the current WHO classification, 76% of lesions previously

classified as RLH are now reclassified as lymphoma. This is due to the recognition that a small number of malignant lymphocytes, whose presence is indicative of lymphoma, can be overshadowed by surrounding normal or reactive lymphoid cells.

The common immunophenotypic expressions of the various types of OAL are shown in Table 95.1. IPA can be carried out qualitatively on tissue sections or quantitatively on dispersed cells (flow cytometry). The use of intact tissue allows localization of marker expression, which can be critical in making the correct diagnosis. For example, bcl-2 is a surface marker not seen in normal follicular structures. If this marker is overexpressed in a follicle, the process would be defined as a follicular lymphoma. Tissue analysis, however, may not detect such critically important cells when sampling effect limits their presence. Flow cytometry, in contrast, accurately quantifies how many cells express each marker, but does not give anatomic information.

Molecular genetic analysis of OAL is important in two ways. Identification of overexpressed heavy chain gene rearrangements is indicative of clonality and typically represents malignancy. Tumor cells can be analyzed for translocations that may be indicative of a specific lymphoma type (Table 95.4). Translocation t(11;18)(q21;q21) is of specific interest as its presence is associated with susceptibility to antibiotic therapy.

The expansion of the tools for lymphocyte characterization has paradoxically increased the chances for contradictory or incomplete characterizations using the new criteria. In such situations the wisdom of an experienced hematopathologist is critical, though some lesions will remain unclassifiable.

## TREATMENT

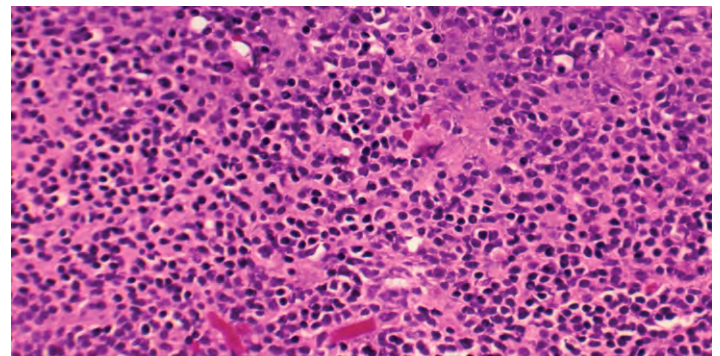
The treatment of OAL is an area of controversy, progress, and change. The established model of OAL treats it as a malignant lymphoma, typically using cytotoxic modalities. With the recognition that the vast majority of OAL are of the EMZL/MALT type, and that there may be an infectious basis for this subgroup, a possibility of deferring cytotoxic modalities has been raised. A second controversy is whether to treat very indolent OAL. A survey of treatment modalities follows.

**Surgery** has been reported to be successful in managing certain cases of OAL and has been recommended for stage I MALT systemic lymphoma in some sites. Its applicability remains dubious for most OAL

**Table 95.3 Staging of non-Hodgkin's lymphoma**

<b>Indolent lymphomas: EMZL, FL, LPL</b>	
Stage I	Localized disease (Ann Arbor [AA] I, IE & II, IIE)
Stage II	Disseminated disease (Ann Arbor [AA] III & IV)
<b>Aggressive lymphomas: DLBCL, MCL</b>	
Stage I	Localized or extranodal disease (Ann Arbor [AA] I or IE)
Stage II	Two or more nodal sites; three or more extranodal sites
Stage III	Stage II with additional poor prognostic features

E, extranodal disease.



**Fig. 95.5** Photomicrograph of monomorphic lymphocytes typical of EMZL-type ocular adnexal lymphoma. (H&E, original magnification × 100.)

**Table 95.4 Common translocations observed in ocular adnexal lymphoma**

Type	Genetic change	Mechanism	Frequency	Proto-oncogene
EMZL	t(11;18)(q21;q21)	Fusion Transcript deregulation	50% rare	API2/MLT Bcl-10
Follicular	t(14;18)(q32;q21)	Transcript deregulation	80–90%	Bcl-2
Mantle cell	t(11;14)	Transcript deregulation	70%	Bcl-1 (encodes cyclin D1)
Lympho-plasmacytic	T(9;14)(p13;q32)	Transcript deregulation	50%	PAX-5
Diffuse large B-cell lymphoma	Der(3)(q27)	Transcript deregulation		Bcl-6

because of the diffuse nature and the frequent juxtaposition of OAL to sensitive ocular tissues. Complete excision should generally be reserved for localized and isolated lesions of the conjunctiva.<sup>7,9</sup>

**Cryotherapy** Cryotherapeutic ablation has received limited use in the management of OAL. It has given variable success and has been thought to debulk but not eliminate tumor. It may have an application in patients with conjunctival OAL unable to receive other treatment modalities.<sup>9</sup>

**Radiation** Historically, external beam radiation has been the most frequently used modality for the treatment of OAL to avoid surgical complications. Analyses of this modality are confounded by small patient numbers, use of early inaccurate classification, short follow-up times, and apparent lack of ophthalmic follow-up. Complications were detected at a rate up to 50% higher when close ophthalmic follow-up was performed.

Both electron and photon irradiation have been successfully employed in OAL. Dosage is based on the tumor grade or type,<sup>19,22,24</sup> typical doses being 28–36 Gy for low-grade OAL and 30–40 Gy for high-grade OAL. The role of lens shielding to reduce the development of cataract is controversial, with some studies showing no effect on local recurrence and others showing recurrences in patients whose lenses were shielded.<sup>29,30</sup>

Analysis of the radiation dose–response relationship of EMZL revealed that 5-year local tumor control rates were 81% with doses below 30 Gy but 100% with doses higher than that.<sup>19</sup> Variable sensitivity to radiotherapy was observed, as follicular lymphoma showed a 100% response rate to both high and low doses. Whereas radiation studies frequently emphasize the ability to obtain local control, the effect of this modality on the overall course and prognosis is less clear (see Fig. 95.1B). Even stage IV-EA disease showed good local control, although survival was significantly lower. Multiple studies revealing higher rates of delayed systemic recurrence suggest that longer follow-up is necessary for accurate assessment of treatment effect.<sup>24</sup>

**Chemotherapy** Because OAL frequently presents as localized disease (stage IE), chemotherapy is rarely used unless it is DLBCL. The review of chemotherapy used in lymphoma is beyond the scope of this chapter. Standard chemotherapy for OAL when it is part of more advanced disease is that of standard systemic lymphoma regimens using cyclophosphamide, doxorubicin, vincristine and prednisone (CHOP), chlorambucil, and more recently, purine analogs fludarabine, cladribine, and pentostatin. Although some have used systemic

corticosteroids for tumor suppression in OAL, steroids offer ineffective long-term control.

### Immunotherapy

**Interferon** (IFN)- $\alpha$  has been used rarely for OAL despite its long-standing use in systemic lymphoma. One report of five cases showed 80% initial complete response with short-term follow-up.<sup>31</sup> One patient with stage IIA disease died of systemic lymphoma at 1 year. More data regarding local and systemic efficacy are needed before this modality can be accepted.

**Antilymphocyte antibody** is a recent form of lymphoma treatment. The most commonly used to date has been an antibody to CD-20, rituximab, which leads to the destruction of B cells using mechanisms of complement- and antibody-mediated destruction as well as induction of apoptosis. These antibodies are most commonly used in combination with other agents, so their solitary effect is hard to assess.<sup>32</sup> There appears to be an effect in reducing but not eliminating lymphoma.

**Antimicrobial treatment** The most exciting development in OAL management is based on the IMM model of lymphomagenesis. There is increasing evidence of a role for chronic infection in OAL. Both *C. psittaci* and *H. pylori* have been identified to date.<sup>15,16</sup> Follow-up data from the *C. psittaci* detection study suggest a therapeutic effect in half of patients using a 3-week course of doxycycline, presumably to eradicate the infection that underlies lymphomagenesis. Another study has shown effect in a few patients using the typical anti-*H. pylori* triple therapy.<sup>33</sup> The author has successfully treated RLH with doxycycline as well. Larger studies are needed to clarify the role of this therapy, and based on the model of lymphomagenesis the author has proposed a putative role for combined treatment with systemic corticosteroids to suppress the inflammatory response. Controversy does exist, as there are questions as to how antibiotic elimination of underlying infection could eradicate a genetic dysregulation, but the data from gastric lymphoma are so convincing as to suggest an important role for this treatment in the future.

### PROGNOSIS

The prognosis of OAL is evaluated in three ways: local control, systemic involvement, and death from lymphoma. Excellent local control has been reported using external beam radiation. Among OAL, EMZL has a quantitatively better prognosis than other tumor types with

regard to spread and lymphoma-related death, though the risk ratio was similar among the milder forms EMZL, LPCL, and FCL. The mortality ranges were: EMZL 0–20%, DLBCL 25–75%, FL 20–37%, MCL 38–100%, and LPL 14–100%.<sup>7,19,20,24</sup>

Extraorbital spread can occur in over 45% of EMZL patients with a mean follow-up of 63 months, suggesting that longer follow-up is needed.<sup>24</sup> Patients with indolent disease may survive decades without treatment.

## FUTURE RESEARCH

Future research will focus on the mechanisms of lymphomagenesis to determine whether prelymphomatous conditions can be detected and treated with less toxic methods. One key question is whether the role of infectious agents will be as important as in gastric lymphoma, where it has revolutionized care. Understanding lymphomagenesis may also allow for more targeted therapeutic agents.

## REFERENCES

- Shields JA, Bakewell B, Augsburger JJ et al. Classification and incidence of space-occupying lesions of the orbit: a survey of 645 biopsies. *Arch Ophthalmol* 1984; 102: 1606–1611.
- Char DH. Orbital lymphoid lesions. In: Char DH. *Clinical ocular oncology*. Philadelphia: Lippincott-Raven, 1997; 349–364.
- Henderson JW. The individual tumors. In: Henderson JW. *Orbital tumors*. New York: Raven Press, 1994; 44.
- Spraul CW, Grossniklaus HE. Analysis of 24,444 surgical specimens accessioned over 55 years in an ophthalmic pathology laboratory. *Int Ophthalmol* 1998; 21: 283–304.
- Fisher SG, Fisher RI. The epidemiology of non-Hodgkins lymphoma. *Oncogene* 2004; 23: 6254–6234.
- Knowles DM, Jakobiec FA, McNally L et al. Lymphoid hyperplasia and malignant lymphoma occurring in the ocular adnexa (orbit, conjunctiva, and eyelids): a prospective multiparametric analysis of 108 cases during 1977 to 1987. *Hum Pathol* 1990; 21: 959–973.
- Coupland SE, Hellmich M, Auw-Haedrich C et al. Prognostic value of cell-cycle markers in ocular adnexal lymphoma: an assessment of 230 cases. *Graefes Arch Clin Exp Ophthalmol* 2004; 42: 130–145.
- Stafford SL, Kozelsky TF, Garrity JA et al. Orbital lymphoma: Radiotherapy outcome and complications. *Radiother Oncol* 2001; 59: 139–144.
- Shields CL, Shields JA, Carvahlo C et al. Conjunctival lymphoid tumors: clinical analysis of 117 cases and relationship to systemic lymphoma. *Ophthalmol* 2001; 108: 979–984.
- Ye H, Liu H, Attygale A et al. Variable frequencies of t(11; 18)(q21: q21) in MALT lymphomas of different sites: significant association with CagA strains of *H. pylori* in gastric MALT lymphoma. *Blood* 2003; 102: 1012–1018.
- Raffeld M, Jaffe ES. Bcl-1, t(11; 14), and mantle cell-derived lymphomas. *Blood* 1991; 78: 259–263.
- Takada S, Yoshino T, Taniwaki M et al. Involvement of the chromosomal translocation t(11; 18) in some mucosa-associated lymphoid tissue lymphomas and diffuse large B-cell lymphomas of the ocular adnexae: evidence from multiple reverse transcriptase–polymerase chain reaction and fluorescence in situ hybridization on using formalin-fixed, paraffin embedded specimens. *Mod Pathol* 2003; 16: 445–452.
- Remstein ED, James CD, Kurtin PJ. Incidence and subtype specificity of API2-MALT1 fusion translocations in extranodal, nodal and splenic marginal zone lymphomas. *Am J Pathol* 2000; 156: 1183–1188.
- Hoover RN. Lymphoma risks in populations with altered immunity: A search for mechanism. *Cancer Res* 1992; 52: 5477.
- Ferreri AJ, Guidoboni M, De Conciliis C et al. Evidence for an association between *Chlamydia psittaci* and ocular adnexal lymphomas. *J Natl Cancer Inst* 2004; 96: 586–594.
- Chan CC, Smith JA, Shen DF et al. *Helicobacter pylori* (*H. pylori*) molecular signature in conjunctival mucosa-associated lymphoid tissue (MALT) lymphoma. *Histol Histopathol* 2004; 19: 1219–1226.
- Harris NL, Jaffe ES, Stein H et al. A revised European–American classification of lymphoid neoplasms: a proposal from the International Lymphoma Study Group. *Blood* 1994; 84: 1361–1392.
- Jaffe ES, Harris NL, Stein H, Vardiman JW (eds) *Pathology and genetics: tumours of haematopoietic and lymphoid tissues*. (WHO Classification of Tumours) Lyon, IARC Press, 2001.
- Fung CY, Tarbell NJ, Lucarelli MJ et al. Ocular adnexal lymphoma: clinical behavior of distinct World Health Organization classification subtypes. *Int J Radiat Oncol Biol Phys* 2003; 57: 1382–1391.
- McKelvie PA, McNab A, Francis IC et al. Ocular adnexal lymphoproliferative disease: a series of 73 cases. *Clin Exp Ophthalmol* 2001; 29: 387–393.
- Mannami T, Yoshino T, Oshima K et al. Clinical, histopathological, and immunogenetic analysis of ocular adnexal lymphoproliferative disorders: characterization of malt lymphoma and reactive lymphoid hyperplasia. *Mod Pathol* 2001; 14: 641–649.
- Bhatia S, Paulino AC, Buatti JM et al. Curative radiotherapy for primary orbital lymphoma. *Int J Radiat Oncol Biol Phys* 2002; 54: 818–823.
- Sharara N, Holden JT, Wojno TH et al. Ocular adnexal lymphoid proliferations: Clinical, histologic, flow cytometric, and molecular analysis of forty-three cases. *Ophthalmology* 2003; 110: 1245–1254.
- Jenkins C, Rose GE, Bunce C et al. Histological features of ocular adnexal lymphoma (REAL classification) and their association with patient morbidity and survival. *Br J Ophthalmol* 2000; 84: 907–913.
- Nakata M, Matsuo Y, Katsuma N et al. Histology according to the Revised European American Lymphoma Classification significantly predicts the prognosis of ocular adnexal lymphoma. *Leuk Lymphoma* 1999; 32: 533–543.
- White VA, Gascoyne RD, McNeil BK et al. Histopathologic findings and frequency of clonality detected by the polymerase chain reaction in ocular adnexal lymphoproliferative lesions. *Mod Pathol* 1996; 9: 1052–1061.
- Cho EY, Han JJ, Ree HJ et al. Clinicopathologic analysis of ocular adnexal lymphomas: extranodal marginal zone B-cell lymphoma constitutes the vast majority of ocular lymphomas among Koreans and affects younger patients. *Am J Hematol* 2003; 73: 87–96.
- Auw-Haedrich C, Coupland SE, Kapp A et al. Long term outcome of ocular adnexal lymphoma subtyped according to the REAL classification. Revised European and American Lymphoma. *Br J Ophthalmol* 2001; 85: 63–69.
- Le QT, Eulau SM, George TI et al. Primary radiotherapy for localized orbital MALT lymphoma. *Int J Radiat Oncol Biol Phys* 2002; 52: 657–663.
- Uno T, Isobe K, Shikama N et al. Radiotherapy for extranodal, marginal zone, B-cell lymphoma of mucosa-associated lymphoid tissue originating in the ocular adnexa: a multi-institutional, retrospective review of 50 patients. *Cancer* 2003; 98: 865–871.
- Blasi MA, Gherlinzoni F, Calvisi G et al. Local chemotherapy interferon- $\alpha$  for conjunctival mucosa-associated lymphoid tissue lymphoma. *Ophthalmology* 2001; 108: 559–562.
- Sullivan TJ, Grimes D, Bunce I. Monoclonal antibody treatment of orbital lymphoma. *Ophth Plast Reconstr Surg* 2004; 20: 103–106.
- Abramson DH, Rollins I, Coleman M. Periocular mucosa-associated low grade lymphomas: treatment with antibiotics. *Am J Ophthalmol* 2005; 140: 729–730.



# Malignant tumors of the orbit

Bhupendra C. K. Patel

## INTRODUCTION

Malignant orbital tumors represent a broad spectrum of tumors which includes primary, secondary (extension from adjacent structures) and metastatic tumors (Chapter 86). In addition, orbital inflammation and infection may clinically simulate an orbital neoplasm (Chapter 89). In a recent survey of 1264 consecutive patients with suspected orbital tumor referred to an ophthalmic oncology center, 36% were malignant.<sup>1</sup> The percentage of malignant tumors increases with age, owing to the higher incidence of lymphoma and metastasis in the older age groups.<sup>1</sup>

Malignant tumors of vascular (Chapter 90), neural (Chapter 92), fibrocytic, and osseous origin are rare in the orbit. Rhabdomyosarcoma is the most frequent primary malignant orbital tumor in children (Chapter 97), and lymphoproliferative disorders including lymphoma are most frequent in older adults (Chapter 95). Malignant orbital tumors may also arise from the lacrimal gland (Chapter 93) and lacrimal sac (Chapter 94). The details of clinical examination (Chapter 84), clinical evaluation (Chapter 87 and Chapter 88), and imaging techniques (Chapter 85) supplement the contents of this chapter. Malignant orbital tumors not covered under other chapters are reviewed herein.

## ESTHESIONEUROBLASTOMA

Esthesioneuroblastoma is a tumor of neural crest origin that arises from the sensory olfactory epithelium and can invade the cribriform plate, the ethmoid sinuses, and the orbit. Most esthesioneuroblastomas seen in the orbit have invaded the orbit secondarily.<sup>2</sup> Approximately 25% of newly diagnosed esthesioneuroblastomas will present with orbital extension. The peak incidence is in the second to third decades. They are frequently mistaken for other small cell tumors.

**Clinical features** When the tumor is confined to the nasal cavity or paranasal sinus, patients will have nasal obstruction, bloody nasal discharge, and headache. Three-quarters of patients with olfactory esthesioneuroblastoma have ophthalmic symptoms, such as periorbital pain, epiphora, reduced vision, and diplopia. The most common ophthalmic signs include eyelid edema and proptosis. Ptosis and cranial nerve palsies may also be present.

**Diagnostic evaluation** CT scans shows an isodense homogeneous tumor in the nasal cavity and ethmoid sinus, often with orbital extension.<sup>3</sup> Esthesioneuroblastomas are classified according to their location: Group A tumors are confined to the nasal cavity; Group B tumors

affect the nasal cavity and one or more paranasal sinuses; and Group C tumors extend into the cranium or orbit.

**Treatment** The prognosis is best for group A (75% survival at 5 years) and worst for Group C (less than 45% survival at 5 years). Treatment consists of aggressive craniofacial resection with adjunctive radiotherapy and chemotherapy. Esthesioneuroblastoma is characterized by extended remissions and multiple recurrences.

## MALIGNANT PERIPHERAL NERVE SHEATH TUMOR

This rare tumor may develop *de novo*, following radiotherapy, or secondary to plexiform neurofibroma. About 50% of malignant peripheral nerve sheath tumors are associated with neurofibromatosis.<sup>4</sup>

**Clinical features** These tumors are seen in the fourth and fifth decades, except in patients with neurofibromatosis, when it occurs in the teens. Patients present with proptosis and globe displacement. Periorbital pain, hypoesthesia, ptosis, and visual loss frequently occur.

**Diagnostic evaluation** CT imaging shows an irregular, nodular, poorly defined mass. There may be bone destruction or enlargement of the superior orbital fissure. The supraorbital nerve is more commonly affected. T<sub>1</sub>-weighted MRI shows a heterogeneous signal isointense with muscle and hypointense to fat. T<sub>2</sub>-weighted sequences show a signal that is hyperintense to both muscle and fat.<sup>5</sup> Ultrasound may show cystic spaces within the tumor. Histopathologically, the tumors can resemble fibrosarcomas with long fascicles of spindle cells forming a herringbone pattern. Immunostaining for S100 protein, Leu-7, and myelin basic protein confirms nerve sheath differentiation.

**Treatment** In cases of orbital involvement, exenteration is often needed. Ancillary chemotherapy and radiotherapy have been used but do not appear to improve survival. Recurrences are typical and often grow rapidly. Sometimes, recurrences are seen after many years. Most patients with orbital disease develop intracranial extension or pulmonary metastases.<sup>6</sup>

## ALVEOLAR SOFT PART SARCOMA

This is a rare tumor, believed to be of myogenic origin.<sup>7</sup> It occurs mostly in the lower extremities and buttocks. The head and neck region is the site of primary tumor in only 10% of cases. The mean

age at presentation is 20–30 years. Females are affected three times more frequently than males.

**Clinical features** Proptosis and globe displacement develop rapidly over 4–6 months. Apical tumors cause visual loss, orbital congestion, and ocular motility disturbances. Sensory nerve involvement causes pain.<sup>8</sup> Anterior masses may present as eyelid lumps with dilated epibulbar vessels.

**Diagnostic evaluation** CT imaging shows a moderately well-defined mass, usually involving the superior orbit, with marked contrast enhancement owing to tumor hypervascularity. Tumor necrosis results in a central area of low attenuation. Histopathology shows large, round, or polygonal cells with large nuclei and prominent nucleoli.

**Treatment** Wide surgical resection is mandatory. For recurrences or large tumors, orbital exenteration is necessary. The role of chemotherapy and radiotherapy has not been definitively determined.<sup>9</sup> Tumors localized to the orbit carry a better prognosis than alveolar soft part sarcoma developing in the lower extremities and buttocks. The tumor-related mortality is about 15% over 10 years for orbital alveolar soft part sarcoma.

## OSTEOSARCOMA

Osteosarcoma, also called osteogenic sarcoma, is the most common primary malignant neoplasm of bone. Most cases arise de novo but may be secondary to Paget's disease, fibrous dysplasia, radiation therapy, giant cell tumor, or osteoblastoma.<sup>10</sup> Osteosarcoma is also seen as a second tumor in patients with familial retinoblastoma, even in the absence of a history of radiotherapy.<sup>11</sup> Although it may affect any of the orbital bones, the maxillary bone is the most frequent orbital site of the tumor.

**Clinical features** Most patients present with chronic symptoms, of at least several months' to a year's duration. Presentations include proptosis, dyesthesias, and diplopia. However, patients may present with rapid-onset painful proptosis and sudden decrease in vision.

**Diagnostic evaluation** CT imaging shows a mixed lytic and sclerotic mass with indistinct margins. The appearance depends on the predominance of osseous, cartilaginous or fibrous tissue components. Bone destruction and calcification with new bone formation often occurs.

**Treatment** of osteosarcoma involves preoperative chemotherapy, resection, and continuation of the chemotherapy. Radiotherapy may be used as an adjunctive treatment for residual tumor. The prognosis of osteosarcoma involving the orbital bones remains poor. It is rare for a patient to survive 5 years following treatment.

## MALIGNANT FIBROUS HISTIOCYTOMA

Fibrous histiocytoma is the most common mesenchymal orbital tumor in adults, seen most commonly in the middle-aged (Chapter 91).<sup>12</sup> They may be benign, locally aggressive, or malignant (Chapter 28). Patients present with proptosis, a mass effect, reduced vision, double vision, pain, eyelid swelling, and ptosis (Fig. 96.1). Malignant fibrous histiocytoma or myxofibrosarcoma may arise de novo or follow orbital radiotherapy, especially in children with the germline mutation of

retinoblastoma (Chapter 71). Malignant fibrous histiocytoma requires exenteration. Although metastases are rare, the tumor shows local infiltrative features with a tendency to local recurrence.

## LEIOMYOSARCOMA

Leiomyosarcomas are usually seen as radiation-induced tumors following orbital irradiation in children. They arise from the smooth muscle in blood vessels, Müller's muscle, and from smooth muscle precursor cells decades after the radiation.<sup>13,14</sup>

**Clinical features** Patients present with progressive painless proptosis. The duration of symptoms varies from 6 weeks to 18 months. Globe proptosis and displacement are seen. Patients develop motility disturbance and visual loss. Anterior lesions may be palpable as a firm mass.<sup>15</sup>

**Diagnostic evaluation** A heterogeneously dense, well-defined, lobulated mass is seen within the orbit on CT scans. The borders may mold around the globe. Destruction of the adjacent bone may be seen. Histopathology may show well-differentiated or poorly differentiated tumors with multinucleated giant cells.<sup>16</sup>

**Treatment** Most cases require aggressive resection with extended orbital exenteration, including adjacent bones. Local or small tumors may be treated with local resection and adjunctive radiotherapy. Systemic metastases require chemotherapy. Local resection alone is associated with 60% local recurrence within 3 years. Most patients progress to develop metastases to the lungs, liver, kidney, and brain.

## LIPOSARCOMA

Liposarcoma is a common soft tissue sarcoma in adults but it rarely arises within the orbit.<sup>17</sup> Very rarely, liposarcoma may metastasize to the orbit.<sup>18</sup>

**Clinical features** There are no specific clinical features diagnostic of liposarcoma. In a series of five cases, diplopia and proptosis were most frequent clinical findings (Fig. 96.2).<sup>19</sup>

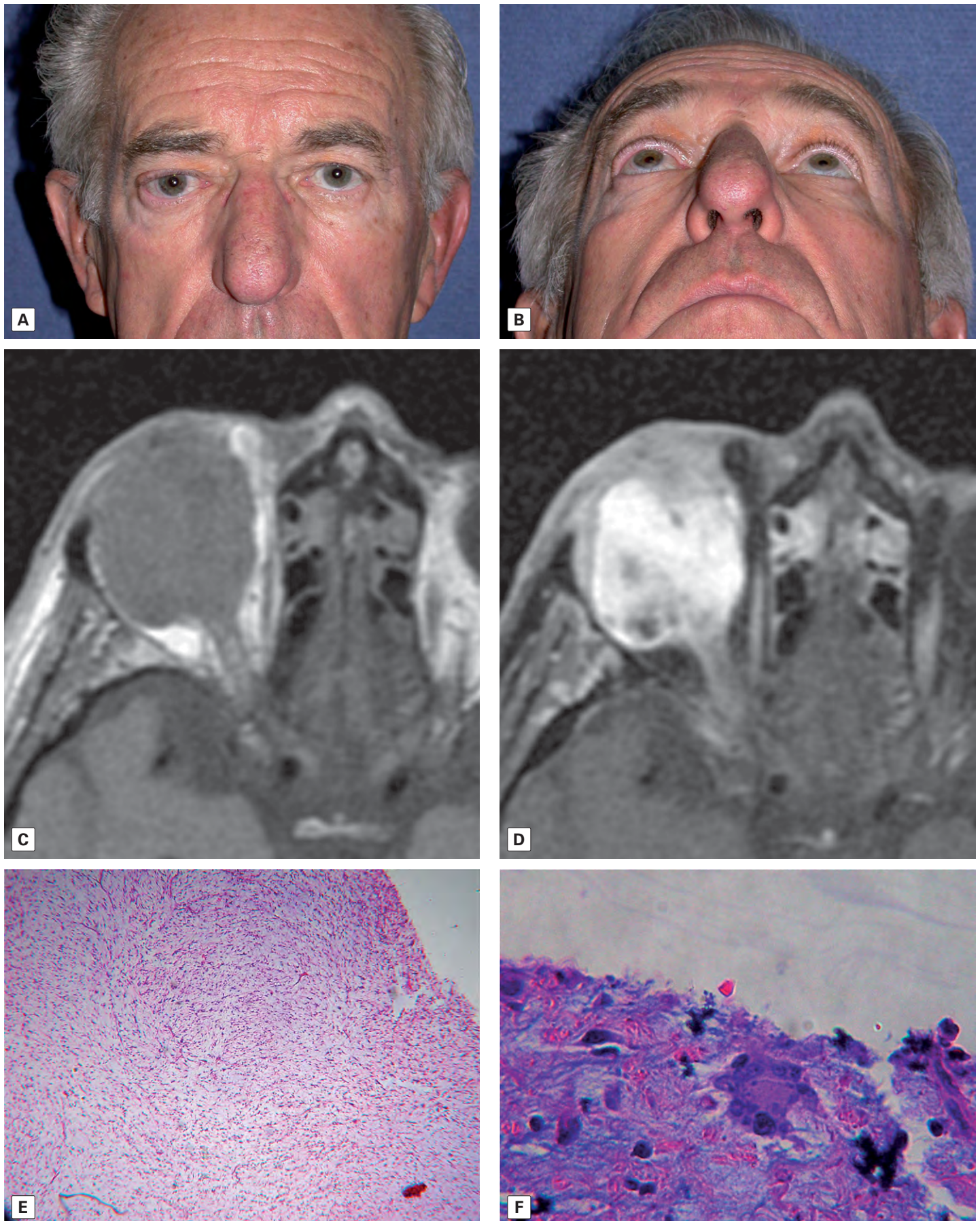
**Diagnostic evaluation** The CT scan appearance of fat density enclosed by a radiodense pseudocapsule can lead to an initial impression of a cyst.<sup>19</sup> MRI will confirm the presence of fat within the lesion (hyperintense signals on T<sub>1</sub>-weighted images).<sup>19</sup> Liposarcoma should be considered in the differential diagnosis of any unusual mesenchymal tumor in the orbit.<sup>17</sup>

**Treatment** Limited resection followed by radiation may be adequate in well-differentiated tumors without invasion into orbital structures.<sup>20</sup> In some cases, despite exenteration and radiation delayed local recurrence has been observed.<sup>21</sup> Regional or distant metastases are uncommon.<sup>19</sup>

## SECONDARY ORBITAL TUMORS

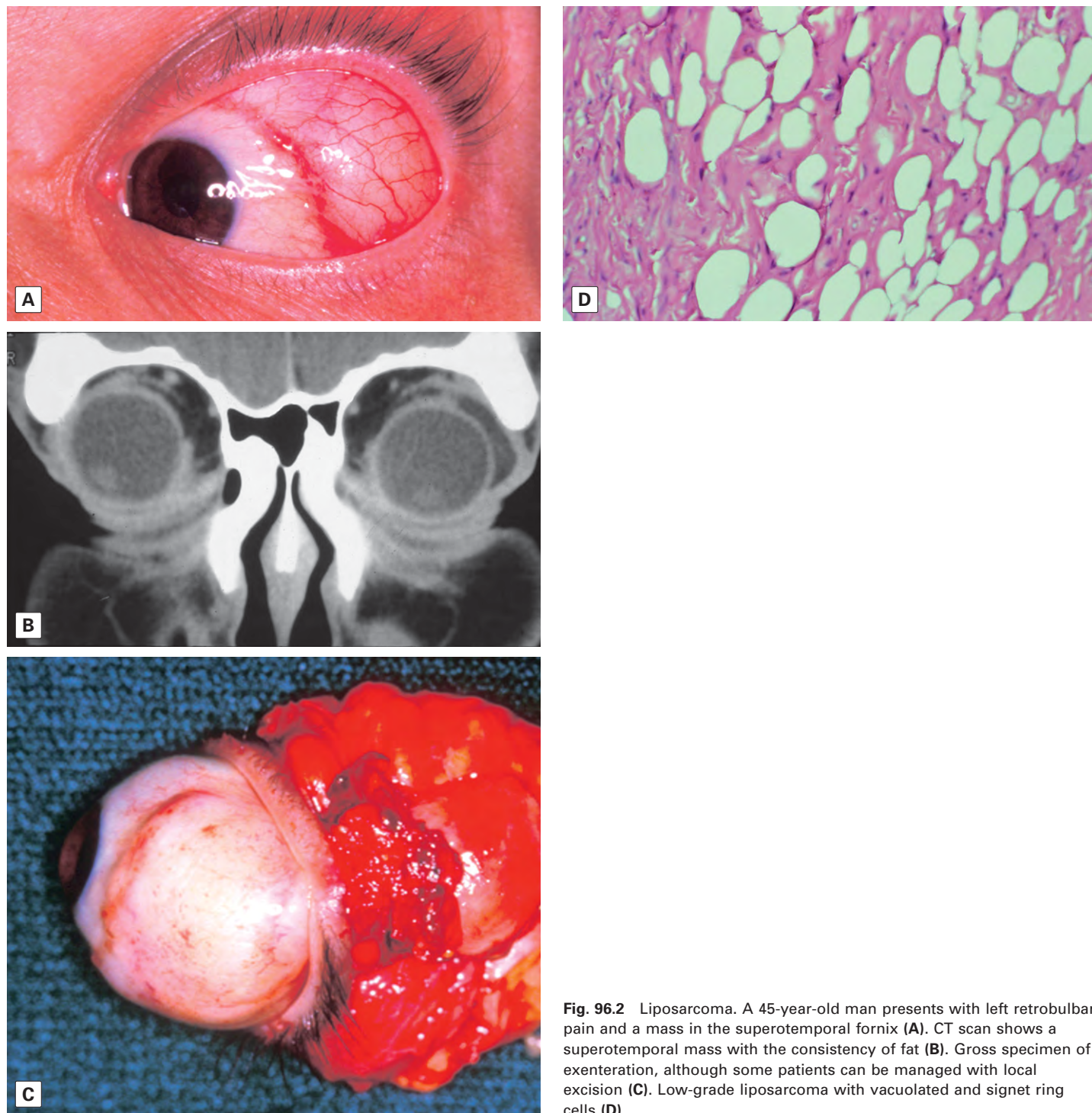
Secondary orbital tumors represent contiguous orbital extension of a primary ocular, conjunctival, eyelid, sinus, or intracranial tumor. Basal cell, squamous cell, melanoma, and sebaceous cell carcinoma of the eyelid may secondarily invade the orbit because of late presentation, incomplete excision (sebaceous cell carcinoma), rapid and





**Fig. 96.1** Malignant histiocytoma or myxofibrosarcoma. A 75-year-old man with onset of double vision over 2 months and limitation of ocular movements in all fields of gaze. Note hypoglobus (A) and proptosis (B) on the right side. MRI shows a right superior orbital mass (C), which enhances irregularly with gadolinium (D). On histopathology, storiform or cartwheel-like growth pattern is seen (E). Note Touton giant cell (F). Exenteration was performed and the patient is recurrence free at 4 years.





**Fig. 96.2** Liposarcoma. A 45-year-old man presents with left retrobulbar pain and a mass in the superotemporal fornix (A). CT scan shows a superotemporal mass with the consistency of fat (B). Gross specimen of exenteration, although some patients can be managed with local excision (C). Low-grade liposarcoma with vacuolated and signet ring cells (D).

aggressive growth, or perineural spread (squamous cell carcinoma and melanoma).

### Clinical features

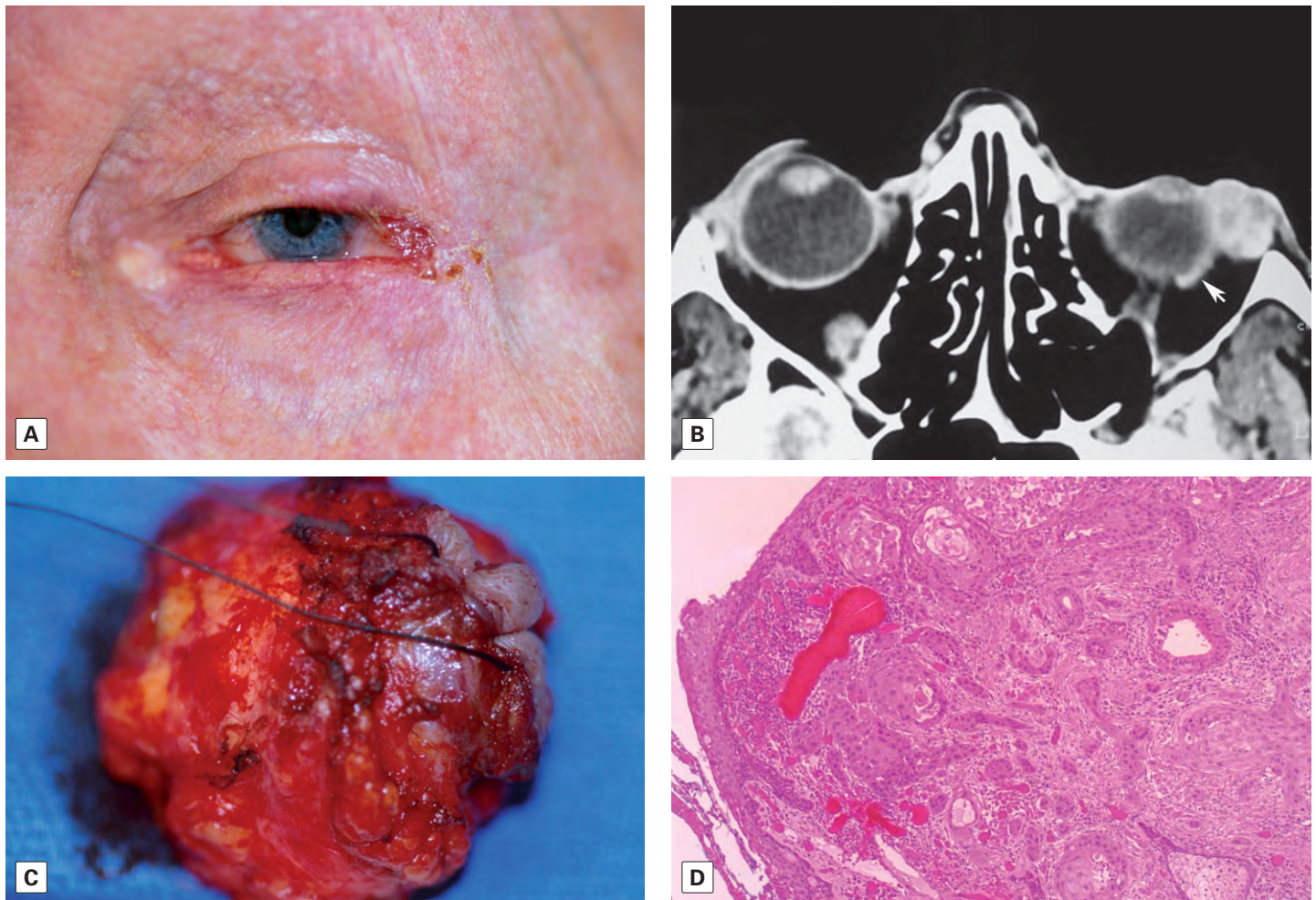
**Basal cell carcinoma** invasion of the orbit is most often seen medially with extraocular muscle restriction and fixation of the tumor to the adjacent bone.<sup>22</sup>

**Squamous cell carcinoma** tends to spread along fascia and fatty planes relatively rapidly compared to basal cell carcinoma (Fig. 96.3). Perineural invasion may occur and is associated with pain or

ophthalmoplegia.<sup>23</sup> Squamous cell carcinoma is capable of metastasis to regional preauricular or submandibular lymph nodes. Squamous cell carcinoma of the conjunctiva may also invade the orbit.

**Melanoma** Multiple recurrences of conjunctival melanoma associated with primary acquired melanosis (Chapter 27) may lead to orbital extension.

**Sebaceous carcinoma** is more prevalent in Asian populations. About one-third of epithelial malignancies invading the orbit are sebaceous carcinoma. This tumor tends to spread to the



**Fig. 96.3** Extension of squamous cell carcinoma into the orbit. A 71-year-old man with a 5-year history of multiple resections of left lower lid squamous cell carcinoma (A). CT scan shows an irregular but lobulated, well-defined density involving the tissues anterior to the orbital septum and extending into the retroseptal space (arrow) (B). Moh's resection was attempted but the deep tumor could not be removed, necessitating exenteration (C). On histopathology, islands of squamous cells with dyskeratosis and keratin whorls were observed (D).

lymphatic system and subsequently to the lung, liver, brain, or skull.

**Merkel cell carcinoma** is an eyelid neoplasm that may arise in the eyelid or periocular region (Chapter 20). It demonstrates rapid growth with a bulging, red appearance and overlying telangiectatic vessels in the elderly (Fig. 96.4). The diagnosis is confirmed by the characteristic immunocytochemical and electron microscopic features. The tumor is associated with local recurrence and satellite lesions, regional nodal metastases, and distant metastases in about half of patients. Orbital invasion is associated with tumor recurrence and may lead to intracranial spread.

**Diagnostic evaluation** Careful assessment of extraocular muscle function is necessary in patients with periocular malignancies. Medial spread of a tumor will often present with restriction of gaze followed by double vision. CT scans will reveal an irregular, often lobulated, well-defined mass extending from the preseptal to the postseptal space. Spread down the nasolacrimal duct and along the extraocular muscles may be seen.

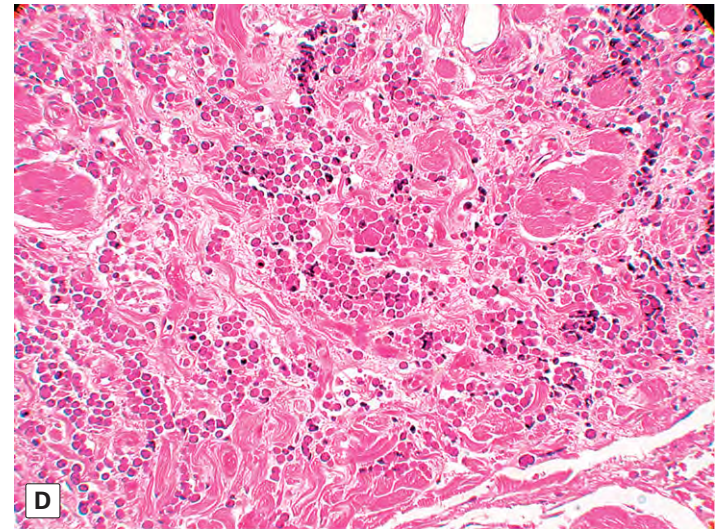
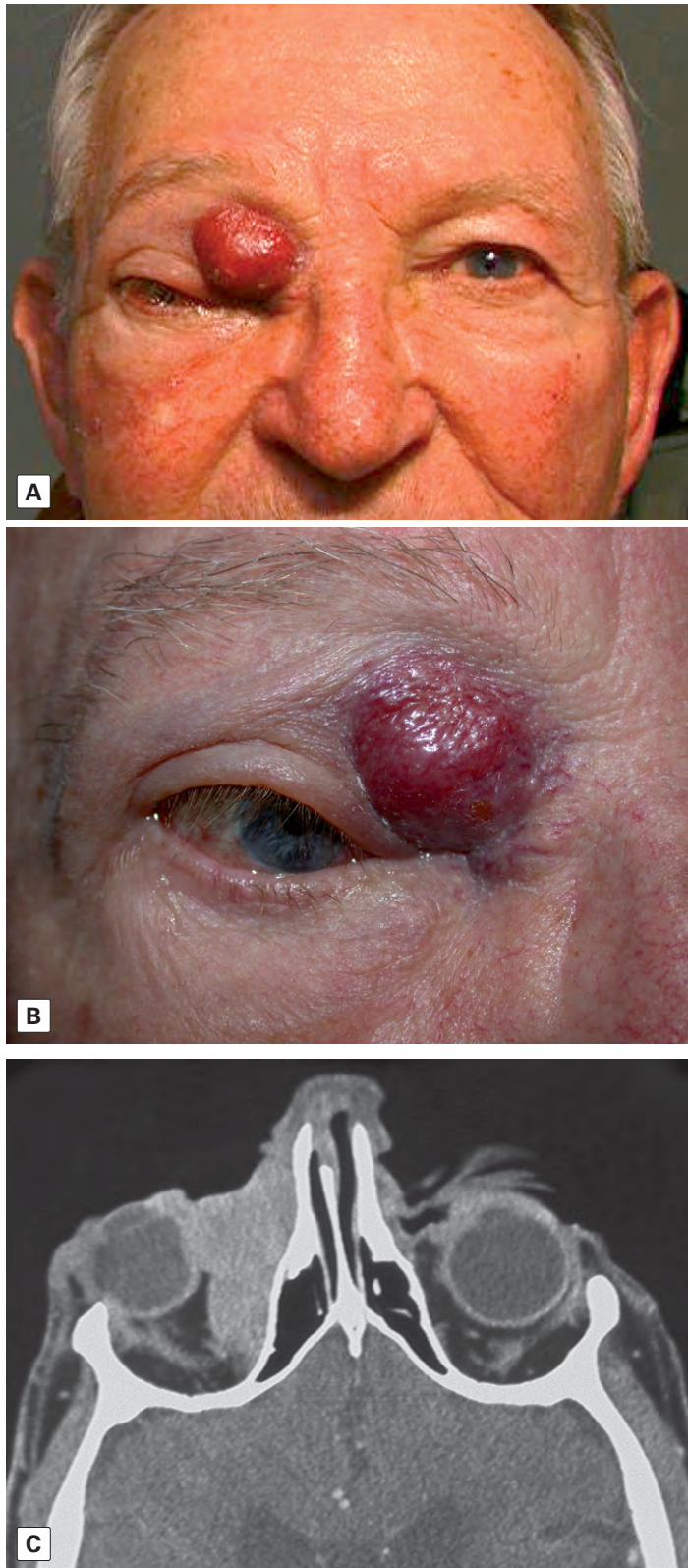
**Treatment** For orbital basal cell carcinoma, a globe-sparing resection may be attempted. However, the more aggressive basal cell carcinomas and squamous cell carcinomas may require aggressive resection with free borders, and may need an exenteration.

Sebaceous carcinomas need radical resection and lymph node dissection. Radiotherapy may control local disease if the patient is unable to undergo surgery. When conjunctival malignant melanoma spreads into the orbit, exenteration with nodal resection may be required. Treatment of Merkel cell carcinoma consists of aggressive surgical excision with wide margins and postoperative radiotherapy.

### ORBITAL METASTASES: ADULTS

Approximately 8% of all orbital neoplasms are metastatic in origin. Breast cancer, lung cancer, prostate cancer, and melanoma are the most frequent primary tumors in adults that metastasize to the orbit (Fig. 96.5). In approximately 10% of cases the primary tumor remains unidentified. In the majority of cases (75%) a diagnosis of pre-existing primary tumor is known, but in about 25% of cases the orbital tumor is the first presentation (Fig. 96.6).<sup>24</sup>



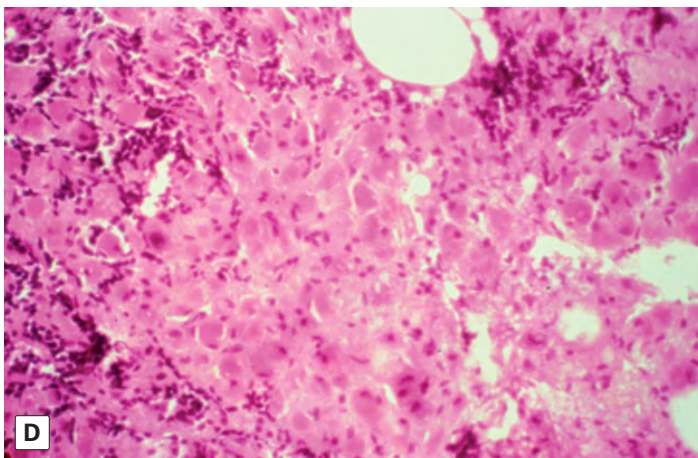
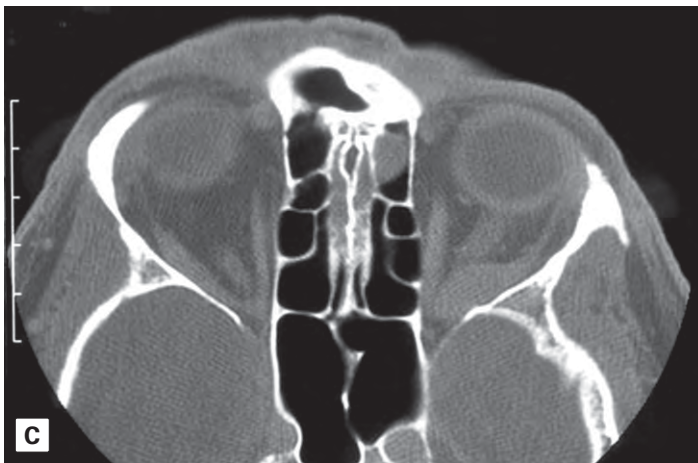
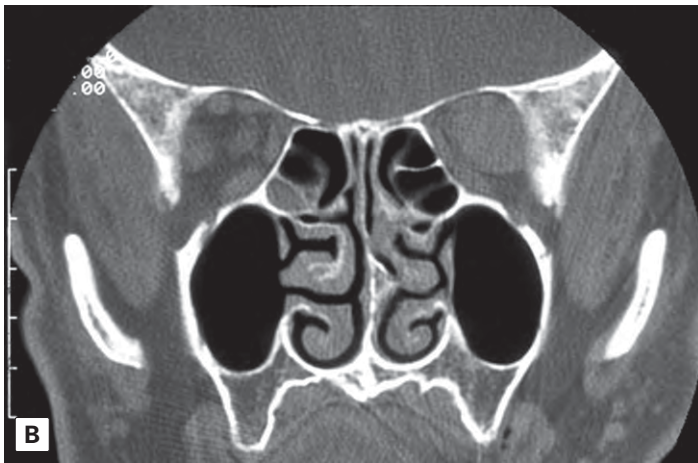
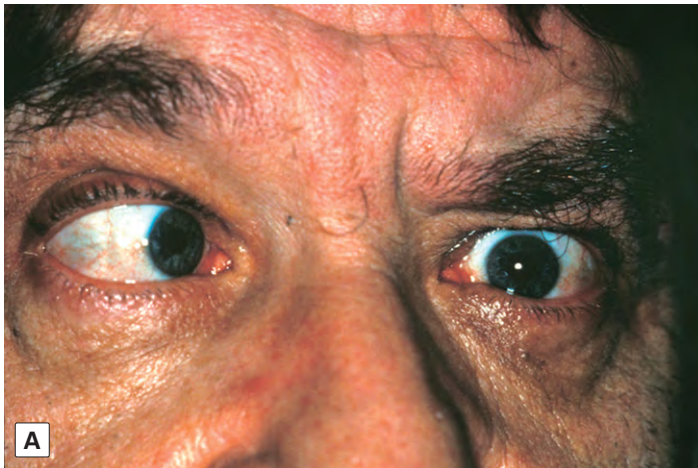**Fig. 96.4** Merkel cell carcinoma. A 78-year-old man with a right medial canthal lesion initially biopsied elsewhere and diagnosed as basal cell carcinoma (A). He was referred after 'recurrence.' Note typical budding reddish lesion with overlying vascularity (B). CT scan showed diffuse tumor with orbital invasion but without bone involvement (C). Note relatively large cells with uniformly staining eosinophilic cytoplasm (D).

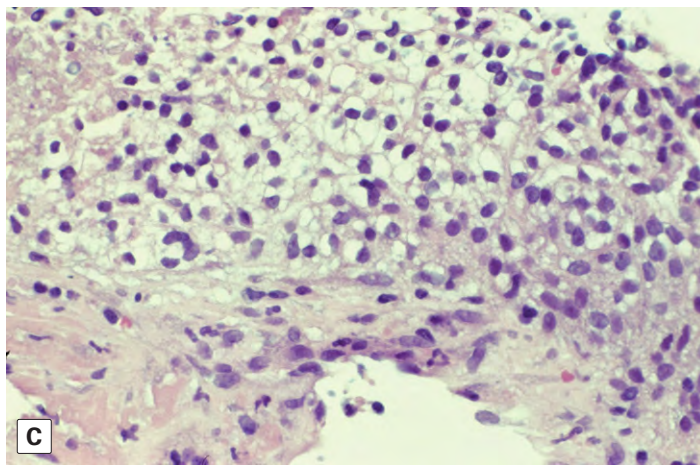
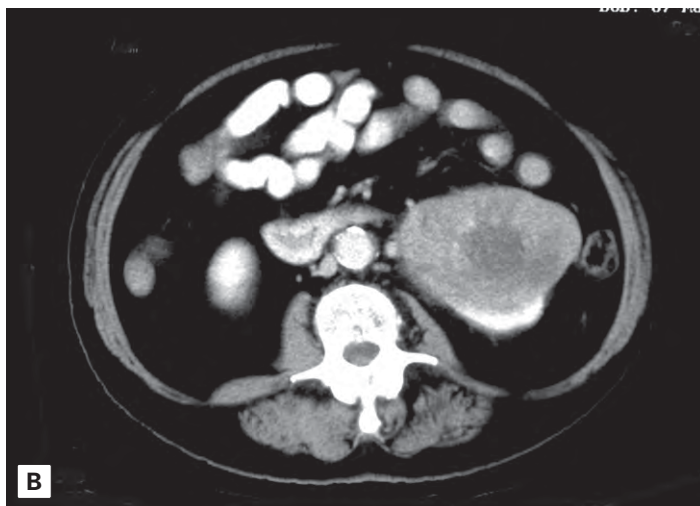
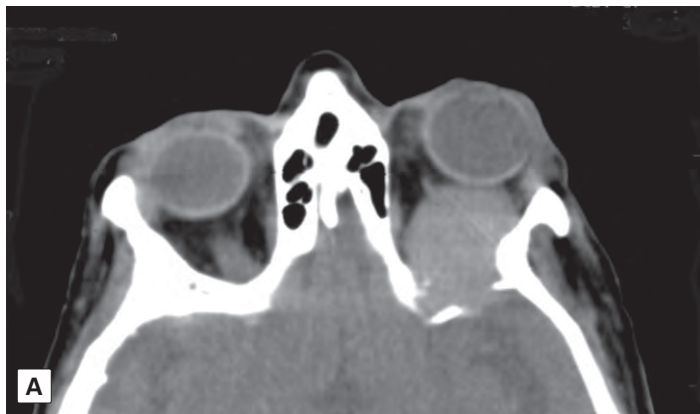
**Clinical features** Patients have more rapid onset of symptoms than with other types of orbital neoplasia. Proptosis and motility disturbances are the most common presenting symptoms and signs. Pain is noted early in the course of the disease. Other symptoms and signs include a palpable mass, blepharoptosis, and reduced

vision. Enophthalmos is present in 10% of cases (most being metastasis from breast cancer). Clinical presentation of orbital metastatic disease can be categorized into mass effect, infiltrative (causing diplopia, enophthalmos), functional (neurological deficits), inflammatory (pain, chemosis, swelling), or silent (discovered





**Fig. 96.5** Metastatic lung carcinoma. A 55-year-old male smoker presented with marked limitation of left eye abduction, slight left enophthalmos, and reduction of vision to counting fingers in the left eye (A). Coronal (B) and axial (C) CT scans show a homogeneous posterior lateral rectus mass with compression of the optic nerve. Muscle is infiltrated with mixed small cell/large cell malignant cells with minimal cytoplasm and hyperchromatic nuclei (D).



**Fig. 96.6** Metastatic renal carcinoma. A 63-year-old woman presented with proptosis, diplopia, and reduced vision in the left eye. Axial CT scan shows a circumscribed homogenous orbital mass with bone destruction (A). Evaluation for primary tumor revealed a large mass replacing the right kidney (B). Fine needle aspiration biopsy of the kidney confirmed a clear cell renal carcinoma (C).

on imaging or at surgery with no symptoms or signs) (Table 96.1).<sup>25</sup>

**Diagnostic evaluation** CT imaging may show a mass, bony changes (hyperostosis-prostate or hypostatic-thyroid), enlargement of muscle, or diffuse orbital tissue enlargement. Open orbital biopsy or needle biopsy confirms the diagnosis.

**Table 96.1** Clinical features of orbital metastases

Category	Feature
Mass effect	Visible or palpable mass
Infiltrative	Diplopia, exophthalmos, enophthalmos
Functional	Neurological deficits
Inflammatory	Pain, chemosis, swelling
Silent	Discovered on imaging or at surgery with no symptoms or signs

(Modified with permission from Goldberg RA, Rootman J. Clinical characteristics of metastatic orbital tumors. *Ophthalmology* 1990; 97: 620–624)

**Treatment** may include radiotherapy, hormonal therapy, chemotherapy, or surgery. In some patients control of local disease may limit progressive orbital pain, corneal exposure, and vision loss.

### ORBITAL METASTASES: CHILDREN

Neuroblastoma, Ewing's sarcoma, Wilms' tumor, testicular embryonal sarcoma, ovarian sarcoma, and renal embryonal sarcoma may cause metastases to the orbit in children.

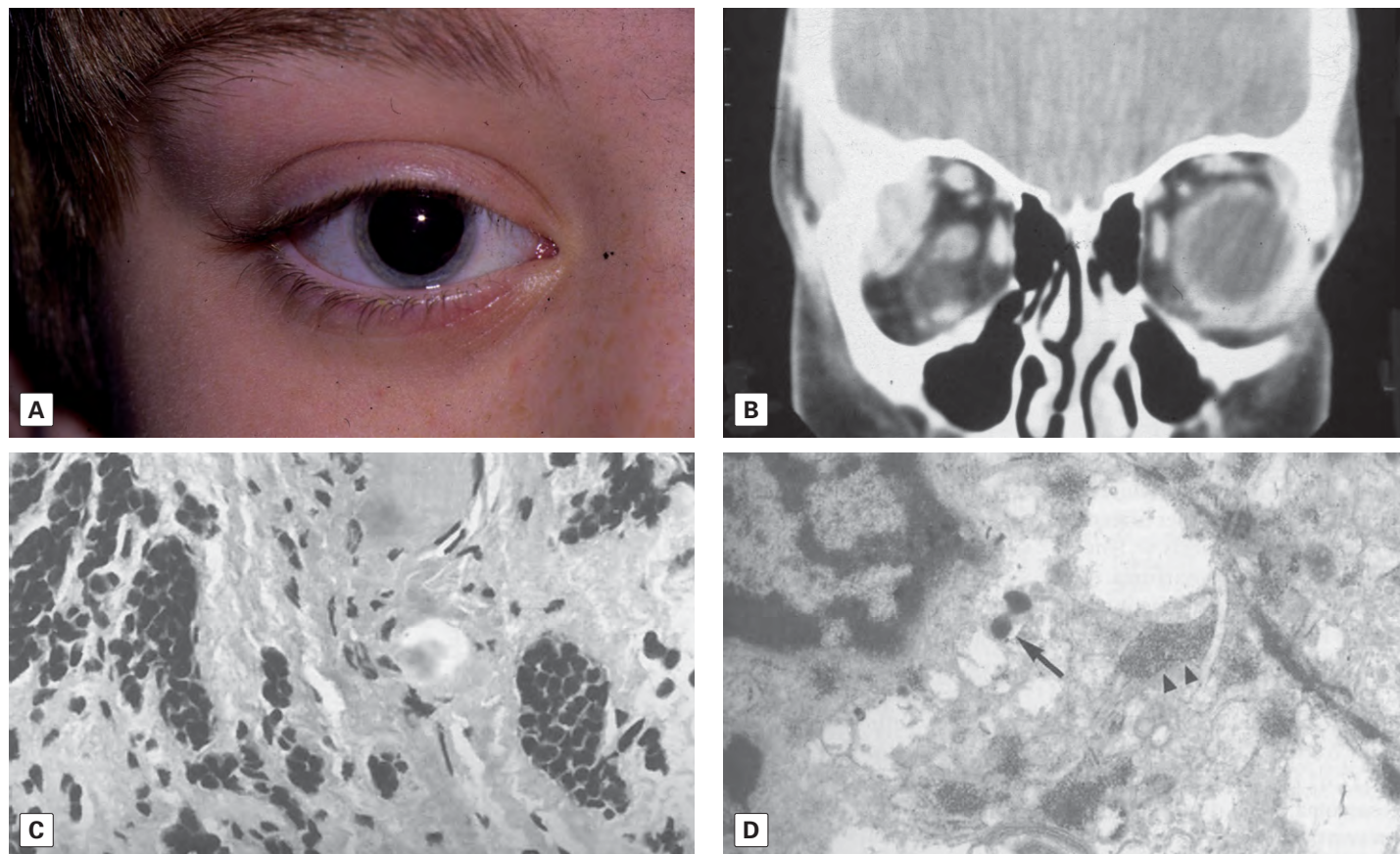
**Neuroblastoma** is the second most common orbital malignancy of childhood after rhabdomyosarcoma. Neuroblastoma arises from embryonic neural crest tissue of the postganglionic sympathetic nervous system. The most common site for the primary tumor is in the abdomen, but the thorax, neck, or pelvis may also be affected. The tumor presents any time in the first two decades, although the vast majority present before the age of 3 years.<sup>26</sup>

There is sudden and rapid progression of proptosis, which may be unilateral or bilateral and accompanied by edema, ecchymosis, and ptosis. The differential diagnosis includes orbital cellulites, rhabdomyosarcoma, Ewing's sarcoma, medulloblastoma, Wilms' tumor, and lymphangioma. The superolateral orbit is most commonly involved.

There is a combination of bone and soft tissue involvement. There may be evidence of bone destruction or other cranial metastases. The patient may have Horner's syndrome, opsoclonus, myoclonus, and metastases to the iris or choroids. Aggressive combination chemotherapy and total body irradiation are used, but the prognosis remains poor.

**Ewing's sarcoma** is a highly malignant, small, round cell tumor of primitive mesenchymal cells in the bone marrow. These tumors may present as metastatic tumors or primary soft tissue orbital tumors.<sup>27</sup> Primitive neuroectodermal tumor of the orbit closely resembles Ewing's sarcoma (Fig. 96.7).<sup>28</sup> The maxilla and the mandible are more commonly affected than the orbit. This tumor usually presents in the second decade of life. Orbital tumors present with rapidly progressing proptosis with or without orbital hemorrhage. The involved bone has a moth-eaten appearance. Treatment includes radiotherapy and chemotherapy along with local resection. These tumors are quite radio-sensitive. The 5-year survival rate is 80% with surgery, radiation, and chemotherapy. Second primary osteogenic sarcoma may occur, so long-term follow-up is necessary.





**Fig. 96.7** Primitve neuroectodermal tumor. A 10-year-old girl with proptosis of the right eye and slight swelling of the lateral portion of the right upper eyelid of 3 weeks' duration (**A**). Coronal contrast-enhanced CT scan shows a solid extraconal mass in the superolateral aspect of the orbit. Note secondary bone destruction and hyperostosis (**B**). Histopathologic examination demonstrated nesting of small cells with a high nuclear/cytoplasmic ratio separated by a fibrous stroma (**C**). Neurosecretory granules (arrow) and cytoplasmic glycogen (arrowheads) were observed by electron microscopy (**D**). These findings, taken together with immunohistochemistry staining pattern, confirmed a diagnosis of primitve neuroectodermal tumor of the orbit. (Reproduced with permission from Singh AD, Husson M, Shields CL, De Potter P, Shields JA. Primitve neuroectodermal tumor of the orbit. *Arch Ophthalmol* 1994; 112: 217–221.)

## REFERENCES

- Shields JA, Shields CL, Scartozzi R. Survey of 1264 patients with orbital tumors and simulating lesions: The 2002 Montgomery Lecture, part 1. *Ophthalmology* 2004; 111: 997–1008.
- Laforest C, Selva D, Crompton J, Leibovitch I. Orbital invasion by esthesioneuroblastoma. *Ophthalm Plast Reconstr Surg* 2005; 21: 435–440.
- Loevner LA, Sonners AI. Imaging of neoplasms of the paranasal sinuses. *Magn Reson Imag Clin N Am* 2002; 10: 467–493.
- Lyons CJ, McNab AA, Garner A, Wright JE. Orbital malignant peripheral nerve sheath tumors. *Br J Ophthalmol* 1989; 73: 731–738.
- Bhargava R, Parham DM, Lasater OE et al. MR differentiation of benign and malignant peripheral nerve sheath tumors: use of the target sign. *Pediatr Radiol* 1997; 27: 124–129.
- Erzurum SA, Melen O, Lissner G et al. Orbital malignant peripheral nerve sheath tumors. Treatment with surgical resection and radiation therapy. *J Clin Neuro-Ophthalmol* 1993; 13: 1–7.
- Ordenez NG, Mackay B. Alveolar soft-part sarcoma: a review of the pathology and histogenesis. *Ultrastruct Pathol* 1998; 22: 275–292.
- Jordan DR, MacDonald H, Noel L et al. Alveolar soft-part sarcoma of the orbit. *Ophthalm Surg* 1995; 26: 269–270.
- Sherman N, Valvilala M, Pollock R, Romsdahl M, Jaffe N. Radiation therapy for alveolar soft-part sarcoma. *Med Pediatr Oncol* 1994; 22: 380–383.
- Mark RJ, Sercarz JA, Tran L et al. Osteogenic sarcoma of the head and neck. The UCLA experience. *Arch Otolaryngol* 1991; 117: 761–766.
- Abramson DH, Ronner HJ, Ellsworth RM. Second tumors in non-irradiated bilateral retinoblastoma. *Am J Ophthalmol* 1979; 87: 624–627.
- Jacobiec FA, Howard GM, Jones IS, Tannenbaum M. Fibrous histiocytomas of the orbit. *Am J Ophthalmol* 1974; 77: 333–345.
- Folberg R, Cleaseby G, Flanagan JA, Spencer WH, Zimmerman LE. Orbital leiomyosarcoma after radiation therapy for bilateral retinoblastoma. *Arch Ophthalmol* 1983; 101: 1562–1565.
- Font RL, Jurco S III, Brechner RJ. Postradiation leiomyosarcoma of the orbit complicating bilateral retinoblastoma. *Arch Ophthalmol* 1983; 101: 1557–1561.
- Kaltreider SA, Destro M, Lemke BN. Leiomyosarcoma of the orbit. A case report and review of the literature. *Ophthalm Plast Reconstr Surg* 1987; 3: 35–41.
- Jacobiec FA, Howard G, Rosen M et al. Leiomyoma and leiomyosarcoma of the orbit. *Am J Ophthalmol* 1975; 80: 1028–1042.
- Cai YC, McMenamin ME, Rose G et al. Primary liposarcoma of the orbit: a clinicopathologic study of seven cases. *Ann Diagn Pathol* 2001; 5: 255–266.
- Tehrani AH, Heegaard S, Prause JU et al. Liposarcoma metastatic to the orbit. *Eur J Ophthalmol* 2003; 13: 108–112.
- Jacobiec FA, Rini F, Char D et al. Primary liposarcoma of the orbit. Problems in the diagnosis and management of five cases. *Ophthalmology* 1989; 96: 180–191.



20. Costas A, Castro P, Munoz JM. Primary orbital liposarcoma: case report and review of the literature. *Int J Oral Maxillofac Surg* 2001; 30: 170–172.
21. Cockerham KP, Kennerdell JS, Celin SE, Fechter HP. Liposarcoma of the orbit: a management challenge. *Ophthalm Plast Reconstr Surg* 1998; 14: 370–374.
22. Howard GR, Nerad JA, Carter KD, Whitaker DC. Clinical characteristics associated with orbital invasion of cutaneous basal cell and squamous cell tumors of the eyelid. *Am J Ophthalmol* 1992; 113: 123–133.
23. Reifler DM, Hornblass A. Squamous cell carcinoma of the eyelid. *Surv Ophthalmol* 1986; 30: 349–365.
24. Goldberg RA, Rootman J, Cline RA. Tumors metastatic to the orbit: a changing picture. *Surv Ophthalmol* 1990; 35: 1–24.
25. Goldberg RA, Rootman J. Clinical characteristics of metastatic orbital tumors. *Ophthalmology* 1990; 97: 620–624.
26. Levy WJ. Neuroblastoma. *Br J Ophthalmol* 1957; 41: 48–53.
27. Dutton JJ, Rose JG Jr, DeBacker CM, Gayre G. Orbital Ewing's sarcoma of the orbit. *Ophthalm Plast Reconstr Surg* 2000; 16: 292–300.
28. Singh AD, Husson M, Shields CL, De Potter P, Shields JA. Primitive neuroectodermal tumor of the orbit. *Arch Ophthalmol* 1994; 112: 217–221.

# Rhabdomyosarcoma

Benson Chen and Julian D. Perry

## INTRODUCTION

Rhabdomyosarcoma (RMS) represents the most common orbital malignancy in children, and patients with this disease often present to the ophthalmologist. Because current therapeutic regimens offer an excellent chance for curing isolated orbital disease, prompt diagnosis and treatment are essential. Much of the success in reducing the morbidity and mortality over the past three decades has been through the collaborative efforts of the Intergroup Rhabdomyosarcoma Studies (IRS) formulated in the 1970s. Treatment of RMS with multiple modalities has transformed the dismal 3-year life expectancy from 25% in the 1960s to about 95% today.<sup>1,2</sup> With such success, clinicians now have the opportunity to focus on minimizing the serious late sequelae of aggressive therapy.

## ETIOLOGY

Rhabdomyosarcoma accounts for almost 45% of juvenile sarcomas. Each year in the United States 350 new cases of rhabdomyosarcoma are diagnosed, of which about 10% occur in the orbit.<sup>3</sup> Orbital RMS classically presents around age 8 years, but peak onset varies by histologic subtype, with the alveolar morphology more common in adolescents and the rare pleomorphic type more common in adults. There is a slight predilection for males, with a 1.7:1 male:female ratio.<sup>3</sup> No significant hereditary tendency for orbital rhabdomyosarcoma exists, although the malignancy has been observed in siblings.<sup>1</sup> There are no recognizable environmental, infectious, or biochemical influences in the pathogenesis of rhabdomyosarcoma; however, the malignancy has occurred secondarily in patients after radiotherapy for retinoblastoma and squamous cell carcinoma.<sup>4</sup>

## PATHOGENESIS

RMS represents a malignant neoplasm of cells showing histologic features of striated muscle in various stages of embryogenesis. Although RMS was once believed to arise from extraocular muscles, it is now accepted that it originates from undifferentiated mesenchymal cells possessing the capacity to differentiate into striated muscle.

## CLINICAL FEATURES

**Symptoms** Orbital RMS most commonly presents as a rapidly progressing mass with soft tissue changes suggestive of inflammation, and should be suspected in any pediatric patient developing subacute unilateral proptosis or periorbital swelling. Low suspicion and a confusing history of minor periocular trauma often delay diagnosis.

**Signs** depend primarily on the location of the tumor. Hertel exophthalmometry typically reveals proptosis and hypoglobus as the lesion occurs most commonly in the supranasal quadrant. Abnormal extraocular motility and ptosis are common findings. Anteriorly located tumors within the conjunctiva or eyelid tissues may produce eyelid edema, erythema, and chemosis. Such a presentation often masquerades as an infectious or inflammatory etiology. Slit lamp examination may reveal conjunctival chemosis, hyperemia, and signs of exposure keratoconjunctivitis. Funduscopic examination may show choroidal folds or optic disc edema with posterior orbital lesions. Orbital RMS may also occur secondarily due to local spread from the adjacent sinus cavities, meninges, or other soft tissues of the head and neck (Box 97.1).

## DIAGNOSTIC EVALUATION

Diagnostic evaluation should proceed urgently. CT imaging typically demonstrates a moderately well-defined homogeneous orbital mass (Fig. 97.1). The lesion is isodense to the extraocular muscles and enhances after contrast administration. Signs of adjacent bone destruction are common. MRI studies often show a lesion isointense to the extraocular muscles and hypointense to the orbital fat on T<sub>1</sub>-weighted studies (Fig. 97.2). Gadolinium-DPTA-enhanced MRI studies often show moderate to marked enhancement. Orbital ultrasonography may show a nodular contour with hypoechogenic and irregular internal reflectivity. Color Doppler imaging may show profound intralesional flow.

The evaluation proceeds with excisional or incisional biopsy. Initial surgery should debulk as much tumor as possible, with care to preserve vital orbital structures. Well-circumscribed, accessible lesions may allow for complete excision. More commonly, surgery results in significant gross residual tumor in order to preserve ocular function. The surgical approach to RMS should preserve orbital periosteum, which may act as a barrier to local spread. Spread to local lymph nodes occurs uncommonly, typically from more anteriorly located tumors. Palpable nodes require biopsy with cytological confirmation for staging. Metastases can occur hematogenously to lung and bone. Orbital RMS requires a full metastatic evaluation performed by the pediatric oncologist.<sup>5</sup>

## HISTOLOGY

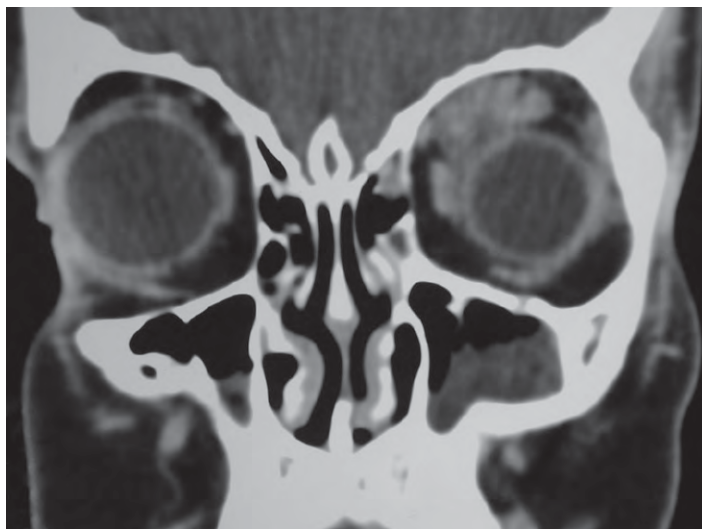
**Light microscopy** Four major histopathologic variants of RMS exist: embryonal, alveolar, botryoid, and pleomorphic. The majority of orbital RMS are of the embryonal type. The alveolar and botryoid

embryonal subtypes are uncommon and the pleomorphic type is rare in the orbit.<sup>6,7</sup> As pure classification into subtypes may be difficult, in 1995 the International Classification of Rhabdomyosarcoma (ICR) placed all variants into one of two divergent prognostic categories: superior or poor. Superior prognostic morphologies include the botryoid and spindle cell embryonal variants. Alveolar and diffusely anaplastic variants fall into the poor prognostic category.<sup>8</sup> The histologic appearance and ICR category influence the treatment plan and significantly correlate with prognosis (Table 97.1).

**Immunohistochemistry** Differentiation from other spindle cell tumors often presents a significant challenge to the pathologist. Immunohistochemistry and electron microscopy aid in diagnosis and in determining the histologic variant. Numerous immunohistochemical markers can identify the skeletal muscle-specific expression in an RMS tumor (Box 97.2). Antibodies against desmin show the greatest specificity and retain positive reaction in even poorly differentiated rhabdomyoblasts.<sup>9</sup> Vimentin staining assists in ruling out other small round cell tumors of childhood. Antibodies to myogenin and MyoD1 show high expression in more primitive cells, but only faintly stain differentiated cell types. Caveolin-3 is a new marker that appears highly sensitive and specific for more differentiated RMS tumors and may help to detect residual tumor following chemotherapy.<sup>10</sup>

#### BOX 97.1 Signs of Orbital Rhabdomyosarcoma

- Proptosis/hypoglobus
- Palpable mass
- Lid edema or erythema
- Chemosis, exposure keratopathy
- Optic neuropathy or disc edema
- Choroidal folds



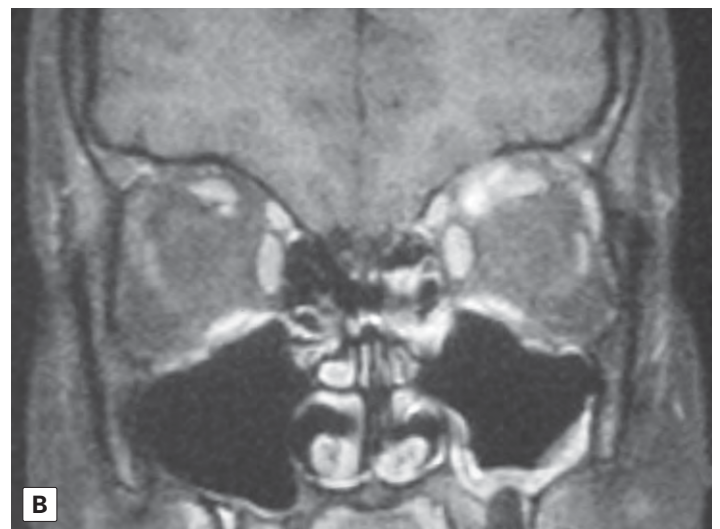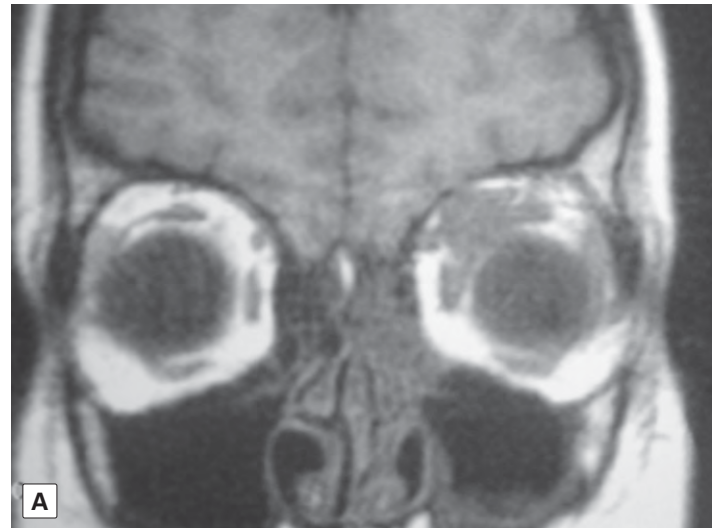
**Fig. 97.1** Coronal CT of an alveolar rhabdomyosarcoma demonstrates a moderately well-defined superior nasal quadrant lesion that is isodense to the extraocular muscles. Adjacent bony destruction, although common in rhabdomyosarcoma, is not demonstrated in this study.

**Electron microscopy** may show parallel rays of thick myosin filaments and sarcomeric units with Z-banding; however, this banding may be difficult to demonstrate and controversy exists regarding its diagnostic value.

**Molecular analysis** can assist in classifying the primary orbital tumor cells and detecting early disease recurrence. Translocations of chromosome 13 are specific for alveolar RMS, with  $t(2;13)$  associated with a more aggressive form than  $t(1;13)$ .<sup>11,12</sup> Tetraploid alveolar cells and diploid embryonal cells signify more aggressive tumors.<sup>13,14</sup>

#### DIFFERENTIAL DIAGNOSIS

Orbital RMS should be considered in the differential diagnosis of any child with proptosis and subacute edema. The rapidly progressive course and associated inflammatory signs can suggest both benign and malignant etiologies. Malignancies that can simulate RMS include neuroblastoma, leukemia or other metastases, lymphoma, and other sarcomas. Non-malignant diseases include orbital cellulitis, dacryocystitis, idiopathic orbital inflammation, lymphangioma, capillary hemangioma, and dermoid cyst.



**Fig. 97.2** T<sub>1</sub>-weighted MRI shows the lesion is isointense to the extraocular muscles and hypointense to the orbital fat (A). Moderate enhancement with Gadolinium – DPTA (B).



**TREATMENT**

Treatment guidelines have evolved into a sophisticated regimen of multiagent chemotherapy, radiation, and surgery. Successful IRS treatment protocols have allowed current studies to focus on minimizing the long-term side effects of radiation and chemotherapy for patients with a low risk of recurrent disease.<sup>15</sup> In current IRS treatment protocols, group, stage, histology, and patient age contribute to the risk and

treatment stratification necessary to optimize outcome (Table 97.2).<sup>15</sup>

**PROGNOSIS**

Isolated orbital involvement carries the best prognosis of all primary RMS locations, with an overall survival rate of 96% and eye preservation rate of 86%.<sup>2</sup> Children who present between ages 1 and 10 years

**Table 97.1 International Classification of Rhabdomyosarcoma, histology, and prognosis**

Recurrence risk	Embryonal or botryoid RMS (ERMS)	Alveolar RMS (ARMS)
Low	Isolated orbital ERMS Orbital ERMS with parameningeal or sinus extension (stage 2, 3)	Group I, II, III Complete surgical resection or gross resection with microscopic residual tumors (group I or II)
Intermediate	Orbital ERMS with distant metastasis (stage 4)	Gross residual tumors (group III) Orbital ARMS without distant metastasis (stage 1, 2, 3)
High		Orbital ARMS with distant metastasis (stage 4)

RMS, rhabdomyosarcoma.

**BOX 97.2 Immunohistochemical Markers for Rhabdomyosarcoma**

- Desmin
- Vimentin
- Muscle-specific actins
- Myoglobin
- Myogenin
- MyoD1
- Caveolin-3

**Table 97.2 Current IRS treatment protocol by group, stage, and histology**

Treatment category by recurrence risk	Treatment protocol	
	Chemotherapy (by stage)	Conventional fractionation radiation therapy (by group)
Low	Node negative (stage 1, 2)	VA Group I No RT Group II 40 Gy
	Node positive (stage 3)	VAC Group III 50 Gy
Intermediate	VAC +/- (V, T, C)	Group III 50 Gy Group IV Local and distant RT
High	CPT-11 then VAC	Group IV Local and distant RT

V, vincristine; A, actinomycin D; C, cyclophosphamide; T, topotecan; CPT-11, irinotecan; RT, radiotherapy.

have a more favorable prognosis than infants or young adults. Histologic examination and molecular analysis contribute significantly to prognosis. For the more favorable embryonal tumors, prognosis improves with evidence of genetic hyperploidy. In contrast, less favorable alveolar tumors fare even worse with evidence of tetraploid DNA content.<sup>13</sup> Karyotype detection of chromosomal translocations indicates alveolar morphology, with the t(2;13) PAX3 FKHR fusion gene faring worse than those bearing the t(1;13) PAX7-FKHR fusion gene.<sup>12</sup> In rare instances where the orbital disease is refractory to standard treatment, aggressive secondary surgery yields 3-year survival rates up to 70%.<sup>16</sup> Patients with metastatic disease may benefit from myeloablative treatment with stem cell support.<sup>17</sup> Survivors of previous treatment protocols now show the unfortunate side effects of radiotherapy, with over 70% of eyes suffering some degree of vision loss.<sup>2</sup> Other common late sequelae include cataracts and facial hypoplasia (Box 97.3).

## FOLLOW-UP

After treatment, patients require serial comprehensive examinations and imaging studies to document their new baseline status and residual tumor size. Follow-up should be every 3–4 months for the first year, then every 4–6 months for several years thereafter. Secondary biopsy offers low yield with significant risk and should be reserved for patients with clinical indications of recurrence and changes on serial imaging studies.<sup>7</sup>

## FUTURE RESEARCH

Stereotactic radiotherapy with intensity-modulated radiotherapy (IMRT),<sup>18</sup> external beam proton radiation therapy,<sup>19</sup> and brachytherapy<sup>20</sup> may produce equivalent or superior results with fewer sequelae, but these modalities require further investigation. The IRS V protocol will determine whether initial chemoreduction followed by surgery can reduce the radiation dose while maintaining survival rates.<sup>15</sup> Combination cyclophosphamide and radiotherapy increases the risk of secondary malignancy compared to each of these therapeutic modalities independently.<sup>21</sup> Limiting the use of these modalities should lower

### BOX 97.3 Late Ocular Sequelae of Radiation Therapy

- Cataract 82%
- Impaired vision in the treated eye 70%
- Orbital hypoplasia and asymmetry 59%
- Dry eyes 30%
- Ptosis/enophthalmos 28%

Modified from Raney RB, Anderson JR, Kollath J et al. Late effects of therapy in 94 patients with localized rhabdomyosarcoma of the orbit: Report from the Intergroup Rhabdomyosarcoma Study (IRS)-III, 1984–1991. *Med Pediatr Oncol* 2000; 34: 413–420.

the risk of secondary malignancies and myelosuppression. New anti-neoplastic agents, including topoisomerase-1 inhibitors such as topotecan and irinotecan, show promise against more aggressive cases.<sup>22,23</sup> Further tumor-specific marker discoveries and a better understanding of gene expression pathways should allow for the identification of new therapeutic targets to produce less toxic systemic treatments. The IRS V protocol requests fresh samples of tumor, bone marrow, and peripheral blood lymphocytes for newly diagnosed RMS to build a growing tissue sample library.<sup>15</sup>

## SUMMARY

RMS represents the most common childhood orbital malignancy. Despite recent advancements in treatment it remains a potentially fatal disease, and current treatment regimens continue to carry significant morbidity. As the management of orbital RMS becomes increasingly complex, close collaboration between the ophthalmic surgeon, pathologist, pediatric oncologist, and the radiation oncologist is becoming necessary to optimize outcome.

## REFERENCES

- Howard GM, Castern VG. Rhabdomyosarcoma of the orbit in brothers. *Arch Ophthalmol* 1963; 70: 319–322.
- Raney RB, Anderson JR, Kollath J et al. Late effects of therapy in 94 patients with localized rhabdomyosarcoma of the orbit: Report from the Intergroup Rhabdomyosarcoma Study (IRS)-III, 1984–1991. *Med Pediatr Oncol* 2000; 34: 413–420.
- Crist WM, Raney RB, Tefft M et al. Soft tissue sarcomas arising in the retroperitoneal space in children. A report from the Intergroup Rhabdomyosarcoma Study (IRS) Committee. *Cancer* 1985; 56: 2125–2132.
- Hasegawa T, Matsuno Y, Niki T et al. Second primary rhabdomyosarcomas in patients with bilateral retinoblastoma: a clinicopathologic and immunohistochemical study. *Am J Surg Pathol* 1998; 22: 1351–1360.
- Shields JA, Shields CL. Rhabdomyosarcoma: Review for the ophthalmologist. *Surv Ophthalmol* 2003; 48: 39–57.
- Kodet R, Newton WA, Hamoudi AB et al. Orbital rhabdomyosarcomas and related tumors in childhood: relationship of morphology to prognosis – an Intergroup Rhabdomyosarcoma Study. *Med Pediatr Oncol* 1997; 29: 51–60.
- Shields CL, Shields JA, Honovar SG et al. Clinical spectrum of primary ophthalmic rhabdomyosarcoma. *Ophthalmology* 2001; 108: 2284–2292.
- Newton WA Jr, Gehan EA, Webber BL et al. Classification of rhabdomyosarcomas and related sarcomas. Pathologic aspects and proposal for a new classification – an Intergroup Rhabdomyosarcoma Study. *Cancer* 1995; 76: 1073–85.
- Kodet R. Rhabdomyosarcoma in childhood. An immunohistological analysis with myoglobin, desmin and vimentin. *Pathol Res Pract* 1989; 185: 207–213.
- Fine SW, Lisanti MP, Argani P, Li M. Caveolin-3 is a sensitive and specific marker for rhabdomyosarcoma. *Appl Immunohistochem Mol Morphol* 2005; 13: 231–236.
- Douglass EC, Rowe ST, Valentine M et al. Variant translocations of chromosome 13 in alveolar rhabdomyosarcoma. *Genes Chromosomes Cancer* 1991; 3: 480–482.
- Sorensen PH, Lynch JC, Qualman SJ et al. PAX3-FKHR and PAX7-FKHR gene fusions are prognostic indicators in alveolar rhabdomyosarcoma: a report from the Children's Oncology Group. *J Clin Oncol* 2002; 20: 2672–2679.
- Pappo AS, Crist WM, Kuttesch J et al. Tumor-cell DNA content predicts outcome in children and adolescents with clinical group III embryonal rhabdomyosarcoma. The Intergroup Rhabdomyosarcoma Study Committee of the Children's Cancer Group and the Pediatric Oncology Group. *J Clin Oncol* 1993; 11: 1901–1905.
- Staibano S, Franco R, Tranfa F et al. Orbital rhabdomyosarcoma: relationship between DNA ploidy, p53, Bcl-2, MDR-1 and Ki67 (MIB1) expression and clinical behavior. *Anticancer Res* 2004; 24: 249–258.
- Raney RB, Anderson JR, Barr FG et al. Rhabdomyosarcoma and undifferentiated sarcoma in the first two decades of life: a selective review of IRS group experience and rationale for IRS V. *J Pediatr Hematol Oncol* 2001; 23: 215–220.
- Lawrence W Jr, Anderson JR, Gehan EA et al. Pretreatment TNM staging of childhood rhabdomyosarcoma: a report of the Intergroup Rhabdomyosarcoma Study Group. *Children's Cancer Study Group. Pediatric Oncology Group. Cancer* 1997; 80: 1165–1170.
- Endo M, Tanosaki R. Myeloablative chemotherapy with autologous bone marrow and/or peripheral blood stem cell transplantation in children with high-risk solid tumor. *Gan To Kagaku Ryoho* 1995; 22: 1762–1770. [Japanese]
- Wolden SL, Wexler LH, Kraus DH et al. Intensity-modulated radiotherapy for head-and-neck rhabdomyosarcoma. *Int J Radiat Oncol Biol Phys* 2005; 61: 1432–1438.

19. Yock T, Schneider R, Friedmann A et al. Radiotherapy for orbital rhabdomyosarcoma: Clinical outcome and a dosimetric comparison with photons. *Int J Radiat Oncol Biol Phys* 2005; (Epub ahead of print.)
20. Abramson DH, Fass D, McCormick B et al. Implant brachytherapy: a novel treatment for recurrent orbital rhabdomyosarcoma. *JAAPOS* 1997; 1: 154–157.
21. Heyn R, Haerberli V, Newton WA et al. Second malignant neoplasms in children treated for rhabdomyosarcoma. IRS Committee. *J Clin Oncol* 1993; 11: 262–270.
22. Cosetti M, Wexler LH, Calleja E et al. Irinotecan for pediatric solid tumors: the Memorial Sloan–Kettering experience. [Review] *J Pediatr Hematol Oncol* 2002; 2: 101–105.
23. Pappo AS, Leyden E, Breneman J et al. Up-front window trial of topotecan in previously untreated children and adolescents with metastatic rhabdomyosarcoma: IRS. *J Clin Oncol* 2001; 19: 213–219.



# Enucleation and orbital implants

David R. Jordan and Stephen R. Klapper

## INTRODUCTION

The loss of an eye to tumor, trauma, or end-stage ocular disease is devastating. There is a loss of binocular vision, with reduced peripheral visual field and loss of depth perception. Job limitations may arise and affected individuals may experience a sense of facial disfigurement. Because eye contact is such an essential part of human interaction, it is extremely important for the patient with an artificial eye to maintain a natural, normal-appearing prosthetic eye. In the past decade there have been numerous developments and refinements in anophthalmic socket surgery with respect to implant material and design, implant wrapping, implant–prosthesis coupling, and socket volume considerations. It is now possible to provide the anophthalmic patient with an artificial eye that looks and moves almost as naturally as a normal one.

## POROUS ORBITAL IMPLANTS

**Hydroxyapatite implants** In the effort to design a biocompatible, integrated orbital implant Perry<sup>1</sup> in 1985 introduced coralline (sea coral) hydroxyapatite (HA) spheres (Bio-Eye, Integrated Orbital Implants, San Diego, CA). The HA implants represented a new generation of buried, integrated spheres with a regular system of interconnecting pores that allowed host fibrovascular ingrowth (Fig. 98.1).<sup>1,2</sup> Fibrovascularization potentially reduced the risk of migration, extrusion, and infection of the implant.<sup>3</sup> The HA implant also allowed secure attachment of the extraocular muscles, which in turn leads to improved implant motility.<sup>1,2</sup> By drilling into the implant, inserting a peg and coupling the peg to the prosthetic eye, an improved range of movement as well as fine darting prosthetic eye movements (commonly seen during close conversational speech) were seen. This gave a more life-like quality to the artificial eye.

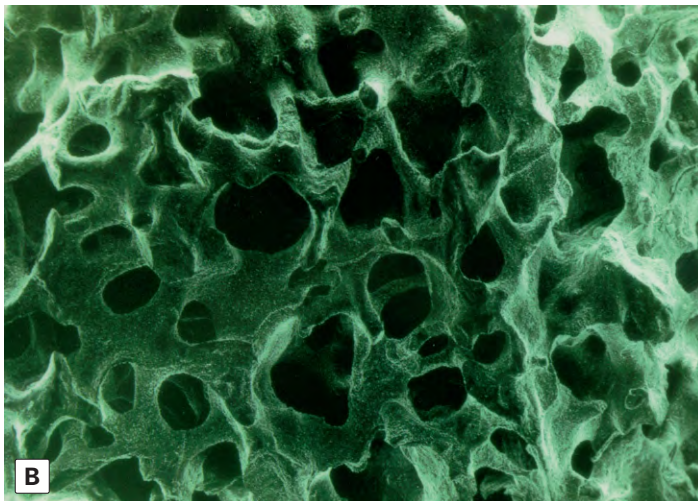
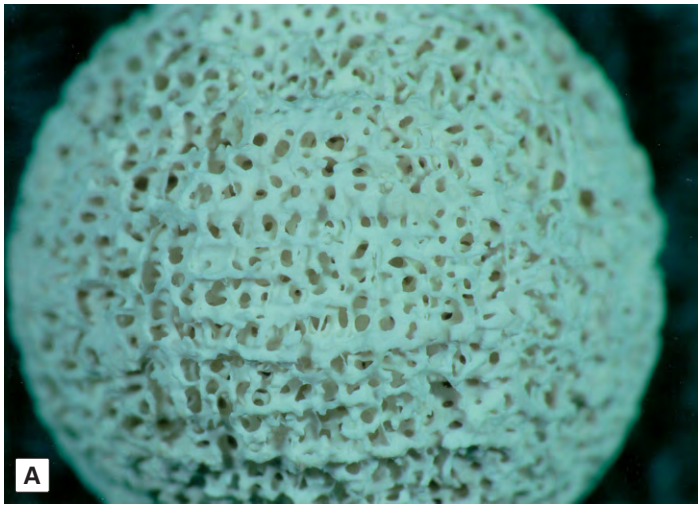
Although HA implants represented a significant advance in anophthalmic surgery, experience with them over the last decade has expanded our understanding of the limitations of HA. Reported complications are not uncommon and include implant exposure, conjunctival thinning, socket discharge, pyogenic granuloma formation, implant infection, and persistent pain or discomfort.<sup>4–8</sup> Exposure problems continue to deter some surgeons from using HA implants, but this complication appears to be related more to surgical technique (including HA implant wrap selection) and host factors than to the properties of HA spheres.<sup>3</sup>

The introduction of HA as an orbital implant significantly raised the costs associated with enucleation, evisceration, and secondary orbital implant procedures. The Bio-Eye HA implant may cost over

\$600 (US) more than traditional silicone or polymethylmethacrylate (PMMA) spherical implants (\$15–\$50 US). Additional expenses associated with HA placement include an implant wrap material, assessment of implant vascularization with a confirmatory magnetic resonance (MR) imaging study, a secondary drilling procedure with peg placement, and prosthesis modification. In the search for porous orbital implants with a reduced complication profile and diminished surgical and postoperative costs, numerous alternative implant materials have been introduced around the world.

**Synthetic porous implants** Polyethylene (MEDPOR, Porex Surgical Inc., Newnan, GA, USA) implants were introduced over a decade ago for use in the orbit and have been widely accepted as an alternative to the HA Bio-Eye.<sup>9–12</sup> Porous polyethylene implants, although less biocompatible than HA,<sup>13</sup> are typically well tolerated by orbital soft tissue. They have a smoother surface than HA implants, which permits easier implantation and provides potentially less irritation of the overlying conjunctiva following placement (Fig. 98.2A, B). These implants have a high tensile strength and yet are malleable, which allows sculpting of the anterior surface of the implant. They may be used with or without a wrapping material and the extraocular muscles can be sutured directly on to the implant, although most surgeons may find this difficult without predrilled holes. Porous polyethylene implants are available in spherical, egg, conical, and mounded shapes (quad-implant).<sup>10–12</sup> The anterior surface can also be manufactured with a smooth, non-porous surface to prevent abrasion of the overlying tissue (e.g. MEDPOR smooth surface tunnel implant – SST) while retaining a larger pore size posteriorly to facilitate fibrovascular ingrowth. The MEDPOR implant costs approximately \$200 (US) less than the Bio-Eye HA sphere, depending on the quantity ordered.



**Synthetic hydroxyapatite implants** developed by FCI (Issy-les-Moulineaux, France) are currently in their third generation (FCI<sub>3</sub>). The FCI<sub>3</sub> implant has a chemical composition identical to that of the Bio-Eye, although scanning electron microscopy (SEM) has revealed reduced pore uniformity and interconnectivity and the presence of blind pouches.<sup>14</sup> Central implant fibrovascularization in a rabbit model still appears to occur in a similar manner in both the Bio-Eye and FCI<sub>3</sub> implants.<sup>15</sup> The synthetic FCI<sub>3</sub> implant has gained in popularity in many parts of the world over the past 10 years; however, it is not yet available in the United States. The problems and complications associated with it are similar to those of the Bio-Eye.<sup>16</sup> It is less expensive than the Bio-Eye (approximately \$480 US).



**Fig. 98.1** The porous architecture of the Bio-Eye hydroxyapatite implant is well visualized (A). Scanning electron microscopy illustrating the porous architecture of a Bio-Eye (B) (222 × 10).

Other forms of HA implant in use around the world include the Chinese HA and the Brazilian HA implants.<sup>17,18</sup> Although less expensive than the Bio-Eye, these implants have impurities or poor porous structures that offer little advantage. Other implant designs continue to surface, some of which are of little added value<sup>19</sup> whereas others have only been in use for a short time and there may be advantages/disadvantages that are not yet apparent.<sup>20</sup>

**Ceramic implants** Aluminum oxide ( $\text{Al}_2\text{O}_3$ ) is a ceramic implant biomaterial that has been used in orthopedic surgery and dentistry for more than 30 years. Spherical and egg-shaped Bioceramic Orbital Implants (FCI, Issy-Les-Moulineaux, France) were approved for use in the United States by the FDA in April 2000 and for use in Canada by Health and Welfare Canada in February 2001. Aluminum oxide is a porous, inert substance and has been suggested as a standard reference material in studies of implant biocompatibility.<sup>21</sup> These implants permit host fibrovascular ingrowth similar to the Bio-Eye.<sup>22,23</sup> Human fibroblasts and osteoblasts proliferate more rapidly on aluminum oxide than on HA, suggesting that it is a more biocompatible substance than HA.<sup>13,21</sup> The Bioceramic implant is lightweight, has a uniform pore structure and excellent pore interconnectivity (Fig. 98.3A, B).<sup>14</sup> The microcrystalline structure is smoother than the rough-surfaced Bio-Eye (Fig. 98.3C). In our experience, anophthalmic sockets reconstructed



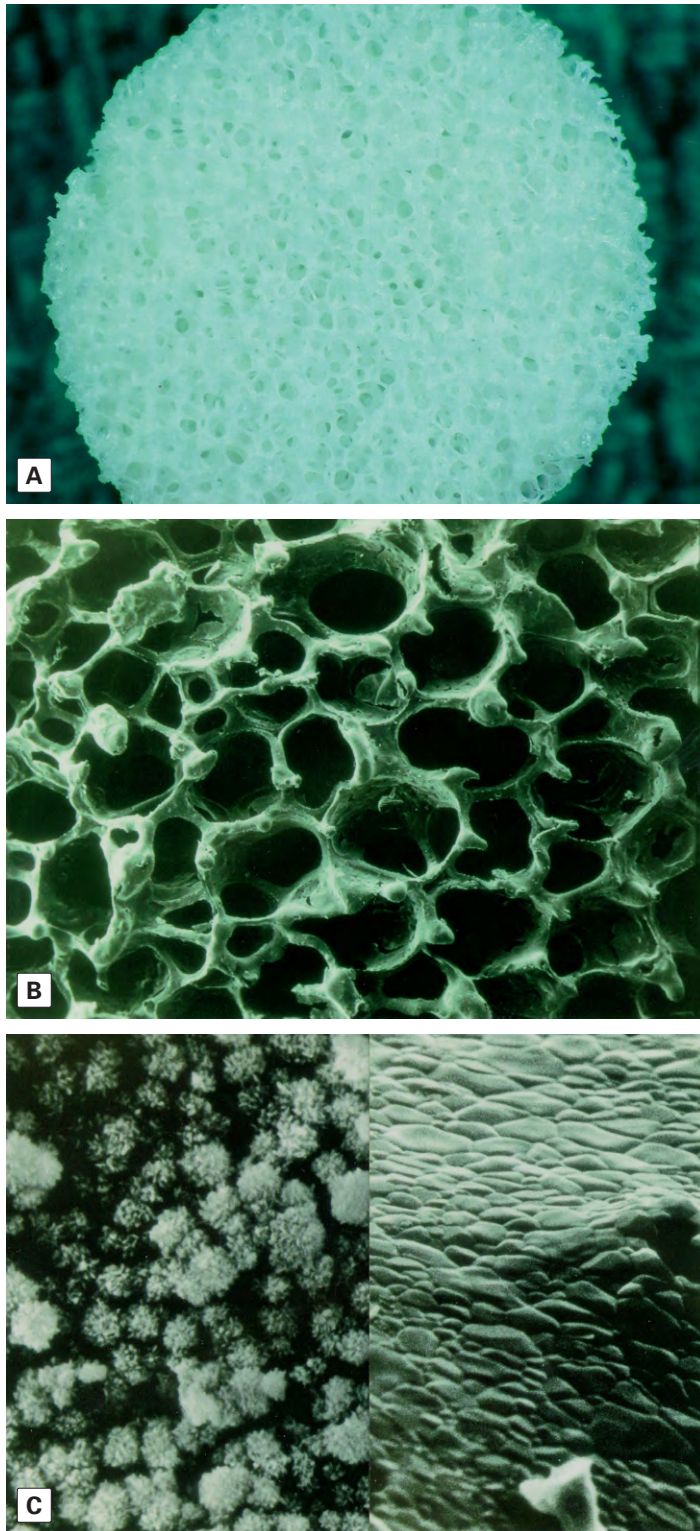
**Fig. 98.2** On gross examination the porous polyethylene implant appears to have more of a channel system than pores (A). Scanning electron microscopy of a porous polyethylene implant (222 × 10) illustrating the smooth surface of the architecture as well as the channel system (B).

with aluminum oxide implants appear to have less postoperative tissue inflammation than sockets in which HA implants have been placed.<sup>23</sup> Problems (e.g. exposure) encountered with its use are similar to those seen with the Bio-Eye orbital implants, but appear to occur less often.<sup>23,24</sup> As with the other available porous orbital implants, aluminum oxide is less expensive than the Bio-Eye (\$450 US vs \$650 US).

## IMPLANT SELECTION

There continues to be little consensus regarding orbital implant material and design preference.<sup>25</sup> Surgeons have their own preferences regarding the use of spherical versus shaped, wrapped versus unwrapped, and pegged versus unpegged implants. Costs, hospital budgets, and marketing pressures also play a role in implant selection. In a 2004 survey of 1919 primary orbital implants used following enucleation, porous polyethylene was used in 42.7% of cases, followed by coralline HA (27.3%), non-porous alloplastic (19.9%), Bioceramic (1.8%), synthetic HA (0.9%), dermis fat grafts (7.2%), and mammalian bone (0.2%).<sup>25</sup> It is important to recognize that the trends reported in this survey are only reflective of a usage





**Fig. 98.3** The porous architecture of an aluminum oxide (Bioceramic) implant is well visualized (A). Scanning electron microscopy illustrating the more uniform porous architecture of the aluminum oxide orbital implant (B) ( $222 \times 10$ ). On high-power scanning electron microscopy ( $230 \times 10^3$ ) the solid component of the Bio-Eye (left half of photo) has a rough-appearing microcrystalline structure compared to the smooth-appearing microcrystalline structure of the aluminum oxide (Bioceramic) implant (right half of photo) (C).

pattern in those responding to the survey (31.4% response rate) and do not necessarily suggest clinical superiority with scientific evidence.<sup>25</sup>

When deciding which implant to use, these authors divide the various products into three useful categories: porous spheres that may potentially be pegged (HA – coralline or synthetic; porous polyethylene; aluminum oxide); quasi-integrated implants (Universal implant, Quad MEDPOR); and standard non-porous sphere (polymethylmethacrylate, silicone).

If the patient is healthy and between the ages of 15 and 65 years a porous implant (Bioceramic) that can potentially be pegged is our first choice as it offers the highest degree of movement.<sup>25,26</sup> If a peg is not being remotely considered, the advantage of using a porous spherical implant are diminished, as the movement associated with a non-pegged porous orbital implant is equal to that of a wrapped non-porous spherical implant.<sup>27–29</sup> However, the advantage of fibrovascular ingrowth and the potentially diminished risk of implant migration remain reasons to consider using a porous implant.

A quasi-integrated implant such as the Universal (PMMA) or MEDPOR Quad implant is an alternative consideration to the porous spherical implant, as the mounded surface offers improved motility over a standard sphere as a result of the coupling that occurs between the mounds on the implant and the posterior surface of the prosthesis.

A standard sphere (PMMA, silicone), wrapped, centered within the muscle cone and attached to the four rectus muscles, is another alternative if pegging is not a consideration. Although prosthetic movement occurs, it is not as much as that seen with a mounded implant or pegged porous implant. A standard sphere placed into the orbit, without a wrap and without connection to the rectus muscles, is the least desirable choice as it offers little movement and the implant is prone to migration.

In a young child (under 5 years) we prefer either a PMMA mounded implant (Universal, MEDPOR Quad) or a wrapped sphere (PMMA, silicone) centered within the muscle cone and connected to the rectus muscles and the inferior oblique muscle. Implant exchange with a porous orbital implant that can potentially be pegged is considered at a later age (>15 years). In the aging individual (>65 years) the authors do not use porous orbital implants and prefer a mounded type (Universal, MEDPOR Quad) or a standard sphere (PMMA, silicone) wrapped and centered in the muscle cone and connected to the rectus muscles.

## VOLUME CONSIDERATIONS

Removal of an eye following enucleation or evisceration creates an orbital soft tissue volume deficiency. Insufficient volume replacement results in an abnormally deep superior sulcus, upper eyelid ptosis, and enophthalmos, and may require a larger than desirable prosthesis.<sup>30–34</sup>

Approximately 70–80% of the volume of an individual's normal globe should be replaced with the orbital implant.<sup>32</sup> This generally allows for a prosthetic volume that is approximately 2 mL.<sup>30</sup> Larger prostheses often result in progressive lower eyelid laxity and malposition owing to the weight of the prostheses on the eyelid. Larger prostheses may also have limited socket excursion.<sup>31</sup>

Several authors have reported that the variability of axial length and globe volume is significant, with globe volumes varying between 6.9 and 9.0 mL.<sup>32–34</sup> Proper implant volume may be determined either preoperatively or intraoperatively (enucleation cases) from the axial



length of the eye or by determining the volume of fluid the enucleated eye displaces in a graduated cylinder.<sup>32–34</sup> Kaltreider<sup>32,35</sup> has shown that the axial length minus 2 mm (or A-scan minus 1 mm) approximates the implant diameter for optimal volume replacement in emmetropic and myopic individuals. Custer<sup>33</sup> suggested that a graduated cylinder be used to measure the volume of fluid displaced by an enucleated eye. The volume of the globe minus 2 mL gives the ideal implant size to use. Individualization of the implant size is important in optimizing orbital volume replacement and in achieving the best possible aesthetic result.<sup>31,32, 34,35</sup>

## ORBITAL IMPLANT WRAPPING

Placement of an HA or Bioceramic implant within the soft tissue of the eye socket is facilitated by a smooth wrapping material that diminishes tissue drag.<sup>1</sup> In addition, the wrap facilitates precise fixation of the extraocular muscles to the implant surface.<sup>1</sup> Implant wraps may also provide a barrier function over the spiculated porous implant surface,<sup>1</sup> although there is some debate about whether covering the anterior surface of the implant with an avascular material is helpful in preventing exposure.<sup>36–38</sup> In a recent survey, the majority of respondents (59%) preferred not to wrap.<sup>25</sup> The advantages of placing an unwrapped implant include simplification of the procedure, decreased operating room time, reduced cost, avoidance of a second surgical site for harvesting autogenous wrap, and a decreased risk of disease transmission.<sup>25,37,38</sup>

If a wrap is used human donor sclera has traditionally been the first choice.<sup>1,2</sup> The use of such material has, however, recently fallen out of favor with both surgeons and patients because of the potential risk of transmission of HIV, hepatitis B or C, and prions (Creutzfeldt–Jakob disease).<sup>39</sup> Although we are not aware of any reports of disease transmission from donor sclera, segments of the human immunodeficiency virus (HIV)-1 genome have been identified in preserved human sclera.<sup>40</sup> Creutzfeldt–Jakob disease transmission from dural and corneal transplants has been reported.<sup>41–43</sup> In addition, seronegative organ and tissue donors may transmit HIV.<sup>44</sup> Many eye banks charge a substantial fee to provide donor sclera.

Specially processed human donor pericardium, fascia lata, and sclera are marketed as safe alternative implant wraps for preserved human donor tissues (Biodynamics International (US), Inc., Tampa, FL, USA). These wraps have the convenience of a long (up to 5 years) shelf life; however, they are currently priced at levels that may exceed the cost of the implant itself.

Processed bovine pericardium (Peri-Guard or Ocu-Guard Supple, Bio Vascular Inc., Saint Paul, MN, USA) is FDA approved and also available as an implant wrap material.<sup>45,46</sup> Although there have been only a few cases of bovine spongiform encephalopathy (BSE) in American cattle to date, reports of infected cattle in Alberta, Canada, have recently surfaced and the potential for the disease to occur with possible prion transmission still exists.<sup>39</sup>

Autologous temporalis fascia,<sup>47</sup> fascia lata,<sup>48</sup> rectus abdominis sheath,<sup>49</sup> and posterior auricular muscle complex grafts<sup>50</sup> have been tried as orbital implant wrapping materials. Use of these tissues requires a second operative site, prolonged operative time, and a potentially increased risk of morbidity.

Microporous expanded polytetrafluoroethylene (e-PTFE) (Gore-Tex, WL Gore & Associates, Flagstaff, AZ, USA) has also been advocated as an implant wrapping material (Oculo-Plastik, Montreal, Quebec, Canada), but complications with its use have made it undesirable.<sup>51–53</sup>

Undyed polyglactin 910 mesh (Vicryl mesh, Ethicon, Somerville, NJ, USA) is a bioabsorbable synthetic material and is our preference as a wrapping material for porous orbital implants.<sup>54,55</sup> Vicryl mesh eliminates the risk of infectious disease transmission, does not require a second surgical site, is readily available, is simple to use, and is inexpensive. Vicryl mesh-wrapped HA implants have been shown to permit rapid implant fibrovascularization in an animal model,<sup>55,56</sup> and may provide the potential advantage of permitting fibrovascular ingrowth over the entire implant surface, unlike implants wrapped in sclera.<sup>57</sup> We have reported a 2.1% incidence of implant exposure in 187 consecutive patients receiving Vicryl mesh-wrapped HA orbital implants.<sup>58</sup> With refinements in placement technique, our incidence of exposure is now less than 1% (unpublished data). Oestreicher et al.<sup>7</sup> also reported a low exposure incidence using a similar bioabsorbable wrapping material composed of polyglycolic acid (Dexon mesh style no. 8, non-stretch, medium-weight closed tricot, Davis & Geck, Manati, Puerto Rico). Despite our success with polyglactin 910 mesh as a wrap material, some surgeons continue to believe that it is associated with a higher rate of implant exposure.<sup>59,60</sup> It remains the view of the authors that high exposure rates with Vicryl mesh-wrapped implants is a technique-related problem that can be significantly minimized with correct insertion and meticulous tension-free wound closure.

## PEGGING POROUS ORBITAL IMPLANTS

A recent infrared oculographic study has demonstrated significant objective improvement in horizontal gaze after motility peg placement.<sup>26</sup> Despite the improved motility many surgeons and patients still elect to avoid peg placement because of the satisfactory results without pegging and the possibility of pegging-related complications.<sup>61–66</sup> Although the use of pegging has declined dramatically over the past few years we believe that a precise and meticulous technique<sup>67</sup> in appropriately selected individuals can be very successful.

Proper care of the artificial eye and regular follow-up visits with the oculist and ophthalmic plastic surgeon are important. If the patient is unlikely, unable, or unwilling to do this then pegging should probably be avoided. The authors do not feel that children (roughly less than age 15 years), adults over the age of 65, or individuals of any age with a chronic illness (collagen vascular disease, sarcoidosis, diabetes, immunosuppressive therapy, etc.) should be considered for pegging.

Peg systems were generally designed for peg placement once fibrovascularization of the implant is complete. Fibrovascularization is believed to diminish the risks of implant infection, exposure, and migration.<sup>9,57</sup> Drilling into an avascular area of the implant may predispose the implant to infection.<sup>68</sup> Gadolinium-enhanced MR imaging is currently the recommended method of assessing the extent of implant vascularization.<sup>69</sup> Fibrovascular ingrowth may occur at varying rates in different patients. Implant drilling and peg placement are generally deferred until 5–6 months after HA implant insertion.

Several titanium peg systems are currently available for use with porous orbital implants. Titanium is more biocompatible and better tolerated by human soft tissue than the original peg systems made of polycarbonate.<sup>70</sup> The FCI peg system utilizes a hydroxyapatite-coated titanium sleeve.<sup>67</sup> The HA coating potentially allows for stronger interface bonding with the orbital fibroblasts than the uncoated P-K system supplied for use with the Bio-Eye. The MEDPOR Motility Coupling Post (MCP) (Porex Surgical, College Park, GA, USA) is a titanium screw that can be screwed directly into porous polyethylene implants.<sup>71,72</sup>

Some authors have advocated primary placement of the MCP at the time of implant insertion.<sup>73,74</sup> This practice, however, remains controversial, and most surgeons defer implant pegging for more than 6 months after implant placement.

## SUMMARY

Anophthalmic surgery is no longer simply about replacing a diseased eye with an orbital implant. Ophthalmic surgeons and oculists are now more than ever focused on restoring a patient's appearance and prosthetic motility to as near normal as possible. Although evisceration

surgery has recently increased in popularity and is favored by many surgeons because of the simplicity of the technique, less disruption to the socket anatomy, and excellent cosmetic results, enucleation is still required in patients with known or potentially occult ocular malignancies as well as blind, painful and/or unsightly eyes with opaque media and unknown or unclear past ocular histories.<sup>75</sup>

## REFERENCES

- Perry AC. Advances in enucleation. *Ophthalm Plast Reconstr Surg* 1991; 4: 173-182.
- Dutton JJ. Coralline hydroxyapatite as an ocular implant. *Ophthalmology* 1991; 98: 370-377.
- Nunery WR, Heinz GW, Bonnin JM, Martin RT, Cepela MA. Exposure rate of hydroxyapatite spheres in the anophthalmic socket: histopathologic correlation and comparison with silicone sphere implants. *Ophthalmic Plast Reconstr Surg* 1993; 9: 96-104.
- Goldberg RA, Holds JB, Ebrahimpour J. Exposed hydroxyapatite orbital implants: report of six cases. *Ophthalmology* 1992; 99: 831-836.
- Kim YD, Goldberg RA, Shorr N, Steinsapir KD. Management of exposed hydroxyapatite orbital implants. *Ophthalmology* 1994; 101: 1709-1715.
- Remulla HD, Rubin PAD, Shore JW et al. Complications of porous spherical orbital implants. *Ophthalmology* 1995; 102: 586-593.
- Oestreicher JH, Liu E, Berkowitz M. Complications of hydroxyapatite orbital implants: a review of 100 consecutive cases and a comparison of Dexon mesh (polyglycolic acid) with scleral wrapping. *Ophthalmology* 1997; 104: 324-329.
- Jordan DR, Brownstein S, Jolly SS. Abscessed hydroxyapatite orbital implants: a report of two cases. *Ophthalmology* 1996; 103: 1784-1787.
- Blaydon SM, Shepler TR, Neuhaus RW, White WL, Shore JW. The porous polyethylene (Medpor) spherical orbital implant: a retrospective study of 136 cases. *Ophthalm Plast Reconstr Surg* 2003; 19: 364-374.
- Karesh JW, Dresner SC. High density porous polyethylene (Medpor) as a successful anophthalmic implant. *Ophthalmol* 1994; 101: 1688-1696.
- Rubin PAD, Popham J, Rumeldts S et al. Enhancement of the cosmetic and functional outcomes of enucleation with the conical orbital implant. *Ophthalmol* 1998; 105: 919-925.
- Anderson RL, Yen MT, Lucci LM et al. The quasi-integrated porous polyethylene orbital implant. *Ophthalm Plast Reconstr Surg* 2002; 18: 50-55.
- Mawn LA, Jordan DR, Gilberg S. Proliferation of human fibroblasts in vitro after exposure to orbital implants. *Can J Ophthalmol* 2001; 36: 245-251.
- Mawn L, Jordan DR, Gilberg S. Scanning electron microscopic examination of porous orbital implants. *Can J Ophthalmol* 1998; 33: 203-209.
- Jordan DR, Munro SM, Brownstein S, Gilberg SM, Grahovac SZ. A synthetic hydroxyapatite implant: the so-called counterfeit implant. *Ophthalm Plast Reconstr Surg* 1998; 14: 244-249.
- Jordan DR, Bawazeer A. Experience with 120 synthetic hydroxyapatite implants (FCI<sub>3</sub>). *Ophthalm Plast Reconstr Surg* 2001; 17: 184-190.
- Jordan DR, Pelletier C, Gilberg S, Brownstein S, Grahovac SZ. A new variety of hydroxyapatite: The Chinese Implant. *Ophthalm Plast Reconstr Surg* 1999; 15: 420-424.
- Jordan DR, Hwang I, McEachren TM et al. Brazilian hydroxyapatite implant. *Ophthalm Plast Reconstr Surg* 2000; 16: 363-369.
- Jordan DR, Brownstein S, Gilberg S et al. Investigation of a bioresorbable orbital implant. *Ophthalm Plast Reconstr Surg* 2002; 18: 342-348.
- Klett A, Guthoff R. Deckung von Orbitaimplantaten mit muskelgesteilter autologer sklera. *Ophthalmologie* 2003; 100: 449-452.
- Christel P. Biocompatibility of alumina. *Clin Orthop* 1992; 282: 10-18.
- Jordan DR, Mawn L, Brownstein S et al. The bioceramic orbital implant: a new generation of porous implants. *Ophthalm Plast Reconstr Surg* 2000; 16: 347-355.
- Jordan DR, Gilberg S, Mawn LA. The bioceramic orbital implant: experience with 107 implants. *Ophthalm Plast Reconstr Surg* 2003; 19: 128-135.
- Jordan DR, Gilberg SM, Bawazeer A. The coralline hydroxyapatite orbital implant (Bio-Eye™): experience with 170 Patients. *Ophthalm Plast Reconstr Surg* 2004; 20: 1: 69-71.
- Su GW, Yen MT. Current trends in managing the anophthalmic socket after primary enucleation and evisceration. *Ophthalm Plast Reconstr Surg* 2004; 20: 4: 274-280.
- Guillinta P, Vasani SN, Granet DB, Kikkawa DO. Prosthetic motility in pegged versus unpegged integrated porous orbital implants. *Ophthalm Plast Reconstr Surg* 2000; 19: 119-122.
- Custer PL, Kennedy RH, Woog JJ, Kaltreider SA, Meyer DA. Orbital implants in enucleation surgery, a report by the American Academy of Ophthalmology. *Ophthalmology* 2003; 110: 2054-2061.
- Custer PL, Trinkaus KM, Fornoff J. Comparative motility of hydroxyapatite and alloplastic enucleation implants. *Ophthalmology* 1999; 106: 513-516.
- Colen TP, Paridaens DA, Lemij HG et al. Comparison of artificial eye amplitudes with acrylic and hydroxyapatite spherical enucleation implants. *Ophthalmology* 2000; 107: 1889-1894.
- Kaltreider SA. The ideal ocular prostheses. Analysis of prosthetic volume. *Ophthalm Plast Reconstr Surg* 2000; 16: 388-392.
- Kaltreider SA. The ideal ocular prosthesis: analysis of prosthetic volume. *Ophthalm Plast Reconstr Surg* 2000; 16: 388-392.
- Kaltreider SA, Lucarelli MJ. A simple algorithm for selection of implant size for enucleation and evisceration. *Ophthalm Plast Reconstr Surg* 2002; 18: 336-341.
- Custer PL, Trinkaus KM. Volumetric determination of enucleation implant size. *Am J Ophthalmol* 1999; 128: 489-494.
- Thaller VT. Enucleation volume measurement. *Ophthalm Plast Reconstr Surg* 1997; 13: 18-20.
- Kaltreider SA, Jacobs JL, Hughes MO. Predicting the ideal implant size before enucleation. *Ophthalm Plast Reconstr Surg* 1999; 15: 37-43.
- Perry JD. Hydroxyapatite implants [letter]. *Ophthalmology* 2003; 110: 1281.
- Long JA, Tann TM, Bearden WH, Callahan MA. Enucleation: is wrapping the implant necessary for optimal motility 2003; 19: 194-197.
- Suter AJ, Moltano AC, Becin TH et al. Long term follow-up of bone derived hydroxyapatite orbital implants. *Br J Ophthalmol* 2002; 86: 1287-1292.
- Nunery WR. Risk of prion transmission with the use of xenografts and allografts in surgery. *Ophthalm Plast Reconstr Surg* 2003; 17: 389-394.
- Seiff SR, Chang Jr. JS, Hurt MH, Khayam-Bashi H. Polymerase chain reaction identification of human immunodeficiency virus-1 in preserved human sclera. *Am J Ophthalmol* 1994; 118: 528-529.
- Long CJ, Heckman JG, Neunderfer B. Creutzfeldt-Jakob disease via dural and corneal transplants. *J Neurol Sci* 1998; 160: 128-139.
- Hogan RN, Brown P, Heck E, Cavanagh H. Risk of prion disease transmission from ocular donor tissue transplantation. *Cornea* 1999; 18: 2-11.
- Heckman JG, Lang CJ, Petrucci F et al. Transmission of Creutzfeldt-Jakob disease via a corneal transplant. *J Neurol Neurosurg Psychiatry* 1997; 63: 388-390.
- Simonds RJ, Holmberg SD, Hurwitz RL et al. Transmission of human immunodeficiency virus type 1 from a seronegative organ and tissue donor. *N Engl J Med* 1992; 326: 726-732.
- Arat YO, Shetlar DJ, Boniuk M. Bovine pericardium versus homologous sclera as a wrapping for hydroxyapatite orbital implants. *Ophthalm Plast Reconstr Surg* 2003; 19: 189-193.
- Gayre GS, DeBacker CM, Lipham W et al. Bovine pericardium as a wrapping for orbital implants. *Ophthalm Plast Reconstr Surg* 2001; 17: 381-387.
- Pelletier C, Gilberg S, Jordan DR. Use of temporalis fascia for management of exposed hydroxyapatite implants. *Ophthalm Plast Reconstr Surg* 1998; 14: 198-203.
- Naugle TC Jr, Fry CL, Sabatier RE, Elliot LF. High leg incision fascia lata harvesting. *Ophthalmology* 1997; 104: 1480-1488.
- Kao SCS, Chen S. The use of rectus abdominis sheath for wrapping of the hydroxyapatite orbital implants. *Ophthalmic Surg Lasers* 1999; 30: 69-71.
- Naugle TC Jr, Lee AM, Haik BG, Callahan MA. Wrapping hydroxyapatite orbital implants with posterior auricular muscle complex grafts. *Am J Ophthalmol* 1999; 128: 495-501.
- Karesh JW. Polytetrafluoroethylene as a graft material in ophthalmic plastic and reconstructive surgery: an experimental and clinical study. *Ophthalm Plast Reconstr Surg* 1987; 3: 179-185.
- Choo PH, Carter SR, Crawford JB, Seiff SR. Exposure of expanded polytetrafluoroethylene-wrapped hydroxyapatite orbital implant: a report of two patients. *Ophthalm Plast Reconstr Surg* 1999; 15: 77-78.
- Kao L. Polytetrafluoroethylene as a wrapping material for a hydroxyapatite orbital implant. *Ophthalm Plast Reconstr Surg* 2000; 16: 286-288.
- Jordan DR, Allen LH, Eils A et al. The use of Vicryl mesh (polyglactin 910) for implantation of hydroxyapatite orbital implants. *Ophthalm Plast Reconstr Surg* 1995; 11: 95-99.
- Jordan DR, Eils A, Brownstein S et al. Vicryl-mesh wrap for the implantation of hydroxyapatite orbital implants: an animal model. *Can J Ophthalmol* 1995; 30: 241-246.

56. Klapper SR, Jordan DR, Punja K et al. Hydroxyapatite implant wrapping materials: analysis of fibrovascular ingrowth in an animal model. *Ophthalm Plast Reconstr Surg* 2000; 16: 278–285.
57. Gayre GS, Lipham W, Dutton JJ. A comparison of rates of fibrovascular ingrowth in wrapped versus unwrapped hydroxyapatite spheres in a rabbit model. *Ophthalm Plast Reconstr Surg* 2002; 18: 275–278.
58. Jordan DR, Klapper SR, Gilberg SM. The use of vicryl mesh in 200 porous orbital implants. *Ophthalm Plast Reconstr Surg* 2003; 19: 53–61.
59. Custer PL. Enucleation: past, present, and future. *Ophthalm Plast Reconstr Surg* 2000; 16: 316–321.
60. Custer PL. Reply to Dr D.R. Jordan's letter on polyglactin mesh wrapping of hydroxyapatite implants. *Ophthalm Plast Reconstr Surg* 2001; 17: 222–223.
61. Jordan DR, Chan S, Mawn L, Gilberg SM, Brownstein S, Hill V. Complications associated with pegging hydroxyapatite orbital implants. *Ophthalmology* 1999; 106: 505–512.
62. Edelstein C, Shields CL, DePotter P, Shields JA. Complications of motility peg placement for the hydroxyapatite orbital implant. *Ophthalmology* 1997; 104: 1616–1621.
63. Lin CJ, Lio SL, Jou JR et al. Complications of motility peg placement for porous hydroxyapatite orbital implants. *Br J Ophthalmol* 2002; 86: 394–396.
64. Jordan DR. Spontaneous loosening of hydroxyapatite peg sleeves. *Ophthalmology* 2001; 108: 2041–2044.
65. Cheng MS, Lio SL, Lin L. Late porous polyethylene implant exposure after motility coupling post placement. *Am J Ophthalmol* 2004; 138: 420–424.
66. Lee SY, Jang JW, Lew H, Kim SJ, Kim HY. Complications in motility peg placement for hydroxyapatite orbital implants in anophthalmic socket. *Jpn J Ophthalmol* 2002; 46: 103–107.
67. Jordan DR, Klapper SR. A new titanium peg system for hydroxyapatite orbital implants. *Ophthalm Plast Reconstr Surg* 2000; 16: 380–387.
68. Ainbinder DJ, Haik BG, Tellado M. Hydroxyapatite orbital implant abscess: histopathologic correlation of an infected implant following evisceration. *Ophthalm Plast Reconstr Surg* 1994; 10: 267–270.
69. Klapper SR, Jordan DR, Ells A, Grahovac SZ. Hydroxyapatite orbital implant vascularization assessed by magnetic resonance imaging. *Ophthalm Plast Reconstr Surg* 2003; 19: 46–45.
70. Cook S, Dalton J. Biocompatibility and biofunctionality of implanted materials. *Alpha Omegan* 1992; 85: 41–47.
71. Choi JC, Iwamoto MA, Bstandig S, Rubin PA, Shore J. Medpore motility coupling post: a rabbit model. *Ophthalm Plast Reconstr Surg* 1999; 15: 190–201.
72. Rubin PAD, Fay AM, Remulla HD. Primary placement of motility coupling post in porous polyethylene orbit implants. *Arch Ophthalmol* 2000; 118: 826–832.
73. Hsu WC, Green JP, Spilker MH, Rubin PAD. Primary placement of a titanium motility post in a porous polyethylene orbital implant. *Ophthalm Plast Reconstr Surg* 2003; 16: 370–379.
74. Tawfik HA, Dutton JJ. Primary peg placement in evisceration with the spherical porous polyethylene orbital implant. *Ophthalmology* 2004; 111: 1401–1406.
75. Timothy NH, Feilich DE, Linberg JV. Perspective: evisceration versus enucleation, the ophthalmologist's standpoint. *Ophthalm Plast Reconstr Surg* 2003; 19: 6: 417–420.



# Principles of orbital surgery

José Perez-Morerias, Javier Coloma and Consuelo Prada

## INTRODUCTION

The history of modern orbital surgery began in 1888 when Krönlein described the lateral orbitotomy, which involved removal of the lateral orbital wall to access the orbital cavity. Prior to this historic event, attempts to approach orbital lesions often implicated removal of the globe with unavoidable loss of vision. Berke and Reese modified the temporal Krönlein approach, making the incision straight from the lateral canthus to auditory canal.<sup>1</sup> In 1968 Stallard, and years later, Wright, popularized the S-shaped incision for lateral orbitotomy, avoiding damage to the frontal branches of the facial nerve.<sup>2</sup> In 1971 Smith and Reese reported combined conjunctival approach and lateral orbitotomy for removal of intraconal orbital tumors. In 1975 and 1976 Wright and Kenderdell, respectively, introduced more sophisticated instrumentation for orbital surgery.

Recent advances in the diagnostic and therapeutic areas have extended our knowledge of orbital pathology. Computed tomography (CT), magnetic resonance (MR) imaging, and high-resolution ultrasonography have allowed surgeons to localize orbital tumors and to establish the relationships with vital structures of the orbit. These techniques have also permitted the surgeon to infer possible histology based on imaging characteristics to allow for a better surgical plan.

## MICROSURGICAL PRINCIPLES

Surgery for orbital tumors should allow for treatment with conservation of function and cosmesis. Although the main goal of surgery is removal of the tumor and preservation of function, optimal treatment must occasionally sacrifice function or cosmesis. With these principles in mind, any surgical approach must offer optimal visualization of the very delicate structures of the orbit.

## INSTRUMENTATION

For more than 20 years we have used a wide-field surgical microscope with a 250 mm focal length lens (such as the Zeiss OPMI 111 or any ENT/neurosurgical microscope) using 0.4–1.0× magnification for all orbital procedures. The use of the endoscope has been proposed, but the lack of binocularity and stereopsis, as well as the impossibility of using expansive solutions inside the orbit, have hindered its use. Surgical loupes are employed by many surgeons to provide less cumbersome magnification, but these may be quite heavy and they often do not provide the required quality and amount of magnification for use in the orbit, especially in the intraconal space and orbital apex. Loupes also require the use of a headlight aligned with the surgeon's visual axis, which may be a hindrance for the surgical assistant. We have also

found that loupes allow for easier surgeon mobility around the patient's head and are more useful for oculoplastic and anterior orbital surgery. We strongly recommend the use of a microscope for all cases of orbital surgery, especially for intraconal and orbital apex lesions, where it provides the benefits of magnification, coaxial light illumination, and the possibility of at least two assistants, allowing for better surgical assistance.<sup>3</sup>

The use of surgical microscopes,<sup>4</sup> the possibility of having two assistants during surgery, and improved instrumentation permit small incisions and the avoidance of osteotomy, allowing a microsurgical approach for the great majority of orbital surgery. The microsurgical approach also requires expert anesthetists, and collaboration with other surgical specialists is sometimes needed.

## ANESTHESIA

**Monitored anesthetic care** When an anesthesiologist monitors a patient receiving local anesthesia with or without sedative–analgesic drugs, the technique is known as monitored anesthetic care (MAC). MAC provides for patient comfort and safety by relieving anxiety and producing intraoperative amnesia, and also providing relief from pain and other noxious stimuli, without interfering with the patient's ability to communicate verbally or protect their airway. However, monitoring devices and emergency systems must be available during MAC. Surgery under MAC offers many advantages, including preservation of protective reflexes, decreased postoperative pain, nausea and vomiting, reduced cardiovascular and respiratory side effects, and faster recovery. MAC is often used for anterior orbital or conjunctival surgery.

**General anesthesia** Retrobulbar, intraconal, and apical lesions are typically approached with the patient under general anesthesia. Because orbital surgery is often performed with a surgical microscope, it is essential to keep the surgical field free of blood. The anesthesiologist can help with hemostasis by carefully controlling the blood pressure intraoperatively. Typically the goal is to keep the mean arterial pressure about 25% lower than preoperative level.

## INDICATIONS FOR SURGERY

The basic indications for oncological surgery of the orbit are incisional biopsy, excisional biopsy, and exenteration. Other indications for orbital surgery include abscess drainage, orbital decompression, and orbital reconstruction in trauma, but these aspects are beyond the scope of this chapter.

Around 20% of orbital diseases require a diagnostic biopsy. Well-defined, slowly enlarging encapsulated masses causing optic neuropathy with only globe displacement or axial proptosis often result from a benign lesion that typically requires surgical excision. On the other hand, poorly defined masses, with indefinite borders and functional signs, often result from malignant lesions that may require adjuvant therapy. In these cases, often only incisional biopsy is indicated. Exenteration is a mutilating surgery with the objective of removing orbital structures in order to excise a malignant lesion that cannot otherwise be controlled, to prevent extension to the central nervous system or other adjacent regions.

Biopsy can be performed by taking a small fragment of the lesion (incisional), or by removing all or most of it (excisional) without injury to underlying orbital structures. When biopsy is performed to confirm a suspected diagnosis (new disease or relapse of a previous disease) the specimen can be taken to the pathologist after completion of the procedure; if biopsy is required for diagnosis, the specimen must be sent to the laboratory during the procedure, and surgery can continue or stop depending on the results. The biopsy specimen must be handled delicately to avoid artifacts that can hinder analysis by the pathologist, especially when a lymphoid lesion is suspected. To prevent surgical artifacts the surgeon should use blunt instruments, minimize the use of electrical or thermal instruments, and employ delicate forceps to avoid crushing the tissue.

Needle biopsy, introduced by Schyberg in 1975, with prior CT or MRI, can be used for anterior tumors with little connective tissue, such as suspected lymphoma, metastasis, carcinoma, and inflammatory diseases. A pathologist specializing in cytology must be readily available.<sup>5</sup>

**SURGICAL TEAM**

Orbital surgery is not served by a unified, cohesive medical infrastructure, as orbital surgeons are more artisans than surgeons. For these reasons, surgical specialties, such as maxillofacial, otorhinolaryngology (ENT), neurosurgery, and plastic surgery, include orbital and eyelid surgery in their training. Understanding that the orbit is in proximity to vital structures, such as the paranasal sinuses and CNS,

as well as the eye, we strongly believe that orbital surgeons should work in collaboration, not in competition, with other specialties. We believe that ophthalmologists are best suited to lead the orbital surgery subspecialty, as they have the most surgical training and knowledge of orbital anatomy, functionality, and relationship with the ocular globe.

**PLANNING THE SURGICAL APPROACH**

The surgeon must plan the approach based on the examination and diagnostic images to correctly develop the surgery. Many aspects must be considered to correctly plan orbital surgery.

**Tumor location** is one of the most important aspects. Tumors located anterior to the equator of the globe (tumors that cause more displacement than exophthalmos) can often be excised under local anesthesia. If the tumor is localized in the extraperiosteal space, the surgeon should preserve the periosteum without disruption of the orbital cavity. On the other hand, intraconal (intraperiosteal) tumors require blunt dissection of the soft tissue of the orbit.

**Relationship to adjacent structures** The second most important aspect of proper surgical planning is the relationship between the tumor and adjacent structures. For intraconal tumors, the optic nerve determines the approach (Table 99.1); the surgeon should attempt to approach the tumor opposite to the nerve. For example, if the lesion displaces the nerve inferiorly and laterally, the surgical approach should be from the superior and medial aspect of the orbit. This principle uses the mass to buffer and protect the optic nerve. Once the tumor is reached, the surgeon will apply traction on the lesion toward the approach incision, moving the lesion away from the nerve to avoid potential injury. When the tumor is not arising from the nerve or when it is not firmly attached, orbital fat prolapses between the tumor during dissection, keeping dissecting instruments away from the nerve.

The relationship of the tumor to the extraocular muscles is also important when planning a surgery in order to avoid muscle injury and consequent postoperative diplopia.

Table 99.1 Surgical approaches to orbital tumors		
	Location	Approach
Extraconal	Superior	Upper eyelid crease incision
	Inferior	Conjunctiva subtarsal incision
Intraconal	Medial–superior (ON displaced inferiorly)	Upper eyelid crease incision (internal)
	Lateral–superior (ON displaced inferiorly)	Upper eyelid crease incision (whole)
	Lateral–inferior (ON displaced superiorly)	Conjunctiva–tarsal incision (lateral)
	Medial–inferior (ON displaced superiorly)	Conjunctiva–tarsal incision (medial)
Apical	Superior	Medial eyelid crease incision Lateral eyelid crease incision
	Inferior	Conjunctiva–tarsal incision
	Superior or inferior	Transfrontal approach

ON, optic nerve.

**Tumor margins** must be known precisely to determine the extent of surgery and the potential degree of secondary damage from surgical intervention. Tumor margins also determine whether the tumor can be completely excised. Well-defined lesions can often be resected en bloc, but in some instances large tumors, ill-defined tumors, or tumors that will require adjuvant medical therapy require only partial excision to avoid collateral injury. Adherences between the mass and surrounding structures are very important; apical lesions tend to have firm adherences, making removal more difficult and increasing the risk of collateral injury.

**Tumor composition** Imaging studies (ultrasonography, MRI, and CT) assist in predicting the histopathology of the mass, especially for well-defined tumors (capsulated, round, oval), and these studies play a fundamental role in determining the need for an osteotomy. Tumors with a myxoid component, such as schwannomas with a pseudocapsule, or cystic lesions with true capsules, can often be drained to reduce their size through a keyhole incision prior to excision without osteotomy. Once the mass has been reached and isolated, an opening in the capsule/pseudocapsule can be made to extract the internal component using a blunt spoon, and the capsule/pseudocapsule can then be excised by freeing adherences using blunt dissection from the adjacent tissues. An ultrasonic fragmentation device, such as the Cavitron ultrasonic aspirator (Valley Labs, Richmond Hill, Ontario, Canada), may be useful, but longer tips are required for posterior tumors, which limit its use. Other well-defined tumors, such as cavernous hemangiomas and lymphangiomas, can be excised in a similar way. These tumors are reached and isolated, and an incision is made in the pseudocapsule to aspirate the contents and reduce the size enough to allow for removal through a small incision. Drainage often reduces cavernous hemangiomas more dramatically in younger patients than in older patients owing to the less solid nature of the tumor in the younger age group. Using these techniques a great majority of orbital tumors can be excised completely, without the need for an osteotomy. Some tumors, such as pleomorphic adenomas, have the potential to recur or undergo malignant transformation if the capsule is violated, and these lesions must be excised en bloc. For large or ill-defined lesions where a biopsy is mandatory and osteotomy is not needed, internal structure can aid in the diagnosis but is not essential for surgical planning.

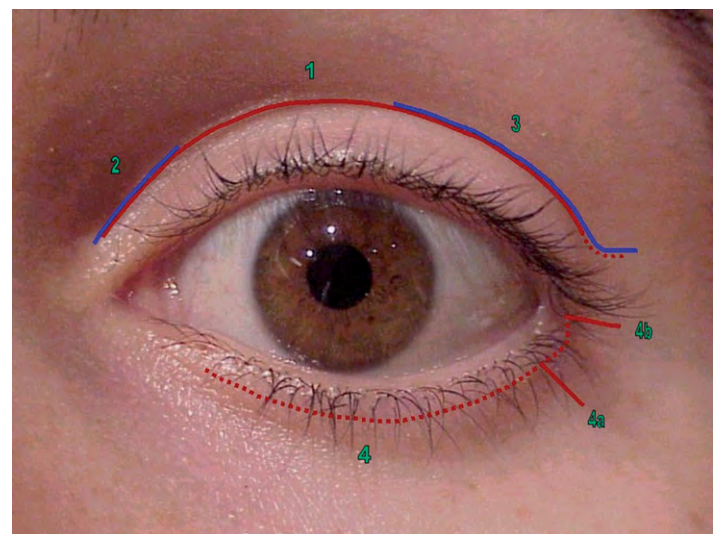
## MICROSURGICAL APPROACH TO THE ORBIT

**Conjunctival approach** Bulbar conjunctival incisions are typically reserved for tumors anterior or just posterior to the equator of the globe, generally for small biopsies. A periostomy is made, avoiding damage to limbal stem cells, and dissection is performed until the tumor is reached.

**Caruncular approach** A caruncular approach can be used for removal of tumors located adjacent to the medial wall of the orbit.

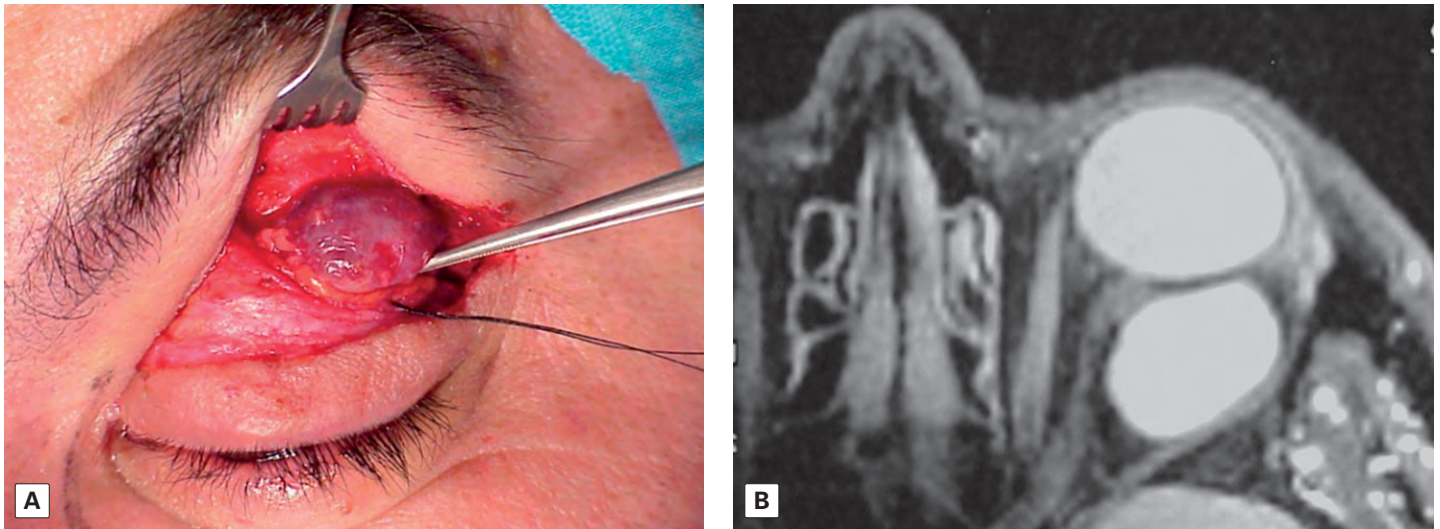
**Perez-Morerias approach** Although this approach is preferred by some authors for orbital decompression, we prefer the Perez-Morerias approach for decompression of the medial wall and floor (beside the infraorbital rim) through a medial superior eyelid crease incision.<sup>6,7</sup> We have performed more than 500 orbital decompressions through this approach, with good outcomes.

**Superior orbitotomy** Whenever possible, incisions are made following relaxed skin tension lines. The use of a microscope allows for very small incisions to avoid deforming scars (Fig. 99.1). Superior orbitotomy is performed for tumors located in the superior orbit, or for intraconal masses that displace the optic nerve inferiorly. The incision is made in the upper eyelid crease for tumors located along the orbital roof, the lacrimal fossa or posteriorly, and the superomedial intraconal space (Fig. 99.2). For the latter, the incision extends along the whole length of the superior eyelid crease, and a plane between the orbicularis and orbital septum is dissected to the superior orbital rim. The periosteum is incised approximately 2 mm superior to the rim and is dissected from the bone to expose the entire orbital roof. The supra-orbital neurovascular bundle must be respected (and can be dissected, but this is seldom necessary) to avoid postoperative frontal hypoesthesia. At this point the periorbita is incised 2 mm posterior to the arcus marginalis to access the intraconal space and expose the tumor.<sup>8</sup> When a lacrimal gland tumor is removed using this approach, an osteotomy is usually not necessary (Fig. 99.3). For lateral osteotomy, once the zygomaticofrontal process has been exposed, dissection must continue within the temporal fossa between the muscular fascia and the temporal skin layer. An incision in the periosteum at the lateral and external border of the zygomaticofrontal process is made to dissect the temporalis muscle, and the periosteum is detached. Relaxing incisions in the muscle may allow for better mobilization of the temporalis muscle.<sup>9</sup> Osteotomy is performed using an oscillating saw at the necessary level according to tumor location. Lateral osteotomy has not been needed for resection of any tumor in our center for several years. The superonasal approach for intraconal tumors requires an incision in only the medial aspect (10–15 mm) of the superior eyelid crease (Fig. 99.4). A small dissection of the orbicularis from the septum is recommended in order to facilitate exposure. The septum is then transected and the medial fat pad is reached. This allows for access medial to the levator muscle, between the aponeurosis and the medial wall. Prolapsing fat can be coagulated using 20 W without causing significant iatrogenic injury; blunt dissection through the orbital fat pads is used until the tumor is reached. It is important to gently displace the superior oblique tendon upward with an orbital retractor in order to avoid

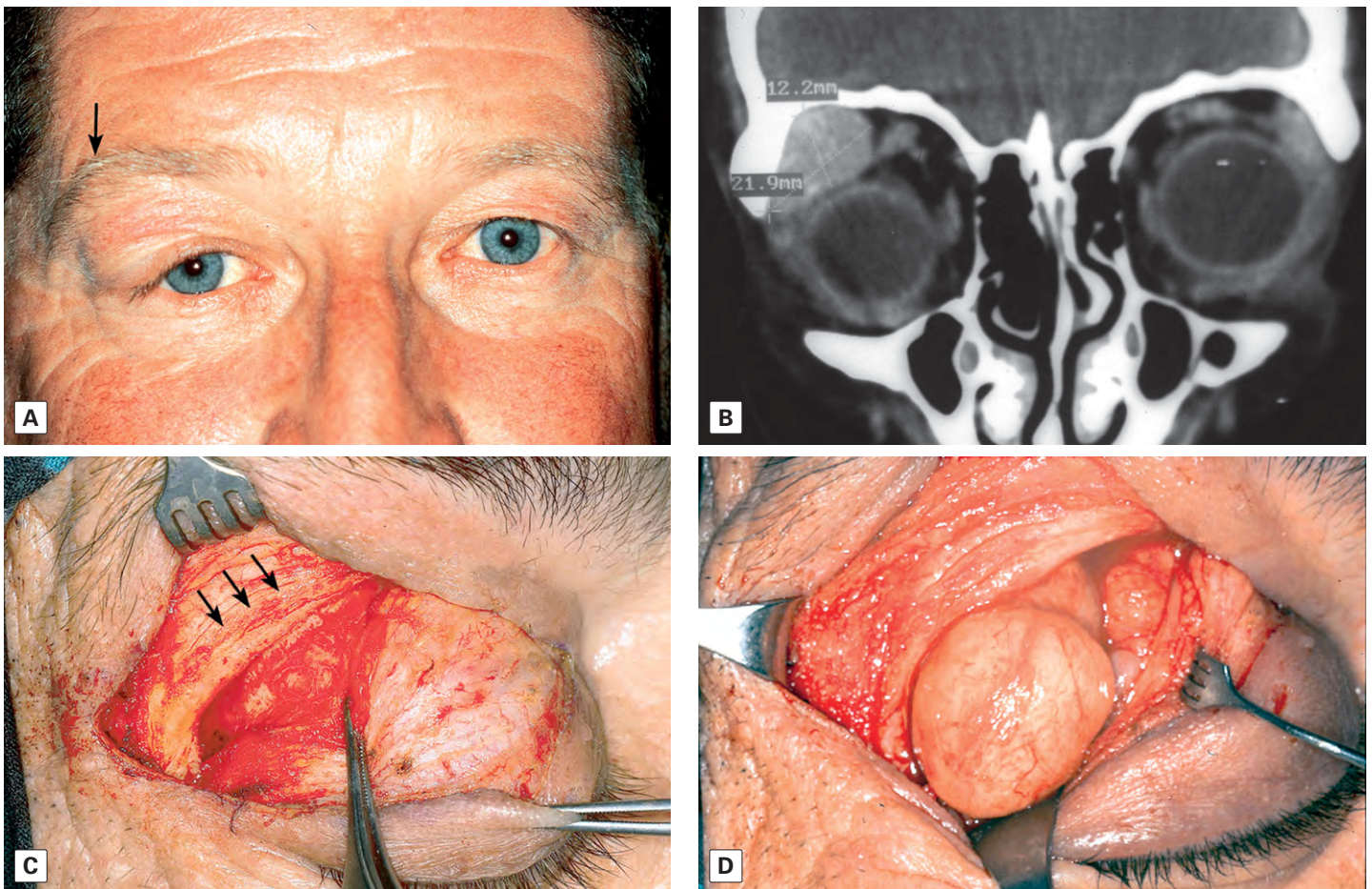


**Fig. 99.1** Incisions for orbital surgery. Eyelid crease incision (1), medial (2) and, external (3). Conjunctival incisions (4, dotted line) sub tarsal incision with tarsectomy (4a) and canthotomy–cantholysis (4b).



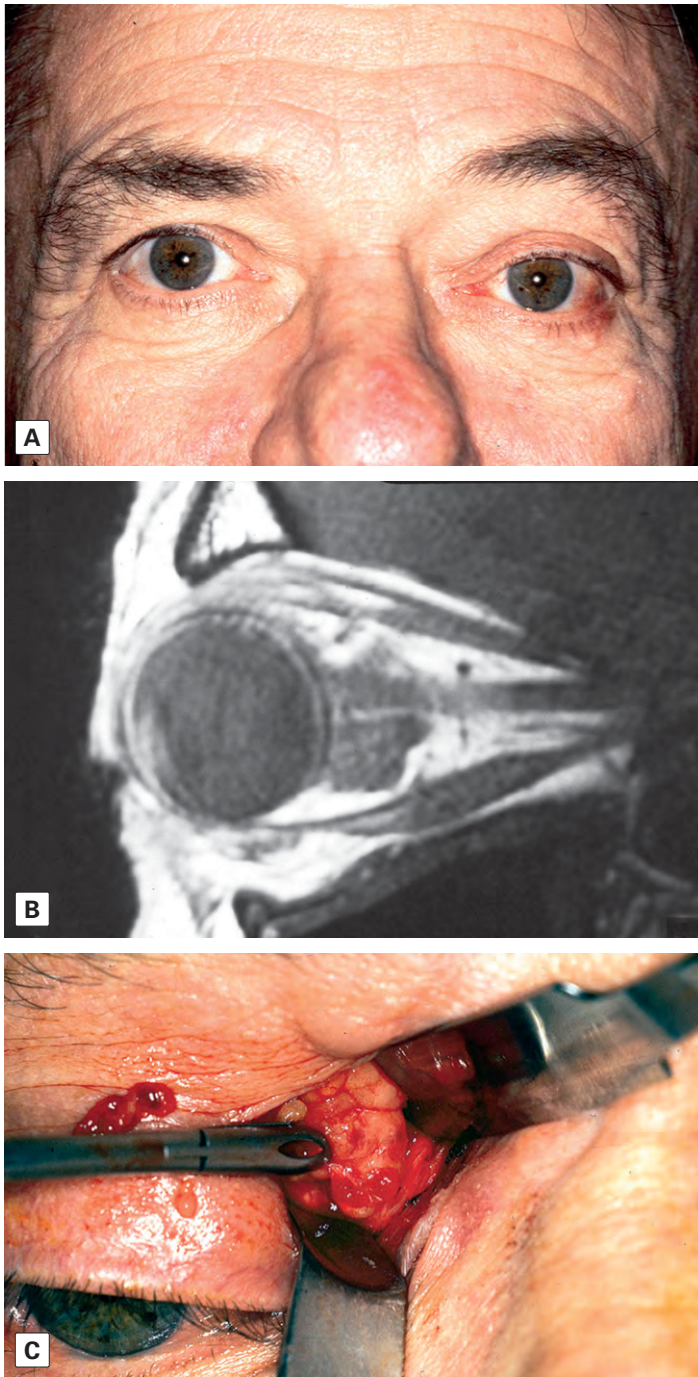


**Fig. 99.2** Superotemporal approach for intraconal tumor (A). MRI (axial view) shows the intraconal tumor with medial displacement of the optic nerve (B).



**Fig. 99.3** Lacrimal gland tumor (pleomorphic adenoma). Clinical appearance (A). CT scan showing a mass expanding the lacrimal fossa (B). Periosteum (arrows) is incised 2 mm from the orbital rim (C), and the tumor is removed en bloc without osteotomy (D).

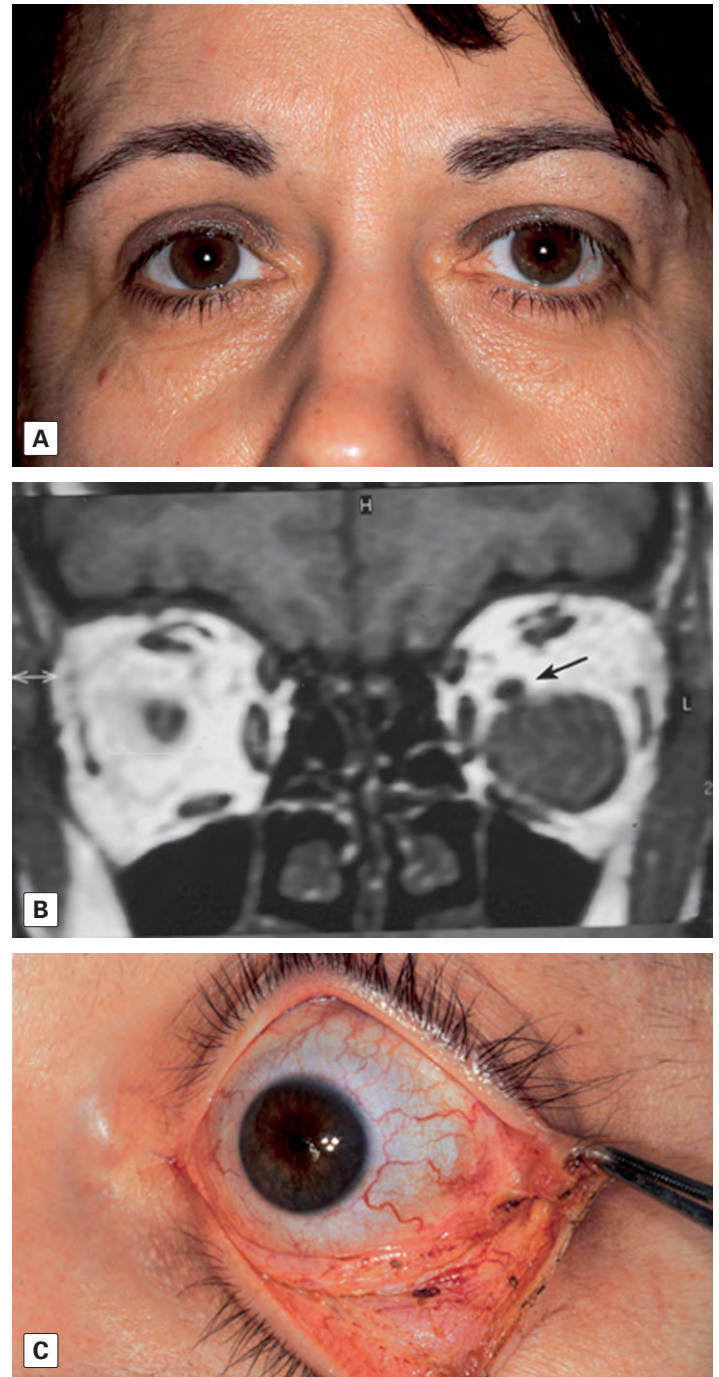




**Fig. 99.4** Superomedial approach for intraconal tumor. Clinical appearance (A). MRI shows an ill-defined retrobulbar intraconal mass suggestive of lymphoma. Orbital biopsy via superomedial approach (C).

any damage to this structure. This approach allows for excellent exposure of the superomedial intraconal space.

**Inferior orbitotomy** We prefer inferior orbitotomy through a transconjunctival approach, as the subciliary approach offers no advantages and risks lid retraction and external scarring. The conjunctiva is incised below the tarsal plate in order to detach the retractors from the tarsus. This approach can be performed with or without lateral canthotomy/cantholysis, depending on underlying tissue laxity. If the surgeon prefers to respect lateral canthus anatomy a tarsectomy can be performed. Once the retractors are detached, blunt dissection between the septum and the orbicularis is performed inferiorly, toward the

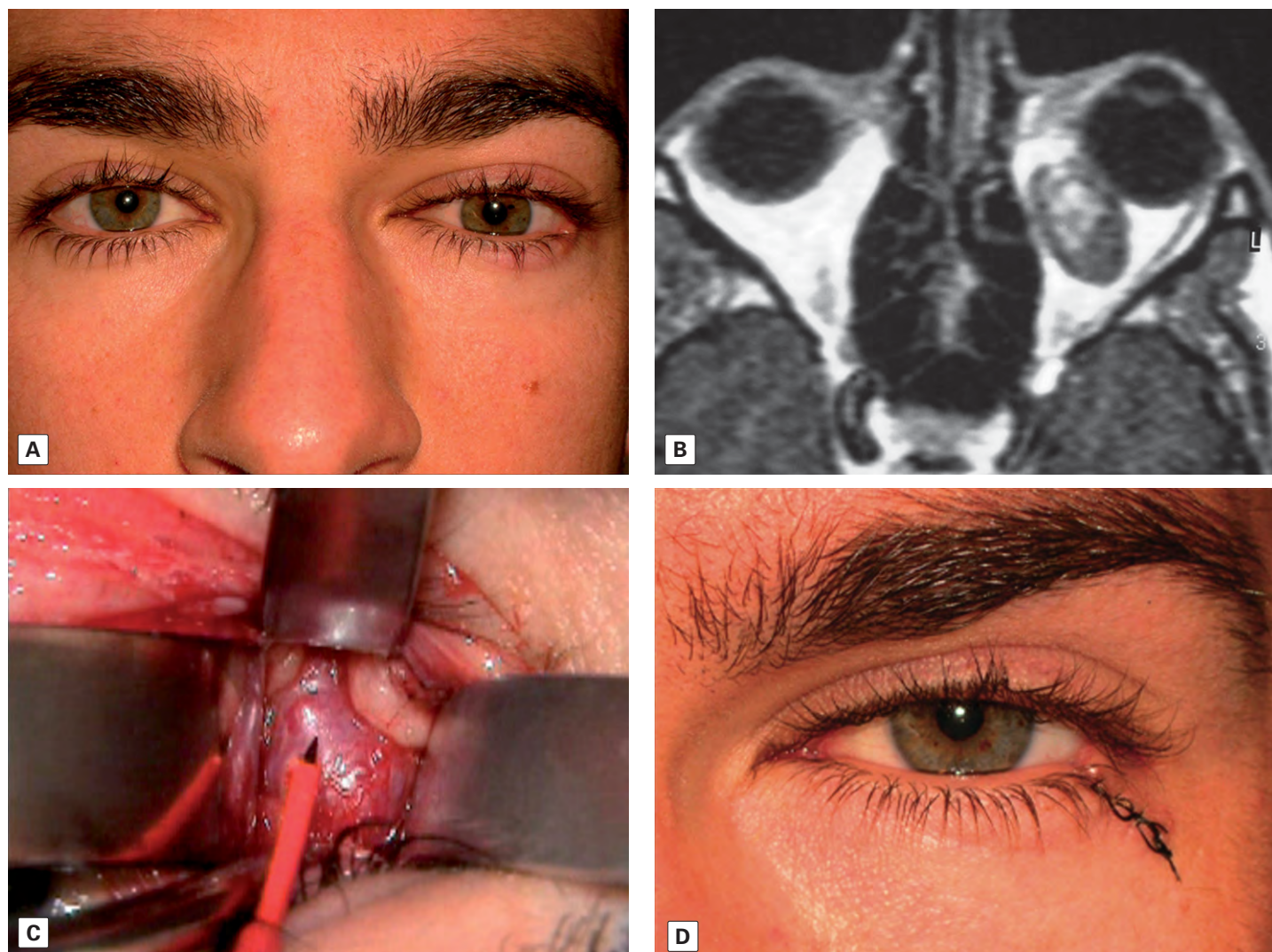


**Fig. 99.5** Inferolateral conjunctival approach for intraconal tumor. Clinical appearance (A). MRI is suggestive of cavernous hemangioma that has displaced optic nerve superomedially (arrow) (B). Inferolateral conjunctival approach with tarsectomy (C).

inferior orbital rim. With the septum widely exposed, we can access the intraconal and extraconal spaces of the inferior and inferolateral orbit, where no important anatomical structures exist (Fig. 99.5). Such an approach also permits access to the inferomedial intraconal space; however, this space is very narrow and careful dissection must be performed to avoid injury to the inferior oblique muscle (Fig. 99.6).

Tumors of the orbital apex must be removed by a superior eyelid crease or inferior conjunctival approach. A lateral osteotomy can be performed to allow for greater lateral retraction and access, but a lateral





**Fig. 99.6** Inferomedial conjunctival approach for intraconal tumor. Clinical appearance (A), MRI suggestive of a cavernous hemangioma (B), inferomedial conjunctival approach with tarsectomy (C), and 1 week postoperative appearance (D).

osteotomy alone does not offer significant access to the orbital apex. A transfrontal craniotomy approach may be an alternative for some tumors of the orbital apex.

### SUMMARY

Following relaxed skin tension lines and hidden conjunctival incisions allows for access to nearly all orbital tumors. The use of a surgical

microscope with improved instrumentation, and appropriate knowledge of orbit anatomy allows for preservation of surrounding vital structures. With these tools, the great majority of orbital tumors can be safely removed without the need for osteotomy, as has been the rule in our center for 15 years. The microsurgical approach also requires expert anesthetists, and collaboration with other surgical specialists is sometimes needed.

### REFERENCES

1. Reese A. Tumors of the eye, 3rd edn. New York; Harper & Row, 1976; 459–464.
2. Wright JE. Orbital surgery. In: Ophthalmic plastic surgery, 3rd edn. San Francisco American Academy of Ophthalmology, 1977.
3. Nerad J. Oculoplastic surgery. The requisites in ophthalmology. In: Surgical approaches to the orbit. St Louis: Mosby, 2001; 387–418.
4. Alio J, Eiras J, Rabinal F et al. Microcirugía de los tumores orbitarios. Arch Soc Esp Oftalmol 1982; 43–2: 226–237.
5. Rootman J. Diseases of the orbit: a multidisciplinary approach, 2nd edn. Philadelphia: Lippincott Williams & Wilkins, 2003; 385–416.
6. Pérez Morerías JV et al. Capítulo 41, Oftalmopatía Distiroidea. In: Pérez Morerías JV, Prada Sanchez MC. Patología orbitaria, Vol 2. Barcelona: Edika-Med, 2002; 949–1033.
7. Moreiras JV, Coloma J, Prada MC, Adenis JP. Thyroid orbitopathy. In: Moreiras JV, Prada MC. Orbit: examination, diagnosis, microsurgery, pathology, Vol II. Highlights of Ophthalmology 2004; 949–1036.
8. Moreiras JV, Coloma J, Prada MC et al. Microsurgical approaches for tumors of the orbit. In: Moreiras JV, Prada MC. Orbit: examination, diagnosis, microsurgery, pathology, Vol II. Highlights of Ophthalmology 2004; 1039–1118.
9. Rootman J, Stewart B, Goldberg RA. Orbital surgery: a conceptual approach. Philadelphia: Lippincott-Raven, 1995; 151–289.



# Index

- A**
- actinic (solar) keratosis 70, 132
  - actinomycin D 52
  - adenocarcinoma
    - ciliary pigment epithelium 368–9
    - retinal pigment epithelium 362
  - adenoid squamous cell carcinoma 139
  - adenoma
    - ciliary pigment epithelium 368–9, 370
    - retinal pigment epithelium 362
  - adnexal glands 62
  - adnexal tumors 64
    - eyelid 94–8
      - classification 94
      - cystic lesions 94
      - hair follicle tumors 97
      - sebaceous gland tumors 97–8
      - sweat gland tumors 94–6
    - lymphoma *see* ocular adnexal lymphoma
  - adriamycin 51, 52
  - aflatoxins 9
  - AIDS, and OSSN 136
  - alcohol 6
  - alveolar soft part sarcoma 571–2
  - amyloidosis 165, 167, 168
  - anesthesia 592
  - aneurysmal bone cyst 546, 547
  - angiogenesis 16–24, 32–3
    - antiangiogenic therapy 19
    - inhibitors 18–19
      - endogenous 18
      - pharmaceutical 18–19
    - metastatic cascade 16
    - promoters 16–18
      - angiopoietins 18
      - fibroblast growth factor 17–18
      - vascular endothelial growth factor 16–17
    - specific ophthalmic tumors 19–23
    - steps in 16
    - tumor angiogenesis 16
    - tumor vessels 16
  - angiogenic switch 16
  - angiopoietins 18
  - angiosarcoma 103
  - anisocoria 505
  - anterior visual pathway glioma 549–51
    - clinical features 549, 550
    - diagnostic evaluation 549
    - histopathology 549–50
    - prognosis 551
    - treatment options 550–1, 551
  - anthracyclines 51, 52
  - antiangiogenic therapy 19–23
  - antibodies against uveal melanoma 29
  - antilymphocyte antibody 569
  - antiostatin 18
  - anti-VEGF agents 18–19
  - apocrine gland adenocarcinoma 96
  - apocrine hidrocystoma 94–5
  - apoptosis 31–2
  - argon laser 37
  - arteriovenous malformations 103
  - L-asparaginase 51, 52
  - astrocytic hamartoma 489
  - astrocytoma, acquired 356–7
  - ataxia-telangiectasia 397–8
- B**
- bacteria 9
  - Bannayan-Riley-Ruvalcaba syndrome 164
  - basal cell carcinoma 76–9
    - clinical features 76, 77
    - differential diagnosis 78, 87, 90–1
    - etiology 76
    - follow-up 79
    - histopathologic features 76–8
    - metastases 79
    - mortality 79
    - orbit 574
    - pathogenesis 76
    - prognosis 79
    - recurrence 79
    - treatment 78–9
      - chemotherapy 79
      - cryotherapy 79
      - curettage and electrodesiccation 79
      - radiotherapy 79
      - surgical excision 79
  - Bcl-2 32
  - bear tracks 358, 359
  - behavioral exposure 6
  - benign epidermal tumors 67–74
    - melanocytic 71–3
      - epithelial pigmentation 71
      - melanocytic nevus 71–3
    - melanocytic premalignant epidermal tumors 73–4
    - non-melanocytic 67–9
      - inverted follicular keratosis 67
      - keratoacanthoma 67–8
      - reactive hyperplasia 68–9
      - seborrhic keratosis 67
      - squamous cell papilloma 67
    - non-melanocytic premalignant 69–71
      - actinic (solar) keratosis 70
      - intraepithelial neoplasia 70–1
      - non-specific keratosis 69–70
      - sebaceous nevus (of Jadassohn) 71, 97
  - benign melanocytic uveal tumors 185–97
    - choroidal nevus 187–90
    - ciliary body nevus 190
    - iris nevus 185–7
    - melanocytoma 194–6
    - melanocytosis 190
    - optic disc melanocytoma 190–4
  - benign orbital tumors 539–47
    - aneurysmal bone cyst 546, 547
    - cholesterol granuloma 541
    - dermoid and epidermoid cysts 155, 513, 517, 518, 539–40, 540
    - fibrous dysplasia 546
    - fibrous histiocytoma 543, 545
    - meningioma 543, 544
    - mucocele 540–1, 541
    - neurilemmoma (schwannoma) 542–3, 542
    - neurofibroma 542–3
    - orbital cephalocele 541–2
    - osteoma 545, 546
    - teratoma 543
  - bevacizumab 18
  - bias 3
  - bilateral diffuse uveal melanocytic proliferation 380–1
  - bilateral melanoma 208
  - Bio-Eye implant 586, 587
  - biopsy 60
    - diagnostic 107
    - lacrimal sac tumors 560
    - metastatic uveal tumors 323–5
    - orbital tumors 522, 526–7
    - sentinel lymph node 107
  - blastoma 11
  - blue nevus 71, 133
  - bone erosion 510
  - bone infiltration 510
  - bone lysis 510
  - bone molding 510

- brachytherapy** 43  
 OSSN 139  
 radionuclides 242  
 retinoblastoma 455, 457–8, 459  
 uveal melanoma 241–7  
   collateral damage 243–4  
   combined treatment 243  
   follow-up 242–3  
   local tumor recurrence 244–5  
   ocular conservation 246–7  
   plaque modifications 243  
   plaque positioning 242  
   preoperative assessment 241–2  
   radiation 241  
   radiation safety 243  
   survival 246  
   visual outcome 244
- BRCA** 32
- C**
- café au lait spots** 385, 387
- calcifying epithelioma of Malherbe** 97
- camptotecans** 51
- cancer-associated retinopathy** 378–9
- cancer etiology** 6–10  
   carcinogenic agents 6  
   chemical carcinogens 6  
   dietary factors 9  
   genetic susceptibility 9  
   iatrogenic cancers 9  
   microbial agents 8–9  
   ultraviolet light 6–8
- cancer pathology** 11–15  
   classification of neoplasia 11  
   diagnostic techniques 14–15  
   metastatic process 13  
   microscopic features 11–13  
   research techniques 15  
   tissue sampling and processing 13–14
- capillary hemangioma**  
   conjunctiva 150  
   eyelid 101–3  
   orbit 511, 512, 535–6, 536  
   magnetic resonance imaging 511, 512
- carboplatinum** 51, 52  
   retinoblastoma 450, 480  
   structure 450
- carcinogenic agents** 6
- carcinoma** 11  
   adenoid squamous cell 139  
   basal cell *see* basal cell carcinoma  
   glands of Moll 96  
   Merkel cell 104, 575, 576  
   mucoepidermoid 139  
   sebaceous 574–5  
   sebaceous gland *see* sebaceous gland carcinoma  
   in situ 138  
   spindle cell 139  
   squamous cell *see* squamous cell carcinoma
- Carney complex**  
   conjunctival/corneal tumors 162  
   eyelid tumors 118–19, 121
- cartilaginous tumors** 518
- caruncle** 125
- caruncular tumors** 128, 135
- case-control studies** 4
- case series** 4
- cataract, brachytherapy-induced** 243
- cavernous hemangioma**  
   conjunctiva 150  
   eyelid 103  
   orbit 536–7, 537
- celecoxib** 19
- cell proliferation antigens** 224
- cellular differentiation** 12
- cellular proliferation** 11–12
- central nervous system**  
   hemangioma 389  
   lymphoma 372–6  
     clinical features 372  
     diagnostic evaluation 372–4  
     differential diagnosis 374–5  
     pathogenesis 372  
     prognosis 376  
     treatment 375–6
- cephalocele, orbital** 541–2
- ceramic orbital implants** 587, 588
- cerebellar ataxia** 397
- chalazion** 87
- chemoembolization** 285
- chemotherapy** 9, 50–3  
   anterior visual pathway glioma 551  
   cell generation cycle 50, 51  
   clinical trials 51–2  
   combination regimen 50  
   drug development 51  
   drug resistance 50–1  
   mechanism of action 50  
   metastatic uveal tumors 325  
   multimodality therapy 52  
   ocular adnexal lymphoma 569  
   retinoblastoma 449–52, 501–2  
   side effects 52  
   tumor cell kinetic model 50
- children**  
   counseling 56–7  
   infantile capillary hemangioma 511, 512, 535–6, 536  
   orbital tumors 520–3  
     biopsy 522  
     diagnostic imaging 521–2, 521, 522, 522  
     examination 520–1, 521, 521  
     history 520  
     laboratory evaluation 521  
     metastases 578, 579  
     retinoblastoma *see* retinoblastoma  
     rhabdomyosarcoma 581–4
- Children's Oncology Group** 491–4  
   committee on retinoblastoma 491  
   establishment of 491  
   retinoblastoma protocols 491–4
- Chimmelpenning-Feuerstein-Mims syndrome** *see* nevus sebaceous (of Jadassohn)
- Chlamydia psittaci*** 9
- cholesterol granuloma** 541
- choristoma** 11  
   complex 156  
   conjunctiva/cornea 128, 155–6, 157
- eyelid** 104–5  
   osseous 156
- choroid**  
   in leukemia 330  
   lymphoma *see* primary choroidal lymphoma  
   tears 262
- choroidal atrophy** 244
- choroidal granuloma, differential diagnosis** 293
- choroidal hemangioma** 213, 215  
   circumscribed 289–97  
     clinical features 289  
     diffuse 297–8, 392–3  
     diagnostic evaluation 291–4  
     differential diagnosis 289, 291  
     treatment 294–7
- choroidal melanocytoma** 194–6
- choroidal melanoma** 207–10, 212–16  
   alterations of retina 208  
   alterations of retinal pigment epithelium 208–9  
   clinical features 207  
   diagnostic features 212  
   differential diagnosis 212–16, 293  
   extrascleral extension 209–10  
   inflammatory reaction 209  
   intraocular pressure 209  
   optic nerve invasion 210  
   pigmentation 208  
   site of origin 208  
   size and shape 207  
   symptoms 207  
   variants 208
- choroidal metastases** 213  
   differential diagnosis 293
- choroidal nevus** 187–90, 199  
   clinical features 189  
   differential diagnosis 212–13  
   growth rate 188  
   prevalence 187  
   risk factors 190
- choroidal osteoma** 305–6
- chromosome 13q14- deletions** 443
- ciliary body**  
   hemangioma 289  
   melanocytoma 184  
   melanoma 205–7  
     annular (ring) 207  
     circumscribed 205, 207  
   nevus 190  
   tumors 216–17
- ciliary pigment epithelium tumors** 366–71  
   acquired tumors 367–9  
     adenoma and adenocarcinoma 368–9  
     pseudoadenomatous hyperplasia 367–8  
   anatomy 366  
   classification 366  
   congenital tumors 366–7
- ciliochoroidal tumors** 216–17
- cisplatinum** 51, 52
- clinical epidemiology** 1–5  
   bias 3  
   measures of association 1–3  
   outcome measures 1  
   precision of estimate 3

- research question 1
  - study designs 3–5
  - clinical trials 51–2**
  - Coats' disease 348–52**
    - clinical features 348
    - diagnostic evaluation 348–50
    - differential diagnosis 350–2
    - etiology and pathogenesis 348
    - prognosis 352
    - treatment 352
  - cobalt gray equivalents 42**
  - Cogan-Reese syndrome 185**
  - cohort studies 4**
  - Collaborative Ocular Melanoma Study 267–71**
    - adjunct studies 270
    - classification of choroidal melanoma 267
    - eligibility and exclusion criteria 267
    - enucleation alone versus pre-enucleation irradiation 269–70
    - enucleation versus brachytherapy 267–9
    - natural history observational study 270
    - screening for metastases 270–1
    - small choroidal melanoma observational study 267
  - color Doppler imaging**
    - orbital tumors 507
    - uveal tumors 178
  - complex choristoma 156**
  - complexion-associated conjunctival pigmentation 134**
  - compound nevus 133**
  - computed tomography**
    - choroidal osteoma 305, 308
    - helical 507, 509
    - orbital tumors 507–8, 508, 509
    - sclerochoroidal calcification 308
    - three-dimensional 507–8
    - uveal tumors 179
  - COMS *see* Collaborative Ocular Melanoma Study**
  - conformal radiotherapy 42–3, 465**
  - confounding 3**
  - congenital melanosis oculi 134**
  - conjunctiva**
    - nevus 132–4
      - surgical excision 160
    - radiotherapy, complications 45
    - squamous cell carcinoma 22–3, 24
    - surgical techniques 158–60
      - anesthesia 158
      - complications 160
      - conjunctival excision 158–9
      - melanocytic tumors 160
      - postoperative management 160
      - presurgical evaluation 158
      - specimen preparation 160
      - squamous tumors 160
      - substantia propria tumors 160
      - supplemental cryotherapy 160
      - wound closure 160
  - conjunctival/corneal tumors 125–8**
    - benign 129–35
      - caruncular 135
      - epithelial 129–32
      - melanocytic 132–4
        - see also individual tumors*
    - classification 126, 127
    - cryotherapy 34–5
    - diagnosis 126
    - differential diagnosis 126, 128
    - examination 125–6
    - histology 125
    - melanoma 146–9
      - clinical course 149
      - clinical features 146–7
      - diagnosis and differential diagnosis 147–8
      - epidemiology 146
      - etiology and associated diseases 146
      - treatment 148–9
    - stromal 150–7
      - choristoma 155–6, 157
      - fibrous tumors 152
      - histiocytic tumors 153
      - leukemic infiltrates 155
      - lipomatous tumors 154
      - lymphangiectasia and lymphangioma 151–2
      - lymphoproliferative tumors 154–5
      - metastatic and secondary tumors 156–7
      - myogenic tumors 154
      - myxoid tumors 153
      - neural tumors 152–3
      - vascular tumors 150–1
    - systemic associations 162–8
      - amyloidosis 165, 167, 168
      - Carney complex 162
      - Goldenhar syndrome 162, 164
      - multiple endocrine neoplasia type 2B 164–5, 166
      - Peutz-Jeghers syndrome 162, 163
      - Proteus syndrome 164
      - sebaceous nevus syndrome 162
      - xeroderma pigmentosum 165, 167
  - cooption 16**
  - coping mechanisms 54**
  - cornea**
    - radiotherapy, complications 45
    - squamous cell carcinoma 139
    - surgical techniques 158–60
      - anesthesia 158
      - complications 160
      - corneal excision 158
      - melanocytic tumors 160
      - postoperative management 160
      - presurgical evaluation 158
      - specimen preparation 160
      - squamous tumors 160
      - substantia propria tumors 160
      - supplemental cryotherapy 160
      - wound closure 160
    - tumors *see* conjunctival/corneal tumors
  - corticosteroids 51, 52**
    - orbital inflammatory disease 531
  - counseling 54–7**
    - children 56–7
    - communication 55–6
    - coping mechanisms 54
    - emotional needs 54–5
    - emotions and fears 54
    - patients' needs 54
    - psychological support 56
    - self-help 56
  - Cowden syndrome 118**
  - cranial nerve function 506**
  - cross-sectional studies 4**
  - cryotherapy 34–6**
    - basal cell carcinoma 79
    - Coats' disease 352
    - complications 35–6
    - cooling rate 34
    - freeze-thaw cycle 34
    - indications 34–5
      - conjunctival tumors 34–5
      - eyelid tumors 34
      - intraocular tumors 35
      - orbital tumors 35
    - mechanism of tissue injury 34
    - ocular adnexal lymphoma 569
    - OSSN 139
    - primary acquired melanosis 144
    - repetitions 34
    - retinal hemangioma 342
    - retinoblastoma 455, 457
    - sebaceous gland carcinoma 88
    - techniques 35
    - tissue temperature 34
    - uveal melanoma 228
  - cyclophosphamide 51, 52**
  - cyclotron 41**
  - cystic tumors 64**
  - cysts**
    - aneurysmal bone cyst 546, 547
    - dermoid 155
      - magnetic resonance imaging 513
    - epidermal inclusion 94
    - epithelial 131–2
      - magnetic resonance imaging 513
    - hemorrhagic 513
    - retention 94
    - sebaceous 94
    - trichilemmal (pillar) 94
  - cytokeratins 224**
  - cytology 13**
  - cytosine arabinoside 51**
- D**
- dacryoadenoma 131**
  - dancing eyes 383**
  - daunomycin 51, 52**
  - dellen 134**
  - dermoid cysts 155, 517, 518, 539–40, 540**
    - magnetic resonance imaging 513
  - dermolipoma 155–6**
  - diagnostic evaluation 60**
  - dietary factors in cancer etiology 9**
  - diode laser 38**
  - DNA testing 442, 446**
  - drug development 51**
  - drug resistance 50–1**
  - Duane syndrome 162**
  - dye laser 38**
  - dysplastic nevus 73, 90**
    - and primary acquired melanosis 141



- E**
- eccrine hidrocystoma 95
  - eccrine spiradenoma 95
  - electrodessication 79
  - electromagnetic radiation 40
  - electron microscopy 14
  - endoresection 264, 265
  - endoretinal biopsy 339
  - endostatin 18
  - enucleation 267–9, 280
    - meticulous intraoperative hemostasis 458–9, 461
    - retinoblastoma 458–61, 502
    - see also orbital implants
  - epheles 71
  - epidermal inclusion cyst 94
  - epidermal melanocytic tumors 63–4
  - epidermal non-melanocytic tumors 63–4
  - episcleral plaque radiotherapy 228
  - epithelial cysts 131–2
    - magnetic resonance imaging 513
  - epithelial tumors 126
  - epithelioid cell melanoma 220–1
  - epithelium 125
  - Epstein-Barr virus 8
  - essential thrombocythemia 332
  - esthesioneuroblastoma 571
  - ethnicity
    - racial melanosis 134
    - uveal melanoma 198
  - etoposide 51, 52
    - retinoblastoma 450–1, 480
    - structure 451
  - Ewing's sarcoma 578
  - examination
    - eyelid 59–60
      - biopsy 60
      - diagnostic evaluation 60
      - history 59
      - ocular adnexa 59
    - orbital tumors 505–6
      - history 505
      - visual inspection 505–6, 506
    - uveal tumors 171–4
      - ancillary tests 174
      - fundus drawing 173
      - history taking 171
      - indirect ophthalmoscopy 171–3
      - slit lamp examination 171
      - three-mirror examination 173–4
      - transillumination 174
      - tumor dimensions 173
      - visual acuity 171
  - excimer laser 38
  - external beam radiotherapy 42
    - retinoblastoma 502
  - external biopsy 337–9
  - extraocular muscles
    - enlargement 514, 515, 516
    - motility 505
  - eyelashes, loss of 45, 46
  - eyelid
    - adnexal glands 62
    - adnexal tumors 94–8
      - classification 94
      - cystic lesions 94
      - hair follicle tumors 97
      - sebaceous gland tumors 97–8
      - sweat gland tumors 94–6
    - examination 59–60, 505
      - biopsy 60
      - diagnostic evaluation 60
      - history 59
      - ocular adnexa 59
    - hemangioma 22, 23
    - keloids 99
    - lower eyelid defects 107–12
    - margin 62
    - nerve supply 62
    - nevus 90
    - orbicularis oculi 62
    - palpebral conjunctiva 62
    - radiotherapy, complications 45
    - reconstruction 107, 116
    - skin 62
    - surgical techniques 107–16
      - definitive treatment 107
      - diagnostic biopsy 107
      - insufficient anterior lamella 114–15
      - insufficient posterior lamella 114
      - insufficient vascularized pedicle 115
      - lower eyelid defects 107–12
      - medial canthal defect 113–14
      - reconstruction 107, 116
      - sentinel lymph node biopsy 107
      - upper eyelid defects 112–13
    - tarsus 62
    - upper eyelid defects 112–13
    - vascular system 62
  - eyelid tumors 62–5
    - classification 63, 64, 65
    - cryotherapy 34, 35
    - differential diagnosis 63–5
    - melanoma 90–2
    - stromal 99–105
      - fibrohistiocytic tumors 99–101
      - fibrous tissue tumors 99
      - inflammatory and infective lesions 105
      - lipomatous tumors 101
      - lymphoid, plasmacytic and leukemic tumors 104–5
      - metastatic tumors 105
      - neurogenic tumors 104
      - skeletal muscle tumors 101
      - smooth muscle tumors 101
      - vascular tumors 101–4
    - systemic associations 117–25
      - Carney complex 118, 120
      - Cowden syndrome 118
      - Gardner syndrome 117
      - Muir-Torre syndrome 120–3
      - neurofibroma 117
      - nevoid basal cell carcinoma syndrome 117–18
- F**
- familial adenomatous polyposis 117, 118, 360, 361
  - familial atypical mole and melanoma syndrome 73–4, 200–1
  - fibroblast growth factor 17–18
  - fibrohistiocytic tumors 99–101, 518
  - fibroma
    - conjunctiva 152
    - eyelid 99
  - fibromatosis 99, 100
  - fibro-osseous tumors 518
  - fibrosarcoma 99
  - fibrous dysplasia 546
  - fibrous histiocytoma 100–1, 152
    - orbital 543, 545, 572, 573
    - magnetic resonance imaging 511
  - fibrous tissue tumors
    - conjunctiva 152
    - eyelid 99
  - fibrous tumors 314
  - fine needle aspiration biopsy 335–7
    - uveal melanoma 275, 336
  - fluorescein angiography
    - choroidal osteoma 305
    - metastatic uveal tumors 322–3, 324
    - OSSN 138
    - retinocytoma 489
    - sclerochoroidal calcification 308
    - uveal melanoma 236
    - uveal tumors 175
  - 5-fluorouracil 51
    - OSSN 139–40
  - fractionated stereotactic radiotherapy 254–7
  - freckles 71
  - Fuchs' (coronal) adenoma 367
  - fundus
    - drawing 173
    - examination, orbital tumors 506, 506
    - photography 175
  - fungi 9
- G**
- gamma knife 254
  - Gardner syndrome 117, 118, 360, 361
  - genetics 31–3, 403–4
    - angiogenesis 32–3
    - apoptosis and senescence 31–2
    - proliferation and cell cycle 31
    - role in cancer 403
  - genetic susceptibility to cancer 6
  - glands of Moll, carcinoma 96
  - glaucoma 392
    - brachytherapy-induced 244
    - melanomalytic 220
    - neovascular 220
    - secondary 219–20
  - glioneuroma 366
  - globe
    - displacement 521, 525
    - position 505
    - resistance to retropulsion 505
  - Goldenhar syndrome 155, 162, 164
  - Gorlin-Goltz syndrome 117–18
  - graft-versus-host disease 332
  - granular cell tumor 153
  - granuloma
    - cholesterol 541
    - choroidal 293
    - pyogenic
      - conjunctival 150, 151
      - eyelid 101, 102

granulomatous inflammation 530  
 growth factor signaling pathways 31

## H

hair follicle tumors 97  
 hamartoma 11  
   astrocytic 489  
   conjunctiva/cornea 129  
   eyelid 104–5  
   retinal astrocytic 354–6  
   retinal pigment epithelium  
     combined 362–5  
     simple 362  
 hazard ratio 2  
 HDM2 31–2  
 head, examination 521, 526  
*Helicobacter pylori* 9  
 hemangioma  
   capillary  
     conjunctiva 150  
     eyelid 101–3  
     orbit **511, 512**, 535–6, **536**  
     retina 341–3  
   cavernous  
     conjunctiva 150  
     eyelid 103  
     orbit 536–7, 537  
   central nervous system 389  
   choroidal 213, 215  
     circumscribed 289–97  
     diffuse 297–8, 392–3  
   ciliary body 289  
   eyelid 22, 23  
   iris 289, 290  
   retinal 341–4  
     capillary 341–3  
     cavernous 343–4, 394–5  
 hemangiopericytoma 150  
   magnetic resonance imaging 511  
   orbit 537  
 hemorrhagic cysts, magnetic resonance  
   imaging **513**  
 hepatitis B/C 9  
 hereditary benign intraepithelial  
   dyskeratosis 131  
 hereditary breast cancer syndrome 429  
 Hertel exophthalmometry **526**  
 histiocytic tumors 153, 518  
 histology 14, 125  
 histopathology  
   ocular surface squamous neoplasia  
     138–9  
   primary acquired melanosis 142–3  
   squamous cell carcinoma 81–2  
   uveal melanoma 219–24  
 HLA *see* human leukocyte antigen  
 holmium laser 38  
 human leukocyte antigen 224  
 human papillomavirus 8  
   and OSSN 136  
 human T-cell lymphotropic virus-1 9  
 hydroxyapatite orbital implants 586,  
   587  
 hyperostosis 510  
 hyperthermia *see* thermotherapy  
 hypoxia-inducible factor 32

## I

iatrogenic cancers 9  
 ifosfamide 51  
 immunohistochemistry 14  
 immunology 27–30  
   immunological escape 27  
   innate and specific immune responses  
     27  
   uveal melanoma 27–30  
 immunosuppression 9  
 immunotherapy 285  
   ocular adnexal lymphoma 569  
 incidence of ocular cancers 1  
 indocyanine green angiography  
   choroidal osteoma 305  
   metastatic uveal tumors 322–3  
   uveal melanoma 235  
   uveal tumors 175–7  
 infantile capillary hemangioma **511, 512**,  
   **535–6, 536**  
 inflamed juvenile conjunctival nevus  
   133–4  
 information bias 3  
 innate immune response 27  
 insulin-like growth factor-1 receptor  
   224  
 intensity-modulated radiotherapy 465  
 interferon- $\alpha$  52  
   ocular adnexal lymphoma 569  
 interferon- $\alpha_{2a}$  19  
 interferon- $\alpha_{2b}$ , OSSN 139–40  
 intraepithelial neoplasia 70–1  
 intraocular biopsy 334–9  
   endoretinal biopsy 339  
   external 337–9  
   fine needle aspiration 335–7  
   indications 334  
   vitrectomy 334–5  
 intraocular pressure in choroidal  
   melanoma 209  
 inverted follicular keratosis 67, 129–30  
 inverted papilloma *see* inverted follicular  
   keratosis  
 ionizing radiation 40  
 irenotecan 51  
 iridectomy 259  
 iridocyclectomy 259–60  
 iris  
   hemangioma 289, 290  
   lymphoma *see* primary iridal lymphoma  
   mammillations 185  
   melanocytoma 194  
   melanoma 205  
   mortality 281  
   primary iridal lymphoma 319–21  
   radiotherapy, complications 45  
   tumors 216–17  
 iris nevus 185–7  
   differential diagnosis 217  
   diffuse 185, 186  
   syndrome 185  
 isemaxamib 19

## J

junctional nevus 133  
 juvenile xanthogranuloma 314

## K

Kaposi's sarcoma  
   conjunctiva 150–1  
   eyelid 103–4  
   herpesvirus 8  
 Kasabach-Merritt syndrome 520  
 keloids 99  
 keratoacanthoma 67–8, 130  
 keratotic plaque 132  
 Klippel-Trenaunay-Weber syndrome 164  
 Knudson's two-hit hypothesis 405  
 krypton laser 37–8

## L

lacrimal gland  
   enlarged 514, **515**  
   radiotherapy, complications 46  
   tumors 517, **518**, 555–9  
     adenoid cystic carcinoma 557, 557,  
       558–9  
     benign 556, 556  
     clinical features 555, 556  
     diagnostic evaluation 555–7, 556, 557  
     differential diagnosis 557  
     epidemiology 555, **556**  
     malignant 556, 557  
     malignant mixed 558, 559  
     metastatic 558, 559  
     pathology 557  
     pleomorphic adenoma 557–8  
     prognosis 558–9  
     treatment 557–8, **558**  
 lacrimal sac tumors 517, 560–3  
   clinical features 560, 561  
   diagnostic evaluation 560, 561  
   differential diagnosis 560–1  
   histopathological classification 561–3, 562,  
     **562, 563**  
   prognosis 563  
   treatment 563  
 lacrimal system, examination 506  
 Langerhans cell histiocytosis 314  
 laser photocoagulation 38  
   choroidal hemangioma 294  
   choroidal osteoma 306  
   Coats' disease 352  
   retinal hemangioma 342  
   retinoblastoma 454–6  
   uveal melanoma 228, 232  
 laser therapy 37–9  
   laser properties 37  
   photodynamic therapy 39  
   tissue effects 37  
   transpupillary thermotherapy 38–9  
   treatment variables 37  
   types of laser 37–8  
     argon 37  
     diode 38  
     dye 38  
     excimer 38  
     holmium 38  
     krypton 37–8  
     ruby 37  
 leiomyosarcoma 314  
   orbital 572  
 lens, radiotherapy complications 45–6

- lentigo maligna** 74, 90  
   histology 91  
**lentigo simplex** 71  
**leptomeningeal hemangiomas** 393  
**leukemias** 11, 328–32  
   ophthalmic features 329  
   prognosis 331–2  
   signs 329–31  
   symptoms 329  
   systemic features 326–7  
   treatment 331  
**leukemic infiltrates** 104–5, 155  
**Lhermitte-Duclos disease** 118  
**Li-Fraumeni syndrome** 201, 429  
**light microscopy** 14  
**linear accelerator** 40–1, 256  
**lipoma**  
   conjunctiva 154  
   eyelid 101  
**lipomatous tumors**  
   conjunctiva 154  
   eyelid 101  
   orbit 517  
**liposarcoma**  
   conjunctiva 154  
   eyelid 101  
   orbital 572, 574  
**Lisch nodules** 385, 387  
**Luedde exophthalmometer** 521  
**lymphangiectasia** 151–2  
**lymphangioma**  
   conjunctiva 151–2  
   eyelid 103  
**lymphoid tumors** 104–5  
   surgical excision 160  
**lymphoma** 11  
   central nervous system 372–6  
   clinical features 372  
   diagnostic evaluation 372–4  
   differential diagnosis 374–5  
   pathogenesis 372  
   prognosis 376  
   treatment 375–6  
   ocular adnexal 565–70  
     classification 565–6, **566**  
     clinical features 566–7, 576  
     diagnostic evaluation 567–8, 567, 568  
     differential diagnosis 568  
     epidemiology 565  
     etiology and pathogenesis 565  
     pathologic features 568, 568, **569**  
     prognosis 569–70  
     staging 568, **568**  
     treatment 568–9  
   primary choroidal 316–19  
     clinical features 316, 317  
     diagnostic evaluation 316, 317  
     differential diagnosis 317–19, 320  
     etiology and pathogenesis 316  
     histology 316–17  
     prognosis 319  
     treatment 319  
   primary iridal 319–21  
     clinical features 319  
     cytology and histology 319  
     diagnostic evaluation 319  
     differential diagnosis 319–20  
     etiology and pathogenesis 319  
     prognosis 321  
     treatment 321  
   retina and CNS 372–6  
     clinical features 372  
     diagnostic evaluation 372–4  
     differential diagnosis 374–5  
     pathogenesis 372  
     prognosis 376  
     treatment 375–6  
**lymphoproliferative tumors** 154–5, 517  
**Lynch syndrome** 429  
  
**M**  
**McCoy Facial Trisquare** 505  
**McCune-Albright syndrome** 546  
**Maffucci syndrome** 164  
**magnetic resonance imaging**  
   choroidal osteoma 306  
   fetal 496–7, 498, 499  
   metastatic uveal tumors 323  
   orbital tumors 508  
   uveal tumors 179  
**magnetic resonance spectroscopy** 179  
**malignant tumors** 11  
   *see also individual tumors*  
**mean score differences** 2–3  
**measures of association** 103  
**medial canthal defect** 113–14  
**medulloepithelioma** 366–7  
**melanocytic benign epidermal tumors**  
   71–3  
   epithelial pigmentation 71  
   melanocytic nevus 71–3  
**melanocytic epithelial tumors** 126  
**melanocytic nevus** 71–3  
**melanocytic premalignant epidermal tumors** 73–4  
**melanocytoma** 194–6  
   differential diagnosis 215  
**melanocytosis** 190  
**melanoma** 11  
   bilateral 208  
   choroidal 207–10, 212–16  
     alterations of retina 208  
     alterations of retinal pigment epithelium 208–9  
     clinical features 207  
     diagnostic features 212  
     differential diagnosis 212–16, 293  
     extrascleral extension 209–10  
     inflammatory reaction 209  
     intraocular pressure 209  
     optic nerve invasion 210  
     pigmentation 208  
     site of origin 208  
     size and shape 207  
     symptoms 207  
     variants 208  
   ciliary body 205–7  
   conjunctival 146–9  
   differential diagnosis 87  
   epithelioid cell 220–1  
   eyelid 90–2  
     clinical features 90, 91  
     differential diagnosis 90–1  
     epidemiology 90  
     etiology and pathogenesis 90  
     histopathology 91  
     metastases 92  
     mortality 92  
     prognosis 92  
     treatment 91–2  
   iris 205  
   mixed-cell 221  
   multifocal 208  
   necrotic 221, 273  
   orbit 574  
   small peripapillary 208  
   spindle cell 220, 273  
   uveal 19–22, 198–203  
     adjuvant therapy 230  
     aftercare 230  
     angiogenesis 20  
     bilateral 200  
     brachytherapy 41–7  
     clinical features 205–10  
     COMS results 267–71  
     counseling 230  
     detection 226  
     diagnosis 226–7  
     differential diagnosis 212–17  
     etiology 198–203  
     familial 200  
     genetic predisposition 199–200  
     histopathology 219–24  
     immunology 27–30  
     incidence 109  
     metastasis 20–2, 283–7  
     mortality 277–81  
     organization of patient care 230–1  
     prognostic factors 272–5  
     referral 226  
     screening for systemic disease 229–30  
     treatment 22, 228–9  
     tumor grading 228  
     tumor staging 227–8  
     in young people 200  
**melanoma-associated retinopathy**  
   379–80  
**melanotic freckle of Hutchinson** 74  
**melphalan** 51  
**meningeal tumors** 518  
**meningioma** 543, 544  
**mental retardation** 444  
**mercaptopurine** 51, 52  
**Merkel cell carcinoma** 104, 575, 576  
**metastatic cascade** 16  
**methotrexate** 51, 52  
**microbial agents** 8–9  
**microcephaly** 360  
**mitomycin C**  
   OSSN 139–40  
   primary acquired melanosis 144  
**mixed-cell melanoma** 221  
**Mohs' surgery** 92, 108  
**monostotic fibrous dysplasia** 546



- mortality** 1  
 iris melanoma 281  
 uveal melanoma 277–81
- mosaicism** 443–4
- mucinous sweat gland adenocarcinoma** 96
- mucocele** 540–1, 547  
 frontoethmoid 540  
 magnetic resonance imaging 513  
 maxillary 541  
 sphenoid and posterior ethmoid 541
- mucoepidermoid carcinoma** 139
- Muir-Torre syndrome** 118, 120–1, 122–3
- multifocal melanoma** 208
- multiple endocrine neoplasia type 2B** 164–5, 166
- multiple hamartoma syndrome** 118
- Myc** 31
- myogenic tumors** 154, 517
- myxoid tumors** 153
- myxomatous tumors** 517
- N**
- nasal endoscopy** 506
- Naugle exophthalmometer** 505, 506
- neck, examination** 521, 526
- necrotic melanoma** 221, 273
- neural tumors** 152–3
- neurilemmoma (schwannoma)** 104, 152–3  
 magnetic resonance imaging 511  
 orbital 542–3, 542  
 uveal 302–3
- neuroblastoma** 578
- neurocutaneous melanosis** 71, 398
- neurofibroma** 117, 385  
 conjunctiva 152  
 eyelid 104  
 magnetic resonance imaging 511  
 orbit 542–3  
 uveal 300–2
- neurofibromatosis, s type 1, clinical features** 385–7
- neurofibromatosis** 118, 164, 201  
 type 1 385–7  
 diagnostic evaluation 387  
 genetic aspects 385  
 optic nerve sheath meningioma 552  
 pathogenesis 385  
 prognosis 387  
 treatment 387  
 type 2 387–9  
 clinical features 388–9  
 diagnostic evaluation 389  
 genetic aspects 388  
 pathogenesis 388  
 prognosis 389  
 treatment 389
- neurogenic tumors** 104
- neuro-oculocutaneous syndromes** 343, 385–99  
 ataxia-telangiectasia 397–8  
 neurocutaneous melanosis 398  
 neurofibromatosis 1 385–7  
 neurofibromatosis type 2 387–9  
 nevus sebaceous syndrome (of Jadassohn) 71, 97, 162, 395–7  
 phakomatosis pigmentovascularis 399  
 retinal cavernous hemangioma 394–5  
 Sturge-Weber syndrome 118, 297–8, 391–4  
 tuberous sclerosis 391  
 von Hippel-Lindau disease 343, 389–91  
 Wyburn-Mason syndrome 344–5, 394
- nevroid basal cell carcinoma syndrome** 117–18
- nevus**  
 blue 71, 133  
 choroidal 187–90, 199  
 clinical features 189  
 differential diagnosis 212–13  
 ciliary body 190  
 compound 133  
 conjunctival 132–4  
 surgical excision 160  
 dysplastic 73, 90  
 eyelid 90  
 inflamed juvenile conjunctival 133–4  
 iris 185–7, 217  
 junctional 133  
 melanocytic 71–3  
 of Ota 72, 90  
 and primary acquired melanosis 141  
 Spitz 133  
 split (kissing) 71, 72, 73  
 subepithelial 133
- nevus flammeus (port wine stain)** 101, 104, 117, 393
- nevus sebaceous (of Jadassohn)** 71, 97, 162, 395–7
- nodular fasciitis**  
 conjunctiva 152  
 eyelid 99
- non-ionizing radiation** 40
- non-melanocytic epidermal tumors** 67–9  
 inverted follicular keratosis 67  
 keratoacanthoma 67–8  
 reactive hyperplasia 68–9  
 seborrheic keratosis 67  
 squamous cell papilloma 67
- non-melanocytic epithelial tumors** 126
- non-melanocytic premalignant epidermal tumors** 69–71  
 actinic (solar) keratosis 70  
 intraepithelial neoplasia 70–1  
 non-specific keratosis 69–70  
 sebaceous nevus (of Jadassohn) 71, 97
- non-specific keratosis** 69–70
- nuclear cytoplasmic ratio** 12
- O**
- occupational exposure** 6  
 uveal melanoma 203
- ocular adnexal lymphoma** 565–70  
 classification 565–6, 566  
 clinical features 566–7, 576  
 diagnostic evaluation 567–8, 567, 568  
 differential diagnosis 568  
 epidemiology 565  
 etiology and pathogenesis 565  
 pathologic features 568, 568, 569  
 prognosis 569–70  
 staging 568, 568  
 treatment 568–9
- ocular surface squamous neoplasia** 136–40  
 clinical features 137  
 diagnostic evaluation 137–8  
 differential diagnosis 137  
 epidemiology 136  
 etiology and associated diseases 136  
 histopathology 138–9  
 prognosis 140  
 treatment 139–40
- oculoauriculovertebral dysplasia see Goldenhar syndrome**
- oculodermal melanocytosis** 90, 200
- odds ratio** 2
- Ollier's disease** 164
- oncocyoma** 131
- ophthalmoscopy, indirect** 171–3
- opsoclonus** 383
- optical coherence tomography**  
 choroidal osteoma 305  
 retinocytoma 489  
 uveal tumors 179
- optic disc melanocytoma** 190–4
- optic nerve**  
 enlarged 513–14, 514  
 glioma 387  
 in leukemia 330–1  
 tumor invasion 219  
 tumors 518, 549–54  
 anterior visual pathway glioma 549–51, 550, 550, 551  
 malignant optic nerve glioma 551–2  
 optic nerve sheath meningioma 552–4, 552, 553
- optic neuropathy, brachytherapy-induced** 243
- orbicularis oculi** 62
- orbital apex syndrome** 529, 530
- orbital bones, radiotherapy complications** 46
- orbital examination** 525
- orbital imaging** 507–16  
 color Doppler imaging 507  
 computed tomography 507–8, 508, 509  
 interpretation 508–10  
 appearance 510  
 bone characteristics 510  
 content 510  
 contrast enhancement 510  
 location of lesions 508, 510  
 magnetic resonance imaging 508  
 ultrasonography 507
- orbital implants** 586–90  
 porous 586–7, 587  
 ceramic 587, 588  
 hydroxyapatite 586, 587  
 pegging 589–90  
 synthetic 586, 587  
 synthetic hydroxyapatite 586–7  
 selection 587–8  
 volume 588–9  
 wrapping 589

- orbital inflammatory disease** 528–32  
 clinical features 528–30, 529, 530  
 diagnostic evaluation 530–1  
 histopathology 531  
 imaging 530  
 immunohistochemistry 531  
 laboratory testing 530–1  
 differential diagnosis 531, 531  
 pathogenesis 528  
 prognosis 532  
 treatment 531–2  
 radiation 532  
 steroids 531  
 steroid-sparing agents 532  
 surgery 532
- orbital myositis** 529
- orbital retinoblastoma** 477–83  
 accidental 477, 479  
 management 480–2  
 diagnostic evaluation 477–8  
 incidence 477  
 management 478–82  
 microscopic 477, 480  
 management 482  
 overt 477  
 management 482  
 primary 477  
 management 478, 480  
 secondary 477, 478  
 management 480
- orbital soft tissues**  
 acoustic properties 508  
 radiotherapy, complications 46
- orbital surgery** 592–7  
 anesthesia 592  
 caruncular approach 594  
 conjunctival approach 594  
 incisions 594  
 indications 592–3  
 inferior orbitotomy 596–7, 596, 597  
 instrumentation 592  
 microsurgery 592  
 Perez-Morerias approach 594  
 planning of 593–4, 593  
 superior orbitotomy 594, 595, 596, 596  
 surgical team 593
- orbital tumors**  
 benign 539–47  
 aneurysmal bone cyst 546, 547  
 cholesterol granuloma 541  
 dermoid and epidermoid cysts 155, 513, 517, 518, 539–40, 540  
 fibrous dysplasia 546  
 fibrous histiocytoma 543, 545  
 meningioma 543, 544  
 mucocele 540–1, 541  
 neurilemmoma (schwannoma) 542–3, 542  
 neurofibroma 542–3  
 orbital cephalocele 541–2  
 osteoma 545, 546  
 teratoma 543  
 children 520–3  
 biopsy 522  
 diagnostic imaging 521–2, 521, 522, 522
- examination 520–1, 521, 521  
 history 520  
 laboratory evaluation 521  
 classification 517–19, 518  
 imaging 519  
 cryotherapy 34, 35  
 differential diagnosis 517  
 examination 505–6, 524–6, 525, 526  
 biopsy 526–7  
 diagnostic imaging 526  
 history 505, 524  
 laboratory evaluation 526  
 surgical decisions 527  
 visual inspection 505–6, 506
- fibrohistiocytic 518  
 histiocytic 518  
 imaging *see* orbital imaging  
 lacrimal gland *see* lacrimal gland tumors  
 lacrimal sac *see* lacrimal sac tumors  
 lipomatous 517  
 lymphoma *see* ocular adnexal lymphoma  
 lymphoproliferative 517  
 malignant 571–9  
 alveolar soft part sarcoma 571–2  
 basal cell carcinoma 574  
 esthesioneuroblastoma 571  
 fibrous histiocytoma 572, 573  
 leiomyosarcoma 572  
 liposarcoma 572, 574  
 melanoma 574  
 Merkel cell carcinoma 575, 576  
 osteosarcoma 572  
 peripheral nerve sheath tumor 571  
 sebaceous carcinoma 574–5  
 secondary orbital tumors 572, 574–5, 575, 576  
 squamous cell carcinoma 574, 575  
*see also* orbital tumors, metastases
- meningeal 518  
 metastases 519  
 adults 575–8, 577, 578  
 children 578, 579  
 magnetic resonance imaging 511, 512  
 myogenic 517  
 myxomatous 517  
 optic nerve *see* optic nerve tumors  
 peripheral nerve 517  
 primary bone tumors 518–19  
 primary melanocytic 517  
 radiological differential diagnosis 510–16  
 anomalies of bony orbit 514, 516  
 enlarged extraocular muscles 514, 515, 516  
 enlarged lacrimal gland 514, 515  
 enlarged optic nerve 513–14, 514  
 ill-defined solid tumors 511, 512  
 well-circumscribed cystic lesions 511–13, 513, 513  
 well-circumscribed solid tumors 510–11, 511, 512  
 retinoblastoma *see* orbital retinoblastoma  
 rhabdomyosarcoma *see* rhabdomyosarcoma  
 secondary 519  
 vascular 517, 518, 533–8
- capillary hemangioma 511, 512, 535–6, 536  
 cavernous hemangioma 536–7, 537  
 hemangiopericytoma 537  
 vascular malformations 533–5, 534, 535, 536  
*see also* enucleation
- orbital varix, magnetic resonance imaging** 511
- organoid nevus syndrome** 155
- osseous choristoma** 156
- OSSN** *see* ocular surface squamous neoplasia
- osteoma**  
 choroidal 305–6  
 orbital 545, 546
- osteosarcoma** 572
- outcome measures** 1
- P**
- p53** 31–2
- palpation** 505, 521, 525–6
- paraneoplastic disease** 378–83  
 bilateral diffuse uveal melanocytic proliferation 380–1  
 cancer-associated retinopathy 378–9  
 melanoma-associated retinopathy 379–80  
 opsoclonus 383  
 paraneoplastic optic neuropathies 381–2
- paraneoplastic melanocytic proliferation** 380–1
- paraneoplastic optic neuropathies** 381–2
- parasites** 9
- pegatanib** 19
- pegging of orbital implants** 589–90
- periorbital skin, radiotherapy complications** 45
- peripheral nerve sheath tumor** 571
- perivascular tumors** 104
- Peutz-Jeghers syndrome** 162, 163
- phakomatoses** *see* neuro-oculocutaneous syndromes
- phakomatosis pigmentovascularis** 399
- pheochromocytoma** 389
- photocoagulation** *see* laser photocoagulation
- photodynamic therapy** 39  
 choroidal hemangioma 295–7, 298  
 choroidal osteoma 306  
 retinal hemangioma 342  
 squamous cell carcinoma 83  
 uveal melanoma 228
- photography, uveal tumors** 175
- pigmented ocular fundus lesions** 359–62  
 clinical features 360–1  
 diagnostic evaluation 362  
 etiology and pathogenesis 359  
 pathology 359–60  
 prognosis 362  
 treatment 362
- pilomatrixoma** 97
- pilot studies** 5
- plasmacytic tumors** 104–5
- platelet-derived growth factor** 530
- pleomorphic adenoma** 95

- plica semilunaris 125  
 polycythemia vera rubra 332  
 polyostotic fibrous dysplasia 546  
 port wine stain *see* nevus flammeus  
 positron emission tomography, uveal tumors 179–80  
 precision 3  
 pre-enucleation radiotherapy 269–70, 280  
 prevalence 1  
 primary acquired melanosis 141–4  
   clinical features 141, 142  
   diagnostic evaluation 143  
   differential diagnosis 143  
   etiology 141  
   histopathology 142–3  
   prognosis 144  
   treatment 143–4  
   withouth atypia 134  
 primary choroidal lymphoma 316–19  
   clinical features 316, 317  
   diagnostic evaluation 316, 317  
   differential diagnosis 317–19, 320  
   etiology and pathogenesis 316  
   histology 316–17  
   prognosis 319  
   treatment 319  
 primary iridal lymphoma 319–21  
   clinical features 319  
   cytology and histology 319  
   diagnostic evaluation 319  
   differential diagnosis 319–20  
   etiology and pathogenesis 319  
   prognosis 321  
   treatment 321  
 proliferative hematopoietic disorders 328–32  
   essential thrombocythemia 332  
   graft-versus-host disease 332  
   leukemias 328–32  
   polycythemia vera rubra 332  
 Proteus syndrome 164  
 proton beam radiotherapy 228, 465–7  
   choroidal hemangioma 298  
   uveal melanoma 248–53  
     follow-up protocol 250  
     irradiation procedure 249–50  
     metastasis and survival 252  
     ophthalmic outcomes 250–2  
     patient characteristics 250  
     patient evaluation 248  
     pre-radiation surgery 248–9  
     proton treatment planning 249  
 pseudocarcinomatous hyperplasia 130  
 pseudoepitheliomatous hyperplasia 130  
 psychological support 56  
 pulsation 521, 526  
 punctate keratitis 46  
 pupils, examination 505  
 pyogenic granuloma  
   conjunctiva 150, 151  
   eyelid 101, 102
- Q**  
 quality of life 1
- R**  
 race *see* ethnicity  
 racemose hemangioma 150  
 radiation dermatitis 46  
 radiation optic neuropathy 48–9  
   clinical features 48  
   diagnostic evaluation 48  
   pathogenesis 48  
   prognosis 48  
   treatment 48  
 radiation retinopathy 46–8  
   clinical features 46–7  
   diagnostic evaluation 47  
   differential diagnosis 47, 48  
   pathogenesis 46  
   prognosis 47  
   treatment 47  
 radiotherapy 9, 40–3  
   anterior visual pathway glioma 551  
   basal cell carcinoma 79  
   brachytherapy 43  
   choroidal hemangioma 294, 298  
   cobalt grey equivalents 42  
   conformal 42–3, 465  
   dual nature of radiation 40  
   external beam therapy 42  
   fractionation 42  
   intensity-modulated 465  
   ionizing/non-ionizing 40  
   metastatic uveal tumors 325  
   ocular adnexal lymphoma 569  
   ocular complications 45–9  
     conjunctiva 45  
     cornea 45  
     eyelid/periorbital skin 45  
     iris 45  
     lacrimal gland 46  
     lens 45–6  
     orbital bones 46  
     orbit soft tissue 46  
     radiation optic neuropathy 48–9  
     radiation retinopathy 46–8  
     sclera 45  
   proton beam *see* proton beam radiotherapy  
   radiation dose 41  
   radioactive decay 40  
   relative biological effectiveness 41  
   retinal hemangioma 342  
   retinoblastoma 462–7  
     efficacy 462  
     recommendations 467  
     reduction of side effects 464–7  
     side effects and secondary malignancies 462–4  
   sebaceous gland carcinoma 88  
   squamous cell carcinoma 83  
   stereotactic radiosurgery 43  
   target volume 42  
   teletherapy sources 40–1  
     cobalt-60 unit 40  
     cyclotron 41  
     linear accelerator 40–1  
   tissue tolerance 42  
   total dose 42  
   uveal melanoma 280
- randomized controlled trials 4  
 ranibizumab 19  
 Rb1 cancer predisposition syndrome 428–33  
   background 428  
   clinical management 432  
   genetic testing 431  
   genotype 428, 431  
   genotype-phenotype correlation 431  
   imprecise terminology 431–2  
   phenotype 428  
   terminology 428  
   *see also* retinoblastoma  
 Rb-p16Ink4a-cyclin D pathway 31  
 reactive epithelial hyperplasia 130  
 reactive hyperplasia 68–9  
 relative biological effectiveness 41  
 relative risk 1–2  
 retention cyst 94  
 reticulohistiocytoma 153  
 retina  
   choroidal melanoma 208  
   combined hamartoma 362–5  
   lymphoma 372–6  
     clinical features 372  
     diagnostic evaluation 372–4  
     differential diagnosis 374–5  
     pathogenesis 372  
     prognosis 376  
     treatment 375–6  
   tumor invasion 219  
 retinal detachment 219  
   rhegmatogenous 262  
 retinal pigment epithelium  
   choroidal melanoma 208–9  
   melanoma-induced changes 219  
   tumors 215–16, 358–65  
     adenoma and adenocarcinoma 362  
     classification of 359  
     combined hamartoma 362–5  
     congenital grouped pigmentation 358–9  
     congenital hypertrophy 358  
     pigmented ocular fundus lesions 359–62  
     simple hamartoma 362  
 retinal progenitor cells 406  
 retinal tumors  
   astrocytic 354–7  
     acquired astrocytoma 356–7  
     retinal astrocytic hamartoma 354–6  
   vascular 341–6  
     capillary hemangioma 341–3  
     cavernous hemangioma 343–4, 394–5  
     vasoproliferative tumor 345–6  
     Wyburn-Mason syndrome 344–5  
 retinoblastoma 19, 403–4, 405–8  
   angiogenesis in 475  
   at-risk pregnancies 496–9  
   care protocols 497–9  
   fetal magnetic resonance imaging 496–7, 498, 499  
   fetal ultrasound 496, 497, 498  
   benign *see* retinocytoma  
   cell of origin 405–7  
   chemotherapy 449–52, 501–2  
   drugs 450–1



- extraocular retinoblastoma 452
  - optimization of 449
  - prophylactic 451
  - response to 449
  - toxicity 451
- Children's Oncology Group trials 491–4
  - clinical features 417
  - clinical implications 408
  - delayed diagnosis 417–18
  - developing countries 420, 501
  - discovery of *RB1* gene 403–4
  - environmental and behavioral risk factors 413–14
  - etiological factors 414–15
    - advanced paternal age 414
    - atomic bomb survivors 414–15
    - cancer survivors 414
    - germline mutagens in animals 414
  - extraocular 417, 418, 452, 484–6
    - clinical features 484
    - with CNS involvement 452, 486
    - diagnostic evaluation 484
    - differential diagnosis 484
    - future research 486
    - treatment and prognosis 484–6
    - without CNS involvement 484–6
  - familial 410
  - future directions 420–1, 501–4
  - genetic testing and counseling 441–8
    - confounding factors 443–4
    - DNA testing options 442
    - future of DNA testing 446
    - genetic counselor's role 442
    - integration of genetic services 442
    - linkage analysis 445
    - mutation detection 445
    - pedigree/family history 443
    - preparation of family and patient 442–3
    - referral for 441–2
    - unilateral retinoblastoma 444–5
  - geographic variation 410–13, 414
    - Africa 411, 412, 413
    - Asia 411
    - Central and South America 411
    - Europe 411
    - North America 410
    - Oceania 413
  - grouping 424–7
  - growth patterns 468, 469
  - histopathologic features 468, 469, 470, 471
  - importance of *RB1* gene in cancer biology 404
  - incidence 410, 417
    - by sex 413
    - terminology 431–2
  - international classification 422, 423
    - clinical application 427
    - grouping system 424–6
    - staging system 423–4
  - international perspective 417–21
  - Knudson's two-hit hypothesis 405
  - late diagnosis 501
  - limitations of published studies 475
  - mouse models 405
  - non-heritable 410
    - etiology 415
      - socioenvironmental causes 501
    - non-ocular tumors 434–6
      - clinical features 435–6
      - genetic susceptibility 434
      - incidence 435
      - pathogenesis 434–5
      - prevention 436
      - prognosis 436
      - radiation therapy 434–5
      - screening 436
      - treatment 436
      - types of 435
    - orbital 477–83
      - clinical manifestations 477
      - diagnostic evaluation 477–8
      - incidence 477
      - management 478–82
      - prognosis 482
      - prognostic factors 482
    - presenting signs 417
    - prognostic factors 470–1, 474–5
      - anterior segment involvement 474
      - invasion of choroid 471, 474
      - invasion of optic nerve 470–1
      - scleral and extrascleral extension 474
      - size and tumor characteristics 474–5
      - tumor at surgical margins and orbit 474
    - progression of 407–8
      - pseudo bilateral 431
      - pseudo low-penetrance 431
      - pseudo unilateral 431
    - radiotherapy 462–7
      - efficacy 462
      - recommendations 467
      - reduction of side effects 464–7
      - side effects and secondary malignancies 462–4
    - Reese-Ellsworth classification 422, 423
      - revision of 449–50
    - routes of extraocular spread 468–9
      - choroidal invasion 468, 473
      - hematogenous dissemination 469
      - lymphatic dissemination 469
      - optic nerve invasion 468, 472, 473
    - screening 419
      - socioeconomic factors 418
    - sporadic heritable 410
      - etiology 414–15
        - RB1* cancer predisposition syndrome 428–33
  - staging 422–4
    - Childrens' Cooperative Group Classification 422–3
    - Grabowski-Abramson Classification 423
    - St Jude's Hospital system 422
  - survival 418–20
  - treatment 454–61
    - brachytherapy 455, 457–8, 459
    - chemoreduction 454
    - consolidation 454–7
    - cryotherapy 455, 457
    - in developing countries 420
    - enucleation 458–61, 502
    - external beam radiotherapy 502
    - future strategies 475–6
    - hyperthermia 454
    - local primary 454
    - neoadjuvant chemotherapy 454
    - photocoagulation 454–6
    - systemic chemotherapy 501–2
    - thermochemotherapy 454, 455, 456
    - thermotherapy 454, 455, 456–7
  - treatment goals 502–4
  - trilateral 438–40, 452
    - age at diagnosis 438–40
    - incidence 438
    - midline intracranial tumors 438
    - prognosis 440
    - treatment 440
    - unique aspects of 422
- retinocytoma 487–90**
  - clinical features 487, 488
  - diagnostic evaluation 489
  - differential diagnosis 489
  - etiology and pathogenesis 487
  - prognosis 490
  - relationship to retinoblastoma 487, 489
  - treatment 490
- retinoic acid 51, 52**
- retinoma see retinocytoma**
- retinopathy**
  - brachytherapy-induced 243–4
  - cancer-associated 378–9
  - melanoma-associated 379–80
- rhabdomyoma 101**
- rhabdomyosarcoma**
  - conjunctiva 154
  - eyelid 101
  - orbital 581–4
    - classification **583**
    - clinical features 581
    - diagnostic evaluation 581, 582
    - differential diagnosis 582
    - etiology 581
    - follow-up 584, **584**
    - future research 584
    - histology 581–2, **582**
    - pathogenesis 581
    - prognosis 583–4
    - treatment 583, **583**
    - uveal 314
- rhegmatogenous retinal detachment 262**
- Riedel's thyroiditis 530**
- risk difference 2**
- rituxan 51**
- Rosai-Dorfman disease 104, 105**
- ruby laser 37**
- S**
- salmon patch 154, 167**
- sarcoidosis 531**
- sarcoma 11**
  - alveolar soft part 571–2
  - Ewing's 578
  - Kaposi's
    - conjunctival 150–1
    - eyelid 103–4
  - see also various different types
- schwannoma see neurilemmoma**
- sclera**
  - radiotherapy, complications 45

- tumor invasion 219
- scleral-based choroidal resection** 337–9
- scleral melting** 244
- scleritis** 216
- posterior 293
- sclerochoroidal calcification** 306–10
- sclerosing inflammation** 530
- screening**
- for metastases 270–1
- retinoblastoma 419
- non-ocular tumors 436
- systemic disease in uveal melanoma 229–30
- sebaceous carcinoma** 574–5
- sebaceous cysts** 94
- sebaceous gland carcinoma** 85–8
- clinical features 85, 86
- diagnostic evaluation 87
- differential diagnosis 87–8
- epidemiology 85
- etiology 85
- histopathologic features 85–7
- immunohistochemistry 87
- mortality 88
- prognosis 88
- treatment 88
- sebaceous gland tumors** 97–8
- adenoma 97
- epithelioma 97
- hyperplasia 97
- sebaceous nevus (of Jadassohn)** 71, 97, 162, 395–7
- seborrheic keratosis** 67, 90
- SEER Program** 198
- selection bias** 3
- self-help** 56
- senescence** 31–2
- sentinel lymph node biopsy** 107
- skeletal muscle tumors** 101
- slit lamp examination** 125
- orbital tumors 505–6
- uveal tumors 171
- small peripapillary melanoma** 208
- smoking, and primary acquired melanosis** 141
- smooth muscle tumors** 101
- solar lentigo** 71
- specific immune response** 27
- spindle cell melanoma** 220, 273
- spindle cell squamous carcinoma** 139
- Spitz nevus** 133
- split nevus (kissing nevus)** 71, 72, 73
- squamous cell carcinoma** 81–3
- clinical features 81, 82
- diagnostic evaluation 82
- differential diagnosis 82, 87
- epidemiology 81
- etiology 81
- histopathology 81–2
- invasive 138
- metastasis 83
- mortality 83
- orbit 574, 575
- prognosis 83
- spindle cell 139
- treatment 82–3
- squamous cell papilloma** 67, 129, 130
- adults 129
- children 129
- surgical excision 160
- stereotactic radiosurgery** 43, 254
- stereotactic radiotherapy** 228
- fractionated 254–7
- indications and contraindications 257–8
- types of 254
- uveal melanoma 254–8
- steroids** *see* **corticosteroids**
- stroma** 125
- stromal tumors** 64
- conjunctival 126
- choristoma 155–6, 157
- fibrous tumors 152
- histiocytic tumors 153
- leukemic infiltrates 155
- lipomatous tumors 154
- lymphangiectasia and lymphangioma 151–2
- lymphoproliferative tumors 154–5
- metastatic and secondary tumors 156–7
- myogenic tumors 154
- myxoid tumors 153
- neural tumors 152–3
- vascular tumors 150–1
- corneal 126
- eyelid 99–105
- fibrohistiocytic tumors 99–101
- fibrous tissue tumors 99
- inflammatory and infective lesions 105
- lipomatous tumors 101
- lymphoid, plasmacytic and leukemic tumors 104–5
- metastatic tumors 105
- neurogenic tumors 104
- skeletal muscle tumors 101
- smooth muscle tumors 101
- vascular tumors 101–4
- study designs** 3–5
- Sturge-Weber syndrome** 118, 297–8, 391–4
- clinical features 392–3
- diagnostic evaluation 393
- genetic aspects 392
- pathogenesis 392
- prognosis 393
- treatment 393
- subepithelial nevus** 133
- substantia propria** 125
- sunlight exposure**
- and OSSN 136
- and primary acquired melanosis 141
- and uveal melanoma 201
- surgical techniques**
- conjunctiva/cornea 158–60
- anesthesia 158
- complications 160
- conjunctival excision 158–9
- corneal excision 158
- melanocytic tumors 160
- postoperative management 160
- presurgical evaluation 158
- specimen preparation 160
- squamous tumors 160
- substantia propria tumors 160
- supplemental cryotherapy 160
- wound closure 160
- eyelid** 107–16
- definitive treatment 107
- diagnostic biopsy 107
- insufficient anterior lamella 114–15
- insufficient posterior lamella 114
- insufficient vascularized pedicle 115
- lower eyelid defects 107–12
- medial canthal defect 113–14
- reconstruction 107, 116
- sentinel lymph node biopsy 107
- upper eyelid defects 112–13
- orbital surgery** 592–7
- anesthesia 592
- caruncular approach 594
- conjunctival approach 594
- incisions 594
- indications 592–3
- inferior orbitotomy 596–7, 596, 597
- instrumentation 592
- microsurgery 592
- Perez-Morerias approach 594
- planning of 593–4, **593**
- superior orbitotomy 594, 595, 596, 596
- surgical team 593
- sweat gland tumors** 94–6
- swinging flashlight test** 505
- synthetic orbital implants** 586–7
- syringocystadenoma papilliferum** 95–6
- syringoma** 95, 96
- malignant 96
- systematic reviews** 5
- ytosine arabinoside** 52
- T**
- tarsus** 62
- taxanes** 51
- telangiectasia** 397
- telomerase** 32
- teratoma** 11
- orbital 543, 543
- thalidomide** 51, 52
- thermochemotherapy** in retinoblastoma 454, 455, 456
- thermotherapy** 38–9
- choroidal hemangioma 294
- complications 237
- contraindications 232–4
- follow-up 235
- indications 232
- metastatic uveal tumors 325–6
- retinoblastoma 454, 455, 456–7
- technique 234–5
- tumor recurrence 235–7, 238
- uveal melanoma 228, 232, 232–7, 280
- visual results 237
- three-mirror examination** 171
- thrombospondin** 18
- thyroid-associated orbitopathy** 531
- tissue tolerance** 42
- tobacco** 6
- topotecan** 51
- transillumination** 174
- transpupillary thermotherapy** *see* **thermotherapy**

- trans-scleral choroidectomy** 260–4  
 indications and contraindications 260  
 result and complications 262–4  
 surgical technique 260–2
- trastuzumab (herceptin)** 19
- trichilemmal (pillar) cyst** 94
- trichilemmoma** 97
- trichoadenoma** 97
- trichoepithelioma** 97
- trichofolliculoma** 97
- tuberous sclerosis** 391
- tumor angiogenesis** 16
- tumor growth factor- $\beta$  pathway** 31
- tumor-infiltrating macrophages** 223
- tumor infiltration** 12–13
- tumor vessels** 16
- Turcot syndrome** 360
- U**
- ultrasonography**  
 choroidal osteoma 305  
 fetal 496, 497, 498  
 metastatic uveal tumors 323  
 orbital tumors 507  
 retinocytoma 489  
 sclerochoroidal calcification 308  
 three-dimensional 178  
 uveal tumors 177–8
- ultrasound biomicroscopy**  
 OSSN 138  
 uveal tumors 178
- ultraviolet light** 6–8  
*see also* sunlight exposure
- uveal melanoma** 19–22, 198–203  
 adjuvant therapy 230  
 aftercare 230  
 angiogenesis  
 indocyanine green angiography 20  
 microvessel density 20  
 pseudovasculature channels 20  
 VEGF expression 20  
 bilateral 200  
 brachytherapy 241–7  
 collateral damage 243–4  
 combined treatment 243  
 episcleral radioactive plaque 241  
 follow-up 242–3  
 local tumor recurrence 244–5  
 ocular conservation 246–7  
 plaque modifications 243  
 plaque positioning 242  
 preoperative assessment 241–2  
 radiation 241  
 radiation safety 243  
 survival 246  
 visual outcome 244  
 clinical features 205–10  
 choroidal melanoma 207–10  
 ciliary body melanoma 205–7  
 iris melanoma 205  
 COMS results 267–71  
 classification of choroidal melanoma 267  
 eligibility and exclusion criteria 267  
 observational studies 267–9  
 outcome measures 267
- counseling 230  
 detection 226  
 diagnosis 226–7  
 differential diagnosis 212–17  
 choroidal melanoma 212–16  
 iris, ciliary body and ciliochoroidal tumors 216–17  
 etiology  
 environmental factors 201–3  
 host factors 198–201  
 familial 200  
 genetic predisposition 199–200  
 histopathology 219–24  
 collar-stud shape 219  
 dome shape 219  
 growth patterns 219  
 indicators of prognosis 220–4  
 irradiated melanoma 224  
 local invasion 219  
 metastatic melanoma 224  
 retinoinvasive pattern 219  
 ring pattern 219  
 secondary intraocular damage 219–20  
 immunology 27–30  
 antibodies 29  
 anti-tumor immune responses 29  
 anti-uveal melanoma T-cell responses 28–9  
 HLA expression 28  
 immunosuppressive environment 29  
 infiltrating immune cells 28  
 tumor antigen expression 27–8  
 incidence 109  
 metastasis 20–2, 283–7  
 clinical features 283  
 diagnostic evaluation 283–5  
 pathogenesis 283  
 treatment 285, 286  
 mortality 277–81  
 competing risks 277  
 erroneous death certificate 277–8  
 future research 285  
 impact of therapy on 279–81  
 iris melanoma 281  
 lead-time bias 277  
 loss to follow-up 277  
 onset of metastasis 278–9  
 prognosis 285  
 survival probability and tumor size 277  
 organization of patient care 230–1  
 prognostic factors 272–5  
 conventional clinical examination 272, 283  
 examination of resected tumors 272–4  
 fine needle aspiration biopsy 275  
 non-invasive testing 275  
 referral 226  
 screening for systemic disease 229–30  
 treatment 22, 228–9  
 hyperthermia 232  
 photocoagulation 232  
 proton beam radiotherapy 248–53  
 resection 259–66  
 stereotactic radiotherapy 254–8
- thermotherapy 232–7  
 tumor grading 228  
 tumor staging 227–8  
 in young people 200
- uveal tumors**  
 benign melanocytic 185–97  
 choroidal nevus 187–90  
 ciliary body nevus 190  
 iris nevus 185–7  
 melanocytoma 194–6  
 melanocytosis 190  
 optic disc melanocytoma 190–4  
 classification of 181–4  
 etiopathogenic 181  
 genotypic 183–4  
 histogenetic 183  
 histopathological 181–3  
 TNM 184  
 diagnostic techniques 175–80  
 computerized tomography 179  
 fluorescein angiography 175  
 indocyanine green angiography 175–7  
 magnetic resonance imaging/spectroscopy 179  
 optical coherence tomography 179  
 photography 175  
 positron emission tomography 179–80  
 ultrasonography 177–8  
 examination 171–4  
 ancillary tests 174  
 fundus drawing 173  
 history taking 171  
 indirect ophthalmoscopy 171–3  
 slit lamp examination 171  
 three-mirror examination 173–4  
 transillumination 174  
 tumor dimensions 173  
 visual acuity 171  
 lymphoproliferative 316–21  
 primary choroidal lymphoma 316–19  
 primary iridal lymphoma 319–21  
 melanoma *see* uveal melanoma  
 metastatic 322–6  
 clinical features 322, 323  
 diagnostic evaluation 322–5  
 differential diagnosis 325  
 incidence and prevalence 322  
 prognosis 326  
 signs 322  
 symptoms 322  
 treatment 325–6  
 myogenic, fibrous and histiocytic 311–14  
 clinical features 311  
 cytogenetic analysis 313  
 diagnostic evaluation 311–12  
 differential diagnosis 314  
 fibrous tumors 314  
 follow-up 314  
 immunohistochemical findings 312–13  
 juvenile xanthogranuloma 314  
 Langerhans cell histiocytosis 314  
 leiomyosarcoma 314  
 pathogenesis 311  
 prognosis 314



- rhabdomyosarcoma 314
- salient diagnostic findings 312
- transmission electron microscopy 313
- treatment 314
- neural 300–3
  - uveal neurofibroma 300–2
  - uveal schwannoma 302–3
- osseous 305–10
  - choroidal osteoma 305–6
  - sclerochoroidal calcification 306–10
- vascular 289–98
  - ciliary body hemangioma 289
  - circumscribed choroidal hemangioma 289–97
  - diffuse choroidal hemangioma 297–8
  - iris hemangioma 289, 290
  - see also* uveal melanoma
- Vaquez-Osler disease 332
- varix 150
- vascular endothelial growth factor 16–17, 32
- vascular malformations 533–5, 534, 535, **536**
  - arterial-flow 535, 535
  - no-flow 533, 534
  - venous-flow 534, 534
- vascular tumors**
  - conjunctiva 150–1
  - eyelid 101–4
  - orbit 517, **518**, 533–8
    - capillary hemangioma **511**, **512**, 535–6, **536**
    - cavernous hemangioma 536–7, 537
    - hemangiopericytoma 537
    - vascular malformations 533–5, 534, 535, **536**
  - retina 341–6
    - capillary hemangioma 341–3
    - cavernous hemangioma 343–4, 394–5
    - vasoproliferative tumor 354–6
    - Wyburn-Mason syndrome 344–5
- V**
  - VEGF *see* vascular endothelial growth factor
  - velban 51, 52
  - vinca alkaloids 51, 52
  - vincristine 51, 52
    - retinoblastoma 451, 480
    - structure 451
  - viruses 8–9
  - visual acuity 171
  - vitrectomy 334–5
- vitreous hemorrhage 212
- von Hippel-Lindau disease 22, 32–3, 343, 389–91
  - clinical features 389–90
  - diagnostic evaluation 390
  - genetic aspects 389
  - pathogenesis 389
  - prognosis 390–1
  - treatment 390
- von Recklinghausen's disease 152
- W**
  - Wegener's granulomatosis 531
  - Wyburn-Mason syndrome 344–5, 394
- X**
  - xanthelasma 100
  - xanthogranuloma
    - conjunctiva 153
    - eyelid 100
  - xanthoma 153
  - xeroderma pigmentosum 165, 167
- Z**
  - Zimmerman's tumor 105