



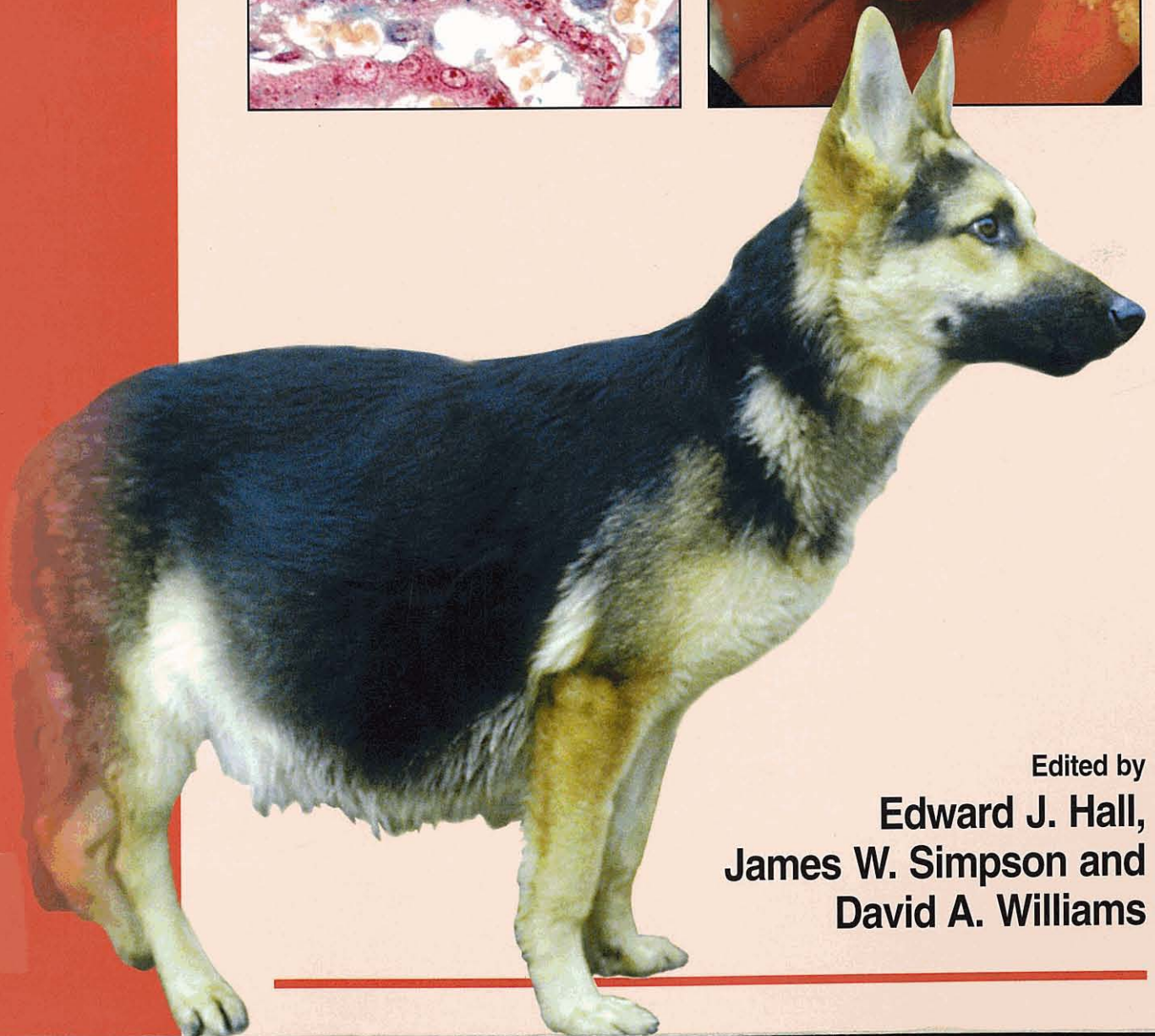
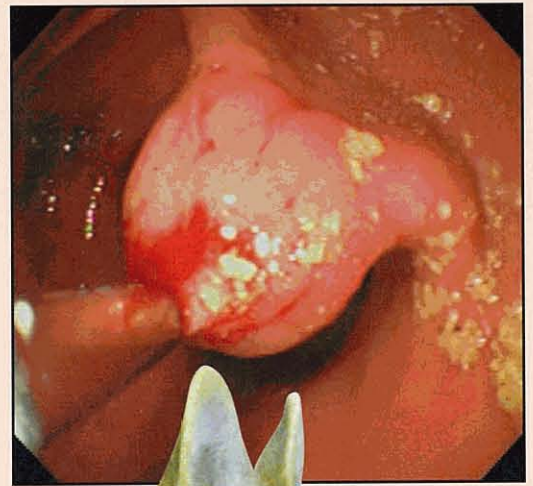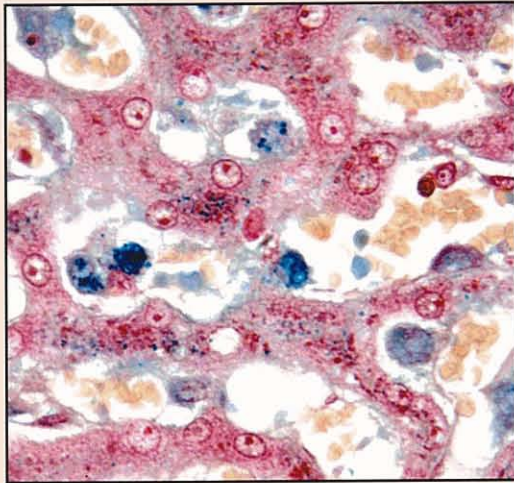
British  
Small Animal  
Veterinary  
Association

---

BSAVA Manual of  
**Canine and Feline  
Gastroenterology**

---

Second edition



Edited by  
**Edward J. Hall,  
James W. Simpson and  
David A. Williams**

---

---

# **BSAVA Manual of Canine and Feline Gastroenterology**

## **Second edition**

Editors:

**Edward J. Hall**

**MA VetMB PhD DipECVIM-CA MRCVS**

Department of Clinical Veterinary Science, University of Bristol,  
Langford House, Langford, Bristol BS40 5DU

**James W. Simpson**

**SDA BVM&S MPhil MRCVS**

Royal (Dick) School of Veterinary Studies,  
Easter Bush Veterinary Centre, Roslin, Midlothian EH25 9RG

and

**David A. Williams**

**MA VetMB PhD MRCVS DipACVIM DipECVIM-CA**

Department of Small Animal Clinical Sciences, 4474 TAMU,  
Texas A&M University, College Station, TX 77843-4474, USA

Published by:

**British Small Animal Veterinary Association**  
Woodrow House, 1 Telford Way, Waterwells  
Business Park, Quedgeley, Gloucester GL2 2AB

A Company Limited by Guarantee in England.  
Registered Company No. 2837793.  
Registered as a Charity.

Copyright © 2005 BSAVA

First edition 1996  
Second edition 2005

All rights reserved. No part of this publication may be reproduced, stored  
in a retrieval system, or transmitted, in form or by any means, electronic,  
mechanical, photocopying, recording or otherwise without prior written  
permission of the copyright holder.

The following illustrations were created by Ellen Williams, Mold,  
Flintshire: Figures 5.13b, 5.14, 5.15, 5.19, 5.20, 5.23, 5.24, 22.1,  
22.2, 22.3, 22.4 and 22.6.

Figures 1.11, 5.5, 5.7, 5.8, 5.9, 5.10, 5.12 and 17.1 were drawn  
by S. J. Elmhurst BA Hons. and are printed with her permission.

A catalogue record for this book is available from the British Library.

ISBN 0 905214 73 0

The publishers and contributors cannot take responsibility for information  
provided on dosages and methods of application of drugs mentioned  
in this publication. Details of this kind must be verified by individual users  
from the appropriate literature.

Typeset by: Fusion Design, Wareham, Dorset, UK  
Printed by: Replika Press Pvt. Ltd., India

---



156128

MITRA  
636.7/8.09  
HAL 6

# Other titles in the BSAVA Manuals series:

*Manual of Advanced Veterinary Nursing*  
*Manual of Canine & Feline Behavioural Medicine*  
*Manual of Canine & Feline Clinical Pathology*  
*Manual of Canine & Feline Dentistry*  
*Manual of Canine & Feline Emergency and Critical Care*  
*Manual of Canine & Feline Endocrinology*  
*Manual of Canine & Feline Haematology and Transfusion Medicine*  
*Manual of Canine & Feline Infectious Diseases*  
*Manual of Canine & Feline Nephrology and Urology*  
*Manual of Canine & Feline Neurology*  
*Manual of Canine & Feline Wound Management and Reconstruction*  
*Manual of Canine & Feline Oncology*  
*Manual of Companion Animal Nutrition and Feeding*  
*Manual of Exotic Pets*  
*Manual of Ornamental Fish*  
*Manual of Psittacine Birds*  
*Manual of Rabbit Medicine and Surgery*  
*Manual of Raptors, Pigeons and Waterfowl*  
*Manual of Reptiles*  
*Manual of Small Animal Anaesthesia and Analgesia*  
*Manual of Small Animal Cardiorespiratory Medicine and Surgery*  
*Manual of Small Animal Dermatology*  
*Manual of Small Animal Diagnostic Imaging*  
*Manual of Small Animal Fracture Repair and Management*  
*Manual of Small Animal Ophthalmology*  
*Manual of Small Animal Reproduction and Neonatology*  
*Manual of Veterinary Care*  
*Manual of Veterinary Nursing*  
*Manual of Wildlife Casualties*

## Forthcoming titles:

*Manual of Canine & Feline Abdominal Surgery*  
*Manual of Canine & Feline Articular Surgery*  
*Manual of Canine & Feline Head, Neck and Thoracic Surgery*  
*Manual of Canine & Feline Lameness Diagnosis*

For information on these and all BSAVA publications please visit our website: [www.bsava.com](http://www.bsava.com)

# Contents

---

List of contributors	v
Foreword	vii
Preface	viii
<b>Part 1: Diagnostic procedures</b>	
1 <b>Approach to the investigation of gastrointestinal diseases</b> <i>James W. Simpson</i>	1
2 <b>Laboratory evaluation of gastrointestinal disease</b> <i>Jörg M. Steiner</i>	13
3 <b>Imaging the gastrointestinal tract, liver and pancreas</b> <i>Robert T. O'Brien</i>	22
4 <b>Gastrointestinal endoscopy</b> <i>James W. Simpson</i>	34
5 <b>Gastrointestinal immunology and biopsy</b>	
a <b>Gastrointestinal immunology</b> <i>Michael J. Day</i>	50
b <b>Biopsy: sample collection</b> <i>John M. Williams</i>	57
c <b>Biopsy: handling, processing and interpretation</b> <i>Michael J. Day</i>	62
<b>Part 2: Presenting complaints</b>	
6 <b>Dysphagia and regurgitation</b> <i>Robert J. Washabau</i>	69
7 <b>Acute and chronic vomiting</b> <i>Kenneth W. Simpson</i>	73
8 <b>Acute diarrhoea</b> <i>Michael S. Leib</i>	78
9 <b>Chronic diarrhoea</b> <i>Albert E. Jergens</i>	82
10 <b>Malabsorption</b> <i>David A. Williams</i>	87
11 <b>Gastrointestinal haemorrhage</b> <i>Michael D. Willard</i>	91
12 <b>Dyschezia and tenesmus</b> <i>Albert E. Jergens</i>	94
13 <b>Ascites</b> <i>Edward J. Hall</i>	97
14 <b>Jaundice</b> <i>Susan E. Bunch</i>	103

---

---

15	<b>Hepatic encephalopathy</b> <i>Jill E. Maddison</i>	109
16	<b>Infectious and parasitic diseases</b> <i>Stanley L. Marks</i>	112
<b>Part 3:</b>	<b>Systems approach</b>	
17	<b>Disorders of the oral cavity</b> <i>Linda J. DeBowes</i>	122
18	<b>Disorders of the pharynx and oesophagus</b> <i>Robert J. Washabau</i>	133
19	<b>Diseases of the stomach</b> Kenneth W. Simpson	151
20	<b>Diseases of the small intestine</b> <i>Alexander J. German</i>	176
21	<b>Diseases of the colon and rectum</b> <i>Albert E. Jergens and Debra L. Zoran</i>	203
22	<b>Disorders of the perineum and anus</b> <i>John M. Williams</i>	213
23	<b>Diseases of the exocrine pancreas</b> <i>David A. Williams</i>	222
24	<b>Diseases of the liver</b> <i>Penny Watson</i>	240
25	<b>Diseases of the biliary system</b> <i>Jan Rothuizen</i>	269
<b>Part 4:</b>	<b>Critical care and therapeutics</b>	
26	<b>Critical care of patients with gastrointestinal disease</b> <i>Maureen McMichael</i>	279
27	<b>Feeding tubes</b> <i>Debra L. Zoran</i>	288
28	<b>Therapeutics</b> Edward J. Hall	297
<b>Appendices</b>		
	1 <b>Drug formulary</b>	313
	2 <b>Abbreviations used throughout the text</b>	319
	3 <b>Conversion tables</b>	321
<b>Index</b>		322

---

# Contributors

---

**Susan E. Bunch** DVM PhD DipACVIM  
13514 Steeplechase Drive, Bowie, MD 20715, USA

**Michael J. Day** BSc BVMS(Hons) PhD FASM DipECVP MRCPATH FRVS  
Division of Veterinary Pathology, Infection and Immunity, Department of Clinical Veterinary Science,  
University of Bristol, Langford, Bristol BS40 5DU

**Linda J. DeBowes** DVM MS DipACVIM (Small Animal) DipAVDC  
Shoreline Veterinary Dental Practice, 16037 Aurora Avenue North, Seattle, WA 98133-5653, USA

**Alexander J. German** BVSc(Hons) PhD CertSAM DipECVIM-CA MRCVS  
Department of Veterinary Clinical Sciences, University of Liverpool, Small Animal Hospital,  
Crown Street, Liverpool L7 7EX

**Edward J. Hall** MA VetMB PhD DipECVIM-CA MRCVS  
Division of Companion Animal Studies, Department of Clinical Veterinary Science, University of Bristol,  
Langford House, Langford, Bristol BS40 5DU

**Albert E. Jergens** DVM MS DipACVIM  
Department of Veterinary Clinical Sciences, College of Veterinary Medicine, Iowa State University,  
Ames, IA 50014, USA

**Michael S. Leib** DVM MS DipACVIM  
Virginia Maryland Regional College of Veterinary Medicine, Virginia Tech, Blacksburg, VA 24061, USA

**Jill E. Maddison** BVSc Dip.Vet.Clin.Stud PhD FACVSc MRCVS  
Beamont Animals' Hospital, Royal College Street, London NW1 0TU

**Stanley L. Marks** BVSc PhD DipACVIM (Internal Medicine, Oncology) DipACVN  
University of California Davis, School of Veterinary Medicine, Department of Medicine and Epidemiology,  
Davis, CA 95616, USA

**Maureen McMichael** DVM DipACVECC  
College of Veterinary Medicine and Biomedical Sciences, 4474 TAMU, Texas A&M University,  
College Station, TX 77843-4474, USA

**Robert T. O'Brien** DVM MS ACVR  
Vet Med Consultants, 4015 East Cactus Road, Phoenix, AZ 85032, USA

**Jan Rothuizen** DVM PhD DECVIM-CA  
Department of Clinical Sciences of Companion Animals, Faculty of Veterinary Medicine,  
University of Utrecht, Yalelaan 8, P O Box 80.154, 3508 TD Utrecht, Netherlands

**James W. Simpson** SDA BVM&S MPhil MRCVS  
Royal (Dick) School of Veterinary Studies, Easter Bush Veterinary Centre, Roslin, Midlothian EH25 9RG

**Kenneth W. Simpson** BVM&S PhD DipACVIM-CA DipACVIM MRCVS  
College of Veterinary Medicine, Cornell University, Ithaca, NY 14853-6401, USA

**Jörg M. Steiner** med.vet Dr.med.vet PhD DipACVIM DipECVIM-CA  
Department of Small Animal Medicine and Surgery, 4474 TAMU, Texas A&M University, College Station,  
TX 77843-4474, USA

---

**Robert J. Washabau** VMD PhD DipACVIM

Department of Veterinary Clinical Sciences, College of Veterinary Medicine, 1352 Boyd Avenue,  
University of Minnesota, St. Paul, MN 55108, USA

**Penny Watson** MA VetMB CertVR DSAM DipECVIM MRCVS

Queen's Veterinary School Hospital, Department of Veterinary Medicine, University of Cambridge,  
Madingly Road, Cambridge CB3 0ES

**Michael D. Willard** DVM DipACVIM

College of Veterinary Medicine, 4474 TAMU, Texas A&M University, College Station, TX 77843-4474, USA

**David A. Williams** MA VetMB PhD MRCVS DipACVIM DipECVIM-CA

Department of Small Animal Clinical Sciences, 4474 TAMU, Texas A&M University, College Station,  
TX 77843-4474, USA

**John M. Williams** MA VetMB CertVR FRCVS DipECVS

Oakwood Veterinary Referrals, 267 Chester Road, Hartford, Northwich, Cheshire CW8 1LP

**Debra L. Zoran** DVM PhD DipACVIM

Department of Small Animal Clinical Sciences, 4474 TAMU, Texas A&M University, College Station,  
TX 77843-4474, USA

# Foreword

---

For this second edition of the *BSAVA Manual of Canine and Feline Gastroenterology* the editors have successfully drawn together the knowledge of internationally recognized specialists.

The Manual is divided into four sections and has a logical and user-friendly layout. The first section provides a comprehensive overview of diagnostic methods and their interpretation. The second section takes a problem-solving approach to the investigation of presenting signs. This is complemented by the third section, which takes a 'systems approach'. Critical care and therapeutics comprise the final section to complete the manual. Sections are cross-referenced in order to make certain this is a 'joined-up' reference resource. The text is amply supplemented throughout with clear tables, photographs and excellent line drawings.

Thanks are due to the editors for their hard work in preparing the manual and to the authors for contributing their expertise and time to producing yet another high quality publication. As usual, thanks also go to the Publications Committee and the team at Woodrow House, without whose superb efforts no manual could be produced.

As with the previous edition I am confident that this manual will become an immensely valuable part of every practice library.

**Ian Mason** BVetMed PhD CertSAD DipECVD MRCVS  
**BSAVA President 2004–2005**



# Preface

---

This second edition of the *BSAVA Manual of Canine and Feline Gastroenterology* builds on the strengths of the first edition, incorporating not just new information available since its original publication in 1996, but also additional chapters on diagnostic techniques and a new section on problem solving based on the presenting complaint. The addition of an American-based editor, with contributions from many eminent gastroenterologists who are leaders in their field, strengthens the international appeal of the Manual. This is important because there are gastrointestinal diseases which, although currently restricted in geographical distribution, are already important to overseas readers, and may be important in the future to British veterinary surgeons as quarantine regulations are relaxed.

The book is divided into four parts – diagnostic techniques, presenting complaints, organ systems, and critical care and therapeutics – which are heavily cross-referenced to help give a logical approach to diagnosis and treatment of gastrointestinal and hepatic diseases. Each chapter is well illustrated, and the inclusion of video-endoscopic images highlights the power of this diagnostic modality. Other chapters in the first section include descriptions of how to perform radiographic and ultrasound examination of the gastrointestinal tract in practice (whilst giving an insight into potential future modalities) and diagnostic laboratory tests. The section concludes with a description of how to collect biopsy samples by endoscopy and surgery, and an exploration of the role of histopathology in diagnosis.

In the second part, short chapters provide a practical approach to the investigation of presenting complaints such as regurgitation, vomiting, diarrhoea, GI bleeding, ascites and jaundice. The third part adopts the more traditional organ-based systems approach to gastroenterology, passing through the conventional route from mouth to anus. The section includes new chapters on oral, anal and perineal diseases, as well as new information in chapters reprised from the first edition: the role of *Helicobacter* in gastritis; the distinction between antibiotic-responsive diarrhoea and small intestinal bacterial overgrowth; the immune dysregulation that underlies inflammatory bowel disease; and latest information on the diagnosis and treatment of pancreatic diseases. Hepatic diseases are subdivided into hepatocellular and biliary system chapters as our understanding of their differences grows.

The Manual concludes with a fourth part containing chapters on the increasingly sophisticated medical therapies available to treat gastrointestinal and hepatic diseases, and an appendix of drug dosages. Appropriate surgical techniques are recommended, but the reader is referred to the forthcoming *BSAVA Manual of Canine and Feline Abdominal Surgery* for instructions on how to perform such procedures. References for each chapter are restricted to important papers published since 2000, with further reading indicating key reviews for the keen reader requiring more information.

In summary, the editors believe this new edition of the *BSAVA Manual of Canine and Feline Gastroenterology* presents the most up-to-date information on gastrointestinal, pancreatic and hepatic disease in a format that gives the busy practitioner a logical approach to gastrointestinal problems and their solutions.

**Edward J. Hall**  
**James W. Simpson**  
**David A. Williams**

**December 2004**

# Approach to the investigation of gastrointestinal diseases

James W. Simpson

## Introduction

Disorders of the gastrointestinal (GI) tract are one of the commonest reasons for seeking veterinary assistance in small animal practice. The majority of alimentary disorders in dogs are self-limiting and are usually associated with dietary indiscretions; these patients respond well to symptomatic treatment. However, in a significant minority of dogs and in most cats, an investigation will be required either because the animal fails to respond to symptomatic treatment or because it is seriously ill from the outset.

Traditionally the GI tract includes not only the digestive tract but the liver and pancreas. It is natural to assume that patients presenting with vomiting and/or diarrhoea have a primary GI disorder but these signs may be observed in patients with systemic disease. Many of the signs are non-specific or vague and may not point directly to an alimentary tract problem. Even when symptoms such as jaundice are present, the clinician must consider a wider differential diagnosis than just liver disease and be aware of the possible presence of pre-hepatic or post-hepatic disease. In extreme cases the clinician can be completely misled; for example, a patient presenting with coughing, dyspnoea, pyrexia and exercise intolerance may have aspiration pneumonia secondary to oesophageal disease.

It is therefore very important when investigating a patient with suspected GI disease to start with the collection of a thorough history and then carry out a full physical examination. In this way systemic diseases will not be missed and vague or misleading presentations of alimentary tract disease will not be misinterpreted. The history assumes special importance when considering the alimentary tract because the majority of the tract is relatively inaccessible to routine physical examination, although diagnostic imaging may supplement information which might otherwise have been obtained from the physical examination. For example, physical examination of the oesophagus is limited to the cervical region, and disorders involving the thoracic oesophagus may be suspected from the history but cannot be confirmed from the physical examination alone.

It is also extremely important to be aware that some of the diseases of the GI tract are infectious, some of which are zoonotic. Therefore, when collecting a history from a client it may be useful not only to ask about vaccination status, but the health of in-contact animals

and the health of the owner. Where zoonotic disease is suspected precautions must be taken to ensure the safety of all practice personnel and other patients.

## Clinical recognition versus problem solving

When approaching a new clinical case the clinician has two options:

- Use clinical recognition
- Employ a problem-solving approach.

The majority of dogs and cats presented with GI signs will be diagnosed and treated by recognition of a set of clinical signs previously observed by the clinician in similar cases. The majority of these patients will respond to this treatment and make a full recovery. Good examples of this would be patients with parvovirus infection, haemorrhagic gastroenteritis and parasitism.

Where the patient fails to make a satisfactory recovery, is referred with a chronic history of alimentary tract disease or presents with a set of clinical signs which do not fit with a recognized pattern, then the clinician should adopt a problem-solving approach to the case.

## Problem-solving approach

With this method the clinician uses a systematic logical approach based on identifying all of the patient's problems. The basis of this system is shown in Figure 1.1 and always starts with the clinical examination, comprising a detailed history and a thorough physical examination of all body systems. The importance of carrying out a thorough clinical examination and formulating a diagnostic plan cannot be over-emphasized. The use of sophisticated diagnostic tests, such as ultrasonography and endoscopy, should be reserved for those cases where the clinical examination and investigation suggest their use; they should **not** be used to replace the clinical examination.

Once the clinical examination has been carried out a problem list can be established. This should take the form of a bullet point list of all abnormalities found during the history and examination. From this list the clinician can determine whether the patient's condition is life-threatening and in need of immediate therapy

Clinical features
Patient details: <ul style="list-style-type: none"> <li>• breed, age and sex of the patient</li> </ul> Owner's complaint or reason for seeking veterinary advice Previous medical history including: <ul style="list-style-type: none"> <li>• details of vaccination and worming</li> <li>• previous illnesses and operations</li> <li>• administration of any medications</li> <li>• other pets in the household</li> <li>• human illness</li> <li>• dietary management</li> <li>• overseas travel</li> <li>• reproductive history</li> </ul> Current history: <ul style="list-style-type: none"> <li>• when did the signs first appear?</li> <li>• expansion of the owner's complaint</li> <li>• detailed information regarding the function of all body systems</li> </ul> Physical examination of all body systems
Diagnosis
Problem list: <ul style="list-style-type: none"> <li>• a summary of all identified problems from the above data</li> </ul> Production of a differential diagnosis for each problem Diagnostic plan: <ul style="list-style-type: none"> <li>• a structured set of investigative procedures aimed at identifying the underlying cause, ruling out differentials or substantiating suspicions</li> </ul> Revised problem list based on primary investigations Second or third diagnostic plan to reach a definitive diagnosis
Treatment
Treatment protocol

**1.1** Method of carrying out a problem-solving approach to the investigation of alimentary tract disorders.

prior to further investigation. If this is the case a balance must be found between reaching a definitive diagnosis and providing supportive therapy. Wherever possible attempts should be made to collect samples prior to administration of even life-saving treatment, as this will prevent the emergency treatment interfering with the results of diagnostic tests. These samples will also provide a set of baseline results on which to assess response to treatment.

Sometimes the body system (or organ) responsible for these problems may be identified. It is important to assess whether all the problems fit a pattern which can be associated with a single disease or whether there is evidence of two or more concurrent diseases. For example, where problems such as vomiting, diarrhoea, jaundice and abdominal pain are recorded, a pattern can be seen where all the signs could be related to one disease, such as pancreatitis. Otherwise, a differential diagnosis should be made, and from this a diagnostic plan established.

The diagnostic plan aims to follow up the abnormalities detected and should consider the most valuable diagnostic procedures appropriate to the problem list. Selection of diagnostic tests should be made on the basis of how useful they will be in confirming or ruling out as many differential diagnoses as possible. Selecting such procedures will be cost effective and helpful in

reaching a definitive diagnosis. For example, a patient presented with regurgitation of food shortly after eating carries a differential diagnostic list that includes disorders of the pharynx and oesophagus. In this case, radiography is likely to yield highly valuable additional information and possibly a definitive diagnosis. Detection of a foreign body permits the clinician to proceed immediately to a treatment protocol. However, the presence of a megaesophagus confirms suspicions but requires a second diagnostic plan in order to reach a definitive diagnosis; this might include endoscopy to look for a stricture or oesophagitis and blood tests for hypoadrenocorticism and myasthenia gravis.

The ultimate aim of the diagnostic plan is to account for all the identified problems and obtain a definitive diagnosis. Consequently, the clinician can initiate specific therapy in order to treat the patient. If the patient fails to respond adequately the clinician should be prepared to re-assess the patient and, if necessary, carry out further diagnostic tests in order to reconfirm the diagnosis or address any inaccuracy in diagnosis. It must be remembered that the patient may have more than one disease present.

In some cases the clinician may not reach a definitive diagnosis through cost constraints or because the ability to carry out specialized tests is limited. In the former situation, as many differential diagnoses as possible should be ruled out and then the most likely condition treated, provided this treatment will do no harm. It is essential to evaluate the treatment regime and re-assess the patient if it fails. In the latter situation, the case should be referred to a specialist centre for further specific investigation.

## History

The first step in any investigation is to record the patient's details. This allows the clinician to consider specific conditions or any breed predisposition to alimentary tract disease (Figure 1.2). Consideration should be given to the patient's age as young animals are more likely to have a congenital or hereditary condition, while older animals are more likely to have acquired or neoplastic disease.

The previous medical history of the patient should be reviewed. It may yield important information regarding the cause of the present problem. For example, repeated episodes of chronic vomiting, diarrhoea and anorexia in a cat may be associated with chronic pancreatitis; a dog which has previously recovered from parvovirus infection may subsequently develop small intestinal absorptive difficulties.

Whether the environment in which the patient lives presents an increased risk of alimentary tract disease should be considered. A farm dog or cat may be able to scavenge or have access to a variety of chemicals and other toxic agents which predispose to alimentary tract disease.

The patient which has been kept indoors, adequately vaccinated and wormed is unlikely to develop distemper, infectious canine hepatitis, leptospirosis, feline or canine parvovirus, feline leukaemia, hookworms, or whipworms, while those living in a multi-pet household and with access to outdoors are more likely to.

Breed	Confirmed or suspected disease predisposition
<b>Dogs</b>	
Airedale Terrier	Pancreatic tumour
Basenji	Lymphocytic plasmacytic enteritis
Beagle	Chronic hepatitis
Bedlington Terrier	Copper hepatotoxicosis
Belgian Shepherd Dog	Gastric carcinoma
Boston Terrier	Vascular ring anomaly
Boxer	Histiocytic colitis
Bulldog	Vascular ring anomaly
Cairn Terrier	Portosystemic shunt; microvascular dysplasia
Chow Chow	Exocrine pancreatic insufficiency
Cocker Spaniel	Chronic hepatitis; pharyngeal dysphagia
Dobermann	Chronic hepatitis
Fox Terrier	Anal tumours
German Shepherd Dog	Exocrine pancreatic insufficiency; inflammatory bowel disease; antibiotic-responsive diarrhoea; megaesophagus; vascular ring anomaly
Golden Retriever	Inflammatory bowel disease, especially colitis
Great Dane	Gastric volvulus; megaesophagus
Irish Setter	Megaesophagus; gastric volvulus; gluten sensitivity; vascular ring anomaly
Irish Wolfhound	Megaesophagus; portosystemic shunt
Lhasa Apso	Pyloric stenosis
Jack Russell Terrier	Salivary gland necrosis
Poodle	Hepatic encephalopathy
Maltese	Haemorrhagic gastroenteritis; lymphangiectasia
Miniature Schnauzer	Haemorrhagic gastroenteritis; pancreatitis
Norwegian Lundehund	Protein-losing enteropathy and lymphangiectasia
Rottweiler	Lymphangiectasia; parvovirus enteritis; protein-losing enteropathy
Rough Collie	Gastric tumour; exocrine pancreatic insufficiency
Scottish Terrier	Chronic hepatitis
Shar Pei	Inflammatory bowel disease; food intolerance
Shih Tzu	Pyloric stenosis, cricopharyngeal achalasia
Soft Coated Wheaten Terrier	Protein-losing enteropathy and often concurrent protein-losing nephropathy
West Highland White Terrier	Chronic hepatopathy
Yorkshire Terrier	Portosystemic shunt; lymphangiectasia; protein-losing enteropathy
<b>Cats</b>	
General	Hepatic lipidosis
Abyssinian	Megaesophagus; inflammatory bowel disease
Bengal	Inflammatory bowel disease; feline infectious peritonitis
Manx	Constipation and faecal incontinence
Persian	Feline infectious peritonitis; polycystic kidneys/pancreas/liver; lymphocytic cholangiohepatitis
Siamese	Megaesophagus; pyloric stenosis; gastric tumours
Sphinx	Inflammatory bowel disease

**1.2** Confirmed and suspected species and breed predispositions to alimentary tract disease.

Diet plays an important part in the aetiology of alimentary tract disease, especially in the dog. In particular the type and amount of food given, including all snacks and treats, should be considered bearing in mind clients rarely view the latter as 'food' or 'diet'. Important questions include:

- Does the patient scavenge either food or water (i.e. drinking out of rivers or dirty puddles)?
- Have there been any sudden dietary changes or changes in the patient's appetite?

It should be noted that alimentary tract disease can present with a normal appetite, anorexia or polyphagia.

Many of the signs observed in patients with alimentary tract disease are not specific (Figure 1.3). It is therefore very important to ask questions about all body systems to ensure that a distinction can be made between primary disease of the alimentary tract and systemic disease (Figure 1.4). Although signs such as

Sign	A or S	Sign	A or S
Abdominal pain	A + S	Haematochezia	A + S
Anorexia	A + S	Halitosis	A + S
Ascites	A + S	Jaundice	A + S
Behaviour changes	A + S	Melaena	A + S
Borborygmi	A	Nausea	A + S
Coprophagia	A + S	Pica	A + S
Depression, lethargy	A + S	Polyphagia	A + S
Diarrhoea	A + S	Polyuria and polydipsia	A + S
Dyschezia	A	Ptyalism	A + S
Dysphagia	A + S	Tenesmus	A
Flatus	A	Vomiting	A + S
Haematemesis	A + S	Weight loss	A + S

**1.3** Signs associated with alimentary tract disease are almost all non-specific. They may be observed in dogs and cats with either primary alimentary tract disease (A) or systemic disease (S).

- Central nervous system trauma and tumours
- Diabetes mellitus
- Drug interaction: digoxin, morphine, codeine, xylazine
- Feline immunodeficiency virus
- Feline infectious peritonitis
- Feline leukaemia virus
- Hypoadrenocorticism
- Hypoparathyroidism
- Limbic epilepsy
- Masticatory myositis
- Meningitis
- Metastatic disease
- Motion sickness
- Myasthenia gravis
- Poisoning: lead, ethylene glycol, organophosphates
- Primary hyperparathyroidism
- Pyometra
- Renal failure
- Vestibular disease

**1.4** This figure lists some of the systemic diseases that may lead to signs of alimentary tract disease in the dog and cat.

vomiting, diarrhoea and jaundice may strongly suggest alimentary tract disease, they may all be associated with disease of other body systems.

In addition to recording the signs, it is important to note their duration and frequency as this helps reflect the severity of the disease. For example, a patient with inflammatory bowel disease (IBD) may present with a history of chronic vomiting for several weeks but may be still eating and relatively bright, whereas another patient with a pyloric obstruction may present with severe vomiting, dehydration and anorexia. Weight loss is another common feature of alimentary tract disease. The rapidity and severity of weight loss should be assessed. Clearly a patient that has been vomiting for several weeks but has maintained its body condition is less likely to be seriously ill than a patient which has the same signs but has lost 20% of its bodyweight. Although no rule can be established, it has been the author's experience that patients with a significant weight loss are often hypoalbuminaemic. Yet many of these patients will not show signs of ascites, hydrothorax or subcutaneous oedema which would normally draw the clinician's attention to the possibility of hypoalbuminaemia. Serum albumin and globulin concentrations should always be evaluated in the initial diagnostic evaluation of these patients.

**Appetite**

Appetite will vary considerably in patients with GI disease. Dysphagic patients are usually hungry and may even be described as polyphagic due to repeated attempts to eat. Where weight loss is associated with true polyphagia, the clinician should consider the pathway by which food is used by the animal. It is important to assess the quantity and quality of food ingested and whether signs could be due to digestive or absorptive failure, such as with exocrine pancreatic insufficiency (EPI) or IBD. Some patients are hypermetabolic and lose weight because of increased utilization of nutrients, as can occur with feline hyperthyroidism and neoplastic disease. Interestingly, although most EPI patients are polyphagic, most IBD patients are not and may have a normal or even depressed appetite. Coprophagia and pica are often associated with EPI but could be associated with specific nutrient deficiency. Anorexia is also observed in patients who are in pain, or where nausea is present.

**Thirst**

Usually thirst and urination remain normal in patients with alimentary tract disease. However, polydipsia may be seen in primary alimentary tract disease where the patient is losing water and electrolytes through vomiting and/or diarrhoea. Polyuria and polydipsia in conjunction with alimentary signs may be observed where there is systemic disease present, such as hypoadrenocorticism, hyperthyroidism, hepatopathy and renal disease.

**Halitosis**

This is most often associated with oropharyngeal disease or coprophagia. Occasionally it will be observed with pulmonary disease where a foreign body is present or in oesophageal or gastric disease where the mucosa is infected, and sometimes in malabsorption.

**Salivation**

Increased production of saliva or ptyalism is a normal physiological response to the sight, smell or taste of food. However, it may be associated with: oropharyngeal disease; as a response to irritant drug administration; where an oesophageal foreign body exists; and with limbic epilepsy. Excessive salivation has been observed in cats with portosystemic shunts and in dogs with gastric neoplasia. Impairment of the swallowing process will prevent the animal from removing normal amounts of saliva from the mouth, giving the impression of hypersalivation.

**Gas**

The production of excessive amounts of gas evidenced by eructation or flatulence may be associated with inappropriate diet or aerophagia. However, accumulation of gas may reflect a more serious alimentary tract disease, such as gastric dilatation and volvulus, motility disorders (e.g. ileus) or perhaps, most commonly, malabsorptive disorders.

**Abdominal pain**

The detection of pain in animals can be difficult due to their individual character and pain threshold. Changes in behaviour that suggest abdominal pain include

arching the back or adopting the praying position. This may be further evaluated by palpation of the abdomen during the physical examination.

**Ascites**

Abdominal enlargement associated with fluid accumulation is an important clinical finding in the patient with alimentary tract disease. There are many types of fluid that can accumulate in the abdomen and determining which type of fluid is present can be of considerable diagnostic value (Figure 1.5; see Chapter 13).

**Dysphagia**

This may be defined as difficulty in eating and is usually associated with either oral, pharyngeal or oesophageal disease (Figure 1.6), and almost always with eating. Regurgitation, which is a passive process involving no abdominal contractions, is the most common manifestation of dysphagia. Inhalation of food and fluid is common in the dysphagic patient. Consequently, there will usually be additional signs associated with the respiratory system, such as coughing or dyspnoea; the animal may also have pyrexia and show exercise intolerance. Occasionally dysphagic patients may present only with signs of respiratory disease because the owner has not observed the regurgitation (see Chapter 6).

Fluid type	Potential cause
True transudate	Hypoproteinaemia
Modified transudate	Cardiac failure; portal hypertension (liver disease)
Exudate	Septic and aseptic peritonitis; feline infectious peritonitis
Bile effusion	Ruptured gall bladder; perforated bile duct
Gut contents	Perforating foreign body or tumour; gunshot
Urine	Ruptured kidney, ureter or bladder
Blood	Clotting defect; haemangiosarcoma; trauma
Chylous	Tumour; trauma; idiopathic

**1.5** Ascites may have many causes. Classification of the fluid present allows the differential diagnosis to be reduced or a definitive diagnosis made.

Oral dysphagia <sup>a</sup>	Pharyngeal dysphagia <sup>b</sup>	Oesophageal dysphagia <sup>c</sup>
Caustic agent ingestion	Cranial nerve deficit	Botulism
Cleft palate	Cricopharyngeal achalasia	Canine and feline dysautonomia
Cranial nerve deficit	Foreign body	Diverticulum
Eosinophilic granuloma	Neoplasia: squamous cell carcinoma, tonsillar carcinoma, melanoma	Foreign body
Foreign body	Pharyngitis	Hiatus hernia
Fractured mandible	Rabies	Hypoadrenocorticism
Masticatory myositis		Lead poisoning
Pemphigus; systemic lupus erythematosus		Megaesophagus
Sialocele		Myasthenia gravis
Stomatitis; gingivitis; periodontal disease		Oesophagitis
Tooth fracture and abscesses		Organophosphate poisoning
Tumour		<i>Spirocerca lupi</i>
		Stricture formation
		Systemic lupus erythematosus
		Tumour
		Vascular ring anomaly

**1.6** This figure shows how dysphagia can be divided into three main categories and illustrates the disorders which may be associated with each division. <sup>a</sup> Problems with prehending food, constant chewing and food falling out of the mouth. <sup>b</sup> Associated with gagging, retching and food appearing at the nostrils. <sup>c</sup> Associated with regurgitation and aspiration pneumonia.

**Regurgitation versus vomiting:** Many clients report their pet to be 'vomiting' but in a significant minority of cases they are actually referring to the patient 'regurgitating'. It is therefore very important not to take the owners complaint of 'vomiting' at face value but to confirm what is actually happening by asking additional questions (Figure 1.7):

- Is the 'vomiting' associated with eating?
- Does the patient appear anxious, salivate and retch before food is brought up?
- Are there strong abdominal contractions present or does the patient simply arch its neck and expel the food?
- What is actually produced?

These questions will help the clinician determine which process is present and direct the investigation accordingly.

Sign	Regurgitation	True vomiting
Prodromal salivation	No	Yes
Prodromal retching	No	Yes
Abdominal contractions	No	Yes
pH of vomitus	Neutral or high	Usually low
Presence of bile	No	Yes
Sausage-shaped vomitus	Yes	No
Undigested food	Always	Sometimes

**1.7** This figure shows some of the ways in which regurgitation can be differentiated from true vomiting.

**Vomiting**

Unlike regurgitation, vomiting is an active process involving contraction of abdominal muscles against a fixed diaphragm. It may be associated with primary GI disease or may be secondary to systemic disease (Figure 1.8). The material produced can vary considerably from undigested food, to bile, water, blood and intestinal contents (see Chapter 7).

Projectile vomiting has been considered pathognomonic of pyloric outflow obstruction, but in fact may occur whenever there is severe GI disease. Vomiting is likely to be persistent where there is severe gastric inflammation or obstruction at the level of the pylorus or proximal small intestine.

Chronic intermittent vomiting is usually associated with chronic inflammation of the GI tract but may be observed in patients with distal small intestinal obstruction and intussusception. Where gastritis is present, the patient may vomit immediately after eating (often confused with regurgitation); however, in this situation it is associated with failure in receptive relaxation of the fundus to accommodate food thereby increasing intragastric pressure and reflexly causing vomition. Equally, some patients with gastritis develop gastric atony and may vomit undigested food many hours after eating. If the patient vomits bile this implies there has

Primary vomiting	Secondary (systemic) vomiting
Acute gastritis	Azotaemia and uraemia
Chronic gastritis	Central nervous system trauma or tumour
Colitis	Diabetic ketoacidosis
Gastric foreign body	Drugs: morphine, xylazine
Gastric neoplasia	Hyperthyroidism
Gastric ulceration	Hypoadrenocorticism
Hepatitis	Motion sickness
Hypertrophic gastritis	Poisons: ethylene glycol, lead
Intestinal obstruction	Pyometra
Intussusception	Vestibular disease
Lymphocytic-plasmacytic gastritis	
Pancreatitis	
Peritonitis	
Pyloric stenosis	

**1.8** The aetiology of vomiting carries a large differential diagnosis and includes primary alimentary tract disorders and secondary systemic diseases in the dog and cat.

been retroperistalsis of duodenal secretions into the stomach and consequently the pylorus must be patent. Bilious vomiting is most often observed in patients persistently vomiting on an empty stomach.

Occasionally patients will be reported to vomit 'faecal' material. This is associated with intestinal obstruction and retroperistalsis or with coprophagia. Haematemesis is often considered pathognomonic for primary gastric ulceration, but such bleeding may be associated with protracted vomiting with rupture of gastric capillaries, a clotting disorder or swallowing blood produced in the respiratory system, which is coughed up and swallowed (see Chapter 11). Where gastric ulceration is present it may be associated with neoplasia, eosinophilic gastritis or use of drugs, such as steroids or non-steroidal anti-inflammatory drugs. The detection of 'coffee grounds' in the vomitus reflects the presence of blood which has been degraded in the stomach by gastric acid and pepsin. It is important to note that not all patients with gastric ulceration exhibit haematemesis.

**Faeces**

The faecal character of patients with intestinal, pancreatic, hepatic or systemic disease may become diarrhoeic. Diarrhoea may be defined as the passage of faeces with a greater than normal content of water and/or nutrients. Equally, patients with colonic, rectal or anal disease may present with constipation, passage of very hard faeces or failure to pass faeces at all.

Diarrhoea is a common presenting complaint particularly in the dog but also in cats and it is important to determine the character of the diarrhoea during collection of a history (Figure 1.9). The questions are designed to try and assess whether the diarrhoea originates from the small or large bowel. Although usually rewarding, questioning can yield confusing results giving signs of both small and large bowel disease. This may reflect the fact that there is disease of both the small and large bowel, or that small bowel disease has overwhelmed the large bowel's functional reserve.

Symptom	Small bowel	Large bowel
Faecal volume	Increased	Decreased
Faecal frequency (motions per day)	Less than 3	More than 6
Urgency	Usually none	Often present
Tenesmus	Absent	Often present
Faecal mucus	Rare	Often present
Haematochezia	Rare	Often present
Melaena	May be present	Rare
Steatorrhoea	May be present	Absent
Dyschezia	Absent	May be present
Weight loss	Common	Rare
Vomiting	May be present	May be present
Flatus/borborygmi	Present	Absent

**1.9** During collection of a history, asking questions regarding the clinical signs may help the clinician determine the origin of the diarrhoea.

Faecal colour can vary considerably and changes in colour should be interpreted with caution. Truly acholic faeces with steatorrhoea may be observed in hepatic disease and post-hepatic bile duct obstruction (see Chapter 14). Where fresh blood, mucus and tenesmus are present, they are strong indicators of distal large bowel involvement. It should be noted that up to 30% of patients with colitis will present with vomiting as well as diarrhoea, but have no gastric disease. Where undigested food is present in the diarrhoea, together with significant weight loss, this points to EPI or small bowel disease. In these cases the diarrhoea will cease if the patient is starved, confirming the presence of an osmotic diarrhoea. Diarrhoea which does not resolve with dietary rest is likely to be secretory and may have an infectious aetiology. Patients with parvovirus produce a very characteristic diarrhoea which is usually fluid, contains blood and often mucosa and has a typical foetid smell. Patients with haemorrhagic gastroenteritis (HGE) also produce haemorrhagic foetid diarrhoea, but this differs from that seen in parvovirus patients as it more closely resembles whole blood.

Animals that produce normal faeces in the morning but progressively develop diarrhoea during the day may have irritable bowel syndrome (IBS) rather than pathological disease. In these cases the investigation should focus on the patient's environment. Most suspected cases of IBS occur in toy breeds and working dogs. Activity will also affect faecal quality, and patients which are hospitalized or restricted in exercise often develop constipation, hence the reason why many patients with diarrhoea improve on hospitalization.

Constipation carries a large and divergent differential diagnosis list (Figure 1.10) so the patient requires a thorough physical examination to identify the underlying problem. In addition, a careful examination of the perineal region for herniation and tumours, anal tone and for anal sac disease should be carried out. This should be followed by a rectal examination to determine whether there is obstruction to the passage of faeces.

- Colonic disorders:
  - stricture
  - tumour
- Dehydration
- Drug administration (codeine, morphine, sucralfate, barium sulphate contrast media)
- Feline and canine dysautonomia
- Food:
  - fur and hair ingestion
  - bones
  - high or very low fibre diets
- Hospitalization (inactivity)
- Megacolon
- Orthopaedic:
  - fractured pelvis
  - hindlimb injury
  - disc protrusion
- Paraprostatic cyst
- Prostatic disease
- Rectal disorders:
  - stricture
  - tumour
  - foreign body
  - perineal hernia
  - anal sac disease
  - anal furunculosis
  - pseudocoprostasis

**1.10** This figure shows the diverse aetiologies of constipation. It is important to remember it also includes disorders that are not associated with the intestinal tract.

**Physical examination**

This should not be viewed as a separate procedure but rather an extension of history collection. The physical examination should substantiate the historical findings and supplement them with additional observations, thus allowing the clinician to establish an overall impression of the patient.

- The clinician should:
1. Observe the unrestrained patient from a distance, and assess body condition, attitude to surroundings, posture, breathing pattern and general behaviour. If the patient is reported to be dysphagic, food or water is offered and the response observed.
  2. Examine each body system in turn and not concentrate solely on the alimentary tract. Examination of the mucous membranes will assist in determining whether the patient is dehydrated, shocked, anaemic or jaundiced. The capillary refill time will help assess peripheral perfusion. Peripheral lymph node enlargement may point to infection or neoplastic disease. Pyrexia suggests pain or infection while a subnormal temperature may reflect overwhelming disease or shock.
  3. Inspect the mouth and pharynx for ulceration, periodontal disease, halitosis, evidence of neoplasia or foreign bodies. If the patient is dysphagic a more detailed examination may be required under general anaesthesia. The exterior of the pharynx and neck should be palpated for pain and masses, especially thyroid masses in cats, and the cervical oesophagus for abnormalities.



4. Examine the thorax. Physical examination of the thoracic oesophagus is limited and, where the history supports a problem in this region, imaging should be used to obtain additional information. However, the thorax should be auscultated and percussed particularly as dysphagic patients may develop aspiration pneumonia. The heart should be auscultated as vascular ring anomalies causing dysphagia occasionally result in abnormal heart sounds. When the patient has ascites associated with hypoproteinaemia, auscultation and percussion of the thorax can assist in determining whether hydrothorax is present.
5. Palpate the abdomen. This should be carried out thoroughly and is generally easier in cats than in dogs. A sound knowledge of the topographical anatomy will assist in identifying abnormalities found during this part of the examination. Suddenly applying pressure to the abdomen will evoke 'boarding' or 'splinting', which is a normal reflex action and needs to be differentiated from abdominal pain. Pain, when present, may be generalized or localized to one quadrant of the abdomen. Figure 1.11 shows how it is possible to suggest the likely source of localized pain.

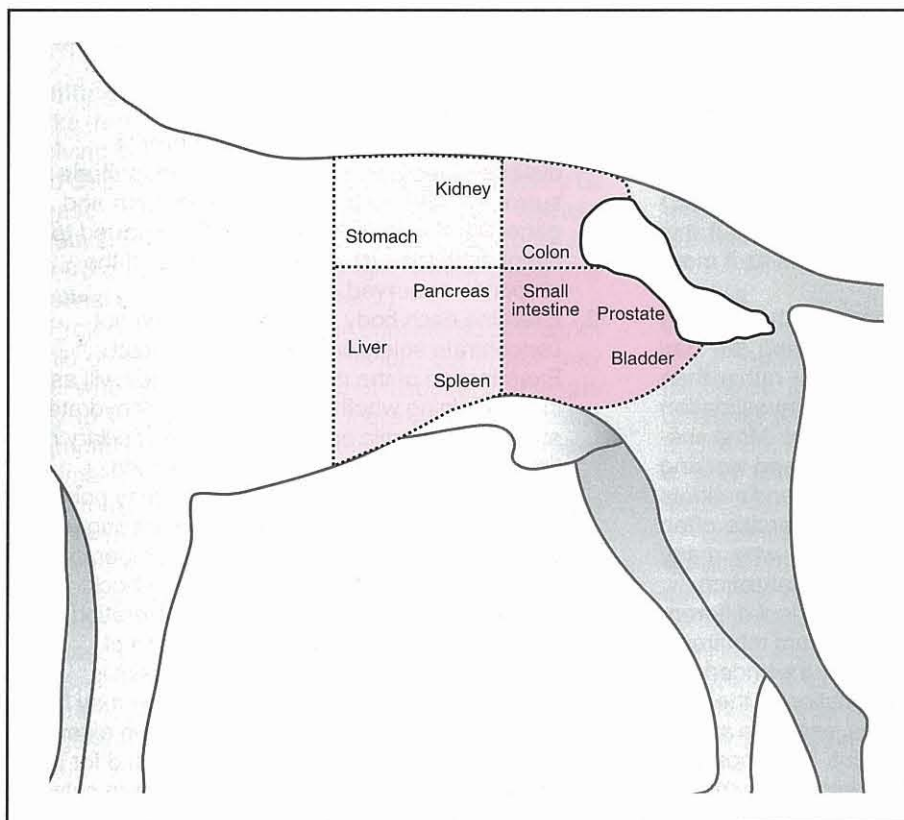
The abdomen is examined from behind with the patient standing. Using the finger tips gently to increase pressure over the abdomen the clinician can identify normal structures such as liver, spleen, kidneys and intestines. By being systematic, starting at the front of the abdomen and working backwards slowly, palpation should detect organomegaly, masses or fluid

accumulation. If palpation induces vomiting this usually indicates generalized peritonitis. The stomach is often difficult to palpate unless full because when empty it normally lies under the costal arch. To assist in gastric palpation, the patient may be elevated by its front legs.

When examining the small intestine the fingers should be spread on each side of the abdomen and gently drawn backwards, allowing the intestines to 'slip' through the fingers. This will minimize the chances of missing intestinal foreign bodies, tumours and intussusceptions. While palpating the intestine it is sometimes possible to gain an impression of wall thickness. In addition the presence of fluid, gas or hard faeces in the intestine can usually be determined. Lack of borborygmi detected by auscultation of the abdomen can assist in determining the presence of ileus.

Palpation of the colon is often best initiated at the pelvic inlet, where a faecal-filled colon can usually be detected. The fingers can be moved forward slowly along the length of the descending colon until the costal arch is reached. Here the transverse and ascending colon start and are less easily palpated.

6. Examine the perineal region and perform a rectal examination. These examinations should be carried out routinely in patients with alimentary signs. The examination aims to rule out the presence of perineal hernia, anal sac disease, rectal stricture, tumours or foreign bodies. Assessing anal tone is particularly



**1.11** Careful palpation of the abdomen can yield valuable diagnostic information. The clinician aims to identify normal structures and any abnormal structure suggesting the presence of pain, foreign bodies, masses or fluid accumulations. By dividing the abdomen into four sections, it should be possible to localize the lesion detected to one quadrant and then to consider what tissues normally lie in this area and could therefore be involved.

important in those cases presenting with faecal incontinence. Prostatic size and pelvic canal dimensions can be determined by the rectal examination. Finally carrying out a rectal examination permits the clinician to detect the presence of fresh blood or melaena.

**Problem list**

From the clinical examination the clinician can produce a problem list. This is a bullet point summary of the abnormalities detected in the history and physical examination. From this list the clinician can look for patterns of disease and ask the following questions.

- Do all the problems fit with disease of the alimentary tract or do they suggest a systemic disease?
- Do the problems appear divergent suggesting more than one disease process is present?
- What are the differential diagnoses for the problems?

**Diagnostic plan**

A differential diagnosis should be produced from the problem list and a diagnostic plan established. The initial diagnostic plan aims to use a diagnostic test to reach a definitive diagnosis where the problems clearly point towards one disease, or to follow up identified problems in order to get closer to the definitive diagnosis. In the latter case a second, and sometimes a third, diagnostic plan may be required using more specific tests in order to reach a definitive diagnosis. The types of diagnostic tests used in assessing patients with alimentary tract disease are shown in Figure 1.12.

**Initial diagnostic (screening) tests**

**Routine haematology:** In general, haematology is not a high yielding diagnostic procedure in primary alimentary tract disease. It is more likely to be of diagnostic value where systemic disease is suspected. Where melaena, haematochezia or haematemesis is detected, measuring red cell indices, including reticulocytes and platelets, together with clotting factors, may be of value. Infectious disease may result in changes in the white cell series, especially in those cases where translocation of infection from the intestine has taken place. Alimentary parasitism may produce a persistent eosinophilia. Dogs and cats with alimentary lymphoma rarely show systemic changes in the white cell picture, although occasionally the lymphocyte count may be low. This may also be observed with lymphangiectasia. Hypoadrenocorticism may result in lymphocytosis and eosinophilia.

**Serum biochemistry:** Serum biochemistry can be valuable in the investigation of both primary alimentary tract and systemic disease. It is extremely important to interpret biochemical results in relation to the patient. Carrying out screening tests as a short cut to diagnosis, instead of carrying out a thorough clinical examination, will lead to incorrect interpretation of results, misdiagnosis and failure of treatment.

Initial diagnostic plan
Routine haematology
Serum biochemistry
Urinalysis
Faecal analysis – direct smear and flotation, selective bacterial culture
Survey radiography
Specific diagnostic tests
ACTH stimulation test
Serum trypsin-like immunoreactivity (TLI)
Serum folate and cobalamin assay
Breath hydrogen assay
Duodenal aspiration and culture
Serum lipase
Serum pancreatic lipase immunoreactivity (PLI)
Liver function tests – serum bile acids, pre- and postprandial bile acids
Survey and contrast radiography
Fluoroscopy
Ultrasonography
Endoscopy
Exploratory laparotomy
Dietary trials
Drug therapy

**1.12** In the majority of clinical cases the tests shown in the initial diagnostic plan will allow a diagnosis to be reached. However, in other cases the initial tests will indicate the most likely diagnosis, which can be confirmed using more specific tests carried out in a second diagnostic plan.

Elevations in serum alanine aminotransferase (ALT), aspartate aminotransferase (AST), gamma glutamyl transferase (GGT), alkaline phosphatase (ALP) and bilirubin suggest hepatic disease. Care should be taken in assessing ALP levels in dogs as it may be elevated during bone growth, bone disease and endogenous and exogenous steroid administration. Unlike in the dog, ALP tends not to become elevated after steroid administration in the cat or in feline cholestatic disease, although it is often elevated in feline hepatic lipidosis. In the cat GGT is a better marker of cholestasis than ALP. The ratio of conjugated to unconjugated bilirubin as a method of differentiating hepatic from post-hepatic disease (van den Bergh test) is extremely unreliable and should not be used.

The presence of hyponatraemia or hyperkalaemia may reflect hypoadrenocorticism, although electrolyte abnormalities may be absent in this disease. Serum electrolyte changes similar to those seen with hypoadrenocorticism have also been observed in primary GI diseases. An adrenocorticotrophic hormone (ACTH) stimulation test is required to make a definitive diagnosis regarding the presence or absence of hypoadrenocorticism.

Elevations in blood urea and creatinine suggest renal disease or severe dehydration. Urinalysis together with assessment of serum calcium and phosphate concentrations usually helps to clarify the underlying cause. Elevations in blood urea alone may occur with GI bleeding, while low blood urea levels together with elevations in serum ammonia may be associated with portosystemic shunts.

Serum protein measurements can be very useful in GI investigations. Panhypoproteinaemia (low albumin and globulin) is most often seen with protein-losing enteropathy (PLE). However, occasionally hypoproteinaemia may be associated with a fall in albumin alone. In these cases the changes are more likely to be due to hepatic or renal disease, although PLE should still be considered. Albumin tends to fall late in hepatic disease, so significant changes in liver enzymes and function tests should be present, and where protein-losing nephropathy (PLN) is suspected, urinalysis will reveal proteinuria. Hyperglobulinaemia (values >70 g/l) is a feature of two feline diseases: feline infectious peritonitis and lymphocytic cholangiohepatitis; and it may occur in some dogs with PLEs, particularly Basenji dogs and dogs with fungal enteropathies.

**Urinalysis:** In addition to detecting the presence of renal disease, urinalysis can assist in the assessment of the state of hydration. A significantly increased urine protein:creatinine ratio indicates the presence of PLN, which sometimes occurs concurrently with PLE, especially in Soft Coated Wheaten Terriers. Some patients with hepatic disease, and especially those with cirrhosis or portosystemic shunts, excrete ammonium biurate crystals in their urine. Bilirubin can normally be conjugated and excreted by the canine kidney. However, this is not the case in cats, where the presence of bilirubinuria is always considered abnormal and suggests hepatic disease.

**Faecal analysis:** Faecal analysis for parasites and selected bacterial pathogens should be carried out in all patients presenting with diarrhoea. The types of diagnostic test that can usefully be performed on faeces are shown in Figure 1.12.

The presence of undigested food particles may suggest maldigestion, but this must be confirmed by carrying out more specific tests, such as the trypsin-like immunoreactivity test (TLI), and such faecal examination is no longer recommended. Similarly, measuring faecal proteolytic activity using X-ray film, gelatin tube and azo-casein plates should be avoided as they frequently yield false results and have been superseded by the TLI test in both dogs and cats.

Various tests are available for the detection of intestinal parasitism (see Chapter 16). Salt flotation is used to detect nematode and cestode eggs. Where giardiasis is suspected at least three zinc sulphate flotations or an enzyme-linked immunosorbent assay test should be carried out. Repeat examinations for *Giardia* cysts are required as parasites are excreted intermittently. It is occasionally possible to observe *Giardia* trophozoites and cysts in fresh faecal smears, but these are very unreliable.

Culture of faeces for bacterial pathogens such as *Salmonella* spp., *Campylobacter* spp., *Clostridium difficile* and *Clostridium perfringens* can be carried out (see Chapter 16). However, rectal samples do not necessarily reflect bacterial populations within the small intestine and repeat cultures may be required as pathogens are often excreted intermittently. Confirming the presence of *C. perfringens* can be difficult

and its significance is still uncertain. In general it is necessary to detect not the organism (which is often present in normal dogs) but rather the toxin. The latter test is limited to very few commercial laboratories and tends to be very expensive. The importance of *Escherichia coli* in feline and canine gastroenterology is unclear. There appear to be some pathogenic strains, but the availability of tests to detect these strains is still very limited and their significance is still controversial.

When bleeding into the GI tract is suspected, an occult blood test can be carried out. Tests cross-react with meat-containing foods so there may be a requirement to feed a special diet for at least 3 days prior to testing (see Chapter 2).

**Survey radiography:** Survey chest and abdominal radiographs are important diagnostic tests in patients with regurgitation, vomiting and acute diarrhoea but are less helpful in cases of chronic diarrhoea. They allow identification of foreign bodies, obstructions and masses (see below and Chapter 3).

#### **Specific diagnostic tests**

Specific procedures, such as ultrasonography, endoscopy and exploratory laparotomy, should not be used to replace the clinical examination, formation of a problem list and initial diagnostic plan. The tests in this category are reserved for those cases where the investigation strongly supports a specific disease, so the test chosen will yield a definitive diagnosis. For example, where chronic diarrhoea or weight loss is reported, EPI is a major differential diagnosis and a TLI test will confirm or refute the diagnosis. Where the patient presents with vomiting, jaundice and anterior abdominal pain and the liver enzyme tests are elevated, it would be appropriate to carry out liver function tests and tests for pancreatitis, together with ultrasound examination of the liver and pancreas. Specific organ biopsy may be required to make a definitive diagnosis.

**ACTH stimulation test:** This test should be carried out if there are clinical signs or electrolyte changes that make hypoadrenocorticism a possibility.

**Serum trypsin-like immunoreactivity test:** Species-specific TLI tests are now available for both dogs and cats and allow a definitive diagnosis of EPI in both species. The TLI test may also be used to assist in reaching a diagnosis of pancreatitis. However, the TLI assay is less sensitive than the newer serum pancreatic lipase immunoreactivity (PLI) test, which is more reliable for the diagnosis of pancreatitis (see Chapter 23).

**Serum folate and cobalamin:** Measurement of these vitamins is useful for the detection of small intestinal disease. Where concentrations of serum folate and cobalamin are very low (in the absence of EPI) they indicate the presence of severe small intestinal disease. Furthermore, vitamin supplementation may be required to rectify deficiency states. Serum folate and

cobalamin concentrations have also been used to detect the presence of small intestinal bacterial overgrowth (SIBO). However, the definition of SIBO is controversial and results should be interpreted with great caution (see Chapters 2 and 20).

**Breath hydrogen assay:** Measuring exhaled hydrogen levels in dogs and cats after ingestion of a test meal or substrate, such as glucose, has been used to detect the presence of carbohydrate malabsorption. The principle of the test relies on overgrowing bacteria in the intestine metabolizing the sugar and producing hydrogen as a by-product. This is absorbed and excreted in exhaled breath. Unfortunately, multiple protocols for breath hydrogen testing have been described and none has been widely adopted (see Chapters 2 and 20).

**Duodenal aspiration and culture:** Duodenal aspirates collected by endoscopic catheter placement can be of diagnostic value. Aspirates have been used to detect *Giardia* trophozoites and pathogenic bacteria such as *Salmonella* spp. However, the main use of duodenal aspiration and culture has been for the detection of SIBO, and has traditionally been considered the gold standard test for this condition. However, bacteriological culture of duodenal aspirates is now recognized to be an unreliable method to quantify the endogenous microflora and in any case practical constraints and expense limit the application of this approach (see Chapter 20).

**Serum amylase and lipase:** Serum amylase and lipase activities have previously been used to support a diagnosis of acute pancreatitis but are now considered to be unreliable because neither is pancreas-specific in origin and because any impairment of renal function will reduce excretion of these enzymes and artificially elevate their activities. Furthermore, it is not uncommon for animals with pancreatitis to have normal activities of both enzymes. However, recently developed assays for canine and feline PLI appear to overcome these limitations, and provide tests for pancreatitis that appear to be both sensitive and specific (see Chapter 23).

**Liver function tests:** Elevations in liver enzymes indicate hepatocyte damage and cholestasis but they do not measure liver function. Where the clinical examination and liver enzyme tests suggest liver disease to be present, it is important to carry out additional tests that will detect liver dysfunction. Serum bile acids, a bile acid stimulation test and measurement of serum albumin, ammonia and clotting factors will give an indication of liver function. Liver biopsy will be required to reach a definitive diagnosis (see Chapter 24).

**Intestinal function tests:** A relatively large number of dynamic function tests have been used in the past to assess small intestinal and pancreatic function. Specifically, the xylose absorption test, fat absorption test and benzoyl-tyrosyl para-amino-benzoic acid (BT-PABA) test have been used, but have now been

consigned to history. However, intestinal sugar permeability testing may still be of value. In these tests two or more sugars (a monosaccharide and disaccharide) are given orally and the amount absorbed and excreted in the urine measured over 6 hours. The tests are designed to detect increased intestinal permeability to some sugars related to reduced intestinal surface area or enterocyte dysfunction, all of which may be associated with IBD or intestinal neoplasia (see Chapter 2).

**Plain and contrast radiography, and fluoroscopy:** Plain radiographs of the thorax are invaluable in assessing the thoracic oesophagus, as it cannot be examined as part of the physical examination. Where an abnormality is detected these films may be supplemented by contrast studies, often carried out using fluoroscopy. Contrast studies are particularly valuable in patients presenting with dysphagia but should not be used where oesophageal perforation is suspected.

Plain radiography of the abdomen should always be carried out on patients presenting with vomiting, an acute abdomen or where there is suspicion of obstruction. The value of abdominal radiography in patients with chronic diarrhoea is limited. Contrast studies may be used to assess gastric emptying, intestinal transit or confirm obstruction. However, contrast media should not be used when perforation is suspected. Barium impregnated polyethylene spheres (BIPS) are now available for a simpler assessment of gastric emptying and intestinal transit time. In addition, BIPS may be used to detect a partial obstruction. Plain radiography may be used to detect peritonitis, fluid accumulations and abnormalities of the liver and possibly the pancreas.

Angiography, involving catheterization of a mesenteric vein and use of an iodine-based contrast medium, is of particular diagnostic value in detecting the presence of portosystemic shunting. In some cases portosystemic shunts may be diagnosed using ultrasonography.

**Ultrasonography:** The diagnostic value of ultrasonography in the investigation of the alimentary tract disease cannot be over-stated. In experienced hands this is a very powerful diagnostic tool that is being used with increasing frequency in gastroenterology. Not only can the architecture of the tissues be assessed, but the size of organs and especially the intestinal wall thickness can be measured, motility observed, lymph nodes assessed and small fluid accumulations detected. Ultrasonography can be used to assist in collection of biopsy samples for histopathology and for detecting abnormal blood flow to the liver.

**Endoscopy:** Endoscopy is another powerful diagnostic tool when used in the right circumstances by an experienced operator. Where adequate evidence has been collected from the clinical examination and initial diagnostic tests indicate oesophageal, gastric or intestinal disease, endoscopy may be considered the most effective method of reaching a definitive diagnosis. Not only can the mucosal surface of the oesophagus,

stomach, duodenum, jejunum and colon be assessed but biopsy samples can be collected from these areas. In addition, endoscopy can be used to remove some oesophageal and gastric foreign bodies. Where specialist equipment is available, oesophageal strictures can be dilated with balloon catheters and minor surgical procedures, such as polyp removal using diathermy, can be carried out. Gastrostomy tubes may also be placed during endoscopy. Being a relatively non-invasive technique, endoscopy allows the clinician to re-assess the GI tract following treatment, a procedure which most clients find acceptable where repeat exploratory laparotomy would not be.

**Biopsy:** Samples collected by endoscopy are small and only sample the mucosa, and it is therefore possible to miss deeper lesions. Thus, in each individual case the clinician must determine whether endoscopy or exploratory laparotomy is the most effective method of progressing the investigation to reach a definitive diagnosis (see Chapter 4).

**Dietary and drug regimes:** There is no definitive method available for the detection of true dietary sensitivities, although serum tests that measure immunoglobulin levels to food antigens are available. Since no laboratory tests are reliable when food sensitivity is suspected, a dietary trial must be employed as a diagnostic procedure, using a novel protein source together with a single carbohydrate fed to the exclusion of all other foods. If a favourable response is obtained, provocative testing using previous dietary ingredients can be carried out to confirm specific sensitivities (see Chapter 20).

Diet does also play an important part in the management of many GI disorders, especially IBD. The mechanism of action of diet in IBD is not clear and may be due to correction of a dietary sensitivity, provision of different fermentable or non-fermentable fibres, or to modification of the intestinal flora.

The use of diets and or drugs as diagnostic tests, other than described above, should be avoided. The

employment of empirical treatment regimes in chronic alimentary tract disease will usually fail and ultimately cost more than initiating a proper problem-solving investigation as described in this chapter.

## References and further reading

- Bissett SA, Guilford WG and Spohr A (1997) Breath hydrogen testing in small animal practice. *Compendium on Continuing Education for the Practising Veterinarian* **19**, 916–931
- Burrows CF (1994) An approach to the patient with chronic diarrhoea. *Proceedings WSAVA, Durban, South Africa*, pp. 346–351
- Delles EK (1992) Chronic vomiting in the dog. *Waltham Focus* **2**, 14–19
- DiBartola SP, Johnson SE, Davenport DJ, Prueter JC, Chew DJ and Sherding RG (1985) Clinicopathological findings resembling hypoadrenocorticism in dogs with primary gastrointestinal disease. *Journal of American Veterinary Medical Association* **187**, 60–63
- Hart CA, Embaye H, Getty B, Saunders JR and Batt RM (1990) Ultrastructural lesions to the canine intestinal epithelium caused by enteropathogenic *E. coli*. *Journal of Small Animal Practice* **31**, 591–594
- Marks SL, Katter EJ, Kass PH and Melli AC (2002) Genotypic and phenotypic characterisation of *Clostridium perfringens* and *Clostridium difficile* in diarrheic and healthy dogs. *Journal of Veterinary Internal Medicine* **16**, 533–540
- Quigg J, Bryden G, Ferguson A and Simpson JW (1993) Evaluation of canine small intestinal permeability using the lactulose/rhamnose urinary excretion test. *Research in Veterinary Science* **55**, 326–332
- Simpson JW (2001) Pathophysiology of vomiting. *UK Vet* **6**, 27–30
- Simpson JW (2001) Problem orientated small animal medicine. *UK Vet* **6**, 36–42
- Simpson JW and Else RW (1991) Diseases of the large intestine. In: *Digestive Disease in the Dog and Cat*, ed. JW Simpson and RW Else pp. 140–169, Blackwell Scientific Publications, Oxford
- Simpson KW, Simpson JW, Lake S, Martin DB and Batt RM (1991) Effects of pancreatectomy on plasma activities of amylase, isoamylase, lipase and trypsin-like immunoreactivity in dogs. *Research in Veterinary Science* **51**, 78–82
- Stonehewer J, Mackin AJ, Tasker S, Simpson JW and Mayhew IG (2000) Idiopathic phenobarbital responsive hypersiallosis in the dog: an unusual form of limbic epilepsy. *Journal of Small Animal Practice* **41**, 416–421
- Tams TR (1992) Irritable bowel syndrome. In: *Current Veterinary Therapy XI*, ed. RW Kirk et al., pp. 604–608. WB Saunders, Philadelphia
- Tasker S and Gunn-Moore D (2000) Differential diagnosis of ascites in cats. *In Practice* **22**, 472–479
- Yam P (1997) Decision making in the management of constipation in the cat. *In Practice* **19**, 434–440
- Willard M (1989) Chronic intestinal bacterial overgrowth. In: *Current Veterinary Therapy X*, ed. RW Kirk et al., pp. 933–938. WB Saunders, Philadelphia

# Laboratory evaluation of gastrointestinal disease

Jörg M. Steiner

## Introduction

Clinical signs of gastrointestinal (GI) disease, such as changes in appetite, vomiting, weight loss and diarrhoea, are extremely common in small animal patients. When seeking advice from a veterinary surgeon, pet owners expect an accurate diagnosis and definitive therapy of the problem. In few cases can the diagnosis be made by physical examination alone, e.g. an oral foreign body. Usually the veterinary surgeon has to use tests to make a diagnosis, and a major challenge is to choose the most appropriate tests to arrive at an accurate diagnosis. Intestinal biopsy is an important diagnostic test and is discussed in detail in Chapter 5.

## Choosing a test

Prior to discussion of a number of laboratory tests, the following paragraphs outline important epidemiological factors that should be considered when choosing diagnostic tests (see Figure 2.1). In general, clinicians should only perform diagnostic tests when the result of the test will have an impact on patient management. This principle can be expressed more scientifically by stating that:

- A diagnostic test should only be performed if the post-test probability for a disease is either significantly less than, or significantly greater than, the pre-test probability.

The pre-test probability in a given patient is determined by the prevalence of the disease in a particular population of animals. For example, the pre-test probability for exocrine pancreatic insufficiency (EPI) in any dog is probably somewhere in the range of 0.01%; that is one in 10,000 dogs is affected. The pre-test probability might increase to 1.0% if one were to limit the population to German Shepherd Dogs, and would be even higher, perhaps 10.0%, if one were to evaluate only German Shepherd Dogs with chronic diarrhoea and weight loss.

- The relationship of pre-test and post-test probability is determined by the likelihood ratio, which is defined as the probability that a specific test result will be found in patients with the disease, divided by the probability that the same test result will be found in a patient without the disease.

The likelihood ratio can be calculated from studies that evaluate the test in a group of clinical patients (Figure 2.1).

Patients	Test results		
	Positive	Negative	Test sums
Patients with disease	A	B	A + B
Patients without disease	C	D	C + D
Patient sums	A + C	B + D	A + B + C + D

Sensitivity =	$A/(A + B)$
Specificity =	$D/(C + D)$
Accuracy =	$[A/(A + B)] \times [D/(C + D)]$
Prevalence =	$(A + B) / (A + B + C + D)$
Positive predictive value =	$A/(A + C)$
Negative predictive value =	$D/(B + D)$
Likelihood ratio for a positive test =	$[A/(A + B)] / [C/(C + D)]$
Likelihood ratio for a negative test =	$[B/(A + B)] / [D/(C + D)]$

### 2.1

Definition of epidemiological parameters. This figure gives the mathematical formulae for deriving some important epidemiological parameters that are used to describe the clinical usefulness of diagnostic tests.

## Evaluating test results

Other, more commonly used parameters of the clinical usefulness of diagnostic tests are sensitivity, specificity, accuracy, positive predictive value and negative predictive value (see Figure 2.1).

- Sensitivity is a measure of how well a diagnostic test identifies patients with a disease.
- Specificity is a measure of how well the test distinguishes patients with the disease from those that do not have the disease.
- Accuracy is derived from the multiplication of sensitivity and specificity and reflects overall test performance.

Sensitivity and specificity are characteristic for each test and are not influenced by the prevalence of the disease. However, the clinician also needs some sense of how to interpret a test result in light of the population examined.

- Positive predictive value is a measure for the confidence the clinician can place in a positive test result.

- Negative predictive value is a measure of how confident the clinician can be to exclude the disease in a patient with a negative test result.

Predictive values do depend on the prevalence of the disease in the test population, which should be taken into account when evaluating the clinical usefulness of a new diagnostic test, i.e. if a disease is rare, the chances of a test result indicating a true positive may be outweighed by the chances of a false-positive.

Another issue that must be carefully considered when evaluating test results is that of 'cut-off' values. While some diagnostic tests are either negative or positive, most will yield a quantitative result that needs to be interpreted. This is achieved by comparing the result observed in a diseased animal with that of healthy animals (reference, control or normal population). However, a result outside the reference range does not necessarily indicate disease, and cut-off values need to be determined that afford the best test characteristics for the diagnosis of a disease. A result outside the reference range may have different implications for different tests. For example, if the upper limit of the reference range for serum creatinine concentration is 120 mmol/l, a result of 150 mmol/l may very well be significant, whilst a serum alanine aminotransferase (ALT) activity of 76 IU/l in a dog may be of no significance if the reference range is 0–65 IU/l. Therefore, for each diagnostic test a cut-off value that determines whether a result is abnormal enough to warrant diagnosis of a disease must be identified.

## Tests for gastric diseases

### Bacteriology

#### *Helicobacter*

*Helicobacter pylori* is one of the most important infectious organisms in human beings and is believed to be responsible for a wide variety of gastric disorders. *Helicobacter pylori* has not been identified in naturally infected dogs and cats, but several other *Helicobacter* spp. have frequently been identified in both species. The pathogenic impact of *Helicobacter* spp. in dogs and cats is still unknown, but when no other aetiology for gastric disease can be identified and the presence of *Helicobacter* spp. can be verified, it may be prudent to recommend trial therapy.

A number of different tests have been described for the diagnosis of *Helicobacter* infections.

- Cytological examination of touch preparations after Gram or Diff-Quik staining has been reported to be sensitive for diagnosing *Helicobacter* infections.
- *Helicobacter* organisms can also be observed by histopathology, but special stains may be required when the colonization density is low.
- Quick-urease tests are simple and rapid. One or more biopsy sample(s) are collected and placed into the testing device. The device contains urea and a pH indicator. If *Helicobacter* organisms are present urease from these organisms breaks

down urea to ammonia, leading to a rise in pH and a colour change of the pH indicator.

- Although not commercially available, *Helicobacter* can be identified in gastric biopsy samples (or faecal samples) using polymerase chain reaction (PCR) techniques employing specific primers for individual *Helicobacter* spp.

For all four tests collection of samples from multiple sites is recommended since organisms are not evenly distributed throughout the gastric mucosa.

*Helicobacter* infection can also be diagnosed by detection of antibodies in serum. However, serological tests are usually specific for one species of *Helicobacter* and serological test kits for species most commonly observed in dogs and cats are not commercially available. Non-radioactive carbon isotope ( $^{13}\text{C}$ )-based tests, which have been widely used in human beings for the diagnosis of *Helicobacter pylori* infections, have also been used in dogs and cats. An aqueous solution of  $^{13}\text{C}$ -urea is administered orally or by orogastric intubation. Breath or blood samples are collected at several time points after  $^{13}\text{C}$ -urea administration. The presence of *Helicobacter* organisms in the stomach leads to breakdown of urea, release of  $^{13}\text{C}$ , and an increase in the fraction of  $^{13}\text{C}$  in  $\text{CO}_2$  in sampled breath or gas extracted from blood samples. When collected into appropriate tubes, blood and breath samples are stable at room temperature for several weeks and months, respectively, and can be shipped to a laboratory that offers fractional mass spectrometry for quantification of  $^{13}\text{C}$ .

### Parasitology

#### Vomitus

The gastric nematode *Ollulanus tricuspis* has been reported in cats worldwide. The prevalence varies widely depending on geographical location, but can reach up to 40%. The parasite occurs much less frequently in dogs. Microscopic examination of vomitus is the only reliable method for the diagnosis of this parasite other than biopsy of the gastric mucosa. The parasite is rather small (i.e. <1 mm long) and has a rolled up anterior end.

#### Faecal flotation

The stomach of dogs and cats can be infested with several other parasites. *Physaloptera* (not in the UK), a nematode infesting the stomach of dogs, and less commonly cats, can be diagnosed by detection of eggs during faecal flotation, but is most commonly diagnosed by gross observation during gastroscopy. Eggs of other nematodes, including *Gnathostoma* in cats, *Spirocerca lupi* in dogs and cats, and *Aonchotheca putorii* in cats, are occasionally identified during faecal flotation.

### Biochemistry

#### Gastrin

Gastrinomas, neuroendocrine tumours that secrete gastrin and most commonly located in the pancreas,

can lead to hyperchlorhydria, gastric ulceration and gastric mucosal hypertrophy. Gastrin concentration in serum or plasma is the most valuable test for diagnosis of gastrinoma. Even though a species-specific assay for the determination of gastrin concentration in dogs or cats is not available, several test kits developed for use in human beings have been validated for use in dogs and also appear to be useful in the cat. According to diagnostic recommendations for humans, a presumptive diagnosis of gastrinoma should be made when the 24-hour fasting serum gastrin concentration is ten times the upper limit of the reference range. This recommendation is rather conservative and reflects the high prevalence of chronic atrophic gastritis in human beings, which can also cause severely elevated serum gastrin concentrations. If the fasting serum gastrin concentration is not severely increased, a secretin- or calcium-challenge test may lead to a more definitive diagnosis. It should be noted therapy with antacids, such as H<sub>2</sub> antagonists, or proton pump inhibitors may lead to falsely elevated serum/plasma gastrin concentrations.

### Pepsinogen

Pepsinogen, the zymogen (enzyme precursor) of the gastric protease pepsin, is secreted by cells of the gastric mucosa. Different isoforms of pepsinogen have been identified and have been assigned to two groups (A and C) in humans. Serum concentrations of pepsinogen A and C, and especially the ratio of serum pepsinogen A to serum pepsinogen C, have been used to diagnose a variety of gastric disorders in human beings. A group of closely related pepsinogens, all very similar to human pepsinogen A isoforms, have been identified in both dogs and cats, and species-specific immunoassays have been established. Unfortunately, initial studies in dogs and cats have failed to show significant clinical utility of serum pepsinogen A concentrations in the diagnosis of gastric diseases.

### Sucrose permeability

The mucosa lining the GI tract serves as a barrier against potentially harmful substances. In normal individuals the gastric mucosa is also impermeable to sucrose and all orally administered sucrose reaches the duodenum, where it is hydrolysed by brush border sucrase to glucose and fructose, which are then absorbed in the small intestine. When there is gastric ulceration or gastritis, the gastric mucosa becomes more permeable and sucrose passes intact into the vascular space, and is subsequently excreted in urine. The amount of sucrose that has permeated the gastric mucosa can thus be quantified in serum or urine. This test has been evaluated in human beings, horses, laboratory animals and dogs. Treatment of gastric ulcers leads to normalization of sucrose permeability. Few laboratories are able to assay sucrose concentrations in urine or serum samples, however, and the practical utility of sucrose permeability testing for the diagnosis of gastric disease in clinical patients remains to be demonstrated.

## Tests for intestinal diseases

### Virology

#### Parvovirus

Parvovirus enteritis can be diagnosed by observation of virus particles in faeces using electron microscopy. However, this is not widely available and not cost-effective in most cases. Several immunological assays for detection of parvovirus-specific antigens have been developed. These assays are highly sensitive and specific for the presence of viral particles in faeces. However, it has been speculated that false-negative test results can be observed if the animal has mounted an immune response, leading to the binding of virus particles by endogenous antibodies, rendering the viral particles undetectable by the test kit (see Chapters 16 and 20).

### Bacteriology

#### *Clostridium* enterotoxin

The pathogenic role of *Clostridium perfringens* and *Clostridium difficile* has not been conclusively demonstrated (see Chapter 16). Both organisms may be present in the faeces of healthy dogs and cats, but diarrhoea occurs only when the bacteria produce specific enterotoxins. Therefore, diagnosis has focused on identification of enterotoxin in faeces. The enterotoxin of *C. perfringens* is released during lysis of the vegetative cell and can be identified by latex agglutination or by enzyme immunoassay (EIA). Similarly, *C. difficile* enterotoxin can be identified by latex agglutination or enzyme-linked immunosorbent assays (ELISAs). However, the presence of either enterotoxin in a faecal sample does not establish a cause and effect relationship in a particular patient with diarrhoea. PCR-based assays for the expression of genes encoding various enterotoxins have been described but these tests are currently only used on an experimental basis.

### Small intestinal bacterial overgrowth

**Duodenal juice culture:** Quantitative bacteriological culture of duodenal juice is considered the gold standard test for small intestinal bacterial overgrowth (SIBO) (see Chapter 20). Duodenal juice can be collected during endoscopy by aspiration through a sterile tube advanced through the working channel of the endoscope, or by direct needle aspiration during exploratory laparotomy. However, collection of sufficient duodenal juice can be difficult. Duodenal juice must be cultured immediately after collection in order to preserve obligate anaerobic organisms. Qualitative and quantitative bacteriological assessment requires culture of the sample at several different dilutions and on several different selective media, rendering this technique both impractical and prohibitively expensive for routine use. Furthermore, reported normal ranges for results of duodenal juice culture in dogs and cats vary widely, making assessment of a result from a single clinical sample virtually impossible. Standardized procedures for collection and quantitative culture of duodenal juice have not yet been adopted.



**Serum unconjugated bile acids:** Bile acids are synthesized and conjugated in the liver. After secretion into the small intestine they facilitate fat emulsification. A small proportion of intraluminal bile acids are deconjugated by bile salt hydrolase-producing bacteria, and this deconjugation increases when there is SIBO with those anaerobic bacterial species that possess deconjugating hydrolases. Unconjugated bile acids are quickly reabsorbed into the bloodstream where they can be quantified. In a preliminary study, 9 of 10 dogs with culture-proven SIBO had increased serum concentrations of unconjugated cholic acid, the predominant bile acid in dogs. Unfortunately, for reasons that are unclear, unconjugated serum bile acid concentrations do not appear to identify dogs with antibiotic-responsive diarrhoea (see Chapter 20), and this test is probably more useful for longitudinal studies of individual patients rather than for the diagnosis of SIBO in clinical practice.

**Breath hydrogen:** Mammalian cells do not synthesize hydrogen, but bacterial metabolism leads to hydrogen production. Several protocols have been described for hydrogen breath testing in dogs and cats. One protocol involves oral administration of a sugar solution, followed by assay of breath hydrogen every 15 minutes for several hours. In normal dogs the sugars in the test solution are digested and absorbed before they reach the bacterial flora of the large intestine and only small amounts of hydrogen are produced. However, in dogs with SIBO appreciable carbohydrate fermentation may occur because of the increased number of bacteria in the small intestine. Hydrogen generated as a result of this fermentation diffuses into the bloodstream, reaches the alveoli and is excreted in expiratory air. Since the hydrogen is produced in the small intestine, the peak in breath hydrogen concentration occurs earlier than in patients with malabsorption, in which unabsorbed carbohydrates are eventually fermented by bacteria in the large intestine, thereby generating a later peak in breath hydrogen concentration. Unfortunately, no standardized protocol for breath hydrogen testing has been widely adopted, and its value in the diagnosis of SIBO is still unclear.

#### **Faecal culture**

Non-specific culture of faeces is of little use for the diagnosis of GI disorders. However, culture of faecal material for specific pathogens is indicated in some patients. Fresh faecal material can be cultured for *Salmonella* spp., *Campylobacter* spp. and *Yersinia* spp. While each of these organisms can cause chronic diarrhoea in dogs and cats they are more commonly observed in immunocompromised patients that are hospitalized. These patients commonly have an acute onset of bloody diarrhoea, often associated with systemic clinical signs. However, the yield of faecal cultures for these enteropathogens is low in most cases.

#### **Parasitology**

##### **Faecal smear and flotation**

The true prevalence of GI parasites in dogs and cats is unknown and dependent on many factors. Pets that

live outside have a higher prevalence of endoparasites, but even pets that live exclusively indoors can be infested with parasites. Given the low cost of evaluating a patient for endoparasitic infestation and the low cost, efficacy and ease of treatment, faecal examination for evidence of endoparasitic infestation should be routine in any small animal patient presenting with clinical signs of intestinal disease (see Chapter 16).

A fresh faecal smear can be examined under low magnification for the presence of *Giardia* or *Tritrichomonas foetus* trophozoites. *Giardia* trophozoites show a typical 'falling leaf' motion, while *T. foetus* trophozoites show erratic movement and an undulating membrane. A zinc sulphate flotation should also be performed. This technique is quick and simple and allows identification of many common endoparasites. However, a faecal zinc sulphate flotation is the most reliable means of identifying the presence of *Giardia* cysts in faecal samples. In one study, three consecutive flotations had a sensitivity for *Giardia* infestation in dogs of 96%. *Giardia* cysts can sometimes be confused with yeasts but *Giardia* cysts are much larger and contain visible internal structures.

**Giardia:** While *Giardia* infestation can be diagnosed by faecal smear or zinc sulphate flotation, in many cases multiple faecal examinations are required to detect the organism. A direct immunofluorescent assay as well as several ELISAs that detect *Giardia*-specific antigens have been developed. The immunofluorescent assay uses a monoclonal antibody directed against a component of the *Giardia* cyst wall and needs to be performed by a laboratory equipped for fluorescence microscopy. Faecal samples can be shipped in 10% formalin. The ELISAs are directed against different proteins produced by *Giardia* trophozoites. While highly sensitive for *Giardia* infections in human patients, a report has indicated one ELISA test to be slightly less sensitive for diagnosis of *Giardia* infection in the dog than three consecutive zinc sulphate flotations performed properly.

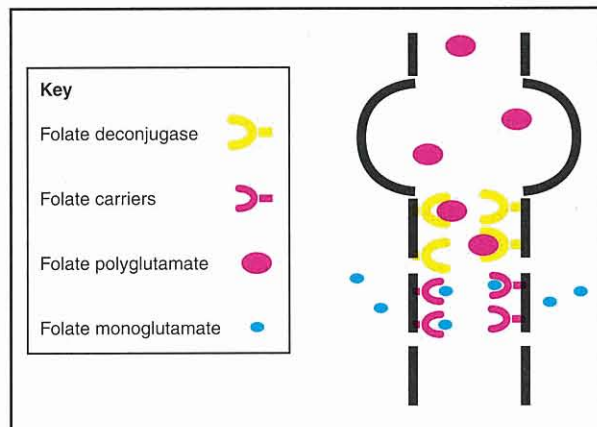
**Cryptosporidium:** *Cryptosporidium parvum* is a ubiquitous coccidian that can infect dogs and cats. In otherwise healthy animals cryptosporidiosis will lead to shedding of infectious oocysts without clinical signs. Immunocompromised or otherwise sick dogs and cats, especially neonates, may show clinical signs of small bowel diarrhoea. As for *Giardia*, *Cryptosporidium* can be diagnosed by identification of oocysts during zinc sulphate flotation. Identification of *Cryptosporidium* by formalin-ethyl-acetate sedimentation and direct smears using acid-fast stains has also been reported. A specific immunofluorescence assay and several ELISAs are available to detect specific antigens, but the clinical utility of these assays has not been conclusively demonstrated in dogs and cats. Detection of *Cryptosporidium* in faeces by PCR-based methods has been reported in human beings but not in dogs and cats. As the oocysts that are present in fresh faeces are infectious to laboratory personnel, faecal samples should be mixed with formalin (1 part formalin and 9 parts faeces) in order to inactivate the oocysts before shipping.

**Tritrichomonas foetus in cats:** *Tritrichomonas foetus*, a protozoan known to infect the reproductive tract of cattle, has recently been shown to be an intestinal pathogen in cats leading to chronic large bowel-type diarrhoea. Affected cats are usually young and live in large colonies. *Tritrichomonas* trophozoites can be identified on a direct faecal smear but the sensitivity of this technique is probably low. Use of a culture system developed for the diagnosis of *T. foetus* from the reproductive tract of cattle has recently been described in cats. A tiny amount of faecal material (<0.1 g) is placed into the culture pouch. Culture pouches are kept at room temperature for up to 11 days and can be intermittently examined by light microscopy at a magnification of x20 to x40 for motile organisms.

**Biochemistry**

**Folate**

Folic acid is a water-soluble B vitamin that is plentiful in most commercial pet foods. However, dietary folic acid is present as folate polyglutamate, which can not be readily absorbed. In the proximal small intestine folate polyglutamate is converted by brush border folate deconjugase to folate monoglutamate, which is then absorbed by specific folate carriers located exclusively in the proximal small intestine (Figure 2.2).



2.2 Principles of folate absorption.

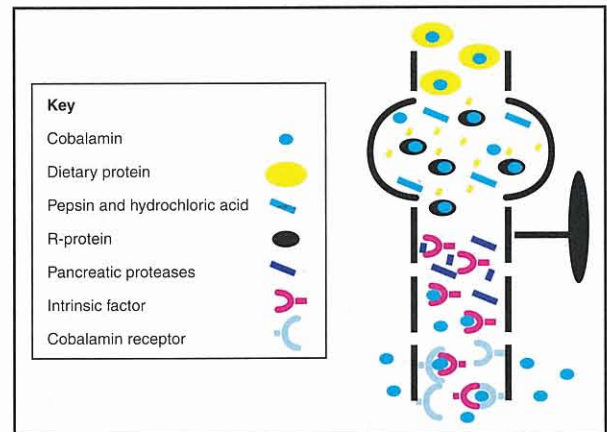
When there is severe disease affecting the proximal small intestine, folate absorption can be compromised. If malabsorption is sufficiently severe and long-standing, body stores of folate may be depleted, leading to a decreased serum folate concentration.

Dogs with true SIBO have an altered microflora in the upper small intestine, and may develop increased serum folate concentrations if one or more of the species proliferating in abnormal numbers is synthesizing folic acid. The clinical utility of folate and cobalamin concentration in antibiotic-responsive diarrhoea and SIBO is further discussed in Chapter 20.

**Cobalamin**

Cobalamin, vitamin B12, is also a water-soluble vitamin that is plentiful in most commercial dog and cat foods. Dietary cobalamin is bound to dietary protein

and can not be absorbed in this form. In the stomach digestion of dietary protein is initiated by pepsin and hydrochloric acid, and cobalamin is released (Figure 2.3). Free cobalamin is immediately bound by R-protein present in saliva and gastric juice, thereby once again rendering the vitamin unabsorbable. In the small intestine R-proteins are digested by pancreatic proteases and the liberated cobalamin is bound by intrinsic factor, of which 90% is secreted by the pancreas in the dog, and 99% in the cat. Finally, cobalamin-intrinsic factor complexes are absorbed by specific receptors in the ileum. Cobalamin malabsorption in itself does not necessarily lead to cobalamin deficiency. Only if cobalamin malabsorption is long-standing do body stores become depleted, ultimately leading to cobalamin deficiency.



2.3 Principles of cobalamin absorption.

Distal small intestinal disease may lead to loss of cobalamin receptors in the ileum, thereby causing cobalamin malabsorption. In a recent study 61% of 80 cats with clinical signs of chronic GI disease had decreased serum cobalamin concentrations. Diffuse small intestinal disease may also lead to cobalamin malabsorption as long as the ileum is involved in the disease process; concurrent subnormal serum cobalamin and folate concentrations usually reflect quite severe disease affecting the entire length of the small intestine. Exocrine pancreatic insufficiency can also lead to cobalamin deficiency in dogs, and almost invariably does so in cats, reflecting the relative importance of the pancreas as a source of intrinsic factor in these species. Finally, SIBO can lead to a decreased serum cobalamin concentration since many bacterial species, particularly obligate anaerobic bacteria, compete for dietary cobalamin. The clinical utility of folate and cobalamin concentrations in antibiotic-responsive diarrhoea and SIBO is further discussed in Chapter 20.

Cobalamin is essential for catalysis of some important biochemical reactions in the body, and virtually all tissues need cobalamin for optimal function. Clinical signs of cobalamin deficiency vary considerably with age and species. Some patients may just show lethargy, anorexia and weight loss, while others may show diarrhoea, intermittent septic episodes or even neurological signs. Experimental cobalamin deficiency in kittens leads

to progressive anorexia, weight loss and an unkempt haircoat. Additionally, humans with cobalamin deficiency have been shown to develop intestinal abnormalities including villous atrophy, infiltration of the intestinal mucosa with inflammatory cells, further cobalamin malabsorption and malabsorption of other nutrients. Similar GI effects of cobalamin deficiency have not been proven in dogs or cats with cobalamin deficiency but there is evidence that they occur. Thus, cobalamin deficiency can lead to further and more severe clinical signs, and dogs and cats with GI disease and concurrent cobalamin deficiency may not respond to other therapies unless also treated with cobalamin supplementation.

### **C-reactive protein**

C-reactive protein is one of the acute phase reactants, a group of proteins that are synthesized and secreted by the body during a variety of inflammatory conditions. An assay for canine C-reactive protein in serum has been developed and is available commercially. Initial data have shown that serum C-reactive protein concentration correlates with disease severity in canine patients with inflammatory bowel disease (IBD). Thus, serum C-reactive protein concentration can be used to objectively monitor therapeutic success in patients with IBD. Unfortunately, measurement of canine C-reactive protein is rather expensive and currently not widely available.

### **Faecal $\alpha_1$ -proteinase inhibitor**

Many GI disorders are associated with enteric protein loss. The gold standard for the diagnosis of GI protein loss is measurement of loss of  $^{51}\text{Cr}$ -labelled albumin into faeces, but this test is impracticable, labour and time intensive, and associated with exposure of the patient and technical staff to radioactivity. Recently, assays for canine and feline  $\alpha_1$ -proteinase inhibitors in faeces have been developed.  $\alpha_1$ -Proteinase inhibitor ( $\alpha_1$ -PI) is synthesized primarily in the liver and inhibits a variety of different proteinases, most importantly neutrophil elastase.  $\alpha_1$ -Proteinase inhibitor has a molecular mass of approximately 60,000 Daltons, similar to that of albumin. Thus, when GI disease is severe enough to be associated with GI albumin loss,  $\alpha_1$ -PI is also lost. In contrast to albumin, however,  $\alpha_1$ -PI is not hydrolysed in the GI tract since it is a proteinase inhibitor, and it can be detected in faeces when measured by a species-specific immunoassay. Thus, significant GI protein loss is associated with an increased faecal  $\alpha_1$ -PI concentration.

Patients with hypoalbuminaemia should first be evaluated for potential blood loss. After blood loss has been ruled out, protein-losing nephropathy and hepatic failure should be ruled out by evaluating urine protein:creatinine ratio and serum total bile acids concentration, respectively. If these test results are negative, measurement of faecal  $\alpha_1$ -PI can be used to confirm GI protein loss. Faecal  $\alpha_1$ -PI can also be used to monitor the severity of GI disease associated with enteric protein loss. Finally, faecal  $\alpha_1$ -PI can be used as an early indicator of GI disease in dogs with a potential genetic predisposition to protein-losing enteropathy (PLE). For example, Soft Coated Wheaten Terriers with PLE have increased

faecal  $\alpha_1$ -PI concentrations long before they develop clinical signs of GI disease or hypoalbuminaemia.

Currently, these assays are only available through the GI Laboratory at Texas A&M University.

### **Faecal occult blood**

Many GI disorders are associated with loss of blood into the intestinal lumen. While some disorders (e.g. parvovirus enteritis) can be associated with fresh blood in the stool, other disorders, such as severe gastric ulceration, can be associated with melaena. Both groups of patients are easy to assess as the presence of blood in faeces is obvious. In other instances, GI blood loss may be hidden or 'occult', and definitive diagnosis may require use of an occult blood test kit. Several types of test kits are available. Kits that use specific antibodies to detect specific blood proteins in humans are not useful in dogs and cats because of lack of immunological cross-reactivity between species. Kits based on two different test principles are available for use in veterinary patients.

- Guaiac-based tests contain guaiaconic acid, which when oxidized by haemoglobin leads to development of a blue quinone.
- O-toluidine-based tests contain tetramethylbenzidine, which when oxidized by haemoglobin also leads to generation of a blue compound.

Both kit types can give positive test results when exposed to red meat or peroxidase-rich foods, such as turnip and cauliflower, present in the diet. However, in one study an o-toluidine-based test was associated with far fewer false-positive results due to diet than a guaiac-based test. In another study the same o-toluidine-based test was also slightly more sensitive than a guaiac-based test at 12 hours after oral administration of haemoglobin.

### **Intestinal permeability and mucosal function**

The intestinal mucosa serves as a barrier against uncontrolled entry of unwanted molecules that are potentially harmful to the body. The barrier is not complete and trace amounts of a wide range of relatively small molecules can traverse the intestinal mucosa in normal animals. The integrity of the barrier function of the GI tract has been evaluated by permeability testing in several species, and many different marker molecules, including  $^{51}\text{Cr}$ -EDTA, polyethylene glycols, and mono- and disaccharides, have been evaluated.

In general, the GI mucosa is believed to have two types of aqueous pores through which there is non-carrier-mediated uptake of small molecules. The smaller pores are hypothesized to be located within the cell membranes and are believed to allow permeation by small molecules, including monosaccharides. The overall frequency of these transcellular pores is believed to be large and proportional to the total surface area of the intestinal mucosa. Small intestinal disease is often associated with villous atrophy and a consequent decrease in surface area leading to decreased permeability to monosaccharide markers. The larger pores are believed to be

located paracellularly in the area of the tight junctions. The overall frequency of these pores, which allow permeation of larger molecules such as  $^{51}\text{Cr}$ -EDTA and disaccharides, is much smaller and is largely dependent on mucosal integrity. In many small intestinal disorders tight junctions become leaky, leading to increased permeability to disaccharide markers.

The urinary recovery of other monosaccharides transported across the intestinal mucosa by specialized carriers, such as methylglucose and xylose, has also been used to evaluate small intestinal absorptive capacity, thereby concurrently evaluating another aspect of small intestinal mucosal function.

For combined GI permeability and mucosal function testing a solution containing several sugar markers is administered orally, and the sugars that either permeate the GI mucosa or are absorbed by a carrier-mediated process are assayed in serum or urine. GI permeability and mucosal function testing has been evaluated in many GI and systemic diseases but is currently not used in routine practice.

## Tests for hepatobiliary diseases

### Biochemistry

Serum activities of hepatic enzymes are analysed as markers for hepatocellular damage. Unfortunately, some of these enzymes are also expressed in other tissues. Therefore, increased activities of some hepatic enzymes can be seen with many other conditions unrelated to impaired hepatic function (see *BSAVA Manual of Canine and Feline Clinical Pathology*).

Serum urea, cholesterol and albumin concentrations can all be decreased in dogs and cats with hepatic failure. However, these findings are rather insensitive and are also not specific for hepatic failure.

### Bile acid

Bile acids are synthesized from cholesterol, conjugated in the liver and secreted in bile. After a meal, the hormone cholecystokinin (CCK) stimulates gall bladder contraction resulting in release of bile into the duodenum. Conjugated bile acids play a crucial role in fat absorption as they help to emulsify fat. A small amount of bile acids are deconjugated by the small intestinal microflora. These unconjugated bile acids are absorbed in the small intestine and are no longer available for fat emulsification. In contrast, conjugated bile acids are absorbed into the portal blood when they reach the ileum, and are subsequently extracted from the portal blood by the liver.

Pre- and postprandial bile acid concentrations are used for the diagnosis of hepatic dysfunction and portosystemic shunting. Food is withheld from the patient for 12 hours and a serum sample is collected. A small amount of food, rich in fat, is fed to cause CCK release and stimulate gall bladder contraction, and another serum sample is collected 2 hours later. When hepatic function is significantly impaired extraction of bile acids from the portal blood becomes less efficient and both pre- and postprandial serum bile acid concentrations may increase. In patients with portosystemic

vascular anomalies preprandial serum bile acid concentrations may be only mildly increased, while postprandial concentrations are often severely increased. In some normal patients paradoxical results are observed in that preprandial serum bile acid concentrations are higher than postprandial concentrations. It has been suggested that this finding is due to unpredictable intermittent gall bladder contractions. Increased preprandial bile acid concentrations have also been found in some dogs with evidence of an altered small intestinal microflora; in these patients the increased total serum bile acids reflects an increase in the concentration of unconjugated bile acids as a result of microbial deconjugation.

Recently, an assay of sulphated and non-sulphated urinary bile acid concentrations in dogs and cats with suspected hepatic disease has been described. However, further studies are necessary before routine assay of bile acids in urine rather than serum can be recommended.

### $^{13}\text{C}$ -aminopyrine demethylation blood or breath test

Aminopyrine, a compound chemically similar to the non-steroidal anti-inflammatory drugs antipyrine and phenylbutazone, is demethylated by microsomal enzymes in the liver. The liberated methyl groups are oxidized to  $\text{CO}_2$ , which diffuses into the bloodstream, reaches the pulmonary alveoli and is released in the expiratory air. The administration of aminopyrine labelled with either  $^{13}\text{C}$  or  $^{14}\text{C}$  isotopes allows specific measurement of  $\text{CO}_2$  derived from aminopyrine, by detection of  $\text{CO}_2$  isotopes present in either expired breath or acid-treated blood. The amount of labelled  $\text{CO}_2$  measured is given as a percentage of aminopyrine administered.

The aminopyrine breath test (ABT) has been shown to be useful in quantifying hepatic microsomal enzyme function in human beings and laboratory animals. Several studies have shown that the ABT is a useful indicator of disease severity in human patients with chronic hepatitis or hepatic cirrhosis. Reproducible collection of breath samples can be difficult in veterinary species. Therefore, a  $^{13}\text{C}$ -aminopyrine demethylation blood test has been developed and is currently being evaluated in dogs and cats that undergo hepatic biopsy. Initial results are encouraging.

## Tests for exocrine pancreatic diseases

### Serum biochemistry

#### Trypsinogen activation peptide

When trypsinogen is activated to trypsin a small peptide, trypsinogen activation peptide (TAP), is split from the trypsinogen molecule. Under normal conditions activation of trypsinogen occurs only in the small intestine. Thus, normal dogs and cats have undetectable or minimal concentrations of TAP circulating in the bloodstream. During pancreatitis, trypsinogen is activated prematurely in the pancreas and TAP is released into the vascular space, where its concentration increases.

In a clinical trial the sensitivity of urinary TAP:creatinine ratio and plasma TAP concentration in dogs with pancreatitis were poor. Another recent study also evaluated plasma and urinary TAP concentrations for the diagnosis of feline pancreatitis. Only plasma TAP concentration was significantly increased in cats with pancreatitis, but plasma TAP concentration does not appear to have any advantage over the determination of serum feline trypsin-like immunoreactivity (fTLI) concentration. Furthermore, TAP is relatively labile in plasma and urine samples, and the assay is expensive and not widely available, making plasma TAP less attractive than serum TLI as a diagnostic tool. Thus, use of the TAP assay for the diagnosis of pancreatitis in dogs and cats cannot be recommended.

#### $\alpha_1$ -Proteinase inhibitor–trypsin complexes

In healthy animals, only minimal quantities of trypsin reach the vascular space. In contrast, when the pancreas is inflamed, trypsin is released into the vascular space from where it is removed by two scavenger molecules,  $\alpha_1$ -proteinase inhibitor and  $\alpha_2$ -macroglobulin.  $\alpha_1$ -Proteinase inhibitor binds trypsin reversibly. Under normal conditions, the concentration of  $\alpha_1$ -proteinase inhibitor–trypsin complexes in serum is undetectable or low, while during pancreatitis increased concentrations would be expected. In one experimental study of canine pancreatitis, serum concentrations of  $\alpha_1$ -proteinase inhibitor–trypsin complexes were significantly higher than in healthy controls, and the magnitude of elevation reflected disease severity. However, serum  $\alpha_1$ -proteinase inhibitor–trypsin complexes were not significantly increased in dogs with spontaneous pancreatitis, thus indicating that this parameter is not clinically useful for the diagnosis of spontaneous disease in the dog.

#### $\alpha_2$ -Macroglobulin

$\alpha_2$ -Macroglobulin is another scavenger protein for prematurely activated trypsin. While trypsin binds reversibly to  $\alpha_1$ -PI, the bond with  $\alpha_2$ -macroglobulin is irreversible and trypsin– $\alpha_2$ -macroglobulin complexes are rapidly removed by the reticuloendothelial system. Thus,  $\alpha_2$ -macroglobulin is utilized during pancreatic inflammation and serum concentrations decrease. Unfortunately, measurement of serum  $\alpha_2$ -macroglobulin is not clinically useful for the diagnosis of canine pancreatitis; an assay for this protein in cats has not been evaluated.

#### Lipase

Serum lipase activity has been used for diagnosis of human and canine pancreatitis for several decades. However, in both species it has been well recognized that serum lipase activity is neither very sensitive nor very specific for pancreatitis. Many cell types have been shown to synthesize and secrete lipases. Lipases of different cellular origins share a common function and thus can not be differentiated by use of a catalytic assay, such as the ones currently used to determine lipase activity in serum. Serum lipase activity is not decreased in dogs with EPI, indicating that most serum lipase activity originates from additional sources other

than pancreatic acinar cells. Many non-pancreatic conditions including renal disease, hepatic disease and neoplastic diseases have been associated with increases in serum lipase activity. Heat stress and administration of prednisolone or dexamethasone also cause increases in serum lipase activity in dogs. While some dogs with pancreatitis have increased serum lipase activities, others exhibit no, or minimal, increases in serum lipase activity. In one study, serum lipase activity showed a specificity for canine pancreatitis of only 55% and a sensitivity of 73%. Thus, in dogs, serum lipase activity should be used only as a screening test until the diagnosis can be confirmed by other, more specific, tests. Even then, pancreatitis can be present when serum lipase activity is normal.

Cats with experimentally induced pancreatitis showed significantly increased serum lipase activities in one study, but cats with spontaneous pancreatitis usually do not, suggesting that, in cats, serum lipase activity is of no value in the diagnosis of pancreatitis.

#### Amylase

Serum amylase activity, like serum lipase activity, is not specific for exocrine pancreatic function. Dogs with experimentally induced pancreatitis have increased serum amylase activities, but while some dogs with spontaneous pancreatitis have increased activities, others have activities in the normal range. Furthermore, dogs with non-pancreatic GI disease sometimes have increased serum amylase activities. Finally, administration of prednisolone and dexamethasone to healthy dogs leads to decreased serum amylase activity, in contrast to the increases observed in serum lipase activity. In one study serum amylase activity had a specificity of 57% and a sensitivity of 62% for canine pancreatitis, indicating that as for serum lipase activity, serum amylase activity should at best only be used as a screening tool for canine pancreatitis until the diagnosis can be confirmed by other tests.

Serum amylase activity was decreased in one study of cats with experimental pancreatitis but in cats with spontaneous disease changes in serum amylase activities have not been observed, suggesting that serum amylase activity has no clinical usefulness in the diagnosis of feline pancreatitis.

#### Trypsin-like immunoreactivity

Pancreatic acinar cells synthesize and secrete trypsinogen, the inactive zymogen of the proteolytic enzyme trypsin. Almost all trypsinogen is secreted into the duodenum via the pancreatic ducts. However, a small proportion is released into the vascular space and can be measured by use of species-specific immunoassays for measurement of TLI.

Dogs and cats with EPI have a severely depleted number of pancreatic acinar cells, and thus a decreased secretion of pancreatic enzymes, including trypsinogen, both into the duodenum and into the vascular space, leading to a decreased serum TLI concentration. Canine serum TLI concentrations  $\leq 2.5$   $\mu\text{g/l}$  are highly sensitive and specific for diagnosis of canine EPI, while values of feline TLI  $\leq 8$   $\mu\text{g/l}$  are highly specific for EPI in cats.

Pancreatic inflammation can lead to increased release of trypsinogen into the vascular space. Also, in pancreatitis, prematurely activated trypsin leaks directly into the vascular space, where it is rapidly bound by plasma protease inhibitors. Like trypsinogen, trypsin is also detected by immunoassays for TLI, although with much lower efficiency, and so total serum TLI concentration can increase in dogs and cats with pancreatitis. Significantly increased serum TLI concentration (>50 µg/l in dogs and >100 µg/l in cats) is highly specific for pancreatitis but has a limited sensitivity of 30–60%, most likely due to its short half-life. Serum TLI concentration is probably of most diagnostic value early in the course of spontaneous pancreatitis in dogs and cats, while pancreatic lipase immunoreactivity (PLI; see below) is superior as the disease evolves.

#### Pancreatic lipase immunoreactivity

Many different cell types in the body synthesize and secrete lipases. In contrast to non-specific catalytic assays for the measurement of lipase activity, immunoassays allow specific measurement of lipase activity specifically synthesized by the exocrine pancreas. Immunoassays for the measurement of serum concentrations of canine and feline PLI (cPLI, fPLI) have recently been developed and validated, and increases in serum PLI can be seen in dogs and cats with both experimental and spontaneous pancreatitis.

Serum cPLI concentrations are decreased in dogs with EPI showing that cPLI is pancreatic acinar cell-specific. However, there is slightly more overlap of serum cPLI concentrations than serum cTLI concentrations between healthy dogs and dogs with EPI, indicating that serum cTLI remains the test of choice for the diagnosis of EPI. In a study of dogs with histologically confirmed spontaneous pancreatitis, the sensitivity of serum cPLI concentration was >80%, compared to <55% and <35% for serum lipase activity and serum cTLI, respectively. Serum cPLI concentration is significantly greater in dogs with experimentally induced chronic renal failure than in clinically healthy dogs, but most dogs with renal failure have serum cPLI concentrations within the reference range, and concentrations do not exceed currently recommended cut-off values for diagnosing pancreatitis. Thus, this indicates that serum cPLI concentrations can be used as a diagnostic test for pancreatitis even in dogs with renal failure. Oral administration of prednisolone does not change serum cPLI concentration.

Initial clinical studies of fPLI in cats have also been promising. In a group of cats with experimentally induced pancreatitis, both serum fTLI and fPLI concentrations increased initially but the increase in serum fPLI persisted much longer than that of serum fTLI suggesting that, as in the dog, serum PLI concentration is more sensitive for pancreatitis than serum TLI concentration. In another study of cats with spontaneous pancreatitis serum fPLI concentration was both more sensitive and specific than either serum fTLI concentration or abdominal ultrasonography.

Thus, in both dogs and cats serum PLI concentration is the most sensitive and specific diagnostic test for pancreatitis yet identified. These assays are currently only available through the GI Laboratory at Texas A&M University.

#### References and further reading

- Barr SC (1998a) Cryptosporidiosis and cyclosporiasis. In: *Infectious Diseases of the Dog and Cat, 2<sup>nd</sup> edn*, ed. CE Greene, pp. 518–524. WB Saunders, Philadelphia
- Barr SC (1998b) Enteric protozoal infections. In: *Infectious Diseases of the Dog and Cat, 2<sup>nd</sup> edn*, ed. CE Greene, pp. 482–491. WB Saunders, Philadelphia
- Center SA (1996) Diagnostic procedures for evaluation of hepatic disease. In: *Strombeck's Small Animal Gastroenterology, 3<sup>rd</sup> edn*, ed. WG Guilford *et al.*, pp. 130–188. WB Saunders, Philadelphia
- Gookin JL, Foster DM, Poore MF, Stebbins ME and Levy MG (2003) Use of a commercially available culture system for diagnosis of *Tritrichomonas foetus* infection in cats. *Journal of the American Veterinary Medical Association* **222**, 1376–1379
- Johnston KL (1999) Small intestinal bacterial overgrowth. *Veterinary Clinics of North America: Small Animal Practice* **29**, 523–550
- Lund EM and Klausner JS (1995) Clinical epidemiology for the veterinary practitioner: the diagnostic process. In: *Kirk's Current Veterinary Therapy, XII edn*, ed. JD Bonagura, pp. 7–11. WB Saunders, Philadelphia
- Mansfield CS and Jones BR (2000) Plasma and urinary trypsinogen activation peptide in healthy dogs, dogs with pancreatitis and dogs with other systemic diseases. *Australian Veterinary Journal* **78**, 416–422
- Neiger R and Simpson KW (2000) *Helicobacter* infection in dogs and cats: facts and fiction. *Journal of Veterinary Internal Medicine* **14**, 125–133
- Simpson KW, Fyfe J, Cornetta A, Sachs A, Strauss-Ayali D, Lamb SV and Reimers TJ (2001) Subnormal concentrations of serum cobalamin (Vitamin B<sub>12</sub>) in cats with gastrointestinal disease. *Journal of Veterinary Internal Medicine* **15**, 26–32
- Steiner JM (1998) Clinical endocrinology of the gastrointestinal tract. In: *BSAVA Manual of Small Animal Endocrinology, 2<sup>nd</sup> edn*, ed. AG Torrance and CT Mooney, pp. 173–178. BSAVA Publications, Cheltenham
- Steiner JM (2003) Diagnosis of pancreatitis. *Veterinary Clinics of North America: Small Animal Practice* **33**, 1181–1195
- Williams DA (1996) The pancreas. In: *Small Animal Gastroenterology, 3<sup>rd</sup> edn*, ed. DR Strombeck *et al.*, pp. 381–410. WB Saunders, Philadelphia

# 3

## Imaging the gastrointestinal tract, liver and pancreas

Robert T. O'Brien

### Introduction

Many clinical signs of gastrointestinal (GI) disease are vague and do not localize precisely to a particular organ. Imaging is often very important both to identify an obvious abnormality and to gain confidence that no obvious condition exists that would dictate a surgical emergency. This chapter provides an overview of imaging modalities and stresses the indications, contraindications, and normal and abnormal findings.

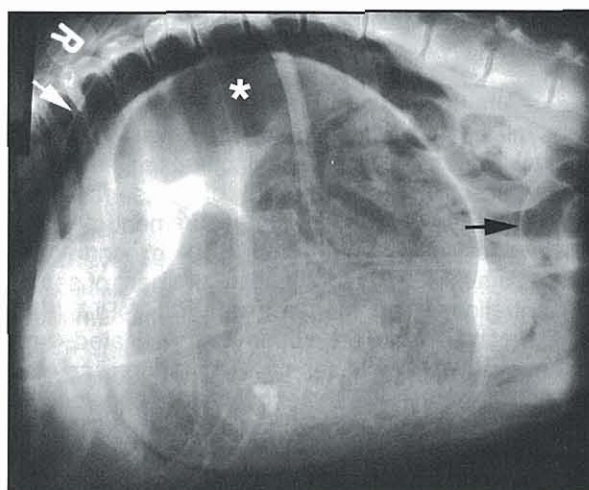
### Gastrointestinal imaging

Radiography is the most common imaging modality in veterinary medicine. While hazardous if misused, few modalities can match the clinical utility of radiography for providing an overview of the neck, thorax and abdomen in clinical evaluation of the entire GI tract.

### Survey abdominal radiography

Abdominal radiography is a very important tool for many reasons. The most important purpose is for the diagnosis of the acute abdomen: gastric dilatation and volvulus (GDV); GI foreign body; small intestinal obstruction; and pneumoperitoneum as a sign of a ruptured segment of GI tract. Secondly, radiography provides an overview of abdominal contrast. Causes of decreased peritoneal or retroperitoneal contrast are listed in Figure 3.1. The importance of abdominocentesis or ultrasonography in the clinical evaluation of radiographic loss of detail should be noted.

GI diseases can often be diagnosed with survey radiography. For example, classic signs of GDV are dilatation (with gas, fluid, food or a combination thereof), compartmentalization and malposition of the gastric fundus and pylorus (Figure 3.2). The pylorus is normally



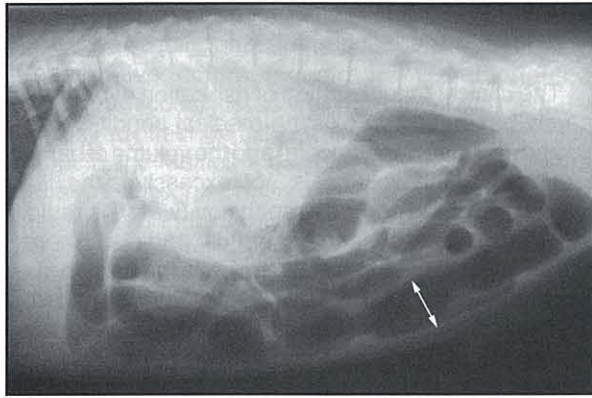
**3.2** Right lateral radiograph of 6-year-old male neutered Doberman with a 3-hour history of retching. Note the gastric dilatation volvulus with air-filled pylorus (\*) in cranial dorsal position. Pneumoperitoneum is seen secondary to gastric wall necrosis, as shown by the free air caudal to the diaphragm (white arrow) and the increased serosal detail of intestinal loops (black arrow).

ventral, caudal and right-sided, and the fundus is dorsal, cranial and left-sided. During a GDV the pylorus rotates to the left and assumes a more cranial and dorsal location relative to the fundus. The fundus is identified by longitudinal folds (rugae) and the pylorus by the connection to the duodenum.

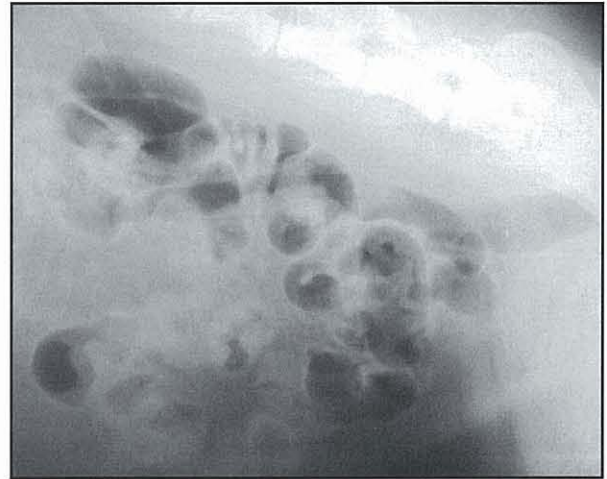
The most important small intestinal disease that can be diagnosed by survey radiography is mechanical obstruction. Whether caused by neoplastic mass, lucent foreign body, intussusception or dysfunctional aboral segment, the resultant effect is dilatation of the orad portion. The criteria of dilatation are somewhat controversial and a ratio of 1.6:1 between the maximum small intestinal diameter and the height of the body of the fifth lumbar vertebra at its narrowest point has been considered the upper limit of normal intestinal diameter. Alternatively small intestinal loops should not be wider than the 'height' of a cranial lumbar vertebral endplate (not the mid-body region) on a lateral projection of the abdomen (Figure 3.3). The diagnosis of mechanical obstruction requires persistence of the dilatation and, therefore, repeat radiographs are almost always prudent. Additionally, right and left lateral projections are complementary for demonstration of dilated intestinal gas patterns (Figure 3.4).

Cause	Adjunctive tests
Neonatal brown fat	Correlate with clinical details
Emaciation	Correlate with physical examination
Mass/organomegaly	Abdominal ultrasonography
Free fluid	Abdominocentesis; ultrasonography
Peritonitis	Abdominocentesis; ultrasonography
Carcinomatosis	Abdominocentesis; ultrasonography

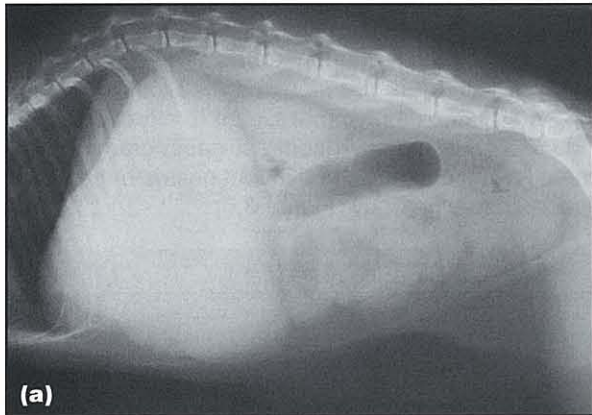
**3.1** Differential diagnoses for loss of peritoneal detail.



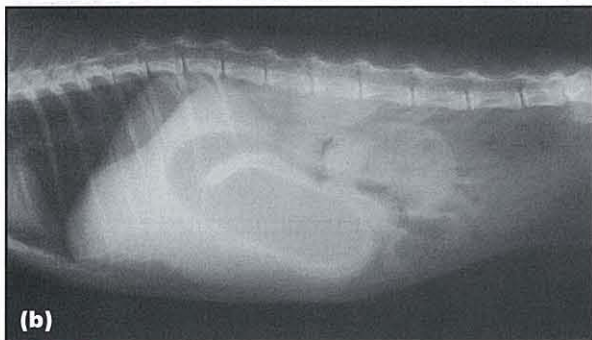
**3.3** Radiograph of a 5-year-old intact male Golden Retriever with progressive vomiting for 48 hours. The dog had eaten a terrycloth wristband, and evidence of small intestine (SI) obstruction is demonstrated by loops of SI that are wider (serosa-to-serosa) than the height of the vertebral endplate of L2.



**3.5** Lateral radiographic projection of 4-year-old German Shepherd Dog with 2 days' duration of vomiting following ingestion of a linear foreign body. Note the abnormally shaped small intestine. The gas pockets in the small intestines in the ventral abdomen are round to ovoid, the loops are bunched and the intestines are bending in tight corners.



(a)



(b)

**3.4** (a) Right and (b) left lateral radiographs of 3-year-old female spayed Domestic Short-hair cat with gastric dilatation caused by pyloric obstruction. The stomach appears as a soft tissue mass, indistinguishable from a liver mass, on the right lateral projection. On the left lateral projection the luminal gas rises to the non-dependent pylorus and descending duodenum providing better contrast and verification of the cause of the cranial organomegaly.

An important surgical condition in cats and dogs is a linear foreign body. Although many are diagnosed on history and oral examination, the remainder are usually identified by radiographic findings. These findings include clumping of the intestines, tight bends or figure C-shaped loops and many round to ovoid (but not tubular-shaped) gas pockets in the small bowel (Figure 3.5).

While many medical causes of GI disease result in mild to moderate intestinal wall thickening, measurements of wall thickness should not be attempted on survey radiography; this can only be performed during an upper GI contrast study.

### Contrast radiography

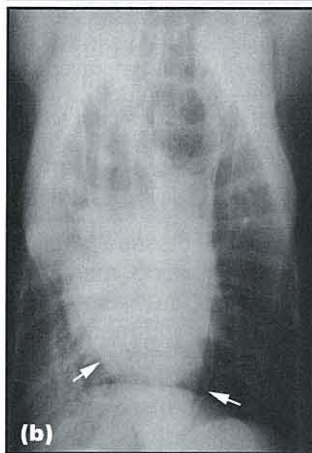
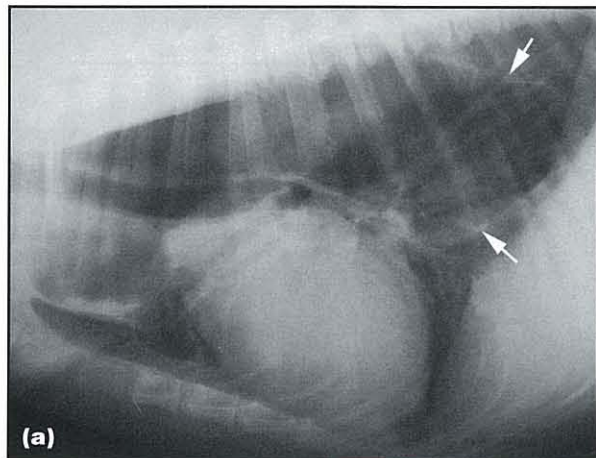
#### Oesophagography

In cases of dysphagia or regurgitation, imaging of the head and neck is essential (see Chapters 6 and 18). While some of these disorders can be diagnosed by a single lateral projection (e.g. metallic foreign body), the majority are dynamic conditions requiring the real-time imaging of a positive contrast oesophagram. Although uncommon in general practice, analogue or digital image-intensified fluoroscopy is available in larger referral practices and academic institutions. These are challenging studies even with proper equipment, so are not discussed here.

Similar to oropharyngeal diseases, some oesophageal diseases may be diagnosed by a complete set of plain film thoracic radiographs. The most common condition seen in general practice is megaesophagus (Figure 3.6). This is very commonly misinterpreted or even overlooked. In fact, the more severe the oesophageal dilatation, the more commonly the walls are not seen. It is very important to search for the distribution of the megaesophagus and concurrent lesions, and to determine whether the oesophageal dilatation is regional or throughout the entire thorax. In a neonate, a megaesophagus limited to the cranial thoracic and caudal cervical regions should alert the clinician to a possible vascular ring anomaly. Concurrent lesions that may be associated with localized megaesophagus include foreign bodies or masses.

In the event that clinical signs suggest regurgitation, but there is no evidence on plain radiography of a megaesophagus, then a dynamic contrast study is indicated. Ideally the same real-time imaging equipment,





**3.6** (a) Left lateral and (b) ventrodorsal radiographs of a 9-year-old German Shepherd Dog with a 6-month history of regurgitation. Note the wall of the oesophagus (white arrows) on left lateral and ventrodorsal projections. Regions of alveolar consolidation are seen in the right middle and caudal lung lobes. The dog was diagnosed with idiopathic megaesophagus and aspiration pneumonia.

as mentioned above for a positive contrast oesophagram, should be used. This will optimize location of subtle lesions, such as oesophageal stricture, or functional diseases of the gastro-oesophageal junction. Nevertheless, a single lateral projection at approximately 5 seconds after swallowing will often produce a diagnostic image. Contrast agents available for oesophagography include barium-coated kibble, barium paste and barium suspension. Oesophagrams are usually begun with the type of material the patient has historically swallowed best. If the dog gags on water but eats food with no discomfort, then an oesophagram with barium-coated kibble should be attempted first followed, if necessary, by paste and finally barium suspension. Alternatively, if a megaesophagus is suspected but is intermittent on the images and is possibly due to a systemic disease or sedation provided for the imaging, then barium suspension may be indicated as the sole contrast agent. This material will pass into the stomach most easily and can be removed if necessary by placement of an oesophageal tube.

The most important complication with the use of oral barium contrast media is aspiration, which may cause a dramatic loss of ventilatory capacity. This risk can be minimized by avoiding oral administration of barium in certain clinical contraindications, for example:

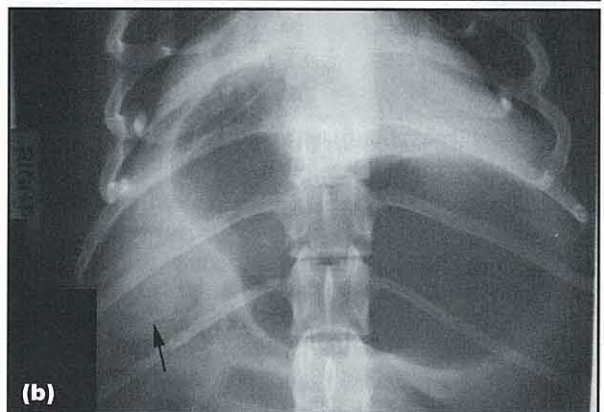
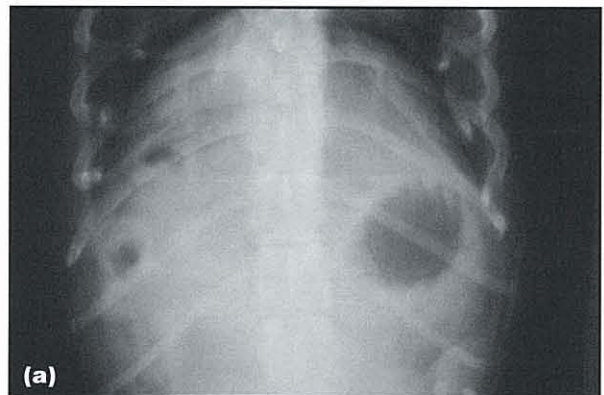- A strong clinical suspicion of megaesophagus
- Broncho-oesophageal fistula or oesophageal rupture

- A demonstrated tendency for aspiration pneumonia
- Evidence of oesophageal perforation.

The clinical manifestation of aspiration of barium is largely based on pre-existing medical conditions (including aspiration pneumonia) and the volume of barium aspirated. If the volume is not excessive, the fluid component of the barium suspension (water) is rapidly absorbed and the suspended barium particles cleared by the mucociliary apparatus. If severe the barium may become alveolarized, resulting in barium granuloma formation and possible deposition in the tracheobronchial lymph nodes. This may result in permanent and dramatic, albeit often subclinical, changes noted on future thoracic radiographs.

### Gastrography

The diagnosis of a radiolucent gastric foreign body can be quite challenging. Residual food may resemble cloth or another type of lucent foreign body, and so the time of last food ingestion is very important. Most dogs will have an empty stomach within 4 hours of a typical meal, and persistent amorphous soft tissue material admixed with air in the stomach may indicate either delayed gastric emptying or lucent foreign body (see Figure 3.4). A negative contrast gastrogram is indicated for the diagnosis of a lucent gastric or proximal duodenal foreign body (Figure 3.7).



**3.7** (a) Survey and (b) negative contrast ventrodorsal projections of the cranial abdomen of a 1-year-old Cardigan Welsh Corgi with vomiting of 4 months duration. The survey radiograph was normal but on the negative contrast gastrogram, air in the proximal descending duodenum surrounds a round soft tissue filling defect (arrowed). The dog had a large acorn removed endoscopically.

The specific dosages for common GI contrast studies are provided (Figure 3.8). However, the dosages for the negative contrast gastrogram and pneumocolonogram could just as well read 'to effect', because the desired effect is a full (not dilated) stomach or colon, respectively. Multiple positions are often required to place the foreign body in a diagnostic location. Both laterals (see Figure 3.4), ventrodorsal and dorsoventral projections may all be necessary. The recommended sedative for contrast radiography of the GI tract, due to its dependable level of sedation for ease of orogastric tube placement and minimal effect on GI motility, is acepromazine maleate.

Contrast study	Dose	Contrast medium
Oesophagram	1 ml per 5 kg bodyweight	Barium suspension (60% weight/volume)
Upper gastrointestinal series	13 ml/kg	Barium suspension (20% weight/volume)
Negative contrast gastrogram	6 ml/kg	Air
Pneumocolonogram	6 ml/kg	Air

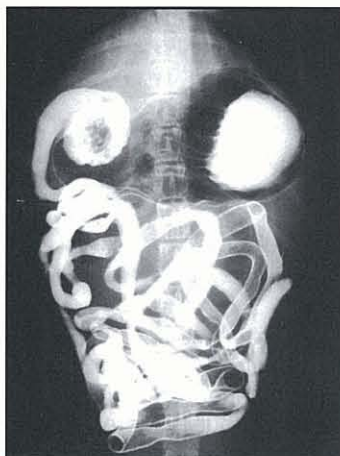
**3.8** Dosages and media for contrast radiography of the GI tract.

**Upper gastrointestinal series**

An upper GI contrast study (Figure 3.9) is indicated when clinical signs indicate the GI tract is involved and obstruction needs to be ruled out first. This study is technically demanding to perform and amongst the most difficult to interpret. The most common technical mistakes are:

- Too low a volume of administered barium suspension
- Improper patient preparation
- Insufficient radiographs at suitable time points.

Patients should be fasted for at least 12 hours and have cleansing enemas; the goal is an empty stomach and colon. Persistence of gastric contents is a relative contraindication for starting the upper GI



**3.9** Ventrodorsal radiograph of a 5-year-old intact Labrador Retriever bitch with lethargy for 3 days, obtained 15 minutes after administration of 13 ml/kg of 20% weight/volume barium suspension. Note the normal position and shape of the small intestinal loops.

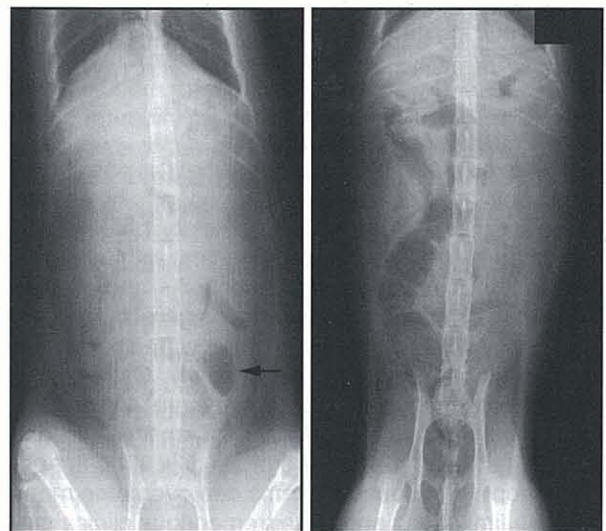
series. Radiography, usually right lateral and ventrodorsal projections, should be obtained at 0, 5, 15, 30 and 60 minutes, and then hourly until the end of the study. Compared with a properly exposed survey radiograph, the kVp should be increased 10% during the upper GI contrast study. The images obtained early in the study are often the most important since the oral intestinal loops may only be full of barium immediately after the start of the series. The endpoints for an upper GI contrast study are:

- Small intestinal transit (time for the leading edge of the barium to reach the colon)
- Gastric emptying (time for all the barium to leave the stomach).

Radiological determination of a gastric emptying disorder is based on substantial residual barium suspension in the stomach 2 hours (cat) or 4 hours (dog) after beginning the upper GI contrast study, although the onset of gastric emptying in the cat is variable depending on levels of endogenous sympathomimetics. Since the timing described above is based on the time of onset of emptying, some cats will benefit from being placed in a calm, quiet environment to allow the stomach to begin normal contractions.

**Pneumocolonography**

Intestinal obstruction is an important diagnosis and yet often difficult to establish on survey radiography. One major radiological dilemma is proper identification of small and large intestine. A pneumocolonogram can aid this process. Slow infusion of air (see Figure 3.8) into the rectum through an inflated balloon-tipped catheter can provide negative contrast enhancement of the colon (Figure 3.10).



**3.10** Survey dorsoventral and post-contrast ventrodorsal (pneumocolonogram) radiographs of 10-year-old female spayed Domestic Short-hair cat with 2-month history of vomiting. On the survey image a caudal left-sided bowel loop (black arrow) was thought to be a dilated small intestinal loop. On the pneumocolonogram the loop is no longer seen on the left side, but the gas-filled descending colon is on the right side.

### Ultrasonography

The use of ultrasonography has largely replaced contrast radiography for the diagnosis of GI neoplasia, intussusception and diffuse mural infiltrative disease. It now has become the gold standard in veterinary medicine for evaluating the abdomen for metastatic disease. The complete ultrasound evaluation of the GI tract in cats and dogs has never been easier or more rewarding. All intra-abdominal segments should be systematically evaluated for thickening (Figure 3.11), loss of layering and regional lymphadenopathy. A limited ultrasound evaluation of the cranial thorax for sternal lymphadenopathy is possible when GI or other cranial abdominal neoplasia is suspected. Radiography is an important complementary imaging modality, especially when an apparent overabundance of gas makes complete evaluation of the abdomen difficult.

Ultrasonography is a very demanding operator-dependent modality. Image quality is based on machine-related issues (as in all imaging), but is more dependent on the skill and experience of the operator (ultrasonographer) than any other imaging modality. In the GI tract these limitations are compounded by variable amounts of gas, food and faeces.

Gastrointestinal segment	Cat	Dog
Stomach: fundus	2.0	5.0
pylorus	2.5	5.0
Duodenum	2.5	5.0 (< 30 kg bodyweight) 6.0 (≥ 30 kg bodyweight)
Jejunum	2.5	4.0 (< 20 kg bodyweight) 4.5 (≥ 20 kg bodyweight)
Ileum	3.2	4.0
Colon	1.7	2.0

**3.11** Upper limit of normal gastrointestinal wall segment thickness (mm).

### Oropharyngeal and oesophageal

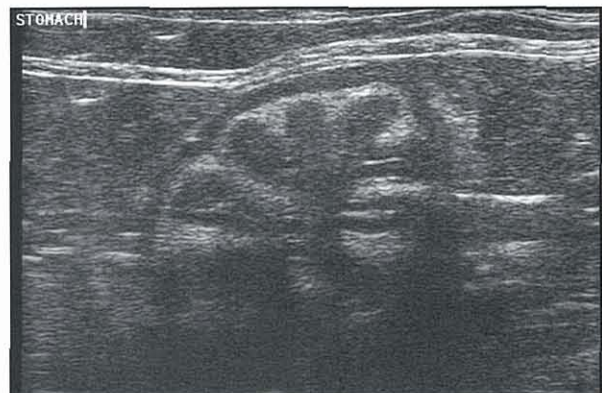It is not overly simplistic to suggest that it is possible to image any body location with ultrasonography as long as the anatomy is known. The oral cavity, pharynx and oesophagus can be imaged in cats with signs of dysfunction or a mass, e.g. neoplastic and chronic inflammatory conditions usually lead to hypoechoic thickening. These changes are appreciated best when asymmetrical and located superficially. Case examples include lymphoplasmocytic pharyngitis and oropharyngeal lymphoma. Deeper locations, especially lesions hidden beneath airways, are more difficult to image. Endoscopic ultrasound systems can overcome many of these limitations and have tremendous clinical potential for oesophageal imaging.

### Stomach

Dogs tend to pant and fill their stomachs with gas making evaluation of all but the most superficial portions of the stomach difficult. Cats in comparison tend to pant less and will usually have an empty stomach that takes on the

ultrasonographic appearance of a halved grapefruit (Figure 3.12). This classical appearance allows evaluation of wall layer definition and thickness.

Wall thickening may be associated with chronic inflammatory or neoplastic conditions but thickening with loss of normal layers is more commonly associated with neoplasia. Regional thinning within a thickened area may represent a gastric ulcer. Other signs of ulceration include a trapped focus of air in the ulcer crater, which will persist regardless of positioning of the patient. Concurrent free fluid indicates a peritonitis and aspiration should be attempted for culture and cytology if clinically indicated. If there is luminal fluid, the gastric contents can be evaluated for evidence of foreign bodies. Gastric outflow disorders usually result in large amounts of luminal gas or fluid accumulations. The hepatic lymph nodes are often seen within the lesser curvature of the stomach and adjacent to the portal vein in normal cats.



**3.12** Transverse plane ultrasound image of normal stomach of a cat. Measurements of wall thickness should be made in the regions between rugal folds.

The pyloric region should be evaluated in every patient. If the stomach is empty the pylorus is right-sided in dogs and closer to midline in cats. With increased gastric volume the pylorus in cats will be positioned more to the right. In order to locate the pylorus, the descending duodenum can be traced to the cranial duodenal flexure and eventually to the stomach. This method dictates that the operator is able to identify the duodenum with confidence.

A major advantage with ultrasound is the real-time capability to watch gastric contractions and pyloric emptying. However, patients given various sedatives or that are very excited may have abnormally decreased gastric function.

### Duodenum

The duodenum is often the first small intestinal loop ventral to the right kidney. This is also important for proper examination of the pancreas. The duodenal wall has excellent layer definition and has a uniformly hypoechoic mucosal layer.

Both inflammatory bowel diseases and lymphoma can have manifestations ranging from normal ultrasonographic appearance to generalized thickening with enlarged regional lymph nodes. More specific to lymphoma is loss of distinct layers. Pancreatic

adenocarcinoma may invade the duodenal wall resulting in the appearance of a duodenal wall mass. This tumour has often metastasized to regional lymph nodes, liver and the thorax by the time of initial diagnosis. Whenever GI neoplasia is suspected, ultrasonographers should perform a limited ultrasound examination of the cranial thorax. The sternal lymph nodes, pleural space and lung are very commonly affected with GI tumours and are easily scanned as an adjunct to the abdominal ultrasound examination.

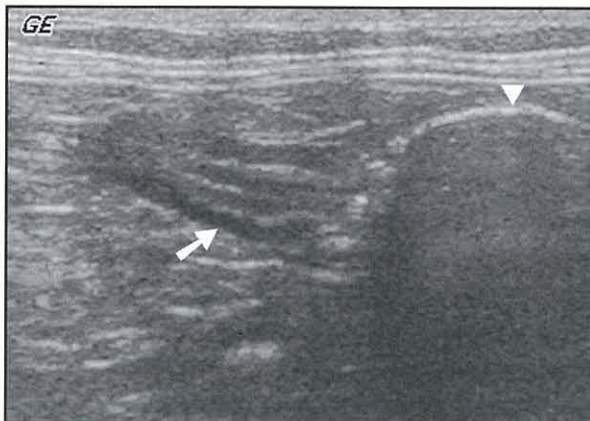
Identification of masses or foreign bodies requires a complete evaluation of the duodenum. Foreign bodies will usually have complete attenuation of the transmitted sound, resulting in a dense shadow artefact and focal intestinal dilatation.

### Jejunum

The challenge with imaging this segment is in being as complete as possible. Unlike the duodenum, a complete tracing of the entire length of the jejunum is all but impossible. All that can be done is to try to perform a methodical search of the entire mid-abdomen. An overabundance of gas in the small intestines should alert the ultrasonographer to potential obstructive GI disease. Under these circumstances radiographic evaluation may be helpful.

### Ileum

The ileum is a very special subsection of the SI that only recently has received an appropriate level of attention from ultrasonographers. The ileum is a 'must see' structure on the list of organs necessary for a complete abdominal ultrasound examination (Figure 3.13) as this very small part of the intestines seems overly predisposed to infiltrative diseases, including lymphoma, and to intussusceptions. This segment is found by searching the right mid-abdomen for a small intestinal loop with a typically thick muscularis layer (compared with other segments) that is contiguous with the large intestine. The colon is typically much thinner and gas- or faeces-filled. The lymph nodes in this region (right colic lymph nodes) are seen in many cats with no clinical signs and may be normal, but could represent mildly reactive lymph nodes in subclinical disease.



**3.13** Sagittal plane ultrasound image of normal ileocolic junction of a cat. Arrow indicates the ileum; note the thick outer hyperechoic (darker) muscularis layer. Arrowhead indicates the colon; note the thin walls and barely detectable layering.

### Colon

Usually the colon is intentionally avoided during the course of most of the abdominal ultrasound examination. Faeces and gas in the colonic lumen cause substantial challenges to obtaining a diagnostic image during routine scanning. A fasted cat will typically have a full colon. Although cleansing enemas may be necessary to empty the colon, many cats with lower GI signs have lower residual volumes associated with their tenesmus. Like other regions of the intestinal tract, the colon is at high risk for inflammatory bowel diseases and lymphoma. If diffuse or regional thickening is noted, evaluation of the medial iliac (sublumbar) lymph nodes for evidence of metastasis or concurrent inflammation is indicated and may provide an easier organ on which to perform ultrasound-guided biopsy than the affected colon.

### Liver imaging

Advances in imaging of the liver have proceeded at a very rapid rate in the last 10 years. Major progress has been made with ultrasonography, scintigraphy, computed tomography (CT) and magnetic resonance imaging (MRI) of the liver in small animal patients. Whilst most general small animal practitioners will be limited to radiography and ultrasonography, there should be an awareness of the advantages of more advanced imaging techniques.

### Survey radiography

For the determination of liver size, survey radiography is probably still the best tool. Liver size is determined from the consensus of the gastric axis, the extent of the liver beyond the costal arch, and the thickness of liver between gastric wall and diaphragm. The gastric axis is the line drawn between the centre of the fundus (dorsal-, cranial- and left-most aspect of the stomach) and the centre of the pyloric antrum (ventral-, caudal- and right-most aspect of the stomach). The normal gastric axis on lateral projections is a line that lies within the angle formed by a line perpendicular to the spine and a line parallel to the ribs. On ventrodorsal projections the normal gastric axis is perpendicular to the spine. If the liver is small the pylorus is positioned closer to the diaphragm making the axis more vertical (or even inclined cranially) on lateral projections and deviated with the pylorus more cranial than the fundus on ventrodorsal projections. Most normal livers do not extend beyond the costal arch. As more experience is gained, a subjective interpretation of normal liver width on lateral projections is incorporated into the radiological interpretation.

Evaluation of the gall bladder and biliary tract with survey radiography is limited to changes in opacity. Occasionally reflux of duodenal gas or infection with gas-forming organisms may cause a decreased opacity to the biliary tract. Mineralization can cause increased opacity in the gall bladder or biliary tract. Although uncommon, stones (cholelithiasis or cholidocholithiasis) can sometimes be visualized.

### Ultrasonography

Ultrasonography is the gold standard in general practice for evaluating the internal structures and overall texture of the liver. Adequate machine systems can be quite affordable and, with moderate training and skill, the general practitioner will be able to locate the liver and identify many abnormalities. Most of the liver can be imaged via an acoustic window immediately caudal to the xyphoid. Application of some pressure while angling the transducer cranially from the paraxiphoid and subcostal approaches may be required to obtain good images. Portions of the hepatic parenchyma that cannot be imaged from this site are usually accessible via paraxiphoid, subcostal and right intercostal approaches. In most dogs it is necessary to use an intercostal acoustic window to image the liver cranial to the right kidney. When using an intercostal window excessive pressure upon and between the ribs must be avoided as it will cause patient discomfort and therefore reduce patient compliance.

The normal hepatic parenchyma has a diffusely coarse echotexture best described as 'homogeneously heterogeneous'. When compared with the normal echogenicity of splenic and renal parenchyma, the liver is intermediate, appearing hypoechoic to the spleen and hyperechoic to the renal cortex. In cats, comparison of hepatic echogenicity to that of the normal spleen is frequently difficult, particularly in obese patients. The best comparative structure for assessment of hepatic echogenicity in cats is the fat of the falciform ligament, which is hyperechoic compared with normal hepatic parenchyma. The division of the liver into individual lobes by fissures is not apparent in the normal liver except in instances of peritoneal effusion. The margins of the liver are usually smooth with sharp edges.

The hepatic and portal veins are anechoic and round in transverse plane. However, rotation of the transducer 90 degrees elongates the vessels so that they appear as tapering and branching tubes. Portal veins are distinguished from the hepatic veins by virtue of their apparently thicker, hyperechoic walls. The walls of the hepatic veins blend with the adjacent hepatic parenchyma and are not seen. The vasculature at the *porta hepatis* has a hyperechoic rim due to fat and connective tissue. The normal hepatic arteries and intra-hepatic bile ducts are not seen ultrasonographically.

The normal gall bladder is located to the right of midline and is an anechoic round to oblong tapering structure. The wall of the gall bladder appears as a thin hyperechoic rim or alternatively is not seen at all. As a consequence of distal enhancement (or through transmission), structures imaged deep to the gall bladder appear hyperechoic when compared with adjacent parenchyma at the same depth in the ultrasound image. Commonly there is echogenic debris within the lumen of the gall bladder that settles in its dependent portion. This material (inspissated bile or 'sludge') is usually considered of no clinical significance. It is normal for a gall bladder to be distended in an animal that has not eaten for one or more days.

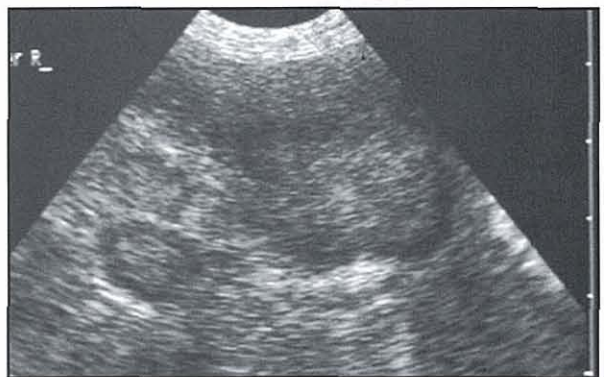
### Ultrasonography of hepatopathies

Hepatic pathology will be detectable ultrasonographically only if it leads to a change in the size, shape, margination or echogenicity of the liver.

Changes in the size of the liver are reliably detected only at the extremes. Microhepatica is usually apparent by virtue of the difficulty in finding the liver via the usual acoustic windows. Differential diagnoses for microhepatica include hypoplasia (secondary to congenital portosystemic shunt), cirrhosis or a normal variant. Another consideration for difficulty finding the liver is diaphragmatic herniation. Care must be taken to avoid confusing this with the mirror image artefact that is frequently associated with the curve of the diaphragm. Generalized hepatomegaly is recognized when a large portion of the liver extends beyond the costal arch and the margins are rounded.

Changes in the shape and margination are important ultrasonographic signs of hepatic disease. These can be subtle but are often the only sign in cases where there is a diffuse or focal disease that has not altered the echogenicity of the affected hepatic parenchyma. Sometimes changes in shape and margination are only visible due to distortion of the normal hepatic structures, such as displacement of vasculature, the gall bladder or cystic duct, or as irregularities of the usually smooth contour and sharp edges of the normal liver.

Changes in liver echogenicity can be focal or diffuse. Focal lesions are more easily detected in the liver than diffuse hepatopathies provided that they are sufficiently different from the normal surrounding echogenicity and are of a sufficient size. The lesion will often not be seen within the typical coarse echotexture of the hepatic parenchyma in large dogs when imaging with a low frequency transducer or when imaging is rushed so that a thorough examination is not performed. Differences in echogenicity and ability to visualize small lesions are improved with higher transmitted frequencies. An important diagnostic and prognostic consideration is the location and number of lesions. A solitary small lesion in an older dog is very often benign. Multiple lesions throughout the liver (Figure 3.14) offer a poorer differential diagnosis and limit surgical options. Multiple lesions may represent more than one pathological process. Differential diagnoses for common focal liver diseases are listed in Figure 3.15.



**3.14** Ultrasound image of 12-year-old spayed Golden Retriever bitch with multiple mixed echogenic masses in the liver representing metastatic intestinal adenocarcinoma.

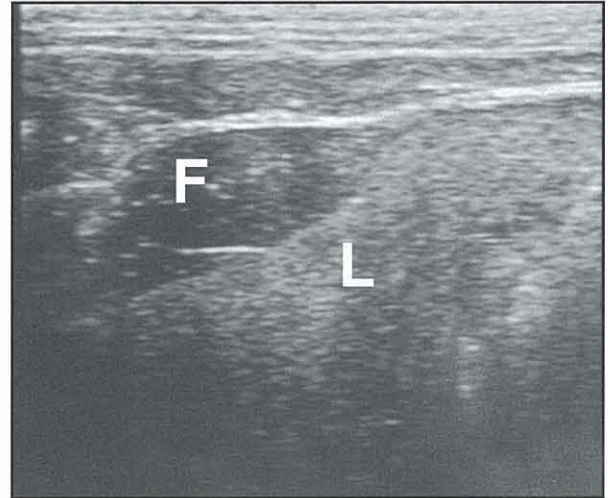
Hyperechoic	Hypoechoic	Mixed echoic
Metastatic neoplasia	Metastatic neoplasia	Metastatic neoplasia
Nodular hyperplasia	Nodular hyperplasia	Nodular hyperplasia
Dystrophic mineralization	Primary neoplasia	Primary neoplasia
Focal parenchymal gas	Abscess	Abscess
Focal fatty infiltration	Cyst (anechoic)	

**3.15** Differential diagnosis list for common focal liver diseases.

Widespread changes of the liver echogenicity usually represent a diffuse infiltrative process. Figure 3.16 gives the differential diagnosis list for common diffuse liver diseases. These diseases may cause the liver to be diffusely hyperechoic or hypoechoic. Diffuse changes in liver echogenicity are reliable only at extremes and require the echogenicity of the spleen or renal cortex to be normal for valid comparison. To complicate matters further, some diffuse hepatopathies, such as lymphoma, feline infectious peritonitis and cholangiohepatitis, may not affect hepatic echogenicity at all. Ultrasonographic determination of diffuse hepatopathies that result in an increase in echogenicity are more easily detected than those that result in hypoechoic. This is partly associated with the diffuse increase in acoustic attenuation (reduction of image brightness with increased depth in the image) which frequently occurs with many diseases that cause hyperechogenicity of the liver. In these cases the hepatic parenchyma in the near field appears brighter and that in the distal field appears darker than normal liver. Diffuse infiltration of the liver with lipid, as occurs with diabetes mellitus and feline hepatic lipidosis (Figure 3.17), or glycogen, as occurs in steroid hepatopathies (endogenous and iatrogenic), causes the liver to be hyperechoic and hyperattenuating compared with normal. Cats that are obese accumulate lipid within vacuoles in hepatocytes and sinusoidal lining cells. This results in a liver that is hyperechoic when compared with the fat of the falciform ligament, although less echoic and less attenuating than in feline hepatic lipidosis.

Hyperechoic	Isoechoic	Hypoechoic
Steroid hepatopathy (dog)	Normal	Hepatitis
Hepatic lipidosis (cat)	Lymphosarcoma	Cholangitis
Cirrhosis/fibrosis	Cholangitis	Lymphosarcoma
Lymphosarcoma	Feline infectious peritonitis	Congestion
Fat (diabetes mellitus)		
Fatty (cat: normal variant)		

**3.16** Differential diagnosis list for common diffuse liver diseases.



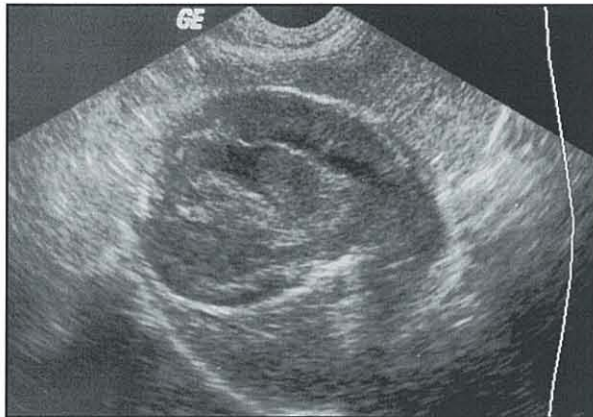**3.17** Sagittal plane of liver (L) and falciform fat (F) of an 11-year-old male neutered Domestic Short-hair cat with hepatic lipidosis.

It is important to note that both benign and malignant disease can account for similar, even identical, lesions on ultrasonography. A cytological or histological diagnosis is necessary to determine the aetiology. Ultrasound guidance allows accurate diagnostic sampling via fine needle aspiration for cytological examination and biopsy for histopathological evaluation.

**Ultrasonography of gall bladder diseases**

There is normal variation in the size of the gall bladder. As described above, the gall bladder of a fasted or anorexic animal will be dilated. The normal common bile duct is not seen ultrasonographically. Even with marked dilatation of the gall bladder in a dog or cat that has not eaten for some time, the common bile duct will not be dilated. When distended secondary to obstruction of the common bile duct, the neck of the gall bladder is wider and more tortuous. The dilated common bile duct can be traced from the neck of the gall bladder ventral to near the portal vein. It is frequently difficult to follow the bile duct as it passes behind the stomach via the lesser curvature because of gas within the gastric lumen. However, with distal dilatation it may be seen adjacent to the proximal portion of the duodenum. Dilatation of the lower biliary tract can extend to the intra-hepatic bile ducts and canaliculi, but since this may take up to a week to develop following extra-hepatic obstruction it is not a reliable sign of acute biliary obstruction. Dilated intra-hepatic bile ducts have echogenic walls and anechoic lumens, similar to the portal veins, but are tortuous and irregularly branching. Once dilated, any portion of the biliary tract may remain persistently dilated after resolution of the obstruction. Extra-hepatic obstruction may be caused by pancreatic, hepatic, duodenal or mesenteric masses (abscess, granuloma, neoplasm, lymphadenopathy), pancreatitis or cholelithiasis.

The most common cause of regional or generalized irregular gall bladder wall thickening is idiopathic cystic mucinous hypertrophy (Figure 3.18). In more severe forms of this disease the bile becomes gelatinous and dogs may present with signs of biliary obstruction. This



**3.18** Ultrasound image of gall bladder in a 13-year-old spayed Cocker Spaniel bitch with cystic mucinous hypertrophy and severely inspissated and gelatinized bile, causing biliary obstruction.

disease is poorly understood and difficult to manage medically. Uniform thickening of the wall of the gall bladder with a distinct hypoechoic 'halo' is seen with oedema or cholecystitis. Oedema of the gall bladder wall may be due to focal inflammatory conditions or a result of any systemic cause of hydrostatic, oncotic or vasogenic oedema. Cholecystoliths (gall bladder stones) are freely movable, dependently located, hyperechoic foci within the lumen of the gall bladder that cause distal shadowing due to their mineral content.

#### Ultrasound-guided biopsy of the liver and gall bladder

Ultrasonography allows safe and accurate placement of a needle (22 gauge) for cytological diagnosis of focal or diffuse hepatic disease (see Chapter 5). Similarly it is generally safe to aspirate bile from the gall bladder lumen for culture and cytology in cases of suspected cholangitis. The potential for bile peritonitis can be minimized by directing the needle through adjacent liver into the gall bladder lumen. It is contraindicated to puncture the gall bladder if the biliary tract is under pressure in cases of biliary obstruction.

Cytology may be non-diagnostic with sampling errors (e.g. missed target, haemodilution or paucity of cells) or diseases that have occult multifocal distribution, do not exfoliate well or require architectural information for diagnosis. Diseases that fall into the last group, which demand larger samples for histological diagnosis, include:

- Cirrhosis
- Portosystemic vascular shunting
- Many mesenchymal tumours
- Low grade lymphoma
- Differentiation of regenerative nodules from hepatocellular carcinoma.

Core biopsy, involving larger diameter samples for histological evaluation, carries a higher likelihood of morbidity from bleeding and requires anaesthesia and/or sedation with analgesia to avoid pain and movement of the patient. All patients will require haematological examination (clotting profiles and resting haematocrit)

before a biopsy procedure. Ultrasound-guided core biopsy may be contraindicated in suspected cases of cirrhosis, feline hepatic lipidosis or severe necrosis due to increased risk of bleeding during the procedure.

#### Doppler ultrasonography

Doppler ultrasonography provides very good vascular information and allows differentiation of abnormal dilated bile ducts from normal vessels. The diagnosis of portosystemic shunt is considerably more accurate when colour Doppler is used. The three forms of Doppler suitable for abdominal use are spectral, colour and power.

**Spectral Doppler:** Spectral Doppler is the tool most often utilized in the abdomen to determine estimates of velocities and differentiate between vessel types based on flow patterns. This is achieved by displaying the distribution of frequencies (reflector velocities) contributing to the signal. By convention the velocities towards the transducer are displayed above the baseline (positive) and flow away below (negative). In spectral Doppler a sample volume (gate) is placed within the concurrently displayed B-mode image and represents the sites where frequency shifts will be detected. The angle of flow must be corrected for, or the ultrasound machine assumes the flow is parallel to the incident sound beam path.

**Colour Doppler:** With colour Doppler a colour is assigned to the average Doppler shift frequencies (blood velocities) from a small region in the area of interest. Unlike spectral Doppler, in colour Doppler no quantitative information is available from the graphic representation of velocities. By convention the velocities towards the transducer are displayed as shades of red and flow away as shades of blue. Aliasing is a persistent problem with colour Doppler since the calculations of average velocity utilize  $\cos\Theta$ , where  $\Theta$  is the angle formed by the direction of blood flow compared with the direction of the ultrasound beam. In colour Doppler the regions of sampling may be larger, providing more of an overview of regional flow patterns. Frame rate and colour sector width are inversely proportional; the wider the area being interrogated the slower the frame rate.

**Power Doppler:** Power Doppler is similar to colour Doppler in that flow is graphically displayed with a colour. However, power Doppler provides no velocity information. The brightness of the colour is ultimately related to the number of moving reflectors, regardless of the velocity. Some machines provide directional information with power Doppler. Aliasing is not a concern since velocity is not calculated, and power Doppler is less subject to limitations due to incident angle of interrogation. The clinical utility of Power Doppler lies in the reported superiority in low flow detection, compared with spectral and colour Doppler. Identification of many diseases requires identification of 'no flow' states, e.g. the ability to differentiate a dilated bile duct from adjacent vessels. Disadvantages of power compared with colour Doppler include the lack of velocity and directional information, and increased flash artefact. Flash artefact is related to colour signals arising

from tissue motion or transducer movement. Even normal respiratory motion can produce an excessive amount of flash artefact.

### Advanced imaging

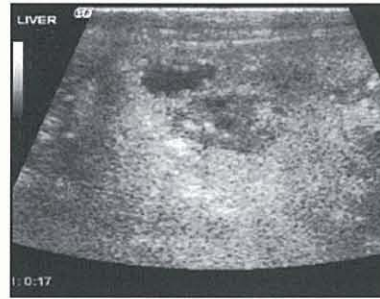Beyond Doppler technologies are a number of advanced imaging techniques suitable for examination of the liver. These are not yet widely available on machine systems in general veterinary use. The usefulness of 3D and extended-field-of-view technologies seems somewhat limited at this time due to slow reconstruction time and need for an immobile patient. This will probably be resolved when faster computer processors become available. Harmonic ultrasonography, however, has already demonstrated clinical applications in veterinary medicine.

### Harmonic ultrasonography

In fundamental ultrasonography the same frequency spectrum  $f$  is transmitted and received; i.e. a 3 MHz transducer has a 3 MHz transmitted signal, and receives and processes the reflection of the same 3 MHz signal. Harmonic ultrasonography is based on the principle of transmitting at frequency  $f$  and receiving at frequency  $2f$ . This technology has become available through the development of wide bandwidth transducers. Using newer wide bandwidth technology a 3 MHz transducer may transmit or receive a range of frequencies from 1–7 MHz; e.g. a 3 MHz transmitted pulse could be transmitted and a 6 MHz signal received and processed by the machine.

There are two forms of harmonic ultrasonography: tissue and contrast. In ultrasound imaging the transmitted signal is distorted in the patient, generating sound frequencies that are multiples of the original fundamental frequency. Tissue harmonics make use of the distortion of transmitted ultrasound signals. Different tissues distort the signal differently, resulting in increased contrast of the image. Many lesions that are subtle or isoechoic on fundamental ultrasonography have improved visibility in the tissue harmonic mode. Another advantage of this modality is the decreased number of detrimental artefacts, such as body wall ring-down, scattering and volume averaging, but an increase in clinically useful artefacts, such as shadowing and distal enhancement. The image quality using tissue harmonic ultrasonography is consistently improved in every patient, but which organ or lesion will demonstrate the improvement is not predictable.

Intravenous ultrasound contrast agents are small (2–5  $\mu\text{m}$ ) microencapsulated bubbles of inert gas and very efficient generators of harmonics. Changing the incident frequency, acoustic pressure and pulse repetition affects the harmonic response of contrast media. This feature allows imaging of contrast media in either high flow locations (large vessels or the heart) or in terminal arterials and capillaries as an indication of tissue perfusion. Contrast harmonics have demonstrated improved detection of subtle or isoechoic mass lesions (Figure 3.19). There are indications that this modality will provide improved differentiation of benign versus malignant lesions. Many malignant lesions in the liver have increased arterial vessels and a concurrent different



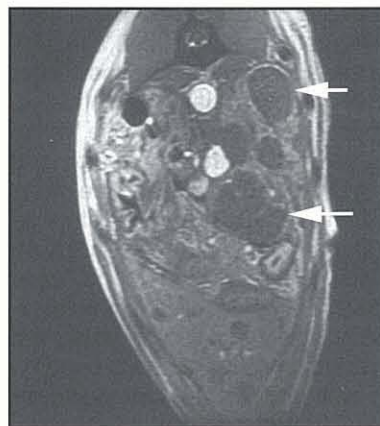
**3.19** Contrast harmonic ultrasound image of metastatic nodule in a 12-year-old Labrador Retriever with primary splenic haemangiosarcoma. Note hypoechoic irregularly shaped nodules surrounded by

normal hyperechoic liver. At this phase of the contrast study, mid-portal perfusion peak, the normal liver is well perfused (and therefore hyperechoic), but the nodules are poorly perfused (hypoechoic). Poor perfusion of a mass or nodule in the liver, during peak perfusion of normal adjacent liver, is the characteristic of malignancy.

perfusion pattern compared with adjacent normal liver. Harmonic imaging has the potential to enter into veterinary medicine fairly rapidly, at least into the academic and tertiary referral setting.

### Computed tomography and magnetic resonance imaging

Both CT and MRI have been used for clinical imaging of hepatobiliary diseases. Clinical studies demonstrating improved accuracy with decreased dependence on the technician's expertise have been reported for both the CT and MRI diagnosis of congenital and acquired portosystemic shunts in dogs. Both of these modalities are limited to tertiary referral institutions or private practices with access to scan centres that possess these very advanced imaging techniques. There is also great promise for improved visibility and differentiation between benign and malignant liver nodules with these modalities (Figure 3.20). CT-guided biopsy may be used in situations where ultrasonography is difficult.

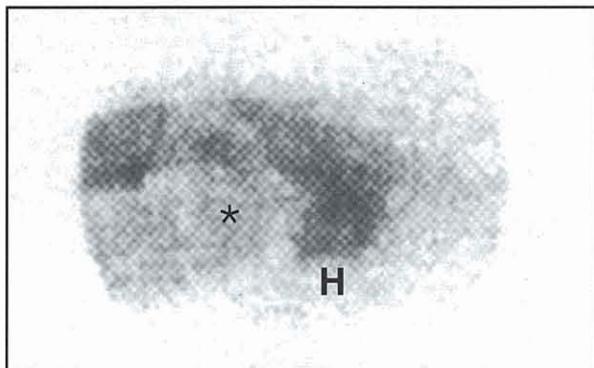


**3.20** Magnetic resonance image (T1 post-contrast) of hypointense poorly enhanced nodules (arrowed) in the liver of a dog with metastatic haemangiosarcoma.

### Scintigraphy

Scintigraphy is the imaging of radioactive pharmaceutical agents. The dominant clinical use of scintigraphy in small animal practice is for the diagnosis of congenital portosystemic shunts (Figure 3.21). The overall accuracy of scintigraphy is quite high, although limitations include: the need for very specialized equipment; radiation safety issues; and low specificity for differentiating congenital from acquired shunts, and intra-hepatic from extra-hepatic forms of the disease.





**3.21** Scintigraphic image of 8-month-old male Yorkshire Terrier with solitary extra-hepatic portocaval shunt. Note the small liver with poor radioactivity (\*) caudal to the heart (H).

### Pancreatic imaging

The pancreas is one of the most difficult organs to image in the dog or cat. It is not normally seen on radiography, and only with great expertise when using ultrasonography. The diagnosis of pancreatitis or pancreatic neoplasm is made only indirectly with radiography and with difficulty ultrasonographically (see Chapter 23). The gas, ileus and pain associated with many cases severely confound the ultrasound examination.

#### Radiography

Radiographically the normal pancreas is occult except under unusual circumstances. In obese cats it is occasionally seen medial to the spleen and caudal to the gastric fundus on the ventrodorsal projection. With pancreatitis the regional inflammation results in a spectrum of inconsistent roentgen signs. In cats most cases of pancreatitis are occult. The most common sign in dogs is loss of peritoneal detail in the right dorsal cranial abdomen. However, this part of the abdomen has inherently poor detail. Other more specific signs, although less common, include the 'signal' or 'sentinel loop' sign, more generalized loss of detail associated with effusion, and secondary systemic signs of vasculitis. The 'signal loop' sign represents ileus in the region of localized peritonitis caused by the inflamed pancreas. The manifestation of this peritonitis is gas-filled or distended intestinal loops in the right dorsal abdomen, including the duodenum, ascending colon and stomach. More generalized signs of pancreatitis include the manifestations of a generalized vasculitis (including peritoneal and pleural effusion), pulmonary and peripheral oedema and signs compatible with disseminated intravascular coagulation. The role of contrast radiography for the diagnosis of pancreatitis is indirect. An upper GI contrast study can provide supportive evidence of a regional ileus but is never specific for pancreatitis.

#### Ultrasonography

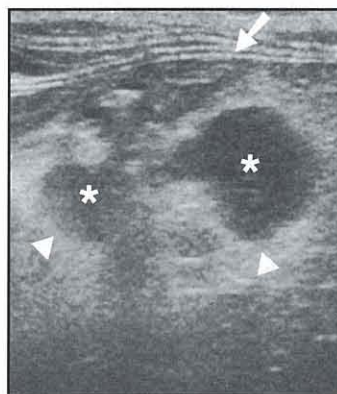
Ultrasonographic imaging of the pancreas requires a strict regimen of finding the duodenum and splenic hilus in every dog and cat. By scanning in the transverse plane and ignoring the occasionally dorsally positioned colon, the duodenum is usually the first small intestinal loop ventral to the right kidney. After

identification of the duodenum, the imaging should continue cranially to the pancreatic body region and then caudally to the region of the distal right limb, searching for regions of hypoechogenicity. The normal pancreaticoduodenal vein lies within the right limb of the pancreas and is a very useful landmark. This structure should not be mistaken for a dilated pancreatic duct. The left pancreatic limb is in the region of the splenic hilus, medial and slightly caudal to the spleen and cranial to the left kidney. In cats the blood vessel is peripheral and the duct a dependably central structure.

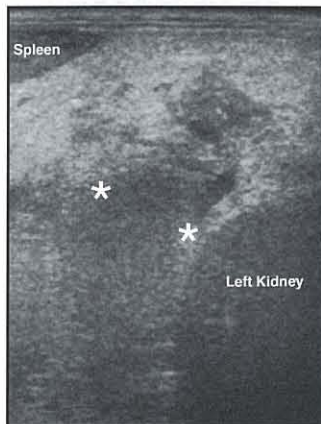
Ultrasonographic diagnosis of pancreatitis is specific, depending on the findings of the ultrasound examination, although variably sensitive with differing levels of operator proficiency. The ultrasonographic findings of pancreatitis include:

- Hypoechoic pancreatic parenchyma
- Hyperechoic peripancreatic fat
- Regional effusion
- Biliary obstruction
- Regional intestinal ileus
- Localized pain during the procedure.

Peripancreatic hyperechogenicity (Figure 3.22) is the most specific sign in dogs and cats. In cats the hypoechoic pancreas may be the only abnormality. Of special note is the distribution of pancreatitis in dogs and cats. While in dogs ultrasonographic abnormalities seem to be much more common in the right pancreatic limb, in cats they are more evenly distributed between the left and right limbs (Figure 3.23). Part of the ultrasound examination for a dog or cat with pancreatic disease involves the identification of secondary



**3.22** Ultrasound image of 11-year-old female spayed Domestic Short-hair cat with diabetes mellitus and 1 day history of vomiting and diarrhoea. Note the hypoechoic pancreas (asterisk) below the cat's right abdominal wall (arrowed), surrounded by hyperechoic peripancreatic fat (arrowheads).



**3.23** Ultrasound image of same cat in Figure 3.22, obtained after 5 months. The cat had another acute onset of vomiting and incoordination. Note the ill-defined hypoechoic pancreas and hyperechoic peripancreatic fat adjacent to spleen and left kidney. The asterisks mark the dimensions of the width of the pancreas at its thinnest point; the width was 1.25 cm.

manifestations of pancreatitis (including biliary obstruction), metastasis and the effects of vasculitis.

Pancreatic neoplasia is usually radiographically occult and ultrasonographically very challenging to differentiate from inflammation. Radiographically the most common manifestations are the widespread metastases in the abdomen (liver and lymph nodes) and lungs. Ultrasonographic signs are the metastases and often the ability to detect the infiltration and loss of distinct layering of the duodenum. A hypoechoic pancreas in the face of lymphadenopathy and liver metastases makes a strong case for primary pancreatic neoplasia.

### References and further reading

- Agut A, Wood AK and Martin IC (1996) Sonographic observations of the gastroduodenal junction of dogs. *American Journal of Veterinary Research* **57**, 1266–1273
- Brawner WR and Bartels JE Jr. (1983) Contrast radiography of the digestive tract. Indications, techniques, and complications. *Veterinary Clinics of North America: Small Animal Practice* **13**, 599–626
- Daniel GB, Bright R, Ollis P, *et al.* (1991) Per rectal portal scintigraphy using 99m technetium pertechnetate to diagnose portosystemic shunts in dogs and cats. *Journal of Veterinary Internal Medicine* **5**, 23–27
- Etue SM, Penninck DG, Labato MA, *et al.* (2001) Ultrasonography of the normal feline pancreas and associated anatomic landmarks: a prospective study of 20 cats. *Veterinary Radiology and Ultrasound* **42**, 330–336
- Gomez JA (1974) The gastrointestinal contrast study. Methods and interpretation. *Veterinary Clinics of North America* **4**, 805–842
- Guffy MM (1973) Radiography of the gastrointestinal tract. *Veterinary Clinics of North America* **2**, 105–129
- Koblik PD, Hornof WJ, Yen CK, *et al.* (1995) Use of technetium-99m sulfur colloid to evaluate changes in reticuloendothelial function in dogs with experimentally induced chronic biliary cirrhosis and portosystemic shunting. *American Journal of Veterinary Research* **56**, 688–693
- Kull PA, Hess RS, Craig LE, *et al.* (2001) Clinical, clinicopathologic, radiographic, and ultrasonographic characteristics of intestinal lymphangiectasia in dogs: 17 cases (1996–1998). *Journal of the American Veterinary Medical Association* **219**, 197–202
- Kumar R, Peshin PK and Nigam JM (1981) Double contrast gastrography in dogs. *Modern Veterinary Practice* **62**, 719–721
- Lamb CR (1999) Recent developments in diagnostic imaging of the gastrointestinal tract of the dog and cat. *Veterinary Clinics of North America: Small Animal Practice* **29**, 307–342
- Lester NV, Roberts GD, Newell SM, *et al.* (1999) Assessment of barium impregnated polyethylene spheres (BIPS) as a measure of solid-phase gastric emptying in normal dogs – comparison to scintigraphy. *Veterinary Radiology and Ultrasound* **40**, 465–471
- Manczur F and Voros K (2000) Gastrointestinal ultrasonography of the dog: a review of 265 cases (1996–1998). *Acta Veterinaria Hungarica* **48**, 9–21
- Moon ML, Biller DS and Armbrust LJ (2003) Ultrasonographic appearance and etiology of corrugated small intestine. *Veterinary Radiology and Ultrasound* **44**, 199–203
- Paoloni MC, Penninck DG and Moore AS (2002) Ultrasonographic and clinicopathologic findings in 21 dogs with intestinal adenocarcinoma. *Veterinary Radiology and Ultrasound* **43**, 562–567
- Papageorges M, Breton L and Bonneau NH (1987) Gastric drainage procedures: effects in normal dogs. II. Clinical observations and gastric emptying. *Veterinary Surgery* **16**, 332–340
- Quick CB and Rendano VT (1978) The use of contrast media in small animal radiology. *Cornell Veterinarian* **68**, 89–102
- Roberts GM, Roberts EE, Davies RL and Evans KT (1977) In vivo and in vitro assessment of barium sulphate suspensions. *British Journal of Radiology* **50**, 541–545
- Root CR and Morgan JP (1969) Contrast radiography of the upper gastrointestinal tract in the dog. A comparison of micropulverized barium sulfate and U.S.P. barium sulfate suspensions in clinically normal dogs. *Journal of Small Animal Practice* **10**, 279–286
- Saunders HM, VanWinkle TJ, Drobatz K, Kimmel SE and Washabau RJ (2002) Ultrasonographic findings in cats with clinical, gross pathologic, and histologic evidence of acute pancreatic necrosis: 20 cases (1994–2001). *Journal of the American Veterinary Medical Association* **221**, 1724–1730
- VanEnkevort BA, O'Brien RT and Young KM (1999) Pancreatic pseudocysts in 4 dogs and 2 cats: ultrasonographic and clinicopathologic findings. *Journal of Veterinary Internal Medicine* **13**, 309–313
- Weber MP, Stambouli F, Martin LJ, Dumon HJ, Biourge VC and Nguyen PG (2002) Influence of age and body size on gastrointestinal transit time of radiopaque markers in healthy dogs. *American Journal of Veterinary Research* **63**, 677–682
- Ziegler L and O'Brien RT (2002) Harmonic ultrasound: a review. *Veterinary Radiology and Ultrasound* **43**, 501–509
- Zontine WJ (1973) Effect of chemical restraint drugs on the passage of barium sulfate through the stomach and duodenum of dogs. *Journal of the American Veterinary Medical Association* **162**, 878–884

# Gastrointestinal endoscopy

James W. Simpson


## Introduction

The history and the physical examination of a patient indicates to the clinician the probable region of the gastrointestinal (GI) tract responsible for clinical signs. Further investigations using plain and contrast radiography, ultrasonography and functional tests may permit a tentative diagnosis to be made. However, these investigative procedures rarely permit a definitive diagnosis. Until recently clinicians have been limited in their ability to diagnose GI disease morphologically because of the need to carry out an exploratory laparotomy in order to obtain biopsy samples, where such a procedure may compromise an already seriously ill patient. The ability to pass a flexible endoscope directly into the GI tract and visualize the mucosa for gross abnormalities and collect biopsy samples without resorting to surgery has revolutionized gastroenterology.

However, endoscopy should not be viewed as the ultimate diagnostic tool for GI disease. In some cases GI function may be compromised in the absence of morphological changes and in some cases an exploratory laparotomy may be a more appropriate method of evaluating the case, for example when imaging detects a foreign body, intussusception or torsion, or where the potential exists not only to collect biopsy samples but also to carry out corrective surgery. The author has experience of cases where the small size of endoscopic biopsy samples has not permitted a definitive diagnosis to be made, and recourse to full-thickness biopsy sampling has been required. Even where endoscopy can provide valuable information, for example to confirm an oesophageal foreign body, flexible endoscopes are often unable to remove such foreign bodies. They are usually better removed using a rigid endoscope (Figure 4.1) and large grasping forceps. Rigid endoscopes are not only useful for the examination of the oesophagus but have value in examination of the rectum and distal colon.

Previously only human endoscopes were available for veterinary use and in most cases were unsuitable for the purpose. However, with the availability of specific veterinary endoscopes and many different sizes of human endoscopes it is now possible to use flexible endoscopy to examine all but the mid and distal jejunum in many dogs and cats.

This chapter reviews the role of flexible endoscopy in the diagnosis of GI disease in the dog and cat. The



**4.1** Rigid endoscopes can be used for examination of the oesophagus, removal of oesophageal foreign bodies and examination of the rectum.

use of endoscopy to assist in placement of feeding tubes is discussed in Chapter 27. Information provided in this chapter will assist not only the clinician considering the initial purchase of an endoscope but also those practitioners already using them.

For most general practitioners the major issues include choosing the right equipment and the cost of that equipment. Although rigid endoscopes are much cheaper than flexible endoscopes they are limited in their application, as indicated above. Second-hand human endoscopes are now available at reasonable prices, but care must be exercised to ensure the endoscope is not only suitable for veterinary purposes but of serviceable quality. Several companies are now offering refurbished human endoscopes with a guarantee of quality. However, new veterinary endoscopes now cost much less than equivalent human endoscopes. These represent excellent value and in most cases the companies offer sound advice to ensure the right instrument is purchased. The latest video endoscopes are definitely out of reach of most practices in the UK but second-hand systems are becoming increasingly affordable. It is clearly essential to buy high quality equipment and to maintain the equipment in good working condition so it can be of diagnostic value and more importantly, to ensure the safety of both endoscopist and patient.

Given the variation in size of patients seen in small animal practice there is no 'universal' endoscope to fit all patients. In the ideal world this problem would be solved by purchasing two or three endoscopes designed for different sized patients and procedures. In practice this is rarely justifiable on economic grounds, so a single endoscope is usually chosen that is often a compromise aimed at suiting the majority of patients.

Having obtained a suitable endoscope the second major problem for practitioners involves the ability to use the equipment effectively. Like learning to drive a car, this cannot be achieved from a textbook and takes practice to master. The best advice that can be given is to try and obtain training from an experienced endoscopist and to use the endoscope initially to carry out simple procedures, such as oesophagoscopy and proctoscopy, thus avoiding the frustration of failure while building confidence. Intubation of the duodenum should not be expected on one's first attempt to use the flexible endoscope, as this will probably end in failure and disappointment for beginners. Even the most experienced endoscopist occasionally finds this procedure difficult or even impossible.

Endoscopy is remarkably well tolerated, even in seriously ill patients, in part because unless duodenal intubation is attempted often only light general anaesthesia or sedation is required. Complications associated with endoscopy *per se* are fortunately rare, but may include haemorrhage and bowel perforation.

A major limiting factor associated with endoscopy is the inability to observe macroscopic or microscopic changes when pathology lies in deeper tissues. Only mucosa can be visualized and biopsy samples obtained, so changes in deeper tissues may go undetected. Fortunately in the majority of patients exhibiting chronic symptoms of GI disease there is almost always mucosal involvement.

### Flexible endoscope design

#### Fibreoptic endoscopes

Fibreoptic endoscopes are composed of bundles of individual optic fibres. Each fibre has the ability to transmit light or part of an image along its length, even when the fibres are bent as happens when the endoscope is passed along the GI tract.

Light can be lost from the optical fibre at its reflective surface, thereby reducing the quality of the light/image transmission (Figure 4.2). For this reason each optical

fibre is coated in a reflective substance, which reduces the loss and improves the quality of the light/image along the length of the fibre. These are called clad fibres. Each fibre has a very small diameter, so more than 200,000 fibres are incorporated into bundles in order to be practically useful in carrying an image.

Non-coherent bundles of optical fibres are arranged at random, so no recognizable image can be transmitted along the bundle. Such bundles are much cheaper to produce and are perfectly adequate for the transmission of light down the endoscope to illuminate the mucosa.

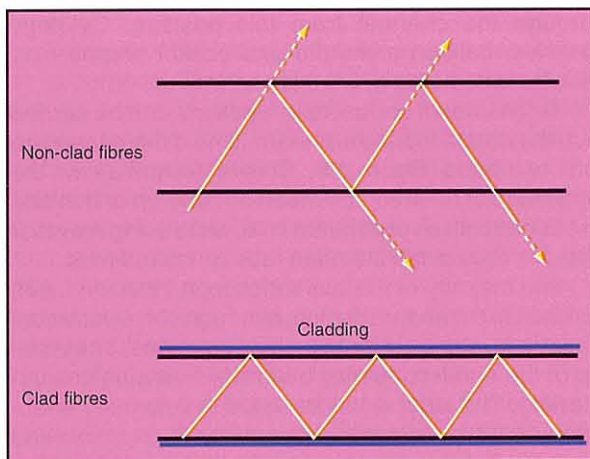
Coherent bundles of optical fibres are used to transmit images to the eye piece from the distal tip of the endoscope. In this construction the individual fibres are orientated so that the fibres at one end of the bundle are in the corresponding location at the other end. Images are therefore transmitted intact along the fibre bundle and can be observed through the eye piece. While small, such images are adequate for diagnostic purposes. Video cameras can often be attached to the eye piece to transmit the image for display on to a monitor, which is useful for teaching or group evaluation. However, the quality of such images falls short of those obtained using video endoscopes.

#### Video endoscopes

In the most modern endoscopes, coherent fibreoptic bundles have been replaced by a small video chip (charge coupled device) located in the distal end of the endoscope. The chip transmits signals via cables to a computer, which constructs a colour image that is displayed on a monitor.

There is no eye piece on video endoscopes and the operator performs the procedure whilst viewing the video monitor. The quality and size of the image is such that even subtle changes to the mucosa can be detected, making the video endoscope a better diagnostic tool. Video endoscopes are excellent teaching tools, permit group evaluation of observed abnormalities and allow storage of all endoscopic findings in a variety of electronic formats.

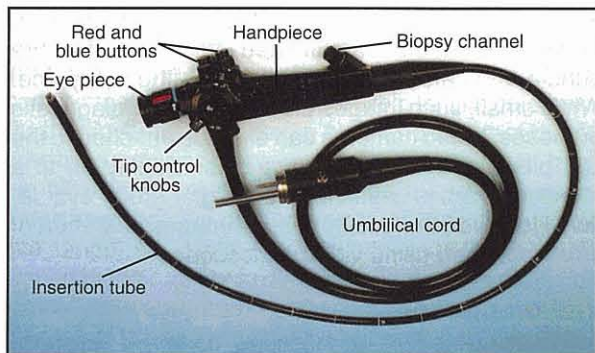
The video camera lies just behind the objective lens at the distal end of the endoscope. Some systems employ a colour chip but in the UK a monochrome chip is used. In order to view the image in colour using a monochrome chip, a sophisticated illumination and processing system is required to project a colour image on to the monitor. This is achieved by placing a wheel containing red, green and blue filters separated by opaque segments in front of the light source. This wheel rotates more than thirty times per second so the light transmitted down the endoscope flashes pulses of red, green and blue light and not a constant white light beam. During the red phase the video camera captures an image of the mucosa, which is transmitted to the computer and stored during the period when an opaque segment shuts off the light. The same process occurs for the pulses of green and blue light. Each time the filter wheel rotates once, a new image is created. The data stored by the computer as red, green and blue images are transmitted to the electron guns of the monitor where a complete colour picture is produced, so providing a new live image.



**4.2** There would be a loss of light passing along non-clad fibres due to the absence of suitable cladding around the fibre. This is why only light is transmitted down non-clad fibres, while the more expensive clad fibres are used to transmit the image.

### Components of the endoscope

All flexible endoscopes are constructed in a similar manner (Figure 4.3). The handpiece is the control centre of the endoscope from which all operations are carried out. It is connected to the light source by an umbilical cord. This cord transmits not only light to the endoscope tip but also air for inflation of the bowel and suction for removal of GI secretions and excess gas. The insertion tube is the portion of the endoscope that is introduced into the patient. It has a smooth cylindrical, yet flexible, structure and the distal end of it (the bending section) can be moved in four different directions via the two wheels on the handpiece.




**4.3** Flexible endoscope including the insertion tube, handpiece and umbilical cord.

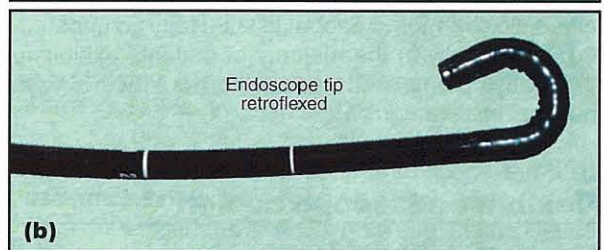
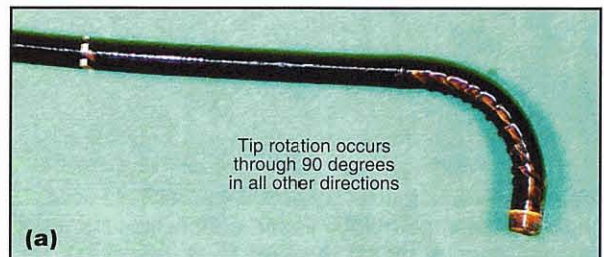
The insertion tube of a fibreoptic endoscope contains coherent and non-coherent optical fibre bundles for the transmission of the image and illuminating light, respectively. A biopsy channel is also included within the insertion tube, as is a small tube carrying water and air to the endoscope tip for washing the light and objective lens and inflating the gut, respectively.

The handpiece carries various important operational controls (Figure 4.4). The two rotating wheels on the right-hand side of the handpiece control movement at the endoscope tip. The inner wheel controls up and down movement, while the outer wheel controls left and right movement. Generally, movement through 90 degrees is possible in all directions, with movement of at least 180 (and up to 210) degrees in one specific direction. This permits the endoscopist to retroflex the endoscope tip to examine blind spots within the GI tract (Figure 4.5). A locking device is normally included to hold the tip in a particular position. On fibreoptic endoscopes there is usually a focus control on the eye piece to allow optimal visualization by individual operators.

On the top of the handpiece are two colour-coded buttons. The code is the same for all manufacturers. The first button (red) activates suction when depressed. The second button (blue) has a hole on its surface through which air from the light source (delivered by the umbilical cord) can escape. When this hole is covered by a finger, air is diverted down the endoscope allowing the bowel to be inflated in a controlled manner. If the blue button is fully depressed water is directed down the insertion tube to wash the lens when it becomes soiled.



**4.4** The handpiece of a flexible endoscope carries various important operational controls.



**4.5** The tip of the insertion tube can be rotated through 90 degrees in three planes and 180 degrees in one plane.

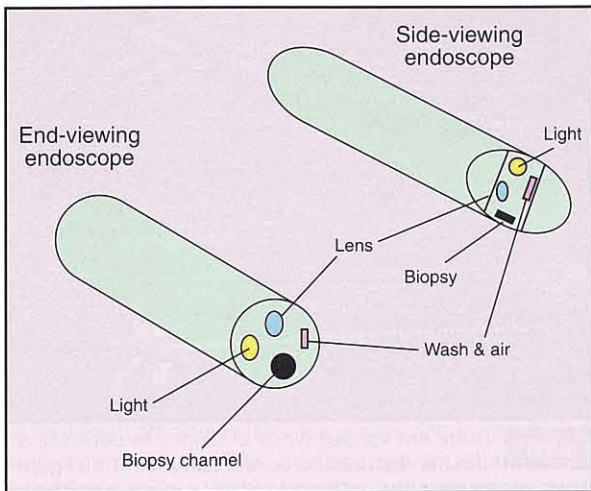
The entrance to the biopsy channel will be found in one of several locations depending on the model of endoscope being used. It is closed by a replaceable rubber valve through which instruments can be introduced without allowing air to escape from the GI lumen. Biopsy forceps of various designs can be introduced through the channel from this position. Cytology brushes, balloon catheters and basket snares may also be introduced down this channel.

To ensure all endoscopic functions can be carried out, the endoscopist must learn to hold the handpiece with one hand (Figure 4.6). This technique allows the endoscopist to direct the insertion tube tip and inflate the lumen with air or aspirate fluid, while using the other hand to control the insertion tube or instruments.

The majority of flexible endoscope insertion tubes are built to a standard design, although some individual variations may exist for specialist purposes. The distal tip of the endoscope may be forward-viewing or side-viewing. The latter is of little value in veterinary endoscopy as it is designed specifically to examine and intubate the human pancreatic or bile duct from the duodenal lumen. Forward-viewing endoscopes are the most appropriate for veterinary use as they allow the operator to see directly ahead of the advancing insertion tube (Figure 4.7).



**4.6** One-handed manipulation of the headpiece. All endoscopists need to learn this technique.



**4.7** There are two types of end piece available for flexible endoscopes. The end-viewing tip is more popular and is used for the majority of examinations, where the endoscopist wishes to see directly forward. The side-viewing endoscope is designed to allow good visualization of the wall of the bowel and to assist in catheterizing ducts, such as the bile duct. It is rarely used in small animal practice.

The size of the insertion tube may vary depending on its purpose. The majority of endoscopes are made with an insertion tube length of 1 metre, although models ranging from 500 cm (bronchoscopes) to 2 metres (colonoscopes) or longer are available. The outside diameter of the insertion tube is of considerable importance to the veterinary endoscopist. When the GI tract of both the dog and cat are to be examined, the ideal diameter of insertion tube is 7–9 mm. Many human endoscopes have an 11 mm or 14 mm diameter insertion tube, which is only suitable for very large dogs and is of no value in small dogs and cats.

The size of the biopsy channel is to some extent dependent on the diameter of the insertion tube. The larger the insertion tube diameter, the larger the biopsy channel that can be incorporated. Ideally the endoscope should have a biopsy channel of at least 2 mm and preferably 2.8 mm to permit biopsy samples of the best diagnostic quality to be collected (see Chapter 5).


In summary, the following facilities must be available on the flexible endoscope when the GI tract of dogs and cats are to be examined:

- 1 metre insertion tube length (maximum 1.5 m)
- Insertion tube diameter of 7 to 9 mm
- A minimum of 2 mm biopsy channel
- Four-way tip deflection
- 180 degree deflection of the tip in at least one direction
- Locking device for the tip
- Water and air feed facility
- Forward-viewing tip

### Light source

There are basically two types of light source available for modern endoscopes: the halogen bulb and the xenon bulb. The former is a low cost 150 watt cold light source that is effective for routine use with fibreoptic endoscopes (Figure 4.8). The xenon bulb is more expensive but much brighter and is used routinely with video endoscopes. It provides excellent light for photography.

A new metal halide light source provides the brightness of a xenon bulb at a cost closer to a halogen bulb.



**4.8** Two types of halogen cold light source designed for fibreoptic endoscopes.

Normally the GI tract is an empty collapsed tube that cannot be viewed without first being dilated with air. It is extremely important, therefore, that the system includes an air inflation pump. Air is directed down the endoscope to dilate the lumen when a finger is placed over the blue button. Where an air pump is incorporated into the light source it is usually accompanied by a wash facility, permitting the lens on the endoscope tip to be cleaned *in situ* when the blue button on the handpiece is fully depressed.

Suction units (Figure 4.9) are sold as separate units and are not incorporated into the light source. Suction is attached to the umbilical cord of the endoscope and is operated by the red button on the handpiece. Suction units are not essential, but are highly desirable to facilitate removal of accumulated liquid and excess gas.



**4.9** Two types of suction unit that can be used with flexible endoscopes.

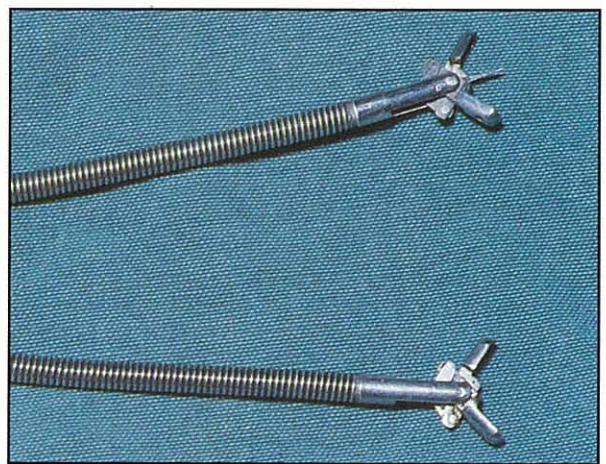
**Accessories**

The accessories available for flexible endoscopes include:

- Biopsy forceps: fenestrated, spiked or plain
- Cytology brushes
- Grasping forceps
- Basket forceps
- Wire snares
- Sterile catheters.

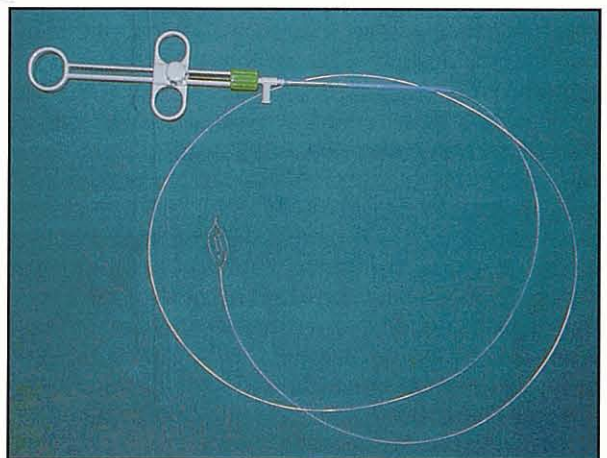
The only essential accessories required for routine endoscopy are biopsy forceps, which are all very

similar in basic design. The main variables are the length and the diameter of the forceps and the type of collection cups at the distal end. The diameter of biopsy forceps varies from 2 to 3 mm and is dependent on the size of the biopsy channel. The forceps work from a handpiece that opens and closes two half cups at the other end of the flexible metal rod that passes down the biopsy channel. In addition to plain cups there are fenestrated cups, which permit the collected biopsy to bulge through the side walls to prevent artifactual damage to the sample. Whether plain or fenestrated, the cups may contain a spike to assist in fixing the forceps on to the mucosa to be sampled; this may be useful when the forceps are not perpendicular to the mucosa, such as occurs in the small intestine (Figure 4.10).



**4.10** There are various types of biopsy forceps cups that can be used to collect samples. This figure shows biopsy forceps, with and without a central spike, which are commonly used for biopsy collection.

Grasping and basket forceps are designed for removal of foreign bodies, although, this is usually limited by the actual size and strength of the forceps available (Figure 4.11). Under no circumstances should biopsy forceps be used to retrieve foreign bodies as the forceps will become irreparably damaged.



**4.11** Basket forceps which can be used to retrieve gastric foreign bodies with the endoscope.

## Care and cleaning of endoscopes

Endoscopes should always be transported in their original case to avoid damage, especially to the coherent optical fibres, as even gentle knocks can break individual fibres without necessarily damaging the insertion tube casing.

When not in use, endoscopes should be hung up on a suitable endoscope holder. This allows the endoscope to dry and the insertion tube to hang vertically, keeping it straight. If the endoscope is kept curled in its case, the insertion tube eventually develops a permanent curve which makes it difficult to use and if put away damp it may grow mould.

An endoscope should never be exposed to temperature extremes. Very low temperatures cause the optic fibres to become brittle whilst high temperatures will damage the waterproof covering of the insertion tube and lens mounts.


Disinfection should be employed to reduce cross-infection between patients. Aseptic technique is obviously limited, especially when conducting a colonoscopy, emphasizing the need for thorough cleaning and disinfection after every use. The manufacturers' instructions regarding cleaning should always be followed and it is important to remember that only the more recent endoscopes (i.e. those with a blue ring around the eye piece) are fully immersible. With older endoscopes only the insertion tube can be immersed in cleaning and disinfection solutions as the handpiece is not waterproof.

Thorough washing of the outer surface and the various channels to ensure all secretions are removed is required; otherwise, blockage may occur, resulting in equipment failure. **The endoscope must never be sterilized using heat as this will result in total destruction of the equipment.** Disinfectant solutions specifically designed for endoscopes are available including: Gigasept FF, containing succindialdehyde and MedDis, containing halogenated tertiary amines. As with all disinfectants, they should be used with care and following the manufacturers' instructions carefully. The endoscope should be rinsed thoroughly after disinfection to avoid exposing the patient's GI mucosa to disinfectant solution at the next endoscopy.

Personal protection while washing and using the endoscope is essential. Disposable gloves and other protective clothing should be used to avoid contact with body secretions. Operators should always be aware of the risk of zoonotic disease and take appropriate precautions.

## Common problems encountered during endoscopy

During endoscopy, the endoscopist will periodically be unable to recognize any structures and will see a diffuse red colour. This image is called a 'red out' and is due to the reflection of light at the endoscope tip, which has come into contact with the collapsed lumen of the bowel or with GI secretions (Figure 4.12). This 'red out' is observed, even by experienced endoscopists,



**4.12** 'Red out' occurs whenever the endoscope is passed through a sphincter or comes up against the mucosal surface.

at various times during most endoscopic examinations. Correction of 'red out' involves stopping further advancement of the endoscope and slowly inflating the lumen with air until an image is seen. Where the tip of the endoscope is still in contact with the mucosa the endoscope should be withdrawn slightly and the image will be restored.

The presence of food, mucus or faeces within the bowel will interfere with image quality and prevent the endoscopist viewing the underlying mucosa. If the endoscope enters such material it should be slightly withdrawn and the lens flushed with water using the blue button on the handpiece. A highly reflective image, resulting in a loss of definition, is most frequently due to the presence of mucus on the lens. This can usually be resolved by washing the lens again or by aspiration of the material covering the lens.

Inability to illuminate the mucosa adequately may be due to contamination of the endoscope lens with faeces, food or blood. It may also occur if the light source is faulty or where the non-coherent optical bundles have been damaged. The presence of distinct black dots in the image is an indication of individual optical fibre damage in the coherent image bundle. The more fibres that are broken, the more black dots that appear. This sign of damage indicates that the endoscope is reaching the end of its useful working life.

The passage of the endoscope along the GI tract may cause abrasions to the mucosa, which are unavoidable. Care must be exercised in interpreting such damage as inflammation or ulceration. Mucosal bleeding is commonly observed after collecting a biopsy sample. Such bleeding should be no more than minor seepage and should stop shortly after the biopsy has been collected.

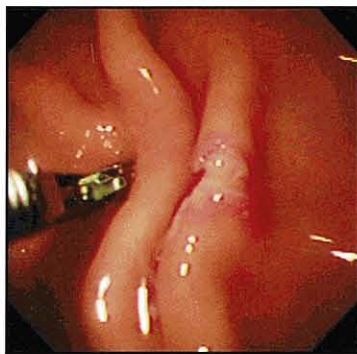## Biopsy collection

The mucosa should be carefully examined for macroscopic abnormalities. Where a focal lesion is found, multiple biopsy samples of the lesion and surrounding 'normal' tissue should be collected into separate bottles.

Where no obvious lesion can be detected biopsy samples should still be collected as many GI conditions can only be diagnosed following histological examination. Multiple samples should be collected from different areas of the tissue being examined.



When a lesion is observed, the endoscope should be orientated so that a clear forward view of the lesion is provided. The biopsy forceps should be guided towards the lesion with the jaws open (Figure 4.13). The forceps should be pushed into the lesion and the jaws closed. With the jaws closed the forceps should be withdrawn completely via the biopsy channel together with the sample. An assistant can now carefully remove the biopsy from the forceps using a small hypodermic needle and place the sample in 10% buffered formal saline. The sample should not be crushed and may be placed on a presoaked card or nylon sieve to prevent transport damage and to facilitate orientation of the specimen during subsequent processing. Alternatively the forceps can be immersed directly in formalin to fix the biopsy but must be washed before reinserting into the patient.



**4.13** Gastric biopsy site and biopsy forceps as seen through the endoscope.

It must be remembered that the samples collected by endoscopy are very small. The only way that the pathologist can offer a diagnosis is if adequate samples have been collected and they have been carefully stored. Since some biopsy samples will always be damaged during handling and preparation, multiple biopsy samples are essential to maximize the diagnostic yield.

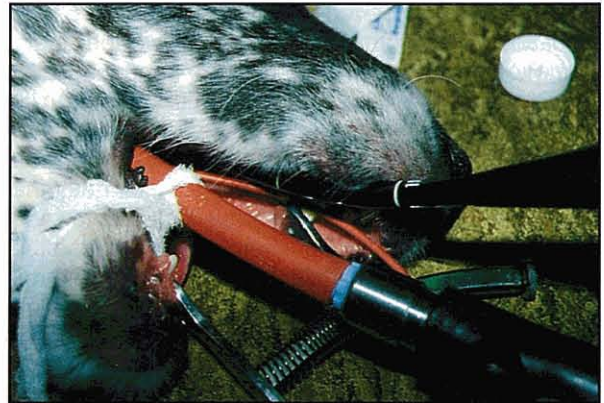### Patient preparation for the upper GI endoscopy

Upper GI endoscopy refers to the examination of the pharynx, oesophagus, stomach and duodenum. With specialist endoscopes it is also now possible to examine the jejunum.

Patient preparation starts with 12–24 h withdrawal of food, with water being withheld for 4 hours prior to the examination. Where delayed gastric emptying is suspected, a plain lateral radiograph should be taken before initiating the procedure to ensure the stomach is empty.

General anaesthesia is required for both dogs and cats. The author uses acepromazine maleate and buprenorphine as premedicant followed by propofol intravenously, intubation and maintenance on halothane and oxygen. Endotracheal intubation is essential to prevent aspiration pneumonia from occurring. Tying the endotracheal tube to the mandible and not the maxilla, can aid the passage of the endoscope into the

oesophagus, which lies dorsal to the trachea (Figure 4.14) but is not essential. A mouth gag is essential to prevent damage to the endoscope and the patient should be placed in left lateral recumbency, as this aids the passage of the endoscope through the pylorus and into the duodenum.



**4.14** The patient is placed in left lateral recumbency with the endotracheal tube tied to the mandible and with the mouth gag in place. The flexible endoscope can now pass easily along the hard palate and into the pharynx.

## Oesophagoscopy

### Indications

Oesophagoscopy is indicated for those patients presented with regurgitation of undigested food, in dysphagic patients and where there is unexplained salivation.

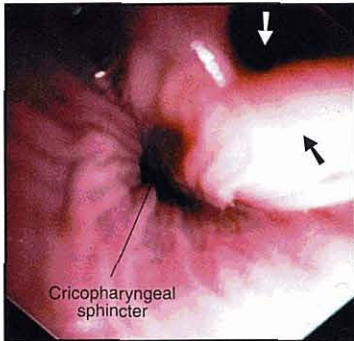
Clinical examination may strongly suggest oesophageal disease and this may be further substantiated by plain and contrast radiography. In some cases this will provide a definitive diagnosis of oesophageal disease. Megaesophagus, oesophageal foreign body, vascular ring anomaly, stricture formation (see *BSAVA Manual of Canine and Feline Head, Neck and Thoracic Surgery*) and extra-oesophageal masses may be diagnosed in this manner. However, endoscopy can play an important role in evaluation of these conditions and in their treatment. Endoscopy is the only practical method of diagnosing reflux oesophagitis as this cannot be detected using radiography. The only other alternative is placement of a pH probe in the distal oesophagus, a technique not readily available. Oesophageal neoplasia is rare but is most easily definitively diagnosed by endoscopy and biopsy.

### Procedure

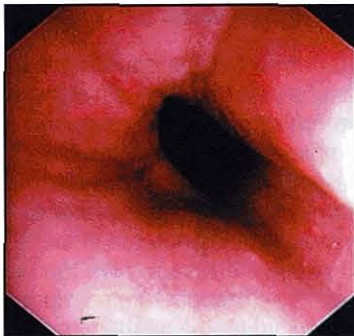Contrast studies should not be carried out immediately prior to oesophagoscopy as retention of barium in the oesophagus may make endoscopy difficult and will increase the risk of pulmonary aspiration. Patients should be prepared in the manner described in the preceding section.

1. Advance the endoscope along the midline of the hard palate and into the pharynx.

2. Stop at this point and carefully visualize the pharyngeal tissue before entering the oesophagus. The cricopharyngeal sphincter lies dorsal to the lateral folds of the larynx and the endotracheal tube (Figure 4.15). The cricopharyngeal sphincter is usually closed, so advancing the endoscope will be met with resistance and 'red out' will be observed.
3. Once past the sphincter, stop further advancement and inflate the oesophagus with air until an image is observed.
4. Move the endoscope slowly along the oesophagus, keeping the entire mucosal circumference in view (Figure 4.16).



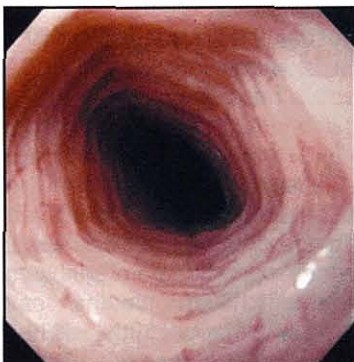**4.15** Endoscopic view of the pharynx. The laryngeal opening (white arrow) and the lateral fold of the larynx (black arrow) are visible.



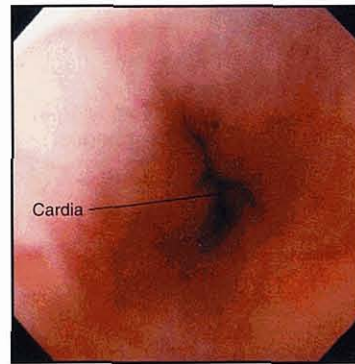
**4.16** View along the length of a normal cranial oesophagus.

### Findings

By examining the mucosa as the endoscope is advanced, pathological lesions will not be confused with iatrogenic damage. It will be noted that the trachea indents into the oesophagus, and in the cat annular rings will be observed in the mucosa of the distal oesophagus (Figure 4.17). The gastro-oesophageal junction is a high pressure zone rather than a true sphincter and is easily recognized by its slit-like appearance (Figure 4.18).

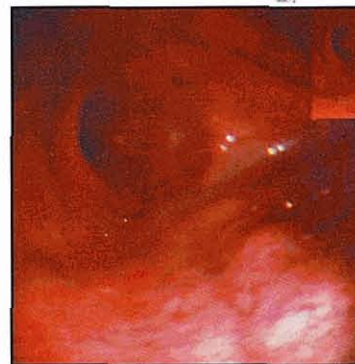

**4.17** Annular rings seen in the caudal oesophagus of all cats.



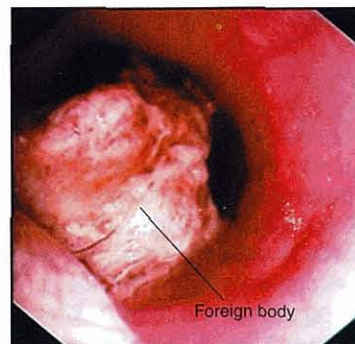
**4.18** The cardia high pressure zone, separating the oesophagus from the stomach.

In megaesophagus endoscopy will simply reveal a large cavernous oesophageal lumen, not created by air inflation, extending from the cricopharyngeal sphincter to the cardia (Figure 4.19). In megaesophagus secondary to vascular ring anomaly, dilatation extends only to the heart base whilst the oesophageal diameter beyond is normal. In both cases saliva will be observed to accumulate to varying degrees within the dilated oesophageal lumen.

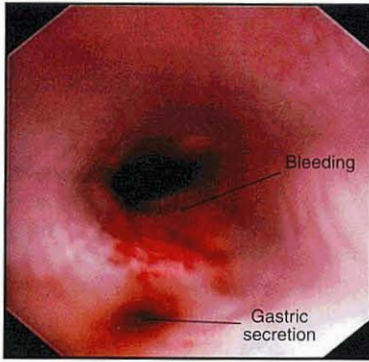


**4.19** Large cavernous oesophagus associated with megaesophagus.

Oesophageal strictures can occur anywhere along the length of the oesophagus but are more common distally. Strictures usually develop secondary to a foreign body (Figure 4.20) or reflux oesophagitis (Figure 4.21). Varying degrees of dilatation will be observed cranial to the stricture depending on how long it has been present. The stricture appears as a distinct circumferential narrowing of the lumen, and is often pale due to fibrous tissue deposition (Figure 4.22) and may be sufficiently narrow to prevent advancement of the endoscope.

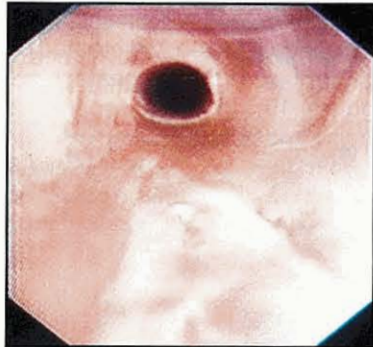

**4.20** Oesophageal foreign body lodged in the caudal oesophagus.



4.21

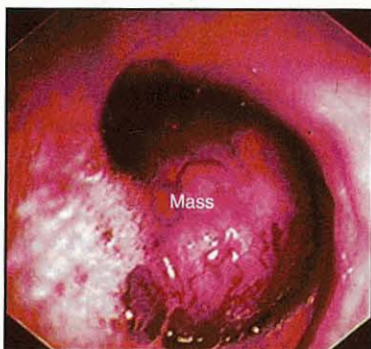
Reflux oesophagitis with gastric secretions, lying in the oesophagus.



4.22

Oesophageal stricture showing changes to the mucosal colour due to fibrosis.

Oesophageal foreign bodies are readily detected as the endoscope is passed along the oesophagus (see Figure 4.20). Although they are most common in the region between the base of the heart and the cardia, they can occur anywhere along the length of the oesophagus. In some cases they may be difficult to see due to the accumulation of saliva cranial to the obstruction; in such cases the use of suction will permit better visualization. Many objects can obstruct the oesophagus but chicken bones and vertebral bones are the most common. Tumours of the oesophagus are very rare except in geographical areas where infection with *Spirocerca lupi* is common, but when present tumours usually occur in the distal oesophagus and become space-occupying (Figure 4.23).



4.23

Oesophageal tumour. These are rare in dogs and cats.

The oesophageal mucosa is very tough and is normally very difficult to biopsy. Fortunately this is rarely required. On those occasions where tissue is required, focal lesions with abnormal soft surfaces are often present and sampling using a cytology brush, as well as biopsy forceps, may be helpful.

### Therapeutic use

Endoscopy can be used to treat some forms of oesophageal disease, including removal of foreign bodies and dilatation of oesophageal strictures (see Chapter 18 and *BSAVA Manual of Canine and Feline Head, Neck and Thoracic Surgery*).

### Gastroscopy

#### Indications

Gastroscopy is often indicated in patients presenting with vomiting. With acute vomiting, following radiographic examination, endoscopy may permit the clinician to confirm the presence of a gastric foreign body and may be used for its removal. With chronic vomiting, radiographic changes may suggest a filling defect associated with an ulcer or a gastric tumour. Endoscopy can be used to confirm the likely presence of a tumour by visualizing the tissues and collecting biopsy samples for cytological and histopathological examination. Inflammatory disease is a common cause of chronic vomiting and in these cases no changes will be observed with radiography. Endoscopic examination and biopsy collection is therefore essential in reaching a diagnosis.

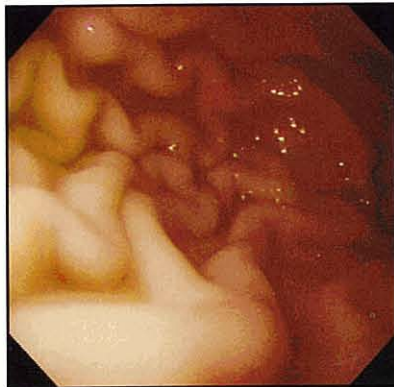
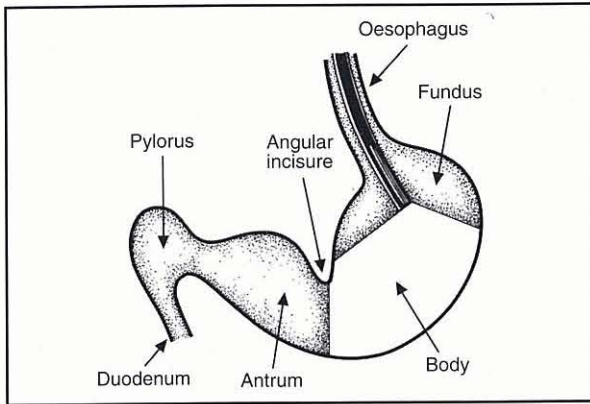
#### Enteroscopy

Enteroscopy is often performed at the same time as gastroscopy. It has been suggested that attempts to intubate the duodenum are more likely to succeed if carried out **before** complete gastroscopy or biopsy collection. This is because it is easy to over-distend the stomach while collecting biopsy samples, which can reflexively close the pylorus, making duodenal intubation very difficult.

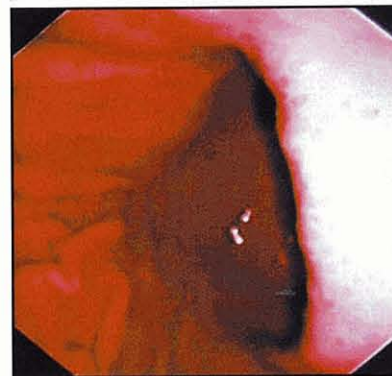
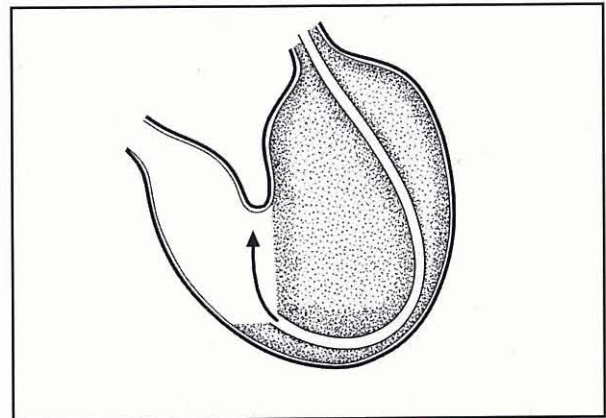
#### Procedure

Patients should be prepared in the manner described above.

1. Insert the endoscope into the oesophagus until the gastro-oesophageal junction is visualized.
2. Align the tip of the endoscope with the cardia (see Figure 4.18) and gently advance overcoming the slight resistance, during which 'red out' will occur. As the endoscope enters the stomach there will be a sudden loss of resistance. Stop further advancement of the endoscope and inflate the stomach with air until an image of the gastric mucosa is seen.
3. If resistance is not lost as the endoscope attempts to enter the stomach, this is usually because the endoscope has been misdirected. Do not apply excessive force; withdraw the endoscope slightly and redirect before beginning the process again. Occasionally the cardia will be open and entry into the stomach can be achieved without loss of the image or increased resistance.
4. Once the tip of the endoscope has entered the stomach and a clear image has formed, the fundic mucosa, complete with rugal folds, will be revealed (Figure 4.24). As the stomach is inflated



**4.24** Normal gastric fundus showing the rugal folds. (Diagram reproduced from Tams (1990) with permission from Elsevier.)



**4.25** The images show a view of the angular incisure on the lesser curvature of the stomach. This is a very important endoscopic landmark. (Diagram reproduced from Tams (1990) with permission from Elsevier.)

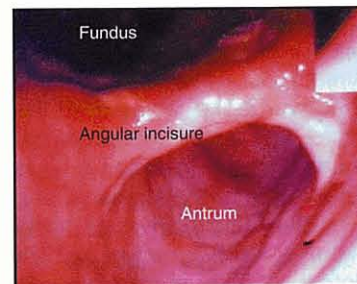
with air, so the rugal folds become less prominent. If the rugal folds are completely absent, creating a smooth mucosal surface, over-inflation with air has occurred. In this situation, decompress the stomach using endoscopic suction. Failure to reverse this distension may not only close the pylorus and make duodenal intubation impossible, but also compromise anaesthetic safety by impairing venous return to the heart and breathing.

5. Examine the fundus carefully for lesions by moving the endoscope tip in different directions.
6. Advance the endoscope slowly a little further to allow a clear view of the body of the stomach and entrance to the antrum (Figure 4.25). Look carefully at the angular incisure, which is an important landmark found on the lesser curvature of the stomach at the entrance to the antrum. It appears as a crescent-shaped band across the stomach, which becomes more prominent as the stomach is inflated with air (Figure 4.26).

### Findings

The initial examination of the stomach should permit the detection of foreign bodies, food, fluid, bile and blood. Such findings may provide important indicators of the underlying pathology but may hinder further endoscopic examination of the stomach.

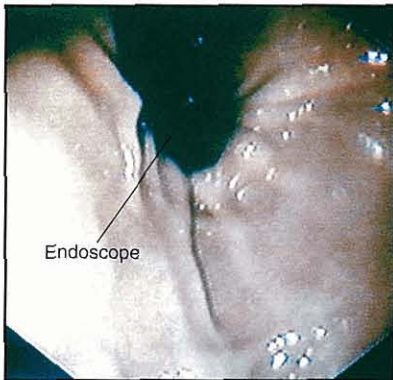
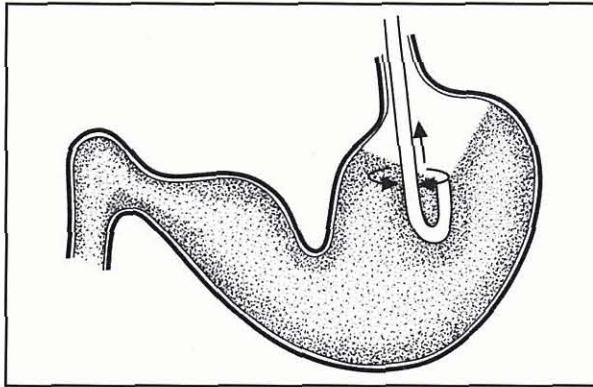
The presence of food in the stomach of a patient that has been adequately fasted prior to endoscopy may suggest delayed gastric emptying. Food will prevent full examination of the stomach as it often accumulates in the antrum making visualization poor and passage of the endoscope into the duodenum difficult.



**4.26** The angular incisure becomes more prominent as the stomach becomes distended with air.

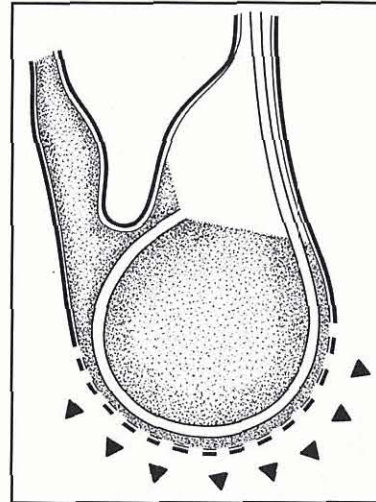
Fluid can usually be removed by suction allowing the gastroscopy to continue. But both food and fluid can mask the presence of a foreign body. Bile in the stomach indicates a patent pylorus but may also indicate failure of gastric housekeeper contractions or the presence of retroperistalsis associated with an intestinal obstruction or other motility abnormality. Observing fresh or changed blood (coffee grounds) is abnormal, and the endoscopist should look for a bleeding focus such as an ulcer or tumour.

Irrespective of whether abnormalities have been detected upon initial examination, the remainder of the stomach should now be examined. The endoscope should be pushed gently forward towards the antrum along the greater curvature of the stomach. If the antrum cannot initially be observed, follow the rugal folds as they pass towards the antrum. Before entering the antrum, the tip of the endoscope should be retroflexed to allow visualization of the cardia and fundic area, which lies in the 'blind spot' on entry to the stomach (Figure 4.27). This examination is performed by gently rotating the insertion tube on its long axis. After this has been completed the tip should be returned to view the antrum.



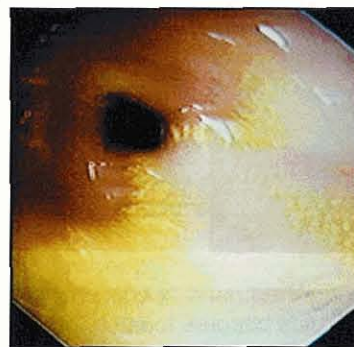
4.27

Retroflexed view of the gastric cardia with the endoscope clearly visible entering the stomach. (Diagram reproduced from Tams (1990) with permission from Elsevier.)



4.28

Over-distension of the stomach will result in the angular incisure closing over the antrum, leading to difficulty in intubating the antral canal and pylorus. (Reproduced from Tams (1990) with permission from Elsevier.)



4.29

The pylorus can usually be visualized with the endoscope in the antral canal. Often the pylorus is closed, but here it is open. Some bile-stained fluid can be seen in the antral canal.

Advancement of the endoscope into the antrum looks easy from this location but in practice this can be a very difficult manoeuvre. As the tip looks along the antral canal and the insertion tube advanced, the tip may appear to move backwards, i.e. away from the antrum rather than forward. This is called paradoxical movement and occurs because the insertion tube is lying along the greater curvature of the stomach, and pressure applied to the insertion tube to advance the tip is actually directed at the greater curvature, which expands to accommodate it. If pressure is continually applied the tip often swings past the angular incisure and back into the fundus. This occurs more readily if the stomach is over-inflated as it closes the antrum and makes movement to the pylorus difficult.

Over-inflation of the stomach and pressure on the greater curvature can move the angular incisure to close off the antral canal so that the stomach assumes a round ball like structure (Figure 4.28). In this case it is difficult to find the pylorus and intubate the duodenum. When this occurs air must be removed from the stomach by suction and the endoscope tip moved back to the fundus before repeating the manoeuvre. When repeated, it is important to ensure that air is not continually being fed into the stomach and to keep the endoscope tip lying along the greater curvature, so that the tip is more likely to move into the antral canal successfully. Gentle rotation of the insertion tube on its long axis may assist in this process and is of particular value in cats. The inexperienced endoscopist may have to try this procedure several times before the endoscope passes into the antral canal.

Once in the antrum it will be noted that there are no rugal folds, the mucosa is smooth and paler in colour and the lumen tapers towards the pylorus (Figure 4.29).

Peristaltic contractions against a closed pylorus are frequently observed and may intermittently obscure the image. The pylorus itself may be open or closed in the normal animal and bile may be observed to reflux into the stomach. The endoscope should be moved along the antral canal looking for abnormalities.

#### Neoplasia

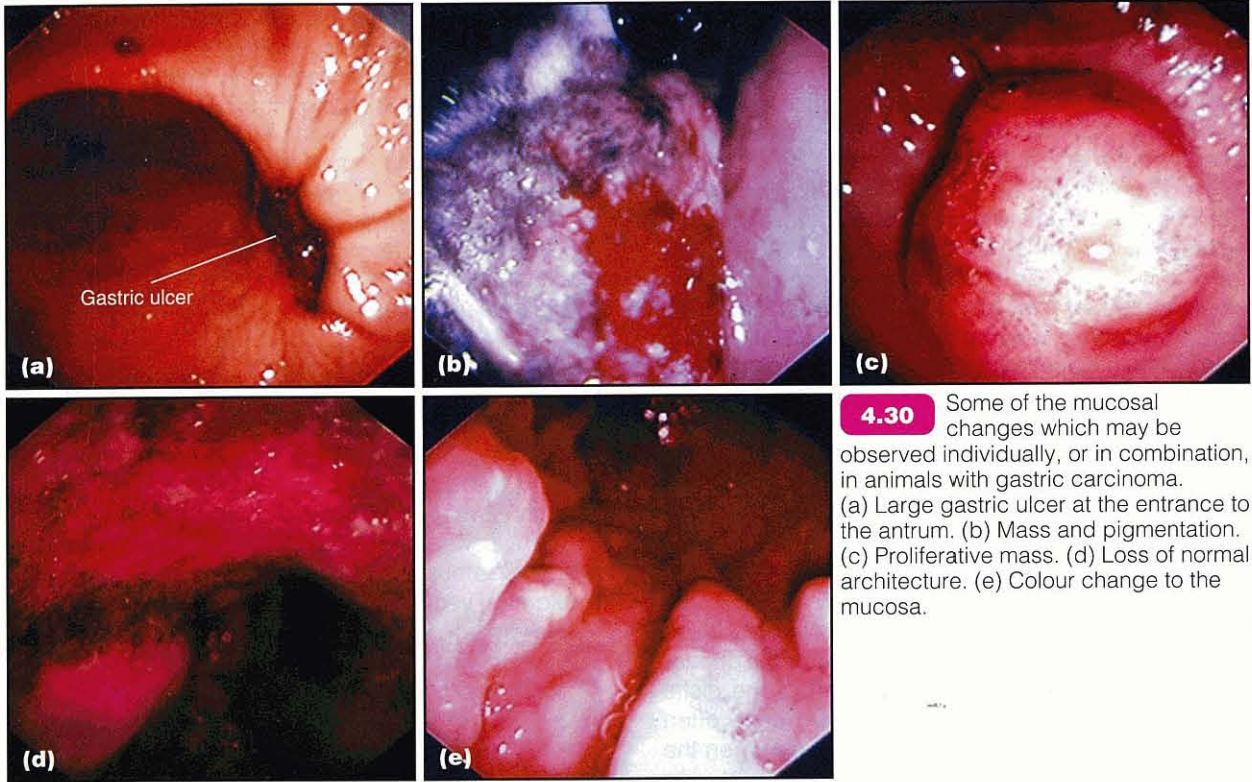
On gastroscopy, one of the following observations (Figure 4.30) is suspicious for neoplasia; three or more is highly suspicious:

- Ulceration
- An obvious mucosal mass
- Deep pigmentation of the mucosa
- Loss of normal gastric landmarks
- Mucosal colour change to a mottled purple instead of pink
- Rigidity of the gastric mucosa.

However, in all cases the observational diagnosis must be confirmed by biopsy and histopathological examination.

#### Biopsy

Where macroscopic lesions are detected during gastroscopy, multiple biopsy samples should be collected from the 'lesion' and the surrounding 'normal' tissue. If no macroscopic lesions have been observed, chronic inflammatory disease may still exist and biopsy samples should **always** be collected from all regions of the



stomach. When collecting biopsy samples the stomach should not be over-inflated as this stretches the mucosa and results in collection of very small samples. Ideally, the forceps should be advanced through the endoscope and applied perpendicular to the mucosa to ensure a good sample is collected (see Figure 4.13). At least four biopsy samples should be collected from the fundus, two from the body and two from the antral canal. The mucosa of the antrum is tough and can be difficult to biopsy. Where an ulcer is observed, biopsy samples should be collected from the periphery and not the centre of the lesion. This is because biopsying the centre of the ulcer crater may result in perforation, and is usually not diagnostic, harvesting only fibrous or necrotic tissue and some inflammatory cells. When neoplastic disease is suspected, repeated sampling from the same peripheral site may reveal neoplastic cells deeper in the lesion, while superficial layers contain only non-specific necrotic and inflammatory changes.

**Complications**

Gastroscopy is a relatively safe procedure and although problems may arise, they are fortunately rare. Over-inflation of the stomach is the commonest problem encountered. This will reduce venous return to the heart and exert pressure on the diaphragm, causing respiratory difficulty. Over-inflation hinders antral and pyloric intubation and also reduces the quality of the biopsy samples.

Haemorrhage following collection of biopsy samples is rarely significant. Where a significant bleed does occur, application of ice cold water through an endoscopic catheter will usually halt the bleeding. If this fails an epinephrine (adrenaline) solution (1:1000) may be applied in a similar manner.

Perforation of the stomach is very rare. It is most likely to occur if ulcers are biopsied or excessive pressure is applied to the insertion tube. It is more likely to occur when trying to intubate the duodenum.

**Treatment**

Gastroscopy can be used to remove gastric foreign bodies. The ability to carry out this procedure is dependent on the size and shape of the foreign body. It is also dependent on the type and size of retrieval forceps available. In some cases the problem is not grasping the foreign body but trying to get it through the closed cardia.

**Enteroscopy**


**Indications**

Enteroscopy is indicated in cases of chronic vomiting and diarrhoea. It is especially indicated where the patient also exhibits haematemesis, melaena, hypo-proteinaemia and weight loss thought to be of intestinal origin. Patients, especially cats, with small intestinal disease often present with chronic vomiting rather than chronic diarrhoea. In some cats recurring fur balls are associated with inflammatory bowel disease, thus indicating the need for enteroscopy. In all cases where the stomach is being examined, it is usual to examine the duodenum at the same time.

The investigation of chronic small intestinal disease initially involves faecal analysis, haematology, serum biochemistry profile, diagnostic imaging and GI function tests (see Chapters 1, 2, 3 and 20). The results of these procedures are used to provide evidence to suggest small intestinal disease and demonstrate the

need to collect biopsy samples. Biopsy samples can be collected by exploratory laparotomy or endoscopy. The latter is minimally invasive, safe and where diffuse disease exists, provides a diagnosis without recourse to surgery. In addition, patients with protein-losing enteropathies are poor surgical risks, often having delayed healing and poor immune status. Endoscopy provides the clinician with the safest method of obtaining a definitive diagnosis in these cases. However, it is important to emphasize that on some occasions endoscopic biopsy samples are not diagnostic and exploratory laparotomy may still be required to obtain full-thickness biopsy material.

Endoscopy has proved to be of considerable value in diagnosing small intestinal disease now that biopsy samples can be taken from the duodenum, jejunum and ileum. Most standard length gastroscopes will permit the duodenum to be visualized in all but the largest dogs. However, where a specialist enteroscope with an insertion tube longer than 1 metre is available, it is possible to visualize and biopsy the jejunum (Figure 4.31). Recent research has shown that similar morphological changes are usually observed in duodenum and ileum. However, visualization of the distal small intestine (ileum) can be achieved quite often during flexible colonoscopy, or alternatively when the endoscope reaches the ileocolic junction during colonoscopy, biopsy forceps may be blindly passed through the sphincter into the ileum.



**4.31** A flexible endoscope made with a 1.6 metre insertion tube, permitting the jejunum to be examined in dogs and cats. (Courtesy of Guide Dogs for the Blind)

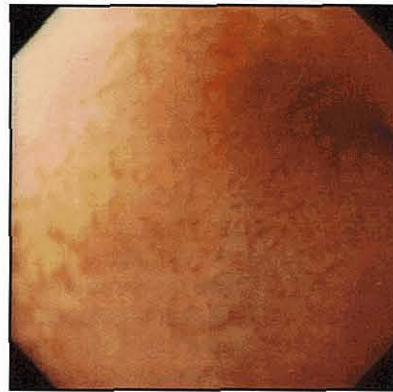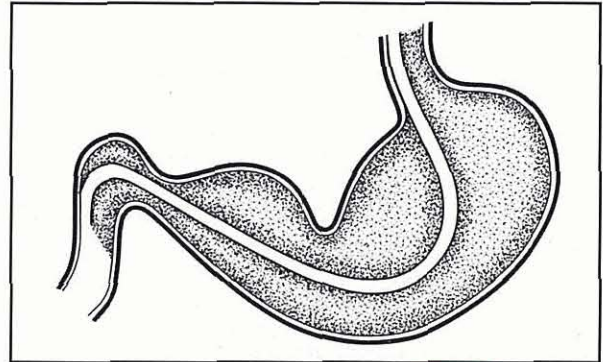
### Preparation

Preparation for enteroscopy is similar to that required for the examination of the oesophagus and stomach. If ileal biopsy samples are required then further preparation is required (see below).

### Procedure

1. Position the endoscope in the antrum, with the tip aligned with the pylorus in the centre of the field of view (see Figure 4.29).
2. Gently apply pressure to the insertion tube so that the tip lies against the pylorus.
3. Maintain the pressure until the tip is 'accepted' by the pylorus during the next antral contraction. 'Red out' occurs throughout this procedure, so intubation is not so much a visual, but a tactile process.

4. As the tip of the endoscope passes through the pylorus, the resistance will lessen and often a colour change from 'red out' to 'yellow out' may be observed, indicating the presence of bile in the duodenum.
5. Once in the duodenum, stop advancing the endoscope and inflate the lumen with air so that the mucosa can be visualized (Figure 4.32).



**4.32**

Normal duodenal mucosa has a 'velvet' appearance due to the presence of thousands of intestinal villi. (Diagram reproduced from Tams (1990) with permission from Elsevier.)

It is important to emphasize that duodenal intubation is one of the most difficult endoscopic procedures to carry out, especially where the pylorus is closed. In such cases the tip of the endoscope is often retroflexed back into the fundus by antral peristaltic contractions. Even experienced endoscopists can find intubation of the duodenum in some individuals impossible to achieve. It is therefore important not to persist in such cases as injury or perforation of the pylorus can occur. Undue force to try and enter the duodenum should never be used as this will certainly increase the risk of perforation. Occasionally in these patients, rotating the animal to a dorsal or a right lateral recumbency may facilitate success.

Once the descending loop of duodenum has been visualized it is normally relatively easy to push the endoscope along the intestine. Paradoxically, further movement along the duodenum can often be achieved by slightly withdrawing the insertion tube, thereby reducing the curvature of the insertion tube in the stomach. Only the descending loop of the duodenum can be reached using standard length endoscopes in average-sized dogs. With longer endoscopes (enteroscope) the ascending loop of duodenum and proximal jejunum can often be examined and sampled.

## Findings

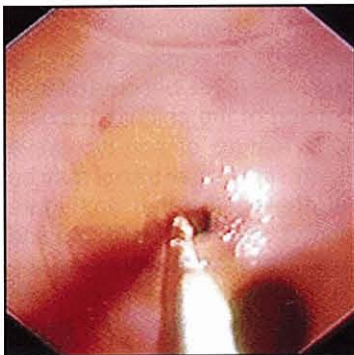
As with other regions, the duodenum should be carefully examined as the endoscope is advanced in order to ensure iatrogenic changes are not misdiagnosed as pathological disease. The villus structure of the duodenum gives the mucosa a 'velvet' appearance in the normal dog and cat. Lymphoid tissue is abundant in the duodenum and Peyer's patches will often be observed in dogs as flat pale circular-like depressions in the mucosa. The major and minor duodenal papillae may be observed as raised nipple-like structures.

## Biopsy

Duodenal ulceration is rare in the dog and cat, however inflammation is common. This may lead to friability of the mucosa, loss of the velvet appearance and occasional bleeding. However, it is important to note that many forms of small intestinal disease are not apparent macroscopically and can be detected only after histological examination of biopsy samples. Therefore, in all cases, multiple mucosal biopsy samples should be collected from different regions of the small intestine. Biopsy collection is not easy as it is difficult to get the biopsy forceps perpendicular to the mucosa. If the biopsy forceps are used parallel to the mucosa only the villus tips will be sampled, making histopathological examination less rewarding. Collection of representative samples of diagnostic quality may be facilitated by waiting for a duodenal contraction to occur in front of the forceps; as the lumen closes in front of the endoscope the forceps can be advanced on to the mucosa perpendicularly. Sample collection is also usually productive where the descending turns to form the ascending loop.

## Ileoscopy

This can only be performed following successful colonoscopy, as described in the next section. In order to visualize the ileocaecocolic junction, the small intestine and colon must have been thoroughly prepared. The ileocolic junction can be recognized next to the blind-ended sac, the caecum (Figure 4.33). It often has a button or mushroom-like appearance and appears darker red in colour. Although the sphincter is usually closed, it is not difficult to intubate.



**4.33** Biopsy of the ileum can be carried out via the colon.

1. Place the endoscope tip directly in front of the sphincter.
2. Advance the endoscope gently through the sphincter and into the ileum.

If the endoscope tip does not move into the ileum, biopsy collection may be carried out 'blind' after advancing the biopsy forceps through the ileocolic valve. This procedure may be repeated several times at different distances from the valve to ensure representative samples are obtained safely.

## Colonoscopy

### Indications

Colonoscopy is a common endoscopic procedure carried out in dogs and cats. There are several reasons for this:

- Colonic disease is common, especially in the dog
- The colon is very accessible for complete endoscopic examination
- Colonoscopy frequently provides a definitive diagnosis without recourse to surgery.

For these reasons, and because colonoscopy is a safe procedure, it has become the method of choice for investigating patients exhibiting classical signs of colonic disease (see Chapter 21). Radiography and contrast studies are rarely carried out in these patients as they are time-consuming and expensive. Even when an abnormality is detected biopsy collection is still required. Surgical collection of biopsy samples is rarely indicated, except where surgical excision of mass lesions is attempted in cases of suspected neoplastic disease.

Indications for colonoscopy include dyschezia, tenesmus, constipation or chronic diarrhoea containing mucus and/or fresh blood. These signs may be associated with underlying inflammatory, neoplastic or infectious disease.

Patients with suspected colonic disease should undergo a haematological and biochemical screen together with faecal culture, faecal flotation and examination for giardiasis. A rectal examination should always be carried out in order to rule out a rectal obstruction and to ensure that administration of enemas can be carried out safely.

### Preparation

The importance of correct patient preparation cannot be over-emphasized. Even when the colon has been thoroughly prepared using enemas, the ascending colon is difficult to evacuate and rapidly refills with ileal contents, making complete colonic examination difficult to achieve. For this reason the patient should be starved for 24 hours prior to colonoscopy and oral cleansing solutions should be administered on the afternoon before the procedure. These human oral cleansing solutions, containing polyethylene glycol as an osmotic laxative and electrolytes to prevent dehydration, are of considerable value in dogs and cats but ideal doses for their use have not been determined. Previous texts have suggested using bowel cleansing



solutions at approximately 20–30 ml/kg. Patients can rarely be coaxed to ingest such volumes and so the preparations usually need to be administered by gastric intubation. On the morning of the procedure the patient should receive two warm water enemas at up to 20 ml/kg, with the last being given one hour before the colonoscopy. The patient's tail should be bandaged to reduce soiling of the coat.

After the last enema has been administered, the patient should receive a suitable sedative and analgesic. The author has found a combination of acepromazine maleate at 0.05 mg/kg and buprenorphine at 0.01 mg/kg given intramuscularly to be the effective for dogs. This combination ensures patient compliance without the risk associated with general anaesthesia. When cats are to undergo colonoscopy, or if upper GI endoscopy is to be performed at the same time in dogs, a general anaesthetic is recommended.

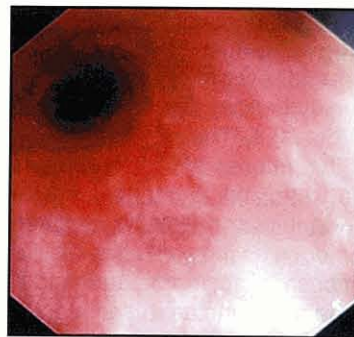
For flexible colonoscopy, the patient should be placed in left lateral recumbency. This ensures that any fluid in the transverse colon drains into the descending colon by gravity, enabling better visualization of the transverse and ascending colon. This position also allows easier passage of the endoscope through the colonic flexures. In contrast, rigid colonoscopy is usually performed with the patient in right lateral recumbency.

### Procedure

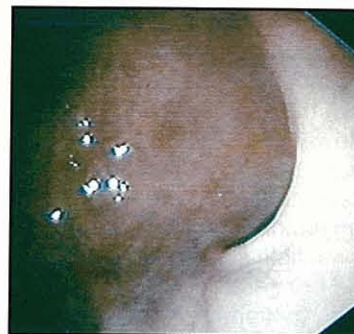1. Insert the endoscope gently through the anus and into the rectum.
2. Once in the rectum, inflate the lumen with air until the mucosa can be visualized. Pinching the anus aids inflation by preventing air leakage.
3. Advance the endoscope; it should be possible to see directly along the descending colon (Figure 4.34).
4. Advance the endoscope along the descending colon, observing the mucosa for evidence of pathological change. At the cranial end of the descending colon the first of two flexures will be observed (Figure 4.35). The splenic flexure separates the descending colon from the transverse colon. The transverse colon is much shorter than the descending colon and ends at the second flexure (the hepatic flexure), which separates the transverse and ascending colon. Sometimes movement round these flexures can be difficult, but significant resistance should not be encountered.
5. To enter the ascending colon, gently manipulate the endoscope forwards and backwards while inflating with some air. Redirection of the endoscope tip is sometimes necessary.

### Findings

The ascending colon is short and ends with a distinct opening into the caecum, next to which lies a raised button-like structure, which is the opening into the ileum (see Figure 4.33). The caecum can be routinely examined without difficulty but the ileum is sometimes difficult to enter. However, biopsy of the ileum with direct visualization rarely provides more diagnostic information than blind biopsy collection.



**4.34** View along the descending colon from the rectum.

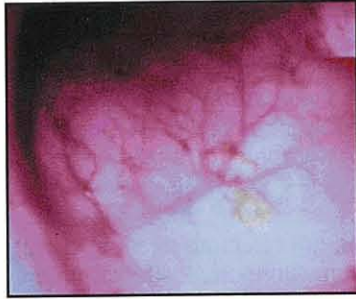

**4.35** The splenic flexure can be clearly seen, indicating the end of the descending colon and the start of the transverse colon.

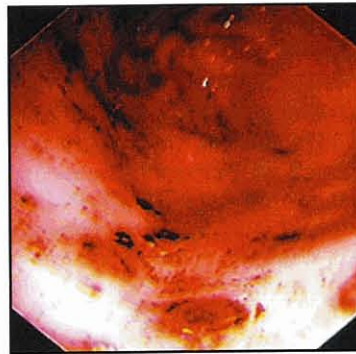
The entire length of the colonic mucosa should always be examined while advancing the endoscope. Once at the ileocaecocolic junction, the endoscope should be withdrawn slowly re-examining the mucosa and collecting biopsy samples. Only if a focal lesion is detected should biopsy samples be collected immediately. Biopsy samples should be collected from the actual lesion and surrounding 'normal' tissue, each being placed in separate suitably labelled containers. When no gross lesions are found samples should be collected from the ascending, transverse and descending colon. The majority of patients with colitis have diffuse disease involving the whole colon but occasionally more focal inflammation may exist.

Tenesmus is frequently associated with rectal lesions due to stricture, polyps, inflammation or tumours. Careful examination is required since lesions can be obscured by extensive mucosal folding. In addition to examining the mucosa on the initial passage of the endoscope, it is well worthwhile examining the mucosa carefully while removing the endoscope, keeping the lumen dilated with air. Sometimes lesions will be seen in this phase of the examination that were missed on initial examination, particularly at the anorectal junction.

In colitis the submucosal blood vessels, which are normally very prominent (Figure 4.36), become difficult to visualize due to thickening of the colonic mucosa. This is the most obvious feature of non-ulcerative colitis. In ulcerative colitis multiple small ulcers may be observed throughout the length of the mucosa (Figure 4.37). The mucosa in such cases is often friable and even gentle contact with the endoscope along the bowel wall will result in haemorrhage. Patients with eosinophilic and histiocytic colitis often have friable and ulcerated mucosae.



**4.36** In the normal dog or cat, colonic submucosal blood vessels can be easily seen. This is not an indication of inflammation.

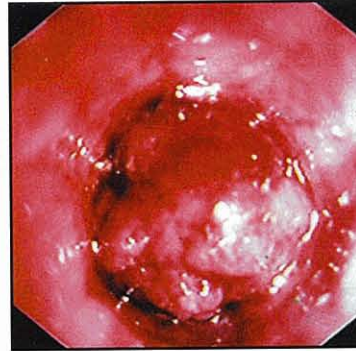

**4.37** Ulcerative colitis in the dog.

Whipworm colitis is rare in the UK but, when present, adult worms are readily seen on the mucosal surface. Whipworm larvae may be found on histological examination of biopsy samples since they invade the mucosa and induce a chronic inflammatory response. Granulomatous colitis is the least common of all the inflammatory disorders and often presents with a focal area of ulceration and bleeding in the ascending colon, rather than diffuse disease. Finally, care is required to distinguish artefactual damage to the rectal and colonic mucosa secondary to enema administration from true

lesions of colonic disease. The former should be restricted to the distal colon and rectum.

Tumours of the large bowel include rectal adenomas and polyps, which are usually space-occupying and are often traumatized and ulcerated by the passage of faeces (Figure 4.38). Adenocarcinomas may occur in the rectum or colon, grow aggressively into the lumen and frequently ulcerate, resulting in bleeding and dyschezia. Lymphosarcomas are more often diffuse and tend not to grow into the lumen of the bowel. They often appear macroscopically similar to non-ulcerative colitis and histopathological examination is required to make the distinction.



**4.38** Rectal adenoma obstructing the lumen of the rectum.

### References and further reading

- Brearley MJ, Cooper JE and Sullivan M (1991) *A Colour Atlas of Small Animal Endoscopy*. Wolfe Publishing, London
- Brockman D and Holt D (in preparation) *BSAVA Manual of Canine and Feline Head, Neck and Thoracic Surgery*. BSAVA Publications, Gloucester
- Simpson JW (2002) Inflammatory bowel disease: a brief review and results of recent clinical research. *UK Vet* 7, 53–60
- Strombeck DR and Guilford WG (1990) *Small Animal Gastroenterology, 2<sup>nd</sup> edn*. Stonegate Publishing, California
- Tams TR (1990) *Small Animal Endoscopy*. Mosby, Philadelphia

# 5a

## Gastrointestinal immunology

Michael J. Day

### Introduction

The gastrointestinal (GI) tract has the highest concentration of immunological tissue within the body, which is not surprising given the continual bombardment of the GI mucosal surface with antigenic material. The GI immune system is highly regulated and retains the ability to mount a robust immune response to invading pathogens (e.g. bacteria, viruses, protozoa, helminths) whilst selectively ignoring other classes of antigen that are of benefit to the host (e.g. commensal flora, food particles). This latter phenomenon is the classical example of a process known as mucosal (oral) tolerance.

A clear knowledge of the anatomy and function of the GI immune system is essential for understanding the pathogenesis and management options for the spectrum of immune-mediated diseases that affect the GI tract (e.g. inflammatory bowel disease, IBD; dietary hypersensitivity; small intestinal bacterial overgrowth, SIBO; antibiotic-responsive diarrhoea, ARD). Moreover, study of the delivery of antigen to the intestinal mucosa is an active area of immunological research that will lead to future development of oral vaccine strategies, or exploitation of the oral tolerance phenomenon to treat systemic immune-mediated (autoimmune or allergic) disease.

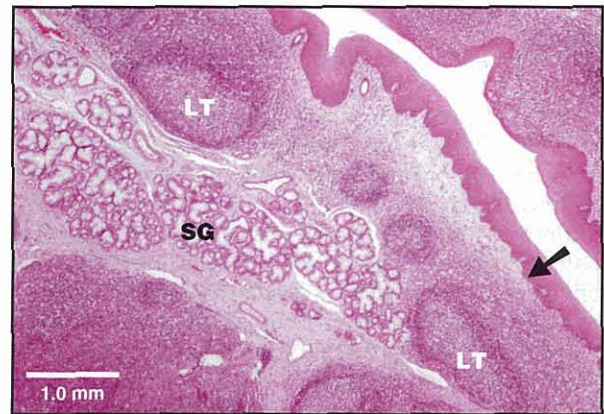Whilst we now have an increasing knowledge of the GI immune system of dogs and cats, there is little known about the immune system of the liver as it relates to normal immunological homeostasis, the immune response to hepatic insult, and the range of putative immune-mediated hepatopathies in these species.

### Anatomy of the GI immune system

#### Oral cavity

The oral cavity is a complex environment rich in resident microflora and subject to continual minor mucosal abrasion and exposure to foreign (food) antigen. As elsewhere in the body, there are regional examples of organized lymphoid tissue, best epitomized by the tonsils (Figure 5.1) together with scattered mucosal lymphoid tissue. Recent studies have characterized the latter tissue in the feline oral cavity and identified small subepithelial aggregates of T lymphocytes and antigen-presenting cells (APCs). The oral cavity is bathed in salivary secretion that is rich in antimicrobial substances, particularly immunoglobulin. The saliva of

both dogs and cats has a high concentration of IgA with less IgG and IgM. These immunoglobulins are primarily produced by local plasma cells (numerous IgA plasma cells are associated with salivary tissue) but some may leak from the serum. The mucosal surfaces of the oral cavity drain to the regional submandibular and retropharyngeal lymph nodes.

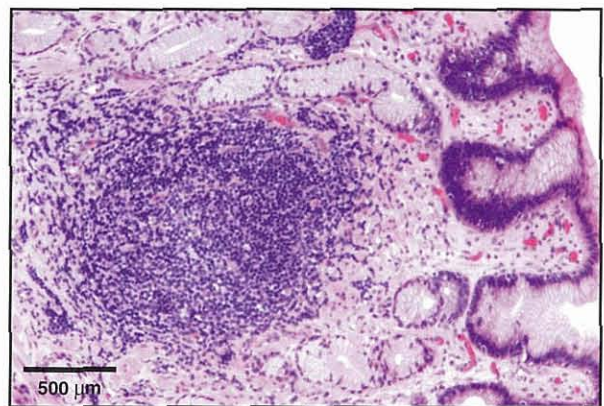


5.1

Section of a canine tonsil. Squamous epithelium (arrowed) covers the organized lymphoid tissue (LT) of the organ. The salivary gland (SG) is present deep to the lymphoid area.

#### Stomach

The acidic environment of the stomach has traditionally led to this area being considered sterile, and thus the gastric immune system has received little attention. The stomach mucosa has a diffuse scattering of isolated gastric lymphoid follicles (Figure 5.2) that are best



5.2

Section of canine gastric mucosa showing an unencapsulated lymphoid aggregate.

characterized in the dog. These are a normal constituent of the mucosa with both T and B lymphoid zones represented, and are present in greatest number in the fundic area. As elsewhere in the GI tract, a diffuse light scattering of mixed mononuclear cells (lymphocytes, plasma cells and macrophages) and occasional eosinophils are normal within the superficial lamina propria of the gastric mucosa. Afferent lymph from the gastric mucosa drains to the hepatic, splenic, gastric and pancreaticoduodenal lymph nodes.

In recent years, much research has focused upon the apparently commensal *Helicobacter* spp. that live associated with the gastric mucosa of both dogs and cats.

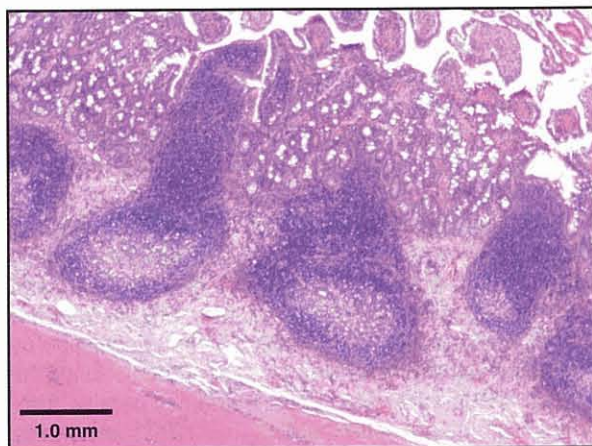
There is evidence that cats and dogs carrying gastric *Helicobacter* more commonly have mucosal inflammation and hyperplasia of the gastric lymphoid follicles.

### Small intestine

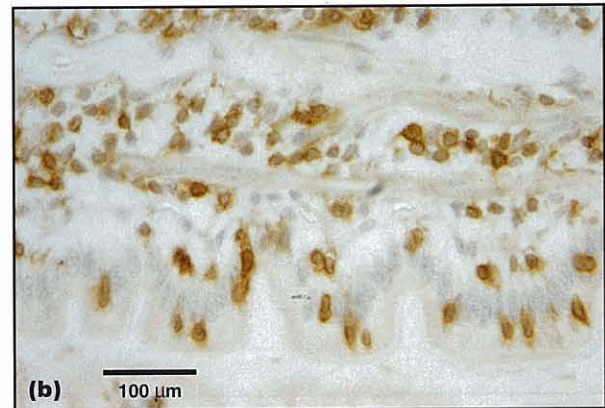
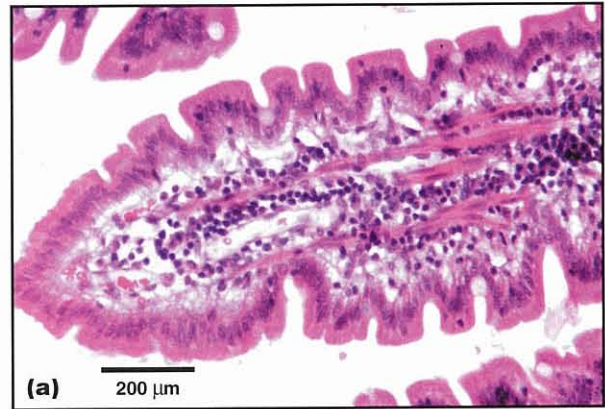The immune system of the small intestine is the best characterized part of the gut-associated lymphoid tissue (GALT) in both the dog and cat. As in other species, there are three specific immunological 'compartments' within the small intestine.

- The first compartment comprises the organized, unencapsulated, secondary lymphoid tissues represented by the Peyer's patches (Figure 5.3).
- The second compartment comprises diffuse lymphoid tissue scattered throughout the mucosal lamina propria (Figure 5.4a).
- The third compartment comprises the epithelial lining of the intestine (enterocytes) and is also considered immunologically active (Figure 5.4b).

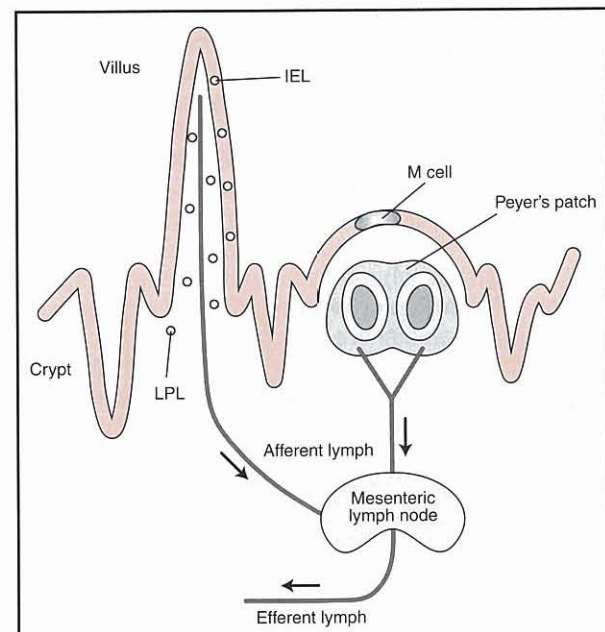
These sites are drained by the mesenteric lymph nodes, the efferent lymph from which in turn drains eventually into the vascular system (Figure 5.5). In the dog, the nature of the cellular content of both Peyer's patches and lamina propria varies between duodenum, jejunum and ileum. The small intestinal GALT is the most cited model of mucosal immunity, and the functional relationship of these anatomical compartments will be considered further below.



**5.3** Section of a Peyer's patch from a feline ileum. Note the extension of lymphoid tissue up into modified areas of 'dome'-shaped mucosa.



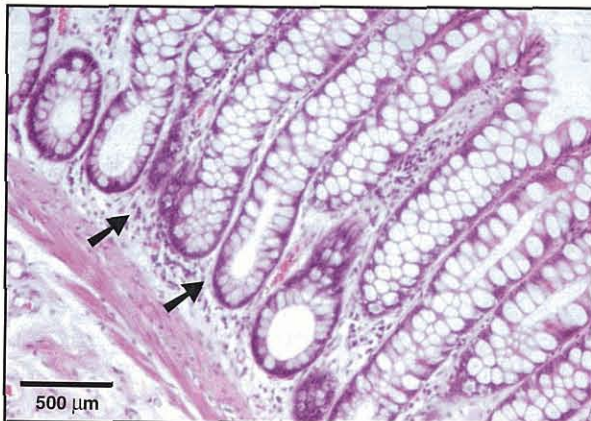**5.4** (a) Section of canine villus showing the enterocytes and underlying lamina propria, which contains a mixture of mononuclear cell types. (b) Section of canine villus immunohistochemically labelled to stain T lymphocytes (expressing the CD3 molecule) golden brown. Intraepithelial and lamina propria T cells are evident.



**5.5** Diagram showing the major compartments of the small intestinal GALT; the epithelium, lamina propria and Peyer's patch. Lymphoid cells activated by exposure to antigen in the Peyer's patch or lamina propria migrate in afferent lymph to mesenteric lymph nodes. IEL = intraepithelial lymphocyte; LPL = lamina propria lymphocyte.

### Large intestine

The caecum of dogs and cats is small, relative to that in herbivorous species, but is rich in organized lymphoid tissue that concentrates around the ileal ostium in the dog, and the caecal apex in the cat. The colon is also well supplied by GALT – present both as isolated colonic lymphoid aggregates with follicular and parafollicular zones, and as diffusely scattered lamina propria mononuclear cells (Figure 5.6). Similar structures provide immune defence to the recto-anal tissue, and in dogs there is a high concentration of lymphoid tissue at the recto-anal junction (the ‘anal tonsil’).

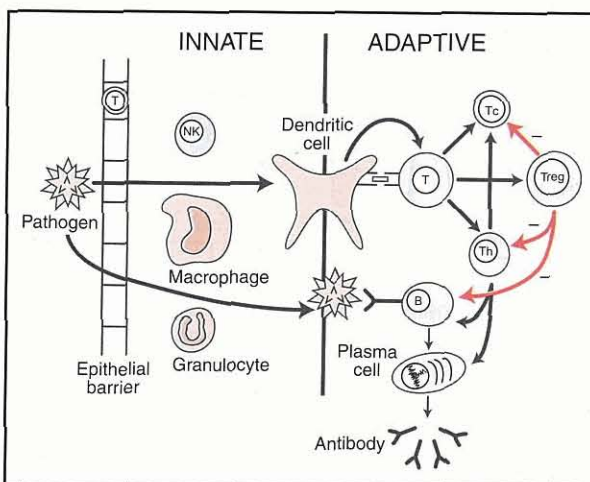


**5.6** Section of canine colonic mucosa. There are scattered mononuclear cells (arrowed) within the normal lamina propria.

### Basic immunology

An understanding of the GI immune system requires a background explanation of the basic immune response as it occurs in any part of the body (Figure 5.7).

The immune system has two broad divisions – innate and adaptive. Innate immunity is more primitive, probably evolutionarily older and is continually active at body surfaces providing the ‘first line’ of defence.



**5.7** The basic immune response. Foreign antigen first contacts the innate immune system and, after processing by a dendritic cell, there is subsequent activation of the T and B lymphocytes of the adaptive immune system. NK = natural killer cell; Tc = T cytotoxic cell; Th = T helper cell; Treg = T regulatory cell.

### Innate immune system

The innate immune system of the GI tract includes factors such as:

- The epithelial barrier with tight junctions, which in part mediates ‘immune exclusion’ of luminal antigen from the underlying lamina propria
- The presence of commensal microflora
- The peristaltic movement of the gut
- Secretions containing antimicrobial substances and ‘polyreactive’ immunoglobulins (IgA and IgM) able to bind with low specificity to a wide range of antigens and contribute to the effect of ‘immune exclusion’ of antigen
- The alternative and lectin pathways of complement activation
- Leucocytes, including lamina propria neutrophils, mast cells, macrophages, dendritic cells, natural killer (NK) cells and some subtypes of T lymphocyte. One particular form of T cell considered to be part of this innate immune system is the intraepithelial lymphocyte (IEL); a first line of contact with antigen passing through the epithelial barrier (see Figure 5.4). These IELs are particularly characterized by the expression of a T cell receptor (TCR) comprising  $\gamma$  and  $\delta$  chains (the  $\gamma\delta$  TCRs).

Although once considered simplistic, the innate immune system is now recognized to control the subsequent induction of the adaptive immune system and even the fine functional specificity of this adaptive immune response. The key cell that links the innate and adaptive immune systems is the dendritic APC.

### Adaptive immune system

The adaptive (or specific) immune system includes:

- The various populations of lymphocytes (B cells, T cells including T helper, T cytotoxic and T regulatory or ‘suppressor’ cells)
- The antibody-secreting plasma cells
- High specificity antibodies of the IgG, IgM, IgA or IgE classes
- Molecules of the classical pathway of the complement system
- The cytokines (interleukins, monokines), which mediate ‘communication’ between immune cells
- The chemokines (chemotactic cytokines), which direct the movement of immune cells within tissue.

The first stage of a generic immune response involves the foreign antigen being taken up (generally by phagocytosis) by an APC, primarily dendritic cells and macrophages. The APC translocates antigen from the site of exposure to the regional lymphoid tissue by migration within the afferent lymph. Additionally, the foreign antigen is broken down into small peptide fragments within the cytoplasm of the APC, and these fragments are re-expressed (‘presented’) on the surface of the cell in association with class I or class II molecules of the major histocompatibility complex (MHC).

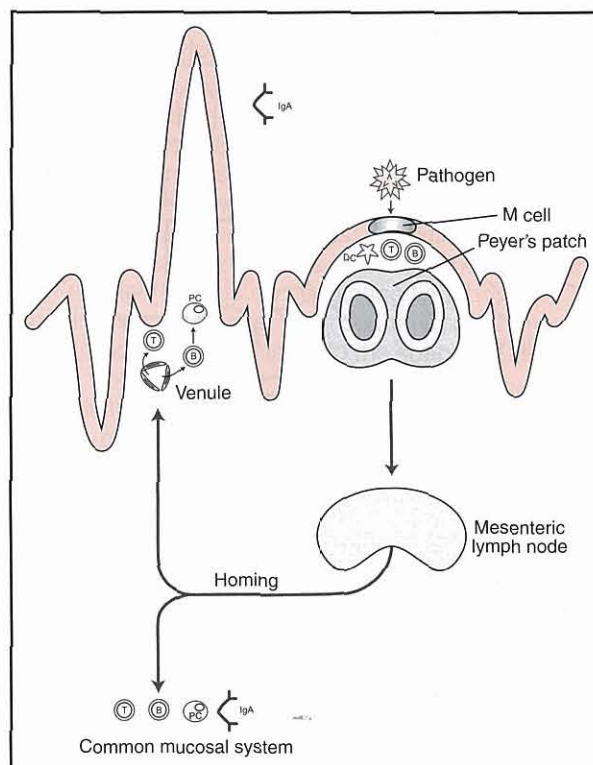
Within the lymphoid tissue, the antigenic peptide is recognized by a small number of T helper lymphocytes through interaction of the antigen-specific T cell receptor with the MHC-peptide complex. In the presence of other surface molecular interactions and cytokine signalling, the T cells become activated and migrate from the T cell zone (e.g. the lymph node paracortex) to the B cell follicles. Here the T helper cells are involved in activation of antigen-specific B lymphocytes by 'co-stimulating' B cells that have bound the same antigen via surface membrane immunoglobulins (the B cell receptor, BCR).

The consequence of these activation events is the division (clonal proliferation) of the antigen-relevant T and B cells within the lymphoid tissue. These numerous activated lymphocytes are then exported to the bloodstream where they 'recirculate' until they reach the vascular supply of the tissue where the antigen was originally encountered. Here, the antigen-specific lymphocytes selectively egress from the circulation to the tissue, by virtue of the interaction of specific molecules expressed by the lymphocytes and the local vascular endothelium.

The ensuing 'effector phase' of the immune response results in antigen elimination by mechanisms such as antibody production (humoral immunity) for opsonization and phagocytosis, or complement-mediated lysis or cytotoxicity of target cells bearing the antigen (cell-mediated immunity, CMI) mediated by cytotoxic T cells. At the conclusion of the effector phase, the large numbers of antigen-specific cells must be controlled before they cause damage to normal tissue. This involves the populations of T regulatory (suppressor) cells, of which there are several types now recognized. The antigen-activated lymphocyte population is never totally eliminated, as a small group of memory T and B cells will be retained to mount the more potent 'secondary immune response' on re-exposure to antigen.

## GI immune responses

GI immune responses are best exemplified by the response of the small intestinal mucosa to antigen (Figure 5.8). A wide range of pathogens can potentially infect the small intestine and will induce an immune response that in many cases will be protective. In general terms, antigen derived from the pathogen is first taken up by the GALT. It is believed that the most important route of uptake of pathogen-derived antigen is via the microfold ('M') cells within the modified dome epithelium that overlies the Peyer's patch. These M cells translocate antigen to the waiting population of APCs, and T and B cells within the subepithelial dome, initiating an immune response either in the Peyer's patch itself or within the draining mesenteric lymph node. As described above, antigen-activated T lymphocytes will migrate ('home') back to the GI mucosa from the blood, via the expression of molecules (particularly MAdCAM-1) on the vascular endothelium and (particularly  $\alpha_4\beta_7$ ) on the activated lymphocytes. Similar recirculation occurs for antigen-specific B



### 5.8

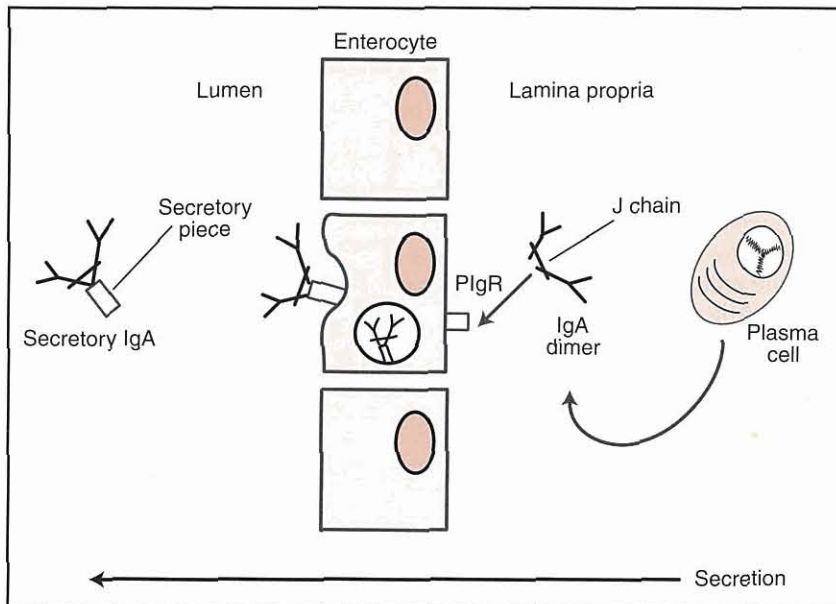
Response of the GALT to a pathogenic organism. Pathogen-derived antigen most likely enters the Peyer's patch via the M cell. Antigen-specific T and B lymphocytes are activated within the patch or the mesenteric lymph node and must circulate through the bloodstream to enter the intestinal lamina propria to mount the 'effector phase' of the immune response. Some activated lymphocytes enter other mucosal tissues as part of the 'common mucosal' immune system. DC = dendritic cell; PC = plasma cell.

lymphocytes. Some gut-activated lymphocytes may also leave the circulation at other mucosal sites (e.g. respiratory tract, mammary gland, ocular, urogenital) as part of the 'common mucosal system'.

The nature of the effector immune response will be determined by the antigen but may primarily involve:

- IgA production and secretion across the epithelium into the gut lumen (for example in response to some bacterial infections). IgA may also bind antigens within the lamina propria or within enterocytes, whilst undergoing transcytosis through the cell (immune elimination)
- An IgE mast cell and eosinophil dominated type I hypersensitivity response (in response to helminth parasites). This is a classical 'type 2' immune response that is controlled by a population of T helper 2 (Th2) lymphocytes
- A cell-mediated T cell cytotoxic and cytokine (e.g.  $\text{IFN}\gamma$ ) response to viral infection. This is a classical 'type 1' immune response that is controlled by a population of T helper 1 (Th1) lymphocytes.

The secretion of IgA is fundamental to the GI immune response (Figure 5.9). IgA is produced by intestinal lamina propria plasma cells as a dimer of two IgA molecules with a joining chain. The IgA dimer is



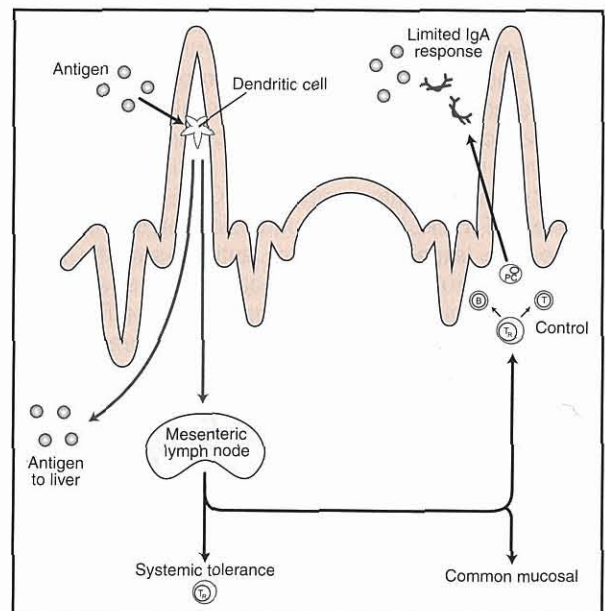
**5.9** Secretion of IgA across the epithelial barrier. IgA dimers (two IgA monomers linked by the J chain) are secreted by a lamina propria plasma cell. The dimer binds to the polymeric Ig receptor (pIgR) on the basal surface of an enterocyte and this complex is internalized by the cell. The complex passes through the cell cytoplasm to become re-expressed on the luminal surface. The dimer is released, carrying a small portion of the pIgR as the 'secretory piece' that protects it from proteolysis within the intestinal lumen.

bound by the polymeric immunoglobulin receptor (pIgR) expressed on the basal surface of the enterocyte, internalized and transcytosed to the luminal surface. Here the molecule is released, carrying with it a portion of the pIgR that becomes the protective 'secretory piece' that wraps around the IgA dimer and prevents proteolysis in the luminal environment.

**Oral tolerance**

Whilst the generation of an active immune response to pathogens is not surprising, the more striking feature of the GI immune system is the ability to selectively recognize and ignore non-pathogenic antigens (e.g. commensal bacteria and food particles). A range of mechanisms is thought to underlie this phenomenon of 'oral tolerance' (Figure 5.10). Oral tolerance was first recognized experimentally, when laboratory rodents were fed an antigen and subsequently failed to respond immunologically to the same antigen injected parenterally. The mechanisms of oral tolerance have been largely described using such rodent models, but the phenomenon has also been demonstrated in the dog and cat.

Oral tolerance is regarded as being an 'active' immunological process, rather than the gut simply ignoring these classes of antigen and failing to respond to them. It is believed that such antigens may preferentially enter the lamina propria compartment through the enterocytes or lamina propria dendritic cells that extend cytoplasmic processes through the epithelial tight junctions (as opposed to via M cells and Peyer's patches). Here, they are presented (by either dendritic cells or enterocytes, or both) to activate regulatory populations of T cells, in particular T regulatory cells characterized by dominant production of the regulatory cytokine interleukin 10 (IL-10) or T helper 3 (Th3) cells that predominantly express transforming growth factor beta (TGFβ). These regulatory T cells may mediate local unresponsiveness and may, in addition, travel to the systemic immune system to mediate the systemic unresponsiveness that characterises experimental oral tolerance. The ability to induce



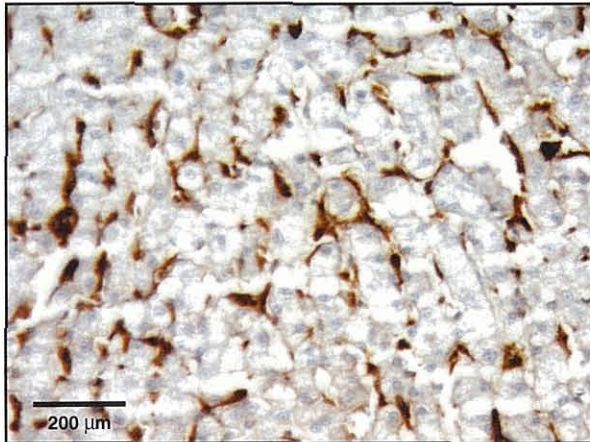
**5.10** Mechanisms of oral tolerance. Antigens from food or endogenous microflora enter the lamina propria and activate populations of regulatory T lymphocytes that prevent a full-scale immune response being mounted. These regulatory cells may also act systemically to prevent reactions to the same antigens encountered parenterally. PC = plasma cell; T<sub>R</sub> = T regulatory cell.

systemic immune unresponsiveness by feeding antigen (or delivery of antigen via other mucosal routes) is an active area of current research as a means of treating inappropriate immune reactivity such as occurs in autoimmune or allergic diseases. Of greater immediate relevance to companion animals, the pathogenesis of the spectrum of IBD is thought to involve a failure of normal tolerance to endogenous bacterial microflora, and dietary hypersensitivity clearly involves failure of immunological tolerance to normal dietary constituents. Novel therapies for these disorders involve blocking the immune pathways described above.

**Liver immunology**

Relative to the GI tract, there has been little study of the hepatic immune system in companion animals, so most of our understanding is based upon extrapolation from other species. The normal liver is endowed with a large population of mobile sinusoidal Kupffer cells that are actively phagocytic, express MHC class II (Figure 5.11), secrete cytokines (e.g. IL-6 and tumour necrosis factor alpha (TNF $\alpha$ ), which stimulate production of acute phase proteins) and act as APCs. Macrophages and dendritic cells may also be found within the portal triad. The liver has a resident population of lymphoid cells, including portal and sinusoidal T cells, and intraepithelial T cells within the bile duct epithelium. The T cell population is enriched for CD8<sup>+</sup> and  $\gamma\delta$ TCR<sup>+</sup> cells, and a significant number of NK cells are also present. B lymphocytes are found in small numbers in the portal areas.

The population of mesenchymal cells within the space of Disse (Ito cells, stellate cells or hepatic lipocytes) produce collagen, collagenases, collagenase



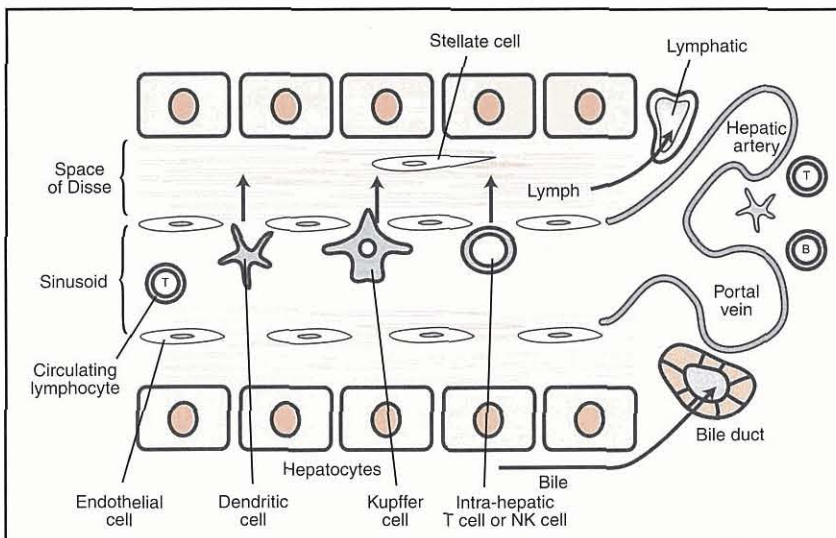
**5.11** Section of liver labelled immunohistochemically to show expression of the class II molecules of the major histocompatibility complex by Kupffer cells and dendritic cells (stained brown) within sinusoids and the space of Disse.

inhibitors and a range of cytokines and chemokines that recruit monocytes and lymphocytes. Hepatic sinusoids are lined by a unique population of liver sinusoidal endothelial cells (LSECs) which have gaps between each cell, are fenestrated, lack a basement membrane and can present antigen. There is therefore ready movement of molecules from the sinusoidal blood into the space of Disse (Figure 5.12). These cells constitutively express adhesion molecules that can engage ligands on circulating lymphocytes. Circulating lymphocytes and dendritic cells may be chemotactically attracted into the space of Disse and move from there into the portal lymphatic vessels. The biliary epithelial cells may also be immunologically active, can express MHC class II and act as APCs akin to enterocytes.

Bile is extremely rich in IgA in both dogs and cats, but little is known of the method and significance of secretion of biliary IgA in these species. In other species (e.g. rodents) some biliary IgA is produced locally, but most is produced in the intestinal mucosa, absorbed into the vascular circulation and transferred from blood to bile by hepatocytes following binding of the IgA to hepatocyte pIgR. This is a minor mechanism in humans where there is very low expression of hepatic pIgR.

In addition to having the capacity to mount an active immune response, the liver is also a major site for induction of immunological tolerance to a variety of antigens, including food-derived antigens that enter the liver via the portal circulation. The LSECs may be important in presenting such antigen to hepatic lymphoid populations in the initiation of this tolerance. The tolerogenic environment is enhanced by the production of the regulatory cytokines IL-10 and TGF $\beta$  by Kupffer cells, sinusoidal endothelium and Ito cells. This 'default' state of hepatic immunological tolerance may underlie a range of phenomena including:

- Long-term maintenance of liver allografts
- Ready establishment of tumour metastases in the liver
- Persistence of some hepatic infections.



**5.12** Hepatic immune system. A range of antigen-presenting cells (APCs) and lymphocytes migrate from the sinusoidal blood to the space of Disse. Other resident immune cells are found within the portal areas of the liver.



**References and further reading**

---

- Crispe IN (2003) Hepatic T cells and liver tolerance. *Nature Reviews Immunology* **3**, 51–62
- Day MJ (1998) Immunohistochemical characterisation of the lesions of feline progressive lymphocytic cholangitis/cholangiohepatitis. *Journal of Comparative Pathology* **119**, 135–147
- German A, Bland PW, Hall EJ and Day MJ (1998) Expression of major histocompatibility complex class II antigens in the canine intestine. *Veterinary Immunology and Immunopathology* **61**, 171–180
- German AJ, Hall EJ and Day MJ (1999) Analysis of leucocyte subsets in the canine intestine. *Journal of Comparative Pathology* **120**, 129–145
- German AJ, Hall EJ and Day MJ (2000) Relative deficiency in IgA production by duodenal explants from German shepherd dogs with small intestinal disease. *Veterinary Immunology and Immunopathology* **76**, 25–43
- German AJ, Hall EJ and Day MJ (2003) Chronic intestinal inflammation and intestinal disease in dogs. *Journal of Veterinary Internal Medicine* **17**, 8–20
- German AJ, Hall EJ, Moore PF, Ringler DJ, Newman W and Day MJ (1999) Analysis of the distribution of lymphocytes expressing  $\alpha\beta$  and  $\gamma\delta$  T cell receptors and expression of mucosal addressin cell adhesion molecule-1 in the canine intestine. *Journal of Comparative Pathology* **121**, 249–263
- Harley R, Gruffydd-Jones TJ and Day MJ (2003) Salivary and serum immunoglobulin levels in cats with chronic gingivostomatitis. *Veterinary Record* **152**, 125–129
- Harley R, Gruffydd-Jones TJ and Day MJ (2003) Characterisation of immune cell populations in oral mucosal tissue of healthy adult cats. *Journal of Comparative Pathology* **128**, 146–155
- Kita H, Mackay IR, van de Water J and Gershwin ME (2001) The lymphoid liver: considerations on pathways to autoimmune injury. *Gastroenterology* **120**, 1485–1501
- Knolle PA and Limmer A (2001) Neighborhood politics: the immunoregulatory function of organ-resident liver endothelial cells. *Trends in Immunology* **22**, 432–437
- Kolbjørnsen O, Press CMcL, Moore PF and Landsverk T (1995) Lymphoid follicles in the gastric mucosa of dogs. Distribution and lymphocyte phenotypes. *Veterinary Immunology and Immunopathology* **40**, 299–312
- Lamb ME and Phillips-Quagliata JM (2002) Origin and homing of intestinal IgA antibody-secreting cells. *Journal of Experimental Medicine* **195**, F5–F8
- Lau AH and Thomson AW (2003) Dendritic cells and immune regulation in the liver. *Gut* **52**, 307–314
- Mowat AM (2003) Anatomical basis of tolerance and immunity to intestinal antigens. *Nature Reviews Immunology* **3**, 331–341
- van Egmond M, Damen CA, van Spruiel AB, Vidarsson G, van Garderen E and van de Winkel JGJ (2001) IgA and the IgA receptor. *Trends in Immunology* **22**, 205–211
- Waly N, Gruffydd-Jones TJ, Stokes CR and Day MJ (2001) The distribution of leucocyte subsets in the small intestine of normal cats. *Journal of Comparative Pathology* **124**, 172–182
- Weiner HL (1997) Oral tolerance: immune mechanisms and treatment of autoimmune diseases. *Trends in Immunology* **18**, 335–343
-

# Biopsy: sample collection

John M. Williams

## Gastrointestinal biopsy

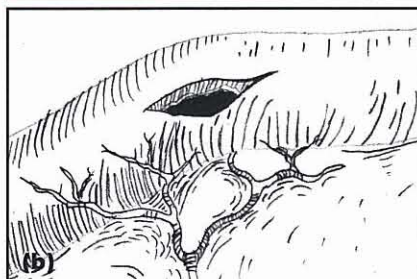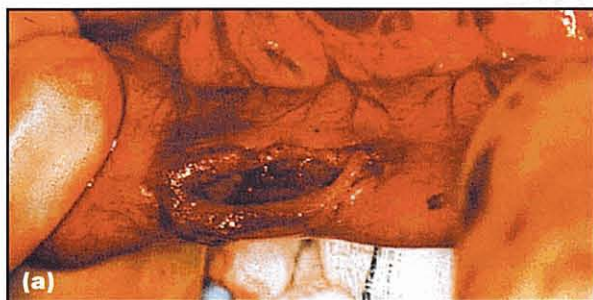Indications for biopsy are discussed elsewhere in the Manual.

### Pre-biopsy considerations

The collection of gastrointestinal (GI) biopsy samples is an elective abdominal procedure, which involves entering a viscus and can be classified as either clean or clean/contaminated. Due to the risk of postoperative infection, antibiotics should be given intravenously 30–60 minutes prior to surgery to ensure maximal tissue concentration at the time of surgery. Systemic antibiotics prevent bacterial multiplication for up to three hours with a maximal effect at around one hour. As the risk is of the order of 5% then either clavulanic acid potentiated amoxicillin or a second generation cephalosporin should be considered.

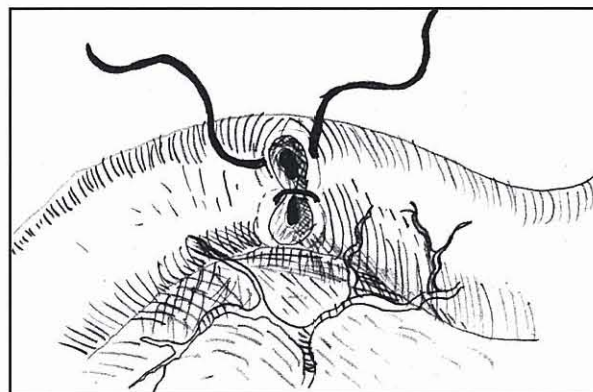
### Biopsy technique

Following exteriorization and packing off the selected portion of intestine, the contents are milked away from the proposed incision site; atraumatic bowel clamps may be applied to isolate the area but are not essential. The antimesenteric border is selected and, using a scalpel blade, a full-thickness longitudinal incision is made (Figure 5.13). The longitudinal enterotomy is ideal for obtaining elliptical biopsy samples; where there is concern over luminal narrowing, transverse closure can be performed (Figure 5.14).



5.13

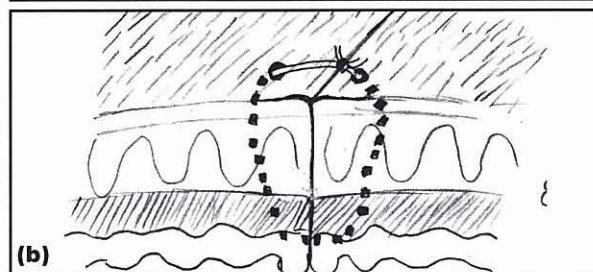
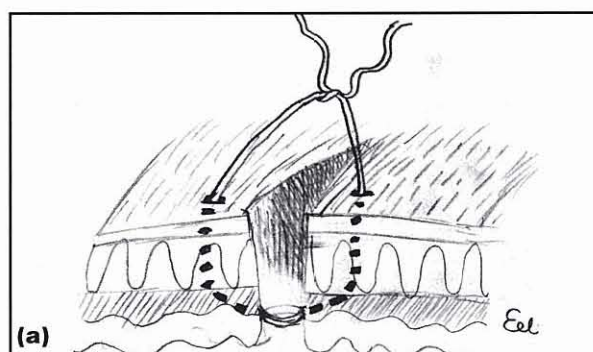
Longitudinal antimesenteric biopsy.



5.14

Diagrammatic representation of a transverse closure, used to minimize loss of luminal diameter.

For optimal healing by first intention, accurate apposition of the wound edges is needed. This requires proper alignment of the submucosa so that there is approximation of blood vessels. Such direct apposition promotes rapid re-epithelialization and deposition of well vascularized collagen and minimizes the risk of reducing the bowel lumen diameter. It is critical with appositional suturing to pass the suture material through the submucosa (Figure 5.15), the collagen-containing



5.15

Diagrammatic representation of suture material passing through submucosa.

layer of strength within the intestinal tract. The suture material needs to be 2 Metric monofilament for the stomach, with 1.5 Metric used for the intestine. A swaged-on taper point needle is preferred.

A synthetic monofilament absorbable suture is preferred. Poliglecaprone 25 is absorbed by hydrolysis, produces minimal friction and drag as it passes through tissue and has minimal memory, which allows snug safe knots to be produced. Chromic catgut is best avoided in GI tract surgery as there is always an inflammatory response, more so in cats than dogs, which can lead to fibrosis and marked intestinal narrowing.

The selection of suture pattern and material is very much an individual choice but one- or two-layer appositional suturing is the most logical. The pattern may be simple interrupted, an interrupted crushing suture, or simple continuous; if a two-layer closure is selected, the inner layer is the mucosa and submucosa while the outer layer is the muscularis and serosa. Two-layer closure is usually reserved for the stomach as single layer closure is adequate for the intestines.

### The colon

The large intestine poses a particular problem to the surgeon because healing tends to be slower. This is due in part to the poorer vascular supply to this area and the greater potential risk of contamination from bacteria. Bowel preparation (i.e. oral antibiotics, multiple enemas) is not necessary, particularly as enemas can increase the risk of peritoneal spillage by producing a liquid slurry within the colon, which readily leaks. During the early stages of the healing process in the colon, it is believed that collagen lysis greatly exceeds synthesis, though recent molecular studies have questioned this. Care must be taken in apposing the tissue and a 1.5–2 Metric synthetic monofilament absorbable suture should be used e.g. polydioxanone, monofilament Glycomer 631 or poliglecaprone 25. Vascular supply to the area should be augmented by overlying the wound with omentum.

### Endoscopic biopsy

Endoscopy may be used to harvest mucosal biopsy samples from the stomach, duodenum and colon. The technique is discussed in Chapter 4.

### Hepatic biopsy

Indications for biopsy are discussed in Chapter 24.

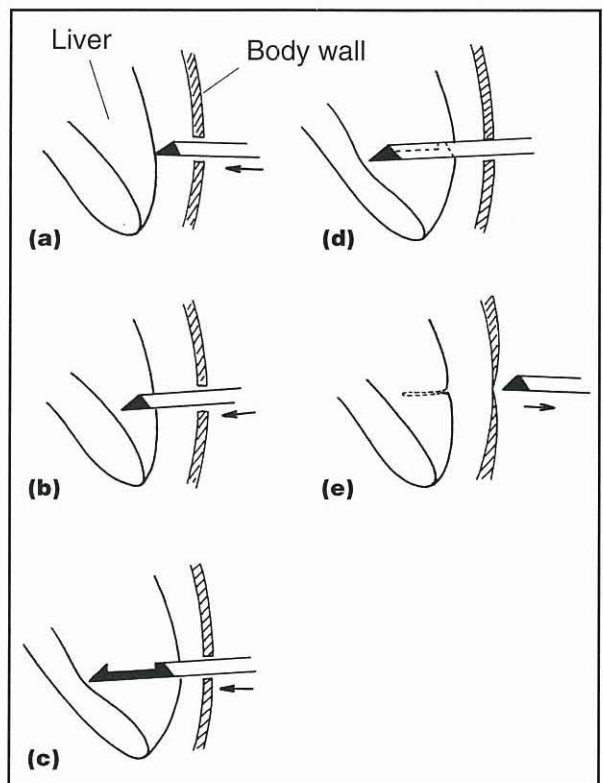
### Pre-biopsy considerations

Severe haemorrhage is a potential consequence of hepatic biopsy in small animals but it is rare; it is only likely if there is a significantly prolonged bleeding time or concurrent thrombocytopenia (usually when the patient has disseminated intravascular coagulation, DIC). In animals with severe hepatocellular damage, or a suspected complete extra-hepatic bile duct obstruction, a coagulation profile should be obtained preoperatively. It is now recognized that in patients with only mild coagulation abnormalities post-operative haemorrhage is rare. If animals are severely


hypoalbuminaemic as a consequence of liver disease, wound healing may be impaired and such patients should be given a pre-biopsy plasma transfusion regardless of the surgical technique employed.

### Percutaneous ultrasound-guided biopsy

The competent ultrasonographer can identify focal hepatic lesions, such as neoplasia, cysts or abscesses, and identify generalized changes in the hepatic parenchyma. This allows for accurate guided needle or core biopsy of from solid lesions (Figure 5.16). The advent of 'one-handed' biopsy instruments has made this easier (Figure 5.17). Cysts and abscesses should not be biopsied percutaneously.



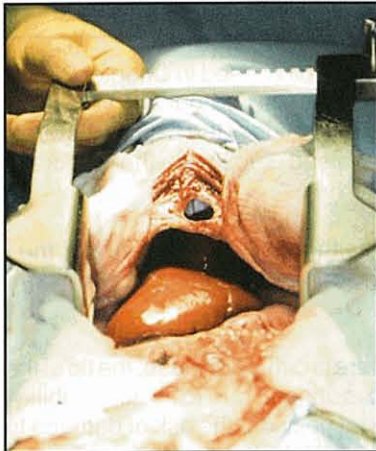
5.16 Percutaneous ultrasound-guided core biopsy technique.



5.17 Core biopsy instrument.

### Surgical biopsy

This biopsy technique has the advantage of allowing exploration of the abdomen and specific areas of the liver (Figure 5.18). The disadvantage is that a general anaesthetic and an invasive surgical procedure are required. It is important to consider the role of the liver in metabolizing sedative and induction agents when choosing an anaesthetic protocol.

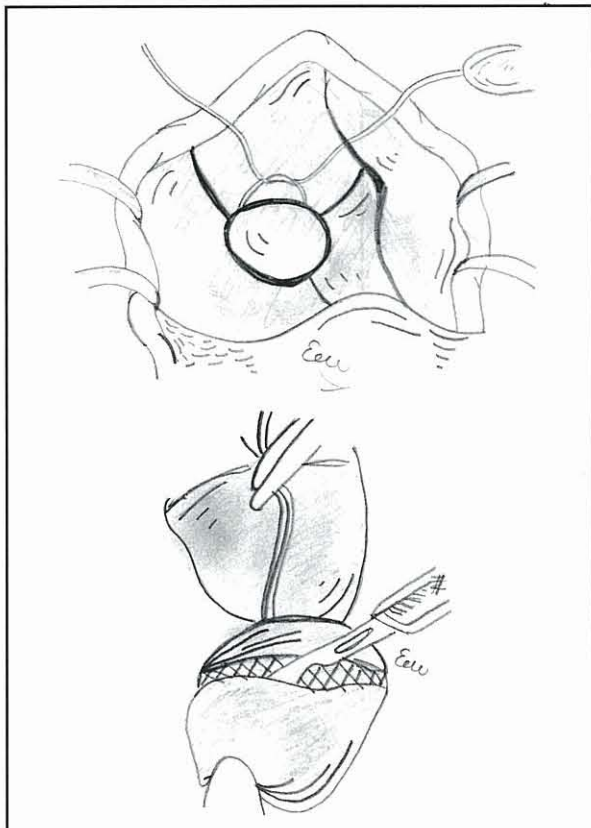


**5.18** Liver at laparotomy.

Bleeding from the biopsy site can be identified and controlled. If generalized hepatic disease is present, the sample can be taken from the most accessible site. With focal disease the entire liver should be palpated carefully for the presence of intraparenchymal nodules or cavities.

**Guillotine ligature technique**

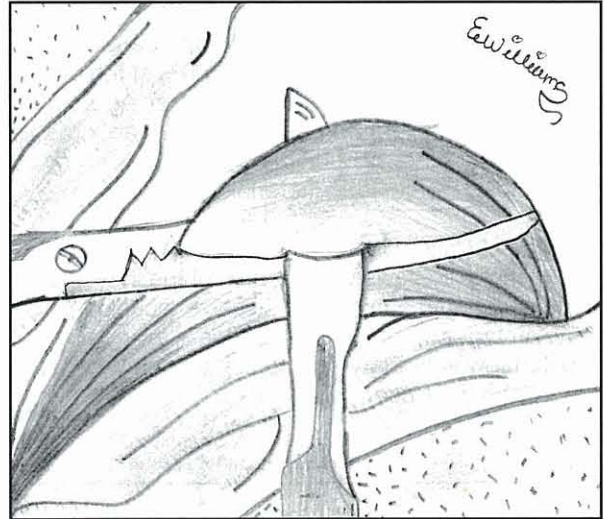
Marginal biopsy samples using ligatures are easy to obtain. A loop of a synthetic absorbable ligature is passed over an easily accessible edge of liver lobe and the parenchyma crushed as the ligature is tightened, thereby ligating vessels and biliary ducts (Figure 5.19). The sample is removed by amputating approximately 5 mm distal to the ligature. If there is any haemorrhage, an absorbable haemostatic material can be applied or the omentum placed over the site.



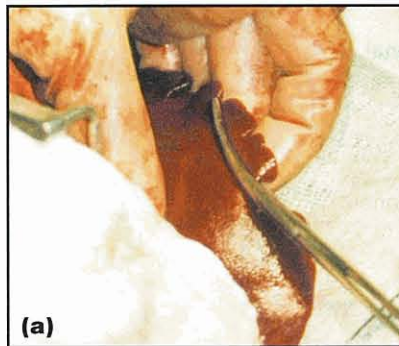**5.19** Guillotine ligature technique for liver biopsy.

**Forceps technique**

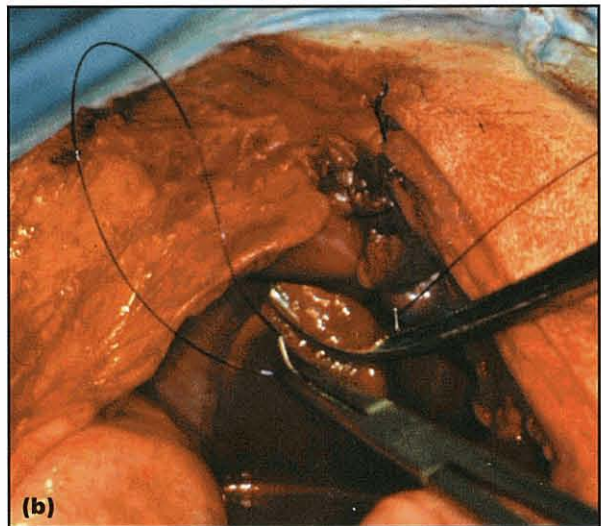
A pair of haemostatic forceps is placed across the tip of a liver lobe to crush the parenchyma. Tissue distal to the forceps is excised with a scalpel. Absorbable mattress sutures may be placed proximal to the forceps if required to control haemorrhage (Figures 5.20 and 5.21).



**5.20** Forceps technique for liver biopsy.



**5.21** (a) Forceps technique at surgery. (b) Mattress suture passed through parenchyma.



**'Skin punch' biopsy**

Since the forceps technique is relatively straightforward, a 'skin punch' technique (Figure 5.22) is rarely required. Its use is generally limited to focal



5.22 Skin or 'Keys' punch.

lesions on the ventral liver surface and care must be taken not to penetrate deeper than 50% of the parenchyma. The resulting defect can either be sutured with a mattress suture of a synthetic absorbable suture material, or be plugged with omentum or an absorbable haemostatic material.

### Laparoscopy

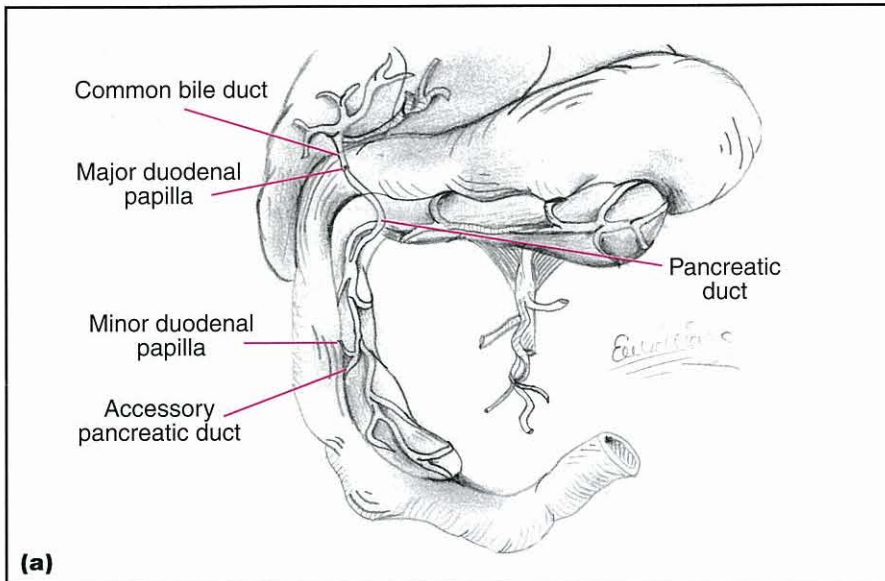
This technique allows visualization of the liver and for focal biopsy with a minimally invasive technique. The disadvantages currently are expense of the equipment and that few veterinary surgeons have the necessary experience in its use.

### Pancreatic biopsy

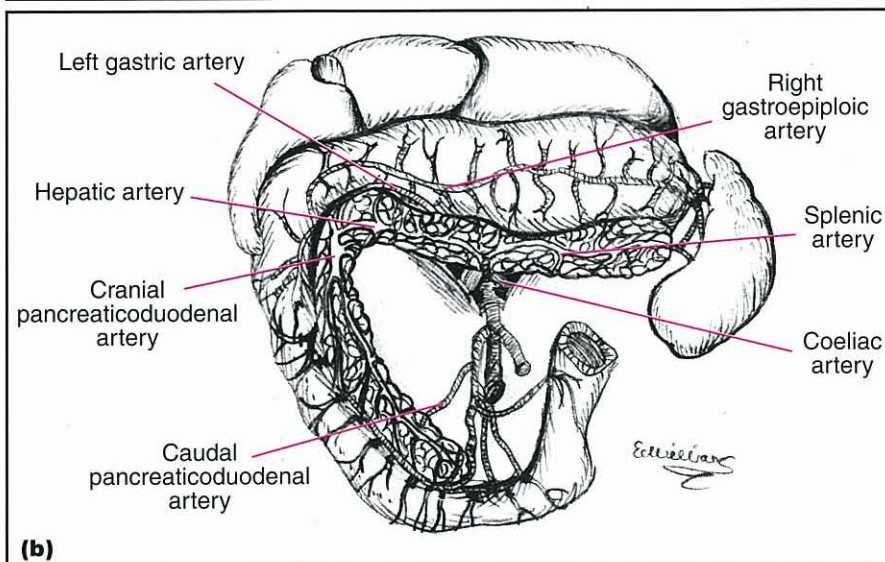
Indications for biopsy are discussed in Chapter 23. If a pancreatic biopsy is to be carried out the veterinary surgeon must know the location of the pancreatic ducts and understand the blood supply to the pancreas (Figure 5.23).

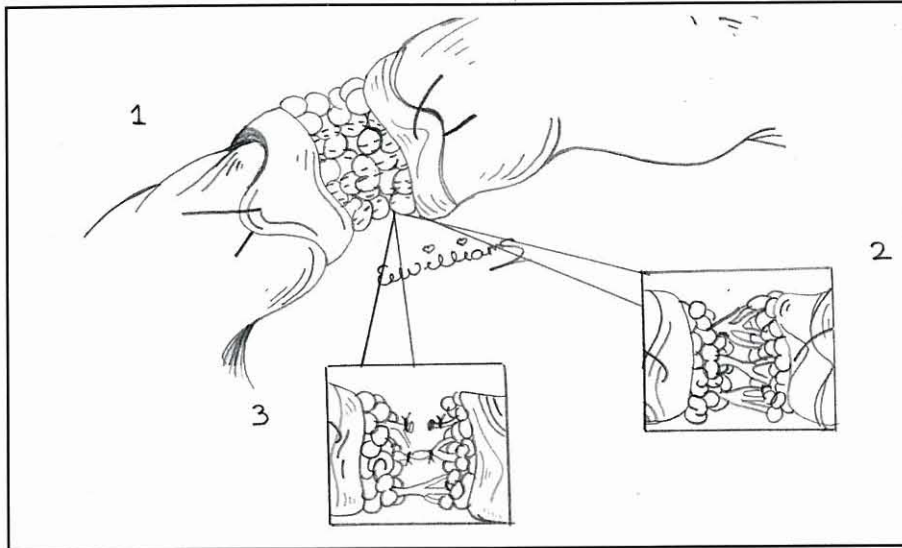
It is essential that neither the duct system nor the vascular system is damaged during the biopsy procedure.

In cases where there is diffuse disease, the tip of the right (duodenal) limb is chosen due to its accessibility; and given its peripheral position, the risk of damage to ducts and vessels is small. Either a suture fracture or surgical dissection and ligation (Figure 5.24) can be used. Whichever technique is used, it is essential to suture the mesoduodenum closed and to cover the wound with omentum. This will help minimize the risk of pancreatic enzyme leakage.



5.23 (a) Anatomical relationship of pancreatic ducts. (b) Blood supply to the pancreas.





**5.24** Surgical dissection and ligation for pancreatic biopsy.

### References and further reading

Brown DC (2003) Small intestines. In: *Textbook of Small Animal Surgery*, 3<sup>rd</sup> edn, ed. D Slatter, pp. 644–664. WB Saunders, Philadelphia  
Dunning D (2003) Surgical wound infection and the use of antimicrobials. In: *Textbook of Small Animal Surgery*, 3<sup>rd</sup> edn, ed.

D Slatter, pp. 113–122. WB Saunders, Philadelphia  
Holt DE and Brockman D (2003) Large intestine. In: *Textbook of Small Animal Surgery*, 3<sup>rd</sup> edn, ed. D Slatter, pp. 665–682. WB Saunders, Philadelphia  
Niles JD, Williams JM and Cripps PJ (2001) Haemostatic profiles in 39 dogs with congenital portosystemic shunts. *Veterinary Surgery* **30**, 97–104

## 5c

# Biopsy: handling, processing and interpretation

Michael J. Day

### Routine histopathology

#### Sample collection and processing

The approaches to endoscopic 'pinch' biopsy and full-thickness intestinal biopsy performed during laparotomy are described in Chapter 4 and Chapter 5b, respectively. Similarly, percutaneous needle core biopsy of liver and wedge biopsy of liver and pancreas are discussed in Chapter 5b. The sampling of oral or pharyngeal lesions is not specifically considered here, but in general terms either excisional or incisional biopsy will be performed at these sites. Evaluation of regional lymph nodes may also be indicated, particularly for suspected neoplastic disease. Oesophageal lesions are most often sampled by endoscopy.

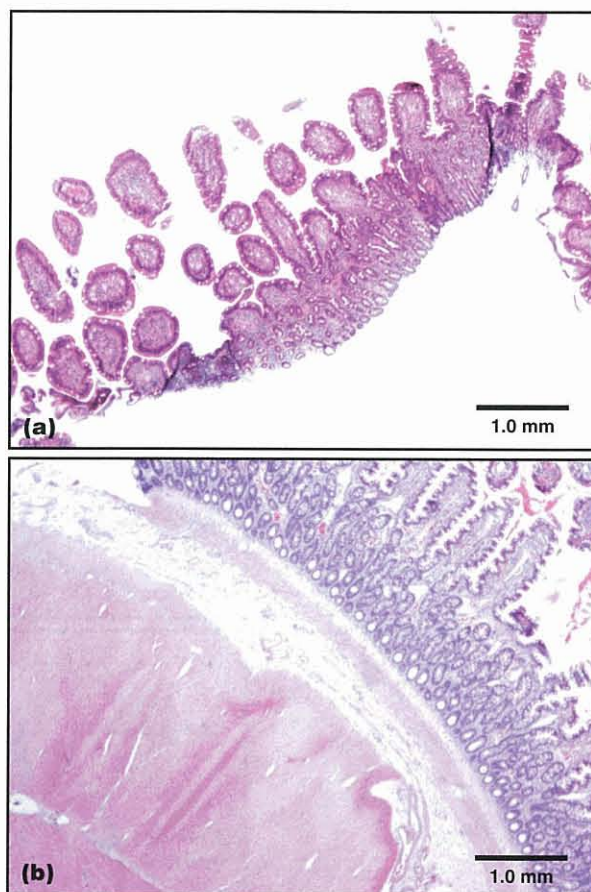
Although the use of cytological examination is not discussed in this chapter, oropharyngeal, gastrointestinal (GI), hepatic or pancreatic lesions may be sampled by impression smear or fine needle aspiration. The relative merits of cytological *versus* histological assessment are discussed elsewhere, but the sensitivity and specificity of cytological diagnosis for various sample sites has been recently reported by Cohen *et al.* (2003) who reported that of all sample types, cytological examination was least reliable for diagnosis of liver lesions. (See Chapters 12 and 16 for the use of faecal cytology as a diagnostic procedure.)

#### Biopsy samples

From the pathologist's perspective 'more is better' is the rule of thumb for collection of biopsy samples. If endoscopic biopsy samples are taken, a minimum of 6–8 should be collected from each site. This will maximize the chance of sampling the lesion, and will allow for the variability in quality of tissue and variation in tissue orientation during embedding, as discussed below. Optimally, endoscopic specimens should be routinely collected from gastric mucosa (fundic and pyloric), small intestine and colon. Even if there is no apparent indication for sampling these sites, evaluation of the entire GI tract is useful as subclinical lesions may be detected. It can often be helpful also to sample areas of apparently normal tissue for comparative purposes; but if this is done, these 'control' samples should be placed into a separate, appropriately labelled, formalin pot.

Although endoscopy is a valuable and minimally invasive technique for use in biopsy, it should be remembered that the samples collected are small and superficial (rarely including tissue below the

muscularis mucosa). The superficial nature of the samples means that it is not possible to rule out deeper underlying pathology (Figure 5.25). For example, the mucosa overlying an alimentary neoplasm might be ulcerated and inflamed; an endoscopic biopsy might only sample this reactive tissue and miss the underlying tumour.



**5.25** Sections from (a) endoscopic and (b) full-thickness biopsy samples of small intestine showing the relative levels of tissue sampled by these procedures. The endoscopic sample does not include tissue beneath the level of the mucosa. H&E stained sections.

A pathologist is always more likely to be able to make a more meaningful diagnosis with a full-thickness biopsy of intestine taken at laparotomy. At laparotomy, it is again optimal to sample multiple levels of the GI tract. Biopsy should be performed even if the

gut appears grossly normal, as there may still be histological abnormalities. Full-thickness biopsy samples of intestinal mucosa will tend to curl when placed into formalin, which will make preparation of a well orientated section difficult. This effect may be prevented if the sample is first placed, serosal side down, on to a small piece of card before immersing the card and sample in formalin. If there is a suggestion of liver or pancreas abnormality, these tissues should also be sampled whilst the opportunity presents, rather than regretting the absence of a key sample later. This is particularly the case in cats where there may be concurrent intestinal, hepatic and pancreatic inflammatory disease ('triaditis'). Where intestinal neoplasia is suspected, biopsy of the draining mesenteric lymph node to check for metastatic spread is indicated.

In the case of liver biopsy, a wedge sample taken at laparotomy is the most likely to be diagnostic (Figure 5.26). Needle core biopsy specimens obtained by blind percutaneous sampling are less valuable than percutaneous ultrasound-guided or laparoscopic samples that may target specific focal lesions. Even if a core biopsy includes predominantly liver tissue (and percutaneous core biopsy samples often comprise chiefly muscle or fat), it generally does not permit assessment of the entire hepatic unit. Commonly, a liver core biopsy would not include portal areas that are often the focus of hepatic disease. It has been suggested that a minimum of 15

portal triads should be assessed to determine whether there is portal or periportal pathology. Therefore, ideally, at least 2–3 core biopsy samples should be taken to increase the likelihood of achieving a histopathological diagnosis.

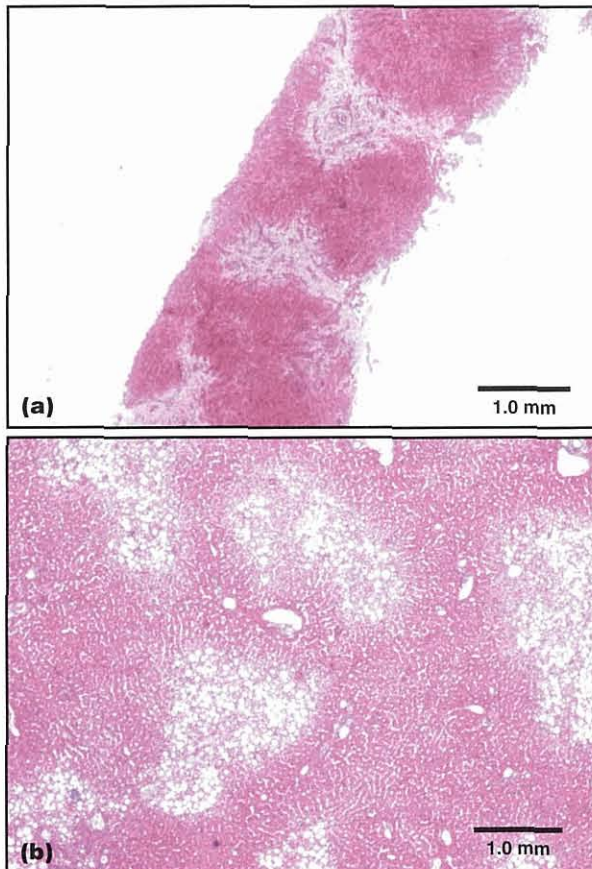
#### Post-mortem samples

Greater scope for sample collection arises at post-mortem examination. In conducting a necropsy examination of a case with GI disease, samples of grossly affected and unaffected tissue (or samples containing the junction of these types of tissue) should be collected. Sample collection should not be restricted to a single site that may be indicated by ante-mortem diagnostic procedures, and samples should be collected from multiple locations to check for subclinical pathology. For example, during a necropsy examination of a dog with colitis, samples might be collected from stomach, duodenum, jejunum, ileum, mesenteric lymph node, liver and pancreas in addition to affected colonic tissue. For intestinal samples taken at post-mortem, an intact 4 cm section of the entire intestine may be sampled. It is best to fix this sample unopened, as a flat portion of intestine will curl during processing as described above for full-thickness biopsy.

#### Processing

All samples for routine histopathological examination should be placed immediately after collection into an excess (minimum volume ten times the tissue size) of 10% neutral buffered formalin. Speed of fixation is essential for gut tissue, particularly for post-mortem samples as autolytic change can be pronounced within 20 minutes after death. Samples should be submitted to the laboratory with a complete clinical history. Where multiple intestinal sites are sampled, the tissues should be submitted in separate pots that are clearly labelled with the origin of the sample.

On submission to the laboratory, samples will be routinely processed through graded alcohols in an automatic tissue processor, and finally embedded in paraffin wax blocks. Larger tissue samples will be examined and 'trimmed' by the pathologist to a size optimum for preparation of a standard microscope slide, and sometimes multiple areas of a larger tissue sample will be selected for examination. Endoscopic pinch biopsy specimens provide a particular challenge to the histology technician. The uniformly small size of these samples often necessitates that they are processed within a purpose-designed fine-mesh container within the standard histological 'cassette', and after processing they are difficult, if not impossible, to orientate correctly within the wax block. The difficulty in processing these samples is a further reason for collecting multiple specimens from each location. It has been suggested that such material might be placed on to card with the mucosal surface uppermost before fixation. However, in practice these samples are likely to detach from the card during transit. In some referral centres, the biopsy samples are placed on to a purpose designed sponge insert for a histological cassette and the entire cassette placed into formalin. Where multiple endoscopic biopsy samples are taken from a particular



**5.26** Sections from (a) a needle core and (b) a wedge biopsy of liver showing the relative amount of tissue sampled by these procedures. The wedge biopsy includes many more complete hepatic units for assessment. H&E stained sections.



site, these will generally be blocked together to prepare a single microscopic section. Needle core biopsy specimens can also be fragile, particularly when the tissue of origin is friable, and these may also fragment during transit. Following embedding in paraffin wax, a standard 4 µm section will be prepared and stained by haematoxylin and eosin (H&E) for standard histopathological examination.

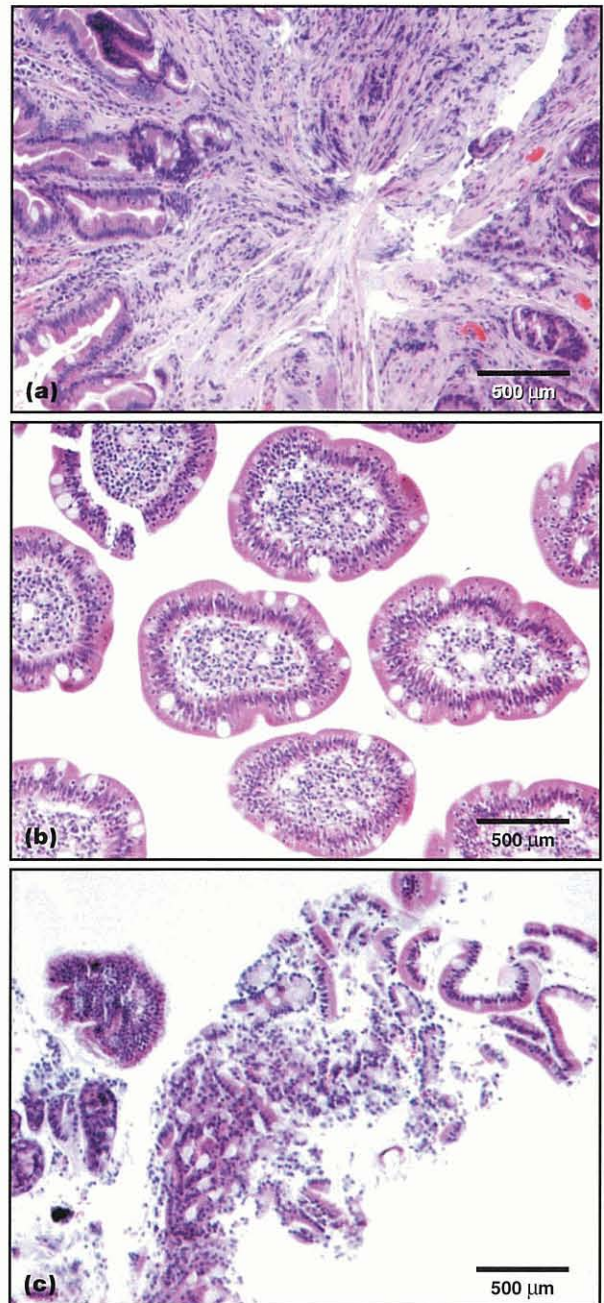
### Histopathological examination

Histopathological examination is a subjective procedure involving aspects of both science and art! It is well documented that intestinal biopsy samples provide the greatest challenge to the histopathologist, particularly endoscopic specimens where tissue that appears abnormal to the endoscopist may be histologically normal, and *vice versa*. Several studies have shown that there is often little agreement between pathologists on the interpretation of a single biopsy specimen. Moreover, there is no clear consensus on the histopathological criteria that define a specific diagnosis, and the criteria and nomenclature used sometimes vary between North America and Europe. There have been few attempts to standardize the criteria for histopathological diagnosis of dog or cat GI, liver or pancreatic disease. The World Small Animal Veterinary Association Liver Working Group (<http://www.wsava.org/Liver.htm>) is the first to attempt to produce standardized international nomenclature and criteria, and similar approaches to GI pathology are now in progress.

The pathology report should include a gross description of the sample submitted (most relevant for biopsy performed at laparotomy or post-mortem samples), which can provide a useful cross-check for the veterinary surgeon that what has been submitted to the laboratory has actually been sectioned. A microscopic description of each site sampled should be given, together with an interpretative comment and diagnosis. In the case of endoscopic or core biopsy, the pathologist may seek to provide an overview of the multiple samples, but highlight any specific localized abnormality (e.g. 'the overall appearance of the samples is normal, but in one of the specimens of fundic mucosa there is a focus of ulceration and neutrophilic inflammation'). Particular problems faced by the pathologist when interpreting endoscopic pinch biopsy samples (which may be mentioned in the report) include:

- Poor orientation of the biopsy for sectioning, such that a cross-section of individual villi is presented, rather than a longitudinal section through the villus-crypt unit
- Fragmentation of the biopsy with separation of the epithelial layer
- Crush artefact at the base of the biopsy that obliterates fine cellular detail (Figure 5.27).

Additionally, small foci of superficial or peripheral haemorrhage are common artefacts within endoscopic samples, as is a degree of separation of the connective tissue of the lamina propria, which must be distinguished from oedema. A recent study by Willard *et al.* (2001) has documented the variable quality of sections



**5.27** Sections of endoscopic biopsy samples demonstrating common artefacts seen with this procedure. (a) Crush artefact with loss of discernible tissue and cellular structure. (b) Cross-section of isolated villi when tissue is not orientated in a perpendicular fashion. (c) Fragmentation of a small tissue biopsy. H&E stained sections.

from endoscopic biopsy between diagnostic histopathology laboratories, and related this variation to the quality of sample submitted by the clinician rather than the technical process of preparing the biopsy.

In the case of inflammatory lesions, attempts have been made to grade these on severity and nature of the inflammatory infiltrate. There is no consensus grading scheme but most pathologists use a four-point scale of normal (0), mild (1), moderate (2) or severe (3) inflammation (Figure 5.28). The nature of inflammation may be reported as neutrophilic, granulomatous (macrophage dominated), pyogranulomatous (neutrophils and

Score	Criteria
0	Normal
1	Low number of inflammatory cells in the lamina propria without other changes
2	High numbers of inflammatory cells, together with separation and distortion of crypts and mild villous stunting
3	High numbers of inflammatory cells with marked separation of crypts, fibrosis and marked villous stunting and fusion

**5.28** Example of scoring system for inflammatory change of the small intestinal mucosa (after Baez *et al.*, 1999).

macrophages), eosinophilic, lymphoplasmacytic (lymphocyte and plasma cell dominated) or mixed. Fibrosis may occur in chronic lesions. In addition, abnormalities of mucosal microarchitecture (e.g. villus stunting, lacteal dilatation, ulceration, crypt distortion, crypt abscesses) will be described.

Similarly, there is no consensus grading scheme for neoplastic lesions of the alimentary tract. The nature of the neoplastic population (e.g. epithelial, spindle cell, round cell), the histological arrangement (e.g. sheet, acinar, whorled) and cytological features (e.g. pleomorphism, nuclear-cytoplasmic ratio, nucleoli, chromatin, mitoses) should be described. Other basic parameters, such as extent of tissue destruction, infiltration of deep margins (difficult to assess with endoscopic pinch biopsy) or invasion of blood or lymphatic vessels, should also be reported.

Similar basic principles of interpretation should be applied to the assessment and reporting of liver or pancreatic biopsy samples with inflammatory or neoplastic disease. Where possible, assessment of the entire hepatic unit should be performed, and for pancreatic samples assessment of both exocrine and endocrine pancreatic tissue should be made.

### Specialized pathological examinations

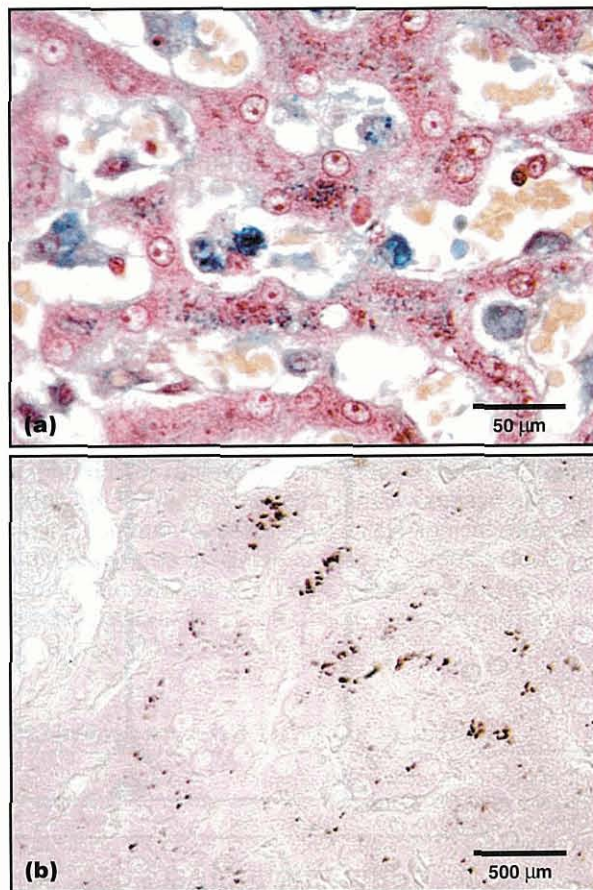
#### Special stains

The examination of an H&E stained section is the first line of the histopathological examination and in the majority of cases no further assessment is required. However, most histopathology laboratories will be able to perform a panel of 'special stains' to assess particular features of a biopsy sample. These will generally be selected by the pathologist on the basis of the examination of the H&E section, but it can be helpful for the clinician to suggest where these might be indicated (e.g. 'possible mycobacterial involvement, please perform Ziehl-Neelsen stain').

In the case of a granulomatous or pyogranulomatous inflammatory lesion, it would be routine to perform a panel of special stains that included Gram stain (for bacteria), periodic acid-Schiff (PAS, for fungi) and Ziehl-Neelsen (ZN, for acid-fast bacteria) to attempt to identify

an infectious aetiology. The Warthin-Starry silver stain may be used for the detection of spirochaete bacteria. The clinician should be aware that these special stains are relatively insensitive, and may be negative where culture or polymerase chain reaction (PCR) may yield a positive result. However, special stains are generally performed retrospectively (i.e. on the sample submitted for routine histopathology), whereas culture and PCR require fresh tissue. The Giemsa stain may be used to identify protozoans (e.g. *Leishmania*). Where eosinophils may be difficult to appreciate in some H&E stained sections, special stains such as Sirius red can highlight these cells for assessment of their role in an inflammatory enteropathy. In the case of neoplastic disease, the most widely used example of the application of special stains is the performance of toluidine blue staining in mast cell neoplasia.

Special stains are perhaps more often indicated in the assessment of liver biopsy material. The presence of intra-hepatocyte granular pigment is a common finding, and a distinction should be made between iron (haemosiderin, stained by Perl's Prussian blue) and copper (stained by rubeanic acid) (Figure 5.29). Copper accumulation may be more common than currently appreciated as rubeanic acid staining is not always widely available. Fouchet's stain can be used to highlight bile pigment accumulation in cases of biliary



**5.29** Sections of liver stained by (a) Perl's Prussian blue for haemosiderin and (b) rubeanic acid for copper. These stains are to investigate the nature of the cytoplasmic, brown, granular pigment observed within hepatocytes on a routine H&E section.

obstruction. Hepatic fibrosis can be assessed by use of the Haematoxylin Van Gieson (HVG) stain for collagen, and silver-based staining, such as the Gordon and Sweet method, for reticulin fibres. Hepatic lipid can be stained by Oil red O and glycogen by PAS, but these stains must be performed on frozen tissue sections. Amyloid deposition can be detected by Congo red staining and examination of the section by polarized light for birefringence. The same range of special stains for infectious agents can be applied to liver tissue with evidence of inflammatory change suggestive of microbial involvement.

**Electron microscopy**

Transmission electron microscopy (TEM) is rarely indicated or available in a routine diagnostic pathology setting. However, TEM can sometimes be useful in characterizing microbial agents that might not be easily identified by routine light microscopy (e.g. enteropathogenic *Escherichia coli* or *Cryptosporidium*) or characterizing ultrastructural lesions (e.g. lysosomal storage diseases). TEM can be performed retrospectively by removing a sample of tissue from the paraffin wax block for further processing. For prospective TEM examination, tissue fixed in glutaraldehyde is optimal and the laboratory should be consulted for specific requirements.

**Immunohistochemistry**

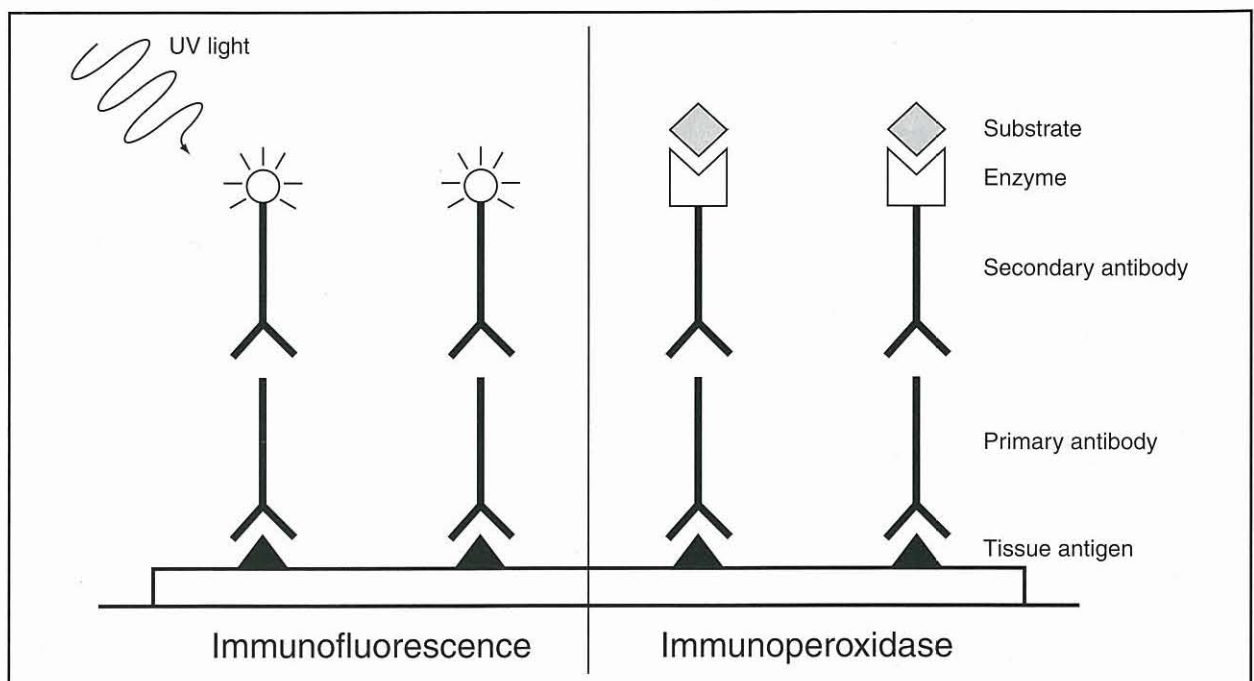
Immunohistochemistry utilizes an antibody (polyclonal or monoclonal) to detect a specific antigenic molecule within a tissue sample. Some antibodies may be applied to formalin-fixed tissue, making it possible to perform retrospective studies using the same biopsy sample that was processed for routine histopathologi-

cal evaluation. In contrast, other antibodies may only be used with snap-frozen fresh tissue that has been sectioned with a cryostat. There is a specific protocol for snap freezing tissue samples for immunohistochemistry, and this is usually not possible in a general practice setting. Unless immunohistochemistry is offered routinely, it is wise to consult with the laboratory regarding sample requirements for such studies.

The principle of immunohistochemistry is depicted in Figure 5.30. The binding of antibody to target molecule is detected via labelling of the primary or secondary antibody with either a fluorochrome (immunofluorescence) or an enzyme (immunoperoxidase). Various enhancement procedures (e.g. avidin-biotin immunohistochemistry) have been applied to the methodology. Immunohistochemistry is increasingly available as more commercial laboratories acquire the capacity to perform automated immunolabelling. Manual immunohistochemistry is a time-consuming and costly process that is not widely available.

Immunohistochemistry may be used to detect specific infectious agents in tissue and is far more sensitive than the special stains described above. For example, detection of coronavirus antigen in the serosal lesions of feline infectious peritonitis (FIP) would be a useful adjunct to diagnosis. Immunohistochemistry may also be used to detect amyloid and to distinguish between AA and AL forms of the protein.

At the experimental level, immunohistochemistry has been used to characterize the inflammatory cell types in intestinal biopsy samples from dogs and cats with inflammatory bowel disease (IBD). The relative proportions of lamina propria (CD4<sup>+</sup> αβT cell receptor<sup>+</sup>) and intraepithelial T cells (CD8<sup>+</sup>, γδT cell receptor<sup>+</sup>), plasma cells (IgG, IgM, IgA) and antigen-presenting



**5.30** Principle of immunohistochemistry. Target antigens within tissue are identified by a primary antibody, which is in turn bound by a secondary antibody that is chemically conjugated to either a fluorochrome or enzyme (typically peroxidase). The target antigen is visualized by exciting the fluorochrome with light of an appropriate wavelength, or generating local colour change following the addition of substrate.

cells (major histocompatibility complex (MHC) class II<sup>+</sup>, MAC387<sup>+</sup>) have all been examined. It is clear that such immunohistochemical evaluation of inflammatory lesions has diagnostic value. In dogs with chronic diarrhoea histopathological examination of the H&E section may reveal no apparent abnormality, causing frustration for both clinician and pathologist. However, such morphologically normal samples may still have an imbalance in the proportions of CD4 and CD8 T cells. At this time, however, such immunohistochemical methods are not routinely applied to the diagnosis of IBD, as in addition to the labelling procedure, the enumeration of the cell populations is very time consuming and technically demanding. Similar immunohistochemical characterization has been made of the lesions of inflammatory liver disease in the dog and cat.

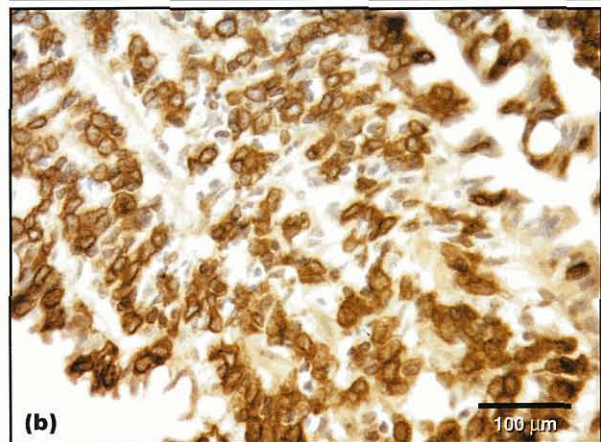
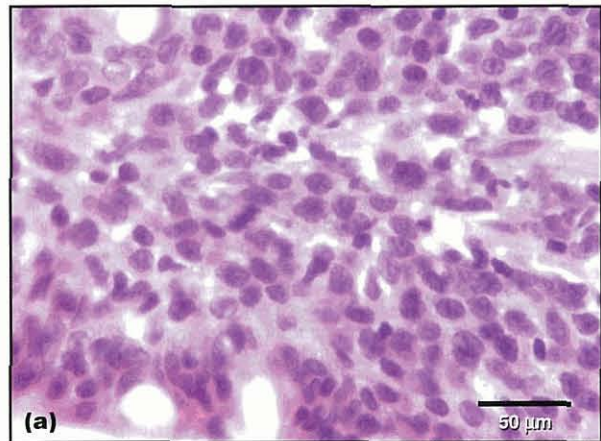
The diagnosis of alimentary neoplasia may also benefit from the application of immunohistochemistry. The most common indication for this is to make the distinction between lymphocytic IBD and early stage alimentary lymphoma. This is extremely difficult at the histopathological level, and in some cases immunohistochemistry can aid in differentiating between these diagnoses. In lymphoma, a lymphocytic infiltrate is clonal, so virtually all of the lymphocytes in the sample will be of one phenotype (i.e. T or B cell), whereas in an inflammatory process a mixture might be expected. The phenotyping (T versus B lymphocyte) of overt examples of alimentary lymphoma can be performed (Figure 5.31). Contrary to earlier belief, not all alimentary lymphoma is of B cell origin, and in some studies T cell lymphoma (sometimes epitheliotropic) predominates. There are no clear data to suggest that the phenotype of alimentary lymphoma affects outcome in either the dog or cat.

Other tumour markers may be evaluated immunohistochemically, often using anti-human antisera that cross-react with canine or feline molecules. For example, Sharpe *et al.* (2000) diagnosed alimentary haemangiosarcoma on the basis of expression of von Willebrand's Factor (Factor VIII-related antigen), and a large panel of epithelial (cytokeratin) and stromal markers are available.

### Future techniques

The future of diagnosis from biopsy tissue is not restricted to the light microscope. Experimental studies have shown that it is possible to identify microbial DNA or RNA in fresh or fixed tissue by PCR or reverse transcription PCR (RT-PCR) amplification, and to quantify levels of expression of these materials by real-time RT-PCR. These techniques using tissue are difficult to establish and control, and may be some way off becoming readily available. By contrast, PCR for microbial genetic material using blood samples is already commercially available.

RT-PCR and real-time RT-PCR have also been applied to biopsy tissue for the detection (and quantification) of cytokine gene transcription; it may be that a particular 'cytokine profile' is associated with specific disease entities (e.g. subtypes of IBD). A range of other key immunological molecules can be indirectly evaluated by RT-PCR, but the main limitation of



**5.31** Section of small intestinal villus from a dog with alimentary lymphoma. (a) The H&E stained section shows replacement of normal mucosal structure by a diffuse sheet of neoplastic round cells with mitotic activity. (b) These are identified as T lymphocytes by immunohistochemical expression of CD3.

these techniques is that messenger RNA production does not necessarily equate to synthesis of the encoded protein.

Recent studies by Burnett *et al.* (2003) have shown that it is possible to evaluate the clonality of a lymphoid population within a biopsy sample and to distinguish lymphoma from inflammation on the basis of restricted genotype. In North America, clonality assays are becoming commercially available for cytological samples and will soon be available for tissue samples. Ideally, biopsy samples will still be screened by routine histopathology but the range of 'follow-on' techniques in the future will be greatly expanded.

### References and further reading

- Baez JL, Hendrick MJ, Walker LM and Washabau RJ (1999) Radiographic, ultrasonographic, and endoscopic findings in cats with inflammatory bowel disease of the stomach and small intestine: 33 cases (1990–1997). *Journal of the American Veterinary Medical Association* **215**, 349–354
- Boisclair J, Dore M, Beauchamp G, Chouinard L and Girard C (2001) Characterization of the inflammatory infiltrate in canine chronic hepatitis. *Veterinary Pathology* **38**, 628–635
- Burnett RC, Vernau W, Modiano JF, Olver CS, Moore PF and Avery AC (2003) Diagnosis of canine lymphoid neoplasia using clonal rearrangements of antigen receptor genes. *Veterinary Pathology* **40**, 32–41

## Chapter 5c Biopsy: handling, processing and interpretation

- Caney SMA, Day MJ, Gruffydd-Jones TJ, Helps CR, Hirst TR and Stokes CR (2002) Expression of chemokine receptors in the feline reproductive tract and large intestine. *Journal of Comparative Pathology* 126, 289–302
- Center SA (1999) Chronic liver disease: current concepts of disease mechanisms. *Journal of Small Animal Practice* 40, 106–114
- Cohen M, Bohling MW, Wright JC, Welles EA and Spano JS (2003) Evaluation of sensitivity and specificity of cytological examination: 269 cases (1999–2000). *Journal of the American Veterinary Medical Association* 222, 964–967
- German AJ, Hall EJ and Day MJ (2001) Characterization of immune cell populations within the duodenal mucosa of dogs with enteropathies. *Journal of Veterinary Internal Medicine* 15, 14–25
- German AJ, Hall EJ, Kelly DF, Watson AD and Day MJ (2000a) An immunohistochemical study of histiocytic ulcerative colitis in boxer dogs. *Journal of Comparative Pathology* 122, 163–175
- German AJ, Helps CR, Hall EJ and Day MJ (2000b) Cytokine mRNA expression in mucosal biopsies from German shepherd dogs with small intestinal enteropathies. *Digestive Diseases and Sciences* 45, 7–17
- Harley R, Helps CR, Harbour DA, Gruffydd-Jones TJ and Day MJ (1999) Analysis of intralesional cytokine mRNA expression in feline chronic gingivostomatitis. *Clinical and Diagnostic Laboratory Immunology* 6, 471–478
- Sharpe A, Cannon MJ, Lucke VM and Day MJ (2000) Intestinal haemangiosarcoma in the cat: clinical and pathological features of four cases. *Journal of Small Animal Practice* 41, 411–415
- Waly N, Gruffydd-Jones TJ, Stokes CR and Day MJ (2001) The distribution of leucocyte subsets in the small intestine of normal cats. *Journal of Comparative Pathology* 124, 172–182
- Willard MD, Lovering SL, Cohen ND and Weeks BR (2001) Quality of tissue specimens obtained endoscopically from the duodenum of dogs and cats. *Journal of the American Veterinary Medical Association* 219, 474–479
- Zentek J, Hall EJ, German AJ, Haverson K, Bailey M, Rolfe V, Butterwick R and Day MJ (2002) Morphology and immunopathology of the small and large intestine in dogs with non-specific dietary sensitivity. *Journal of Nutrition* 132, 1652S–1654S
-

# Dysphagia and regurgitation

Robert J. Washabau

## Introduction

*Dysphagia and regurgitation are the two main clinical signs associated with swallowing disorders in dogs and cats.*

- Dysphagia is defined as difficulty in swallowing.
- Regurgitation is defined as the passive evacuation of undigested food from the oesophagus.

Differentiation between dysphagia and regurgitation may help to localize the anatomical site of the disease, as dysphagia is the most important clinical sign associated with diseases of the oral cavity and pharynx whilst regurgitation is the most important clinical sign associated with diseases of the oesophagus. In most swallowing disorders one of these clinical signs (dysphagia or regurgitation) tends to predominate, thereby providing a clue to the site of

the lesion. In some animals, however, regurgitation and dysphagia may coexist, in which case other clinical signs may be useful in differentiating the site of the lesion (Figure 6.1).

## Dysphagia

### Clinical features

#### History

Dysphagia is the most important clinical sign associated with diseases of the oral cavity and pharynx.

- *Oral dysphagias* are often characterized by difficulty in the prehension of food and water, dropping of food and water from the mouth and repeated unproductive attempts to prehend food and water.

Clinical sign	Oropharyngeal disease	Oesophageal disease	Gastric disease
Dysphagia	Always present	Sometimes present (with oesophagitis or obstruction)	Absent
Regurgitation	Absent	Present	Absent
Vomiting	Absent	Absent	Present
Hypersalivation	Usually present	May be present	May be present
Gagging	Often present	Usually absent	Absent
Ability to drink	Abnormal	Normal	Normal
Ability to form a solid bolus	Abnormal	Normal	Normal
Dropping of food from the mouth	Present	Absent	Absent
Time of food ejection	Immediate	Delayed, minutes to hours	Delayed, minutes to hours
Character of food ejected	Undigested	Undigested	Partially digested, bile-stained, acidic pH
Odynophagia ( <i>pain on swallowing</i> )	Occasionally seen	Frequent, particularly with oesophagitis	Absent
Number of swallowing attempts	Multiple	Single to multiple	Usually single
Associated signs	Nasal discharge	Dyspnoea, cough	Abdominal pain, retching
Reluctance to eat	May be present	May be present	May be present
Muscle atrophy	May be present	May be present	Usually absent
Ptosis/lip droop/enophthalmos	May be present	May be present	Usually absent

### 6.1

Localization of clinical signs for oropharyngeal, oesophageal and gastric diseases.

- *Pharyngeal dysphagias* are characterized by gagging, drooling saliva, multiple unproductive attempts at swallowing, and by nasal discharge and coughing due to misdirection of food into the nasopharynx or larynx, respectively.

Both oral and pharyngeal dysphagias may be characterized by other concurrent clinical signs including: excessive salivation; odynophagia (pain felt during swallowing); reluctance to eat; and general malaise due to aspiration pneumonia (see Figure 6.1).

**Physical examination**

The pathogenesis of many of the oropharyngeal dysphagias should be fairly obvious on physical examination (e.g. trauma, neoplasia, stricture, inflammation, foreign body); however, a complete assessment may require sedation or general anaesthesia in some patients. Animals with neuromuscular disorders may have fewer physical examination abnormalities. Focal or generalized muscle atrophy and a diminished or absent gag reflex may be the only abnormal findings in animals affected with neuromuscular disorders. If aspiration pneumonia is present, fever, dehydration, tachypnoea, coughing and harsh lung sounds may be evident on the physical examination.

**Diagnosis**

Initial laboratory testing should include haematology, biochemistry profile and urinalysis. This database will be useful in excluding systemic and metabolic disease, and will provide information about the animal's hydration status. Survey radiography of the oral cavity, neck and/or chest should be obtained in any animal with

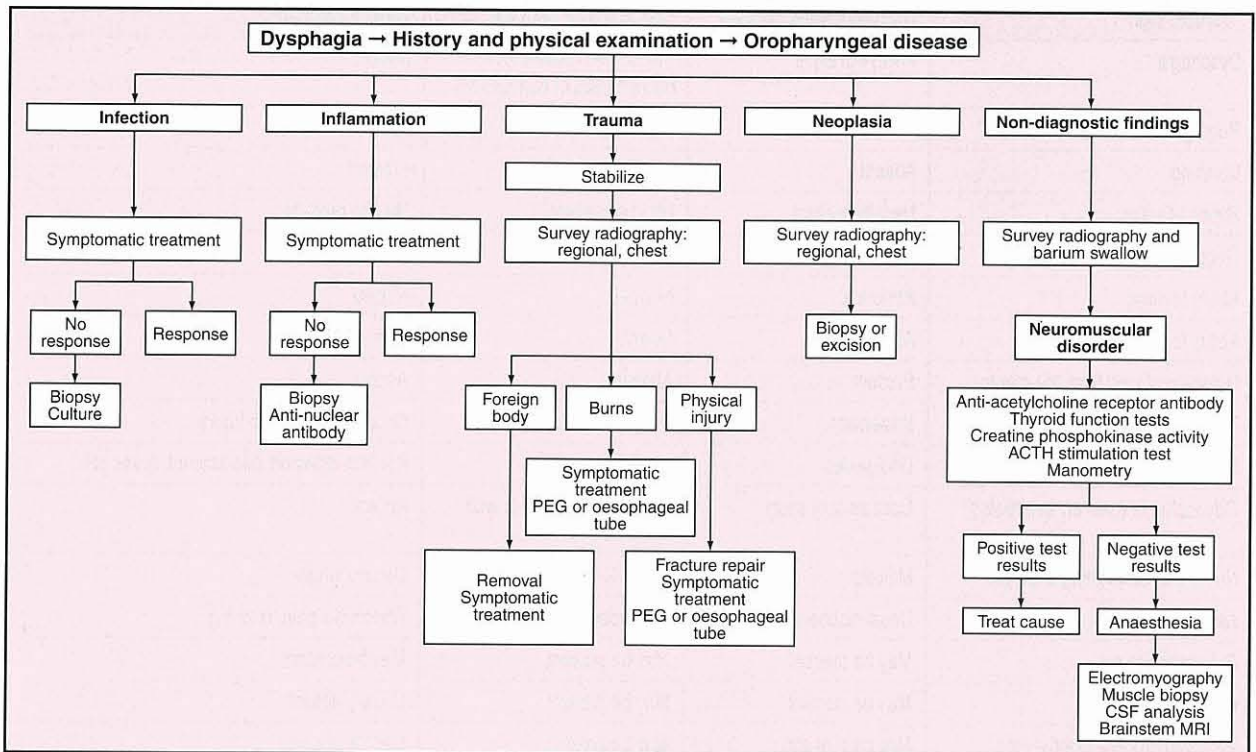
oropharyngeal dysphagia and may help in delineating foreign bodies, masses, dental disease, temporomandibular disease and distant metastasis. An approach to the diagnosis of oropharyngeal dysphagias is outlined in Figure 6.2. The diagnosis of most oropharyngeal dysphagias is straightforward and, aside from tissue biopsy or culture, may not require any additional diagnostic testing. The diagnosis of neuromuscular disorders is more difficult and may require the use of videofluoroscopy, muscle biopsy, electrophysiology, cerebrospinal fluid analysis and brainstem MRI. If these techniques are not readily available in the private practice setting, cases can be referred to specialist centres.

**Treatment**

The goal of therapy is always to resolve or remove the underlying cause. For example:

- Fracture repair
- Direct treatment of thermal injury
- Removal of foreign bodies
- Treatment of bacterial infection with antibiotics
- Treatment of inflammatory or immune-mediated disease with anti-inflammatory or immunosuppressive doses of glucocorticoids
- Mass excision.

Animals with neuromuscular disorders may benefit from changing the amount, frequency and consistency of the food, or by placement of an oesophagostomy or percutaneous endoscopic gastrostomy (PEG) tube. Vigilance for, and treatment of, aspiration pneumonia may prove the difference between early demise and long-term recovery.



**6.2** An approach to the diagnosis of dysphagia associated with oropharyngeal disease. ACTH = adrenocorticotrophic hormone; CSF = cerebrospinal fluid; MRI = magnetic resonance imaging; PEG = percutaneous endoscopic gastrostomy.

## Regurgitation

### Clinical features

#### History

Regurgitation is the most important clinical sign of oesophageal disease and should be differentiated from dysphagia associated with oropharyngeal disease and vomiting associated with gastric disease (see Figure 6.1). The severity of clinical signs with oesophageal disease is somewhat dependent upon the pathogenesis of the disease. For example, animals with oesophagitis may have anorexia, dysphagia, odynophagia and salivation in conjunction with regurgitation. Other systemic signs associated with oesophagitis may include weight loss and, if aspiration pneumonia is present, dyspnoea, fever, dehydration and/or coughing. Whereas animals with idiopathic adult-onset megaesophagus may have severe regurgitation, their appetite is usually excellent because of secondary malnutrition.

#### Physical examination

A physical examination is important primarily from the standpoint of excluding other gastrointestinal or systemic disease. However, weight loss, fever and harsh lung sounds are common physical examination findings in animals affected with severe regurgitation and aspiration pneumonia. Occasionally a foreign body or oesophageal dilatation may be detected during examination of the oropharynx and neck. Neurological examination should always be performed to evaluate for neuromuscular (e.g. myasthenia gravis) or neurological (e.g. afferent neural dysfunction) causes of megaesophagus (see Chapter 18).

#### Diagnosis

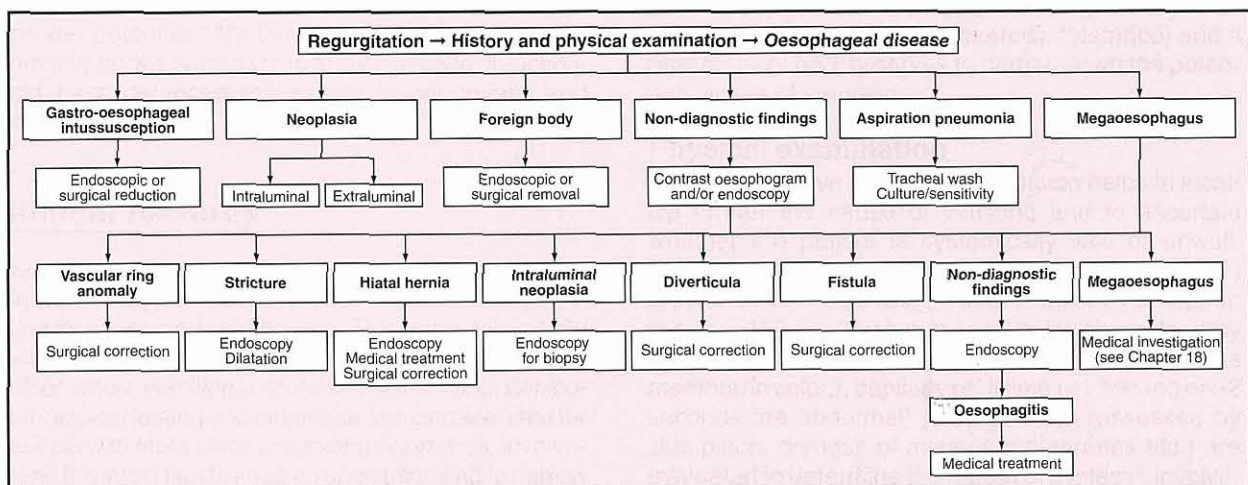
An approach to the diagnosis of regurgitation associated with oesophageal disease is outlined in Figure 6.3. Initial laboratory testing should include routine haematology, serum biochemistry profile, urinalysis and faecal parasitological examination. This database will be useful in excluding systemic (e.g. lead poisoning, immune-mediated disease) or metabolic (e.g.

hypoadrenocorticism) disease as a cause of secondary oesophageal signs. Twenty-five to thirty percent of cases of canine adult-onset idiopathic megaesophagus are associated with the development of myasthenia gravis; therefore, assessment of megaesophagus should always include testing for nicotinic anti-acetylcholine receptor antibody.

Survey radiography, contrast radiography and oesophageal endoscopy are the diagnostic methods currently available in modern veterinary practice (see Chapters 3 and 4). Animals suspected of having oesophageal disease should have survey radiography of the neck and thorax. Definitive diagnosis or evidence in support of a diagnosis may be obtained with survey radiographs in many cases, including gastro-oesophageal intussusception, oesophageal foreign body, megaesophagus, neoplasia and hiatal hernia. Thoracic radiography will also identify some of the complications of oesophageal disease including: aspiration pneumonia; pleural effusion; mediastinitis; and pneumothorax.

Contrast radiography can be performed to identify oesophageal lesions or to confirm a tentative diagnosis. Disorders not readily diagnosed by survey radiography (e.g. radiolucent foreign body, oesophagobronchial fistula, oesophagitis, diverticula and stricture) may be more readily diagnosed by contrast radiography. Dynamic contrast studies, i.e. videofluoroscopy, should be used instead of static barium radiography whenever possible. In addition to structural information, dynamic studies will provide some information about oesophageal motility. Contrast studies may be performed using barium paste (80–100% weight/volume), barium suspension (30% weight/volume), barium-coated meals or iodinated contrast agents. The choice of a specific contrast agent will depend upon which oesophageal disease is suspected (see Chapter 3).

Oesophageal endoscopy has become a very useful tool in the diagnosis and treatment of oesophageal disease (see Chapter 4). Usually performed after survey radiographic assessment, endoscopy is particularly useful in diagnosing oesophageal strictures, oesophagitis, intraluminal masses, foreign bodies and diverticula. Endoscopy may also be used therapeutically to remove



6.3 An approach to the diagnosis of regurgitation associated with oesophageal disease.



## Chapter 6 Dysphagia and regurgitation

foreign bodies, dilate oesophageal strictures or to place gastrostomy feeding tubes.

Ultrasonography may be useful in the diagnosis of peri-oesophageal masses or other mediastinal disease. Oesophageal manometry is useful for diagnosing cricopharyngeal achalasia, generalized oesophageal motility disorders and caudal oesophageal sphincter incompetence, but the technique is currently performed at only a few referral centres. Nuclear scintigraphy and oesophageal pH monitoring have also been used to diagnose oesophageal motility disorders and gastro-oesophageal reflux, respectively.

### Treatment

Specific treatments are given in Chapter 18, but the primary goal of therapy with oesophageal disorders is to resolve the underlying cause. For example:

- Removal of foreign bodies
- Treatment of oesophagitis with chemical diffusion barriers (e.g. sucralfate)
- Incisional or excisional (mass) biopsy
- Dilatation of oesophageal strictures
- Reduction of gastro-oesophageal intussusceptions
- Surgical correction of vascular ring anomalies
- Surgical correction of oesophageal diverticula or fistulae.

Affected patients may also benefit from changing the amount, frequency and consistency of the food, or by placement of oesophagostomy or PEG tubes. Recognition and treatment of aspiration pneumonia may improve outcome in severely affected patients.

---

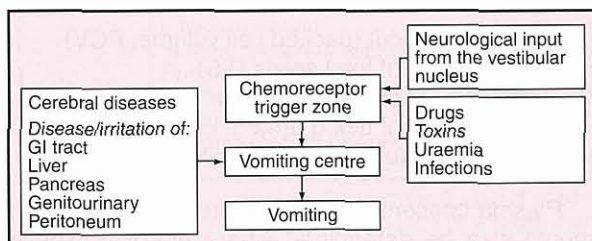
# Acute and chronic vomiting

Kenneth W. Simpson

## Introduction

Vomiting is a reflex act initiated by stimulation of the vomiting centre in the medulla.

The vomiting centre can be stimulated either directly or indirectly via the chemoreceptor trigger zone (CRTZ). Disease or irritation of the gastrointestinal (GI) tract, abdominal organs or peritoneum can directly stimulate the vomiting centre, as can cerebral diseases. Blood-borne substances (such as toxins or drugs) and neurological input from the vestibular nucleus cause dopamine release in the CRTZ and indirect stimulation of the vomiting centre (Figure 7.1). Once the vomiting centre is stimulated a set of reflex actions are coordinated to cause the active expulsion of gastric contents from the mouth.



7.1 Initiation of vomiting.

The clinical importance of vomiting stems from its association with a large and varied group of diseases, and the potentially life-threatening consequences of vomiting *per se*, such as fluid and electrolyte depletion, acid-base derangement, aspiration pneumonia and oesophagitis.

## Clinical features

Because vomiting is a sign of so many diseases (see Figure 7.2) a systematic approach is essential to determine its cause and significance. This approach initially focuses on historical and physical findings, which often suffice where vomiting is acute and self-limiting. Clinicopathological testing and diagnostic imaging are used for patients with more chronic vomiting or systemic involvement. It is important to keep an open mind and to narrow down progressively the list of possibilities to achieve a specific diagnosis. Integration of the patient's age, sex,

breed and environment, with historical and physical findings often helps to focus the investigation. For example, dietary indiscretion, foreign body ingestion, intussusception and infectious diseases are more common in young animals, whereas gastric neoplasia is much more frequent in older animals.

## History

Patient history should be used to try to distinguish vomiting (presence of active abdominal effort, bile etc.) from regurgitation (see Chapter 6) and to obtain a clear picture of the vomiting episodes (duration, frequency, contents, colour, progression, relationship to eating). Where vomiting cannot be adequately distinguished from regurgitation it is important to watch the animal eat, observe the 'vomiting episodes', and take a thoracic radiograph to detect oesophageal dilatation or obstruction. *Non-productive vomiting* (often described as persistent retching) and abdominal distension in deep-chested large-breed dogs are frequently associated with gastric dilatation and volvulus (GDV); this requires rapid diagnosis and treatment. Vomiting of food >10–12 hours after ingestion indicates delayed gastric emptying and requires investigation to distinguish gastric outflow obstruction from defective gastric propulsion. Details of the environment (whether indoor, outdoor, single or multi-animal household), access to foreign bodies, toxins or medications, and vaccination status should be obtained. A thorough review of body systems (including attitude, mentation, presence of polyuria, polydipsia, weight loss, diarrhoea, coughing, sneezing, exercise tolerance) and a past medical history serves to narrow down the potential causes of vomiting.

## Physical examination

A comprehensive physical examination helps to localize further the cause of vomiting and to ascertain whether the patient is systemically well or unwell. Temperatures of <37.5°C or >39°C (<99.5°F or >102°F) are abnormal. Pulse rate (in dogs: <60 or >180 b.p.m.; in cats: <150 or >250 b.p.m.) and pulse character may be abnormal. Respiratory rate and character, mucous membrane colour, capillary refill time (<1 second or >2 seconds are abnormal) and hydration (assessed by skin pinch, dryness of mucous membranes etc.) are evaluated to determine the nature of systemic involvement. The presence of localizing findings such as naso-ocular discharge, uveitis, retinal abnormalities,

coughing, jaundice, lymphadenopathy, organomegaly, abdominal distension, abdominal masses, abdominal pain and dermatological abnormalities should be determined. Palpation of the thyroid gland is especially important in older cats. A rectal examination to evaluate stool consistency, occult melaena and rectal or perianal abnormalities (e.g. anal sac carcinoma as a cause of hypercalcaemia-induced vomiting) should not be overlooked.

### Problem list

Historical and physical findings are integrated to generate a problem list that focuses the diagnostic and therapeutic plan (see Chapter 1). It is helpful from a diagnostic and therapeutic standpoint to categorize the patient as systemically well or unwell, and vomiting as acute (<5 days) or chronic, mild or severe.

### Differential diagnosis

Figure 7.2 lists the differential diagnoses for vomiting in dogs and cats.

Type	Causes
Gastric	Gastritis; ulceration; neoplasia; outflow obstruction; foreign bodies <sup>a</sup> ; motility/functional disorders
Intestinal	Inflammatory bowel disease; neoplasia; foreign bodies <sup>a</sup> ; intussusception <sup>a</sup> ; bacterial overgrowth/antibiotic-responsive enteropathy <sup>a</sup> ; functional disorders
Intra-abdominal non-GI tract	Pancreas: pancreatitis, pancreatic neoplasia Liver: cholangiohepatitis, biliary obstruction, hepatitis, bile duct rupture Genitourinary: pyometra, nephritis, nephrolithiasis, urinary obstruction, prostatitis
Metabolic/endocrine	Uraemia; hypoadrenocorticism; diabetic ketoacidosis; hyperthyroidism; hepatic encephalopathy; hypercalcaemia; septicaemia
Drugs	Digoxin; erythromycin; chemotherapy; xylazine; apomorphine; intravenous medications
Toxins <sup>a</sup>	Strychnine; ethylene glycol; lead
Dietary <sup>a</sup>	Sudden change; indiscretion; intolerance; allergy
Neurological	Vestibular disease; encephalitis; neoplasia; raised intracranial pressure
Infectious <sup>a</sup>	Distemper; parvovirus; infectious canine hepatitis; leptospirosis; feline panleucopenia; feline infectious peritonitis; <i>Salmonella</i>

**7.2** Causes of vomiting. <sup>a</sup> Conditions that are more common in younger dogs and cats.

### Diagnosis

#### Acute vomiting and systemically well

If vomiting is acute and the animal is systemically well with no historical or physical 'red flags', further diagnostic testing is usually not warranted as vomiting often

resolves on its own, or after symptomatic therapy. If there is any doubt about hydration status, a minimum database of tests consisting of a microhaematocrit and total protein can be performed to evaluate hydration status more objectively (see below). In puppies a faecal examination to detect endoparasites may also be performed.

#### Chronic vomiting or systemically unwell

If the animal is systemically unwell, has been vomiting for >5 days, or has haematemesis, bloody diarrhoea or localizing signs (such as abdominal pain or jaundice), a more aggressive investigation is necessary to define the nature of the problem. The combination of non-productive vomiting and abdominal distension is characteristic of gastric dilatation or GDV, which are emergency situations requiring rapid diagnosis (via clinical findings and abdominal radiography) and intervention to relieve gastric distension and provide haemodynamic support.

The diagnostic approach described below and outlined in Figure 7.3 should enable the clinician to detect the majority of causes of vomiting. The emphasis is on efficiently identifying conditions that require surgical intervention (e.g. GDV or septic peritonitis) and ruling out non-GI causes of vomiting, before proceeding to more specialized or invasive diagnostic procedures aimed at detecting primary gastric and intestinal disorders.

#### Rapid initial tests

Rapid initial tests (a minimum database) are recommended for vomiting animals that are suspected of being dehydrated. These rapid tests are:

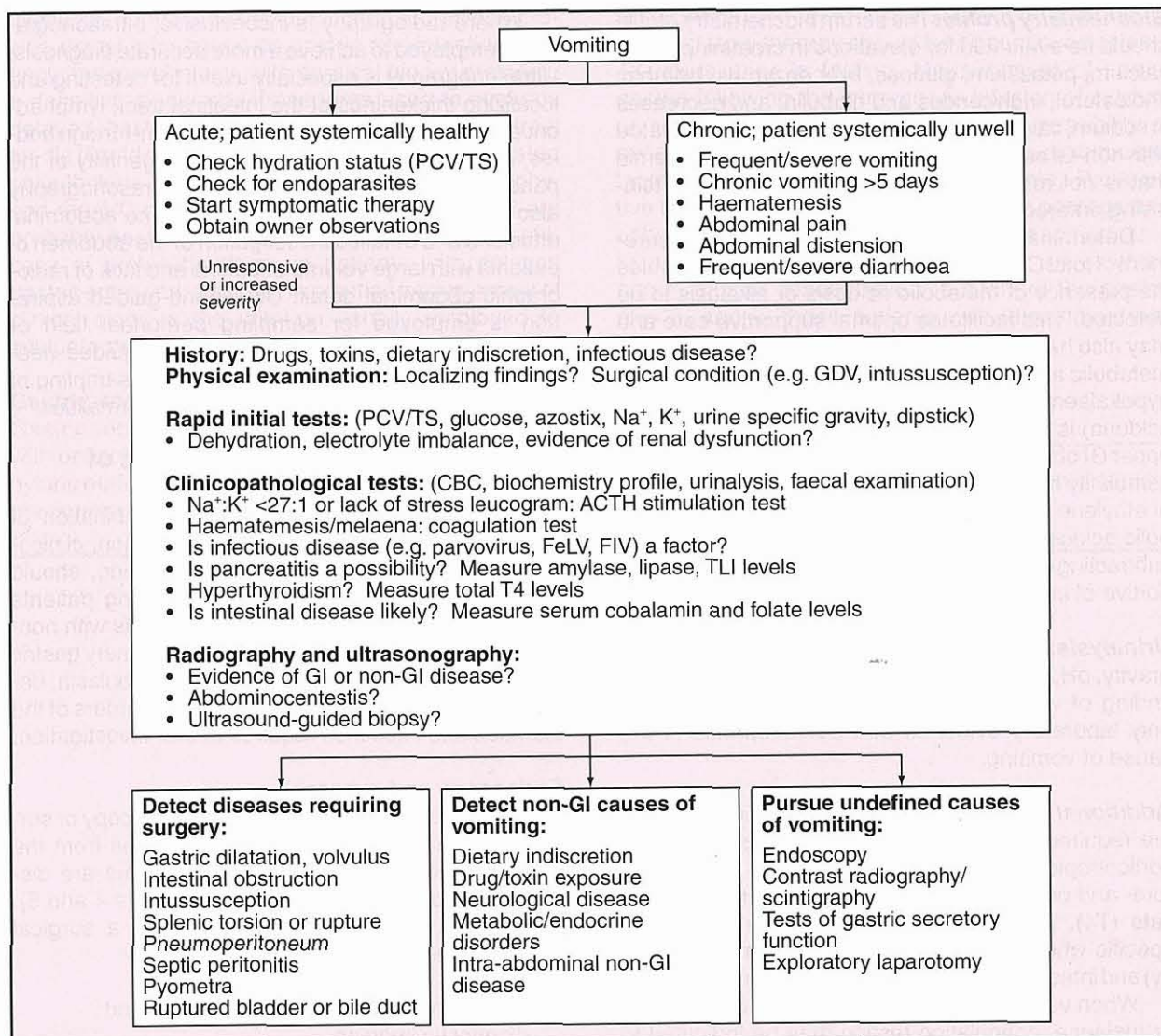
- Microhaematocrit (packed cell volume, PCV)
- Measurement of total solids (TS)
- Measurement of blood glucose
- Measurement of blood urea or creatinine
- Urinalysis (including urine specific gravity).

Plasma concentrations of sodium and potassium should also be determined where possible. These simple tests provide valuable information that helps to determine cause (e.g. azotaemia and unconcentrated urine suggests renal disease; Na<sup>+</sup>:K<sup>+</sup> <27:1 suggests hypoadrenocorticism) and guide initial management, pending more definitive testing. An interpretation of the results obtained from these rapid tests is given in Figure 7.4.

#### Clinicopathological testing

Clinicopathological testing is used to detect the causes and consequences of vomiting. It is very important that blood and urine samples submitted for analysis are obtained *prior* to treatment.

**Haematology:** A haematological examination may yield abnormalities such as anaemia (regenerative, non-regenerative), erythrocyte microcytosis, macrocytosis or basophilic stippling, and leucocytosis, leucopenia, eosinophilia or thrombocytosis that help to identify the cause of vomiting. For example, non-regenerative microcytic anaemia is relatively common in dogs with bleeding gastric tumours, whereas parvovirus infection is often associated with a leucopenia and neutropenia.



**7.3** Diagnostic approach to vomiting. ACTH = adrenocorticotrophic hormone; CBC = complete blood count; FeLV = feline leukaemia virus; FIV = feline immunodeficiency virus; GDV = gastric dilatation and volvulus; GI = gastrointestinal; PCV = packed cell volume; TLI = trypsin-like immunoreactivity; TS = total solids.

Test	Results	Possible interpretation	
<b>Azostix</b>	↑ Urea (>10 mmol/l)	Azotaemia: pre-renal (common with GI disease), renal, post-renal, GI bleeding	
<b>Glucostix</b>	Hypoglycaemia: (<2.75 mmol/l) Hyperglycaemia: (>7.0 mmol/l)	Sepsis; severe liver disease; hypoadrenocorticism; hepatoma; insulinoma; insulin overdose; diabetes mellitus; stress (particularly cats)	
<b>Urinalysis</b>	Urine SG <1.030 in a dehydrated dog or <1.035 in a dehydrated cat	Kidney must be suspected as a cause of, or a contributor to, the dehydration. Increased PCV/TS, high urine SG and pre-renal azotaemia are common in dehydrated patients	
<b>PCV/TS</b>	<b>PCV</b>	<b>TS</b>	
	↑	↑	Dehydration (common with vomiting, diarrhoea, gastroenteritis)
	↑	N or ↓	Splenic contraction; erythrocytosis; hypoproteinaemia; dehydration
	N	↑	Anaemia with dehydration; hyperproteinaemic disorder
	↓	↑	Anaemia with dehydration; anaemia with hyperproteinaemia
	↓	N	Non-whole blood-loss anaemia
N	N	Normal; acute haemorrhage; dehydration + anaemia + hypoproteinaemia	

**7.4** Interpretation of the rapid initial tests. GI = gastrointestinal; N = normal; PCV = packed cell volume; SG = specific gravity; TS = total solids.

**Biochemistry profile:** The serum biochemistry profile should be evaluated for elevations in creatinine, urea, calcium, potassium, glucose, liver enzymes, bilirubin, cholesterol, triglycerides and globulin, and decreases in sodium, calcium, urea or albumin that are associated with non-GI causes of vomiting. Panhypoproteinaemia that is not related to blood loss suggests a protein-losing enteropathy.

Determination of acid–base status by measurement of total CO<sub>2</sub> or venous blood gas analysis enables the presence of metabolic acidosis or alkalosis to be detected. This facilitates optimal supportive care and may also help to determine the cause of vomiting, e.g. metabolic alkalosis accompanied by hypochloreaemia, hypokalaemia and an acid urine (so called paradoxical aciduria) is highly suggestive of gastric outflow, or an upper GI obstruction. Venous blood gases and plasma osmolality are often determined in animals suspected of ethylene glycol ingestion, with the findings of metabolic acidosis and a high osmolal gap (calculated by subtracting calculated from measured osmolality) supportive of ingestion.

**Urinalysis:** Urine should be evaluated for specific gravity, pH, glucose, casts, crystals and bacteria. The finding of white cell casts in the urine may be the only laboratory evidence that pyelonephritis is the cause of vomiting.

**Additional tests:** Additional clinicopathological tests are required to detect hypoadrenocorticism (adrenocorticotrophic hormone stimulation), liver dysfunction (pre- and postprandial bile acids), hyperthyroidism in cats (T<sub>4</sub>), pancreatitis (amylase, lipase (pancreas-specific where possible), trypsin-like immunoreactivity) and intestinal disease (serum cobalamin and folate).

When vomiting is accompanied by haematemesis or melaena, coagulation testing may be indicated to determine whether coumadin derivatives have been ingested. Coagulation testing is also indicated in patients with an acute abdomen (e.g. GDV or pancreatitis) to detect disseminated intravascular coagulation and in those patients with chronic vomiting and diarrhoea, or weight loss, to detect vitamin K malabsorption.

Infectious diseases associated with vomiting and diarrhoea require faecal examination (e.g. *Giardia*, helminths, *Salmonella*, *Campylobacter*), an enzyme-linked immunosorbent assay (e.g. parvovirus) or serological testing (e.g. feline leukaemia, feline immunodeficiency virus) for diagnosis (see Chapter 16).

### **Diagnostic imaging**

Diagnostic imaging provides information that complements and extends clinicopathological testing. The primary diagnostic imaging modalities employed to investigate vomiting are abdominal radiography and abdominal ultrasonography (see Chapter 3). Radiography is preferred for the initial evaluation of cases with vomiting and acute abdomen (abdominal pain), as it provides information on gastric position and contents, size of the liver, kidneys and spleen, and may identify foreign bodies, GI obstruction, intussusception, peritonitis and changes suggestive of pancreatitis.

Where radiography is inconclusive, ultrasonography is employed to achieve a more accurate diagnosis. Ultrasonography is especially useful for detecting and localizing thickenings of the intestinal tract, lymphadenopathy, abdominal masses, radiolucent foreign bodies, and changes in the size and echogenicity of the pancreas, liver, kidneys or spleen. Ultrasonography also enables the detection of low-volume abdominal effusions and detailed investigation of the abdomen of patients with large volume effusions and lack of radiographic abdominal detail. Ultrasound-guided aspiration is employed for sampling peritoneal fluid or parenchymal abnormalities. Ultrasound-guided needle biopsy is also useful for non-invasive sampling of abdominal organs and parenchymal abnormalities.

### **Further investigation of GI causes of vomiting**

The above approach, employing a combination of patient details, history, physical examination, clinicopathological testing and diagnostic imaging, should enable the accurate diagnosis of vomiting patients requiring urgent surgery and those patients with non-GI causes of vomiting. The diagnosis of primary gastric or intestinal inflammation, ulceration or neoplasia, delayed gastric emptying, and functional disorders of the stomach and intestines requires further investigation.

### **Endoscopy and surgery**

Further investigations usually entail endoscopy or surgery to visualize and take biopsy samples from the stomach and intestines. These procedures are discussed in detail elsewhere (see Chapters 4 and 5). The choice of either an endoscopic or a surgical approach depends on the:

- Results of clinicopathological testing and diagnostic imaging
- Most likely cause of the vomiting
- Availability of endoscopic or surgical facilities.

For example, a dog with chronic vomiting and normal clinicopathological and imaging results has a high likelihood of having inflammatory bowel disease, and therefore, would be a good candidate for endoscopic visualization and biopsy of the stomach and small intestine. When endoscopy is not available a surgical biopsy could achieve the same result, but with higher morbidity. When the patient is a vomiting cat with abnormal liver enzymes, thickened intestines and an enlarged pancreas, then surgical biopsy is the most efficient means of determining the nature of disease, e.g. cholangiohepatitis, pancreatitis and inflammatory bowel disease or GI lymphoma.

### **Diagnostic imaging**

The ability of ultrasonography and endoscopy to detect obstructive, inflammatory and neoplastic diseases of the GI tract has meant that contrast radiographic procedures are often restricted to the investigation of delayed gastric emptying associated with defective propulsion, and 'functional' intestinal disorders. However, if endoscopy and ultrasonography are not

available, contrast radiographic procedures can provide useful information on gastric and intestinal patency and morphology, with surgical biopsy providing a definitive diagnosis. Procedures used to evaluate delayed gastric emptying include barium contrast media (liquid or mixed with food), barium impregnated polyethylene spheres (BIPS), nuclear scintigraphy, and the  $^{13}\text{C}$ -octanoate breath test. These tests are probably best used to determine accurately the efficacy of prokinetic drugs in patients with delayed gastric emptying, although in practice improvement of clinical signs is the criterion usually employed to evaluate therapeutic response.

**Gastric secretory testing**

Gastric secretory testing is often restricted to patients with oesophagitis, GI ulceration or hypertrophy of the pyloric outflow tract. In its simplest form it involves the measurement of fasting gastric pH and serum gastrin

to determine if acid hypersecretion is present. Antisecretory therapy should be discontinued at least 48 hours prior to testing. Measurement of serum gastrin following the intravenous infusion of calcium or secretin is used to investigate the possibility of exogenous gastrin production by pancreatic tumours, 'gastrinomas' (Zollinger–Ellison syndrome). Provocative testing of gastric acid secretion with pentagastrin or bombesin may be performed to detect achlorhydria in patients with atrophic gastritis, or an elevated serum gastrin concentration (but where the gastric  $\text{pH} > 3$ ), and in those patients with idiopathic small intestinal bacterial overgrowth.

**Treatment**

---

For information on the treatment of acute and chronic vomiting see Chapter 19.

---

# Acute diarrhoea

Michael S. Leib

## Introduction

Diarrhoea is defined as increased faecal fluidity, usually accompanied by an increased defecation frequency and volume of faeces.

An abrupt onset of diarrhoea that often lasts <7 days is a common problem in dogs and cats. Most cases are associated with mild clinical signs, are self-limiting, and require minimal diagnostic testing and therapy. However, diarrhoea may be unpleasant for the animal and inconvenient for the owner. The most common causes of acute diarrhoea are dietary indiscretion and gastrointestinal (GI) parasites. Life-threatening causes of diarrhoea, such as parvovirus, intussusception and haemorrhagic gastroenteritis (HGE), do occur and these require more intensive diagnostic evaluation and patient care.

Because there are numerous causes of acute diarrhoea in dogs and cats a thorough and logical diagnostic plan must be followed in order to obtain an accurate diagnosis and to administer appropriate therapy. This chapter reviews the practical clinical approach to the problem of acute diarrhoea in dogs and cats.

## Pathophysiology

There are four major mechanisms that can result in diarrhoea:

- Osmosis
- Hypersecretion
- Increased mucosal permeability
- Abnormal intestinal motility.

In most diarrhoeal diseases of dogs and cats multiple mechanisms contribute to diarrhoea. Because of the large daily physiological secretion from the salivary glands, stomach, small and large intestines, pancreas and liver, a large amount of fluid can be lost in the faeces when the small and/or large intestine do/does not function normally. Fluid loss is increased further when intestinal hypersecretion or increased mucosal permeability occurs. Osmotic causes and increased mucosal permeability are the most common mechanisms that occur in small animals with diarrhoea.

The number of osmotically active solutes retained within the bowel lumen determines faecal water content.

Osmotic diarrhoea occurs with many malabsorptive disorders where nutrients are not digested and absorbed normally, remain within the GI lumen and osmotically attract water. Retention of nutrients can lead to bacterial overgrowth and fermentation of carbohydrates, which further increases the number of osmotically active particles. Osmotic diarrhoea can also occur due to overeating, abrupt dietary changes and ingestion of spoiled foods containing poorly absorbed nutrients.

Excessive stimulation of crypt enterocytes results in secretion of large volumes of fluid that exceed the absorptive ability of the intestine. This occurs most commonly with infectious diseases, such as colibacillosis and salmonellosis, but metabolic products produced during bacterial overgrowth can also stimulate excessive intestinal secretion.

Increased mucosal permeability causes the loss of fluids, electrolytes, proteins and red blood cells into the intestinal lumen. Increased mucosal permeability commonly accompanies erosive or ulcerative, inflammatory and neoplastic processes, such as inflammatory bowel disease, hookworm infection and alimentary lymphosarcoma.

Abnormal motility is often a secondary problem in disorders that cause diarrhoea. Decreased segmental contractions result in transport of ingesta at a rate too rapid for efficient digestion and absorption. Metabolic products produced during bacterial overgrowth can also cause abnormal motility. Abnormal motility occurs in cases with inflammatory diseases, feline hyperthyroidism and following abdominal surgery.

Mild diarrhoea results in few metabolic consequences. However, moderate or profuse diarrhoea may lead to profound dehydration, hypovolaemic shock, electrolyte and acid-base disturbances. Hypokalaemia, hypochloraemia and hyponatraemia can develop. Metabolic acidosis develops secondary to loss of intestinal bicarbonate and dehydration leading to hypovolaemia, anaerobic metabolism and production of lactic acid. Death associated with many severe diarrhoeal disorders is not due to the primary cause but secondary to fluid imbalance.

## Clinical features

### History

The animal's clinical details and history may contain the information necessary to make a tentative diagnosis

or help rank the differential diagnosis. Young puppies and kittens, especially from rescue centres and pet stores, are prone to viral diseases, GI parasites and *Campylobacter jejuni*. The history may detect dietary indiscretion, potential exposure to foreign materials, chemicals, plants or toxins, administration of drugs (especially antibiotics), an incomplete vaccination or an inadequate worming programme, or recent exposure to other animals with diarrhoea. Dietary indiscretion can encompass a sudden diet change, ingestion of a low quality diet, table scraps and treats or free-roaming behaviour with the potential for garbage consumption.

**Clinical signs**

Acute diarrhoea often originates from small intestinal disease or from mixed small and large bowel disease (see Chapter 1). On occasion, signs of large bowel disease only may be present. Signs of small bowel diarrhoea include melaena, normal to moderate increased frequency of defecation and production of a large volume of faeces per defecation. Signs of large bowel diarrhoea include haematochezia, tenesmus, excess faecal mucus, moderate to greatly increased frequency of defecation and a reduced volume of faeces per defecation. In many cases vomiting, depression, decreased appetite and abdominal discomfort may be present.

Physical examination may detect gas and/or fluid distended bowel segments and abdominal pain. In some cases an abdominal mass or dilated loop of bowel may be identified, suggesting the possibility of a foreign body or intussusception. Dehydration may be indicated by dry mucous membranes, a loss of skin turgor, prolonged capillary refill time, enophthalmos or cold extremities. Assessment of the degree of dehydration is imprecise and should be used only as an estimate. An animal must be at least 5% dehydrated before it can be clinically detected by mild changes in the physical characteristics previously listed. More pronounced alterations in these parameters indicate moderate dehydration (7–9%), while extreme alterations indicate severe dehydration (10–12%) approaching hypovolaemic shock (tachycardia and weak peripheral pulses).

Other clinical signs may be related to a systemic cause of diarrhoea and include pyrexia, icterus, ascites, lymphadenopathy, oliguria/anuria, hepatomegaly, ocular and nasal discharge and coughing (Figure 8.1).

**Differential diagnosis**

Figure 8.2 lists the differential diagnoses for acute diarrhoea in dogs and cats.

**Diagnosis**

The most important initial step in evaluating animals with acute diarrhoea is to classify them as having a self-limiting or potentially life-threatening problem (Figure 8.3). This distinction is crucial as it guides the level of

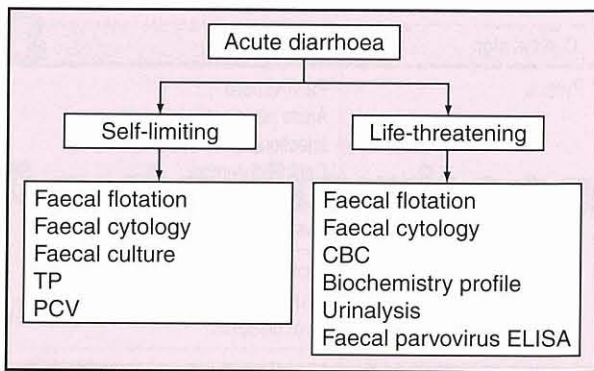
Clinical sign	Disease
Pyrexia	Parvoviruses Acute pancreatitis Infectious canine hepatitis Canine distemper Leptospirosis Liver diseases
Icterus	Leptospirosis Acute pancreatitis Liver diseases
Ascites	Liver diseases Infectious canine hepatitis Feline infectious peritonitis
Lymphadenopathy	Infectious canine hepatitis Salmon poisoning
Oliguria/anuria	Acute renal failure Leptospirosis
Ocular and nasal discharge	Canine distemper
Cough	Canine distemper Infectious canine hepatitis

**8.1** Clinical signs associated with systemic diseases that cause acute diarrhoea.

Self-limiting	
Dietary indiscretion	Diet change; garbage; table scraps; foreign material; chemicals and toxins; plants
Parasites	Hookworms; roundworms; <i>Giardia</i> ; coccidia; whipworms
Coronavirus	
Drugs	Non-steroidal anti-inflammatory drugs; digoxin; antibiotics; corticosteroids; magnesium antacids; cancer chemotherapeutics
<i>Clostridium perfringens</i>	
Idiopathic	
Life-threatening	
Severe dietary indiscretion	
Severe parasitism	Hookworms; whipworms
Intestinal obstruction	Foreign body; intussusception
Parvoviruses	
Haemorrhagic gastroenteritis	
Systemic diseases	Acute pancreatitis; acute liver diseases (infectious canine hepatitis); acute renal failure (leptospirosis); canine distemper; salmon poisoning
Bacteria	<i>Salmonella</i> ; <i>Campylobacter</i> ; <i>Clostridium perfringens</i>

**8.2** Differential diagnoses for acute diarrhoea.





**8.3** Diagnostic approach to acute diarrhoea. CBC = complete blood count; ELISA = enzyme-linked immunosorbent assay; PCV = packed cell volume; TP = total protein.

diagnostic testing and therapy needed and should be based on a thorough history, careful physical examination, clinical experience and judgement and a sound understanding of the differential diagnosis of acute diarrhoea (see Figure 8.2). Animals should be considered to have a potentially life-threatening problem if some of the following are present: moderate to severe dehydration; abdominal pain; depression; melaena or haematochezia; palpable abdominal mass or dilated loop of bowel; frequent vomiting; or signs of systemic diseases (see Figure 8.1). If the distinction is not clear it is better to be cautious and initially assume the animal has a life-threatening problem.

**Self-limiting diarrhoea**

A minimum database for self-limiting diarrhoea includes multiple faecal examinations (with zinc sulphate; see Chapter 2), faecal culture, faecal cytology, and measurement of total protein and haematocrit, which will help assess hydration and provide baseline values that can be used for comparison if clinical signs persist or progress. If dietary indiscretion is present, removal of the incriminating factors and/or feeding a highly digestible diet that is low in fibre and moderately low in fat for 3–5 days often resolves the diarrhoea. If GI parasites are detected, diarrhoea should improve after appropriate anthelmintic treatment in 2–3 days.

Faecal cytology may identify many ‘safety pin’ shaped bacterial spores that may indicate the presence of *Clostridium perfringens* enterotoxigenesis (see Chapter 16). If present, a faecal sample can be submitted for enterotoxin identification. If an aetiology is not detected, a diagnosis of acute idiopathic self-limiting diarrhoea may be made. Symptomatic therapy is often followed by resolution of clinical signs within 1–3 days. If diarrhoea persists, worsens, or if additional clinical signs develop, a life-threatening problem may exist requiring more thorough diagnostic evaluation and intensive therapy.

**Life-threatening diarrhoea**

A diagnostic plan for life-threatening cases includes multiple faecal examinations, faecal cytology, complete blood count, biochemistry profile, urinalysis, abdominal radiography and a faecal enzyme-linked immunosorbent assay (ELISA) for parvovirus in puppies. Faecal examination may identify parasites that could be the cause of

the diarrhoea or contribute to its severity. Faecal cytology may show increased numbers of neutrophils, ‘seagull’ shaped bacteria (*Campylobacter*), or ‘safety pin’ shaped spores (*Clostridium perfringens*), suggesting a faecal sample should be submitted for bacterial culture or enterotoxin analysis.

Abnormalities detected on the laboratory evaluation should help to rank the differential diagnosis (Figure 8.4). In addition, laboratory tests will help assess

Laboratory abnormality	Disease
Decreased total protein	Hookworms Whipworms Canine parvovirus Haemorrhagic gastroenteritis (late) <i>Salmonella</i>
Anaemia	Canine parvovirus Haemorrhagic gastroenteritis (late)
Elevated haematocrit	Haemorrhagic gastroenteritis
Neutrophilia	Acute pancreatitis Liver diseases Infectious canine hepatitis (late) <i>Salmonella</i> (late) Leptospirosis (late) <i>Campylobacter</i> Salmon poisoning
Neutropenia	Canine parvovirus Feline parvovirus Leptospirosis Infectious canine hepatitis <i>Salmonella</i> Salmon poisoning
Lymphopenia	Canine parvovirus Feline parvovirus Canine distemper Infectious canine hepatitis <i>Salmonella</i>
Eosinophilia	Gastrointestinal parasites
Hypoglycaemia	Canine parvovirus <i>Salmonella</i>
Increased alanine aminotransferase and alkaline phosphatase	Acute pancreatitis Liver diseases Infectious canine hepatitis Leptospirosis
Hyperbilirubinaemia	Acute pancreatitis Liver diseases Leptospirosis
Increased urea, creatinine and phosphorus	Acute renal failure Leptospirosis
Hypocalcaemia	Acute pancreatitis
Increased amylase, lipase, trypsin-like immunoreactivity and pancreatic lipase immunoreactivity	Acute pancreatitis
Increased prothrombin and partial thromboplastin times	Infectious canine hepatitis Liver diseases Feline parvovirus
Proteinuria	Acute renal failure Infectious canine hepatitis Leptospirosis

**8.4** Laboratory abnormalities associated with cause of life-threatening diarrhoea.

the severity of dehydration and electrolyte abnormalities and allow a rational plan for fluid therapy to be developed. Survey abdominal radiographs may demonstrate an abdominal mass, dilated loop of bowel, intussusception or foreign body obstruction, which require surgical therapy. In some cases, additional diagnostic tests may be indicated to definitively diagnose a specific disorder (e.g. liver biopsy for hepatic diseases, serum titre for leptospirosis) or pursue diagnosis if a cause for the diarrhoea is not yet evident (e.g. upper GI barium series, abdominal ultrasonography, faecal culture).

### **Treatment and prognosis**

The treatment for diarrhoea is dependent on the underlying cause; and further information can be found in Chapters 16, 20 and 28.

The prognosis for cases of self-limiting diarrhoea is excellent. However, the prognosis for those with life-threatening disorders is variable and depends on the underlying cause, the severity of fluid and metabolic derangement, and the response to initial therapy. Animals with heavy parasitism and severe dietary indiscretion should improve with diligent care. Most puppies and

kittens with parvovirus and dogs with HGE will survive with aggressive care. Survival of patients with small bowel obstruction due to foreign body ingestion or intussusception is dependent upon the severity of intestinal damage, the presence of peritonitis, the severity of secondary metabolic consequences and the timing of corrective surgery. Bacterial causes are usually associated with a good prognosis while systemic causes of acute life-threatening diarrhoea are usually associated with a poor prognosis.

### **References and further reading**

- Hansen B and DeFrancesco T (2002) Relationship between hydration estimate and body weight change after fluid therapy in critically ill dogs and cats. *Journal of Veterinary Emergency and Critical Care* 12, 235-243
- Jergens A (1995) Acute diarrhea. In: *Kirk's Current Veterinary Therapy XII*, ed. JD Bonagura, pp. 701-705. WB Saunders, Philadelphia
- Leib MS and Matz ME (1997) Diseases of the intestines. In: *Practical Small Animal Internal Medicine*, ed. MS Leib and WE Monroe, pp. 685-760. WB Saunders, Philadelphia
- Moon H (1978) Mechanisms in the pathogenesis of diarrhea: a review. *Journal of the American Veterinary Medical Association* 172, 443-448
- Twedt DC (1992) *Clostridium perfringens*-associated enterotoxigenesis in dogs. In: *Current Veterinary Therapy XI*, ed. JD Bonagura and RW Kirk, pp. 602-604. WB Saunders, Philadelphia
- Whipp SC (1978) Physiology of diarrhea. *Journal of the American Veterinary Medical Association* 173, 662-666

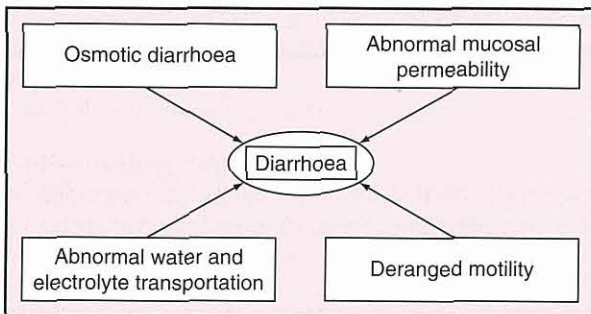
# Chronic diarrhoea

Albert E. Jergens

## Introduction

Diarrhoea is the most common clinical manifestation of intestinal disease.

Diarrhoea is defined as increased frequency, fluidity or volume of bowel movements, and is most often characterized by duration (acute *versus* chronic) or aetiology (Figure 9.1).



**9.1** A simplified concept of the pathophysiology of diarrhoea. Osmotic causes and altered intestinal permeability are most clinically prevalent in dogs and cats.

In simple terms, diarrhoea results from diseases affecting the small intestine, large intestine or the distal large bowel and rectum. It is noteworthy that diarrhoea may or may not accompany other clinical signs of intestinal disease. Animals may present with alterations in appetite, ranging from polyphagia to complete anorexia. Weight loss is often associated with nutrient malabsorption as a consequence of diffuse mucosal disease. Vomiting occurs with a variety of upper gastrointestinal (GI) disorders and is especially prevalent in animals with inflammatory bowel disease (IBD). Colorectal diseases are often associated with tenesmus, dyschezia and large bowel diarrhoea characterized by the presence of fresh blood and mucus on stools. Chronic diarrhoea is particularly challenging to the clinician, since most animals will not respond to empirical therapies, necessitating a well formulated, cost-effective diagnostic plan. Specific treatment is necessary and is most often based on a definitive diagnosis or histopathological characterization subsequent to intestinal biopsy.

## Clinical features

### History

The investigation of chronic diarrhoea should always start with history-taking and a physical examination (see Chapter 1). This will ensure that systemic causes of chronic diarrhoea are not missed and, where primary disease is present, indicate whether small or large intestinal disease exists.

The history provides important clues for determining the potential cause(s) of chronic diarrhoea. Key questions that should be addressed include the following:

- What is the clinical course of the diarrhoea; is it static, cyclical or progressive?
- What are the faecal characteristics; can the diarrhoea be localized to the small or large bowel (Figure 9.2)?
- Is there an association with diet, such as recent dietary change, a history of dietary indiscretion or possible adverse reactions to food?
- Is the patient on any medications that might cause diarrhoeic episodes?
- Has the animal responded to previous drug therapies?

Symptom	Small bowel	Large bowel
Dyschezia	Absent	May be present
Faecal frequency (motions per day)	Less than 3	More than 6
Faecal mucus	Rare	Often present
Faecal volume	Increased	Decreased
Flatus/borborygmi	Present	Absent
Fresh blood	Uncommon	Common
Melaena	May be present	Rare
Steatorrhoea	May be present	Absent
Tenesmus	Absent	Often present
Urgency	Usually none	Often present
Vomiting	May be present	May be present
Weight loss	Common	Rare

**9.2** Differentiation of small *versus* large bowel diarrhoea by clinical signs.

- Is the diarrhoea associated with other GI signs such as weight loss, vomiting or anorexia?
- Is there evidence suggesting a systemic cause for the animal's diarrhoea, such as hypoadrenocorticism, renal dysfunction or hepatobiliary disease?

Localizing the site of the intestinal dysfunction to either the small or large intestine expedites a diagnosis, since the diagnostic investigation of small and large bowel diarrhoea are suitably different. Several diffuse diseases (e.g. IBD, histoplasmosis, lymphosarcoma) of the GI tract may produce concurrent small and large bowel signs, and occasionally gastric signs, such as vomiting, may also be present.

**Physical examination**

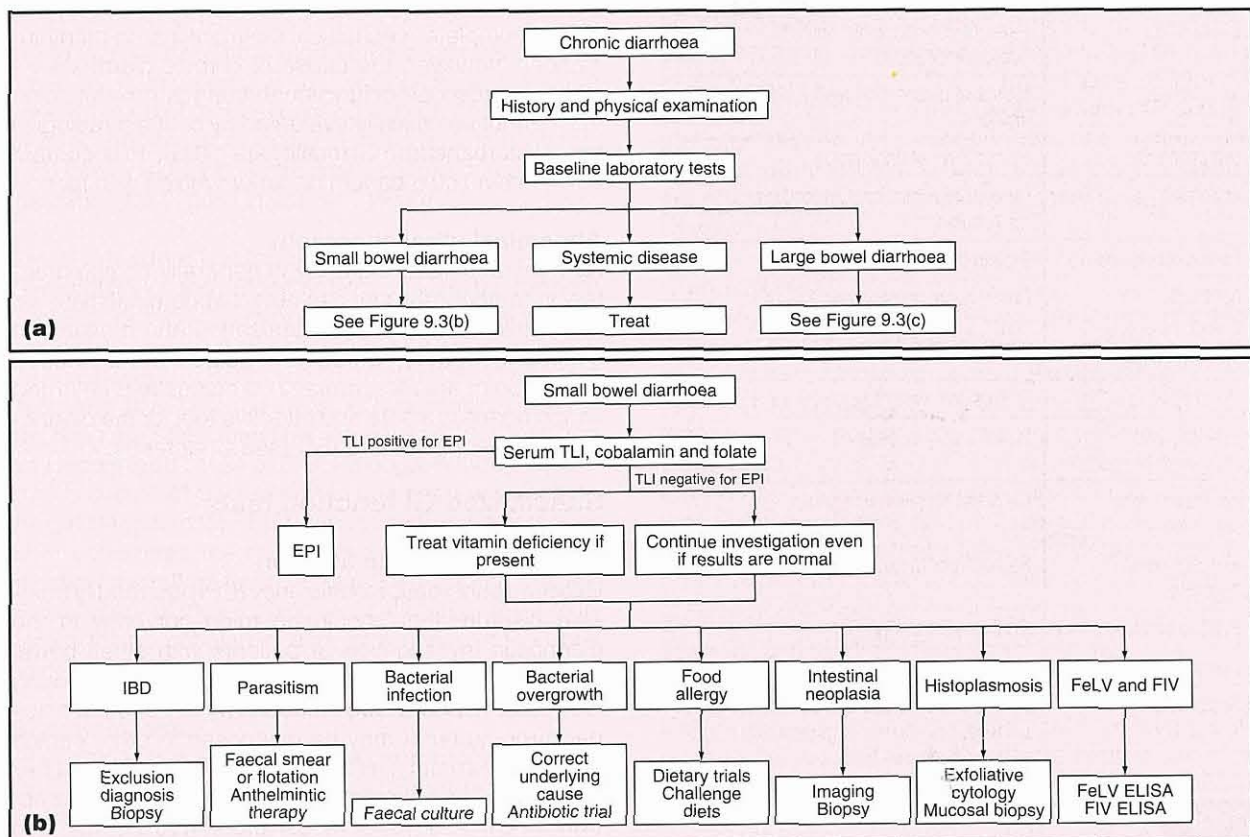
A thorough physical examination may reveal important information concerning the origin and severity of chronic diarrhoea. Special attention should be placed on the presence of:

- Emaciation/malnutrition (suggestive of chronic malabsorption or a protein-losing enteropathy, PLE)
- A dull unthrifty general appearance (indicative of nutrient malassimilation)
- Fever (seen with infectious diseases)
- Oedema and effusions (secondary to PLE)
- Mucous membrane pallor (as a consequence of GI blood loss).

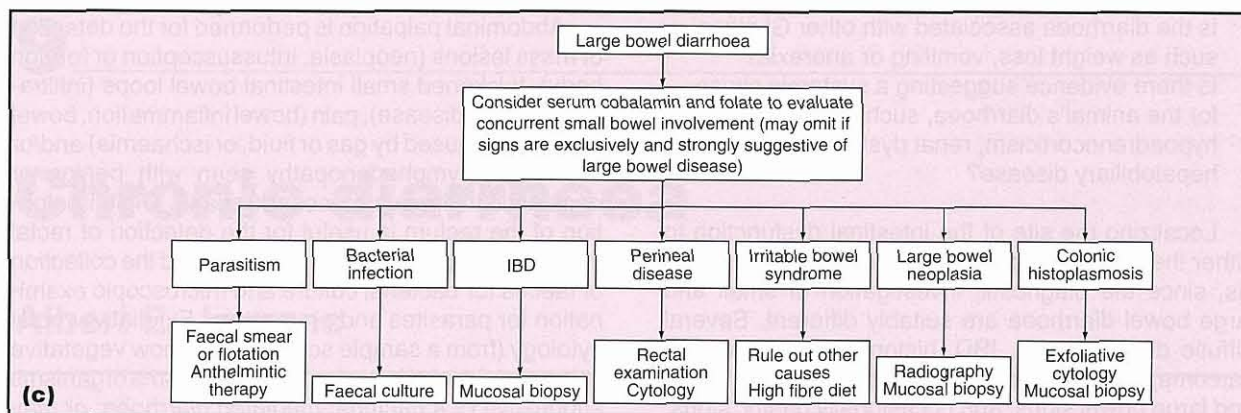
Abdominal palpation is performed for the detection of mass lesions (neoplasia, intussusception or foreign body), thickened small intestinal bowel loops (infiltrative mucosal disease), pain (bowel inflammation, bowel distension caused by gas or fluid, or ischaemia) and/or mesenteric lymphadenopathy seen with benign or neoplastic infiltrative mucosal disease. Digital palpation of the rectum is useful for the detection of rectal masses, retroperitoneal obstruction, and the collection of faeces for bacterial culture and microscopic examination for parasites and protozoans. Exfoliative rectal cytology (from a sample scrape) may show vegetative spores (clostridial infection) or *Histoplasma* organisms suggestive of a bacterial-mediated diarrhoea; or may show an increase in the number of faecal leucocytes (neutrophils) or immune cells suggestive of an immune-mediated diarrhoea.

**Diagnosis**

The common causes of chronic diarrhoea and the diagnostic procedures routinely employed for the evaluation of such patients are shown in Figure 9.3. Strategies for determining the cause of chronic diarrhoea begin with a clinical examination and baseline laboratory tests, the results of which may indicate that imaging, specialized GI function tests and/or endoscopic examination with mucosal biopsy are required.



**9.3** Diagnostic approach to chronic small and large bowel diarrhoea. ELISA = enzyme-linked immunosorbent assay; EPI = exocrine pancreatic insufficiency; FeLV = feline leukaemia virus; FIV = feline immunodeficiency virus; IBD = inflammatory bowel disease; TLI = trypsin-like immunoreactivity. (continues)



**9.3** (continued) Diagnostic approach to chronic small and large bowel diarrhoea. ELISA = enzyme-linked immunosorbent assay; EPI = exocrine pancreatic insufficiency; FeLV = feline leukaemia virus; FIV = feline immunodeficiency virus; IBD = inflammatory bowel disease; TLI = trypsin-like immunoreactivity.

**Baseline laboratory tests**

Baseline laboratory tests should be performed to determine whether primary GI or metabolic/systemic disorders are causing the diarrhoea. In most instances this will involve a complete blood count (CBC), biochemistry profile, urinalysis, and faecal examinations for parasites and infectious agents. Baseline testing may also include specialized assays for common disorders known to have chronic diarrhoea as a salient sign (e.g. serum thyroxine level in older cats with diarrhoea and weight loss, for exclusion of hyperthyroidism). Potential key findings and their cause are summarized in Figure 9.4.

Key finding	Causes
Eosinophilia	Parasitism; eosinophilic enteritis; hypoadrenocorticism
Neutrophilia	Infiltrative mucosal disease ± ulcers or erosions
Lymphopenia	Intestinal lymphangiectasia
Anaemia	Chronic inflammation; GI blood loss; malnutrition
Panhypoproteinaemia	Protein-losing enteropathy
Apothecia	Dehydration; primary renal failure
Hyperkalaemia/hyponatraemia	Hypoadrenocorticism
Hypokalaemia	GI fluid and electrolyte loss; anorexia
Elevated liver enzymes/bile acids	Hepatobiliary disease
Increased urea/creatinine	Dehydration; primary renal failure
Elevated serum thyroxine	Feline hyperthyroidism
Positive serology	Confirms FeLV, FIV, FIP
Faecal flotation/smear	Nematode or protozoan parasites
Rectal cytology	Spores and/or WBCs with enteropathogenic bacteria; <i>Histoplasma</i> organisms; immune cells (as seen with IBD)

**9.4** Results of diagnostic procedures and their possible aetiology. FeLV = feline leukaemia virus; FIP = feline infectious peritonitis; FIV = feline immunodeficiency virus; GI = gastrointestinal; IBD = inflammatory bowel disease; WBC = white blood cell.

**Diagnostic imaging**

**Survey abdominal radiography**

Survey abdominal radiographs are useful for the detection of intestinal mass lesions or abnormal fluid–gas patterns suggestive of mechanical obstruction (foreign body or intussusception). They may also demonstrate gross alterations in the size, shape or location of the liver and kidney, as well as detect abdominal effusion, abdominal masses and evidence of pancreatitis.

**Upper GI tract contrast radiography**

Upper GI tract contrast radiography is indicated for the evaluation of mucosal abnormalities (irregularity, filling defects, mural distortion) and the presence of partial and/or complete mechanical obstructions. In many instances, however, the cause of chronic diarrhoea involves microscopic or functional changes in the intestine that cannot be critically evaluated by contrast radiography. Disturbances in GI motility are difficult to document using either liquid barium or barium mixed with food.

**Abdominal ultrasonography**

Abdominal ultrasonography is generally complementary to radiography and can detect abdominal masses, mural thickenings or disorganization and mesenteric lymphadenopathy. Ultrasound-guided percutaneous aspiration of masses, mural thickenings and enlarged lymph nodes is a safe and effective tool for the diagnosis of GI neoplasia and IBD (see Chapter 3).

**Specialized GI function tests**

**Exocrine pancreatic function**

Exocrine pancreatic insufficiency (EPI) is a readily treatable disorder that should be ruled out early in the diagnostic investigation of patients with small bowel diarrhoea. EPI should be considered especially in young German Shepherd Dogs (secondary to pancreatic acinar atrophy) but it may be diagnosed in other canine breeds and in cats. The best method for diagnosis of EPI is a species-specific assay of trypsin-like immunoreactivity (TLI). Assays of faecal proteolytic activity with azocasein hydrolysis are sensitive but are too cumbersome and impractical to recommend in a clinical setting. Microscopic examination of Sudan- and iodine-stained

faecal smears for excessive fat and undigested starch, respectively, is notoriously unreliable and is actively discouraged (see Chapter 23).

#### Serum folate and cobalamin

Serum concentrations of folate and cobalamin (vitamin B12) reflect intestinal absorptive function and help localize the site of dysfunction. Serum folate reflects absorptive function of the proximal small bowel (i.e. jejunum) while serum cobalamin depends on absorption in the distal small intestine (i.e. ileum). Therefore, low serum folate levels reflect impaired absorption in the proximal small intestine and low serum concentrations of cobalamin are suggestive of enteropathies causing impaired absorption in the distal small bowel. Diffuse mucosal disorders (lymphoma, IBD) may cause decreased serum concentrations of both folate and cobalamin. Reduction in the serum concentration of either vitamin may reflect a deficiency state, and consideration should be given to replacement therapy as part of overall patient management. Alterations in serum folate and/or cobalamin concentrations are less reliable indicators of small intestinal bacterial overgrowth (SIBO) or antibiotic-responsive diarrhoea (ARD) (see Chapter 20).

#### Intestinal permeability and mucosal function

Changes in mucosal permeability and function as a consequence of diffuse small intestinal disease may alter absorption of orally administered sugars (see Chapter 2). Testing involves the administration of a combination of monosaccharides and disaccharides that are then recovered from the patient's urine. In diseases such as IBD, less surface area is available for monosaccharide permeation while disaccharide permeability is increased. Thus, with disease the urine concentration of monosaccharides is greater than that of disaccharides. If mucosal function testing is abnormal, intestinal biopsy is usually required to determine the cause for altered intestinal function.

#### Small intestinal bacterial overgrowth

Overgrowth of the upper small intestine by resident bacterial organisms may cause malabsorption and chronic diarrhoea. A variety of diverse structural (e.g. stasis caused by mechanical obstruction) and functional (e.g. infiltrative disease causing hypomotility) lesions involving the small intestine can cause SIBO. EPI is a well recognized cause of SIBO in dogs. Although quantitative culture of duodenal fluid has been regarded as the gold standard for SIBO, controversy now exists over what constitutes the normal canine and feline small intestinal microflora (see Chapter 20). Furthermore, the clinical utility of indirect biochemical marker tests (e.g. serum folate, cobalamin and total unconjugated bile acids) for SIBO has not been reliably proven.

#### GI protein loss

GI protein loss is a normal daily occurrence. However, the term PLE denotes a spectrum of chronic intestinal diseases that cause excessive loss of plasma proteins into the gut. PLE is most common in the dog and is usually due to lymphangiectasia (e.g. loss of protein-rich lymph secondary to lymphatic hypertension) or

infiltrative mucosal disease (e.g. severe IBD, alimentary lymphoma or GI histoplasmosis), which can increase intestinal permeability and result in protein leakage. The measurement of  $\alpha_1$ -proteinase inhibitor in the faeces is a sensitive indicator of intestinal protein loss in dogs (see Chapter 2). This assay is a useful diagnostic tool to detect enteric protein loss in humans, but is not widely used in veterinary clinical medicine because of its limited availability. For this reason assessing intestinal permeability using sugar probes and measuring serum protein levels can assist in determining intestinal protein loss.

#### Endoscopic examination and intestinal biopsy

Endoscopic examination with mucosal biopsy is required for definitive diagnosis and to provide prognostic information for patients with chronic diarrhoea once dietary, parasitic, infectious and systemic/metabolic causes have been excluded. When performing upper GI endoscopy or colonoscopy, multiple (at least 10) mucosal biopsy specimens should always be procured, regardless of mucosal appearance. Furthermore, it is imperative that biopsy tissues be forwarded to a pathology service skilled in the handling, processing and diagnostic interpretation of such specimens (see Chapter 5).

#### Upper GI endoscopy

Upper GI endoscopy (e.g. duodenoscopy) performed with a flexible endoscope allows for: visual assessment of the duodenum and/or proximal jejunum (in small dogs and all cats); targeted biopsy of the intestinal mucosa for histopathological review; and sampling for exfoliative cytology. The normal duodenal appearance varies from pale pink to yellow and has a slightly granular texture. Alterations in mucosal texture (increased granularity), increased friability and erosions are often seen with infiltrative mucosal diseases (see Chapter 4).

#### Colonoscopy

Colonoscopy with a flexible endoscope is performed for visualization of the colonic lumen, targeted biopsy of the colonic mucosa and procurement of exfoliative cytological samples. Occasionally, retrograde ileoscopy is performed in some dogs when proximal intestinal biopsy is inadequate and/or examination or biopsy of the ileal mucosa is needed. The normal colonic mucosa appears smooth, and pale pink and contains abundant submucosal blood vessels that are readily visualized in the dog. Abnormal mucosal appearances caused by colitis include increased granularity, increased friability, erosions and masses (see Chapter 4).

#### Exploratory coeliotomy

Exploratory coeliotomy allows visual inspection, palpation and procurement of multiple biopsy samples from the abdominal organs. This diagnostic procedure is most useful in the retrieval of full-thickness intestinal mucosal specimens when endoscopic biopsy fails to deliver a definitive diagnosis (e.g. differentiation of severe IBD from GI lymphoma).

**Treatment**

---

For information on the treatment of chronic diarrhoea see Chapter 28.

**References and further reading**

---

Guilford WG (1996) Approach to clinical problems in gastroenterology. In: *Strombeck's Small Animal Gastroenterology, 3<sup>rd</sup> edn*, ed. WG

Guilford *et al.*, pp. 50–76. WB Saunders, Philadelphia  
Jergens AE (1999) Inflammatory bowel disease: current perspectives. *Veterinary Clinics of North America: Small Animal Practice* **29**, 501–521  
Sherding RG and Johnson SE (2000) Diseases of the intestines. In: *Saunders Manual of Small Animal Practice, 2<sup>nd</sup> edn*, ed. SJ Birchard and RG Sherding, pp. 787–815. WB Saunders, Philadelphia  
Zoran D (1999) Pathophysiology and management of canine colonic diseases. *Compendium on Continuing Education for the Practicing Veterinarian* **21**, 824–841

---

# Malabsorption

David A. Williams

## Introduction

Diseases in which digestion of food and/or subsequent net absorption of nutrients are defective are traditionally classified as either primary failure to digest (maldigestion), or primary failure to absorb (malabsorption). This classification is misleading however, since the digestive and absorptive processes are inextricably linked and failure of absorption is an inevitable consequence of defective digestion.

For example, most patients with exocrine pancreatic insufficiency (EPI) have associated abnormalities of small intestinal function and most diseases affecting the small intestine (SI) will inevitably impair the terminal processes of digestion that take place at

the luminal surface of the intestinal mucosa. It is therefore preferable to use the term malabsorption as a global one to encompass all aspects of impaired digestion and absorption.

Utilizing this broad definition of malabsorption, it is useful to categorize diseases by the site of the primary abnormality as premucosal (intraluminal), mucosal or postmucosal (haemolymphatic) (Figure 10.1). Associated pathophysiological mechanisms can also be categorized as to whether premucosal, mucosal or postmucosal phases of absorption are compromised (Figure 10.2). It is important to recognize, however, that additional factors (such as defective gastrointestinal (GI) motility or immunological function) may also be involved, and that intraluminal, mucosal and haemolymphatic abnormalities often coexist.

Location of primary abnormality	Representative diseases
Premucosal defect (intraluminal defect)	Exocrine pancreatic insufficiency Small intestinal bacterial overgrowth (antibiotic-responsive diarrhoea)
Mucosal defect	Inflammatory bowel diseases: idiopathic infectious enteropathies (parasitic, fungal, bacterial, others) dietary sensitivities Villous atrophy Neoplastic infiltration Intestinal resection (short bowel syndrome) Brush border enzyme or carrier deficiencies (congenital)
Postmucosal defect (haemolymphatic defect)	Primary (congenital) intestinal lymphangiectasia Secondary (acquired) intestinal lymphangiectasia Vascular failure (cardiac failure, portal hypertension)

### 10.1 Classification of malabsorptive disorders.

Phase of absorptive process	Pathophysiological mechanism	Examples of disease process
Premucosal (luminal)	Defective substrate hydrolysis: enzyme deficiency enzyme inactivation rapid intestinal transit	Exocrine pancreatic insufficiency Gastric acid hypersecretion Hyperthyroidism
	Defective solubilization of fat: decreased bile salt secretion bile salt deconjugation bile salt loss impaired release of pancreatic secretagogue	Biliary obstruction Bacterial overgrowth Resection or disease of terminal ileum Severe small intestinal disease
	Intrinsic factor deficiency	Exocrine pancreatic insufficiency
	Bacterial competition for cobalamin	Bacterial overgrowth

### 10.2 Pathophysiological mechanisms of malabsorption. (continues)



Phase of absorptive process	Pathophysiological mechanism	Examples of disease process
Mucosal	Brush border enzyme deficiency: congenital defects acquired defect secondary to diffuse enteropathies	Enteropeptidase; lactase (humans)
	Brush border transport deficiency: selective defects generalized defects	Inherited selective cobalamin malabsorption Inflammatory bowel diseases; villus atrophy intestinal resection
	Enterocyte processing defects	Abetalipoproteinaemia (humans)
	Disruption of lamina propria	
Postmucosal (haemolymphatic)	Lymphatic obstruction: primary lymphangiectasia secondary (acquired) lymphatic obstruction	Neoplasia; infiltrative infectious or inflammatory disease
	Vascular failure	Intestinal ischaemia; intestinal vasculitis; portal hypertension

**10.2** (continued) Pathophysiological mechanisms of malabsorption.

Depending on the mechanisms in play, one or many nutrients may be malabsorbed resulting in a variety of potential clinical consequences (Figure 10.3). With long-standing disease there may be a spectrum of abnormalities, including weight loss, diarrhoea, muscle wasting, coagulopathy, skin and haircoat changes, anaemia and hypoproteinaemia. While documented reports of specific nutrient deficiencies are rare, both vitamin K and cobalamin deficiencies have been reported.

Nutrient	Potential clinical signs	Laboratory abnormalities
Fat	Diarrhoea; weight loss	Steatorrhoea
Protein	Weight loss; muscle wasting; oedema	Hypoalbuminaemia
Carbohydrate	Weight loss; diarrhoea; flatulence; borborygmi	Positive hydrogen breath test
Cobalamin	Anorexia; subnormal serum cobalamin; intestinal dysfunction	Subnormal serum cobalamin concentration; methylmalonic aciduria and aciduria
Folate	Diarrhoea; anaemia	Subnormal serum folate
Vitamin K	Coagulopathy	Prolonged prothrombin and/or activated partial thromboplastin times
Vitamin A	Hyperkeratosis; night blindness; impaired immunological function	
Vitamin D	Osteomalacia	
Vitamin E	Retinal degeneration; myopathy; myelopathy	Oxidant-induced haemolytic anaemia
Calcium	Tetany (very rare)	Hypocalcaemia
Zinc	Anorexia; zinc responsive dermatosis	Subnormal serum zinc
Iron	Anaemia	Increased red cell width distribution; hypochromasia; microcytosis

**10.3** Clinical and laboratory sequelae to nutrient malabsorption.

## Defects of premucosal function (intraluminal malabsorption)

### Exocrine pancreatic insufficiency

#### Primary exocrine pancreatic failure

Progressive loss of pancreatic acinar cells ultimately leads to malabsorption due to inadequate production of digestive enzymes (Figure 10.4). Activity of pancreatic lipase may also be compromised by gastric acid hypersecretion and deficiency of bile acids (see below). The aetiology, pathophysiology, diagnosis and treatment of the primary causes of EPI are discussed in detail in Chapter 23.

Factors	Causes
Decreased synthesis (reduced functional acinar cell mass)	Pancreatic acinar atrophy Chronic pancreatitis Pancreatic or extrapancreatic neoplasia Congenital enzyme deficiency
Decreased secretion (reduced pancreatic stimulation)	Decreased secretagogue release with severe enteropathies
Decreased zymogen activation	Enteropeptidase (enterokinase) deficiency (hypothetical in dogs and cats)
Decreased enzyme cofactors	Bile salt deficiency Co-lipase deficiency
Increased enzyme degradation	Small intestinal bacterial overgrowth
Enzyme inactivation or denaturation	Gastric acid hypersecretion

**10.4** Factors that may decrease pancreatic enzyme activity in the lumen of the small intestine.

#### Inactivation of pancreatic digestive enzymes

When hypersecretion of gastric acid is extreme (specifically in Zollinger–Ellison syndrome, in which there is hypergastrinaemia due to a gastrin-secreting tumour, see Chapter 19) SI intraluminal pH can be sufficiently acidic to inactivate proteases reversibly and denature

pancreatic lipase irreversibly. This results in fat malabsorption. Therapy to inhibit gastric acid secretion will normalize pancreatic digestive enzyme activity.

## Bile salt insufficiency

### Deficient bile salt secretion

Normal digestion and absorption of dietary fat is dependent on adequate secretion of bile. Bile acids participate in the emulsification of fat, in the activation (with co-lipase) of pancreatic lipase, and in the formation of micelles that facilitate transfer of the products of fat digestion to the intestinal mucosa. Absence of bile salts does not completely block fat absorption; other mechanisms facilitate as much as approximately 50% of normal fat absorption but steatorrhoea is more dramatic in the absence of pancreatic lipase. Nonetheless, sufficient intra-hepatic and extra-hepatic biliary obstruction due to any cause will cause mild to moderate malabsorption of fat and fat-soluble vitamins.

Complete obstruction of the biliary tract results not only in systemic icterus due to hyperbilirubinaemia, but also in pale (acholic) faeces because of the lack of bile pigments in the gut lumen. Faecal colour is due mainly to products of bile pigment metabolism. Only small amounts of bile are needed to produce brown faeces and thus acholic faeces are only produced when the bile duct is totally obstructed (see Chapters 14 and 25). While stool colour can provide clues as to the patency of the biliary tree, it should be noted that faecal colour also varies with diet, intestinal transit time and antibiotic therapy.

Reduced hepatic bile salt secretion may sometimes occur with hepatocellular liver disease in the absence of jaundice and can also lead to fat malabsorption. However, abnormalities in fat absorption are usually subtle under these circumstances, more commonly manifesting as reduced absorption of fat-soluble vitamins (vitamins K and E) rather than overt steatorrhoea. In general, patients with liver disease have many other potentially severe problems (other than those due to malabsorption) and these are discussed in Chapters 24 and 25.

### Bile salt deconjugation

Fat malabsorption may occur in patients with small intestinal bacterial overgrowth (SIBO). Conjugated bile acids exist as fully ionized, water-soluble bile salts at neutral pH. In this form they participate in micelle formation and remain free in the lumen of the upper SI, since they are not absorbed across the intestinal mucosa until they contact specific receptors in the ileum. Bacteria in the gut lumen, particularly obligate anaerobic bacteria, can deconjugate bile acids to form protonated (non-ionized, lipid-soluble) free bile acids that are readily absorbed by passive means along the entire length of the SI, rendering them relatively ineffective or unavailable to participate in micelle formation. Antibiotic therapy in SIBO will normalize bile salt activity. Diagnosis of SIBO is difficult and is discussed below and in Chapter 20.

### Bile salt precipitation

Some drugs, including neomycin, cause precipitation of bile salts so that they are ineffective in micelle formation. Glycine-conjugated bile acids also precipitate out of solution when the pH falls below 5.0. In addition, fatty acids are protonated when the pH is less than 6.0 and have poor solubility in bile salt micelles, an additional factor contributing to fat malabsorption in gastric acid hypersecretory states.

### Bile salt loss

When there is severe ileal disease or following ileal resection, bile acid resorption fails and this results in bile acid induced diarrhoea; bile acid binding drugs (such as colestyramine) may help diarrhoea resolve in these circumstances. However, chronic bile acid malabsorption may eventually lead to progressive depletion of the circulating bile acid pool, an inadequate intraluminal concentration of bile acids, and fat malabsorption. In these circumstances supplementation with oral bile acids will ameliorate steatorrhoea and diarrhoea.

### Bile salt binding

Cholestyramine is a drug that specifically binds bile salts and is used to inhibit bile salt induced diarrhoea. However, it renders bile salts ineffective in fat absorption and, when used in excess, results in steatorrhoea.

### Small intestinal bacterial overgrowth

SIBO describes the absolute or relative proliferation of abnormal numbers of one or more species of bacteria in the lumen of the upper SI. The abnormal microflora usually include species that are normal inhabitants of that area, but may also include species not normally present in the upper SI. The abnormal microflora may predispose to malabsorption by several mechanisms including:

- Direct injurious effects on brush border enzymes and carrier proteins
- Secretion of enterotoxins
- Deconjugation of bile acids
- Hydroxylation of fatty acids
- Competition for nutrients.

Via a combination of primary intraluminal and secondary mucosal mechanisms, SIBO leads to malabsorption of fat, fat-soluble vitamins, carbohydrate and protein. Bacterial competition for some nutrients (especially cobalamin), decreased brush border enzyme activities and damage to carrier proteins are probably of major importance in the failure of these absorptive processes. Protein-losing enteropathy associated with SIBO also contributes to progressive protein depletion, muscle wasting and possibly eventual hypoproteinaemia. The pathophysiology, diagnosis and treatment of SIBO and antibiotic-responsive diarrhoea are discussed extensively in Chapter 20.

### **Defects of mucosal function (mucosal malabsorption)**

---

It is important to remember that mucosal disease of the SI results in failure of digestion as well as defective absorption. The mechanisms are multifactorial, but probably most commonly involve reduced synthesis or increased degradation of the brush border carbohydrases and peptidases that normally complete the digestive process. Normal digestion and absorption may also be compromised by reduced brush border enzymes due to a decreased villus or microvillus surface area.

The most common cause of chronic malabsorption in the dog and cat is idiopathic chronic inflammatory bowel disease. In a small minority of cases underlying or associated dietary sensitivity, or SIBO can be identified. Occasionally villus atrophy with a minimal inflammatory component is seen. Diffuse neoplastic infiltration may be seen with intestinal lymphosarcoma. In some geographical areas a variety of fungal and other infectious enteropathies, such as histoplasmosis and phycosporidiosis, may be encountered, while parasitic enteropathies, such as that caused by *Giardia*, are widely recognized as common causes of malabsorption. Resection of large lengths of the SI may lead to significant nutrient malabsorption (short bowel syndrome).

Cobalamin deficiency may exacerbate malabsorption because of impaired maturation of the enterocyte during migration to the villus tip: Although specific inherited cobalamin malabsorption (reported in the Giant Schnauzer, Beagle and Border Collie) is recognized, acquired cobalamin deficiency (such as may occur in SIBO) is far more common.

Laboratory findings and potential clinical sequelae of mucosal malabsorption are summarized in Figure 10.3. Diagnosis and management of specific causes of malabsorption are described in the chapters on infectious

and parasitic intestinal diseases (see Chapter 16), small intestinal disease (see Chapter 20) and exocrine pancreatic insufficiency (see Chapter 23).

### **Defects of postmucosal function (postmucosal malabsorption)**

---

#### **Lymphatic obstruction**

Obstruction of the lymphatic system, either as a primary defect or secondary to pressure changes in the vasculature into which the lymphatic vessels drain (as in heart failure), leads to impaired absorption of chylomicrons (and hence steatorrhea), lymphocytes and extracellular fluid proteins present in lymph. In some cases, accelerated loss of these proteins can overwhelm the limited capacity for compensatory increases in synthesis of albumin and other proteins, and panhypoproteinaemia ensues. Diagnosis and management of these lymphatic disorders are discussed further in Chapter 20.

#### **Vascular diseases**

Chronic portal hypertension secondary to liver disease (cirrhosis), intestinal vasculitis, thrombosis or neoplastic infiltration may lead to nutrient malabsorption and perhaps enteric protein loss. Intestinal ischaemia may also cause malabsorption. Diagnosis and management of these vascular disorders are discussed in relation to protein-losing enteropathy in Chapter 20.

### **References and further reading**

---

- Williams DA (1996) Malabsorption, small intestinal bacterial overgrowth, and protein-losing enteropathy. In: *Small Animal Gastroenterology*, ed. DR Strombeck *et al.*, pp. 367–380. WB Saunders, Philadelphia

# Gastrointestinal haemorrhage

Michael D. Willard

Gastrointestinal (GI) haemorrhage may be signalled by haematemesis, melaena, haematochezia, anaemia or hypovolaemia.

## Haematemesis

Haematemesis (vomiting of blood) can be difficult to recognize. While fresh red blood is easily identified by clients, digested blood is typically a particulate, brown material resembling 'coffee grounds' that is not appreciated as blood (Figure 11.1). Therefore, not explaining the appearance of digested blood is inviting the client to give an inaccurate history.



**11.1** Typical appearance of digested blood that has been vomited. Note the 'coffee-grounds'-like appearance.

Haematemesis can be due to:

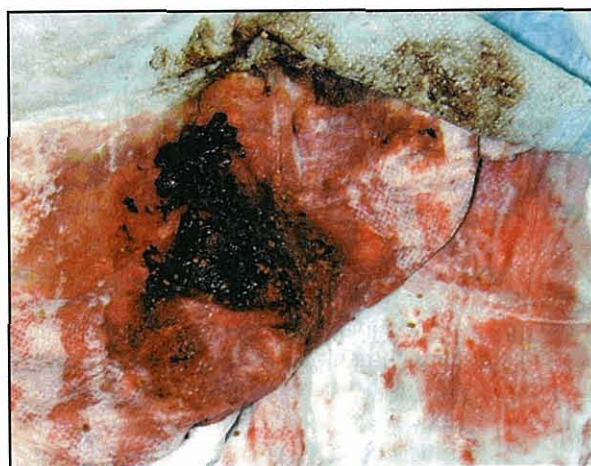- Lesions in the oesophagus, stomach or duodenum
- Ingestion of blood from the mouth, nose or lower respiratory tract
- Coagulopathy.

## Clinical features

The first question is whether haematemesis is clinically significant. Vomiting is a relatively violent act, and repeated vomiting often ruptures superficial gastric mucosal vessels, resulting in small reddish flecks in the vomited material (Figure 11.2). Such haematemesis is an effect of vomiting and not a cause for alarm. Larger amounts of fresh or digested blood (Figure 11.3) or



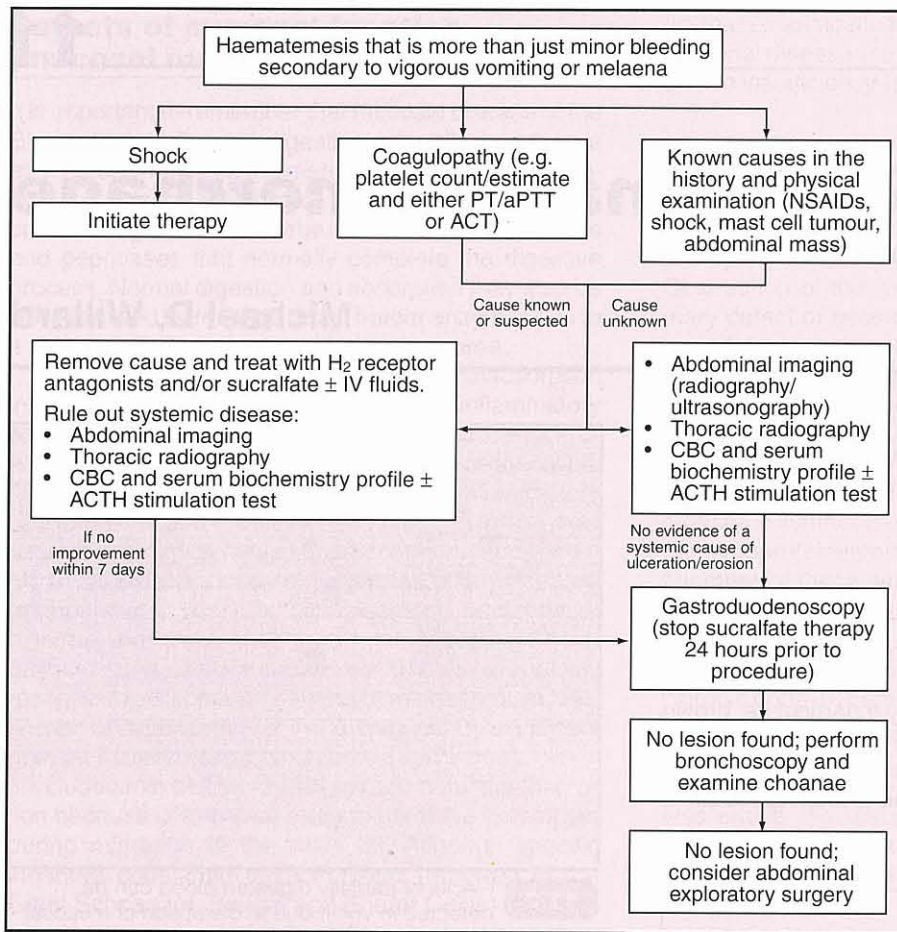
**11.2** Flecks of partially digested blood can be detected in vomit due to disruption of mucosal vessels. This disruption was caused by repeated, vigorous vomiting.



**11.3** Vomited material that contains substantial amounts of red blood as well as partially digested blood. Note black material in centre.

evidence of anaemia or hypovolaemia require attention (Figure 11.4).

History and physical examination are the first steps. The possibility of ingestion of blood should be sought in the history. Coagulopathies are uncommon causes but potentially catastrophic; the platelet count and coagulation times should always be checked. After coagulopathy and ingestion of blood are eliminated, gastroduodenal ulceration/erosion (GUE) is the main consideration.



**11.4** Basic diagnostic approach to the patient with haematemesis and melaena. ACT = activated clotting time (not available in the UK); ACTH = adrenocorticotropic hormone; aPTT = activated partial thromboplastin time; CBC = complete blood count; NSAID = non-steroidal anti-inflammatory drug; PT = prothrombin time.

**Differential diagnosis**

The most common causes of canine GUE are non-steroidal anti-inflammatory drugs (NSAIDs), shock, gastritis, mast cell tumours and ulcerated GI tumours. Oesophageal foreign bodies, hepatic failure, hypoadrenocorticism, gastrinoma and gastric foreign bodies are also possible. Newer COX-2 NSAIDs have less ulcerogenic potential than the older, non-selective NSAIDs, but can still cause GUE. Some steroids (e.g. dexamethasone) clearly have ulcerogenic potential while others (e.g. prednisolone) have much less potential. Concurrent administration of steroids and NSAIDs greatly increases the risk of GUE. Cats uncommonly have GUE associated with lymphosarcoma or gastritis.

**Diagnosis**

The veterinary surgeon should also examine the vomitus if possible. While using a urine dipstick on apparently vomited material may help determine whether it is from vomiting or regurgitation (acidic pH indicating gastric content, the presence of bilirubin indicating duodenal juice), almost all such material will cause a positive reaction for blood due to the meat products in most diets. Thus, such a reaction is not accurate for determining if haematemesis is present.

**Diagnostic imaging**

Abdominal ultrasonography is relatively specific but insensitive for detecting bleeding GI lesions. Chest radiography may reveal oesophageal tumours or foreign bodies.

If imaging is unrevealing, then gastroduodenoscopy is usually the next diagnostic step, being the most sensitive test for GUE, foreign bodies and bleeding tumours.

**Endoscopy**

Endoscopic examination reveals many gastric lesions missed during laparotomies and even gastrotomies. Sucralfate should not be administered within 24 hours of endoscopy as it may obscure lesions. The endoscopist must be skilled; ulcers just within the pylorus or at the cardia are often missed by novices.

Respiratory tract lesions (e.g. nasal or lung tumours, lung lobe torsion) can cause blood to be coughed up, swallowed and then vomited. If gastroduodenoscopy fails to reveal a lesion then bronchoscopy and examination of the choanae is often a reasonable next step, even if there are no respiratory signs.

**Laparotomy**

If a laparotomy is performed the entire alimentary tract should be examined and palpated, even if there is an obvious gastric lesion. If no lesions are found, multiple biopsy samples from the stomach and intestines are warranted. Looking for blood in the lumen may help localize the lesion.

**Treatment**

If the patient is haemodynamically stable and there is an obvious, potentially treatable cause of GUE (e.g. NSAID administration, severe shock) it is usually

reasonable to perform minimal diagnostics (e.g. haematology, serum biochemistry profile, coagulation tests) and then manage the patient medically. Medical treatment of GUE consists of:

- Giving a blood transfusion if necessary
- Removing the cause whenever possible
- Symptomatic therapy with sucralfate and acid blockers ( $H_2$  receptor antagonists) to enhance healing.

It is typically futile to treat GUE medically if the cause persists. Gastric foreign bodies typically prevent GUE healing, even if they did not cause the ulceration. Some clinical improvement is expected within 5–7 days of initiating symptomatic therapy. If there is no improvement after 5–7 days of therapy, or the haemorrhage is potentially life-threatening, then a more aggressive approach is indicated. This may include diagnostics and/or surgical removal of the ulcer. When ulcers are removed surgically, presurgical (or intra-operative) endoscopy helps ensure that all are found and removed.

### Melaena

Melaena (i.e. 'coal-black' stool resembling asphalt) can be due to anything causing bleeding in the upper GI tract and consequently it can be difficult to determine and resolve the cause. Many things cause stools to be 'dark', for example eating raw liver can mimic melaena. However, 'asphalt-black' stools are caused by large amounts of digested blood or administration of bismuth compounds. Because large amounts of blood are required to produce melaena, it is absent in many animals with substantial GI bleeding. If it is uncertain whether a dark stool is melaenic, a fresh sample of the stool should be put on a white paper towel. If the stool is melaenic, a reddish tint will be seen as fluid diffuses away from the faeces (Figure 11.5). The diagnostic approach to melaena is the same as for haematemesis (see Figure 11.4). Treatment will depend on the underlying cause.

### Haematochezia

Haematochezia is commonly seen with colitis, proctitis, trichuriasis, rectal polyps, tumours and anal sac disease. Intussusception or coagulopathy are rarely



**11.5** Normal faeces covered with black digested blood (melaena). Note the red colour as the faecal fluid diffuses out from the faeces.

responsible. If the haematocrit is relatively normal and there is no sign of hypovolaemia, then haematochezia should be approached as for any large bowel/rectal problem (see Chapter 12). Digital rectal examination *must* be done, even if it requires anaesthesia. If that is unrewarding, imaging or colonoscopy/biopsy usually provide a definitive diagnosis. Treatment will depend on the underlying cause.

### Anaemia and hypovolaemia

Some patients with GI haemorrhage do not have haematemesis, melaena or haematochezia; they are just anaemic or hypovolaemic. Anaemia caused by GI haemorrhage is usually associated with hypoalbuminaemia. Serum albumin concentrations should always be measured; hyperglobulinaemic animals may have normal total serum protein concentrations despite substantial blood loss. Microcytosis and hypochromasia (i.e. iron deficiency) are sometimes seen with chronic, not acute, blood loss. Checking blood smears and examining the red cell distribution width are more sensitive than evaluating the mean corpuscular volume (MCV) when looking for microcytosis. Total serum iron concentration and total iron binding capacity are potentially difficult to interpret when looking for iron deficiency anaemia. However, in dogs, assessing iron stores in a bone marrow aspirate is a relatively easy way to determine whether an iron deficiency is present. If there is apparent GI blood loss without haematemesis, melaena or haematochezia, the approach is as for haematemesis (see Figure 11.4). Treatment will depend on the underlying cause.

# Dyschezia and tenesmus

Albert E. Jergens

## Introduction

Dyschezia and tenesmus are clinical signs usually associated with colorectal diseases.

- Dyschezia describes difficult or painful defecation, which is most commonly observed with recto-anal disorders.
- Tenesmus is a clinical sign characterizing an animal that is straining to defecate (common) or urinate (less common).

Tenesmus is usually due to large bowel disease, in particular colitis (Figure 12.1). Straining is evident as an animal remains postured to defecate for an extended period or time, or repeated attempts to defecate are observed. Tenesmus is often associated with other clinical signs of colonic disease including large bowel diarrhoea (e.g. increased frequency of defecation, the production of scant faecal volumes), haematochezia (fresh red blood on the faeces) and/or excessive faecal mucus (see Chapter 21).

### Colonic disorders

Constipation  
Colitis  
Neoplasia  
Motility abnormalities, such as irritable bowel syndrome (IBS)

### Perianal/perineal disorders

Perineal hernia  
Perineal fistula  
Anal sac abscess  
Anal sac neoplasia

### Urogenital disorders

Cystitis and urethritis  
Urinary calculi  
Prostatomegaly, such as hyperplasia, neoplasia and abscessation  
Urogenital neoplasia

### Caudal abdominal disorders

Abdominal cavity masses  
Pelvic fracture

**12.1** Major causes of tenesmus and dyschezia. (Modified from Guilford, 1996)

## Clinical features

### History

A history pertaining to both the urinary system and the gastrointestinal (GI) tract in patients with tenesmus should always be obtained (see Chapter 1). Besides tenesmus, lower urinary tract disorders (especially cystitis or urethritis) often result in haematuria and pollakiuria, which are readily apparent to most clients. Normal urinary habits are most suggestive of tenesmus caused by colorectal disorders. Tenesmus preceding defecation usually indicates an obstructive lesion, whereas irritative disorders are often associated with persistent tenesmus following evacuation.

### Physical examination

The physical examination provides important localizing information as to the potential cause(s) of dyschezia and tenesmus.

- The perineal region is carefully examined for perineal hernia, perianal fistula, abnormalities to the anal sacs (inflammation, rupture, tumour) and perianal masses.
- Abdominal palpation may suggest a large turgid bladder (indicative of urinary obstruction), a faecal impacted colon (indicative of constipation) or prostatomegaly.
- Rectal examination is performed to rule out colonic stricture (rare), intraluminal masses (polyps or malignant tumours), abnormalities of the anal sacs, prostate or urethra, and caudal abdominal cavity disorders (mass, pelvic fracture).
- The penis and vagina are also closely examined by the clinician for evidence of pain, masses or calculi.

## Diagnosis

Diagnostic procedures are based on localization of tenesmus to abnormalities involving the genitourinary or GI tract. Diagnostic tests that may be required to rule out non-colonic causes for tenesmus include:

- Urinalysis
- Cultures of urine or prostatic fluid
- Survey and/or contrast radiography

- Abdominal ultrasonography
- Urethroscopy
- Biopsy of the genitourinary tract.

However, most patients with tenesmus will have underlying disturbances of the colon or rectum necessitating GI testing (Figure 12.2).

Procedure	Clinical use
History	Localizes site of tenesmus
Physical examination	Localizes site of tenesmus
Perineal inspection	Recto-anal disease
Routine haematology	Eosinophilic colitis; endoparasitism
Faecal flotation	Trichuriasis
Faecal direct smear	<i>Giardia</i> ; <i>Entamoeba</i>
Faecal rectal cytology	Bacterial colitis; histoplasmosis; IBD; clostridial spores
Faecal culture	Enteropathogenic bacteria
Serum antibody/antigen tests	FelV; FIV infection
Abdominal radiography	Constipation; foreign bodies; prostatomegaly; intussusception; colonic mass
Pneumocolon	Intussusception; colonic mass
Ultrasonography	Mural thickening; mesenteric lymphadenopathy; intussusception; prostatomegaly; urinary neoplasia
Colonoscopy	IBD; colonic neoplasia; polyps; intussusception
Laparotomy	Abdominal masses; biopsy and correction

**12.2** Diagnostic procedures for evaluation of tenesmus. FelV = feline leukaemia virus; FIV = feline immunodeficiency virus; IBD = inflammatory bowel disease. (Modified from Guilford, 1996)

### Faecal analysis

The examination of multiple faecal samples for parasites is recommended in all cases: some nematode parasites with low fecundity, such as *Trichuris vulpis*, may yield false-negative results on a single faecal examination. Evaluation of direct smears of saline-admixed fresh faeces for protozoan parasites, such as *Giardia* or *Entamoeba histolytica*, may also be helpful. Cytological examination of a faecal smear or rectal scrape (preferred) should be performed for detection of protozoans, *Histoplasma* organisms, vegetative spores supportive of *Clostridium perfringens* enterotoxigenesis, or inflammatory cells indicative of colitis. Large numbers of faecal leucocytes (neutrophils) may be seen in animals with bacterial causes for colitis. Cytology of fine needle aspiration samples from rectal and perineal masses may allow rapid identification of neoplasms.

Faecal cultures are indicated in animals suspected of having bacterial-mediated diarrhoea. Culture of faeces for *Salmonella* or *Campylobacter* is important in patients that develop large bowel diarrhoea subsequent to kennelling or procurement from animal holding

facilities. However, accurate interpretation of faecal culture results is confounded by the isolation of potential pathogens (*Escherichia coli*, *Campylobacter*, *Salmonella*, *Clostridium*) in both diarrhoeic and healthy animals.

### Diagnostic imaging

Diagnostic imaging consisting of survey radiography, air-filled enemas and/or ultrasonography is sometimes utilized for animals with colorectal causes for tenesmus (see Chapter 3). These techniques help to confirm colonic foreign bodies, faecal impaction, intraluminal masses, ileocolic intussusception and mesenteric lymphadenopathy associated with both benign (e.g. inflammatory bowel disease) and malignant (e.g. lymphoma, adenocarcinoma) infiltrative mucosal diseases. In animals suspected of having genitourinary causes for tenesmus, survey and contrast radiography and ultrasonography are useful in detecting prostatomegaly, urinary masses, urinary obstruction and abdominal masses.

### Colonoscopy

Colonoscopy with mucosal biopsy is indicated in animals with chronic colitis (see Chapter 4). In these instances, most patients have failed routine empirical therapies for their GI signs, requiring definitive diagnosis and specific therapy. The clinician may choose one of two endoscopic options:

- Rigid proctoscopy, which allows evaluation of only the rectum and descending colon
- Flexible endoscopy, which permits detailed examination of all colonic regions up to the ileocolic region.

Advantages of full colonoscopy include direct visualization of the proximal colonic regions, the ability to obtain targeted biopsy samples under endoscopic guidance, and the ability of the clinician to perform retrograde ileoscopy (if needed) for small bowel biopsy and interventional procedures (e.g. stricture dilatation, polypectomy). Biopsy of the colonic mucosa is always performed and facilitates characterization of the disease process such that treatment and prognostic recommendations may be made to the client.

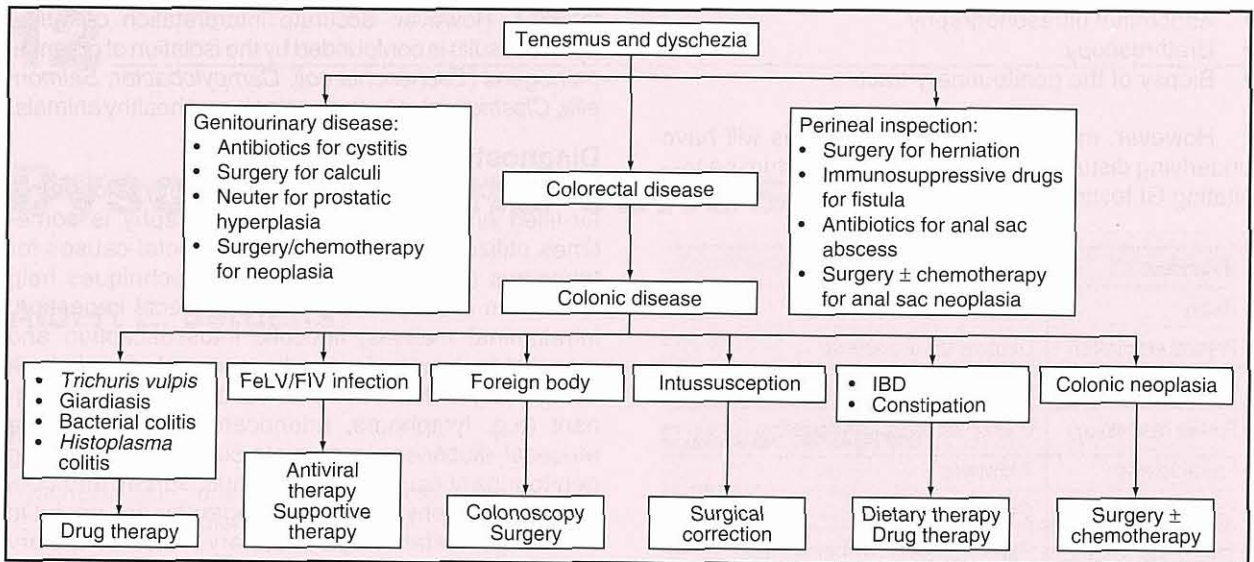
### Baseline laboratory tests

Baseline laboratory tests consisting of a complete blood count (CBC), biochemistry profile and urinalysis should be performed in animals having tenesmus associated with systemic signs (e.g. anorexia, weight loss, dehydration). These tests may also identify incidental problems in other systems of the body, facilitate choice of fluid therapy, and aid in the identification of other GI problems such as infectious, parasitic and eosinophilic colitis.

### Treatment

A general treatment strategy for animals with tenesmus and dyschezia is given in Figure 12.3. Further information on treatment can be found in Chapters 21, 22 and 28.





**12.3** General treatment strategies for animals with tenesmus and dyschezia. FeLV = feline leukaemia virus; FIV = feline immunodeficiency virus; IBD = inflammatory bowel disease.

**References and further reading**

Guilford WG (1996) Approach to clinical problems in gastroenterology. In: *Strombeck's Small Animal Gastroenterology, 3<sup>rd</sup> edn*, ed. WG

Guilford *et al.*, pp. 50–76. WB Saunders, Philadelphia  
 Sherding RG and Johnson SE (2000) Diseases of the intestines. In: *Saunders Manual of Small Animal Practice, 2<sup>nd</sup> edn*, ed. SJ Birchard and RG Sherding, pp. 787–815. WB Saunders, Philadelphia

# Ascites

Edward J. Hall

## Introduction

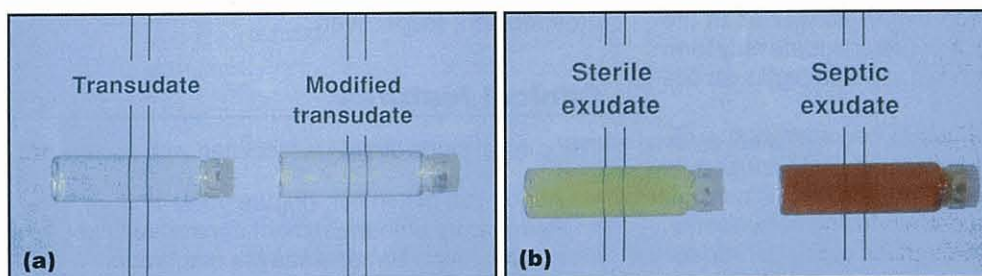
Ascites is a pathological accumulation of free fluid within the peritoneal cavity (from the Greek *askos* = bag, *-ites* = like a; syn. hydroperitoneum, dropsy).

Strictly, ascitic fluid is serous in nature and is classified, depending on its protein and cellular content composition (Figures 13.1 and 13.2), into the following categories:

- Transudate
- Modified transudate
- Exudate.

In addition, the term ascites has been broadened to include fluid accumulations (Figure 13.3) primarily composed of:

- Bile
- Blood
- Chyle
- Urine.



**13.1** Gross appearance of (a) a transudate and modified transudate and (b) sterile and septic exudates. A crude distinction can be made by the clarity of an image viewed through the fluid.

Serous ascitic fluids	Transudate	Modified transudate	Exudate
Clarity	Clear	Slightly cloudy	Often cloudy; serosanguineous
Urine specific gravity	<1.017	1.017–1.025	>1.025
Protein (g/l)	<25	25–50	>25
Nucleated cells (per mm <sup>3</sup> )	<2500	<7000	>7000
Cytology		Mainly macrophages and mesothelial cells	Reactive mesothelial cells Septic: neutrophils; macrophages; intracellular bacteria Non-septic: lymphocytes; macrophages Carcinomatosis: malignant cells

**13.2** Characteristics of serous ascitic fluids.

Non-serous ascitic fluids	Colour and smell	Content	Cytology
Bile	Yellow/brown/green	Bilirubin	Variable
Blood	Red Serosanguineous	Haemoglobin Blood	Red blood cells
Chyle	Cloudy white/cream Cream layer on standing	Triglyceride > plasma Cholesterol < plasma	Lymphocytes Fat globules
Urine	Yellow Uriferous	Creatinine > plasma Urea $\approx$ plasma	

**13.3** Characteristics of non-serous ascitic fluids.

## Pathophysiology

The different types of ascitic fluid may accumulate due to:

- An imbalance in Starling's law that governs tissue fluid formation and removal, i.e.
  - decreased colloid osmotic pressure in plasma (transudate)
  - increased hydrostatic pressure in venous and/or lymphatic drainage (transudate, modified transudate)
  - increased vascular permeability (exudate)
- Leakage from a vessel (i.e. blood, chyle)
- Leakage from a viscus (i.e. bile, urine).

Thus, ascites is a reflection of one, or a combination of different, pathophysiological mechanisms.

### Hypoalbuminaemia

Albumin is the major source of plasma colloid osmotic pressure, and a very low serum albumin concentration leads to formation of a pure transudate in the extravascular space. This process will begin at any point after the serum concentration falls below approximately 15 g/l. The fluid may accumulate in the pleural space (hydrothorax) or tissues (oedema), as well as in the peritoneal cavity (ascites). A pure transudate may form at one or more of these sites but at which particular site is unpredictable.

Reduction in serum albumin concentration sufficient to give rise to ascites is most likely caused by protein loss, either through the gastrointestinal (GI) mucosa into the faeces (a protein-losing enteropathy, PLE; see Chapter 20) or through the glomeruli into the urine (a protein-losing nephropathy, PLN). Failure of hepatic albumin synthesis may also lead to ascites. This is sometimes seen with congenital portosystemic shunts, but chronic hepatopathies more frequently cause ascites through a combination of reduced serum albumin concentration and portal hypertension.

### Portal hypertension

Increased venous hydrostatic pressure in the portal vasculature leads to formation of ascites; there is accompanying bowel wall oedema and often diarrhoea. The site of origin of the portal hypertension determines the nature of the ascitic fluid because the permeability of blood vessels varies.

- Pre-hepatic obstruction to portal blood flow (i.e. before it reaches the liver) tends to produce fluid low in protein (transudate) because capillaries in the splanchnic bed are relatively impermeable to proteins.
- Conversely, post-hepatic obstruction to portal blood flow causes accumulation of protein-rich fluid because the sinusoids and lymphatics within the liver are lined with a fenestrated endothelium and are permeable to albumin. The fluid produced is usually categorized as a modified transudate because of its protein content, although it can be argued that it is really a protein-rich transudate as it is not actually modified after formation; its

protein content reflects the fact that the vascular permeability is naturally high.

- Consequently, with intra-hepatic obstruction to portal blood flow, the protein content of any ascitic fluid varies depending on where within the liver the site of the obstruction occurs. Perihilar/periportal fibrosis is likely to cause a low-protein ascites, whilst central vein fibrosis or hepatic vein obstruction produces a more protein-rich ascites.

### Inflammation

Any inflammatory process (septic or non-septic) will cause increased vascular permeability and leakage of protein-rich fluid from the capillary bed. The inflammation can be caused by infectious or non-infectious processes.

### Leakage

A generalized bleeding problem, rupture of a major blood vessel, or rupture of a highly vascular organ, such as the liver or spleen, can lead to a haemoperitoneum. Leakage from intra-abdominal lymphatics will cause a chylous effusion and is most often associated with primary lymphatic abnormalities (e.g. lymphangiectasia, see Chapter 20) or obstruction by tumours. Traumatic rupture of the extra-hepatic biliary tract and the urinary tract lead to bile peritonitis and uroabdomen, respectively.

## Clinical features

The clinical signs directly associated with ascites are:

- Abdominal distension (Figure 13.4)
- Respiratory embarrassment if massive fluid accumulation compresses the diaphragm
- Pleural effusion and subcutaneous oedema if hypoalbuminaemic.



**13.4** Grossly ascitic dog with massive abdominal enlargement. Ascites was due to a chronic hepatopathy.

Certain signs in animals with ascites are related to the primary cause of fluid accumulation:

- Diarrhoea and weight loss in PLE
- Polyuria/polydipsia (PU/PD) in chronic renal disease
- Thromboembolic disease in PLE and PLN
- Jaundice in liver failure or bile peritonitis
- Exercise intolerance and collapse in heart failure and cardiac tamponade

- Anuria and uraemia in uroabdomen
- Collapse if haemoperitoneum.

### Differential diagnosis

The common and uncommon causes of each type of ascitic fluid are listed in Figure 13.5.

### Diagnosis

#### Detection of ascites

The presence of ascites is usually evident on physical examination. Ballottement (abdominal percussion to detect fluid and intra-abdominal masses) transmits a fluid wave across the abdomen to the other hand. Ascites must be distinguished from other causes of

Fluid composition	Condition	Common causes	Uncommon causes
Transudate – hypoalbuminaemia	Hepatic failure Protein-losing enteropathy (PLE)	None Inflammatory bowel disease	Congenital PSS (rare) Cirrhosis Alimentary lymphosarcoma Lymphangiectasia
	Protein-losing neuropathy (PLN)	Glomerulonephritis	Amyloidosis
	Pre-hepatic hypertension (may be transudate)	Following ligation of PSS	Portal vein thrombosis: vascular occlusion from torsions Vascular occlusion from strangulations (hernias)
Modified transudate – portal hypertension	Intra-hepatic portal hypertension	Chronic hepatitis; cirrhosis	Idiopathic hepatic fibrosis Hepatic AV fistula: hepatic neoplasia; liver flukes (not in UK)
	Post-hepatic portal hypertension Caudal vena cava compression/obstruction	None	Veno-occlusive disease: Budd–Chiari syndrome; 'kinked' CVC (post-traumatic); CVC webs and thrombosis; cor triatrium dexter
	Cardiac tamponade	Idiopathic pericardial haemorrhage Right atrial haemangiosarcoma	Heart base tumour Restrictive pericarditis: mesothelioma; septic pericarditis
	Right-sided heart failure	Valvular heart disease Dilated cardiomyopathy	Intra-cardiac neoplasia <i>Angiostrongylus</i> , <i>Dirofilaria</i> (not in UK)
	Septic (bacterial)	GI perforation Migrating foreign body Penetrating wound Volvulus/infarction of GI tract Ruptured pyometra	<i>Mesocestoides</i> (not in UK) Mycotic <i>Nocardia</i> or <i>Actinomyces</i>
Exudate – inflammatory	Non-septic	FIP Feline lymphocytic cholangiohepatitis Pancreatitis Carcinomatosis	Steatitis Diaphragmatic rupture and entrapment
Bile – biliary leakage		Traumatic rupture of gall bladder	Necrotizing cholecystitis Perforated common bile duct (trauma, choleliths) Perforated proximal duodenal ulcer
Blood – haemorrhage		Generalized bleeding disorder Ruptured splenic haematoma or haemangioma Ruptured splenic or hepatic haemangiosarcoma Traumatic splenic or hepatic rupture	Splenic torsion Liver lobe torsion Hepatic amyloidosis in cats Hepatic peliosis in cats
Chyle – lymphatic obstruction or leakage		Cardiomyopathy Lymphangiectasia	Intestinal obstruction Neoplasia, especially phaeochromocytoma
Urine – rupture of urinary tract		Ruptured bladder	Ruptured kidney Ruptured ureter(s)

**13.5** Causes of ascites classified according to fluid composition and relative incidence of the cause of each fluid type. AV = arteriovenous; CVC = caudal vena cava; FIP = feline infectious peritonitis; GI = gastrointestinal; PSS = portosystemic shunt.

abdominal enlargement (Figure 13.6). In particular, the 'pot belly' due to fat redistribution, hepatomegaly and weak abdominal musculature in hyperadrenocorticism is often confused with ascites, yet it is *not* associated with peritoneal fluid accumulation.

Abdominal neoplasia  
Diabetes mellitus  
Hyperadrenocorticism  
Obesity  
Ovarian cyst  
Paraprostatic cyst  
Pregnancy  
Pyometra  
Urine retention (urethral obstruction or atonic bladder)

**13.6** Causes of abdominal distension that may mimic ascites.

Abdominal radiographs are rarely helpful if there is significant ascites, beyond confirming the presence of fluid because the loss of abdominal contrast obscures all detail (so-called 'ground glass' appearance). Ultrasound examination is the more sensitive technique for detecting small volumes of fluid, especially pocketed fluid, as this technique is capable of detecting as little as 5 ml/kg.

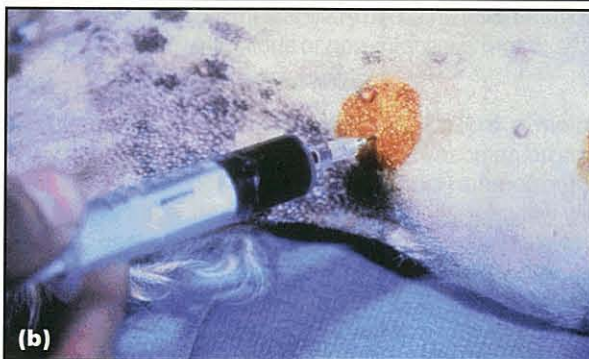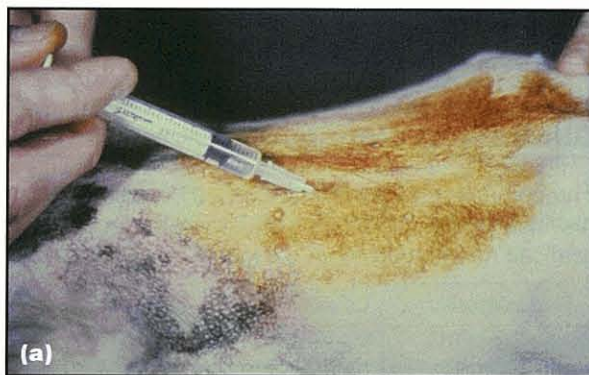### Diagnostic approach

Free peritoneal fluid can be confirmed by imaging (see above). The overall diagnostic approach to an ascitic patient is then:

1. Check serum albumin concentration. If  $<15$  g/l the ascites is likely to be a pure transudate and the diagnostic effort should be aimed at determining the cause (see Figure 13.5); abdominocentesis is likely to be unhelpful.
2. If the serum albumin concentration is  $>15$  g/l, perform abdominocentesis for fluid collection and classification based on laboratory analysis, cytological examination and culture (see Figures 13.2 and 13.3). Following identification of the nature of the ascitic fluid, specific investigations are performed to determine the underlying cause (see Figure 13.8).

### Abdominocentesis

Ultrasound guidance can be used for aspiration of small pockets of ascites but if there is palpable fluid accumulation ultrasound guidance is unnecessary. Instead, fluid is readily aspirated blindly via a needle or (preferably) an over-the-needle catheter. For diagnostic purposes only a small volume (1–5 ml) is required. The site should be clipped and prepared aseptically and can be infiltrated with local anaesthetic (Figure 13.7). Abdominocentesis is usually performed with the patient restrained in lateral recumbency to move bowel loops away from the wall. Theoretically the ideal site is in the midline, through the avascular linea alba just caudal to the umbilicus and behind the falciform fat. However, if there is massive ascites, continued leakage may occur when the patient stands. In such situations an off-midline approach may be better as the



**13.7** Abdominocentesis. (a) Sterile preparation and infiltration of the linea alba with local anaesthetic prior to abdominocentesis. (b) Collection of blood by emergency abdominocentesis in a dog with a ruptured spleen and haemoperitoneum.

penetrated muscle will tend to occlude the hole. Diagnostic peritoneal lavage is performed if the amount of ascites is too small to be aspirated even under ultrasound guidance (see *BSAVA Manual of Canine and Feline Emergency and Critical Care*).

### Laboratory examination of ascites

The gross appearance of the ascitic fluid may be helpful (see Figure 13.1) but laboratory analysis will determine its exact nature (see Figure 13.2). The serum–ascites–albumin gradient (SAAG) is the difference between the albumin concentration of the serum and the ascites. If  $>11$  g/l, any ascitic fluid has been formed by portal hypertension, whilst SAAG  $<11$  g/l reflects transudation due to hypoalbuminaemia. This test is used in humans who have ascites and may be of value in dogs.

In cats a high protein exudate is characteristic of lymphocytic cholangitis or, more commonly, effusive feline infectious peritonitis (FIP). In FIP the total protein concentration of the ascites is usually  $>35$  g/l and consists of more globulin than albumin. An albumin:globulin ratio of  $<0.4$  indicates FIP is quite likely, whilst a ratio of  $>0.8$  rules out FIP as the cause of the effusion. Identification of bacteria in the ascitic fluid may reflect contamination unless intracellular organisms are detected. Finding an exudate is an indication to perform bacterial culture.

### Further investigation

The further investigations performed to determine the cause of ascites are listed in Figure 13.8.

Type of ascitic fluid	Test	Results
Transudate	Haematology	Mild (microcytic) anaemia in PSS
	Serum biochemistry	Hypoalbuminaemia (< 15 g/l) Globulins decreased in PLE, normal in PLN Liver enzymes increased in liver disease Bile acids increased with PSS
	Urinalysis	Proteinuria in PLN
	UPC ratio	Increased in PLN
	Faecal $\alpha_1$ -PI	Increased in PLE
	Abdominal imaging	Liver size PSS
	Portovenography	Portal vein obstruction, PSS
	Chest radiography	Hydrothorax
Modified transudate	Haematology	Mild (microcytic) anaemia in liver disease Inflammatory leucogram in septic peritonitis
	Bile acids	Increased in liver disease
	Abdominal ultrasonography	Primary hepatic disease Secondary hepatic congestion Hepatic AV fistula
	Hepatic arteriogram	AV fistula
	Exploratory laparotomy	Liver biopsy Identification of neoplasia
	Chest radiography	Cardiac disease
	Cardiac ultrasonography	Cardiac tamponade DCM Right heart failure
	ECG	Cardiac tamponade Right heart failure
	Angiography	CVC abnormalities
Exudate	Haematology	FIP: neutrophilia; lymphopenia Inflammatory leucogram in pancreatitis
	Serum globulins	Elevated in FIP >70 g/l
	Culture of ascites	Septic peritonitis
	Coronavirus serology	Indicates exposure to coronavirus (not diagnostic of FIP)
	Pancreatic enzymes: amylase, lipase, TLI, PLI may be increased in serum and ascitic fluid	Pancreatitis (Serum PLI is the most specific blood test. Sensitivity and specificity of testing ascitic fluid is unknown)
	Ultrasonography	Pancreatitis
	Exploratory laparotomy	Identification and resolution of cause of septic peritonitis Identification of carcinomatosis
Blood	Coagulation profile (OSPT, aPTT, FDPs, PIVKAs, d-dimer)	Generalized bleeding problem
	Monitor for shock	Traumatic haemorrhage Ruptured haemangioma/haemangiosarcoma
	Abdominal radiography	Splenic or hepatic mass
	Thoracic radiography	Metastatic disease
	Ultrasonography	Splenic or hepatic mass
	Exploratory laparotomy	Traumatic bleeding not responding to fluid therapy Identification and removal of mass

**13.8** Further investigations in ascites. aPTT = activated partial thromboplastin time; AV = arteriovenous; CVC = caudal vena cava; DCM = dilated cardiomyopathy; ECG = echocardiogram; FDP = fibrin degradation products; FIP = feline infectious peritonitis; OSPT = one-stage prothrombin time; PI = proteinase inhibitor; PIVKA = proteins induced by vitamin K absence; PLE = protein-losing enteropathy; PLI = pancreatic lipase immunoreactivity; PLN = protein-losing nephropathy; PSS = portosystemic shunt; TLI = trypsin-like immunoreactivity; UPC = urine protein to creatinine. (continues)

## Chapter 13 Ascites

Type of ascitic fluid	Test	Results
Bile	Exploratory laparotomy	Identification and repair of site of bile leakage
Chyle	Ascites cholesterol concentration < serum	Identification of chyle
	Ascites triglyceride concentration > serum	Identification of chyle
	Lymphangiography	Identification of site of lymphatic leakage or obstruction
	Exploratory laparotomy	Identification and ligation of site of lymphatic leakage or removal of obstruction
Urine	Ascites creatinine concentration > serum	Identification of uroabdomen (Urea equilibrates across the peritoneal membrane and is less useful)
	Intravenous urography Cystography	Identification of site of urine leakage
	Exploratory laparotomy	Identification and repair of site of urine leakage

**13.8** (continued) Further investigations in ascites. aPTT = activated partial thromboplastin time; AV = arteriovenous; CVC = caudal vena cava; DCM = dilated cardiomyopathy; ECG = echocardiogram; FDP = fibrin degradation products; FIP = feline infectious peritonitis; OSPT = one-stage prothrombin time; PI = proteinase inhibitor; PIVKA = proteins induced by vitamin K absence; PLE = protein-losing enteropathy; PLI = pancreatic lipase immunoreactivity; PLN = protein-losing nephropathy; PSS = portosystemic shunt; TLI = trypsin-like immunoreactivity; UPC = urine protein to creatinine.

### Treatment

Information on the treatment of ascites can be found in Chapters 20 and 24.

### References and further reading

Dittrich S, Yordi LM and de Mattos AA (2001) The value of serum-

ascites albumin gradient for the determination of portal hypertension in the diagnosis of ascites. *Hepatogastroenterology* **48**, 166–168

Henley RK, Hager DA and Ackerman N (1989) A comparison of two-dimensional ultrasonography and radiography for the detection of small amounts of free peritoneal fluid in the dog. *Veterinary Radiology* **30**, 121–124

King L and Hammond R (1999) *BSAVA Manual of Canine and Feline Emergency and Critical Care*, BSAVA Publications, Gloucester

# Jaundice

Susan E. Bunch

Jaundice is the yellow staining of tissues caused by excess bilirubin (hyperbilirubinaemia). The terms *jaundice* and *icterus* may be used interchangeably.

## Normal bilirubin formation and disposal

Bilirubin is a waste product of haem protein degradation. The primary source of haem proteins is senescent erythrocytes; myoglobin and haem-containing enzyme systems in the liver are additional sources. Mononuclear phagocytic cells, primarily in the bone marrow and spleen, engulf old erythrocytes, after which haem oxygenase in the phagocytic cells opens the protoporphyrin ring of haemoglobin, forming biliverdin. Biliverdin is converted to fat-soluble bilirubin IXa, which is then released into the circulation where it is bound by albumin. Hepatocytes take up the bilirubin and conjugate it with various carbohydrates, making the bilirubin water-soluble. Conjugated bilirubin is then excreted into the bile canaliculi and travels in the bile ducts with other bile constituents to the gall bladder, where it is stored until it is expelled into the duodenum. In the intestine conjugated bilirubin undergoes bacterial deconjugation and then reduction to urobilinogen, which is mostly resorbed into the portal system and returned to the liver. A small fraction of urobilinogen is excreted in the urine and the remainder stays in the intestinal tract where it is converted to stercobilin, which imparts normal faecal colour. Bilirubin metabolism is discussed further in the *BSAVA Manual of Canine and Feline Clinical Pathology*.

## Pathophysiology of hyperbilirubinaemia

Inherited defects of bilirubin metabolism have been described in other species (e.g. rats, sheep, humans) but have not been identified in dogs and cats; thus, hyperbilirubinaemia is considered an acquired condition. Hyperbilirubinaemia ( $> 5 \mu\text{mol/l}$  in cats and  $>10 \mu\text{mol/l}$  in dogs) is caused by one or more of the following mechanisms:


- Pre-hepatic hyperbilirubinaemia (haemolysis): increased production of bilirubin; exceeds the normal concentration that the liver is able to take up and process
- Hepatic hyperbilirubinaemia (intra-hepatic cholestasis): reduced elimination of bilirubin and other bile constituents due to impaired hepatocellular handling

- Post-hepatic hyperbilirubinaemia: ineffective delivery of bilirubin into the duodenum (extra-hepatic cholestasis) or bile leakage into the abdominal cavity (bile peritonitis), leading to resorption of bilirubin into the circulation.

## Pre-hepatic hyperbilirubinaemia

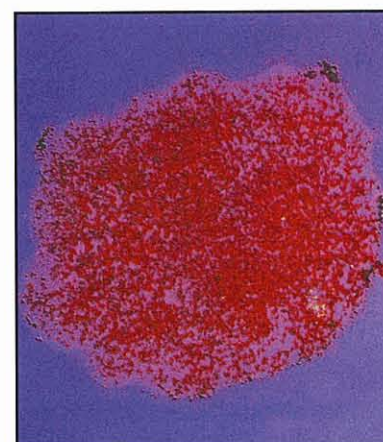
### Haemolysis

The most common causes of hyperbilirubinaemia attributable to haemolysis are severe intravascular and extravascular haemolytic anaemia of various types, and incompatible blood transfusion (Figures 14.1 and 14.2). The normal liver has a large reserve capacity for



14.1

(a) Haematocrit tubes from a cat that had received an incompatible transfusion. (b) Serum from a dog with immune-mediated intravascular haemolysis. The tube shows hyperbilirubinaemia and haemoglobinaemia.

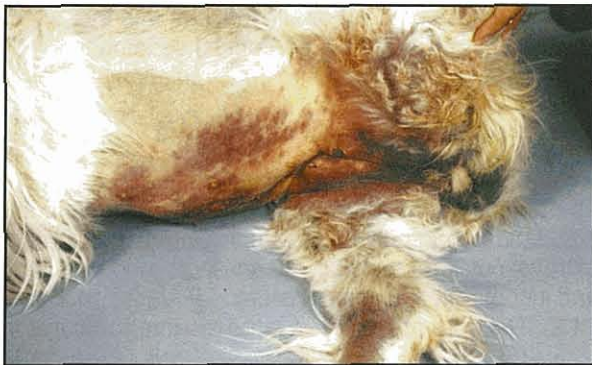

14.2

Saline agglutination test demonstrating erythrocyte clumping on gross inspection. Agglutination was confirmed by microscopic examination, confirming a diagnosis of immune-mediated haemolytic anaemia.



bilirubin processing and so haemolysis alone does not cause jaundice; concurrent reduced hepatic ability to excrete bilirubin must also be present. Most dogs with haemolytic anaemia also have hypoxic liver injury, which further impairs bilirubin excretion. Rarely, jaundice can occur following resorption of a major intramuscular haemorrhage, a large haematoma (Figure 14.3) or multiple large subcutaneous ecchymoses. Bleeding into the body cavities does not cause jaundice because erythrocytes are absorbed intact, but if hepatic insufficiency is present jaundice may ensue. Jaundice is never associated with bleeding into the gastrointestinal (GI) tract because haemoglobin entering the intestine is transformed to other porphyrins that are not resorbed for recycling into haemoglobin synthesis.



**14.3** Subcutaneous bruising associated with leakage from a femoral arterial catheter site following surgery to repair a congenital portosystemic shunt. The dog only became icteric after surgery.

### Hyperthyroidism

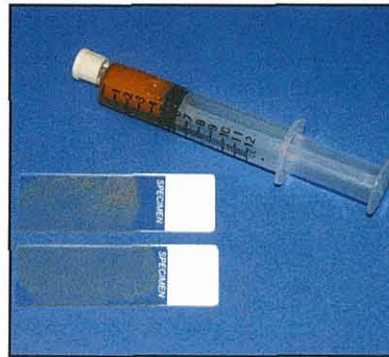Mild hyperbilirubinaemia may also occur in a small number of hyperthyroid cats. There is no histological evidence of cholestasis at the light microscopic level in affected cats, and the hyperbilirubinaemia resolves with return to euthyroidism. Experimental investigations of thyrotoxicosis in laboratory animals have demonstrated increased production of bilirubin, which is believed to be associated with accelerated degradation of hepatic haem proteins.

### Hepatic hyperbilirubinaemia

#### Intra-hepatic cholestasis

Intra-hepatic cholestasis in many primary hepatocellular diseases is likely to be attributable to a combination of the inability to take up, process and excrete bilirubin into the bile canaliculi. Altered red blood cell (RBC) membranes and consequent RBC destruction in animals with hepatobiliary disease often contributes to a high serum bilirubin concentration. Jaundice is more likely to be a clinical feature of liver disorders that involve primarily the periportal (zone 1) hepatocytes than if the lesion involves the centrilobular (zone 3) hepatocytes. Inflammation and swelling of larger intra-hepatic biliary structures (i.e. cholangitis; Figure 14.4) could similarly delay bile excretion. For further details see Chapter 24.

Some extra-hepatobiliary disorders cause cholestasis by poorly understood means. Bacterial sepsis in humans and dogs, arising other than from the liver or



**14.4**

Bile obtained via ultrasound-guided cholecystocentesis from a cat with acute (bacterial) cholangitis.

biliary tract, can cause hepatocellular dysfunction and jaundice with high liver enzyme activities and bile acid concentrations resembling primary hepatobiliary disease, but with minimal histopathological changes in the liver. Cytokines released during inflammation, such as tumour necrosis factor (TNF $\alpha$ ), injure hepatocyte membranes, interfering with bilirubin and bile acid transport. This change is reversible upon successful treatment of bacteraemia.

### Post-hepatic hyperbilirubinaemia

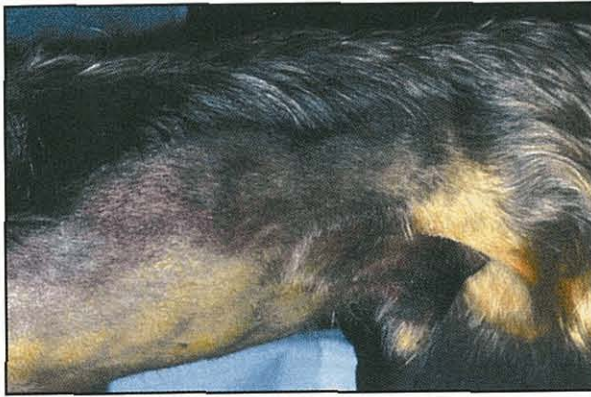#### Extra-hepatic cholestasis

Distal obstruction of the bile duct causing extra-hepatic cholestasis results in increased intraluminal biliary tract pressure, interhepatocellular regurgitation of bile constituents into the circulation, and jaundice. If only one of the hepatic bile ducts exiting the liver is blocked, or if only the cystic duct exiting the gall bladder is obstructed, there are biochemical clues for localized cholestasis, such as high serum alkaline phosphatase (ALP) activity. However, the overall ability of the liver to process bilirubin is preserved and jaundice does not develop. Total obstruction to bile flow leads to acholic faeces (Figure 14.5) and steatorrhea secondary to the complete absence of bile pigment and bile acids, respectively, in the intestine. Mechanical diseases of the extra-hepatic biliary tract (e.g. traumatic bile duct avulsion from the duodenum, persistent complete extra-hepatic bile duct obstruction) are the most common causes (Figure 14.6) of acholic faeces in cats and dogs. Rarely, in cats with severe cholangitis, normal bile flow ceases. The bile consists of only clear, viscous biliary epithelial secretions ('white bile syndrome') that may result in production of acholic faeces in the absence of mechanical obstruction.




**14.5**

Acholic faeces from a dog with severe intra-hepatic cholestasis.



**14.6** Abdominal ecchymoses associated with bile duct avulsion following blunt abdominal trauma. The bleeding tendency was caused by vitamin K deficiency.



**14.7** Abdominal fluid from a dog with lethargy, vomiting and abdominal effusion. The gall bladder had ruptured for unknown reasons, resulting in bile peritonitis.

**Rupture**

Traumatic or spontaneous (pathological) rupture of the biliary tract (i.e. gall bladder, bile duct near the duodenum) allows leakage of bile into the peritoneal space and absorption of some bile components (Figure 14.7). This results in the total bilirubin concentration in the abdominal fluid being greater than that in serum (see Chapter 25).

**Differential diagnosis**

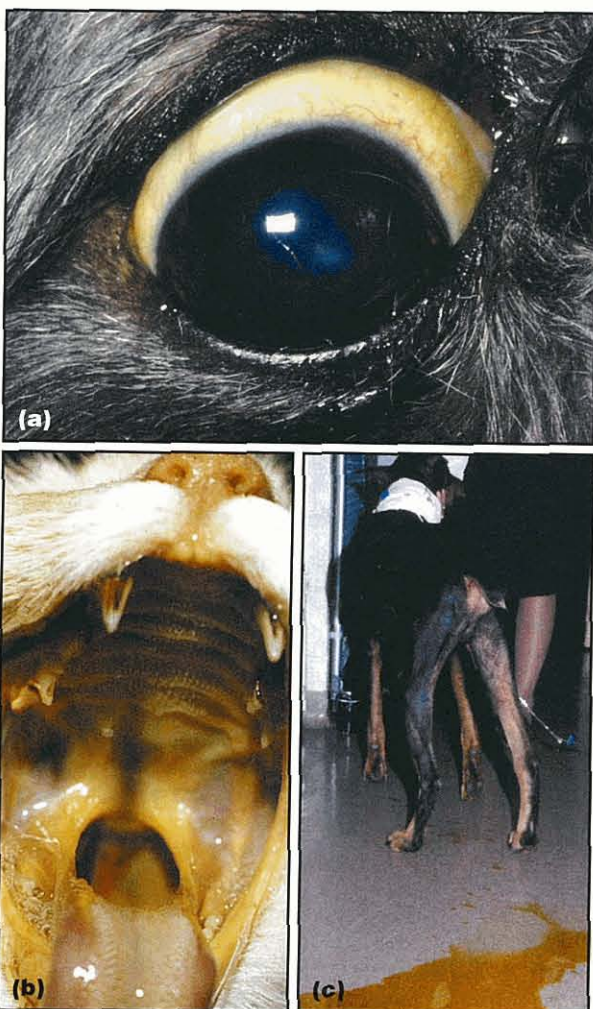
Specific examples of haemolytic and hepatobiliary conditions that could cause jaundice are listed in Figure 14.8.

Haemolytic anaemia (Pre-hepatic <sup>a</sup> )	Cholestasis (Hepatic)	Cholestasis (Post-hepatic)
Immune-mediated haemolytic anaemia: Certain drugs e.g. sulphonamides Systemic lupus erythematosus Modified live virus vaccination Idiopathic  Secondary immune-mediated injury associated with lymphoma, endocarditis, other  Delayed transfusion reaction  Infectious agents: <i>Babesia gibsoni</i> and <i>B. canis</i> <i>Ehrlichia canis</i> <i>Mycoplasma haemofelis</i> <i>Mycoplasma canis</i> <i>Cytauxzoon felis</i> Feline leukaemia virus <i>Dirofilaria immitis</i> (dogs)  Chemicals and toxins: Hyperthyroidism (cats) Zinc Onions Methylene blue Copper (rare) Hypophosphataemia Paracetamol (acetaminophen)  Congenital erythrocyte defects <sup>b</sup>  Use of an oxygen-carrying fluid, such as bovine haemoglobin glutamer-200	Chronic hepatic injury: Advanced chronic hepatitis, including familial types (e.g. Bedlington Terrier, Dobermann, Dalmatian, American and English Cocker Spaniel) drug-associated and idiopathic forms Cirrhosis  Acute hepatic necrosis  Biliary tract inflammation: Acute cholangitis (dogs, cats) Chronic cholangitis (cats)  Diffuse infiltrative neoplasia: Lymphoma Myeloproliferative disease  Liver involvement with systemic infections: Histoplasmosis (cats) Feline infectious peritonitis (FIP) Leptospirosis (dogs) Acute infectious canine hepatitis  Hepatic lipidosis (cats) Secondary to effects of cytokines elaborated in association with bacterial infections elsewhere in the body  Hyperthyroidism (mild, $\leq 40 \mu\text{mol/l}$ ) in about 20% of affected cats; may be caused by excess degradation of hepatic haem proteins	Bile duct obstruction: Pancreatitis Pancreatic carcinoma Duodenitis Duodenal carcinoma Stricture Cholelithiasis Inspissated bile Blood clot Biliary carcinoma Flukes (cats)  Bile duct or gall bladder rupture: Abdominal trauma Diseased, friable biliary tissues Idiopathic necrotizing cholecystitis

**14.8** Specific causes of hyperbilirubinaemia in dogs and cats. <sup>a</sup> Centrilobular hepatocyte necrosis is a contributing factor. <sup>b</sup> Unlikely to be severe enough to cause jaundice except for phosphofructo-kinase deficiency.

## Diagnosis

Although hyperbilirubinaemia is defined as  $>5 \mu\text{mol/l}$  in cats and  $>10 \mu\text{mol/l}$  in dogs, the serum concentration at which jaundice is detectable in mucous membranes is only approximately  $30\text{--}40 \mu\text{mol/l}$  (Figure 14.9). This is because the human eye is not as sensitive at detecting bilirubin against the pink background of mucous membranes as serum biochemical testing. Jaundice is usually visible in the sclera first as the background is white. The predominant form of bilirubin in disorders causing jaundice is water-soluble conjugated bilirubin; this makes measurement of direct-reacting (conjugated) and indirect-reacting (unconjugated) bilirubin by the van den Bergh reaction useless in differentiating haemolysis from hepatobiliary disease. Canine renal tubules, particularly in males, have the capacity to metabolize filtered haemoglobin to bilirubin and so mild bilirubinuria in a concentrated urine specimen is not necessarily abnormal in dogs. Furthermore, increasing bilirubinuria in dogs may precede development of clinically overt jaundice (see Figure 14.9c). Feline kidneys cannot process bilirubin and have a high renal threshold for bilirubin, so bilirubinuria is always abnormal in cats.



**14.9** Jaundice can be indicated by (a) a yellow sclera, (b) yellow oral mucous membranes and (c) marked bilirubinuria.

If the packed cell volume (PCV) is within or just below the reference range, the cause cannot be haemolytic anaemia (Figure 14.10) and hepatobiliary causes (Figure 14.11) are pursued with clinico-pathological testing and imaging studies (Figure 14.12). A suggested step-by-step diagnostic approach for evaluating a dog or cat with jaundice is provided in Figure 14.13.

### Historical features

- Lethargy
- Anorexia
- Weakness
- Change in colour of skin, urine or faeces
- Recent blood transfusion or use of oxygen-carrying fluid, such as bovine haemoglobin glutamer-200
- Ingestion of coins containing zinc
- Severe trauma with haematoma formation
- Breed-associated erythrocyte defects

### Physical examination findings

- Pale mucous membranes
- Jaundice (if the serum bilirubin level exceeds  $40 \mu\text{mol/l}$ )
- Hepatomegaly
- Splenomegaly
- Lymphadenomegaly
- Marked evidence of bleeding into the skin or muscles
- Orange faeces
- Fever
- Cardiac murmur if PCV  $<20\%$
- Tachypnoea

**14.10** Historical features and physical examination findings in dogs and cats with haemolysis causing hyperbilirubinaemia. (Note that jaundice only occurs with haemolysis if there is marked erythrocyte lysis and decreased hepatic elimination.) PCV = packed cell volume.

### Historical features

- Lethargy
- Anorexia
- Jaundice, change in urine or faecal colour
- Abdominal enlargement
- Altered mentation
- Vomiting
- Diarrhoea
- Polyuria, polydipsia

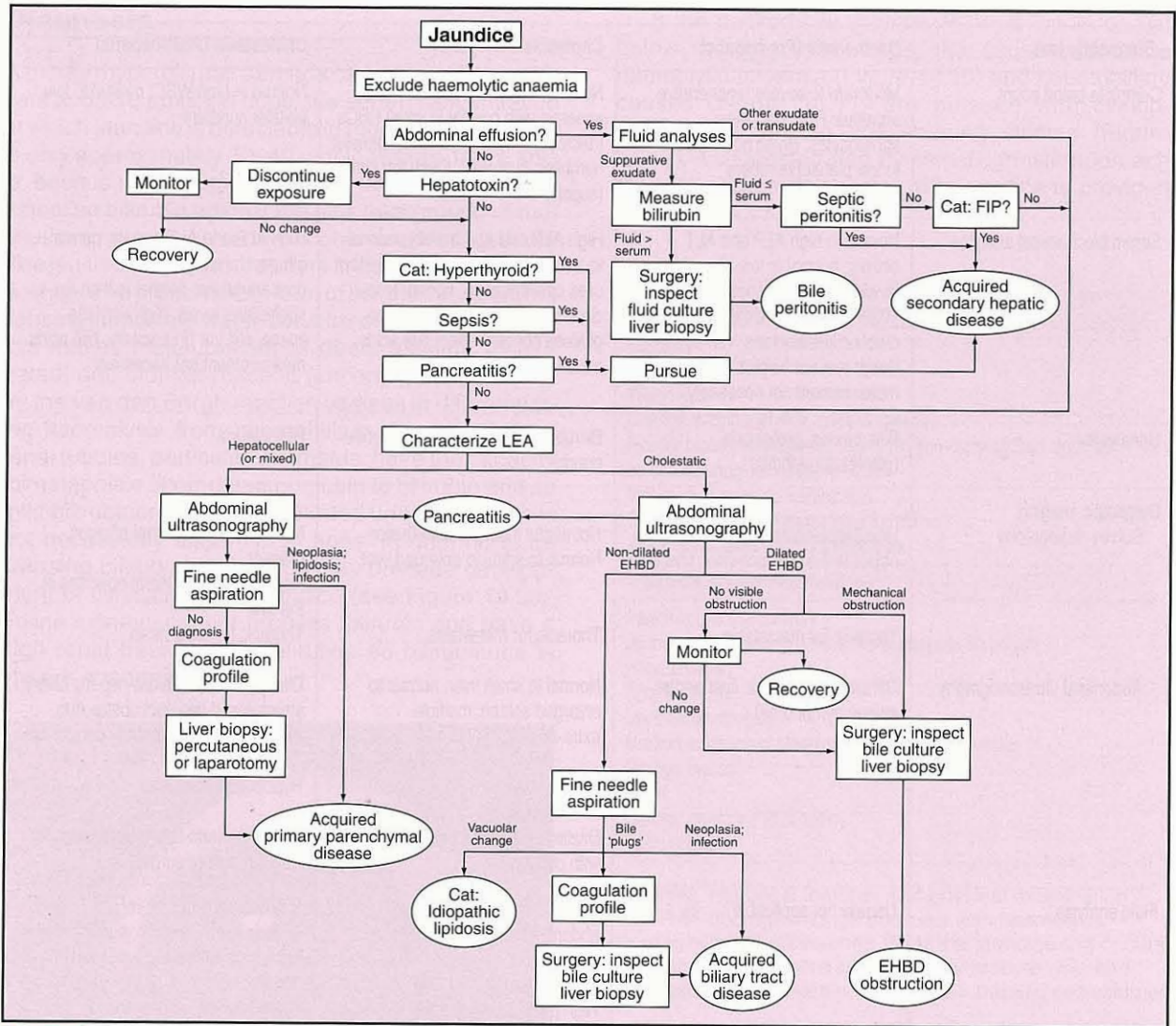
### Physical examination findings

- Weight loss
- Jaundice
- Altered mentation
- Hepatomegaly
- Splenomegaly
- Abdominal effusion
- Cranial abdominal mass
- Cranial or generalized abdominal pain
- Fever
- Melaena or acholic faeces on rectal examination
- Ecchymosis

**14.11** Historical features and physical examination findings in dogs and cats with hyperbilirubinaemia caused by cholestasis.

Diagnostic test	Haemolysis (Pre-hepatic)	Cholestasis (Hepatic)	Cholestasis (Post-hepatic)
Complete blood count	Moderate to severe regenerative anaemia; RBC parasites; spherocytes; Heinz bodies; normal to low platelet numbers	Normal to mild non-regenerative anaemia with normal to small RBCs (microcytosis); normal to low platelet numbers; high WBCs with left shift (sepsis)	Normal to high WBC; normal to low platelet numbers
Serum biochemical analytes	Normal to high ALP and ALT activity; normal to low albumin levels; phosphate concentration <0.65 mmol/l in animal with diabetic ketoacidosis; van den Bergh test not helpful; bile acids measurement not necessary	High ALP and ALT activity; normal to low albumin levels; normal to low urea concentration; normal to low cholesterol levels; normal to low glucose concentration; bile acids measurement not necessary	High ALP and ALT activity; normal albumin, urea, glucose concentrations; normal to high cholesterol levels; high amylase, lipase, cPLI or fPLI activity; bile acids measurement not necessary
Urinalysis	Bilirubinuria; proteinuria (glomerulonephritis)	Bilirubinuria; normal to low specific gravity	Bilirubinuria
Diagnostic imaging: Survey radiography	Hepatosplenomegaly; metallic object in the stomach (zinc toxicosis)	Not useful if abdominal effusion <i>Normal to small to enlarged liver</i>	Not useful if abdominal effusion present Hepatosplenomegaly, mineral opacities in the liver
Abdominal ultrasonography	Thoracic for metastasis  Diffusely hypoechoic liver and/or spleen (lymphoma)	Thoracic for metastasis  Normal to small liver, normal to enlarged spleen, multiple extra-hepatic shunts  <i>Nodular liver</i>  Dilated biliary structures in cats with cholangitis	Thoracic for metastasis  Dilated intra- and extra-hepatic biliary structures. If bile duct obstruction, identify cause and site of obstruction  <i>Hypoechoic pancreas</i>  Obtain aspirate tissue specimens for cytology before surgery
Fluid analysis	Usually not applicable	Pure to modified transudate abdominal fluid in dogs with cirrhosis  High protein concentrations in abdominal fluid of cats with FIP and progressive lymphocytic cholangitis  Bacteria seen on Gram staining of bile (cats)  <i>'White bile' (severe cholestasis)</i>	Bile duct obstruction: results related to underlying cause (e.g. carcinoma cells, high lipase and amylase activity) Bile peritonitis: appearance is characteristic; fluid bilirubin concentration > serum bilirubin concentration; bilirubin crystals; cytology consistent with inflammation
Coagulation tests	Normal to markedly prolonged clotting times (DIC)	Normal to clinically inapparent prolonged clotting times; markedly prolonged clotting times (vitamin K deficiency or DIC)	
Microbial culture and sensitivity testing	Usually not applicable	Blood and/or other specimens (e.g. urine) if pursuing extra-hepatobiliary sepsis; bile in dogs and cats with acute cholangitis	Peritoneal fluid to rule out septic peritonitis
Other	Serological testing for infectious causes; Coombs' test (if no spherocytes); saline agglutination test; antinuclear antibody test; blood smear or serological/molecular testing for parasites	Apparent focus of infection leading to bacteraemia on the basis of Hx and PE findings (sepsis); serum thyroxine levels (cats); serological/molecular testing for infectious causes; liver biopsy	Faecal sedimentation test for fluke eggs (predatory cats from tropical and subtropical climates)

**14.12** Diagnostic tests and useful clues in discriminating causes of hyperbilirubinaemia. ALP = alkaline phosphatase; ALT = alanine aminotransferase; cPLI = canine pancreatic lipase immunoreactivity; DIC = disseminated intravascular coagulation; FIP = feline infectious peritonitis; fPLI = feline pancreatic lipase immunoreactivity; Hx = history; PE = physical examination; RBC = red blood cell; WBC = white blood cell.



**14.13** Suggested algorithm for evaluation of a dog or cat with jaundice (Modified from Hess and Bunch, 2000 with permission from Elsevier.) EHBD = extra-hepatic bile duct; FIP = feline infectious peritonitis; LEA = liver enzyme activity.

**Treatment**

For information on the treatment of conditions causing jaundice see Chapters 24, 25 and 28.

**References and further reading**

Hess PR and Bunch SE (2000) Diagnostic approach to hepatobiliary disease. In: *Kirk's Current Veterinary Therapy XIII Small Animal Practice*, ed. JD Bonagura, pp. 659-664. WB Saunders, Philadelphia  
 Villiers E and Blackwood L (in preparation) *BSAVA Manual of Canine and Feline Clinical Pathology*, 2<sup>nd</sup> edition. BSAVA Publications, Gloucester

# Hepatic encephalopathy

Jill E. Maddison

## Introduction

The term hepatic encephalopathy refers to a complex of neurological abnormalities that may occur in the presence of advanced liver disease.

In the dog and cat, hepatic encephalopathy most commonly results from a single congenital vascular shunt from the portal circulation, which bypasses the hepatic circulation and allows mesenteric blood to enter directly either the caudal vena cava or the azygos vein. Acquired portosystemic shunting also occurs as a consequence of diseases that induce portal hypertension, including cirrhosis, arteriovenous (AV) fistula and hepatoportal fibrosis.

## Clinical features

Clinical signs are usually noticed in dogs and cats <1 year of age but the patient can be presented at any age.

### Dogs

Typical clinical signs in the dog include:

- Episodic lethargy
- Depression, with episodes of disorientation
- Aimless wandering
- Compulsive pacing
- Head pressing against walls
- Amaurotic blindness
- Coma.

Occasionally, seizures may be the presenting complaint in dogs. Neurological signs may be temporally related to prior ingestion of a meal in approximately 25% of cases.

Affected dogs have poor growth (Figure 15.1) and experience episodes of anorexia and gastrointestinal (GI) signs, such as vomiting. Other key features of the clinical history may include dramatic but temporary resolution of clinical signs with antimicrobial therapy, and prolonged recovery from sedation or anaesthesia. Polyuria and polydipsia occur in approximately one-third of dogs with hepatic encephalopathy. The mechanism for this has not been elucidated but may be related to central or primary (psychogenic) neuronal stimulation of the thirst centre as a manifestation of encephalopathy, alterations in portal vein osmoreceptors or a renal concentrating defect.



**15.1** These Maltese dogs are littermates; the one on the right has a congenital portacaval shunt.

### Cats

The clinical presentation of cats with hepatic encephalopathy differs in several important aspects. In contrast with dogs, cats are often reported to be well grown and in good body condition. Hypersalivation is the most frequently reported clinical abnormality in cats with congenital hepatic encephalopathy but is rarely reported in dogs.

Seizures also appear to occur more frequently in cats than in dogs with hepatic encephalopathy. Seizures occurred in approximately 50% of the feline cases reported in the literature but are not a particularly common feature of hepatic encephalopathy in dogs. Inappropriate aggression is also reported relatively frequently in cats in contrast with dogs. However, compulsive behaviour (i.e. head pressing, circling, aimless wandering) is observed more frequently in dogs than in cats. Neurological signs such as disorientation, ataxia and stupor are frequently observed in both species.

GI abnormalities, such as vomiting, diarrhoea and anorexia, are reported less frequently in cats than in dogs, as are polyuria and polydipsia.

## Differential diagnosis

The clinical signs of hepatic encephalopathy may often be confused with those of primary GI or neurological disease. However, the concurrence of both GI and neurological dysfunction in a young dog or cat should alert the clinician to the possibility of hepatic encephalopathy as a diagnosis. Lead toxicity will also result in GI and neurological signs in young animals. However, in general the neurological dysfunction associated with

lead poisoning in dogs is of a more hyperkinetic nature, resulting in seizures and hysteria. In contrast, dogs and cats with hepatic encephalopathy typically present depressed, apathetic and disorientated.

### Breed predilection

Intra-hepatic shunts occur most commonly in large breeds of dog such as Doberman, Labrador Retriever, Golden Retriever, Old English Sheepdog and Irish Wolfhound. In contrast, extra-hepatic shunts occur in smaller breeds of dogs such as Yorkshire Terrier, Maltese and Miniature Schnauzer. Single extra-hepatic shunts are also the predominant shunt type in cats although intra-hepatic shunts have been reported. There appears to be no breed predilection for congenital portosystemic shunts in cats.

### Diagnosis

Non-specific clinicopathological changes frequently observed in dogs and cats with hepatic encephalopathy include hypoproteinaemia and mild to moderate elevations in serum alanine aminotransferase (ALT) and alkaline phosphatase (ALP). However, ALT and ALP may occasionally be in the reference range. Subnormal plasma urea concentrations are often detected. Increased liver enzymes and hypoalbuminaemia occur less consistently in cats with hepatic encephalopathy compared with dogs. A small proportion of dogs are hypoglycaemic, which may contribute to clinical signs such as weakness and seizures.

The majority of affected animals will have fasting hyperammonaemia and all will exhibit intolerance to orally or rectally administered ammonium chloride. Fasting or, particularly, postprandial serum bile acids are invariably increased in dogs but (uncommonly) may be normal in cats.

An interesting haematological finding in many dogs with congenital shunts is the presence of microcytosis of erythrocytes, which is not usually associated with anaemia. This haematological abnormality has also been reported in up to 54% of cats.

Approximately 50% of dogs will have ammonium biurate crystalluria. Occasionally ammonium biurate calculi will form and cause signs of urinary tract disease including haematuria and recurrent urethral obstruction. The incidence of ammonium biurate crystalluria appears to be less in cats than in dogs.

Plain abdominal radiographs of dogs with hepatic encephalopathy show microhepatica and often renomegaly. This combination of radiographic signs has been reported less frequently in cats. The increase in the size of the renal shadow in dogs is often marked, being >4 times the length of the second lumbar vertebra. The aetiology of this enlargement has not been determined. It may be related to altered splanchnic blood flow or to increased metabolic activity of the kidney in the presence of hyperammonaemia. The presence of a small liver and enlarged kidneys on plain radiography of a young dog is highly suggestive of the presence of a portosystemic shunt.

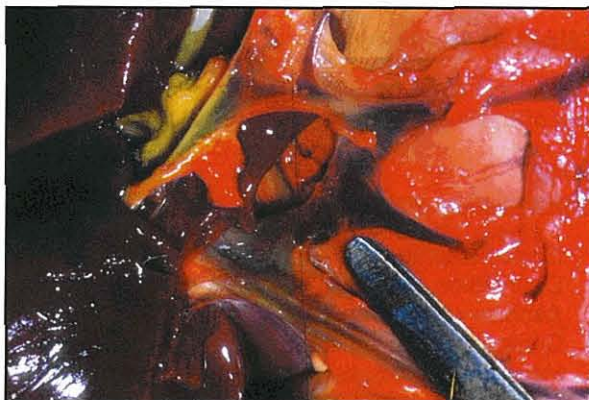The presence of portosystemic shunts is usually confirmed by techniques such as hepatic ultrasonography, visualization at surgery or operative mesenteric venography. Cranial mesenteric angiography, trans-abdominal splenoportography, coeliac arteriography and quantitative hepatic scintigraphy can also be used, but are not suited to general practice.

### Treatment

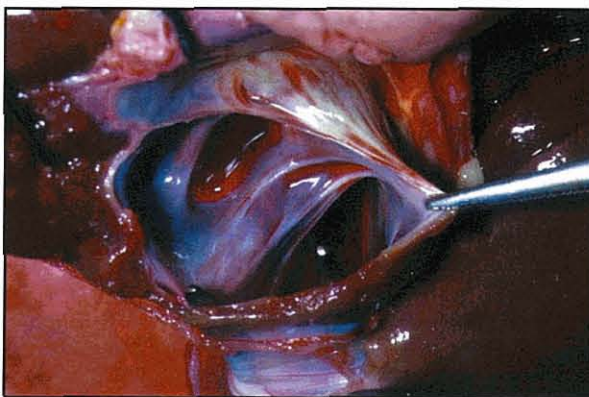
#### Surgical management

Both extra- (Figure 15.2) and intra-hepatic (Figure 15.3) shunts can be ligated successfully by experienced surgeons. Single extra-hepatic shunts are more amenable to surgical correction, but the difficulty with surgical correction of intra-hepatic shunts lies with their relative inaccessibility.

Complete attenuation of the shunt is often not possible because of unacceptable increases in portal vein pressure. However, long-term amelioration of clinical signs is usually achieved in 85% of canine cases. Clinical experience suggests that good to excellent clinical results can be expected in the majority of dogs, regardless of whether the shunt is completely or partially occluded. In contrast, in a study of the results of surgical management of feline portosystemic shunts, all four cats whose shunts were only partially ligated relapsed clinically several months



15.2 An extra-hepatic shunt in a Maltese dog prior to ligation.



15.3 An intra-hepatic shunt in an Australian Cattle Dog. The vena cava communicates directly with the portal vein within the parenchyma of the liver.

after surgery. Clinical outcome has been reported to be significantly worse in dogs older than 2 years at the time of surgery.

Uncommon postsurgical sequelae in both dogs and cats are the development of intractable seizures and neurological deficits such as blindness. There are reports of successful management of this problem, including use of propofol infusion. However, in many cases management is unsuccessful; mortality is high and irreversible brain damage common in survivors. The pathogenesis of the seizures has not been determined.

### Medical management

Medical management of hepatic encephalopathy is worth attempting when surgical correction is not possible due to the nature of the shunt or if appropriate surgical skills are not available or affordable. However, medical management may result in only temporary alleviation of clinical signs.

Medical therapy involves use of a restricted or modified protein diet, gut-active antimicrobial agents (such as neomycin and metronidazole) and lactulose syrup. The aim of dietary management in patients with liver disease is to provide sufficient nutrients and energy to support hepatic tissue repair, reduce the metabolic load on the liver (such as amino acid deamination, glyconeogenesis, lipid metabolism and bile secretion) and minimize the potential for encephalopathy to develop. Diets should contain high quality protein in moderate amounts and rely on non-protein sources for most of the kilojoules. Commercially available feline or canine restricted protein diets or home-prepared diets based on cottage cheese, eggs, rice and liver are useful. Protein should only be restricted as

needed to control neurological signs; muscle atrophy, which may occur with a highly protein restricted diet, can reduce the patient's ability to metabolize ammonia. Excessive fat intake should be avoided and a good quality vitamin and mineral supplement (without methionine) should be provided.

Lactulose is a synthetic disaccharide that is neither hydrolysed nor absorbed by the small intestine. Although its mode of action is uncertain, it is believed to act as an osmotic laxative, clearing ammonia-producing bacteria from the colon, as well as acidifying the colon to trap ammonia. Lactulose has been shown in controlled studies in humans to be beneficial in portosystemic encephalopathy and to reduce ammonia absorption from the gut. The therapeutic goal is to administer a sufficient amount of lactulose solution orally to result in the passage of 2 or 3 soft stools per day.

Oral antibiotics, such as neomycin, ampicillin or metronidazole, are initially given concurrently with lactulose and a low protein diet. (Occasional problems have been encountered with the use of neomycin, including ototoxicity and the development of gut microbial antibiotic resistance.) Once the patient is stable, the antibiotic treatment is ceased and the low protein diet is withdrawn to determine whether the condition can be managed with lactulose alone.

### References and further reading

- Heldmann E, Holt DE, Brockman DJ, Brown DC and Perkowski SZ (1999) Use of propofol to manage seizure activity after surgical treatment of portosystemic shunts. *Journal of Small Animal Practice* 40, 590-594



# 16

## Infectious and parasitic diseases

Stanley L. Marks

### Introduction

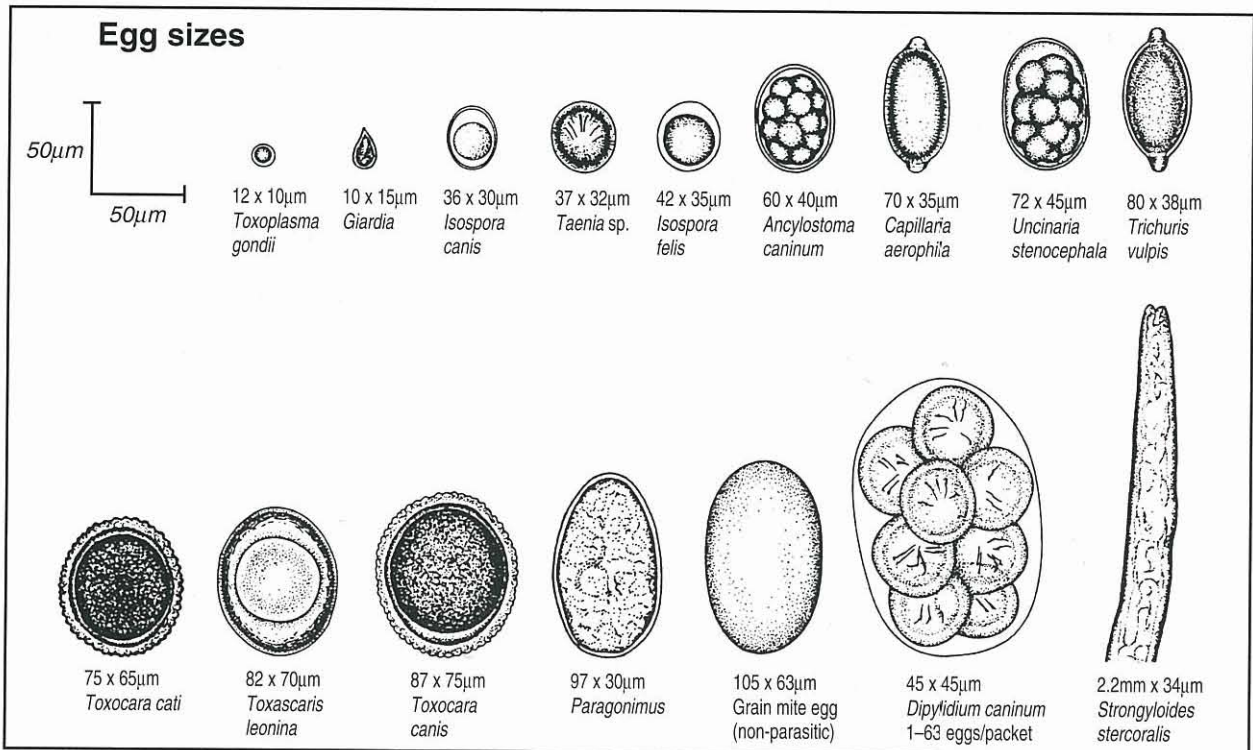
Vomiting and diarrhoea in dogs and cats are two of the most common maladies facing the small animal practitioner today, and bacterial, viral and parasitic enteropathogens play an important role in many of these cases. Dogs and cats harbouring intestinal parasites or even bacterial pathogens can remain asymptomatic, but may develop clinical signs ranging in severity from a mild, self-limiting diarrhoea, to a potentially fatal acute haemorrhagic diarrhoeal syndrome. Evaluation of the animal's history and physical examination are integral to formulating an appropriate list of differential diagnoses ranking the most likely infectious agents involved. Parvovirus enteritis is an important consideration in a young, unvaccinated puppy presenting with a history of lethargy, anorexia and vomiting, whereas salmonellosis is an important consideration in a middle-aged or older immunocompromised animal that is febrile and presents with a history of haemorrhagic diarrhoea.

### Faecal examination

A faecal examination is integral to the diagnostic investigation of dogs and cats with vomiting, diarrhoea and weight loss (Figure 16.1). The techniques used most commonly include direct saline smear (wet preparation), stained smear and faecal flotation. A Baermann technique is indicated when parasitic larval stages are being evaluated.

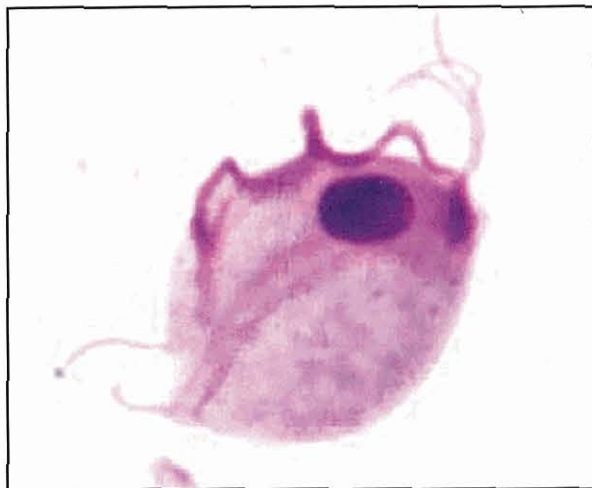
### Direct smear

Fresh faeces (ideally <2 hours old) should always be used to preserve the motility of trophozoites, such as *Giardia* spp. and *Tritrichomonas foetus* (Figure 16.2). A small amount of faeces is placed on a warm slide and a drop of 0.9% saline is mixed with the faeces. It is important that the smear is not too thick, as trophozoites may be missed. A simple rule of thumb is that one should be able to read the fine print of a newspaper through the smear. After application of a coverslip, the smear is evaluated for motile organisms by



16.1

Identification of protozoan cysts and worm eggs that may be found in the faeces of dogs and cats. (Courtesy of Hoechst-Roussel-Agri Vet Company, USA; permission requested)



**16.2** Stained faecal smear showing characteristic appearance of *Tritrichomonas foetus* with its long undulating membrane.

examining at x10 magnification, with confirmation at x40 magnification.

#### Stained smear

Stained smears have traditionally been examined to evaluate for: the presence of endospores associated with *Clostridium perfringens*; the presence of spiral-shaped, Gram-negative bacteria consistent with *Campylobacter* spp.; or the presence of increased white blood cells. Unfortunately, the diagnostic utility of increased faecal endospores is very limited as some healthy, non-diarrhoeic dogs can also have increased faecal endospores. In addition, there is no correlation between the finding of increased faecal endospores and the presence of enterotoxin. The presence of spiral-shaped bacterial organisms should be interpreted with caution as there are a number of *Campylobacter* spp. in dogs and cats, some of which may be non-pathogenic. Perhaps the best use of stained faecal smears is to make a diagnosis of *Histoplasma* or *Prototheca*. The diagnostic yield of stained faecal smears can be increased by using a cotton swab introduced into the rectum and gently rotated several times. The cotton swab is rolled on to a glass slide, which is then stained after air-drying. However, this sample is not ideal for culture, where a sample of faeces is preferred.

#### Faecal flotation

Faecal flotations are indicated for the recovery of cysts, oocysts and ova in faeces. Fresh faeces should be examined whenever possible, or a fresh specimen can be refrigerated for up to 72 hours for detection of cysts, oocysts or ova via a concentration technique. Fresh faeces can also be placed in 10% buffered formalin if evaluation will be delayed more than 72 hours. Specimens fixed in formalin are suitable for concentration techniques, acid-fast stains and immunoassays. Although standing (gravitational) flotation methods are easier and quicker to perform than centrifugation flotation, there is abundant evidence supporting the superior sensitivity (up to eight-fold) of centrifugation flotation (Figure 16.3). Animals with low parasite burdens could have a false-negative result if the gravitational method



**16.3** Centrifuge with free swinging buckets showing a coverslip in place before centrifugation.

is utilized. It is important to appreciate that faecal flotations have limitations and should not be used to detect heavy ova that do not float (e.g. *Paragonimus*) or larvae (e.g. *Aelurostrongylus*).

The type and specific gravity of the flotation medium used are important considerations. The author recommends zinc sulphate with a specific gravity of 1.18 to 1.2 for flotations. This solution and specific gravity are optimal for flotation of ova and *Giardia* cysts, while maintaining the structural detail of the *Giardia* cyst.

#### Procedure for centrifugal flotation:

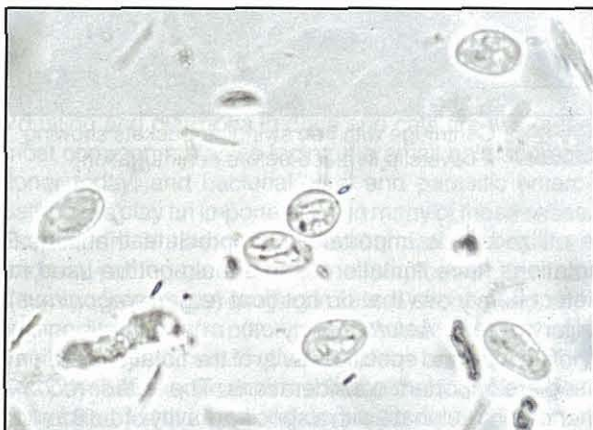
1. Prepare a faecal emulsion using 2–5 g of faeces and 30 ml of saturated salt or zinc sulphate solution.
2. Strain the emulsion through a tea strainer or cheesecloth into a 15 ml conical centrifuge tube. Suspending a funnel over the tube facilitates filling the tube.
3. Fill the tube with flotation medium to create a positive meniscus.
4. Place a coverslip on top of the tube.
5. Balance the tube in the centrifuge.
6. Centrifuge the tubes for 10 minutes at 400–600 G (approximately 1500 r.p.m.).
7. Carefully remove the coverslips from the tubes by lifting straight up and place them on a slide.
8. Examine the slide within 10 minutes. Examine entire coverslip at x10. Use x40 to confirm identification by visualizing internal structures and measuring the organism.

**Modification:** If using a *fixed-angle* centrifuge that does not have free swinging buckets, the above technique is used but the centrifuge tube is filled to within an inch or so from the top, and a coverslip is not added for the final spin. When the final centrifugation step is complete, the tube is carefully set upright in a test tube rack. A pipette is then used to gently run additional flotation solution down the side of the tube while disturbing the contents as little possible. A positive meniscus is created and a coverslip set on top. The tube is allowed to stand for 5 minutes only. The cover-

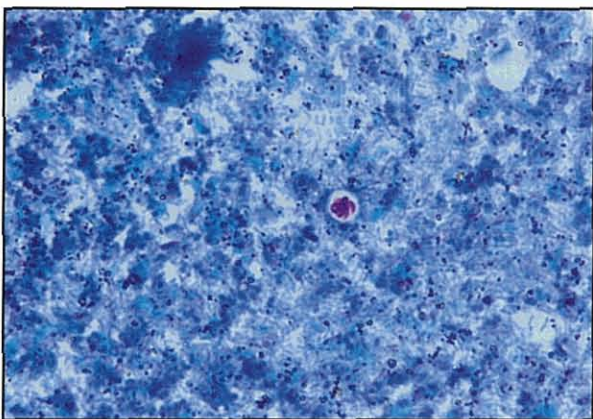
slip is removed and placed onto a slide and examined as described in step 8.

### Faecal immunoassays

The morphological detection of *Giardia* cysts (Figure 16.4) or *Cryptosporidium* oocysts (Figure 16.5) via faecal flotation can be technically demanding and time-consuming. Implementation of immunoassays avoids the necessity for morphological identification altogether, while relying upon the observation of a colorimetric reaction in a well. In addition, immunoassays can be performed on formalinized or frozen faeces.



16.4 Zinc sulphate flotation showing *Giardia* cysts.



16.5 Faecal smear showing a single acid-fast stained *Cryptosporidium* oocyst in a diarrhoeic cat.

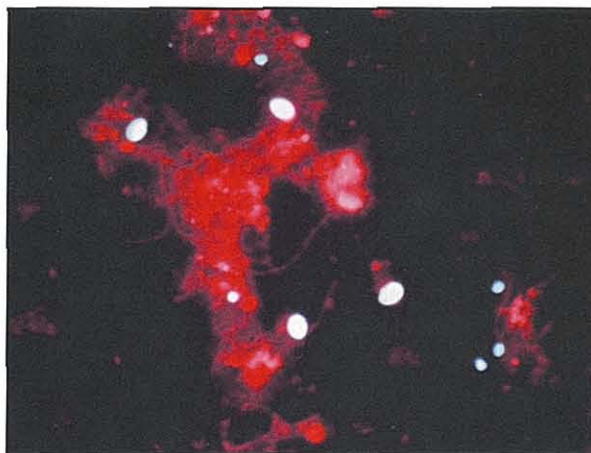
## Intestinal parasites

### Protozoa

#### *Giardia*

Direct fluorescent antibody assay (DFA) is often the standard against which other tests for *Giardia* are measured (see Figures 16.4 and 16.6). The Merifluor® *Cryptosporidium/Giardia* assay uses a fluorescein isothiocyanate (FITC)-labelled monoclonal antibody directed against cell wall antigens of *Giardia* cysts in the stool. A positive result is indicated by apple green fluorescence of the cyst (Figure 16.6). Morphological identification is facilitated by the fluorescent appearance of the cysts or oocysts; however, a fluorescent

microscope is necessary to perform this test. Enzyme immunoassays are relatively simple to perform and do not require morphological identification of the cyst or oocyst. A capture (polyclonal) antibody adsorbed to the bottom of a micro-well is used to detect the presence of *Giardia*-specific antigen (GSA) in the faeces. An in-house *Giardia* SNAP test (Idexx Laboratories) is also now commercially available.



16.6 Direct fluorescent antibody assay showing fluorescent *Giardia* cysts (larger, oval) and *Cryptosporidium* oocysts (smaller, round).

**Treatment:** Metronidazole is moderately effective in the dog, with a reported efficacy of 67%. The drug appears to be effective in cats, although neurological adverse effects are occasionally seen in dogs at the higher recommended dose of 50 mg/kg p.o. q24h for 5–10 days. Metronidazole is administered at 25 mg/kg p.o. q12h for 5 days in cats. Albendazole (25 mg/kg p.o. q12h for 5 days for cats) is also effective, but may cause leucopenia in some animals and it should not be used in early pregnancy. Fenbendazole is not approved for use in the cat in the USA but is licensed in the UK. It is effective in both dogs and cats when used for 3–5 days at 50 mg/kg p.o. q24h.

**Vaccination:** A vaccine is available in the USA, but as infection is readily diagnosed and treated and many infected dogs are asymptomatic, the merit of vaccination against giardiasis has not been convincingly demonstrated. Indeed the vaccine does not prevent infection but only reduces shedding of trophozoites or cysts. Thus routine vaccination for *Giardia* is not recommended in household dogs. The vaccine may have application in breeding kennels where large numbers of dogs are housed in close proximity to one another.

#### *Cryptosporidium*

*Cryptosporidium* can cause chronic diarrhoea in cats and dogs, although it is usually considered a self-limiting infection. Detection by faecal flotation is difficult as the organism is very small. Acid-fast staining of faecal smears and immunoassays aid detection.

**Treatment:** Eradication of this parasite has proven difficult and many putatively effective drugs are toxic in cats or dogs. The macrolide, tylosin, is not effective for

eradication of *Cryptosporidium*. Azithromycin is used in humans for management of cryptosporidiosis and can be administered at 7–10 mg/kg p.o. q12h for 7 days in dogs and cats. The aminoglycoside, paramomycin, is potentially nephrotoxic and ototoxic and should preferably not be used. Nitazoxanide may also be effective (see Chapter 28).

### Toxoplasma

For information on *Toxoplasma* see *BSAVA Manual of Canine and Feline Infectious Diseases*.

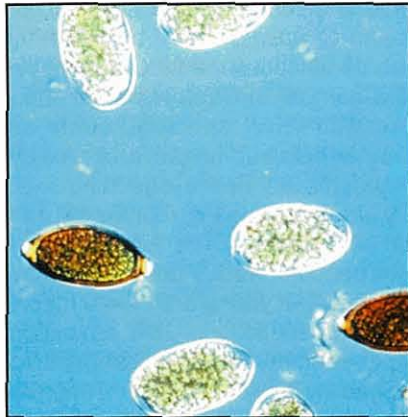### *Tritrichomonas foetus*

*Tritrichomonas foetus* is considered a cause of mild colitis in some animals, particularly cats.

## Nematodes

### Whipworms

Animals acquire *Trichuris vulpis* infection (Figure 16.7) by ingesting ova. The adult worms burrow into the colonic and caecal mucosa and may cause inflammation, haematochezia and intestinal protein loss. Cats rarely acquire whipworms. Severe infection may cause hyponatraemia and hyperkalaemia, mimicking hypoadrenocorticism.



16.7

Faecal flotation showing *Trichuris vulpis* ova (darker appearing bipericulate ova) and *Ancylostoma caninum* ova.

**Diagnosis:** *T. vulpis* should always be considered in dogs with evidence of colonic disease. A faecal centrifugation flotation should allow recognition of the bipericulate ova; however, intermittent shedding has been well documented in dogs, and animals with a negative faecal flotation should be empirically treated.

**Treatment:** Fenbendazole is a broad spectrum anthelmintic that is remarkably safe. The drug is administered orally at 50 mg/kg q24h for 5 consecutive days, and the regime is repeated at 3 weeks and 3 months following initiation of therapy.

### Roundworms

Roundworms are common in dogs (*Toxocara canis* and *Toxascaris leonina*) and cats (*Toxocara cati* and *Toxascaris leonina*). In young puppies and kittens common clinical signs include diarrhoea, failure to thrive, a poor haircoat and a 'pot bellied' appearance. Vomiting is occasionally observed when the roundworms gain access to the stomach.

**Diagnosis:** The large ova (approximately 80 µm) with a characteristic thick wall are easy to appreciate on faecal flotation.

**Treatment:** Piperazine and pyrantel are safe in puppies and kittens (see Chapter 28). The treatment should be repeated at approximately 3 weeks. Fenbendazole is also an effective anthelmintic and can be administered to newborn puppies at 100 mg/kg for 3 days to kill more than 90% of prenatal larvae. Puppies should be routinely treated every 2 weeks, starting at 2 weeks of age, until 8 weeks.

### Hookworms

*Ancylostoma* spp. are voracious blood suckers, where the worms live in the small intestinal lumen and attach to the mucosa. Dogs are infected when they ingest ova or by transcolostral transmission. Puppies and occasionally kittens can have life-threatening blood loss or iron-deficiency anaemia, melaena, haematochezia and failure to thrive.

*Uncinaria* spp. are not blood suckers, but can cause both profuse diarrhoea and interdigital dermatitis due to transdermal larval migration.

**Diagnosis:** Faecal flotation should be positive as the worms produce a large number of eggs.

**Treatment:** Fenbendazole, pyrantel and milbemycin are all effective in the dog.

## Enteropathogenic bacteria

The bacteria most commonly incriminated in canine and feline diarrhoea include *Clostridium perfringens*, *Clostridium difficile*, *Campylobacter* spp., *Escherichia coli* and *Salmonella* spp. However, the clinical significance of isolation of enteropathogenic bacteria in dogs and cats as a cause of diarrhoea is clouded by the existence of many of these organisms as normal constituents of the indigenous intestinal flora. Veterinary surgeons are faced with a quandary when attempting to diagnose suspected bacterial-associated diarrhoea in small animals because the isolation rates for putative bacterial enteropathogens are indeed often similar in diarrhoeic and non-diarrhoeic animals, and because the incidence of bacterial-associated diarrhoea is extremely variable. The indications for performing faecal enteric panels are poorly defined, resulting in indiscriminate testing and misinterpretation of results. Faecal cultures and toxin analysis should be reserved for dogs and cats developing diarrhoea after kennelling or show attendance, in animals with an acute onset of bloody diarrhoea in association with evidence of sepsis, and in diarrhoea outbreaks occurring in more than one pet in a household. Screening for *Clostridium difficile*, *Campylobacter* spp. or *Salmonella* spp. is also indicated when zoonotic concerns are present because of an immunocompromised owner.

### *Clostridium perfringens*

*Clostridium perfringens* is an anaerobic, spore-forming, Gram-positive bacillus that has been associated with outbreaks of acute, often severe diarrhoea in

humans, horses, dogs and cats. The elaboration of four major toxins ( $\alpha$ ,  $\beta$ ,  $\tau$ , and  $\epsilon$ ) is the basis for typing the organism into five toxigenic phenotypes, A to E. Each type may also express a subset of at least 10 other established toxins, including *C. perfringens* enterotoxin (CPE), a well characterized virulence factor whose production is supposedly co-regulated with sporulation. Dogs with *C. perfringens*-associated diarrhoea frequently exhibit large bowel diarrhoea characterized by increased frequency of bowel movements with tenesmus, faecal mucus and haematochezia; however, clinical signs of enteritis or enterocolitis are also commonly seen. A strong association has also been detected between the CPE (detected via an enzyme-linked immunosorbent assay, ELISA) and acute haemorrhagic diarrhoeal syndrome (AHDS). CPE was detected in the faeces of 8 of 12 dogs (67%) that had clinical signs consistent with AHDS. Of the four dogs that had peracute symptoms and died as a result of the disease, all had faecal specimens positive for CPE.

### Diagnosis

Currently, diagnosis of *C. perfringens*-associated diarrhoea in the dog is made based on detection of CPE in faecal specimens in conjunction with clinical signs of disease. The value of quantitative faecal culture and faecal spore counts have been shown to be of poor diagnostic value as the organism is isolated from more than 80% of healthy dogs, and there is no correlation between spore counts and detection of enterotoxin. There is only one commercially available ELISA kit (Techlab Inc.) for detection of CPE in faecal specimens; however, the performance characteristics of this assay have not been validated in the dog to date.

### Treatment

Antibiotics that have been recommended for the treatment of canine *C. perfringens*-associated diarrhoea include oral ampicillin (22 mg/kg p.o. q8h), metronidazole (10 mg/kg p.o. q12h) and tylosin (15 mg/kg p.o. q12h). Tetracycline use should be avoided due to the high incidence of tetracycline resistance.

### *Clostridium difficile*

*Clostridium difficile* is a Gram-positive, anaerobic spore-forming bacillus and is the major cause of antibiotic-associated pseudomembranous colitis in human patients. *C. difficile* has also been associated with diarrhoea and enterocolitis in foals and adult horses, as well as diarrhoea in dogs. *C. difficile*-associated diarrhoea is less common in cats and a recent study by the author documented an incidence of 5% in diarrhoeic cats. Two toxins, A and B, are thought to be primarily responsible for disease associated with the organism, although other toxins may also play a role.

### Diagnosis

Current diagnosis of *C. difficile*-associated diarrhoea is primarily made based upon detection of toxin A or toxin B in faecal specimens via ELISA. Isolation of the organism alone is not sufficient for diagnosis due to the presence of non-toxigenic strains. In addition, previous

studies have reported no significant difference in the isolation of *C. difficile* from diarrhoeic and non-diarrhoeic dogs, although animals that are toxin-positive are invariably culture-positive. Similar to *C. perfringens*, a strong association was found between the detection of *C. difficile* toxin A and the presence of AHDS.

### Treatment

Metronidazole (10 mg/kg p.o. q12h for approximately 7 days) administration is the therapy of choice for dogs and cats with suspected *C. difficile*-associated diarrhoea. Although metronidazole-resistant *C. difficile* isolates obtained from foals and adult horses have been reported, a recent study evaluating the susceptibilities of 70 canine *C. difficile* isolates showed that all were susceptible to  $\leq 1$   $\mu$ g/ml metronidazole. The second drug of choice in humans and occasionally in horses is vancomycin; however, it is used only in cases of non-responsive *C. difficile*-associated diarrhoea or when metronidazole-resistant strains have been demonstrated.

### *Campylobacter*

*Campylobacter* species are small (0.2–0.5 x 0.5–5  $\mu$ m), microaerophilic, Gram-negative curved rod-shaped bacteria. *Campylobacter* species that have been implicated in canine enteric disease include *C. jejuni*, *C. coli*, *C. helveticus* and *C. upsaliensis*. It has recently been shown that some selective media can have an inhibitory effect on a number of *Campylobacter* spp., resulting in more sensitive species, such as *C. upsaliensis*, or other catalase-negative or weakly positive species being missed. Faecal shedding of *C. jejuni* is significantly greater in dogs <6 months old and during the summer and autumn. The higher prevalence of infection in puppies versus adult dogs may reflect increased exposure of young animals to faecal excrement and confinement to a limited space. In addition, the unexposed immune system of puppies may increase susceptibility to intestinal colonization by *C. jejuni*. Other enteric pathogens, such as parvovirus, *Giardia* or *Salmonella*, may play a synergistic role. The isolation of *Campylobacter* spp. from a diarrhoeic animal does not necessarily implicate *Campylobacter* as a cause of the diarrhoea. Indeed a recent study documented a significantly higher incidence of *Campylobacter* in healthy, non-diarrhoeic cats (20%) than in diarrhoeic cats (11%).

### Diagnosis

*Campylobacter*-like organisms (CLOs) can be identified by examining stained smears (Gram stain or Romanowsky-type stain) of fresh faeces from the patient. The characteristic morphology of the organism (slender, curved rods with an 'S' shape or seagull-shaped appearance) allows it to be identified relatively easily. The major limitation of direct examinations is that the procedure fails to differentiate between species of *Campylobacter* or between related organisms including *Helicobacter* spp. and *Anaerobiospirillum* spp. In addition, identification of CLOs is not sufficient to warrant a diagnosis of *Campylobacter*-associated diarrhoea as many healthy dogs and cats can harbour

CLOs in their intestinal tract.

For optimal recovery of *Campylobacter* spp., faeces or faecal swabs should be fresh or placed immediately into anaerobic transport medium before refrigeration at 4°C. For isolation, the use of a formulated selective medium containing antimicrobial agents (e.g. Campy-CVA containing cefoperazone, vancomycin and amphotericin B) gives better recovery than other direct-plating selective media. Microaerophilic incubation conditions should be maintained and the plates should be incubated at 37°C, or at 42°C, when isolation of *C. jejuni* and *C. coli* from faeces is attempted. Suspect colonies should be Gram-stained and sub-cultured to 5% sheep blood agar (SBA). Biochemical tests can then be performed to determine the species of all CLOs isolated. The use of selective medium containing cefoperazone should be used when attempting to isolate *C. upsaliensis*, as the organism is more resistant to cefoperazone than to cephalothin. Characterization of *Campylobacter* infections or mixed infections with *Helicobacter* and *Campylobacter* spp. is best accomplished utilizing molecular structure-based diagnostics, employing genus- and species-specific polymerase chain reaction (PCR), restriction fragment length polymorphism (RFLP) analysis and 16S rRNA sequence analysis.

#### Treatment

Although diarrhoea produced by *Campylobacter* organisms is usually self-limiting, the zoonotic potential of the organism often necessitates medical therapy. It is now recognized that *Campylobacter* are a leading cause of enteric disease in people and that diarrhoeic and non-diarrhoeic dogs can serve as sources of infection for humans. The drugs of choice are the macrolides (erythromycin at 10–15 mg/kg p.o. q8h) or quinolones (enrofloxacin at 5 mg/kg p.o. q12h). However, due to the high rate of mutational resistance *Campylobacter* organisms have to the quinolones, a resistance that sometimes occurs while animals are being treated, they are not the drug of choice. Erythromycin is the drug of choice, despite the associated gastrointestinal (GI) side-effects. The duration of excretion in infected dogs and cats can be as long as 4 months and infected animals should be quarantined away from children during this period.

#### Salmonella

*Salmonella* species are primarily motile, non-spore-forming, Gram-negative aerobic bacilli. There are currently over 2000 described serotypes of *Salmonella* that have been associated with both human and animal disease. *Salmonella* spp. are one of the most common causes of human food-borne disease. Clinical salmonellosis in dogs and cats is rare, although prevalences are higher in puppies and kennel populations. Isolation of *Salmonella* spp. from adult dogs ranges from 0 to 2% in non-diarrhoeic animals, and from 0 to 1% in diarrhoeic dogs. The isolation rates are similar in non-diarrhoeic and diarrhoeic cats. A recently published study evaluating the prevalence of *Salmonella* among dogs fed raw food diets, isolated *Salmonella* spp. from 80% of the diet samples and 30% of the stool samples.

#### Clinical signs

Most *Salmonella*-infected dogs and cats are asymptomatic, although some animals may manifest clinical signs of systemic sepsis. Signs of clinical salmonellosis in dogs include fever, anorexia, diarrhoea (which may be bloody), vomiting, weight loss, nasal discharge, pelvic limb paresis and abortion.

#### Diagnosis

The traditional diagnosis of salmonellosis is made based on isolation of the organism in conjunction with clinical signs and assessment of potential risk factors, such as hospitalization, age, environmental exposure and antibiotic administration. However, isolation of *Salmonella* is not necessarily indicative of involvement in disease as similar isolation rates can be detected in healthy non-diarrhoeic animals. Haematological abnormalities are variable, and include a non-regenerative anaemia, lymphopenia, thrombocytopenia and neutropenia with a left shift. Toxic neutrophils are found in animals with systemic disease and endotoxaemia, findings similar to those documented with canine parvovirus. Fresh faecal specimens should be placed on to one or more selective media, including MacConkey agar, XLD agar, and brilliant green agar. For enrichment, selenite F, tetrathionate, or Gram-negative broth are recommended.

#### Treatment

Intravenous fluid therapy may be required depending on the severity of the diarrhoea. Antibiotic therapy is typically indicated for animals with concurrent signs of systemic infection or history of immunosuppression. Antibiotics reported to be effective against *Salmonella* include fluoroquinolones, chloramphenicol, trimethoprim-sulphonamide and amoxicillin. Fresh-frozen plasma may be beneficial for dogs with more severe signs of endotoxaemia.

#### Pathogenic *Escherichia coli*

*Escherichia coli* is a pleomorphic, Gram-negative, non-spore-forming rod that is a member of the family *Enterobacteriaceae*. Several distinct pathogenic categories (pathotypes) of diarrhoeogenic *E. coli* are now recognized. Although the virulence determinants of each *E. coli* pathotype are distinct, they can generally be categorized as either colonization factors (adhesins), which enable the bacteria to bind closely to the intestinal mucosa and resist removal by peristalsis, or secreted toxins, which interfere with the normal physiological process of host cells. Despite the occurrence of *E. coli* as a normal commensal in the canine intestine, there is increasing evidence that certain *E. coli* pathotypes cause intestinal disease in dogs. The three pathotypes that have been studied in the dog are enterotoxigenic *E. coli* (ETEC), enterohaemorrhagic *E. coli* (EHEC) and enteropathogenic *E. coli* (EPEC). Very little is known about pathogenic *E. coli* in cats, although EPEC was isolated from approximately 5% of cats with diarrhoea, enteritis or septicaemia.

#### Enterotoxigenic *E. coli*

The true incidence of this pathotype in canine diarrhoea is still unclear, with reported prevalences among

diarrhoeic dogs ranging from 0 to 31%. The bacteria colonize the proximal small intestine, where they produce heat-stable (ST) and occasionally heat-labile (LT) enterotoxins. These enterotoxins result in overproduction of cyclic adenosine monophosphate (cAMP) and cyclic guanosine monophosphate (cGMP) with consequent development of a secretory diarrhoea.

#### Enteropathogenic *E. coli*

EPEC strains are negative for Shiga-toxin and enterotoxin (ST and LT) genes, but carry the chromosomally located gene, *eaeA* (*E. coli* attaching effacing). *E. coli* isolates from 44 of 122 dogs (36%) dying with diarrhoea were found to have the *eaeA* gene and *E. coli* was the sole pathogen identified in 15 of 44 (34%) dogs.

#### Enterohaemorrhagic *E. coli*

EHEC strains bind tightly to epithelial cells and produce the same type of attachment-effacement lesions as seen with EPEC. EHECs are minimally invasive but do incite an inflammatory response, predominantly in the large intestine. The prototype EHEC, a strain of *E. coli* of the serotype O157:H7, is a significant food-borne pathogen of human beings. Haemolytic-uraemic syndrome is the most important complication of *E. coli* O157 infection, and is characterized by microangiopathic haemolytic anaemia, thrombocytopenia and acute renal failure in approximately 7% of human cases. To date, only a single report has documented the isolation of this serotype from a dog's faeces. The isolated strain was found to be identical to a strain isolated from an affected child who had contact with the dog. This finding suggests that similar to cattle, dogs may serve as potential vectors for transmission of EHEC O157.

#### Clinical signs

Pathogenic *E. coli* strains are commonly isolated from faeces of apparently healthy dogs, and clinical signs can range from asymptomatic carriage to haemorrhagic diarrhoea. In addition, clinical signs can be variable because of the relatively high incidence of concurrent enteric infections with parvovirus, *Clostridium perfringens* and intestinal parasites. The predominant clinical sign of enterotoxigenic *E. coli* infection is profuse watery diarrhoea.

#### Diagnosis

Because *E. coli* is a significant component of the commensal canine intestinal flora, isolation of the organism is not diagnostic, nor does it allow differentiation between pathogenic and non-pathogenic strains. However, culture enables the application of molecular techniques for detection of specific toxin genes among isolated organisms. Culture of *E. coli* involves spreading fresh faecal specimens on to selective media, such as MacConkey agar, which will only support the growth of Gram-negative organisms. Single lactose-positive colonies are then sub-cultured and speciated through biochemical testing. PCR has become one of the most common methods for detecting and differentiating pathogenic strains of *E. coli*. A recent study showed that it is possible to detect 11 of the major virulence

genes of *E. coli* in faecal specimens from dogs with four multiplex PCRs. Although EPEC and EHEC are associated with characteristic attaching and effacing lesions, molecular techniques for the detection of genes specific for each pathotype is more reliable than histological examination.

#### Treatment

The use of antimicrobials is controversial for several reasons. These bacteria have a relatively high incidence of inherent resistance to antibiotics because of the presence of a Gram-negative cell wall, and because of the high incidence of conjugative transfer of resistance determinants. In addition, antibiotic therapy may enhance toxin synthesis or promote its release from the bacteria with a consequent increased rate of haemorrhagic colitis. Canine patients with only mild clinical signs probably do not warrant antibiotic treatment, whereas parenteral antibiotics and fluid therapy are indicated in severe cases, particularly if the patient is septicemic. The *Enterobacteriaceae* are usually resistant to chloramphenicol, tetracyclines, ampicillin and sulphonamides. Clinically stable animals can be treated with amoxicillin-clavulanate and first- or second-generation cephalosporins until susceptibility results are known. Dogs with life-threatening bacteraemia should be treated with amikacin, a third-generation cephalosporin, or enrofloxacin.

Orally administered autogenous or recombinant vaccines have been studied extensively in farm animals in an effort to help prevent or treat ETEC-mediated diarrhoea. An orally administered autogenous vaccine containing heat inactivated *E. coli* was administered to diarrhoeic puppies and adult dogs once daily for 14 days, and led to a significant decrease in morbidity and mortality. Additional studies are warranted to ensure the safety of this therapeutic regimen.

### Viral infections

Canine and feline viral enteritis are usually diagnosed in younger unvaccinated animals. The animal's age, history, clinical signs and haematological findings are important in ranking a viral aetiology as a likely cause of the animal's diarrhoea.

#### Canine parvovirus

Dogs are susceptible to infection by two types of parvovirus. Canine parvovirus-1 (CPV-1) is a relatively non-pathogenic virus that is occasionally associated with myocarditis, pneumonitis and gastroenteritis in very young puppies. Canine parvovirus-2 (CPV-2) causes classic parvovirus enteritis 5–12 days after infection via the faecal-oral route. CPV-2b is a more recently recognized mutated form of CPV-2, which may be more pathogenic in some dogs. Dobermanns, Rottweilers, Pit Bull Terriers and Labrador Retrievers appear more susceptible than other breeds.

The virus replicates in the intestinal crypts and causes severe villous blunting, diarrhoea, vomiting and subsequent bacterial translocation. Presenting complaints can vary from lethargy and anorexia, to

vomiting with or without blood. Diarrhoea can be absent in the early stages of infection and usually occurs 24–48 hours after onset of vomiting. The diarrhoea can often be profuse and haemorrhagic. Protein-losing enteropathy characterized by panhypoproteinaemia can be seen in severe cases. Dogs are predisposed to sepsis, secondary to neutropenia associated with viral damage to bone marrow progenitors, and bacterial translocation due to intestinal damage. *Clinical signs* can be exacerbated with concurrent infection with distemper virus, coronavirus, *Salmonella*, *Campylobacter*, *Giardia* or other intestinal parasites.

### Clinical signs

Anorexia, lethargy, fever, vomiting, diarrhoea and dehydration are common. Hypothermia, icterus and disseminated intravascular coagulation (DIC) are typically seen in severe cases with bacterial sepsis or endotoxaemia.

### Diagnosis

The diagnosis is often made tentatively on the basis of clinical details, history and physical examination findings. A history of sudden onset of vomiting and diarrhoea in a young dog, particularly if the puppy is unvaccinated or only partially vaccinated, warrants consideration. The presence of neutropenia on the haemogram in association with signs of enteritis is suggestive of CPV; however, salmonellosis or severe infections can also be associated with neutropenia. There are no pathognomonic findings on a serum biochemistry profile, although hypoglycaemia, hypokalaemia, prerenal azotaemia and increased bilirubin or liver enzymes are commonly found. Abdominal radiography is indicated to help rule out an intestinal foreign body, and may reveal intestinal gas, intestinal fluid and ileus. A faecal ELISA test for CPV-2 should always be performed on faeces, even if diarrhoea is not present. The test is considered sensitive and specific; however, the ELISA test result may be negative if the assay is performed too early in the clinical course of the disease, or after 10–14 days following infection. Other tests that can be undertaken to confirm the diagnosis of CPV include electron microscopic evaluation of the faeces for the presence of the virus (CPV-1 is indistinguishable from CPV-2), haemagglutination inhibition for serum IgM, histopathology of intestinal lesions and immunohistochemistry of intestinal biopsy samples.

### Treatment

Treatment is supportive and similar to other severe, acute infectious enteropathies. Intravenous fluid and electrolyte therapy is indicated, with particular attention given to potassium repletion. The intramedullary route can be utilized in very small puppies, although the subcutaneous route is likely to be inadequate. Dextrose solution (2.5–5%) is added to the intravenous fluids if the dog is hypoglycaemic. Plasma or colloids (dextran 70 or hetastarch) are indicated if the serum albumin concentration drops below 20 g/l. Antibiotics are administered to febrile or severely neutropenic dogs. If the animal is neutropenic, but afebrile, the administration of a first-generation cephalosporin is reasonable. Dogs in septic shock should be treated

with a broad spectrum aerobic and anaerobic antibiotic (e.g. ampicillin plus amikacin). Human granulocyte colony-stimulating factor (G-CSF) at 5 µg/kg s.c. or i.v. q24h has been used to increase neutrophil numbers, but may not influence patient outcome, whereas some benefit has been shown for ω-interferon. Anti-emetics, such as prochlorperazine, metoclopramide or ondansetron, are indicated if the vomiting is intractable. Metoclopramide is most effective when administered as a constant rate infusion at a dose of 1 mg/kg q24h. Gastric protectants, including H<sub>2</sub> receptor antagonists and sucralfate, are indicated if there is evidence of secondary oesophagitis. Broad spectrum anthelmintics to treat concurrent intestinal parasites should be administered when the dog is no longer vomiting. Most dogs can be gradually weaned on to a bland diet of cottage cheese and rice, or a commercially available highly digestible diet; however, the presence of intractable vomiting might warrant the administration of partial or total parenteral nutrition.

### Vaccination

Vaccination with a modified live parvovirus is effective at preventing the disease. Vaccines should not be given before 6 weeks of age because of interference by maternally derived antibody. Depending on the vaccine used, an initial course of vaccination is completed at 10–12 weeks.

The frequency of booster vaccinations is controversial, and serum antibody concentration, although a relatively crude measure of immunity, shows relatively good correlation between a 'positive' antibody titre and protection against canine parvovirus. However, the absence of antibody (an obvious decision point in establishing the 'need' to administer booster vaccine) does not necessarily correlate with susceptibility. Furthermore, there are no established test standards for measuring antibody titres in dogs and cats. One should expect, for the same serum sample sent to two different laboratories, two different reference ranges and two quite different antibody titres reported. For example, one laboratory will report a 'positive' titre against canine parvovirus as >1:80, while another laboratory reports a value of >1:5 as 'positive'. Interpreting test results can be confusing for the clinician and frustrating for the pet owner.

### Feline parvoviral enteritis

Feline parvoviral enteritis (feline panleucopenia) is caused by a parvovirus distinct from CVP-2b, although CVP-2b can also infect cats and cause disease. Feline parvovirus has become an uncommon disease because of routine vaccination; however, outbreaks are occasionally seen in unvaccinated animals, particularly feral populations and catteries. *The clinical signs are similar to those described for dogs with parvoviral enteritis.*

### Diagnosis

Diagnosis is based on the history, physical examination findings, results of a haemogram (neutropenia) and faecal ELISA. The ELISA test used to detect canine parvovirus has been reported to cross-react with feline parvovirus.



### Treatment

The principles of treatment are virtually identical to those described for the dog with parvovirus enteritis.

### Vaccination

Vaccination with a modified live parvovirus is very effective and is given to kittens at 10–12 weeks of age. A killed vaccine should be administered to pregnant queens, as transplacental infection of kittens with the vaccine strain can cause cerebellar hypoplasia.

The frequency of booster vaccinations is controversial and serum antibody concentration, although a relatively crude measure of immunity, shows good correlation between a 'positive' antibody titre and protection against feline parvovirus.

### Canine coronavirus enteritis

Canine coronavirus is closely related to feline enteric coronavirus/feline infectious peritonitis (FIP) and transmissible gastroenteritis in pigs. Infection with canine coronavirus is associated with milder clinical signs than parvovirus, as the virus destroys mature enterocytes at the villus tips while sparing the intestinal crypts. The bone marrow is typically spared, affording these dogs a relatively good prognosis with supportive therapy.

Although a canine coronavirus vaccine is available, there is no scientific evidence that this disease is a significant problem in household dogs. It is mainly a problem when large numbers of dogs are brought together under heavy stress (i.e. in dog shows or kennel situations).

### Feline enteric coronavirus

Feline enteric coronavirus is related to FIP-producing strains of coronavirus, and invades the enterocytes at the tips of the villi. Infected cats may be asymptomatic, or develop mild, transient diarrhoea and fever. Infected cats can seroconvert and test positive on serological testing. In addition, feline enteric coronavirus may mutate to FIP virus.

## Intestinal fungal infections

### *Histoplasma*

*Histoplasma capsulatum* may affect the GI tract, respiratory tract, bones and eyes; infection has not been reported in the UK. Intestinal involvement in dogs is characterized by diarrhoea (with or without melaena or haematochezia) and severe weight loss. Cats are more commonly presented with pulmonary involvement. In dogs, the colon is usually more severely affected, resulting in clinical signs of tenesmus, mucoid stools and haematochezia. Severe disease can be associated with panhypoproteinaemia.

### Diagnosis

Identification of the organism via cytology or histology is required. Rectal scrapings should be performed in dogs suspected of having histoplasmosis. A comprehensive diagnostic investigation, consisting of a fundoscopic examination to look for evidence of chorioretinitis,

thoracic radiography to evaluate for pulmonary interstitial infiltrates or hilar lymphadenopathy, and abdominal ultrasonography to evaluate the spleen, liver and mesenteric lymph nodes is usually indicated.

### Treatment

Itraconazole (5 mg/kg p.o. q12h for 4 days, then q24h thereafter) or amphotericin B (0.25 mg/kg i.v. as test dose, then 0.5 mg/kg i.v. up to three times weekly) are usually effective. The prognosis is extremely variable depending at what stage the disease is diagnosed.

## Conclusion

Comprehensive faecal exams are pivotal in the diagnostic investigation of dogs and cats with diarrhoea or vomiting. The diagnostic yield will be markedly increased with the examination of fresh faecal specimens, the utilization of a centrifugation technique with zinc sulphate solution, and the timely incorporation of immunoassays for diagnosing *Giardia* and *Cryptosporidium* spp. The clinical documentation of enteropathogenic bacteria causing diarrhoea in dogs is clouded by the presence of many of these organisms existing as normal constituents of the indigenous intestinal flora. The diagnosis of a putative bacterial enteropathogen(s) in dogs and cats should be made based on a combination of parameters, including clinical details and predisposing factors, clinical signs, serological assays for toxins, faecal culture and PCR. Relying on results of faecal culture alone is problematic because *Clostridium perfringens*, *Clostridium difficile*, *Campylobacter* spp., and pathogenic and non-pathogenic *E. coli* are commonly isolated from apparently healthy dogs and cats. Faecal cultures may be useful in procuring isolates for the application of molecular techniques, such as PCR, for detection of specific toxin genes or molecular typing of isolated strains to establish clonality in suspected outbreaks. The oversimplified attempt to characterize acute bacterial-associated diarrhoea by anatomical localization of clinical signs should be discouraged, as most of the above mentioned bacteria have been associated with both small and large intestinal diarrhoea. Accurate diagnosis of infections may require diagnostic laboratories to incorporate PCR-based assays using genus- and species-specific primers to facilitate detection of toxin genes and differentiation of species that appear phenotypically and biochemically similar.

## References and further reading

- Alcaino HA and Baker NF Baker (1974) Comparison of two flotation methods for detection of parasite eggs in feces. *Journal of the American Veterinary Medical Association* **164**, 620–622.
- Aspinall ST, Wareing DR, Hayward PG and Hutchinson DN (1996) A comparison of a new campylobacter selective medium (CAT) with membrane filtration for the isolation of thermophilic campylobacters including *Campylobacter upsaliensis*. *Journal of Applied Bacteriology* **80**, 645–650.
- Baljer G, Hinsch F and Mayr B (1990) Clinical experience with kennel-specific *E. coli* oral vaccines in dogs. *Tierärztliche Praxis* **18**, 65–68.
- Barr SC, Bowman DD and Heller RL (1994) Efficacy of fenbendazole against giardiasis in dogs. *American Journal of Veterinary Research* **55**, 988–990.

- Bartlett JG, Chang TW, Gurwith M, Gorbach SL and Onderdonk AB (1978) Antibiotic-associated pseudomembranous colitis due to toxin-producing clostridia. *New England Journal of Medicine* **298**, 531–534
- Bruce D, Zochowski W, Fleming GA (1980) *Campylobacter* infections in cats and dogs. *Veterinary Record* **107**, 200–201
- Cave NJ, Marks SL, Kass PH, Melli AC and Brophy MA (2002) Evaluation of a routine diagnostic fecal panel in dogs with diarrhea. *Journal of the American Veterinary Medical Association* **221**, 52–59
- Glickman LT, Domanski LM, Patronek GJ and Visintainer F (1985) Breed-related risk factors for canine parvovirus enteritis. *Journal of the American Veterinary Medical Association* **187**, 589–594
- Hammermueller J, Kruth S, Prescott J and Gyles C (1995) Detection of toxin genes in *Escherichia coli* isolated from normal dogs and dogs with diarrhea. *Canadian Journal of Veterinary Research* **59**, 265–270
- Hoskins JD, Mirza T and Taylor HW (1996) Evaluation of a fecal antigen ELISA test for the diagnosis of canine parvovirus. *Journal of Veterinary Internal Medicine* **10**, 159
- Joffe DJ and Schlesinger DP (2002) Preliminary assessment of the risk of *Salmonella* infection in dogs fed raw chicken diets. *Canadian Veterinary Journal* **43**, 441–442
- Marks SL and Kather EJ (2003) Antimicrobial susceptibilities of canine *Clostridium difficile* and *Clostridium perfringens* isolates to commonly utilized antimicrobial drugs. *Veterinary Microbiology* **94**, 39–45
- Marks SL, Kather EJ, Kass PH and Melli AC (2002) Genotypic and phenotypic characterization of *Clostridium perfringens* and *Clostridium difficile* in diarrheic and healthy dogs. *Journal of Veterinary Internal Medicine* **16**, 533–540
- Mohr E and Mohr I (1992) Statistical analysis of the incidence of positives in the examination of parasitological specimens. *Journal of Clinical Microbiology* **30**, 1572–1574
- Mead PS, Slutsker L, Dietz V, McCaig LF, Bresee JS, Shapiro C, Griffin PM and Tauxe RV (1999) Food-related illness and death in the United States. *Emerging Infectious Disease* **5**, 607–625
- Monaghan C, Tierney U and Collieran E (1981) Antibiotic resistance and R-factors in the fecal coliform flora of urban and rural dogs. *Antimicrobial Agents and Chemotherapy* **19**, 266–270
- Pass MA, Odedra R and Batt RM (2000) Multiplex PCRs for identification of *Escherichia coli* virulence genes. *Journal of Clinical Microbiology* **38**, 2001–2004
- Torre E and Tello M (1993) Factors influencing fecal shedding of *Campylobacter jejuni* in dogs without diarrhea. *American Journal of Veterinary Research* **54**, 260–262
- Trevena WB, Hooper RS, Wray C, Willshaw GA, Cheasty T and Domingue G (1996) Vero cytotoxin-producing *Escherichia coli* O157 associated with companion animals. *Veterinary Record* **138**, 400
- Turk J, Maddox C, Fales W, Ostlund E, Miller M, Johnson G, Pace L, Turnquist S and Kreeger J (1998) Examination for heat-labile, heat stable, and Shiga-like toxins and for the eaeA gene in *Escherichia coli* isolates obtained from dogs dying with diarrhea: 122 cases (1992–1996). *Journal of the American Veterinary Medical Association* **212**, 1735–1736

# Disorders of the oral cavity

Linda J. DeBowes

## Introduction

Oral disease is a common problem of dogs and cats of all ages. An oral examination is a very important part of every physical examination. Some abnormality of the oral cavity is usually found when a dog's or cat's mouth is examined.

Clinical signs of oral disease vary depending on the underlying problem. A problem in the oral cavity should be suspected and ruled out for any dog or cat showing evidence of oral pain, difficulty eating, interest in food but reluctance to eat, excessive salivation, facial swellings or draining fistulas, halitosis or bleeding from the oral cavity.

## Periodontal disease

Periodontal disease is one of the most common problems in dogs and cats and increases in incidence and severity with advancing age.

Periodontal disease is a term that includes all stages of inflammation of the structures surrounding the teeth, ranging from gingival inflammation (gingivitis) to severe periodontitis, resulting in attachment loss and eventual tooth loss.

Gingivitis is reported to be present in at least 70% of cats and dogs by the time they are two years of age. Gingivitis will not progress to periodontitis in all animals. Many animals, however, will develop periodontitis (inflammation of the structures supporting the teeth). Most dogs by five years of age have some degree of periodontitis. The incidence of periodontal disease increases with age in dogs and cats, and decreases with increased size in dogs. Small and toy breed dogs are especially prone to gingivitis and periodontitis.

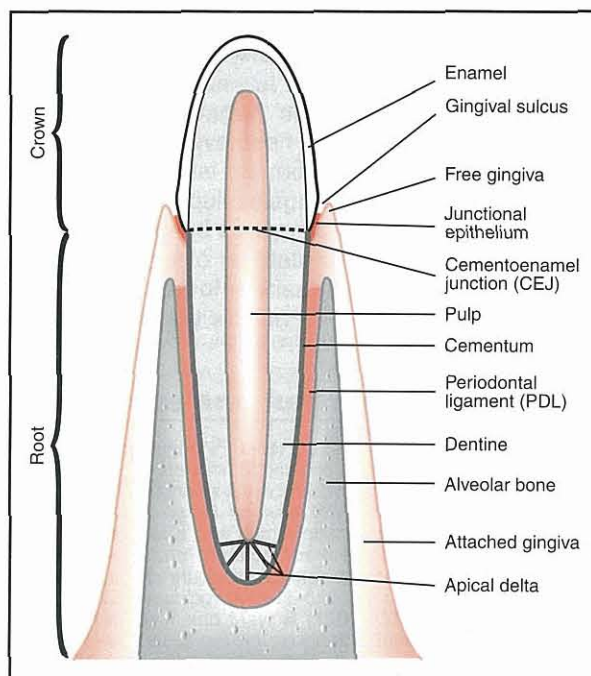
Several factors that predispose to the development of periodontal disease include:

- Crowding of the teeth
- Periodontal foreign material (e.g. hair or grass between teeth, in gingival sulcus)
- Eating non-abrasive foods (foods with no dental benefits)
- Malocclusions
- Specific plaque bacteria
- Rough tooth surfaces
- Abnormal host immunity.

Diabetes mellitus and retroviral infections also affect periodontal health and may predispose to gingivitis and periodontitis.

## Anatomy and physiology of the healthy periodontium

The tissues involved in periodontal disease include those collectively referred to as the periodontium. These tissues include the gingiva, periodontal ligament (PDL), alveolar bone and cementum (Figure 17.1). The gingival tissues include the attached and the free gingiva. The gingival sulcus is the space between the tooth and free gingiva. The 'normal' depth of the gingival sulcus, in healthy animals, is considered to be <3 mm in dogs and <0.5 mm in cats. The gingival epithelium attaches to the tooth surface at, or slightly below, the cemento-enamel junction (CEJ). This area of attachment is referred to as the junctional epithelium. The sulcular epithelium lines the inside of the gingival sulcus. The gingiva, especially the junctional epithelium, is important for providing a barrier between the oral cavity (gingival sulcus) and the tissues underneath (PDL, alveolar bone, cementum).



17.1 Anatomy of the healthy periodontium.

The tooth roots are covered by cementum, a non-vascular, non-innervated specialized calcified tissue that serves to attach the periodontal ligament fibres to the tooth root.

The alveolar bone surrounding the tooth root is a dense cortical bone to which the periodontal ligament attaches. The periodontal ligament is a highly vascularized and cellular connective tissue that anchors the tooth to the alveolar bone and distributes the forces of mastication to the surrounding alveolar bone.

Leucocytes (mainly neutrophils) migrate from local vessels through the junctional epithelium into the gingival sulcus as part of the normal defence mechanism in healthy gingiva. In addition to leucocytes, the gingival crevicular fluid (GCF) contains complement, antibodies and other defence mechanisms preventing and controlling local infection.

**Basic terminology**

The basic terminology used to describe periodontal disease is given in Figure 17.2.

Term	Definition
Calculus (tartar)	Calcified plaque
Endodontic disease	Disease of the dental pulp and dental periapical tissues
Gingivitis	Inflammation of the gingiva
Pellicle	A thin film of salivary glycoproteins that adhere to the tooth surface
Periodontitis	Inflammation and destruction of the periodontium (gingiva, PDL, cementum, alveolar bone)
Plaque	A sticky yellow/tan coloured bio-film that accumulates on the teeth. It contains bacteria, bacterial by-products, salivary products, debris and other cells. It is responsible for local inflammation
Pulp	The tissue in the central portion of the tooth, made up of blood vessels, nerves and cellular elements, including the odontoblasts that produce dentin.

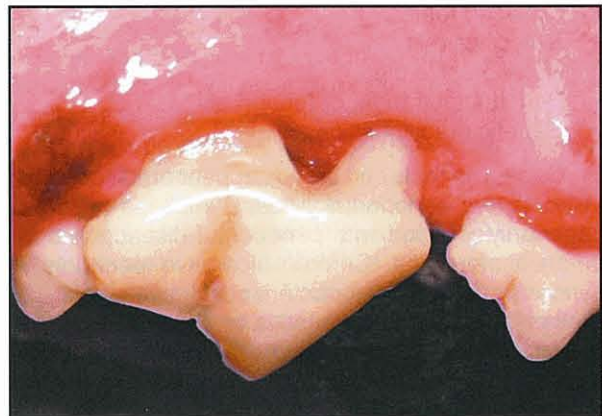**17.2** Basic terminology used in the description of periodontal disease. PDL = periodontal ligament.

**Pathogenesis**

Periodontal disease is the result of bacterial plaque accumulation and the associated inflammatory response. The initial bacteria attach to the tooth surface by adhering to the pellicle. Gram-positive bacteria express adhesion molecules that bind to salivary glycoproteins. These adhesions are important for bacterial colonization and growth of supragingival plaque. Gram-negative bacteria bind to the Gram-positive bacteria within days of initial plaque formation. If left on the tooth surface, the tightly adhered bacterial plaque becomes visible on the tooth surface adjacent to the gingival margin within days. If not removed, the supragingival plaque will increase, mature, and incite an inflammatory response in the gingiva. This initial gingivitis is referred to as marginal gingivitis. If the

plaque is removed at this early stage of periodontal disease, the inflammation resolves and the gingiva returns to normal healthy tissue. If the plaque is not removed, it may extend subgingivally where it will continue to elicit an inflammatory response in the gingiva, resulting in gingivitis. The subgingival area is where the disease is initially located and where the plaque must be eliminated to prevent chronic gingivitis and the potential of developing periodontitis.

Periodontitis is present when the other tissues of the periodontium become involved. The attached epithelium loses its coronal attachment and eventually the PDL, cementum and alveolar bone are affected. Not all dogs and cats with chronic gingivitis will develop periodontitis. It is impossible to determine which pets will have progressive disease and which will not. As the epithelial attachment is lost there will be an increase in the gingival sulcus depth. When this occurs it is referred to as a periodontal pocket. As disease progresses apically, and the PDL and alveolar bone are destroyed, there is an increasing periodontal pocket depth. If there is gingival recession as the attachment loss occurs a periodontal pocket may not form (Figure 17.3). In this case the attachment loss is measured from the CEJ to the attached gingiva (bottom of gingival sulcus).



**17.3** Gingival recession in a dog with periodontitis.

Plaque bacteria and bacterial by-products, such as lipopolysaccharide (LPS), stimulate the local production and release of proinflammatory cytokines. As part of the inflammatory process there is an increased production of matrix metalloproteinases (MMPs) and prostaglandin E<sub>2</sub> (PGE<sub>2</sub>). Proinflammatory cytokines stimulate and attract neutrophils to migrate into the GCF, adding to the inflammatory response. With increasing inflammation the quantity of GCF increases, as does the tendency to bleed more easily. Attachment loss associated with periodontitis results from destruction of the PDL and alveolar bone. The MMPs degrade the constituents of unmineralized connective tissues (e.g. collagen). The bone destruction is mediated through the release of PGE<sub>2</sub>.

Chronic inflammation and altered sulcular epithelium allow subgingival bacteria and bacterial substances to enter the gingival connective tissues and microcirculation, leading to continued production of degradative products and tissue destruction.

Early in the inflammatory process, neutrophils, followed later by macrophages and lymphocytes, migrate into the extravascular compartment, forming an inflammatory infiltrate. Periodontal pocket formation is associated with an inflammatory infiltrate of neutrophils, lymphocytes and monocyte–macrophages.

Periodontitis is generally considered an irreversible process with an inability for regrowth of normal cementum, PDL and alveolar bone. The progressive nature of this process will result in tooth loss if left untreated. In certain cases it may be possible to gain attachment or regrowth of periodontal supporting structures if more advanced dental techniques are used (see *BSAVA Manual of Small Animal Dentistry*).

**Clinical features**

Clinical signs of periodontal disease are:

- Halitosis
- Blood on toothbrush after brushing
- Blood on chew toys or food
- Blood-tinged saliva
- Discomfort on eating
- Nasal discharge (oronasal fistula)
- Lethargy and inappetence in severe cases.

Factors predisposing to periodontal disease:

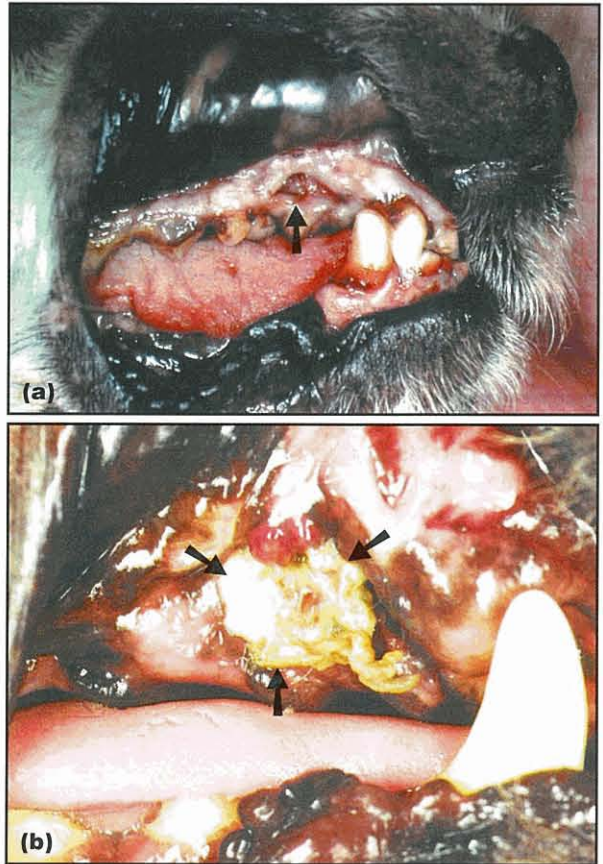
- Crowded teeth
- Malocclusions
- Non-abrasive diet
- Periodontal trauma or foreign bodies
- Genetic predisposition.

Certain animals and breeds appear predisposed to more severe periodontal disease. Maltese dogs are commonly affected with periodontal disease and ulcerative stomatitis. Chronic ulcerative periodontitis syndrome (CUPS) is characterized by severe halitosis, oral pain, ulcerative stomatitis and advancing periodontitis. Any breed may be affected; Greyhounds are a breed in which this problem is frequently seen.

Complications of periodontal disease are:

- Tooth loss
- Oronasal fistula formation
- Mandibular fracture
- Periodontal abscess
- Endodontic disease.

Severe periodontitis can result in several local problems and complications. Common manifestations of periodontitis include halitosis, gingival recession, tooth mobility and tooth loss. The maxillary canine teeth, especially in smaller breeds with narrow noses (e.g. Dachshund, Poodle) frequently have deep periodontal pockets on their palatal aspect. There is a thin layer of bone between the nasal cavity and the canine tooth root. Destruction of the bone occurs with severe periodontitis, resulting initially in an inapparent oronasal fistula. This may not cause clinical signs. On the other hand, sneezing may be present. In chronic cases with increased inflammation and infection a nasal discharge may be seen. Once the canine tooth is lost there is an apparent oronasal fistula (Figure 17.4) and unless it is very small there will be clinical signs.



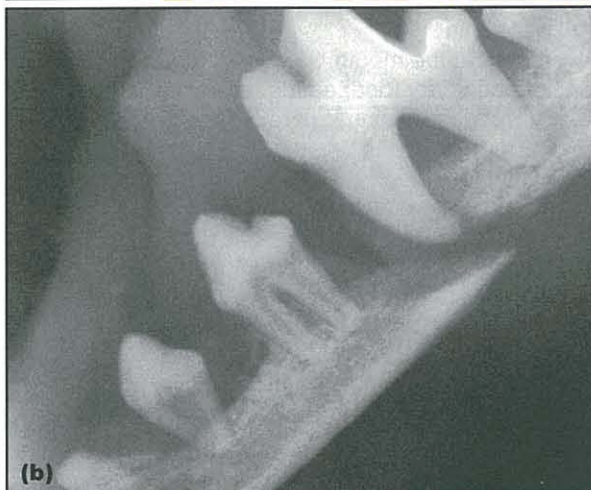**17.4** (a) Oronasal fistula (arrowed) secondary to severe periodontal disease and loss of the canine tooth. (b) Food and debris (arrowed) impacted in an oronasal fistula.

Periodontitis resulting in severe bone loss may predispose to mandibular fractures. This is especially true when significant bone loss occurs around the mandibular canines or first molars in small-breed dogs. Fractures in these dogs may occur easily when attempting to extract the tooth or if there is trauma such as from biting on a hard object or fighting with another dog (Figure 17.5).

The infection and inflammation associated with chronic periodontal disease can affect the animal's general health and well being. This appears especially true in pets with severe, generalized infection and inflammation. Owners may notice improved appetites, attitudes, haircoats and activity levels following treatment of chronic severe periodontitis in their pets. An association between the severity of periodontal disease and histological changes in the kidney, myocardium and liver has been found by DeBowes *et al.* (1996). There is mounting evidence in the human population that periodontal disease is a risk factor for cardiovascular disease, stroke, respiratory problems, pregnancy problems, and perhaps other problems as well. However, this canine study does not prove a cause and effect relationship between periodontal disease and disease of the myocardium, liver or kidneys. Additional studies will be necessary to document such an effect, if it does indeed exist. Diabetes in people is a risk factor for developing periodontal disease, and the presence of periodontal disease can affect the regulation of a diabetic patient.



(a)



(b)

**17.5** (a) Trauma from another dog resulting in a fractured mandible in a Yorkshire Terrier with severe periodontal disease. (b) Radiograph of patient in (a) showing a fracture in the mandible rostral to the carnassial tooth.

### Treatment

The goals of treatment are to remove all supra- and subgingival plaque and calculus to eliminate the stimulus for continued inflammation of the periodontal tissues. Polishing the teeth after scaling is essential to smooth the enamel surface and decrease the micro-etches in the tooth that make it more plaque retentive.

Periodontitis may result in deep periodontal pockets that may require more advanced therapy. Periodontal pockets deeper than 4–5 mm cannot be adequately scaled without exposure of the root surface. A gingival flap can be created to expose the root surface and allow for adequate scaling. Another treatment for periodontal pockets >4 mm is to scale the tooth root without creating a flap, and then place a slow-release antibiotic (doxycycline) preparation locally.

When teeth become mobile from severe attachment loss, extraction is often the best or only treatment option. Guided tissue regeneration (GTR) is possible, in selected cases, to allow for replacement of lost PDL and alveolar bone. Referral to a dental specialist is recommended for the advanced cases with special treatment needs. (The reader is referred to the *BSAVA*

*Manual of Small Animal Dentistry* and the References and further reading for in depth details on the treatment of periodontal disease.)

### Prevention of periodontal disease

To prevent periodontal disease, plaque must not be allowed to accumulate on the teeth and result in gingivitis and periodontitis. Predisposing factors should be eliminated if possible. Regular oral hygiene at home and regular professional care are both necessary for optimal oral health.

Oral home care includes:

- Brushing
- Dental diet
- Treats
- Chew toys.

Daily tooth brushing is recommended to mechanically remove the dental plaque. It is usually only necessary to brush the buccal and labial tooth surfaces. This is much easier for owners to do than trying to open a dog's or cat's mouth to brush the palatal and lingual aspects of the teeth. If the gingiva bleed when the teeth are brushed this indicates the presence of gingivitis. The owners should continue to brush the teeth and if the bleeding does not resolve in 10–14 days there is probably subgingival plaque or calculus or some other problem that is causing the ongoing inflammation. This area should be checked with an explorer and possibly dental radiography.

Mechanical removal of the plaque with daily tooth brushing is ideal. The addition of a dental diet to decrease plaque and calculus is the next step in a home oral hygiene plan. Additional helpful methods to decrease plaque and calculus include oral rinses or gels (e.g. chlorhexidine rinse), treats with dental benefits and toys that will help remove plaque.

Some of the treat products have the potential to cause dental problems. Any hard object that is small enough to get between the carnassial teeth (upper fourth premolar and lower first molar) for a dog to bite on has the potential of fracturing a tooth. Usually this is the upper fourth premolar. The author suggests only giving products that are so large they cannot pass between these teeth but can only be gnawed upon (e.g. large knuckle bone). If smaller treats are given that the pet can chew on, they should be flexible enough that they can be bent slightly. Fractured teeth from chewing on hard objects are a very common problem in dogs, especially those that are aggressive chewers.

When evaluating the effectiveness of diets or treats that have dental claims it is helpful to look for the Veterinary Oral Health Council (VOHC) seal on the package. The VOHC evaluates the research behind the various dental claims. The seal is awarded to those companies to use on the packaging of products that have passed the standards for a dental benefit as determined by the VOHC (<http://www.vohc.org/>). This is similar to the American Dental Association (ADA) or Good Housekeeping seal of approval.

## Disorders of the oral cavity

### Chronic gingivostomatitis in cats

Chronic gingivostomatitis is a relatively common and one of the most painful oral conditions in cats. It can also be one of the most frustrating oral problems for owners and for the veterinary surgeon trying to treat it.

There is inflammation and proliferation of the gingiva and oral mucosa. The inflammation ranges from mild to severe and with increasing chronicity the inflammation usually increases and the tissues may become ulcerated. The affected areas may include the gingiva, buccal mucosa, palatal mucosa, pharynx, mucosa in the back of the mouth in the area lateral to the palatoglossal arch, glossopalatine arch and tongue. The fauces is the archway between the pharyngeal and oral cavities, formed by the tongue, anterior tonsillar pillars and soft palate. When this area in the caudal portion of the oral cavity is involved and there is inflammation, with or without ulceration, it is referred to as faucitis.

### Aetiology

The underlying aetiology of chronic gingivostomatitis is not known and in fact may be multifactorial or there may be multiple syndromes with different aetiologies.

Cats with chronic gingivostomatitis have significantly higher serum IgG, IgM and IgA concentrations, and lower salivary IgA levels compared with healthy cats. The decrease in salivary IgA concentrations may be a factor in the pathogenesis of this disease.

Viral infections have been suggested as potential causes or contributing factors in the development of stomatitis and faucitis in cats. Feline calicivirus can cause acute faucitis and has been isolated from cats with chronic gingivostomatitis. Cats with chronic gingivostomatitis are more likely to be shedding feline calicivirus and feline herpes virus 1 from the oral mucosa than cats without chronic gingivostomatitis. However, feline calicivirus has not been shown to cause feline chronic gingivostomatitis. It may be a contributing factor to the aetiology or severity of chronic gingivostomatitis but until additional studies are done we will not know its role, if any, in chronic gingivostomatitis. Feline immunodeficiency virus (FIV) may play a role in the development of gingivostomatitis in some cases. Low salivary IgA levels in FIV-positive cats may predispose to oral diseases. FIV-associated oral inflammation is more likely in older cats with very severe chronic oral lesions. Feline leukaemia virus (FeLV) does not appear to be a significant risk factor for developing chronic oral inflammatory lesions. The extent to which viral infections play a role in chronic oral inflammatory lesions has not been determined. In many cases of chronic oral inflammatory disease a primary aetiology other than periodontal disease is not identified. It has been speculated that these cats have an exaggerated inflammatory response to the bacterial plaque.

*Bartonella henselae* infection has been suggested as a possible factor in the development of feline chronic gingivostomatitis. Cats positive for *B. henselae* and

FIV have an increase in mandibular lymph node swelling and gingivitis compared with non-infected cats. The role of *B. henselae* in feline chronic ulcerative stomatitis and faucitis remains an unknown and controversial issue at this time. The treatment (with azithromycin) of a few cats in the author's practice with severe ulcerative stomatitis and a positive *B. henselae* titre, has resulted in similar improvements as seen with other antibiotics administered but not a resolution of the problem itself.

### Clinical features

The clinical signs for chronic gingivostomatitis in cats include:

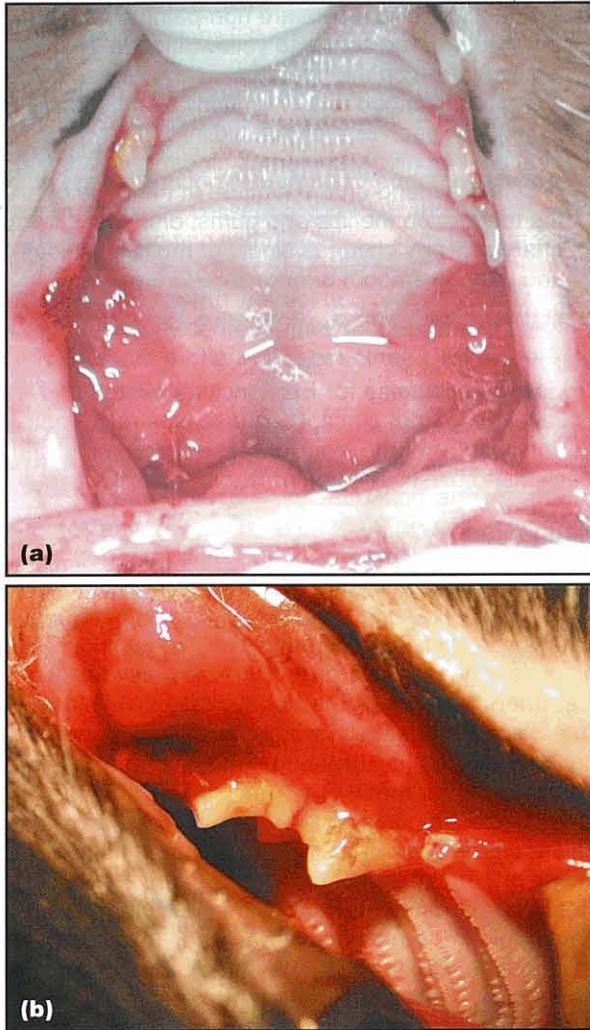
- Halitosis
- Dysphagia
- Pawing at the mouth
- Not eating dry food, eating only soft food
- Not eating anything, anorexic
- Growling or crying when eating
- Weight loss
- Decreased or lack of grooming, unkempt appearance
- Crying when yawning or has stopped yawning
- Excess drooling
- Blood-tinged saliva
- Change in temperament, may be nasty or reclusive
- Mandibular lymph node enlargement.

It may be difficult to open the mouth of a cat with chronic ulcerative stomatitis and faucitis without analgesia, sedation or general anaesthesia. However, in most cases, if gentle, the lips can be pulled back to get an idea of the inflammation present, and often if the mouth is opened very slowly the entire oral cavity can be viewed. An oral examination may reveal:

- Pain on opening the mouth
- Gingivitis and stomatitis
- Faucitis
- Proliferation of tissue with or without ulceration
- Oral tissues are friable and bleed easily
- Fairly symmetrical distribution of inflammation on both sides of the mouth.

### Diagnosis

The diagnoses of stomatitis and faucitis are made by visual inspection of the oral cavity (Figure 17.6). The diagnostic evaluation is focused towards identifying any possible underlying factors or concurrent diseases. Diagnostics should include evaluation of FeLV and FIV status. Consideration is given to evaluation for calicivirus (virus isolation from oral swab) and *B. henselae* infection. If there are missing teeth, dental radiographs should be made to evaluate for retained roots. If there is an area of asymmetrical inflammation and ulceration a biopsy sample should be taken for histopathology to evaluate for neoplasia.



17.6

(a) Cat with stomatitis and faucitis. (b) Severe inflammation and bleeding in a cat with stomatitis.

### Treatment

**Extraction:** The most successful long-term treatment for cats with chronic gingivostomatitis is the extraction of all premolars and molars including any retained root tips (referred to as a full-mouth extraction). While medical management (see below) is successful in the short-term in some patients, responses are often transient. The reason for extracting the premolars and molars is to remove the site of attachment for the bacterial plaque. This is based on the opinion that these cats appear to have an exaggerated inflammatory response to the plaque bacteria. By decreasing the plaque the inflammation may then resolve. Many cats will have an excellent response to this treatment requiring no chronic medical treatment. The inflammation usually takes 3–6 weeks to resolve following the extractions and during this time supportive medical management may be indicated. In evaluating the response, the improved clinical condition should be taken into account and it is not necessary to treat minor residual inflammation in an asymptomatic cat. Some cats have only a partial improvement and require long-term medical management. These cats may respond well to low doses of immunosuppressive drugs and antibiotics.

A few cats will have no response and require long-term medical management for bacterial infections and suppression of the inflammation. Fortunately, these are the minority of patients. The poor responders may also be those patients that have had long-standing, chronic inflammation that has been treated with high and repeated doses of glucocorticoids. The earlier the teeth are extracted the better the outcome in most cases.

One of the major reasons that the full-mouth extraction procedure is less successful than desired is that roots may be retained. If the teeth break during extraction or have lost their crowns leaving roots behind, the roots will still serve as an area for bacterial accumulation. Thus, it is essential to remove all tooth roots. Curetting the alveolus to remove any remaining periodontal ligament has also been recommended. Antibiotic administration following extractions is recommended to help resolve the oral infection in severe cases. In some cases with slow improvement it may be beneficial to treat with 2 weeks each, in succession, of clindamycin, amoxicillin–clavulanic acid and metronidazole to resolve the residual infection/inflammation and return cats to normal eating behaviour. Analgesia is an important consideration in these patients. Appropriate pre-emptive analgesia should be given with the pre-anaesthesia medications. Postoperative analgesia is managed very well with oral (buccal mucosal) administration of buprenorphine for 3–5 days.

**Medical management:** Owners may be reluctant to have multiple extractions done initially and may want to try medical management instead. The goals of medical management are to decrease the bacterial plaque accumulation and inhibit the associated inflammatory response. Concurrently with medical management a complete oral examination and dental cleaning should be done. Any teeth with severe periodontitis and any retained root should be extracted.

Systemic antibiotics may result in improvement in some cases. However, this is usually temporary and some patients will relapse even while on antibiotic therapy. Several antibiotics are appropriate including amoxicillin–clavulanic acid, clindamycin, metronidazole and azithromycin. Topical rinses or gels (i.e. with 1.2% chlorhexidine) may also be beneficial in some cats.

The most commonly used drugs for suppressing the inflammatory and immune response in these cats are glucocorticoids. Glucocorticoid administration will result in clinical improvement in a greater number of cases than antibiotic therapy alone. Usually antibiotic therapy and glucocorticoids are used concurrently, at least in the initial treatment, and during flare-ups. The long-term use of corticosteroids may have detrimental effects and the lowest amount possible should be given. Either injectable (methylprednisolone acetate) or oral route (prednisolone) may be used. Injectable treatment is usually recommended initially because the cat's mouth is so painful that orally administered medications may be difficult for the owner to give. The author usually gives 15–20 mg methylprednisolone acetate s.c. per cat. This usually improves the cat's attitude and appetite within 24–48



hours and the effects generally last for 3–6 weeks. In the most severe cases repeat treatment may be required every 3 weeks to maintain the cat's ability to eat and be comfortable.

Injectable ketoprofen (1–2 mg/kg s.c. once) will decrease the inflammation and improve the attitude and appetite in most cases. If a cat is not eating and is in pain the author uses ketoprofen instead of glucocorticoids as a single treatment, prior to a full-mouth extraction, if the procedure is not going to be performed for several days.

Ciclosporin A has been recommended as an immunosuppressive therapy for cats with chronic gingivostomatitis. It should be used with caution in cats with hepatic or renal disease. The reported responses indicate that it may help control gingivostomatitis in a certain number of these cats. There is very little information currently in the veterinary literature documenting its therapeutic effect but it may provide an alternative to glucocorticoid therapy. The bioavailability of the two available forms (Sandimmune®, Neoral®) is different and therefore the dose will depend on which form is used. Recommended doses for Sandimmune® are 4–15 mg/kg/day p.o. divided q12h and for Neoral® 1–5 mg/kg/day p.o. divided q12h. Serum ciclosporin levels should be monitored within 24–48 hours of beginning therapy, then weekly for a month, then monthly to evaluate serum concentrations and maintain them within a reported therapeutic range and avoid toxic levels. Additional blood tests to evaluate for side-effects should be done on a regular basis. The recommended therapeutic range reported for cats varies between 250–500 ng/ml and 500–1000 ng/ml. Cats with high blood levels (>1000 ng/ml) may develop anorexia. The expenses associated with ciclosporin and laboratory testing can be cost prohibitive for some clients and these should be discussed with the client prior to initiating treatment.

Lactoferrin administered topically to the oral mucosa or orally may be beneficial in some patients, most likely those with mild inflammation. Lactoferrin is normally found in mucosal surfaces and neutrophil granules, and it has antibacterial and anti-inflammatory properties. The topical application of lactoferrin (40 mg/kg of bodyweight) to the oral mucosa in seven ill cats with chronic gingivostomatitis resulted in clinical improvement demonstrated by decreased pain and salivation, and increased appetite.

Anecdotally, co-enzyme Q10 (30 mg daily) has successfully resolved severe oral inflammation that persisted following a full-mouth extraction procedure. In this cat the response to the co-enzyme Q10 took about 3 months to be evident. Currently the author recommends 30–100 mg co-enzyme Q10 for a minimum of 4 months for those cats that have not had a completely satisfactory response to a full-mouth extraction.

### **Feline eosinophilic granuloma complex oral lesions**

Oral lesions of the eosinophilic granuloma complex (EGC) seen in cats include eosinophilic ulcers (rodent or indolent lip ulcer) and eosinophilic granulomas (linear granulomas).

- Oral eosinophilic ulcers are non-painful, non-pruritic, firm, red-brown to yellow, ulcerated lesions found on the upper lip. They are usually well circumscribed and often fairly symmetrically located on each side of the midline.
- Oral eosinophilic granulomas (linear granulomas) in cats are found on the tongue, at the base of the tongue, on the lips and gums, or in the pharynx. They occur as single or multiple lesions and may be smooth or nodular and are sometimes ulcerated.

### **Aetiology**

Proposed aetiologies for EGC include allergies (e.g. flea allergies, atopy), infectious diseases (e.g. bacterial, mycotic), trauma from excessive grooming and reactions to plastic feeding or watering dishes.

### **Diagnosis**

Definitive diagnosis is based on histological examination. Differential diagnoses include neoplasia, mycotic infections and foreign body reactions. Allergy testing may be beneficial if allergies are suspected.

### **Treatment**

Treatment includes removing any possible underlying cause, such as treating for fleas and trading plastic bowls for metal or ceramic ones. Administration of glucocorticoids is also recommended and most lesions will respond. Injectable methylprednisolone at a dose of 2 mg/kg (minimum 20 mg) every 2 weeks for a total of 2–3 treatments is recommended. Intralesional triamcinolone (3 mg weekly) has been successful in some cases. Doxycycline may also benefit some of these cats. Other suggested treatments have included hypoallergenic diet, Zyrtec (an antihistamine with anti-eosinophil effects), CO<sub>2</sub> laser therapy and surgical removal.

### **Canine eosinophilic granulomas**

Dogs also get oral eosinophilic granulomas. They may occur in any breed; however, they are most common in Siberian Huskies. Lesions typically occur on the lateral and ventral surfaces of the tongue and the soft palate. Eosinophilic granulomas are areas of proliferative tissue, with or without superficial ulcerations. Definitive diagnosis is made with histopathological examination. Recommended treatment is orally administered prednisolone at a dose of 0.5–1.0 mg/kg q12h for 7 days, followed by a tapering dose over 2–3 weeks.

### **Ulcerative eosinophilic stomatitis**

Cavalier King Charles Spaniels have been reported to have a problem with ulcerative eosinophilic stomatitis/eosinophilic granulomas/eosinophilic pharyngeal ulcers. Clinical signs include clearing the throat, swallowing problems, snoring sound during breathing, coughing during and after meals, reduced appetite and difficulty eating. The lesions are characterized by a granuloma or plaque formation in the oral cavity, usually on the palatal soft tissue. They may resolve spontaneously. Corticosteroid administration has been associated with partial or complete remission of the lesions. Recommended therapy is oral prednisolone at 1–2 mg/kg q24h.

### Resorptive lesions

Resorptive lesions (RLs) are a common oral problem in cats and can cause significant discomfort. They may not result in obvious clinical signs and therefore an oral examination is very important to identify lesions or possible lesions.

The resorption occurs when odontoclasts, derived from the blood vessels of the PDL and alveolar bone, are activated and stimulated to resorb tooth structure. The odontoclasts first resorb cementum and then they progress to absorb the root or crown dentin. A recently reported study demonstrated that RLs begin anywhere on the tooth root and not just at the CEJ as often has been suggested.

### Aetiology

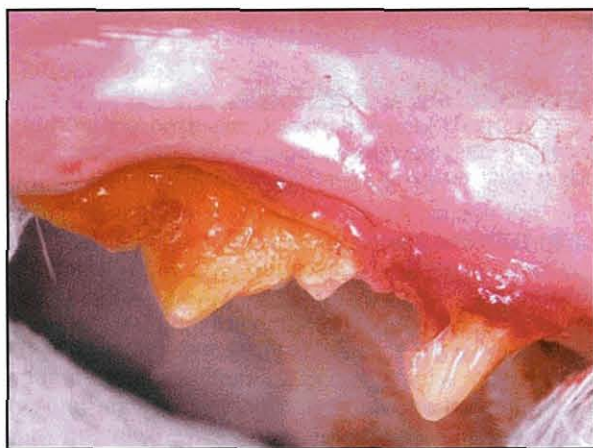
Proposed aetiopathogenesis for the development of RLs have included diet, inflammation, abnormal dental forces and infectious diseases. The aetiology of RLs has not been identified and there may be more than one cause for different lesions. The results of a recent study suggest that the chronic excess intake of vitamin D (in commercial cat foods) may play an important role in the development of RLs in cats. A recent histological study of cat teeth supported RLs as being non-inflammatory replacement resorption, resulting in ankylosis.

### Clinical features

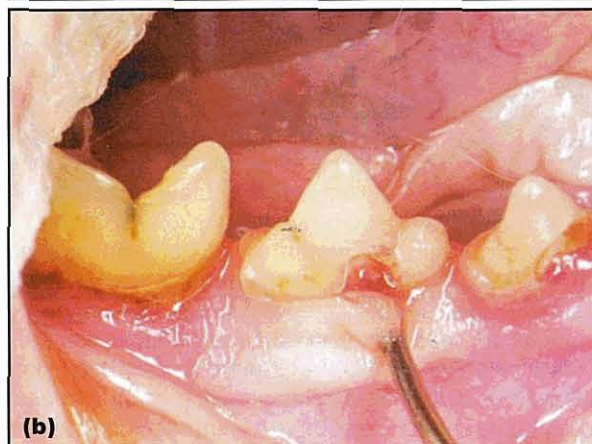
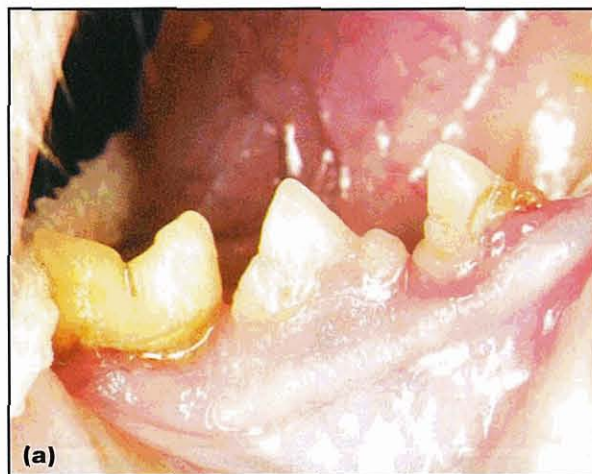The clinical signs for resorptive lesions include:

- Reluctance to eat dry food
- Pain with eating
- Altered eating behaviour
- Pain on tooth brushing.

The presence of resorptive lesions may be suspected based on clinical signs. An extensive RL resulting in significant tooth loss may be apparent on oral examination (Figure 17.7). Granulation tissue often covers an RL on the tooth crown. The presence of red, often raised, gingival tissue covering an area on the crown is an indication to evaluate that tooth for an RL (Figure 17.8). A large RL may weaken a tooth to the point where the crown separates from the root and is lost. In these instances the gingiva either heals over the roots or the root fragments protrude through the gingiva.



17.7 Resorptive lesion resulting in loss of tooth crown.

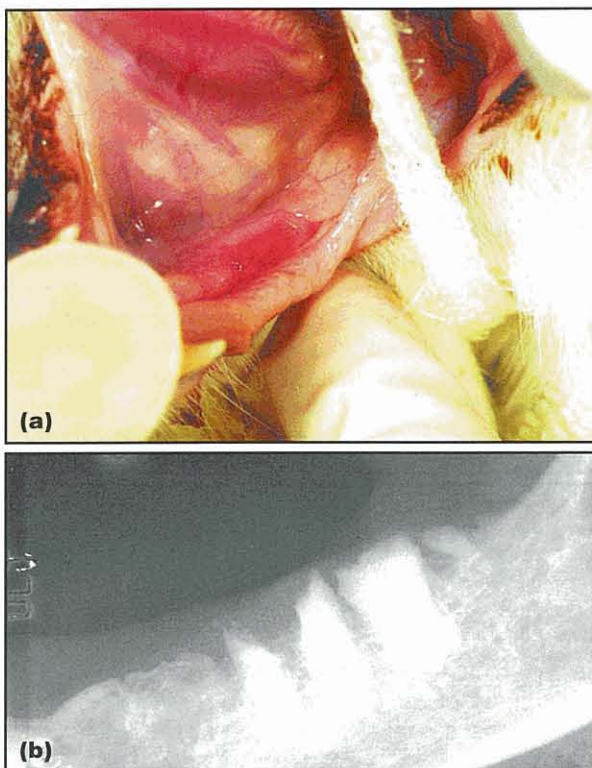


17.8 (a) Hyperplastic gingival tissue covering a resorptive lesion. (b) Retraction of the gingiva reveals an underlying resorptive lesion.

### Diagnosis

**Diagnostic imaging:** Radiography is indicated to evaluate for retained roots if the gingiva is inflamed or retained roots are suspected (Figure 17.9). A complete oral examination, including dental radiography, under general anaesthesia is required to detect all the lesions. Canine teeth often have extensive root resorption with minimal or no visible crown loss. In these teeth it is especially important to pay attention to gingival inflammation and small defects under the gingiva. If any abnormalities are detected radiographs should be made to assess the tooth roots.

Radiography is also necessary to determine whether an RL is a Type I or Type II lesion. Type I lesions are associated with inflammation and radiographically the root and crown density are similar to surrounding unaffected teeth and there is a distinct PDL space around each tooth root. Type II lesions are not associated with inflammation and the roots become replaced with bone-cementum-like tissue and the PDL space is not visible on dental radiographs. Tooth roots with Type II lesions appear radiolucent compared with adjacent roots. Tooth roots of affected teeth have histopathological evidence of concurrent resorptive and reparative processes resulting in root replacement in chronic cases.



**17.9** (a) Inflammation associated with suspected retained roots in the mandible of a cat. (b) Radiograph of the mandible of the cat in (a) demonstrating retained roots.

A recent study by DuPont and DeBowes (2002) reported that Type I roots were 8.17 times more likely to be associated with periodontitis than were Type II roots. Cat teeth with RLs and periodontitis had a significantly higher proportion of Type I compared with Type II root lesions. This finding suggests that there may be different aetiologies for the two types of RL. Inflammation is associated with the Type I lesion and it is suggested that traumatic injury to the periodontal attachment apparatus from abfraction (flexure of the tooth) may be associated with the Type II lesion development.

**Treatment**

The recommended treatment of a tooth with an RL is usually either an extraction or a crown amputation with intentional root retention. A tooth with a Type I lesion should be extracted and no portion of the root should be left in the alveolus. When there is no evidence of associated periodontal or endodontic disease, a tooth with a Type II lesion can be treated by amputating the tooth crown and leaving the roots. The roots will continue with the process of resorption and repairing.

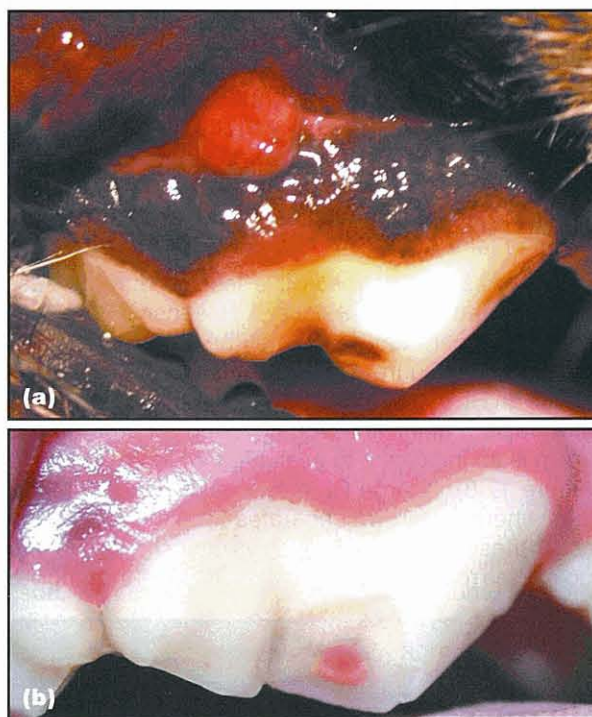
Canine teeth with severe root resorption may be difficult to extract due to the ankylosis of the root. In these instances, if there is no root pathology associated with the RL, the crown and a portion of the root may be removed and the gingiva closed over the remaining root.

Retained roots with associated gingival inflammation or signs of pathology, such as radiolucencies, should be extracted.

Placing restorations in teeth with RLs is not a recommended treatment because of the poor long-term success of the restorations and the progressive nature of the lesions. Extractions and crown amputations will be the treatment of choice until other methods are proven to give superior results.

**Trauma**

Falls from heights, being hit by a vehicle, being struck with a hard object, dogfights and chewing on hard objects all may result in traumatic injury to the oral tissues. One of the most common injuries is a fractured tooth (Figure 17.10a). Untreated fractured teeth with pulp exposure will develop varying degrees of periapical inflammation and infection (Figure 17.10b). Clinical signs may be very difficult to detect, especially early in the process. Reluctance to chew or bite down on the tooth is a sign of discomfort associated with periapical disease. Facial swelling, draining fistulas and reluctance to eat hard food are other clinical signs. The fractured tooth with pulp exposure should receive endodontic treatment, such as a root canal or extraction. When extracting these teeth all the roots must be removed to ensure a successful outcome.



**17.10** (a) Fractured tooth with pulp exposure and abscess of endodontic origin. (b) Fractured upper fourth premolar with pulp exposure.

**Oral tumours**

**Epulides**

Epulides are the most common benign tumours in the oral cavity of dogs. The two types are:

- Peripheral odontogenic fibromas (previously termed fibromatous epulis)
- Acanthomatous ameloblastoma (previously termed acanthomatous epulis).

The peripheral odontogenic fibroma may be mineralized (previously termed ossifying epulis). Conservative local excision is usually curative for the peripheral odontogenic fibroma. The acanthomatous ameloblastoma is locally a more aggressive tumour and successful excision requires a more extensive surgical procedure. Radiation treatment has also been used to treat these tumours with success.

#### Malignant oral tumours

Oral tumours are one of the most common cancers seen in veterinary patients. Clinical signs include:

- Halitosis (may be very severe)
- Ptyalism
- Blood found on chew toys, in food or water dish
- Blood found in saliva
- Decreased food consumption (especially hard foods)
- Not chewing on hard treats or chew toys
- Dysphagia
- Weight loss
- Swellings on the face, mandible or in area of local lymph nodes
- A visible mass (less common).

When a dental procedure is done and a loose tooth or inflamed ulcerated area is found in a mouth that is otherwise healthy, oral neoplasia should always be considered. Following extraction of a tooth if the extraction site does not heal normally, neoplasia should be considered. Always perform a biopsy in these cases and submit the sample for histological examination.

Diagnostic evaluation of patients with suspected oral neoplasia includes histopathological evaluation of the mass, radiography or computed tomography (CT) of the region containing the oral mass, fine needle aspiration (FNA) or biopsy of regional lymph node(s), and thoracic radiography (ventrodorsal, and both lateral views). A complete blood count and biochemistry profile are also recommended to evaluate for concurrent problems or paraneoplastic syndromes associated with the tumour.

#### Malignant melanoma

Malignant melanomas are the most common malignant tumour in dogs but are rare in cats. The most common site is the gingiva, although they can be found anywhere in the oral cavity. Amelanotic tumours tend to occur in younger dogs and melanotic tumours in older dogs. These melanomas are highly malignant and tend to metastasize to the tonsils, regional lymph nodes and lungs. The prognosis is guarded, especially for tumours >4 cm in diameter or those that have lymph node involvement or distant metastases. Complete surgical removal is the best chance for a cure. It is difficult to achieve adequate margins unless the tumour is small and in the rostral aspect of the mouth. Radiation therapy is generally only an option for palliative treatment and not for a cure.

#### Squamous cell carcinoma

Squamous cell carcinomas (SCCs) are the most common oral malignant neoplasia in cats, accounting for approximately 75 % of oral tumours. It is the second most common malignant oral neoplasia in dogs. These tumours, especially in cats, are locally very aggressive,

often with extensive bone lysis at the time of diagnosis. Radiography or CT is necessary to evaluate the extent of local invasion. Metastases are uncommon with the exception of canine tonsillar or lingual SCC.

SCCs occur most frequently in older cats and may be found anywhere in the oral cavity. The use of certain flea control products and the high intake of canned foods, especially canned tuna fish, have both been associated with an increased risk of oral SCC in cats. Hypercalcaemia may be a paraneoplastic sign in cats with SCC. Sublingual SCCs at the base of the tongue are particularly difficult to deal with. Difficulty eating and altered use of the tongue may be an early sign of lingual SCC in cats. These cats may first present with difficulty using their tongue without having any obvious evidence of a tumour.

The prognosis in cats is very poor with a 1-year survival rate of <10% and most have a median survival of 1–2 months. Combination therapy with radiation and mitoxantrone chemotherapy has shown some promise in cats with a reported median survival of 6 months. The best prognosis would be for very small tumours with minimal local invasion that occur in the rostral part of the mouth. These may be cured by surgical removal. If found in the back of the mouth, surgical excision is generally not possible and local recurrence following surgery almost always occurs. Cats do not tolerate extensive oral surgeries as well as dogs. Surgery is rarely used as a treatment for SCCs, only being done in cases where the diagnosis has been made very early and the tumour is small. Any suspicious area should be biopsied to confirm a diagnosis as early as possible. Piroxicam and meloxicam have both been suggested for palliative care in oral SCCs in cats.

The prognosis for dogs with SCC depends on tumour location. Rostral tumours, which account for most SCCs in dogs, may be cured with surgery or radiation therapy. Photodynamic therapy shows promise for treating dogs with SCC. Palliative care with piroxicam has been suggested.

#### Fibrosarcoma

Fibrosarcomas are the third most common oral malignant tumour in dogs and the second most common in cats. The most common sites are the gingiva and palate. They are rapidly growing tumours and extensively invade the local soft tissue and bone. The recurrence rate after surgery is high. They have a moderate rate of distant metastases.

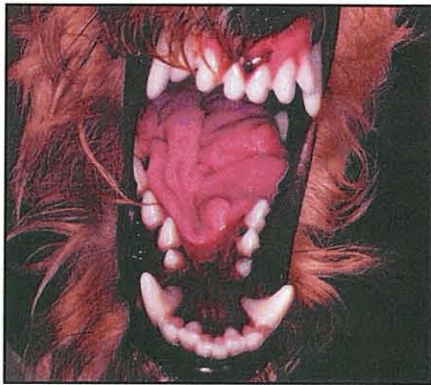Oral fibrosarcomas with a histopathologically low-grade but with a biologically high-grade activity have been found in young dogs, with Golden Retrievers being the breed making up the largest numbers. This has also been seen in a number of black Labrador Retrievers. The oral fibrosarcomas in these dogs are very aggressive and more likely to metastasize.

#### Congenital defects

Congenital defects of the secondary palate (e.g. hard and soft palate) are associated with difficulty eating and drinking, nasal discharge, coughing, gagging, stunted growth and aspiration pneumonia. Early diagnosis is important to avoid complications. Multiple

surgeries may be required to close the defects, especially in young growing dogs. Nutritional supplementation and treatment of complications may be required.

Microglossia has been identified in week-old puppies as well as mature animals. The neonatal puppy with severe microglossia may not be able to nurse adequately and will die without nutritional support. Older animals are typically described as messy eaters and they drool excessively. Physical examination will reveal a tongue that is small and short compared with a normal tongue (Figure 17.11).



17.11

Congenital microglossia in an adult dog. (Courtesy of Gregg A. DuPont)

### Enlarged salivary glands

Sialoceles are large, usually non-painful, swellings associated with accumulation of saliva caused by a salivary duct rupture or obstruction. Depending on location they may be associated with dysphagia, gagging, dyspnoea or no clinical signs. Diagnosis is based on cytological evaluation of aspirated fluid. Complete surgical removal of the affected salivary ducts and associated gland should result in complete resolution.

Differential diagnoses for enlarged salivary glands include sialadenitis, sialadenosis, malignant neoplasms, salivary gland infection and salivary gland infarction.

Sialadenitis is characterized on FNA cytology or histopathological examination by an inflammatory response with no evidence of infection. Common presenting signs include gagging, coughing, inappetence, lethargy, fever and enlarged painful salivary glands. Affected dogs usually respond to glucocorticoid therapy.

Sialadenosis is a non-painful, afebrile enlargement of the salivary glands primarily reported in dogs. A cat with suspected sialadenosis responding to phenobarbital therapy has been reported. Clinical signs include retching, gulping, ptyalism and poor appetite. Cytological and histological examination of the salivary glands does not reveal any significant changes. Occasionally there may be evidence of necrosis on cytological or histopathological examination. It has been suggested that this is a manifestation of limbic epilepsy. Most patients respond rapidly to treatment with phenobarbital. In resistant cases, monitoring phenobarbital levels to assure a therapeutic range and using potassium bromide may be necessary for complete control.

### Lingual lesions

Lingual lesions may include tumours, traumatic injuries (such as lacerations or puncture wounds), inflammatory or immune-mediated lesions, and ulcers.

Glossitis and stomatitis may result from the ingestion or chewing of certain household plants such as dumbcane (*Dieffenbachia* spp.), philodendron (*Philodendron* spp.), peace lily (*Spathiphyllum*) and devil's ivy (*Epipremnum aureum*). Associated clinical signs may include profuse salivation, pawing at the mouth, oral pain, head shaking, loss of vocalization, and if severe inflammation and swelling occurs there may be breathing difficulties.

Lingual ulcers may result from chemical burns, embedded plant materials, electrical cord bites, systemic infections, metabolic disorders (e.g. uraemia) and immune-mediated diseases, such as pemphigus vulgaris.

Diagnostic evaluation may include evaluation for systemic infections, renal failure and biopsy for evaluation for tumour or immune-mediated disease.

Treatment depends on the underlying aetiology. In many cases of local trauma or irritation, symptomatic treatment to control pain and support hydration are all that is necessary. Topical sucralfate (suspension or slurry made from tablet) may help with the discomfort associated with ulcerated areas.

### References and further reading

- Bertone ER, Snyder LA and Moore AS (2003) Environmental and lifestyle risk factors for oral squamous cell carcinoma in domestic cats. *Journal of Veterinary Internal Medicine* **17**, 557–562
- Boydell P, Pike R, Crossley D, et al. (2000) Sialadenosis in dogs. *Journal of the American Veterinary Medical Association* **216**, 872–874
- Boydell P, Pike R and Crossley D (2000) Presumptive sialadenosis in a cat. *Journal of Small Animal Practice* **41**, 573–574
- Crossley DA and Penman S (1995) *BSAVA Manual of Small Animal Dentistry*. BSAVA Publications, Cheltenham
- DeBowes LJ (2000) Dentistry: periodontal aspects. In: *Textbook of Veterinary Internal Medicine: Diseases of the Dog and Cat, 5th edn*, ed. SJ Ettinger and EC Feldman, pp. 1127–1134. WB Saunders, Philadelphia
- DuPont GA (2002) Step-By-Step. Crown amputation with intentional root retention for dental resorptive lesions in cats. *Journal of Veterinary Dentistry* **19**, 107–110
- DuPont G (2003) Feline dental resorptive lesions – theory of etiopathogenesis. In: *Proceedings of the 8th World Veterinary Dental Congress*, pp. 189–191. Kyoto, Japan
- DuPont GA and DeBowes LJ (2002) Comparison of periodontitis and root replacement in cat teeth with resorptive lesions. *Journal of Veterinary Dentistry* **19**, 71–75
- Gorrel C and Larsson A (2003) Feline odontoclastic resorptive lesions—unveiling the early lesion. In: *Proceedings of the 8th World Veterinary Dental Congress*, p. 188. Kyoto, Japan
- Hardy WD, Zuckerman E and Corbishley J (2002) Serological evidence that *Bartonella* causes gingivitis and stomatitis in cats. In: *Proceedings of the 16th Annual Veterinary Dental Forum*, pp 79–82. Savannah, Georgia
- Harley R, Gruffydd-Jones TJ and Day MJ (2003) Salivary and serum immunoglobulin levels in cats with chronic gingivostomatitis. *Veterinary Record* **152**, 125–129
- Harley R, Helps CR, Harbour DA, Gruffydd-Jones TJ and Day MJ (1999) Cytokine mRNA expression in lesions in cats with chronic gingivostomatitis. *Clinical and Diagnostic Laboratory Immunology* **6**, 471–478
- Lommer MJ and Verstraete FJM (2003) Concurrent oral shedding of feline calicivirus and feline herpesvirus 1 in cats with chronic gingivostomatitis. *Oral Microbiology and Immunology* **18**, 131–134
- Nelson AW (2003) Cleft palate. In: *Textbook of Small Animal Surgery, 3rd edn*, ed. D Slatter, pp. 814–823. WB Saunders, Philadelphia
- Reiter AM (2003) Evaluation of serum concentrations of calcitropic hormones in cats with feline Odontoclastic Resorptive lesions (FORL). In: *Proceedings of the 8th World Veterinary Dental Congress*, pp. 186–187. Kyoto, Japan
- Savary KCM, Price S and Vaden SL (2000) Hypercalcemia in cats: a retrospective study of 71 cases (1991–1997). *Journal of Veterinary Internal Medicine* **14**, 164–189
- Stonehewer J, Mackin AJ, Tasker S, Simpson JW and Mayhew IG (2000) Idiopathic phenobarbital-responsive hypersialosis in the dog: an unusual form of limbic epilepsy? *Journal of Small Animal Practice* **41**, 416–421
- Ward PP (2002) Lactoferrin and host defense. *Biochemistry Cell Biology* **80**, 95–102

# Disorders of the pharynx and oesophagus

Robert J. Washabau

## Pharynx

### Anatomy and physiology

Whilst the anatomy and physiology of the canine and feline pharynx have been reviewed in detail (see References and further reading) from a purely clinical perspective, the oropharyngeal phase of swallowing can be subdivided into three stages.

- The first or *oral* stage begins with the prehension of food with teeth and tongue, and the formation of the bolus at the base of the tongue.
- In the second or *pharyngeal* stage, rostral to caudal pharyngeal contractions propel the bolus from the base of the tongue to the cricopharyngeal or cranial oesophageal sphincter opening.
- The cricopharyngeus relaxes during the third or *cricopharyngeal* stage, and the bolus passes into the cranial oesophageal body. The cricopharyngeus subsequently contracts, pharyngeal muscles relax, and the oropharyngeal phase is repeated over and over again.

Abnormalities in any of the oropharyngeal stages can produce oropharyngeal dysphagia, which can be either functional or morphological in origin. Most functional disorders consist of failure, spasticity or incoordination of muscular contractions and are due to neuromuscular diseases. Morphological disorders that interfere with the oropharyngeal phase of swallowing include strictures, foreign bodies, and neoplastic, traumatic and inflammatory processes of the oral cavity and pharynx. The morphological disorders of the pharynx often involve the oral cavity primarily and are discussed separately in Chapter 17.

### Diagnostic approach

#### History

Dysphagia (difficulty in swallowing) and hypersalivation are the most important clinical signs with oropharyngeal disorders. Pet owners may also describe gagging, difficulties in drinking water or forming a solid bolus, excessive mandibular or head motion, persistent forceful ineffective swallowing efforts, dropping of food from the mouth, nasal discharge due to misdirection of food into the nasopharynx, excessive salivation, foaming from the mouth, coughing, failure to thrive and reluctance to eat. Regurgitation, a common sign of oesopha-

geal disease, is less frequently reported with the oropharyngeal dysphagias (see Chapter 6).

### Physical examination

Findings on physical examination are dependent upon the pathogenesis and severity of the dysphagia. Many morphological abnormalities (e.g. neoplasia, stricture, inflammation, foreign body) are fairly obvious on examination of the pharynx. Animals with functional oropharyngeal dysphagias, on the other hand, may have few morphological abnormalities. Focal or generalized muscle atrophy and diminished or absent gag reflex may be the only abnormal findings in animals with neuromuscular disease.

### Laboratory tests

An approach to the diagnosis of dysphagia and hypersalivation associated with oropharyngeal disease is depicted in Chapter 6. The diagnosis of a morphological abnormality is usually straightforward and, except for tissue biopsy or culture, usually does not require any additional diagnostic testing (see Chapter 17 for further details).

### Diagnostic imaging

Survey radiography, ultrasonography, computerized tomography and magnetic resonance imaging (MRI) may be performed to assess for severity of local traumatic injury, or to look for distant metastasis. The diagnosis of functional oropharyngeal dysphagias is more difficult and may require the use of videofluoroscopy or electrophysiology. If these techniques are not readily available in the private practice setting, cases can be referred to a university teaching hospital or other referral centre.

## Disorders of the pharynx

### Oropharyngeal dysphagia

#### Aetiology

Three types of oropharyngeal dysphagia have been characterized in companion animal species:

- Oral stage dysphagias with prehension deficits mainly due to loss of tongue function
- Pharyngeal stage dysphagias with transport deficits mainly due to loss of cranial and caudal pharyngeal constrictor function

- Cricopharyngeal stage dysphagias with cricopharyngeal opening or closure deficits (achalasia or chhalasia, respectively), or incoordination between pharyngeal contraction and cricopharyngeal sphincter relaxation.

### Pathogenesis

Neuromuscular disease is the underlying pathogenetic mechanism of oropharyngeal dysphagia, but the precise aetiologies are rarely identified. Some cases have been associated with brainstem disease, peripheral neuropathy, myasthenia gravis, polymyositis, muscular dystrophy and hypothyroidism. A unique form of oropharyngeal dysphagia bearing some resemblance to muscular dystrophy has been described in the Bouvier des Flandres breed.

### Diagnosis

**Clinical signs:** The diagnosis of oropharyngeal dysphagia is usually made on the basis of clinical signs and by exclusion of other oropharyngeal and oesophageal pathology. Once an oropharyngeal dysphagia is suspected, it should be further classified into an oral, pharyngeal or cricopharyngeal stage disorder.

**Diagnostic imaging:** Videofluoroscopy is the diagnostic test of choice since it is impossible to further classify these disorders on the basis of physical examination or survey radiography. The videofluoroscopic findings of oral stage dysphagias are typified by weak tongue-thrust action, retention of contrast medium in the oropharynx and loss of contrast medium from the mouth. Aspiration pneumonia is not a typical finding in oral stage dysphagias.

Aspiration pneumonia is a typical finding in pharyngeal stage dysphagias. Videofluoroscopic findings consistent with a pharyngeal stage dysphagia include:

- Incomplete pharyngeal contraction with adequate cricopharyngeal relaxation
- Slow induction and slow progression of peristaltic-like contractions from the rostral to the caudal pharynx
- Laryngotracheal aspiration.

In cricopharyngeal stage dysphagia, the cricopharyngeus fails to relax (achalasia) or relaxes at an inappropriate time (incoordination) following pharyngeal contraction.

**Electromyography:** This may be useful in distinguishing oropharyngeal dysphagia from cricopharyngeal achalasia. Fibrillation and positive sharp waves observed in oropharyngeal musculature suggest that the disorder involves the structures of the oral cavity and pharynx instead of the cricopharyngeus.

**Laboratory tests:** Other diagnostic tests that may be warranted after an oropharyngeal dysphagia has been diagnosed are serology for nicotinic acetylcholine receptor antibody, antinuclear antibody, thyroid function testing, serum creatine phosphokinase activity,

muscle biopsy and brainstem MRI. Other oropharyngeal (e.g. neoplasia, eosinophilic granuloma, trauma, inflammation; reviewed in Chapter 17) and oesophageal pathologies are the major differential diagnoses for the oropharyngeal dysphagias.

### Treatment

Except for cricopharyngeal achalasia (which is treated surgically by cricopharyngeal myotomy; see *BSAVA Manual of Canine and Feline Head, Neck and Thoracic Surgery*) the oropharyngeal dysphagias are all treated medically. Cricopharyngeal myotomy appears to be of no benefit in oral and pharyngeal stage dysphagias; indeed, oropharyngeal dysphagias may be worsened by cricopharyngeal myotomy. The medical therapy for functional oropharyngeal dysphagias is mostly supportive and consists of nutritional support (e.g. gastrostomy tube feeding; see Chapter 27) on a temporary or permanent basis. Elevated feedings and different food consistencies may be attempted, but these efforts are often of little clinical benefit. In early cases of myasthenia gravis, acetylcholinesterase inhibitors (e.g. pyridostigmine) may yield substantial clinical improvement. Glucocorticoid therapy (prednisolone) will also improve clinical signs in many myasthenic and polymyositis patients, although some cases of canine myasthenia gravis appear to resolve spontaneously without immunosuppressive therapy. Thyroid hormone replacement therapy should be attempted in animals with documented hypothyroidism.

### Prognosis

In general, the prognosis for oropharyngeal dysphagia is guarded to poor. Only those associated with myasthenia gravis, polymyositis and hypothyroidism will show some clinical improvement with therapy. Bouvier des Flandres dogs may have a better prognosis particularly if the disorder is confined to the oesophagus instead of the oropharynx.

### Cricopharyngeal achalasia

**Aetiopathogenesis:** Cricopharyngeal achalasia is a neuromuscular disorder of young dogs characterized by hypertension of the cranial oesophageal sphincter and inadequate relaxation of the sphincter with swallowing. Dysfunction of the inhibitory neuron-mediating sphincteric relaxation has been postulated, but the aetiology, pathogenesis and breed predisposition of this disorder are unknown.

**Diagnosis:** Affected animals have progressive dysphagia and regurgitation soon after weaning. They typically make repeated, unproductive swallowing attempts that culminate in regurgitation of undigested food. Coughing and pulmonary crackles may develop as a consequence of food being aspirated into the airways. Physical examination is usually unremarkable.

Because of the inability to evaluate the rapid and complex series of events that occur during swallowing, survey and static barium-contrast radiography are not particularly useful in diagnosing the disorder. Definitive diagnosis of cricopharyngeal achalasia requires the use of videofluoroscopy and oesophageal manometry.

The videofluoroscopic finding of multiple, unproductive attempts at swallowing barium liquid or paste is consistent with a diagnosis of cricopharyngeal achalasia. This should be supported by the manometric demonstration of elevated basal pressures and inadequate relaxation with swallowing. If manometry is unavailable and the diagnosis is still questionable, electromyography of the oropharyngeal musculature should be performed to exclude the possibility of a more proximal oropharyngeal dysphagia.

**Treatment:** It is difficult to generalize based on the small number of cases that have been reported, but the disorder is probably best treated with cricopharyngeal myotomy. Most animals experience immediate relief following surgery. Effective medical management has not been described for this disorder.

**Prognosis:** The prognosis is guarded to poor without surgery. Untreated animals will suffer from malnutrition and recurrent bouts of aspiration pneumonia. Significant and longstanding improvement has been reported with cricopharyngeal myotomy.

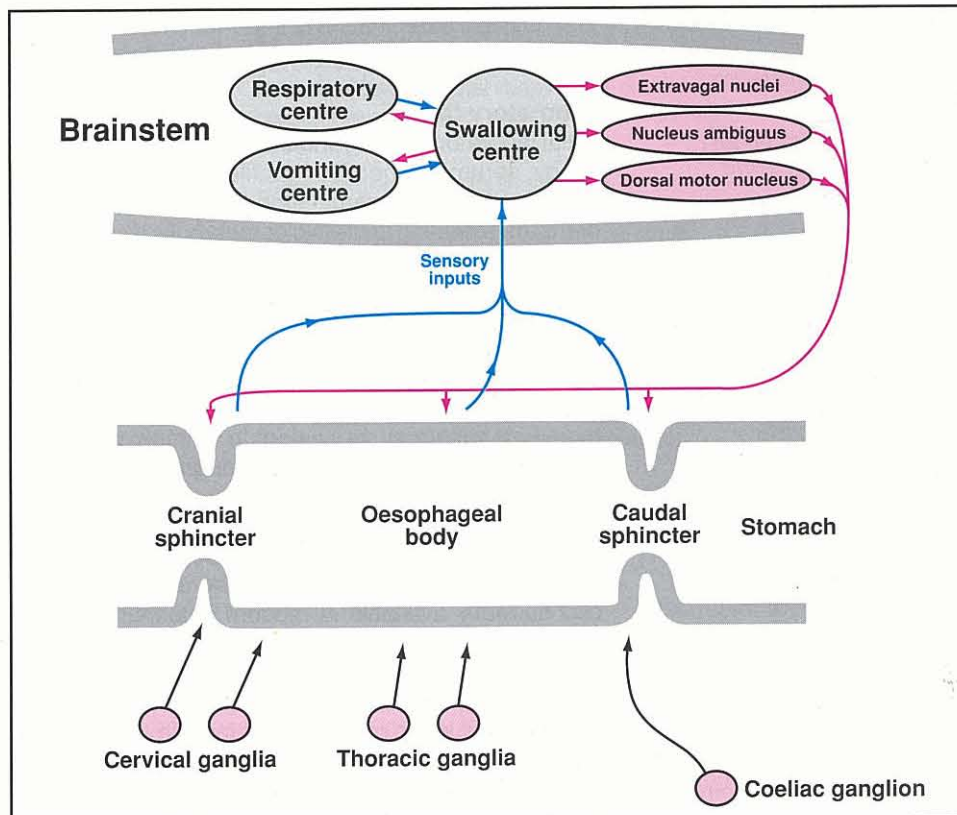
## Oesophagus

### Anatomy and physiology

The transport of ingested liquids and solids from the oral cavity to the stomach is the major function of the oesophagus. Anatomical structures that permit this function are the striated muscle of the cranial oesophageal sphincter (cricopharyngeus), the striated and smooth muscle of the oesophageal body, and the smooth muscle of the caudal oesophageal (gastro-oesophageal) sphincter.

An important species difference between the dog and cat is in the musculature of the oesophageal body. The full length of the canine oesophageal body is composed of striated muscle, whereas the distal one-third to one-half of the feline oesophageal body is composed of smooth muscle. The striated muscle of the cranial oesophageal sphincter and oesophageal body is innervated by somatic branches (glossopharyngeal, pharyngeal and recurrent laryngeal) of the vagus nerve arising from the brainstem nucleus ambiguus. The smooth muscle of the oesophageal body and caudal oesophageal sphincter are innervated by autonomic branches (oesophageal) of the vagus nerve, arising from the dorsal motor nucleus of the vagus (Figure 18.1).

The physiology of the canine and feline oesophagus has been reviewed in detail (see References and further reading). In summary, during fasting, the elevated pressures of the cranial and caudal oesophageal sphincters prevent movement of food and chyme into the oesophageal body from the oral cavity and stomach, respectively. When an animal swallows, the cranial oesophageal sphincter relaxes to permit the movement of liquids and solids into the proximal oesophageal body. Swallowing also initiates a wave of peristaltic contractions (primary peristalsis) in the oesophagus that transports food into the distal oesophageal body. Primary peristaltic contractions are reinforced by a secondary wave of contraction (secondary peristalsis) physiologically mediated by intraluminal distension. The caudal oesophageal sphincter relaxes in advance of the propagated pressure wave to permit food to empty into the stomach. Once the bolus of food has passed into the stomach, the caudal oesophageal sphincter resumes its high resting pressure.



**18.1** Neural regulation of swallowing in the dog and cat. Potential sites of oesophageal hypomotility and megaesophagus: afferent sensory neurons, brainstem swallowing centre, brainstem nuclei (dorsal motor nucleus of the vagus, nucleus ambiguus), efferent motor neurons and neuromuscular junction are also shown. (Redrawn after Washabau and Holt (2003).)



### Pathophysiology

Inflammation (oesophagitis, gastro-oesophageal reflux, oesophageal fistulae), hypomotility (idiopathic mega-oesophagus, dysautonomia, diverticula) and obstruction (stricture, hiatal hernia, neoplasia, intussusception, foreign bodies, vascular ring anomalies) are the major pathophysiological processes involving the oesophagus of dogs and cats. With mild oesophagitis and hypomotility lesions, the oesophagus may undergo healing without further complication. In more severe cases, the oesophagus may respond with extensive fibrosis, muscular hypertrophy, oesophageal narrowing, and/or loss of neural regulation (i.e. flaccidity). Luminal flow is directly related to the fourth power of the oesophageal radius so that even small diminutions result in significant reductions in oesophageal transit.

### Diagnostic approach

An approach to the diagnosis of regurgitation associated with oesophageal disease is outlined in Chapter 6.

### History

A careful history is useful in differentiating clinical signs of oesophageal disease from oral, pharyngeal and gastric disease, and in planning diagnostic tests needed in the evaluation of the patient. Signs consistent with oesophageal disease include regurgitation, odynophagia (painful swallowing), dysphagia, multiple swallowing attempts, excessive salivation (particularly with inflammatory disorders) and changes in appetite (ravenous appetite with motility disorders or reduced appetite with inflammatory disorders). Some breeds are at increased risk for swallowing disorders (Figure 18.2).

Regurgitation is the most important clinical sign of oesophageal disease and should be differentiated from vomiting, gagging and dysphagia (see Chapter 6). Regurgitation differs from vomiting in that it is characterized by the passive retrograde evacuation of undigested food from the oesophagus. Vomiting is characterized by coordinated activities of the gastrointestinal (GI), musculoskeletal and nervous systems culminating in the active evacuation of digested or partially digested food from the GI tract. Vomiting usually signifies disease caudal to the gastro-oesophageal (caudal) sphincter. The severity of clinical signs with oesophageal disease is somewhat dependent upon the pathogenesis of the disease. Animals with vascular ring anomaly, for example, may have severe regurgitation, but their appetite is usually excellent because of secondary malnutrition. Animals with inflammatory oesophageal disease (e.g. oesophagitis), on the other hand, may have anorexia, dysphagia, odynophagia and salivation without much evidence of regurgitation. The latter group clearly presents a diagnostic challenge because of the differing clinical signs. Finally, signs referable to aspiration pneumonia, e.g. coughing and dyspnoea, may be the major presenting complaint in some animals. A good history will usually elicit the other signs of oesophageal disease in those patients.

### Physical examination

Physical examination findings may be minimal in some animals with primary oesophageal disease. Severe regurgitation and malnutrition may result in mild to moderate cachexia. Fever and pulmonary crackles or wheezes occur in association with aspiration pneumonia. Occasionally a cervical foreign body or oesophageal dilatation may be detected during the examination. The physical examination is important from the standpoint of excluding other GI or systemic disease.

### Laboratory tests

Initial laboratory testing should include routine haematology, serum biochemistry profile, urinalysis and faecal parasitological examination. This database will be useful in excluding systemic or metabolic disease as a cause of secondary oesophageal signs. In the absence of systemic or metabolic disease, hypoalbuminaemia (associated with malnutrition) and leucocytosis (associated with oesophageal inflammation or aspiration pneumonia) are the only laboratory abnormalities that are sometimes encountered. Hyponatraemia and hyperkalaemia may be evident in animals with hypoadrenocorticism and secondary megaesophagus.

### Diagnostic imaging

Survey radiography, contrast radiography, fluoroscopy and oesophageal endoscopy are the diagnostic methods currently available in modern veterinary practice (Figure 18.3). Survey radiography of the neck and thorax should be performed in all animals suspected of having oesophageal disease. Definitive diagnosis or evidence in support of a diagnosis may be obtained with survey radiographs in many cases, e.g. oesophageal foreign body, megaesophagus, neoplasia, hiatal hernia and gastro-oesophageal intussusception. Thoracic

Condition	Breed
Oral neoplasia	Golden Retriever; Weimaraner; Boxer; Cocker Spaniel
Oropharyngeal dysphagia	Bouvier des Flandres; Golden Retriever; Labrador Retriever
Oral eosinophilic granuloma	Siberian Husky
Hiatal hernia	Shar Pei; Chow Chow; Bulldog; French Bulldog
Persistent right aortic arch	German Shepherd Dog
Anomalous coronary artery	Bulldog
Congenital megaesophagus	Miniature Schnauzer; Fox Terrier; Irish Setter; Great Dane; German Shepherd Dog; Labrador Retriever; Shar Pei; Newfoundland
Myasthenia gravis-associated megaesophagus	German Shepherd Dog; Golden Retriever; Smooth Fox Terrier; Jack Russell Terrier; Springer Spaniel
Gastro-oesophageal intussusception	German Shepherd Dog
Oesophageal fistula	Cairn Terrier
Cranio-mandibular osteopathy	West Highland White Terrier

**18.2** Known breed predispositions for diseases of the oropharynx and oesophagus. (Data from Washabau and Holt (2003))

Oesophageal disorder	Radiographic findings	Endoscopic findings
Oesophageal foreign body	Radiopaque foreign bodies are usually detected on survey radiography. Contrast radiography may be required to document radiolucent foreign bodies	Many radiopaque and radiolucent foreign bodies are readily identified and treated with endoscopy
Oesophageal fistula	Lobar pneumonia is a common finding. The oesophagus may appear normal on survey radiography unless a foreign body has become lodged near the fistula. Contrast radiography usually demonstrates abnormal communication between oesophagus and bronchus, lung or trachea	Large fistulae are usually visible, but small fistulae may not be readily apparent. Fistulae appear as round lesions on the oesophageal mucosa with raised hyperaemic margins
Vascular ring anomaly	Proximal oesophageal dilatation may be apparent in severe cases. The oesophageal stricture at the base of the heart is usually apparent only with contrast radiography	Narrowing is observed near the base of the heart, pulsations of the major arteries can be observed in the region of oesophageal narrowing
Oesophageal neoplasia	Peri-oesophageal neoplasia arising from the lung, thyroid, heart base or other structures may be readily apparent on survey radiography. Contrast radiography and endoscopy are often required to document intraluminal neoplasia	Peri-oesophageal neoplasia is not visible with endoscopy, but oesophageal narrowing may be apparent due to extraluminal compression. Intraluminal neoplasia may appear focal, pedunculated and polypoid, or may appear diffuse with mucosal haemorrhage and ulceration
Oesophagitis	Mild to moderate dilatation may be apparent with survey or contrast radiography in some cases. Minimal change or no abnormalities observed in other cases. The latter cases should be further investigated with endoscopy	Erythema, ulceration, constriction, bleeding, evidence of reflux
Oesophageal stricture	Survey radiography is usually unremarkable. Barium contrast radiography usually reveals diffuse or segmental narrowing	Narrowing of the oesophageal lumen may be accompanied by erythema, haemorrhage or ulceration
Oesophageal diverticulum	Focal or segmental sacculations are observed on survey or contrast radiography	Sacculations of the oesophageal wall may be evident with endoscopy, but it may be necessary to aspirate food and fluid from the sacculated segment to visualize the defect
Megaesophagus	Variable degrees of oesophageal dilatation will be observed with survey radiography. Contrast radiography will confirm oesophageal dilatation as well as provide some limited information about oesophageal motility. Endoscopy is not needed to make the diagnosis	Variable degrees of oesophageal dilatation will be apparent at endoscopy. Oesophagitis or obstruction may be observed
Hiatal hernia	Survey radiography is usually diagnostic (e.g. caudodorsal gas-filled opacity in the thoracic cavity) in congenital forms of the disease. Several contrast studies may be required to document the same findings in animals with acquired hiatal hernias	Findings consistent with the diagnosis include cranial displacement of the gastro-oesophageal sphincter, a large oesophageal hiatus and oesophagitis
Gastro-oesophageal reflux	Survey radiography is usually unremarkable. The contrast radiographic findings of irregular mucosal surface and oesophageal dilatation are consistent with oesophagitis secondary to gastro-oesophageal reflux. Gastro-oesophageal reflux of barium may or may not be abnormal. Endoscopy should be performed	Endoscopic findings may be similar to oesophagitis or mucosa may be normal. Definitive diagnosis may require pH and pressure measurements
Gastro-oesophageal intussusception	Proximal oesophageal dilatation, consolidation or mass effect between the cardiac silhouette and diaphragm and gastric rugal folds within the intrathoracic oesophagus are findings consistent with the diagnosis of gastro-oesophageal intussusception	An intra-oesophageal mass completely obstructing the lumen of the oesophagus is evident. Gastric rugal folds may be visible

**18.3** Radiographic and endoscopic findings in oesophageal disorders of the dog and cat.

radiography will also identify some of the complications of oesophageal disease, including aspiration pneumonia, pleural effusion, mediastinitis and pneumothorax.

Contrast radiography and fluoroscopy can be performed to identify oesophageal lesions or to confirm a tentative diagnosis. Disorders not readily diagnosed by survey radiography (e.g. radiolucent foreign body, oesophagobronchial fistula, oesophagitis, diverticulum

and stricture) may be more readily diagnosed by contrast radiography. Dynamic contrast studies, e.g. videofluoroscopy, should be used instead of static barium radiography whenever possible. In addition to structural information, dynamic studies will provide some information about oesophageal motility. Contrast studies may be performed using barium paste (80–100% weight/volume), barium suspension (30%

weight/volume), barium-coated meals or iodinated contrast agents. The choice of a specific contrast agent will depend upon which oesophageal disease is suspected (see Chapter 3).

Oesophageal endoscopy has become a very useful tool in the diagnosis and treatment of oesophageal disease (see Chapter 4). Usually performed after survey radiographic assessment, endoscopy and biopsy are particularly useful in diagnosing oesophageal stricture, oesophagitis, intraluminal mass, foreign body and diverticula (see Figure 18.3). Endoscopy may also be used therapeutically to remove foreign bodies, dilate oesophageal strictures or to place gastrostomy feeding tubes.

Ultrasonography has proved useful in the diagnosis of peri-oesophageal masses and other mediastinal disease. Oesophageal manometry is useful for diagnosing cricopharyngeal achalasia, generalized oesophageal motility disorders and caudal oesophageal sphincter incompetence, but the technique is currently only performed at major referral centres and university teaching hospitals. Nuclear scintigraphy and oesophageal pH monitoring have also been used to diagnose oesophageal motility disorders and gastro-oesophageal reflux, respectively.

## **Inflammatory diseases of the oesophagus**

### **Oesophagitis**

#### **Aetiology**

Oesophagitis is an acute or chronic inflammatory disorder of the oesophageal mucosa that occasionally involves the underlying submucosa and muscularis. It most often results from chemical injury from swallowed substances, oesophageal foreign bodies or gastro-oesophageal reflux. The oesophageal mucosa has several important barrier mechanisms to withstand caustic substances including: stratified squamous epithelium with tight intracellular junctions; mucous gel; and surface bicarbonate ions. Disruption of these barrier mechanisms results in inflammation, erosion and/or ulceration of the underlying structures. Clinical signs are related to the type of injury, the severity of inflammation and the involvement of structures underlying the oesophageal mucosa, e.g. the muscularis. Oesophagitis may occur at any age; however, young animals with congenital oesophageal hiatal hernia may be at increased risk for reflux oesophagitis. Cats appear to be particularly susceptible to doxycycline-associated oesophagitis and oesophageal stricture. Anaesthesia, poor patient preparation and poor patient positioning during anaesthesia places other animals at risk for gastro-oesophageal reflux and oesophagitis.

#### **Diagnosis**

**Clinical signs:** Signs characteristic of oesophagitis include regurgitation, salivation, odynophagia, extension of the head and neck during swallowing, and avoidance of food. Coughing may be observed in some animals with concurrent aspiration pneumonia.

The physical examination is often unremarkable in affected animals, although fever and salivation may be detected in animals with ulcerative oesophagitis. Pulmonary wheezes and coughing occur with aspiration pneumonia.

**Laboratory tests:** Leucocytosis and neutrophilia may be found in animals with severe oesophagitis or aspiration pneumonia but results of routine haematology, serum biochemistry and urinalysis are generally unremarkable.

**Diagnostic imaging:** The oesophagus often appears normal on survey thoracic radiography. Aspiration pneumonia may be evident in the dependent portions of the lung. Barium-contrast radiographic findings include irregular mucosal surface, segmental narrowing, oesophageal dilatation and diffuse oesophageal hypomotility. Stricture formation may also be observed in chronic undiagnosed or untreated oesophagitis. Endoscopy and biopsy are the most reliable means of diagnosing this disorder (see Chapter 4). In severe cases of oesophagitis, the mucosa will appear hyperaemic and oedematous with areas of ulceration and active bleeding. Milder cases of oesophagitis may appear normal on endoscopic examination and mucosal biopsy will be necessary to confirm the diagnosis. Oesophagitis will have several important differential diagnoses including:

- Oesophageal foreign body
- Oesophageal stricture
- Hiatal hernia
- Megaoesophagus
- Oesophageal diverticulum
- Vascular ring anomaly.

Each of these disorders can be differentiated by survey or contrast radiography, or endoscopy.

#### **Treatment**

Animals with mild oesophagitis may be managed on an outpatient basis. Oral food intake should be withheld for 2–3 days in cases of mild oesophagitis. Animals with more severe oesophagitis (e.g. complete anorexia, dehydration, aspiration pneumonia) may require hospitalization. Food and water should be withheld in such cases, and animals may need additional enteral or parenteral nutritional support. Oral sucralfate suspensions are the most important and specific therapy for oesophagitis. Sucralfate suspensions are more therapeutic than intact sucralfate tablets because the liquid suspension will bind more readily to an erosive or ulcerative site. Gastric acid secretory inhibitors (e.g. cimetidine, ranitidine, famotidine, omeprazole) might be useful in suspected cases of gastro-oesophageal reflux. Broad spectrum antibiotics should be used in animals with aspiration pneumonia or severe oesophagitis.

#### **Prognosis**

Animals with mild oesophagitis generally have a favourable prognosis. Ulcerative oesophagitis, on the other hand, warrants a more guarded prognosis. The

most important complication of oesophagitis is oesophageal stricture. Animals affected with oesophageal stricture develop progressive regurgitation, weight loss and malnutrition. Oesophagitis and stricture also place animals at risk for aspiration pneumonia.

### Gastro-oesophageal reflux

#### Aetiology

Gastro-oesophageal reflux is a disorder of the caudal oesophageal sphincter permitting reflux of GI fluids or ingesta into the oesophagus. Varying degrees of oesophagitis result from prolonged contact of gastric acid, pepsin, trypsin, bile salts and duodenal bicarbonate with the oesophageal mucosa. The frequency of reflux and composition of the refluxed material determines the severity of the oesophagitis. Gastric acid alone produces a mild oesophagitis, whereas combinations of gastric acid and pepsin or trypsin, bicarbonate, and bile salts produce a severe oesophagitis. The risk of reflux oesophagitis is also greater with multiple episodes than with a single long episode of acid exposure. Gastro-oesophageal reflux has been poorly documented in dogs and cats, but it is undoubtedly more common than previously thought. Chronic vomiting, disorders of gastric emptying, hiatal hernia and anaesthesia-induced reductions in caudal oesophageal sphincter pressure have been implicated in the pathogenesis of gastro-oesophageal reflux in dogs and cats.

#### Diagnosis

**Clinical signs:** The clinical signs of gastro-oesophageal reflux are similar to those of oesophagitis. In severe cases, animals may develop regurgitation, salivation, odynophagia, extension of the head and neck during swallowing, and total avoidance of food. However, in milder cases, affected animals may have only an occasional episode of regurgitation, particularly in the early morning hours. The latter cases result from transient relaxations of the caudal oesophageal sphincter during sleep. The physical examination is usually unremarkable, but fever and excessive salivation may be detected in animals with severe concurrent oesophagitis.

**Diagnostic imaging:** The diagnosis of gastro-oesophageal reflux may be little more than clinical suspicion. Survey radiography does not aid in the diagnosis. Videofluoroscopy may demonstrate intermittent gastro-oesophageal reflux, but this finding may also be observed in animals with normal oesophageal function. Endoscopy is currently the best method for documenting mucosal inflammation consistent with reflux oesophagitis (see Chapter 4). Definitive diagnosis of gastro-oesophageal reflux would require continuous measurements of caudal oesophageal sphincter pressure and 24-hour intraluminal pH, procedures with which most dogs and cats are not compliant. Hiatal hernia, oesophagitis and oesophageal stricture are the most important differential diagnoses for gastro-oesophageal reflux.

#### Treatment

Because dietary fat delays gastric emptying and reduces caudal oesophageal sphincter pressure, animals should be fed fat-restricted diets. Pet owners should also avoid late night feedings because this would tend to reduce caudal oesophageal sphincter pressure during sleep. In addition to nutritional considerations, rational medical therapy for this disorder includes diffusion barriers (e.g. sucralfate), gastric acid secretory inhibitors (e.g. cimetidine, ranitidine, famotidine, omeprazole) and prokinetic agents (e.g. metoclopramide). Diffusion barriers are perhaps the most important medical therapy in gastro-oesophageal reflux. Sucralfate, for example, protects against mucosal damage from gastro-oesophageal reflux and promotes healing of existing oesophagitis. Refractory cases of gastro-oesophageal reflux should also be medicated with acid secretory inhibitors and/or prokinetic agents (see Chapter 28). The H<sub>2</sub> histamine receptor antagonists, e.g. cimetidine, ranitidine and famotidine, inhibit gastric acid secretion and reduce the amount of acid reflux. Omeprazole (a H<sup>+</sup>,K<sup>+</sup> adenosine triphosphatase (ATPase) inhibitor) could also be used to inhibit gastric acid secretion. Metoclopramide and low-dose erythromycin may be useful in treating gastro-oesophageal reflux because they increase caudal oesophageal sphincter pressure. 5-Hydroxytryptamine<sub>4</sub> (5-HT<sub>4</sub>) agonists, like cisapride, also increase tone in the caudal oesophageal sphincter but cisapride has been withdrawn from several international markets.

#### Prognosis

The prognosis for most animals with gastro-oesophageal reflux is good with medical management.

### Oesophageal fistula

#### Aetiology

An oesophageal fistula is an abnormal communication between the oesophagus and adjacent structures. Most oesophageal fistulae involve the lungs or airway structures, e.g. oesophagopulmonary, oesophagobronchial or oesophagotracheal fistulae. Occasionally, oesophageal fistulae expand into the pleural space or cervical tissues. Both congenital and acquired fistulae have been described. Congenital fistulae are rare and result from incomplete separation of the tracheobronchial tree from the digestive tract, from which it is formed during embryological development. An increased incidence of congenital oesophageal fistulae (and oesophageal diverticula) has been reported in the Cairn Terrier. Affected animals often have concurrent oesophageal foreign bodies, presumably because of abnormalities in oesophageal motility associated with the fistula.

Acquired oesophageal fistulae typically result from foreign body ingestion, oesophageal perforation and extension of inflammation into adjacent tissues. Bones and grass awns are most commonly incriminated. A traction diverticulum often also develops because of the inflammatory reaction between the oesophagus and bronchus. Secondary complications that may occur with oesophagobronchial fistula are localized pneumonias, pulmonary abscessation and pleuritis. The severity of the secondary complications usually depends on the duration and size of the fistula.

**Diagnosis**

**Clinical signs:** Animals with congenital oesophageal fistulae usually develop clinical signs shortly after weaning, whereas animals with acquired fistulae develop signs later in life. Clinical signs in nearly all cases are related to the respiratory system and include coughing and dyspnoea. Other signs that may develop include regurgitation, lethargy, anorexia, fever and weight loss. Regurgitation is usually reported in relation to an oesophageal foreign body.

**Diagnostic imaging:** The radiographic manifestations of oesophagobronchial fistula consist of localized alveolar, bronchial and/or interstitial lung patterns. The right caudal, right intermediate and left caudal lung lobes are most often involved. The oesophagus appears normal with radiography unless a radiopaque oesophageal foreign body is observed. Definitive diagnosis of oesophageal fistulae requires contrast radiography or endoscopy. An oesophagram should be performed with a thin mixture of barium sulphate contrast media (30% weight/volume) to elucidate the fistula. Use of iodinated contrast agents should be avoided since they are hyperosmolar and chemically irritating to the lung, although aspirated barium may also induce lung pathology. Endoscopy may also be useful in documenting an oesophageal fistula although small fistulae are occasionally missed. Lobar pneumonia is the most important differential diagnosis for oesophagobronchial fistula. Aspiration, bacterial and foreign body pneumonias can all mimic oesophagobronchial fistula.

**Treatment**

Surgical excision and repair provides the most successful outcome in animals with oesophagobronchial fistula. The fistula is surgically excised and the defect in the oesophagus is closed. Resection of the affected lung lobe is also generally warranted. A postoperative course of broad spectrum antibiotics should be prescribed in all cases.

**Prognosis**

The prognosis is guarded if secondary complications, such as pneumonia, pulmonary abscesses or large quantities of pleural fluid, are present. In the absence of such complications the prognosis is generally good.

**Hypomotility disorders of the oesophagus**

**Idiopathic megaesophagus**

**Aetiology**

Idiopathic megaesophagus is the most common cause of regurgitation in the dog. Apart from in dysautonomia, megaesophagus is a rare finding in the domestic cat. The disorder is characterized by oesophageal hypomotility and dilatation, regurgitation and progressive loss of body condition. Several forms of the syndrome have been described including congenital, acquired secondary and acquired idiopathic megaesophagus (Figure 18.4).

Cause	Investigations	Treatment
<b>Congenital megaesophagus</b>		
Myasthenia gravis	Edrophonium response ± electrophysiology	Pyridostigmine (1.0–3.0 mg/kg p.o. q12h)
Neuropathy	Oesophageal manometry ± electrophysiology	Elevated, small frequent feedings; bethanechol
Hiatal hernia	Survey and contrast chest radiography	Diaphragmatic crural apposition, oesophagopexy and gastropexy
Glycogen or lipid storage disease	Muscle or liver biopsy; white blood cell or fibroblast enzyme assays; urine metabolic screening	Enzyme replacement therapy?; supportive care; gene therapy
<b>Acquired idiopathic megaesophagus</b>		
Neuropathy	Oesophageal manometry ± electrophysiology	Elevated, small feedings; sucralfate
<b>Acquired secondary megaesophagus</b>		
Myasthenia gravis	Nicotinic acetylcholine receptor antibody; edrophonium response (difficult to assess) ± electrophysiology	Pyridostigmine ± prednisolone
Polymyositis/polymyopathy	Serum creatine phosphokinase; muscle biopsy ± electrophysiology	Prednisolone
Systemic lupus erythematosus	Antinuclear antibody	Prednisolone
Hypoadrenocorticism	ACTH stimulation test	Prednisolone; fludrocortisone
Hiatal hernia	Contrast radiography and oesophageal endoscopy	Sucralfate; cimetidine; omeprazole; corrective surgery
Gastric dilatation and volvulus	Survey ± contrast radiography	Reduce volvulus; gastropexy
Lead toxicity	Haematology; blood lead concentration	Chelation with calcium EDTA

**18.4** Medical investigation and treatment of megaesophagus. (continues)

Cause	Investigations	Treatment
<i>Acquired secondary megaesophagus (continued)</i>		
Organophosphate toxicity	Whole blood cholinesterase activity	Atropine; pralidoxime chloride for acute exposure; supportive care
Oesophagitis	Oesophageal endoscopy	Sucralfate; cimetidine; omeprazole
Hypothyroidism?	Thyroid function tests	Levothyroxine
Dermatomyositis	Skin and muscle biopsy	Prednisolone
Distemper	Cerebrospinal fluid analysis	Supportive care
Thymoma	Chest radiography; thymic aspiration and/or resection	Surgical resection
Dysautonomia	Clinical diagnosis	Supportive care

**18.4** (continued) Medical investigation and treatment of megaesophagus.

Congenital idiopathic megaesophagus is a generalized hypomotility and dilatation of the oesophagus, causing regurgitation and failure to thrive in puppies shortly after weaning. An increased breed incidence has been reported in the Irish Setter, Great Dane, German Shepherd Dog, Labrador Retriever, Shar Pei and Newfoundland, and autosomal dominant inheritance has been demonstrated in the Miniature Schnauzer and Fox Terrier. The pathogenesis of the congenital form is incompletely understood, although several studies have pointed to a defect in the vagal afferent innervation of the oesophagus. Congenital idiopathic megaesophagus has been reported in several cats and in one group of cats secondary to pyloric dysfunction.

Most cases of adult-onset megaesophagus have no known aetiology and are referred to as acquired idiopathic megaesophagus. The syndrome occurs spontaneously in adult dogs usually between 7 and 15 years of age without sex or breed predilection. The disorder has been compared erroneously to oesophageal achalasia in humans. Achalasia is a failure of relaxation of the lower oesophageal sphincter and ineffective peristalsis of the oesophageal body. A similar disorder has never been rigorously documented in the dog, although isolated case reports still appear from time to time. Several important differences between idiopathic megaesophagus in the dog and achalasia in humans have been documented. Although aetiologies have not been identified, some studies have suggested a defect in the afferent neural response to oesophageal distension, similar to that of congenital megaesophagus.

Acquired secondary megaesophagus may also develop in association with a number of other conditions. Myasthenia gravis accounts for 25–30% of the secondary cases. In some cases of myasthenia gravis, regurgitation and weight loss may be the only presenting signs of the disease, whereas in most other cases regurgitation is one of many clinical signs, including peripheral muscle weakness. Acquired secondary megaesophagus has also been associated with hypoadrenocorticism, lead poisoning, lupus myositis and severe forms of oesophagitis. Hypothyroidism has been suggested as a secondary cause of idiopathic megaesophagus but retrospective risk factor analysis has not identified it as an important cause.

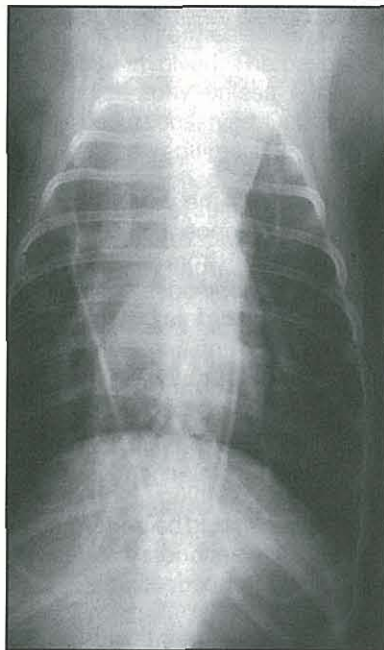
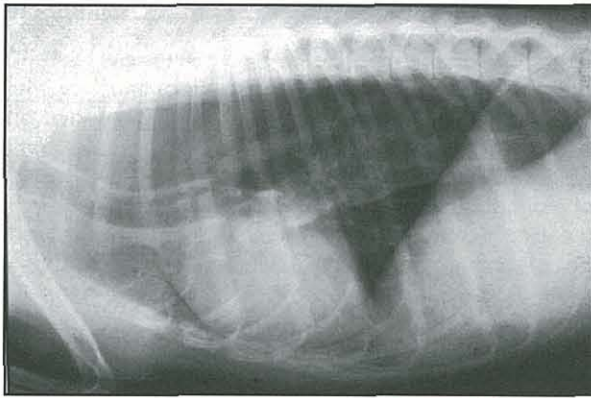
### Diagnosis

**Clinical signs:** Regurgitation is the most frequent clinical sign associated with megaesophagus. The frequency of regurgitation may vary from as little as one episode every few days to many episodes per day. As with many other oesophageal disorders, affected animals may suffer from malnutrition and aspiration pneumonia. Physical examination often reveals excessive salivation, mild to moderate cachexia, coughing and pulmonary crackles or wheezes.

**Laboratory tests:** Routine haematology, serum biochemistry profile and urinalysis should be performed in all cases to investigate possible secondary causes of megaesophagus (e.g. hypoadrenocorticism).

**Diagnostic imaging:** Survey radiography will be diagnostic for most cases of megaesophagus (Figure 18.5). Contrast radiography may be necessary in some cases to confirm the diagnosis, evaluate motility, and exclude foreign bodies or obstruction as the cause of the megaesophagus. Endoscopy will confirm the diagnosis (see Chapter 4). It may also reveal oesophagitis, a common finding in canine idiopathic megaesophagus. Risk factor analysis suggests that oesophagitis markedly increases the risk for the development of megaesophagus. It is not yet clear whether oesophagitis is a cause or consequence of megaesophagus.

**Additional tests:** If acquired secondary megaesophagus is suspected (see Figure 18.4) additional diagnostic tests should be considered, for example: serology for nicotinic acetylcholine receptor antibody; adrenocorticotrophic hormone (ACTH) stimulation test; and, if clinically indicated, serology for antinuclear antibody, serum creatine phosphokinase activity, electromyography and nerve conduction velocity, and muscle and nerve biopsy. Such additional medical investigations will be dependent upon the individual case presentation. A clear association with hypothyroidism has not been proven and thus thyroid function testing should be performed only in suspicious cases.



**18.5**

Idiopathic megaesophagus in an 8-year-old mixed-breed dog. Note the visible borders of the air-filled oesophagus on both the lateral and dorsoventral thoracic radiographs. On the lateral radiograph the trachea is depressed ventrally, and the overlying oesophageal wall creates a visible line (the 'tracheal stripe').

### Treatment

Animals with secondary acquired megaesophagus should be differentiated from those with other oesophageal disorders and treated appropriately (see Figure 18.4). Dogs affected with myasthenia gravis should be treated with pyridostigmine, corticosteroids or azathioprine. Mycophenolate mofetil has also been used in the treatment of myasthenia gravis, but it has not been sufficiently evaluated at this time to be recommended. Dogs affected with hypothyroidism should be treated with levothyroxine, and dogs affected with polymyositis should be treated with prednisolone. If secondary disease can be excluded, therapy for the congenital or acquired idiopathic megaesophagus patient should be directed at nutritional management and treatment of aspiration pneumonia.

Affected animals should be fed a high calorie diet in small frequent feedings, from an elevated or upright position to take advantage of gravity drainage through a hypomotile oesophagus. Dietary consistency should be formulated to produce the fewest clinical signs. Some animals handle liquid diets quite well, while others do better with solid meals. Animals that cannot maintain adequate nutritional balance with oral intake should be fed by temporary or permanent tube gastrostomy (see Chapter 27).

Pulmonary infections should be identified by culture and sensitivity, and an appropriate antibiotic selected for the offending organism(s). This may be accomplished by trans- or endotracheal wash or by bronchoalveolar lavage at the time of endoscopy.

Smooth muscle prokinetic (e.g. metoclopramide or cisapride) therapy has been advocated for stimulating oesophageal peristalsis in affected animals. However, metoclopramide and cisapride stimulate gastro-oesophageal sphincter contraction, but are unlikely to have much of an effect on the striated muscle of the canine oesophageal body. Oesophageal 5-HT<sub>4</sub> receptors are present in many animal species, but they are apparently absent in canine oesophageal striated muscle. Bethanechol (5–15 mg/dog p.o. q8h) has been shown to stimulate oesophageal propagating contractions in some affected dogs and is therefore a more appropriate prokinetic agent for the therapy of this disorder. Because of the high incidence of oesophagitis in canine idiopathic megaesophagus, affected animals should also be medicated with oral sucralfate suspensions.

Surgical cardiomyotomy (myotomy of the caudal oesophageal sphincter) has been recommended in the past as a therapeutic measure in the belief that canine megaesophagus is similar to human achalasia. Because most studies have reported normal caudal oesophageal sphincter tone and appropriate relaxation with swallowing, cardiomyotomy cannot be recommended for the treatment of this disorder. Indeed, animals treated with myotomy generally have had poorer outcomes than untreated animals.

### Prognosis

Animals with congenital idiopathic megaesophagus have a fair prognosis. With adequate attention to caloric needs and episodes of aspiration pneumonia, many animals will develop improved oesophageal motility over several months. Pet owners must be committed to months of physical therapy and nutritional support.

The morbidity and mortality of acquired idiopathic megaesophagus remain unacceptably high. Many animals eventually succumb to the effects of chronic malnutrition and repeated episodes of aspiration pneumonia. A poor prognosis must be given in such cases.

Animals with acquired secondary megaesophagus have a more favourable prognosis if the underlying disease can be promptly identified and successfully managed. Indeed, one recent report suggested that myasthenia gravis may spontaneously resolve within 6 months of the onset of the disease in 90% of cases. Refractory cases result from chronic oesophageal distension, myenteric nerve degeneration and muscle atrophy.

### Dysautonomia

#### Aetiology

Dysautonomia is a generalized autonomic neuropathy that was originally reported in cats in the United Kingdom, but that has now been documented in dogs and cats throughout Western Europe and the United States. The clinical signs reflect a generalized autonomic dysfunction of the GI and urinary tracts but megaesophagus,

oesophageal hypomotility and regurgitation are fairly consistent findings. Pathologically, degenerative lesions are found in autonomic ganglia, intermediate grey columns of the spinal cord and some sympathetic axons. Despite an intensive search for genetic, toxic, nutritional and infectious aetiological agents, no definitive aetiology has ever been established.

### Diagnosis

**Clinical signs:** The most frequently reported clinical signs are depression, anorexia, constipation and regurgitation or vomiting. Faecal and urinary incontinence have been reported less commonly. Physical examination findings consistent with dysautonomia include dry mucous membranes, pupillary dilatation, prolapsed nictitating membranes, reduced or absent pupillary light reflex, bradycardia, intestinal distension, urinary bladder distension and areflexic anus. Paresis and conscious proprioceptive deficits have been reported in a small number of animals.

A clinical diagnosis is made in most cases based on the historical and physical examination findings. Additional findings consistent with the diagnosis would include:

- Oesophageal dilatation and hypomotility on survey and barium contrast radiography
- Delayed gastric emptying on barium contrast radiography
- Reduced tear production in Schirmer tear tests
- Atropine-insensitive bradycardia
- Bladder and colonic distention on survey radiography.

There are few differential diagnoses to consider in a dog or cat presenting with the myriad manifestations of the syndrome. Early in the course of the illness, however, other differential diagnoses to consider are colonic or intestinal obstruction, other causes of megaesophagus and lower urinary tract disease.

### Treatment

Supportive care (e.g. artificial tears, elevated feedings, expressing the urinary bladder, antibiotics) is still the basis of therapy for this disorder, although some dogs and cats are reported to show mild improvement with parasympathomimetic drugs (e.g. bethanechol or metoclopramide). Gastrostomy tube feedings or total parenteral nutrition may sustain some animals until they regain neurological function.

### Prognosis

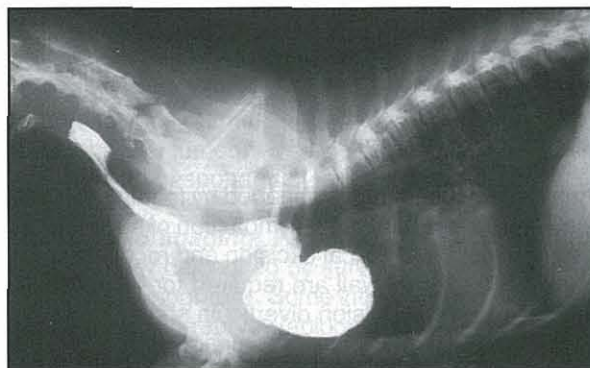
In general, dysautonomia carries a very guarded to poor prognosis for long-term survival in both the dog and the cat. Twenty to forty percent of affected cats are likely to recover, although cats may take 2–12 months to do so. Recovery rates are lower still in the dog. Complete recovery is uncommon and many cats and dogs are left with residual impairment, e.g. intermittent regurgitation, dilated pupils and faecal or urinary incontinence.

## Oesophageal diverticula

### Aetiology

Oesophageal diverticula are circumscribed sacculations in the wall of the oesophagus that interfere with normal oesophageal motility patterns. Both congenital and acquired forms have been described. The normal redundancy of the canine oesophagus, frequently pronounced in the brachycephalic breeds, should not be confused with the sacculation of an oesophageal diverticulum.

Congenital diverticula have been attributed to abnormalities in embryological development that permit herniation of the mucosa through a defect in the muscularis (Figure 18.6). Acquired diverticula are subdivided into either traction or pulsion forms. Traction diverticula tend to develop in the cranial and mid-oesophageal body and result from peri-oesophageal inflammation and fibrosis. Adhesions to adjacent tissue (e.g. lung, bronchus, lymph node) distort the oesophageal lumen and create sacculations. Abscess development from grass awn migration is a common cause of traction diverticula in the western United States. Pulsion diverticula develop in association with increases in intraluminal oesophageal pressure, abnormal regional oesophageal motility, or when normal peristalsis is obstructed by a stenotic lesion. Pulsion diverticula may develop as a consequence of vascular ring anomalies in the cranial oesophagus or from foreign bodies that become lodged in the distal oesophagus, in which case they are referred to as epiphrenic diverticula.



**18.6** Positive contrast radiograph of an oesophageal diverticulum in a 9-month-old Dachshund.

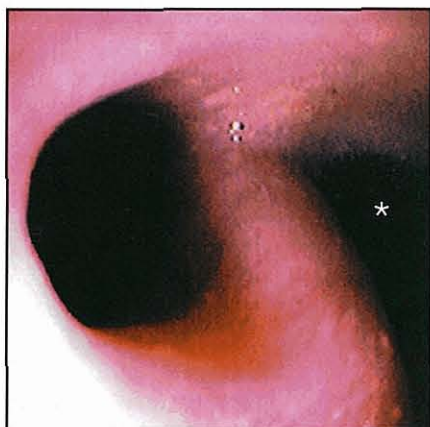
### Diagnosis

**Clinical signs:** The clinical signs of oesophageal diverticula are typical of many other oesophageal disorders and include regurgitation, odynophagia and retching. Signs usually result from impaction of food and/or fluid in the sacculated segment, and if this has not occurred diverticula may be incidental findings not associated with clinical signs. On rare occasions, weakening of the muscularis results in perforation of the diverticulum, leakage of food and fluid into the mediastinum and signs of sepsis.

**Diagnostic imaging:** Survey radiography may reveal an air-filled or tissue-density mass adjacent to or involving the oesophagus but contrast radiography is necessary to differentiate an oesophageal diverticulum from



a peri-oesophageal, mediastinal or pulmonary mass. An epiphrenic diverticulum could also easily be confused with a hiatal hernia or gastro-oesophageal intussusception on survey radiography. Contrast radiography will demonstrate a focal dilated segment of oesophageal lumen that fills partially or completely with contrast media (see Figure 18.6). Videofluoroscopy might also demonstrate an underlying oesophageal motility disorder associated with the diverticulum. Endoscopy will confirm the diagnosis, although it may be necessary to suction food and fluid to visualize the diverticulum (Figure 18.7).



**18.7**

Endoscopic view of an oesophageal diverticulum (\*) opening from the oesophageal lumen in a 12-month-old Dachshund bitch.

The differential diagnoses for cranial and mid-oesophageal diverticula should include oesophageal or peri-oesophageal abscess, necrotic tumour and pulmonary mass. Hiatal hernia and gastro-oesophageal intussusception are the major differential diagnoses for epiphrenic diverticula.

#### **Treatment**

Small diverticula may be managed by feeding liquid or semi-liquid diets to minimize impaction of solid food in the diverticulum. Surgical excision and reconstruction of the oesophageal wall are required for larger diverticula. Even small pulsion diverticula should probably be treated surgically since food impaction might cause them to enlarge.

#### **Prognosis**

Most cases warrant a guarded prognosis since segmental oesophageal hypomotility may persist after surgery. Animals are also at some risk for oesophageal stricture following corrective surgery. In cases of traction diverticula, the prognosis will also be somewhat dependent upon the pathogenesis and resolution of the peri-oesophageal inflammation.

### **Oesophageal obstructions**

#### **Oesophageal stricture**

##### **Aetiology**

Oesophageal stricture is an abnormal narrowing of the oesophageal lumen. The most important aetiologies of stricture are chemical injury from swallowed substances, oesophageal foreign bodies, oesophageal surgery,

and intraluminal or extraluminal mass lesions (neoplasia or abscesses). Anaesthesia, poor patient preparation and poor patient positioning during anaesthesia place some animals at risk for gastro-oesophageal reflux, oesophagitis and subsequent stricture formation. Cats appear to be particularly susceptible to doxycycline-associated oesophagitis and oesophageal stricture. Fibrosis and mass compression are the most important pathogenetic mechanisms involved in stricture formation.

#### **Diagnosis**

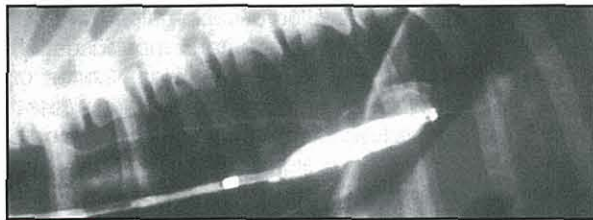
**Clinical signs:** The clinical signs of progressive regurgitation and dysphagia are related to the severity and extent of the stricture. At the outset, the animal's appetite is unaffected. Regurgitation occurs shortly after feeding and the animal may attempt to re-ingest the regurgitated meal. An important clinical sign is that liquid meals are often better tolerated than solid meals. With progressive oesophageal narrowing and inflammation affected animals develop complete anorexia, weight loss and malnutrition. Some animals also develop aspiration pneumonia. The physical examination is remarkable for ptyalism, cachexia and malnutrition. Pulmonary signs (wheezes and cough) may be detected in animals affected with aspiration pneumonia.

**Diagnostic imaging:** As with other oesophageal disorders, the diagnosis is based on clinical signs and radiographic and endoscopic findings. Intraluminal or extraluminal mass lesions may be evident on survey radiography in animals with compressive oesophageal stricture. Survey radiographs are usually unremarkable in animals with benign fibrosing strictures. Segmental or diffuse narrowing observed with barium contrast radiography is usually diagnostic of the disorder. There may also be some oesophageal dilatation proximal to the stricture site. Ultrasonography has not proved useful in diagnosing benign fibrosing strictures, but it may be useful in diagnosing those caused by mass compression. Some mediastinal and other peri-oesophageal masses may be successfully aspirated with ultrasound guidance. Endoscopy should be performed in all animals to confirm the site and severity of stricture (see Chapter 4) and to exclude the possibility of intraluminal malignancy. Benign fibrosing strictures must be differentiated from vascular ring anomalies, oesophagitis, intraluminal oesophageal masses and extraluminal peri-oesophageal masses. These disorders can usually be differentiated with survey and contrast radiography, endoscopy and thoracic ultrasonography.

#### **Treatment**

Oral feedings should be withheld in cases of severe stricture or oesophagitis. In such cases, a temporary gastrostomy tube may be placed at the time of oesophageal dilatation as a means of providing continuous nutritional support (see Chapter 27). Liquid meals should be used when re-instituting oral feedings. Animals may be discharged from the hospital after

adequate rehydration, dilatation of the affected oesophageal segment, nutritional intervention and appropriate therapy for aspiration pneumonia. Oesophageal strictures are best managed with mechanical dilatation. Dilatation may be achieved with balloon dilatation catheters or bougienage tubes. Balloon dilatations are safer and more effective in applying radial forces to expand the stricture site. A greater risk of perforation is associated with the use of bougienage tubes due to shearing forces applied by the instrument. Multiple dilatations at 1–2 week intervals may be necessary until the stricture is resolved. Oesophageal dilatation is best performed with direct observation at the time of endoscopy, but it can be performed with videofluoroscopy (Figure 18.8).



**18.8** Placement of an oesophageal balloon dilatation catheter at a stricture site. The balloon is distended with a radiopaque contrast agent.

Medical therapies aimed at treating the inflammatory component of this lesion are best used as adjunctive therapy to mechanical dilatation. Animals with concurrent oesophagitis should be treated with oral sucralfate suspensions and gastric acid secretory inhibitors (e.g. cimetidine, ranitidine, famotidine or omeprazole). It has also been suggested that anti-inflammatory doses of corticosteroids (e.g. prednisolone) have also been advocated to prevent fibrosis and re-stricture during the healing phase following oesophageal dilatation. It has been suggested that intra-lesional steroid injections (e.g. 1 mg triamcinolone acetonide) administered at the time of stricture dilatation may be beneficial in reducing the risk of recurrence.

Surgical resection of oesophageal strictures has been reported, but resections are complicated by inadequate surgical exposure, lengthy resections, tension on the anastomosis and poor healing properties of the thoracic oesophagus. Surgical correction by jejunal interposition or by creation of a traction diverticulum has been attempted, but only in a small number of cases. Recent developments with bioresorbable collagen or extracellular matrix scaffolds may help to facilitate repair following oesophageal resection.

### Prognosis

Strictures associated with foreign body ingestion or oesophagitis have a guarded to fair prognosis. Multiple dilatations are often required to achieve an adequate oesophageal lumen. Oesophageal perforation is a potentially life-threatening complication of oesophageal stricture dilatation. Perforations usually occur at the time of oesophageal dilatation, although they have been observed several days to weeks afterwards. Malignant strictures have a poor prognosis. Surgical resection is often the only possible recourse.

## Oesophageal neoplasia

### Aetiology

Oesophageal cancer accounts for <0.5% of all cancers in the dog and cat. Tumours of the oesophagus may be of primary oesophageal, peri-oesophageal or metastatic origin. The most common primary oesophageal tumours in the dog are osteosarcomas and fibrosarcomas, particularly in areas where *Spirocerca lupi* infection is endemic. Spirocerca oesophageal granulomas may undergo metaplastic and neoplastic transformation to fibrosarcomas and osteogenic sarcomas. Squamous cell carcinoma is the most common primary oesophageal tumour in the cat. Less commonly reported primary oesophageal tumours of the dog and cat include leiomyo(sarco)mas, scirrhous carcinomas and adenocarcinomas. Metastatic lesions appear to be the most common oesophageal tumours in dogs and cats and include thyroid, pulmonary and gastric carcinomas. Tumours of the peri-oesophageal structures (lymph node, thyroid, thymus and heart base) cause local oesophageal invasion and/or direct mechanical obstruction of the oesophagus.

### Diagnosis

**Clinical signs:** The primary clinical signs of oesophageal neoplasia are regurgitation, dysphagia, odynophagia and weight loss. Clinical signs develop gradually and reflect progressive oesophageal obstruction or abnormal oesophageal motility. Animals with metastatic disease may have general debilitation and signs of other organ system involvement, such as dyspnoea or cough. Physical examination may reveal little more than cachexia, although some peri-oesophageal and oesophageal tumours may be palpable if they involve the cervical oesophagus.

**Diagnostic imaging:** Peri-oesophageal tumours are often readily diagnosed by survey radiography or thoracic ultrasonography. Some intraluminal tumours may be diagnosed on survey radiography alone, while others may require barium contrast radiography or endoscopy and mucosal biopsy. The major differential diagnoses for intraluminal oesophageal neoplasia are benign fibrosing stricture and foreign bodies. Radiography and endoscopy will usually differentiate these disorders.

### Treatment

Chemotherapy, surgical resection and radiation therapy are conventionally accepted methods for the treatment of malignant oesophageal neoplasia. Radiation therapy may be complicated by acute or chronic injury to adjacent mediastinal structures, while surgical resections are complicated by inadequate surgical exposure, lengthy resections, tension on the anastomosis and poor healing properties of the thoracic oesophagus. Photodynamic and cryotherapy have been studied under physiological circumstances but have not yet been applied in clinical patients. Recent developments with bioresorbable collagen or extracellular matrix scaffolds may help to facilitate repair following oesophageal resection. Lymphosarcoma may be treated in some cases

with chemotherapy or immunotherapy. Benign oesophageal neoplasia, e.g. leiomyoma, generally have a favourable prognosis following surgical resection.

### Prognosis

Except for the rare benign lesion or lymphosarcoma, the overall prognosis for oesophageal neoplasia is poor for cure or palliation.

## Oesophageal foreign bodies

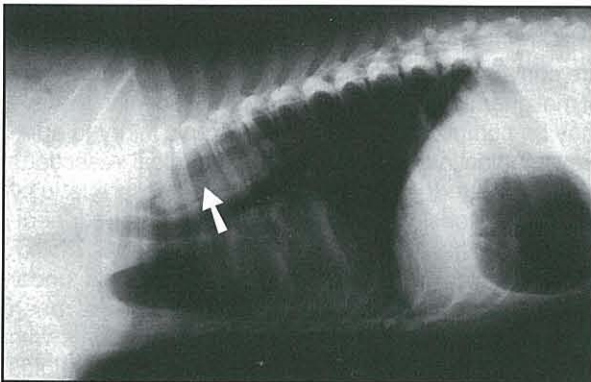
### Aetiology

Oesophageal foreign bodies are a frequent clinical problem in dogs and cats. The most common oesophageal foreign bodies found in dogs are bones, bone fragments, and coins, whereas play objects are more commonly found in cats. Many foreign bodies are regurgitated or transported into the distal gastrointestinal tract, but others remain lodged in the oesophageal body. Those that are too large to pass through the oesophagus cause mechanical obstruction. The severity of oesophageal damage is dependent upon foreign body size, angularity or sharp pointedness, and the duration of obstruction.

### Diagnosis

**Clinical signs:** In many cases there is a history of foreign body ingestion. Some cases go unnoticed, however, particularly those associated with scavenging. The onset of clinical signs will depend upon the severity of oesophageal obstruction. Animals with complete oesophageal obstruction are often presented with acute signs, whereas animals with incomplete obstruction may be presented with signs of days' to weeks' duration. Relevant clinical signs include regurgitation, excessive salivation, odynophagia, anorexia, dysphagia, retching and tachypnoea.

**Diagnostic imaging:** Bone foreign bodies can occasionally be palpated if they become lodged in the cervical oesophagus but definitive diagnosis usually requires radiography. Radiodense foreign bodies can be detected with survey radiography (Figure 18.9) but confirmation of radiolucent foreign bodies requires administration of contrast agents. Contrast agents should be used with caution if oesophageal perforation is suspected. Foreign bodies may subsequently be



**18.9** Oesophageal foreign body (arrowed) in a 6-year-old mixed-breed dog.

confirmed (and removed) during endoscopy. A tentative diagnosis of oesophageal foreign body may be made in animals presented with oesophageal signs following a history of foreign body ingestion.

Without a compatible history, the most important differential diagnoses would include oesophageal stricture, neoplasia, hiatal hernia and gastro-oesophageal intussusception. Each of these conditions can be differentiated with radiography and/or endoscopy.

### Treatment

Oesophageal foreign bodies should be removed promptly. Prolonged retention increases the likelihood of oesophageal mucosal damage, ulceration and perforation. Rigid or flexible fibreoptic endoscopic retrieval should be the initial approach to treating an oesophageal foreign body, although fluoroscopic-guided retrieval is also possible. A rigid endoscope is most useful in retrieving large foreign bodies, particularly bones or bone fragments. Large grasping forceps are passed through the rigid endoscope to retrieve the foreign body, and in many cases, the foreign body can be pulled into the endoscope for safe removal. Large foreign bodies that cannot be safely removed through the mouth can occasionally be pushed into the stomach and removed by gastrotomy. Smaller foreign bodies are best managed with a flexible fibreoptic endoscope and basket, tripod or snare retrieval forceps. Flexible endoscopes are particularly useful in retrieving fish hooks.

Affected animals should be fasted for 24–48 hours after foreign body removal. Longer periods of fasting may be required if the oesophagus is necrotic or ulcerative. In the latter circumstance, animals may instead be fed through a gastrostomy tube placed at the time of endoscopy. Specific therapy for oesophagitis should include oral sucralfate suspensions. Suspensions of sucralfate are more therapeutic than intact tablets. Anti-inflammatory doses of glucocorticoids (e.g. prednisolone) should also be considered in those animals at risk for oesophageal stricture. The risk of oesophageal stricture is greatest in animals with 180 degree or greater transmucosal ulceration. Finally, broad spectrum antibiotics should be considered in animals with severe ulceration or small perforations.

Surgery is indicated if endoscopy fails or if there is evidence of oesophageal perforation. Gastrotomy is preferred to oesophagotomy for distal oesophageal foreign bodies because of the poorer healing properties of the oesophagus and the potential for stricture formation. However, oesophagotomy would certainly be indicated in those cases where the foreign body could not be removed through gastrotomy. Surgery is also indicated to repair oesophageal perforation.

### Prognosis

The prognosis for most oesophageal foreign bodies is generally good, especially if they are removed immediately. A poorer prognosis is associated with foreign bodies that are large, have sharp points or are retained for a prolonged period of time. Immediate complications include complete obstruction or laceration, whereas late complications include perforation, haemothorax, fistulation and diverticulum or stricture formation.

## Vascular ring anomalies

### Aetiology

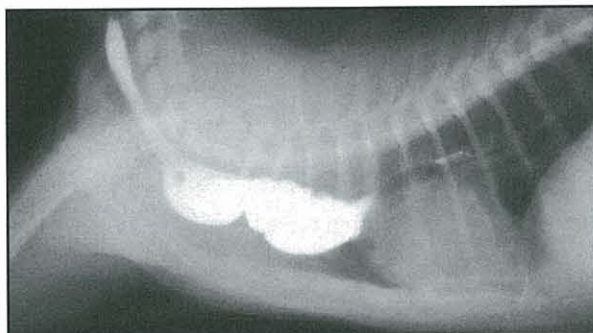
Vascular ring anomalies are congenital malformations of the major arteries of the heart that, because of altered anatomical relationships, entrap the oesophagus and trachea. Persistent right aortic arch, persistent right or left subclavian arteries, persistent right dorsal aorta, double aortic arch, left aortic arch and right ligamentum arteriosum, and aberrant intercostal arteries have been described in both dogs and cats. Persistent right aortic arch is the most common vascular ring anomaly found in dogs and cats. Circular compression of the oesophagus by the right fourth aortic arch results in physical obstruction of the oesophagus and/or trachea. The anomaly is considered to be a familial disease with evidence of a hereditary basis in German Shepherd Dogs. Aberrant subclavian arteries are the second most common vascular ring anomaly. The latter anomalies result in significant oesophageal compression from the left subclavian artery and brachycephalic artery.

### Diagnosis

**Clinical signs:** Affected puppies and kittens are presented at a young age with the major complaints of regurgitation and failure to thrive. Animals usually do well until weaning when they change from liquid to solid foods. Aspiration pneumonia develops in some animals as a result of constant regurgitation, but signs of tracheal compression are uncommon. Physical examination most often reveals a thin, stunted animal that is apparently malnourished but normal in other respects. Occasionally, a dilated oesophagus can be observed or palpated in the cervical region.

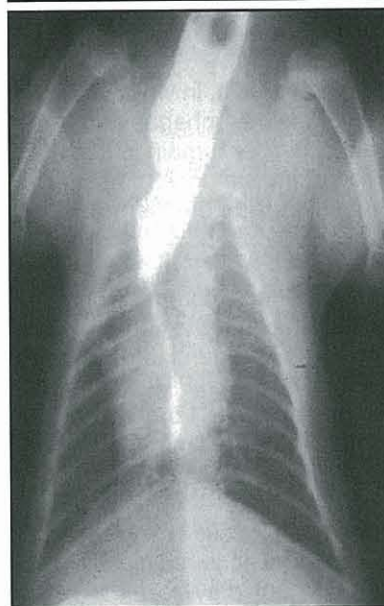**Laboratory tests:** Laboratory findings are usually normal. As with other oesophageal disorders, regenerative neutrophilia may be associated with aspiration pneumonia, and hypoalbuminaemia may be associated with malnutrition.

**Diagnostic imaging:** The diagnosis of a vascular ring anomaly is based upon a compatible history, tracheal narrowing and the barium contrast radiographic finding of oesophageal body dilatation cranial to the base of the heart (Figure 18.10); a proximal diverticulum occasionally forms with longstanding untreated vascular ring anomalies. The caudal oesophagus usually appears normal but there might be a mild dilatation with reduced motility. The most important differential diagnosis for vascular ring anomaly is intraluminal stricture (see above). Endoscopy can be performed to differentiate intraluminal stricture from extraluminal compression. With a vascular ring anomaly, pulsations of the major arteries can be observed in the region of oesophageal narrowing. Furthermore, vascular ring anomalies occur at the base of the heart, whereas intraluminal strictures can occur in any segment of the oesophageal body and are more common in adult animals. Angiography is only occasionally performed to clarify complex or atypical vascular ring anomalies or to determine the best surgical approach.



18.10

Lateral and dorsoventral positive contrast radiographs showing pooling of contrast media in a dilated oesophageal segment cranial to a narrowing caused by a persistent right aortic arch in a 3-month-old Persian kitten.



### Treatment

Persistent right aortic arch is best managed surgically using a left intercostal approach. Persistent right ductus arteriosus, aberrant right subclavian artery and double aortic arch are best approached by right intercostal thoracotomy. Surgical ligation and division of the ligamentum arteriosum is the recommended therapy in cases of persistent right aortic arch. At surgery, areas of peri-oesophageal fibrosis should be reduced and the strictured site should be dilated with a balloon dilatation catheter. Other techniques to resect, reduce or replace the redundant oesophagus have not proven beneficial. (See *BSAVA Manual of Head, Neck and Thoracic Surgery*)

Some animals may have persistent oesophageal hypomotility and clinical signs following corrective surgery. This is most likely if treatment is delayed. These animals may benefit from elevated feedings. Unfortunately, there are no drugs to improve striated muscle contraction in the canine oesophagus. Metoclopramide may be of some benefit in cats with oesophageal motility disorders but only those confined to the smooth muscle of the distal oesophageal body.

### Prognosis

The best outcomes are obtained with early diagnosis and early surgical intervention. In undiagnosed cases progressive oesophageal dilatation causes irreversible myenteric nerve degeneration and oesophageal hypomotility, but recent studies suggest that a 90% or greater

recovery rate can be expected. Clients should be informed that, although surgical correction is the preferred treatment, clinical signs may persist after surgery.

## Hiatal hernia

### Aetiology

Two types of hiatal hernia have been recognized in the dog and cat:

- Sliding hiatal hernia, in which the abdominal segment of the oesophagus and parts of the stomach are displaced cranially through the oesophageal hiatus
- Para-oesophageal hiatal hernia, in which the abdominal segment of the oesophagus and caudal oesophageal sphincter remain in a fixed position but a portion of the stomach herniates into the mediastinum alongside the thoracic oesophagus.

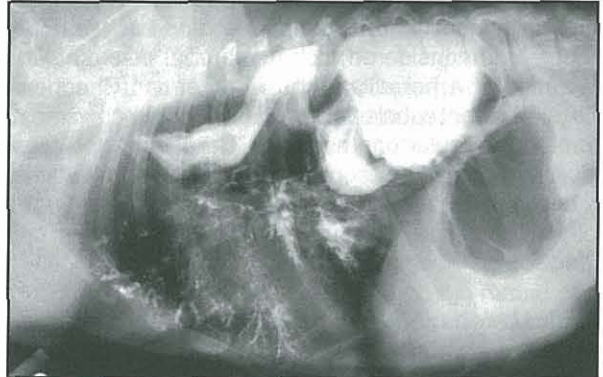
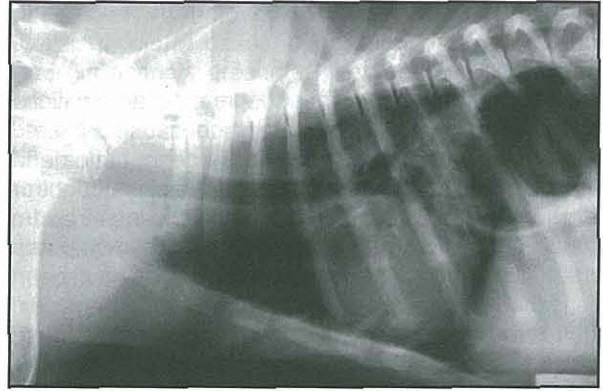
Sliding hiatal hernia is the most common form and may occur as a congenital or acquired lesion in the dog and cat. Congenital sliding hiatal hernias have been reported in the Shar Pei, Chow Chow, Bulldogs and French Bulldogs. The hernia results from incomplete fusion of the diaphragm during early embryonic development. Affected animals develop clinical signs shortly after weaning.

Acquired hiatal hernia may occur in any breed of dog or cat. The pathogenesis of acquired hiatal hernia is incompletely understood but may result from increases in intra-abdominal pressure with chronic vomiting disorders, or from chronic increases in negative intrathoracic pressure in animals with intermittent airway obstruction, e.g. laryngeal paralysis.

### Diagnosis

**Clinical signs:** Regurgitation, vomiting and hypersalivation are the most important clinical signs in congenital hiatal hernia. Regurgitation and hypersalivation result from the chemical effects of gastric juice (e.g. H<sup>+</sup> and pepsins) on the oesophageal mucosa, while vomiting may result from the obstructive effects of the hernia. Dyspnoea and coughing may also occur with severe herniation or aspiration pneumonia. Findings on physical examination are usually unremarkable but may include dehydration, pulmonary crackles or wheezes and decreased bodyweight. Clinical findings are usually similar, but less severe, in animals with acquired hiatal hernia; these animals may have inspiratory stridor associated with laryngeal paralysis.

**Diagnostic imaging:** The survey radiographic finding of a caudodorsal gas-filled intrathoracic soft-tissue opacity is consistent with the diagnosis of hiatal hernia (Figure 18.11). Affected animals may also have oesophageal dilatation and dependent alveolar consolidation consistent with aspiration pneumonia. Barium contrast studies may confirm the diagnosis and further delineate oesophageal dilatation and hypomotility. Videofluoroscopy should always be performed to as-



**18.11** Congenital hiatal hernia in a 3-month-old Shar Pei puppy. An unusual gas-filled mass protruding through the line of the diaphragm into the caudal thorax was confirmed by contrast radiography to be a hiatal hernia. However, inhalation of barium into the ventral lung fields occurred when the puppy regurgitated.

sess for intermittent herniation if a hiatal hernia is suspected but not proven by survey radiography. Endoscopic findings consistent with the diagnosis include cranial displacement of the caudal oesophageal sphincter and a large oesophageal hiatus. Because young animals with congenital hiatal hernia have varying degrees of oesophageal dilatation, a misdiagnosis of congenital idiopathic megaesophagus could be made if herniation at the hiatus is not readily apparent. Therefore, the finding of oesophageal dilatation in a young Shar Pei or another susceptible breed should raise a high index of suspicion of an underlying hiatal hernia. Gastro-oesophageal reflux, gastro-oesophageal intussusception, epiphrenic diverticulum and diaphragmatic hernia are the other major differential diagnoses for hiatal hernia.

### Treatment

A sliding hiatal hernia is not always associated with clinical signs, particularly the acquired form of the disease. When animals develop clinical signs, medical therapy should be attempted first. Medical therapy is similar to that for gastro-oesophageal reflux and should be directed at reducing gastric acid secretion (e.g. H<sub>2</sub> receptor antagonism, H<sup>+</sup>, K<sup>+</sup> ATPase inhibition), restoring the health of the oesophageal mucosa (e.g. sucralfate) and increasing the tone of the caudal oesophageal sphincter (e.g. metoclopramide or erythromycin). Many acquired sliding hiatal hernias will respond to conservative medical therapy, although laryngeal surgery (e.g.

partial laryngectomy or lateralization of the vocal folds) should be considered if laryngeal paralysis has contributed to the pathogenesis of the hernia. Congenital hiatal hernias often require surgical correction. Diaphragmatic crural apposition, oesophagopexy and gastropexy are usually sufficient to restore normal hiatus anatomy. Tube gastrotomy should be considered in those animals with concurrent severe oesophagitis or ulceration. Fundoplication procedures may be performed but are generally not necessary.

### Prognosis

The prognosis for surgical correction is generally favourable. Animals have few if any clinical signs following restoration of the normal anatomy.

### Gastro-oesophageal intussusception

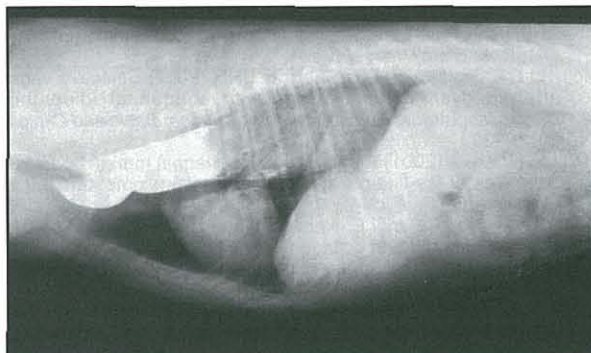
#### Aetiology

Gastro-oesophageal intussusception is a rare condition of young dogs (most younger than 3 months of age) resulting from invagination of the stomach into the oesophagus, with or without other abdominal organs, e.g. spleen, duodenum, pancreas and omentum. The disorder is more common in dogs than in bitches, with a higher incidence reported in German Shepherd Dogs. Many affected animals have pre-existing oesophageal disease, most importantly idiopathic megaesophagus. The role of idiopathic megaesophagus in the pathogenesis of gastro-oesophageal intussusception is not very well understood, but it may be that the greatly enlarged capacity of a dilated oesophagus accommodates the invagination of the stomach through the diaphragmatic hiatus. Gastro-oesophageal intussusception is a true GI emergency that may culminate in the death of the animal if untreated.

#### Diagnosis

**Clinical signs:** The initial clinical signs are vomiting or regurgitation, dyspnoea, haematemesis and abdominal discomfort. If diagnosis and therapy are delayed, these clinical signs are rapidly followed by marked deterioration in condition, shock, respiratory and cardiac arrest, and death.

**Diagnostic imaging:** Survey radiography will reveal proximal oesophageal dilatation, consolidation or mass effect between the cardiac silhouette and the diaphragm, and gastric rugal folds within the intrathoracic oesophagus. Contrast radiographic studies usually reveal that the column of barium sulphate contrast media traverses the proximal oesophageal body but does not enter the distal oesophagus or stomach (Figure 18.12). Endoscopy will confirm an intra-oesophageal mass that completely obstructs the lumen of the oesophagus. The major differential diagnoses are hiatal hernia, epiphrenic diverticulum and diaphragmatic hernia. It is sometimes difficult to distinguish these entities from gastro-oesophageal intussusception. Since the defining characteristic of a gastro-oesophageal intussusception is the invagination of the stomach into the oesophagus, gastric rugal folds are often readily identified within the lumen of the oesophagus on survey or contrast radiography.



**18.12** Positive contrast radiograph of a gastro-oesophageal intussusception in a 12-month-old mixed breed dog.

#### Treatment

The recommended therapy is a brief period of stabilization followed by definitive endoscopic or surgical reduction. After reduction of the intussusception, a gastropexy should be performed to prevent recurrence. If disease of the oesophageal hiatus is involved in the pathogenesis of the intussusception, then restorative surgery (e.g. diaphragmatic crural apposition) should also be performed.

#### Prognosis

The prognosis is poor unless the disorder is quickly recognized and treated. Mortality rates have been reported in excess of 95%.

### References and further reading

- Adamama-Moraitou KK, Rallis TS, Prassinou NN and Galatos AD (2002) Benign esophageal stricture in the dog and cat: a retrospective study of 20 cases. *Canadian Journal of Veterinary Research* **66**, 55–59
- Badyak S, Meurling S, Chen M, Spievack A and Simmons-Byrd A (2000) Resorbable bioscaffold for esophageal repair in a dog model. *Journal of Pediatric Surgery* **35**, 1097–1103
- Berghaus RD, O'Brien DP, Johnson GC and Thorne JG (2001) Risk factors for development of dysautonomia in dogs. *Journal of the American Veterinary Medical Association* **218**, 1285–1290
- Berry WL (2000) *Spirocerca lupi* esophageal granulomas in 7 dogs: resolution after treatment with doramectin. *Journal of Veterinary Internal Medicine* **14**, 609–612
- Brockman D and Holt D (in preparation) *BSAVA Manual of Canine and Feline Head, Neck and Thoracic Surgery*. BSAVA Publications, Gloucester
- Cohn LA, Stoll MR, Branson KR, Roudabush AD, Kerl ME, Langdon PF and Johannes CM (2003) Fatal hemothorax following management of an esophageal foreign body. *Journal of the American Animal Hospital Association* **39**, 251–256
- Cox MR, Franz SJ and Martin CJ (2000) The effect of fundoplication on the motility of the canine lower oesophageal sphincter. *Australian and New Zealand Journal of Surgery* **70**, 68–72
- Detweiler DA, Biller DS, Hoskinson JJ and Harkin KR (2001) Radiographic findings of canine dysautonomia in twenty-four dogs. *Veterinary Radiology and Ultrasound* **42**, 108–112
- Frost D, Lasota J and Miettinen M (2003) Gastrointestinal stromal tumors and leiomyomas in the dog: a histopathologic, immunohistochemical and molecular genetic study of 50 cases. *Veterinary Pathology* **40**, 42–54
- Graham JP, Lipman AH and Newell SM (2000) Esophageal transit of capsules in clinically normal cats. *American Journal of Veterinary Research* **61**, 655–657
- Han E, Broussard J and Baer KE (2003) Feline esophagitis secondary to gastroesophageal reflux: clinical signs and radiographic, endoscopic and histopathological findings. *Journal of the American Animal Hospital Association* **39**, 161–167
- Harkin KR, Andrews GA and Nietfeld JC (2002) Dysautonomia in dogs: 65 cases (1993–2000). *Journal of the American Veterinary Medical Association* **220**, 633–639

## Chapter 18 Disorders of the pharynx and oesophagus

- Head KW, Else RW and Dubielzig RR (2002) Tumors of the alimentary tract. In: *Tumors in Domestic Animals*, ed. DJ Meuten, pp. 401–481. Iowa State Press, Ames
- Holland CT, Satchell PM and Farrow BRH (2002) Selective vagal afferent dysfunction in dogs with congenital idiopathic megaesophagus. *Autonomic Neuroscience: Basic and Clinical* **99**, 18–23
- Hotston Moore A (2001) Removal of oesophageal foreign bodies in dogs: use of the fluoroscopic method and outcome. *Journal of Small Animal Practice* **42**, 227–230
- Kovacs T, Kovacs I, Pandi E, Nemeth T and Kralovanszky J (2001) Bursting strength and collagen content changes in esophageal anastomoses. Comparative experimental study in dogs. *Annales Chirurgiae et Gynaecologiae* **90**, 266–270
- Leib MS, Dinnel H, Ward DL, Reimer ME, Towell TL and Monroe WE (2001) Endoscopic balloon dilation of benign esophageal strictures in dogs and cats. *Journal of Veterinary Internal Medicine* **15**, 547–552
- Melendez L and Twedt DC (2000) Esophageal strictures secondary to doxycycline administration in 4 cats. *Feline Practice* **28**, 10–12
- Mu L and Sanders I (2000) Neuromuscular specializations of the pharyngeal dilator muscles: II. Compartmentalization of the canine genioglossus muscle. *Anatomical Record* **260**, 308–325
- Nawrocki MA, Mackin AJ, McLaughlin R and Cantwell HD (2003) Fluoroscopic and endoscopic localization of an esophagobronchial fistula in a dog. *Journal of the American Animal Hospital Association* **39**, 257–261
- Niles JD, Williams JM, Sullivan M and Crowsley FE (2001) Resolution of dysphagia following cricopharyngeal myectomy in six young dogs. *Journal of Small Animal Practice* **42**, 32–35
- O'Brien DP and Johnson GC (2002) Dysautonomia and autonomic neuropathies. *Veterinary Clinics of North America: Small Animal Practice* **32**, 251–265
- Panjehpour M, DeNovo RC, Petersen MG, Overholt BF, Bower R, Rubinchik V and Kelly B (2002) Photodynamic therapy using Verteporfin (benzoporphyrin derivative monoacid ring A, BPD-MA) and 630 nm laser light in canine esophagus. *Lasers in Surgery and Medicine* **30**, 26–30
- Pasricha PJ, Hill S, Wadwa KS, Gislason GT, Okolo PI 3<sup>rd</sup>, Magee CA Canto MI, Kuo WH, Baust JG and Kalloo AN (1999) Endoscopic cryotherapy: experimental results and first clinical use. *Gastrointestinal Endoscopy* **49**, 627–631
- Pollard RE, Marks SL, Davidson A and Hornof WJ (2000) Quantitative videofluoroscopic evaluation of pharyngeal function in the dog. *Veterinary Radiology and Ultrasound* **41**, 409–412
- Pratschke KM, Bellenger CR, McAllister H and Campion D (2001) Barrier pressure at the gastroesophageal junction in anesthetized dogs. *American Journal of Veterinary Research* **62**, 1068–1072
- Shelton GD and Lindstrom JM (2001) Spontaneous remission in canine myasthenia gravis: implications for assessing human MG therapies. *Neurology* **57**, 2139–2141
- Swann HM and Holt DE (2002) Canine gastric adenocarcinoma and leiomyosarcoma: a retrospective study of 21 cases (1986–1999) and literature review. *Journal of the American Animal Hospital Association* **38**, 157–164
- Washabau RJ (2000) Diseases of the esophagus. In: *Textbook of Veterinary Internal Medicine*, 5<sup>th</sup> edn, ed. SJ Ettinger and EC Feldman, pp. 1142–1153. WB Saunders, Philadelphia
- Washabau RJ (2003) Gastrointestinal motility disorders and G.I. prokinetic therapies. In: *Veterinary Clinics of North America*, ed. MD Willard, pp. 1007–1028. WB Saunders, Philadelphia
- Washabau RJ and Holt DE (2003) Pathophysiology of gastrointestinal disease. In: *Textbook of Veterinary Surgery* 3<sup>rd</sup> edn, ed. D Slatter, pp. 530–555. WB Saunders, Philadelphia
- Westfall DS, Twedt DC, Steyn PF, Oberhuser EB and VanCleave JW (2001) Evaluation of esophageal transit of tablets and capsules in 30 cats. *Journal of Veterinary Internal Medicine* **15**, 467–470
- <http://caltest.vet.upenn.edu/giphys> An interactive clinical case of canine dysautonomia and review of autonomic nervous system physiology.

# Diseases of the stomach

Kenneth W. Simpson

## Structure and function

The stomach functions as a reservoir that controls the size and rate of passage of ingesta into the small intestine, and initiates the digestion of protein and fat, and the absorption of vitamins and minerals.

The stomach is made up of four functional regions: the cardia, fundus, body and antrum (Figure 19.1).

- The fundus and body expand to accommodate ingesta.
- The antrum is thick and muscular and grinds food into small particles that are triturated into the duodenum.
- The pyloric sphincter controls efflux into the duodenum, and the lower oesophageal sphincter prevents reflux of ingesta into the oesophagus.

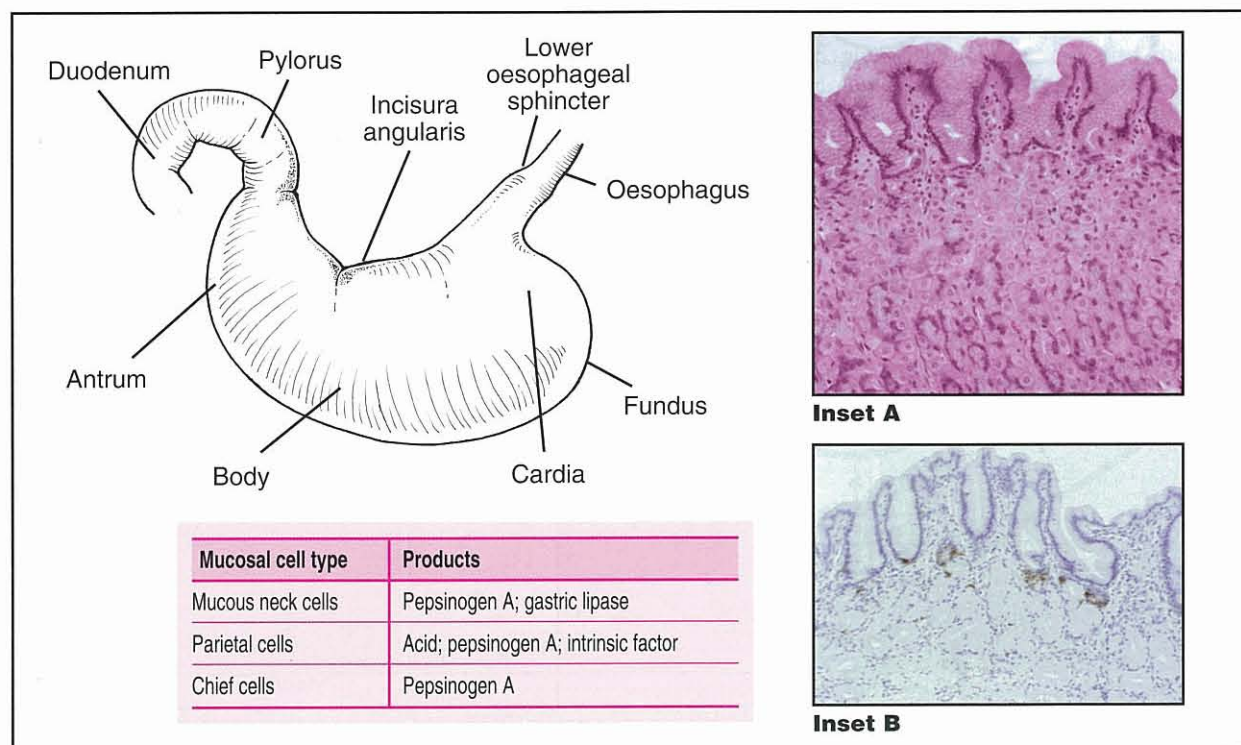
The gastric wall is composed of a mucosa, muscularis and serosa. The mucosa has a superficial epithelium,

gastric glands and an innermost layer of smooth muscle, with fine structure and function varying depending on the region. The mucosa in the cardia and pylorus is thinner and less glandular than in the fundus and body.

A variety of neuroendocrine cells involved with the secretion of gastric acid are interspersed between the glands. The predominant cells are enterochromaffin-like (ECL) and somatostatin-producing cells in the fundus; and gastrin- and somatostatin-producing cells in the antrum (Figure 19.1). Localized small aggregates of lymphoid tissues are observed at the base of the gastric glands. Intertwined between the gastric glands is a rich network of blood vessels, lymphatics and nerves. Beneath the submucosa are two layers of smooth muscle that run perpendicular to each other. The serosa is the outermost layer.

## Digestion and assimilation of nutrients

The stomach has a limited role in the digestion of protein, fat and micronutrients.



19.1

Functional anatomy of the stomach. Inset A = fundic mucosa; Inset B = pyloric mucosa showing gastrin-positive cells stained brown.

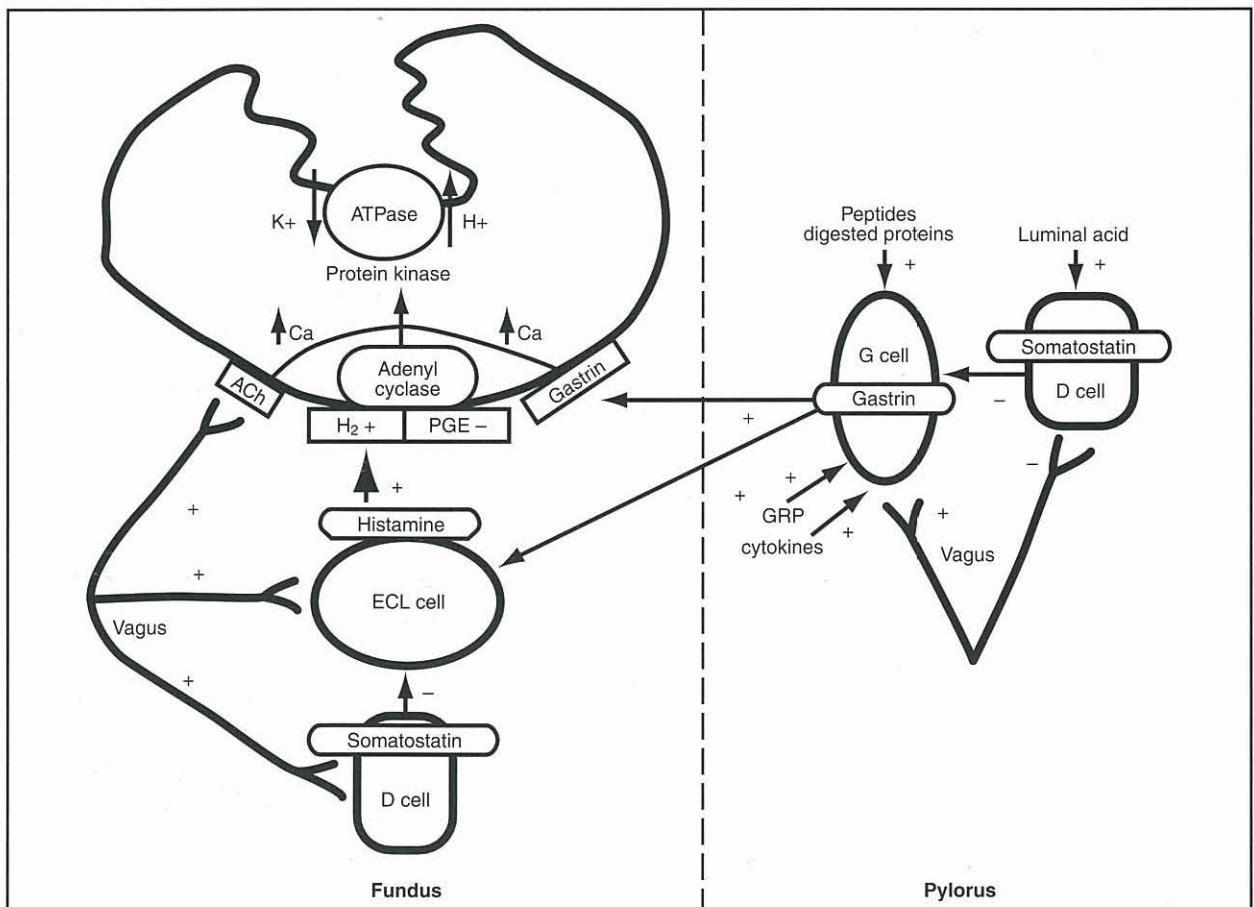


- Pepsin digests proteins and is secreted as pepsinogen in response to acetylcholine and histamine, in tandem with gastric acid.
- Canine gastric lipase digests fat and is secreted in response to pentagastrin, histamine, prostaglandin E<sub>2</sub> and secretin, and parallels the secretion of gastric mucus.
- Canine gastric lipase remains active in the small intestine and constitutes up to 30% of total lipase secreted.
- Gastric lipase and pepsin are not essential for the assimilation of dietary fat and protein, but the entry of peptides and fatty acids into the small intestine probably helps to coordinate gastric emptying and pancreatic secretion.
- Intrinsic factor, which is necessary for cobalamin (vitamin B12) absorption, is produced by parietal cells and cells at the base of antral glands in the dog, but not the cat. The importance of gastric intrinsic factor secretion in dogs is questionable as the pancreas is the major site of secretion (and the sole site in cats).
- Gastric acid aids the peptic digestion of proteins, increases the availability of minerals (such as iron and calcium), limits the proliferation of transient gastrointestinal (GI) microflora and stimulates pancreatic secretion.

### Regulation of acid secretion

Acid secretion is regulated by a variety of neurochemical and neurohumoral stimuli:

- Non-stimulated acid secretion in dogs and cats is minimal
- Luminal peptides, digested protein, acetylcholine and gastrin-releasing peptide (GRP) stimulate gastrin-secreting G cells and effect histamine release from ECL cells (Figure 19.2)
- Acetylcholine and gastrin, and histamine released from mast cells, can also directly stimulate parietal cells
- Stimulation results in a rapid increase in fluid and hydrogen ion secretion, with intra-gastric pH rapidly declining to around pH 1
- In the stimulated state H<sup>+</sup>:K<sup>+</sup>-adenosine triphosphatase (ATPase) and potassium chloride (KCl) transporters are incorporated into the parietal cell canalicular membrane and hydrogen ions are transported into the gastric lumen in exchange for potassium ions by the H<sup>+</sup>:K<sup>+</sup>-ATPase. KCl transporters enable luminal transfer of potassium and chloride. Hydroxyl ions (OH<sup>-</sup>) combine with CO<sub>2</sub>, catalysed by carbonic anhydrase, to form bicarbonate (HCO<sub>3</sub><sup>-</sup>), which then diffuses into the blood (this



**19.2** Regulation of acid secretion. ACh = acetylcholine receptor; ATPase = adenosine triphosphatase; ECL = enterochromaffin-like cell; GRP = gastrin-releasing peptide; H<sub>2</sub> = histamine H<sub>2</sub> receptor and PGE = prostaglandin E<sub>2</sub> receptor. (Reproduced from Simpson *et al.* (2000a); © Kenneth Simpson. With permission from the publishers)

is known as the postprandial 'alkaline tide'). The concentrations of  $K^+$  and  $Cl^-$  in gastric juice are higher than in plasma

- Somatostatin, released when gastric pH falls below 3, acts to decrease gastrin, histamine and acid secretion.

The stomach is protected from gastric acid by a functional unit known as the *gastric mucosal barrier* (GMB):

- Tightly opposed epithelial cells
- A coating of bicarbonate-rich mucus
- An abundant mucosal blood supply delivering bicarbonate, oxygen and nutrients
- Local production of prostaglandins ( $PGE_2$ ) modulating blood flow, bicarbonate secretion and epithelial cell renewal
- When damage occurs epithelial cells rapidly migrate over superficial mucosal defects aided by the local production of growth factors, such as epidermal growth factor (EGF).

### Gastric motility

Normal gastric motility is the result of the organized interaction of smooth muscle with neural and hormonal stimuli.

- The rate of gastric emptying is determined by the difference in pressure between the stomach and the duodenum, and the resistance to flow across the pylorus.
- Liquids are expelled more rapidly than solids and the rate of expulsion of liquids increases with volume.
- The rate of expulsion of solids depends on caloric density. In dogs, digestible solids <2 mm diameter are emptied into the duodenum, and gastric emptying is modulated via intestinal osmo- and chemoreceptors.
- Carbohydrates, amino acids and especially fats retard gastric emptying.
- Large, non-digestible solids are expelled from the stomach in the fasted state by phase III of the

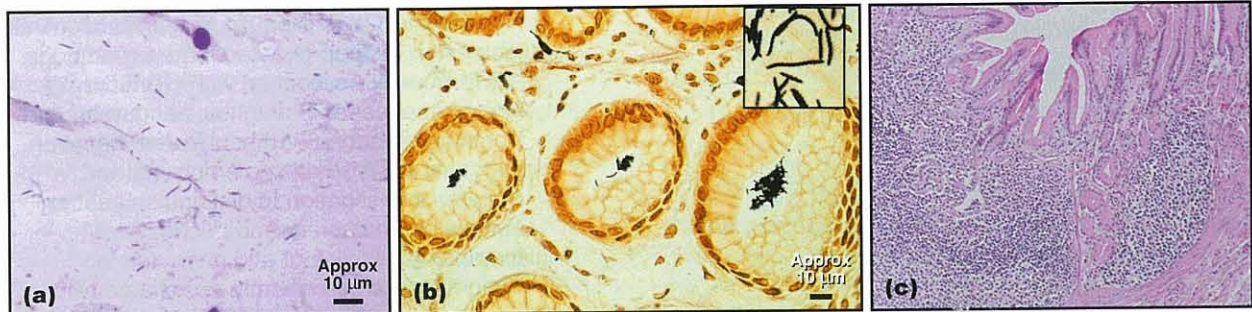
migrating myoelectric complex (MMC) in response to the release of motilin.

### Gastric flora

- The concept of the stomach as a sterile place was dispelled by the isolation of the bacterium *Helicobacter pylori* from humans in 1983. *Helicobacter* and a variety of other bacterial species may play a role in the development of gastritis and possibly cancer (see Chronic gastritis).
- The stomach of dogs and cats harbours a diverse spectrum of large, spiral, acid-tolerant, *Helicobacter* species (Figure 19.3). *Helicobacter* spp. produce urease that catalyses the formation of ammonia from urea to buffer gastric acidity.
- A mixed flora of aerobes and anaerobes (approximately  $10^6$ – $10^7$  colony forming units/ml) is rapidly established soon after birth in dogs, and colonization with *Helicobacter* spp., which are likely acquired from the dam, has been documented as early as 6 weeks of age.
- Bacterial species, such as *Proteus*, *Streptococcus* and *Lactobacillus*, may transiently increase after a meal or coprophagia.
- Acid secretion and gastric emptying probably regulate much of this transient flora, but bacteria may proliferate in the event of gastric acid hyposecretion due to glandular atrophy or pharmacological inhibition. Bacteria, such as *Escherichia coli* and *Proteus*, produce urease that can occasionally lead to a false-positive test result for *Helicobacter* spp.

### Diagnostic approach

Gastric disease is usually the result of inflammation, ulceration, neoplasia or obstruction, and manifests clinically as vomiting, haematemesis, melaena, retching, burping, hypersalivation, abdominal distension, abdominal pain or weight loss. The clinical approach is simplified by considering gastric diseases as a group of clinical syndromes based on the combination of aetiology, pathology and clinical presentation (Figure 19.4).



**19.3** *Helicobacter*-associated gastritis. *Helicobacter* infection is best diagnosed from impression smears or biopsy samples. (a) Numerous spiral organisms are visible in this Diff-Quik-stained impression smear of gastric juice. (b) Modified Steiner-stained, formalin-fixed, paraffin-embedded biopsy sample showing *Helicobacter* organisms stained dark blue. (c) Lymphoid follicle hyperplasia and lymphocytic gastritis in a cat with *H. felis*-associated gastritis (H&E stain). The significance of *Helicobacter* infection is based on the presence of histopathological changes on biopsy.

Clinical syndrome	Predominant features
Acute gastritis	Sudden-onset vomiting
Ulceration or erosion	Vomiting; haematemesis; melaena ± anaemia
Gastric dilatation/volvulus	Non-productive retching; abdominal distension; tachycardia
Chronic gastritis	Chronic vomiting of food or bile
Delayed gastric emptying	Acute to chronic vomiting >8–10 h after food
Neoplasia	Chronic vomiting; weight loss ± anaemia

**19.4** Diseases of the stomach.

**Clinical features**

Many non-gastric disorders can cause similar clinical signs, so a systematic approach is essential to determine whether gastric disease is the cause. The diagnostic approach initially focuses on historical and physical findings, with clinicopathological testing and diagnostic imaging employed in patients with systemic involvement or chronic signs.

The combination of clinical details, history and physical examination helps to discriminate many non-gastric from gastric causes of vomiting.

**Clinical details**

The age and breed of the patient are helpful in diagnosing certain gastric disorders (Figure 19.5).

Clinical detail	Disposition
Age	Young dogs are more likely to ingest foreign bodies or to suffer from outflow obstruction caused by pyloric stenosis or <i>Pythium insidiosum</i> Older dogs and cats are more likely to have gastric cancer than younger animals
Breed disposition: Gastric dilatation/volvulus Hypertrophic gastropathy Atrophic gastritis Gastric cancer	Giant breeds, dogs with deep chests (e.g. Great Dane and Irish Setter) Drentse Patrijshond; Basenji; smallbreed brachycephalic dogs (e.g. Shih Tzu) Norwegian Lundehund Belgian Shepherd Dog; Rough Collie; Staffordshire Bull Terrier; Beagle; Norwegian Lundehund; Chow Chow

**19.5** Clinical details that may suggest specific gastric diseases.

**History**

Vomiting is the principal clinical sign of gastric disease.

A detailed history helps to:

- Form a clear picture of the vomiting episodes: i.e. duration, frequency, contents, colour, progression, relation to eating
- Distinguish vomiting from regurgitation:
  - active abdominal effort; presence of bile

- where vomiting cannot be adequately distinguished from regurgitation, it is essential to observe ‘vomiting episodes’ and the animal eating. Thoracic radiographs help to detect and rule out oesophageal dilatation or obstruction
- the presence of fresh or digested blood (‘coffee grounds’) in vomitus, with or without melaena, is suggestive of gastric ulcers or erosions.
- Ascertain access to foreign bodies, toxins or medications and vaccination status
- Define the living conditions: e.g. indoor, outdoor, single or multi-animal household
- Screen other body systems: i.e. attitude, mentation, presence of polyuria/polydipsia, weight loss, diarrhoea, coughing, sneezing, exercise tolerance.

**Physical examination**

Physical examination is frequently normal in patients with primary gastric disease.

- Abdominal distension is a feature of gastric dilatation/volvulus (GD/GDV) or delayed gastric emptying.
- Abnormal perfusion, hydration status, temperature, respiratory rate, mucosal pallor and abdominal pain often accompany diseases, such as GD/GDV, gastric outflow obstruction, ulceration and perforation.

Historical and physical findings are integrated to determine whether the patient is systemically well or unwell, and if the clinical signs are acute (<10 days), chronic, mild or severe (see Figure 19.4 and Chapter 7).

- If vomiting is *acute and the animal is systemically well*, with no historical or physical ‘red flags’, further diagnostic testing is often postponed in favour of symptomatic therapy.
- If the animal is *systemically unwell*, or has significant historical or physical abnormalities, the emphasis is on efficiently identifying conditions that require surgical intervention and ruling out non-GI causes of vomiting, before proceeding to more specialized or invasive diagnostic procedures aimed at detecting primary gastric disorders (see Chapter 7).
  - Non-productive vomiting, retching and abdominal distension in deep-chested large-breed dogs are frequently associated with GD/GDV, which requires rapid diagnosis and treatment.
  - Vomiting of food >8–10 hours after ingestion suggests delayed gastric emptying, and requires investigation to distinguish gastric outflow obstruction from defective gastric propulsion.
  - Weight loss is infrequently associated with gastric disease but can accompany cancer, fungal infections, outflow obstruction and gastropathies that are part of a more generalized disease process, e.g. Basenji and Norwegian Lundehund gastroenteropathy.

**Clinicopathological testing**

Clinicopathological testing helps to differentiate primary GI disease from non-GI disease, and to ascertain the metabolic consequences of GI disease. Blood and urine samples should be obtained prior to treatment.

**Haematology:**

- Rapid evaluation of microhaematocrit (packed cell volume, PCV), total solids (TS) or total protein (TP), blood glucose, blood urea, urine specific gravity, glucose, ketones and protein, and plasma concentrations of sodium and potassium, help to detect life-threatening diseases, such as renal failure (azotaemia and unconcentrated urine) and hypoadrenocorticism (where Na<sup>+</sup>:K<sup>+</sup> is <27:1), and guide initial management pending more definitive testing.

Abnormalities in complete blood count (CBC) are infrequent with primary gastric disease, but the following abnormalities may be seen:

- Haemoconcentration frequently accompanies GDV, gastric perforation or gastric obstruction
- The combination of a haematocrit >55 l/l and a normal or decreased protein concentration is encountered in dogs with haemorrhagic gastroenteritis (see Chapter 20)
- Anaemia, erythrocyte microcytosis and thrombocytosis (signs of iron deficiency) may be present in dogs with chronic gastric bleeding
- Stomatocytosis has been described in Drentse Patrijshond dogs with familial stomatocytosis–hypertrophic gastritis
- Basophilic stippling of red cells suggests lead toxicity.

**Biochemistry:** Biochemical abnormalities in primary gastric disease are usually restricted to alterations in electrolyte and acid–base concentrations, pre-renal increases in creatinine and urea, and occasionally hypoproteinaemia. Vomiting of gastric and intestinal contents is variably accompanied by hypochloraemia, hypokalaemia and hyponatraemia.

Determination of acid–base status by measurement of total CO<sub>2</sub> or venous blood gas analysis enables the presence of metabolic acidosis or alkalosis to be detected.

- Metabolic acidosis is generally more common than metabolic alkalosis in dogs with GI disease.
- Where the gastric outflow tract or proximal duodenum is obstructed, the loss of chloride may exceed that of bicarbonate, resulting in hypochloraemia, hypokalaemia and metabolic alkalosis.
  - Metabolic alkalosis is enhanced by HCO<sub>3</sub><sup>-</sup> conservation due to volume, and potassium and chloride depletion.
  - The net effect is a preferential conservation of extracellular volume at the expense of the extracellular pH.
  - The renal reabsorption of almost all filtered bicarbonate, and the exchange of sodium for

hydrogen in the distal tubule, promotes an acid urine pH despite an extracellular alkalaemia ('paradoxical aciduria').

- Metabolic alkalosis is also encountered in dogs with parvovirus enteritis, acute pancreatitis and diseases characterized by acid hypersecretion, such as gastrinoma.
- Venous blood gases and plasma osmolality are often determined in animals suspected of ethylene glycol ingestion, with the findings of metabolic acidosis and a high osmolal gap (calculated by subtracting the measured osmolality from the calculated osmolality) supportive of ingestion.
- Elevated serum urea in the absence of elevated creatinine suggests GI bleeding.
- Hypoalbuminaemia may be detected in Basenjis or Norwegian Lundehunds with protein-losing gastroenteropathy, dogs with pythiosis, and dogs or cats with gastric neoplasia.
- Elevated globulin concentrations have been observed in Basenji gastroenteropathy, *Pythium* infection and gastric plasmacytoma.
- Elevations in creatinine, urea, calcium, potassium, glucose, liver enzymes, bilirubin, cholesterol, triglycerides and globulin, and decreases in sodium, calcium, urea or albumin, frequently herald non-GI causes of vomiting.

**Urinalysis:** Urine should be evaluated for specific gravity, pH, glucose, casts, crystals and bacteria. Thorough urinalysis is important, e.g. white cell casts in the urine may be the only evidence that pyelonephritis is the cause of vomiting and should not be overlooked.

**Coagulation testing:** Coagulation testing is indicated in patients with haematemesis or melaena to detect underlying coagulopathies, and in those patients with acute abdomen to detect disseminated intravascular coagulation (DIC). Infectious diseases associated with vomiting and diarrhoea require faecal examination (*Giardia*, endoparasites, *Salmonella*, *Campylobacter* and parvovirus (enzyme-linked immunosorbent assay, ELISA)) or serological testing for diagnosis (feline leukaemia virus, FeLV; feline immunodeficiency virus, FIV).

**Additional tests:** The additional clinicopathological tests that are required are listed in Figure 19.6.

Disorder	Clinicopathological test
Hypoadrenocorticism	Adrenocorticotrophic hormone stimulation test
Liver dysfunction	Pre- and postprandial bile acid
Hyperthyroidism in cats	Thyroxine (T4)
Pancreatitis	Amylase; lipase (pancreas-specific (PLI) where possible); trypsin-like immunoreactivity (TLI)
Intestinal disease	Serum cobalamin and folate; biopsy

19.6

Adjunctive laboratory tests for non-gastric causes of vomiting.

**Diagnostic imaging**

**Radiography:** Abdominal radiography is the test of choice for the initial evaluation of gastric disease, vomiting and abdominal pain. Survey radiographs provide information on gastric position and contents that help to diagnose GD/GDV, foreign bodies and gastric outflow obstruction. They also enable the evaluation of the size and shape of the liver, kidneys and spleen and detection of intussusception, peritonitis, pneumoperitoneum and changes suggestive of pancreatitis. Contrast radiography may provide further information when survey radiography is inconclusive (Figure 19.7).

The combination of ultrasonography and endoscopy is often more effective for detecting obstructive, inflammatory and neoplastic GI disorders than contrast radiography. Contrast studies are often restricted to the investigation of delayed gastric emptying associated with defective propulsion, or 'functional' intestinal disorders. However, when ultrasonography and endoscopy are not available, contrast radiography can be used.

- Distension of the stomach with air (negative contrast radiography) may reveal gastric thickening, masses or foreign bodies.

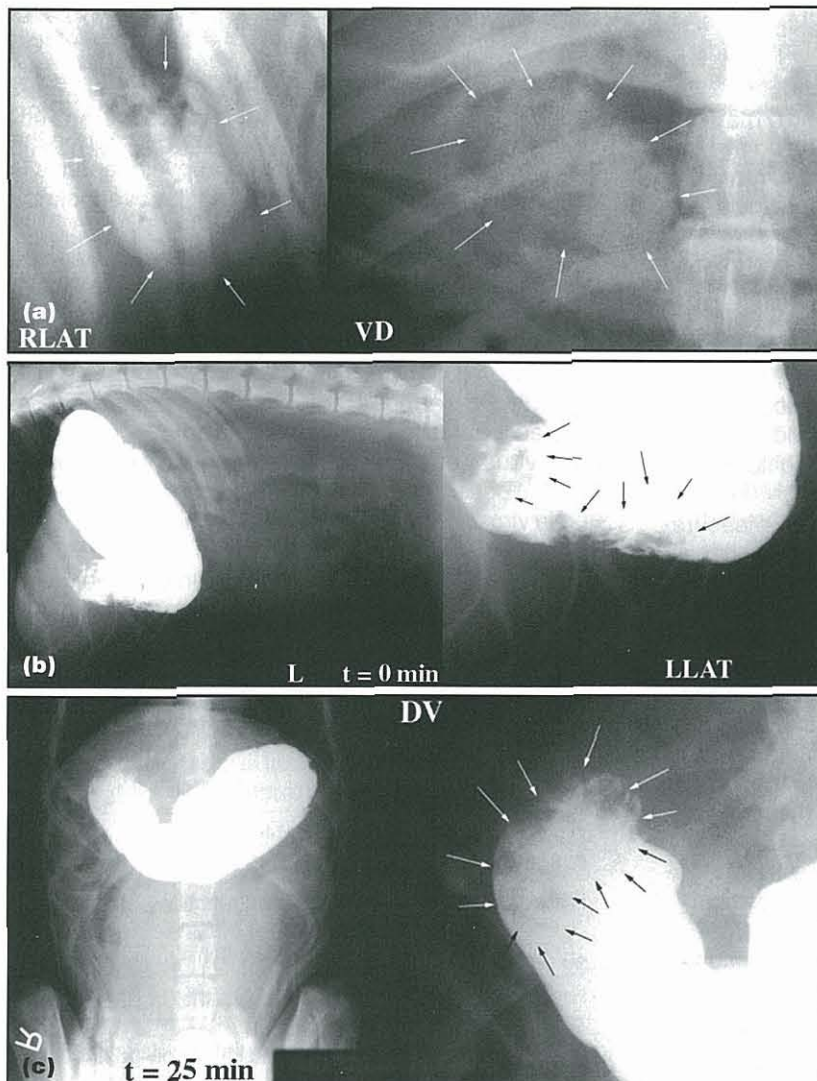
- Positive contrast radiography with barium sulphate media can provide further information, and is also used to evaluate patency of the gastric outflow tract (see Figure 19.7).
- The combination of fluoroscopy and positive contrast media is helpful for evaluating pyloric patency and gastric emptying.
- Contrast radiography can be followed up with surgical biopsy to achieve a definitive diagnosis.

**Ultrasonography:** Ultrasound examination (Figure 19.8) can be used to evaluate gastric wall structure and thickness, gastric contents and emptying, but is often hampered by GI gas. Its major value is often the detection of non-gastric lesions in animals with signs of GI disease.

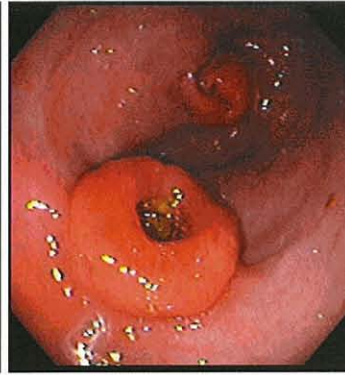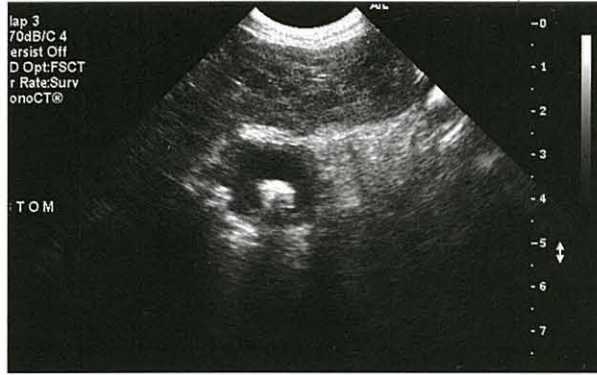For further information on diagnostic imaging see Chapter 3.

**Endoscopy**

- Enables direct visualization and biopsy of the stomach and duodenum, and is the best way of diagnosing primary gastric inflammation, ulceration or neoplasia (Figure 19.8), removing



**19.7** Contrast radiographic evaluation of a dog presented for investigation of chronic vomiting. (a) Survey radiographs show a soft tissue density in the antrum (arrowed). (b and c). Left lateral and ventrodorsal radiographs show retention of liquid barium contrast, revealing the presence of a mass in the pyloric outflow tract (arrowed).



**19.8** Imaging of the stomach with ultrasonography and endoscopy provides complementary information. The ultrasonogram shows a mass projecting into the lumen of the stomach of a dog presented for the investigation of vomiting and hyperglobulinaemia (IgA). Endoscopy confirmed the presence of a mass and enabled a biopsy diagnosis of gastric plasmacytoma.

- small foreign bodies, and evaluating patients prior to quantification of gastric emptying.
- Does not provide good information on submucosal lesions or functional diseases.
- Endoscopic biopsy samples are often too superficial to diagnose the cause of gastric masses or mural thickening and surgical biopsy may be required for accurate diagnosis.
- Further information on equipment and techniques can be found in Chapter 4.

**Evaluating gastric function**

**Gastric emptying**

Procedures used to evaluate delayed gastric emptying (Figure 9.9) include:

- Barium contrast media (liquid or mixed with food)
- Barium impregnated polyethylene spheres (BIPS)
- Nuclear scintigraphy
- <sup>13</sup>C-octanoate breath test
- Ultrasonography.

Tests of gastric emptying are used to confirm a suspicion of delayed gastric emptying in patients with normal or equivocal survey radiographs. They are also used where gastric outflow obstruction and obvious causes of defective propulsion have been ruled out prior to, and after, prokinetic drugs. The limitations and benefits of these approaches are discussed below.

Method	D/C	Test meal	Number of animals tested	Gastric half emptying time (t <sub>1/2</sub> ) <sup>a</sup>	Reference
Nuclear scintigraphy	Dog	Eggs, starch and glucose	27	66 min (median), 45–227 min (95% confidence interval)	Muir, 1982
		Beef baby food and kibble	6	4.9 ± 1.96 hours (mean ± standard deviation, SD)	Brockman <i>et al.</i> , 1995
		Liver	4	About 2 hours	Cryer, 2001
		Canned dog food and egg	6 (18 tests)	172 ± 17 min (mean ± standard error, SE)	Murtaugh <i>et al.</i> , 1993
		Canned dog food and egg	7 (14 tests)	285 ± 34 min (mean ± SD); 294 ± 39 min (mean ± SD)	Richter, 2003
		Canned dog food	6	77 min (mean)	Fox <i>et al.</i> , 1990
	Cat	Dry cat food	10	2.47 ± 0.71 hours (mean ± SD)	Guilford and Strombeck, 1996
		Liver and cream	6 (15 tests)	163 ± 11 min (mean ± SE)	Rossi <i>et al.</i> , 1999
		Canned cat food	20	2.69 ± 0.25 hours (mean ± SD)	Lloyd and Debas, 1994
		Dry cat food	20	3.86 ± 0.24 hours (mean ± SD)	Lloyd and Debas, 1994
		Eggs	10	330 min (median); 210–769 min (range)	Sachs, 1994
Radiography	Dog	Dry dog food and radio-opaque solids	10	3.5 hours (median); 1–6 hours (range)	Schiffirin and Blum, 2002
		Canned dog food and egg and barium impregnated polyethylene spheres (BIPS)	6 (18 tests)	Small BIPS: 416 ± 81 min (mean ± SE)	Murtaugh <i>et al.</i> , 1993
		Canned dog food and BIPS	20	Small BIPS: 6.05 ± 2.99 hours (mean ± SD) Large BIPS: 7.11 ± 3.60 hours (mean ± SD)	Lindholm <i>et al.</i> , 1998

**19.9** A review of methods for assessment of the rate of gastric emptying in the dog and cat: (data from Wyse *et al.*, 2003). <sup>a</sup> Gastric emptying rate is expressed as gastric half emptying time unless otherwise stated. (continues) ▶

Method	D/C	Test meal	Number of animals tested	Gastric half emptying time (t <sub>1/2</sub> ) <sup>a</sup>	Reference
Radiography <i>continued</i>	Dog	Kibble and BIPS	8	Small BIPS: 8.29 ± 1.62 hours (70% of dogs ± SE) Large BIPS: 29.21 ± 18.31 hours (70% of dogs ± SE)	Simpson <i>et al.</i> , 2000a
		Kibble and liquid barium	9 (27 tests)	Total gastric emptying time: 7–15 hours (range)	Simpson, 1999
		Kibble and liquid barium	4	Total gastric emptying time: 7.6 ± 1.98 hours (mean ± SE)	Simpson <i>et al.</i> , 2000b
	Cat	Canned cat food and BIPS	10	Small BIPS: 6.43 ± 2.59 hours (mean ± SD) Large BIPS: 7.49 ± 4.09 hours (mean ± SD)	Slappendel <i>et al.</i> , 1991
		Canned cat food and BIPS	6	Small BIPS: 7.7 hours (median), 3.5–10.9 hours (range) Large BIPS: 8.1 hours (median), 5–19.6 hours (range)	Soll and Berglindh, 1994
		Canned cat food and BIPS	10	Small BIPS: 5.36 hours (median) Large BIPS: 6.31 hours (median)	Sullivan <i>et al.</i> , 1987
		Cat food and liquid barium	8	Gastric emptying time: 11.6 ± 0.9 hours (mean ± SD)	van der Gaag, 1988
Gastric emptying breath test	Cat	Canned cat food	6	Peak <sup>13</sup> C-excretion: 56.7 ± 9.8 min (mean ± SD)	van der Gaag and Happe, 1989
	Dog	Bread, egg and margarine	6 (18 tests)	3.43 ± 0.50 hours (mean ± SD)	Mahony <i>et al.</i> , 1995

**19.9** (continued) A review of methods for assessment of the rate of gastric emptying in the dog and cat (data from Wyse *et al.*, 2003). <sup>a</sup> Gastric emptying rate is expressed as gastric half emptying time unless otherwise stated.

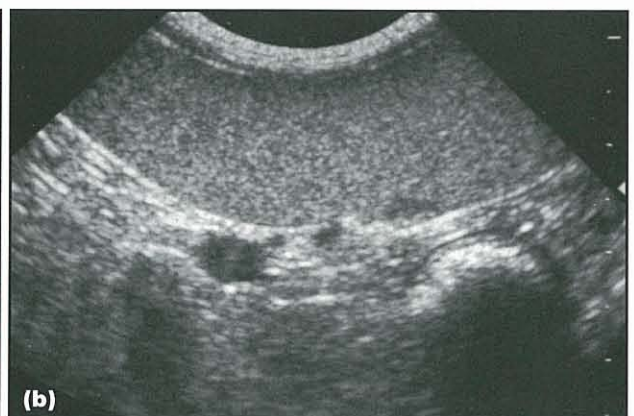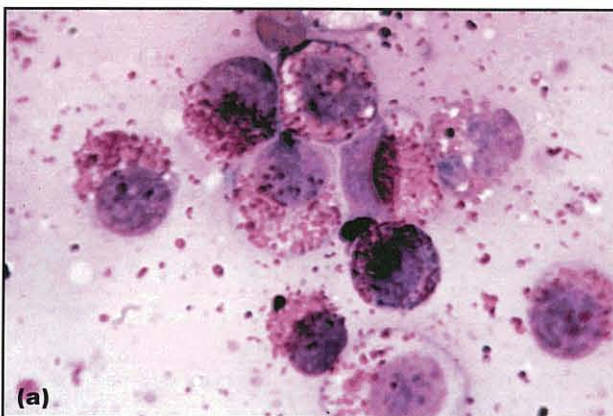
**Gastric secretory testing**

Gastric secretory testing is primarily performed in patients with oesophagitis, GI ulceration, mucosal hypertrophy or copious amounts of gastric fluid that are suspected of having acid hypersecretion (Figure 19.10).

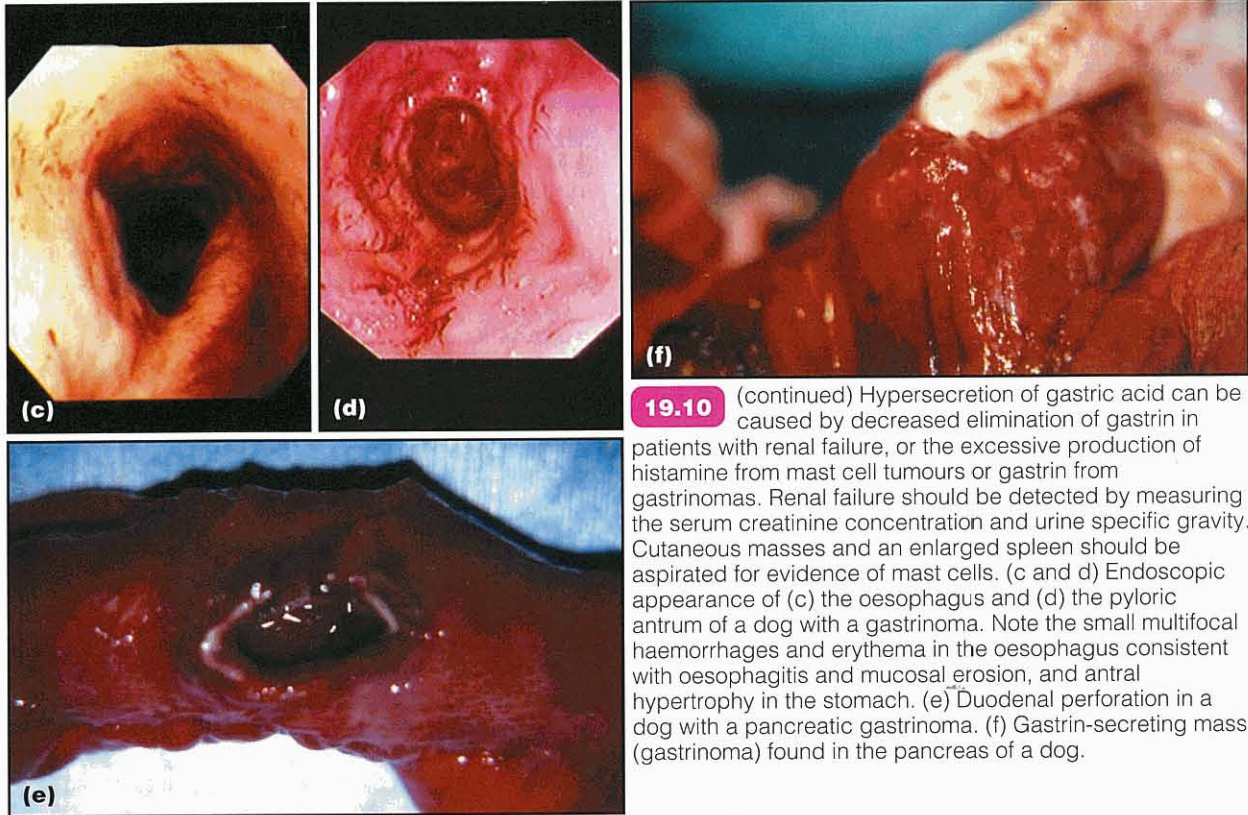
In its simplest form, fasting gastric pH and serum gastrin are measured to determine whether acid hypo- or hypersecretion is likely:

- Antisecretory therapy should be discontinued for 48 hours prior to testing

- Renal and hepatic dysfunction should be ruled out as these increase concentrations of circulating gastrin
- Fasting, non-stimulated gastric pH in dogs and cats ranges from pH 1–8
- The presence of a gastric pH (i.e. pH <3) in the face of a high serum gastrin concentration raises the possibility of a gastrinoma (see below)
- Dogs with mast cell tumours have low serum gastrin concentrations
- Dogs with achlorhydria probably have a high gastrin level but a gastric pH >3.



**19.10** Hypersecretion of gastric acid can be caused by decreased elimination of gastrin in patients with renal failure, or the excessive production of histamine from mast cell tumours or gastrin from gastrinomas. Renal failure should be detected by measuring the serum creatinine concentration and urine specific gravity. Cutaneous masses and an enlarged spleen should be aspirated for evidence of mast cells. (a) Fine needle aspirate of a cutaneous mass on a dog with vomiting associated with mastocytosis showing round cells containing cytoplasmic pink-stained granules. (b) Ultrasonographic detection of splenomegaly in a cat with chronic vomiting enabled fine needle aspiration and cytological diagnosis of mastocytosis. (continues)



**19.10** (continued) Hypersecretion of gastric acid can be caused by decreased elimination of gastrin in patients with renal failure, or the excessive production of histamine from mast cell tumours or gastrin from gastrinomas. Renal failure should be detected by measuring the serum creatinine concentration and urine specific gravity. Cutaneous masses and an enlarged spleen should be aspirated for evidence of mast cells. (c and d) Endoscopic appearance of (c) the oesophagus and (d) the pyloric antrum of a dog with a gastrinoma. Note the small multifocal haemorrhages and erythema in the oesophagus consistent with oesophagitis and mucosal erosion, and antral hypertrophy in the stomach. (e) Duodenal perforation in a dog with a pancreatic gastrinoma. (f) Gastrin-secreting mass (gastrinoma) found in the pancreas of a dog.

Measurement of serum gastrin following the intravenous infusion of secretin or calcium is used to further investigate the possibility of exogenous gastrin production by pancreatic tumours, termed 'gastrinomas' (Zollinger–Ellison syndrome). However, increased gastrin release in response to secretin stimulation has also been reported in Basenjis with gastroenteropathy and diarrhoea without evidence of gastrinoma. Provocative testing of gastric acid secretion with pentagastrin or bombesin stimulation may be performed to detect achlorhydria in patients with atrophic gastritis or elevated serum gastrin levels and gastric pH >3, and in those patients with idiopathic small intestinal bacterial overgrowth (SIBO or antibiotic-responsive diarrhoea), to determine whether achlorhydria is a contributing factor. Pentagastrin-stimulated acid secretion in dogs reaches a peak of 28 ml/kg<sup>0.75</sup>/h, equivalent to 4.1 mmol HCl/kg<sup>0.75</sup>/h, after 45 minutes. Sedation with oxymorphone and acepromazine maleate is an alternative to anaesthesia for secretion studies in dogs. In anaesthetized cats, acid output (mean ± standard deviation) in response to pentagastrin (8 µg/kg/h) ranges from pH 0.9–1.1, with secretion rates of 1.2 (0.6–2.7) mmol/ kg<sup>0.75</sup>/h after 45 minutes.

### Diseases of the stomach

#### Acute gastritis

Acute gastritis is the term applied to the syndrome of sudden-onset vomiting, presumed to be due to a gastric mucosal insult or inflammation (Figure 19.11).

Cause	Examples
Dietary indiscretion or intolerance (non-allergic and allergic)	Scavenging; garbage intoxication
Foreign bodies	Bones; toys; hairballs
Drugs and toxins	Non-steroidal anti-inflammatory drugs; corticosteroids; heavy metals; antibiotics; plants; cleaners; bleach
Systemic disease	Uraemia; liver disease; hypoadrenocorticism
Parasites	<i>Ollulanus</i> ; <i>Physaloptera</i>
Bacteria	Bacterial toxins; ? <i>Helicobacter</i>
?Virus	No known examples

**19.11** Causes of acute gastritis.

- In most patients the cause is inferred from the history, e.g. dietary indiscretion.
- A diagnosis is rarely confirmed by biopsy, and treatment is symptomatic and supportive.
- Animals with acute gastritis associated with drug toxicity, foreign body ingestion or metabolic disorders often present with haematemesis, melaena, concurrent diarrhoea or other signs of systemic illness, and need a more thorough diagnostic approach to determine the cause (as discussed above) and to provide optimal care.
- There is little evidence in the literature to support a role of viral infections, such as parvovirus, distemper or infectious canine hepatitis, in acute gastritis.



**Clinical signs**

Sudden-onset vomiting is the principal clinical sign. Haematemesis, melaena and systemic abnormalities may also be present. The patient history may reveal access to, or ingestion of, spoiled food, garbage, toxins, medications or foreign bodies. Signs of toxicity may be evident: e.g. jaundice and pallor with zinc ingestion; ptyalism or defecation with organophosphate toxicity; or hypersalivation and oral ulceration with chemical ingestion.

**Diagnosis**

A diagnosis of acute gastritis is usually based on clinical findings and the response to symptomatic treatment. A specific diagnosis may be sought if the patient:

- Has access to foreign objects or toxins
- Is systemically unwell
- Has haematemesis, melaena or vomiting that fails to respond to symptomatic therapy
- Other signs of more serious disease (see above).

Laboratory testing in most animals with primary acute gastritis is often not performed in the absence of a suspicion of more serious disease. Abdominal radiographs can be taken to detect foreign objects or GI obstruction. Further diagnostic imaging, such as ultrasonography and endoscopy, is rarely indicated as most animals with simple gastritis respond to symptomatic therapy.

**Treatment**

Therapy for uncomplicated acute gastritis is symptomatic and supportive, and includes fluid therapy, dietary restriction and modification, mucosal protectants or adsorbents, and possibly antacids.

**Fluid therapy:** Small amounts of oral fluids, given little and often, can be administered in the face of vomiting, with the volume of fluid increasing as the vomiting subsides. Subcutaneous administration of an isotonic balanced electrolyte solution may be sufficient to correct mild fluid deficits (<5%), but is insufficient for patients with moderate to severe dehydration. Patients requiring intravenous fluids should undergo a more extensive diagnostic evaluation.

**Dietary restriction and modification:** Where vomiting is acute, oral intake should be discontinued for at least 24 hours. Small amounts of a liquid diet can be offered in the face of vomiting to maintain GI barrier function and to determine whether vomiting has resolved. A bland diet (non-spicy, fat-restricted) either homemade (e.g. boiled chicken and rice, low fat cottage cheese and rice; given in a 1:3 ratio) or commercial (usually fat-restricted and rice-based) is then introduced (fed little and often) with a gradual transition back to a normal diet over a week or so.

**Protectants and adsorbents:** Bismuth subsalicylate, kaolin-pectin and sucralfate are often employed in acute vomiting or diarrhoea to coat the GI mucosa and to bind bacteria and their toxins (see Chapter 28).

These agents are probably safer and more efficacious than antibiotics or motility modifiers in acute gastroenteritis. Acid-reducing drugs, such as H<sub>2</sub> receptor antagonists, can be administered but are usually reserved for patients with signs of gastric erosion or ulceration (i.e. melaena and haematemesis), or persistent gastritis as described below. The author generally avoids anti-emetics in patients with acute gastritis to enable response to therapy to be ascertained. Patients who continue to vomit require further investigation.

**Prognosis**

The prognosis for uncomplicated acute gastritis is usually complete recovery.

**Gastric erosion and ulceration**

Gastric erosions and ulcers are associated with a number of primary gastric and non-gastric disorders (Figure 19.12).

Type of disease	Examples
Drug-induced	Non-steroidal and steroidal anti-inflammatory drugs
Hypotension	Shock; sepsis
Idiopathic	Stress; spinal surgery; exercise-induced (e.g. sled dogs)
Inflammatory	Gastritis
Metabolic/endocrine	Hypoadrenocorticism; uraemia; liver disease; mastocytosis; disseminated intravascular coagulation; hypergastrinaemia and other APUDomas
Neoplastic	Leiomyoma; adenocarcinoma; lymphosarcoma

**19.12** Diseases associated with gastric ulceration and erosion.

**Clinical signs**

Clinical signs range in duration and severity, from acute to chronic and from mild to life-threatening.

Vomiting, haematemesis and melaena may be present in patients with gastric erosions or ulcers. Pale mucous membranes, abdominal pain, weakness, inappetence, hypersalivation (potentially associated with oesophagitis as a consequence of gastric acid hypersecretion) and evidence of circulatory compromise are more variably present. Access to toxins and drugs, particularly non-steroidal anti-inflammatory drugs (NSAIDs), should be determined.

**Pathogenesis**

Gastric damage can be broadly attributed to impairment of the GMB (defined above) through direct injury, interference with gastroprotective prostaglandins (PGE<sub>2</sub>), mucus or bicarbonate, decreased blood flow and hypersecretion, or gastric acid.

NSAIDs cause direct mucosal damage and interfere with prostaglandin synthesis (see Figure 19.12). Flunixin meglumine, aspirin and ibuprofen have all been associated with erosions in healthy dogs. The

combination of an NSAID and a glucocorticoid, either alone or in combination with intervertebral disc disease, is a recipe for GI ulceration. Drugs that preferentially block 'inducible' cyclooxygenase (COX-2), sparing COX-1 and 'friendly prostaglandins' like PGE<sub>2</sub>, such as carprofen, meloxicam, deracoxib and potentially etodolac, are less ulcerogenic in normal dogs. However, even COX-2 selective drugs, such as meloxicam, are ulcerogenic in combination with dexamethasone and their safety in sick animals remains to be determined. High doses of glucocorticoids alone, e.g. dexamethasone and (methyl)prednisolone, have also been associated with gastric erosions but the mechanisms by which they induce damage are not clear. Their effects are not ameliorated by PGE<sub>2</sub> analogues, such as misoprostol.

Hypersecretion of gastric acid in response to histamine release from mast cell tumours, and gastrin from gastrinomas has been clearly implicated as a cause of gastroduodenal ulceration and oesophagitis in dogs and cats (see Figure 19.10). Renal failure, hepatic failure, hypoadrenocorticism and hypotension are frequently proposed as risk factors for gastric erosion or ulceration, though there are few published details on the pathogenesis, frequency or severity of gastric damage in these conditions. Racing sled dogs, like human and equine athletes, are prone to develop gastric erosions and ulcers; the pathogenesis is not understood but they are responsive to acid suppression. Erosions and ulcers are also sequelae of gastric cancer and gastritis, which are discussed elsewhere in this chapter.

### Diagnosis

Clinicopathological testing is directed at identifying diseases associated with gastric erosions and ulcers (see Figure 19.12) and the consequences of erosion and ulceration.

**Haematology:** This may reveal anaemia, which is initially regenerative, but can progress to become microcytic, hypochromic and minimally regenerative. When accompanied by thrombocytosis and decreased iron saturation or low serum ferritin, these findings are characteristic of chronic bleeding and iron deficiency.

Lack of a stress leucogram, and lymphocytosis or eosinophilia, in dogs is supportive of hypoadrenocorticism. Eosinophilia could also be consistent with dietary allergy, eosinophilic gastroenteritis, mastocytosis or a hypereosinophilic syndrome. Examination of a buffy coat smear may help to detect mastocytosis. A neutrophilic leucocytosis and a left shift may indicate inflammation or possible gastric perforation.

### Biochemistry and urinalysis:

- Reveals dehydration (azotaemia and hypersthenuria), renal failure (e.g. azotaemia and isosthenuria), hepatic disease (e.g. increased liver enzymes or bilirubin; decreased cholesterol, albumin, urea) and hypoadrenocorticism (i.e. Na<sup>+</sup>:K<sup>+</sup> ratio <27:1).
- Identifies electrolyte and acid-base abnormalities associated with vomiting and GI ulceration. The

presence of a metabolic alkalosis, hypochloraemia, hypokalaemia and acid urine is consistent with upper GI obstruction (physical or functional) or a hypersecretory state.

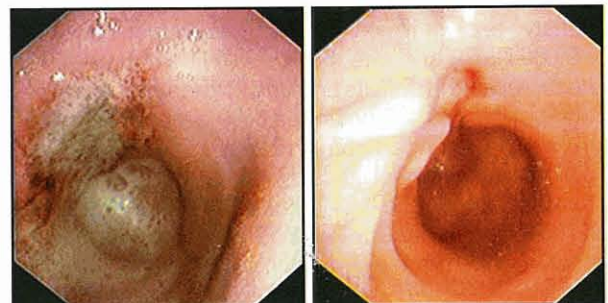
- Should be performed to detect abnormalities in primary and secondary haemostasis that may be associated with GI bleeding.
- Can evaluate serum gastrin, and potentially histamine, concentrations where acid hypersecretion is suspected as a cause of ulceration. Dogs with mast cell tumours and hyperhistaminaemia-induced acid hypersecretion have low serum gastrin concentrations. The combination of gastric pH <3 and a high serum gastrin concentration prompts further investigation of gastrinoma by secretin stimulation test, ultrasonography (liver and pancreas) and pentoctreotide scintigraphy.

**Diagnostic imaging:** Plain radiography is not usually helpful in diagnosing gastric erosions or ulcers but may help to rule out other causes of vomiting, e.g. foreign bodies, peritonitis and gastric perforation. Contrast radiography may reveal filling defects but does not allow detailed mucosal evaluation or sampling.

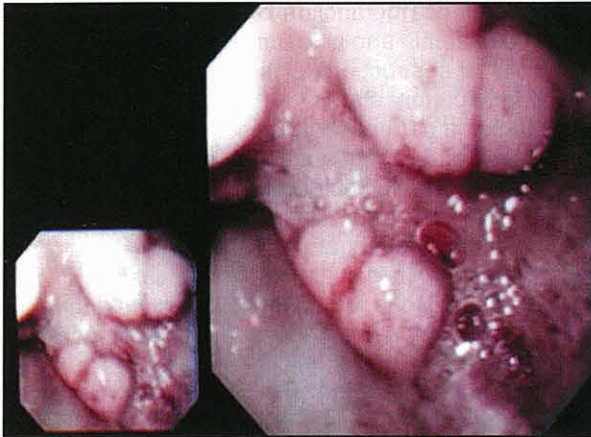
Ultrasonography helps detect gastric thickening associated with ulcers and masses, and also helps to rule out non-gastric causes of vomiting. Splenomegaly may be evident in patients with systemic mastocytosis or lymphoma (see Figure 19.9). The information provided by radiography and ultrasonography is complementary to endoscopic evaluation, which is the diagnostic test of choice.

Endoscopy allows the direct evaluation of gastric damage and mucosal sampling.

- NSAID-associated ulcers are often found in the antrum and are not usually associated with marked mucosal thickening or irregular edges (Figures 19.13 and 19.14).
- Ulcerated tumours frequently have thickened edges and surrounding mucosa.
- Biopsy samples should be taken at the periphery of ulcers to avoid perforation.
- Endoscopic biopsy is not ideal for diagnosing infiltrative gastric tumours, and several samples from the same site are usually taken to enable sampling of deeper tissue.



**19.13** Gastric ulceration caused by ibuprofen before and after 1 week's treatment with cimetidine and sucralfate.



**19.14** Gastric ulceration associated with a gastric carcinoma. Note the mucosal thickening surrounding the ulcer compared with the NSAID-induced ulcer in Figure 19.13.

- Endoscopic-guided fine needle aspiration, using a sheathed needle through the biopsy channel, can also be used to sample deep lesions. Even with this approach the diagnosis may be missed, and surgical biopsy required for a definitive diagnosis.

The combination of mucosal erosion or ulceration, antral mucosal hypertrophy, copious gastric juice, and oesophagitis is highly suggestive of a gastric hypersecretory state (see Figure 19.10).

#### Treatment

Treatment of gastric erosions and ulcers is directed at the underlying cause, ensuring adequate hydration and perfusion, including blood transfusion if needed, and restoring electrolyte and acid–base disturbances. Additional support is directed at shoring up the gastric mucosal barrier by enhancing mucosal protection and cytoprotection, and decreasing gastric acid secretion. Where vomiting is persistent, anti-emetics may help to reduce fluid loss, discomfort and the risk of oesophagitis.

Where acid hypersecretion is present, or is suspected at endoscopy, it is probably best managed with proton pump inhibitors (e.g. omeprazole).

**Fluid therapy:** The rate of fluid administration depends on the presence or absence of shock, the degree of dehydration and the presence of diseases, e.g. cardiac or renal, which predispose to volume overload. Mildly dehydrated patients are usually responsive to crystalloids (e.g. lactated Ringer's solution or 0.9% NaCl) at a rate that will provide maintenance and replace both deficits and ongoing losses over a 24-hour period. Potassium depletion is often a consequence of prolonged vomiting or anorexia, and most polyionic replacement fluids contain only small amounts of potassium, hence KCl is added to parenteral fluids on the basis of serum levels. Patients with signs of shock require more aggressive support.

- The volume deficit can be replaced with crystalloids at an initial rate of 60–90 ml/kg/h, then tailored to maintain tissue perfusion and hydration.

- Colloid solutions (e.g. Hetastarch, Haemaccel) at 10–20 ml/kg i.v. over 4–6 hours can be used to reduce the amount of crystalloid required. Plasma, colloids, packed cells or whole blood are occasionally required to treat severe hypoproteinaemia or anaemia, which can develop in vomiting animals with severe ulceration or haemorrhagic gastroenteritis (HGE).

Central venous pressure monitoring and evaluation of urinary output are necessary in patients with severe GI disease, particularly those complicated by third space losses of fluid into the gut or peritoneal cavity.

**Correction of acid–base imbalances:** The effect of vomiting on acid–base balance is hard to predict, and therapeutic intervention to correct imbalances should be based on blood gas determination. Where severe metabolic acidosis is present (i.e. pH <7.1;  $\text{HCO}_3^-$  <10 mmol/l) sodium bicarbonate (1 mmol/kg) can be given with careful monitoring for the development of worsening hypokalaemia, hypocalcaemia and cerebrospinal fluid (CSF) acidosis. Further bicarbonate supplementation is based on repeated blood gas analysis. Metabolic alkalosis usually responds to replacing volume deficit, chloride and potassium with intravenous 0.9% NaCl plus KCl. Diagnostic investigations should initially centre on ruling out upper GI obstruction. The administration of antisecretory drugs, such as  $\text{H}_2$  antagonists, may help to limit chloride efflux into the gastric juice.

Acid secretion (see Figure 19.2) can be blocked by antagonists of  $\text{H}_2$  (cimetidine, ranitidine, famotidine), gastrin (proglumide) and acetylcholine (atropine, pirenzepine) receptors, and drugs that inhibit adenylyl cyclase (PGE analogues) and  $\text{H}^+:\text{K}^+$ -ATPase (omeprazole). Long-acting somatostatin analogues, such as octreotide, directly decrease the secretion of gastrin and gastric acid.

$\text{H}_2$  receptor antagonists promote mucosal healing in dogs with a variety of experimentally induced ulcers and erosions (see Figure 19.13). Famotidine is an attractive choice as it does not inhibit P450 enzymes and can be given once daily. The additional prokinetic activity of ranitidine or nizatidine (mediated by anti-cholinesterase activity) may make them good choices if there is delayed gastric emptying associated with defective propulsion.

$\text{H}^+:\text{K}^+$ -ATPase inhibitors, such as omeprazole, are used for gastric ulceration that is refractory to  $\text{H}_2$  antagonists and are the initial choice in patients with acid hypersecretion secondary to mast cell tumours and gastrinoma (Zollinger–Ellison syndrome). Omeprazole has been shown to have few long-term side-effects in dogs. It should be used with caution in patients with liver disease and reviewed for interactions with drugs, such as cisapride. Omeprazole reduced exercise-associated gastric haemorrhage in sled dogs, but was associated with increased frequency of diarrhoea (omeprazole 54%, placebo 21%). The authors suggest further investigation of diarrhoea associated with omeprazole treatment before omeprazole can be recommended for routine prophylactic treatment in these animals.

Somatostatin analogues, such as octreotide, can be used to rapidly decrease gastric acid secretion in patients discovered to have large ulcers at endoscopy, and may also help to control gastric bleeding. The combination of the long-acting somatostatin analogue octreotide, and omeprazole, effectively reduced vomiting in a dog with gastrinoma.

**Mucosal protectants:** The PGE<sub>2</sub> analogue, misoprostol, protects against NSAID-induced erosions in dogs at doses that do not inhibit acid secretion, and may be given to dogs receiving chronic NSAIDs for arthritis. The main side-effects of misoprostol are diarrhoea and abortion. It *must not* be given to pregnant animals.

The mucosal protectant polyaluminium sucrose sulphate (sucralfate) binds to areas denuded of mucosal epithelium regardless of the underlying cause and is useful for treating gastric erosions and ulcers, and oesophagitis. Sucralfate can be given to patients receiving injectable antacids but it may compromise absorption of other oral medications, and thus is probably best given 2 hours after the acid blockers.

**Prophylaxis:** In contrast to the efficacy of misoprostol and H<sub>2</sub> antagonists in preventing NSAID-induced erosions, prophylactic administration of various combinations of misoprostol, cimetidine and omeprazole has not been shown to prevent gastric erosions in dogs, with or without intervertebral disc disease, receiving high-dose glucocorticoids. However, these drugs may speed healing of gastric lesions in these patients. Sucralfate is probably the drug of choice for treating GI ulceration in patients receiving high doses of corticosteroids as it is not dependent on the premise that acid is causing or delaying healing.

**Anti-emetics:** These drugs can be used where vomiting is severe, compromising fluid and electrolyte balance or causing discomfort. The initial agent used in dogs is usually metoclopramide, which antagonizes D<sub>2</sub>-dopaminergic and 5HT<sub>3</sub>-serotonergic receptors, and has cholinergic effects on smooth muscle. Phenothiazine derivatives, such as chlorpromazine and prochlorperazine, are antagonists of  $\alpha_1$ - and  $\alpha_2$ -adrennergic, H<sub>1</sub>- and H<sub>2</sub>-histaminergic, and D<sub>2</sub>-dopaminergic receptors in the vomiting centre and chemoreceptor trigger zone (CRTZ), and are used if metoclopramide is ineffective and the patient is normotensive. Non-selective cholinergic receptor antagonists (other than the M<sub>1</sub> specific antagonist, pirenzepine) such as atropine, scopolamine, aminopentamide and isopropamide are best avoided as they may cause ileus, delayed gastric emptying and dry mouth.

**Antibiotics and analgesia:** Prophylactic antibiotic cover (e.g. cephalosporins, ampicillin) may be warranted in animals with shock and major GI barrier dysfunction. Leucopenia, neutrophilia, fever and bloody stools are additional indications for prophylactic antibiotics in animals with vomiting or diarrhoea. Initial choices include ampicillin or a cephalosporin (effective against Gram-positive and some Gram-negative and anaerobic bacteria) which can be combined with an

aminoglycoside (effective against Gram-negative aerobes) when sepsis is present and hydration status is adequate. Enrofloxacin is a suitable alternative to an aminoglycoside in skeletally mature patients at risk of nephrotoxicity from an aminoglycoside. Analgesia can be initially provided using opioids, such as buprenorphine and can be stepped up with complete agonists, such as pethidine or fentanyl.

**Surgery:** Surgical management may be required when the cause of ulceration is unclear, or to resect large non-healing ulcers or those about to perforate.

### Prognosis

Prognosis depends on the cause of the ulcer.

### Gastric dilatation and volvulus

GD and GDV are characterized by the dramatic distension of the stomach with air. With volvulus the stomach twists about its axis moving dorsally and left of the fundus. Both GD and GDV cause caudal vena cava obstruction and impair venous return to the heart. This results in hypovolaemic shock that can be exacerbated by devitalization of the gastric wall, splenic torsion or avulsion, congestion of the abdominal viscera, endotoxic shock and DIC.

### Clinical signs

Non-productive retching, salivation, abdominal distention, weakness or collapse raise the possibility of GD or GDV, particularly in large-breed and deep-chested dogs. Usually abdominal distension and tympany, tachycardia and mucosal pallor are present. Hypothermia, depression and coma may be seen when shock is severe. Cardiac arrhythmias, such as ventricular premature beats or ventricular tachycardia, may be detected on the initial examination or develop up to 72 hours after presentation.

### Pathogenesis

No single cause of GD or GDV has been identified. Large-breed dogs with deep chests, such as Akitas, Bloodhounds, Collies, Great Danes, Irish Setters, Irish Wolfhounds, Newfoundlands, Rottweilers, Saint Bernards, Standard Poodles and Weimaraners are at greater risk. Cumulative incidence of GDV has been estimated at 6% for large-breed and giant-breed dogs. The lifetime risk is influenced by breed, ranging from 3.9% for Rottweilers to 39% for Great Danes. In large breed and giant dogs factors significantly associated with an increased risk of GDV include increasing age, having a first-degree relative with a history of GDV, having a faster speed of eating, once-daily feeding and having a raised feeding bowl and aerophagia. The personality of the dogs may also have an impact, with happier dogs having a decreased incidence.

Analysis of gastric gas supports aerophagia as the cause of distension, with dilatation explained by an inability to eructate or empty air into the intestines. Dogs with GDV recovering from gastropexy have abnormal electrical activity and gastric emptying that may be related to the development of gastric dilatation. The

interrelationship of volvulus and gastric distension is unclear but the length of the hepatogastric ligament may facilitate torsion.

**Diagnosis**

**Haematology and biochemistry:** Haematological changes are often restricted to an increase in haematocrit. A variety of acid–base and electrolyte disturbances have been observed in dogs with GDV:

- Metabolic acidosis and hypokalaemia are the most common abnormalities. Metabolic acidosis is likely due to tissue hypoperfusion, anaerobic metabolism and the accumulation of lactic acid
- Metabolic alkalosis may also occur and may be related to the sequestration of gastric acid
- Respiratory acidosis and alkalosis have been variably observed and reflect hypoventilation or hyperventilation, respectively.

The variable nature of acid–base and electrolyte abnormalities in dogs with GDV indicates that fluid therapy should be individualized on the basis of blood gas and electrolyte measurements. It is important to monitor and correct acid–base abnormalities as they may predispose to cardiac arrhythmias and muscle weakness.

Coagulation abnormalities are usually consistent with DIC (thrombocytopenia, increased D-dimer or fibrin degradation products (FDPs), reduced anti-thrombin III (ATIII) or prolongation of the activated partial thromboplastin time (aPTT)).

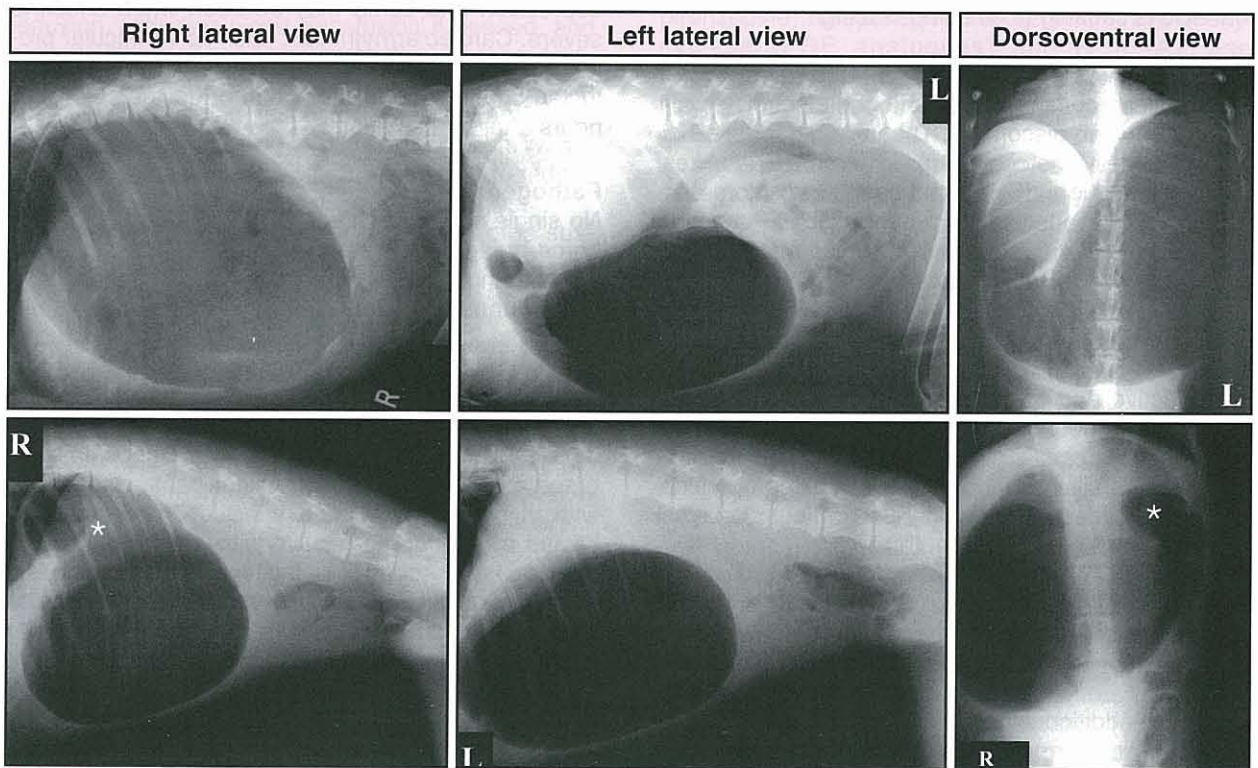
**Diagnostic imaging:** Radiography is usually performed after fluid support and decompression, and helps to distinguish simple dilatation, from dilatation and volvulus. Right and left lateral recumbent views are taken. Dilatation is associated with gas distension, and on a right lateral position air is present in the fundus (Figure 19.15).

With volvulus the pylorus moves dorsally and left, and the stomach is compartmentalized. On a right lateral radiograph the fundus is viewed as a large ventral compartment with the smaller gas-filled pylorus located dorsally and separated from the fundus by a band of soft tissue, forming the ‘Popeye’s arm’ sign (Figure 19.15). Loss of abdominal contrast may indicate peritonitis or bleeding from avulsed splenic vessels. Increased contrast prompts consideration of pneumoperitoneum and gastric rupture.

**Treatment**

Fluid support and gastric decompression are the most important emergency treatments.

**Fluid therapy:** Shock doses of lactated Ringer’s solution (60–90 ml/kg/h) may be given via large bore catheters into the cephalic or jugular veins. Experimental studies that have compared crystalloids (60 ml/kg, followed by 0.9% NaCl at 20 ml/kg/h) with hypertonic saline (7% NaCl in 6% dextran at 5 ml/kg single dose, followed by 0.9% NaCl at 20 ml/kg/h) in dogs with GDV-induced shock, indicate that hypertonic saline maintains better myocardial performance, higher heart rate and lower systemic vascular resistance than the crystalloid. The resuscitative dose of hypertonic saline was delivered in 5–10 minutes *versus* an hour for crystalloids.



**19.15** Radiographic diagnosis of gastric dilatation (top row), and dilatation and volvulus (bottom row). Right and left lateral, and dorsoventral radiographs showing gastric compartmentalization with the pylorus (\*) separated from the fundus by a soft tissue density in the lower row.

Fluid therapy should be aggressively monitored by frequent measurement of blood pressure, heart rate, PCV and total solids, and urine output. Hypokalaemia is common after fluid therapy and 30–40 mmol KCl/l should be added to fluids after the initial shock dose. Potassium and bicarbonate are best administered on the basis of blood gas and electrolyte measurements.

**Gastric decompression:** Decompression can be performed by orogastric intubation with a well lubricated stomach tube, or a 16 gauge catheter can be used to trocharize the stomach. Oral decompression can also be performed after trocharization. Decompression should be maintained until surgery. Sedation with butorphanol or oxymorphone and diazepam may be necessary to pass a stomach tube.

**Adjunct therapy for endotoxic shock and reperfusion injury:** Adjunct therapy frequently includes:

- Prednisolone sodium succinate (10 mg/kg i.v.) or dexamethasone sodium phosphate (10 mg/kg i.v.) for shock
- Broad spectrum antibiotics, such as a cephalosporin in combination with a fluoroquinolone, to circumvent bacterial translocation and endotoxaemia
- Some clinicians advocate flunixin meglumine for endotoxic shock, but the author does not because it may damage the GI mucosa and kidneys, especially if the patient is hypovolaemic
- The administration of agents to decrease lipid peroxidation (U70046F) and chelate iron (desferoxamine) has decreased mortality attributed to reperfusion injury in dogs with experimental GDV. These agents are best given before reperfusion occurs, i.e. prior to untwisting a torsion.

Specific treatment for cardiac arrhythmias may be indicated because ventricular premature complexes and ventricular tachycardia are present in approximately 40% of patients and may have an impact on mortality. The arrhythmias can develop up to 72 hours after presentation and are considered a consequence of electrolyte, acid–base and haemostatic abnormalities, and reperfusion injury. Indications for specific treatment are arrhythmias associated with weakness or syncope, persistent ventricular tachycardia at a rate of >150, or runs of tachycardia showing R on T complexes. The arrhythmias are managed by correcting underlying acid–base, electrolyte (especially K<sup>+</sup>, Ca<sup>2+</sup>, Mg<sup>2+</sup>) and haemostatic disturbances, and administering lidocaine either as a bolus or continuously. Procainamide is used where arrhythmias are persistent.

**Surgery:** The aims of surgery are to reposition the stomach and spleen, and to perform a gastropexy to enable short-term decompression and prevent recurrence. Surgery can be complicated by the presence of gastric necrosis, which requires partial gastrectomy,

and avulsion or torsion of the spleen that may require resection or removal (see *BSAVA Manual of Canine and Feline Abdominal Surgery*).

**Prophylaxis:** The recurrence rate of GD/GDV has been estimated at 11% over 3 years in one study, with median survival of 547 *versus* 188 days for dogs with a gastropexy compared to those without. Prophylactic gastropexy in Great Danes, Irish Setters, Rottweilers, Standard Poodles and Weimaraners reduced mortality by 2.2-fold in Rottweilers and 29.6-fold in Great Danes.

### Prognosis

Mortality rates for dogs with simple GDV are approximately 15%. Dogs with gastric necrosis, gastric resection or splenectomy have a higher mortality rate (>30%). The presence of gastric necrosis can be predicted by measuring plasma lactate concentration; a concentration >6 mmol/l yields a specificity of 88% and a sensitivity of 66% for necrosis.

### Chronic gastritis

Gastritis is a common finding in dogs, with 35% of dogs investigated for chronic vomiting and 26–48% of asymptomatic dogs affected. The prevalence in cats has not been determined. The diagnosis of chronic gastritis is based on the histological examination of gastric biopsy samples and it is usually sub-classified according to histopathological changes and aetiology.

### Histopathological features

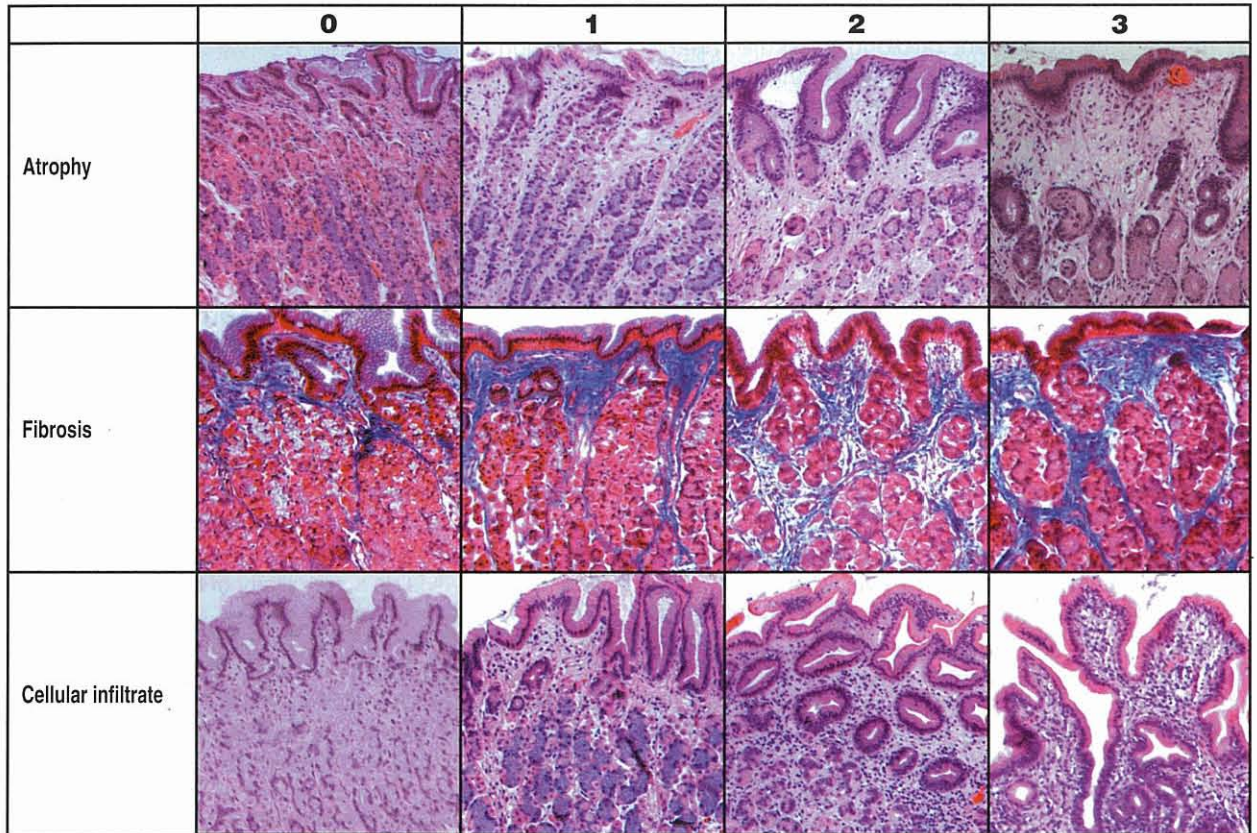
Gastritis in dogs and cats is usually classified according to:

- The predominant cellular infiltrate (eosinophilic, lymphocytic, plasmacytic, granulomatous, lymphoid follicular)
- The presence of architectural abnormalities (atrophy, hypertrophy, fibrosis, oedema, ulceration, metaplasia)
- Its subjective severity (mild, moderate, severe).

A standardized visual grading scheme was proposed by Happonen *et al.* (1998) and has been adapted for pathologists (Figure 19.16). The most common form of gastritis in dogs and cats is mild to moderate superficial lymphoplasmacytic gastritis with concomitant lymphoid follicle hyperplasia (see Figure 19.3).

### Aetiology

Despite the high prevalence of gastritis an underlying cause is rarely identified. Thus, in the absence of systemic disease, ulcerogenic or irritant drugs, gastric foreign objects, parasites (*Physaloptera*, *Ollulanus*) or, in rare instances, fungal infections (*Pythium insidiosum*, *Histoplasma*), gastritis is usually attributed to dietary allergy or intolerance, occult parasitism, or a reaction to bacterial antigens or unknown pathogens. Treatment is often empirical but can serve to define the cause of gastritis, e.g. diet-responsive, antibiotic-responsive, steroid-responsive or parasitic.



**19.16** A standardized photographic scale for atrophy, fibrosis and cellular infiltrate. 0 = normal; 1 = mild; 2 = moderate; 3 = severe. (Reproduced from Wiinberg *et al.* (in press) with permission from the American College of Veterinary Internal Medicine)

**Clinical signs**

The major clinical sign of chronic gastritis is vomiting of food or bile. Decreased appetite, weight loss, melaena or haematemesis are variably encountered. The concurrent presence of dermatological and GI signs raises the likelihood of dietary sensitivity. Access to toxins, medications and foreign bodies, and dietary practices should be thoroughly reviewed.

The patient details should not be overlooked as it may increase the probability that chronic gastritis is the cause of vomiting, for example:

- Hypertrophy of the fundic mucosa is frequently associated with a severe enteropathy in Basenjis; and stomatocytosis, haemolytic anaemia, icterus and polyneuropathy in Drentse Patrijshonds
- Hypertrophy of the pyloric mucosa is observed in small brachycephalic dogs, such as Lhasa Apsos, and is associated with gastric outflow obstruction (see below)
- Atrophy of the gastric mucosa that may progress to adenocarcinoma has been reported in Norwegian Lundehunds with protein-losing gastroenteropathy
- Young, large-breed, male dogs in the Gulf States of the USA may have granulomatous gastritis caused by *Pythium* spp. with infection more prevalent in autumn (fall), winter and spring.

Physical examination is often unremarkable in patients with chronic gastritis. Abdominal distension may be related to delayed gastric emptying caused by obstruction or defective propulsion. Abdominal masses, lymphadenopathy or ocular changes may be encountered in dogs with gastric fungal infections.

**Diagnosis**

**Clinicopathological testing:** Clinicopathological test results are often normal in patients with chronic gastritis. A biochemical profile, CBC and urinalysis should be performed and thyroxine concentrations measured (cats) as a basic screen for metabolic, endocrine, infectious, and other non-GI causes of vomiting, as well as the acid-base and electrolyte changes associated with vomiting, outflow obstruction or acid hypersecretion.

- Eosinophilia may prompt the consideration of gastritis associated with dietary hypersensitivity, endoparasites or mast cell tumours.
- Hyperglobulinaemia and hypoalbuminaemia may be present in Basenjis with gastropathy/enteropathy or dogs with gastric pythiosis.
- Panhypoproteinaemia is a feature of gastroenteropathy in Norwegian Lundehunds, moderate to severe generalized inflammatory bowel disease, GI lymphoma and GI histoplasmosis.

- More specific tests, such as an adrenocorticotrophic hormone stimulation test or serology for *Pythium insidiosum*, are performed on the basis of these initial test results.
- Determination of food-specific IgE has not been shown to be useful in the diagnosis of dietary sensitivity in dogs or cats.
- The utility of non-invasive tests, such as serum pepsinogen and gastric permeability to sucrose used to diagnose gastritis in people, has not been determined in dogs and cats.

**Diagnostic imaging:** Survey abdominal radiographs are frequently normal in dogs and cats with gastritis but may show gastric distension or delayed gastric emptying (food retained >12 hours after a meal). Contrast radiography may reveal ulcers or thickening of the gastric rugae or wall but has been largely superseded by the combination of ultrasonography (to detect mural abnormalities) and endoscopy (to observe and sample the gastric mucosa).

Endoscopic examination enables the visualization of foreign bodies, erosions, ulceration, haemorrhage, rugal thickening, lymphoid follicle hyperplasia (evident as mucosal pock marks), increased mucus or fluid (clear or bile stained), and increased or decreased mucosal friability. Discrete focal or multifocal mucosal nodules may be observed with *Ollulanus* infection. Parasites such as *Physaloptera* may be observed as 1–4 cm worms. Gastric phycomycosis can be associated with irregular masses in the pyloric outflow tract and may prompt serological testing by ELISA, Western blotting and culture of fresh gastric biopsy samples. Large amounts of bile-stained fluid are suggestive of duodenogastric reflux associated gastritis, whereas lots of clear fluid may indicate hypersecretion of gastric acid.

Gastric fluid can be aspirated for cytology (*Helicobacter*, parasite ova or larvae) and pH measurement. Impression smears of gastric biopsy samples are an effective way of looking for *Helicobacter* spp. (5–12 µm spirals) and are more sensitive than the biopsy urease test (*Helicobacter* spp. produce urease) (see Figure 19.3). Serum gastrin should be measured where there are unexplained gastric erosions, ulcers, fluid accumulation or mucosal hypertrophy. Gastroscopic food sensitivity testing (GFST), the endoscopic procedure of dribbling dietary antigens on to the gastric mucosa to ascertain the presence of food allergy, has not been useful in dogs or cats. GFST is highly subjective, detects only immediate hypersensitivity, and does not correlate with the results of dietary elimination trials.

**Biopsy:** A stomach biopsy should be performed even when it looks grossly normal (usually three samples from each region: pylorus, fundus and cardia). Thickened rugae may require multiple biopsy, and a full-thickness biopsy is often required to differentiate gastritis from neoplasia or fungal infection, and to diagnose submucosal or muscular hypertrophy.

The interpretation of gastric biopsy specimens (see Chapter 5) has important implications for patient care as biopsy findings are often used to guide treatment, e.g. moderate lymphoplasmacytic gastritis without

*Helicobacter* is often treated with corticosteroids, whereas mild lymphoplasmacytic gastritis may be treated with a change in diet. As the histopathological evaluation of a gastric biopsy has not been standardized the prudent clinician should carefully review histological reports or sections to get a feel for their pathologist's interpretation. Even with optimum evaluation similar histological changes can be observed in patients with different underlying aetiologies, so well structured treatment trials often form the basis of an aetiological diagnosis.

Gastric sections should be stained with haematoxylin and eosin (H&E) for evaluation of cellularity and architecture, and modified Steiner stain for gastric spiral bacteria (see Figures 19.3 and 19.16). Further special stains (e.g. Gomori's methenamine silver) are indicated to detect fungi if pyogranulomatous inflammation is present. Masson's trichrome can be used to highlight gastric fibrosis, while sirius red and alcian blue help to reveal eosinophils and mast cells, respectively. Immunohistochemistry can be employed to help distinguish lymphoma from severe lymphocytic gastritis. Mucin staining has been performed in Norwegian Lundehunds with gastric atrophy and showed an abnormal presence of mucus neck cells and pseudopyloric metaplasia.

#### Treatment

Treatment of chronic gastritis initially centres on the detection and treatment of underlying metabolic disorders and the removal of drugs, toxins, foreign bodies, parasites and fungal infections.

#### Bacterial gastritis

**Helicobacter:** The importance of unknown pathogens in the development of gastritis is best demonstrated by the gastric bacterium *Helicobacter pylori*, a Gram-negative bacterium that chronically infects more than half of all people worldwide. The sustained gastric inflammatory and immune response to infection appears to be pivotal for the development of peptic ulcers and gastric cancer in people.

There is a high prevalence of gastric *Helicobacter* infection in dogs (67–100% healthy pet dogs, 74–90% vomiting dogs, 100% laboratory Beagles) and cats (40–100% of both healthy and sick cats). Dogs and cats are colonized by a variety of large spiral organisms (5–12 µm) (see Figure 19.3). In cats *H. heilmannii* is the predominant species, with *H. bizzozeronii* and *H. felis* much less frequent. In dogs *H. bizzozeronii* and *H. salomonis* are most common followed by *H. heilmannii* and *H. felis*; *H. bilis* and *Flexispira rappini* have also been described. Cats can also be colonized by *H. pylori* (2–5 µm) but infection has been limited to a closed colony of laboratory cats. The large *Helicobacter* species found in dogs and cats do not attach to the epithelium but colonize the superficial mucus and gastric glands, particularly of the fundus and cardia, and may also be observed intracellularly.

*Helicobacter* infection of dogs and cats is associated with:

- Degeneration of gastric glands, with vacuolation, pyknosis and necrosis of parietal cells



- Mononuclear inflammation ranging from mild to moderate in severity
- Gastric lymphoid hyperplasia is common and can be extensive (particularly when full-thickness gastric biopsy samples are evaluated)
- A systemic response characterized by increased circulating anti-*Helicobacter* IgG has been detected in sera from naturally infected dogs and cats.

However, GI ulcers, gastric neoplasia and abnormalities in serum gastrin or acid secretion have not been associated with *Helicobacter* infection in dogs and cats.

*Helicobacter* species also carry a potential zoonotic risk. Ownership of dogs and cats has been correlated with an increased risk of infection of *H. heilmannii* in people. Case reports have also suggested the transmission of *Helicobacter* spp. from pets to humans. Recent studies clearly confirm that dogs and cats harbour *H. heilmannii*, but the subtypes of *H. heilmannii* present in dogs and cats (types 2 and 4) are of minor importance (approximately 15% of cases) to humans, who are predominantly colonized by *H. heilmannii* type 1 (which is the predominant *Helicobacter* spp. in pigs).

An uncontrolled treatment trial of dogs and cats with gastritis and *Helicobacter* infection showed that clinical signs in 90% of 63 dogs and cats responded to treatment with a combination of metronidazole, amoxicillin and famotidine, and that 14 of the 19 animals re-endoscoped had resolution of gastritis and no evidence of *Helicobacter* in the gastric biopsy samples. Controlled clinical trials have been hampered by a much higher apparent recrudescence or re-infection rate than the 1–2% a year observed after treatment of *H. pylori*-infected people.

Only symptomatic patients with biopsy-confirmed *Helicobacter* infection and gastritis should be treated. The combination of amoxicillin (20 mg/kg p.o. q12h), clarithromycin (7.5 mg/kg p.o. q12h) and metronidazole (10 mg/kg p.o. q12h) for 14 days may be effective. Ideally eradication should be confirmed by the evaluation of gastric juice or biopsy 1 month after stopping treatment, and non-responsive patients should be evaluated for resistant infections. Further controlled trials of antibiotic therapy in symptomatic patients with gastritis and *Helicobacter* infection are required before clear guidelines regarding the treatment of gastric *Helicobacter* spp. can be made.

#### Parasitic gastritis

***Ollulanus tricuspis*:** *Ollulanus tricuspis* is a microscopic worm (0.7–1 mm long, 0.04 mm wide) infecting the feline stomach. It is transmitted predominantly by cat to cat transmission through ingestion of vomitus, and can also undergo internal autoinfection with worm burdens reaching up to 11,000 per stomach.

Mucosal abnormalities range from none to rugal hyperplasia and nodular (2–3 mm) gastritis. Histological findings include lymphoplasmacytic infiltrates, lymphoid follicular hyperplasia, fibrosis and up to 100 globular leucocytes per high power field.

*Ollulanus* is not detected by faecal examination but requires evaluation of gastric juice, vomitus or

histological sections for larvae or worms. Gastric lavage and xylazine-induced emesis have been described to aid diagnosis. Treatment with fenbendazole at 10 mg/kg p.o. q24h for 2 days may be effective.

**Physaloptera:** These species are approximately 2–6 cm long worms, which are sporadically detected in the stomachs of dogs and cats. *Physaloptera rara* are most commonly described and appear to be primarily a parasite of coyotes. Diagnosis is difficult as worm burden is often low and the eggs are transparent and difficult to see in sugar flotation. Treatment with pyrantel pamoate (5 mg/kg p.o., dogs single dose, cats two doses 14 days apart) may be effective. Control of infection may be difficult due to the ingestion of intermediate hosts (such as cockroaches and beetles) and paratenic hosts (such as lizards and hedgehogs). Given the difficulty of diagnosing *Ollulanus* and *Physaloptera* empirical therapy with an anthelmintic, such as fenbendazole, may be warranted in dogs and cats with unexplained gastritis.

**Other parasites:** Gastric infection with *Gnathostoma* (cats), *Spirocerca* (dogs) and *Aonchotheca* (cats) have been associated with gastric nodules that have been treated by surgical resection of affected gastric tissue.

#### Fungal gastritis

**Gastric pythiosis:** The presence of transmural thickening of the gastric outflow tract and histology indicating pyogranulomatous inflammation raise the possibility of infection with fungi, such as *Pythium insidiosum*. Special staining (Gomori's methenamine silver), culture, serology and polymerase chain reaction (PCR) of infected tissues can be used to help confirm the diagnosis. Treatment consists of aggressive surgical resection combined with itraconazole (10 mg/kg p.o. q24h) and terbinafine (5–10 mg/kg p.o. q24h) for 2–3 months post-surgery. ELISA titres of pre- and post-treatment samples may show a marked drop during successful treatment and drugs can be stopped. Medical therapy is continued for another 2–3 months if titres remain elevated. The prognosis is poor and only <25% of cases are cured with medical therapy alone.

#### Chronic gastritis of unknown cause

Lymphocytic-plasmacytic gastritis of unknown cause is common in dogs and cats. It may be associated with similar infiltrates in the intestines, particularly in cats (who should also be evaluated for the presence of pancreatic and biliary disease). The cellular infiltrate varies widely in severity and it may be accompanied by mucosal atrophy or fibrosis, and less commonly hyperplasia.

**Mild lymphoplasmacytic gastritis:** This is initially treated with diet. The diet is usually restricted in antigens to which the patient has not been previously exposed, e.g. a lamb-based diet if the patient has previously been fed chicken and beef, or contains hydrolysed proteins (usually chicken or soy) that may be less allergenic than intact proteins. Many of these diets are also high in carbohydrate and restricted in fat, which facilitates gastric emptying, and may contain other substances (such as menhaden fish oil or antioxidants) that may alter inflammation.

The test diet is fed exclusively for a period of approximately 2 weeks while vomiting episodes are recorded. If vomiting is improved, a challenge with the original diet is required to confirm a diagnosis of dietary sensitivity. The introduction of a specific dietary component to the test diet, e.g. beef, is required to confirm dietary sensitivity. If vomiting is unresponsive the patient may be placed on a different diet for another 2 weeks, usually the limit of client tolerance, or started on prednisolone (1–2 mg/kg p.o. q24h, tapered to every other day at the lowest dose that maintains remission over 8–12 weeks).

**Moderate to severe lymphoplasmacytic gastritis:** This is usually treated with a combination of a test diet and prednisolone. If the patient goes into remission they should be maintained on the test diet while prednisolone is tapered, and potentially discontinued. Antacids and mucosal protectants are added to the therapeutic regimen if ulcers or erosions are detected at endoscopy, or if haematemesis or melaena are noted. If gastritis is unresponsive to diet, prednisolone and antacids, the diagnosis should be re-evaluated prior to aggressive immunosuppression.

In dogs immunosuppression is usually increased with azathioprine (2 mg/kg p.o. q24h for 5 days then q48h, on alternating days with prednisolone). Chlorambucil is a safer alternative to administer orally than azathioprine in cats and has been successfully employed in the management of inflammatory bowel disease and small cell lymphoma (see below). Prokinetic agents (e.g. metoclopramide, cisapride, erythromycin) can be used as an adjunct where delayed gastric emptying is present.

**Diffuse eosinophilic gastritis:** Diffuse eosinophilic gastritis of undefined aetiology is usually approached in a similar fashion to lymphoplasmacytic gastritis. The presence of eosinophilia, dermatological changes and eosinophilic infiltrates may be even more suggestive of dietary sensitivity. In cats it should be determined whether it is part of a hypereosinophilic syndrome.

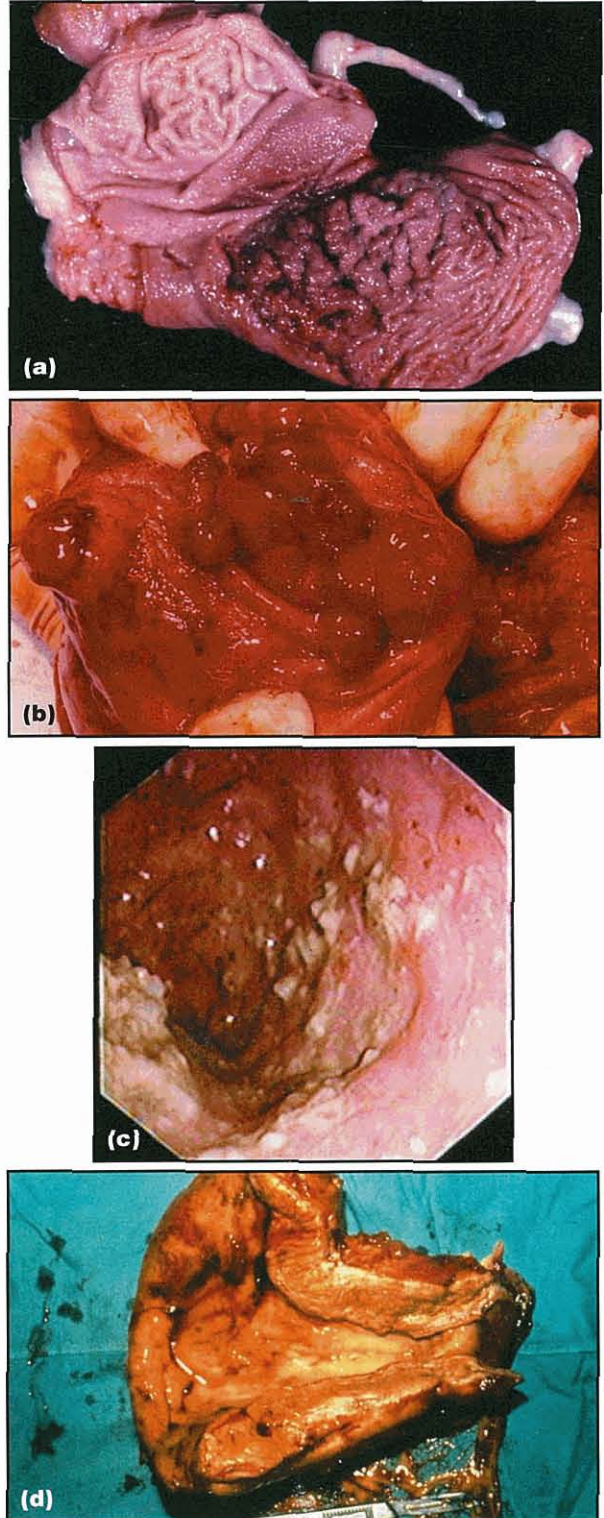
Treatment for occult parasites, dietary trials and immunosuppression can be carried out as described above. Focal eosinophilic granulomas can be associated with parasites or fungal infection, which should be excluded prior to immunosuppression with corticosteroids.

**Atrophic gastritis:** Atrophic gastritis has been infrequently described in dogs and cats but is often associated with a marked cellular infiltrate (see Figure 19.15). Atrophy has also been associated with gastric adenocarcinoma in Norwegian Lundehunds. There is no clear evidence that lymphoplasmacytic gastritis progresses to atrophy and gastric cancer in dogs or cats, and the role of *Helicobacter* or antigastric antibodies in the development of atrophy in dogs and cats remains to be determined.

Dogs and cats with atrophic gastritis have not been reported to develop cobalamin deficiency, unlike humans. This is probably because the pancreas, rather than the stomach, is the main source of intrinsic factor in these species. Achlorhydria has been described in dogs and may enable the proliferation of bacteria in the stomach and upper small intestine, though this has not been

proven. The treatment of atrophic gastritis has received limited attention but *Helicobacter* eradication and immunosuppression have been effective in humans.

**Hypertrophic gastritis:** Hypertrophy of the fundic mucosa (Figure 19.17) is uncommon and is often part



**19.17** Hypertrophic gastropathy. (a) Diffuse fundic hypertrophy. (b) Multifocal fundic hypertrophy. (c) Endoscopic view of antral mucosal hypertrophy. (d) Appearance of antral mucosal hypertrophy caused by *Pythium* spp. infection, resected at surgery.

of the breed-specific gastropathies or gastroenteropathies mentioned above. Concurrent hypergastrinaemia should prompt consideration of underlying hepatic or renal disease, achlorhydria or gastrin-producing tumours, which should be pursued appropriately. Basenji gastroenteropathy is variably associated with fasting hypergastrinaemia and exaggerated secretin-stimulated gastrin, and anecdotal reports suggest that affected Basenjies may respond to antimicrobial therapy. Antral hypertrophy of brachycephalic dogs (Figure 19.17) causes outflow obstruction and is managed surgically (see below).

**Delayed gastric emptying and motility disorders**

Disorders of gastric motility can disrupt the storage and mixing of food and its expulsion into the duodenum. Delayed gastric emptying is the most commonly recognized manifestation of gastric motility disorders. Rapid gastric emptying and motility disorders associated with retrograde transit of bile or ingesta are less well defined. Delayed gastric emptying is caused by outflow obstruction or defective propulsion (Figure 19.18) and is usually suspected by the vomiting of food >8 and often 10–16 hours after a meal.

Mechanism	Cause
Outflow obstruction	Congenital stenosis Foreign bodies Hypertrophy of pyloric mucosa Granuloma Polyps Neoplasia Extra-gastric masses Gastric dilatation and volvulus (GDV) Pancreatitis
Defective propulsion	Gastric disorders (e.g. gastritis, ulcers, neoplasia, gastric dilatation/GDV) Gastroenteritis Peritonitis Pancreatitis Metabolic (hypokalaemia, hypocalcaemia, hypoadrenocorticism) Nervous inhibition (trauma, pain, stress?) Dysautonomia Surgery Drugs (e.g. anticholinergics, narcotics) Idiopathic

**19.18** Causes of delayed gastric emptying.

**Clinical signs**

Vomiting of food some time after ingestion (>8 hours) is the most common sign. Vomiting may be projectile with pyloric stenosis. Abdominal distension, weight loss, melaena, abdominal discomfort, distension, bloating and anorexia are more variably present.

The clinical details and history may be helpful in narrowing down the cause:

- Development of vomiting at weaning raises the possibility of pyloric stenosis

- Access to foreign bodies, bones and medications is of obvious relevance to outflow obstruction
- Brachycephalic, middle-aged, small-breed dogs (such as the Shih Tzu) seem predisposed to hypertrophic pylorogastropathy syndrome, where vomiting is secondary to pyloric outflow obstruction caused by hypertrophy of the pyloric mucosa (see Figure 19.17)
- Gastric neoplasia is usually detected in older animals, and weight loss, haematemesis and pallor may be present
- Gastric pythiosis is more prevalent in young large-breed dogs in the Gulf States of the USA
- Large-breed, deep-chested dogs, which may have an underlying problem with gastric emptying (see above), are more prone to GDV.

A thorough physical examination is performed to detect causes of vomiting (such as string foreign bodies, or intestinal masses or thickenings), non-GI causes including thyroid (cervical nodules in cats), liver (jaundice, hepatomegaly) or kidney (renomegaly, lumpy or small) disease and the systemic effects of vomiting (e.g. dehydration, weakness).

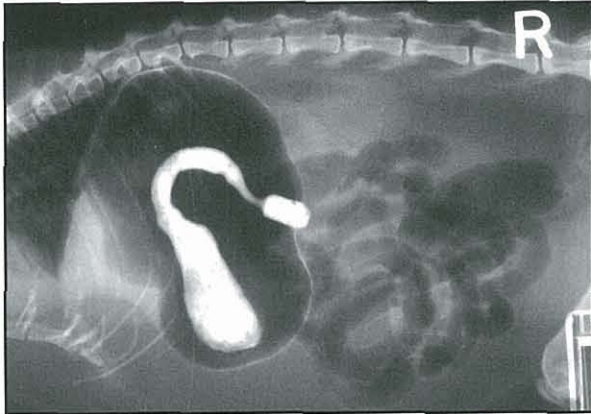
**Diagnosis**

The diagnostic approach is to confirm delayed gastric emptying and to detect causes of gastric outflow obstruction that may require surgery, as well as identifying non-gastric disorders associated with defective propulsion. Historical and physical findings are combined with clinicopathological testing, plain radiography and ultrasonography.

**Clinicopathological testing:** Haematology, serum biochemistry, urinalysis, faecal analysis (e.g. parasites, parvovirus) and serology (e.g. FeLV) help to detect non-GI causes of vomiting or delayed gastric emptying, and determine the consequences of vomiting. Laboratory findings vary depending on the severity of vomiting and completeness of pyloric obstruction, as well as the presence of disorders associated with blood loss or inflammation. The CBC is often normal, but anaemia may accompany gastric ulcers or neoplasia. Hyperglobulinaemia may be present where the outflow obstruction is secondary to fungal granuloma. The presence of hypochloraemia, hypokalaemia and metabolic alkalosis, with or without aciduria, should increase suspicion of an upper GI obstruction or potential hypersecretion of gastric acid.

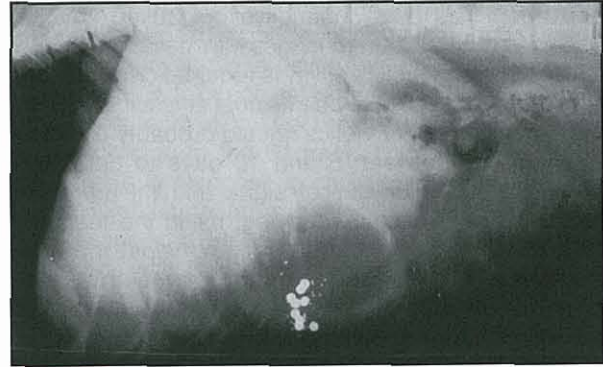
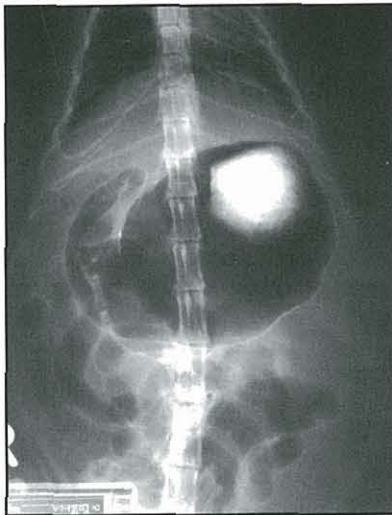**Diagnostic imaging:** Radiography is essential to confirm the retention of food or fluid in the stomach >8 hours after a meal and to detect extra-gastric disorders, such as peritonitis. Contrast radiography can be used to detect mural abnormalities and to confirm a suspicion of gastric obstruction when plain radiographs are inconclusive (see Figures 19.7 and 19.19).

Ultrasonography may detect mural thickening or irregularity of the stomach suggestive of neoplasia, granuloma or hypertrophy (see Figure 19.8). Ultrasound examination may also reveal radiolucent foreign objects and detect non-gastric causes of delayed emptying (e.g. pancreatitis).



19.19

Marked retention of barium in a cat with delayed gastric emptying associated with submucosal infiltration with neutrophils.



19.20

The use of barium impregnated polyethylene spheres (BIPS) to evaluate gastric emptying. This radiograph shows the accumulation of BIPS in the gastric body.

Endoscopy is usually favoured over radiographic procedures for confirming gastric outflow obstruction and gastric and duodenal causes of decreased propulsion (e.g. ulcers, gastritis). However, endoscopy is hampered by the administration of barium contrast media, and so is often performed first. Endoscopic biopsy is limited to the superficial mucosa, and surgical biopsy is frequently required to achieve a definitive diagnosis of granulomatous, neoplastic or hypertrophic conditions (see Figure 19.17).

**Gastric pH and serum gastrin:** Measurement of gastric pH and serum gastrin can help to differentiate idiopathic hypertrophic pylorogastropathy from hypertrophy associated with hypergastrinaemia.

**Additional techniques:** More sophisticated procedures to evaluate gastric emptying and motility directly are usually employed to determine whether vomiting is due to an undefined gastric motility disorder and to optimize prokinetic therapy (Figure 19.9).

Contrast radiography procedures are readily available but are hampered by the wide variability in emptying times for barium in liquid or meal form. The administration of barium impregnated polyethylene spheres (BIPS) is a simplified contrast procedure suited to routine clinical practice as it requires fewer radiographs than a traditional barium series and is standardized in terms of test performance and interpretation. However, the utility of BIPS in clinical patients remains to be determined (Figure 19.20).

Scintigraphic techniques are generally considered the most accurate way to evaluate emptying but are restricted to referral institutions. Ultrasonography can be useful for detecting gastric wall abnormalities and measuring contractile activity. A test employing  $^{13}\text{C}$ -octanoic acid has been evaluated in humans and dogs and found to reflect gastric emptying. The times are slightly greater than for scintigraphy as  $^{13}\text{C}$ -octanoate has to be absorbed and metabolized before  $^{13}\text{CO}_2$  is liberated.

#### Treatment

Treatment of gastric emptying disorders is directed at the underlying cause. Gastric ulcers, erosions and inflammation should be investigated and managed medically (as described above). Foreign bodies should be removed either endoscopically or surgically. Pyloric stenosis, polyps, and hypertrophic gastropathy that is not associated with hypergastrinaemia, are managed surgically.

When hypertrophic gastropathy, ulcers or erosions, or excessive gastric juice are visualized at endoscopy, intravenous  $\text{H}_2$  antagonists can be given during the endoscopic procedure to try to prevent postoperative perforation or oesophagitis. Neoplasia, polyps and granulomas may require extensive gastric resection and Billroth procedures (see *BSAVA Manual of Canine and Feline Abdominal Surgery*).

**Dietary modification:** Dietary modification to facilitate gastric emptying may be beneficial irrespective of cause. Small amounts of semi-liquid, protein and fat restricted diets (e.g. an 'intestinal disease diet' blended with water and mixed with an equal volume of boiled rice) fed at frequent intervals may facilitate emptying.

**Prokinetics:** In non-obstructive situations gastric emptying can be enhanced, and duodenogastric reflux inhibited, by prokinetic agents, such as metoclopramide, cisapride, erythromycin or ranitidine (see Chapter 28). There are no controlled trials in dogs and cats that have evaluated the efficacy of different prokinetics in different disease states.

The choice of prokinetic depends on whether a central anti-emetic effect is required (e.g. metoclopramide), whether a combined antacid prokinetic is indicated (e.g. ranitidine), or whether treatment with

one agent has been ineffective or caused adverse effects (e.g. behavioural changes with metoclopramide). Where true prokinetic activity is required cisapride and erythromycin appear to be the most efficacious. Treatment trials with prokinetics should probably be structured to last between 5 and 10 days to determine benefit. A diary of clinical signs and the objective assessment of gastric emptying, using the tests described above, before and after therapy helps to optimize treatment. Combination therapy (e.g. erythromycin and cisapride) is not recommended due to the potential for adverse drug interactions.

- **Metoclopramide** has central anti-emetic properties, in addition to its prokinetic activity in the stomach and upper GI tract, and is frequently an initial choice in patients with underlying metabolic diseases associated with vomiting and delayed gastric emptying. However, metoclopramide may only facilitate the emptying of liquids and is less effective in promoting organized gastroduodenal and intestinal motility than cisapride.
- **Cisapride** has no central anti-emetic effects but is generally more potent in promoting the gastric emptying of solids than metoclopramide; however, it does have more drug interactions and its availability is limited.
- **Erythromycin** releases motilin and acts at motilin receptors, and mimics phase III of the interdigestive migrating myoelectric complex (MMC) promoting the emptying of solids.
- **Nizatidine** and **ranitidine** have prokinetic activity attributed to an anti-cholinesterase activity.

A suspected motility disorder, characterized by duodenogastric reflux, is thought to account for a syndrome known as the bilious vomiting syndrome. Affected dogs usually vomit early in the morning. Remission may be achieved by feeding the animal late at night. Prokinetic agents may also be employed.

The prognosis for patients with delayed gastric emptying depends on the cause.

### Gastric neoplasia

Gastric neoplasia represents less than 1% of all reported canine and feline neoplasms. Malignant tumours are more common than benign tumours and most types of gastric neoplasms have been reported to occur more frequently in males, except adenomas, which occur more frequently in females. Gastric malignancies reported are:

- Adenocarcinoma: diffuse; intestinal or tubular
- Leiomyosarcoma
- Lymphosarcoma (LSA)
- Fibrosarcoma
- Rare anaplastic sarcomas
- Gastric extramedullary plasmacytoma.

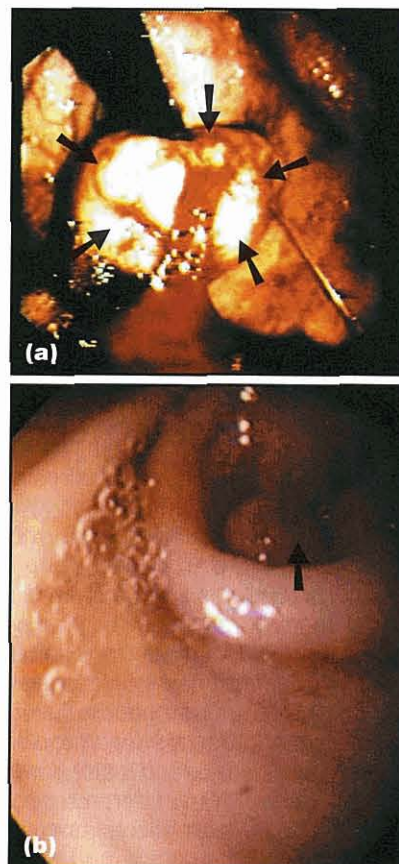
Figure 19.21 summarizes the prevalence, breed predisposition and distribution of gastric tumours in dogs.

Tumour	Most common location	Median age (years)	Reported breed predisposition
Adenocarcinoma	Pyloric antrum; lesser curvature	10	Belgian Shepherd Dog; Rough Collie; Staffordshire Bull Terrier; Norwegian Lundehund
Leiomyoma	Cardia	16	Beagle
Leiomyosarcoma	Not determined	7	None
Lymphosarcoma	Diffuse	10	None

19.21 Characteristics of gastric neoplasia in dogs.

### Benign tumours

Canine gastric leiomyoma is a tumour of old dogs (median age 16 years) and many are discovered incidentally at necropsy or when they are presented for GI bleeding and microcytic anaemia. Adenomatous polyps (Figure 19.22) are rare in dogs but have been reported as raised, sessile and pedunculated, single or multiple growths in the stomach. The most common site is the terminal pyloric antrum and while most are discovered incidentally, they may also cause signs of GI upset with vomiting. Benign GI neoplasia in the cat occurs at a much lower frequency than in the dog, where up to 36% of all GI neoplasia is reported to be benign.



19.22

Benign gastric tumours. (a) An ulcerated gastric leiomyoma (arrowed) in the cardia of a dog. (b) Adenomatous polyp (arrowed) in the pyloric outflow tract of a dog.

### Malignant tumours

**Adenocarcinoma:** Malignant adenocarcinoma is the most common gastric neoplasm in dogs. Gastric adenocarcinoma is extremely rare in cats. The peak age of dogs with gastric carcinomas has been reported to be from 11–12 years, with a range of 3–13 years and an average age of 9–10 years. A breed predilection for gastric carcinoma in related Belgian Shepherd Dogs, Rough Collies, Chow Chows and Staffordshire Bull Terriers has been suggested. Norwegian Lundehunds with atrophic gastritis also seem over-represented, and gastric atrophy and inflammation may precede tumorigenesis as it does in humans. Gastric carcinomas of dogs occur most commonly in the lesser curvature and pyloric region as annular or stenosing lesions, and metastasis is frequent with involvement of lymph nodes, liver and sometimes the lungs (Figure 19.23; see Chapter 4).

There are three morphological patterns of distribution:

- Diffusely infiltrating non-ulcerating lesions, resembling a 'leather bottle'
- Localized, raised thickened plaque often with an elevated excavating central ulcer
- Raised, polypoid sessile lesion projecting into the lumen of the stomach.

Two histological types of gastric carcinoma exist in humans, the diffuse type and the intestinal or tubular type. The diffuse type consists of widespread random infiltrates of neoplastic cells dispersed between stromal elements of the gastric wall. The intestinal type is characterized by a tubular, glandular structure. These same two classifications have been shown to exist in dogs with the diffuse type being more common.

**Lymphosarcoma:** This is the most common GI malignancy in cats and dogs and often involves several segments of the intestinal tract, including the stomach. In dogs the gastric tumour can be described as diffuse or nodular with the diffuse infiltrate being more common (see Figure 19.23). Concurrent involvement of the liver, regional lymph nodes, small intestine and bone marrow is common. Feline gastric LSA is usually FeLV-negative. It has been recently categorized as large cell or small cell, with small cell lymphoma being more

localized in the GI tract and carrying a much better prognosis than large cell lymphoma. In both dogs and cats, lymphocytic-plasmacytic inflammation has been found to precede or coexist with gastric LSA and it has been hypothesized, but not proven, that it is a precancerous change in the GI tract. The development of gastric LSA in response to chronic antigenic stimulation and inflammation is exemplified by gastric mucosal-associated lymphoid tissue (MALT) lymphoma in humans with *Helicobacter pylori*-associated gastritis. Whether a similar situation is present in dogs and cats remains to be determined.

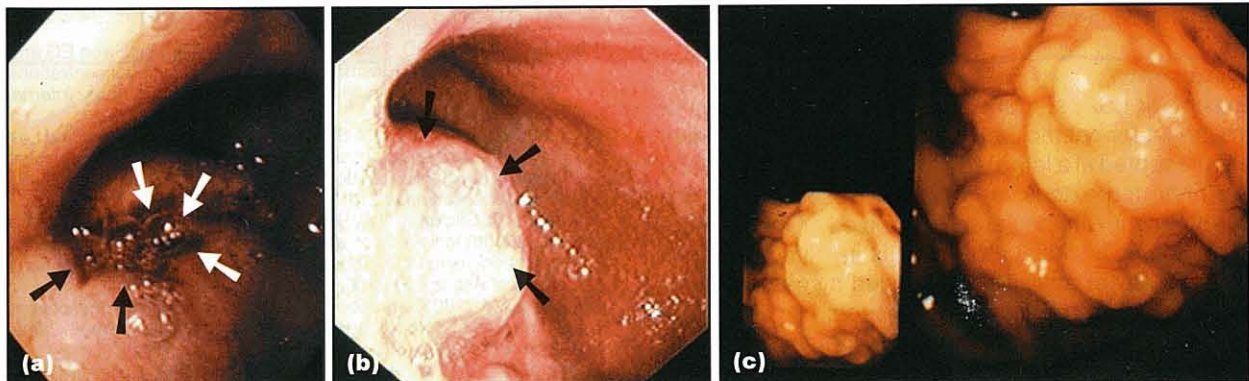
**Leiomyosarcoma:** These are slow growing tumours of smooth muscle origin. The median age of affected dogs is >10 years. Neither breed nor sex predilection has been reported for gastric leiomyosarcoma. Invasion of the gastric wall by leiomyosarcomas is often diffuse. These tumours may cause ulceration, grossly resembling adenocarcinomas, or may appear as discrete masses. The median survival of these dogs was 10 months (ranging from 1 month to 7 years). Of the stomach/small intestine group, 29% eventually died of leiomyosarcoma. Leiomyosarcoma and leiomyoma have been associated with paraneoplastic hypoglycaemia and seizures presumed due to the production of insulin-like growth factors.

### Clinical findings

The most common clinical signs associated with gastric neoplasia are chronic vomiting, weight loss, anorexia, diarrhoea, and haematemesis, melaena or pallor if ulceration is present. Some dogs will also show abdominal pain or a distended abdomen. With GI LSA the onset of clinical signs is often insidious and gradually increases in severity, becoming refractory to symptomatic treatment.

### Diagnosis

**Clinicopathological testing:** Findings in dogs and cats with gastric cancer include anaemia (which may be microcytic and non-regenerative), hyperglobulinaemia and hypoalbuminaemia. Changes in electrolyte and acid–base balance may be secondary to vomiting or gastric outflow obstruction. Metastatic disease can be accompanied by changes in target organ function.



**19.23** Malignant gastric tumours. Endoscopic appearance of (a) diffuse gastric adenocarcinoma (arrowed), (b) focal gastric adenocarcinoma (arrowed) and (c) gastric lymphoma with infiltration of all rugae in the visual field.

Gastric LSA in cats may occur along with a variety of diseases such as pancreatitis, hepatic disease and intestinal inflammation.

**Diagnostic imaging:** Survey radiography may be completely normal or suggest focal gastric wall thickening, an abdominal mass, or evidence of peritonitis, rupture of a viscus, splenomegaly, hepatomegaly or lymphadenopathy. Ultrasonography may reveal mural thickening or irregularities that forewarn the endoscopist the lesion may be more submucosal or muscular than superficial (see Figure 19.8). Lymphadenopathy or regional metastasis may be evident. Gastroscopy is able to detect most gastric tumours efficiently and has largely replaced contrast radiography (see Chapter 4).

- LSA is seen as a diffuse, smooth or cobblestone-like thickening of the rugae with a mucosa that is pink or white (see Figure 19.23), and may have scattered petechial or ecchymotic haemorrhages.
- Gastric carcinomas tend to be focal dark pink to red masses that may appear slightly pedunculated. Discoloured purple to black areas indicate haemorrhage, whereas yellow to brown foci often represent necrotic ulcers. In some cases, lesions may be submucosal and the endoscopist may form the impression that something is indenting the stomach or that the wall seems less distensible or thickened.
- Multiple biopsy specimens should be taken from suspicious areas and masses should be sampled several times in the same place to get deeper into tissue, as gastric tumours may have superficial necrosis, inflammation and ulceration. Biopsy samples should be taken from the periphery rather than the centre of the ulcer to avoid perforation. Surgical biopsy should be performed where the gross endoscopic appearance does not match the histological diagnosis, e.g. a large focal gastric mass with an endoscopic biopsy result of lymphoplasmacytic gastritis.

When endoscopy is not available contrast radiography may be useful with features of gastric neoplasia, including thickening of the gastric wall, filling defects and derangement of normal rugal pattern, and delayed gastric emptying with retention and irregular pooling of barium (see Figure 19.7). Surgery is then performed to sample the affected area.

#### Treatment

Except for LSA, surgery is the most common form of treatment for gastric cancer. However, many patients are presented at a late stage of disease and the lesions are often too extensive to resect. Resection may be curative if the affected area is localized or if the tumour is benign. If a widespread area is involved, a partial gastrectomy or antrectomy followed by gastroduodenostomy (Billroth I) may be attempted.

Gastric adenocarcinoma often metastasizes and regional lymph nodes and liver should be inspected and biopsied. Even with surgery the prognosis for malignant gastric neoplasia is poor with most patients dying within

6 months from recurrent or metastatic disease. Leiomyosarcoma is an exception and carries a good to excellent prognosis if the mass is surgically resectable. Even if gross metastasis is evident at surgery a favourable outcome may be achieved because the tumour is slow growing. Survival in dogs with stomach, small intestinal, splenic and caecal leiomyosarcoma ranges from 0–47 months after surgery, and the median survival is 12.5 months. GI lymphosarcoma has a poor prognosis in dogs. In cats the prognosis for GI lymphosarcoma depends on whether the tumour is small or large cell, with small cell lymphomas achieving substantial remission when treated with chlorambucil and prednisolone. Large cell lymphoma is treated with combination cyclical chemotherapy and carries a much poorer prognosis.

#### References and further reading

- Allen A, Flemstrom G, Garner A and Kivilaakso E (1993) Gastroduodenal mucosal protection. *Physiological Reviews* **73**, 823–857
- Boston SE, Moens NM, Kruth SA and Southern EP (2003) Endoscopic evaluation of the gastroduodenal mucosa to determine the safety of short-term concurrent administration of meloxicam and dexamethasone in healthy dogs. *American Journal of Veterinary Research* **64**, 1369–1375
- Brockman DJ, Washabau RJ and Drobatz KJ (1995) Canine gastric dilatation/volvulus syndrome in a veterinary critical care unit: 295 cases (1986–1992). *Journal of the American Veterinary Medical Association* **207**, 460–464
- Buddington RK (2003) Postnatal changes in bacterial populations in the gastrointestinal tract of dogs. *American Journal of Veterinary Research* **64**, 646–651
- Couto GC, Rutgers HC, Sherding RG and Rojko J (1989) Gastrointestinal lymphoma in 20 dogs: a retrospective study. *Journal of Veterinary Internal Medicine* **3**, 73–78
- Cover T, Berg D, Blaser M and Mobley HLT (2001) *Helicobacter pylori* pathogenesis. In: *Principles of Bacterial Pathogenesis*, ed. E Groisman, pp. 509–558. Academic Press, New York
- Cryer B (2001) Mucosal defense and repair. Role of prostaglandins in the stomach and duodenum. *Gastroenterology Clinics of North America* **30**, 877–894
- Davis MS, Willard MD, Nelson SL, McCullough SM, Mandsager RE, Roberts J and Payton ME (2003) Efficacy of omeprazole for the prevention of exercise-induced gastritis in racing Alaskan sled dogs. *Journal of Veterinary Internal Medicine* **17**, 163–166
- DePapp E, Drobatz KJ and Hughes D (1999) Plasma lactate concentration as a predictor of gastric necrosis and survival among dogs with gastric dilatation-volvulus: 102 cases (1995–1998). *Journal of the American Veterinary Medical Association* **215**, 49–52
- El-Omar EM, Rabkin CS, Gammon MD, Vaughan TL, Risch HA, Schoenberg JB, Stanford JL, Mayne ST, Goedert J, Blot WJ, Fraumeni JF and Chow WH (2003) Increased risk of non-cardia gastric cancer associated with proinflammatory cytokine gene polymorphisms. *Gastroenterology* **124**, 1193–1201
- Faller G, Steininger H, Kranzlein J, Maul H, Kerkau T, Hensen J, Hahn EG and Kirchner T (1997) Antigastric autoantibodies in *Helicobacter pylori* infection: implications of histological and clinical parameters of gastritis. *Gut* **41**, 619–623
- Fox LE, Rosenthal RC, Twedt DC, Dubielzig RR, MacEwen EG and Grauer GF (1990) Plasma histamine and gastrin concentrations in 17 dogs with mast cell tumors. *Journal of Veterinary Internal Medicine* **4**, 242–246
- Glickman LT, Glickman NW, Schellenberg DB, Raghavan M and Lee T (2000a) Non-dietary risk factors for gastric dilatation-volvulus in large and giant breed dogs. *Journal of the American Veterinary Medical Association* **217**, 1492–1499
- Glickman LT, Glickman NW, Schellenberg DB, Raghavan M and Lee T (2000b) Incidence of and breed-related risk factors for gastric dilatation-volvulus in dogs. *Journal of the American Veterinary Medical Association* **216**, 40–45
- Grooters AM (2003) Pythiosis, lagenidiosis, and zygomycosis in small animals. *Veterinary Clinics of North America: Small Animal Practice* **33**, 695–720
- Guilford WG, Jones BR, Markwell PJ, Arthur DG, Collett MG and Harte JG (2001) Food sensitivity in cats with chronic idiopathic gastrointestinal problems. *Journal of Veterinary Internal Medicine* **15**, 7–13

- Guilford WG and Strombeck GR (1996) Chronic gastric disease. In: *Strombeck's Small Animal Gastroenterology, 3<sup>rd</sup> edn*, ed. WG Guilford *et al.* pp. 275–302. WB Saunders, Philadelphia
- Hall JA and Washabau RJ (1999) Diagnosis and treatment of gastric motility disorders. *Veterinary Clinics of North America: Small Animal Practice* **29**, 377–395
- Happonen I, Linden J, Saari S, Karjalainen M, Hanninen ML, Jalava K and Westermarck E (1998) Detection and effects of *helicobacters* in healthy dogs and dogs with signs of gastritis. *Journal of the American Veterinary Medical Association* **213**, 1767–1774
- Kapatkin AS, Mullen HS, Matthiesen DT and Patnaik AK (1992) Leiomyosarcoma in dogs: 44 cases (1983–1988). *Journal of the American Veterinary Medical Association* **201**, 1077–1079
- Lamb CR (1999) Recent developments in diagnostic imaging of the gastrointestinal tract of the dog and cat. *Veterinary Clinics of North America: Small Animal Practice* **29**, 307–342
- Lauwers GY (2003) Defining the pathologic diagnosis of metaplasia, atrophy, dysplasia, and gastric adenocarcinoma. *Journal of Clinical Gastroenterology* **36**, S37–S43
- Lindholm C, Quiding-Jarbrink M, Lonroth H, Hamlet A and Svennerholm AM (1998) Local cytokine response in *Helicobacter pylori*-infected subjects. *Infectious Immunology* **66**, 5964–5971
- Lloyd KKC and Debas HT (1994) Peripheral regulation of gastric acid secretion. In: *Physiology of the Gastrointestinal Tract, 3<sup>rd</sup> edn*, ed. LR Johnson, pp. 1185–1226. Raven Press, New York
- Mahony OM, Moore AS, Cotter SM, Engler SJ, Brown D and Penninck DG (1995) Alimentary lymphoma in cats: 28 cases (1988–1993). *Journal of the American Veterinary Medical Association* **207**, 1593–1598
- Muir WW (1982) Acid-base and electrolyte disturbances in dogs with gastric dilatation-volvulus. *Journal of the American Veterinary Medical Association* **181**, 229–231
- Murtaugh RJ, Matz ME, Labato MA and Boudrieau RJ (1993) Use of synthetic prostaglandin-e1 (misoprostol) for prevention of aspirin-induced gastroduodenal ulceration in arthritic dogs. *Journal of the American Veterinary Medical Association* **202**, 251–256
- Neiger R, Gaschen F and Jaggy A (2000) Gastric mucosal lesions in dogs with acute intervertebral disc disease: characterization and effects of omeprazole or misoprostol. *Journal of Veterinary Internal Medicine* **14**, 33–36
- Neiger R, Seiler G and Schmassmann A (1999) Use of a urea breath test to evaluate short-term treatments for cats naturally infected with *Helicobacter heilmannii*. *American Journal of Veterinary Research* **60**, 880–883
- Neiger R and Simpson KW (2000) *Helicobacter* infection in dogs and cats – what do we really know? *Journal of Veterinary Internal Medicine* **14**, 125–133
- Priestnall SL, Wijnberg B, Spohr A, Neuhaus B, Kuffer M, Wiedmann M and Simpson KW (2004) Evaluation of *Helicobacter heilmannii* subtypes in the gastric mucosae of cats and dogs. *Journal of Clinical Microbiology* **42**, 2144–2151
- Richter KP (2003) Feline gastrointestinal lymphoma. *Veterinary Clinics of North America: Small Animal Practice* **33**(5), 1083–1098
- Rohrer CR, Hill RC, Fischer A, Fox LE, Schaer M, Ginn PE, Preast VA and Burrows CF (1999) Efficacy of misoprostol in prevention of gastric hemorrhage in dogs treated with high doses of methylprednisolone sodium succinate. *American Journal of Veterinary Research* **60**, 982–985
- Rossi G, Rossi M, Vitali CG, Fortuna D, Burrioni D, Pancotto L, Capocchi S, Sozzi S, Renzoni G, Braca G, Del Giudice G, Rappuoli R, Ghiara P and Taccini E (1999) A conventional beagle dog model for acute and chronic infection with *Helicobacter pylori*. *Infectious Immunology* **67**, 3112–3120
- Sachs G (1994) The gastric H<sup>+</sup>/K<sup>+</sup>-ATPase. In: *Physiology of the Gastrointestinal Tract, 3<sup>rd</sup> edn*, ed. LR Johnson, pp. 1119–1138. Raven Press, New York
- Scanziani E, Simpson KW, Monestiroli S, Soldati S, Strauss-Ayali D and Del Piero F (2001) Histological and immunohistochemical identification of different *Helicobacter* species in the gastric mucosa of cats. *Journal of Veterinary Diagnostic Investigations* **13**, 3–12
- Schiffirin EJ and Blum S (2002) Interactions between the microbiota and the intestinal mucosa. *European Journal of Clinical Nutrition* **56 Suppl 3**, S60–S64
- Simpson KW (1999) Gastrinomas. In: *Kirk's Current Veterinary Therapy XIII*, ed. JD Bonagura, pp. 617–621. WB Saunders, Philadelphia
- Simpson KW, Center SA and Birnbaum N (2000a) Fluid and electrolyte disturbances in gastrointestinal, pancreatic and hepatic disease. In: *Fluid, Electrolyte, and Acid-base Disorders in Small Animal Practice, 2<sup>nd</sup> edn*, ed. S DiBartola, pp. 330–374. WB Saunders, Philadelphia
- Simpson KW, Neiger R, DeNovo R and Sherding RG (2000b) ACVIM Consensus statement: the relationship of *Helicobacter* spp. to gastric disease in dogs and cats. *Journal of Veterinary Internal Medicine* **14**, 223–227
- Slappendel RJ, Van der Gaag I, Vannes JJ, Van den Ingh TSGAM and Happe RP (1991) Familial stomatocytosis-hypertrophic gastritis (FSGH), a newly recognised disease in the dog (Drentse Patrijshond). *Veterinary Quarterly* **13**, 30–40
- Soll AH and Berglindh T (1994) Receptors that regulate gastric acid-secretory function. In: *Physiology of the Gastrointestinal Tract, 3<sup>rd</sup> edn*, ed. LR Johnson, pp. 1139–1169. Raven Press, New York
- Steiner JM, Berridge BR, Wojcieszyn J and Williams DA (2002) Cellular immunolocalization of gastric and pancreatic lipase in various tissues obtained from dogs. *American Journal of Veterinary Research* **63**, 722–727
- Straubinger RK, Greiter A, McDonough SP, Gerold A, Scanziani E, Soldati S, Dailidene D, Dailide G, Berg DE and Simpson KW (2003) Quantitative evaluation of inflammatory and immune responses in the early stages of *Helicobacter pylori* infection. *Infectious Immunology* **71**, 2693–2703
- Strauss-Ayali D, Scanziani E, Deng D and Simpson KW (2001) *Helicobacter* spp. infection in cats: evaluation of the humoral immune response and prevalence of gastric *Helicobacter* spp. *Veterinary Microbiology* **79**, 253–265
- Suchodolski JS, Steiner JM, Ruaux CG, Boari A and Williams DA (2002) Purification and partial characterization of canine pepsinogen A and B. *American Journal of Veterinary Research* **63**, 1585–1590
- Sullivan M, Lee R, Fisher EW, Nash AS, and McCantlish IAP (1987) A study of 31 cases of gastric carcinoma in dogs. *Veterinary Record* **120**, 79–83
- van der Gaag I (1988) The histological appearance of peroral gastric biopsies in clinically healthy and vomiting dogs. *Canadian Journal of Veterinary Research* **53**, 468–472
- van der Gaag I and Happe RP (1989) Follow-up studies by peroral gastric biopsies and necropsy in vomiting dogs. *Canadian Journal of Veterinary Research* **53**, 468–472
- Ward MP, Patronek GJ and Glickman LT (2003) Benefits of prophylactic gastropexy for dogs at risk of gastric dilatation-volvulus. *Preventive Veterinary Medicine* **60**, 319–329
- Washabau RJ (2003) Gastrointestinal motility disorders and gastrointestinal prokinetic therapy. *Veterinary Clinics of North America: Small Animal Practice* **33**, 1007–1028
- Williams J and Niles J (in preparation) *BSAVA Manual of Canine and Feline Abdominal Surgery*. BSAVA Publications, Gloucester
- Wolfe MM, Lichtenstein DR and Singh G (1999) Gastrointestinal toxicity of nonsteroidal antiinflammatory drugs. *New England Journal of Medicine* **340**, 1888–1899
- Wyse CA, McLellan J, Dickie AM, Sutton DGM, Preston T and Yam PS (2003) A review of methods for assessment of the rate of gastric emptying in the dog and cat. *Journal of Veterinary Internal Medicine* **17**, 609–621



# Diseases of the small intestine

Alexander J. German

## Introduction

Diseases of the small intestine (SI) are common in dogs and cats, and cause a range of signs including diarrhoea, vomiting and weight loss (or failure to thrive). The initial aim of diagnostic investigations is to exclude diseases of other organs or body systems; more specific diagnostic tests can then be used to obtain a definitive diagnosis. However, given the current limitations in testing, such a definitive diagnosis is sometimes difficult to achieve. In these circumstances treatment trials may provide more diagnostic information.

## Structure and function

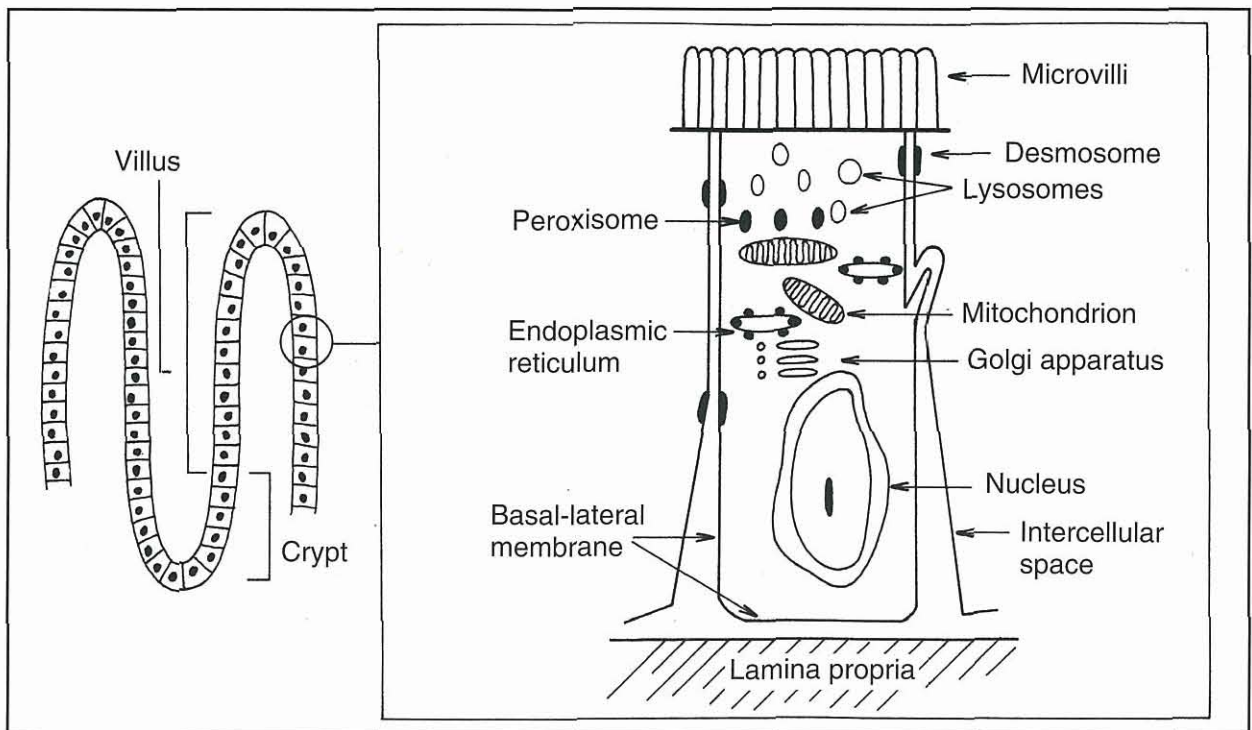
The SI is the principal site for digestion and absorption of nutrients, and absorption of electrolytes and fluids. The villi and microvilli contribute to the large surface area, which facilitates absorption and assimilation of nutrients. Enterocytes line the villi and are highly specialized

cells involved in the absorption processes (Figure 20.1). The brush border (or microvillus membrane, MVM) on the luminal surface of the enterocytes contains digestive enzymes, as well as carrier proteins that assist in transport of nutrients. The turnover of both enterocytes and microvillar proteins is influenced by luminal factors, such as pancreatic enzymes, bile salts and bacteria. New enterocytes are produced in the crypts of Lieberkühn and mature as they migrate up the villi. Those at the top of the villi become mature absorptive cells, whilst old enterocytes are sloughed from the villous tips. The whole process lasts 3–4 days in normal individuals.

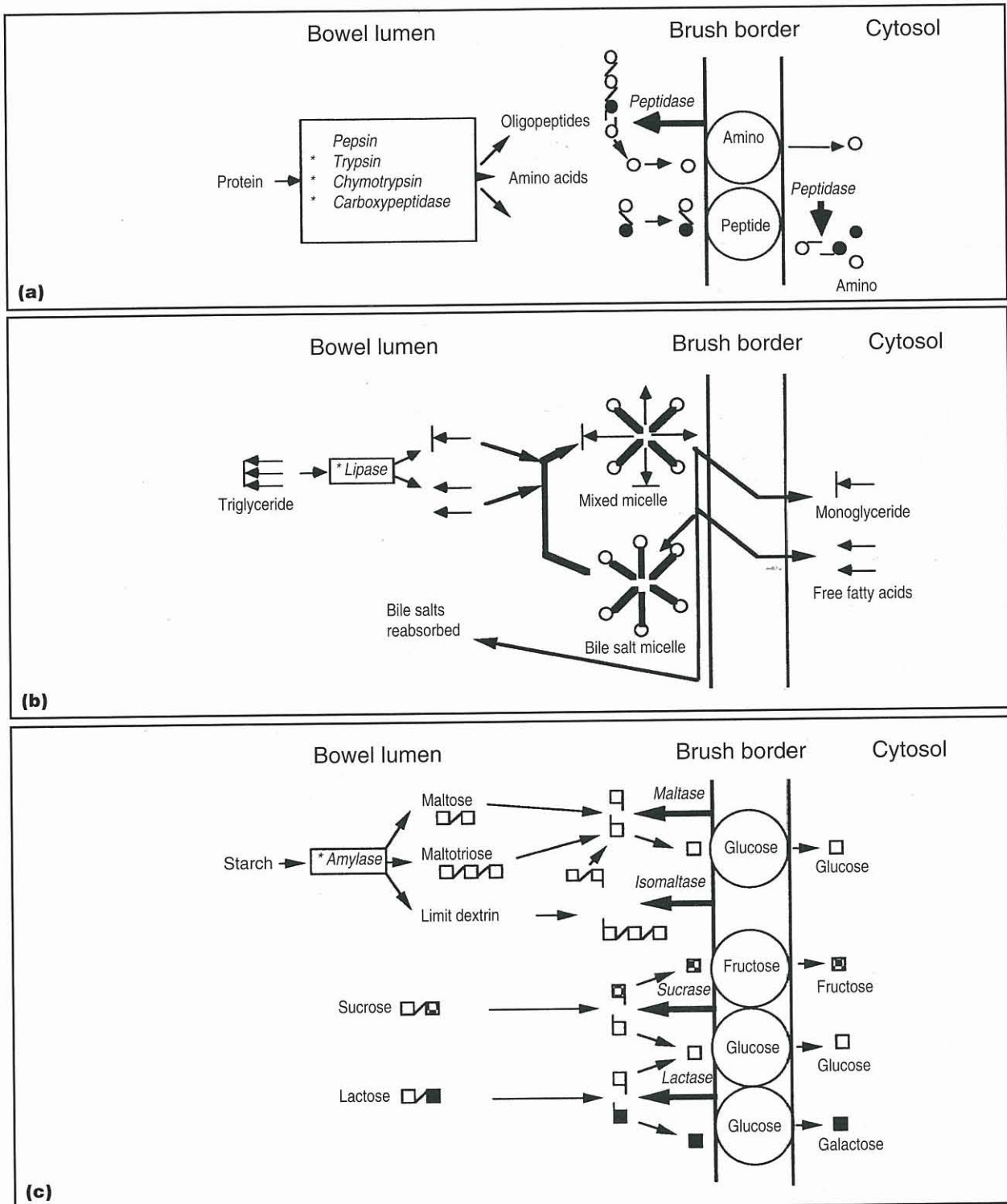
## Digestion and absorption of food

### Proteins

Protein digestion is initiated in the stomach by the enzyme pepsin, although this is inactivated once it has passed into the duodenum. Intestinal protein digestion is carried out by pancreatic and MVM enzymes, as summarized in Figure 20.2. Oligopeptides, dipeptides,



**20.1** Schematic diagram of the villus structure of the small intestine and an enterocyte.



**20.2** Diagrammatic summary of digestion and absorption. Note that galactose is carried on the glucose carriers. o = carrier; *italics* = enzyme; \* = pancreatic enzyme.

tripeptides and free amino acids are produced, which are absorbed by specific carriers in the MVM before entering the portal circulation.

**Lipids**  
The presence of bile acids and pancreatic enzymes (lipase, phospholipase and cholesterol esterase) are critical in lipid digestion and absorption in the small intestine (see Figure 20.2). After absorption, long chain

fatty acids are re-esterified to triglycerides, incorporated into chylomicrons and then enter the lymphatic system. Medium and short chain fatty acids were originally thought to be absorbed directly into the portal circulation but recent work has questioned this theory.

**Carbohydrates**  
Starch is the major dietary polysaccharide and is degraded by pancreatic amylase, predominantly to

maltose (see Figure 20.2). MVM enzymes digest maltose and other dietary disaccharides (lactose and sucrose) to constituent monosaccharides, which can then be absorbed by specific transporter mechanisms. Subsequent to this, the monosaccharides are transported across the basolateral membrane into the portal circulation.

**Fluids and electrolytes**

The net flux of fluid and electrolytes across the gastrointestinal (GI) tract reflects a balance between secretory and absorptive processes. There is net secretion of fluid in the proximal SI, whilst net resorption occurs in the distal SI.

**Intestinal secretion**

Fluid is secreted by the enterocytes within the crypts, mediated by electrogenic transport of chloride across the basolateral membrane and subsequent efflux through MVM chloride channels into the intestinal lumen.

**Absorption and transport processes**

Intestinal absorption of fluid and electrolytes is the combined result of passive absorption, active absorption and solvent drag. The relative importance of all of these mechanisms is site-dependent and differs along the length of the SI. There are also differences along the villus-crypt axis.

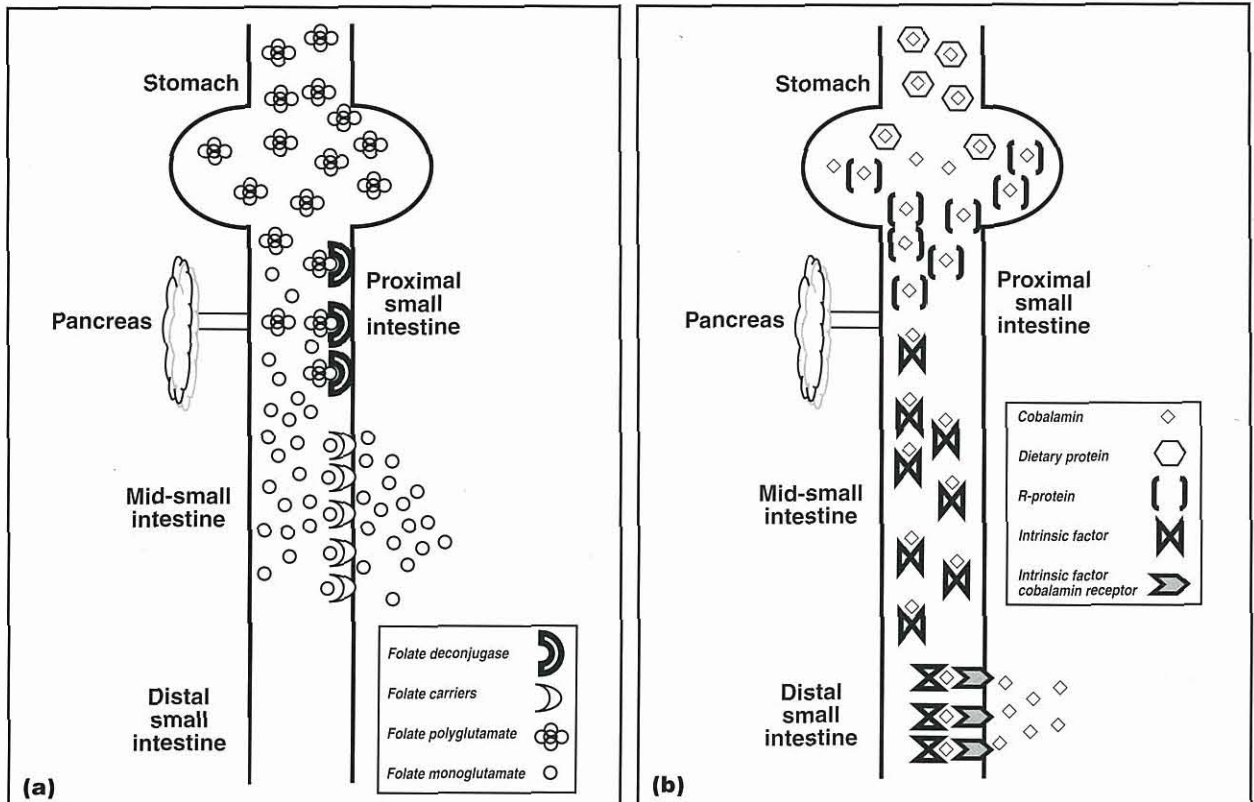
Significant fluid and electrolyte absorption also occurs in the colon (see Chapter 21), which helps to compensate in small intestinal disease. Diarrhoea, resulting from suboptimal small intestinal fluid absorption or excessive fluid secretion, can only occur when this colonic reserve is overcome. Further, signs of large intestinal disease can arise secondary to small intestinal disease, since products of abnormal small intestinal function (e.g. hydroxylated fatty acids and deconjugated bile acids) can impair colonic absorption or stimulate colonic secretion.

**Vitamin and mineral absorption**

**Vitamins**

**Lipid-soluble vitamins:** Lipid-soluble vitamins (A, D, E and K) are dissolved in mixed micelles and passively absorbed across the MVM into the lymphatic system. Therefore, any disease process resulting in malassimilation of fats may also lead to fat-soluble vitamin deficiencies, especially vitamin K.

**Water-soluble vitamins:** Water-soluble vitamins, notably most B vitamins, are absorbed by passive diffusion, facilitated transport or active transport (Figure 20.3) into the enterocytes and subsequently the portal circulation. The absorption of vitamin B12 (cobalamin) is complex and is discussed later in the chapter.



**20.3** Assimilation of folate and cobalamin. (a) Dietary folate is present in the diet as a conjugated form (with glutamate residues). This conjugate is digested by folate deconjugase, an enzyme on the microvillar membrane that removes all but one residue, before uptake via specific carriers situated in the mid-small intestine. (b) Following ingestion, cobalamin is released from dietary protein in the stomach. It then binds to non-specific binding proteins (e.g. 'R-proteins'). This complex is degraded by pancreatic proteases in the small intestine and cobalamin transfers on to intrinsic factor (IF), which is synthesized by the pancreas. Cobalamin-IF complexes pass along the intestine until the distal small intestine, where cobalamin is transported across the mucosa and into the portal circulation.

### Small intestinal microflora

The bacterial microflora increases in both diversity and mass from the duodenum to colon and is regulated by various factors including intestinal motility, substrate availability, bacteriocidal and bacteriostatic secretions (e.g. gastric, biliary and pancreatic secretions), and the presence of a functional ileocolic valve. Disruption of any of these factors may lead to qualitative or quantitative bacterial flora abnormalities.

The normal small intestinal flora is a diverse mixture of aerobic, anaerobic and facultative anaerobic bacteria. Common species include *Staphylococcus* spp., *Streptococcus* spp., *Enterobacteriaceae*, *Escherichia coli*, *Clostridium* spp. and *Bacteroides* spp., with a greater proportion of obligate anaerobic bacteria being reported in cats than in dogs. The total upper small intestinal bacterial counts of healthy cats range from  $10^2$ – $10^8$  colony-forming units (CFU)/ml, and are higher than those reported in humans ( $<10^3$ – $10^5$  CFU/ml). However, there is no clear consensus as to what constitutes a 'normal' SI population in healthy dogs, and some studies suggest that healthy dogs can harbour up to  $10^9$  CFU/ml bacteria in the proximal SI. Therefore, the 'cut-off' for normal flora in dogs and cats cannot be extrapolated from humans, and descriptions of small intestinal bacterial overgrowth (SIBO) in dogs using a cut-off value of  $10^5$  CFU/ml may be flawed.

The resident bacterial flora influences development of small intestinal microanatomy, aids in digestive processes, stimulates the development of the enteric immune system and can protect against pathogen invasion. Healthy individuals are immunologically tolerant of this stable flora, and loss of tolerance may contribute to the pathogenesis of chronic enteropathies, e.g. inflammatory bowel disease (IBD).

### Motility

Intestinal motility results from the coordinated contraction of smooth muscle in response to neuro-humoral and neurochemical input from the enteric nervous system. Segmental contractions slow passage of intestinal contents to allow mixing of nutrients and enzymes ensuring good digestion and absorption. Peristaltic contractions are primarily designed to propel ingesta aborally. Reduced segmental motility and peristalsis lead to rapid transit (causing diarrhoea) or delayed transit (resulting in ileus) of ingesta, respectively. Intestinal motility is characterized by three phases:

- Phase 1 – a quiescent phase
- Phase 2 – a phase of minor contractile activity
- Phase 3 – the final phase, incorporating the migrating myoelectric complex (MMC or 'housekeeper contractions').

The final phase is induced by motilin secretion, and is a short period of intense motor and contractile activity that sweeps undigested food and intestinal contents aborally. Motility in the fed state most closely resembles phase 2 fasting motility.

### Pathophysiology disease

Given that optimal small intestinal function relies upon the function of other organs and body systems (e.g. liver, pancreas and endocrine system), clinical signs can be the result of primary intestinal tract disease or secondary to disorders of other body organs. Further, infectious agents can cause intestinal dysfunction through a variety of mechanisms:

- Parvovirus destroys dividing crypt cells and causes severe villous atrophy, which affects absorption, secretion and mucosal barrier integrity. Clinical consequences are severe because repair cannot keep pace with ongoing damage
- Coronavirus only affects villus tips and damage is less severe, affecting absorption rather than crypt regeneration
- Bacteria, such as *E. coli*, may cause little or no structural damage but they can stimulate excessive intestinal secretion through endotoxin production.

The most frequent sign of small intestinal disease is diarrhoea, defined as passage of faeces containing excess water and resulting in an increase in fluidity, volume or frequency of bowel movements. A number of pathophysiological mechanisms may be involved:

- *Osmotic diarrhoea* results from water retention secondary to unabsorbed substances in the intestinal lumen, which itself is usually due to maldigestion and malabsorption
- *Secretory diarrhoea* results from hypersecretion of fluids and electrolytes by crypt enterocytes and occurs in response to stimulation by pathogenic bacterial toxins or hydroxylated fatty acids
- *Permeability diarrhoea* is characterized by increased mucosal permeability, often due to mucosal inflammatory or infiltrative disorders.
- *Motility disorders* are usually the result of decreased segmental motility rather than increased peristaltic activity.

However, in many cases multiple mechanisms may be involved. For example, inflammatory disorders result in production of inflammatory mediators, which can lead to diarrhoea through increased secretion, abnormal permeability and dysmotility.

### Diagnosis

Given that disease in other body systems can cause secondary intestinal disturbances, the history, physical examination and initial diagnostic investigations should aim to rule out such disorders and localize the disease to the small intestine (see Chapter 1 and Figure 20.4). The extent of further investigations required depends on a number of factors, especially the duration and severity of the problem. If clinical signs are acute and there are no systemic signs of illness,

Abdominal discomfort  
Anorexia  
Ascites  
Borborygmi  
Dehydration  
Diarrhoea  
Flatus  
Melaena  
Oedema  
Polyphagia  
Vomiting  
Weight loss/failure to thrive

**20.4** Clinical signs of small intestinal disease.

detailed investigations are rarely required and symptomatic therapy is usually sufficient (see below). However, when the clinical signs are chronic (i.e. exceeding 3 weeks in duration), systemic signs are present or the patient does not respond to symptomatic therapy, detailed diagnostic investigations are justified.

### History and clinical signs

The age, breed and gender assist in establishing the initial list of differential diagnoses. For example, young dogs are more prone to infectious disorders, whereas metabolic and neoplastic diseases are more common in middle-aged to older animals. Further, certain breeds are prone to different small intestinal disorders; e.g. German Shepherd Dogs are prone to antibiotic-responsive diarrhoea and Soft Coated Wheaten Terriers to protein-losing enteropathy.

The frequency, nature, severity and timing of clinical signs should be determined from the history, and it should then be possible to characterize the diarrhoea as 'small intestinal' rather than 'large intestinal' (see Chapter 1). However, such classification is not clear-cut because small intestinal disorders can provoke secondary large intestinal diarrhoea. Information on environment, past medical history and health status of 'in-contact' animals should also be determined. A thorough dietary history should be taken and in cases with weight loss the amount of food fed should be verified, especially if the diet has been altered during the problem.

### Physical examination

A physical examination helps the clinician to localize the disease process and enables its severity to be assessed. The latter can be determined by the demeanour, attitude and hydration status of the patient. The SI cannot be directly examined during physical examination but careful abdominal palpation can provide useful indirect information, especially in cats and small dogs. Rectal examination enables assessment of faecal characteristics and allows collection of material for faecal cytology, bacteriology and parasitology (see Chapters 16 and 22).

### Formulating a problem list and diagnostic plan

An initial problem list and set of differential diagnoses can be constructed from information derived from the

signalment, history and physical examination (see Chapter 1). The diagnostic plan must be flexible and take account of the problems recorded for the individual patient.

### Further investigations

#### Acute small intestinal disease

The extent of diagnostic investigations depends upon the nature and severity of the clinical signs. Most patients with acute diarrhoea are systemically well and diagnostic investigations are not required. However, some cases do require further investigations. Possible tests include a minimum database of packed cell volume (PCV), total protein, urine specific gravity, urea, glucose and electrolytes. Further, more detailed laboratory evaluations should include haematological and serum biochemical examination, urinalysis, faecal examination, diagnostic imaging (e.g. abdominal radiography and ultrasonography) and specific diagnostic procedures (e.g. targeted fine needle aspiration, endoscopy and exploratory coeliotomy). Other tests may include measurement of trypsin-like immunoreactivity (TLI), faecal enzyme-linked immunosorbent assay (ELISA) for parvovirus and an adrenocorticotrophic hormone (ACTH) stimulation test.

#### Chronic small intestinal disease

Diarrhoea is termed 'chronic' if clinical signs have been present for more than 3 weeks. Preliminary investigations include haematological analysis, serum biochemical analysis, urinalysis and faecal analysis (e.g. bacteriological and parasitological assessment). Additional preliminary tests may include assessment of serum thyroid hormone concentrations, ACTH stimulation test, and feline leukaemia virus (FeLV), feline immunodeficiency virus (FIV) and coronavirus status in cats.

Assuming no abnormalities are detected on initial investigations, specific tests including specialized laboratory investigations (TLI, folate and cobalamin), diagnostic imaging, biopsy and treatment trials are warranted. The exact approach and order of investigations will depend upon many factors including financial constraints, patient factors, available equipment and the wishes of the owner.

### Clinicopathological findings

#### Haematology

Red blood cell parameters will identify and characterize any associated anaemia, which may be the result of intestinal blood loss, secondary to 'chronic disease', or secondary to an associated haematopoietic disorder. Microcytosis, decreased mean corpuscular haemoglobin concentration (MCHC) and thrombocytosis are common with iron deficiency anaemia secondary to chronic GI blood loss associated with ulcerative, neoplastic or parasitic disease. Important differential diagnoses for microcytosis include congenital or acquired portovascular anomalies. In cats, hyperthyroidism and FeLV infection can cause macrocytosis.

When there is evidence of GI haemorrhage (Figure 20.5), a haemostatic profile should be performed. Once haemostatic disorders have been eliminated, the site and aetiology of the haemorrhage can be determined by a combination of diagnostic imaging, endoscopy and exploratory coeliotomy.

Origin of blood	Cause
Ingestion of blood	Oral; nasal; pharyngeal; haemoptysis
Gastrointestinal erosion/ulceration	Metabolic: uraemia, hepatic disease Inflammatory: gastritis, enteritis, hepatic encephalopathy, ulceration Neoplasia: smooth muscle, lymphoma, epithelial cell Paraneoplasia: mast cell tumours, hypergastrinaemia (gastrinomas, APUDomas) Vascular: arteriovenous fistula, aneurysms Ischaemia: hypovolaemia, hypoadrenocorticism, thrombosis, infarction, reperfusion injury Foreign bodies Drug-induced: non-steroidal anti-inflammatory drugs
Haemostatic disorders	Primary: thrombocytopenia, thrombocytopathy, vWD Secondary: factor deficiencies, coumarin toxicity Mixed: disseminated intravascular coagulation

**20.5** Causes of melaena. APUD = amine precursor uptake and decarboxylation; vWD = van Willebrand's disease.

Eosinophilia may arise in association with endoparasitism, hypersensitivity disorders, eosinophilic enteritis, hypoadrenocorticism and hypereosinophilic syndrome. However, mild eosinophilia can be a normal finding in German Shepherd Dogs. Neutrophilia with a left shift can be seen in inflammatory disorders, whilst leucopenia (concurrent with acute GI signs) might suggest canine parvovirus (CPV) infection or sepsis. Lymphopenia can indicate concurrent stress, lymphangiectasia or immunodeficiency syndromes. Atypical lymphocytes can occasionally be seen in cases of lymphoma.

**Serum biochemistry**

Serum biochemical analysis allows diseases of other body systems to be identified; i.e. renal, hepatic and endocrine disorders. Further, electrolyte measurement and acid–base status can identify metabolic consequences of GI disease. Concurrent hyperkalaemia and hyponatraemia is suggestive of hypoadrenocorticism, although other disorders (e.g. *Salmonella*, whipworms) can also demonstrate such changes. In addition, some patients with hypoadrenocorticism can have normal electrolyte concentrations (atypical hypoadrenocorticism), and an ACTH stimulation test should always be performed as part of the diagnostic investigations.

Serum biochemical analysis will also identify other systemic consequences of intestinal disease including hypoalbuminaemia, which usually arises in combination

with hypoglobulinaemia in protein-losing enteropathies (PLEs) (Figure 20.6). However, other causes of hypoalbuminaemia should be discounted including hepatic disease, protein-losing nephropathies (PLNs), malnutrition and blood loss. Mild to moderate increases in liver enzymes (e.g. alanine aminotransferase, ALT) can be seen in cats with hyperthyroidism, and in both dogs and cats with intestinal disease. Hypocholesterolaemia can be seen in malabsorptive diseases, PLEs and other enteropathies, which should be differentiated from exocrine pancreatic insufficiency (EPI) and hepatic disease. Mild to moderate bile acid elevations can occasionally be seen with intestinal disease, which may be secondary to reactive hepatopathy, or to marked elevations in unconjugated bile acids (see below). Hypoglycaemia can occasionally be seen as a paraneoplastic effect of GI smooth muscle tumours. Assay of serum TLI is essential in all cases since it will enable EPI to be excluded (see Chapter 23).

Type	Causes
Lymphangiectasia	Primary: intestinal, generalized Secondary: venous hypertension (e.g. right cardiac failure, hepatic cirrhosis)
Infectious	Parvovirus; <i>Salmonella</i>
Structural	Intussusception
Neoplasia	Lymphoma
Inflammatory	Inflammatory bowel disease: lymphoplasmacytic enteritis, eosinophilic enteritis, granulomatous enteritis
Endoparasitism	<i>Giardia</i> ; ( <i>Ancylostoma</i> )
Gastrointestinal haemorrhage	Hepatic encephalopathy; neoplasia; ulceration

**20.6** Protein-losing enteropathies.

**Urinalysis**

Urinalysis should always be performed in conjunction with serum biochemical analysis. Urine specific gravity assists in assessing hydration status and renal function, whilst protein measurement eliminates PLN from the differentials of hypoalbuminaemia. In cases with GI bleeding, the presence of haematuria suggests a systemic haemostatic disorder. Sediment analysis can detect ammonium biurate or bilirubin crystals, which may suggest hepatic dysfunction.

**Serology**

In cats, serological tests for FeLV and FIV should always be performed, whilst coronavirus serology may be useful in some cases. Parvovirus serology can sometimes be useful, although is often complicated by titres derived from routine vaccination.

**Faecal analyses**

Direct microscopic examination of a fresh faeces sample suspended in saline can detect *Giardia* trophozoite and *Coccidia* oocysts. Examination of a stained faecal smear may demonstrate clostridial

endospores (suggestive of *Clostridium perfringens* enteritis) although their significance is questionable, since recent studies have suggested no association between clostridial spores, toxin production and diarrhoea. Demonstration of faecal clostridial endotoxin may have more value in the diagnosis of *Clostridium*-associated diarrhoea. Faecal flotation with salt solutions will screen for parasitic ova of helminths (ascarids, whipworms and hookworms). Examination of multiple samples by zinc sulphate flotation is also recommended to detect *Giardia* cysts. *Giardia* antigen in faeces can be detected using commercially available ELISAs.

For dogs with acute gastroenteritis, a faecal ELISA is available to detect CPV infection. Routine bacterial culture will detect potential enteropathogens such as *Salmonella*, *Campylobacter* and *Clostridium* spp. Assays are now available for enteropathogenic *E. coli* (EPEC) virulence factors, although again the association between their presence and clinical disease has not yet been clearly established.

Given that melaena or fresh faecal blood is not always seen in cases with chronic GI blood loss, assessment of faecal occult blood can be useful. This test is sensitive but requires that a meat-free diet be fed for 72 hours prior to faecal collection, to avoid false-positive results. Certain drugs, such as cimetidine and iron supplements, can also give false-positive results.

Assessment of undigested or unabsorbed fats, unabsorbed starch and faecal proteolytic activity are unreliable, although measurement of faecal elastase (as a test of EPI) has recently been validated for dogs.

### Diagnostic imaging

Radiography and ultrasonography are most widely employed in clinical practice, although nuclear medicine techniques are sometimes available in research institutions.

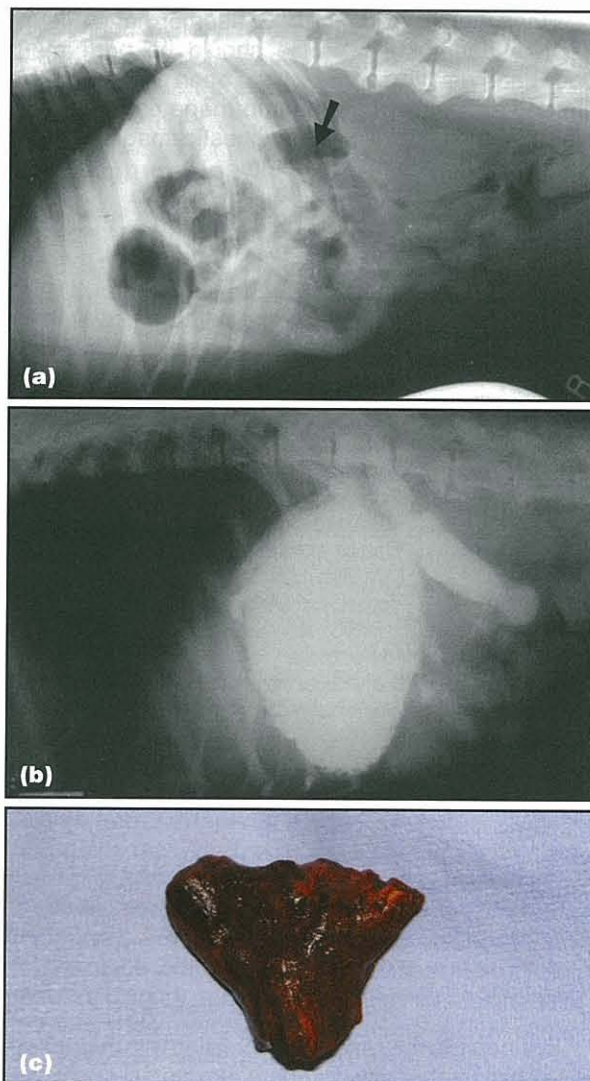
#### Radiography

Survey radiography of the abdomen may enable detection of foreign bodies, mass lesions, obstructive disorders, free peritoneal gas (e.g. due to GI perforation) and decreased serosal detail (due to peritonitis or free peritoneal fluid). Thoracic radiography will screen for metastatic spread (when appropriate), will eliminate oesophageal disease (when vomiting cannot be differentiated from regurgitation) and will assess for cardiac disease in cases with abdominal effusions.

Contrast radiography can be used as an adjunct in the investigation of GI disease. Barium studies can provide information on GI transit, obstructive lesions, intestinal mass lesions or disrupted mucosal integrity. However, a combination of good quality plain radiography and ultrasonography usually provide as much information (Figure 20.7). On occasion, barium-impregnated polyethylene spheres (BIPS) may detect partial or complete obstructions, or ileus.

#### Ultrasonography

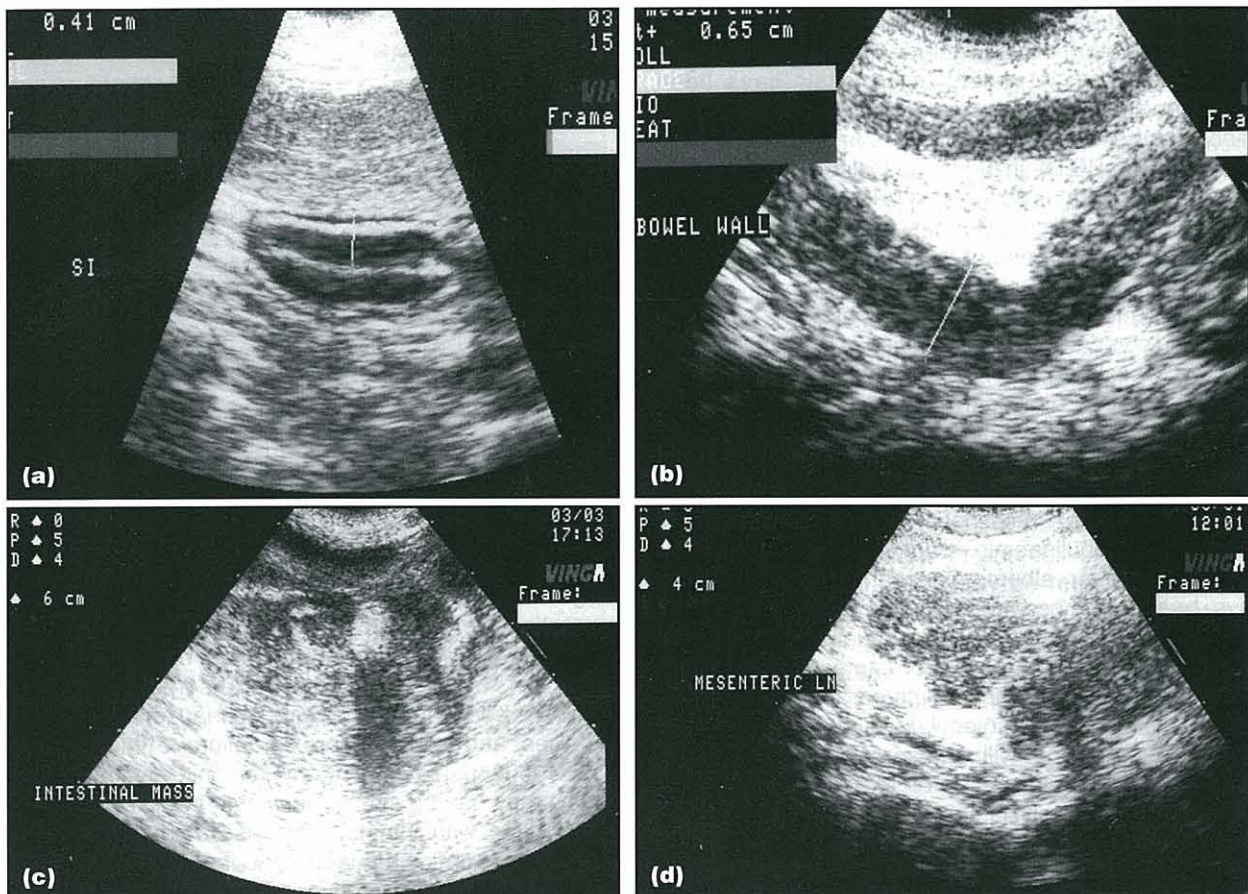
Abdominal ultrasonography is the non-invasive imaging modality of choice for the investigation of the GI tract



**20.7** Radiographic studies on a 10-month-old male Akita with severe vomiting and diarrhoea.

(a) Abnormal intestinal loop can readily be identified on close examination of the plain radiograph (arrowed). (b) Contrast radiography highlighted a dilated loop of small intestine and possible obstruction. (c) The intestinal obstruction was confirmed and found to be caused by a triangular wooden object. (Courtesy of AE Kerins and A Stell, Department of Veterinary Clinical Sciences, University of Liverpool.)

and associated organs (Figure 20.8). Intestinal mass lesions, intussusceptions, mesenteric lymphadenopathy and ascites can all be detected. The small intestinal wall normally has a five-layered appearance, which can be disrupted by focal lesions. Wall thickness can be measured and may be markedly increased in some infiltrative diseases and where mucosal oedema is present. Ultrasonography can eliminate the possibility of disease in other abdominal organs, such as the liver, pancreas, spleen and urogenital tract, and can provide information as to whether diffuse or focal disease is present. If diffuse disease is present, endoscopy is usually most suitable for further investigation and tissue sample procurement; exploratory coeliotomy is more applicable for focal intestinal disease or when other body organs may be involved.



**20.8** Examples of abdominal ultrasonography in cases of GI disease. (a) Ultrasonograph from a 3-year-old male German Shepherd Dog with chronic diarrhoea, demonstrating the normal appearance of the intestinal wall. (b) Ultrasonograph from a 14-year-old neutered male Domestic Shorthair cat with alimentary lymphoma. There is increased thickness of the bowel wall and loss of normal layering. (c) Ultrasonograph from a 10-year-old neutered male crossbred dog with an intestinal haemangiosarcoma (see Figure 20.17); the normal intestinal wall is grossly disrupted by a variably echoic mass. (d) Ultrasonograph from the cat in (c) demonstrating a mesenteric lymphadenopathy. (Courtesy of AE Kerins, Department of Veterinary Clinical Sciences, University of Liverpool.)

In addition, ultrasonography assists in targeting final needle aspiration of enlarged lymph nodes or mass lesions, which may provide a definitive diagnosis without the need for more invasive investigations.

### Tests of intestinal function

A variety of intestinal function tests are available, which may either confirm the presence of intestinal disease or identify consequences of the pathological process (e.g. abnormal, permeability, malabsorption, dysmotility). Occasionally, these tests provide a definitive diagnosis or preclude the need for further investigations, e.g. intestinal biopsy sample collection. However, most intestinal function tests have been adapted from similar tests in human medicine and have not adequately been validated for dogs and cats.

### Breath hydrogen analysis

Measurement of hydrogen concentrations in breath samples can give an indication of hydrogen production by intestinal bacteria. By sequentially determining breath hydrogen concentrations after a test meal, information on the site and amount of breath hydrogen production can be inferred. A number of protocols

have been described for assessing intestinal transit time, absorptive function and bacteriological disruptions. However, techniques remain experimental and have yet to be properly standardized for dogs and cats.

### Tests of intestinal absorption and permeability

The traditional method of assessing absorptive function was to administer a test meal (e.g. xylose or fat) and then measure the degree of absorption in serial blood or urine samples. However, such techniques are now rarely performed since they are cumbersome, insensitive and do not provide a definitive diagnosis.

One limitation to using a single-sugar solution, such as xylose, is that many extra-intestinal factors can affect the amount absorbed. These problems can largely be circumvented by the use of dual- or multiple-sugar solutions. Within the test cocktail, some sugars are absorbed via the paracellular route, whilst others are absorbed via the transcellular route. For sugars absorbed paracellularly, increased permeability causes increased absorption, sugars absorbed transcellularly are decreased if the surface area for absorption is decreased (e.g. villous atrophy). Therefore, by



combining sugars with different characteristics, extra-intestinal factors can be excluded since they counteract each other. A variety of protocols have been described and some commercial laboratories offer assay of these sugars. The excretion of orally administered  $^{51}\text{Cr}$ -EDTA in urine has also been used to evaluate intestinal permeability in dogs but the requirement for handling such radioactive markers limits the widespread use of this test.

**Tests of gastrointestinal protein loss**

The gold standard for determination of intestinal protein loss is faecal excretion of  $^{51}\text{Cr}$ -labelled albumin, although this test is limited by the fact that the compound is radioactive. Low albumin concentrations are reasonably specific for intestinal protein loss, once renal loss, blood loss and lack of hepatic production have been excluded. Further, intestinal protein loss is more likely when hypoglobulinaemia accompanies hypoalbuminaemia. However, albumin concentrations are insensitive because concentrations only decline once the capacity for increased hepatic production is overcome.

More recently, an assay for canine  $\alpha_1$ -proteinase inhibitor ( $\alpha_1$ -PI) has been validated.  $\alpha_1$ -PI is a serum protein with a similar molecular weight to albumin and intestinal protein loss will, therefore, lead to loss of both proteins at a similar rate. Given that  $\alpha_1$ -PI is relatively resistant to proteolysis, it can be measured in the faeces. Preliminary work suggests that this is a more sensitive marker for intestinal protein loss than serum albumin concentrations, although the assay is so sensitive that it will also detect  $\alpha_1$ -PI present because of blood in the stool or rectal trauma caused by sample collection using digital evacuation. The requirement for collection of three fresh faecal samples and for timely transport to a laboratory located outside the UK has so far limited its use.

**Serum folate and cobalamin**

Measurement of folate and cobalamin concentrations has long been used to assess intestinal absorptive function in dogs, and is now available for cats. Such assays are most useful in documenting malabsorption secondary to intestinal or pancreatic disease. They can also be used to document secondary SIBO, although their validity for this use is questionable given that alterations in these parameters arise for many different reasons (Figure 20.9). Circulating concentrations of folate and cobalamin reflect the balance between dietary intake, bacterial metabolism (utilization and production), intestinal absorption and body losses. Serum folate and cobalamin concentrations must be interpreted with caution. Before abnormalities can be attributed to intestinal disease, EPI must be excluded and oral supplementation, parenteral administration and changes in dietary vitamin content must be taken into account. Some medications, such as sulfasalazine, can also affect folate measurements, although this is rarely likely to be of clinical significance.

Low serum cobalamin concentrations can be observed in EPI due to a deficiency of intrinsic factor secretion, as well as with certain intestinal diseases. Given that the carrier mechanism for cobalamin ab-

Substrate	Increased	Decreased
Cobalamin	Parenteral supplementation High dietary intake?	Ileal disease Ileal resection Intestinal bacterial metabolism Exocrine pancreatic insufficiency
Folate	High dietary intake Coprophagia Parenteral supplementations Intestinal bacterial metabolism Exocrine pancreatic insufficiency	Proximal to diffuse SI disease Drugs, e.g. sulfasalazine Increased intestinal pH? Dietary deficiency (rare)

**20.9** Factors influencing serum concentrations of cobalamin and folate.

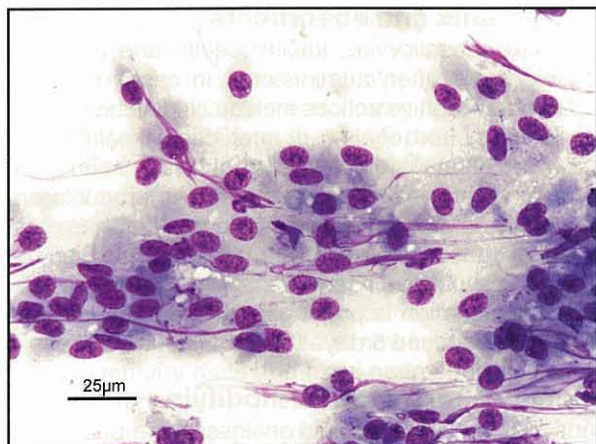sorption is present in the distal SI, disease conditions affecting this region cause the most marked deficiencies. An hereditary selective malabsorption of cobalamin has been reported in Giant Schnauzers and Border Collies, and causes anorexia, failure to thrive, anaemia, leucopenia and methyl-malonic aciduria. Shar Peis may have a similar deficiency, whilst some cats and dogs with intestinal disease also have severe cobalamin deficiency and concurrent methyl-malonic aciduria. Low cobalamin concentrations are relatively common in dogs with distal small intestinal disease (although the deficiency is often less severe than in cats) and while there is methyl-malonic acidemia, indicating cellular cobalamin deficiency, overt clinical consequences have not been documented. Low serum folate concentrations can occur in canine and feline intestinal disease, although such deficiencies are uncommon and usually mild. High folate concentrations can be the result of high dietary intake, intestinal bacterial metabolism or EPI.

**Intestinal biopsy**

**Sample collection**

**Endoscopy:** A comprehensive review of endoscopic equipment and techniques is given in Chapter 4. Endoscopy is most suited to the investigation of diffuse disorders of the SI and is also the initial method of choice in severely hypoproteinaemic cases, where wound dehiscence is a concern. Samples that can be collected during endoscopy include tissue samples for histopathological examination, brush collection or squash preparation for cytological assessment (Figure 20.10) and duodenal juice for quantitative bacteriology.

**Surgical biopsy:** In some cases tissue samples are better collected by surgical biopsy during exploratory coeliotomy or laparoscopy (if available). With this method larger full-thickness samples can be collected from multiple regions and the remainder of the abdomen can be examined; therefore, the chances of obtaining an accurate diagnosis are increased.



**20.10** Appearance of a duodenal biopsy sample acquired via brush collection for cytological assessment. Rapid Romanowsky stain (Rapi-Diff II).

Indications for surgical biopsy include:

- Investigation of focal rather than the diffuse process
- Lack of endoscopic equipment or expertise
- Failure to achieve an appropriate diagnosis at endoscopy
- In cases where therapy in addition to diagnosis may be required.

Biopsy samples should **always** be collected, even if organs appear grossly normal (see Chapter 5).

#### Histopathological interpretation

Histopathological assessment of intestinal biopsy specimens remains the gold standard for diagnosis of intestinal disease (see Chapter 5). Alternate methods by which the intestinal mucosa can be examined include: electron microscopy; characterization of immune cell populations by immunohistochemistry or flow cytometry; cytokine expression by reverse transcriptase polymerase chain reaction (RT-PCR); and assessment of T cell clonality. However, such procedures are largely confined to research centres.

#### Treatment

The initial management of acute and chronic diarrhoea is symptomatic and supportive. The treatment employed is tailored to suit the individual case, based on clinical findings and the initial laboratory database. Animals with chronic diarrhoea have usually failed to respond to symptomatic therapy, and emphasis should be placed on obtaining a definitive diagnosis. Therapeutic options include:

- Fluid therapy
- Dietary modification
- Absorbents and protectants
- Secretion or motility modifiers
- Antibacterials
- Probiotics and prebiotics
- Immunosuppressive medication.

#### Fluid therapy

The reader is referred to specific texts for more details on fluid therapy. Cases with mild dehydration and no vomiting can be treated with oral rehydration therapy, which can be provided as free water or as a balanced electrolyte solution if tolerated. However, the success of oral rehydration should be monitored closely, and aggressive parenteral therapy provided if problems do not resolve.

In cases that are dehydrated and vomiting, parenteral fluid therapy is preferable. The choice of fluid, and requirement for potassium supplementation, depends on the individual case and results of preliminary diagnostic tests, although lactated Ringer's solution is a sensible empirical choice. The aim is to replace existing deficits, supply maintenance fluid requirements and compensate for ongoing losses. The intravenous route is usually best, but the intraosseous route is a suitable alternative in puppies or kittens. More aggressive fluid therapy may be required if there is evidence of decreased tissue perfusion or shock. In these circumstances crystalloids or colloids (e.g. hydroxy-ethyl starch) may be required. Plasma or colloids are most suitable when hypoproteinaemia is present (e.g. total protein <40 g/l; albumin <15 g/l). All animals receiving fluid therapy for diarrhoea must be monitored closely (see Chapter 26).

#### Dietary modification

The most appropriate diets for patients with intestinal disease have not been determined scientifically with controlled trials and most current recommendations are based on 'commonsense' and anecdotal evidence.

#### Acute diarrhoea

The conventional wisdom is that acute diarrhoea is best treated with an initial period of intestinal rest followed by gradual reintroduction of food. In this regard, the animal is starved for 24–48 hours and subsequently offered an easily digestible diet (e.g. boiled chicken and rice) in small frequent meals for 3–5 days. The original diet can then be reintroduced over a further 3–5 days by gradually mixing increasing amounts with the digestible diet. An appropriate digestible diet should be low in fat and fibre, and contain easily digestible components. Suitable components for home-prepared diets in dogs include boiled chicken or low fat cottage cheese together with boiled rice. Since cats have a lower tolerance for complex carbohydrates and a higher tolerance for dietary fat, pure poultry diets are preferable. The diet need not be nutritionally complete since it will only be fed for a short period.

The concept of intestinal rest has been challenged recently because studies in human infants have shown that 'feeding through' diarrhoea promotes recovery. Further, inclusion of 'enterocyte fuels' (e.g. glutamine) may promote recovery and reduce bacterial translocation. Recent work by Mohr *et al.* (2003) in dogs with parvovirus has suggested that early enteral feeding does lead to improvement in some clinical parameters (e.g. bodyweight measurements), although time to recovery from signs of diarrhoea is not altered. However, the use of such dietary regimes in dogs and cats is

difficult when vomiting is a significant clinical sign. More work is required before such a strategy can be recommended for all aetiologies of acute diarrhoea.

### **Chronic diarrhoea**

A highly digestible diet, balanced in micronutrients and restricted in fat is usually recommended for dogs. Cats may benefit more from carbohydrate restriction since their capacity for carbohydrate digestion is small and perhaps becomes limiting more readily than in dogs when there is small intestinal disease. The diet must be palatable and is best fed in small frequent meals. In some circumstances, it is sensible to restrict protein intake to a single source, especially if an adverse food reaction is a possibility.

High digestibility assures that dietary components can be readily assimilated in the face of suboptimal digestive functions. Efficient absorption also minimizes the substrate that is available to intestinal bacteria, or available for commanding an osmotic potential. Fat restriction has been recommended in dogs since unassimilated fatty acids can undergo hydroxylation and stimulate electrolyte secretion, although there may be a tendency to cause weight loss. However, the benefit of fat restriction in cats has been challenged. Supplementation with omega 3 fatty acids may also be of benefit in treating inflammatory diseases, but there is no direct evidence confirming efficacy in intestinal disorders of companion animals.

Protein should be of high biological value and preferably restricted to a single protein source. Given the possibility of an adverse reaction to food, a novel dietary protein should be chosen and possibilities include cottage cheese, egg, rabbit, venison, chicken, fish and turkey. Hydrolysed protein diets are an alternative and are based upon chemically treated, low molecular weight protein derivatives of chicken or soy. In theory, such diets should be less antigenic, but there is no clear evidence to prove that adverse immune responses do not still occur, and adverse reactions caused by food intolerance may arise. Gluten is perceived to be a common food allergen and thus most formulated diets are now gluten-free. This recommendation is based upon extrapolation from coeliac disease in humans, and on a cohort of Irish Setters with a gluten-sensitive enteropathy. Although gluten is a common allergen, other allergens may be equally, if not more, common and the choice of diet should be tailored to the individual patient. If a home-prepared diet is to be used, boiled rice or potatoes are suitable options for carbohydrate source in dogs. However, cats may not tolerate as much carbohydrate in their diet, so carbohydrate is better included based on palatability and response.

Some clinicians recommend home-prepared diets, whilst others prefer a commercial diet. Home-prepared diets have the advantage that the exact ingredients can be better controlled. However, it places an additional burden on the owners and may lead to poor compliance. In addition, since such diets are not balanced for micronutrients they are not suitable for long-term use. The benefits of commercial diets are in consistency of contents, the fact that the diet is properly balanced and the ease of use, which should ensure better compliance.

### **Protectants and absorbents**

Bismuth subsalicylate, kaolin, pectin and activated charcoal are often administered in cases of acute diarrhoea. Putative actions include binding bacteria or endotoxins, and coating or protecting the intestinal mucosa. Although efficacy has not clearly been demonstrated for most GI diseases, these products are generally safe and thus preferable to other therapies, such as anticholinergics or antibacterials. Bismuth products should be used with caution in cats as salicylate elimination is prolonged, and therapy in dogs should not exceed 5 days (at 1 ml/5kg p.o. q8h).

### **Motility and secretion-modifying agents**

Anticholinergics and opioid analgesics are often used for symptomatic management of acute diarrhoea. Anticholinergics can potentiate ileus and are not recommended. Opioids are thought to act by decreasing intestinal secretion, restoring segmentation and promoting absorption, although effects on motility are possible. Loperamide and diphenoxylate can be used for symptomatic management of acute diarrhoea in dogs. Their use is contraindicated if infectious diarrhoea is present.

### **Antimicrobials**

Antimicrobials should be used only when there is a clear indication:

- Bacterial or protozoal infection is documented e.g. *Salmonella*, *Campylobacter*, *Clostridium*, enteropathogenic *E. coli* (EPEC) and *Giardia*. However, treatment for some of these agents is controversial (see below)
- Presence of sepsis, bacteraemia and shock
- Compromised mucosal barrier, as suggested by increased permeability, haematochezia or melaena
- Evidence of immunosuppression, e.g. neutropenia
- Treatment trial for antibiotic-responsive diarrhoea, once tests have eliminated other possible causes
- Adjunctive therapy for IBD.

A four-quadrant approach may be required in cases with septicaemia where the cause is unknown and a combination of bactericidal intravenous drugs is required. A suitable combination would be potentiated amoxicillin, combined with metronidazole for anaerobic cover and a fluoroquinolone for Gram-negative bacteria. Alternatives for anaerobic cover include clindamycin, penicillin or ampicillin, whilst gentamicin would be a suitable alternative for Gram-negative cover.

### **Probiotics and prebiotics**

A probiotic is a living organism that, when administered orally, exerts health benefits beyond those of inherent basic nutrition. Probiotics can directly antagonize pathogenic bacteria and modulate innate (e.g. phagocytic activity) or specific (e.g. secretory IgA) mucosal immune responses. Traditionally, live yoghurt has been recommended but preparations are now commercially available for use in dogs and cats. Some studies have demonstrated the presence of

probiotic bacteria in the faeces during administration but not after the products are discontinued, suggesting that they do not become part of the stable resident flora. Nevertheless, there is emerging evidence to support their use. Given that such products are unlikely to be harmful their use is preferable to indiscriminate use of antimicrobials.

Prebiotics are selective substrates for a limited number of 'beneficial' species and therefore cause alterations in the luminal microflora. Most are non-digestible carbohydrates, such as inulin and fructo-oligosaccharides. Prebiotics are now incorporated into some veterinary diets and have been shown to alter colonic flora, although their effects on small intestinal flora are questionable. Prebiotics may assist in the treatment of both acute and chronic diarrhoea, but more work is required before their use can be justified. Since probiotics and prebiotics can modulate mucosal immune responses, they may also be beneficial in chronic enteropathies that involve immune dysregulation, e.g. IBD and dietary hypersensitivity. However, more work is required.

### Anti-inflammatory and immunosuppressive therapy

Anti-inflammatory or immunosuppressive therapy is indicated for cases of chronic diarrhoea caused by moderate to severe idiopathic IBD or lymphangiectasia. The first choice group of drugs are glucocorticoids, such as prednisolone. For idiopathic IBD an immunosuppressive dose is recommended (e.g. 2–4 mg/kg per day in divided doses), which is gradually tapered (over weeks to months) once remission is achieved. Therapy can sometimes be discontinued altogether, although lifelong therapy may be required. Where traditional glucocorticoids are poorly tolerated budesonide can be considered, although its efficacy has not yet been proven in companion animals and it is expensive. It is an enteric-coated, locally active steroid, 90% of which is removed on first-pass through the liver. Preliminary studies have shown efficacy in dogs, although a recent study demonstrated profound effects on the hypothalamic–pituitary–adrenal axis despite the high first-pass metabolism in the liver.

If glucocorticoids alone are ineffective, a second drug can be added. Azathioprine (at 2 mg/kg p.o. q24h initially) is most commonly used, although its onset of action may be delayed. Haematological parameters must be monitored regularly whilst on therapy to minimize the potential for development of bone marrow suppression. Azathioprine is not recommended for cats, where chlorambucil (at 2–6 mg/m<sup>2</sup> p.o. q24h) is a suitable alternative.

Other immunosuppressive drugs include methotrexate, cyclophosphamide and ciclosporin. Methotrexate is effective in the treatment of human Crohn's disease, but it is not widely used in companion animals. Cyclophosphamide has few advantages over azathioprine and is rarely used. Ciclosporin has demonstrated efficacy in anal furunculosis, but is expensive and there has been little documentation of its use in companion animal IBD.

## Disorders of the small intestine

### Haemorrhagic gastroenteritis

Haemorrhagic gastroenteritis (HGE) is characterized by acute haemorrhagic vomiting and diarrhoea accompanied by marked haemoconcentration. Although the exact aetiology is not known, it may be related to *Clostridium perfringens* enterotoxigenesis or an allergic reaction.

### Clinical signs

Small-breed dogs, such as Toy and Miniature Poodles and Miniature Schnauzers, are most frequently affected. Clinical signs include acute haemorrhagic vomiting and diarrhoea; signs can be progressive with vomiting preceding diarrhoea. Other signs include depression and abdominal discomfort, but pyrexia is rarely seen. After the syndrome develops rapid fluid shifts occur from the intravascular compartment, with loss of protein and fluid into the intestinal tract. Thus, hypovolaemia develops rapidly but the intracellular compartment as a whole is minimally affected, and therefore signs of dehydration (e.g. decreased skin turgor) may not be evident...

### Diagnosis

In HGE, the PCV is usually greater than 60, which contrasts with the lower PCV expected in other similar conditions, e.g. parvoviral enteritis. Total protein concentrations are usually normal or increased, but proportionately lower than would be expected from the corresponding PCV increase (as a consequence of the intestinal protein loss). There is no leucopenia (in contrast to parvovirus infection), whilst radiography and other clinicopathological tests are usually unremarkable. On faecal analysis *C. perfringens* spores or enterotoxin may be evident, but often neither is detected. Since both spores and endotoxin can be detected in normal dogs, care is needed in interpretation of these findings.

### Treatment

Treatment should be instigated prior to performing detailed diagnostic investigations. Aggressive intravenous fluid therapy is essential and, given that marked intestinal protein loss may occur, colloidal solutions or plasma are appropriate to replace the intravascular deficits. Crystalloids can then be used to complete the rehydration process. Rapid improvement is usually noted within a few hours, although clinical signs may take several days to resolve. Since the mucosal barrier is compromised, antibacterial therapy is justified with intravenous bactericidal drugs. Ampicillin is effective against *C. perfringens*, but a 'four-quadrant approach' (e.g. covering against Gram-positive, Gram-negative, aerobic and anaerobic bacteria) may be required given the potential for sepsis. Patients that do not respond adequately to therapy should be re-evaluated for other causes, e.g. parvovirus enteritis, intussusception or intestinal obstruction. Cases are initially maintained nil by mouth, but a highly digestible diet (e.g. boiled chicken and rice) can be introduced once vomiting has ceased.

### Prognosis

The prognosis is usually good with most cases making a complete recovery, as long as there is no concurrent hypoproteinaemia or sepsis. However, recurrences may occur.

### Acute diarrhoea induced by diet, drugs or toxins

Diarrhoea induced by diet is thought to be the most common cause of acute, self-limiting diarrhoea in small animals. Potential mechanisms include rapid dietary change, dietary indiscretion, dietary intolerance and food poisoning. Acute diarrhoea can also be caused by administration of drugs (e.g. antibacterials or NSAIDs) or toxins (e.g. insecticides), although other clinical signs may be recognized. Historical information may enable the cause to be established, but in most circumstances a definitive diagnosis cannot be made. Cases will usually respond to withdrawal of the inciting cause and to the employment of standard therapeutic principles.

### Infectious causes of diarrhoea

Enteric infections are common in animals that are young, immunocompromised or immunologically naïve. Animals housed in colony environments are also predisposed, especially when conditions are unsanitary. The most common potential infectious agents are:

- Viral:
  - parvovirus
  - coronavirus
- Bacterial:
  - *Salmonella*
  - *Campylobacter*
  - *Clostridium* spp. (*C. perfringens* and *C. difficile*)
  - Enteropathogenic *E. coli*.
- Parasitic:
  - Helminth infections
  - *Giardia*
  - *Coccidium*.

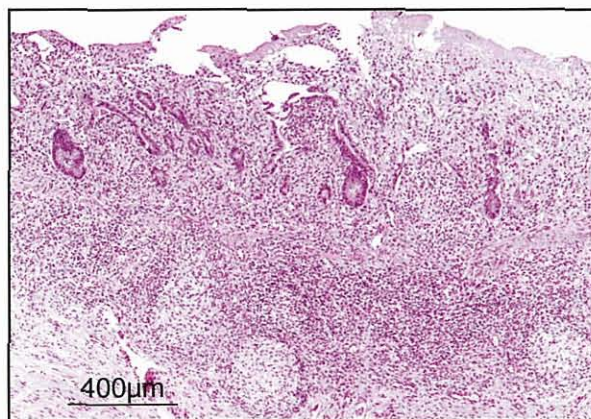
Other infectious agents (e.g. fungi) are possible, but are not prevalent in the UK. Nevertheless, small animal clinicians should be aware of exotic diseases and consult other reference texts when there is a history of overseas travel. Additional potential infectious agents include other viruses (e.g. paramyxoviruses, adenovirus, FeLV, FIV, astroviruses, rotaviruses), bacteria (e.g. *Shigella*) and opportunist yeast infections.

In most cases identification of an infectious agent is easy, but it is more difficult to decide whether this really is the cause of clinical signs. Whilst treatment of such agents seems intuitive, this may lead to the development of antibiotic resistance and thus be inappropriate. However, given that many agents may have zoonotic potential, treatment may be prudent.

### Viral enterides

**Canine parvovirus:** Canine parvovirus type 2 (CPV-2) is a highly contagious cause of acute enteritis. Infection occurs via the faecal–oral route, and infected animals shed billions of virus particles in faeces during the

acute phase of illness and for approximately 2 weeks afterwards. CPV-2 is stable in the environment and can remain infectious for long periods of time. Given its affinity for rapidly dividing cells, CPV-2 targets intestinal crypt cells, bone marrow and secondary lymphoid tissues once infection becomes established. The consequences are intestinal crypt necrosis, severe vomiting, haemorrhagic diarrhoea, leucopenia and lymphoid depletion (Figure 20.11). Clinical signs usually develop approximately 5 days after exposure.



**20.11** Photomicrograph of small intestinal lymphoid tissue from a dog with confirmed canine parvovirus infection. There is severe disruption of the structure of the overlying mucosa. Although the architecture of the Peyer's patch remains, the number of lymphoid cells is severely depleted. H&E stain. (Courtesy of R Fox, Department of Veterinary Pathology, University of Liverpool.)

**Clinical signs:** Associated clinical signs vary in severity and include anorexia, depression, dehydration, pyrexia, vomiting and diarrhoea (which is usually profuse and often haemorrhagic). Shock, endotoxaemia (due to secondary bacterial septicaemia), hypothermia, jaundice and disseminated intravascular coagulation (DIC) may all develop. Death is usually secondary to dehydration, electrolyte imbalances and endotoxic shock from overwhelming bacterial infection through the damaged intestinal mucosal barrier due to leucopenia. The incidence is highest in puppies between weaning and 6 months of age, corresponding to a window of susceptibility between the protection provided by passive immunity (from maternally derived immunoglobulin) and acquired immunity (from vaccination). Further, certain dog breeds are particularly susceptible (e.g. Rottweiler and Dobermann). Other predisposing factors include environmental factors (e.g. colony environment, overcrowding, poor sanitary conditions) and the presence of concurrent infections (e.g. endoparasites, canine distemper virus, coronavirus, *Salmonella* and *Campylobacter*). Rarely, parvovirus infection can lead to other syndromes, such as the development of myocarditis, in puppies as a result of *in utero* infection.

**Diagnosis:** Clinical signs may be suspicious for CPV-2 infection, although haemorrhagic diarrhoea is not pathognomonic. Differential diagnoses include acute salmonellosis, bacterial sepsis, foreign bodies and HGE. Infection should be suspected if acute GI signs, depression and pyrexia are present, especially if the

subject is unvaccinated or has been in contact with infected dogs. The majority of cases (60%) are severely panleucopenic and increasing severity is correlated with decreasing survival rates. Biochemical abnormalities are not pathognomonic and include hypokalaemia, hypoglycaemia, pre-renal azotaemia, hyperbilirubinaemia and increased liver enzymes. Diagnostic imaging may help to rule out other differential diagnoses.

Definitive diagnosis relies upon demonstrating the presence of CPV-2 virus (or antigen) in the faeces by ELISA, which is offered by many commercial laboratories. Other methods of diagnosis include histopathological assessment of tissues, where inclusion bodies can be recognized. Some laboratories offer immunohistochemical confirmation of the presence of virus particles, whilst serology may provide evidence of exposure to CPV-2 in unvaccinated dogs.

**Treatment:** Anti-endotoxin therapy has been used in some studies but efficacy is unproven. In contrast, administration of recombinant feline interferon- $\omega$  is proven to improve clinical signs and reduce mortality. This agent has antiviral and immunomodulatory properties, but its exact mechanism of action is unclear and its use may be limited by the cost.

Supportive therapy includes the use of aggressive intravenous fluid therapy (e.g. lactated Ringer's solution with supplemented potassium as required). In some cases, dextrose should be added to the fluid infused to a final dose of 2.5 g/100 ml. Colloids, plasma infusions, whole blood or blood substitutes may be required in some cases. Once the animal is adequately hydrated and vomiting has ceased, oral fluid therapy can be instigated.

Antibiotics are important given the associated leucopenia, and a four-quadrant approach is sensible. Initially, affected individuals should be maintained nil by mouth, but a standard dietary protocol (as for other acute enteropathies) can be instigated once vomiting has ceased. However, early micro-enteral nutrition (e.g. GI delivery of small amounts of water, electrolytes and readily absorbable nutrients, such as glucose, amino acids and glutamine) may minimize bacterial translocation and speed recovery. Other therapies include anti-emetics, such as metoclopramide, domperidone or phenothiazines, e.g. chlorpromazine. Recombinant human granulocyte colony stimulating factor (G-CSF) may correct the concurrent neutropenia but, whilst neutrophil counts increase, there is no improvement in survival.

Exposure of at risk animals to the virus should be minimized, especially in colony situations. This can be achieved by maintaining strict hygiene and disinfection (e.g. household bleach (sodium hypochlorite  $\leq 0.05\%$  w/v) at a dilution of 1:30 to 1:32). Appropriate vaccination regimes are also critical and most modern inactivated virus vaccines provide excellent protection after two doses. Many vaccine manufacturers now claim that adequate protection can be achieved with protocols involving the final dose at 12 weeks. Yearly boosters are still recommended by most vaccine manufacturers, although studies to determine the optimum revaccination interval are ongoing.

**Prognosis:** The majority of cases recover if dehydration and sepsis are treated appropriately. However, interferon therapy improves the probability of survival and speed of recovery. Severe leucopenia is associated with higher mortality, whilst other complicating factors include hypoglycaemia, hypoproteinaemia, anaemia, intussusception and secondary infections.

**Feline parvovirus:** Feline parvovirus (feline panleucopenia) is a severe highly contagious infection in cats. Sporadic cases and outbreaks are still seen, most commonly in young animals, colony environments, unvaccinated animals and in feral populations. CPV-2 can also infect cats and cause a mild clinical disease. Transmission and pathogenesis of feline panleucopenia infection are similar to that of CPV-2.

**Clinical signs:** Kittens have the highest incidence of generalized infections and the greatest mortality rate. Clinical signs include anorexia, pyrexia, depression, dehydration, vomiting and haemorrhagic diarrhoea. Thickened, painful intestinal loops may be detected on abdominal palpation. Given the associated neutropenia, infected animals are prone to sepsis and endotoxaemia. Early *in utero* infections can cause stillbirth, mummification, foetal death and abortion. Late *in utero* and perinatal (first 1–2 weeks of life) infections may lead to cerebellar hypoplasia.

**Diagnosis:** Diagnosis is similar to that for CPV-2 infection in dogs. Diagnosis is confirmed by documenting parvovirus antigen in faeces (ELISA), histopathological and immunohistochemical evaluation of tissues, or serological assessment (in unvaccinated animals).

**Treatment:** Options for treatment are the same as described for CPV-2 infection. Recombinant feline interferon therapy is likely to be useful for treatment, although no published data yet exist.

**Prognosis:** Mortality is high in young kittens (50–90%). Prognosis is worst when infection is associated with hypothermia, secondary bacterial infection, jaundice and DIC. The disease can be prevented by limiting exposure of the virus to susceptible individuals (e.g. hygiene and disinfection protocols) and by vaccination. Modified live vaccines can provide a more rapid onset of protection than killed vaccines, but cannot be used in pregnant queens and kittens <4 weeks age, since cerebellar hypoplasia results.

**Canine coronavirus:** Canine coronavirus (CCV) may cause acute gastroenteritis in dogs, especially in colony situations since high population densities promote spread of large doses of the virus. Transmission occurs via the faecal–oral route and most infections are subclinical, although some cases develop severe clinical signs. The virus invades enterocytes at the villus tips causing mild villus destruction and diarrhoea. Shedding of virus can occur for months after infection in recovered dogs.

Clinical signs are seen only in severe cases and include anorexia, depression, vomiting and watery-

to-mucoid diarrhoea. However, in contrast to CPV-2 infection, pyrexia and leucopenia are unusual. Faecal electron microscopy can demonstrate the presence of CCV but the significance can be difficult to determine because the viral particles can also be present in healthy individuals.

Supportive treatment is usually all that is required in most cases. Recovery is rapid, although signs can persist for 4 weeks in some dogs. Given that most detergents readily inactivate the virus, outbreaks are best prevented through appropriate hygiene and disinfection strategies. Although vaccination is possible, this is unlikely to be necessary in most circumstances.

**Feline enteric coronavirus:** Feline enteric coronavirus (FECV) is a common enteric virus in cats and has the potential to mutate into a feline infectious peritonitis (FIP)-inducing strain. For a detailed discussion of FIP, readers should consult specific texts on the subject. FECV infection is usually subclinical, but cats may shed FECV in their faeces. Transmission is via the faecal-oral route, and young kittens (4–12 weeks age) are most susceptible.

In adults clinical signs are mild; more severe signs are seen in kittens, but fatalities are rare. Diarrhoea can be watery and contain mucus or fresh blood. Other signs include vomiting, pyrexia, anorexia and depression. A rising immunoglobulin titre to FECV is consistent with exposure. Routine supportive care is appropriate, and the prognosis for a full recovery is excellent. Hygiene, disinfection and isolation measures are advisable in cat colonies.

**Feline immunodeficiency virus and feline leukaemia virus:** FIV infection is associated with a 10–20% incidence of chronic enteritis; disease is usually associated with secondary infections, although occasionally no other aetiological agent is identified. Anorexia, chronic diarrhoea and emaciation are typical, and histopathological examination occasionally reveals chronic enteritis with transmural granulomatous inflammation. FeLV infection may also occasionally cause diarrhoea in cats, and can be associated with fatal peracute enterocolitis, chronic lymphocytic enteritis or alimentary lymphoma.

**Torovirus:** A torovirus-like agent has been isolated from the faeces of cats with the 'chronic diarrhoea and protruding nictitating membrane' syndrome. However, a clear association with clinical signs has not been demonstrated since this agent can be isolated from cats without diarrhoea.

#### **Bacterial enteritides**

Most bacterial infections of the GI tract are associated with acute diarrhoea but, since these organisms can be isolated from healthy animals, their significance is not clear. Host-pathogen interactions are likely to explain why some individuals are tolerant of these organisms, whilst others develop clinical signs. The incidence of infection is greatest in young, kennelled animals or immunocompromised patients. Potential bacterial

enteropathogens include *Campylobacter* spp., *Salmonella* spp., *Shigella* spp. and *Yersinia enterocolitica*. Such organisms might represent a potential zoonotic risk and attempted eradication of these organisms may be advisable. However, such a strategy may be unhelpful or unnecessary, leading to the development of antibiotic resistance or even inducing a carrier state.

**Campylobacter:** *Campylobacter jejuni* and *Campylobacter upsaliensis* are Gram-negative microaerophilic bacteria, which may be associated with enteric infections in dogs and cats, although their role as a causative agent is controversial. Transmission occurs by the faecal-oral route. *Campylobacter* species can be isolated in faeces from animals with clinical signs and from up to 50% of normal dogs. Clinically significant disease is more common in young, immunocompromised individuals or in colony dogs. Dogs with concurrent enteric infections, e.g. endoparasitism, and viral diarrhoea are more severely affected.

**Clinical signs:** Clinical signs may last 5–15 days and usually include diarrhoea (which may be watery, mucoid and haemorrhagic), vomiting, tenesmus, low-grade pyrexia, anorexia and mild abdominal discomfort.

**Diagnosis:** The organism can be detected on a direct faecal smear, as a 'seagull-shaped' bacterium. However, infection should be confirmed by culture of the bacterium from faeces and, given the potential for intermittent excretion, multiple samples may be required. Because the organism is fragile, false-negative results can occur if transport conditions for the sample are not optimal. The isolation of *Campylobacter* may be incidental or may be associated with underlying disease (e.g. IBD). Therefore, positive results must be interpreted with caution and clinicians should consider looking for underlying causes.

**Treatment and prognosis:** Fluoroquinolones and erythromycin are most commonly used, although fluoroquinolones are usually favoured given the potential for erythromycin to cause vomiting. Treatment for a period of 5–10 days is recommended and success of therapy should be confirmed by repeat faecal culture. In some cases, treatment of any underlying disease may eliminate the organism without recourse to antibiotics. Although a clear zoonotic link has not been established, owners of affected dogs should always maintain hygiene and, in some circumstances, antibiotics may be required to eliminate the possibility of transmission.

**Salmonella:** *Salmonella* species are Gram-negative motile rods, which can cause significant clinical infections in dogs and cats. However, *Salmonella* species are not always associated with clinical disease since organisms can be isolated from healthy dogs and cats. Clinical problems are most common in young, kennelled or immunocompromised animals, and concurrent viral infection (e.g. parvovirus) may increase disease severity. Transmission is via the faecal-oral route, and some species have a zoonotic potential.

**Clinical signs:** Infection with *Salmonella* is uncommon and clinical signs are even less common. Acute diarrhoea is most common in severely ill, presumably immunocompromised patients. Severity is variable and blood may be present. If bacterial translocation from the intestine occurs, life-threatening septicaemia may result. If *Salmonella* is isolated from dogs or cats with chronic diarrhoea then the clinician should look for another underlying reason for the diarrhoea.

**Diagnosis:** Diagnosis is made by isolation of the organism from faeces, or blood if the animal is septicaemic. Given problems with intermittent excretion, three faecal cultures are required to confirm a negative result.

**Treatment:** If a *Salmonella* species is isolated from healthy animals, or animals with acute diarrhoea that are not systemically ill, no treatment is needed since antibacterial use could promote resistance and a carrier state. Treatment is necessary only when there is evidence of sepsis, severe haemorrhagic diarrhoea, PLE or neutropenia. The choice of antibacterial should be governed by culture and sensitivity testing, but fluoroquinolones are usually suitable, and the faeces should be re-cultured to verify eradication. In light of the zoonotic risk, owners should be advised to take appropriate precautions to avoid self-infection.

**Prognosis:** In most cases prognosis is good, but the outlook is more guarded in cases with concurrent septicaemia. Negative prognostic indicators include peracute onset, pyrexia (>40°C) or hypothermia, severe haemorrhagic diarrhoea, degenerative left shift and hypoglycaemia.

**Clostridium:** *Clostridium perfringens* and *Clostridium difficile* are anaerobic bacilli, which are part of the normal canine and feline intestinal microflora and may cause signs of large intestinal diarrhoea. For *C. perfringens*, an association between clinical disease and either sporulation or endotoxin production has been suggested, although recent work has not supported such a link. A complex host-pathogen relationship is likely to exist, which explains why only some individuals are affected.

**Clinical signs:** Enterotoxin-producing *C. perfringens* can be associated with infections in hospitals or acute outbreaks in colony environments (e.g. kennels). Both acute and chronic syndromes have been reported, and predisposing factors might include dietary change, stress or concurrent disease. Acute cases present with large intestinal diarrhoea and signs usually resolve within 5–7 days. *C. perfringens* has been documented in some cases with concurrent parvovirus infection, and an association between *C. perfringens* and HGE has been reported.

**Diagnosis:** Clostridial species can be isolated by bacterial culture and are often present in normal individuals. On a faecal smear *C. perfringens* spores have a characteristic 'safety pin' appearance and more than two spores per high power microscope field suggests, but does not confirm, *C. perfringens* enteritis since spores can be seen in healthy dogs. However, identification of

spores is probably more significant if massive numbers are seen or if they are detected in colony dogs with acute clinical signs. The identification of endotoxin might be a better indicator of clinical infection, although this has not been proven definitively.

**Treatment and prognosis:** Acute infections are usually self-limiting but when treatment is necessary a 7-day course of either ampicillin, metronidazole or tylosin is effective. A high fibre diet may control sporulation and such nutritional modification may be of non-specific benefit in treating concurrent fibre-responsive conditions. Empirical use of tylosin (at 10 mg/kg p.o. q8h) may lead to clinical improvement in dogs with chronic enteropathies, and this effect may be mediated through suppression of clostridial species. The prognosis for acute infections is good, although cases of HGE must be treated aggressively.

**Enteropathogenic E. coli:** It is controversial whether enteropathogenic *E. coli* (EPEC) and enterotoxigenic *E. coli* (ETEC) are pathogenic in dogs and cats. Attachment of ETEC and subsequent release of heat-labile, heat-stable and Shiga-like toxins may cause acute diarrhoea. Further, EPEC may attach to the mucosa causing effacement of microvilli, leading to profound malabsorption without morphological abnormalities on histopathological examination. Identification of pathogenic strains requires specialized assays, such as bioassays for toxins and genome probes for identification of pathogenicity markers. However, because these organisms can be seen in healthy animals, a positive result does not necessarily prove a role in clinical disease.

**Miscellaneous bacterial infections:** *Yersinia enterocolitica*, *Y. pseudotuberculosis*, *Bacillus piliformis* and *Providencia alcalifaciens* are all rare causes of diarrhoea in dogs and cats. The reader is referred to specific reference texts for further information.

*Mycobacterium* spp. cause multisystemic granulomatous infections in dogs and cats, occasionally involving the GI tract. Cats may be infected with *M. bovis* by drinking infected cow's milk. Localization to the GI tract is associated with vomiting, diarrhoea, weight loss, mesenteric lymphadenopathy and peritonitis. The diagnosis is confirmed by demonstrating the organism in infected tissues by light microscopy (Ziehl-Neelsen-positive rods), bacterial culture or PCR. During the investigation of any granulomatous disease, a tissue sample should be frozen for culture or PCR if mycobacteria are suspected. Treatment protocols have been reported but therapy is controversial because of the significant public health risk.

#### Fungal, algal and oomycete infections

Fungal infections are rare in the UK but given the increasing popularity of overseas travel such diseases may be seen more commonly in the future. Examples of fungal infections include zygomycoses (fungal infections from Zygomycetes class e.g. *Basidiobolus* spp., *Conidiobolus* spp., *Absidia* spp., *Rhizopus* spp., *Mucor* spp. and *Mortierella* spp.), histoplasmosis, and opportunistic mycotic infections (candidiasis). The most predominant oomycete infection is phythiosis.



Toxic algal blooms, ingested from a contaminated water source, can cause acute gastroenteritis and death. Blue-green algae can synthesize an anticholinesterase that induces vomiting, diarrhoea, ataxia and rapid death of dogs. *Prototheca* spp. are achlorophyllous algae that can occasionally infect the intestine of dogs. Large intestinal disease is more common (see Chapter 21) but fatal disseminated disease involving the SI is reported.

**Endoparasitic infections**

**Nematodes:** Roundworm infections in dogs include ascarids (*Toxocara canis* and *Toxascaris leonina*), whipworms (*Trichuris vulpis*) and hookworms (*Ancylostoma* spp., *Uncinaria stenocephala*) (Figure 20.12). In cats, nematode infections include ascarids (*Toxocara cati* and *Toxascaris leonina*) and occasionally hookworms, although the exact species has not been determined.

Helminth	Dogs	Cats
<b>Nematodes</b>	<i>Toxocara canis</i> <i>Toxascaris leonina</i> <i>Uncinaria stenocephala</i> <i>Ancylostoma caninum</i> <i>Trichuris vulpis</i>	<i>Toxocara cati</i> <i>Toxascaris leonina</i> <i>Ancylostoma tubaeforme</i> (?)
<b>Cestodes</b>	<i>Taenia hydatigena</i> <i>Taenia pisiformis</i> <i>Taenia ovis</i> <i>Taenia serialis</i> <i>Multiceps multiceps</i> <i>Dypylidium caninum</i> <i>Echinococcus granulosus granulosus</i> <i>Echinococcus granulosus equinus</i> <i>Echinococcus multilocularis</i>	<i>Taenia hydatigena</i> <i>Dypylidium caninum</i>

**20.12** Common helminths of dogs and cats.

**Ascarid infections:** Infection can occur transplacentally (*Toxocara canis*), via milk to suckling neonates (*T. canis* and *T. cati*), by ingesting embryonated ova (all species), or by ingesting encysted larvae in a paratenic host (all species). After ingestion, larvae migrate through body tissues to the lungs, are coughed up and then swallowed. This larval migration can cause tissue damage, especially to the liver and lungs. During a patent infection, adult nematodes in the SI shed ova, which then pass out in the faeces and can be detected by faecal flotation. *T. canis* and, to a lesser extent, *T. cati* are of public health importance given the risk of aberrant larval migration (visceral and ocular larval migrans) in humans.

Clinical signs are most often seen in young animals and include diarrhoea, failure to thrive and abdominal distension. A large worm burden may result in intestinal obstruction or perforation, whilst biliary tract obstruction has also been reported. Most adult animals develop strong immunity and can spontaneously clear patent infections, without clinical signs. However, pat-

ent infections invariably occur in pregnant bitches. A variety of anthelmintic medications are available for treatment and prevention of *T. canis*, *T. cati* and *Toxascaris leonina* infections in dogs and cats (see Chapter 28).

**Hookworms:** The main canine hookworm in the UK is *Uncinaria stenocephala*, although occasional infections with *Ancylostoma caninum* occur, usually infesting the large intestine. There have been sporadic reports of hookworm infection in cats in the UK, probably with *A. tubaeforme*. Canine hookworm infestations can be associated with clinical signs; *U. stenocephala* can cause diarrhoea and weight loss, whilst *A. caninum*, is a blood-sucking parasite and can cause anaemia. In addition, interdigital dermatitis and perianal irritation can be seen due to migration of infected *Uncinaria* larvae. Infections are more common in dogs in a kennelled environment. Infection is diagnosed from faecal analysis for hookworm eggs. Treatment options include fenbendazole or pyrantel for *Ancylostoma* spp., and pyrantel for *U. stenocephala*. Control of infection in colony situations relies on both adequate prophylactic anthelmintic therapy and control of environmental exposure (e.g. removal of faeces and effective disinfection).

**Cestodes:** The tapeworms that affect dogs and cats are listed in Figure 20.12. All tapeworms have an immature stage that develops in an intermediate host. *Dypylidium caninum* is the most common cestode infection of dogs and cats in the UK, and the intermediate hosts are fleas and lice. Patent infections in dogs and cats rarely cause clinical signs of intestinal disease. Cestocides are discussed in Chapter 28.

**Protozoal infections**

**Coccidia:** *Isospora* are the most common coccidian parasites of dogs (*I. canis*) and cats (*I. felis*, *I. rivolta*). Transmission occurs by ingestion of ova or paratenic hosts. Sporozoites are liberated in the SI and then enter cells to commence development. The pre-patent period ranges from 4–11 days, depending upon the species of *Isospora*. *Cryptosporidium* spp. can also infect dogs and cats and transmission also occurs by the faecal–oral route.

**Clinical signs:** *Isospora* and *Cryptosporidium* are rarely associated with clinical disease. Puppies and kittens kept in unhygienic conditions or immunosuppressed animals may develop heavy infestations, which can be associated with (haemorrhagic) diarrhoea.

**Diagnosis:** *Isospora* oocysts can be detected by direct faecal smear examination or by faecal flotation. Given that cryptosporidial oocysts can be directly infective, the faeces should be mixed with formalin (1 part 38% formalin to 9 parts fluid faeces) prior to faecal analysis.

**Treatment and prognosis:** *Isospora* infection is often self-limiting although, where treatment is warranted, sulfadimethoxine (at 50 mg/kg p.o q24h for 10 days) or trimethoprim/sulphonamides (at 15–30 mg/kg p.o. q24h

for 5 days) are most appropriate. Cryptosporidiosis is usually self-limiting in immunocompetent individuals and, to date, most available drugs are ineffective. Initial reports that paromomycin was effective in cats, have not been supported by recent data. However, nitazoxanide has recently been shown to be effective in human cryptosporidiosis, and this may become the future treatment of choice for canine and feline cases (see Chapter 28). The prognosis for recovery from both *Isospora* and *Cryptosporidium* are good, except in immunocompromised animals.

**Giardia:** *Giardia* spp. can affect both dogs and cats and are transmitted by the faecal-oral route. *Giardia* predominantly inhabits the duodenum in dogs, whereas the jejunum and ileum are the predominant sites of infection in cats. Giardiasis is most prevalent in kennelled dogs and may have zoonotic potential, although the strains infecting dogs differ from human strains with a low potential for cross-infection.

**Clinical signs:** Infections may be asymptomatic, but when signs are present they can be acute or chronic and vary in severity from mild to severe. Chronic diarrhoea may be associated with steatorrhoea, intestinal protein loss and weight loss.

**Diagnosis:** *Giardia* can be diagnosed by documenting motile trophozoites on a fresh faecal smear or oocysts after zinc sulphate flotation. Shedding of cysts is intermittent and repeated faecal analysis may be required to confirm the diagnosis. An ELISA has also been developed that measures a specific *Giardia* antigen in faeces and requires only a single faecal sample. Although *Giardia* can also be detected in duodenal juice aspirates, the sensitivity of this technique is poor, especially in cats considering the predominant site of colonization. PCR-based methods are available for diagnosis in humans and to document environmental contamination of water supplies, but such techniques are not yet available for companion animals.

**Treatment and prognosis:** Fenbendazole (50 mg/kg p.o. q24h for 3 days) is licensed for treatment of *Giardia* infection in dogs and is often used as a means to exclude this differential in cases of chronic diarrhoea in cats. Studies have reported both safety and efficacy, and the recommended treatment is 5 days in cats. High-dose metronidazole is an alternative (e.g. dogs, 25 mg/kg p.o. q12h for 5 days; cats 10–25 mg/kg p.o. q12h for 5 days) but is effective in only 60% of cases and may cause hypersalivation in cats. Recent studies have also demonstrated that repeated doses of combination wormers containing febantel are effective. Outbreaks in colony situations can be problematic since the organism is highly infectious. In these circumstances treatment of all animals together with hygiene precautions, e.g. cleaning, disinfection, preventing water pooling (since desiccation will kill *Giardia* cysts) and perianal hygiene are recommended. A vaccine has also been developed, which may also aid control in colony outbreaks. In most cases prognosis is good but some infections can be difficult to eradicate.

### Diet-related chronic enteropathies

This group of disorders is most appropriately termed 'adverse reactions to food' and can be the result of hypersensitivities or intolerances. Food hypersensitivities or 'allergies' involve the immune system through the generation of an aberrant acquired immune response (usually type I or type IV hypersensitivity). Food intolerances do not involve the immune system; the reaction instead has a pharmacological or toxicological basis. Neither hypersensitivities nor intolerances have pathognomonic signs and therefore it is difficult to determine their relative frequencies. However, true food hypersensitivities are thought to be rare. One classic adverse reaction to food is gluten-sensitive enteropathy (GSE) in Irish Setters but it is unclear whether this results from an aberrant immune response to gluten, a direct toxic effect of the gluten or both. There is also an ill-defined relationship between dietary hypersensitivities and IBD; aberrant immune responses to food components could provoke the onset of IBD, whilst food hypersensitivities can arise secondary to mucosal inflammation in IBD.

### Clinical signs

Clinical signs include chronic diarrhoea, vomiting and weight loss or failure to thrive. Concurrent dermatological signs related to pruritus may also be present. Other small intestinal signs may include borborygmi, flatus or abdominal discomfort. The history occasionally provides evidence for an association with a particular foodstuff.

### Diagnosis

The initial aim is to rule out other possible causes of diarrhoea; faecal analysis is negative, serum biochemical examination is unremarkable and haematological analysis is usually normal, although eosinophilia is sometimes seen. Diagnostic imaging is unrewarding. Tests for circulating antibodies to food proteins, intradermal skin testing and gastroscopic sensitivity testing are all of limited value in the diagnosis of adverse food reactions. Endoscopy, biopsy sample procurement and histopathological assessment will eliminate other aetiologies; most cases with adverse food reactions have either normal histopathology or only mild inflammatory changes. The gold standard for the diagnosis of an adverse reaction to food is response to an **exclusion diet** and relapse when the original diet is reintroduced. However, this technique does not discriminate true food hypersensitivities from food intolerance.

**Exclusion diet:** The principle of an exclusion diet is to feed dietary components to which the animal has not previously (or recently) been exposed. Complete owner compliance is essential, and all treats and supplements must be withheld. Some clinicians recommend home-prepared diets, because the exact ingredients are better controlled. However, such diets are difficult to balance and owner compliance may be poor. These problems are avoided with the use of a commercial diet based on either hydrolysed protein or a single protein source.

A traditional exclusion diet is composed of single protein and carbohydrate sources, and the exact choice should be tailored to the individual. A wide range of diets is commercially available, containing different protein (e.g. chicken, soya, fish, catfish, venison, and duck) and carbohydrate (e.g. rice, corn [maize], tapioca or potato) sources. Hydrolysed protein diets are usually based either on chicken or soy protein; in theory, the hydrolysis process reduces antigenicity of dietary proteins by splitting them into smaller components, i.e. 10–70 kDaltons. Although there is no clear scientific evidence in animals to support this, such diets are currently the easiest way to guarantee feeding novel antigens and may soon become the preferred approach for an exclusion diet. Preliminary studies have suggested beneficial effects, but superiority over traditional single-source protein exclusion diets has not been demonstrated. The optimum duration for an exclusion diet trial is unknown, and 3–4 weeks has been chosen arbitrarily. However, cases of food allergic skin disease may require up to 10 weeks to respond.

**Challenge:** Once remission is achieved, the animal should be challenged with the original diet to demonstrate relapse and confirm the diagnosis. However, many clients are not willing to pursue this approach particularly if relapse is likely to bring recurrence of diarrhoea. If performed, a series of provocation tests will identify the offending food(s). Challenge trials are conducted for up to 14 days but are discontinued earlier if signs recur on two consecutive days. Once all offending foods have been identified, the animal can be maintained on a commercial diet that only includes non-allergenic components.

**Treatment and prognosis:** Dietary management should be the only treatment required and the diagnosis should be re-evaluated if treatment fails. The prognosis is good if the offending food agents can be identified and eliminated from the diet.

### Small intestinal bacterial overgrowth and antibiotic-responsive diarrhoea

Small intestinal bacterial overgrowth (SIBO) is a sign of an underlying intestinal disease rather than a diagnosis, and may arise from abnormalities in any of the mechanisms intended to modulate the flora. Previously, there have been reports of an idiopathic form of SIBO in dogs. However, the aetiopathogenesis of this disease is not clear and it is controversial whether a genuine idiopathic bacterial overgrowth exists. The consequences of SIBO include:

- Interference with absorption of nutrients (including cobalamin and possibly taurine) and fluid due to microvillar enzyme dysfunction
- Altered mucosal permeability
- Deconjugation of bile acids
- Hydroxylation of fatty acids.

The pathogenetic processes that underlie the idiopathic form have not been elucidated, but a breakdown of tolerance to normal luminal bacteria is one possible mechanism.

In humans SIBO is diagnosed when upper small intestinal bacterial numbers exceed  $10^5$  or  $10^4$  colony-forming units (CFU) per ml of intestinal juice for total bacteria and obligate anaerobes, respectively. Whilst these values were initially adopted for dogs, a number of studies have suggested a larger 'normal' microbial population. Small intestinal bacterial numbers are also greater in healthy cats. Therefore, the current diagnostic criteria for SIBO in companion animals are inappropriate and may lead to misdiagnosis in many cases. It is more appropriate to define two separate conditions. Secondary SIBO is a sign of another underlying intestinal disease where genuine increases in bacterial numbers occur. In contrast, idiopathic cases are more appropriately described as idiopathic antibiotic-responsive diarrhoea (ARD) on the basis that the only consistent finding is response to and remission on antibacterial therapy.

### Secondary SIBO and idiopathic ARD

Numerous diseases can potentially be associated with secondary SIBO (Figure 20.13). If a partial obstruction is present, the history often involves relapsing small intestinal diarrhoea, weight loss, and response to empirical antibacterial use. In all such conditions, it is logical to assume that an increase in bacterial numbers occurs, although few studies have documented its magnitude or whether the overgrowth is responsible for the clinical signs. Further, whilst diagnostic investigations may identify the presence of secondary SIBO, in practice it is better to concentrate the diagnostic effort on identifying the underlying process.

Type of disease	Examples
Decreased gastric acid production (achlorhydria)	Spontaneous (e.g. atrophic gastritis) Iatrogenic (e.g. acid-blocking drugs, surgical resection)
Increased small intestinal substrates	Exocrine pancreatic insufficiency Malabsorptive disorders?
Partial obstructive disorders	Chronic intussusception Stricture Neoplasia Foreign body
Anatomical disorders	Surgical resection of ileocolic valve Blind loop ('self-filling type')
Motility disorders	Primary/idiopathic Secondary: Hypothyroidism Electrolyte disorders Intestinal surgery Sepsis Peritonitis

**20.13** Diseases causing secondary SIBO.

Most cases of idiopathic ARD have been seen in young German Shepherd Dogs, although other breeds may be affected. The exact cause and predisposing factors are not clear, but an association with IgA deficiency or dysregulation has been suggested. However, IgA deficiency has not consistently been identified in cases of idiopathic ARD and the pathogenesis is

likely to be more complex. Other hypotheses include the presence of an occult infectious agent (e.g. enteropathogenic *E. coli* or clostridial species) or a breakdown of immunological tolerance to normal enteric microflora. There is no direct evidence to support any particular hypothesis.

### Clinical signs

The most common signs for both syndromes are chronic small intestinal diarrhoea and weight loss or failure to thrive. Other signs include vomiting, appetite alterations (anorexia, polyphagia, scavenging and coprophagia), excessive borborygmi and abdominal discomfort. A thorough history is important, since this may demonstrate an underlying cause (e.g. previous GI surgery). Abdominal palpation may demonstrate a structural cause of secondary SIBO, e.g. partial intestinal obstruction, although it is unremarkable in cases of idiopathic ARD.

### Diagnosis

Secondary SIBO can be detected by a number of tests but it is essential to discover the underlying cause. EPI can be diagnosed by measuring serum TLI concentration, whilst partial obstructions can be detected with diagnostic imaging.

If no localizing findings are obvious, a complete investigation is recommended, e.g. routine haematology, serum biochemical analysis, urinalysis, faecal bacteriology and parasitology, diagnostic imaging and gastroduodenoscopy. Findings are usually unremarkable or non-specific in cases with idiopathic ARD. At this stage, a treatment trial with an antibacterial should be contemplated. True idiopathic ARD can be diagnosed if the following criteria are established:

- No other cause can be identified (based on the results of the preliminary diagnostic tests and histopathological assessment)
- There is a positive response to an antibiotic trial (e.g. resolution of clinical signs, including weight gain)
- Relapse of clinical signs occurs upon withdrawal of treatment, and remission is achieved when antibiotic therapy is recommenced.

However, although response to antibacterials is critical for the diagnosis, **a thorough diagnostic evaluation must first have been performed to eliminate underlying diseases, especially those that might cause secondary SIBO.**

**Diagnostic tests:** Both direct and indirect diagnostic tests are available, but none has been properly validated for companion animals and widely accepted reference ranges have not been established. Therefore, the results of these tests must be interpreted with caution. The main direct test is quantitative bacterial culture of duodenal juice. Indirect tests include hydrogen breath tests and serum biochemical analyses.

The current diagnostic gold standard for SIBO is duodenal juice culture and the most commonly quoted figure for the upper limit for small intestinal bacterial numbers is  $10^5$  CFU/ml. However, the validity of this cut-off is questionable because quantitatively larger

numbers have been documented in healthy dogs. Further, duodenal juice collection is technically demanding and expensive so is rarely performed routinely.

Given the limitations of the diagnostic gold standard, indirect tests have been adapted from human methodology for use in the clinical setting. Hydrogen concentrations can be measured in exhaled breath, either in a fasted state or after administration of a test meal. However, protocols have not been universally accepted and this remains a research technique. In dogs, measurement of serum folate and cobalamin has been available for many years. Based on the theory that many bacterial species synthesize folate, whilst others can bind cobalamin, increased numbers of small intestinal bacteria may elevate serum folate concentrations, decrease serum cobalamin concentrations, or both. However, measurements of these parameters have poor sensitivity and specificity for canine SIBO and cannot differentiate dogs with ARD from those with other aetiologies. Thus, the use of folate and cobalamin measurements for the diagnosis of SIBO and especially ARD is questionable. Nevertheless, they are still of value in detecting vitamin malabsorption (see below).

Assays for serum unconjugated bile acids (SUBA) have recently become available. Bile acids are synthesized in the liver, conjugated to glycine or taurine and subsequently excreted into the intestine via the biliary tract. Certain bacterial species (*Clostridium*, *Bacteroides*) deconjugate bile acids, which then are absorbed by the SI. While abnormal values do reflect changes in intestinal microflora, recent work has suggested that they are of limited use in the diagnosis of idiopathic ARD.

In summary, none of the diagnostic tests currently available is recommended for diagnosis of either secondary SIBO or idiopathic ARD. Where secondary SIBO is suspected, it is preferable to look for the underlying cause. Given that neither quantitative bacterial culture nor indirect tests reliably identify cases that respond to antibacterials, and given that correlation between all methods is poor, their use in the diagnosis of idiopathic ARD is not recommended.

### Treatment

Therapy for secondary SIBO is best directed at the underlying disorder if appropriate, e.g. surgical resection of lesions causing partial obstruction or pancreatic enzyme supplementation for EPI. Experimental studies have shown that bacterial numbers in dogs with EPI decline with pancreatic enzyme supplementation alone (probably because enzymes are bactericidal and available substrate is reduced), suggesting that the problem will resolve of its own accord. However, in some clinical cases concurrent antibacterial therapy is necessary. For idiopathic ARD an appropriate antibacterial should be administered for an initial period of 4 weeks. If signs relapse, a longer course may be required, and many cases required long-term (or lifelong) therapy to maintain remission of signs.

The choice of antibacterial is controversial; most cases of idiopathic ARD respond well to oxytetracycline at 10–20 mg/kg p.o. q8h and, for long-term

therapy, low doses can often maintain clinical remission (10 mg/kg p.o. q24h). Other suitable drugs include tylosin or metronidazole. Interestingly, when oxytetracycline is administered bacterial numbers do not decline significantly and resistance soon develops, despite resolution of clinical signs. Therefore, the mechanism of action is not currently known. These drugs may exert a selection pressure on the intestinal microflora in the same way as a prebiotic. Alternatively, immunomodulatory effects, as reported for some of the tetracyclines, are possible. In addition, low doses of the same antibiotic (e.g. macrolides) may inhibit bacterial adhesion without any bactericidal or bacteriostatic effects. Oxytetracycline remains first choice for idiopathic ARD, but its use for secondary SIBO is controversial and other drugs may be more appropriate, e.g. tylosin or metronidazole, since their spectrum of activity is better for the organisms that are likely to be present in secondary SIBO. Further, Marks (2003) has questioned the long-term use of tetracyclines since organisms resistant to this group rapidly develop. Fluoroquinolones, e.g. ciprofloxacin, are often used in humans in order to target Gram-negative organisms and might also be indicated.

Adjunctive therapy may be helpful in cases of both secondary SIBO and idiopathic ARD. This involves the feeding of a highly digestible, fat-restricted diet, containing prebiotics (e.g. fructo-oligosaccharides). Whilst these can modulate colonic microflora the effect on small intestinal bacteria is questionable and there is limited current evidence for efficacy in clinical cases.

### **Prognosis**

The prognosis for secondary SIBO depends upon the nature of the underlying cause and success of therapy for the particular condition. The prognosis for idiopathic ARD is guarded; many cases relapse after therapy is discontinued and then require prolonged or even life-long treatment. However, other cases require only occasional short courses of antibacterials to maintain clinical remission. Some cases may improve spontaneously as the animal enters adulthood.

### **Idiopathic inflammatory bowel disease**

The term idiopathic IBD defines a diverse group of GI disorders that are characterized by inflammatory mucosal changes (both architectural abnormalities and cellular infiltrates) without a known inciting cause. Therefore, diagnosis requires that there is histological evidence of inflammation and that all potential causes for inflammation be excluded, e.g. endoparasites, dietary sensitivity and ARD. IBD is usually classified on the basis of the predominant infiltrating cell type; lymphocytes and plasma cells are most commonly seen, whilst eosinophilic predominance is noted in some cases. However, many cases have a generalized increase in several immune cell subsets and cannot easily be classified into one histological group. Such classification is often arbitrary and depends upon the opinion of the pathologist concerned. Attempts have been made to standardize histopathological classification but no scheme has yet been universally accepted.

### **Lymphocytic-plasmacytic enteritis**

Lymphocytic-plasmacytic enteritis (LPE) is characterized by architectural disruption of the intestinal mucosa in conjunction with excessive numbers of lymphocytes and plasma cells. The severity of histopathological abnormalities is variable, can affect a variable length of the SI and can affect other areas (e.g. stomach and colon). Moderate to severe cases are often associated with protein-losing enteropathy. A severe form of the disease has been reported in Basenjis. In cats LPE is often associated with concurrent disease of the pancreas and liver ('triaditis'), i.e. pancreatitis, cholangitis and hepatic lipidosis.

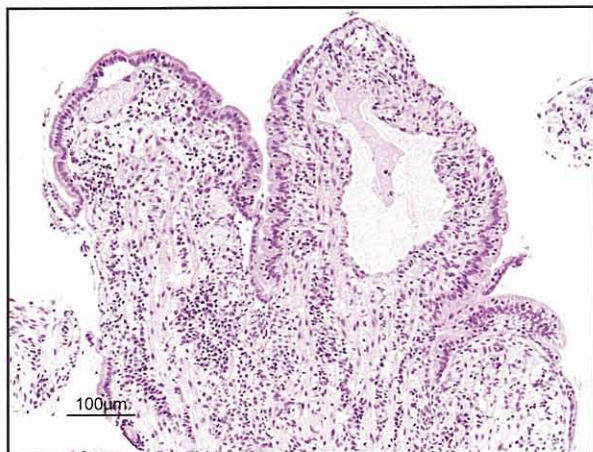
**Pathogenesis:** The underlying aetiology of small animal IBD is unknown and comparisons have been made with human IBD. Breakdown of immunological tolerance to luminal antigens is thought to be critical. In addition, immune dysregulation and disruption of the integrity of the mucosal barrier may also play a part. A role for the immune system in canine LPE has been suggested by studies that document increases in lamina propria T cells (especially CD4<sup>+</sup> cells), IgG<sup>+</sup> plasma cells, macrophages and granulocytes. Marked increases in mucosal cytokines have also been documented in canine LPE, with increased expression of Th1 (IL-2, IL-12 and IFN $\gamma$ ), Th2 (IL-5), proinflammatory (TNF- $\alpha$ ) and immunoregulatory (TGF- $\beta$ ) cytokine mRNA.

**Clinical findings:** In dogs, the most common clinical sign is chronic small bowel diarrhoea, which can be accompanied by weight loss and vomiting. In cats, vomiting is more common than diarrhoea or weight loss, and the vomitus may contain bile and hairballs. Other clinical findings include alterations in appetite, excessive borborygmi and abdominal discomfort. If severe hypoproteinaemia develops, ascites or subcutaneous oedema may be seen. Concurrent systemic immune-mediated disorders and thromboembolism have rarely been reported.

In most cases, no specific abnormalities are detected on physical examination. However, occasional findings include thickened small intestinal loops and mesenteric lymphadenopathy. These findings are usually easier to detect in cats than dogs.

**Diagnosis:** There are no pathognomonic clinicopathological findings in dogs and cats with LPE; panhypoproteinaemia and leucocytosis may be seen sporadically. Serum TLI measurement should eliminate EPI, and faecal analysis endoparasitism or bacterial pathogens. Abdominal radiography may eliminate other differential diagnoses, and is normal in most cases of LPE. Abdominal ultrasonography has a higher diagnostic yield and may reveal evidence of intestinal wall thickening, mesenteric lymphadenopathy or abdominal effusion. Where an alternative diagnosis has not been identified, intestinal biopsy samples should be obtained for histopathological assessment, either via endoscopy or exploratory laparotomy. Biopsy specimens should be collected even if there are no gross abnormalities.

Biopsy specimens are classified on the presence of architectural abnormalities and the presence of cellular infiltrates (Figure 20.14). Architectural abnormalities include villus (atrophy, fusion, increased width), crypt (necrosis, hyperplasia, abscessation), epithelial (erosion, ulceration, increased intraepithelial lymphocytes) and lamina propria changes (haemorrhage, oedema, fibrosis) (see Chapter 5). One recent publication suggested poor correlation between the interpretations of intestinal histopathology amongst pathologists. It can be especially difficult to distinguish mild LPE from normal tissues, and to distinguish severe LPE from intestinal lymphoma. In addition, inflammation secondary to other disorders is also indistinguishable from IBD unless a causative agent (e.g. parasite) is visible in the biopsy specimen. Therefore, histopathological reports should be interpreted cautiously in light of the individual clinical presentation.



**20.14** Photomicrograph from the duodenum of an 8-year-old neutered male crossbred dog with diarrhoea, ascites and severe panhypoproteinaemia (albumin 10 g/l, reference interval: 25–31 g/l; globulins 20 g/l, reference interval: 27–40 g/l). There is evidence of villous atrophy, epithelial erosions and mild lacteal dilatation. There is a variable, mixed inflammatory cell infiltrate within the mucosa. These findings would be consistent with a mixed inflammatory bowel disease. H&E stain. (Courtesy of R Fox, Department of Veterinary Pathology, University of Liverpool.)

**Treatment:** The treatment of LPE often involves a combination of therapies including dietary modification, antibacterial drugs and immunosuppressive medication. If the patient is not too debilitated, treatment trials should first be instigated with dietary modification or with antibacterial drugs. Immunosuppressive medication should be used only when other treatments fail. In this way cases that are truly idiopathic can be discerned from food-responsive and antibiotic-responsive conditions. However, there is some overlap between conditions, because dietary sensitivity can arise secondary to the mucosal inflammation in IBD. Further, the provision of a highly digestible, fat-restricted diet may provide non-specific benefits. Although antibacterials will discriminate cases of ARD, antibacterial therapy may also be directly beneficial in IBD cases. In this regard, some antibacterials may have

immunosuppressive properties (e.g. oxytetracycline, tylosin and metronidazole) or may modulate the bacterial flora reducing severity of the aberrant immune response to the endogenous flora.

Immunosuppressive medication should be administered early in the course of the disease when patients are debilitated, and indeed parenteral therapy may be necessary (e.g. prednisolone by intramuscular injection). If oral medication is employed, the initial starting dose of prednisolone is 1.0 mg/kg p.o. q12h (dogs) and 1.0–2.0 mg/kg p.o. q12h (cats). The starting dose is administered for 2–3 weeks in the first instance and then tapered gradually to effect, e.g. by reducing the dose by a third every 2–3 weeks until alternate day dosing is reached (e.g. 0.5 mg/kg p.o. q48h).

Additional immunosuppressive medication can be added if clinical response is poor or glucocorticoid side-effects are marked, e.g. azathioprine for dogs, chlorambucil for cats. Once remission is achieved, both the steroids and the other immunosuppressives can be tapered gradually. Whilst on azathioprine or chlorambucil, haematological parameters should be monitored regularly (e.g. every 14 days initially). Some clinicians include metronidazole in treatment regimes because of its putative immunosuppressive effects. However, these effects have not been documented clearly in companion animals. Nevertheless, many clinicians report empirical success. There is limited experience with other immunosuppressive medication; for example, budesonide may cause fewer side-effects since a large proportion is metabolized during the 'first-pass' through the liver after absorption. Ciclosporin has been suggested as an alternative treatment but there are limited data on its use.

**Prognosis:** The prognosis for LPE is variable and depends upon disease severity, with some cases responding poorly to therapy. Even when response is good, cases may require prolonged treatment. Where PLE has been identified, serum protein concentrations should be monitored regularly. When repeat endoscopy is performed there may be no improvement in histological abnormalities, despite clinical improvement. The exact reason for this is unclear. Although criteria for accurate monitoring of therapeutic response have not been clearly described, the use of an IBD 'activity index' may prove to be useful in the future.

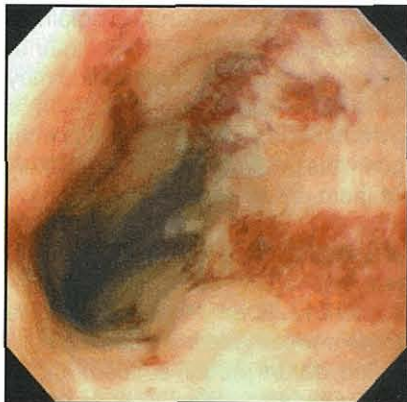### Eosinophilic enteritis

Eosinophilic enteritis (EE) is an idiopathic mucosal inflammation, involving mucosal architectural disturbances and predominance of eosinophils within the inflammatory infiltrate. The disease may be limited to the SI or may include other areas (e.g. stomach and colon). However, the number of eosinophils is variable, even in normal individuals, and so differentiating the normal population from an abnormal number can be difficult. The criteria for diagnosis of eosinophilic enteritis vary between pathologists; some would classify a mixed inflammatory cell infiltrate containing eosinophils as eosinophilic enteritis, other pathologists are more strict and would use the term only when eosinophils predominate. Increases in eosinophil numbers may also arise secondary to other aetiologies, such as

endoparasitism and dietary hypersensitivity, and these differentials should be excluded prior to immunosuppressive treatment for EE.

**Clinical findings:** Chronic small intestinal diarrhoea accompanied by vomiting or weight loss are the main clinical signs. Melaena is subjectively more common in cases of EE than LPE.

**Diagnosis:** The diagnostic approach is similar to that described for LPE. However, peripheral eosinophilia is occasionally documented on haematological examination. Differential diagnoses include mast cell neoplasia, hypoadrenocorticism and endoparasitism. EE in cats can occasionally be related to hypereosinophilic syndrome, where infiltrates of eosinophils may be seen within the spleen, liver, lymph nodes and bone marrow. Other clinicopathological abnormalities in EE include panhypoproteinaemia secondary to concurrent PLE, or anaemia if GI haemorrhage is severe. The protocol for investigation is similar to that for LPE. At endoscopy, gross findings may include the presence of linear ulcers within the duodenal mucosa (Figure 20.15). A definitive diagnosis is again usually achieved by histopathological examination of intestinal biopsy material.



20.15

Endoscopic appearance of linear mucosal ulceration, observed in a case of eosinophilic enteritis. (Courtesy of Edward Hall)

**Treatment:** A combination of treatment modalities may be required and prednisolone should be reserved for those cases that do not respond to other treatments. Given the possibility of underlying endoparasitism or dietary sensitivity, an anti-parasiticide trial with fenbendazole and then an exclusion diet should first be instigated. However, prednisolone or other immunosuppressive medication is often required. Cats with hypereosinophilic syndrome usually respond poorly to therapy, even with combinations of immunosuppressive agents, diet and anthelmintics.

**Prognosis:** If an underlying cause can be detected and treated, the prognosis is good. However, the prognosis is more guarded if initial response is poor; this is especially true for feline hypereosinophilic syndrome.

#### Other inflammatory enteropathies

Some inflammatory diseases may be characterized by infiltrates of neutrophils or by granulomatous inflammation, although these patterns are rare. If neutrophils are evident, an underlying bacterial infection should be

considered. Alternatively, the neutrophilic infiltrate may have arisen from bacterial invasion secondary to mucosal barrier disruption from erosive or ulcerative lesions. Prednisolone is generally not recommended for such cases, unless they fail to respond to all other therapeutic modalities. Potential causes of granulomatous inflammation include *Yersinia* and *Mycobacterium* infections, foreign body reactions and fungal diseases. The last are uncommon in the UK and special staining procedures, serology or culture and PCR of tissue samples is recommended for diagnosis. If possible, treatment should be directed at the underlying disorder. However, if no cause is evident, a staged approach to therapy is recommended, with steroids used as an absolute last resort. The prognosis depends upon the underlying cause.

#### Lymphangiectasia

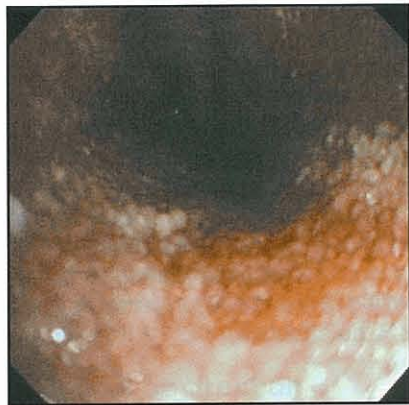
Intestinal lymphangiectasia is relatively common in dogs, but rare in cats. The condition is characterized by the abnormal dilatation and dysfunction of lymphatic vessels within the mucosa and submucosa. It may be a primary disorder, e.g. localized or generalized lymphatic abnormality. Alternatively, lymphatic obstruction can arise secondary to intestinal (e.g. neoplastic infiltration, inflammation or fibrosis) or systemic (e.g. right-sided cardiac failure, caval obstruction or hepatic disease) disorders. Lymphatic abnormalities are often associated with lipogranulomatous inflammation, but it is not clear whether this is the primary event or secondary to the lymphangiectasia. The lacteal dilatation is associated with exudation of protein-rich lymph and severe lipid malabsorption. Yorkshire Terriers, Rottweilers, Norwegian Lundehunds and Soft Coated Wheaten Terriers are predisposed and a genetic association is likely.

**Clinical signs:** Clinical signs include weight loss and chronic diarrhoea, and are the result of intestinal protein loss. Ascites, subcutaneous oedema and chylothorax can develop if severe hypoproteinaemia or disruption of lymphatic flow is present.

**Diagnosis:** Cases may present with signs relating to severe PLE. Clinicopathological findings include panhypoproteinaemia, hypocholesterolaemia and lymphopenia. Hypocalcaemia and hypomagnesaemia have also been reported. The hypocalcaemia is not simply the result of hypoalbuminaemia because ionized hypocalcaemia occurs; therefore, other mechanisms, including vitamin D and calcium malabsorption, may be involved. Specific investigations, such as measurement of faecal  $\alpha_1$ -proteinase inhibitor concentrations, can be used to confirm PLE. Diagnostic imaging may be helpful in narrowing the differential diagnosis list and identifying secondary consequences, such as pleural fluid or ascites. Ultrasonography will enable close assessment of bowel loops but apparent mucosal thickening may be associated with bowel wall oedema rather than a genuine infiltrative disease.

Definitive diagnosis requires intestinal biopsy by either endoscopy or exploratory coeliotomy. Endoscopy is less invasive and distended lacteals can often

be seen grossly as multiple 'rice-grain' nodules over the mucosal surface (Figure 20.16). However, endoscopic biopsy can occasionally miss the characteristic changes of lymphangiectasia, and full-thickness biopsy is preferable. Nevertheless, the increased risk of wound dehiscence may mean that exploratory laparotomy is contraindicated. Plasma oncotic pressure can be supported with colloids or a plasma infusion prior to surgery. At exploratory coeliotomy dilated lymphatics, mesenteric lymphadenopathy and lipogranulomata can be seen. The latter are yellow-white nodular masses (1–3 mm diameter) associated with mesenteric and serosal lymphatics and consist of accumulations of lipid-laden macrophages.



20.16

Endoscopic appearance of grossly distended lacteals associated with lymphangiectasia. (Courtesy of Edward Hall)

The histopathological abnormalities in lymphangiectasia include marked lymphatic dilatation in both the mucosa and submucosa. True lymphangiectasia must be distinguished from secondary lacteal dilatation that can arise secondary to other enteropathies, e.g. IBD. An associated inflammatory cell infiltrate may be seen in the lamina propria, although, if oedema is present, the true cell density may be underestimated. It is often not clear whether such an infiltrate is the cause of the lymphangiectasia or is secondary to it.

**Treatment:** For secondary lymphangiectasia the underlying cause should be identified and treated specifically, e.g. right-sided cardiac failure. For cases of primary lymphangiectasia treatment is supportive and symptomatic. This involves decreasing enteric protein loss, resolving associated inflammation and controlling oedema or effusions. Previously, medium-chain triglycerides were recommended, since it was thought that they bypassed the lymphatics and were absorbed directly into the portal blood circulation. However, recent studies have contradicted this and use of these nutrients cannot be recommended. Supplementation with fat-soluble vitamins is advised, and there are anecdotal reports of improvement with glutamine supplementation.

Prednisolone, at an initial dose of 0.5–1.0 mg/kg p.o. q12h may benefit some cases, especially if the disease is secondary to an inflammatory disorder. Adjunctive therapy with metronidazole or tylosin may also be of benefit, either by modulation of enteric microflora or through potential immunomodulatory effects. Finally, diuretics are indicated in the management of effusions

and combinations of diuretics are preferred (e.g. furosemide and spironolactone). Administration of plasma or colloids may also be of short-term benefit if hypoproteinaemia is marked, but sustained improvement requires correction of the underlying protein leakage.

**Prognosis:** The prognosis is guarded and response is usually poor, although some dogs do well. The reasons for this variation in response are not clear. However, remission may sometimes be maintained for several years, but many respondent patients eventually progress to fulminant hypoproteinaemia.

#### Miscellaneous causes of protein-losing enteropathies

A recent report has documented PLEs associated with intestinal crypt lesions, without evidence of lymphangiectasia or inflammation. Unfortunately the aetiology was not classified and response to therapy, with antibacterials and immunosuppressive medication, was variable. Some dogs with PLE die suddenly from thromboembolic disease.

#### Intestinal neoplasia

The most common malignancies in dogs are lymphoma, adenocarcinoma and smooth muscle tumours; the most common tumours in cats are lymphoma, mast cell neoplasia and adenocarcinoma. However, other types of neoplasia can occur including fibrosarcoma, haemangiosarcoma and plasma cell tumours.

#### Intestinal lymphoma

Lymphoma is characterized by mucosal and submucosal infiltration with neoplastic lymphocytes, which can then lead to clinical sequelae. Diffuse forms affect digestion and absorption, leading to malabsorption and PLE. In contrast, focal forms can cause complete or partial obstruction of the intestine. In cats, lymphoma may be related to FeLV infection, and although most cases are negative for serum FeLV antigen at the time of diagnosis. LPE is hypothesized to progress to lymphoma but can also coexist with LPE in adjacent regions of the SI.

**Clinical signs:** Middle-aged or older dogs and cats are most commonly affected. Clinical signs include weight loss, chronic small intestinal diarrhoea, anorexia, vomiting and melaena. On physical examination, there may be thickened intestinal loops, mass lesions and mesenteric lymphadenopathy. Hepatomegaly may suggest a multicentric form of lymphoma. Clinical signs of hypoproteinaemia may be noted if there is severe concurrent PLE.

**Diagnosis:** Haematological examination may reveal either normocytic-normochromic or microcytic-hypochromic anaemia. Serum biochemical analysis may demonstrate panhypoproteinaemia, but hyperglobulinaemia can be seen in B cell lymphoma. Decreased serum folate or cobalamin concentrations may be noted if significant malabsorption is present. Diagnostic imaging, and especially abdominal ultrasonography, will enable identification and characterization of mass lesions, mesenteric lymphadenopathy



or diffuse intestinal mural thickening with loss of normal layering (see Figure 20.8). Targeted aspiration of abnormal lesions can be performed under ultrasound guidance. Cytological samples can also be collected at endoscopy, although in many cases, intestinal biopsy is required for definitive diagnosis. Endoscopic biopsy samples are easier to procure but significant abnormalities may be missed, especially where the neoplastic infiltration is within the deep mucosa, submucosa or muscularis layers; therefore, many clinicians prefer exploratory coeliotomy. Immunohistochemistry may aid in diagnosis and classification. Flow cytometry and assessment of T cell clonality by PCR may prove to be more accurate in the future.

**Treatment and prognosis:** In dogs, the disease can be rapidly progressive and most patients respond poorly to therapy, although there are some exceptions. Cats with alimentary lymphoma may respond better to combination chemotherapy. Standard combination protocols, based on prednisolone, cyclophosphamide and vincristine sulphate may be used. However, for some cases, a combination of prednisolone and chlorambucil can give prolonged remission and survival. Given that both drugs are administered orally and easily discontinued, this combination is suitable when histopathological differentiation between severe LPE and lymphoma has not been possible.

**Intestinal adenocarcinoma**

Malignant epithelial tumours can be seen in middle-aged to older dogs and cats. In dogs, they are most prevalent in the duodenum, whilst in cats the jejunum

and ileum are more commonly affected. Siamese cats may be over-represented.

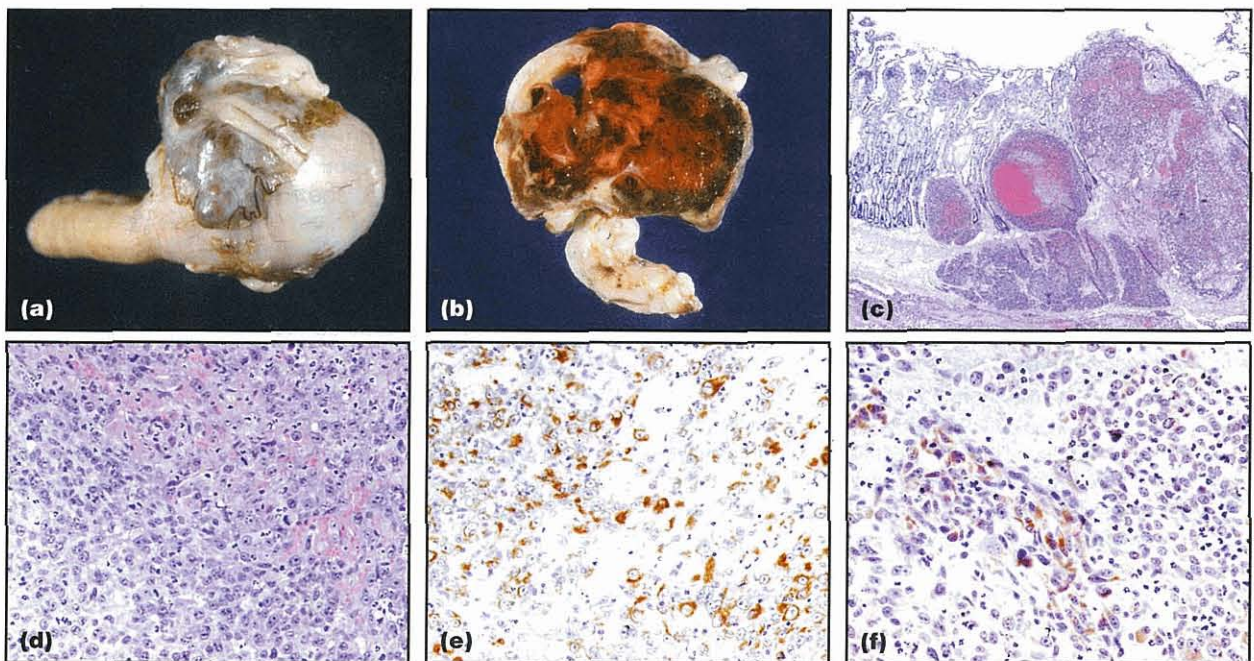
**Clinical findings:** The consequences of adenocarcinoma are usually secondary to local infiltration and intestinal obstruction. On abdominal palpation, a focal mass lesion may be evident, whereas blood loss anaemia and melaena may arise from associated mucosal ulceration.

**Diagnosis:** Clinicopathological assessment may reveal evidence of a microcytic-hypochromic (blood loss) anaemia. Ultrasonography is the best way of identifying, sampling and characterizing these tumours. Biopsy and histopathological assessment are required for definitive diagnosis. Given the focal nature of disease, exploratory coeliotomy is most appropriate and it may also permit surgical correction if appropriate.

**Treatment and prognosis:** Most adenocarcinomas are malignant and have already metastasized by the time of diagnosis. Surgical resection is the treatment of choice, but the prognosis is grave for most cases. Remission periods of up to 2 years have been reported, but survival is usually <12 months. Chemotherapy has been reported not to be effective.

**Other neoplasms**

Other types of neoplasia include smooth muscle tumours, fibrosarcoma, haemangiosarcoma (Figure 20.17) and mast cell tumours. Clinical signs usually result from direct invasion, intestinal blood loss or



**20.17** Pathological, histopathological and immunohistochemical findings from a 10-year-old male crossbred with weight loss and melaena. (a,b) Gross findings from mass resected at surgery. (c,d) Microscopic findings of the resected mass confirmed it as a haemangiosarcoma. H&E stain; original magnification x100. (c) and x200 (d). (e) Immunohistochemical stain demonstrating that some of the neoplastic cells are positive for vimentin; immunoperoxidase method, original magnification x200. (f) Immunohistochemical staining of biopsy material demonstrating positivity for factor VIII; immunoperoxidase method, original magnification x200. (Courtesy of R. Fox, Department of Veterinary Pathology, University of Liverpool.)

through paraneoplastic phenomena. Diagnosis is usually made on histopathological assessment of biopsy samples. Paraneoplastic phenomena are most commonly associated with smooth muscle tumours and include hypoglycaemia and nephrogenic diabetes insipidus. The former is the result of release of an insulin-like substance; the aetiology of the latter is unclear. Mast cell tumours may release histamine, which through stimulation of gastric acid hypersecretion can cause gastric and duodenal ulceration, and hence vomiting, haematemesis and melaena. Gastric and duodenal perforation may also occur.

Treatment involves resection of the primary intestinal mass. Prognosis is variable; fibrosarcomas and haemangiosarcomas have usually already metastasized and recur quickly. However, leiomyosarcomas are slow growing and slow to metastasize, with a median survival time of approximately 2 years, if cases survive the initial postoperative period. Surgical debulking is recommended even in the face of gross abdominal metastases because prolonged survival can still be achieved.

Adenomatous polyps can affect the SI causing vomiting, haematemesis, diarrhoea and anaemia. Cases are best diagnosed with a combination of abdominal ultrasonography and endoscopic evaluation. Surgery is the treatment of choice and can be curative.

### Intestinal obstruction

Intestinal obstruction can be acute or chronic, partial or complete, and simple or strangulated. The cause of the obstruction can be extraluminal, intramural or intraluminal, and a variety of aetiologies are possible. The most common causes include intussusception, neoplasia and foreign bodies. Less common causes include intestinal volvulus and obstruction due to incarcerated intestinal loops. Younger animals are more likely to develop intussusception following gastroenteritis or intestinal surgery, although an increased risk in postparturient queens has also been reported. Intestinal neoplasia is more frequent in middle-aged to older individuals. Common foreign bodies in dogs include peach stones and toys, whilst linear foreign bodies (e.g. needles with associated thread) are more common in cats.

The adverse effects of intestinal obstruction depend upon whether the obstruction is partial or complete, and relate to the consequences of intestinal fluid loss, proliferation of intestinal bacteria and secondary intestinal inflammation. Intestinal perforation is a serious additional complication and is most common with linear foreign bodies and intestinal neoplasia.

### Clinical findings

The clinical findings depend upon the site, severity and cause of obstruction. Net secretion of fluid occurs in the upper SI, whilst there is net resorption in the lower SI. Further, distal small intestinal obstruction is more likely to result in significant secondary SIBO. Therefore, complete upper intestinal obstruction is associated with persistent and severe vomiting of large volumes, together with marked intestinal fluid and electrolyte loss. With distal small intestinal ob-

struction signs are less severe and include anorexia and intermittent vomiting of small volumes, often with a foetid smell (the result of secondary bacterial overgrowth and putrefaction of intestinal contents). However, vomiting is occasionally absent with some distal obstructions. Partial obstruction can also result in intermittent vomiting and diarrhoea. With volvulus there is also rapid accumulation of peritoneal fluid as strangulated intestinal loops become turgid and permeable. Subsequent hypoxia leads to disruption of the mucosal barrier, peritonitis and septicaemia.

Physical findings are variable and depend upon the severity of fluid losses and intestinal compromise. Findings range from mild dehydration to septic shock. Shock and abdominal pain (acute abdomen) are the major findings with strangulated obstructions, such as intestinal volvulus, incarceration and intussusception. A thorough oral examination is indicated, particularly in cats, since linear foreign objects may be anchored under the tongue. Localized discomfort may be evident with foreign objects, volvulus, intussusceptions and tumours; palpation may be resisted or impossible when intestinal inflammation or perforation is present. Focal increases in intestinal thickness suggest tumours, intussusceptions or foreign objects, and a sausage-shaped mass is suggestive of an intussusception. Mesenteric lymphadenopathy is often present in animals with inflammatory and neoplastic intestinal disease.

### Diagnosis

Historical information can be important in the diagnosis and may give clues as to ingestion of foreign bodies or previous signs of diarrhoea. Physical examination findings are variable and depend upon the cause, site and extent of obstruction. A minimum database and clinicopathological tests help to characterize the fluid losses and inflammation. Hypochloraemia, hypokalaemia and acid-base abnormalities are common in patients with upper GI obstruction.

Radiographic features of obstruction include obvious foreign bodies, intestinal dilatation due to the accumulation of fluid or gas (see Figure 20.7), and accumulation of ingested food (gravel sign). Displacement, bunching or plication of the intestine may also be evident, whilst decreased serosal detail and free abdominal gas indicate peritonitis and intestinal perforation, respectively. By quantifying the degree of intestinal dilatation the likelihood of intestinal obstruction can be determined, with obstruction being unlikely when the widest loop is less than 1.6 x the height of the body of L5. However, survey radiography can be unremarkable in chronic partial obstruction and ileo-colic intussusception. Contrast radiography, with liquid contrast media or barium-impregnated polyethylene spheres (BIPS), can assist in diagnosis but may not be appropriate in emergency cases, and often does not give more information than plain radiography. Ultrasonography is an excellent means by which non-palpable obstructive lesions can be identified, and is useful in determining underlying causes of intussusception, such as intestinal neoplasms. Ultrasound-guided needle aspirates further help to establish the identity of any lesions identified.

### Treatment

The main aim of treatment is to remove or resect the cause of the obstruction. Fluid therapy should be initiated on the basis of clinical findings and a minimum database. Fluid shifts can be severe and aggressive; monitoring is necessary to detect and counteract changes in fluid balance (see Chapter 26). Broad spectrum antibacterial drugs (e.g. ampicillin or a cephalosporin, often in combination with metronidazole) are usually administered prophylactically before surgery. Antibiotics should be given to patients with signs of sepsis or intestinal compromise (see above). Fluid balance and electrolyte abnormalities should be corrected as much as possible before surgery.

**Prognosis:** The prognosis depends upon the cause of the obstruction and severity of abnormalities associated with it. Simple foreign bodies have an excellent prognosis, whilst the outlook is grave for metastatic neoplasia.

### Adynamic ileus and intestinal pseudo-obstruction

Adynamic ileus is a common sequel to parvoviral enteritis, abdominal surgery, pancreatitis, peritonitis, endotoxaemia, hypokalaemia and dysautonomia. Intestinal pseudo-obstruction describes a condition where patients have clinical evidence consistent with an obstruction, but with no mechanical cause. The condition has been associated with both visceral neuropathies and myopathies in humans, and such causes may occur in small animals. The majority of canine cases are associated with idiopathic sclerosing enteropathy, with fibrosis and a mononuclear cell infiltrate of the tunica muscularis. A single reported case of feline intestinal pseudo-obstruction was secondary to intestinal lymphoma.

After eliminating the possibility of mechanical obstruction, management of both adynamic ileus and intestinal pseudo-obstruction is aimed at identifying any underlying cause and providing specific treatment. Symptomatic therapy to stimulate intestinal motility is also indicated. In dogs and cats, cisapride appears to be the most effective agent but is no longer marketed. There are now few suitable alternatives; possibilities include certain prokinetic H<sub>2</sub> antagonists (e.g. ranitidine, nizatidine), metoclopramide and erythromycin, although beneficial effects have not been critically assessed. Antibacterials may also be appropriate given the probability of secondary SIBO, and immunosuppressive medication may be appropriate if underlying IBD is suspected. Feeding is of benefit in humans and nutritional support can be continued indefinitely, although vomiting, constipation and diarrhoea usually continue. Unfortunately, most cases reported in the veterinary literature responded poorly to therapy and the prognosis is grave.

### Short bowel syndrome

Short bowel syndrome can develop when a large amount (e.g. greater than two-thirds) of the SI is absent, either because of surgical resection or a congenital anomaly. The remaining absorptive capacity is insufficient for adequate absorption of nutrients and electrolytes, resulting in diarrhoea. The syndrome may be transient after intestinal resection, because the remaining intestine can undergo adaptive hyperplasia.

### Clinical signs and diagnosis

The predominant clinical signs are small intestinal diarrhoea and weight loss. In acquired cases the history of recent bowel resection and subsequent development of clinical signs is usually sufficient to make a diagnosis. In congenital cases, plain or contrast radiography is required.

### Treatment and prognosis

Dietary therapy to control the chronic diarrhoea is essential and a highly digestible low fat diet is recommended. Multivitamin supplementation may also be necessary. Further, if resection involves removal of the ileocaecal valve, secondary SIBO is a possibility and antibacterial drugs are required, e.g. metronidazole or tylosin. In cases that respond poorly, antisecretory agents (e.g. loperamide, diphenoxylate) and antacids (e.g. ranitidine, famotidine) may be required. However, ranitidine has prokinetic properties and may not be helpful. Total or partial parenteral nutrition may be helpful in severe cases in the short term until adaptive hyperplasia occurs. The prognosis depends on the length of functional SI that remains. If adaptive hyperplasia is good, patients may respond, but these animals will always have a limited absorptive reserve and continued dietary management will usually be necessary. Unfortunately, some cases respond poorly to treatment.

### References and further reading

- Hall EJ and German AJ (in press) Diseases of the small intestine. In: *Textbook of Veterinary Internal Medicine*, ed. SJ Ettinger and EC Feldman. WB Saunders, Philadelphia
- Keith CL, Radecki SV and Lappin MR (2003) Evaluation of fenbendazole for treatment of *Giardia* infection in cats concurrently infected with *Cryptosporidium parvum*. *American Journal of Veterinary Research* 64, 1027–1029
- Marks SL (2003) Small intestinal bacterial overgrowth in dogs – less common than you think? *Journal of Veterinary Internal Medicine* 17, 5–7
- Mohr AJ, Leisewitz AL, Jacobson LS, Steiner JM, Ruaux CG and Williams DA (2003) Effect of early enteral nutrition on intestinal permeability, intestinal protein loss, and outcome in dogs with severe parvoviral enteritis. *Journal of Veterinary Internal Medicine* 17, 791–798
- I-Schwartz RD, Donoghue AR, Boggs RB, Clark T and Partington C (2000) Evaluation of the safety of fenbendazole in cats. *American Journal of Veterinary Research* 61, 330–332

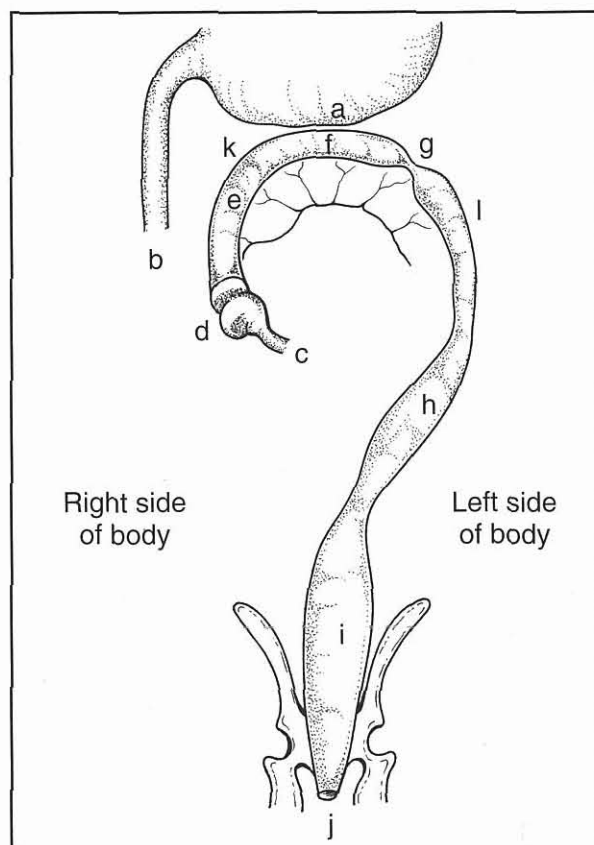
# Diseases of the colon and rectum

Albert E. Jergens and Debra L. Zoran

## Colonic anatomy and physiology

The large intestine serves numerous physiological roles: maintenance of fluid and electrolyte balance, storage site for faecal material, and reservoir for a complex microbial ecosystem that performs diverse functions. Normal colonic physiology may be disrupted by disease that causes diarrhoea or constipation.

The average length of the colon in dogs and cats is 60–75 cm, and it is divided into three anatomically distinct regions: the ascending, transverse and descending colonic segments (Figure 21.1). The

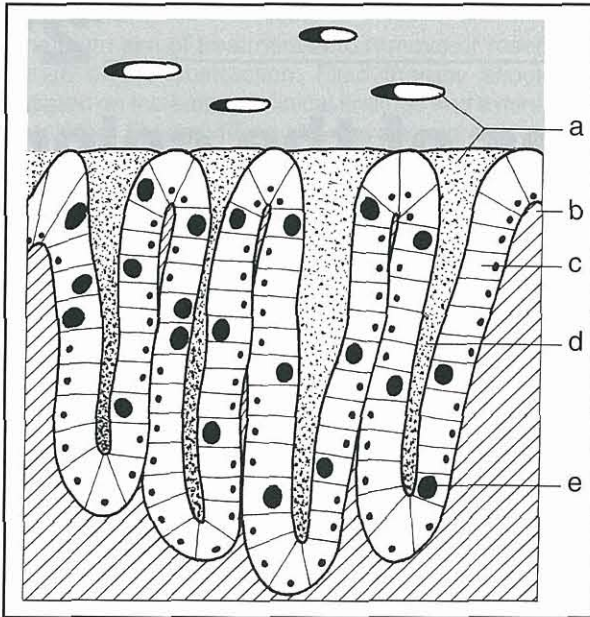


**21.1** Anatomy of the canine colon. a = greater curvature of the stomach; b = descending duodenum; c = terminal ileum; d = caecum; e = ascending colon; f = transverse colon; g = segmental contraction; h = descending colon; i = rectum; j = anus; k = hepatic flexure; l = splenic flexure.

ascending colon is the shortest segment and is attached to the ileum and caecum at a juncture termed the ileocolic orifice. The caecum is a diverticulum of the ascending colon that ranges in length up to 15 cm in dogs and lies midway between the right flank and median plane and is ventral to the duodenum. The ileocolic orifice is usually a button-like structure in dogs but may be slit-like in cats. It functions to separate the small and large intestine but also serves to prevent oral movement of faeces and bacteria. The ascending colon becomes the transverse segment at the right colic (hepatic) flexure where it lies cranial to the duodenum, near the pyloric region of the stomach and left lobe of the pancreas. The transverse colon terminates at the left colic or splenic flexure in the cranial abdomen. The descending colon is the longest segment and passes caudally in the sublumbal region along the medial ventral border of the left kidney, and then gradually inclines to the pelvic region where it becomes the rectum. The rectum is generally considered to begin at the pelvic inlet and continues through the pelvic canal terminating at the anus.

There are four histologically distinct layers in the colon and rectum: the mucosa, submucosa, muscularis and serosa. In contrast to small intestinal mucosa, the colon has a more compact microstructure which lacks villi, is composed of columnar epithelial cells arranged in parallel crypts, and is richly supplied with mucus secreting goblet cells (Figure 21.2). The muscular layers of the colon are similar to those in the remainder of the gastrointestinal (GI) tract and consist of an inner circular and outer longitudinal layer. The colon has a well known and important role in conservation of water, sodium and chloride ions, and it is the site of storage of intestinal waste products until they are expelled as faeces.

There is increasing evidence that the microbial population of the colon plays a unique and important role in digestion and metabolism in the GI tract. Fermentation of dietary fibre and other poorly digestible carbohydrate (CHO) sources by colonic microbes produce short chain fatty acids (SCFAs), carbon dioxide, water, methane and hydrogen gas, and these by-products have many effects on the luminal ecosystem and colonocytes. Enzymes produced by the colonic microflora convert primary bile acids into secondary bile acids, which are known colonic irritants and tumour promoters and may contribute to development of inflammatory bowel disease (IBD) or neoplasia.



**21.2** Structure of the colonic mucosa. a = crypt openings; b = lamina propria; c = columnar epithelial cells; d = crypt; e = goblet cell.

The proximal colon, which functionally corresponds to the ascending and transverse segments of the colon, is the primary site of fermentation of undigested CHOs and proteins by the bacterial flora. Dietary fibre is the primary substrate for bacterial fermentation but not all dietary fibres are fermented equally. Fibres have been categorized (Figure 21.3) based on their fermentability:

- Highly fermentable fibres
- Moderately fermentable or mixed fibres
- Poorly fermentable fibres.

The highly fermentable fibres produce the largest quantities of SCFAs but the fermentation process also reduces faecal bulk. Conversely, the less fermentable a fibre is, the more it retains its structural characteristics and faecal bulk but a lower concentration of SCFAs are produced. The production of SCFAs (e.g. acetate, propionate and especially butyrate) is important because these products are utilized by the colonic epithelial cells

as a source of metabolic energy and are a substrate for cellular lipid synthesis. Furthermore, the production of SCFAs also serves several other important purposes:

- They are the primary cations in the colonic lumen
- They help to maintain a more acidic pH and are involved in sodium and water fluxes in the colon
- The acidic luminal pH reduces the ionization of long chain fatty acids and bile acids (both known colonic irritants)
- They increase the concentration of ammonium ions so that they are removed in the faeces.

The distal colon is the major site of faecal storage and is important in determining the final water content of faeces. The colon has a large capacity for absorption of fluid which is dependent on active sodium absorption coupled with the absorption of SCFAs. Diarrhoea occurs when either the reserve capacity of the colon to absorb water and electrolytes is exceeded, or when there is abnormal colonic function.

The motor activity of the colon includes both segmentation and propulsive movements. Segmentation, controlled by the slow-wave activity of colonic smooth muscle, is responsible for mixing colonic contents which slows the passage of ingesta. Rhythmic segmentation within the colon is mediated by the intrinsic nervous system. Propulsive motor activity propels faeces by three patterns: peristaltic activity, reverse peristalsis and mass peristalsis. Peristalsis is the aboral movement of ingesta through the colon by tonic contractions of smooth muscle. These contractions are stimulated by luminal distension. Reverse peristalsis is unique to the proximal colon and is characterized by contractions that move orally. The motility pattern in the proximal colon is a combination of both segmentation and reverse peristalsis, which serves to thoroughly mix food and allows for complete absorption of nutrients. Mass peristalsis is responsible for motility that propels the colonic contents caudally. In the distal colon, the primary motor pattern is segmentation and propulsion with mass peristaltic activity triggering the act of defecation. Decreased segmentation or propulsion leads to the development of diarrhoea while increased segmentation may cause constipation.

Type of fibre	Physiological effect
Highly fermentable fibre sources	Good source of short chain fatty acids High incidence of diarrhoea and excess gas production
Moderately fermentable fibre sources	Good source of short chain fatty acids Provide ideal faecal dry matter and defecation frequency Increase colonic weight Increase colonic absorptive surface area Produce colonic hypertrophy Have a low incidence of cryptitis and mucus distension
Non-fermentable fibre sources	Reduced short chain fatty acid production ( <i>in vitro</i> ) Increase the dry matter content of the faeces and may actually exacerbate constipation May increase retention time Decrease colonic weight, surface area, crypt depth May lead to cryptitis and mucus distension

**21.3** Summary of the physiological effects of fibres.

## The anorectum

The storage and voluntary evacuation of faeces is under the control of the muscles and nerves serving the pelvic canal, rectum and anus. The ability to retain faeces, to perceive that the rectum is full and to determine appropriate defecation is termed faecal continence. Abnormal function of these muscles or nerves results in loss of faecal continence or constipation but rarely leads to haematochezia or mucoid diarrhoea. Alternatively, inflammatory disorders of the rectal mucosa result in tenesmus, increased faecal mucus, haematochezia or frequent defecation. Faecal incontinence may occur secondary to reservoir function failure in dogs with severe rectal inflammatory disease.

### Anatomy and physiology

The origin of the rectum is the pelvic inlet and it ends at the anal canal. The involuntary smooth muscle of the internal anal sphincter and striated muscle of the voluntary external anal sphincter surround the anal canal and determine its function. Paired anal sacs in this region may become impacted with secretions leading to infection or abscessation. Circumanal glands (non-secretory, subcutaneous sebaceous glands located in the anal subcutaneous zone) may grow in intact male dogs throughout life and form adenomas due to constant androgen exposure. Anal glands are tubular sweat glands located near circumanal glands, which produce a fatty secretion of unknown function (see Chapter 22).

The innervation of the anorectum consists of a well defined myenteric and a submucosal plexus. The innervation to the anus includes branches of the pelvic nerve that provide parasympathetic fibres, which are excitatory to the rectum and inhibitory to the internal anal sphincter. Sympathetic fibres arise from the hypogastric nerve and are inhibitory to the rectum (i.e. causing relaxation) and excitatory to the internal anal sphincter (i.e. causing contraction), thus allowing appropriate storage of faeces. The function of the external anal sphincter allows maximum distention and storage of faeces in the rectum while maintaining anal control. Faecal incontinence can develop in animals with pudendal nerve damage since external anal sphincter function is impaired.

## Diagnostic approach

### History and clinical signs

Most colorectal diseases cause overt signs of large bowel diarrhoea, tenesmus and/or dyschezia (e.g. painful defecation) (Figure 21.4). Large bowel diarrhoea is characterized by frequent (3–6 times normal) urges to defecate, with each bowel movement producing small volumes of faeces that contain excessive mucus and sometimes fresh blood (i.e. haematochezia). Urgency may be seen with colonic or rectal diseases while dyschezia occurs most often with rectal disorders. Since the colon principally functions to absorb water and electrolytes, systemic signs attributable to nutrient malabsorption (e.g. voluminous faeces, significant weight loss) are uncommon. Animals are generally alert, active and well fleshed with normal appetites on presentation. Occasionally, dogs may exhibit abdominal pain or discomfort with colitis. Furthermore, some diseases (i.e. IBD, alimentary lymphoma, mycotic enterocolitis) may cause concurrent small intestinal signs.

The following historical concerns are of significance in patients suspected of having colorectal disorders:

- Is the diarrhoea acute or chronic? Acute, self-limiting large bowel diarrhoea is common and rarely requires an in-depth diagnostic evaluation
- Are clinical signs static, progressive or cyclical? Colorectal neoplasia may cause progressive signs while colonic IBD is characterized by a waxing/waning clinical course
- Is there evidence of dietary, environmental, parasitic or infectious causes for large bowel diarrhoea? Dietary and parasitic causes may constitute up to 50% of clinical cases
- What type of diet is the patient being fed? Note recent dietary changes (this might incriminate responsible nutrients), the amount and frequency of feeding, and the administration of medications (e.g. antibiotics, narcotics, motility modifiers, laxatives) that might alter colonic function
- Do clinical signs resolve when the animal is fed a hypoallergenic or elimination diet? This might suggest the presence of food hypersensitivity or intolerance

Colorectal disease	Perineal–perianal disease	Miscellaneous
Constipation	Anal sac neoplasia	Neoplasia of urethra, bladder, vagina or prostate
Colitis–proctitis (e.g. inflammatory bowel disease, histoplasmosis, enterotoxigenic, protothecosis)	Anal sac abscess or impaction	Pregnancy and parturition
Rectal stricture	Perianal fistula	Prostatic enlargement (benign hypertrophy, paraprostatic cyst, neoplasia); prostatic inflammation (prostatitis, prostatic abscess)
Neoplasia or polyps	Perineal hernia	Urinary calculi (cystic or urethral)
Foreign material	Diverticula	Cystitis
Irritable bowel syndrome		Pelvic trauma or disease
		Caudal abdominal mass or lymphadenopathy

21.4 Causes of tenesmus and dyschezia.

- A positive response to glucocorticoid therapy may indicate the presence of inflammatory or immune-mediated disease, such as IBD or perianal fistula
- Does the animal roam freely? If so, parasitic, toxic and infectious causes for colorectal diseases should be considered more likely
- Does the animal's travel history suggest an increased risk of disease with a regional incidence, such as histoplasmosis (Midwest USA) or intestinal parasites (Southern USA)?

**Physical examination**

The physical examination in most animals with colonic disease is normal. Abdominal palpation is important in assessing for prostatomegaly, genitourinary disorders, faecal impaction and intussusception, which can cause tenesmus or dyschezia (see Chapter 12). A carefully performed digital examination of the rectum should be undertaken to search for rectal masses, pain, diverticulum (perineal hernia), stricture (rare), increased mucosal granularity and perianal disease. Additionally, rectal evaluation affords the opportunity to collect fresh faeces for diagnostic evaluation (e.g. presence of haematochezia, faecal mucus) and provides valuable exfoliative specimens for cytological review.

**Diagnostic tests**

Diagnostic strategies for colorectal disorders vary considerably depending on the severity, chronicity of signs, presence of systemic illness and historical or likely responses to therapy (Figure 21.5). Full haematology, biochemistry profile and urinalysis should be obtained from all animals with colorectal disease on admission.

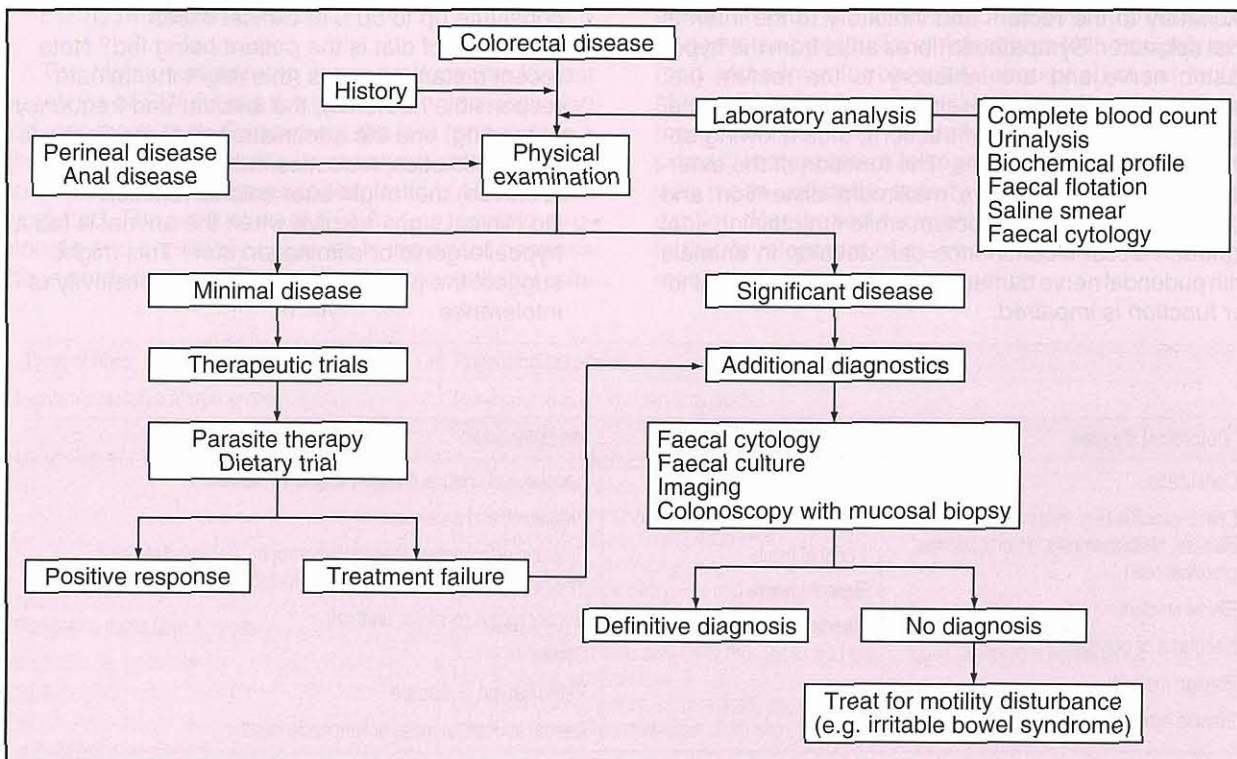
This serves to rule out metabolic or systemic disease that may result in large bowel diarrhoea.

**Faecal examination**

An adequate faecal examination for intestinal parasites is required in all patients. Some parasites (e.g. *Trichuris vulpis* and *Giardia* spp.) are notoriously difficult to diagnose necessitating performance of serial faecal flotations. In order to identify *Giardia* cysts, a zinc sulphate (ZnSO<sub>4</sub>) flotation solution is recommended. Direct saline faecal smears are used to detect motile trophozoites of *Giardia*, *Trichomonas*, *Balantidium* and *Entamoeba* (see Chapters 2 and 16).

Faecal cytological examination involves evaluation of stained rectal/colonic mucosal scrapings under high power or oil immersion to identify aetiological agents and inflammatory cells. A flat conjunctival spatula (carefully advanced digitally) procures specimens of excellent quality, which should be placed on a microscope slide, air-dried and stained with Diff-Quik or Wright's stain. Increased numbers of leucocytes indicate a possible inflammatory or infectious aetiology. The presence of fungal (*Histoplasma*) organisms, neoplastic cells, or a predominance of spirochaetes or clostridial spores also suggests a possible cause for large bowel signs.

Faecal cultures are useful when faecal cytology shows evidence of an inflammatory diarrhoea or when infectious diarrhoea is suspected. The major bacterial pathogens in dogs and cats include *Campylobacter jejuni*, *Salmonella* spp. and *Clostridium*. Note that faecal specimens for culture must be fresh, of adequate quantity (e.g. small pea size amount of stool) and transported rapidly for inoculation into enrichment media (see Chapter 2).



21.5 Diagnostic evaluation of colorectal disorders. (Modified from Tweedt, 1997)

**Diagnostic imaging**

Imaging is infrequently diagnostic in animals with colorectal disease. However, survey abdominal radiography may identify radiopaque foreign objects, faecal impaction or extraluminal obstruction (e.g. pelvic canal stenosis, prostatomegaly, regional lymphadenopathy). Pneumocolon can be performed as a simple alternative to barium enema to highlight luminal masses or when colonic displacement (via mass, organomegaly, adhesions) cannot be determined by survey abdominal radiography.

**Colonoscopy**

Colonoscopy with mucosal biopsy often helps provide a definitive diagnosis of colonic mucosal disease. Either flexible colonoscopy or rigid proctoscopy may be performed. Rigid proctoscopes are inexpensive and easy to use but only permit endoscopic evaluation of the distal colon and rectum. Flexible endoscopy is generally preferred as it enables evaluation of the entire colon, caecum and potentially the distal ileum via retrograde ileoscopy. Proper patient preparation is critical for successful colonoscopy. It is begun by withholding food for 18–24 hours before the endoscopic procedure. In dogs, the administration of two or three doses of a colonic electrolyte lavage solution (e.g. polyethylene glycol electrolyte solution at a dose of 20 ml/kg given 4–6 hours apart orally) the afternoon before endoscopy will adequately cleanse the colon. This is followed by the administration of a warm-water enema the morning of the procedure to optimize mucosal visualization. Cats are typically prepared for colonoscopy by administering several tepid water enemas (20 ml/kg rectally for each enema procedure), although oral lavage solutions can be given via a nasoesophageal tube using a syringe pump.

Abnormal endoscopic observations may include erythema, increased mucosal granularity, increased friability and erosions. Mass lesions (e.g. granulomatous, inflammatory or neoplastic) are predominately observed in the descending colon and rectum (see Chapter 4). Colonic mucosal biopsy specimens (10–12 total from all three colonic regions) are always obtained for histopathological interpretation regardless of the endoscopic appearance.

**Diseases of the colon****Acute colitis**

Acute large bowel diarrhoea is common and generally self-limiting. Potential causes include diet, bacteria and/or their toxins, viral agents and parasites. Rarely is the underlying cause identified, necessitating non-specific symptomatic treatment. Reduced oral intake of a low fat, highly digestible diet, fed at frequent intervals is recommended. Either nutritionally balanced home-made rations or ready-made commercial GI diets can be used. Hypoallergenic diets may be used successfully in some patients. Fibre supplementation is often prescribed for large bowel diarrhoea, since it affects large bowel function by normalizing motility, by binding colonic irritants, and by nourishing and protecting the colonic mucosa (e.g. via fermentation of soluble fibre into SCFAs).

Acute colitis which is non-responsive to dietary management may require anti-diarrhoeal drugs (see Appendix 1). These drugs (e.g. motility modifiers such as diphenoxylate or loperamide) are generally reserved for short-term use of 3–5 days duration. Antibiotics should not be routinely administered in cases of acute colitis of undetermined cause because of their adverse effects on normal intestinal flora and their tendency to promote resistant strains of bacteria.

**Parasitic colitis**

Parasitic colitis is a common cause for colitis affecting dogs in parts of Europe and the United States. *Trichuris vulpis* (whipworms) may infest the proximal colon causing intermittent diarrhoea with blood and mucus at the end of the stool. Eosinophilia, anaemia and hypoalbuminaemia are possible, although uncommon. Diagnosis is made by finding eggs in faeces or parasites during colonoscopy. The treatment of choice is fenbendazole. Due to the prepatent period of *Trichuris*, therapy should be repeated at 3 months. Trichomoniasis caused by *Pentatrichomonas hominis* infection may occur in both dogs and cats. However, diarrhoeic animals with large numbers of organisms may have other causes for diarrhoea. Motile trophozoites identified on direct faecal smears should be treated. Metronidazole typically eliminates the organism, although re-infection may occur. Worming is indicated in cases with mild signs of large bowel diarrhoea and when faecal parasite examinations are negative.

**Infectious disorders****Bacterial colitis**

Enteropathogenic bacteria produce colonic disease by invading the epithelium (i.e. enteroinvasive bacteria) or by attaching to the mucosal surface without invading it and producing enterotoxins (i.e. enterotoxigenic bacteria) that are cytotoxic or that promote fluid and electrolyte secretion. Enteropathogenic bacteria of most clinical importance include *Salmonella* species, *Campylobacter jejuni* and *Clostridium* spp.

**Salmonellosis:** *Salmonella* spp. are Gram-negative bacilli which are occasionally isolated from the faeces of normal and diarrhoeic dogs and cats. Clinical salmonellosis is quite uncommon indicating a prevalent carrier state. Infection is transmitted by the faecal–oral route or through ingestion of contaminated food or water. Rates of infection are greatest in young animals and in kennelling facilities with overcrowding and poor sanitation. *Salmonella* enterotoxigenicosis is characterized by acute, watery or mucoid diarrhoea, vomiting, fever, dehydration, anorexia and tenesmus. Most animals recover in 3–4 weeks, although the shedding of organisms may persist for up to 6 weeks. Rarely, salmonellosis progresses to a fatal bacteraemia or endotoxaemia.

Diagnosis of salmonellosis requires an appropriate history and clinical picture, microbial growth of the organism and elimination of other causes for enterocolitis. Therapy with antibiotics is controversial. Antibacterial therapy may alter the local microbial ecosystem, which prolongs shedding of *Salmonella*



organisms and encourages the development of a carrier state. Antibiotics are indicated when *Salmonella* invasion results in clinical (fever, malaise, bloody diarrhoea) or laboratory (neutropenia, hypoglycaemia) evidence of bacteraemia and endotoxaemia.

**Campylobacteriosis:** *Campylobacter jejuni* is a Gram-negative, microaerophilic bacteria that is an important pathogen in both humans and animals. It is probably transmitted via the faecal-oral route including contaminated food and water. Clinical signs are attributed to mild enterocolitis or enterotoxin-mediated secretory diarrhoea, which causes watery, mucoid diarrhoea that occasionally contains blood. In some animals, diarrhoea may be chronic or intermittent.

A presumptive diagnosis of campylobacteriosis may be based on signs, housing environment, and the observation of 'seagull shaped' organisms and increased faecal leucocytes on rectal cytology. Definitive diagnosis requires culture of *Campylobacter* from fresh faeces using selective media and growth conditions. Antibiotic therapy is usually curative. First choice antibiotics are erythromycin (10–15 mg/kg p.o. q8h for 7 days) or enrofloxacin (5 mg/kg p.o. q24h). Faecal cultures should be repeated one month following antibiotic therapy to ensure that infection has been eliminated. Antibiotic therapy may not eradicate the bacterium and re-infection is likely in kennel situations.

**Clostridial colitis:** *Clostridium perfringens* is a Gram-positive, obligate anaerobe that is part of the normal microflora in dogs and cats. Under ideal conditions, *C. perfringens* produces enterotoxins that cause large bowel diarrhoea. Colitis caused by *C. perfringens* is a major cause of acute, nosocomial and chronic large bowel diarrhoea, which occurs frequently in dogs. The diarrhoea is typically soft and may or may not contain blood and mucus. Another clostridium, *C. difficile*, has been isolated from both diarrhoeic dogs and cats, possibly subsequent to antimicrobial suppression of the resident flora, but is a considerably less common cause for bacterial colitis.

A presumptive diagnosis of *C. perfringens* infection is based on identification of increased faecal leucocytes and populations of large spores on faecal cytology and an assay for faecal enterotoxins using a reversed passive latex agglutination test. Routine dosages of amoxicillin, metronidazole or tylosin orally administered for 5–7 days are usually curative. Some patients also respond to high fibre diets, which alter the colonic microenvironment making conditions unfavourable for the spores to germinate. Prognosis for control is excellent.

**Yersiniosis:** *Yersinia enterocolitica* is a motile, Gram-negative facultative anaerobic bacteria that is uncommonly found in dogs. The organism is transmitted to dogs via the faecal-oral route or ingestion of contaminated food and water. *Yersinia* organisms may then invade the mucosa and/or produce enterotoxins, causing acute or chronic diarrhoea. Diagnosis requires growing the organism and eliminating other causes. Tetracycline, trimethoprim/sulphonamide and cephalosporins are usually effective therapies.

### Fungal and algal colitis

Histoplasmosis is a dimorphic fungus affecting dogs and cats in the USA. Infection occurs after inhaling the spores from the environment. Some infections result in pulmonary disease but may disseminate to other sites, including the GI tract. Colonic disease is common in dogs with disseminated disease where the mycotic infection causes extensive granulomatous tissue reaction. Signs vary in affected dogs from mild, chronic large bowel diarrhoea to severe disease causing tenesmus, haematochezia, faecal mucus, fever and weight loss. Diagnosis requires identification of the aetiological agent in mucosal biopsy specimens or colorectal cytological samples. Special stains (e.g. Periodic acid-Schiff stain, PAS) may be required to confirm that the organism is present in histological specimens. Therapy usually consists of itraconazole (10 mg/kg p.o. q12–24h) alone or in combination with amphotericin B (0.25–0.5 mg/kg i.v. q48h, up to a total cumulative dose of 5–10 mg/kg in dogs and 4–8 mg/kg in cats). Prognosis depends on disease dissemination but is generally good with long-term (4–6 month) antifungal therapy.

Other mycoses affecting the bowel are relatively uncommon. Both *Pythium* spp. (pythiosis) and several genera of zygomycetes (zygomycosis) may deeply invade digestive tissues causing severe granulomatous gastroenteritis. Pythiosis is most common in young, large-breed dogs that reside in the southern USA. Signs include chronic intractable diarrhoea and vomiting, anorexia, depression and weight loss. Physical examination often reveals an abdominal mass or marked regional thickening of the bowel. Diagnosis depends on histological identification of the organisms in mucosal biopsy samples. Treatment is radical surgical excision of the granulomatous mass since these fungi are resistant to standard antifungal drugs. The prognosis is guarded.

*Prototheca* spp. are ubiquitous unicellular algae that may rarely colonize the GI tract of dogs and cats, causing severe ulcerating enterocolitis. Dissemination is common with preferential sites including the eyes, visceral organs and the central nervous system. Diagnosis requires organism identification in affected tissues. There is no effective treatment and the prognosis is poor.

### Chronic colitis (inflammatory bowel disease)

IBD broadly refers to a group of idiopathic chronic GI disorders characterized by infiltration of the GI tract with inflammatory cells. Recent studies involving animal models of intestinal inflammation have identified interactions between the mucosal immune system, the host genetic susceptibility and environmental factors (e.g. normal resident microflora) as potential factors in disease development. Several pathogenic mechanisms have been proposed for chronic intestinal inflammation including an abnormal immune response to a luminal pathogen or abnormal luminal constituent, or an aberrant mucosal immune response to a normal luminal constituent, such as a dietary or microbial antigen. Clinical signs in affected animals are attributed to the effects of mucosal cellular infiltrates and inflammatory mediators (see Chapter 20).

A diagnosis of IBD is one of exclusion and requires ruling out many other diseases that may cause intestinal inflammation. Systemic diseases, chronic parasitism, dietary sensitivity, infectious diseases and alimentary neoplasia are the major differential diagnoses for IBD. Histological evaluation of mucosal biopsy specimens is required for a definitive diagnosis. Unfortunately, no standard microscopic grading system for IBD lesions has been established in dogs or cats. Furthermore, biopsy interpretation is very subjective from one pathologist to the next and is further hampered by a variety of procurement and processing artefacts inherent in evaluation of endoscopic specimens. A definitive histological diagnosis of IBD should be based upon microscopic evidence of mucosal inflammation, which includes:

- Mucosal glandular loss, necrosis or immaturity
- Epithelial erosion or ulceration
- Villous atrophy, fusion or collapse
- Fibrosis or oedema in the lamina propria.

An objective histological grading scheme for the diagnosis of canine and feline IBD has been proposed and has proven useful in numerous clinical and research investigations. Using this system, histological severity of IBD is determined by the extent of epithelial-glandular alterations rather than subjective evaluation of lamina propria cellularity. It is noteworthy that increases in mucosal immune cell populations may be a reflection of the normal immunological responses to diverse dietary and microbial stimuli. Changes in mucosal cellularity alone, without other evidence of inflammation or enterocyte injury, should be interpreted cautiously and are unlikely to be IBD. Nevertheless, veterinary pathologists continue to use standard classification schemes, based upon the predominant infiltrating cell type to define chronic colitis in dogs and cats (see Chapter 5).

**Lymphocytic-plasmacytic colitis:** Lymphocytic-plasmacytic colitis (LPC) is the most common form of chronic colitis in the dog and cat. As in most cases of IBD, affected animals are middle-aged or older, and clinical signs are generally cyclical with tenesmus, mucoid faeces and haematochezia predominating. Abnormalities observed during endoscopy may include increased mucosal friability, increased mucosal granularity, loss of submucosal vascularity and erosions. Absence of these observations does not eliminate LPC so biopsy samples should be collected.

**Eosinophilic colitis:** Eosinophilic colitis (EC) may represent a variant of IBD or may occur as an allergic manifestation to dietary or parasitic antigens. The prevalence of EC is considerably less than that for LPC. As is the case with LPC, middle-aged animals are affected most frequently. Physical examination, including digital examination of rectal mucosa, may detect a roughened irregular mucosa in dogs and cats with EC. Mucosal biopsy samples are required for definitive diagnosis and yield a diffuse infiltration of eosinophils (with perhaps lesser numbers of cell types) within the colonic mucosa. The mucosa will be more friable on endoscopic examination and may be ulcerated as compared with LPC.

**Chronic histiocytic ulcerative colitis:** Chronic histiocytic ulcerative colitis (CHUC) is the least frequently diagnosed IBD variant. Affected dogs present with intractable large bowel diarrhoea, haematochezia or tenesmus of variable severity. Lethargy, anorexia and weight loss are commonly observed. Boxers are predisposed to CHUC and the disease is diagnosed most frequently in male dogs <1 year of age. Histologically, lesions are characterized by a mixed inflammatory infiltrate with PAS-positive histiocytes within the mucosa. Colonoscopy usually reveals increased mucosal granularity, friability and diffuse erosions. The prognosis with this IBD variant is usually very poor. One recent report suggests that clinical signs may resolve with enrofloxacin therapy (rather than traditional immunosuppressive therapy) indicating either an unidentified infection or a possible causal role for the resident microflora in mediating intestinal inflammation of CHUC.

**Dietary treatment:** Dietary therapy, while often not curative alone, is extremely important in the long-term management of most diseases of the colon or anorectum. Dietary therapy (Figure 21.6) may consist of:

- Feeding a novel protein (hypoallergenic) diet
- Feeding a highly digestible diet
- Feeding a high fibre diet.

Each of these approaches has merits, depending on the clinical situation, but there is no specific way to determine which dietary approach might be successful. A reasonable approach is to feed one of the diets for a period of 3–4 weeks and if no positive response is observed then try a diet from the other categories. The most frequently recommended group of diets for therapy of large bowel disease in dogs and cats are those containing increased amounts of dietary fibre. This strategy is reasonable because dietary fibres, depending on their fermentability, influence luminal SCFA production as well as colonic motility, both of which may have a positive influence on the health and function of the colon (see above).

There is ample and increasing evidence that feeding dogs with colitis diets with increased amounts of dietary fibre is beneficial. The question remains, however, as to which fibre type is most appropriate. Dietary trials with either a hypoallergenic diet (e.g. novel protein source) or a highly digestible diet (see Figure 21.6) are prudent due to the role of dietary sensitivity or intolerance in the development of intestinal inflammation. However, most dogs or cats with food hypersensitivity or intolerance have primarily small bowel signs (e.g. vomiting, anorexia, weight loss, and sometimes chronic diarrhoea); thus, signs of large bowel diarrhoea alone are less likely to be due to allergic disease. Feeding patients with colonic disease highly digestible diets would be expected to be beneficial because less ingesta reaches the colon resulting in the production of a smaller faecal mass. This can be especially important in colonic disorders where there is severe mucosal disease, in patients with severe constipation or obstipation where motility is altered or absent, or in recto-anal diseases where

Diet category	Commercial canine diets	Specifics (protein/carbohydrate/fibre/other)
Hypoallergenic (Novel protein and carbohydrate sources)	Hill's Canine <b>d/d</b> (canned & dry) Eukanuba <b>Response Formula FP, KO</b> (canned & dry) IVD Canine <b>Limited Ingredient Diets</b> (canned & dry) Royal Canin Waltham Diets Canine <b>Select Protein</b> (canned & dry) Purina CNM <b>HA Formula/Canine</b> and Purina CNM <b>LA Formula/Canine</b> (dry)	Hill's canned: whitefish or lamb & rice, dry: egg & rice, duck & rice, salmon & rice Eukanuba: canned/dry: catfish, herring meal & potato, kangaroo & oat IVD: rabbit, venison, lamb, whitefish or duck & potato Waltham canned: lamb & rice, dry: catfish & rice, capelin & tapioca Purina <b>HA</b> (dry): modified soy protein & corn starch, <b>LA</b> (dry): salmon meal, trout & rice
Highly digestible (Low fat, low residue)	Hill's Canine <b>i/d</b> (canned & dry) Eukanuba <b>Low Residue/Canine</b> (dry) (Intestinal Formula) IVD <b>Canine Neutral Formula</b> (dry), IVD <b>Sensitive Formula</b> (canned & dry)  Royal Canin Waltham Canine <b>Low Fat Diet</b> (canned & dry) Purina CNM <b>Canine EN Formula</b> (canned & dry)	Hill's canned & dry: soy fibre (soluble fibre) Eukanuba beet pulp fibre (mixed fibre), fructooligosaccharides (FOS), fish oil IVD Neutral: duck & potato, oat bran and oat hulls fibre, FOS IVD Sensitive canned: chicken, egg, cottage cheese, oat bran and guar fibre (soluble), FOS; dry: lamb, rice & potato, pea fibre (mixed), FOS Waltham canned: fish, meat & rice, cellulose powder, guar gum fibre (soluble fibre); dry: cellulose (insoluble fibre), soy protein & rice Purina canned: beef, rice, egg product, gum arabic, medium chain triglycerides (MCTs) and fish oil; dry: rice & corn, min. fibre, MCTs & fish oil
High dietary fibre (Low fat, high fibre)	Hill's Canine <b>w/d</b> (canned & dry)  Hill's Canine <b>r/d</b> (canned & dry)  IVD Canine <b>Hifactor Formula</b> (canned & dry)  Royal Canin Waltham Canine <b>High Fibre Diet</b> (dry) Purina Canine <b>DCO Formula</b> (dry), Canine <b>OM Formula</b> (canned & dry)	Hill's <b>w/d</b> canned: cellulose fibre (insoluble fibre); dry: peanut hulls (insoluble fibre) Hill's <b>r/d</b> canned: cellulose (insoluble fibre); dry: peanut hulls (insoluble fibre) IVD canned: cellulose, rice flour & guar fibre (mixed fibre), FOS, fish oil; dry: rice flour, rice hulls (insoluble fibre), FOS, fish oil Waltham: wheat bran & cellulose (mixed fibre) Purina <b>DCO</b> dry: beep pulp, pea fibre (mixed), fish oil Purina <b>OM</b> canned: pea fibre & beet pulp (mixed); dry: cellulose, wheat gluten (mixed)
Diet category	Commercial feline diets	Specifics (protein/carbohydrate/fibre/other)
Hypoallergenic (Novel protein and carbohydrate sources)	Hill's Feline <b>d/d</b> (canned) Eukanuba <b>Response Formula LB</b> (canned) IVD Feline <b>Limited Ingredient Diets</b> (canned & dry) Royal Canin Waltham Diets Feline <b>Select Protein</b> (canned & dry)	Hill's canned: lamb & rice Eukanuba: canned: lamb & barley IVD: duck, rabbit, venison & lamb & green peas Waltham canned: venison & rice, dry: duck & rice
Highly digestible (Low fat, low residue)	Hill's Feline <b>i/d</b> (canned & dry) Eukanuba <b>Low Residue/Feline</b> (canned & dry) IVD <b>Feline Neutral Formula</b> (dry), Purina Feline <b>EN Formula</b> (soft moist)	Hill's canned & dry: soy fibre (soluble fibre) Eukanuba beet pulp fibre (mixed fibre), FOS, fish oil IVD Neutral: duck & potato, beet pulp (sol. fibre), fish oil, FOS Purina soft: poultry, soybean, fish, vegetable gums, MCTs and fish oil
High dietary fibre (Low fat, high fibre)	Hill's Feline <b>w/d</b> (canned & dry) Hill's Feline <b>r/d</b> (canned & dry) IVD Feline <b>Hifactor Formula</b> (canned & dry)  Royal Canin Waltham Feline <b>Calorie Control Diet</b> (moist & dry) Feline <b>OM Formula</b> (canned & dry)	Hill's <b>w/d</b> canned & dry: cellulose fibre (insoluble fibre) Hill's <b>r/d</b> canned & dry: cellulose (insoluble fibre) IVD canned: cellulose & guar fibre (mixed fibre), FOS, fish oil; dry: poultry by products, corn & rice, pea fibre, beet pulp (mixed fibre), FOS, fish oil Waltham: moist: guar gum (soluble), cellulose, dry: cellulose (insoluble fibre) Purina <b>OM</b> canned: pea fibre & oat fibre (mixed); dry: soybean hulls (insoluble)

**21.6** Commercially available prescription diets for the management of colonic diseases. This list is not intended to be exhaustive but representative of the many commercial products available in Europe and North America.

minimal production of faeces is desirable. Since long-term dietary management may be required in pets with colonic or recto-anal disease, use of a commercial diet (rather than a home-made diet or a diet supplemented with fibre) is often the best approach. However, adding one or two tablespoons per 25 kg bodyweight of psyllium, pumpkin or other mixed fibres (see Appendix 1) to the animal's regular diet is another way of increasing the dietary fibre content.

**Medical treatment:** There are several drug treatment options for the management of colitis in dogs and cats where reducing inflammation is the primary means of controlling the clinical disease (see also Chapter 28). One approach in dogs is to use non-steroidal anti-inflammatory drugs (NSAIDs) such as sulfasalazine. 5-Aminosalicylic acid (5-ASA) is the active moiety and its mechanism of action is its anti-leucotriene activity and free radical scavenging ability. Newer

aminosalicylic acid drugs (e.g. mesalazine) preparations are available that allow delivery of 5-ASA without the sulphur moiety, which is believed to be responsible for the numerous adverse effects (e.g. keratoconjunctivitis, vomiting) associated with sulfasalazine use. These newer products include oral delayed release preparations of 5-ASA that prevent its absorption in the upper GI tract, and products that have an azo bond like sulfasalazine, but the sulphur component is replaced with another amine (balsalazide) or a second 5-ASA (olsalazine). Sulfasalazine and olsalazine are the most common products used in dogs with colitis and have established dosages (see Appendix 1).

The use of these drugs in cats is not recommended due to their increased sensitivity to NSAIDs and increased potential for toxicity. Therapy of all cats (and many dogs) with colitis often requires use of anti-inflammatory or immunosuppressive doses of corticosteroids. Long-term (months) and high dose (>2 mg/kg/day) corticosteroid therapy may be associated with side-effects that limit its use or require alternative therapy choices. Generally, oral prednisolone or methylprednisolone is the preferred corticosteroid for use in both dogs and cats rather than dexamethasone, betamethasone or triamcinolone. In humans, efforts to reduce the corticosteroid side-effects include using rectal suppositories or enemas containing corticosteroids, or use of other newer glucocorticosteroid preparations, which cause fewer systemic side-effects (e.g. budesonide). Budesonide has been used in limited numbers of dogs and cats with IBD and there are a few reports of effectiveness. However, controlled trials using this drug have not been published. The addition of immunosuppressive drugs to the medical therapy protocol is required to manage severe or refractory cases of colitis. The drugs used most commonly are azathioprine or chlorambucil, but ciclosporin is also another therapeutic option (see Appendix 1). Therapy with these drugs can be associated with significant side-effects. Thus, appropriate monitoring and adjustment of the drug dose is recommended. In dogs or cats with severe colitis, combination therapy, using corticosteroids, immunosuppressive drugs, NSAIDs or enemas may be required to achieve adequate control. This has been especially true in Boxer dogs with histiocytic ulcerative colitis, one of the most severe IBD variants.

Antibiotics effective against anaerobic bacteria (amoxicillin, ampicillin, tylosin, clindamycin or metronidazole; see Appendix 1) are often effective in reducing bacterial overgrowth and potential enterotoxin production. Resolution of clinical signs usually occurs following 3–5 days of antibiotic therapy in dogs or cats with acute disease. Alternatively, in animals with chronic colitis, long-term therapy with metronidazole is required to maintain clinical remission. The actions of metronidazole may be attributable to its direct inhibition of cell-mediated immunity or its antimicrobial effect on phlogistic resident microflora.

### Disorders affecting colonic motility

**Intussusception:** Both ileocolic and caecocolic intussusceptions may occur in dogs and cats, with the former being more common. Lesions may develop

secondary to other disease (e.g. parvovirus enteritis, whipworm infestation) but the cause in many cases is unknown. Acute intussusception in the dog classically causes scant bloody diarrhoea, vomiting and abdominal pain. Most affected cats do not have diarrhoea. Chronic intussusceptions may cause diarrhoea without mucus, haematochezia, vomiting or abdominal pain. Abdominal palpation may reveal a mass or a markedly thickened loop of bowel. Occasionally, intussusceptions may 'slide' in and out making palpation unreliable. Survey radiography is seldom diagnostic. Ultrasonography will confirm the presence of the classic 'target' lesion if present in animals with 'sliding' or 'intermittent' intussusception. Colonoscopy may find the telescoped intestine within the colonic lumen. Therapy involves either reduction or resection of the intussusception.

**Irritable bowel syndrome:** Irritable bowel syndrome (IBS) is defined as an uncommon, non-inflammatory large bowel disease associated with abnormal colonic myoelectrical function. Clinical signs are characterized by chronic intermittent large bowel diarrhoea (tenesmus, faecal mucus and/or haematochezia), which is most often seen in large-breed dogs. A diagnosis of IBS is one of exclusion, made only by normal colonoscopic biopsy results and ruling out other causes such as dietary, parasitic, infectious and chronic (IBD) colitis. The primary treatment consists of supplementing dietary fibre (e.g. psyllium, 1–3 tablespoon per meal) to correct abnormal motility patterns. Patients that fail to respond to dietary management alone may benefit from motility modifying drugs, such as loperamide.

**Constipation:** Constipation denotes infrequent or difficult evacuation of faeces and is commonly observed in both dogs and cats. Prolonged and severe faecal impaction may result in irreversible megacolon which fails to respond to medical management. Constipation is particularly common in middle-aged and older cats and is associated with diverse aetiologies (Figure 21.7). It is noteworthy that most cases of feline constipation are attributable to idiopathic megacolon. Diagnosis of constipation is made on history, abdominal palpation of faecal impaction, and/or radiographic confirmation of colonic distension. Specific therapy depends on the severity of constipation and the underlying cause. Animals with mild to moderate constipation are treated with a combination of water enemas, dietary fibre supplements, laxatives (e.g. dioctyl sodium sulfosuccinate (DSS), lactulose) and prokinetic (e.g. cisapride) agents (see Figure 21.6 and Chapter 28). Colectomy should be considered in animals with severe, refractory constipation or idiopathic megacolon.

**Colonic neoplasia:** Both malignant and benign tumours affect the colon in dogs and cats. In dogs, adenocarcinoma is diagnosed most frequently followed by lymphosarcoma and leiomyosarcoma. The majority of canine large bowel neoplasms are located in the descending colon and rectum, although leiomyosarcomas often occur in the caecum. Adenocarcinoma and lymphosarcoma are the most common malignant tumours in cats, followed by mast cell tumours. Malignant feline tumours

Aetiology	Cause
Dietary	Low residue diet Excess fibre Ingested foreign material e.g. bones, hair accumulation
Environmental	Inactivity (obesity, hospitalization) Change in routine Unsanitary living conditions
Painful defecation	Dyschezia (see Chapter 6)
Colonic obstruction	Extraluminal: Enlarged prostate Old pelvic fracture Intraluminal: Stricture, tumour or foreign body Perineal hernia/rectal diverticulum
Neuromuscular	Megacolon Lumbosacral spinal cord disease
Fluid or electrolyte imbalance	Dehydration Hypokalaemia Hypercalcaemia
Drug-induced	Anticholinergics; phenothiazines; opiates Laxative abuse

**21.7** Aetiology of constipation.

usually arise in the ileocolic and descending colonic regions. Regional metastasis of adenocarcinoma to the peritoneum and mesenteric lymph nodes occurs in 50% of cats.

Most malignant tumours occur in older dogs and cats. Clinical signs are often indistinguishable from other causes of chronic colitis. Physical examination in animals with malignant colonic tumours may reveal dyschezia, palpable abdominal mass, mesenteric lymphadenopathy, rectal mass or excessive mucosal granularity on digital examination. Imaging (diagnostic radiography and ultrasonography) provides important staging information concerning disease burden. Colonoscopy with mucosal biopsy confirms a definitive diagnosis. Treatment of colonic neoplasia is variable depending on tumour type, location and extent of metastasis. Surgical excision is recommended for

focal adenocarcinoma and leiomyosarcoma. Diffuse colonic lymphosarcoma is best treated with multiple drug chemotherapy, such as the Madison–Wisconsin or UW-25 protocols. The long-term prognosis for most malignant neoplasms is guarded. Surgical resection or endoscopic polypectomy is recommended in dogs with benign (adenomatous) polyps and carries an excellent prognosis.

**Diseases of the anorectum**

See Chapter 22 for information on diseases of the anorectum.

**References and further reading**

Buddington RK and Sunvold GD (1998) Fermentable fiber and the GI tract ecosystem. In: *Recent Advances in Canine and Feline Nutrition, Vol III*, ed. GA Reinhart and DP Carey, pp. 449–462. Orange Frazier Press, Wilmington

DeNovo RC and Bright RM (2000) Recto-anal diseases. In: *Textbook of Veterinary Internal Medicine 5<sup>th</sup> edn*, ed. SJ Ettinger and EC Feldman, pp. 1257–1277. WB Saunders, Philadelphia

Evans HE (1993) Colonic and rectoanal anatomy. In: *Miller's Anatomy of the Dog*, pp. 385–461. WB Saunders, Philadelphia

Fossum TW (2002) Surgery of perineum, rectum and anus. In: *Small Animal Surgery*, pp. 415–450. WB Saunders, Philadelphia

Guilford WG (1996) Approach to clinical problems in gastroenterology. In: *Strombeck's Small Animal Gastroenterology, 3<sup>rd</sup> edn*, ed. WG Guilford *et al.*, pp. 50–76. WB Saunders, Philadelphia

Guilford WG (1996) Small and large intestine: normal structure and function. In: *Strombeck's Small Animal Gastroenterology, 3<sup>rd</sup> edn*, ed. WG Guilford *et al.*, pp. 318–350. WB Saunders, Philadelphia

Jergens AE (1999) Inflammatory bowel disease: current perspectives. *Veterinary Clinics of North America: Small Animal Practice* **29**, 501–521

Roudebush P (1998) Adverse reactions to foods: a clinical nutritionist's perspective. *Proceedings of the American Academy of Veterinary Dermatology and American College of Veterinary Dermatology*, **14**, 69

Sherding RG and Johnson SE (2000) Diseases of the Intestines. In: *Saunders's Manual of Small Animal Practice, 2<sup>nd</sup> edn*, ed. SJ Birchard and RG Sherding, pp. 787–815. WB Saunders, Philadelphia

Twedt DC (1997) Chronic large bowel diarrhea in dogs. *Proceedings of the American College of Veterinary Internal Medicine* pp. 342–345

Willard MD (1998) Gastrointestinal drugs. *Veterinary Clinics of North America* **28**, 377–394

Willard MD (2001) Colonoscopy, proctoscopy, and ileoscopy. *Veterinary Clinics of North America: Small Animal Practice* **31**, 657–669

Zoran D (1999) Pathophysiology and management of canine colonic diseases. *Compendium on Continuing Education for the Practicing Veterinarian* **21**, 824–841

# Disorders of the perineum and anus

John M. Williams

## Anatomy and physiology

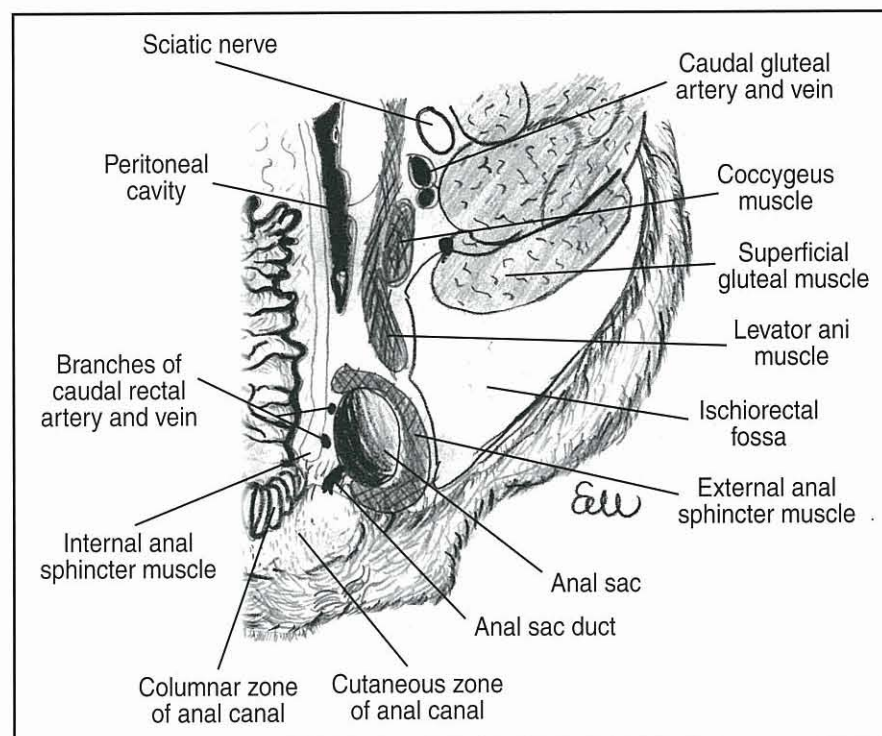
### Perineum

The perineum is made up of the structures which make up the boundary of the pelvic outlet. It extends externally from the dorsal aspect of the scrotum or vulva to the base of the tail; its lateral margins extend to the skin covering the tubers ischii and superficial gluteal muscles. The deep portion is delineated by the ischial arch ventrally, the third coccygeal vertebra dorsally and, in the dog, by the sacrotuberous ligament laterally. Due to the absence of a sacrotuberous ligament in the cat the lateral margins are less well defined. The perineum essentially surrounds the anal and urogenital canals. Within the perineum the most important structures are those which make up the pelvic diaphragm; namely levator ani and coccygeal muscles. These muscles act as a division between the pelvic canal and the wedge shaped ischiorectal fossa, which is bound laterally by the caudal portion of

the superficial gluteal muscle, medially by the external anal sphincter levator ani and coccygeus muscles, and ventrally by the internal obturator muscle (Figures 22.1 and 22.2).

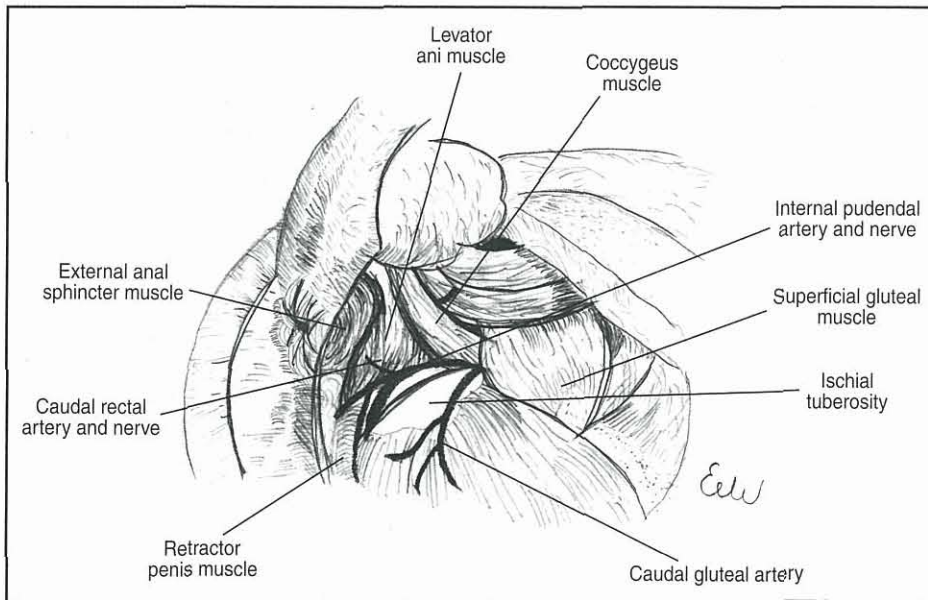
The muscles of the pelvic diaphragm are crucial in supporting the rectum and act not only as a physical partition but are essential in counteracting the effects of raised intra-abdominal pressure. Failure of these muscles has the potential to allow abdominal viscera to herniate through the pelvic canal, as happens in a perineal hernia (see below).

Within the ischiorectal fossa lies the internal pudendal artery and vein and the pudendal nerve, together with fat. The neurovascular structures course caudomedially from the ventrolateral aspect of the coccygeus, over the internal obturator muscle towards the clitoris or root of the penis. Lymphatic drainage of the perineum is via the internal (medial) iliac lymph nodes, while the cutaneous anal area drains via the superficial inguinal lymph nodes.



### 22.1

Horizontal section through the perineal area.



**22.2** Schematic drawing of perineal anatomy.

### Anus

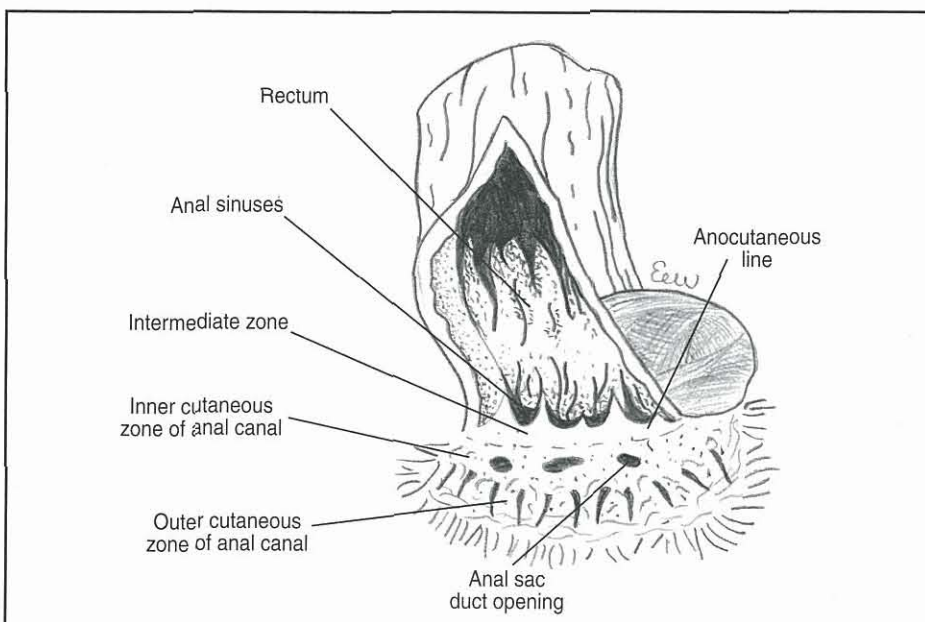
The anus, more correctly termed the anal canal, is approximately 1 cm in length and comprises three zones:

- Cutaneous zone
- Intermediate zone
- Columnar zone.

The most caudal zone, the cutaneous zone, is divided into internal and external regions. The external region is the keratinized hairless area and contains the circumanal glands (hepatoid or perianal glands). The 'true' anal glands together with the anal sacs are to be found in the internal region. The anal sacs (Figure 22.3) are invaginations of the internal region and lie between the internal and external anal sphincter muscles. The intermediate zone forms a scalloped fold, which is termed the anocutaneous line and is composed of a stratified squamous epithelium. The cutaneous zone

together with the anal glands are also lined with stratified squamous epithelium. The inner columnar zone, which is lined by mucosa, comprises longitudinal ridges that fold to create a number of pockets or anal sinuses (Figure 22.3).

The internal anal sphincter muscle, unlike the external anal sphincter muscle, is composed of smooth muscle and is a continuation and thickening of the rectal muscularis. It is innervated by autonomic fibres from the pelvic plexus. Sympathetic innervation is derived from the hypogastric nerve and parasympathetic innervation from the pelvic nerves. The external anal sphincter is composed of striated muscle, which encompasses the anus and is essential for faecal continence. The caudal rectal branch of the pudendal nerve provides motor innervation to the external anal sphincter muscle (see Figure 22.1) and the perineal branch provides sensory input; smaller branches of the pudendal nerve supply the anal canal.



**22.3** Schematic drawing of the anal canal.

The sympathetic nerve supply to the internal anal sphincter muscle is excitatory whilst the parasympathetic supply is inhibitory. This is in contrast to the rectum where the situation is reversed, i.e. sympathetic stimulation leads to relaxation of the rectum and contraction of the internal anal sphincter.

The perineal reflex is elicited via stimulation of the perianal area, the response being contraction of the anus and flexion of the tail. This assesses the pudendal nerve, which arises from spinal cord segments S1–S3. Loss of the perineal reflex suggests damage to the spinal cord at, or caudal to, the level of lumbosacral vertebra 5 or 6.

### 'True' anal glands

These are modified tubular sweat glands, which lie cranio-lateral to the circumanal glands and open into the intermediate zone (see Figure 22.3). The secretion is fatty and their true function is unknown.

### Circumanal (hepatoid or perianal) glands

Circumanal glands are androgen-sensitive glands found subcutaneously up to 4 cm from the anal canal. The glands have a deep non-secretory, non-sebaceous portion and a superficial sebaceous portion. Under the influence of androgens the circumanal glands continue to grow throughout a male dog's life.

### Anal sacs (paranal sinuses)

Anal sacs are paired structures, which are invaginations of the inner area of the cutaneous zone. The sacs are positioned at 4 and 8 o'clock relative to the anus; the diameter of the fundus is usually 8–10 mm in dogs, with the ducts being 1–2 mm wide. In the dog, the duct is predominantly lined by sebaceous glands whilst in the fundus apocrine glands are more prevalent. The combined secretion from these glands, together with bacteria and desquamated epithelial cells, creates a malodorous oily/pasty fluid. In cats there are few apocrine glands, with sebaceous glands being found in both duct and fundus.

## Diagnostic approach

### History

Diseases of the perineum and anus are likely to present with clinical signs that may be easily confused with colorectal disease, such as haematochezia, tenesmus or dyschezia. It is therefore essential that a good history is taken and that a thorough physical examination is carried out. Haematochezia is often seen with anal furunculosis (perianal fistula) or ulcerated circumanal gland tumours in which blood is added to faeces after it has been passed. Dyschezia and tenesmus are very common in conditions such as anal sacculitis, perineal herniation, anal furunculosis and anal tumours. With some perineal disease there may be constipation or obstipation due to an obstruction, as is seen with *atresia ani*, intrapelvic or perineal masses, diffuse anal or perianal tumours, and extensive anal furunculosis. In cases of perineal hernia where there has been herniation and retroflexion of the bladder or where a perineal mass may compress the urethra, dysuria or stranguria may be present.

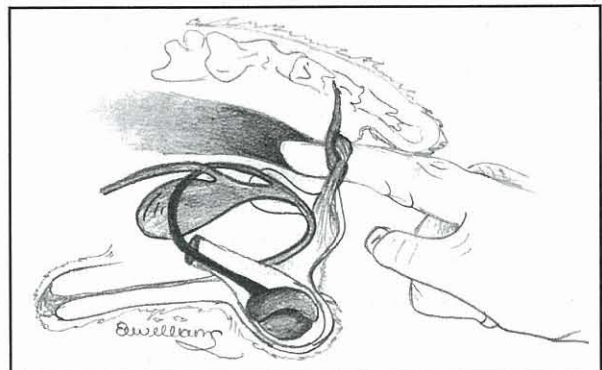
The age and sex of the patient are also helpful in formulating a differential diagnosis: *atresia ani* will be prevalent in the very young; an older entire male dog with a perineal swelling may have a perineal hernia; and a bitch over 10 years old with a perianal swelling may have an anal sac adenocarcinoma.

### Physical examination

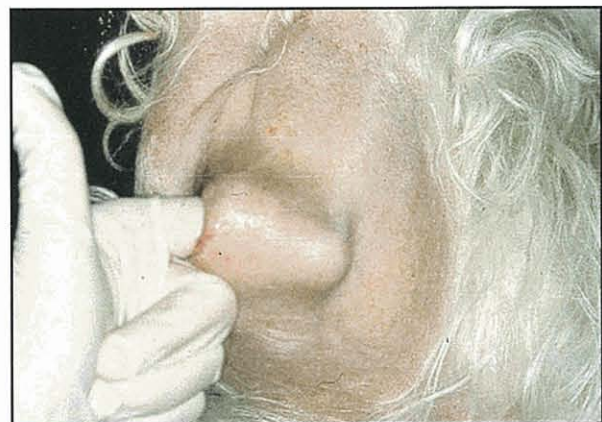Together with the history, a physical examination is perhaps the most important diagnostic step in many cases. It is also important to remember that many perineal and anal diseases are very painful and that a thorough physical examination of the area may have to be carried out with the patient either sedated or anaesthetized. In addition to examining the perineal region a thorough general physical examination is also required.

### Palpation and digital rectal examination

Palpation of the area is essential and may give some indication as to whether the swelling has been caused by a hernia or a space-occupying mass. External palpation should be combined with a digital rectal examination (Figure 22.4); it is extremely helpful in diagnosing both hernias and intrapelvic masses extending into the perineum. If an intrapelvic mass is suspected then caudal abdominal palpation is also useful. With perineal hernias, digital rectal examination will usually reveal that there is sacculuation and a lack of support for the rectum (Figure 22.5). The anal sacs should be palpated per rectum to assess size and for evidence of any mass, or to express them (Figure 22.6).



22.4 Digital rectal examination.



22.5 Rectal examination shows lack of lateral support in a patient with a perineal hernia.





22.6

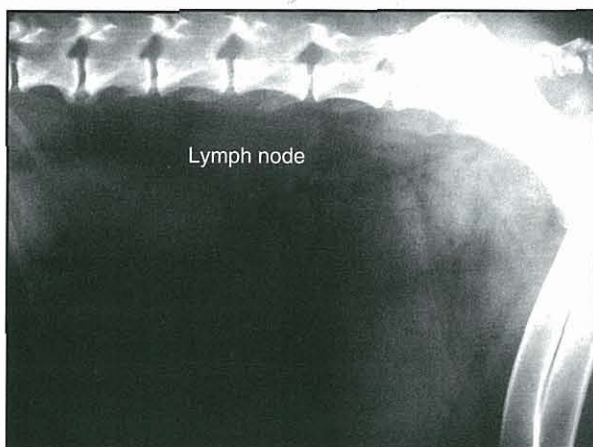
Digital per rectum palpation of the anal sacs.

If an anal or perianal mass is palpated, it may be possible in small dogs to palpate the medial iliac lymph node; the superficial inguinal lymph nodes should also be palpated.

### Diagnostic imaging

#### Radiography

Radiography can be used to assess the extent of local lesions and importantly to check, when tumours are suspected or diagnosed, for evidence of distant spread. Both lateral and ventrodorsal plain radiographs of the caudal pelvic area should be taken; these may show the extent of a mass lesion, evidence of constipation or obstipation, or a herniated bladder. The clinician should look for evidence of medial iliac lymph node enlargement (Figure 22.7) and take left



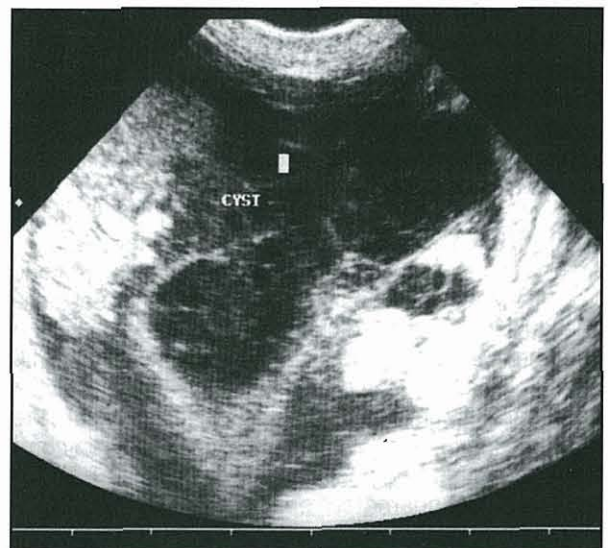
22.7

Radiograph showing an enlarged iliac lymph node.

and right lateral projections of the thorax for evidence of possible lung metastases. Positive and negative contrast studies may be helpful in delineating the urinary tract (pneumocystography, retrograde urethrography) or to assess the extent of an anal lesion (barium enema).

#### Ultrasonography

Where a perineal mass is present ultrasonography is invaluable in determining whether it is solid or fluid-filled (Figure 22.8). Both a retroflexed bladder and paraprostatic cysts are not uncommon in the ischio-rectal fossa. Ultrasonography can also be used to evaluate the prostate in cases where a paraprostatic cyst is suspected. Ultrasonography also aids in allowing accurate fine needle aspirates to be carried out on the mass or fluid-filled structure.



22.8

Ultrasound scan of a perineal prostatic cyst.

#### Proctoscopy

Proctoscopy is of limited value in assessing perineal and anal disease, though it is useful to evaluate possible concurrent colitis in patients with anal furunculosis.

### Clinical disorders of the perineum and anus

The clinical disorders of the perineum and anus are summarized in Figures 22.9 and 22.10.

- Perineal hernia
- Perineal and intrapelvic masses
- Paraprostatic cyst
- Perineal trauma

22.9

Perineal disorders.

**Atresia ani**

(Pseudocoprostasis)

Anogenital cleft

Anal sac disease:

- anal sacculitis
- anal sac impaction
- anal sac abscess
- anal sac adenocarcinoma

Anal furunculosis and perianal fistula

Anal stricture

Anal prolapse

Circumanal gland adenoma

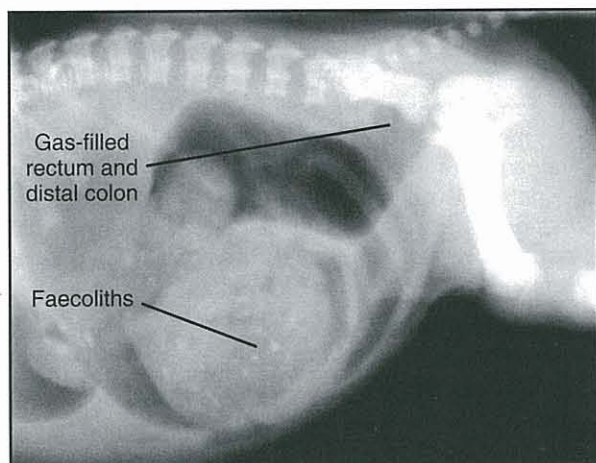
Perianal trauma

**22.10** Anal disorders.

**Atresia ani**

Congenital abnormalities of the anal region are thought to be rare but the recorded incidence may not be a true incidence as many are euthanized due to the poor prognosis associated with these conditions. Classically *atresia ani* is classified into four types:

- I. Congenital stenosis of the anus
- II. Persistent anal membrane with a blind-ending rectal pouch just cranial to the anus
- III. Closed anus with the rectum ending more cranially within the pelvic canal (Figure 22.11)
- IV. Anus and distal rectum are normal; proximal rectum ends as a pouch within the pelvic canal.

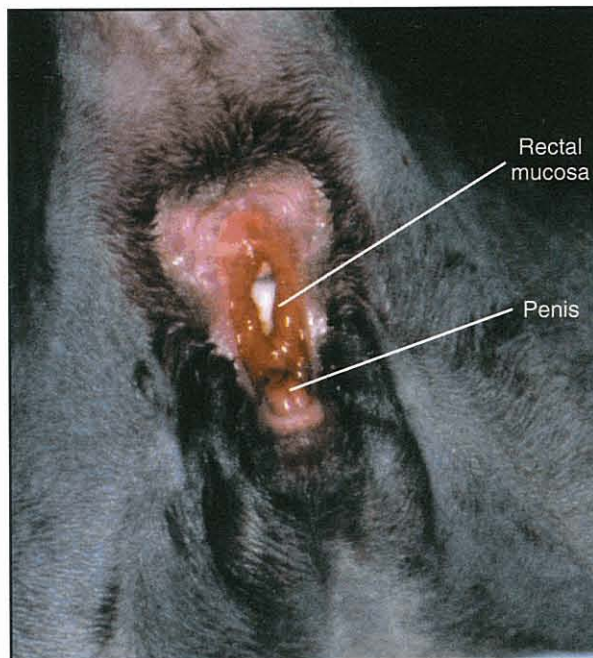


**22.11** Radiograph of a Boxer puppy with Type III *atresia ani*. (Courtesy of FE Crowsley)

These cases usually present in the first few weeks of life with a history of tenesmus and constipation. On examination they usually have an imperforate anus (apart from those patients with Type IV *atresia ani*) and are thin, in poor condition but are very pot bellied. Surgical correction may be attempted but is often unsuccessful and may require repeated procedures. Complications of surgery include recto-anal stricture formation, faecal incontinence, or constipation due to irreversible megacolon.

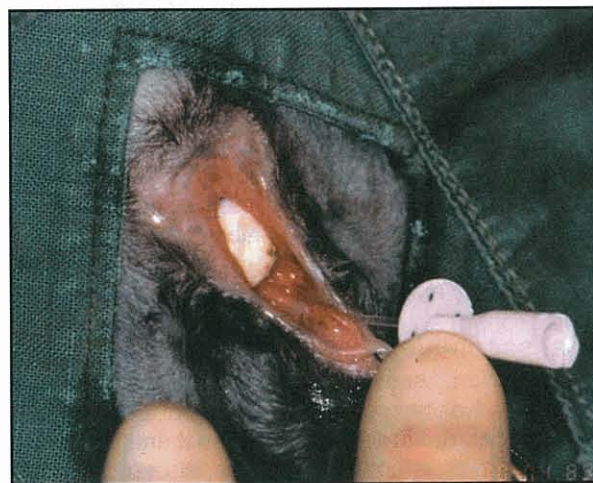**Anogenital clefts**

With anogenital clefts there is a failure of the embryological cloaca to separate so that there is direct communication between the anus and vagina or urethra (Figure 22.12). In males the condition is often associated with hypospadias (incomplete formation of the urethra ventrally); both faecal and urinary continence is usually maintained. In females faecal incontinence is common and more importantly there is often severe faecal contamination of the urinary tract, which may result in pyelonephritis.



**22.12** Anogenital cleft in a male Domestic Short-hair kitten.

Surgical correction (Figure 22.13) may be attempted in both males and females and can be successful, though wound dehiscence and infection are commonly encountered. In the male as well as reconstruction of the ventral anus, a scrotal urethroostomy may also be required in cases of hypospadias as there is often insufficient tissue present to allow reconstruction.



**22.13** Catheterization of a Domestic Short-hair kitten with an anogenital cleft prior to surgical reconstruction.

### Pseudocoprostasis

This is a condition, usually of long-haired animals, where perineal hair and faeces is matted over the anus, resulting in a physical obstruction of the anus. The condition tends to occur in poorly groomed individuals, especially following diarrhoea. Treatment simply involves clipping the hair away and removing any ano-rectal faecoliths.

### Anal sac disease

Anal sac problems account for approximately 12% of canine clinical presentations, though cats are less commonly presented for these problems. The classical presenting signs for any anal sac problem are:

- Chewing or licking excessively over the tail base or anus
- Reluctance or discomfort on sitting
- 'Scooting' – dragging the anus along the ground with the hind limbs extended
- Dyschezia may be noted in extreme cases
- Draining tracks in ruptured abscesses.

It is thought that most disease is related to some degree of obstruction of the anal sac duct, though the precise aetiology is not fully understood. Factors that are believed to initiate and/or perpetuate anal sac problems include:

- Stool consistency
- Diet
- Lack of anal sphincter muscle tone
- Inactivity
- Obesity
- Dogs with generalized seborrhoea
- Recent oestrus
- Anal furunculosis and/or perianal fistulae
- Breed predisposition:
  - Small toy breeds have small ducts
  - German Shepherd Dogs have very deep anal sacs which lie along the rectal wall.

### Anal sac impaction

Anal sac impaction is the most common presentation and is straightforward to treat by digital expression of the anal sacs situated at 4 and 8 o'clock. Internal (per rectum) compression is preferable and more effective than external compression. External compression is reserved for only the smallest of dogs or cats where digital rectal examination is not feasible. The anal sac secretion is viscous, often grey in colour and putty-like in consistency.

In some cases digital expression may be required at regular intervals and in chronic cases anal saccullectomy may be considered.

### Anal sacculitis

In cases of anal sacculitis the anal sacs are often very painful and either sedation or general anaesthesia may be required in order to express them. Following expression of infected anal sacs, they should be cannulated and flushed. The glands can be flushed with either sterile isotonic solution, such as lactated

Ringer's solution, or a mild antiseptic solution (e.g. 0.05% chlorhexidine). There is some debate as to the effectiveness of instilling an antibiotic, an antibiotic plus a corticosteroid, or a corticosteroid alone into the sacs after flushing. If there is an infection present, a suitably chosen systemic antibiotic is likely to prove more effective because the tissue concentration of the antibiotic can be maintained for longer than with a single application of a topical antibiotic. The effectiveness, or otherwise, of instilling corticosteroids has not been proven.

Anal sac flushing may be required at intervals of 10–14 days until the problem resolves. In a few refractory cases anal saccullectomy can be considered (see *BSAVA Manual of Canine and Feline Abdominal Surgery*).

### Anal sac abscessation

As with all abscesses it is essential to incise and drain the infected sacs, it is also beneficial to lavage with an isotonic solution or a dilute 0.05% solution of chlorhexidine (dilute povidone iodine is of little value as it is inactivated by organic matter). The incised sacs should be left open and the animal given a systemic broad spectrum antibiotic, pending the results of culture and sensitivity. The most frequently cultured organisms are *Escherichia coli*, *Streptococcus faecalis* and *Proteus* spp.

Recurrent anal sac abscessation is best managed by anal saccullectomy. The risks associated with this procedure include faecal incontinence and recurrent draining sinuses; the latter being associated with incomplete excision of the sac lining.

### Anal sac adenocarcinoma

Anal sac (apocrine) gland adenocarcinoma predominantly affects older bitches (over 90% of cases), is highly malignant and tends to metastasize readily to the medial iliac lymph nodes. The presenting clinical signs are those typically seen with anal disease and include dyschezia, tenesmus, flattened (ribbon-like) stools and a perineal swelling. Very occasionally a perianal mass is noted during a routine clinical examination.

Anal sac adenocarcinoma may also present initially with polydipsia and polyuria secondary to paraneoplastic hypercalcaemia related to a parathyroid hormone-related peptide produced by the mass.

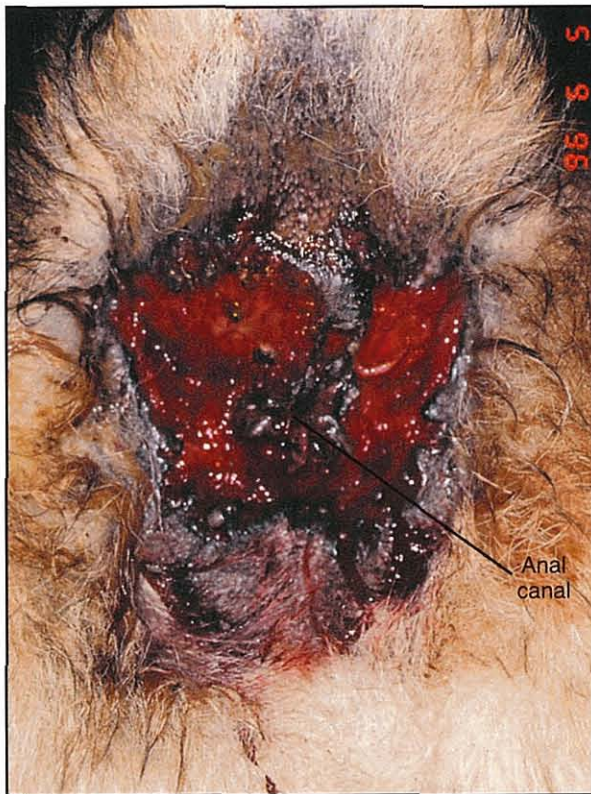
In all cases of a suspected anal sac mass it is important to obtain a full biochemistry profile to assess the concentrations of calcium and phosphate; it is also essential to assess renal function. In cases with hypercalcaemia, high rates of physiological (0.9%) saline should be administered to diurese calcium. Once normocalcaemic, furosemide may be administered (2 mg/kg intravenously) to prevent calcium resorption.

Since metastasis is reportedly seen in over 50% of cases at presentation, it is essential to assess the draining lymph nodes and to check for thoracic metastases. The medial iliac lymph nodes are occasionally palpable per rectum in small dogs or if the node is massive. However, it is better to take caudal abdominal radiographs or to use abdominal ultrasonography.

If there are no detectable metastases and the patient is normocalcaemic, the treatment of choice is surgical excision of the mass. The success in removal will depend on the size of the tumour, which can be between 1 and 10 cm. Potential postoperative sequelae include wound dehiscence, infection, faecal incontinence and local recurrence (25% of cases). There is no reported survival benefit in excising the draining lymph nodes. Recurrence of hypercalcaemia without local tumour recurrence is reported in 35–50% of cases due to the paraneoplastic effects from metastatic tumour deposits. It is therefore important to assess blood calcium levels regularly as well as to check for local regrowth in these patients. Post-surgical survival ranges from 2 to 39 months, with the average survival time being around 8 months.

### Anal furunculosis and/or perianal fistulae

This is an extremely frustrating disease encountered commonly in German Shepherd Dogs and Border Collies, and is characterized by chronic infection and ulceration of the tissues around the anus (Figure 22.14). There are often deeply infiltrating sinus tracts which can form true fistulae with the rectum. The underlying cause of this disease remains elusive. There is some evidence that there is an association with inflammatory bowel disease in both humans and dogs.



**22.14** Anal furunculosis.

The range of clinical signs seen with anal furunculosis vary immensely, from those patients which show few signs apart from licking the perianal region, to advanced cases where damage and scarring of the anal sphincter and rectum prevents normal dilatation of

the anus. These dogs can show severe faecal tenesmus, dyschezia and pain. Conversely, some dogs with severe anal furunculosis lose the ability to close the anal sphincter and become faecally incontinent.

Successful long-term management is still elusive but recent use of immunosuppressive agents holds out the best hope. A number of agents have been tried including prednisolone, azathioprine and ciclosporin. Of these drugs ciclosporin is the most effective, but a major disadvantage of this drug is cost; concurrent administration of ketoconazole helps to reduce the overall dose required. Ketoconazole and ciclosporin compete for the cytochrome P-450 enzyme system and this helps to maintain higher circulating levels of ciclosporin. Though ciclosporin is very effective, usually a 6–8 week course is required to reduce and eliminate the lesions; recurrence once the drug has been stopped is still a problem. A long-term low dose maintenance level of ciclosporin has yet to be established. In cases where cost is an issue then immunosuppressive doses of prednisolone can be tried, initially at 2 mg/kg orally for two weeks then reducing the dose over 4–6 weeks, although historically success has been rare.

Where there is recurrence post-immunosuppression or where the lesions are reduced but not resolved with drug therapy, then surgical excision should be considered (see *BSAVA Manual of Canine and Feline Wound Management and Reconstruction*).

### Anal strictures

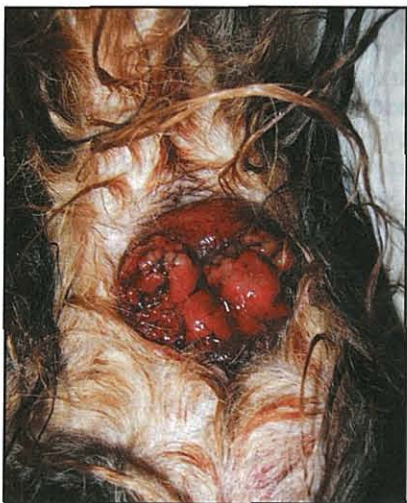Strictures occur secondary to trauma, anal furunculosis, neoplasia or surgery. The clinical signs are faecal tenesmus, dyschezia and haematochezia with flattened stools. Confirmatory diagnosis is by digital rectal examination but many patients require anaesthesia for this to be carried out due to the painful nature of the condition.

Treatment can involve bougienage to dilate the stricture, though this may need to be carried out at regular intervals. In severe cases surgical excision can be attempted, though strictures may recur at the surgical site. In extreme cases, anal resection and a rectal pull-through procedure can be considered. Though a radical procedure this can greatly improve the patient's quality of life and the degree of faecal incontinence is usually mild.

### Anal prolapse

Anal prolapse presents with oedematous, red anal mucosa protruding through the anal orifice at the end of defecation (Figure 22.15). The cause is usually associated with faecal tenesmus and it is essential to determine and treat the underlying cause of the tenesmus as well as managing the prolapse.

In most cases the prolapse can be reduced digitally, following lubrication. For recurrent cases a temporary purse string suture can be placed in the anus for 48 hours; some authors suggest that the purse string is tied loosely to allow faecal passage but prevent mucosal prolapse. In severe cases it may be necessary to carry out mucosal resection if the tissue is devitalized.



22.15

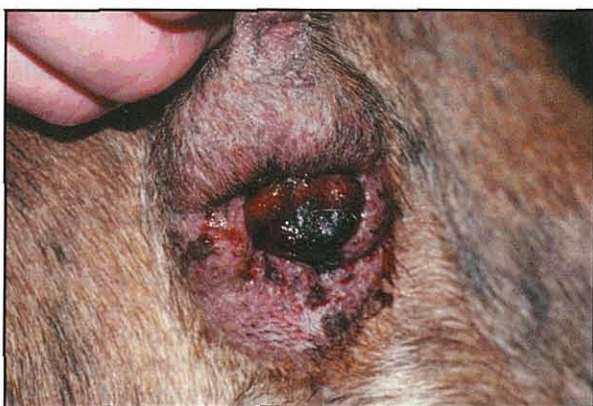Anal prolapse secondary to a rectal mass. (Courtesy of James Simpson)

### Trauma

Perianal and perineal trauma may be the result of projectile injuries, bite wounds or severe road traffic accidents. The management of such wounds may be problematic as either faecal incontinence or stricture formation may result (see *BSAVA Manual of Canine and Feline Wound Management and Reconstruction*).

### Circumanal gland adenomas

The circumanal gland, hepatoid gland or perianal adenoma is the commonest anal tumour of the dog, with some 85% being reported in the older intact male; it is rarely reported in cats. Circumanal gland adenocarcinomas are very rare. Anatomically the adenomas are found in the external region of the outer cutaneous zone, they may be single or multiple on presentation. They may be seen and palpated as discrete swellings often bluish in colour, but can also be large and ulcerated (Figure 22.16). Many owners do not realize there is a problem until there is either fresh blood seen on the stools or there is frank haemorrhage from the ulcerated tumour.



22.16

Circumanal gland tumour (perianal adenoma). (Courtesy of James Simpson)

As these tumours are known to respond to androgenic stimulation, castration of the entire male is the treatment of choice. After castration the tumour, even if ulcerated, will regress. If the tumour is large then surgical excision, in addition to castration, should be carried out.

### Perineal hernias

Perineal hernias or ruptures are mostly seen in the entire male dog, though they are reported in bitches and in the cat. The aetiology remains unclear but is associated with the degenerative changes in the muscles of the pelvic diaphragm. Many factors (Figure 22.17) have been implicated in the aetiopathogenesis but they are difficult to substantiate.

#### Prostatomegaly

Reduced numbers of androgen receptors in the levator ani and coccygeus muscles

Rectal sacculation (most likely to be secondary to herniation)

Colitis and docking

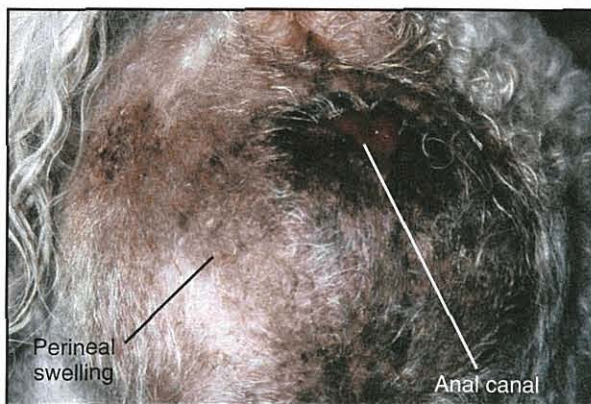
22.17

Factors implicated in aetiopathogenesis of perineal hernias.

The hernia occurs between the levator ani and coccygeus muscles and the external anal sphincter muscle. With the loss of lateral support there is progressive rectal enlargement. Unilaterally this is termed sacculation whilst the bilateral disease is termed dilatation. True rectal diverticula with rectal mucosa protruding through the rectal musculature are extremely rare. Hernias may be complicated by inclusion of pelvic and peritoneal fat, loops of small intestine and, in severe cases, by retroflexion of the bladder with or without the prostate gland.

The commonest clinical sign is perineal swelling either bilaterally (Figure 22.18) or unilaterally, reportedly more common on the right. Defecatory tenesmus is seen in 75–80% of cases. Dysuria and stranguria are seen with bladder herniation (seen in up to 20% of cases) indicating urethral obstruction. Diagnosis can be confirmed by rectal examination where sacculation and lack of lateral rectal wall support is noted (see Figure 22.5). Radiography or ultrasonography are of use to confirm a retroflexed bladder.

To avoid future risk of bladder involvement, all perineal hernias should be managed surgically by reconstruction of the pelvic diaphragm. In those cases with bladder retroflexion, renal and electrolyte status should be assessed and corrected by fluid therapy, if required, before undertaking surgery. If urinary catheterization is



22.18

Perineal swelling associated with a bilateral perineal hernia.

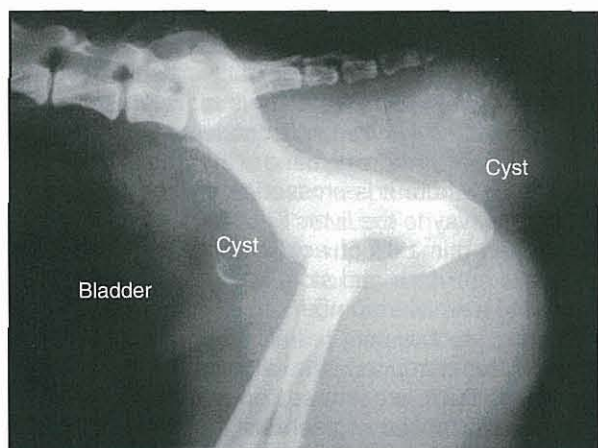
not possible, relief can be gained by perineal cystocentesis. Where there is preoperative bladder retroflexion, replacement into the abdomen and herniorrhaphy is usually adequate and should preclude the need for cystopexy or vas deferensopexy. Castration is carried out routinely in the management of perineal hernia as there is evidence of reduced incidence of recurrence. Potential complications seen following repair include wound dehiscence, rectal eversion and prolapse, sciatic paralysis (very rare) and recurrence.

### Perineal swelling (intrapelvic masses, paraprostatic cysts)

Perineal swellings are present as discrete unilateral bulges in a patient with a history of tenesmus and passing ribbon-like faeces. On examination the perineal swelling is firm and non-reducible and is palpable per rectum. It is important to rule out the possibility of a retroflexed bladder associated with a perineal hernia at an early stage (see above).

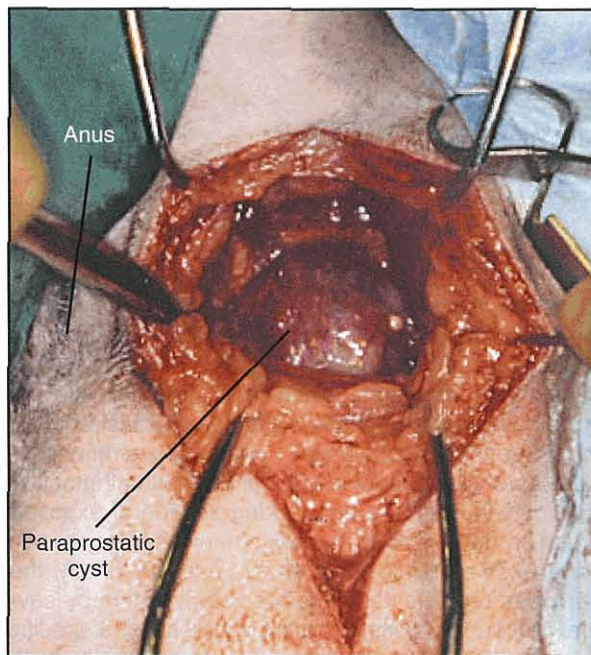
Ultrasonography is invaluable in determining whether the mass is soft tissue or fluid-filled. The latter may occur either with a bladder or if a paraprostatic cyst has herniated through the pelvic diaphragm. A fluid-filled cyst can also be detected on ultrasound examination adjacent to the prostate in the caudal abdomen or pelvic inlet.

Intrapelvic masses may or may not extend into the abdominal cavity and caudal abdominal and pelvic radiographs are valuable in determining the extent of a lesion (Figure 22.19). Intrapelvic masses tend to be of connective tissue origin and range from benign leiomyomas to fibrosarcomas; in view of this a minimum database for an intrapelvic mass should include incisional biopsy, abdominal radiography and ultrasonography to assess draining lymph nodes and thoracic radiography.



22.19 Radiograph of a mineralized prostatic cyst extending into the perineum.

Paraprostatic cysts are managed by surgical exploration (Figure 22.20), drainage and repair of the pelvic diaphragm; castration should also be carried out and in some cases it is necessary to omentalize the intra-abdominal portion of the cyst.



22.20 Intraoperative view of a perineal paraprostatic cyst.

Benign intrapelvic masses may be excised from either a perineal approach, or a combined caudal abdominal and pelvic osteotomy approach. If a sarcoma is diagnosed radical surgery, such as hemipelvectomy, can be considered in order to achieve surgical margins.

### References and further reading

- Aronson L (2003) Rectum and anus. In: *Textbook of Small Animal Surgery*, 3<sup>rd</sup> edn, ed. D Slatter, pp. 665–682. WB Saunders, Philadelphia
- Bellenger CR and Canfield RB (2003) Perineal hernia. In: *Textbook of Small Animal Surgery*, 3<sup>rd</sup> edn, ed. D Slatter, pp. 487–498. WB Saunders, Philadelphia
- De Novo RC and Bright RM (2000) Rectoanal disease. In: *Textbook of Veterinary Internal Medicine*, 5<sup>th</sup> edn, ed. SJ Ettinger and EC Feldman, pp. 1257–1271. WB Saunders, Philadelphia
- Fowler D and Williams JM (1999) *BSAVA Manual of Canine and Feline Wound Management and Reconstruction*. BSAVA Publications, Cheltenham
- Mathews KA, Ayres SA, Tano CA, Riley SM, Sukihani HR and Adams C (1997) Cyclosporin treatment of perianal fistulas in dogs. *Canadian Veterinary Journal* **38**, 39–41
- Van Duijkeren (1995) Disease conditions of canine anal sacs. *Journal of Small Animal Practice* **36**, 12–16
- Williams JM and Niles J (in preparation) *BSAVA Manual of Canine and Feline Abdominal Surgery*, BSAVA Publications, Gloucester

# Diseases of the exocrine pancreas

David A. Williams

## Introduction

Secretion of digestive enzymes is the major function of the exocrine pancreas. Pancreatic juice also contains bicarbonate, which contributes to the neutralization of gastric acid; co-lipase, which facilitates the action of pancreatic lipase; and intrinsic factor which is required for absorption of cobalamin. Pancreatic secretions inhibit bacterial proliferation in the proximal small intestine (SI), contribute to the normal degradation of exposed brush border enzymes, and together with biliary secretions, exert a trophic effect on the mucosa. Finally, the pancreas protects itself against autodigestion by several mechanisms, including the synthesis of a specific trypsin inhibitor that is stored and secreted together with the digestive enzymes (Figure 23.1).

Enzymes secreted as inactive zymogens	
Trypsinogen	→ Trypsin
Chymotrypsinogen	→ Chymotrypsin
Proelastase	→ Elastase
Procarboxypeptidase	→ Carboxypeptidase
Prophospholipase A <sub>2</sub>	→ Phospholipase A <sub>2</sub>
Coenzyme	
Proco-lipase	→ Co-lipase
Enzymes	
α-Amylase	
Classical pancreatic lipase	
Inhibitor	
Pancreatic secretory trypsin inhibitor	

**23.1** Major secretory proteins of the exocrine pancreas. (Reproduced from Williams (1995) with permission from Elsevier)

## Anatomy

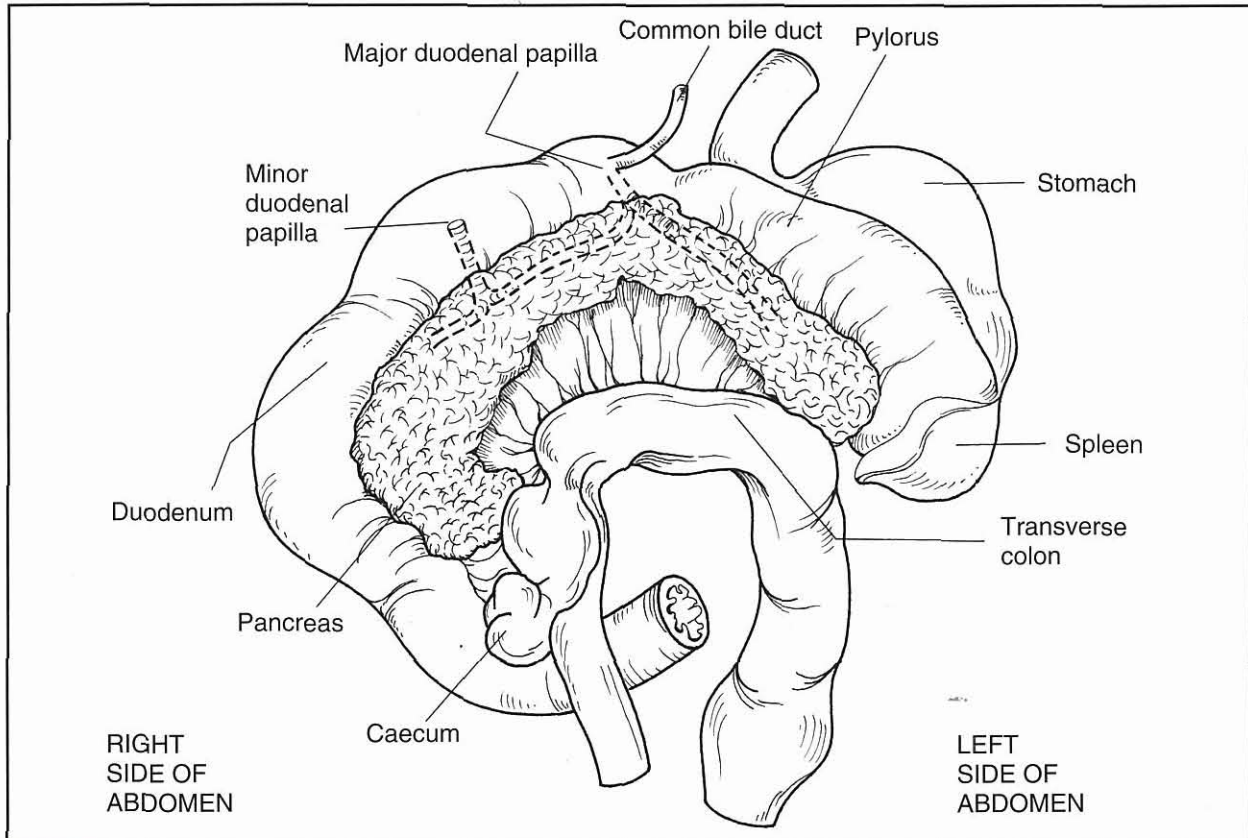
The pancreas of dogs and cats consists primarily of right and left lobes with a small central body where the lobes join together (Figure 23.2). It develops from ventral and dorsal bud-like primordia that arise from the embryonic SI, to which it remains connected by secretory ducts. Since the dorsal or ventral primordium or their associated ducts may involute during development, there is marked species, and to a lesser extent

individual, variation in the origin of the gland and the pattern of its duct system. While the areas of pancreas derived from the two primordia resemble one another histologically, the tissue derived from the ventral pancreatic bud, which contributes primarily to the right lobe, contains most of the pancreatic polypeptide-producing cells. In contrast, glucagon-secreting cells predominate in the tissue that develops from the dorsal bud, which contributes primarily to the left lobe.

In the dog, both primordia usually persist and fuse, and the two original ducts are retained. The duct of the ventral primordium is the pancreatic duct (Wirsung's duct) and opens adjacent to the bile duct on the major duodenal papilla. The duct of the dorsal primordium is the accessory pancreatic duct (Santorini's duct) and opens on the minor duodenal papilla a few centimetres distal to the major duodenal papilla. These two duct systems usually intercommunicate within the gland. In some dogs only the accessory pancreatic duct (the larger of the two) is present and all pancreatic juice enters the duodenum through the minor duodenal papilla. In the majority of cats only the duct of the ventral primordium (the pancreatic duct) persists, and it fuses with the bile duct before opening on the major duodenal papilla. However, in approximately 20% of cats the accessory pancreatic duct is also present.

Anatomically the pancreas is closely associated with the stomach, liver and duodenum (see Figure 23.2). The body lies in the bend of the cranial part of the duodenum where it is crossed dorsally by the portal vein on its way to the liver. Each pancreatic lobule is composed primarily of acinar cells that synthesize digestive enzymes and store them in zymogen granules, and a smaller number of cells that make up the branching duct system (intralobular, interlobular and main pancreatic ducts). The cells comprising the initial part of the ducts are termed centroacinar cells where they line the tubular segments of the gland into which acinar cells secrete. They are the major source of pancreatic bicarbonate and fluid secretion. Finally, the pancreas contains endocrine tissue, the islets of Langerhans, accounting for one to two percent of the gland.

The pancreas is well supplied with blood by branches of the coeliac and cranial mesenteric arteries. Venous drainage is by vessels that ultimately enter the portal vein leading to the liver. In dogs and cats an islet-acinar portal system communicates between the endocrine islet tissue and the exocrine acinar tissue. Pancreatic intralobular arteries give



**23.2** Anatomical associations of the canine pancreas. There is major variation between individual dogs in the anatomy and degree of anastomosis of the two sub-divisions of the duct system. (Reproduced from Strombeck *et al.* (1996) with permission from Elsevier)

branches that divide to form capillary glomeruli within the islets. Numerous efferent vessels (insuloacinar portal vessels) emerge from the glomeruli and enter the surrounding exocrine tissue capillary beds, from which vessels emerge and coalesce into venules. It is believed that essentially all of the blood leaving the islets goes into acinar capillaries before leaving the pancreas, and that therefore the acinar cells, particularly those surrounding the islets, are exposed to high concentrations of islet hormones, which may exert a regulatory role on the exocrine pancreas.

While the pancreas is not supplied by well defined extrinsic nerves it is richly supplied with myelinated and unmyelinated nerve fibres, and nerve trunks. Intrapancreatic ganglia are scattered frequently throughout the tissue. These neurons are either derived from the vagus and splanchnic nerves and reach the organ by following branches of the coeliac and cranial mesenteric arteries, or are intrinsic to the gland. In addition to the traditional cholinergic and adrenergic transmitters, serotonin, dopamine, and a variety of other regulatory peptides play a role in the regulation of pancreatic function.

## Physiology and biochemistry

### Digestive enzymes

The acinar cells secrete a fluid rich in enzymes that degrade proteins, lipids and polysaccharides. This

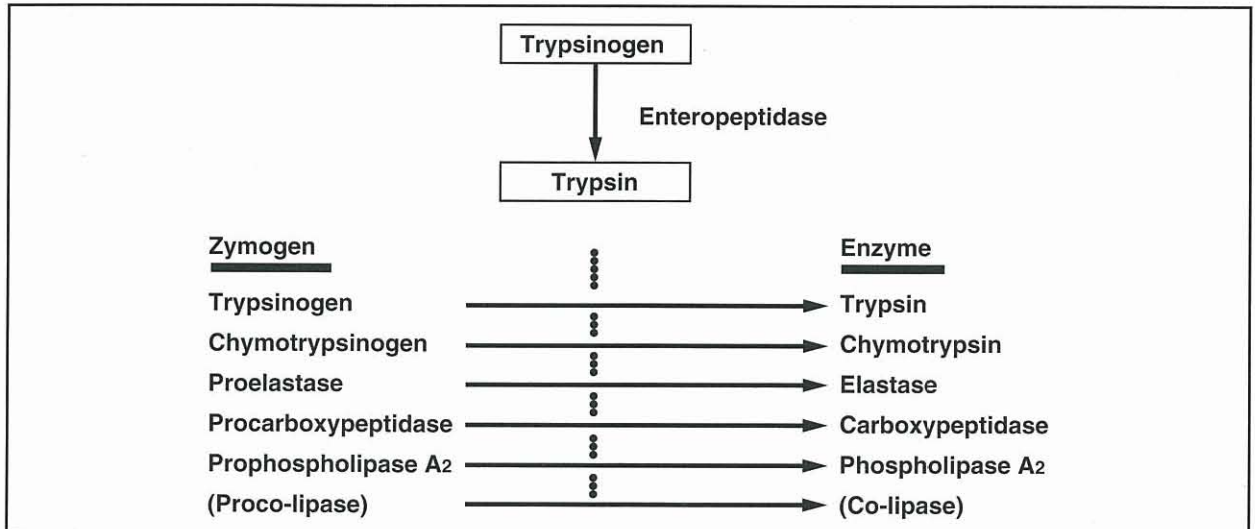
fluid is diluted and carried along the duct system by the profuse, watery, bicarbonate-rich secretion of the centroacinar and duct cells. This secretion contributes to the neutralization of gastric acid emptied into the duodenum.

### Defences against autodigestion

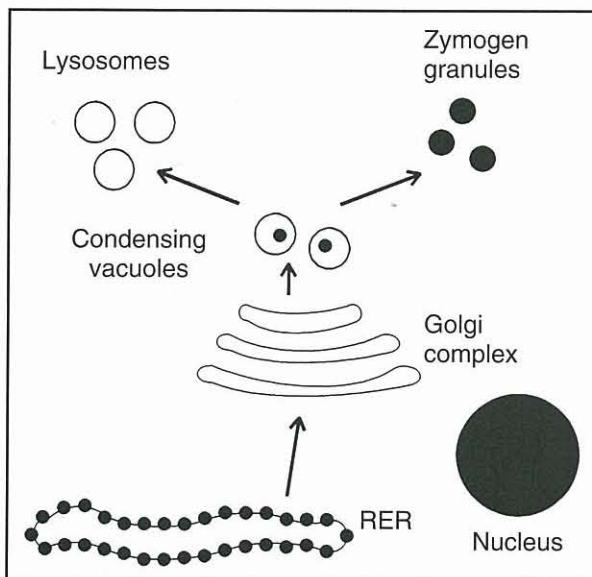
Autodigestion of the pancreas by the enzymes it produces is prevented by several mechanisms. Proteolytic and phospholipolytic enzymes are synthesized, stored and secreted in the form of catalytically inactive zymogens. These zymogens are activated by enzymatic cleavage of a small peptide, the activation peptide, from the amino-terminal of the polypeptide chain (see Figure 23.1). Enzymes from several sources, including some lysosomal proteases, are capable of activating pancreatic zymogens, but ordinarily activation of zymogens does not occur until they are secreted into the SI.

The enzyme enteropeptidase, which is synthesized and expressed in the brush border by duodenal enterocytes, is particularly effective at cleaving the activation peptide from trypsinogen and plays a crucial role in the activation of digestive enzymes. Active trypsin subsequently cleaves the activation peptide from other digestive zymogens (Figure 23.3). During synthesis, processing, storage and secretion digestive enzymes are strictly segregated from other, potentially damaging, cellular enzymes, such as lysosomal enzymes (Figure 23.4).





23.3 Activation of pancreatic proteases and phospholipase. (Reproduced from Williams (1995) with permission from Elsevier)



23.4 Normal intracellular routing of digestive and lysosomal enzymes by the pancreatic acinar cell. (Reproduced from Williams (1995) with permission from Elsevier)

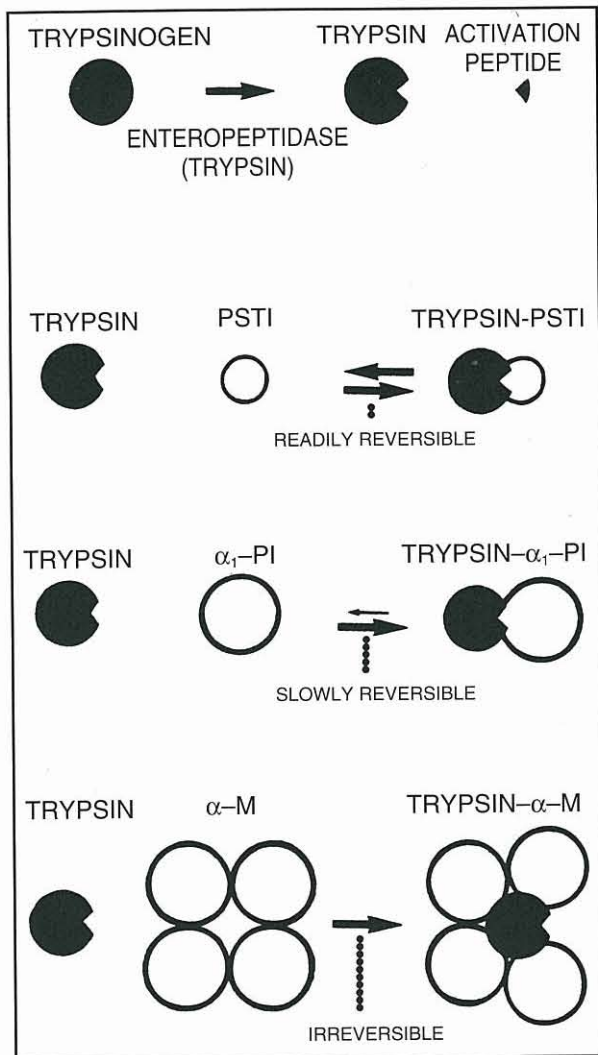
Should spontaneous intrapancreatic activation of trypsinogen occur, there are at least two mechanisms that help limit activation of other zymogens. Firstly, trypsin is quite effective at hydrolysing itself, so activation of small amounts of trypsinogen tends not to be catastrophic. Secondly, should significant activation occur, acinar cells contain a specific trypsin inhibitor, pancreatic secretory trypsin inhibitor (PSTI) that is synthesized, segregated, stored and secreted along with the digestive enzymes (Figure 23.5). PSTI inhibits trypsin activity should there be significant activation of trypsinogen within the acinar cell or duct system (Figure 23.6).

### Regulation of pancreatic secretion

The exocrine pancreas secretes juice into the duodenum both in the absence of food (basal or interdigestive secretion) and in response to a meal. Pancreatic secretion related to feeding occurs as a response to cephalic stimulation (anticipation and smell of food) as well as gastric and intestinal stimulation due to the presence of food in the stomach and SI. The response to these stimuli is mediated by nervous and hormonal mechanisms; in dogs and cats the endocrine mechanisms are

Inhibitor	Pancreatic secretory trypsin inhibitor (PSTI)	$\alpha_1$ -Proteinase inhibitor ( $\alpha_1$ -Antitrypsin, $\alpha_1$ -PI)	$\alpha$ -Macroglobulins ( $\alpha$ -M <sub>1</sub> and $\alpha$ -M <sub>2</sub> )
Principal locations	Pancreas; pancreatic juice	Plasma; intercellular space	Plasma
Approximate molecular weight (daltons)	6000	55 000	750 000
Specificity	Trypsin only	Broad spectrum (serine proteases)	Broad spectrum (serine and other proteases)
Inhibition	Temporary (slowly degraded by trypsin)	Transient (transfers enzyme to $\alpha$ -macroglobulins)	Irreversible (permanent trap for captured enzyme)
Function	Inhibits intrapancreatic autoactivation of trypsin	Readily diffusible inhibitor present in the intercellular space	Traps proteases prior to removal by monocyte-macrophage system

23.5 Major protease inhibitors in the pancreas and plasma. (Reproduced from Williams (1995) with permission from Elsevier)



**23.6** Diagrammatic representations of zymogen activation (trypsinogen) and the binding of proteases (trypsin) by major inhibitors. (Reproduced from Williams (1995) with permission from Elsevier)

probably of particular importance. Secretin and cholecystokinin are released into the blood from the proximal SI when acid and partly digested food are emptied from the stomach into the duodenum. These stimulate the secretion of bicarbonate-rich and enzyme-rich components of pancreatic juice, respectively. Traces of pancreatic enzymes leak into the blood of normal healthy animals and the low concentrations present may also increase transiently in the few hours after feeding. Assays for these enzymes in blood are clinically useful in the diagnosis of pancreatic disease.

**Diseases of the exocrine pancreas**

**Pancreatitis**

Inflammatory disease of the human pancreas is usually divided into acute and chronic types based on a combination of clinical and pathological criteria, this classification may be loosely applied to cats and dogs (Figure 23.7).

- Acute pancreatitis refers to inflammation of the pancreas with a sudden onset and little or no permanent pathological change after recovery.
- Chronic pancreatitis is a continuing inflammatory disease characterized by irreversible morphological change (fibrosis and atrophy) and it possibly leads to permanent impairment of function.

Both acute and chronic pancreatitis may be further subdivided based on the aetiology, if known, and the severity.

Complications of both types of pancreatitis may include:

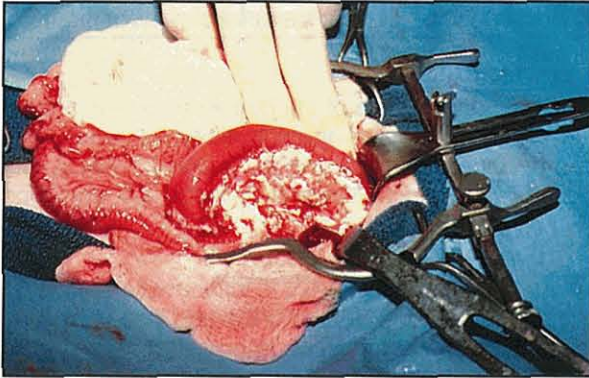
- Fluid accumulations around the inflamed pancreas
- Pseudocyst (a collection of sterile pancreatic juice enclosed by fibrous or granulation tissue)
- Localized necrosis
- Pancreatic abscess (a circumscribed collection of pus, usually in proximity to the pancreas, containing little or no pancreatic necrosis).
- Infected necrosis (from which bacteria can be cultured – very rare).

Classification based on aetiology is desirable, but this is rarely possible.

When examined at exploratory laparotomy or necropsy, the affected pancreas is often oedematous, swollen and soft, and there may be fibrinous adhesions to adjacent organs. Acute fluid collections (often blood-stained and containing fat droplets, but lacking a wall of granulation or fibrous tissue) may be seen in or near the pancreas or throughout the peritoneal cavity, particularly in cats. Severely affected areas of pancreas may be liquefied and pseudocysts may have formed. Haemorrhages may be present in the omentum and in the pancreas, and there are often chalky areas of fat necrosis both adjacent to the pancreas and also in fat as far away as the cranial mediastinum (Figure 23.8). Histologically there is extensive multifocal infiltration by neutrophils and varying degrees of haemorrhage, necrosis, oedema and vessel thrombosis.

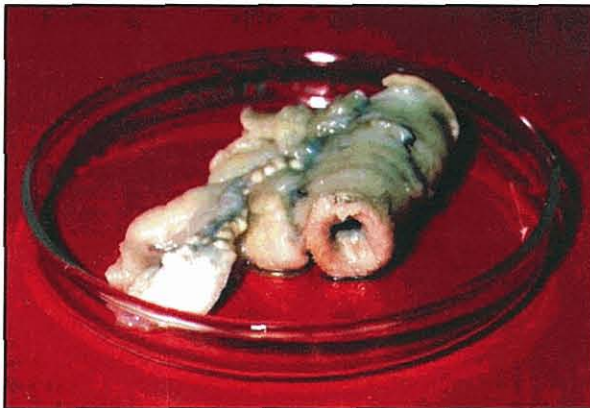Severity	Acute pancreatitis	Chronic pancreatitis
Mild	No multisystem failure; uncomplicated recovery	Minimal morphological change; subclinical loss of exocrine function
Severe	Multisystem failure; complications e.g. pseudocyst, abscess	Severe morphological damage; clinical exocrine pancreatic insufficiency or diabetes mellitus

**23.7** Classification of pancreatitis. (Reproduced from Williams (1995) with permission from Elsevier)



**23.8** Acute pancreatitis in a cat. The pancreas is swollen and oedematous and areas of haemorrhage and chalky fat necrosis are visible in the pancreatic parenchyma and adjacent mesentery. (Courtesy of Steve Holloway)

If an initial acute episode is not fatal, there may be complete resolution or alternatively the inflammatory process may smoulder continuously but asymptotically. Extensive destruction of pancreatic tissue may reduce the gland to a few distorted lobules adjacent to where the ducts enter the duodenum (Figure 23.9) before clinical signs are again evident.



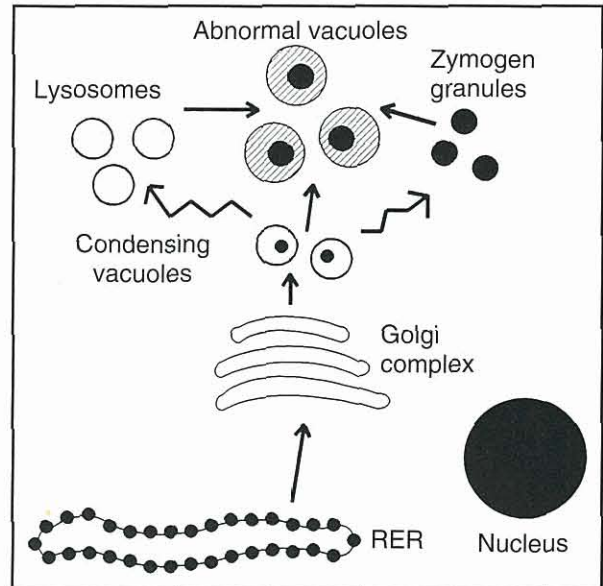
**23.9** Chronic pancreatitis observed at necropsy of an old dog with a history of several bouts of severe acute pancreatitis. Acinar cells were restricted to a few residual nodular areas of relatively normal looking tissue. The pancreatic pathology was not associated with any clinical signs at the time of euthanasia, although the serum concentration of trypsin-like immunoreactivity was subnormal.

Recent reports have described acute necrotizing pancreatitis in cats similar to that seen in dogs, as well as a histologically distinct suppurative form. However, chronic mild interstitial pancreatitis characterized by inflammation of interstitial tissue, apparently associated with the ducts, is the type of pancreatic inflammation most commonly reported in cats. This latter type of pancreatitis is often accompanied by cholangiohepatitis, inflammatory bowel disease or nephritis, any of which may be of greater clinical significance than the pancreatitis.

#### Pathophysiology

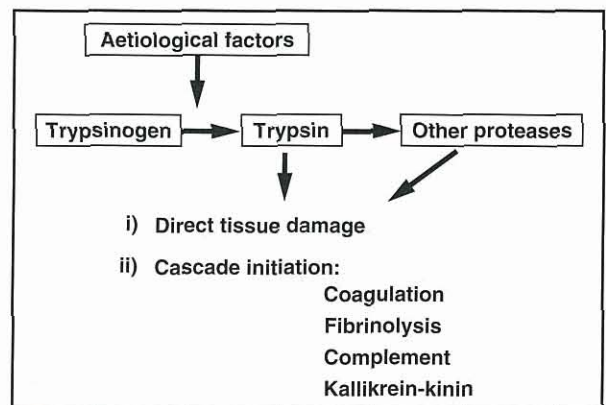
It is generally believed that pancreatitis develops when there is activation of digestive enzymes within the gland with resultant pancreatic autodigestion. In many

experimental models of pancreatitis, abnormal fusion of lysosomes and zymogen granules occurs due to failure of normal secretory processes (Figure 23.10). Lysosomal proteases then activate trypsinogen since PSTI is ineffective at the acid pH present in lysosomes. Subsequent increased capillary permeability, due to endothelial cell membrane damage, leads to pancreatic oedema. Similar changes in duct cell permeability may also trigger other pathophysiological mechanisms and thereby exacerbate pancreatitis.



**23.10** Abnormal intracellular routing of digestive enzymes destined for secretion results in mixing of zymogens and lysosomal proteases in abnormal intracellular vacuoles. Subsequent activation of zymogens by lysosomal proteases is currently considered to initiate development of pancreatitis. (Reproduced from Williams (1995) with permission from Elsevier)

Once intracellular and intraductal activation of trypsinogens to trypsins takes place, further activation of progressively larger amounts of proteases and phospholipase occurs. This is associated with transformation of mild oedematous pancreatic inflammation to haemorrhagic or necrotic pancreatitis with multisystem involvement and consumption of plasma protease inhibitors (Figures 23.11 and 23.12). Once enzyme acti-



**23.11** Local and systemic effects of trypsin in pancreatitis. (Reproduced from Williams (1995) with permission from Elsevier)

Enzyme	Pathophysiological action
Trypsin	Activation of other proteases Coagulation and fibrinolysis (disseminated intravascular coagulation)
Phospholipase A <sub>2</sub>	Hydrolysis of cell membrane phospholipids Pulmonary surfactant degradation Demyelination (cell necrosis and liberation of toxic substances, such as myocardial depressant factor, leading to respiratory distress and neurological signs of pancreatic encephalopathy)
Elastase	Degradation of elastin in blood vessel walls (haemorrhage, oedema, respiratory distress)
Chymotrypsin	Activation of xanthine oxidase and subsequent generation of oxygen-derived free radicals
Kallikrein	Kinin generation from kininogens
Kinins	Vasodilatation, pancreatic oedema (hypotension, shock)
Complement	Cell membrane damage, aggregation of leucocytes (local inflammation)
Pancreatic lipase	Fat hydrolysis (local fat necrosis, hypocalcaemia)

**23.12**

The role of enzymes in the pathophysiology of pancreatitis. (Reproduced from Williams (1995) with permission from Elsevier)

vation is initiated, numerous inflammatory mediators and free radicals are also important in the progression of pancreatitis. These mediators are mostly released from neutrophils and macrophages and include tumour necrosis factor- $\alpha$  (TNF- $\alpha$ ), interleukin-1 (IL-1), IL-2, IL-6, IL-8, IL-10, interferon- $\alpha$  (INF- $\alpha$ ), INF- $\gamma$ , nitric oxide (NO) and platelet activating factor (PAF).

Plasma  $\alpha$ -macroglobulins and  $\alpha_1$ -proteinase inhibitor (see Figures 23.5 and 23.6) are vital in protecting against the otherwise fatal effects of proteolytic enzymes in the vascular space.  $\alpha$ -Macroglobulins are particularly important in this regard. Dogs tolerate experimental intravenous injections of trypsin or chymotrypsin without showing adverse effects provided that free  $\alpha$ -macroglobulins are available to bind the active proteases. Once  $\alpha$ -macroglobulins are utilized, even though there is free  $\alpha_1$ -proteinase inhibitor, dogs die rapidly from acute disseminated intravascular coagulation and shock as the free proteases activate the kinin, coagulation, fibrinolytic and complement cascade systems (see Figure 23.11).

Binding of proteases by  $\alpha$ -macroglobulins result in a change in conformation which allows the complex to be recognized and rapidly cleared from the plasma by the monocyte-macrophage system. This removal is important since  $\alpha$ -macroglobulin-bound proteases retain catalytic activity, particularly against low molecular weight substrates (see Figure 23.3) and normal functioning of the monocyte-macrophage system is an important factor determining survival in experimental pancreatitis.

**Aetiology**

The inciting cause of pancreatitis in the dog is usually unknown but the following potential causes and risk factors should be considered:

- Nutrition, hypertriglyceridaemia and hereditary factors
- Drugs, toxins and hypercalcaemia
- Duct obstruction
- Duodenal and biliary reflux, pancreatic trauma and pancreatic ischaemia and reperfusion.

**Nutrition, hypertriglyceridaemia and hereditary factors:**

It has been suggested that pancreatitis is more prevalent in obese animals and it has been shown that the disease is less severe when induced in lean dogs. Low protein, high fat diets may induce pancreatitis; pancreatitis is more severe when induced in dogs fed a high fat diet and less severe when induced in lean dogs fed the same diet. Malnutrition has also been reported to cause pancreatic inflammation and atrophy in human patients and pancreatitis has been observed after re-feeding following a prolonged fast. Feeding the amino acid analogue ethionine induces pancreatitis in several species, including dogs and cats.

Hypertriglyceridaemia, often grossly apparent, is common in dogs with acute pancreatitis and may develop as a result of abdominal fat necrosis, or may be a cause of the disease in some cases. Some familial hypertriglyceridaemias in humans are associated with frequent episodes of pancreatitis that respond to control of serum triglyceride concentrations. It is widely believed that the high prevalence of pancreatitis observed in Miniature Schnauzers may be related to idiopathic hypertriglyceridaemia. There is also anecdotal evidence that pancreatitis in dogs often develops following a fatty meal.

Hereditary pancreatitis is well documented in human beings. Several contributory mutations of the cationic trypsinogen gene, as well as some other genes (PSTI) have been identified. Similar mutations may be present in dogs and cats, but have not yet been identified.

**Drugs, toxins and hypercalcaemia:** More than 50 drugs and drug classes have been implicated as a cause of pancreatitis in human beings, although absolute proof of a causal relationship is often lacking. Suspect drugs that are also commonly used in veterinary medicine include L-asparaginase, azathioprine, oestrogen, furosemide, potassium bromide, salicylates, sulphonamides, tetracyclines, thiazide diuretics and vinca alkaloids. Corticosteroids have recently been removed from the list of drugs that may induce pancreatitis in human beings. There is also little credible evidence that glucocorticoid administration causes

pancreatitis in dogs, with the possible exception of the use of high doses in association with spinal trauma. Nonetheless, it is probably wise to discontinue the use of any drug in patients with pancreatitis of undetermined cause unless a specific indication for continued use exists and no alternatives are available.

Administration of cholinesterase inhibitor insecticides and cholinergic agonists has been associated with the development of pancreatitis, probably by causing hyperstimulation. Scorpion stings in human beings can cause pancreatitis and experimental administration of scorpion venom to dogs also elicits pancreatitis. Zinc toxicosis has also been reported to cause pancreatitis in the dog. Also, both spontaneous and iatrogenic hypercalcaemia may cause pancreatitis in dogs.

**Duct obstruction:** Experimental obstruction of the pancreatic ducts produces atrophy and fibrosis, although inflammation and oedema may also develop when pancreatic secretion is stimulated. Clinical conditions that may lead to partial or complete obstruction of the pancreatic ducts include biliary calculi, sphincter spasm, oedema of the duct or duodenal wall, neoplastic conditions, parasites, trauma and surgical interference. Biliary calculi are a major cause of pancreatitis in humans but this has not been reported in dogs, presumably because of the low prevalence of biliary stones in this species and because dogs have an accessory pancreatic duct that does not communicate with the common bile duct and serves as the main pancreatic duct. Congenital anomalies of the pancreatic duct system may predispose to pancreatitis in humans and similar mechanisms may occur in the dog and cat but have not been documented.

**Duodenal and biliary reflux, pancreatic trauma and pancreatic ischaemia and reperfusion:** Reflux of duodenal juice into the pancreatic ducts secondary to surgical creation of a closed duodenal loop causes severe acute pancreatitis. Under normal circumstances such reflux is unlikely to occur since the duct opening is surrounded by a specialized compact smooth mucosa over the duodenal papilla and is equipped with an independent sphincter muscle. However, this anti-reflux mechanism may sometimes fail owing to an abnormally high duodenal pressure, such as may occur during vomiting or after blunt trauma to the abdominal cavity.

Surgical manipulation as well as blunt abdominal trauma are potential causes of pancreatitis but reports of pancreatitis following such insults are rare. Pancreatitis following pancreatic biopsy is extremely rare and is also uncommon following resection of pancreatic neoplasms.

Experimental and clinical reports have indicated that ischaemia is important in the pathogenesis of acute pancreatitis, either as a primary cause or as an exacerbating influence. Pancreatic ischaemia may develop during shock or severe acute anaemia, or during temporary occlusion of venous outflow, either during surgical manipulation in the cranial abdomen or secondary to hypotension during general anaesthesia. This latter mechanism may explain some instances of postoperative pancreatitis when organs remote from the pancreas have undergone surgery.

**Miscellaneous:** Viral, mycoplasmal and parasitic infections may be associated with pancreatitis, although this is usually recognized as part of a more generalized disease process. Recently, pancreatitis has been recognized as a potential complication of babesiosis, perhaps as a consequence of anaemia and ischaemia. It is unknown whether bacterial infection plays a role in the development of pancreatitis in some cases but concomitant bacterial infection does increase the severity of experimental pancreatitis. Pancreatitis may occur in association with end-stage renal failure; although this is rare. It is likely that renal failure secondary to acute pancreatitis is encountered more frequently. Acute pancreatitis has been observed in patients with liver disease, perhaps reflecting vascular compromise secondary to coagulation abnormalities, accumulation of toxins (endotoxins, bile acids) secondary to impaired liver function, response to a common initial cause, or reaction to drugs given in an attempt to manage the hepatic failure. Finally, autoimmune mechanisms that respond to glucocorticoid therapy have been incriminated in a small subset of human patients with pancreatic inflammation, and similar mechanisms may play a role in some veterinary patients, particularly in cats.

### Diagnosis

**History and clinical signs:** Dogs with acute pancreatitis are usually presented because of depression, anorexia and vomiting. Severe acute disease may be associated with shock and collapse, while other cases may have a history of less dramatic signs extending over several weeks. Signs of pain may be elicited by abdominal palpation. A cranial abdominal mass is palpable in some cases and occasionally there is mild ascites. Most affected animals are mildly to moderately dehydrated and febrile. Uncommon systemic complications of pancreatitis that may be apparent on physical examination include jaundice, respiratory distress, bleeding disorders and cardiac arrhythmias. While patients of any age may develop pancreatitis, affected animals are usually middle-aged or older, and sometimes obese, and the onset of signs may have followed ingestion of a large amount of fatty food. The clinical signs of mild acute pancreatitis and chronic pancreatitis in dogs are poorly documented but are probably extremely variable and non-specific. The disease may not be clinically apparent at all. As a consequence mild disease probably remains undiagnosed in most cases.

The history of cats with pancreatitis is extremely variable. Most cats with severe disease present with a history of lethargy and anorexia. Key clinical signs of acute pancreatitis in dogs and human beings, vomiting and abdominal pain, have been reported in only 35% and 25%, respectively, of cats with severe pancreatitis. Hypothermia, dyspnoea, diarrhoea and ataxia have also been reported. Mild chronic pancreatitis may be subclinical or may cause anorexia and weight loss.

**Diagnostic imaging:** Definitive radiographic evidence of pancreatitis is rarely seen, the most common finding being a somewhat subjective loss of visceral detail ('ground glass appearance') in the cranial abdomen

(see Chapter 3). Classical abnormalities reported with pancreatitis include:

- Increased density and diminished contrast and granularity in the right cranial abdomen
- Displacement of the stomach to the left
- Widening of the angle between the pyloric antrum and the proximal duodenum
- Displacement of the descending duodenum to the right
- Presence of a mass medial to the descending duodenum
- Static gas pattern in, or thickened walls of, the descending duodenum
- Static gas pattern in, or caudal displacement of, the transverse colon
- Gastric distention suggestive of gastric outlet obstruction
- Delayed passage of barium through the stomach and duodenum with corrugation of the duodenal wall indicating abnormal peristalsis.

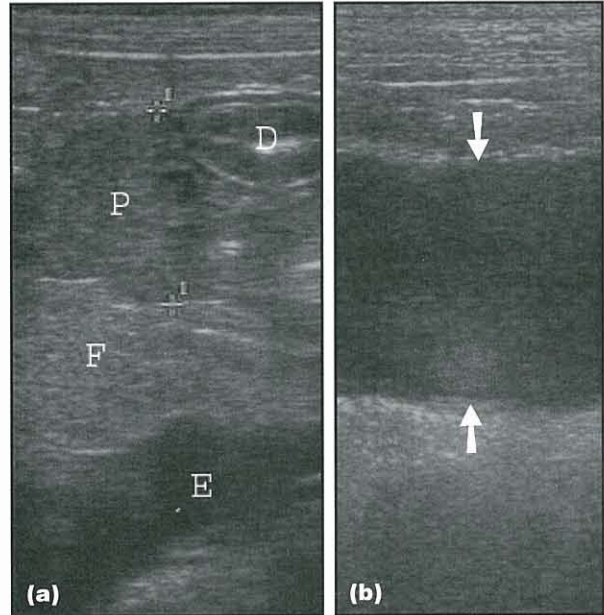
Unfortunately these findings are subjective and definitive radiographic evidence of pancreatitis is usually not present. However, abdominal radiography may provide evidence to rule in or rule out alternative diagnoses.

Abdominal ultrasonography is highly specific for pancreatitis when stringent criteria are applied, with a sensitivity of up to approximately 70% in dogs and 30% in cats. Enlargement of the pancreas and/or localized peritoneal effusion are not sufficient for a diagnosis. Changes in echogenicity are quite useful (Figure 23.13). Decreased echogenicity indicates pancreatic necrosis, which is often associated with hyperechogenicity in the peripancreatic region. Hyperechogenicity of the pancreatic parenchyma itself indicates pancreatic fibrosis and can be seen in cases of chronic pancreatitis. Pancreatic duct dilatation has been reported in cats. Serial examinations are particularly useful for identification and management of pancreatic complications, such as pancreatic pseudocyst or abscess associated with cystic masses.

**Routine laboratory tests:** Leucocytosis is a common haematological finding in acute pancreatitis. The packed cell volume may be increased as a result of dehydration, although in many cases particularly in cats anaemia is observed following rehydration.

Azotaemia is frequently present and usually reflects dehydration. Sometimes there may be acute renal failure secondary to hypovolaemia or to other mechanisms, such as circulating vasotoxic agents and plugging of the renal microvasculature by either fat deposits or microthrombi from the sites of disseminated intravascular coagulation.

Liver enzyme activities are often increased, reflecting hepatocellular injury as a result of either hepatic ischaemia or exposure of the liver to high concentrations of toxic products delivered from the pancreas in portal blood. In some cases, particularly in cats, there is hyperbilirubinaemia and sometimes clinically apparent jaundice, which may indicate severe hepatocellular damage and/or intra-hepatic and extra-hepatic obstruction to bile flow.

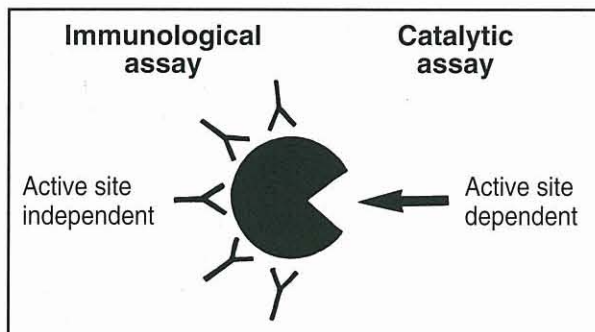


**23.13** Ultrasound scans of the cranial abdomen in two dogs. (a) This dog had severe pancreatitis. The duodenum can be seen in the upper right hand corner (D). The pancreas can be seen as an irregular mixed-echoic structure (P). The dark areas within the pancreas represent areas of pancreatic necrosis. The hyperechoic area right below the mixed-echoic structure represents peripancreatic fat necrosis (F). The hyperechoic area below the peripancreatic fat suggests peritoneal effusion (E). The changes seen here are highly specific for acute pancreatitis. (b) This dog had a pancreatic abscess. There is a large uniformly hypoechoic structure (arrowed) suggesting a fluid-filled mass. Such a fluid-filled mass could represent a pancreatic pseudocyst or a pancreatic abscess and was diagnosed as a pancreatic abscess in this patient following cytological evaluation of aspirated fluid. (Images courtesy of Dr Sharon Shull)

Hyperglycaemia is common in dogs and cats with necrotizing pancreatitis, probably as a result of hyperglucagonaemia and stress-related increases in the concentrations of catecholamines and cortisol. Some patients develop diabetes mellitus and require insulin replacement therapy. In contrast, cats with suppurative pancreatitis often develop hypoglycaemia.

Hypercholesterolaemia and hypertriglyceridaemia are very common in dogs, and hyperlipaemia is often grossly apparent even though food has not been ingested for many hours. Extreme hyperlipaemia may prevent accurate determination of other serum biochemical values. Analysis of plasma lipids has not revealed any clear-cut pattern characteristic of acute pancreatitis. Hypocalcaemia has often been reported but is usually mild to moderate and associated with hypoalbuminaemia. Low ionized calcium in cats has been reported to be a poor prognostic finding.

Serum concentrations of pancreatic digestive enzymes (amylase, lipase, phospholipase A<sub>2</sub>, trypsin-like immunoreactivity (TLI) and pancreatic lipase immunoreactivity (PLI)) are often increased in animals with pancreatitis. Conventional catalytic assays and newer, highly specific, immunoassays exist (Figure 23.14) and it is important that a method appropriate for each species be utilized. Immunoassays are generally only



**23.14** Assay of pancreatic enzymes and zymogens in serum. Catalytic assays detect degradation of specific substrates exposed to the active site of the molecule and therefore measure activity. Immunoassays detect antigenic sites over the surface of the molecule and therefore measure enzyme or zymogen concentration. (Reproduced from Williams (1995) with permission from Elsevier)

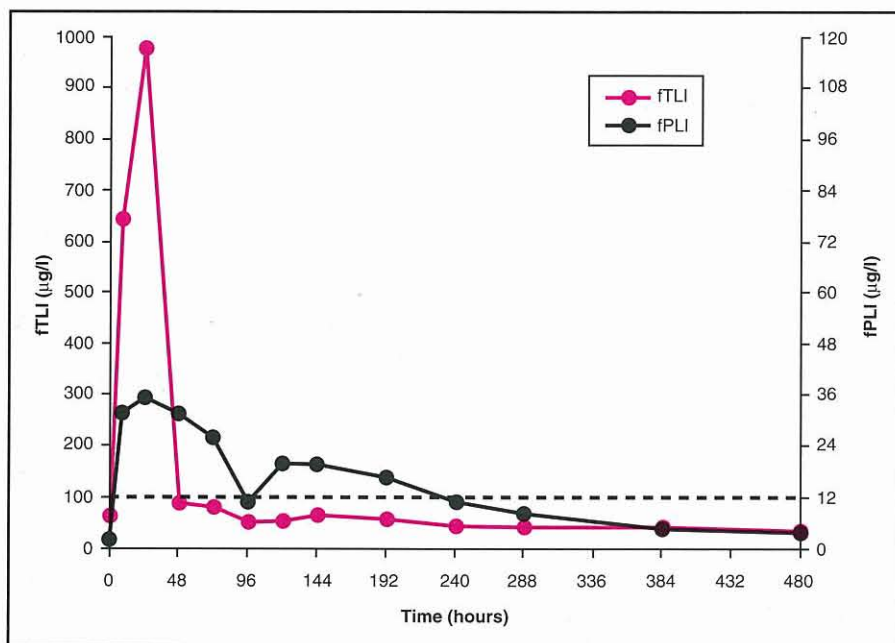
applicable to the species for which they were developed. At the time of writing, feline TLI (fTLI), feline PLI (fPLI) and canine PLI (cPLI) assays are only performed at the author's laboratory.

**Pancreas-specific laboratory tests:** Circulating concentrations of all pancreatic enzymes, except PLI, increase secondary to reduced clearance from plasma in renal failure. As azotaemia is common in acute pancreatitis it may therefore be difficult to determine whether increased levels of pancreatic enzymes are due to pancreatic inflammation or renal disease. Increases more than three times the upper limit of normal are unlikely to result from renal dysfunction alone, although there are exceptions. Increases more than five times the upper limit of normal are likely to reflect pancreatitis since other diseases rarely show such profound elevations. Unfortunately, many patients with both pancreatitis and non-pancreatic disease exhibit mild to moderate increases of the most classical and widely available tests. Unlike TLI and PLI, which are

pancreas-specific, amylase, lipase and phospholipase A<sub>2</sub> activities originate from both pancreatic and extrapancreatic sources including gastric and small intestinal mucosa, and serum activities of these extrapancreatic enzymes may increase in dogs and cats with hepatic, intestinal, gastric or neoplastic disease.

Amylase and lipase activities as traditionally assayed are now recognized to be of no value whatsoever in the diagnosis of feline pancreatitis and increases of these markers usually reflect non-pancreatic disease. Lipase activity is a more reliable marker for pancreatitis in dogs than amylase. However, glucocorticoid administration increases canine serum lipase activity up to five-fold without histological evidence of pancreatitis. Conversely, persistently normal activities are seen in some cases of documented pancreatitis. By the time some clinical cases are investigated, depletion of stored enzymes combined with disruption of synthesis of new enzymes may have resulted in lowered serum levels.

Serum fTLI concentration is specific for exocrine pancreatic function in the absence of azotaemia, but depending on the study the sensitivity of the fTLI test for feline pancreatitis ranges between 30 and 60%. In a group of cats with experimentally induced pancreatitis, both serum fTLI and fPLI concentrations increased initially, but the serum fPLI concentration stayed elevated much longer than did serum fTLI concentration (Figure 23.15). Another study of cats with spontaneous pancreatitis showed serum fPLI concentration to be both more sensitive and more specific for diagnosing pancreatitis than serum fTLI concentration or abdominal ultrasonography. Similar observations have been made in dogs and increasing evidence indicates that serum cPLI and fPLI provide tests that are both sensitive and specific for diagnosing pancreatitis in dogs and cats. Serum cTLI and fTLI are somewhat less sensitive but relatively specific in the absence of azotaemia. Marked increases in serum lipase activities are relatively specific and sensitive in dogs, but not cats, and mild to moderate increases in both species are poorly specific for pancreatitis.



**23.15** Mean serum fTLI and fPLI concentrations over time in six cats with experimentally induced pancreatitis. The pink line shows the mean serum fTLI concentration and the black line shows the mean serum fPLI concentrations over time. The broken line displays the currently recommended cut-off values for diagnosis of pancreatitis of 100 µg/l for fTLI and 12 µg/l for fPLI concentration. The elevation of mean serum fPLI concentration is of far greater duration than that of mean serum fTLI concentration. These data indicate that serum fPLI concentration is more sensitive than serum fTLI concentration for the diagnosis of feline pancreatitis. (Data from Williams *et al.*, 2003)

Trypsin complexed with plasma  $\alpha_1$ -proteinase inhibitor and trypsinogen activation peptides (TAPs; see Figure 23.6) are not normally present in plasma and, in human patients, the concentration of these markers correlates well with the severity and clinical course of the disease. Recent studies have shown that these tests have relatively poor sensitivity for diagnosis of pancreatitis, and technical complexities presently limit the usefulness of these assays in veterinary medicine.

Increased availability of canine and feline TLI and, particularly, PLI assays should facilitate more accurate diagnosis of pancreatitis. In their absence and without direct examination of pancreatic tissue, the diagnosis can only be tentative. Nonetheless, evaluation of the entire clinical picture, particularly if supported by pancreatic abnormalities on ultrasound examination, will in many instances give a high degree of confidence in the presumptive diagnosis. If gross or histopathological confirmation of the diagnosis is required, or the possibility of other abdominal disease needs to be eliminated, it is important that attention be given to stabilization of fluid and electrolyte status prior to general anaesthesia and surgical exploration of the abdomen.

#### Acute treatment

The treatment of acute pancreatitis involves correction and maintenance of fluid and electrolyte balances while the underlying cause, if known, is rectified. The patient is then supported whilst allowing the pancreas to recover from the inflammatory episode. Recent reports have challenged the traditional logic and wisdom of withholding food to 'rest' the pancreas, however, and both parenteral and enteral nutrition have been well tolerated by patients with pancreatitis. There is also evidence that enteral nutrition may be superior to parenteral nutrition. Oral intake should probably only be restricted in those patients with incessant vomiting and then for as short a period as possible.

Mild cases of pancreatitis are probably self-limiting and may spontaneously improve after 1 or 2 days of basic supportive therapy. Other patients require aggressive fluid therapy over several days to treat severe dehydration and ongoing fluid electrolyte loss due to vomiting and diarrhoea. Most animals become hypokalaemic during such therapy and serum potassium should be monitored and supplemented parenterally if required. Serum creatinine or urea levels should also be measured to monitor renal function. While metabolic acidosis is probably common in acute pancreatitis, this may not always be the case and vomiting patients may be alkalotic. Care should be taken that bicarbonate administration to rectify acidosis does not precipitate signs of hypocalcaemia in individuals with borderline low calcium levels.

**Antibiotic therapy:** In contrast to human beings, cats and dogs with pancreatitis rarely have infectious complications and antibiotic therapy would appear to be of minimal benefit. However, for cases where there is good evidence for pancreatic infection it should be noted that trimethoprim-sulphonamide and enrofloxacin penetrate well into the exocrine pancreas in dogs.

**Analgesic therapy:** Analgesic therapy (e.g. subcutaneous pethidine hydrochloride, transdermal fentanyl), morphine by constant rate intravenous infusion or, for dogs, intraperitoneal lidocaine or bupivacaine) should be given to provide relief of pain, even if signs of pain are not apparent.

**Transfusion:** The transfusion of plasma or whole blood to replace  $\alpha$ -macroglobulins may be life-saving in patients with severe disease and has the additional benefit of maintaining plasma albumin concentrations. Albumin is probably beneficial in pancreatitis because of its oncotic properties that not only help maintain blood volume and prevent pancreatic ischaemia, but also limit pancreatic oedema formation. Low molecular weight dextrans have also been used to expand plasma volume but they may aggravate bleeding tendencies, contain no protease inhibitor and provide no major advantages over plasma administration. A hypertonic saline-dextran 70 combination was shown to be effective in maintaining cardiac function without massive fluid administration, thereby avoiding pulmonary hypertension and oedema that can accompany therapy with lactated Ringer's solution alone. Hyperoncotic ultra-high molecular weight dextran solutions have recently been shown to reduce trypsinogen activation, prevent acinar necrosis and lower mortality in rodent pancreatitis, perhaps by promoting pancreatic microcirculation.

**Corticosteroids:** These should be given only on a short-term basis to animals in shock associated with fulminating pancreatitis, and then in concert with fluids and plasma, as described above. Longer periods of administration may impair removal of  $\alpha$ -macroglobulin-bound proteases from the plasma by the monocyte-macrophage system, with resultant complications due to systemic effects of circulating uninhibited enzymes.

**Somatostatin and dopamine:** Somatostatin and its analogues may reduce complications and improve survival in human patients but there is not yet sufficient evidence to recommend their routine use. Infusion of dopamine at a dose that stimulates both dopaminergic and  $\beta$ -adrenergic receptors (i.e. 5  $\mu$ g/kg/min i.v.) is helpful in reducing severity and progression of some feline models of pancreatitis; it is thought that the beneficial effect of dopamine is related to reduction of microvascular permeability rather than to promotion of pancreatic blood flow.

**Secretion prevention:** Nasogastric suctioning of gastric secretions and use of antacids or cimetidine have been recommended in order to indirectly inhibit pancreatic secretion. However, none of these methods has been consistently shown to be effective and their value has largely been discounted. Attempts to rest the pancreas using direct inhibitors of secretion such as atropine, acetazolamide, glucagon and calcitonin have not proved to be effective. Secretin, the hormone that naturally stimulates pancreatic secretion, was beneficial in a rat model of pancreatitis when given at a high dose intravenously.



**Enzyme inhibitors:** Administration of a variety of naturally occurring and synthetic enzyme inhibitors with selective actions against individual pancreatic digestive enzymes, as well as free-radical scavengers such as selenium, have shown promise in experimental studies but their value remains to be conclusively demonstrated in clinical trials.

**Peritoneal dialysis:** The use of peritoneal dialysis to remove toxic material accumulated in the peritoneal cavity is beneficial experimentally and is thought by many to be useful in human patients. While impractical in some veterinary practices, peritoneal dialysis may be of value in some cases. Certainly, in those patients where acute pancreatitis is confirmed at exploratory laparotomy removal of as much free fluid as possible followed by abdominal lavage is advisable. Reports of surgical intervention to debride and drain affected areas are not favourable, although in one report of six dogs with fibrotic obstructive masses, cholecystoduodenostomy was followed by recovery. Many patients that develop obstructive jaundice in association with acute pancreatitis recover spontaneously over 2–3 weeks with conventional supportive care alone.

**Diet:** Small amounts of water should be offered after the patient has stopped vomiting. If there is no recurrence of clinical signs, food may be gradually reintroduced. The diet should have a high carbohydrate content (rice, pasta, potatoes) since protein and fat are more potent stimulants of pancreatic secretion and are therefore more likely to promote a relapse. If there is continued improvement, gradual introduction of a low fat content maintenance diet should be attempted. Another period of food deprivation should be instituted if signs of pancreatitis recur. While the prognosis is poor for those patients that repeatedly cannot tolerate food, total parenteral nutrition may be beneficial by sustaining such patients while the digestive system is rested for 7–10 days.

**Supportive care:** Hyperglycaemia is often mild and transient but in some cases diabetes mellitus may develop, requiring treatment with insulin. Respiratory distress, neurological problems, cardiovascular abnormalities, bleeding disorders and acute renal failure are all poor prognostic indicators. Attempts should be made to manage these complications by appropriate supportive measures (see Chapter 26).

#### **Treatment of complications**

Use of ultrasound imaging has contributed to increased recognition of pancreatic masses in patients with pancreatitis.

Pancreatic pseudocysts have been described in dogs and cats. Clinical signs are those associated with pancreatitis. On abdominal ultrasound a cystic structure in close proximity to the pancreas can be identified. Aspiration of the pseudocyst is relatively safe and should be attempted for diagnostic and therapeutic purposes. Fluid from pancreatic pseudocysts is of low cellularity and is not inflammatory in nature.

Pancreatic pseudocysts can be treated medically or surgically. Medical management of pancreatic pseudocysts involves ultrasound-guided percutaneous aspiration and close monitoring of the size of the pseudocyst. Surgical intervention should be considered in cases in which clinical signs persist or when the size of the pseudocyst does not decrease significantly over time. Surgical correction can involve extirpation of the pseudocyst, with external or internal drainage; internal drainage is the preferred method in human patients.

Pancreatic abscess is a less common possible complication of pancreatitis. Bacterial infection is only rarely present. Clinical signs are non-specific but may include vomiting, depression, abdominal pain, anorexia, fever, diarrhoea and dehydration. In some patients a mass in the cranial abdomen can be identified upon abdominal palpation. Associated clinicopathological findings are similar to those of pancreatitis. Surgical drainage and aggressive antimicrobial therapy are the treatments of choice in human patients. However, in one report only five of nine dogs survived the immediate postsurgical period. Thus, given the mixed results, risks, difficulties and expense associated with anaesthesia, surgery and postoperative care, surgical intervention may be best avoided unless there is clear evidence of an enlarging mass and/or sepsis in a patient that is not responding well to medical therapy. Antimicrobial therapy is of questionable value unless an organism is identified upon bacterial culture.

#### **Long-term therapy**

In many patients with a single episode of pancreatitis, the only long-term therapy recommended is to avoid feeding high fat meals. In other patients, repeated bouts of pancreatitis occur and it may be beneficial to feed a fat-restricted diet permanently. In some patients hypertriglyceridaemia may need to be controlled pharmacologically. Despite all efforts, some animals experience recurrent disease.

Some reports have indicated that oral pancreatic enzyme supplements decrease abdominal pain and discomfort that accompanies chronic pancreatitis in human beings. It is unknown whether they are of similar value in dogs and cats, but a trial period of enzyme therapy may be warranted in individuals with chronic signs of abdominal pain or anorexia.

#### **Prognosis**

Pancreatitis is unpredictable and varies widely in severity; thus, it is difficult to give a prognosis even when a diagnosis is definitively established. Life-threatening signs accompanying acute fulminating pancreatitis are usually followed by death in spite of supportive measures but some dogs recover fully following an isolated severe episode. In other cases, relatively mild pancreatitis persists despite all therapy and either the patient dies from an acute, severe exacerbation of the disease, or is euthanized because of failure to recover or long-term cost. Most patients with uncomplicated pancreatitis probably recover spontaneously after a single episode and do well as long as high fat content foods are avoided.

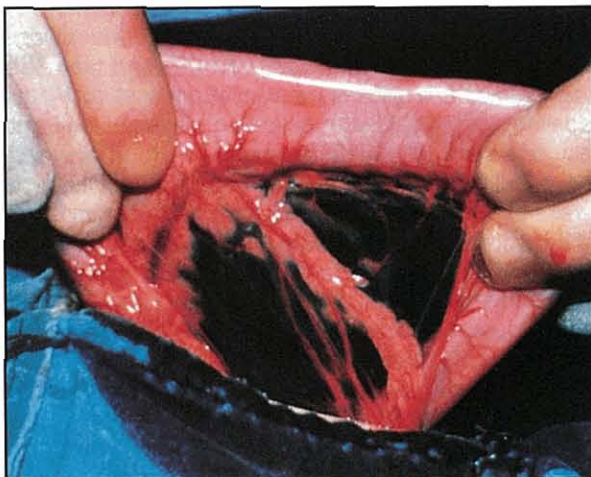
### Exocrine pancreatic insufficiency

Progressive loss of pancreatic acinar cells ultimately leads to malabsorption due to inadequate production of digestive enzymes. The functional reserve of the pancreas is considerable, however, and signs of exocrine pancreatic insufficiency (EPI) do not occur until most of the gland has been destroyed. Although pancreatic enzymes perform essential digestive functions, alternative pathways of digestion for some nutrients do exist. Following experimental exclusion of pancreatic secretion from the intestine, dogs can still absorb up to 63% of ingested protein and 84% of ingested fat. This residual enzyme activity probably originates from lingual and/or gastric lipases and gastric pepsins, from intestinal mucosal esterases and peptidases, and, in young animals, from bile salt-activated lipase in milk. Nonetheless, when exocrine pancreatic function is severely impaired, these alternative routes of digestion are inadequate and clinical signs of malabsorption occur. Feline EPI is much less common than EPI in dogs, but development of a reliable test for fTLI has shown the disease to be far more prevalent than previously realized.

#### Aetiology

Spontaneous development of pancreatic acinar atrophy (PAA) in previously healthy adult animals appears to be unusually common in dogs, in which it is the most common cause of EPI (Figure 23.16). Similar conditions occur sporadically in other species, and the author is aware of cases of a histologically identical condition in cats. Recent studies have revealed that in German Shepherd Dogs and Rough Collie breeds PAA is preceded by subclinical, possibly autoimmune, lymphocytic pancreatitis that leads to acinar cell destruction. Since islet cells are spared these patients do not develop diabetes mellitus.

While chronic pancreatitis resulting in progressive destruction of pancreatic tissue is a common cause of EPI in adult human beings and cats, this is a rare



**23.16** The duodenal limb of the pancreas of a dog with pancreatic acinar atrophy. Residual tissue contains islet (endocrine) cells and blood vessels, so diabetes mellitus is not a feature of this disease. (Reproduced from Williams (1992) with permission from Waltham International Focus)

cause of EPI in dogs. Animals with EPI and coexistent diabetes mellitus probably have *chronic pancreatitis*, since pancreatic inflammation is likely to damage both endocrine and exocrine tissue, in contrast to the selective acinar cell damage in PAA.

Congenital deficiencies of individual pancreatic digestive enzymes or of intestinal enteropeptidase have not been described in dogs or cats. Occasionally, young dogs are seen that have signs of EPI and sometimes *diabetes mellitus* from a very early age, and congenital pancreatic hypoplasia or aplasia may be the underlying cause. Smouldering subclinical EPI is occasionally identified in dogs with immune-mediated *lymphocytic pancreatitis* that has not progressed to frank PAA.

Finally, EPI has been reported as a complication of proximal duodenal resection and cholecystoduodenostomy in cats. This reflects the absence of dual pancreatic ducts in this species, with blockage of pancreatic secretion occurring as a result of damage to the major duodenal papilla. Pancreatectomy will also lead to EPI.

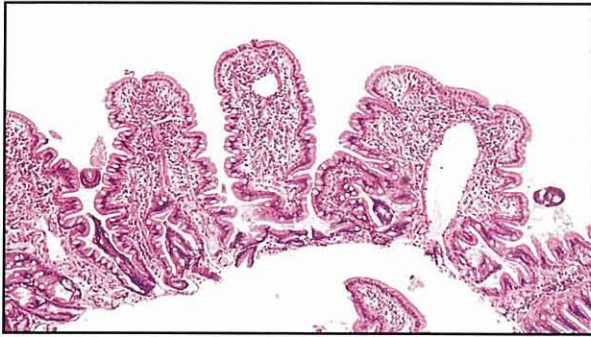#### Pathophysiology

Nutrient malabsorption in canine EPI does not arise simply as a consequence of failure of intraluminal digestion. Morphological changes in the SI of some dogs with EPI have been reported and studies of naturally occurring, and experimental, EPI in several species have revealed abnormal activities and impaired function of mucosal enzymes, indicated by abnormal transport of sugars, amino acids and fatty acids. Absence of the trophic influence of pancreatic secretions, true bacterial overgrowth in the SI and endocrine and nutritional factors may all contribute to this pathology.

**Small intestinal mucosa:** EPI in several species is associated with reduced degradation of exposed brush border proteins, such as maltase and sucrase, as a consequence of decreased pancreatic protease activity within the gut lumen. It has been suggested that accumulation of these brush border membrane proteins may interfere with normal absorption.

**Small intestinal microflora:** Bacterial overgrowth in the lumen of the SI is common in both untreated and treated dogs with EPI. Changes in the intestinal microflora may arise secondary to loss of the antibacterial properties of pancreatic juice or as a consequence of disturbed intestinal immunity or motility.

The pathological changes associated with bacterial overgrowth depend on the type of bacteria involved and the chronicity of the overgrowth. In those dogs with increases in aerobic and facultative anaerobic bacteria, activities of brush border enzymes are often increased as described above. In contrast, when the overgrowth includes obligate anaerobic bacteria there is often a decrease in many enzyme activities, and perhaps partial villous atrophy (Figure 23.17). In both circumstances bacteria may impair absorption by competing for nutrients and by changing intraluminal factors.



**23.17** Partial villous atrophy in a jejunal biopsy specimen from a dog with exocrine pancreatic insufficiency due to pancreatic acinar atrophy. Villi are short and stumpy with a broadened plateau at the extrusion zone, and there is evidence of folding or fusion of villi. (Reproduced from Williams *et al.* (1987) with permission from the *Journal of the American Veterinary Medical Association*)

**Pancreatic regulatory peptides and glucose intolerance:** Histopathological examination of the pancreas from dogs with PAA reveals almost total atrophy of acinar tissue but plentiful, albeit highly disorganized, islet tissue containing many insulin-, glucagon-, somatostatin- and pancreatic polypeptide-immunoreactive cells. These morphological changes may account for subnormal basal plasma insulin concentrations that have been reported in dogs with PAA. In patients with EPI secondary to pancreatitis there may be frank diabetes mellitus secondary to islet cell destruction.

**Nutritional status:** Many patients with EPI have been suffering from malabsorption for a considerable period of time before a diagnosis is made. Thus, the clinical and pathophysiological features associated with EPI may in some instances be due to malnutrition rather than EPI *per se*. Oral and intravenous glucose tolerances are abnormal in untreated dogs with PAA, although diabetes mellitus has not been reported in these dogs. Treatment of PAA is followed by normalization of intravenous glucose tolerance, although basal plasma insulin concentrations remain subnormal. It is probable that the abnormalities in glucose homeostasis are related, at least in part, to metabolic changes associated with the catabolic and undernourished state of many untreated dogs with EPI. Malnutrition in rats impairs the capacity to maintain protective mucosal mucin content, and accelerates the development of brush border enzyme deficiency in intraluminal bacterial overgrowth.

Mildly or severely subnormal serum cobalamin concentrations are commonly observed in dogs and cats with EPI. Deficiencies of pancreatic proteases, as well as pancreatic intrinsic factor, could contribute to cobalamin malabsorption, and overgrowth of cobalamin-binding bacteria in the proximal SI is a likely additional contributory factor. Serum cobalamin concentrations rarely normalize following treatment with oral pancreatic enzymes. Intestinal dysfunction due to persistent cobalamin deficiency may be a contributory factor in those patients with EPI and a suboptimal response to enzyme replacement therapy. Cobalamin

deficiency might also be responsible for the anorexia reported in some patients with EPI.

Serum tocopherol (vitamin E) concentrations are often severely subnormal in EPI and do not increase in response to treatment, perhaps because treatment does not return fat absorption to normal or because bacterial overgrowth persists. Tocopherol deficiency may cause insidious pathological changes in erythrocyte membranes, smooth muscle, the central nervous system, skeletal muscle and the retina.

Subnormal serum concentrations of vitamin A have also been observed in dogs with EPI but no associated signs of deficiency have been reported. Vitamin K-responsive coagulopathy occurs rarely in patients with EPI, but is more common in affected cats than dogs.

### Diagnosis

**History:** Dogs and cats with EPI usually have a history of weight loss but a normal or increased appetite. Polyphagia is often severe and owners may complain that dogs ravenously devour all food offered to them and scavenge from waste bins but some dogs have periods of inappetence. Coprophagia and pica are also common in dogs. Water intake may also increase in some dogs and in chronic pancreatitis there may be polyuria and polydipsia due to diabetes mellitus. Diarrhoea often accompanies EPI but can be very variable in character. Most owners report frequent passage of large volumes of semi-formed faeces, although some patients have intermittent or continuous explosive watery diarrhoea, while in other instances diarrhoea is infrequent and is not considered a problem. Diarrhoea generally improves or resolves in response to fasting. Feeding a low fat or low carbohydrate diet may also decrease or eliminate diarrhoea.

There may be a history of vomiting and commonly there is marked borborygmus and flatulence with sometimes apparent episodes of abdominal discomfort. PAA is prevalent in young German Shepherd Dogs and thus EPI is often initially suspected because of the age and breed of the affected dog. It must be emphasized, however, that even in young German Shepherd Dogs SI disease is more prevalent than EPI and that PAA may occur in a wide variety of breeds at any age. Similarly, most cats with polyphagia, weight loss and diarrhoea are ultimately diagnosed as having SI disease associated with severe cobalamin deficiency; these cases are clinically indistinguishable from those with EPI without appropriate diagnostic testing.

**Clinical signs:** Mild to marked weight loss is usually seen in association with EPI. Some dogs are very emaciated at presentation with severe muscle wasting and no palpable body fat and, in extreme cases, dogs may be physically weak as a result of loss of muscle mass. The haircoat is often in poor condition and some animals may give off a foul odour because of haircoat soiling with fatty faecal material and the passage of excessive flatus. Cats with EPI may exhibit a greasy, wet-looking and generally unkempt hair coat, especially in the perineal region, which may in part reflect severe cobalamin deficiency (Figure 23.18).



**23.18** Unkempt and wet appearance of the haircoat of a cat with exocrine pancreatic insufficiency. This may reflect simple greasy soiling (especially around the perineal region) and/or changes secondary to the severe cobalamin deficiency that is commonly seen in affected cats.

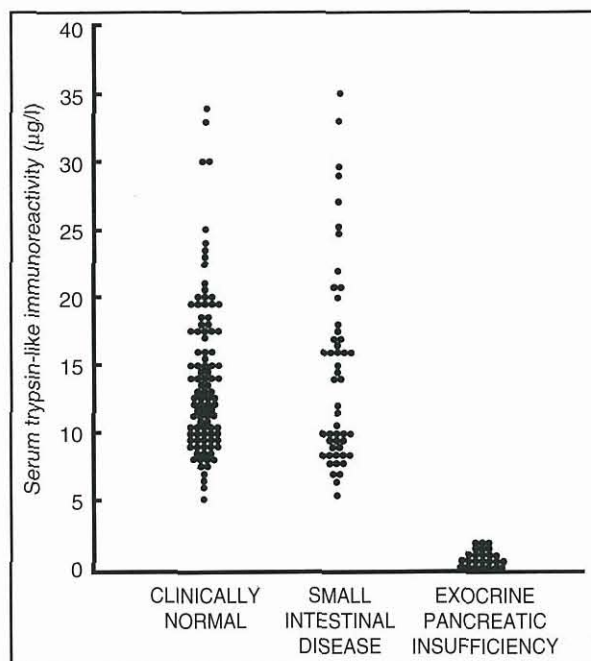
**Laboratory tests:** The history and clinical signs of EPI do not distinguish the condition from other causes of malabsorption (see Chapter 10) and while replacement therapy with oral pancreatic enzymes is generally successful, response to treatment is not a reliable diagnostic approach.

In PAA, extreme atrophy of the pancreas is readily observed on gross inspection at either exploratory laparotomy or laparoscopy. In chronic pancreatitis it may be impossible to gauge accurately the amount of residual exocrine pancreatic tissue because of severe adhesions and fibrosis. These procedures involve unnecessary anaesthetic and surgical risks and their use for diagnostic purposes cannot be recommended, given the availability of reliable non-invasive tests.

Routine laboratory test results are generally not helpful in establishing the diagnosis of EPI. Serum alanine aminotransferase (ALT) activities are mildly to moderately increased and may reflect hepatocyte damage secondary to increased uptake of hepatotoxic substances through an abnormally permeable SI mucosa. Other routine serum biochemical test results are unremarkable, except that total lipid, cholesterol and polyunsaturated fatty acid concentrations are often reduced. Serum protein concentrations are usually normal even when patients are severely malnourished. Lymphopenia and eosinophilia are not uncommon but other abnormalities should be considered as evidence for additional, or alternative, underlying disorders.

Canine serum amylase, isoamylases, lipase and phospholipase A<sub>2</sub> activities are only minimally reduced in EPI, indicating that non-pancreatic sources of these enzymes are clearly present in dogs. The most reliable and widely used test currently available is assay of serum TLI.

Trypsinogen is synthesized exclusively by the pancreas and measurement of the serum concentration of this zymogen by species-specific radioimmunoassay provides a good indirect index of exocrine pancreatic function in the dog. Serum TLI concentration is both highly sensitive and specific for the diagnosis of EPI, since concentrations are dramatically reduced compared with those in normal animals and those with small intestinal disease (Figure 23.19). Marked reductions in serum TLI (to <2 µg/l in dogs or 8 µg/l in cats) may even precede signs of weight loss or diarrhoea. Utilization of this test is simple in that analysis of a single serum sample obtained after food has been withheld for several hours is all that is required. Serum TLI is very stable and samples can therefore be mailed



**23.19** Serum trypsin-like immunoreactivity in 100 healthy dogs, 50 dogs with small intestinal disease and 25 dogs with exocrine pancreatic insufficiency. (Reproduced from Williams and Batt (1988) with permission from the *Journal of the American Veterinary Medical Association*)

to an appropriate laboratory for analysis. It is important to remember that there is no cross-reactivity between canine and feline TLI and that serum fTLI values in normal cats, as well as in cats with EPI, are greater than those in dogs. As noted above, at the time of writing fTLI assay is available only from the author's laboratory at Texas A&M University.

Other tests used for diagnosis of EPI include: assay of faecal proteolytic activity using azoprotein, gelatin or radial enzyme diffusion methods; specific assay of faecal pancreatic elastase in dogs; the bentiromide (BT-PABA) test; plasma turbidity after oral fat administration; and microscopic examination of faeces. Many of these tests give significant proportions of false-negative and false-positive results and their use even as crude 'screening' tests is not recommended. Furthermore, their availability is limited and even when properly performed they are inconvenient and expensive. When EPI is suspected in cats or dogs, serum TLI should be assayed.

### Treatment

**Enzyme replacement:** Most dogs and cats with EPI can be successfully managed by supplementing each meal with pancreatic enzymes present in commercially available dried pancreatic extracts. Numerous formulations of these extracts are available (tablets, capsules, powders, granules) and their enzyme contents and bioavailabilities vary. Addition of approximately two teaspoons of powdered pancreatic extract per 20 kg of bodyweight to each meal is generally an effective starting dose. Extract should be mixed with a maintenance food immediately prior to feeding. Two meals a day are usually sufficient to promote weight gain. Dogs

will generally gain 0.5–1.0 kg per week and diarrhoea and other clinical signs, such as polyphagia and coprophagia, often resolve within 4–5 days.

As soon as clinical improvement is apparent owners can determine a minimum effective dose of enzyme supplement that prevents return of clinical signs. This varies slightly between batches of extract and also from patient to patient, probably reflecting individual variation in extrapancreatic digestive reserve. Most affected dogs require at least one teaspoonful of enzyme supplement per meal but lower doses may be adequate in cats and small dogs. One meal per day is sufficient in some dogs while others continue to require two. If available, chopped raw ox or pig pancreas (100–150 g per 20 kg of bodyweight), obtained from animals certified as healthy following appropriate post-mortem inspection, is an inexpensive alternative to dried extract. Pancreas can be stored frozen at  $-20^{\circ}\text{C}$  for at least 3 months without significant loss of enzyme activity.

**Effectiveness of enzyme replacement:** While administration of pancreatic enzymes with food is generally successful, only a small proportion of the administered enzymes is delivered functionally intact to the SI and fat absorption does not return to normal. Pancreatic lipase is rapidly inactivated at the acid pH encountered in the stomach, while trypsin and some other pancreatic proteases, although relatively acid-resistant, are susceptible to degradation by gastric pepsins. Efforts to increase the effectiveness of enzyme supplementation by pre-incubation of enzymes with food prior to feeding, supplementation with bile salts, neutralization or inhibition of gastric acid secretion and use of enteric-coated preparations have generally not proved effective.

Most notably, pre-incubation of food with enzyme powder for 30 minutes prior to feeding does not improve the effectiveness of oral enzyme treatment in promoting fat absorption in dogs with ligated pancreatic ducts. Gastric acid secretion may be reduced by administration of histamine  $\text{H}_2$  receptor antagonists. Cimetidine administered 30 minutes prior to giving food mixed with pancreatic enzymes does improve fat absorption in dogs with ligated pancreatic ducts but does not decrease faecal wet or dry weight. Routine use of cimetidine is not recommended, however, given the expense of the drug and the fact that so many patients respond well when treated with enzymes alone. Oral antacids, such as sodium bicarbonate, aluminum or magnesium hydroxide, are inexpensive but do not increase the effectiveness of enzyme therapy.

Enteric-coated preparations have been formulated to protect enzymes from gastric acid but they are actually often less effective than powdered pancreatic extract. This may reflect selective retention of enteric-coated particles in the stomach whilst food is emptied or perhaps rapid intestinal transit preventing adequate enzyme release in the upper SI. Future enteric-coated preparations formulated specifically for cats and dogs may prove advantageous. Similarly, new preparations containing acid-resistant fungal or gastric lipases may prove to be effective and economical. Such new preparations are unlikely to help in management of patients with

sub-optimal weight gain since they rarely improve after either increasing the dose of enzymes over that recommended above or giving cimetidine, suggesting that factors other than enzyme delivery to the SI are involved.

**Dietary modification:** Fat absorption does not return to normal despite appropriate enzyme therapy. Patients appear to compensate by eating slightly more than usual and, as with any individual, it is necessary to regulate the amount of food given in order to maintain ideal bodyweight. Some types of dietary fibre impair pancreatic enzyme activity *in vitro* and diets containing large amounts of non-fermentable fibre probably should be avoided. However, low fat diets merely impair caloric uptake and should not be fed. In order to overcome residual digestive deficits, the feeding of a highly digestible, low non-fermentable fibre diet may be beneficial. A non-blinded clinical study found that owners considered that their dogs generally did better (reduced flatulence and borborygmi, decreased faecal volume and frequency of defaecation) when fed a commercial highly digestible diet compared with the previously fed home-cooked or regular maintenance diets, but there was no difference in appetite, drinking, colour or consistency of faeces, or in coprophagy. Results of experimental studies to evaluate highly digestible diets have shown consistent reductions in faecal weight, but have not shown consistent benefit with regard to fat digestibility. Highly digestible diets may be of value in promoting caloric uptake in those dogs with EPI that do not regain normal bodyweight. These patients may also benefit from being fed a diet containing (or supplemented with) readily hydrolysed and absorbed medium chain triglycerides.

**Vitamin supplementation:** Dogs and cats with EPI may have severely subnormal concentrations of serum cobalamin (vitamin B12) and tocopherol (vitamin E). Serum concentrations of cobalamin in particular usually decrease following otherwise effective treatment with pancreatic enzymes. Clinical signs associated with deficiencies of these vitamins in dogs and cats have not been well documented but intestinal mucosal changes, myopathy, myelopathy and other abnormalities of nervous tissue have been reported in other species. Anorexia in dogs and an unkempt wet-looking haircoat in cats (Figure 23.20) have been documented in growing animals with cobalamin deficiency, but it is



**23.20** Unkempt and wet appearance of the haircoat of a cat with experimentally-induced cobalamin deficiency. (Courtesy of Dr Jim Morris)

likely that additional non-specific signs occur in older animals, including a general failure to thrive. Cats are particularly susceptible to development of severe cobalamin deficiency.

In the author's experience, supplementation with large oral doses of tocopherol (5–25 IU/kg bodyweight given orally once daily with food for 1 month) is effective in returning serum concentrations to normal. In contrast, cobalamin must be given parenterally (100–250 µg i.m. or s.c. injection once a week for several weeks) to normalize serum concentrations. Long-term monitoring of serum cobalamin concentration, especially in cats, is recommended.

Malabsorption of vitamin A has also been demonstrated in association with EPI, as has vitamin K-responsive coagulopathy. Enzyme supplements do not correct or prevent these deficiencies. It should be noted that doses of individual vitamins in multivitamin preparations may be insufficient to normalize serum concentrations and that parenteral or very high oral doses may be required for adequate supplementation.

**Antibiotic therapy:** Dogs with EPI commonly have overgrowth of bacteria in the SI but in most cases this is a subclinical abnormality and affected individuals respond very well to treatment with oral enzyme replacement alone, even though the overgrowth often persists. Serum bile acid profiles also suggest altered intestinal microflora in cats with EPI. Altered intestinal microflora can cause malabsorption and diarrhoea, however, and in those individuals that do not respond to oral enzyme supplementation alone, antibiotic therapy may be of value. Oral oxytetracycline, metronidazole or tylosin may be effective in improving the clinical response in some of these patients. Chronic untreated bacterial overgrowth may cause mucosal damage that is only partially reversible following even prolonged antibiotic therapy, and this may explain why some animals fail to return to normal bodyweight. It is not clear whether a predisposition to recurrent colonization by an abnormal microflora persists following antibiotic therapy.

**Glucocorticoid therapy:** In those few patients that respond poorly to the above treatments, oral prednisolone at an initial dosage of 1–2 mg/kg q12h for 7–14 days is usually beneficial. This may be due to resolution of coexisting lymphocytic-plasmacytic gastroenteritis or other effects of glucocorticoids on the GI tract. Long-term glucocorticoid administration is generally unnecessary.

#### Prognosis

The underlying pathological process leading to EPI is generally irreversible and life-long treatment is required. It is particularly important to recognize that *feline patients often require therapy in addition to enzyme replacement*, most notably cobalamin supplementation. Given the expense of treatment it is reasonable in some cases to either repeat a serum TLI assay or withdraw enzyme supplement for a trial period every 6 months or so and observe the patient for recurrence of clinical signs. Pancreatic acinar tissue does have some capacity to regenerate and it is not inconceivable that following either pancreatitis

or subtotal PAA, residual acinar tissue might regenerate sufficiently to normalize digestive function. Possible recoveries from clinically significant enzyme deficiency have been reported. However, in most cases treatment will be required for life but, providing owners are willing to accept the cost of enzyme replacement, the prognosis is generally good. Some patients may fail to regain normal bodyweight but these animals usually have total resolution of diarrhoea and polyphagia and are quite acceptable as pets. A high prevalence of mesenteric torsion and gastric dilatation and volvulus have been reported in German Shepherd Dogs and Rough Collies with PAA in Finland but this has not been documented elsewhere.

Treatment of patients with diabetes mellitus and EPI due to chronic pancreatitis is likely to be troublesome and expensive. *Diabetes mellitus secondary to chronic pancreatitis* is potentially more difficult to regulate than simple diabetes in view of probable coexisting derangements in the secretion of glucagon and somatostatin. Moreover, anorexia and vomiting due to pancreatitis may further complicate treatment of diabetes mellitus.

#### Exocrine pancreatic neoplasia

Pancreatic adenomas are benign tumours, which are usually singular and can be differentiated from pancreatic nodular hyperplasia by the presence of a capsule. Pancreatic adenocarcinoma is the most common neoplastic condition of the exocrine pancreas in the dog and cat, but occurs infrequently. Adenocarcinomas usually originate from the duct system but can also originate from acinar tissue. A few cases of pancreatic sarcomas, i.e. spindle cell sarcoma and lymphosarcoma, have been reported. Whether these tumours are primary neoplastic lesions of the exocrine pancreas, metastatic lesions from tumours of other organs or a localized lesion of a multicentric neoplasia is open to question.

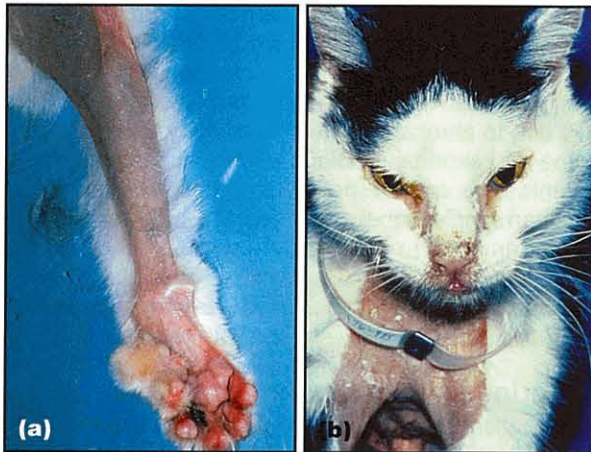#### Aetiology and pathophysiology

The aetiology of neoplastic conditions of the exocrine pancreas is unknown. Benign neoplastic lesions can lead to displacement of cranial abdominal organs. However, these changes are subclinical in most cases and the diagnosis is often made as an incidental finding at necropsy examination. In very few cases a benign growth can obstruct the pancreatic duct and cause secondary atrophy of the remaining exocrine pancreas, leading to EPI. Adenocarcinomas can also cause displacement of cranial abdominal organs and obstruction of the pancreatic duct. In addition, adenocarcinomas can be associated with tumour necrosis and resulting pancreatic inflammation when the tumour outgrows its vascular supply. Pancreatic adenocarcinomas can also spread to neighbouring or distant organs.

#### Diagnosis

**Clinical signs:** The presentation of patients with exocrine pancreatic neoplasia is non-specific and clinical signs observed are often those of chronic pancreatitis, including vomiting, anorexia, diarrhoea or chronic weight loss. Multifocal necrotizing steatitis has been described

in a few dogs that were ultimately diagnosed with pancreatic adenocarcinoma. Clinical signs related to metastatic lesions (e.g. lameness, bone pain, dyspnoea) have also been reported in some cases of pancreatic adenocarcinoma. Recently several cases of paraneoplastic alopecia have been reported in cats with pancreatic adenocarcinoma. The reported alopecia consisted of generalized alopecia of the ventrum, limbs and face in most cases, and diffuse zones of alopecia in the remaining cats (Figure 23.21).



**23.21** Paraneoplastic alopecia in a cat with pancreatic adenocarcinoma. (Image courtesy of Dr Robert Kennis)

**Diagnostic imaging:** Radiography findings are also non-specific in most cases. Abnormal findings include: decreased contrast in the cranial abdomen, suggesting peritoneal effusion into this area; transposition of the spleen caudally; and shadowing in the pyloric region. In some cases abdominal radiography can suggest the presence of a mass in the cranial abdomen. In most cases a soft tissue mass can be identified by abdominal ultrasonography in the region of the pancreas. However, in many if not most cases, pancreatic origin of the mass can not be conclusively established. Similarly, neoplastic lesions of neighbouring organs may be falsely presumed to be of pancreatic origin. Also, patients with severe pancreatitis may show, on ultrasound examination, a mass effect in the area of the pancreas that can be confused with a pancreatic adenocarcinoma. If peritoneal effusion is identified on abdominal ultrasonography, a sample should be aspirated and evaluated cytologically, although neoplastic cells are not routinely identified on cytology as they do not readily exfoliate. Fine needle aspiration or transcutaneous biopsy under ultrasound guidance can be attempted when suspicious masses are identified, and has been reported to be successful in approximately 25% of all cases. The low success rate of fine needle aspiration is probably due to the lack of exfoliation of pancreatic adenocarcinoma cells. In other cases carcinoma cells can be identified but the origin of the cells cannot be determined conclusively. Ultrasound-guided biopsy with histopathological evaluation of biopsy specimens has been reported infrequently but in one study ultrasound-guided biopsy of a pancreatic mass resulted in a diagnosis of pancreatic adenocarcinoma in both of two

cases. In two of three more cases biopsy of the liver revealed metastatic carcinoma. In many cases the diagnosis is made at exploratory laparotomy or even on necropsy examination.

**Laboratory tests:** Neutrophilia, anaemia, hypokalaemia, bilirubinaemia, azotaemia, hyperglycaemia and elevations of hepatic enzymes have all been reported in affected patients, but results of routine blood tests may be unremarkable. Elevations of hepatic enzymes and serum bilirubin concentration are identified most commonly. Hyperglycaemia, when present, is related to concurrent destruction of pancreatic beta cells. Some dogs with pancreatic adenocarcinoma have extremely high serum lipase activities that reach as much as 25 times the upper limit of the reference range. A single dog with a pancreatic adenocarcinoma and pseudohyperparathyroidism, leading to hypercalcaemia has been described in the literature.

### Treatment and prognosis

Pancreatic adenomas are benign and theoretically do not need to be treated, unless they cause clinical signs. However, since the final diagnosis of pancreatic adenocarcinoma is often made at exploratory laparotomy, a partial pancreatectomy should be performed even in cases of suspected pancreatic adenoma. The prognosis in these cases is excellent.

Pancreatic adenocarcinomas often present at a late stage of the disease; metastatic disease is usually present at the time of diagnosis. The most common sites of metastatic disease are the liver, abdominal and thoracic lymph nodes, mesentery, intestines and the lungs, but various other sites have also been reported. In those few cases when gross metastatic lesions are not identified at the time of diagnosis, surgical resection of the tumour may be attempted, but owners should be forewarned that clean surgical margins are only rarely achieved. Total pancreatectomy and pancreaticoduodenectomy, though theoretically possible, have not been described in dogs or cats with spontaneous disease. Extrapolation from human patients suggests high morbidity and mortality for these procedures. Chemotherapy and radiation therapies have shown little success in human or veterinary patients with pancreatic adenocarcinomas. Overall, the prognosis for dogs and cats with pancreatic adenocarcinoma is grave.

### Pancreatic parasites

*Eurytrema procyonis*, the pancreatic fluke of the cat, can be found in the pancreatic ductular system of foxes, raccoons and cats. Little is known about the life cycle of this parasite. *E. procyonis* can lead to thickening of the pancreatic duct system and fibrosis. Even though a significant decrease of exocrine pancreatic secretion has been shown to occur in affected animals, cats presenting with clinical signs of EPI secondary to infestation with this parasite are extremely rare. The diagnosis can be made by detection of characteristic dicrocoeliid eggs (average size 34 µm x 50 µm) with a single operculum in fresh faeces during routine faecal flotation. Fenbendazole at a dose of 30 mg/kg orally q24h for 6 consecutive days has been recommended for therapy.

The hepatic fluke of the cat, *Amphimerus pseudofelineus*, can also infest the pancreas and lead to pancreatitis. Infection with this parasite has been reported in cats from Illinois, Iowa, Louisiana, Maryland, Nebraska, Ohio, Texas and Virginia. The life cycle of this parasite is unknown but it is presumed that similarly to other Opisthorchiidae, molluscs serve as first, and freshwater fish as second, intermediate hosts. Diagnosis can be made on faecal examination with formalin-ethyl acetate sedimentation by identification of yellow-brown eggs of approximately 16 µm x 31 µm with a single operculum. Eggs are destroyed during routine faecal flotation and infestation will be missed in those cases. In one report, treatment with praziquantel at 40 mg/kg q24h for 3 consecutive days was successful in the management of *A. pseudofelineus* infestation. Concurrent symptomatic therapy for pancreatitis, as outlined above, also needs to be instituted in these cases. The dose of praziquantel recommended is high when compared with the standard dose given for treatment of enteric parasites, but the therapeutic range for praziquantel is wide and the dose suggested is similar to that for treatment of hepatic flukes in human beings.

### Pancreatic bladder

A pancreatic bladder is an abnormal extension of the pancreatic duct. Pancreatic bladders can be congenital or acquired and have been described in several cats presented with signs compatible with biliary duct obstruction. Surgical reconstruction may be of benefit in cases with clinical signs attributable to this abnormality.

### Nodular hyperplasia

Nodular pancreatic hyperplasia occurs quite frequently in older cats and dogs. Disseminated small nodules can be found throughout the exocrine portion of the pancreas. Pancreatic nodular hyperplasia can be

differentiated from pancreatic adenomas by the absence of a capsule. Nodular hyperplasia does not lead to functional changes, does not cause any clinical signs and is usually diagnosed incidentally during necropsy examination.

### References and further reading

- Gaskill CL and Cribb AE (2000) Pancreatitis associated with potassium bromide/phenobarbital combination therapy in epileptic dogs. *Canadian Veterinary Journal* **41**, 555–558
- Mohr AJ, Lobetti RG and Van der Lugt JJ (2000) Acute pancreatitis: a newly recognised potential complication of canine babesiosis. *Journal of the South African Veterinary Association* **71**, 232–239
- Saunders HM, VanWinkle TJ, Drobatz K, Kimmel SE and Washabau RJ (2002) Ultrasonographic findings in cats with clinical, gross pathologic, and histologic evidence of acute pancreatic necrosis: 20 cases (1994–2001). *Journal of the American Veterinary Medical Association* **221**, 1724–1730
- Steiner JM and Williams DA (2003) Evaluation of feline pancreatic lipase immunoreactivity and helical computed tomography versus conventional testing for the diagnosis of feline pancreatitis. *Journal of Veterinary Internal Medicine* **17**, 411 (Abstract)
- Strombeck DR, Guilford WG, Center SA, Williams DA and Meyer DJ (1996) *Small Animal Gastroenterology*, 3<sup>rd</sup> edn. WB Saunders, Philadelphia
- Wiberg ME and Westermarck E (2002) Subclinical exocrine pancreatic insufficiency in dogs. *Journal of the American Veterinary Medical Association* **220**, 1183–1187
- Williams DA (1992) Exocrine pancreatic insufficiency. *Waltham International Focus* **2**, 9
- Williams DA (1995) Exocrine pancreatic disease. In: *Textbook of Veterinary Internal Medicine*, 4<sup>th</sup> edn, ed. SJ Ettinger and EC Feldman, pp. 1372–1392. WB Saunders, Philadelphia
- Williams DA (2000) Exocrine pancreatic disease. In: *Textbook of Veterinary Internal Medicine*, 5<sup>th</sup> edn, ed. SJ Ettinger and EC Feldman, pp. 1345–1367. WB Saunders, Philadelphia
- Williams DA and Batt RM (1988) Sensitivity and specificity of radioimmunoassay of serum trypsin-like immunoreactivity for the diagnosis of canine exocrine pancreatic insufficiency. *Journal of the American Veterinary Medical Association* **192**, 195–201
- Williams DA, Batt RM and McLean L (1987) Bacterial overgrowth in the duodenum of dogs with exocrine pancreatic insufficiency. *Journal of the American Veterinary Medical Association* **191**, 201–206
- Williams DA, Steiner JM, Ruaux CG and Zavros N (2003) Increases in serum pancreatic lipase immunoreactivity (PLI) are greater and of longer duration than those of trypsin-like immunoreactivity (TLI) in cats with experimental pancreatitis. *Journal of Veterinary Internal Medicine* **17**, 445–446 (Abstract)

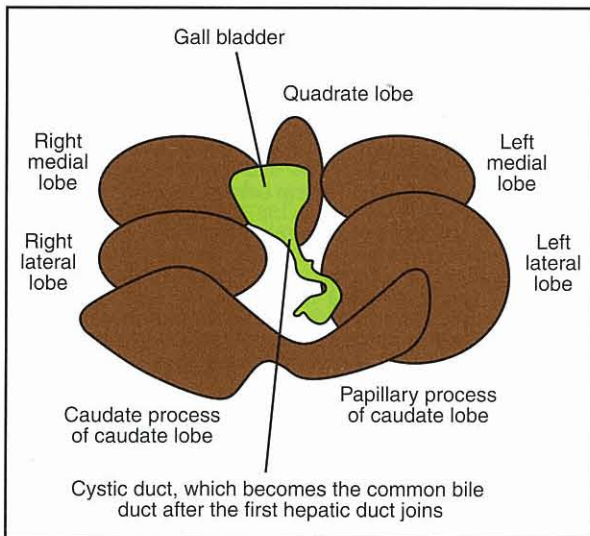


# Diseases of the liver

Penny Watson

## Anatomy

The liver lies in the cranial abdomen, between the diaphragm and the stomach, and is made up of four lobes and a gall bladder. The gall bladder is linked to the duodenum via a common bile duct (Figure 24.1), with a slightly different anatomical arrangement in cats and dogs (see below). The lateral parts of the right and left liver lobes are seen on lateral abdominal radiographs in dogs and cats as the caudoventral edge of the liver shadow under the costal arch (see Chapter 3).



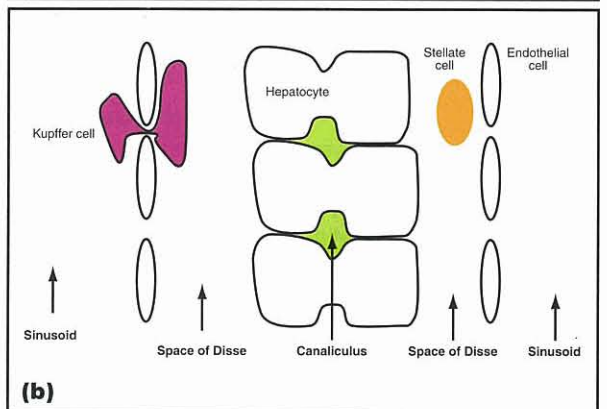
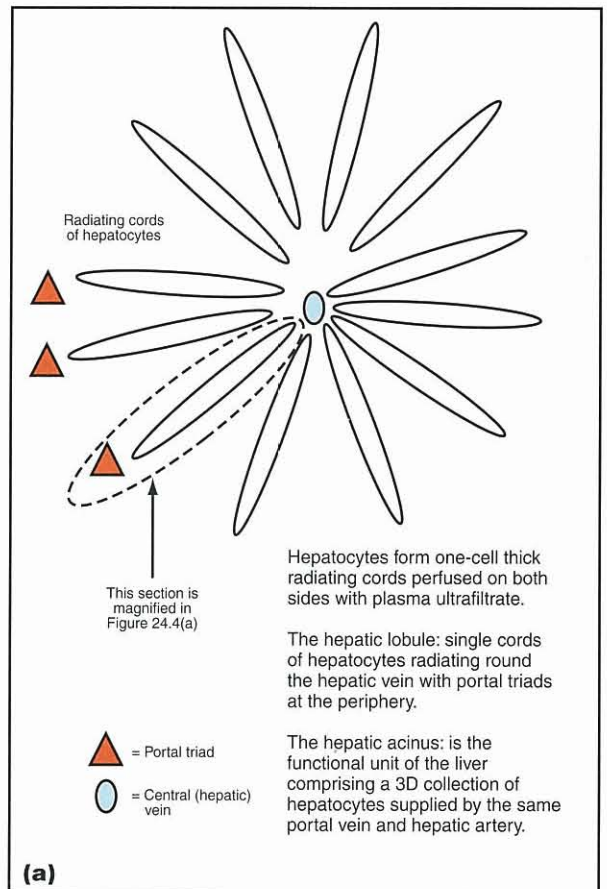
**24.1** Ventral view of the structure of the canine liver. (Reproduced from Watson (2004a) with permission from Blackwell Publishing)

The liver effectively has two afferent blood supplies:

- The hepatic artery, which brings only 25–30% of the afferent blood but 50% of the oxygen used by the liver
- The hepatic portal vein, which carries the balance of the blood and oxygen requirement.

The portal vein carries all the blood draining the stomach, intestines (except the rectum), pancreas and spleen to the liver. The hepatic vein drains the liver.

All of the afferent blood arriving in both the portal vein and hepatic artery then passes into the hepatic sinusoids, mixes and flows in close proximity to the hepatocytes towards the hepatic veins (Figure 24.2).



**24.2** Diagrammatic illustration of the structure of the liver. (a) Hepatic lobule. (b) Diagram of the anatomy of the space of Disse and canaliculi. (Reproduced from Watson (2004a) with permission from Blackwell Publishing)

Most of the metabolic and detoxifying functions of the liver occur during passage of blood along the sinusoids. The hepatocytes are divided into functional 'zones' with zone 1 being nearest to the portal triad (comprising the hepatic portal vein, hepatic artery and bile duct branch), zone 3 being nearest the hepatic vein and zone 2 being in the middle. Hepatocytes in each zone are exposed to different concentrations of oxygen, hormones, metabolites and other substances, and their functions are correspondingly different. They also vary in their sensitivity to various pathological processes: for example, zone 3 hepatocytes are damaged first by hypoxia; whereas zone 1 hepatocytes are usually the first to be damaged by hepatotoxins arriving in the portal blood from the gut. Bile is made in the hepatocytes in zone 3 and flows in the opposite direction to blood (see Chapters 14 and 25 for more details of bile formation).

### Function

The liver has an astounding array of functions. They are complex and summarized in Figure 24.3; such a broad view of these roles is sufficient in the clinical setting. It is particularly important to remember that the

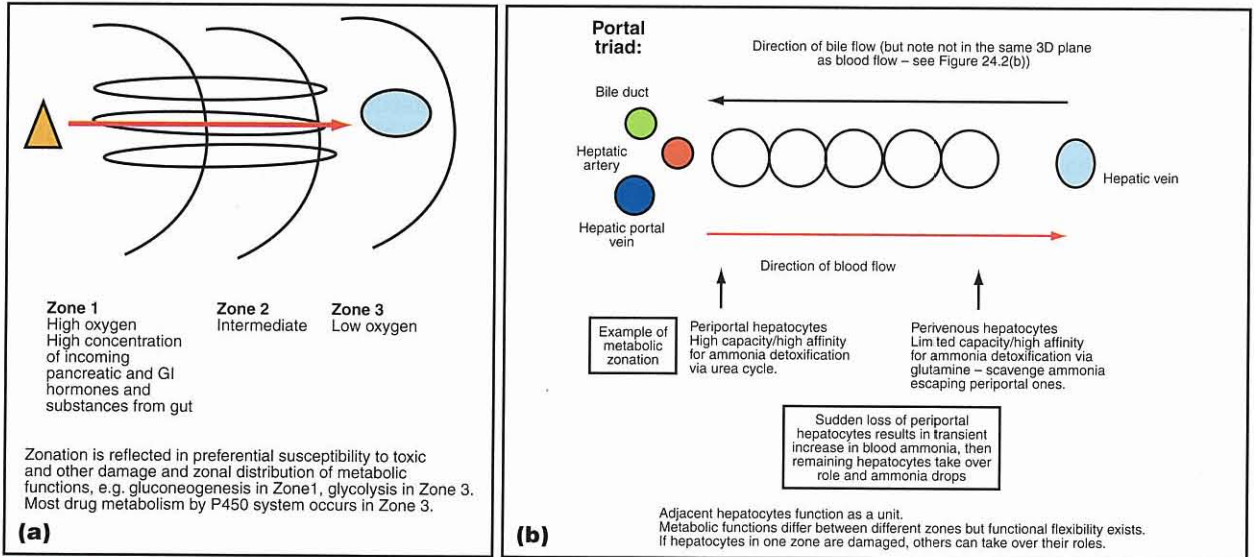
liver is very closely related, both structurally and functionally, to the pancreas and small intestine and that diseases of one of these organs often affects the others. These associations are well documented in cats, but can also be seen in dogs. Food and drugs or toxins taken orally may also have a profound effect on the liver since all absorbed substances pass through the liver in the portal blood prior to entering the systemic circulation.

### Functional plasticity and regenerative capacity

The liver has tremendous functional and structural reserve and also great potential regenerative capacity. The functional zoning described above and illustrated in Figure 24.4 is flexible such that if hepatocytes in one zone are damaged, others can take over their function. Such functional adaptation takes time, however, and therefore acute hepatic failure will result in clinical signs after loss of less liver mass than chronic hepatic disease; with the latter, the hepatocytes have time to adapt and take over the functions of damaged cells and so clinical signs usually do not develop until at least 70% of hepatic functional mass has been lost.

Function	Examples
Metabolism	Glucose and energy metabolism and storage Fat and cholesterol metabolism and storage Protein metabolism, including ammonia detoxification and urea synthesis. Synthesis of albumin, apoproteins for triglyceride transport and all globulins except immunoglobulin
Vitamin and mineral metabolism and storage	Activation, synthesis and storage of fat-soluble vitamins (A, D, E and K) Synthesis of vitamin C Activation, synthesis and storage of B vitamins Storage of minerals: copper, iron, zinc
Hormone metabolism <i>(remember portal blood drains the pancreas so first-pass metabolism of hormones from pancreas is important and some of these hormones are 'trophic' to the liver)</i>	Insulin and glucagon degradation Production of insulin-like growth factor under the influence of growth hormone Degradation of many steroid and polypeptide hormones
Coagulation and anti-coagulation factors	Synthesis of all coagulation factors, except factor VIII Activation of coagulation factors including vitamin-K dependent activation Synthesis of anti-coagulant factors
Immunological functions	Kupffer cells comprise 90% of total body tissue macrophages so have a very important reticuloendothelial function <i>(all portal blood passes through liver so these cells are exposed to any blood-borne bacteria and antigens of GI origin that have escaped the gut-associated lymphoid tissue)</i> Complement metabolism and interleukin production IgA in bile
Haematological functions	Haemopoiesis: <i>in utero</i> and extramedullary haemopoiesis in times of need, such as severe anaemia (may result in noticeable hepatomegaly) Breakdown of senescent red cells and uptake, conjugation and excretion of bilirubin (see Chapter 14) Iron homeostasis <i>(Note iron chelation in liver results in microcytic anaemia in many chronic liver diseases)</i>
Digestive functions	Synthesis, storage and secretion of bile salts for emulsification of fats. Note steatorrhoea due to lack of bile salts is very rare in small animals as complete biliary obstruction is very rare
Detoxification and excretory functions <i>(Note importance of filtering all of the portal blood from gut and 'first pass' metabolism of drugs and toxins)</i>	Bilirubin conjugation and excretion (see Chapter 14) Ammonia detoxification via urea cycle Steroid hormone breakdown and excretion Copper excretion Cholesterol excretion Xenobiotic (substance foreign to the body) detoxification and excretion (e.g. barbiturates, macrolides, benzodiazepines)

24.3 Summary of functions of the liver.



**24.4** Diagrammatic illustration of the function of the liver. (a) Schematic drawing of one cord of hepatocytes showing functional zonation. (b) Schematic drawing of zonal distribution in hepatic acinus. (Reproduced from Watson (2004a) with permission from Blackwell Publishing)

The liver also has a tremendous ability to regenerate, provided the animal is not starved and the damage is not too severe or ongoing. The cells in the 'limiting plate' (the layer of hepatocytes immediately surrounding the portal triads) are the ones which regenerate most actively, and therefore necrosis of this area can particularly inhibit regeneration.

### Differences between dogs and cats

The major causes of chronic and acute liver disease in dogs and cats are outlined in Figures 24.5, 24.6 and 24.7, and discussed at greater length later in the chapter. Chronic liver disease is more common than acute disease in both dogs and cats.

**Cats** (in approximate order of frequency in UK; for USA lipidosis is most common)

Chronic lymphocytic cholangitis (see Chapter 25)

Hepatic lipidosis

Infections:  
Particularly feline infectious peritonitis-associated hepatitis (major differential diagnosis for lymphocytic cholangitis)  
Occasionally toxoplasmosis  
Liver fluke in parts of USA

Vascular disorders:  
Congenital portosystemic shunts and others (less common than dogs)

Neoplasia:  
Primary and secondary, especially lymphosarcoma (may be more acute liver failure)

Amyloidosis: usually multi-organ, including renal involvement, but a few reports of primarily hepatic amyloid

**24.5** Causes of chronic liver disease in cats.

**Dogs** (in approximate order of frequency)

Chronic hepatitis (see Figure 24.23)

True copper storage disease:  
Bedlington Terriers; Dalmatians; Dobermann

Congenital or early developmental disease:  
Vascular disorders – congenital portosystemic shunts, portal vein hypoplasia and others  
Lobular dissecting hepatitis in Standard Poodles and other breeds

Non-cirrhotic portal hypertension in German Shepherd Dogs and other breeds

Chronic cholangitis: less common than in cats; cause unknown, possible ascending infection? (See Chapter 25 for further details)

Chronic progression of acute hepatopathy:  
Chronic toxicity (including chronic anti-convulsant medication)  
Idiosyncratic drug reaction  
Infectious  
Ischaemic  
Obstructive

Chronic viral and bacterial infections are largely undocumented. Organisms often not visible on biopsy (see Figure 24.23), e.g. *Bartonella*, atypical leptospira, chronic forms of canine adenovirus in partially immune individuals

Chronic fungal infections:  
Histoplasmosis; aspergillosis (usually part of more generalized disease)

Neoplasia:  
Primary and secondary, especially lymphoma  
Hepatocellular carcinoma  
Metastases  
Histiocytic

**24.6** Causes of chronic liver disease in dogs.

Type of disease	Potential cause
Acute massive hepatocyte necrosis (severe necrosis with signs referable to liver disease)	Toxic or drug-induced: e.g. acetaminophen (paracetamol) especially in cats, carprofen (especially Labrador Retrievers); diazepam in cats; mebendazole (dogs), thiacetarsamide (dogs); mercury; potentiated sulphonamides (dogs) Infectious, e.g. canine adenovirus type 1; neonatal canine herpes virus; bacterial endotoxaemia Thermal: heat stroke (uncommon) Metabolic: acute hepatic necrosis in young Bedlington Terriers with copper storage disease
Acute hepatic necrosis: mild to moderate, focal (note clinical signs usually referable to primary underlying disease and not to liver)	Milder forms of toxic and drug-induced necrosis Hypoxia: cardiorespiratory disease; severe anaemia Cholestasis Septicaemia: both focal and diffuse Pancreatitis Inflammatory bowel disease Infectious causes: e.g. feline infectious peritonitis; <i>Salmonella</i> ; <i>Leptospira</i> ; <i>Clostridium</i> spp.; <i>Ehrlichia</i> ; <i>Toxoplasma</i> ; disseminated aspergillosis
Acute loss of hepatocyte function with minimal necrosis (usually marked loss of liver function and signs referable to liver)	Hepatic lipidosis in cats Diffuse tumour infiltrate e.g. lymphoma

**24.7** Potential causes of acute hepatic necrosis in dogs and cats.

There are many important differences between cats and dogs in terms of the structure and function of the liver and also in the diseases shown, the liver's response to disease, the clinicopathological findings and the treatments indicated. The most important differences are outlined in Figure 24.8 and referred to where relevant in the text. Notably, cats rarely develop marked hepatic fibrosis, cirrhosis or acquired portosystemic shunts, unlike dogs. Cats therefore tend to have a better prognosis with chronic liver disease than dogs. Historically there has been a

marked difference in the types of hepatic diseases recognized in cats in North America compared with Europe. Primary feline hepatic lipidosis is more common in North America but rare in Europe, whereas primary biliary tract disease is common in Europe but relatively uncommon in North America. The difference is intriguing and the reason unknown, although the pattern of disease seen in North America may be shifting towards that seen in Europe. The types of liver disease seen in dogs are, by contrast, very similar in both continents.

Category	Cats	Dogs	Significance
Anatomy of pancreatic and bile ducts	Bile duct joins single major pancreatic duct before entering small intestine at major duodenal papilla  (20% of cats have a second accessory pancreatic duct and a few cats have separate major pancreatic duct and common bile duct)	Most dogs have two pancreatic ducts (large accessory duct from right limb of pancreas to minor papilla in duodenum; and smaller pancreatic duct from left limb to major papilla). Neither of these pancreatic ducts join the bile duct but the smaller pancreatic duct opens next to the bile duct on major duodenal papilla	Concurrent biliary tract disease, pancreatitis and inflammatory bowel disease are possible in either species but are more common in the cat. Ascending infections of the bile duct also proposed to be more common in cats.
Ability to metabolize drugs and toxins	Relative deficiency of glucuronyl transferase, reducing ability to metabolize drugs and toxins	Generally no deficiency of enzymes but some breed variation, e.g. Dobermanns have impaired detoxification of potentiated sulphonamides	Cats more susceptible to certain types of toxic liver damage than dogs and more sensitive to many potentially hepatotoxic drugs. Some breed variation in susceptibility to toxic liver damage in dogs
Isoenzymes of alkaline phosphatase (ALP)	Do not produce a steroid-induced isoenzyme of ALP. Half-life of ALP also very short in cats (6 hours)	Dogs have a steroid-induced isoenzyme of ALP. Half-life of ALP is long, e.g. half-life of hepatobiliary ALP is 66 hours and glucocorticoid-induced ALP is 74 hours	Steroid treatment or hyperadrenocorticism (HAC) are major differentials for raised ALP in dogs; however, ALP levels are not elevated with steroid therapy (or HAC prior to development of diabetes mellitus) in cats

**24.8** Differences between cats and dogs in terms of liver structure, function and disease. (continues)

Category	Cats	Dogs	Significance
Hepatic metabolism of glucose and protein	<p>Constantly high hepatic gluconeogenesis from protein, even postprandially, and constantly high activity of protein catabolizing enzymes in the liver which cannot be down-regulated</p> <p>High dietary requirement for arginine for the urea cycle</p> <p>Taurine is an essential dietary requirement and bile salts all conjugated with taurine</p>	<p>Dogs, like humans, make glucose from starch, and postprandial insulin release stops gluconeogenesis and switches to glucose storage. Dogs can down-regulate hepatic protein metabolizing enzymes as necessary when the diet is low in protein</p> <p>Dogs have a lower arginine requirement than cats. Dogs have no known dietary taurine requirement</p>	<p>Cats will rapidly develop protein-calorie malnutrition and start breaking down their own body protein if fed a protein-restricted diet in liver disease</p> <p>Arginine deficiency can contribute to the development of hyperammonaemia in cats with liver disease if the cat is fed a diet lacking in arginine (such as dairy protein). Taurine, arginine and protein deficiency can contribute to the pathogenesis of hepatic lipidosis in cats (see below)</p>
Hepatic lipid metabolism and mobilization	Cats are particularly susceptible to clinically serious hepatic lipidosis (either primary or secondary)	Dogs can develop some secondary lipidosis but this is not usually a clinical problem	<p>Cats are susceptible to primary hepatic lipidosis, which is a severe clinical problem</p> <p>Secondary hepatic lipidosis can develop in either dogs or cats with other diseases but is more common and more clinically significant in cats</p>

**24.8** (continued) Differences between cats and dogs in terms of liver structure, function and disease.

### Investigating liver disease

Animals being investigated for liver disease usually fall into one of two groups depending on the presentation and the questions raised:

- The animal has clinical signs – could these be due to liver disease?
- Or
- The animal has abnormal liver test results on routine blood biochemical testing but no related clinical signs – are the test results important? Is the liver problem primary or secondary? Is further testing warranted?

In either situation a further issue is whether or not to take a liver biopsy. The approach to answering these questions is outlined below.

One important question to answer as early in the investigation as possible is whether the hepatopathy is primary or a secondary reaction pattern to another disease process in another organ. The most common causes of secondary hepatopathies in dogs and cats are outlined in Figure 24.9. Secondary hepatopathies are usually not clinically significant in their own right and resolve when the underlying cause is treated. However, in a few cases a secondary hepatopathy can develop into a more serious ‘primary’ problem as a result of chronic secondary stimulation. An example would be chronic cardiac cirrhosis in dogs, which sometimes develops after chronic passive congestion in right-sided heart failure.

It is important to establish whether the hepatopathy is secondary as early as possible to avoid unnecessary hepatic investigations (such as liver biopsy) that might

- Right-sided congestive heart failure including pericardial effusion and heartworm
- Hypoxia:
  - Autoimmune haemolytic anaemia
  - Shock
- Glucocorticoids:
  - Most significant in dogs. Causes a marked increase in alkaline phosphatase with mild increases in alanine aminotransferase, aspartate aminotransferase and bile acids
  - Endogenous (hyperadrenocorticism)
  - Exogenous
- Diabetes mellitus
- Hyperlipidaemia e.g. Schnauzers
- Hyperthyroidism (cats)
- Hypothyroidism (dogs)
- Non-hepatic inflammatory disease:
  - Toxaemia
  - Sepsis
  - GI disease
  - Pancreatitis
- Drug-induced e.g. phenobarbital
- Metastatic disease

**24.9** Common causes of secondary hepatopathies in dogs and cats.

take time and money away from diagnosing and treating the true disease. This differentiation is usually achieved through careful interpretation of history, clinical examination, clinicopathological test results and diagnostic imaging.

### History and clinical signs

A good history and thorough clinical examination are particularly important in patients with suspected liver disease. They will help differentiate primary from secondary hepatopathies and alert the clinician to any concurrent or underlying disease. Figures 24.10 and 24.11 outline

## Acute onset of:

Anorexia  
 Hepatic encephalopathy: depression progressing to seizures and/or coma  
 Vomiting  
 Polydipsia  
 Dehydration  
 Jaundice (more marked/earlier if periportal lesion)  
 Fever  
 Cranial abdominal pain (some but not all cases)  
 Coagulopathy, petechiae ± haematemesis/melaena  
 Ascites and splenomegaly due to portal hypertension (less common but poor prognostic indicator in humans)  
 Renal failure is a severe complication in some cases: both pre-renal and intrinsic renal components

## Additional clinical findings reported in humans but not documented in dogs and cats:

Hypotension  
 Cardiac arrhythmias  
 Cerebral oedema (not just due to hypoalbuminaemia)  
 Primary pulmonary oedema (not just due to hypoalbuminaemia)  
 Pancreatic injury  
 Increased susceptibility to infection with reduced neutrophil function

**24.10** Typical clinical signs of acute fulminating hepatitis in dogs and cats.

(Often no clinical signs until >70% loss of hepatic mass)

Vomiting and/or diarrhoea  
 Occasionally haematemesis and melaena  
 Inappetence  
 Weight loss  
 Polydipsia, polyuria and poorly concentrated urine  
 Ascites  
 Jaundice  
 Hepatic encephalopathy: depression; excitement; ptyalism (especially cats); pacing (uncommon: fitting or coma)  
 Bleeding diatheses (uncommon but serious: suggests large loss of liver mass)

**24.11** Typical clinical signs of chronic liver disease in dogs and cats.

the typical clinical signs of acute and chronic liver disease in dogs and cats. Clinical signs are particularly non-specific in cats and the situation is further complicated in this species by the high incidence of concurrent inflammatory bowel disease (IBD) and/or pancreatitis. The most 'specific' clinical signs for liver disease in dogs and cats are encephalopathy, jaundice and ascites but even these signs could also potentially have other causes (see Chapters 13, 14 and 15).

The clinician should be particularly alert to reports of subtle waxing and waning neurological or gastrointestinal (GI) signs (including melaena, which can occur with portal hypertension) and any evidence of concurrent or underlying disease (such as GI disease or an endocrinopathy). Body condition, mucous membrane colour and abdominal abnormalities (including the presence of ascites) should be carefully assessed. The animal should also be checked for evidence of coagulopathies (petechiae and ecchymoses), particularly in acute disease.

The liver is often not palpable in either normal or abnormal dogs and cats because of its position under the rib cage. Palpable hepatomegaly may be difficult to distinguish from splenomegaly without diagnostic imaging, and both may occur together (hepatosplenomegaly). In dogs, chronic primary liver disease (other than neoplasia) is usually associated with a small liver that will only be appreciated on diagnostic imaging and not on clinical examination. However, a significant number of cats with chronic liver disease (either cholangitis or lipidosi) have palpable hepatomegaly. Pain on cranial abdominal palpation is common in acute liver disease but uncommon in chronic disease in either species, although it may be elicited in some dogs. Pain might also reflect concurrent pancreatitis or upper GI disease.

The severity of the clinical signs seen in liver disease depends on the speed with which the disease develops, the amount of functional liver tissue damaged and the degree of portal hypertension that develops. As discussed above, the liver has tremendous structural and functional reserve. If disease develops slowly, not only can liver tissue regenerate but zonal adaptation can also occur, limiting clinical signs. However, if the damage is acute there is no time for this adaptation to occur. For example, hyperammonaemia and hepatic encephalopathy will develop very quickly in acute disease but more slowly in chronic disease (see Figure 24.4). Therefore, animals with very extensive chronic liver disease may show no clinical signs at all or very subtle signs. These cases would come into the second category outlined above; raised liver enzyme activities in blood, but no clinical signs. It remains important for the clinician to be alert to even subtle signs and to investigate apparently normal animals further if liver enzymes are persistently increased, as liver damage may already be extensive in these cases and treatment may be more effective if instigated as early as possible.

### Clinicopathological changes in liver disease

Blood tests to assess liver enzymes are usually the next (and simplest) step in the investigation of the suspected hepatic case. Carefully chosen blood tests should also help in differentiating primary from secondary disease and in assessing liver function. A detailed discussion of clinical pathology is beyond the scope of this chapter and the reader is referred elsewhere (see Chapter 2 and *BSAVA Manual of Canine and Feline Clinical Pathology*). However, the use of clinical pathology in the investigation of the liver case is outlined below and in Figures 24.12 and 24.13.

It is important to remember that clinical pathology is only a part of the investigation of liver cases and is most important in guiding further tests (diagnostic imaging and biopsy). It is never possible to make a diagnosis of liver disease on the basis of blood tests alone and it is often not even possible to differentiate primary from secondary hepatopathies, although the pattern of changes found, combined with the history and clinical findings, often allow this differentiation. It is also a mistake to think that liver enzymes are a test of liver function or that results give prognostic information; the

Enzyme	General	Dog	Cat
Alanine aminotransferase (ALT)	<ul style="list-style-type: none"> <li>Hepatocellular enzyme (constant activity in hepatocytes); increased blood activities represent increased leakage from cell</li> <li>Degree of elevation does not show amount or severity of liver damage</li> <li>Present in cytoplasm only so leaks relatively easily</li> <li>Relatively liver-specific</li> <li>Remains high in regeneration so rapid return to normal may imply severe cirrhosis</li> <li>Low levels are not significant</li> </ul>	Long $T_{1/2}$ = 40–60 hours so remains elevated for several days after recovery. Persistent elevation for weeks to months implies chronic hepatitis and a biopsy should be performed	Short $T_{1/2}$ = 3.5 hours
Aspartate aminotransferase (AST)	<ul style="list-style-type: none"> <li>Hepatocellular enzyme (constant activity in hepatocytes); increased blood activities represent increased leakage from cell</li> <li>Degree of elevation does not show amount or severity of liver damage except in comparison with increases in ALT</li> <li>Present in both cytoplasm and mitochondria; compared to ALT is released later and only when there is more severe damage than ALT</li> <li>Also found in muscle (skeletal and cardiac); use measurement of other liver and muscle enzymes (creatine kinase) to differentiate source</li> <li>Remains high in regeneration so rapid return to normal may imply severe cirrhosis</li> <li>Low levels are not significant</li> </ul>	$T_{1/2}$ = 12 hours	$T_{1/2}$ = 1.5 hours
Alkaline phosphatase (ALP)	<ul style="list-style-type: none"> <li>Induced enzyme from biliary tract; minimal activity at rest</li> <li>ALP predominantly from canaliculi</li> <li>Induced by drugs and cholestasis</li> <li>Not liver-specific; isoenzymes in other organs including bone and gut. Gut isoenzyme half-life very short (<math>T_{1/2}</math> = 6 minutes in the dog, 2 minutes in the cat), so not important. Bone isoenzyme increased from 3–6 times in young dogs. Separating isoenzymes on blood tests largely unhelpful</li> </ul>	$T_{1/2}$ of biliary isoenzyme = 66 hours. Steroid-induced isoenzyme (= hyperglycosylated gut isoenzyme with prolonged half-life) common cause of elevation; $T_{1/2}$ = 74 hours and remains elevated for weeks after therapy. May be more sensitive than GGT in dogs but rule out other causes	$T_{1/2}$ of biliary isoenzyme = 6 hours and limited capacity to produce it so elevations very significant and indicate ongoing problem. No steroid-induced isoenzyme Classically very high ALP but normal GGT in hepatic lipidosis
Gamma-glutamyl transferase (or transpeptidase) (GGT)	<ul style="list-style-type: none"> <li>Induced enzyme from biliary tract epithelium; minimal activity at rest</li> <li>GGT predominantly from biliary membranes</li> <li>Induced by cholestasis and less by drugs than ALP</li> </ul>	Less sensitive than ALP for detection of biliary stasis in the dog	May be more sensitive to biliary stasis than ALP in cats Classically very high ALP but normal GGT in hepatic lipidosis

**24.12** Interpreting changes in serum liver enzymes in liver disease.

**Non-specific tests of liver function**

(Note changes in all these parameters have many other causes apart from liver disease and reductions in liver disease may be masked by concurrent increases with other diseases)

<b>Plasma proteins:</b> albumin and globulin	All plasma proteins, except gamma globulins and von Willebrand's factor, are made in the liver Liver has large functional reserve; can upregulate production if increased loss. Blood albumin only decreases if <30% of normal liver function If total protein only measured, the drop in albumin in severe, chronic liver disease may be masked by a concurrent rise in globulin (due to antigenic stimulation from liver inflammation and/or increased absorption of bacteria from the gut). Therefore, measure albumin:globulin ratio if possible Electrophoresis to separate out protein fractions further may give some prognostic information (see text)
<b>Urea</b>	Can be reduced in chronic liver disease for a number of reasons including reduced protein metabolism and ammonia detoxification, polydipsia/polyuria causing renal washout, loss of body condition, reduced protein intake and fluid therapy Most commonly low in animals with congenital portosystemic shunts (PSSs) where, in addition to the above reasons, less ammonia is delivered to the liver for detoxification by conversion to urea
<b>Glucose</b>	Low blood glucose is particularly seen in: Fulminant acute hepatic necrosis Congenital PSSs, particularly in small-breed dogs and especially associated with acute hepatic encephalopathy Large hepatic tumours, classically canine hepatomas and hepatocellular carcinomas Very non-specific as many other diseases cause reduced blood glucose but very important to recognize it clinically and treat it, as untreated hypoglycaemia could result in permanent brain damage or even death, particularly in fitting dogs

**24.13** Interpretation of function tests in the investigation of liver disease. BSP = bromsulphthalein; DIC = disseminated intravascular coagulation; MER = Metabolic energy requirement; PIVKA = Proteins induced by vitamin K absence. (continues)

**Non-specific tests of liver function *continued***

<b>Coagulation factors</b>	Reduction in coagulation factors common in liver disease in dogs and cats but prolongation of clotting times uncommon (big functional reserve) Severe reduction and significant prolongation of coagulation times more likely in acute, fulminant failure with rapid loss of a lot of liver mass, cats with concurrent inflammatory bowel disease and/or pancreatitis reducing vitamin K absorption and animals with DIC or thrombi consuming factors PIVKA much more sensitive to reduction in clotting factors than coagulation times in cats
<b>More specific tests of liver function</b>	
<b>Ammonia</b>	Elevated particularly in congenital and acquired PSSs. A postprandial test measuring stimulation 6 hours after feeding a meal of 25% of the daily MER increases the sensitivity and is safer than the traditional per-oral or per-rectal ammonia tolerance test Labile in blood so needs processing carefully and rapidly Other causes of elevation include: microvascular dysplasia; experimental arginine deficiency in cats; and congenital urea cycle defects
<b>Bile acids</b> (see also Chapter 2)	Elevated in early cholestasis (more sensitive than bilirubin) and congenital and acquired PSSs As sensitive and specific for PSSs as ammonia and less labile in the sample but not generally available on practice analysers Sensitivity in PSSs increased by performing a bile acid stimulation test, measuring bile acids pre- and 2 hours post a fatty meal. A stimulation test is not necessary if fasting levels are significantly elevated. Postprandial levels will occasionally be lower than fasting levels due to variations in times of spontaneous gall bladder contractions and bacterial overgrowth in the duodenum (see below) Bile acid elevations are also seen in microvascular dysplasia; elevations tend to be less marked than in congenital PSSs but there is some overlap Mild elevations (usually <50 µmol/l) may also occur in some endocrine diseases, such as hyperadrenocorticism in dogs, and also with bacterial overgrowth in the small intestine, which deconjugates bile acids making them more easily absorbed across the intestinal wall but less easily taken up by hepatocytes Very efficient enterohepatic circulation means that bile acid deficiency is not a feature of even severe, advanced liver disease
<b>Bilirubin</b> (see Chapter 14)	Increased in cholestasis but relatively insensitive Need to differentiate prehepatic, hepatic and post-hepatic causes
<b>Exogenous clearance tests</b> (e.g. BSP)	No longer available and superseded by newer tests

**24.13** (continued) Interpretation of function tests in the investigation of liver disease. BSP = bromsulphthalein; DIC = disseminated intravascular coagulation; MER = Metabolic energy requirement; PIVKA = Proteins induced by vitamin K absence.

degree of elevation of liver enzymes is not related to degree of liver damage or function, and activities of enzymes or bile acids are not usually helpful for prognosis. One exception to this is plasma or serum protein electrophoresis, which can give prognostic information in animals with liver disease by comparing albumin and acute phase protein levels.

The changes in liver enzymes potentially seen in liver disease are outlined in Figure 24.12 and the specific and non-specific function tests are outlined in Figure 24.13. Mild, relatively transient elevation of liver enzymes is not uncommon as a reaction to other diseases particularly in dogs; even IBD and antibiotic-responsive enteropathy can result in elevated liver enzymes. However, persistent significant elevation of liver enzymes for weeks, particularly hepatocellular enzymes (alanine aminotransferase (ALT) or aspartate aminotransferase (AST)) in a dog, and either hepatocellular or biliary enzymes in a cat, should stimulate further investigations. The clinician should be particularly alert to elevated liver enzymes in asymptomatic individuals in a 'high-risk' group, such as persistently elevated ALT in a Doberman or Cocker Spaniel or elevated alkaline phosphatase (ALP) in an obese, anorexic cat. In contrast, persistent mild to moderate elevation of ALP is not uncommon in old dogs and, if hepatocellular enzymes are normal, these animals should not have a liver biopsy before other causes are ruled out. In many cases, raised ALP in dogs is a result

of a hepatopathy secondary to other diseases (such as chronic pancreatitis or hyperadrenocorticism) or may be the result of benign nodular hyperplasia (see below). However, raised ALP is much more significant in cats because of its short half-life and the lack of a steroid-induced isoenzyme in this species.

In addition to blood samples, a urine sample provides useful information in the animal with suspected liver disease. Animals with chronic liver disease often have poorly concentrated urine. Furthermore, ammonium urate crystals or stones may be seen due to reduced purine metabolism, particularly in animals with congenital or acquired portosystemic shunts (PSSs).

If ascites is present, a sample of the fluid should be taken and analysed for cell count, protein level and cytology as this can give useful information. The details of analysis of ascitic fluid are given in Chapter 13.

### Diagnostic imaging

The next investigation after blood tests should be diagnostic imaging (see Chapter 3). Ultrasonography is particularly helpful although radiography is also useful, particularly to identify or eliminate alternative or concurrent diseases.

Abdominal radiography is generally unhelpful in an animal with ascites because the fluid obscures all detail. However, ultrasonography is often rewarding in the cases because the fluid separates the organs and makes them clearly visible. It may be worth taking



an abdominal radiograph if the animal has a swollen abdomen but no definite fluid wave on palpation to establish or refute the presence of ascites, but ultrasonographic detection of free abdominal fluid is more sensitive. It is not uncommon for the pendulous abdomen of a dog with hyperadrenocorticism to appear ascitic on clinical examination and the associated elevation in liver enzymes may suggest primary liver disease. However, abdominal radiography in these cases will be highly suggestive of hyperadrenocorticism with hepatomegaly, a pot bellied appearance and no ascites, and this should direct investigations in that direction rather than towards primary liver disease.

### **Radiography**

In the animal without ascites, abdominal radiography may give a crude indication of liver size (see Chapter 3) but radiographs are insensitive to subtle changes. In general, dogs and cats with acute liver disease have normal to enlarged livers, dogs with chronic liver disease and PSSs have small livers and cats with chronic liver disease have enlarged livers. However, normal dogs (particularly deep-chested breeds) may have apparent microhepatica on radiographs and dogs with PSSs or chronic liver disease may have an apparently normal-sized liver on radiographs. Abdominal radiography may also identify focal hepatic enlargement associated with a hepatic tumour or occasionally due to focal enlargement of the biliary tract in cats. If neoplasia is suspected, right and left lateral thoracic radiographs should also be taken to check for metastases. Radiography may also indicate more generalized disease in other organs, for example there may be concurrent splenomegaly and lymphadenopathy in lymphoma, mast cell tumours or histiocytic neoplasia.

### **Ultrasonography**

Ultrasonography, in the hands of an experienced operator, is an extremely useful tool in the investigation of liver cases as it allows: assessment of the structure of the hepatic parenchyma, biliary tract, portal vein branches and other organs; collection of samples of abdominal fluid and bile; and biopsy of the liver (see Chapter 3). Laparoscopy and laparotomy allow direct visualization of the external appearance of the organ but ultrasonography is still a useful adjunct to these investigations as it allows visualization of the internal structure and lesions within the parenchyma. The liver is relatively straightforward to examine with ultrasonography and the increasing availability of peripatetic ultrasonographers should put this within the reach of most primary care practices.

Ultrasonography allows assessment of the size and structure of the gall bladder, common bile duct and biliary tree. If the common bile duct is grossly dilated, the area distal to it (including the pancreas and proximal duodenum) can be carefully examined for any mass, inflammation or other lesion causing an obstruction. The hepatic parenchyma can be examined for focal or diffuse changes in echogenicity. Focal changes may indicate neoplasia but it is important not to over-

interpret ultrasonographic findings and to remember that an ultrasound abnormality is not a histological diagnosis: such focal changes may equally well represent patchy extramedullary haemopoiesis, patchy lipid or glycogen infiltrate or benign nodular hyperplasia in older dogs. A biopsy is essential to rule these out and diagnose neoplasia; an animal should never be euthanized on the basis of the ultrasonographic appearance of a lesion alone.

Diffuse changes in hepatic echogenicity are common and potential causes are outlined in Chapter 3. There is often a diffuse increase in echogenicity in cirrhosis with a reduction in visualization of vessels. The spleen may appear congested in these cases due to portal hypertension. However, occasionally the liver looks ultrasonographically normal in advanced cirrhosis. Lymphoma classically results in a hypoechoic appearance to the liver as well as the spleen but may also result in a hyperechoic or normal-appearing liver, so neither cirrhosis nor hepatic lymphoma can be ruled out on the basis of a normal-appearing liver on ultrasound.

### **Other modalities**

Other imaging modalities used less often in the investigation of liver disease include scintigraphy, computed tomography (CT) and magnetic resonance imaging (MRI). These imaging modalities are rarely used in clinical cases but are considered further in Chapter 3. Scintigraphy is most useful in the assessment of PSSs and shunting fractions. CT and MRI have been used extensively in humans, particularly in assessment of biliary tract and vascular disease. Their use in small animals is currently very limited, largely due to the cost involved, limited access to equipment and technical complexities, including the need for general anaesthesia.

### **Biopsy**

The next step in the investigation is a liver biopsy (see Chapter 5). It is impossible to make a definitive diagnosis of disease and to make logical decisions about management without a liver biopsy. For example, finding a small, diffusely hyperechoic liver in an animal with ascites may suggest cirrhosis, but it is impossible to be sure without a biopsy. The animal may, in fact, have non-cirrhotic portal hypertension, which carries a much better prognosis (see below). It is also impossible to assess whether the disease is end-stage, so steroid therapy is inappropriate (and potentially dangerous), or whether the fibrosis is still relatively early and potentially sensitive to steroid or other therapy. Even in cats, the clinical, clinicopathological and diagnostic imaging findings will not differentiate acute (neutrophilic) from chronic (lymphocytic) cholangitis, and so again it is impossible to recommend steroid therapy safely without a biopsy, or at least a gall bladder aspirate. Without a biopsy, treatment of liver disease in dogs and cats will be at best non-specific, and at worst counter-productive and dangerous. Therefore, some kind of biopsy should be obtained wherever possible and certainly steroid, copper-chelating and antifibrotic therapies should not be used without biopsy confirmation of disease and stage.

Platelet counts and coagulation times should be checked prior to performing a biopsy. A whole-blood clotting time in a glass tube and buccal mucosal bleeding times are usually adequate clinical tests of coagulation time. If coagulation times are significantly prolonged, vitamin K therapy 12 hours prior to biopsy can help or intravenous plasma may be indicated to replenish clotting factors.

Fine needle aspiration (FNA) cytology is rarely helpful in the diagnosis of liver disease. The results can be misleading and should always be viewed with some suspicion. It is not helpful with diffuse inflammatory diseases but it may be diagnostic in focal tumours, hepatic lymphoma and hepatic lipidosis. Ultrasound-guidance is preferable as it allows the FNA to be taken from the area of interest and avoidance of blood vessels and the biliary tract. FNA of bile from the gall bladder is possible if undertaken with care under ultrasound-guidance (see Chapters 5 and 25). FNA is helpful in animals with primary biliary tract disease and the fluid obtained should be submitted for culture and sensitivity as well as cytology.

Biopsy samples may be taken under ultrasound-guidance with a Tru-cut needle or at laparotomy or laparoscopy. Ultrasound-guided transcutaneous Tru-cut biopsy is less invasive than laparotomy or laparoscopy, can be performed under heavy sedation or general anaesthesia and are better than no biopsy at all. However, they are often too small and non-representative. Multiple biopsy samples should be taken with as large a Tru-cut needle as possible to maximize the chances of obtaining a diagnostic sample. The animal should be monitored carefully for haemorrhage afterwards (preferably hospitalized overnight) which, although uncommon, can develop unnoticed in these animals and be life-threatening.

Laparotomy is much more invasive but allows examination of other abdominal organs (such as the pancreas and small intestine), observation of the liver and careful biopsy (see Chapter 5). The risk of haemorrhage is also smaller than with Tru-cut biopsy as any haemorrhage can be seen and dealt with at the time of surgery. The biopsy specimens obtained are generally bigger and more diagnostic with the proviso that focal lesions deep in the parenchyma may be missed if ultrasonography has not been used as well. If one part of the liver looks normal and another part abnormal, samples should be taken from both areas as it is not uncommon for the apparently 'normal' part to be the diseased area! Laparoscopy is less invasive than laparotomy but has similar advantages.

#### Histopathological interpretation and treatment

Extrapolation of histopathological findings to formulate treatment recommendations can be difficult. The clinician should have a good understanding of the pathophysiology and treatment of liver disease to allow interpretation of the histopathological changes and should not just read the 'bottom line' (diagnosis). An expert pathologist in small animal liver disease should be used and often the clinician will gain more information by discussing the results on the phone with the pathologist. The pathological description of

liver disease in dogs and cats is currently being standardized by the World Small Animal Veterinary Association (WSAVA), which should help in interpretation in the future.

### Pathophysiology of acute and chronic liver disease

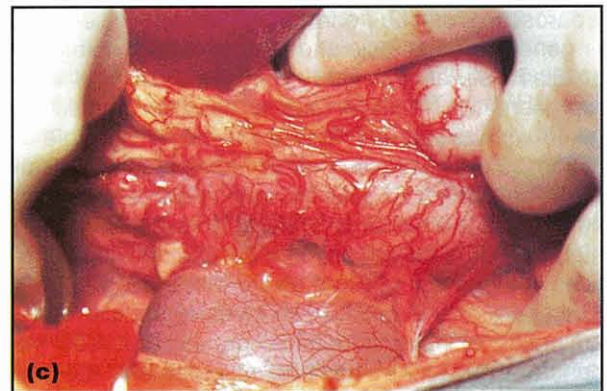
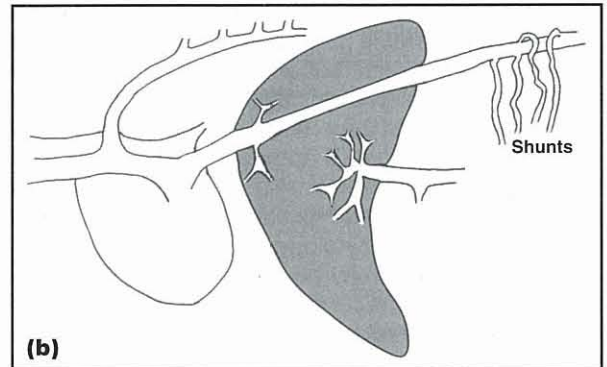
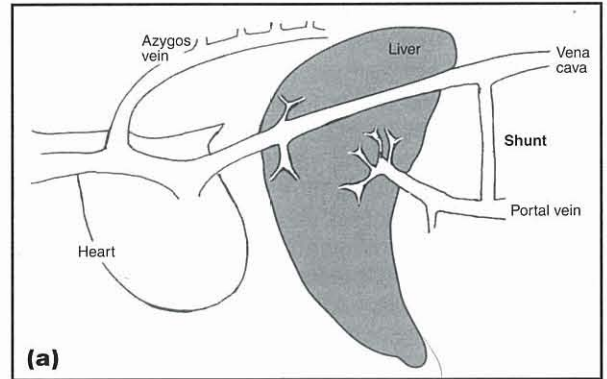
Most acute and chronic liver diseases cause clinical signs as a result of a combination of the following pathophysiological mechanisms:

- **Loss of liver function:** This may be an acute loss or a chronic, insidious loss. Acute loss of function results in more severe clinical signs than chronic loss as the liver has not had time either to regenerate or to adapt functionally by recruiting hepatocytes in other areas (as described above). Congenital PSS results in loss of liver function by a different mechanism; some portal blood bypasses the liver and the liver atrophies as a result of reduced oxygenation and reduced delivery of trophic factors in the portal blood
- **Biliary stasis:** This may develop in acute or chronic disease as a result of a number of factors including primary biliary tract disease (more common in cats) and parenchymal disease, causing hepatocyte swelling and/or fibrosis obstructing the biliary tract. Stones in the biliary tract are very rare in dogs and cats compared with humans. The pathophysiology of biliary stasis is discussed in detail in Chapters 14 and 25
- **The local and systemic results of the inflammatory process and hepatocyte damage occurring in the liver:** This contributes to the local and systemic release of cytokines and other proinflammatory mediators that contribute to pyrexia, anterior abdominal pain, anorexia and cachexia seen with liver disease and also potentially the development of disseminated intravascular coagulation (DIC). The inflammatory changes are most pronounced in acute or 'acute-on-chronic' hepatitis, i.e. acute exacerbation in a patient with chronic hepatitis
- **The development of portal hypertension:** This often occurs in chronic hepatitis in dogs but rarely in cats. It may also develop in acute hepatitis in both dogs and cats owing to acute hepatocyte swelling. Portal hypertension reflects either increasing resistance to flow of blood through the liver as a result of fibrosis and contraction of stellate cells in chronic disease (see below), or hepatocyte swelling or infiltration in acute disease. Typical clinical signs develop as portal pressure rises:
  - Ascites develops as hydrostatic pressure rises downstream of the portal vein in the splanchnic venous bed. The pathophysiology of ascites formation is discussed in Chapter 13.

The mechanisms behind the formation of portal hypertension-associated ascites are rather different from the mechanisms involved in right-sided heart failure and thus the treatment is also rather different. The ascites in portal hypertension is worsened by activation of the renin-angiotensin-aldosterone system (RAAS) as a result of splanchnic pooling of blood reducing systemic blood pressure. Hence, aldosterone antagonists are often the most effective diuretics to use in this type of ascites (see below)

- GI wall congestion and oedema followed by ulceration or a high-risk of ulceration with any additional trigger factor (such as corticosteroid therapy). Bleeding GI ulcers may cause haematemesis and melaena, and the blood lost into the gut may precipitate or worsen hepatic encephalopathy
- Development of acquired PSSs. These typically develop with chronic liver disease in dogs, but are quite rare in cats. They develop with sustained portal hypertension when portal pressure is consistently higher than the pressure in the caudal vena cava. Multiple vessels open up as 'escape valves' between the portal vein and caudal vena cava. These acquired shunting vessels are often recognized grossly at surgery as a fine network of small vessels near the right kidney (Figure 24.14). They perform an important role, protecting the hepatocytes and gut wall from the worst effects of sustained portal hypertension, and attempts at ligation are completely contraindicated.
- Finally, in addition, many of the pathophysiological consequences of chronic liver disease in dogs occur as a result of progressive, damaging and permanent **fibrosis**. Acute hepatic injury is potentially completely reversible provided the limiting plate is not disrupted and the source of injury is not ongoing. However, if the injury is severe and/or ongoing, the liver will respond by laying down fibrous tissue. This represents a 'final common pathway' to a variety of insults and is analogous to the wound-healing response in other tissues.

The hepatic stellate cell (otherwise known as an Ito cell or lipocyte) is central in the development of fibrosis. Stellate cells are located in the space of Disse between the sinusoidal endothelial cells and the hepatocytes (see Figure 24.2). In the normal liver, they are the major storage site of vitamin A. They also synthesize extracellular matrix components, matrix metalloproteinases, cytokines and growth factors. In chronic hepatic injury they undergo a major phenotypic transformation to collagen-secreting, proliferating activated lipocytes, which lose their usual content of vitamin A, become contractile and secrete high-density matrix and collagen into the space of Disse. Cirrhotic liver contains approximately six-times more extracellular matrix than



**24.14** Portosystemic shunts. (a) Diagrammatic representation of a congenital portosystemic shunt. (b) Multiple acquired shunts develop if the pressure in the portal vein is greater than the pressure in the vena cava. (c) Gross appearance of acquired portosystemic shunts joining the caudal vena cava in the region of the right kidney. (Photography by Bryden Stanley.) (Reproduced from Watson (1997) with permission from *In Practice*.)

normal liver. Changes in activation and inhibition of zinc-dependent matrix metalloproteinases are also important to the balance between fibrogenesis and hepatic recovery, and the stellate cells are intimately involved in these changes. Their contractile nature, when activated, contributes to the pathogenesis of intra-hepatic portal hypertension by altering sinusoidal tone and blood flow. In addition to being activated, stellate cells are stimulated to proliferate and migrate to points of injury. This can be obvious in liver samples from dogs with early chronic liver disease where an increase in the number of stellate cells can often be noted histologically before any obvious fibrosis. This is an ominous sign, signalling impending fibrosis.

In most cases of chronic liver disease in dogs, stellate cells are stimulated indirectly via the release of cytokines from inflammatory cells, particularly neutrophils, lymphocytes, platelets and necrotic hepatocytes. Kupffer cells are an important source of these inflammatory mediators in humans, but their role in dogs is unclear. Some substances can act directly on stellate cells to stimulate fibrosis, but this is very unusual in small animals (unlike in humans where acetaldehyde, the first metabolite of ethanol, can activate stellate cells directly so contributing to the development of alcoholic cirrhosis). Oxidant stress and the release of lipid peroxides play an important role in the stimulation of cytokine release from inflammatory cells and hepatocytes. In biliary stasis, damage to mitochondrial membranes by bile acids contributes to this oxidant stress.

'Early' fibrosis in hepatic connective tissue does not disrupt the hepatic architecture. This tends to progress to involve more of the liver, bridging between the portal tracts and progressing to cirrhosis, which is defined as progressive bridging fibrosis, inflammation and nodular regeneration. Traditionally, it has been believed that 'early' fibrosis is potentially reversible whereas more chronic, bridging fibrosis and cirrhosis are not reversible. However, recent work in humans has indicated that even cirrhosis may be reversible if the underlying cause is removed. Effective reversal of cirrhosis has not yet been achieved in dogs.

### Acute liver disease

Acute hepatitis describes a spectrum of disease from mild to severe, fulminating and life-threatening. It is a poorly described and investigated condition in small animals and most of the treatment recommendations are extrapolated from human medicine. Mild forms of acute hepatitis are relatively common in dogs and cats but often unrecognized.

The causes of acute hepatitis are outlined in Figure 24.7. Fortunately, most cases of acute hepatitis are focal and patchy, resulting in mild or subclinical disease. These cases usually do not show clinical signs, except those referable to the underlying cause, so the liver disease is usually unrecognized. Elevated liver enzyme activities in blood samples may be the only indication that the liver is involved. These animals may recover completely or may develop chronic hepatitis. In contrast, severe fulminating acute hepatitis is a serious disease with marked clinical signs and a generally poor prognosis. Some animals go on to complete recovery but may require intensive supportive care. Fortunately, acute fulminant hepatitis is rare in small animals.

### Clinical signs

The classical clinical signs of severe fulminating hepatitis are outlined in Figure 24.10. The most clinically significant are usually: acute hepatic encephalopathy due to acute loss of hepatic detoxifying function with resultant rapid build-up of blood ammonia and other encephalopathic toxins; acute GI signs, often with melaena and haematemesis; and coagulopathies associated with sudden loss of hepatic function and also

triggering of the coagulation cascade and DIC. Additional clinically serious complications that can occur with acute hepatitis in humans are outlined in Figure 24.10, but these have not been reported to date in dogs or cats.

### Clinicopathological tests

Clinicopathological testing in acute hepatitis typically shows an early, marked elevation in hepatocellular enzymes (ALT and AST) followed by slightly later elevations in ALP, bilirubin, bile acids and often ammonia. Hypoglycaemia and hypokalaemia are common, and some dogs develop pre-renal or renal azotaemia. Coagulopathies with both prolonged clotting times and reduced platelet counts are not uncommon.

### Treatment

Treatment of acute fulminant hepatitis is largely supportive and is outlined in Figure 24.15. It should be noted that steroid therapy is not indicated in these cases; in fact, steroid therapy can potentially worsen the disease for the reasons outlined in Figure 24.16. Acute hepatitis results in only temporary disruption of hepatic structure and function. Provided the insult is not ongoing and that the limiting plate remains intact and destruction of hepatic architecture is not extreme, there is the potential for complete recovery. The challenge is to support the animal through the acute crisis while awaiting recovery, which is possible even if 50% of the liver is destroyed. However, there is no effective 'liver dialysis', even in humans, so too great a loss of vital hepatic functions results in death, in spite of intensive care. It is difficult to predict the outcome as some animals show improvement only to deteriorate again. Development of marked portal hypertension with ascites and splenomegaly is a poor prognostic indicator in humans. Some animals go on to complete recovery with no permanent histological lesions, whereas others develop chronic hepatitis, cirrhosis and fibrosis. An experimental study of acute toxic hepatitis in dogs suggested chronic lesions were less likely to develop if the dogs were fed a single-protein milk or soy-bean based diet on recovery than if they were fed an ordinary commercial dog food.

### Acute (suppurative) cholangitis

This disease is centred on the biliary tract and is discussed in Chapter 25.

### Hepatitis caused by drug toxicity

Many drugs can result in hepatotoxicity in dogs and cats by either dose-related or idiosyncratic mechanisms. Most cases of drug toxicity result in acute hepatitis, although this can progress to chronic hepatitis with fibrosis and cirrhosis, particularly when the drug is administered chronically, as for example with anticonvulsants such as phenobarbital. Three important potentially hepatotoxic drugs are outlined below. However, it is important not to assume drug toxicity in every dog or cat with raised liver enzymes. Surveys in humans have shown that drug reactions are over-diagnosed resulting in unnecessary withdrawal of therapeutically important drugs. In cases where there is doubt, a liver biopsy is important in confirming toxicity.

Specific treatment of cause if known: e.g. remove drugs implicated; N-acetylcysteine for paracetamol toxicity (also consider cimetidine, see below)  
 Nil by mouth 1–3 days then exclusion diet based on dairy protein or soy protein. Additional anti-oxidant support during recovery may also be helpful, particularly for toxic liver damage where glutathione depletion is very significant; vitamin E and S-adenosylmethionine (see Chapter 28 and Appendix 1)

**Intravenous fluid support given carefully:**

Dextrose saline usually best but patient often hypokalaemic, so measure potassium and add to fluids as necessary. (Note low potassium precipitates hepatic encephalopathy, HE). Some animals may also be hypophosphataemic, so measure and supplement as necessary  
 Measure blood glucose every few hours initially; often becomes low in acute hepatitis. Needs urgent supplementation when necessary or results in permanent brain damage  
 Generally use a peripheral catheter and monitor rate and renal output carefully; ensure adequate reversal of dehydration and urine output, but do not over-infuse or may worsen ascites. Humans with acute hepatic failure are also susceptible to cerebral oedema, which is made worse with over-infusion. Consider measuring central venous pressure but see note on jugular catheters below. Consider indwelling urinary catheter if checking adequate urine output, but note higher risk of ascending infections of urinary tract so only use if necessary. Consider furosemide boluses and dopamine if renal shutdown but carefully monitor blood potassium levels  
 Only use jugular catheters once happy that coagulation status is OK; potential for severe, life-threatening bleeding around jugular catheter, which might go unnoticed  
 Observe strict asepsis around all catheters because of increased susceptibility to infections  
 Most dogs with acute hepatitis have metabolic acidosis and some have concurrent respiratory acidosis in the later stages of the disease. However, avoid bicarbonate therapy unless essential and closely monitored as alkalosis will worsen HE

**Treat coagulopathy as necessary:**

Consider fresh frozen plasma to replenish clotting factors as necessary. No evidence additional heparin useful  
 Consider vitamin K therapy (see Appendix 1)

**Treat acute HE: (see Chapter 15)**

Check blood glucose and potassium levels regularly  
 Consider propofol infusions. Avoid barbiturates  
 Consider lactulose enemas

**Treat any GI ulceration:**

Consider H<sub>2</sub> blockers: ranitidine in most cases; cimetidine only in selected toxicities, e.g. paracetamol toxicity, where beneficial to inhibit hepatic cytochrome P450 system  
 Consider sucralfate once taking food by mouth  
 Consider metoclopramide if intractable vomiting

**Treat any ascites with spironolactone ± furosemide**

**Antibiotics:**

Consider use either in all cases (to protect against infectious complications and to inhibit gut flora to reduce HE) or reserve for cases with pyrexia and other evidence of infectious complications.  
 Use broad spectrum agents safe for use in liver disease (see Figure 24.16)

**24.15** Outline of treatment recommendations for acute fulminating liver disease in dogs and cats. (Many of these recommendations are extrapolated from humans and are supportive only; very few specific treatment recommendations are known in small animals.)

Drug type	Examples
Drugs requiring hepatic metabolism	Increases half-life so should lengthen dosing interval – in practice often reduce the dose (e.g. metronidazole reduced from 10mg/kg q12h to 7.5 mg/kg q12h)
Drugs stimulating hepatic enzymes	Cimetidine Phenobarbital
Drugs inhibiting hepatic enzymes	Macrolides Lincosamides Chloramphenicol
Drugs increasing complications of hepatic disease	Corticosteroids increase water retention (ascites) and risk of GI ulceration in portal hypertension. Also increase potential for hepatic encephalopathy to develop by increasing body protein catabolism. Also reduce immune function in already compromised individuals Consider protective measures, i.e. use sucralfate if using steroids in portal hypertension
Drugs potentially hepatotoxic	Potentiated sulphonamides Tetracycline Azathioprine Diazepam in cats Primidone Carprofen

**24.16** Types of drugs which should be avoided or used with care in liver disease.

### Potentiated sulphonamides

Potentiated sulphonamides can cause a variety of adverse reactions by both dose-related and idiosyncratic mechanisms. Although these reactions are not common, they account for the majority of reactions to antimicrobials in dogs. Sulphonamide-associated adverse reactions appear to be much more common in dogs than cats.

One of the manifestations of sulphonamide hypersensitivity is acute hepatopathy. This is linked with a poorer prognosis than sulphonamide-associated adverse reactions without associated hepatopathy. It can occur after as little as 5 days of treatment and is an idiosyncratic, not dose-related, phenomenon. Dogs usually present with acute hepatic necrosis, which may also be associated with marked cholestasis or marked lymphoplasmacytic inflammation. Clinical signs and treatment are as for other cases of acute hepatitis and the drug must be withdrawn immediately. In addition, it has been suggested that *N*-acetylcysteine (a glutathione precursor) is helpful. One author also suggests intravenous ascorbate in these cases (30 mg/kg i.v. q6h) because it can reduce nitroso metabolites of sulphonamides.

### Phenobarbital in dogs

Chronic phenobarbital administration has been associated with an acute hepatic necrosis and also chronic hepatitis and cirrhosis in a small number of dogs. Toxicity is uncommon but hepatic enzyme induction is very common, so the challenge in treated dogs is to differentiate normal enzyme induction from hepatotoxicity. The main differences are outlined in Figure 24.17.

In a normal animal, phenobarbital induces cytochrome P450 enzymes and causes enlargement of hepatocytes by swelling of the endoplasmic reticulum. This in itself is not pathological. The potential for hepatotoxicity may be increased by concurrent medication with other drugs requiring hepatic metabolism, so this should be avoided if at all possible. In addition, the diet fed also appears to affect phenobarbital

pharmacokinetics with low protein diets reducing the half-life and increasing the ALP level. It is therefore important to monitor blood concentrations regularly during therapy and adjust dose levels accordingly and not just empirically. Most dogs developing hepatotoxicity with phenobarbital have serum concentrations at, or above, the top end of the therapeutic range and have been on the drug for at least 5 months. If seizures are not adequately controlled at a high blood concentration of phenobarbital it is advisable to add in a second drug which does not require hepatic metabolism, such as potassium bromide or gabapentin (the latter is not licensed for use in animals) rather than to increase the dose of phenobarbital yet further.

The ideal treatment for phenobarbital toxicity would be to withdraw the drug, but in many cases this is not possible without a recurrence of seizures. In these cases, a reduction in dose rate and combination with another drug as described above is indicated. Reductions in phenobarbital dose of between 25% and 100% has been shown to be sufficient to resolve toxicity in most cases. In addition, *S*-adenosylmethionine has a particular indication in phenobarbital toxicity where it appears to be hepatoprotective as it is a precursor for anti-oxidant and detoxifying systems in the liver (see Chapter 28 and Appendix 1).

A different sub-set of dogs with phenobarbital toxicity apparently presenting as superficial necrolytic dermatitis (hepatocutaneous syndrome) in the absence of other signs of hepatic failure has been reported. The liver of these dogs appear very different, both on gross and ultrasound examination, from those of dogs with phenobarbital-induced hepatitis. There are nodular zones of normal hepatic tissue surrounded by areas of collapsed parenchyma, visible as the 'Swiss cheese' appearance on ultrasonography that is also typical in other causes of hepatocutaneous syndrome. The mechanism for phenobarbital-induced superficial necrolytic dermatitis is unknown but it may be due to induction of excessive amino acid metabolism in the liver and thus peripheral (skin) deficiency.

Parameter	Changes with uncomplicated phenobarbital therapy	Evidence of potential hepatotoxicity
Clinical signs	Sedation, ataxia and polyphagia normal side-effects at high doses	All dogs developing hepatotoxicity initially show sedation and ataxia, followed by signs of acute or chronic hepatitis (not all signs in all cases): anorexia, jaundice, ascites, coagulopathy
Liver size and shape (grossly and on radiography)	Enlarged with smoothly rounded border	Enlarged (acute toxicity) or small (chronic toxicity) often with irregular border
Liver appearance on ultrasonography	As above. No change in echogenicity	As above. May be diffusely increased or normal echogenicity
Hepatic enzyme changes	Typical of enzyme induction: mild to moderate increases in alkaline phosphatase and alanine aminotransferase, transient increase in gamma-glutamyl transferase	Typical, acute or chronic hepatitis: in addition to increase in alkaline phosphatase, alanine aminotransferase and aspartate aminotransferase may become more markedly increased
Hepatic function tests	Normal albumin (may be transiently reduced at start of therapy), normal bilirubin and normal bile acids	Most have low albumin, increases in bilirubin and postprandial $\pm$ preprandial bile acids or ammonia

**24.17** Clinical, clinicopathological and diagnostic imaging findings, which help to differentiate uncomplicated phenobarbital-induced enzyme induction from hepatotoxicity.

### Diazepam in cats

Diazepam has the potential to cause an acute, fulminant hepatic failure in cats with a high mortality. This is uncommon but, because of its seriousness, it is advisable to avoid the use of diazepam in cats as much as possible, particularly chronic use. All reported cases had been receiving diazepam orally for at least 5 days with total daily doses ranging from 1.0–2.5 mg. Unlike phenobarbital, diazepam does not induce hepatic enzymes in normal animals. Therefore, a key finding in affected cats is a sudden dramatic increase in hepatic enzymes, particularly ALT, which is markedly elevated. Other clinical and clinicopathological findings are typical of acute hepatic failure. Treatment involves immediate and complete withdrawal of the drug and aggressive intensive support as outlined in Figure 24.15. However, the prognosis is very poor.

### Hepatic lipidosis

Hepatic lipidosis may occur in both cats and dogs but is most clinically significant in cats. It may result in acute or chronic liver disease, but idiopathic lipidosis in cats usually causes an acute loss of liver function that is potentially reversible with appropriate therapy. Not all accumulations of lipid in hepatocytes are associated with significant primary liver disease and it is important to differentiate:

- Primary (idiopathic) hepatic lipidosis: a disease of cats seen most commonly in North America, although it is recognized in the UK. There is no reported breed or gender predisposition but indoor cats are particularly affected. It causes a high mortality unless treated aggressively. It is most commonly recognized in previously obese cats which have become anorexic, and for this reason obese cats should be monitored closely during weight loss, and nutritional support given to any cat with severe anorexia whatever the cause
- Secondary hepatic lipidosis: common in both cats and dogs as a reaction pattern to a number of other diseases including diabetes mellitus, pancreatitis, IBD and primary hyperlipidaemia. In dogs this lipidosis is usually not clinically significant in itself. In severely anorectic cats it can become life-threatening in its own right. In these cases, intensive management of both lipidosis and the underlying (or concurrent) disease is required. Secondary lipidosis is the commonest form of feline hepatic lipidosis recognised in the UK, and such cats are often thin.

### Pathogenesis

The pathogenesis of primary hepatic lipidosis in cats remains poorly understood but appears to involve a combination of:

- Excessive peripheral lipid mobilization, particularly during anorexia, illness or stress. This may be mediated by adrenergic stimulation and other neuroendocrine responses, but peripheral insulin resistance does not appear to play a primary role
- Deficiency of dietary proteins and other nutrients, resulting in reduced hepatic production of lipid

transport proteins and reduced hepatic metabolism of fat. Specific nutrient deficiencies suggested to be important include arginine, methionine, carnitine and taurine. The cat is uniquely susceptible to these deficiencies because of its obligate high resting protein catabolism and specific dietary requirements

- Studies have also suggested disturbances in regulation of appetite in affected cats resulting in inappropriate anorexia. This is likely to be due to disturbances in the complex neurohormonal control of appetite.

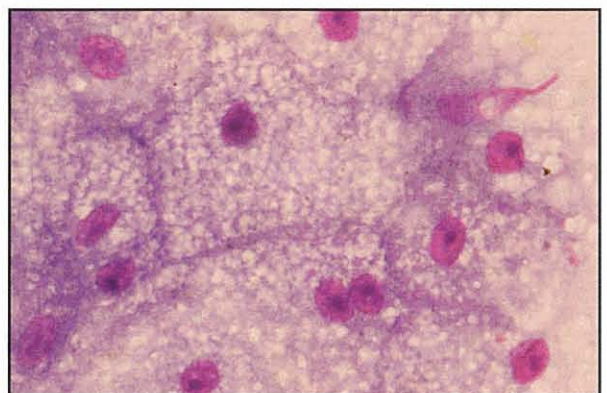
Cats with severe hepatic lipidosis suffer an acute loss of hepatocyte function due to hepatocyte swelling in a similar way to an animal with diffuse hepatic lymphoma; this acute loss of function is serious but potentially reversible if the condition is treated effectively.

### Clinical signs

The clinical signs are related to the acute loss of hepatic function together with hepatocyte swelling causing intra-hepatic cholestasis. Affected cats typically become markedly jaundiced and show hepatic encephalopathy (see Chapter 15) usually manifesting as anorexia and marked depression. Coagulopathies may also develop.

### Diagnosis

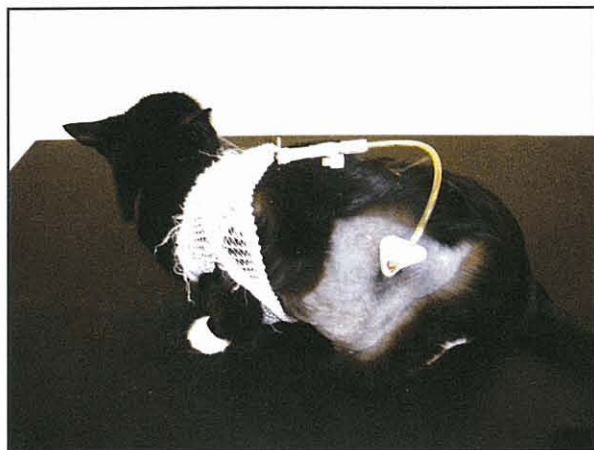
The diagnosis involves demonstration of hepatocytes swollen with lipid, together with ruling out any underlying cause as far as possible (although this should not delay treatment of the lipidosis). Fine needle aspirates of the liver are often sufficient for a diagnosis, avoiding the need for liver biopsy in a very sick cat. It is important to differentiate mild to moderate lipid accumulation in hepatocytes from severe lipidosis on cytology (Figure 24.18) Blood results reflect marked hepatocellular dysfunction and cholestasis with marked elevation of hepatocellular and biliary enzymes and of bilirubin. A hallmark of hepatic lipidosis in cats is a very high ALP level with a disproportionately low gamma-glutamyltransferase (GGT) concentration. Affected cats usually have marked hepatomegaly on radiography and a characteristic ultrasonographic appearance to the hepatic parenchyma (see Chapter 3).



**24.18** Cytological appearance of severe hepatic lipidosis in a cat. Note the great accumulation of fat globules in the hepatocytes. Giemsa stain; original magnification x1000. (Courtesy of Elizabeth Villiers)

### Treatment

The treatment of hepatic lipidosis relies on intensive feeding (Figure 24.19). This is the most significant factor in reducing the mortality in these cases and should be instituted as soon as possible.



**24.19** Cat with hepatic lipidosis and gastrostomy tube in place.

- Treat any identifiable underlying cause as effectively as possible.
- Combine this with nutritional support via a gastrostomy or oesophagostomy tube as feeding will be necessary in most cases for 4–6 weeks (see Chapter 27 for tube placement). A naso-oesophageal tube can be used for temporary support prior to general anaesthesia for more permanent tube placement. A high-quality diet with unrestricted protein should be given, while attempting to manage signs of hepatic encephalopathy by other means (see Treatment for more details). This means using a diet manufactured for nutritional support of hypermetabolic sick cats if possible. Some authors add extra nutrients such as taurine, arginine, B vitamins or carnitine to commercial diets, but there is no evidence that supplementation of any of these nutrients is beneficial.
- Anti-emetics and prokinetic agents, such as ranitidine and metoclopramide may be necessary if the cat is vomiting or has delayed gastric emptying with reflux of food up the feeding tube (see Chapter 27).
- Affected cats also need intravenous fluid support in the early stages of therapy and careful monitoring of blood glucose and electrolytes, particularly potassium and phosphate, which may become low and require supplementation (see Figure 24.15). There is no evidence that adding insulin to the fluids is beneficial, and it should be avoided since it increases the risk of hypokalaemia and hypophosphataemia. After the first few days, fluid and electrolyte balance can usually be maintained by enteral nutrition alone.
- Parenteral vitamin K may be required if there is a coagulopathy.

Treatment of the underlying cause alone in secondary cases will not lead to resolution of lipidosis in most patients, and anorexia will persist unless active feeding is initiated.

Intensive treatment of hepatic lipidosis in cats is worthwhile because it greatly increases the chance of successful treatment and, although it is a potentially fatal disease, there are no reported long-term sequelae when cats recover.

### Chronic liver disease

The causes of chronic liver disease in dogs and cats are outlined in Figures 24.5 and 24.6. The most common cause of chronic liver disease in dogs is chronic hepatitis. The pathophysiology of all forms of chronic hepatitis in dogs is similar in that most cases progress to fibrosis and cirrhosis as an end-stage. However, the underlying cause of the disease is almost always unknown, which contrasts markedly with the situation in humans where the cause of chronic hepatitis is often known and is usually either viral or toxic (alcohol). Cats differ from dogs in that the most common chronic liver disease, at least in Europe, is chronic lymphocytic cholangitis (see Chapter 25). Hepatic copper accumulation is common in hepatopathies in some specific breeds of dog. Congenital vascular disorders, particularly congenital PSSs, are relatively common in dogs but less so in cats. The liver is also frequently involved in primary or secondary neoplasia in both species.

### Copper storage disease in Bedlington Terriers

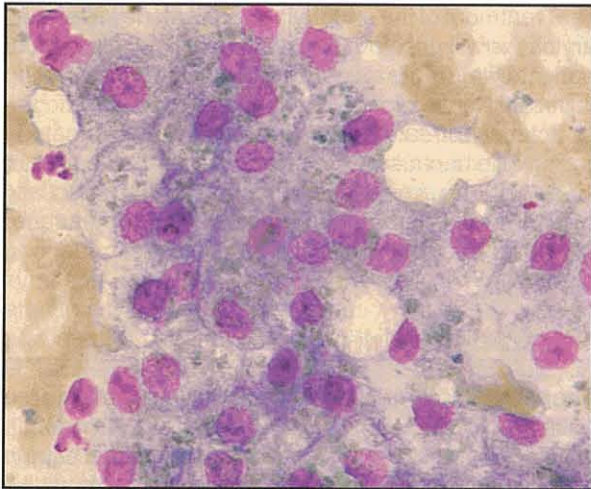
Copper storage hepatopathy in the Bedlington Terrier (Figures 24.20 and 24.21) is the most well understood chronic liver disease in dogs. It is inherited as an autosomal recessive trait and up to 60% of Bedlington Terriers in some countries have been affected in the past, although the incidence is reducing with genetic testing and selective breeding. As few as 11% of Dutch dogs are now affected with the disease.

Affected dogs show progressive pathological accumulation of copper in the lysosomes in their hepatocytes starting in zone 3 (perivenous). It is clearly a primary



**24.20** Bedlington Terrier with copper storage disease.





**24.21** Copper granules in the hepatocytes of a Bedlington Terrier with copper storage disease. Giemsa stain; original magnification x1000. (Courtesy of Elizabeth Villiers)

copper storage disease and is distinguished from most other ‘copper-associated’ hepatopathies in other breeds by the fact that the copper is primary to the disease process, as outlined in Figure 24.22.

Bedlington Terrier copper storage disease is caused by a specific defect in hepatic biliary copper excretion, probably in transport from the hepatocyte lysosomes to the biliary tract, that is an inherited trait. This was originally thought to be due to a defect in hepatic metallothionein, but recent work has identified the gene involved as the *MURR1* gene. *MURR1* codes for a protein of unknown function. Whether mutation of *MURR1* is the only cause of Bedlington Terrier copper storage disease remains to be confirmed as there are some inconsistencies between the localization of the previously reported microsatellite marker within the gene and reported recombination events.

The usual course of the disease in homozygous Bedlington Terriers depends on their dietary copper level and other stresses. It is outlined below:

- Young dogs progressively accumulate hepatic copper. If the build-up is marked and rapid, and

accompanied by an additional stress, they may develop acute fulminant hepatic necrosis with no previous signs. This is usually seen in young middle-aged dogs, and is often accompanied by acute haemolytic anaemia due to the rapid release of copper into the circulation. The prognosis is poor and most animals die within a few days. Fortunately, this is rare

- Most dogs have a more chronic course characterized by:
  - Early increases (1–2 years old) in copper in hepatic lysosomes (visible with rhodamine staining) and persistent elevations in ALT, but no structural changes
  - Later, focal to random areas of hepatic necrosis develop, usually before 3 years of age. Elevations in ALT persist but there are no clinical signs
  - Chronic hepatitis develops with piecemeal necrosis, inflammation and bridging fibrosis, usually before 5 years of age. Elevations in ALT persist and late in this stage clinical signs may develop
  - Chronic hepatitis progresses to cirrhosis, usually in dogs older than 3 years.

Notably, heterozygotes may have a transient (and clinically unimportant) increase in hepatic copper concentrations peaking at 7–9 months old and returning to normal at 9–14 months old. This is reflected in diagnostic recommendations (see below).

**Diagnosis:**

There are two groups of dogs to consider for diagnosis:

- Identification of affected and carrier dogs as young as possible so that measures can be taken to prevent progression of disease, and breeding recommendations can be made before hepatic damage ensues
- Diagnosis of copper storage disease as the cause of clinical signs in an older dog and formulation of a treatment plan with the knowledge that severe hepatic damage may already be present.

Copper toxicosis in the Bedlington Terrier	Copper-associated liver disease in many other breeds
Copper builds up progressively throughout life	Copper levels do not build up progressively throughout life
The amount of liver damage is related to the degree of elevation of hepatic copper	The amount of liver damage is not related to the degree of elevation of hepatic copper and dogs may show marked hepatitis with minimal copper build-up. Copper build-up therefore appears to be an epiphenomenon with another cause and not a primary event
Copper builds up in zone 3 (perivenous) and bile copper levels are low, suggesting a primary problem with transport in to bile	Copper builds up in zone 1 (periportal) and bile copper levels are normal, which may suggest copper build-up is secondary to cholestasis
Early treatment with low copper diet and zinc, copper chelators later; but monitor for copper deficiency if chelators used for years	May use low copper diet and zinc. Use of copper chelators controversial. Probably unnecessary and may result in copper deficiency

**24.22** Differences between primary copper storage disease and secondary copper deposition in canine chronic liver disease.

**Identification of affected dogs as young as possible:**

- Genetic tests are the ideal way of identifying affected dogs as young as possible, and should help in preventing affected dogs being bred from in the first place by careful selection of the parent.
  - **Screening for the specific gene defect** (*MURR1*) would be ideal and should be most accurate. A test based on reverse transcriptase polymerase chain reaction (PCR) of RNA obtained from cheek swabs is now commercially available in the UK. However, there are currently technical problems with the test meaning re-sampling and retesting are often necessary.
  - **Screening using a microsatellite marker** CO4107 was until recently the only commercially available genetic test. This detects not the gene itself but a genetic marker either near or within the gene. In order to avoid a false-positive or false-negative result the test needs to be interpreted in the light of an 'informative pedigree' with at least one histologically confirmed case in the pedigree.
  - **Histological tests** are more invasive but currently more readily available, and are required from some cases in the pedigree for correct interpretation of microsatellite marker blood tests (see above).

**Diagnosis in older animals with disease:**

- If a Bedlington Terrier has persistent elevated ALT levels, even with no clinical signs, this is very suspicious and a liver biopsy is advisable. Feeding a copper-restricted diet to which zinc supplements are added should be initiated (see below)
- If a Bedlington Terrier shows acute disease and haemolysis there will be anaemia and haemoglobinuria
- Liver biopsy samples (expressed as micrograms of copper per gram of liver, on a dry matter basis) are interpreted as follows:
  - Copper levels <350 µg/g are normal and >1000 µg/g are definitely abnormal.
  - If copper levels are >350 µg/g but <2000 µg/g, and there are structural changes, it is significant. The dog is probably homozygous and should be treated with a copper chelator and dietary management
  - If copper levels are <2000 µg/g, there are no structural changes and the dog is <1 year old, it may be a heterozygote (almost all heterozygotes actually have copper levels <800 µg/g). Therefore, feed a copper-restricted diet and repeat the biopsy at 14–15 months old. If the copper level is the same or reduced, it is a heterozygote; if it has an increased level, it is a homozygote and administration of a copper chelator should be considered

- A copper level >2000 µg/g will cause lysosomes to rupture, resulting in structural liver damage. This is always significant and requires institution of copper chelation therapy.

Note that the ideal time to perform a liver biopsy is around 12 months of age since by this time the copper will have built up to diagnostic levels in the liver, but the dog will not have developed chronic changes. Results from samples from older animals should be interpreted carefully since, if there is cirrhosis, the copper distribution becomes uneven with lower concentrations in regenerative nodules. It is also possible to make a qualitative (but not quantitative) diagnosis using cytology of fine needle aspirates of the liver. This is less invasive than liver biopsy so could be useful in a symptomatic patient, but is less appropriate for screening purposes (see Figure 24.21).

**Treatment**

Appendix 1 provides details of drug dosages.

**Preventive in young animal:**

- Feed a low copper diet with increased dietary zinc (see Figure 24.25). This will prevent further copper accumulation but will not effectively 'de-copper' the liver. Clinical diets designed for canine liver disease are low in copper and have increased zinc levels, but they are also restricted in protein and so inappropriate for growth. Avoid tap water in soft water areas with copper pipes. Avoid high copper foods, particularly shellfish, liver, kidney, hearts, cereals, chocolate and legumes
- Additional anti-oxidants such as S-adenosyl-methionine (SAME) and vitamin E are helpful
- If copper levels in the liver are high or rising at diagnosis, consider chelation with penicillamine or 2,2,2-tetramine, but once successfully chelated, return to dietary and zinc therapy alone.

**Acute crisis:**

- Intensive treatment as for acute hepatitis (see Figure 24.15). Blood transfusion may be necessary if haemolysis is severe
- Consider chelation with 2,2,2-tetramine (or 2,3,2-tetramine if obtainable) because this can chelate rapidly. Penicillamine is not helpful in an acute crisis as chelation takes weeks to months
- On recovery, go on to long-term treatment as outlined below.

**Chronic hepatitis:**

- Copper chelation if levels are high or rising
- Feed a low copper diet with added zinc
- Consider other treatments for chronic hepatitis, including anti-oxidants. Avoid use of antifibrotics, such as colchicine concurrently with copper chelators as there are anecdotal reports of drug interactions causing side-effects.

Copper is an essential trace element and small amounts are required even in animals with copper storage disease. Copper deficiency characterized by microcytic anaemia and GI ulceration have been reported in a dog which was overzealously chelated for years with 2,2,2-tetramine. Therefore, copper chelation should be used only when required and patients should be monitored carefully. It should not be used in heterozygotes or other breeds without well defined copper storage disease.

**Copper storage disease in other dog breeds**

Very recently, a copper-associated hepatitis has been reported in a number of young Dalmatians in the USA and Canada, which may share some similarities with the Bedlington Terrier disease, and may represent a primary metabolic defect in hepatic copper metabolism. The Dalmatian disease is associated with acute onset, rapid progression and very high levels of hepatic copper in the absence of significant clinical, clinicopathological or histological evidence of cholestasis. However, it has not been possible to define the zonal distribution of copper in the cases reported to date because of the extensive hepatic necrosis, fibrosis and disrupted architecture. Affected dogs usually present as young adults with acute onset of GI signs and polyuria/polydipsia, by which time severe liver disease is already present. There is marked elevation in ALT levels and more modest elevations in AST and ALP levels. Jaundice develops later in some dogs, and albumin may be mildly to markedly reduced. The prognosis appears to be poor, even with treatment. The disease has been recognized in litter mates suggesting that it might be inherited.

Other 'copper-associated' hepatopathies reported in a variety of breeds share some similarities with Bedlington Terrier copper storage hepatopathy, but also have some important differences. Copper-associated hepatopathies have been reported in Skye and West Highland White Terriers but neither of these appears to be a true 'storage disease' as seen in Bedlington Terriers because copper does not accumulate throughout life and the amount of copper stored is not correlated with the severity of underlying disease and/or is not present very early in the disease process (see Figure 24.22). Recent work suggests that copper accumulation may be a primary event in Dobermann hepatitis.

The role of copper in chronic hepatitis in breeds other than the Bedlington Terrier and Dalmatian remains controversial. The current consensus is that copper does not initiate the disease, except perhaps in some West Highland White Terriers, and that copper accumulation is a result of the underlying disease. How much it contributes to ongoing damage once it is there and therefore whether breeds other than Bedlingtons, Dalmatians and some West Highland White Terriers should be given copper chelation therapy is currently unknown.

**Canine chronic hepatitis**

The term 'chronic hepatitis' describes hepatic mononuclear or mixed inflammatory infiltrate with piecemeal necrosis and varying degrees of fibrosis, combined with clinical or biochemical evidence of hepatocellular dysfunction without improvement for at least 4–6 months. Typically, the inflammation in both human and canine chronic hepatitis affects zone 1 of the hepatic acinus (portal area), although this may not always be the case. Fibrosis tends to progress to cirrhosis, but this is not inevitable. Cirrhosis describes progressive bridging fibrosis, inflammation and nodular regeneration, which has classically been considered end-stage and irreversible.

It is very important to realize that more than one aetiology can give the same clinical appearance and results on clinical pathological testing and liver biopsy. More specifically, infections with viruses or bacteria, such as *Leptospira*, can result in a lymphoplasmacytic infiltrate and many might be misinterpreted as 'immune-mediated disease' but clearly these cases should not receive immunosuppressive therapy.

**Aetiology**

Chronic hepatitis frustratingly usually remains a non-specific diagnosis in dogs and the cause is generally unknown. The potential causes of canine chronic hepatitis are outlined in Figure 24.23.

Chronic hepatitis is recognized in a wide variety of dog breeds including mixed-breed animals. However, reviews of chronic hepatitis in dogs show consistently increased incidences in certain specific breeds as summarized in Figure 24.23. Middle-aged dogs of a number of breeds are over-represented, including American and English Cocker Spaniels (dogs more than bitches), West Highland White

Potential cause	Breeds or types of dogs where it might be seen	Notes on diagnosis and histological appearance
<b>Unrecognized bacterial infections:</b> atypical <i>Leptospira</i> ; <i>Bartonella</i> ; possibly <i>Helicobacter</i>	May cause some cases of chronic hepatitis in any breed	May be unrecognized as organisms often not seen. Some (but not all) <i>Bartonella</i> infections have distinctive histopathology similar to human peliosis hepatitis. Polymerase chain reaction has been used more recently to help diagnosis
<b>Unrecognized viral infections:</b> chronic adenovirus infection in partially immune dogs; canine acidophil cell virus hepatitis	Canine adenovirus 1 (CAV-1) may cause chronic hepatitis in partially immune dogs (causes acute disease if not immune) but only shown experimentally	CAV-1 in partially immune dogs causes periportal mononuclear infiltrates and progressive fibrosis. In some surviving dogs, the virus is cleared and hepatic changes resolved in similar way to interferon-treated human patients with hepatitis virus. 'Canine acidophil cell hepatitis virus' reportedly causes a chronic hepatitis marked by fibrosis and hepatocyte necrosis but sparse inflammatory change

**24.23** Potential unrecognized causes of 'idiopathic' chronic hepatitis in dogs. Note: most cases of canine chronic hepatitis remain idiopathic. However, the potential causes listed have been suggested and demonstrated to be involved in some cases. Awareness of these potential causes should encourage the clinician to consider them and look for them a little more carefully in clinical cases (see Center (1996a) and Watson (2004b) for more details). (continues) ▶

Potential cause	Breeds or types of dogs where it might be seen	Notes on diagnosis and histological appearance
<b>Potential genetic causes of chronic hepatitis</b>	Chronic hepatitis shows an increased incidence in a number of breeds. Breed-associated canine chronic hepatitis suggests genetic causes but the mechanisms are unknown. There are likely to be different mechanisms in different breeds	Breed-associated chronic hepatitis in Skye Terriers, a proportion of West Highland White Terriers and a proportion of Dobermanns is associated with increased copper build-up which is significant, but distinct from copper-storage disease in Bedlington Terriers and Dalmatians. Breed-associated hepatitis in Cocker Spaniels, and a proportion of West Highland White Terriers and Dobermanns is not associated with increased copper. Cocker Spaniels show a change in hepatic $\alpha$ -proteinase inhibitor subtypes but not a true deficiency of $\alpha$ -proteinase inhibitor
<b>Potential autoimmune forms of chronic hepatitis</b>	Autoimmune disease is often assumed to be the cause of canine chronic hepatitis but it has never been proven and some authors doubt if it exists at all in dogs. It may be involved in some breed-related diseases, particularly with increased incidence in bitches (such as Dobermanns) but more research is needed	Finding lymphoplasmacytic inflammation on histopathology of the liver is not enough alone to diagnose primary autoimmune disease, as a similar histological appearance occurs as the final common pathway of many diseases including viral and bacterial. A number of studies have been performed in dogs looking at liver-associated antibodies and cell-mediated responses, but none answer the question as to whether the observed immune response is the primary cause of the disease or a secondary phenomenon

**24.23** (continued) Potential unrecognized causes of 'idiopathic' chronic hepatitis in dogs. Note: most cases of canine chronic hepatitis remain idiopathic. However, the potential causes listed have been suggested and demonstrated to be involved in some cases. Awareness of these potential causes should encourage the clinician to consider them and look for them a little more carefully in clinical cases (see Center (1996a) and Watson (2004b) for more details).

Terriers (no apparent sex predisposition), Skye Terriers (no apparent sex predisposition), Dobermanns (strong bitch predisposition) and Labrador Retrievers (bitch bias). Increased incidence of chronic hepatitis in certain breeds suggests a genetic basis for their disease. However, studies have failed to elucidate specific genetic mechanisms. It is often assumed that breed-associated chronic hepatitis is autoimmune in aetiology but, in fact, autoimmune hepatitis has so far not been convincingly demonstrated to occur in dogs. A genetic predisposition to chronic hepatitis in a dog breed may have one or more of a variety of potential causes but none of these has yet been proved in dogs.

### Pathophysiology

Diagnosis of canine chronic hepatitis and therapeutic decisions rely very heavily on histological descriptions combined with a basic understanding of the significance of the changes described and the pathophysiology of chronic liver disease, without knowledge of the underlying cause. As discussed above, clinical signs appear late in the disease process in chronic hepatitis because of the liver's large reserve capacity. Signs develop as a result of a combination of the pathophysiological processes: a gradual loss of liver function; progressive fibrosis; biliary stasis; local and systemic inflammatory response; the development of portal hypertension with ascites, GI oedema and ulceration; and hepatic encephalopathy. The typical progression of chronic hepatitis in dogs is a slow, asymptomatic, progressive destruction of liver tissue culminating in an acute onset of clinical signs due to a critical reduction in liver function or the development of portal hypertension or biliary stasis. Clinicopathological abnormalities may be identified long before these clinical signs develop and early treatment may delay or halt progression of underlying disease. The development of clinical signs in a dog with chronic hepatitis indicates that severe, generalized liver disease is already present.

### Diagnosis

**Clinical findings:** Dogs with chronic hepatitis typically present with mild non-specific clinical signs, such as vomiting, diarrhoea, anorexia and polyuria/polydipsia (see Figure 24.11). Jaundice or ascites may develop, especially later in the course of the disease. Hepatic encephalopathy is uncommon until end-stage disease, when acquired PSSs are often present. Weight loss is frequently severe, but affected dogs are often surprisingly bright considering the severity of their disease.

**Clinicopathological findings:** The clinicopathological findings are outlined in Figures 24.12 and 24.13. Most dogs with chronic hepatitis have persistent elevations of ALT and other liver enzymes, although activities may become normal in end-stage disease if there is very little remaining liver tissue. Function tests usually reflect severe hepatic dysfunction and serum bile acids may be elevated due to acquired shunting.

**Diagnostic imaging:** Radiography and ultrasonography often reveal a small hyperechoic liver, although the liver may also look normal in some cases. There may be ascites, and ultrasonography may reveal multiple acquired PSSs.

While all of these findings are supportive of a diagnosis of chronic hepatitis none is specific, even taken in combination: for example, elevated liver enzymes and bile acids, ascites and a small liver may all occur in dogs with idiopathic non-cirrhotic portal hypertension (see below). Without hepatic biopsy, these latter cases may be mistakenly presumptively diagnosed as having cirrhosis and a poor prognosis, whereas idiopathic portal hypertension usually has a better prognosis. Hepatic biopsy is therefore strongly recommended so that unexpected findings are not missed, and attempts can be made to stage the disease and select the most appropriate treatment options (see Figure 24.24).

**Treatment**

Details of therapy are outlined in a section at the end of this chapter and Appendix 1. It is important to initiate therapy as early as possible in canine chronic hepatitis to try to inhibit fibrosis and cirrhosis. The clinical and histological findings to consider when deciding on a treatment regime are outlined in Figure 24.24. While specific and effective measures are not proven for canine chronic hepatitis, even non-specific and supportive treatments may lead to marked improvements in the quality of life.

- A palatable high quality protein diet supplemented with zinc, B vitamins and anti-oxidants should be fed (Figure 24.25). Protein should not be restricted unless essential to control encephalopathy, since many patients are malnourished. Manufactured diets for canine liver disease can be used and supplemented with extra high quality protein, such as cottage cheese or egg. Feed little and often to reduce hepatic work.
- Antifibrotic agents may be helpful. Corticosteroids are most effective but the stage

Question	Response
How much inflammation is there?	If there is significant inflammation without evidence of infection or severe fibrosis, consider steroids
How much fibrosis is there?	If there is marked fibrosis, avoid steroids (too late and also potentially dangerous) but consider colchicine
How badly is the architecture disrupted?	If very badly disrupted by fibrosis, avoid steroids (too late and also potentially dangerous) but consider colchicine
Is there any obvious cause (e.g. copper storage diseases; but interpret significance of copper with caution in breeds other than Bedlington Terriers, Dalmatians and West Highland White Terriers)?	If the cause is obvious, treat it
Is there secondary build-up of iron or copper?	If so, consider dietary management, including reduced copper and increased zinc, and also consider cholereitics to encourage bile flow
Is there histological and/or clinical evidence of cholestasis?	If so, rule out complete obstruction (rare) and consider cholereitics
Is there clinical evidence of portal hypertension ± acquired portosystemic shunts?	Give symptomatic treatment

**24.24** Decision-making in the management of canine chronic hepatitis.

Dietary component	Recommendations for dogs	Recommendations for cats
Protein	<p>Only restrict dietary protein if necessary to control hepatic encephalopathy with congenital or acquired portosystemic shunts (PSSs); try other measures first (see Chapter 15). Moderate/normal amount of:</p> <ul style="list-style-type: none"> <li>• high quality protein (all essential amino acids in optimal amounts)</li> <li>• highly digestible protein (so none left in colon for bacteria to break down to ammonia)</li> </ul> <p>Protein should not be given in excess so as to require hepatic metabolism, resulting in increased blood ammonia. Ideal protein to use is cottage cheese, but it is relatively low in arginine. Other high quality proteins are eggs (but also high in methionine which contributes to hepatic encephalopathy), fish (but high in purines, which are metabolized to urates increasing urate urolithiasis in PSSs) and chicken. Vegetable protein is relatively poor quality but it is also a good source of anti-encephalopathic soluble fibre (see below).</p> <p>Low levels of aromatic amino acids and high levels of branched chain amino acids are said to be helpful in reducing hepatic encephalopathy but evidence for whether they can alter the blood ratio by altering the dietary levels is lacking. Single protein source diet based on dairy or soya protein is recommended after recovery from acute hepatitis</p>	<p>In all feline liver diseases, feed a high quality, highly digestible protein.</p> <p>Hepatic lipidosis: feed high protein diet – as high as possible without precipitating hepatic encephalopathy. May add extra arginine, taurine and carnitine. Balanced feline diet for critical care is ideal.</p> <p>Unlike dogs, avoid cottage cheese as major protein source as relatively arginine deficient; big problem in cats with liver disease. Eggs are a good source of arginine.</p> <p>Cholangitis: feed high quality, highly digestible protein. No need for protein restriction as encephalopathy very rare. Hypoallergenic/single protein source diet may be indicated as many cats have concurrent inflammatory bowel disease.</p> <p>Congenital PSSs: careful, moderate, staged protein restriction; try to control clinical signs by other means</p>

**24.25** Dietary advice for liver disease in dogs and cats. The diet should be fed little and often (4–6 times a day) and needs to be palatable as dogs and cats may be anorexic. Sufficient high quality diet is essential for hepatic regeneration and optimal hepatic function. (continues)

Dietary component	Recommendations for dogs	Recommendations for cats
Fat	No special advice in liver disease. Should be fed in normal amounts and not restricted as fat maldigestion and steatorrhoea due to cholestasis and lack of bile salts very rare. Only restrict if clinical steatorrhoea develops. Avoid very high fat diets, particularly with cholestasis or portal hypertension where they may exacerbate GI signs.  Optimizing omega 3: omega 6 may help reduce inflammation	The common concurrent incidence of pancreatitis and inflammatory bowel disease with cholangitis in cats may prompt consideration of fat restriction, although even in these cases normal dietary fat level is usually well tolerated. Some animals may have problems with high fat diets and many renal diets are high fat so should be avoided in liver disease
Carbohydrate	The carbohydrate used should be highly digestible as a primary calorie source, reducing need for hepatic gluconeogenesis from fat and protein. Carbohydrate metabolism usually disrupted in hepatic disease: complex carbohydrates and fat will be better used as an energy source by the animal with liver disease than glucose	Similar comments to dogs. Cats are not adapted to use carbohydrate as their primary energy source and are less able to utilize dietary carbohydrate than dogs. This and the risk of concurrent pancreatitis and possible related glucose intolerance and diabetes in cats should prompt consideration of a good protein level rather than a high carbohydrate diet in cats with chronic liver disease
Fibre	<i>Fermentable fibre</i> : reduces hepatic encephalopathy. Broken down to short chain fatty acids in the colon, which trap ammonia as ammonium ions. Also beneficial effect on colonic bacteria, increasing nitrogen incorporation into bacteria and reducing ammonia production  <i>Non-fermentable fibre</i> : also important as prevents constipation. Constipation is predisposing factor for development of encephalopathy since it increases the contact time for colonic bacteria to act on faeces and produce ammonia  Mixed fibre source in moderate amounts is therefore useful but too much interferes with the digestion and absorption of nutrients	Cats are not well adapted to dietary fibre. Increased soluble fibre increases taurine requirements. Increased dietary fibre may be beneficial in cats with hepatic encephalopathy. In other cases, a highly digestible low residue diet is indicated  The exception might be cats with concurrent inflammatory bowel disease, where some increase in soluble fibre might be indicated to encourage beneficial bacteria, although more studies are necessary to confirm this
Minerals: Zinc	Dogs are proposed to be similar to humans in that zinc deficiency is common with liver disease (due to reduced absorption and increased urinary loss) and supplementation with zinc reduces encephalopathy. Zinc has the following important roles in liver disease: <ul style="list-style-type: none"> <li>• Used in many metalloenzymes in the urea cycle and in muscle metabolism of ammonia</li> <li>• Reduces copper absorption from gut and copper availability in liver in primary or secondary copper storage disease</li> <li>• May also reduce collagen deposition in liver</li> <li>• May stabilize lysosomal membranes.</li> </ul> Supplementing zinc is therefore recommended in any chronic hepatitis in dogs or cats. If it is added to food, must regularly monitor blood concentrations to avoid toxicity (see Figure 24.23)	No current specific advice for cats as both hepatic encephalopathy and copper storage disease very rare
Copper	Animals with copper storage disease should be maintained on a low copper, high zinc diet.	Copper storage disease not recognized in cats so no specific advice.
Vitamins: Fat-soluble	<ul style="list-style-type: none"> <li>• Vitamin E supplementation may be cytoprotective especially in copper toxicity. It neutralizes free radicals and some authors use it in any case of chronic hepatitis at a dose rate of 400–600 IU/day for medium-sized dogs.</li> <li>• Vitamin K supplementation may be necessary if clotting times are prolonged, especially if considering biopsy. It appears to reduce clotting times even in cases where coagulopathy is due to a reduced hepatic production of clotting factors rather than actual vitamin K deficiency (see Figure 24.23).</li> <li>• Vitamins A and D should <i>not</i> be supplemented. Vitamin A can cause hepatic damage and vitamin D supplementation can cause calcification in tissues.</li> </ul>	<ul style="list-style-type: none"> <li>• Vitamin E supplementation may be cytoprotective.</li> <li>• Vitamin K supplementation is particularly necessary in cats, especially if concurrent inflammatory bowel disease and/or pancreatitis causing fat malabsorption.</li> <li>• Vitamins A and D should <i>not</i> be supplemented. Vitamin A can cause hepatic damage and vitamin D supplementation can cause calcification in tissues.</li> </ul>

**24.25** (continued) Dietary advice for liver disease in dogs and cats. The diet should be fed little and often (4–6 times a day) and needs to be palatable as dogs and cats may be anorexic. Sufficient high quality diet is essential for hepatic regeneration and optimal hepatic function. (continues) ▶

Dietary component	Recommendations for dogs	Recommendations for cats
Vitamins: Water-soluble <i>continued</i>	<ul style="list-style-type: none"> <li>B vitamins should be supplemented as there is increased loss in polydipsia/polyuria (PD/PU) associated with liver disease. It is recommended that dogs with liver disease receive a double dose of B vitamins.</li> <li>Vitamin C should <i>not</i> be supplemented as ascorbate can increase the tissue damage associated with copper and iron in liver disease.</li> </ul>	<ul style="list-style-type: none"> <li>B vitamins should be supplemented as there is a markedly increased loss in PD/PU associated with liver disease. Cats also have an increased dietary requirement for some B vitamins to support their metabolism. It is recommended that cats with liver disease receive a double dose of B vitamins.</li> <li>Vitamin C should <i>not</i> be supplemented as ascorbate can increase the tissue damage associated with copper and iron in liver disease.</li> </ul>
Other anti-oxidants	Other anti-oxidants in addition to vitamin E may be added to diet	Other anti-oxidants in addition to vitamin E may be added to diet

**24.25** (continued) Dietary advice for liver disease in dogs and cats. The diet should be fed little and often (4–6 times a day) and needs to be palatable as dogs and cats may be anorexic. Sufficient high quality diet is essential for hepatic regeneration and optimal hepatic function.

of disease should be assessed prior to use. Steroids should not be used in end-stage cirrhosis, non-inflammatory fibrosis or if there is significant portal hypertension. Colchicine could be considered instead in animals with severe fibrosis, and can be administered with corticosteroids in some cases with ongoing inflammation and concurrent fibrosis.

- Ursodeoxycholic acid is probably beneficial in any animal with chronic hepatitis, particularly if there is associated biliary stasis.
- Anti-oxidant agents (SAmE and Vitamin E) are probably warranted in all cases.
- Consider antibiotics, particularly if there is a significant neutrophilic component to the inflammation or there is an indication of ascending cholangitis. Choose appropriate antibiotics that are not potentially hepatotoxic (see Figure 24.16). Ampicillin and metronidazole are often used.
- In end-stage disease, give supportive therapy only with diet, anti-oxidants, ursodeoxycholic acid and treatments for ascites, GI ulceration and hepatic encephalopathy (see end of chapter). Do not use steroids in these cases.

### Lobular dissecting hepatitis

This is an idiopathic inflammatory hepatitis recognized in young dogs with a characteristic appearance of distinctive fibrotic dissection of lobular parenchyma into individual and small groups of hepatocytes. It has been reported in young dogs of a number of breeds, including several Standard Poodles and also in a number of litter-mates. Lobular dissecting hepatitis is probably a response of the juvenile liver to a variety of insults rather than a diagnosis in itself. Infectious aetiologies have been suggested, although not proved, and the age of onset and histological appearance bear a striking resemblance to atypical leptospiral infection in dogs. Treatment recommendations are similar to those for canine chronic hepatitis (see above).

### Non-cirrhotic portal hypertension, portal vein hypoplasia and non-inflammatory hepatic fibrosis

There are a number of conditions reported in predominantly young dogs, which are distinguished from chronic hepatitis in being non-inflammatory conditions that result in portal hypertension with varying amounts of hepatic fibrosis. These include:

- Non-cirrhotic portal hypertension
- Idiopathic hepatic fibrosis
- Portal vein hypoplasia.

It is likely that there is some overlap between these conditions and it has been suggested that they are all caused by intra-hepatic portal vein hypoplasia, but they may also represent a spectrum of disease or diseases of different aetiologies. The most important points for the clinician to recognize are:

- These conditions are non-inflammatory and so do not require treatment with anti-inflammatory drugs (corticosteroids)
- Portal hypertension requires symptomatic treatment and avoidance of drugs that may induce GI ulceration
- The long-term prognosis in these cases is often good (better than chronic hepatitis) but these cases may be misdiagnosed as end-stage chronic hepatitis on the basis of clinical, clinicopathological and imaging findings if a biopsy is not taken.

All these conditions have been reported in both dogs and bitches of a variety of breeds, with ages ranging from 3 months to 8 years, although more than 75% of animals are <4 years old at diagnosis. Young German Shepherd Dogs have been reported to have an increased risk of idiopathic fibrosis. Animals usually present with signs of portal hypertension (low protein ascites), GI signs (vomiting and diarrhoea) being most common, and hepatic encephalopathy and polydipsia in some cases. Clinicopathological findings are very

similar to end-stage chronic hepatitis cases, with microcytic red cells and elevated hepatocellular and cholestatic enzymes. Most cases have low albumin and urea and elevated preprandial bile acids; all cases have elevated 2-hour postprandial bile acids. Ascites and multiple extra-hepatic acquired PSSs can often be demonstrated on diagnostic imaging. The most striking finding on liver biopsy in these dogs is the lack of significant inflammation, which immediately distinguishes it from chronic hepatitis and cirrhosis. Portal veins are often small or absent with increased arterioles and abnormal lobular architecture. There is some fibrosis in some animals, but not as much as in cirrhosis. The treatment is outlined below and the prognosis is good in about 75% of cases.

### Treatment

Treatment is focused upon symptomatic management of portal hypertension, while supplying enough high quality nutrition to support the liver. The generally good prognosis means that dietary and other therapies must be capable of sustaining the animal long term:

- Feed frequent small meals of a high quality, digestible diet, and limit protein only if required to control hepatic encephalopathy (see Figure 24.25). Consider extra anti-oxidants such as SAME or vitamin E
- Control clinical signs of portal hypertension (see below): ascites, any GI ulceration and hepatic encephalopathy. Consider other additional means to control encephalopathy rather than restricting protein; for example, lactulose, other soluble fibre sources, antibiotics, zinc
- Consider use of ursodeoxycholic acid, particularly if there is evidence of biliary stasis
- Consider use of an antifibrotic, such as colchicine, if there is significant fibrosis.

### Congenital vascular disorders

Congenital vascular anomalies are surprisingly common in dogs, and much more common than in humans. They are also recognized in cats but much less often than in dogs.

#### Congenital portosystemic shunts

The commonest congenital vascular disorders seen in dogs are congenital PSSs. Congenital PSSs are distinguished from less common acquired PSSs as outlined in Figure 24.26. Acquired PSSs are particularly rare in cats.

Congenital PSSs are abnormal vascular communications between the portal and systemic circulation. They are usually single, or at most double, vessels and may be intra-hepatic or extra-hepatic in location (Figure 24.14). Large-breed dogs usually have intra-hepatic PSSs and small-breed dogs usually have extra-hepatic PSSs, although these associations are not invariable. Cats may have either type of PSS.

Extra-hepatic PSSs represent abnormal communications between the portal vein or one of its contributors (left gastric, splenic, cranial or caudal mesenteric, or gastroduodenal veins) and the caudal vena cava or

Congenital portosystemic shunts	Acquired portosystemic shunts
Usually single or at most double vessel	Usually multiple vessels
Can be intra-hepatic or extra-hepatic	Usually extra-hepatic
Usually have normal or reduced portal pressure, so no ascites unless very low albumin	Invariably portal hypertension, so ascites common
Usually no underlying liver disease so not jaundiced or showing other signs of liver failure	Usually severe underlying liver disease so often jaundice and other signs
About 75% present <1 year of age	Mostly (but not always) older dogs

**24.26** Differentiation of congenital and acquired portosystemic shunts.

azygos vein. Intra-hepatic PSSs may be left-sided, in which case they are thought to represent a persistence of the foetal ductus venosus after birth (patent ductus venosus), or they may be right-sided or centrally located in the liver, in which case they are thought to be anomalous vessels.

**Pathophysiology:** The pathophysiology of congenital PSSs largely relates to the shunting of unfiltered blood directly into the systemic circulation, resulting in hyperammonaemia and hepatic encephalopathy. Rarely, bacteraemia may lead to secondary infections. The reduction in hepatic and total body reticulo-endothelial function may also contribute to increased risk of infection. Additional effects of portal blood bypassing the liver are hepatic atrophy and a reduction in the metabolic activity of the liver contributing to inefficient use of dietary components, poor growth and loss of lean body mass.

Hepatic atrophy and changes in hepatic organelle function are partly due to changes in hepatic perfusion. The portal blood usually supplies about 50% of the liver's oxygen requirement, but this is obviously reduced in PSSs. Animals with PSSs typically have arteriolar hyperplasia in an attempt to make up for the reduced portal flow, but they often still have some degree of hepatic hypoperfusion. In addition, PSSs result in reduced delivery of 'hepatotrophic factors', such as insulin, to the liver, which contributes to hepatic atrophy. However, it should be noted that although animals with PSSs have small livers, hepatic atrophy does not appear to be progressive throughout life, rather, the liver reaches a 'stable' small size and remains at that size.

**Diagnosis:** The typical clinical signs of congenital PSSs are GI, urinary or neurological in origin. Animals typically present with a history of waxing and waning neurological signs typical of hepatic encephalopathy, rather than a sudden acute hepatic encephalopathic crisis (see Chapter 15). Hepatic encephalopathy is often most severe an hour or two after a meal, but the association with feeding is not obvious in many cases. Animals in acute crisis often present comatose but may



also have seizures. Drug intolerance is common, particularly prolonged recovery from routine anaesthesia for neutering. Animals with PSSs may also show intermittent vomiting or diarrhoea. Urinary tract signs include haematuria associated with urate calculi and polyuria/polydipsia. Impaired urine concentrating ability may reflect reduced renal concentrating gradient secondary to low urea, and increased blood cortisol levels secondary to reduced hepatic breakdown. Dogs and cats with congenital PSSs are also often (but not always) poorly grown compared with their litter-mates and also have a higher incidence of concurrent congenital abnormalities, particularly cryptorchidism in male dogs.

The typical clinicopathological findings with congenital PSSs reflect shunting of blood and reduced liver function and include low urea and albumin, mild elevation in liver enzymes and a microcytic anaemia. However, these are non-specific changes and in some cases they may all be normal. Elevation of postprandial  $\pm$  preprandial bile acids or ammonia is a more sensitive finding. However, definitive diagnosis of a congenital PSS relies on visualizing the shunting vessel either with ultrasonography, contrast portography (see Chapter 3) or at surgery. Portal scintigraphy is a useful technique to define shunting fractions (see Chapter 3) but it does not differentiate congenital from acquired PSSs.

**Treatment:** The treatment of congenital PSS traditionally revolves around partial or total-ligation of the shunting vessel, which is usually a procedure reserved for referral centres. Medical management is described elsewhere (see Chapter 15), and it is advisable for a few weeks prior to surgery to stabilize the patient, and for a couple of months after surgery. Some dogs also do well long term with medical management alone, particularly if they are older at presentation. Intensive medical management may be required to rescue animals from hepatic encephalopathy crisis that are comatose or seizing, but can be remarkably successful (see Chapters 15 and 26).

#### **Other congenital vascular disorders**

A wide variety of other congenital vascular disorders have been reported in dogs, and less frequently in cats, but all of them are rare compared with congenital PSSs. These include:

- Microvascular dysplasia (MVD)
- Portal vein hypoplasia
- Congenital arteriovenous fistulas.

In many cases, these present in a similar way to congenital PSSs with signs of shunting, including hepatic encephalopathy in a young animal. However, a clinically very important distinction is that most of these disorders result in portal hypertension, whereas most dogs with congenital PSSs have normal or reduced portal pressure unless they have concurrent portal vein hypoplasia. Dogs with other vascular anomalies would therefore present with classical signs of portal hypertension, such as ascites and gut wall oedema with or without ulceration, whereas dogs with congenital PSSs do not develop ascites and oedema unless their blood

albumin concentration is very low (see Chapter 13). Therefore, although other congenital vascular anomalies are rare, it is important to be aware of their existence as possible alternative causes of high blood bile acids or ammonia and encephalopathy in young dogs. There is some overlap between some of these conditions and non-cirrhotic portal hypertension (see above) and the clinical findings and treatment recommendations are very similar for all these disorders. The exception is congenital arteriovenous fistulas where the most effective treatment is surgical resection of the affected liver lobe.

**Microvascular dysplasia:** MVD has been reported as a congenital disorder in a number of breeds, but particularly Cairn Terriers and Yorkshire Terriers. It can be confused with congenital PSS as these dogs present with very similar clinical signs and clinicopathological findings. However, clinical signs of MVD and elevations in bile acids tend to be less marked than most dogs with congenital PSSs. Some dogs with MVD present with no overt clinical signs but persistently elevated bile acids and drug intolerance. The shunt fractions on transportal scintigraphy in dogs with MVD are typically much smaller than in dogs with congenital PSSs (<15% rather than 80% or more with a PSS). MVD is diagnosed on the basis of ruling out a gross shunting vessel, and liver biopsy which show changes very similar to those of liver biopsy samples taken from dogs with congenital PSSs. It is proposed that these dogs show shunting at the microscopic level, and that this may be a manifestation of portal vein hypoplasia. Occasionally, dogs may have concurrent MVD or other microscopic vascular anomalies in addition to a gross shunting vessel, and in these dogs, liver function tests fail to normalize after surgical ligation of the PSS and there may be an increased risk of postoperative portal hypertension. Management of MVD can only be medical as there is no gross shunting vessel to ligate. However, fortunately these dogs seem to do relatively well on medical management. Medical management is the same as for congenital PSSs.

#### **Hepatic neoplasia**

Primary liver tumours are rare in dogs and cats, and much less common than they are in humans. They represent 0.6–1.5% of all tumours in dogs and 1.0–2.9% of all tumours in cats. This may be because two of the predisposing factors for development of liver tumours in humans (hepatitis virus infection and  $\alpha_1$ -proteinase inhibitor deficiency) have not been recognized in small animals. No predisposing factors have been identified in cats and dogs, but it is interesting to note that biliary carcinomas are the most common primary liver tumours seen in cats, which may reflect the high incidence of biliary tract disease in this species. In contrast, hepatocellular carcinomas are the commonest primary liver tumours reported in dogs. Malignant primary liver tumours outnumber benign tumours in dogs, whereas in cats benign tumours are more common. An unusual benign tumour occasionally found in feline livers is a myelolipidoma, which has a suggested association with chronic hypoxia and hepatic involvement in diaphragmatic hernias.

Type of tumour	Dogs	Cats
Hepatocellular tumours: hepatocellular carcinoma (HCC) hepatocellular adenoma (hepatoblastoma – very rare)	HCC most common primary liver tumour in dogs (>50%). Most are 'massive', some are nodular or diffuse. MR 22–61%. Adenoma uncommon and usually incidental	Recognized but less common than biliary tumours
Bile duct tumours: biliary carcinoma (including cystadenocarcinoma) biliary adenoma gall bladder tumours	Biliary carcinomas 22–41% of malignant liver tumours. Some 'massive' but many diffuse or nodular. MR 56–88%. Adenomas uncommon and gall bladder tumours very rare	Biliary adenomas are the most common primary liver tumour in cats (>50%). Biliary carcinoma most common malignant feline liver tumour
Neuroendocrine tumours: hepatic carcinoid	Very rare, diffuse or nodular, and always very aggressive	Very rare but very aggressive
Primary hepatic sarcomas: haemangiosarcoma, leiomyosarcoma and others	Uncommon. Most locally aggressive, diffuse or nodular and high MR	Uncommon. Most locally aggressive and high MR

**24.27** Primary liver tumours in dogs and cats. Note also that secondary metastases in the liver are much more common than primary liver tumours in dogs (see Figure 24.26). MR = metastatic rate.

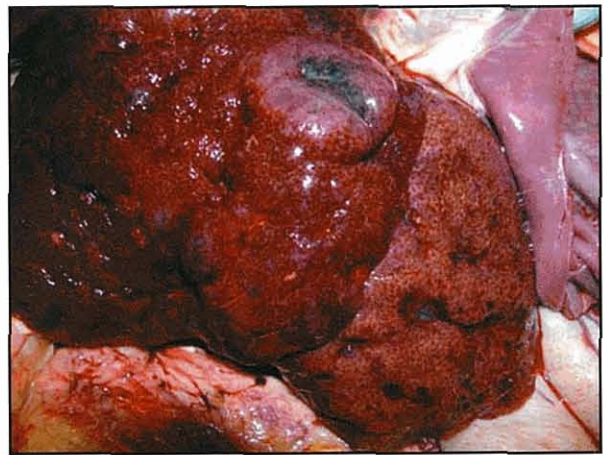
Primary malignant liver tumours are usually seen in older animals (mean age 10–12 years). The types of primary tumour recognized in the liver in dogs and cats are outlined in Figure 24.27. There is no obvious sex predisposition reported except for canine biliary carcinomas, which are more common in bitches in several studies. Canine malignant tumours may be 'massive', which present as a solitary, large mass confined to one lobe; 'diffuse' which describes diffuse involvement of all liver lobes; or 'nodular' in which there is multifocal disease with involvement of several lobes. The diffuse and nodular forms usually carry a poorer prognosis with a higher metastatic rate than the massive forms.

Haemangiosarcomas in the liver may be primary or secondary, and sometimes the origin is difficult to ascertain if multiple organs are involved, although the right atrium and spleen (Figure 24.28) are often primary sites.

Secondary tumours are commonly recognized in the liver because of its excellent blood and lymphatic supply and reticuloendothelial function. Metastases have been estimated to be 2.5 times more common than primary tumours in the liver of dogs. These include particularly haematopoietic tumours (such as lymphoma) and, less commonly, leukaemias, histiocytic tumours and mast cell tumours and metastases from other organs, such as pancreas, mammary glands and GI tract.

### Diagnosis

The presenting clinical signs and laboratory findings of liver tumours are indistinguishable from the findings in any primary liver disease. About half of affected animals may have palpable hepatomegaly or liver masses on abdominal palpation and these will be particularly obvious in dogs with 'massive' tumours. However, at least 50% of cats with liver tumours show no clinical signs at all. On clinical pathology, elevation in liver enzymes and bile acids, and a mild anaemia and neutrophilia are common but non-specific findings. Jaundice is uncommon but can occur. Hypoglycaemia is a notable finding particularly in dogs and especially in those with 'massive' tumours. The blood glucose can be low enough to cause clinical signs of weakness and collapse in these cases.



**24.28** Gross post-mortem appearance of liver from a 2-year-old Husky, which had just a 7-day history of anorexia, vomiting and ascites with marked elevation of liver enzymes and bile acids. The final histological diagnosis was poorly differentiated sarcoma, which had probably originated in the spleen.

Diagnostic imaging, particularly ultrasonography, is very helpful in identifying a hepatic mass and also in checking for metastases. Malignant hepatic tumours commonly metastasize to the peritoneum and local lymph nodes, and less commonly to the lungs. It is important to take both right and left lateral thoracic radiographs in all animals with liver tumours to check for pulmonary metastases. A thorough abdominal ultrasound examination should also be undertaken to check for evidence of metastases (see Chapter 3).

Diagnosis relies on cytology or histopathology. It is very important not to make a presumptive diagnosis on ultrasonographic appearance alone, as this is non-specific. In some cases, fine needle aspirates may be diagnostic but in others they may be difficult to interpret, particularly with benign hepatocellular tumours where the cells may look indistinguishable from normal hepatocytes. Ultrasound-guided 'core' biopsy is usually diagnostic, or alternatively biopsy samples may be taken at laparoscopy or laparotomy. In the case of an apparently single, massive lesion the clinician

may elect to proceed straight to excisional biopsy. Coagulation times and platelet counts should be checked prior to any form of biopsy, although it is unusual for these to be prolonged with primary tumours. However, coagulation times can be very significantly and dangerously prolonged in diffuse hepatic infiltration with lymphoma or other diffuse secondary tumours, and a biopsy should not be considered in these cases until clotting factors have been replenished with a plasma transfusion.

### **Treatment and prognosis**

Treatment of primary hepatic tumours relies on surgical removal if they are resectable. This is advisable even with benign tumours, including biliary adenomas in cats, as there is some limited evidence that they may undergo malignant transformation. Treatment of diffuse, nodular and metastasized tumours is difficult. Primary hepatic tumours generally show a poor response to chemotherapy, and radiotherapy is not recommended as normal liver tissue is very radiosensitive.

Prognosis therefore depends on how easily resectable the tumour is and how malignant it is. The single and massive tumours, which are completely resectable, generally have a good prognosis whereas the diffuse, nodular malignant tumours carry a poor prognosis.

### **Hepatic nodular hyperplasia**

This is a benign condition of unknown aetiology recognized in older dogs. The incidence increases with age and reportedly 70–100% of dogs of 14 years of age or older have some hepatic nodular hyperplasia on post-mortem examination. Based on gross and ultrasonographic appearance it can easily be confused with more serious conditions, particularly hepatic neoplasia and regenerative nodules in cirrhosis (see Chapter 3). Nodular hyperplasia is not always visible on ultrasound examination as it may look very similar to normal parenchyma.

Hyperplastic nodules also often cause an increase in ALP levels, which is usually moderate (2.5–3 times the upper limit of the reference range) but can be as high as 10–14 times normal, and can lead to an erroneous suspicion of more severe liver disease or hyperadrenocorticism in older dogs. Bile acids and bilirubin are usually normal but there may be a mild elevation in hepatocellular enzymes, probably due to cellular regeneration.

Nodular hyperplasia is often difficult to diagnose on a core biopsy and a wedge biopsy is preferred. A core biopsy may simply show vacuolar swelling, suggesting an endocrinopathy, causing further confusion with hyperadrenocorticism in a dog with elevated ALP levels. Core biopsy also does not give such a good indication of hepatic architecture, making differentiation from hepatomas difficult. No treatment is required for nodular hyperplasia as the condition is benign.

### **Treatment of chronic liver disease**

The basic aims of treatment are similar in any chronic liver disease in dogs or cats and are to:

- Treat the underlying cause where possible
- Slow the progression of disease where possible
- Allow hepatic regeneration
- Allow hepatic 'rest' (don't over-work the liver)
- Manage the clinical signs and complications of the disease; particularly hepatic encephalopathy in congenital and acquired PSSs and gastroduodenal ulceration and ascites in animals with cirrhosis and portal hypertension.

In addition, it is important to remember that many drugs undergo hepatic metabolism or are potentially hepatotoxic, so careful consideration should be given to the use of any drug in an animal with liver disease (see Figure 24.16).

### **Diet and liver disease**

When treating any chronic liver disease, it is important to think diet first before drugs. Careful dietary management of these animals is essential as the liver is central to metabolism. All of the portal blood passes through the liver first (unless there is a congenital or acquired PSS) so the food absorbed has an immediate effect on the liver. A general consideration of dietary management of liver disease is given in the Figure 24.25.

As with drug therapy, the diet should be tailored to the individual animal rather than simply reaching for a tin of manufactured diet, considering carefully which diet to use and whether to add extra protein (e.g. as cottage cheese in dogs) or extra carbohydrate. The effectiveness of dietary management from the clinical response of the animal (e.g. reduced clinical signs of hepatic encephalopathy, reduced ascites) should be monitored and bodyweight and serum total protein and albumin measured regularly.

### **Drug therapy in chronic liver disease**

Selection of appropriate therapy in each case relies on addressing the aims of treatment in a way which is tailored to the individual animal and disease. General guidelines for treatment of chronic liver disease are outlined below. These are based more on the anecdotal experience of veterinary hepatologists than on published clinical trials, of which there are very few in dogs and cats. (The doses for drugs used in liver disease are outlined in Chapter 28 and Appendix 1.)

#### **Treat the cause of the liver disease**

The cause of disease should be treated wherever possible. Biopsy may help define the cause but, unfortunately in many cases of chronic liver disease in dogs, the cause is unknown. Two examples of treating the cause are the use of copper chelators (penicillamine or 2,2,2-tetramine) in Bedlington Terriers with copper storage disease, and antibiotics in cats with suppurative cholangitis.

#### **Attempt to slow the progression of the disease**

This is one of the main aims in most cases of chronic hepatitis in dogs. It requires a basic understanding of the pathophysiology of the disease and a representative liver biopsy. The treatment used will depend on the degree of inflammation and fibrosis present, combined

with the distribution in the liver and type of inflammatory cells present. In dogs with chronic liver disease, the following drugs could be considered:

- Steroids
- Immune modulators
- Colchicine
- Zinc
- Ursodeoxycholic acid
- Anti-oxidants.

**Steroids:** These are the most effective antifibrotic agents and are indicated to slow down progression in many cases of chronic hepatitis, but only if there is an inflammatory infiltrate (or at least a pathological accumulation of stellate cells) and not if there is end-stage fibrosis and cirrhosis, when steroid use is unhelpful and can cause severe side-effects. Steroids have anti-inflammatory, immune-modulating and antifibrotic effects. They have a potent indirect antifibrotic action via reducing prostaglandin (PG)/leucotriene production, a weak direct antifibrotic action via inhibiting mRNA and enzymes, and an immune-modulating action via reducing macrophage activity and lymphocyte antibody production. Steroid therapy is not indicated in advanced, bridging fibrosis or non-inflammatory fibrosis.

There are particular adverse effects of steroids in liver disease: they increase protein catabolism; fluid retention; GI ulceration and risk of infections and actually decrease survival time in humans with ascites; GI ulceration; or encephalopathy. Thus steroids should be avoided or used with extreme care in animals with obvious portal hypertension. They may precipitate GI ulceration, which in turn will precipitate acute encephalopathy as a result of blood in the intestinal lumen (a 'high protein meal') and this may result in a downward spiral from which the animal fails to recover. The dose to use and length of treatment is unclear.

Many clinicians recommend the use of immunosuppressive doses on the assumption that dogs have autoimmune hepatitis, yet which has not yet been shown to exist, whereas it might be more logical to use lower anti-inflammatory doses, as in human alcoholic cirrhosis. There are far too few published data in dogs to make a firm recommendation of dose. The author usually starts with 1 mg/kg q24h and then gradually reduces the dose and frequency of dosing, but others start as high as 2 mg/kg q24h. How long to treat is also a problem. In humans, steroid therapy is continued for 6 months beyond remission but this is hard to assess in dogs because of steroid-induced liver enzymes and in addition veterinary patients often have chronic disease. Long-term, low dose, every other day therapy would seem most logical in many dogs.

**Immune modulators:** Other immune modulators, such as azathioprine (dogs only) and ciclosporin, have occasionally been used, but in the absence of proof of the existence of autoimmune hepatitis in dogs their use in liver disease is questionable and potentially dangerous and so they are best avoided. Azathioprine can significantly inhibit hepatic regeneration by inhibiting cell division.

**Colchicine:** This is an alkaloid that binds tubulin and has the potential to reverse or slow hepatic fibrosis. It improves survival in human cirrhotics and there are limited but good reports of its use in dogs (but no reports in cats so it is best avoided in them). Side-effects are uncommon in dogs but include bone marrow suppression and anorexia or diarrhoea; it is the latter which often limits its use in clinical cases.

**Zinc:** This has some antifibrotic action in addition to its other actions, and it is a useful addition to treatment or the diet of dogs with chronic hepatitis.

**Ursodeoxycholic acid:** Ursodeoxycholic acid is used in both dogs and cats in an attempt to modulate the toxic bile acid pool. It is a hydrophilic bile acid which displaces the toxic hydrophobic bile acids. It is also choleric so should be avoided in complete biliary obstruction (which is rare in dogs and cats). It is also immune-modulating (it reduces immunoglobulin and interleukin production and expression of major histocompatibility complex (MHC)-1 on hepatocytes). It is not licensed for use in small animals but it has been used widely and safely in dogs and cats. However, there is only one published case report of its use. It is potentially indicated in any case of hepatitis, particularly if there is associated non-obstructive biliary stasis. However, its use is not currently recommended in feline hepatic lipidosis.

**Anti-oxidants:** These drugs and nutraceuticals, such as SAME, sibilin (the active ingredient of silymarin, extracted from milk thistle) and vitamin E can slow the progression of disease by reducing oxidant damage. Metronidazole is also reported to have some anti-oxidant activity. SAME, which increases hepatic and red blood cell glutathione levels, is widely available as a nutraceutical for dogs and cats. The use of these anti-oxidants appears to be safe although in general there is no firm evidence they improve quality of life or survival. SAME is particularly helpful in toxic hepatopathies in humans, such as phenobarbital-induced hepatopathy, and recent work suggests it might be helpful in chronic and acute liver disease, and steroid hepatopathies in dogs and cats. However, it is worth noting that not all anti-oxidants are innocuous; for example, it is best to avoid supplementing vitamin C in liver disease as ascorbate may increase liver damage by copper and iron.

#### **Treat the signs associated with the liver disease**

It is not helpful (and can be dangerous) to treat animals with end-stage fibrosis and cirrhosis with steroids or other antifibrotic medications. However, it is still worth treating these animals with supportive symptomatic therapy for the complications associated with their disease as they can often be maintained with a good quality of life for a long period.

#### **Symptomatic treatment of GI ulceration associated with liver disease**

- Sucralfate is the mainstay of treatment of GI ulceration due to portal hypertension

- H<sub>2</sub> blockers may be used in addition (avoiding cimetidine) although there is some evidence that gastric pH is normal to increased in liver disease so they may be unnecessary
- Frequent feeding of small, high quality meals will promote ulcer healing (these animals should not be starved).

#### Symptomatic treatment of ascites associated with liver disease

- If blood albumin is low, then increasing dietary protein levels may be effective in controlling ascites, particularly if the animal does not have portal hypertension. If albumin levels have to be increased quickly (e.g. prior to general anaesthesia or surgery) a plasma transfusion may be considered.
- If blood albumin levels are normal but there is concurrent portal hypertension, a staged approach should be adopted.
  - Spironolactone is used alone initially as it does not cause hypokalaemia and is generally the most effective diuretic to use in liver disease. This is because the pathophysiology of ascites formation in liver disease involves activation of the renin–angiotensin–aldosterone system. It is not licensed for use in dogs and cats and takes at least 2–3 days to work; it can take weeks.
  - If after 2–3 days, the ascites persists, furosemide can be added but blood potassium levels must be carefully monitored to avoid hypokalaemia-induced hepatic encephalopathy.
  - Therapeutic paracentesis should be avoided and be performed only if the ascites is life-threatening or causing obvious discomfort (i.e. the animal is very dyspnoeic due to interference with movement of the diaphragm) and only then if a concurrent plasma transfusion is given to maintain albumin levels. Otherwise, removal of the ascites may result in a precipitous drop in blood albumin levels followed by rapid reformation of the ascites. This is because the diseased liver is unable to make albumin quickly enough to replace the loss. If the fall in blood protein levels is significant enough, the animal may develop pulmonary oedema and die.

#### Management of hepatic encephalopathy

This topic is reviewed in Chapter 15.

#### References and further reading

- Bunch SE, Johnson SE and Cullen JM (2001) Idiopathic noncirrhotic portal hypertension in dogs: 33 cases (1982–1988). *Journal of the American Veterinary Medical Association* **218**, 392–399
- Center SA (1996a) Chronic hepatitis, cirrhosis, breed-specific hepatopathies, copper storage hepatopathy, suppurative hepatitis, granulomatous hepatitis and idiopathic hepatic fibrosis. In: *Strombeck's Small Animal Gastroenterology*, ed. WG Guilford et al., pp 705–765. WB Saunders, Philadelphia
- Center SA (1996b) Acute hepatic injury: hepatic necrosis and fulminant hepatic failure. In *Strombeck's Small Animal Gastroenterology*, ed. WG Guilford et al., pp. 654–705. WB Saunders, Philadelphia
- Center SA (2004) Understanding and treating feline hepatic lipidosis. *Waltham Focus* **14**, 12–21
- Center SA, Elston TH, Rowland PH, Rosen DK, Reitz BL, Brunt JE, Rodan I, House J, Bank S, Lynch LR, Dring LA and Levy JK (1996) Fulminant hepatic failure associated with oral administration of diazepam in 11 cats. *Journal of the American Veterinary Medical Association* **209**, 618–625
- Dayrell-Hart B, Steinberg SA, VanWinkle TJ and Farnbach GC (1991) Hepatotoxicity of phenobarbital in dogs: 18 cases (1985–1989). *Journal of the American Veterinary Medical Association* **199**, 1060–1066
- Gillespie TN, Washabau RJ, Goldschmidt MH, Cullen JM, Rogala AR and Breitschwerdt EB (2003) Detection of *Bartonella henselae* and *Bartonella clarridgeiae* DNA in hepatic specimens from two dogs with hepatic disease. *Journal of the American Veterinary Medical Association* **222**, 47–51
- Maguire PJ, Fettman MJ, Smith MO, Greco DS, Turner AS, Walton JA and Ogilvie GK (2000) Effects of diet on pharmacokinetics of phenobarbital in healthy dogs. *Journal of the American Veterinary Medical Association* **217**, 847–852
- March PA, Hillier A, Weisbrode SE, Mattoon JS, Johnson SE, DiBartola SP and Brofman PJ (2004) Superficial necrolytic dermatitis in 11 dogs with a history of phenobarbital administration (1995–2002). *Journal of Veterinary Internal Medicine* **18**, 65–74
- Meyer DJ, Thompson MB and Senior DF (1997) Use of ursodeoxycholic acid in a dog with chronic hepatitis: effects on serum hepatic tests and endogenous bile acid composition. *Journal of Veterinary Internal Medicine* **11**, 195–197
- Seguin MA and Bunch SE (2001) Iatrogenic copper deficiency associated with long term copper chelation for treatment of copper storage disease in a Bedlington terrier. *Journal of the American Veterinary Medical Association* **218**, 1593–1597
- Thamm DH (2001) Hepatobiliary tumours. In: *Small Animal Clinical Oncology*, 3<sup>rd</sup> edition, ed. SJ Withrow and EG MacEwen, pp. 327–334. WB Saunders, Philadelphia
- Trepanier LA (2004) Idiosyncratic toxicity associated with potentiated sulfonamides in the dog. *Journal of Veterinary Pharmacology and Therapeutics* **27**, 129–138
- Ubbink GI, Van den Ingh TS, Yuzbasiyan-Gurkan V, Teske E, Van de Broek J and Rothuizen J (2000) Population dynamics of inherited copper toxicosis in Dutch Bedlington terriers (1977–1997). *Journal of Veterinary Internal Medicine* **14**, 172–176
- Van de Sluis B, Rothuizen J, Pearson PL, Van oost BA and Wijmenga C (2002) Identification of a new copper metabolism gene by positional cloning in a purebred dog population. *Human Molecular Genetics* **11**, 165–173
- Villiers E and Blackwood L (in preparation) *BSAVA Manual of Clinical Pathology*, 2<sup>nd</sup> edition, BSAVA Publications, Gloucester
- Williams PJ (1997) Decision making in the management of portosystemic shunts. *In Practice* **19**, 106–120
- Watson PJ (2004a) The pathophysiology of liver disease part I: normal hepatic structure and function. *UK Vet* **9**, 26–31
- Watson PJ (2004b) Chronic hepatitis in dogs: a review of current understanding of the aetiology, progression and treatment. *Veterinary Journal* **167**, 228–241
- Webb CB, Twedt DC and Meyer DJ (2002) Copper-associated liver disease in Dalmatians: a review of 10 dogs (1998–2001). *Journal of Veterinary Internal Medicine* **16**, 665–668

# Diseases of the biliary system

Jan Rothuizen

## Anatomy and physiology of the biliary system

### Bile system

The liver detoxifies or catabolizes many exogenous and endogenous compounds, and many are removed from the body by excretion into the bile. The biliary system is a branched structure that transports bile from each individual liver cell. The hepatocytes lie in cell plates, which radiate around the central vein and connect central and portal regions of the liver acinus. Blood flows from the portal triads to the central region within the sinusoids, while bile flows in the opposite direction. The lateral membranes connecting adjacent liver cells contain a specialized region; the canalicular membrane. The space between canalicular membranes of adjacent cells is sealed by tight junctions and forms the smallest branches of the bile system, the canaliculi. This excretory region of the hepatocyte membrane encompasses 15% of the cell surface.

Bile is excreted by the hepatocytes into the canaliculi, which transport bile to the portal tracts where they enter the canals of Hering. These short connecting ducts are lined in part by hepatocytes and in part by cuboidal cholangiocytes, and drain into the smallest branches of the intra-hepatic bile ducts, which are completely lined by cholangiocytes. From the smallest bile ductules the bile flows to the interlobular ducts, the septal ducts and via the hilar ducts of each liver lobe into the common bile duct. The common bile duct runs to the duodenum some 3–6 cm from the pylorus, depending on the size of the animal. The junction of the common bile duct and the duodenum near the head of the pancreas, Vater's papilla, is surrounded by the muscular sphincter of Oddi. While dogs have separate openings for the bile and pancreatic ducts, in cats the pancreatic duct and the common bile duct share a common duct entering the papilla.

The gall bladder is connected to the common bile duct via the short cystic duct and is the main storage site of bile, where it is concentrated approximately tenfold. Bile is also concentrated in the larger bile ducts. In healthy animals, the completely filled gall bladder contains around 1 ml of bile per kilogram of bodyweight. Less than half of the bile produced is stored and concentrated; the remainder is immediately transported via the common bile duct and secreted intermittently into the duodenum. Stimulation of the muscular wall of the gall bladder to contract by cholecystokinin (from the

duodenal mucosa) produces a gradual release of bile over several hours. However, bile enters the duodenum only when permitted to do so by periodic relaxations of the sphincter of Oddi. Gall bladder emptying is very variable and almost never complete. An empty gall bladder on ultrasonography is definitely an abnormal finding. Morphine-related drugs cause complete closure of the sphincter, so during anaesthesia the gall bladder may become overfilled. An enlarged gall bladder usually an artefact: only dilatation of the larger bile ducts or the common bile duct indicates an abnormality, such as cholangitis or bile duct obstruction.

### Bile flow

Bile flow is driven by constant bile production in the smaller branches of the biliary tree pushing the fluid already formed into the larger ducts and the gall bladder. About half of the bile production depends on the active excretion of bile acids by the hepatocytes into the canaliculi. Bile acids are produced by the liver from cholesterol as a major route of cholesterol excretion. The two acids formed are cholic acid and, to a lesser extent, chenodeoxycholic acid (the so-called primary bile acids). These bile acids are conjugated with glycine or taurine before excretion, rendering them hydrophilic and thereby facilitating their retention in the gut lumen, where they aid fat digestion and absorption. Active excretion induces a huge concentration gradient with a ratio of approximately 2000:1 between the concentrations in plasma and those in bile. The resulting osmotic gradient induces a passive excretion of water into the canaliculi. The magnitude of the bile flow is therefore directly related to excretion of bile acids.

Conjugated bile acids in the intestines may be transformed by intraluminal bacteria in two ways: by deconjugation and by 7 $\alpha$ -hydroxylation. In the latter type of reaction, the secondary bile acids deoxycholate and lithocholate are produced from cholic and chenodeoxycholic acid, respectively. Deconjugation renders the bile acids hydrophobic and leads to rapid absorption by passive diffusion; in contrast conjugates are actively absorbed only in the ileum. Lithocholic acid, which is hepatotoxic and may induce severe cholestasis, is poorly absorbed. The small reabsorbed fraction of lithocholic acid is sulphated (tertiary sulpholithocholic acid) in the liver, in which form it is not reabsorbable during the next enteric cycle. Reabsorbed bile acids are very efficiently cleared by the liver from the portal blood (>90% in each passage) although this is less

efficient for unconjugated bile acids. All bile acids are subsequently re-excreted into the canaliculi, after reconjugation, if required. Bile acids reabsorbed from the intestine (of which 60% is by active absorption) account for 90% of the bile acids excreted by the liver; therefore, only a small fraction is lost from the enterohepatic circulation despite a cycling frequency of 10–15 per day. The lost fraction is replenished by *de novo* synthesis in the liver.

An amount of bile production approximately equal to the bile acid dependent fraction also occurs following active secretion of Na<sup>+</sup> into the canaliculi. This secretion is stimulated by barbiturates and insulin, and inhibited by oestrogens, derivatives of chlorpromazine and in hypothyroidism. Finally, approximately 30% of the bile is produced not by hepatocytes but by the epithelium of the intra-hepatic bile ducts, which secretes water in combination with bicarbonate and chloride in response to gastrin and secretin stimulation.

### **Pathophysiology of biliary dysfunction**

#### **Cholestasis**

Cholestasis is a reduction in bile flow in the biliary tract and can be caused by intra- or extra-hepatic obstruction. Most clinical cases have intra-hepatic cholestasis but, because of the reserve capacity of the liver, jaundice occurs only when the intra-hepatic disease involves the entire liver, such as in hepatitis. Therefore, since intra-hepatic cholestasis most often only partially reduces bile flow, most cases do not become icteric. In contrast, obstruction of the common bile duct (see below), while less common, is likely to obstruct the entire bile flow, often leading to icterus.

Cholestasis leads to accumulation of bile components in the liver, including the toxic bile acids such as lithocholic acid. The toxic effects of these bile acids are normally not exerted because in healthy animals their concentrations are very low. When they accumulate, however, there may be necrosis of hepatocytes with concurrent inflammatory reaction. Hepatic inflammation is common whenever there is cholestasis.

Liver histology in extra-hepatic cholestasis reveals typical changes in both dogs and cats. Acute extra-hepatic cholestasis is characterized by enlarged portal areas with oedema and infiltration of neutrophils into the stroma. The more chronic the cholestasis, the more proliferation of bile ducts becomes noticeable in the portal areas. Chronic cases also show portal fibrosis, infiltration by macrophages loaded with brown bile pigment, and inflammatory reaction with lymphocytes and plasma cells. In very chronic cases, characteristic concentric onion-ring shaped areas of periductal fibrosis are present.

#### **Intra-hepatic cholestasis**

The hepatocytes lie in cell plates that separate sinusoidal blood flow from canalicular bile flow. Intra-hepatic cholestasis may occur due to leakage of the tight junctions that separate canaliculi from sinusoids. This occurs in all liver diseases in which hepatocytes are damaged for any reason (e.g. toxin, virus or drug

reaction). The integrity of this separation is lost when cells die and this always results in backflow of bile into the space of Disse and, with the hepatic lymph, back into the bloodstream. Notably, enzymes released by leptospiral organisms may destroy tight junctions of multiple hepatocytes and produce severe intra-hepatic cholestasis, and therefore dogs with leptospirosis nearly always become jaundiced. However, this infection does not lead to hepatocyte death, although the cells do lose intercellular contact, thereby stimulating cell division; cases of leptospirosis are characterized by multiple mitotic figures in hepatocytes as a consequence. Intra-hepatic cholestasis may also be caused by diffuse swelling of hepatocytes, such as in feline hepatic lipidosis. Frequent causes of intra-hepatic cholestasis are infiltration by inflammatory cells (e.g. hepatitis), tumour cells (e.g. malignant lymphoma) or fibrous tissue (e.g. chronic liver disease) in or around the portal areas, which hinders flow of bile from the canaliculi into the ductules. All these factors may be present in different combinations, so that in fact there are very few cases of liver disease without intra-hepatic cholestasis.

#### **Extra-hepatic cholestasis**

Obstruction of the extra-hepatic bile ducts is rare in dogs, but less so in cats. In dogs the cause nearly always resides in the distal common bile duct near the duodenal papilla. Acute pancreatitis or tumours of the pancreas or the duodenum are the most common cause; gall stones are infrequent. The same causes also occur in cats. However, the most frequent cause in cats is inflammation of the (intra- and extra-hepatic) bile ducts. In particular chronic lymphocytic cholangitis may cause decreased bile flow due to increased viscosity of bile. Hyperplasia of the biliary epithelium, which may be caused by progestins, can also cause cholestasis. Cholangiocarcinomas may also obstruct the bile flow; these tumours tend to spread diffusely throughout the biliary tract and produce severe blockage of bile flow. Rarely the extra-hepatic bile ducts may also become incarcerated in a diaphragmatic rupture or pericardio-peritoneal diaphragmatic hernia, resulting in blockade of the bile flow.

In extra-hepatic cholestasis the large bile ducts become dilated and tortuous, which is clearly visible on ultrasound examination. However, cats with chronic lymphocytic cholangitis also have such abnormal bile ducts. The difference may become apparent only with histological examination of a liver biopsy sample. In extra-hepatic cholestasis the gall bladder may be distended but in chronic cases the bile is concentrated, leaving a small amount of viscous uncoloured fluid ('white bile') in the gall bladder, which may also be of normal or reduced size. Since drugs, such as morphine derivatives, cause closure of the sphincter of Oddi, an 'overfilled' gall bladder is usually of no importance when seen during anaesthesia.

#### **Jaundice**

Bilirubin is the pigment that causes jaundice (see Chapter 14). It is the normal end product of haem catabolism. In healthy animals the liver has a huge reserve capacity to handle bilirubin; therefore, when

there is increased production (haemolysis) jaundice is not the immediate result. Jaundice due to haemolysis occurs only when erythrocyte degradation causes such severe hypoxia that the centrolobular liver cells become necrotic, resulting in intra-hepatic cholestasis. The combination of increased bilirubin production and cholestasis then causes jaundice, which like all other forms of icterus is caused by both conjugated (direct) and unconjugated (indirect) bilirubin. Differentiation of direct and indirect bilirubin by the van den Bergh test therefore has no clinical relevance in dogs and cats.

Measurement of urobilinogen by the Ehrlich reaction on urine dipsticks in order to differentiate icterus of cholestasis from that of haemolysis has been used in the past, but is of no value. The concentration of urobilinogen in urine varies depending on many factors, such as intestinal bacteria, hepatic clearance efficiency, and urine pH and concentration. Urobilinogen in urine is also rapidly oxidized to urobilin, which does not participate in the Ehrlich reaction. Bilirubin itself may also be excreted in the urine by healthy male dogs without any cholestasis or haemolysis since renal tubular cells have all the enzymes necessary for production and conjugation of bilirubin.

Abnormally low amounts of bilirubin and its black-brown breakdown pigments in faeces may occur as a result of cholestasis. Lightly coloured (yellow or grey) faeces due to absence of pigments is seen only in very severe cholestasis (Figure 25.1). Such acholic faeces almost invariably indicate complete extra-hepatic bile duct obstruction and these animals have severe jaundice. The only intra-hepatic form of cholestasis that may be so severe that it mimics complete extra-hepatic bile duct obstruction (sometimes also with acholic faeces) is destructive cholangitis, which is typically a hypersensitivity reaction to sulphonamides. It should be noted that the absence of acholic faeces does not exclude obstruction of the common bile duct (or destructive cholangitis).

Conjugated bilirubin in plasma may bind covalently (irreversibly) to albumin. This biliprotein complex can be cleared from the circulation only when albumin, with a half-life of about 2 weeks, is catabolized. Icterus therefore does not always reflect the current ongoing state of hepatic function, a factor that should be considered when interpreting the test results during both diagnosis and treatment.



**25.1** Acholic faeces. Pale faeces lacking bile pigments passed by a jaundiced dog with a complete bile duct obstruction caused by a pancreatic carcinoma. (Courtesy of Edward Hall)

## Clinical signs

The larger bile ducts and gall bladder have a rich autonomous innervation and when damage results from inflammation, tumours or other causes, or when there is distension of the biliary tree, this stimulation typically results in nausea. Thus, disease of the larger bile ducts or gall bladder often leads to anorexia, which may be variable in degree over time in chronic cases. Vomiting is a frequent sign in many cases, especially in acute biliary diseases. Anorexia and vomiting cause weight loss in chronic conditions. Jaundice is not necessarily present, especially when biliary obstruction is incomplete and only in those rare patients with complete common bile duct obstruction will there be acholic faeces. Spontaneous haemorrhagic diathesis associated with vitamin K deficiency most commonly develops secondary to fat malabsorption, particularly in cats, and is sometimes associated with isolated bile duct obstruction.

## Diagnosis

### Biochemical investigation of cholestasis

Cholestasis is characterized by increased plasma concentrations of bile acids, alkaline phosphatase (ALP) and gamma glutamyl transferase (GGT). Of these parameters, the enzymes are specific for both intra- and extra-hepatic cholestasis; bile acids are increased in cholestasis, portosystemic shunting and when there is reduced hepatocyte function for any reason. Also the metabolism of bile acids (as reflected by the postprandial concentration) is not essentially different between cholestatic diseases and portosystemic shunting. Serum bile acids, while very sensitive for assessing cholestasis, are therefore not very specific. Of the enzymes GGT is a very specific indicator of cholestasis, but is not as sensitive as the total bile acid concentration. ALP is also sensitive but is less specific since it resides in many tissues other than the hepatobiliary system. In dogs, ALP from the liver has a very long half-life in contrast to isoenzymes from other tissues, except the skeleton, so that high ALP levels in dogs without skeletal diseases can usually be related to hepatobiliary disease. The steroid-induced isoenzyme of ALP, which is produced in the liver of dogs in reaction to increased exposure to steroids, has an equally long half-life but no relation with cholestasis. Cats do not produce a steroid-induced isoenzyme of ALP. However, the feline liver contains much less ALP than the liver of dogs and it has a much shorter half-life, and thus ALP is not a sensitive test in cats. Therefore, for the reasons outlined, when abnormal ALP is observed in cats this is very specific for the presence of significant liver disease.

### Diagnostic imaging

#### Ultrasonography

Ultrasonography is the easiest and most informative method to examine the presence and nature of biliary disorders. Only the larger intra-hepatic ducts and the extra-hepatic ducts, the common bile duct, the gall



bladder and the cystic duct (which connects the gall bladder with the common bile duct) can be evaluated. Pure intra-hepatic cholestasis, which is the most common form of cholestasis, can only be evaluated biochemically and histologically.

Ultrasonography is the first and most important method for differentiating intra-hepatic from extra-hepatic cholestasis (see Chapter 3). The difference is that with extra-hepatic cholestasis the common bile duct is dilated, whereas it is not in patients with intra-hepatic cholestasis. When there is chronic obstruction of the extra-hepatic bile flow, the common bile duct and larger intra-hepatic ducts become irregular and tortuous. Therefore, ultrasonography may give clues to the presence and also the chronicity of extra-hepatic bile duct obstruction. It may be difficult to distinguish a dilated common bile duct from larger blood vessels, such as the portal vein, but the difference is always clear with Doppler examination, which will demonstrate the virtual absence of flow in the bile ducts. If all the bile ducts are distended, the cause of extra-hepatic obstruction lies nearly always in the region of Vater's papilla near the duodenum. Common causes, such as tumours of the pancreas or the intestinal wall, and gall stones, can often be found with careful ultrasonographic evaluation of this region. Ultrasonography also permits confirmation by fine needle aspiration of such lesions.

In cats the most common disease of the larger bile ducts is not extra-hepatic obstruction, but inflammation. Lymphocytic cholangitis is usually a very chronic disease that leads to distension and irregular tortuosity of the common bile ducts and larger intra-hepatic bile ducts. This ultrasonographic picture cannot be distinguished from that of extra-hepatic bile duct obstruction. The histological changes, however, are very different so that in cats the diagnosis of such disorders is never complete without histological examination of the liver. It should be noted that the gall bladder is often not enlarged in cases of extra-hepatic bile duct obstruction; only dilatation of the common bile duct is relevant.

Not all extra-hepatic bile duct or gall bladder diseases are visible with ultrasonography. This is especially true for neutrophilic cholangitis in cats and cholecystitis in dogs. In these disorders the gall bladder wall may be thicker than normal due to oedema, which can be seen as a black line in the wall. However, this is not pathognomonic, because gall bladder oedema can also be present in dogs with hepatitis, and in addition it is often absent in dogs and cats with cholecystitis or cholangitis. The liver histology is not specific in many of these cases with only non-specific reactive hepatitis; cats with neutrophilic cholangitis may histologically show neutrophils in the wall and lumen of the portal bile ducts. Fine needle aspiration of bile from the gall bladder with cytological and bacteriological examination may be the only way to diagnose cholangitis and cholecystitis.

In many healthy dogs and cats the bile does not appear as a completely clear, hypoechoic fluid on ultrasound examination. It may contain multiple very small crystals composed of cholesterol and bilirubin, without any significance. This sediment or 'sludge' is often readily visible on ultrasonography (but not with radiography).

Calcification of the wall of bile ducts may occur when there is chronic stasis of bile or inflammation, and is visible both on ultrasonography and routine radiography. Such calcifications in the liver are nearly always localized in the wall of the biliary tree and indicate chronic biliary disease or congenital cystic lesions arising from the bile ducts. Gas in the biliary tract is a clear sign of severe bacterial infection and is immediately obvious with ultrasonography and radiography.

### Scintigraphy

Nuclear imaging is available in specialized centres. The bile flow, and therefore the degree of cholestasis, can be measured by analysing the hepatic uptake and transport time to the gall bladder of a  $^{99m}\text{Tc}$ -labelled iminodiacetate derivative. For quantitation of the bile flow, the sphincter of Oddi should be closed by administration of methadone so that activity is quantitatively collected and measured in the gall bladder. If patency of the opening of the common bile duct into the duodenum is examined, the same label can be used without methadone so that flow of activity into the duodenum can be visualized.

### Fine needle aspiration

Sampling of bile can be very informative and is often the only way to diagnose cholecystitis in dogs or neutrophilic cholangitis in cats. Sampled bile should undergo cytological examination for inflammatory or tumour cells or bacteria, and be cultured for growth and sensitivity testing of bacteria. Anaerobic as well as aerobic culture should also be performed in order not to overlook Clostridia or other anaerobes. Some bacteria are very hard or impossible to culture. If such bacteria (e.g. *Helicobacter*) are suspected a suitable polymerase chain reaction (PCR) test may reveal their presence, and may even be performed semi-quantitatively in specialized laboratories.

Centesis from the gall bladder can be done without risk when there is no common bile duct obstruction. A thin needle (20 or 22 gauge) is required, and puncture is performed under ultrasound guidance. There is no need to approach the gall bladder through the adjacent liver, as is sometimes advocated, in order to compress the gall bladder wall and stop possible bleeding. The gall bladder can be punctured in the corpus at any convenient site and several millilitres of bile aspirated. Sedation or (local) anaesthesia is not needed because the thin needle puncture is tolerated well. Only cats that are resistant to restraint in general may require sedation. Whereas puncture with a thin needle is without risk, puncture with a thick needle should be avoided. The gall bladder is richly innervated and trauma with a thick (e.g. liver biopsy) needle may produce vagotonia and shock within 10–15 minutes.

## Biliary diseases

Strictly interpreted, intra-hepatic cholestasis is a biliary disorder associated with many hepatic diseases (see Chapter 24) but only diseases of the larger bile ducts and gall bladder are dealt with in this chapter. Destructive cholangitis is the only strictly intra-hepatic biliary

disease discussed since it has a pure biliary pathogenesis, although there are additional repercussions in the hepatic parenchyma.

There have been different names and diagnostic criteria to diagnose and describe hepatobiliary diseases of dogs and cats. However, under the auspices of the World Small Animal Veterinary Association international standards for the nomenclature and diagnostic criteria of hepatobiliary diseases have been formulated. These names and diagnostic criteria are used here.

**Extra-hepatic bile duct obstruction**

Obstruction of the common bile duct occurs rarely in dogs. The site of the lesion is usually at the junction of the common bile duct and the duodenum, near Vater's papilla.

**Clinical signs**

The extra-hepatic bile duct obstruction must be complete or nearly complete for clinical signs to develop. Since there is no or almost no bile flow left, there is severe icterus in most cases. Bile duct dilatation is painful and may cause nausea, so a decreased appetite and vomiting are common. There may also be distinct polyuria and polydipsia.

**Pathogenesis**

There are many potential causes of common bile duct obstruction (Figure 25.2). The most frequent causes of obstruction are tumours of the pancreas or the duodenum. Pancreatic carcinomas tend to disseminate to the liver via the portal system. Bile duct carcinomas are usually highly malignant and spread rapidly in the liver via the lymphatic system and biliary tree.

Very chronic bile duct obstructions may be accompanied by so much fibrosis that fibrous connections between portal areas occur. This biliary fibrosis (strictly there is no disruption of the architecture so that the term cirrhosis is incorrect) may give rise to portal hypertension, ascites, portosystemic collateral circulation and hepatic encephalopathy. Biliary fibrosis is rare and incurable.

**Diagnosis**

**Biochemical investigation:** Bile duct obstruction causes hyperbilirubinaemia and is usually characterized by marked increases in serum ALP activity and hypercholesterolaemia. Milder increases in ALT are seen, and reflect hepatocyte damage caused by accumulation of toxic bile salts.

**Ultrasonography:** The diameter of the common bile duct is very small, so the lesion occluding it may also be very small, yet still cause complete blockade of the bile flow. Therefore it is not always possible to identify the underlying lesion with ultrasonography.

**Treatment**

**Medical management:** Surgical intervention should be preceded by haemostasis testing, since vitamin K deficiency may lead to a coagulopathy. This can be corrected by administering vitamin K1.

**Surgical management:** It is theoretically possible to perform a salvage procedure, cholecystoduodenostomy. This technique permits bile to flow to the duodenum through a direct connection made between the

Cause	Relative frequency	Treatment	Outcome
<b>Extraluminal compression</b>			
Pancreatitis	Most frequent	Often resolves spontaneously; surgery if persistent	Relatively good
Pancreatic carcinoma	Frequent	Surgery	Mostly poor
Duodenal lymphoma	Less frequent	Chemotherapy	Poor
Duodenal tumours (e.g. carcinoma)	Less frequent	None	Poor
Bile duct carcinoma	Infrequent	None	Poor
Diaphragmatic rupture with incarceration of bile duct	Infrequent	Surgery	Good
Miscellaneous: Duodenal foreign body Severe duodenitis	Rare	Surgery Steroids	Good Guarded
<b>Intraluminal obstruction</b>			
Gallstones	Less frequent	Surgery	Good
Mucinous hyperplasia (progestins)	Very infrequent	Antibiotics; stop progestins	Guarded
<b>Stricture of common bile duct</b>			
Secondary to trauma, inflammation	Very infrequent	Surgery	Relatively good
Congenital atresia	Very infrequent	Surgery	Relatively good

**25.2** Causes of extra-hepatic cholestasis in dogs, with relative frequency and prognosis.

gall bladder and the duodenum. This approach is quite complex and should probably be reserved for non-malignant conditions, such as stricture of the common bile duct. The complications after surgery are recurrent ascending infections via the relatively wide intestinal connection, so that such animals require antibiotic therapy with each new episode of postoperative cholangitis (as indicated by anorexia, nausea, vomiting or fever). Induction of increased bile flow by medication with ursodeoxycholic acid after surgery (15 mg/kg/day in two doses) may be helpful to reduce the risk of ascending bacterial infections. Ursodeoxycholic acid medication is contraindicated in the presence of bile duct obstruction.

### Bile duct rupture

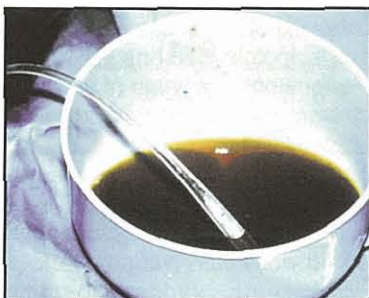Rupture of the extra-hepatic bile system may occur as a result of trauma, or due to weakening of the wall of the gall bladder (rarely the common bile duct) by necrotizing inflammation or tumour. Inflammation leading to spontaneous rupture is often related to the chronic presence of choleliths. Mucocoele of the gall bladder may occur in older dogs and lead to rupture in about half of the cases. Rupture of the bile system can be caused by trauma at any age. In most traumatic cases, one of the hilar ducts (draining bile from an entire liver lobe into the common bile duct) is disrupted from the common bile duct.

### Clinical signs

In all cases of bile duct rupture, bile accumulates in the peritoneal cavity. The high concentration of bile acid causes a severe chemical peritonitis within a few days. The dog becomes severely jaundiced because bilirubin is reabsorbed by the peritoneum. Fever and ascites with distension of the abdominal cavity are regular findings. Peritonitis is often complicated by bacterial infection caused by *Clostridium*, *Escherichia coli*, *Pseudomonas*, *Enterobacter* or other species of bacteria.

### Diagnosis

Diagnosis of a bile duct rupture is easy because abdominocentesis reveals free abdominal fluid, which is bile (Figure 25.3). After 1 or 2 days, the severe inflammatory reaction with leucocytes and haemorrhage results in a dirty, turbid, brown fluid that may be mistaken as indicating intestinal rupture. Culture and cytology are indicated to determine whether there is a potential bacterial infection.



**25.3** Bile peritonitis. Obvious bile-like fluid obtained by abdominocentesis in a dog 7 days after abdominal trauma and gall bladder rupture in a road traffic accident. (Courtesy of Edward Hall)

### Treatment

Treatment is surgical and successful in some cases. Ruptures of the bile duct may be repaired, but in cases where the hilar duct has been disrupted it may be easier to remove the entire lobe. If spontaneous rupture of the gall bladder is the cause, cholecystectomy is indicated to achieve complete recovery. Antibiotic treatment is indicated, either with amoxicillin and metronidazole or based on results of culture and sensitivity testing.

### Cholecystitis

Cholecystitis is a relatively rare condition in dogs.

### Clinical signs

Cholecystitis may be a very chronic disease but in most cases it presents as an acute disease with nausea, vomiting, abdominal pain, peripheral leucocytosis and a high neutrophil count. Jaundice is often present, but not in all cases since the common bile duct is usually patent. The reaction to endotoxins from the gall bladder produces a non-specific reactive hepatitis with intra-hepatic cholestasis, which is one cause of jaundice in these cases. Choleliths or inspissated bile may also cause common bile duct obstruction with icterus.

### Pathogenesis

The exact pathogenesis of cholecystitis is unknown. Certainly obstruction of bile flow, mucocoele and presence of choleliths or tumours are inciting factors, but these are not present in many cases. After cholecystoduodenostomy, the widened connection of the bile system with the duodenum enhances the risk of ascending infection. Cholecystitis may be a severe disease, and necrotizing and emphysematous inflammations are accompanied by signs of sepsis. These cases may easily develop spontaneous rupture of the gall bladder and bile peritonitis (see above).

### Diagnosis

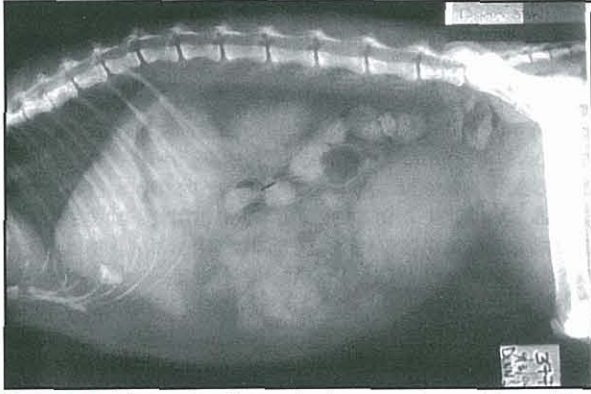
The diagnosis may be made with ultrasonography and cytological or bacteriological evaluation of bile. Any suspicion of an abnormal gall bladder wall at ultrasonography is an indication for fine needle aspiration. However, even when ultrasonography shows no abnormalities, cholecystitis cannot be excluded. The presence of the relevant signs and leucocytosis with high serum liver enzymes or bile acids may be a good indication to take a bile sample. Histology of a liver biopsy sample may reveal neutrophilic inflammation of the portal bile ducts, but the changes may be non-specific.

### Treatment

The treatment is with antibiotics. The combination of amoxicillin with metronidazole is the preferred initial treatment whilst awaiting culture and sensitivity test results. If the gall bladder is ruptured, it should be removed completely and not repaired. Recurrent cholecystitis can best be treated with cholecystectomy. This operation has no functional consequences.

### Cholelithiasis

Gallstones (Figure 25.4) can easily be recognized with ultrasonography. Most dogs and cats with cholelithiasis are asymptomatic and the stones are recognized incidentally. Canine and feline choleliths usually contain



**25.4** A lateral radiograph of a cross-breed dog with a radiodense cholelith lying within the gall bladder close to the ventral border of the liver. (Courtesy of James Simpson)

little calcium, but are composed of bilirubin and cholesterol. These stones are dark brown or black, and soft. Inflammation of the gall bladder promotes formation of stones and *vice versa*. There is often bacterial infection of the gall bladder in symptomatic cases, so sampling of bile and cytology with culture should be performed.

Symptomatic cases have signs of abdominal pain, nausea and vomiting. Liver enzymes and bile acids may be increased, and there is often leucocytosis. Both aerobic and anaerobic culture may be positive. Treatment is only necessary for symptomatic cases. If there is bacterial infection antibiotics should be given (see Cholecystitis). Non-calcified stones may resolve in response to oral medication with ursodeoxycholic acid for several months; resolution can be monitored with ultrasonography. Unresponsive cases with recurring clinical signs should be treated surgically, and it is advisable to perform a cholecystectomy instead of the more conservative cholecystotomy to remove the choleliths. The prognosis is usually very good.

## Canine cholangitis

### Destructive cholangitis

Destructive cholangitis is a disease only known in dogs and is caused by an idiosyncratic reaction to drugs (nearly always sulphonamides in one form or another). The reaction is always very acute, and usually associated with prolonged or repeated medication with trimethoprim-sulpha or another sulphonamide. There is acute necrosis of the bile ducts in the smaller portal areas. The smallest ducts of the biliary system are not visible with ultrasonography and the diagnosis relies entirely on histological evaluation of a liver biopsy sample. In very acute cases the changes may not have become specific enough for a certain diagnosis and then a repeat biopsy is needed in 5–7 days. The complete or partial vanishing of bile ducts causes very severe (intra-hepatic) cholestasis, resulting in severe icterus. The reduction of the bile flow may be so complete that the gall bladder is more or less empty, which is invariably abnormal.

The occurrence of acute disease with severe jaundice in dogs treated with any sulphonamide should prompt immediate discontinuation of this drug. Swift treatment with prednisolone (2 mg/kg/day divided over two doses for 1 week) and ursodeoxycholic acid

(15 mg/kg/day, divided over two doses) may help to reduce bile epithelial necrosis as much as possible. Ursodeoxycholic acid is used to increase bile flow in the remaining bile ducts, which may help to prevent accumulation of toxic bile acids that would aggravate the disease.

The prognosis is often poor, but depends very much on early recognition. After 8–12 weeks the disease has stabilized and at that stage a renewed biopsy reveals the extent of permanent damage by evaluation of the fraction of portal tracts with or without a bile duct. The injured bile ducts do not regenerate, and so patients may require lifelong medication with ursodeoxycholic acid even though there is not ongoing damage. This unusual absence of regenerative capacity in the liver may be a reflection of the fact that multipotent stem cells of the liver actually normally reside in the affected region.

## Feline cholangitis

In dogs diseases of the larger bile system are relatively rare and true liver diseases, such as hepatitis, are frequent. Cats are distinctly different because (excluding hepatic lipidosis) they have predominantly diseases of the bile ducts rather than parenchymal hepatic disease. Inflammatory liver diseases in cats are in fact biliary diseases. The primary site of the disease is the bile system and if the liver becomes involved it is only secondary and confined to the portal tract area as an overflow from the portal bile ducts. Therefore, these inflammatory processes should be termed cholangitis, and not hepatitis or cholangiohepatitis. There are many synonyms for these diseases, but in fact there are only three forms of feline cholangitis and the standardized names are now:

- Neutrophilic cholangitis
- Lymphocytic cholangitis
- Cholangitis due to liver flukes.

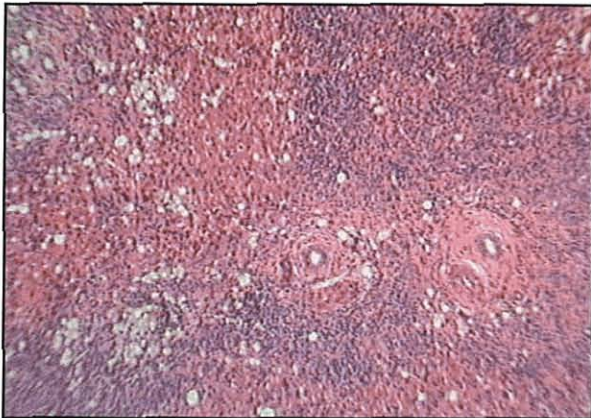
Examples of the profusion of adjectives for these three forms, and used in arbitrary combination with cholangitis or cholangiohepatitis, are *suppurative*, *non-suppurative*, *mixed* (neutrophilic–lymphocytic), *lymphocytic–plasmacytic*, *exudative*, *lymphocytic*, *chronic* or *progressive lymphocytic*, *pericholangiohepatitis*, *sclerosing cholangitis*, *portal hepatitis* and *biliary cirrhosis*.

### Neutrophilic cholangitis

Neutrophilic cholangitis is most likely due to an ascending infection from the intestinal tract. It presents usually as an acute disease with signs of sepsis and cholestasis. It causes signs of malaise, inappetence, vomiting, occasionally fever and often jaundice. Neutrophilic cholangitis is a common disease in cats.

The neutrophilic inflammation of the bile system is mostly reflected in the results of laboratory examination by the presence of leucocytosis with neutrophilia, increased bile acids, alanine aminotransferase (ALT), GGT and bilirubin. Ultrasonography usually reveals no specific abnormalities; occasionally oedema of the gall bladder wall may be visible as a black line. The inflammation causes a non-specific reaction in the liver, but in most cases histology of a biopsy sample

reveals the presence of neutrophils in the lumen and epithelium of the portal bile duct walls. In acute cases there may be oedema in the portal tract. Neutrophilic inflammation may spill over into the portal tract and in severe cases even into the surrounding liver parenchyma (Figure 25.5). When the process becomes more chronic the inflammatory cell type in the portal tracts changes slightly to a mixed infiltrate of neutrophils, lymphocytes and plasma cells.



**25.5** Section of hepatic parenchyma from a jaundiced dog, demonstrating obliteration of most of the normal liver architecture, particularly periportally. A marked inflammatory cell infiltrate is evident periportally and extending well into parenchyma; comprising predominantly neutrophils with some macrophages. The histopathological diagnosis was severe neutrophilic cholangitis. H&E stain, original magnification x500. (Courtesy of Emma O'Neill)

The primary site of infection is the lumen of the bile ducts, and the diagnosis is based on examination of bile, sampled under ultrasound guidance, from the gall bladder. Cytology reveals many neutrophils and often also bacteria. Culture identifies the underlying bacteria, which are usually *Escherichia coli*. Histology of a liver biopsy specimen usually confirms the diagnosis, but may be useful to rule out an underlying lymphocytic cholangitis.

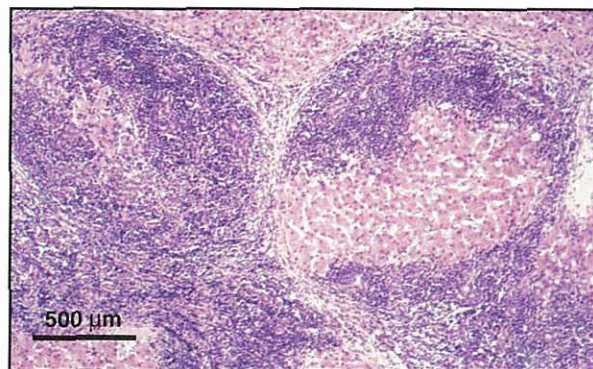
Antibiotic sensitivity testing is needed, but a good first choice antibiotic therapy is amoxicillin. Treatment should be given for long enough to eliminate the organism; i.e. preferably over 3 to 4 weeks. The prognosis is good when treatment is started early enough. Very chronic cases are much harder to treat.

### Lymphocytic cholangitis

This form of cholangitis behaves very differently from the neutrophilic form. There is no acute onset of the disease and when cats first present with signs they are already in the chronic stage. This is one of the most chronic diseases encountered in cats, and many cases progress slowly for 6 months to several years. Lymphocytic cholangitis occurs quite regularly in cats, although there seems to be a variable relative frequency of occurrence in different countries. In the UK there is a clear predisposition in Persians. Cats with this disease have variable signs but generally have a reduced appetite, vomit occasionally and gradually lose weight. The progress is often so slow that the owner only recognises problems at an advanced stage of disease.

The disease primarily affects the larger bile ducts and results in irregular distension and thickening of the wall of the larger intra-hepatic and the extra-hepatic bile ducts. The common bile duct, which normally is 2 mm in diameter, may become as wide as 3 cm, with narrower constrictions and tortuosity in-between. The bile ducts usually remain patent, although less functional. The wide and irregular appearance of the ducts on ultrasonography is identical to what can be seen in cases of chronic extra-hepatic cholestasis. Differentiation is only possible with histological evaluation of a liver biopsy sample, where the changes seen in obstructive disease are distinctly different from those of lymphocytic cholangitis.

Liver histology shows moderate to severe infiltration of the portal tracts with small lymphocytes, which may also be present in the lumen and epithelium of the bile ducts (Figure 25.6). There is a tendency to fibrosis and in very chronic cases strands of fibrous tissue may connect the different portal areas. The large numbers of lymphocytes in the portal areas may often give the impression of lymphoma; however, lymphoma does not produce the typical ultrasonographic appearance of cholangitis. Most, but not all, cats develop icterus. They may become very thin, depending on the stage of the disease, but tend to do relatively well for long periods. Blood examination reveals increased bile acids and ALT in most cases. These values may, however, also be in the reference range. Nearly all cases have (often distinctly) increased globulins, mainly gamma globulin. The serum protein spectrum is often as abnormal as in cats with feline infectious peritonitis (FIP), which therefore is one of the main differential diagnoses. Ultrasonography in combination with the typical histology of the liver is diagnostic.



**25.6** Histological appearance of lymphocytic cholangitis in a middle-aged Domestic Short-hair cat, showing a lymphocytic infiltrate centred on the portal areas. H&E stain. (Courtesy of Michael Day)

This is a very difficult disease to treat. It is usually advised to give prednisolone, but in the author's experience it often has no notable effect, even with prolonged high doses. Therefore, the author omits steroids completely for this disease and uses ursodeoxycholic acid. This bile acid has several effects that should be beneficial for affected cats. First, the bile flow is increased, which may help to avoid the bile becoming too viscous; viscous bile can aggravate cholestasis. Second, it has distinct anti-inflammatory effects, in part

explained by reduction of lithocholic acid in the bile acid pool. In the author's experience cats may improve considerably with ursodeoxycholic acid, but need very long-term or sometimes lifelong treatment. Extra-hepatic bile duct obstruction should be excluded before giving ursodeoxycholic acid.

There is no known aetiology, but with a specific PCR *Helicobacter* has been found in many of these cats. However, there is no proof yet that this is the cause of the disease. Cats with other diseases, such as neutrophilic cholangitis, may also have an identical strain of *Helicobacter* in their bile, although this has been reported less frequently. The author has treated three cats in very poor condition from end-stage lymphocytic cholangitis with intra-biliary injection of antibiotics (into the gall bladder). Two of the cats recovered completely, started eating and remained well, although their bile ducts still appeared distended on ultrasonography. This could indicate a bacterial pathogenesis, although bacterial culture is routinely negative. Clearly, more research into the pathogenesis is needed before better treatment becomes possible for this unrewarding disease.

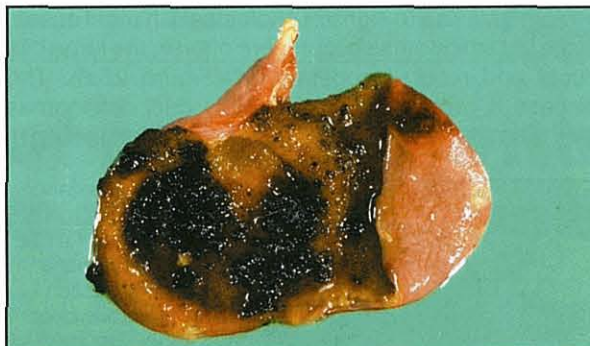#### Cholangitis due to liver flukes

A variety of liver flukes throughout the world may cause a chronic inflammation of the bile ducts in cats. Cats can ingest metacercariae by eating infected raw fish. The migrating larvae invade the bile ducts and cause chronic inflammation. The bile ducts become wide and tortuous as in lymphocytic cholangitis or bile duct obstruction. Histologically, the liver lesions are slightly different from those of lymphocytic cholangitis. In the portal areas fibrosis and inflammation inside and around the bile ducts is evident, but the inflammatory cell type is less monotonous. There are not only lymphocytes, but also some plasma cells, neutrophils and eosinophils. Sometimes liver fluke eggs with their typical polar capsule can be found histologically in the bile ducts. The preferred treatment is with praziquantel, and the prognosis is reasonably good.

#### Neoplasia

##### Mucocele and cystic mucinous hyperplasia

In older dogs hyperplasia of the epithelium of the gall bladder wall may occur. The same lesion, more or less pronounced, may be present in the common bile duct and cystic duct. There is extreme production of mucin so the gall bladder becomes largely distended and filled with a thick green or light brown mucinous content. The exact pathogenesis is not clear, but it is known that long-term progestin treatment may induce this change. This condition may be subclinical for a long time, but secondary neutrophilic cholecystitis with bacterial infection is common (Figure 25.7). Affected dogs may develop signs similar to those of cholecystitis. The gall bladder wall may easily rupture causing bile peritonitis. In rare cases hyperplasia of common bile duct epithelium also causes bile duct obstruction. The diagnosis can be made with ultrasonography. Treatment is by cholecystectomy in combination with antibiotic therapy. The prognosis is good.



**25.7** Mucosal surface of the gall bladder removed from a 10-year-old Springer Spaniel with recurrent bacterial cholecystitis, showing gall bladder enlargement, thickening of the wall and cystic mucinous hyperplasia. (Courtesy of Edward Hall)

#### Cystic disease

Cysts in the liver invariably arise from the bile ducts and are lined by a single layer of biliary epithelium. There can be large solitary cysts and multiple small cysts. These cysts are spaces filled with watery fluid or mucus, and vary in size from a few millimetres to approximately 10 cm. Both large and small cysts occur in dogs and cats.

Caroli's disease is the irregular dilatation with fibrosis of the larger intra-hepatic ducts. There is often calcification of bile duct walls. Affected dogs also have cystic renal lesions that may be calcified, and involve the collecting ducts, which gives them a radial appearance. Another form consists of diffuse small cysts, often at a microscopic level, with liver fibrosis and accompanied by multiple small round cysts of the kidneys. The third form has one or a few large solitary cysts in the liver, but no involvement of the kidneys.

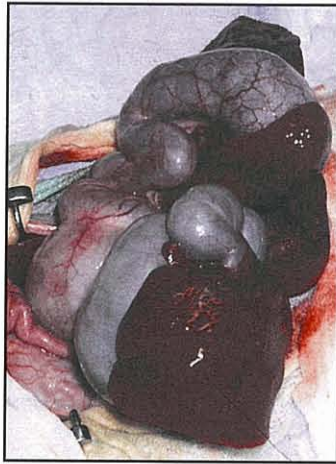
Cystic liver disease is usually subclinical. However, the cysts may become infected and cause general signs of malaise, vomiting and fever. Single large cysts may become so big that displacement of the stomach causes nausea and vomiting. Persian cats have a high frequency of autosomal dominant polycystic kidney disease. These cats also have liver fibrosis and (microscopic) liver cysts that may not be visible with ultrasonography. Fibrosis associated with cystic liver may be so pronounced that it causes severe portal hypertension, portosystemic collateral shunting and ascites. Such cases may mimic portal vein hypoplasia or cirrhosis.

The diagnosis is made with ultrasonography for the larger cysts, although liver histology is needed to classify the subtype. Renal function tests and kidney biopsy are required to complete the diagnosis, and conversely in animals with cystic kidney disease, a liver biopsy is needed to determine involvement of the liver. Biliary cystic disease is congenital and medical management is restricted to treatment of secondary infections with antibiotics (see Cholecystitis). Single large cysts may be removed surgically, in which case the prognosis is good.

#### Carcinoma

Carcinomas of the biliary epithelium occur infrequently. They may arise from the extra- or intra-hepatic bile ducts and readily metastasize to the liver and other organs. The multiple metastases throughout the biliary

system give rise to signs of cholestasis in most cases. In the cat carcinomas occur more often in the large bile ducts and result in obstruction (Figure 25.8). The disease is rapidly progressive. Bile duct carcinomas may also form cystic lesions (cystadenocarcinoma).



**25.8** Appearance at surgery of the biliary tract of a cat with an extra-hepatic bile duct obstruction caused by a bile duct carcinoma. (Courtesy of Susan Bunch)

There is often widespread infiltration of the tumour within the liver, which causes enlargement of the liver and jaundice. Animals with these tumours are unwell, eat less and tend to vomit. The diagnosis is made by histological examination of a liver biopsy sample, which should be taken under ultrasound guidance in order not to miss the disease process. In most cases no treatment is possible by the time the tumour becomes symptomatic; chemotherapy is ineffective.

### Adenoma

As an incidental finding, ultrasonography or laparotomy may reveal a benign circumscribed tumour that is paler than normal liver and contains several small cystic lesions. This is the typical appearance of a bile duct adenoma, which has a benign behaviour and is usually not associated with clinical signs. The diagnosis can only be made with histological examination of a biopsy sample collected under guidance.

### Double gall bladder

In the dog, and more often in the cat, there is sometimes a double gall bladder. Although the emptying of the gall bladder is not optimal and there is a local stasis of bile, this disorder almost never leads to clinical problems. The condition may be detected by abdominal ultrasonography or at surgery.

## References and further reading

- Abiru H, Sarna SK and Condon RE (1994) Contractile mechanisms of gallbladder filling and emptying in dogs. *Gastroenterology* **106**, 1652–1661
- Adler R and Wilson DW (1995) Biliary cystadenoma of cats. *Veterinary Pathology* **32**, 415–418
- Anwer MS and Meyer DJ (1995) Bile acids in the diagnosis, pathology, and therapy of hepatobiliary diseases. *Veterinary Clinics of North America: Small Animal Practice* **25**, 503–517
- Besso JG, Wrigley RH, Gliatto JM and Webster CRL (2000) Ultrasonographic appearance and clinical findings in 14 dogs with gallbladder mucocele. *Veterinary Radiology and Ultrasound* **41**, 261–271
- Bromel C, Barthez PY, Leveille R and Scrivani PV (1998) Prevalence of gallbladder sludge in dogs as assessed by ultrasonography. *Veterinary Radiology and Ultrasound* **39**, 206–210
- Center SA, Erb HN and Joseph SA (1995) Measurement of serum bile acids concentrations for diagnosis of hepatobiliary disease in cats. *Journal of the American Veterinary Medical Association* **207**, 1048–1054
- Center SA, Slater MR, Manwarren T and Prymak K (1992) Diagnostic efficacy of serum alkaline phosphatase and gamma-glutamyltransferase in dogs with histologically confirmed hepatobiliary disease: 270 cases (1980–1990). *Journal of the American Veterinary Medical Association* **201**, 1258–1264
- Day MJ (1998) Immunohistochemical characterization of the lesions of feline progressive lymphocytic cholangitis/cholangiohepatitis. *Journal of Comparative Pathology* **119**, 135–147
- Friman S, Radberg G, Bosaeus I and Svanik J (1990) Hepatobiliary compensation for the loss of gallbladder function after cholecystectomy. An experimental study in the cat. *Scandinavian Journal of Gastroenterology* **25**, 307–314
- Funch-Jensen P and Sorensen SS (1991) Influence of graded distension of the gallbladder on sphincter of Oddi activity in dogs. *Digestive Diseases* **9**, 408–413
- Furukawa N and Okada H (1992) Effects of selective vagal stimulation on the gallbladder and sphincter of Oddi and peripheral vagal routes mediating bile evacuative responses induced by hypothalamic stimulation. *Japanese Journal of Physiology* **42**, 321–334
- Gagne JM, Armstrong PJ, Weiss DJ, Lund EM, Feeney DA and King VL (1999) Clinical features of inflammatory liver disease in cats: 41 cases (1983–1993). *Journal of the American Veterinary Medical Association* **15**, 513–516
- Gagne JM, Weiss DJ and Armstrong PJ (1996) Histopathologic evaluation of feline inflammatory liver disease. *Veterinary Pathology* **96**, 521–526
- Gorlinger S, Rothuizen J, Bunch S and van den Ingh TS (2003) Congenital dilatation of the bile ducts (Caroli's disease) in young dogs. *Journal of Veterinary Internal Medicine* **17**, 28–32
- Kirpensteijn J, Finland RB, Ulrich T, Sikkema DA and Allen SW (1993) Cholelithiasis in dogs: 29 cases (1980–1990). *Journal of the American Veterinary Medical Association* **202**, 1137–1142
- Leveille R, Biller DS and Shiroma JT (1996) Sonographic evaluation of the common bile duct in cats. *Journal of Veterinary Internal Medicine* **10**, 296–299
- Ludwig LL, McLoughlin MA, Graves TK and Crisp MS (1997) Surgical treatment of bile peritonitis in 24 dogs and 2 cats: a retrospective study (1987–1994). *Veterinary Surgery* **26**, 90–98
- Mayhew PD, Holt DE, McLear RC and Washabau RJ (2002) Pathogenesis and outcome of extrahepatic biliary obstruction in cats. *Journal of Small Animal Practice* **43**, 247–253
- Neer TM (1992) A review of disorders of the gallbladder and extrahepatic biliary tract in the dog and cat. *Journal of Veterinary Internal Medicine* **6**, 186–192
- Nyland TG, Koblik PD and Tellyer SE (1999) Ultrasonographic evaluation of biliary cystadenomas in cats. *Veterinary Radiology and Ultrasound* **40**, 300–306
- Ohta T, Nagakawa T, Tsukioka Y, Sanada H, Miyazaki I and Terada T (1992) Proliferative activity of bile duct epithelium after bacterial infection in dogs. *Scandinavian Journal of Gastroenterology* **27**, 845–851
- Ohta T, Nagakawa T, Ueda N, Nakamura T, Kayhara M, Ueno K, Miyazaki I, Terada T and Nakanuma Y (1991) Adenomatous hyperplasia of the bile duct epithelium of the canine liver, caused by bacterial infection. *Scandinavian Journal of Gastroenterology* **26**, 1107–1114
- Parchman MB and Flanders JA (1990) Extrahepatic biliary tract rupture: evaluation of the relationship between the site of rupture and the cause of rupture in 15 dogs. *Cornell Veterinarian* **80**, 267–272
- Rege RV and Prystowsky JB (1996) Inflammatory properties of bile from dogs with pigment gallstones. *American Journal of Surgery* **171**, 197–201
- Rothuizen J, van Papendrecht R and Van den Brom WE (1990) Post prandial and cholecystokinin-induced emptying of the gall bladder in dogs. *Veterinary Record* **126**, 505–507
- Rothuizen J and van den Brom WE (1990) Quantitative hepatobiliary scintigraphy as a measure of bile flow in dogs with cholestatic disease. *American Journal of Veterinary Research* **51**, 253–256
- Rothuizen J, van den Brom WE and Fevery J (1992) The origins and kinetics of bilirubin in dogs with hepatobiliary and haemolytic diseases. *Journal of Hepatology* **15**, 17–24
- Savary-Bataille KC, Bunch SE, Spaulding KA, Jackson MW, Mac Law J and Stebbins ME (2003) Percutaneous ultrasound-guided cholecystocentesis in healthy cats. *Journal of Veterinary Internal Medicine* **17**, 298–303
- Van den Ingh TS, Rothuizen J and van den Brom WE (1986) Extrahepatic cholestasis in the dog and the differentiation of extrahepatic and intrahepatic cholestasis. *Veterinary Quarterly* **8**, 150–157
- Yokohata K, Kimura H, Ogawa Y, Naritomi G and Tanaka M (1994) Biliary motility. Changes in detailed characteristics correlated to duodenal migrating motor complex and effects of morphine and motilin in dogs. *Digestive Diseases and Sciences* **39**, 1294–1301

# Critical care of patients with gastrointestinal disease

Maureen McMichael

## Introduction

Recent advances in the monitoring, management and pharmacological treatment of critically ill animals with gastrointestinal (GI) diseases have enhanced the chances of survival. The goals of the intensive care unit (ICU) patient care team are to provide excellent monitoring and nursing care, and to prevent complications that result from anorexia, inactivity, the presence of invasive lines (i.e. catheters, feeding tubes, chest tubes, etc.) and from the primary disease itself.

Some of the more common complications that can occur in critically ill GI patients include:

- Venous thromboembolism
- Stress- and drug-related upper GI bleeding
- Catheter-related infections.

In addition, sepsis (from bacterial translocation, intestinal perforation and immunosuppression), hypoglycaemia (hepatic failure, sepsis) and pulmonary thromboembolism (decreased antithrombin, pancreatitis) may adversely affect patient survival. These patients are predisposed to bacterial translocation because of the use of multiple antibiotics (disruption of the balance of the normal GI microflora), the use of parenteral nutrition (decreased delivery of nutrients to the enterocytes), the presence of hypotension (decreased GI perfusion) and their generally poor underlying nutritional status (decreased intestinal barrier function).

With optimal monitoring, supportive care and an index of suspicion many of these complications can either be avoided or discovered early and rectified before significant damage ensues.

## Role of the gut in multiple organ failure

Death in the ICU is often related to multiple organ failure (MOF). In humans, MOF has a mortality rate from 40% to 100%, proportional to the number of affected organs. The GI tract is believed to be crucial to the pathogenesis of MOF. Its importance was first proposed in response to the observation of a number of patients dying of MOF with sepsis but no focus of infection. Underlying bacterial translocation across the GI tract was suspected, referring to the passage of microbes from the GI lumen to the bloodstream, and then to other sites. The GI tract

contains numerous and diverse bacterial populations and the movement of even small numbers of bacteria can have devastating results. Movement of microbes can occur through several different routes including microscopic defects in the GI epithelium and enterocyte uptake. Resident microbial flora and the local gut-associated lymphoid tissue (GALT) are key to prevention of this abnormal translocation of microbes.

A 'two hit' model of MOF has been proposed. The first or priming hit causes the immune system to initiate an exaggerated inflammatory response during the subsequent second hit. Priming can be caused by many clinical conditions including hypoperfusion or infection. GI tract hypoperfusion may invoke an ischaemic phase with subsequent reactive oxygen species (ROS) generation upon reperfusion. Studies suggest that ischaemia reperfusion (IR) injury of the mesentery results in the generation of ROS, which attract neutrophils. Neutrophils then generate more ROS, creating a vicious cycle that perpetuates the damage. One hypothesis is that IR injury of the GI tract primes the immune system allowing a relatively low dose of endotoxin to activate a systemic inflammatory response and MOF.

Although debate remains about whether bacterial translocation is clinically relevant, maximizing the health of the GI tract (e.g. by enhancing perfusion, feeding the enterocytes) should be an early goal of a proactive ICU team.

## General supportive measures

Since no single physiological value can convey all aspects of an animal's status, several variables are frequently monitored in an attempt to give a global picture of the animal's well-being. Monitoring should be thought of as supplementing the findings of physical examination with objective data. There are several crucial parameters that should be monitored frequently in critically ill animals (Figure 26.1).

## Analgesia

Assessment of pain is essential, although an optimal pain-scoring system has not been formulated. Many animals will not show 'classic' signs of pain but still may be in severe pain. Generally, if an animal has either a painful disease or has had a painful procedure it should receive analgesics. Adequate analgesia has been shown to decrease morbidity and mortality in many diseases.



**Clinical parameters**

Heart rate; rhythm; pulse quality  
 Respiratory rate and effort; lung sounds  
 Body temperature  
 Blood pressure and central venous pressure  
 Oxygenation (pulse oximetry,  $PaO_2$ )  
 Perfusion (urine output, lactate, peripheral temperature)

**Laboratory parameters**

Coagulation indices  
 Complete blood count  
 Serum biochemical profile  
 Acid-base and lactate concentration  
 Electrolyte status  
 Haematocrit; total protein; azotaemia; glucose

**Clinical assessment of perfusion**

Urine output  
 Peripheral temperature  
 Pulse quality  
 Mucous membrane refill time  
 Mentation

**Laboratory assessment of perfusion**

Blood lactate  
 Oxygen delivery ( $DO_2$ )  
 Oxygen uptake ( $VO_2$ )  
 Oxygen extraction ( $O_2ER$ )  
 Gastric tonometry

**26.1** Essential monitoring in critically ill animals.

Several new options for pain management are available including transdermal fentanyl, oral morphine and COX-1-sparing non-steroidal anti-inflammatory drugs. Readers are referred to Hansen (2000) for in-depth coverage of analgesia.

**Vital signs**

Vital signs include: body temperature; heart rate (HR) and rhythm; and respiratory rate (RR) and effort. Generally body temperature is monitored less frequently than HR and RR; usually every 8 hours unless specific concerns exist. The HR can be assessed continuously with an electrocardiogram (ECG) monitor and ECG pads placed on the animal. This allows continuous monitoring for dangerous dysrhythmias, such as ventricular tachycardia or third degree atrio-ventricular block, which may need immediate correction. RR and effort are usually assessed every hour in critically ill patients that are not oxygenating appropriately. Arterial blood pressure can serve as an index of circulatory status but is not specific since it can increase with pain, fear, anxiety, stress and increased intracranial pressure. Hypotension can reflect hypovolaemia but it can also accompany sepsis, late stages of shock and anaphylactic reactions. Arterial blood pressure can be measured directly and most accurately by insertion of an arterial catheter, or indirectly by use of Doppler-based or oscillometric detectors. When using indirect methods the cuff width should be 40% of the circumference of the limb. Cuffs that are too narrow may give falsely elevated values and cuffs that are too wide falsely low values.

**Perfusion**

Perfusion is one of the most crucial parameters to monitor in critically ill patients. Evaluation of perfusion can be done using both clinical and laboratory parameters (Figure 26.2).

Central venous pressure and arterial blood pressure are often used to supplement other data in the determination of adequate fluid volume.

Urine output is one of the single most important parameters of perfusion for the critically ill animal. Urine output should remain above 1–2 ml/kg/h. A common

**26.2** Perfusion indices in small animals.

cause of apparent oliguria is an obstructed urinary catheter and so every effort should be made to troubleshoot the equipment (i.e. flush the urinary catheter, replace if questionable) before declaring oliguria or anuria. Since in the absence of renal disease urine output is a rough estimate of perfusion, decreased urine output in the face of adequate volume suggests decreased perfusion to the kidneys and other organs (such as the GI tract). If urine output decreases the clinician should rule out decreased blood volume (assess central venous pressure (CVP), haematocrit (HCT), total solids), decreased cardiac output (assess with an echocardiogram) and the onset of renal failure (assess azotaemia, urine specific gravity, presence of casts).

The peripheral temperature or the core-web gradient (i.e. the difference between the core temperature and the temperature of the extremities or the 'web' of the digits) can be used to gauge peripheral perfusion along with pulse quality and mucous membrane refill time.

CVP is an indicator of volume status and can be used to assess vascular volume if cardiac function is normal. Adequate volume does not necessarily mean that perfusion is adequate, however, since vasoconstriction and decreased cardiac output can both impair perfusion in the face of adequate volume.

Of the laboratory indices of perfusion (see Figure 26.2), venous lactate is most practical to evaluate since it is non-invasive, easily obtained, inexpensive, easily interpreted and is a very good index of perfusion in most circumstances. When perfusion is decreased there is decreased tissue oxygenation, a shift to anaerobic metabolism and increased lactate production. Venous lactate in healthy adult dogs is normally <2.0 mmol/l.

Measurement of oxygen delivery ( $DO_2$ ), oxygen uptake ( $VO_2$ ) and oxygen extraction ( $O_2ER$ ) require the insertion of a pulmonary arterial catheter and are rarely practical options. Gastric tonometry is also impractical for technical reasons in most veterinary hospitals.

**Electrolyte status**

Hyponatraemia signifies relative water excess and can occur in animals with liver disease. Rapid initial correction of chronic hyponatraemia can lead to central pontine demyelination with severe neurological manifestations. Clinical signs develop several days after rapid correction

of hyponatraemia and include weakness, ataxia, hypermetria and paresis. Patients with chronic hyponatraemia are often asymptomatic and acute hyponatraemia is very rare in veterinary medicine. Patients with symptomatic chronic hyponatraemia (i.e. seizures, cerebral oedema) should have their sodium increased by less than 10–12 mmol/l over 24 hours. Asymptomatic patients with hyponatraemia can have their sodium corrected slowly by mild water restriction if they are not hypovolaemic. It should be noted that volume restoration alone can correct the hyponatraemia if the patient is hypovolaemic since it will eliminate the stimulus for vasopressin release and allow the animal to excrete free water. In animals with oedema and hyponatraemia, diuretics may help rectify the 'water excess'.

Hypokalaemia is common in critically ill animals and can impair renal concentrating mechanisms leading to polyuria and polydipsia. Cardiac, smooth and skeletal muscle dysfunction may lead to cardiac dysrhythmias, delayed GI transit and generalized weakness. Treatment usually involves supplementation of intravenous fluids at a rate not to exceed 0.5 mmol/kg/h. Magnesium is required for potassium transport across cell membranes and the enzyme  $\text{Na}^+ \text{K}^+$  adenosine triphosphatase has an absolute requirement for magnesium, contributing to excess potassium loss during periods of hypomagnesaemia. In cases of refractory hypokalaemia, magnesium sulphate should be started as a constant rate infusion (CRI) at 1 mmol/kg over 24 hours.

Disorders of calcium occur commonly in cats with pancreatitis. Hypocalcaemia can result from calcium soap deposition or from derangements in parathyroid hormone levels. Hypercalcaemia has also been reported but is rare.

### Infection surveillance

Critically ill animals are at an increased risk for nosocomial infection due to their immunosuppressed state, inactivity and the presence of numerous invasive lines (e.g. catheters). In addition, anorexia, vomiting and diarrhoea all increase the risk of infection. Infection control measures include: careful monitoring of all catheter sites several times daily for signs of warmth, pain or swelling; monitoring for pyrexia; and evaluation of frequent complete blood counts for evidence of infection.

Any new fever should prompt an immediate search for the cause. If no cause is apparent, blood should be collected for bacteriological culture and antibiotic sensitivity testing. Broad spectrum antibiotics are warranted in all critically ill animals with evidence of infection (pyrexia, leucocytosis or leucopenia, swollen catheter site). Ideally samples for bacteriological culture should be obtained prior to administration of antibiotics.

The patient should be cleaned and bandages changed as needed. The environment (cages, floors, the entire ICU) must be kept clean and free of contamination. At the first sign of infection any questionable invasive line (i.e. venous catheter, urinary catheter) should be removed and the tip cultured. If another line is needed this should be placed aseptically. Infection control is of utmost importance in critically ill animals and efforts must be made to recognize and treat impending infection as quickly and effectively as possible.

## Specific disorders

### Gastric dilatation volvulus

Gastric dilatation and volvulus (GDV) is defined as the progressive dilatation and rotation of the stomach. It is most often seen in large-breed, deep-chested dogs and the cause is unknown.

The rotation and dilatation of the stomach cause compression of the caudal vena cava and portal vein leading to systemic vascular compromise. Hypovolaemia occurs due to a combination of blood loss (short gastric arteries and splenic vessels often torn during rotation) and fluid loss into the distended stomach. There is decreased perfusion and therefore decreased oxygen delivery to the GI tract, which can precipitate sepsis from bacterial translocation. Gastric necrosis may also be seen and if perforation of the stomach occurs this can lead to peritonitis and systemic sepsis. Decreased oxygen delivery to all tissues occurs, leading to a systemic hypoperfused state, shock and eventually death if left untreated.

### Monitoring

HR and rhythm, RR, peripheral pulse quality, mucous membrane colour and refill time, pulse oximetry and blood pressure are recorded as soon as possible. Ideally a minimum database consisting of HCT, total solids, blood glucose, electrolytes, azostix and lactate is collected. Lactate concentration has been shown to be prognostic. A lactate concentration of >6 mmol/l was associated with 58% survival while a lactate concentration of <6 mmol/l was associated with 99% survival in one study carried out at the University of Pennsylvania. Lactate concentrations can be measured easily with an inexpensive handheld monitor, although this machine has not yet been validated in dogs. Preliminary studies by the author indicate that it is accurate for following trends. If possible a complete blood count, biochemical profile, coagulation profile and urinalysis are also collected.

### Treatment

Initial treatment is focused on maximizing perfusion and oxygenation. Intravenous fluids are given via two large bore (14–18 gauge) peripheral catheters. One-third to one-half of a shock dose (i.e. 30–45 ml/kg) of isotonic crystalloids is given rapidly and haemodynamic status is re-assessed. If the HR and blood pressure are normalizing, the remainder of the shock dose (i.e. 90 ml/kg total) is given over the next 1–2 hours. If the initial bolus does not improve the haemodynamic status, the remainder of the shock dose is given rapidly. Colloids, which remain in the vasculature much longer than crystalloids, are added to the crystalloid infusion in cases where the partial crystalloid bolus fails to improve the haemodynamic status. Hetastarch is the colloid used most frequently unless coagulation abnormalities indicate the need for fresh frozen plasma. When colloids are used the dose of crystalloids is decreased by 40%. Improvement is indicated by normalization of HR, blood pressure, increased urine output, improved mentation and a decreased lactate concentration.

Gastric decompression is most easily done by trocharization. Trocharization does not require sedation, is rapid and easy to learn. An 18 gauge over-the-needle catheter is inserted into the gas-filled fundus (the area with the loudest 'ping'), which is often found on the right-hand side in dogs with GDV. All gas that can be aspirated and the catheter is removed. After initial stabilization, right lateral radiography is used to confirm the diagnosis. Broad spectrum antibiotics are given due to the high risk of sepsis in these cases.

Surgical correction of GDV is described elsewhere (see Chapter 19 and *BSAVA Manual of Canine and Feline Abdominal Surgery*). The postoperative goals are to maximize oxygen support and perfusion and to provide analgesia. Oxygen supplementation can be given at an FiO<sub>2</sub> of 40% for 24 hours to optimize oxygenation. Fluid therapy comprises either crystalloids alone or a combination of crystalloids and colloids depending on the haemodynamic status of the patient. In stable patients crystalloids alone are often enough, while in hypotensive or hypoperfused patients the author uses a combination of crystalloid and colloid. For analgesia a combination of an opioid (fentanyl CRI) combined with either lidocaine or ketamine is started. If the combination of fentanyl and lidocaine is not sufficient ketamine is added (or vice versa).

Cardiac dysrhythmias and coagulation abnormalities are two of the most common postoperative complications. If coagulation abnormalities are detected clinically (i.e. bleeding, oozing from incision) or on the coagulation panel (i.e. prolonged activated partial thromboplastin time (aPTT), low antithrombin) fresh frozen plasma is the colloid of choice (Figure 26.3). The most common dysrhythmias seen are ventricular premature contractions and ventricular tachycardia. Before specific treatment is begun hypoxaemia, hypovolaemia, hypoperfusion, acid-base and electrolyte imbalances, anaemia, anxiety and pain are all ruled out. In addition, ionized magnesium concentrations should be assessed and magnesium sulphate should be given by CRI if the

ionized magnesium level is low or borderline low. If all of these have been ruled out and the dysrhythmia is causing haemodynamic instability, treatment with lidocaine (an initial bolus followed by a CRI) is started.

It is essential to pay attention to any postoperative deterioration, particularly between days 2 and 5 as this is the time when gastric necrosis and dehiscence may occur. Any new onset of abdominal pain, vomiting or fever should be investigated and abdominocentesis with cytology and culture, complete blood count and lactate concentration should be assessed.

GDV involves complex pathophysiological abnormalities requiring intensive pre- and postoperative monitoring and treatment to minimize morbidity and mortality.

**Small intestinal obstruction**

In small animals, mechanical obstruction is most commonly caused by a foreign body in the GI tract. Linear foreign bodies in cats are a common cause of mechanical obstruction. Mechanical obstruction can also be due to changes in the anatomy of the GI tract causing blockage of ingesta. Causes of this type of obstruction include neoplasia, intussusception, incarceration in a hernia, extrinsic compression and a large parasite burden. Functional obstruction occurs due to changes in GI transit time. This can be secondary to medications (opioids, anticholinergics), inflammation, electrolyte abnormalities and pancreatitis.

**Monitoring**

Clinical signs of GI obstruction include anorexia, vomiting, lethargy, dehydration and occasionally abdominal pain. Changes seen on blood work may include hypocholemaemic metabolic alkalosis if the obstruction is in the proximal small intestine, resulting in vomiting of acidic gastric contents. Metabolic acidosis can also occur if the obstruction is more distal, resulting in vomiting of bicarbonate. Other abnormalities may include hypokalaemia, hyponatraemia and azotaemia. Generally complete obstructions cause more severe

Transfusant	Dose	Rate	Unit size	Comments
Whole blood (fresh)	20 ml/kg	5–10 ml/kg/h <i>Emergency rate: 20–25 ml/kg/h</i>	Dogs: 450 ml Cats: 50–60 ml	2.2 ml/kg will raise packed cell volume (PCV) by 1% Platelet function begins to decrease within 1 hour
Whole blood (stored)	20 ml/kg	5–10 ml/kg/h <i>Emergency rate: 20–25 ml/kg/h</i>	Dogs: 450 ml Cats: 50–60 ml	2.2 ml/kg will raise PCV by 1% Platelets are non-viable
Packed red blood cells	10 ml/kg	5–10 ml/kg/h	Dogs: 250–300 ml Cats: 25–30 ml	1 ml/kg will raise PCV by 1% May be diluted with plasma or 0.9% NaCl
Fresh frozen plasma	6–10 ml/kg	5–10 ml/kg/h	Dogs: 120 and 240 ml Cats: 25ml	Contains: all coagulation factors, von Willebrand factor (vWF), albumin, immunoglobulins
Cryoprecipitate	1 unit per 10 kg	5–10 ml/kg/h	60–70 ml	~50% factor VIII, 20% fibrinogen, and some factor XIII, vWF and VIIIc
Oxyglobin	Dogs: 15–30 ml/kg Cats: 5–10 ml/kg	Dogs: 5–10 ml/kg/h Cats: 1–3 ml/kg/h	60ml and 120 ml	Dose is based on half-life; use higher doses for increased duration

**26.3** Blood transfusion guidelines.

clinical signs. A thorough oral examination to check for a linear foreign body under the tongue is essential in all animals, particularly cats and young dogs.

Abdominal radiography may reveal a radiopaque foreign body or a calcified tumour. The presence of gas-distended loops of small intestine with hair pin turns is suggestive of obstruction. The presence of free air in the peritoneal cavity suggests perforation and peritonitis. A positive contrast (barium) study can be performed if radiography is equivocal (see Chapter 3).

### Treatment

The treatment for small intestinal obstruction is surgical correction of the primary problem. Preoperative stabilization includes correction of hypovolaemia, hypotension, acid-base status, electrolyte abnormalities and alleviation of pain. Postoperative care includes adequate analgesia, which often requires a combination of an opioid (e.g. fentanyl CRI) and either a ketamine or lidocaine CRI. Monitoring of haemodynamic status and oxygenation are also essential postoperatively. In addition monitoring for postoperative deterioration, particularly between day 2 and day 5, is essential as this is the time when intestinal necrosis and dehiscence may occur. Any new onset of abdominal pain, vomiting or fever should be investigated and abdominocentesis with cytology and culture, complete blood count and lactate concentration should be assessed.

### Peritonitis

Peritonitis is defined as inflammation of the peritoneal surfaces. The causes can be both septic and non-septic. Septic peritonitis is caused by free bacteria in the abdominal cavity, most often due to perforating lesions of the GI tract, foreign bodies, or necrosis secondary to obstruction or intussusception. Non-septic or chemical peritonitis can occur secondary to leakage of bile, urine and pancreatic enzymes. Chemical peritonitis can also become septic when the material that has leaked is not sterile (e.g. infected urine).

As the disease progresses, profound systemic inflammation, leading to severe hypotension and shock occurs. There is fluid loss into the peritoneal cavity and severe vasodilatation caused by the toxins involved.

### Monitoring

Clinical signs include depressed mentation, tachycardia with weak or bounding pulses, tachypnoea, pale, cyanotic or muddy mucous membranes, hyper- or hypothermia and abdominal pain.

Essential first-line diagnostics include a complete blood count, blood glucose, venous lactate concentration and an abdominocentesis. A significant increase or decrease in the white blood cell count, decreased blood glucose and increased lactate concentration (>2.5 mmol/l) are all strongly suggestive of sepsis. Abdominocentesis is performed after sterile preparation of the caudoventral abdomen. An unattached 20 gauge needle is slowly inserted up to the hub in the ventral abdomen just caudal to the umbilicus. If no fluid is retrieved, another needle is inserted approximately 2 cm from the first needle, leaving the first one in place.

Often the insertion of the second needle will cause fluid to flow from the first needle. Fluid should be collected into a sterile red top tube, an EDTA tube and into a bacteriological culture tube. A drop of the fluid should be placed on a slide and stained to check for intracellular bacteria, the hallmark of septic peritonitis. The fluid can also be assessed for: amylase and lipase (pancreatitis); bile (biliary leak); creatinine (urine); and glucose and lactate (sepsis). Septic peritonitis is suggested if the lactate concentration of the abdominal fluid is >5.5 mmol/l or the glucose concentration is <2.8 mmol/l. Laboratory analysis of abdominal fluid is discussed further in Chapter 13.

Additional blood work may include a serum biochemical profile, haematocrit and total solids, venous blood gas and coagulation studies. Abdominal radiographs showing free gas are strongly suggestive of peritonitis. Thoracic radiographs should be evaluated for evidence of metastatic disease. Indications for emergency surgery include intracellular bacteria identified on cytological examination of abdominal fluid, obvious penetrating abdominal wound, or free air visible on abdominal radiographs.

### Treatment

On initial presentation a balanced crystalloid solution (30–45 ml/kg) along with a colloid (hetastarch, 5 ml/kg i.v. by bolus injection in dogs but not cats) should be administered, after which haemodynamic parameters should be re-assessed. In the author's experience rapid and aggressive fluid therapy can temporarily improve the haemodynamic status immensely, but rapid deterioration ensues unless definitive correction of the underlying peritonitis is undertaken in a very short time (usually 1–2 hours): Reversible analgesia (opioids) and broad spectrum antibiotics (preferably after samples for bacteriological culture and susceptibility have been collected) are also given.

Adequate fluid therapy is of utmost concern in the postoperative period. Ideally a central venous catheter is placed and used to monitor volume status. A CVP of 8–10 cm H<sub>2</sub>O is desirable in postoperative septic shock patients. Up to seven times normal maintenance fluid requirements may be needed to maintain CVP. In addition to crystalloids, colloids are essential to maintaining perfusion in these critically ill patients. If, despite adequate fluid therapy (i.e. CVP 8–10 cm H<sub>2</sub>O with a normal echocardiogram to rule out right heart dysfunction), the animal remains hypotensive, vasopressor therapy should be started. The vasopressor of choice in the author's ICU is vasopressin by CRI (0.5 mIU/kg per minute). Monitoring parameters include HR and rhythm, RR, oxygenation (pulse oximetry and arterial blood gas), urine output, mentation, pulse quality, body temperature and appetite. Laboratory monitoring includes haematocrit, total solids, blood glucose and urea, venous blood gas, lactate concentration, electrolytes, complete blood count, biochemical profile and coagulation panel.

Peritonitis is a complex, multifactorial disease process that is fatal in the majority of cases. With rapid diagnosis and aggressive treatment the prognosis is improved significantly but is still guarded at best.

**Pancreatitis**

Acute pancreatitis can be a life-threatening condition in both dogs and cats. During pancreatitis the premature activation of pancreatic enzymes leads to inflammation, ROS production and cellular death. Increased vascular permeability leads to fluid sequestration into the pancreas and abdominal cavity. Neutrophilic infiltration perpetuates the vicious cycle by releasing more ROS, which then contribute to more inflammation, leading to more ROS.

**Treatment**

The mainstay of treatment is supportive care with aggressive replacement of fluid and electrolyte losses and vigilant monitoring of haemodynamic, renal and respiratory status. Frequent assessments for pain, electrolyte abnormalities, perfusion, oxygenation, infection and coagulation abnormalities are required (Figure 26.4). Treatment includes fluid and electrolyte support (including oncotic therapy), analgesia and infection control (see Chapter 23).

Decreased perfusion of the pancreas is thought to play a key role in converting mild to severe necrotizing pancreatitis. Careful attention must be given to assessment of fluid and electrolyte status, with regard to both crystalloid and colloid components, both at presentation and during the progression of the disease. Balanced crystalloid fluids are chosen based on the electrolyte derangements. Hypokalaemia is common because of anorexia and GI losses, and is corrected by addition of potassium to the fluids, at a rate not to exceed 0.5 mmol/kg/h, based upon serum potassium concentrations. Other common electrolyte changes in animals with pancreatitis include hyponatraemia and hypochloraemia, most likely due to vomiting losses.

Hypocalcaemia is common and, in those rare cases that are symptomatic (i.e. twitching, tetany), is treated by parenteral supplementation (0.5–1 ml/kg of 10% calcium gluconate i.v. over 30 minutes, with ECG monitoring for dysrhythmias). Both hypoglycaemia and hyperglycaemia are common but stress-induced hyperglycaemia and transient hyperglycaemia secondary to hyperglucagonaemia should be ruled out before treating with insulin.

In experimental studies, the pancreatic microcirculation has been more effectively maintained by perfusion with colloids than with crystalloids. Plasma has been the colloid of choice in pancreatitis for years but its effectiveness has been questioned. Antiproteases present in plasma neutralize activated pancreatic enzymes and were thought to be protective. Several human clinical trials have failed to show a benefit of plasma over albumin treatment in pancreatitis. Oncotic support is essential in the treatment of severe pancreatitis since many patients also have hypoalbuminaemia (from GI losses and increased capillary permeability). Albumin binds detergents, lysolecithin, toxins, drugs and bilirubin. Although the amount of albumin present in normal doses of plasma is low, it is still the author's oncotic fluid of choice for pancreatitis. Other options include hetastarch or dextrans. If oxygen-carrying capacity is low (i.e. anaemia) stabilized bovine haemoglobin glutamer is a good choice for colloid in dogs. A low dose dopamine infusion (5.0 µg/kg/min) was also effective, when given early, in an experimental model of feline acute pancreatitis.

Analgesia is an essential component of the treatment regimen. Fentanyl citrate (2.0–5.0 µg/kg/h by CRI) is a good option in mild to moderate cases. Animals with severe disease or in severe pain often

Parameter	Clinical signs and laboratory results	Options for treatment
Pain	Sometimes none; can see tachycardia, hypertension, anxiety or hiding	Fentanyl CRI; oxymorphone; addition of ketamine (0.1–1.0mg/kg/h) or lidocaine (1.0 mg/kg/h) to opioid
Perfusion	Cold extremities; decreased urine output; elevated lactate level	Maximize fluid volume (CVP 7–10 cm H <sub>2</sub> O); check cardiac function; consider inotropes (dopamine, dobutamine) or vasopressor (vasopressin)
Sepsis	Hypoglycaemia; sudden change (increase or decrease) in WBCs; tachycardia; hypotension; poor perfusion (cold extremities, decreased urine output, high lactate level)	Maximize perfusion (fluid therapy, oxygen supplementation, vasopressors as indicated) and search for cause (ultrasonography for pancreatic abscess, abdominal tap or diagnostic peritoneal lavage). Exploratory laparotomy may be indicated
Coagulation	DIC (prolonged PT, aPTT, increased FDPs or D-dimer, low platelets, low antithrombin); clinical evidence of bleeding	Fresh frozen plasma administration at 6–10 ml/kg (complete transfusion within 4 hours to minimize bacterial contamination). Consider heparin (75–150 IU/kg s.c. q8h) if hypercoagulability a concern
Hypoxia	Pulse oximetry <94%; PaO <sub>2</sub> <85 mmHg	Oxygen supplementation via cage, hood or nasal route. Consider thoracic radiography. Consider pulmonary thromboembolism (PTE; may see no changes on radiography). Consider anticoagulant therapy if strong suspicion of PTE
Cerebral oedema	Increased blood pressure; bradycardia; papilloedema; decerebrate posturing	Mannitol (1.0 g/kg i.v. over 20 mins), followed in 15 minutes by furosemide (0.7 mg/kg i.v.). Consider anti-oxidants, N-acetylcysteine (50 mg/kg i.v. over 60 mins q6h) or S-adenosylmethionine

**26.4** Monitoring critically ill patients with pancreatitis or liver disease. aPTT = activated partial thromboplastin time; CRI = constant rate infusion; CVP = central venous pressure; DIC = disseminated intravascular coagulation; FDP = fibrin degradation product; PCV = packed cell volume; PT = prothrombin time; WBC = white blood cell.

need additional analgesia. Lidocaine (2.0 mg/kg) and bupivacaine (1.5–3.0 mg/kg) can be mixed with 50 ml warm saline and injected into the intraperitoneal space in dogs, using sterile technique. Addition of sodium bicarbonate (1 part bicarbonate to 9 parts analgesic solution) decreases the pain of the injection. This should not be used in animals that have had abdominal surgery within 1 week. Since cats are so sensitive to lidocaine this procedure is not suitable for that species. Alternative methods of pain control include a low dose of ketamine (0.1–1.0 mg/kg/h) by CRI along with an opioid infusion for both cats and dogs. This combination can be synergistic and provides good pain control. Another option, for dogs only, is addition of a low dose of lidocaine (1.0 mg/kg/h) to this mixture.

Hypercoagulability occurs commonly in pancreatitis and anticoagulation using heparin should be considered, especially for those at increased risk (i.e. those patients with low antithrombin, short activated partial thromboplastin time (aPTT) or prothrombin time). Heparin has the additional benefit of activating lipoprotein lipase and this may help clear lipaemia.

Centrally acting anti-emetics (i.e. metoclopramide or chlorpromazine) are good options with mild to moderate vomiting. Intractable vomiting should be treated with one of the serotonin (5HT<sub>3</sub>) antagonists (i.e. ondansetron hydrochloride or dolasetron mesylate). Intractable vomiting increases the chances of aspiration pneumonia and bacterial translocation, and so should be treated aggressively.

### Complications

There is growing concern in human medicine regarding potential complications of H<sub>2</sub> antagonist antacid therapy. Gastric alkalization and colonization with Gram-negative bacilli are thought to play a causal role in nosocomial pneumonia. Studies show a higher percentage of nosocomial pneumonia occurs in patients on H<sub>2</sub> antagonists than in patients receiving sucralfate. Antacid therapy should therefore be withheld unless other specific indications are present, since pancreatitis *per se* is not a reason for antacid therapy.

While it is accepted that infection control is very important in critically ill patients, the use of prophylactic antibiotics in patients with pancreatitis is controversial. *Escherichia coli* was shown to migrate from the colon to the compromised pancreas in a feline model of pancreatitis. Also unlike the dog, the cat has a common opening at the duodenal papilla, allowing refluxed duodenal contents to perfuse the pancreatic and biliary systems. Cats also are reported to have a higher small intestinal bacterial load predisposing them to pancreatic bacterial influx. Animals with pancreatitis are at an increased risk of bacterial translocation due to hypotension (decreased blood supply to GI tract), hypercoagulability (increased risk of microthrombi to the GI tract compromising blood flow) and decreased enteral nutrition (enterocyte starvation). Despite these considerations, infectious complications in canine and feline pancreatitis are very rare, and antibiotic treatment should ideally be restricted to those patients in which infection has been confirmed by bacteriological culture. When used, antibiotic treatment should be effective against Gram-negative bacteria and

anaerobes until results regarding specific antibiotic susceptibilities are available.

Enteral nutrition has traditionally been withheld from patients with pancreatitis in order to diminish pancreatic enzyme secretion. However, enteral feeding has many benefits including decreasing bacterial translocation and thereby potentially preventing sepsis. Despite theoretical considerations that naso-jejunoscopy feeding tubes or surgically placed jejunostomy tubes may be preferable since they bypass the pancreas, clinical experience shows that results with oesophagostomy tubes and gastrostomy tubes are good unless vomiting is intractable and non-responsive to anti-emetics.

Complications that can occur in more severe cases of pancreatitis include sepsis or endotoxic shock from bacterial translocation, thromboembolism (hypercoagulability), disseminated intravascular coagulation, hypoxia (pleural effusion, pulmonary thromboembolism), diabetes mellitus, and renal and liver compromise. The patient care team of the critically ill dog or cat must be vigilant in monitoring the patient's status and aggressive in the correction of hypoperfusion, electrolyte and acid-base abnormalities, and hypercoagulability.

### Liver disease

Symptomatic liver disease in dogs and cats is associated with several serious complications including fluid and electrolyte abnormalities, hypoxia, coagulopathy, hypoperfusion, portal hypertension, hepatic encephalopathy (HE), cerebral oedema, ascites, renal disease and sepsis (see Figure 26.4).

### Treatment

When calculating fluid therapy in animals with severe liver disease one must consider the propensity to shift fluid to a third space (i.e. ascites, oedema) and the albumin level. Most of these animals have hypoalbuminaemia resulting in an inability to retain fluid in the vascular space. Sodium retention, and subsequent water retention, is common in patients with severe liver disease. Therefore, if ascites or oedema is present the sodium load in the crystalloid fluid should be minimized (i.e. give 0.45% NaCl with 2.5% dextrose). Hypokalaemia, hypophosphataemia and hypoglycaemia are quite common. Acid-base changes include metabolic alkalosis (i.e. from diuretics, vomiting) and respiratory alkalosis. The development of lactic acidosis is suggestive of either hypoperfusion (i.e. anaerobic metabolism) or severely decreased liver function since the liver metabolizes lactate.

Animals with severe liver disease have hypoalbuminaemia. Colloids are very effective at raising the plasma osmotic pressure and can be helpful in mobilizing ascites. The colloid of choice in animals with liver disease is fresh frozen plasma. This supplements clotting factors and provides a small amount of albumin and anti-thrombin. Of the synthetic colloids hetastarch is thought to be safer than Dextran 70, which is reported to cause bleeding tendencies in animals with liver disease that have normal coagulation profiles prior to surgery. When colloids are given, the rate of crystalloid administration should be decreased by approximately 40%.

### Complications

Decreased arterial oxygenation has been reported in both humans and dogs with severe liver disease, and oxygen supplementation is warranted if there is any concern about oxygenation. Haemodynamic changes that occur with severe liver disease can mimic those of sepsis reflecting a hyperdynamic state. There is increased cardiac output, decreased peripheral vascular resistance (PVR) and hypotension. In one study of experimental cirrhosis in dogs, the cardiac output increased by 20% while the PVR and blood pressure decreased.

Sudden neurological deterioration in a patient with liver disease should prompt the clinician to search aggressively for the cause. Generally the two most common causes are HE and cerebral oedema. The Cushing's reflex can occur with increases in intracranial pressure (ICP); the increased ICP causes systemic hypertension and, via a reflex arc, bradycardia ensues. Bradycardia and hypertension with papilloedema of the ocular fundus are very suggestive of increased ICP, and mannitol (0.5 g/kg i.v. over 20 minutes) should be instituted immediately, followed by furosemide (0.7 mg/kg i.v.) 15 minutes later.

Interestingly N-acetylcysteine (NAC) decreases cerebral oedema both experimentally and in human patients with this complication of liver disease. It can be used along with mannitol, and the suggestion is to use the acetaminophen (paracetamol) antidote dosage in dogs and cats (i.e. 140 mg/kg i.v. loading dose given over 1 hour, then 70 mg/kg q6h for 4–6 more doses). There is less risk of anaphylactoid reaction if NAC is given over 1 hour. If HE is the suspected cause of the neurological deterioration, specific treatment should be directed toward alleviating HE (see Chapter 15). It is important to remember that hypokalaemia and metabolic alkalosis exacerbate HE and should be aggressively treated when present. Azotaemia also worsens HE, since increased blood urea increases urea diffusion into the GI tract, which leads to further increases in ammonia production. It is important to avoid hypoglycaemia, infections, administration of old blood products, constipation and drugs, such as benzodiazepines, which can all exacerbate HE.

Animals with severe liver disease have a tendency to bleed due to a combination of processes. There are often decreases in the coagulation factors that are produced in the liver (all factors except factor VIII, von Willebrand factor and tissue thromboplastin), decreased vitamin K ingestion or absorption, decreased levels of activation of the vitamin K-dependent coagulation factors in the liver (i.e. factors II, VII, IX, X), and decreased platelet function related to decreased albumin concentration. Cats with liver disease are predisposed to Heinz body anaemia. Clinical evidence indicates that animals with liver disease are responsive to vitamin K1 treatment (0.5–1.5 mg/kg s.c. q12h for three treatments, and then once per week). The best treatment for anaemia in these animals is fresh whole blood.

Ascites causes increased abdominal pressure, which can further increase portal venous pressure in liver disease. Protein loss from the GI tract and GI tract haemorrhage can both be potentiated by as-

cites, and if ascites is severe enough both respiration and cardiac output can also be negatively affected. Increased cardiac output, stroke volume and ventricular ejection have been shown to occur after the removal of abdominal fluid and so it is essential to monitor patients very carefully during treatment for ascites, as treatment itself can lead to serious complication (e.g. electrolyte derangements, dehydration). Treatment for ascites includes sodium restriction, diuretics and, only if these are not successful, careful removal of a portion of the fluid, but only just enough to make the animal more comfortable.

### Diarrhoea

Although not uncommon, diarrhoea is often not a top priority when the ICU staff are attempting to monitor more immediately potentially life-threatening cardiovascular, respiratory and infectious complications. Diarrhoea, however, can result in electrolyte and fluid disturbances, and skin infections, and can interfere with nutritional therapy. In the ICU diarrhoea can be iatrogenic (Figure 26.5), secondary to primary underlying diseases or can be a manifestation of primary, often infectious GI disease. Oral antibiotics and other medications (i.e. agents that increase the osmotic load of the gut such as magnesium-containing antacids or lactulose) are the cause of most iatrogenic cases of diarrhoea. Enteral feeding, especially when associated with oral antibiotic use, can also cause diarrhoea. Diarrhoea secondary to underlying disease, can be caused by GI bleeding since blood acts as both a gut irritant and an osmotic agent. Sepsis and primary adrenal insufficiency can both cause diarrhoea in the critically ill animal.

Antibiotics  
Antacids (especially magnesium-containing antacids)  
Magnesium and phosphorus supplementation  
Lactulose  
Colchicine  
Non-steroidal anti-inflammatory drugs  
Cimetidine  
Misoprostol  
Cytotoxic drugs

#### 26.5

Some medications that may be associated with development of diarrhoea.

### Treatment

The first step in the management of patients with diarrhoea is correction of fluid and electrolyte balance. Most often sodium, potassium, phosphorus and magnesium will need to be replaced in addition to correcting the fluid balance. If fluid losses are severe it is suggested that replacement is monitored using CVP. Good nursing care, proper hygiene and skin care, and careful monitoring are palliative treatments that can decrease fluid losses and protect against skin infections.

Infectious causes of diarrhoea (e.g. parvovirus, *Salmonella*, *Giardia*, *Campylobacter*; see Chapter 16) must also be considered. If an infectious cause of diarrhoea is found or suspected the patient should be

isolated immediately. All drugs suspected of causing diarrhoea should be discontinued if possible. Enteral feedings should be decreased in volume, diluted or given by constant rate infusion, but should not be discontinued since recent evidence suggests that any enteral nutrition is superior to the standard nothing *per os* (NPO) treatment. In one clinical study, early enteral nutrition of puppies with parvovirus enteritis resulted in

earlier clinical improvement compared to identically treated puppies that were kept NPO.

### **References and further reading**

---

- Hansen B (2000) Acute pain management. *Veterinary Clinics of North America: Small Animal Practice* **30**, 899–915  
Williams J and Niles J (in preparation) *BSAVA Manual of Canine and Feline Abdominal Surgery*. BSAVA Publications, Gloucester
-



# Feeding tubes

Debra L. Zoran

## Introduction

Nutrition is a vital aspect of the medical management of many, if not all, patients with gastrointestinal (GI) disease and for all pets with critical illness or severe trauma. When any animal has an illness that results in significant weight loss, inability to eat or special feeding needs, nutritional support through alternative feeding methods is often critical to successful medical management. This chapter is an overview of the approach to proper utilization and placement of feeding tubes in dogs and cats, including both endoscopic and non-endoscopic methods for placement of feeding tubes. In addition, selection of appropriate foods, feeding frequency and feeding volume will be reviewed. In general, providing enteral nutrition for dogs and cats is approached similarly, but where there are differences, they will be discussed.

## Selecting a feeding route and setting up a feeding plan

### Feeding route

There are many enteral feeding methods available to the practising veterinary surgeon ranging from oral or force feeding, to numerous tube-feeding methods including:

- Naso-oesophageal
- Pharyngeal
- Oesophageal
- Gastrostomy
- Percutaneous endoscopic gastrostomy (PEG)
- Jejunostomy.

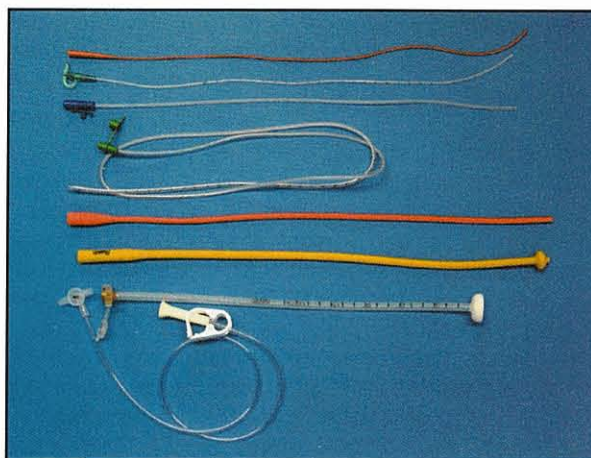
Each feeding method employs a variety of different tubes (Figure 27.1). Each of these different enteral nutrition routes has its own pros and cons, as discussed individually below and summarized in Figure 27.2.

The feeding route selected for a particular animal is based on the premise that it is best to feed the gut as high up as it is functional. In other words, if the dog has megaesophagus and a feeding tube is going to be placed to provide nutritional support, a gastrostomy or PEG tube should be used. Whereas, if the cat has a severe case of gingivitis or stomatitis and is unable (or unwilling) to eat, an oesophagostomy tube

is reasonable. The second rule of thumb is to determine the feeding method that is best suited for the patient's situation by asking the following questions:

- Is the feeding tube going to be required long-term?
- Is there an anaesthetic risk that makes tube placement an unacceptable hazard?
- What types of diet does the patient require? (Some foods can't be fed through very small-bore feeding tubes, such as naso-oesophageal or jejunostomy tubes).

Finally, it is extremely important to include the owner in the decision-making process, as they must be willing and able to provide the necessary nutrition if the animal is to be able to go home. Many owners can handle the three or four feedings per day which is typically required for oesophagostomy or PEG tubes. However, in animals with jejunostomy tubes, bolus feeding of the diet three or four times a day will likely cause diarrhoea due to volume and osmotic overload of the small intestine. Jejunostomy tube feeding is best implemented using very frequent (e.g. every 2–3 hours) small meals or by continuous infusion of food (using a fluid pump), which may not be practicable in the home setting. Thus, choosing the best feeding method requires not only a nutritional assessment of the patient's needs, but also an assessment of the ability of the caregivers to provide the nutrition appropriately.



27.1

Multiple sizes and types of feeding tube available for use in dogs and cats.

Route	Advantages	Disadvantages	Other
Oral or force feeding	No special equipment Physiological method of feeding if tolerated by patient	Anorectic animals or those in pain will refuse or fight feeding Stressful to both the animal/care-giver Difficult to achieve caloric requirements	May induce food aversion in cats
Naso-oesophageal tube	Rapidly placed No need for anaesthesia – only local anaesthetic (proparacaine, proxymetacaine) No special equipment needed for placement Excellent for short-term feeding (2–3 days) of cats or small dogs	Patient discomfort May be easily dislodged by patient Must use liquid diets only – thus difficult to use in large dogs Contraindicated in comatose, recumbent or dysphoric cats or dogs that are at risk of aspiration Not tolerated long-term	Caution should be advised in placing a naso-oesophageal tube in any patient with nasal disease, a clotting disorder or with severe thrombocytopenia
Oesophagostomy tube	Placed rapidly (5–10 minutes) Only requires short-term or light anaesthesia Can use commercial feeding tubes and kit or 'homemade' materials (e.g. red rubber catheter) Can use blended canned or liquid foods Well tolerated for long periods (weeks to months)	Vomiting may result in tube being expelled or retroflexed into the nasopharynx Tube site requires daily care to prevent infection Cannot be used in comatose, recumbent or dysphoric animals at risk of aspiration Should not be used in animals with oesophagitis or severe oesophageal dysfunction Most common complication is infection at tube site	Tube can be removed at any time following placement as permanent stoma does not form and site heals rapidly Tube does not interfere with eating (many cats will start eating with the tube in place), which may not occur with naso-oesophageal or pharyngostomy tubes
Gastrostomy including PEG tube	Can use commercial feeding tubes and kit or 'homemade' materials (e.g. Pezzer catheter) Can use blenderized canned or liquid foods Well tolerated for long periods (weeks to months) and is best method for prolonged (months to years) feeding Can be placed with use of endoscope, an ELD device or at surgery Excellent for dogs or cats with oral or oesophageal disease	Requires longer anaesthesia period for placement Requires some special equipment and expertise Complications from tube placement are more serious (e.g. peritonitis, tube leakage into abdomen)	Well tolerated by most animals for long periods Easy to access tube for feeding
Jejunostomy tube	Excellent means of providing enteral nutrition for hospitalized patients with severe vomiting or gastric disease	Placement requires special equipment, endoscopic expertise and/or surgical skill Must feed liquid diets Best to feed with continuous infusion (pump) to avoid overload of intestines with boluses of food Expensive for larger dogs due to large volume of liquid diets needed Nasojejunosotomy tubes are not tolerated long-term	An important means of delivering nutrition in special situations

## 27.2 Enteral nutrition routes.

### Feeding plan

Once the feeding route has been decided, a feeding plan must be established. There are several steps involved in setting up a feeding plan, and the first is to determine how many calories are needed for that animal in its particular situation. Secondly, the type of food to be fed must be selected (based on tube type, food availability and the nutritional needs of the patient), and finally, the timing, frequency and amount of food to be fed at each meal must be determined.

The caloric needs of an individual can be determined by a number of different equations (Figure 27.3), but in general for very sick patients that have not been

eating well or have been unable to hold food down, the goal should be to reach the animal's resting energy requirement (RER) for calories. For most cats, the RER is all they need even when they are under severe metabolic stress. Dogs may require additional calories (e.g. 1.25–1.5 × RER) when under severe metabolic stress (e.g. burns), but under most circumstances meeting their RER is more than enough to maintain gut health, immune function and basic needs for protein and energy metabolism. The easiest equation to use in a clinical situation is the linear equation:

$$\text{RER} = 30 \times \text{BW (kg)} + 70$$

The equation for calculation of RER by most nutrition experts, and one that is more accurate in very small or very large animals, is:

$$\text{RER} = 70 \times \text{BW}^{0.75} \text{ (kg)}$$

Once the animal's RER has been calculated, the next step is to select the diet that meets the needs of the medical circumstance (e.g. highly digestible or high energy/recovery diet; hypoallergenic or hydrolysed diet). This is a subject that is of considerable importance, but is beyond the scope of this chapter (see *BSAVA Manual of Companion Animal Nutrition and Feeding*).

Once the caloric needs are determined and diet selected, the final step is to determine the best way to initiate feeding in the patient. With tubes of a 10 French or larger size, most canned foods can be blenderized into a gruel or slurry and fed directly through the tube. Tubes of a smaller diameter, especially naso-oesophageal or jejunostomy tubes (which are usually 5 French or smaller) will require a liquid diet as even blenderized and strained foods will plug the tube. The most widely available liquid diets for dogs and cats (*Clinicare* (Abbott

Labs) in the USA and *Reanimyl* (Virbac) in the UK), are balanced and high-energy (moderate fat, high carbohydrate), and suitable for dogs or cats with normal GI function. However, for those animals with significant GI disease, or those that are fat intolerant or require low carbohydrate in their diet, these diets may not be the best choice. There are a wide range of products available for human enteral nutrition that have varying fat, protein and carbohydrate concentrations that can be used for short-term feeding in dogs. Unfortunately, these diets will not provide adequate protein and are deficient in a number of amino acids (e.g. taurine, arginine and carnitine) and other nutrients (e.g. arachidonic acid, certain B vitamins) that cats require, and thus should not be fed to cats without supplementation of these missing nutrients.

Once the amount and type of food is determined, a plan is developed to deliver the nutrients efficiently but to minimize vomiting or other complications. In most cats, small, frequent meals are tolerated more readily than large boluses of food because the feline stomach is not as readily distensible. When initiating feeding in either dogs or cats, the aim on Day 1 is to provide 4–6 meals over the course of the day using half of the RER as the caloric goal. If that amount of food is tolerated, on Day 2 the feedings are increased by a quarter, and so on. Some patients with GI disease will not be able to tolerate the volume of food required to meet RER; however, even if the animal is able to tolerate only half the daily RER, it will minimize the risk of intestinal bacterial translocation, immune deficiency from protein deficits and death from sepsis. An outline of a proposed feeding plan for an animal requiring enteral nutritional support is provided for illustration of these concepts (Figure 27.3).

**Step 1. Calculate resting energy requirement (RER):**

RER = 70 x BW<sup>0.75</sup> (kg)  
 RER = 30 x BW (kg) + 70  
 Patient RER = \_\_\_\_\_

**Step 2. Determine food to be used and the kcal/ml of the food:**

Example: *Clinicare* (Abbott labs) = 1.04 kcal/ml, 237 ml/can  
 What is the total volume of food to be administered/day at full RER? \_\_\_\_\_

**Step 3. Set up a feeding schedule:**

Will feeding be intermittent? \_\_\_\_\_  
 If so, how many feedings/day? \_\_\_\_\_  
 If feeding will be continuous, \_\_\_\_\_ ml/hr  
 For intermittent or continuous feeding, start slowly and work up to RER over 3–4 days:  
 Day 1: 1/2 RER = \_\_\_\_\_ divided into 3–6 meals/24 hr  
 = \_\_\_\_\_ ml food/meal  
 Day 2: 3/4 RER = \_\_\_\_\_ divided into 3–6 meals/24 hr  
 = \_\_\_\_\_ ml food/meal  
 Day 3: RER = \_\_\_\_\_ divided into 3–6 meals/24 hr  
 = \_\_\_\_\_ ml food/meal  
 Day 4: Take RER and divide into 3–4 meals/day  
 = \_\_\_\_\_ ml food/meal

**Step 4. Feeding instructions:**

- Warm all food to body temperature
- Aspirate tube before feeding (do not feed if >10 ml fluid present)
- Administer gastric or oesophageal meal over 15–20 minutes, continuous infusion is best for intestinal feeding
- Flush tube with warm water to prevent clogging before recapping
- Use only clean food bags and administration lines. Replace continuous administration lines every 24–48 hours
- Use liquid medication if possible to prevent tube clogging

**Placement of feeding tubes**

**Naso-oesophageal tubes**

Naso-oesophageal tubes are an important feeding option for all hospitalized animals that require short-term feeding but are unable or unwilling to eat. These tubes are easily placed in most animals without anything more than local analgesia (proparacaine or proxymetacaine ophthalmic drops) of the nose or mild sedation for those animals that are extremely anxious. The main contraindications to using naso-oesophageal tube feeding are:

- Severe nasal disease or dysphagia, when passing the tube may be difficult or impossible
- Animals with a coagulopathy (the tube placement may cause epistaxis)
- Severe or uncontrolled vomiting (the tube will not stay in place)
- Patients that are unable to protect their airway (comatose, lateral recumbent animals that are at risk of aspiration).

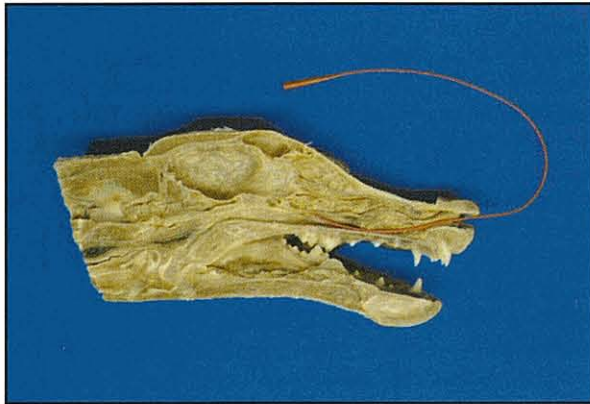
This type of feeding is best used as a form of 'bridge' nutrition, as most animals will not tolerate the tube in their nose for more than 1–3 days. In addition, while

**27.3** Feeding plan.

naso-oesophageal tubes can be placed in any sized animal, they are generally used only in cats and small dogs because the tubes are so small that liquid diets must be fed. In large dogs, the sheer volume of a liquid diet required to meet the energy needs is very large and is frequently limiting (both in inventory as well as in capability to administer that volume easily).

### Procedure

Naso-oesophageal tube placement is relatively straightforward. Before beginning to pass the tube, the distance from the nose to the last rib is measured and, moving forward 2–3 rib spaces, the distance is marked on the tube. This will ensure that the tube does not enter the stomach, thus reducing gastric reflux. Lubrication of the tube with lidocaine gel can aid insertion. Once the anaesthetic drops (e.g. proxymetacaine) are instilled, the animal's head is placed in a normal pose (i.e. not too flexed or extended) and the tube directed downward as it enters the nose so that it will pass into the ventral meatus of the nasal cavity (Figure 27.4).



**27.4** Canine head (anatomical model) used to illustrate proper placement of a naso-oesophageal feeding tube in the ventral meatus.

By holding the animal's head in a normal position, it is easier for the dog or cat to sense the presence of the tube in the laryngeal area. As the tube is passed and reaches the larynx the animal will swallow, thus making it more likely that the tube will enter the oesophagus and not the trachea. While most animals will cough if the tube does enter the trachea, it is very important to check its position carefully. If the tube is in the oesophagus, there should be negative pressure when suction is placed on the tube. As an additional test, a small amount of water can be instilled in the tube before administering food. Finally, a lateral radiograph should always be taken to ensure not only that the tube is in the proper location, but also that it is not kinked or twisted.

### Pharyngostomy and oesophagostomy tubes

Pharyngostomy and oesophagostomy tubes offer several advantages to practitioners over gastrostomy tubes because they can be placed without having specialized equipment or expertise. In addition, while both pharyngostomy and oesophagostomy tubes require anaesthesia for proper placement, the amount

of time required is much shorter than for other procedures. For that reason, and many others, these tubes are a useful method of providing enteral nutrition in the practice setting. That being said, pharyngostomy tubes have fallen from favour compared to oesophagostomy tubes, as they tend to be associated with more complications and are less well tolerated, especially for long-term feeding (weeks to months). They also interfere with epiglottic movement and laryngeal function, and have been associated with recurrent laryngeal nerve injury and dysfunction. Many animals are reluctant to resume eating as long as the pharyngostomy tube is in place, which is not a problem in animals with an oesophagostomy tube. For these reasons, placement of an oesophagostomy tube is preferred and is the method described here. The reader is referred to Marks (1998) for information about placement of pharyngostomy tubes.

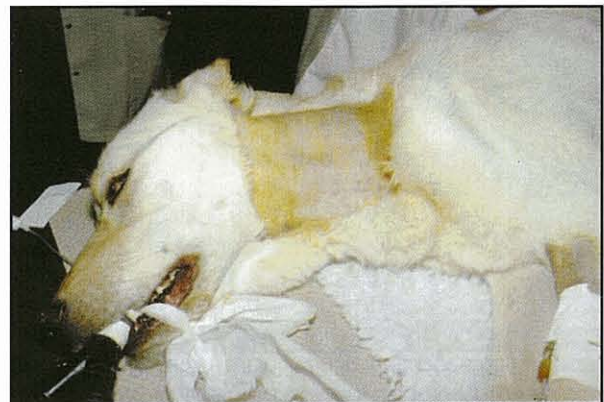The advantages of oesophagostomy tubes are many (see Figure 27.2) and include easy placement (once the operator is familiar with the technique) under short-term general anaesthesia or heavy sedation. More importantly, the only major complication reported in association with oesophagostomy tube placement is infection at the stoma site. Oesophagostomy tubes are especially useful in cats because they are well tolerated and allow long-term feeding (months) if needed. Such long feeding periods may be required in some cats with idiopathic hepatic lipidosis or chronic renal failure.

### Procedure

There are several different techniques described for placement of oesophagostomy tubes. However, for all techniques, the first steps are placement of the patient in right lateral recumbency, clipping the hair from the angle of the jaw to the shoulder and surgically preparing the area (Figure 27.5). The two most common procedures are:

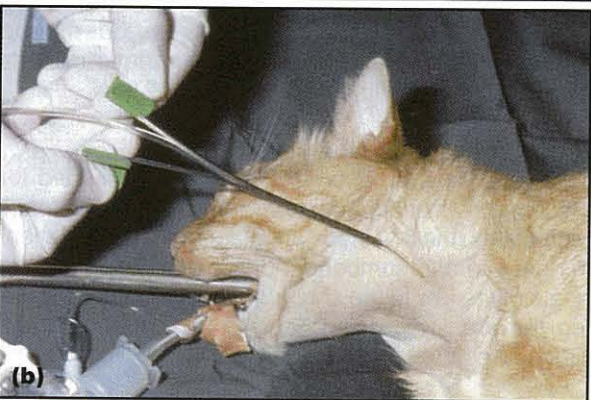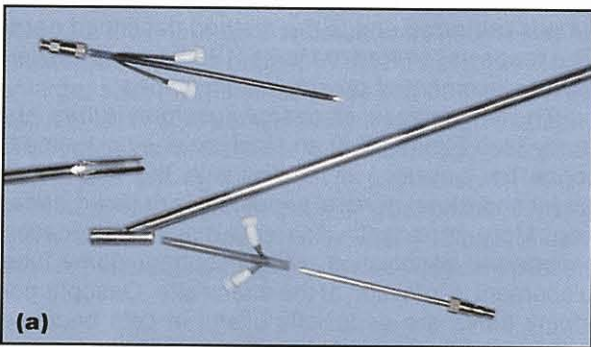
- A percutaneous (14 gauge needle) technique
- A surgical cut-down technique.

The reader is referred to Marks (1998), Tams (1999) and Devitt and Seim (2000) to learn other techniques.

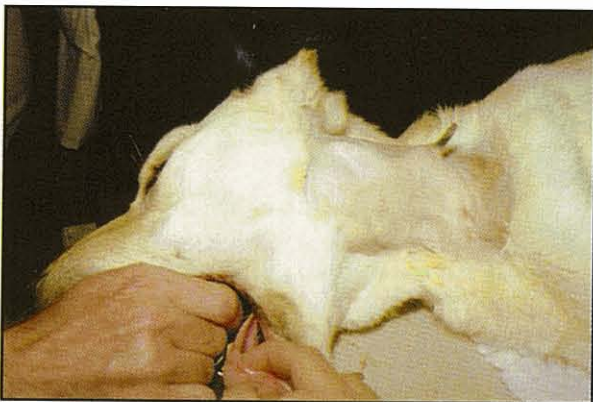

**27.5** Patient in right lateral recumbency, with the neck prepared for placement of an oesophagostomy tube.

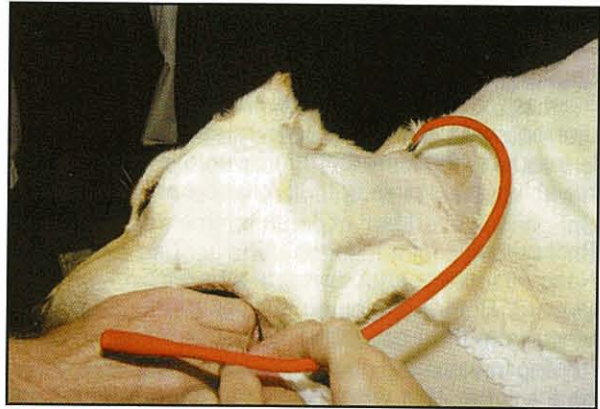
Oesophagostomy tube placement parts are commercially available (Figure 27.6). The advantage of the surgical technique is that larger tubes (greater than 12 French) can be placed, which will allow easier, faster feeding of blenderized canned foods. With smaller tubes (5–10 French) only liquids can be used without difficulty. In the surgical technique, curved Carmalt forceps are inserted into the oesophagus through the mouth and a surgical cut-down is made over the tip of the forceps (Figure 27.7). The pre-measured tube is then grasped by the forceps, pulled into the oesophagus and advanced to the desired position (Figure 27.8).



**27.6** (a) Introducer with needle and 'peel-away' catheters. (b) Patient undergoing insertion of van Noort oesophagostomy tube. (Courtesy of Ronald von Noort)

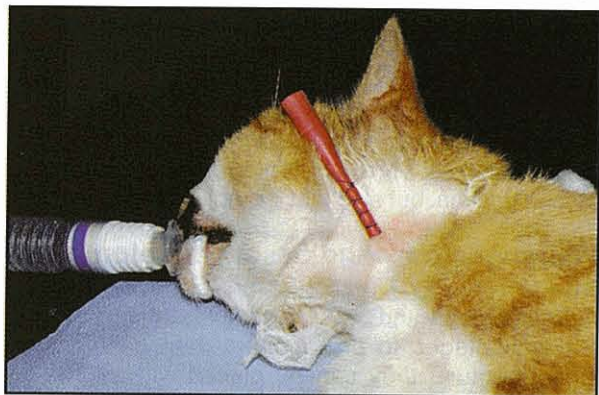

**27.7** Curved Carmalt forceps inserted into the oesophagus and used to make an incision at the site of the oesophagostomy tube placement. These forceps are also used to grasp the tube to pull it into the oesophagus during placement.



**27.8** Advancing the oesophagostomy tube down the oesophagus.

The size of tube selected depends on the size of the animal and the type of tubes available, but most cats easily tolerate a 10–14 French gauge tube (e.g. red rubber tube, standard polyurethane feeding tube or silicone feeding tube). Larger dogs can tolerate 18–24 French gauge sizes easily. The advantage of using polyurethane is that it is stronger and lasts longer than silicone, which while softer and more flexible (and so easier to manoeuvre) is less durable. Once the tube is placed and is positioned in the oesophagus at the desired depth, the tube is secured by placement of a Chinese finger-trap (friction) suture, with or without a tape 'butterfly' to anchor it, and a purse string is placed around the base of the tube (Figure 27.9). A soft, padded, loose, neck wrap is placed to keep the remaining tube from being caught on objects or removed by rear claws. The stoma site will not seal around the tube, so oozing around the site is common. The key to prevention of stoma site infection is daily cleaning of the site, and if oozing of purulent liquid suggests infection, an antibiotic ointment, such as silver sulfadiazine, should be applied. The stoma site will close rapidly once the tube is removed (inadvertently or purposely), so if a tube needs to be replaced it should be done as soon as possible after it is removed (within 4–8 hours). The stoma site will heal rapidly by granulation, and despite the potential for oesophageal stricture or fistula formation, these complications are apparently very rare.

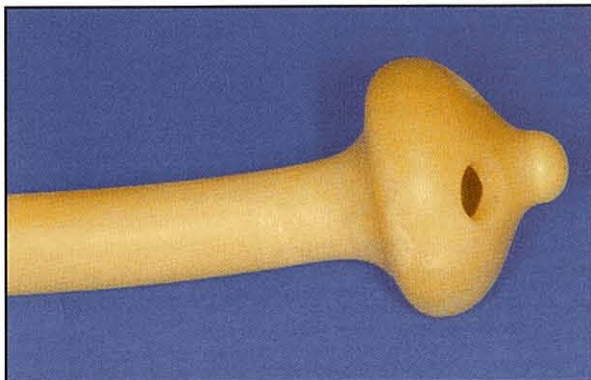

**27.9** Securing the oesophagostomy tube with a purse-string stay suture and a Chinese finger trap (overlapping) suture to prevent sliding.

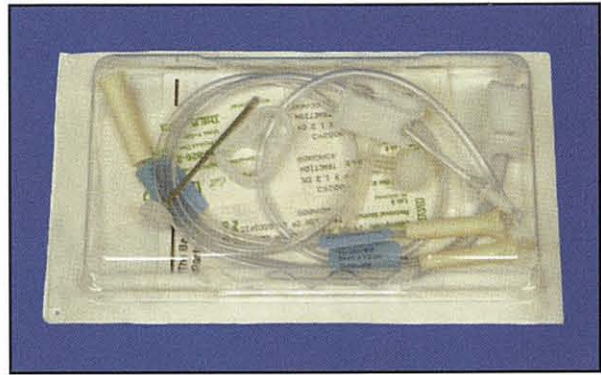
## Gastrostomy tubes

Gastrostomy tubes are the best method for feeding animals with severe oesophageal disease, animals that are vomiting and likely to expel an oesophagostomy tube, or animals for which long-term feeding is anticipated. The major drawbacks of using gastrostomy tubes are that their placement is more complicated and requires specialized equipment (e.g. endoscopy or an ELD device), placement requires more anaesthesia time, and, if they are not placed surgically and the animal is very active or vomiting, the tube site can leak gastric contents into the abdomen. The contraindications to gastrostomy tube feeding are similar to those for oesophagostomy tubes, in that it should be avoided in comatose animals, animals with laryngeal paralysis (or inability to protect their airway) and any animal with a gastric outflow obstruction. If these things are taken into consideration, gastrostomy tubes are an efficient and very effective means of delivering nutrition to both dogs and cats over long periods (months to years).

One of the many advantages of using a gastrostomy tube for enteral nutrition is that the diameter of the tubes placed is relatively large (e.g. cats 12–16 French, dogs 18–24 French). These sizes of tubes allow easy use of blenderized canned foods instead of feeding exclusively liquid enteral diets. In cats, the tubes also allow easy administration of medications, which can be difficult if not impossible or dangerous in anorectic cats. The most common tube used for gastrostomy in the author's hospital, in both dogs and cats, is the mushroom-tipped urological catheter (also called a Pezzer catheter) (Figure 27.10). The tip of the catheter is removed prior to placement to increase the openings to allow food through the end more easily. However, gastrostomy tube kits (e.g. these are intended for human use but work well in dogs and cats) are available (Figure 27.11) and provide a tube with all of the required disposable supplies. In the UK, kits with veterinary PEG tubes with swaged-on wire loops for ease of placement are available. It is important to recognize that there are several options available for tube placement, but the key is to become very familiar with one or two so that the procedure becomes second nature.



**27.10** A Pezzer urological catheter used for gastrostomy tube feeding.



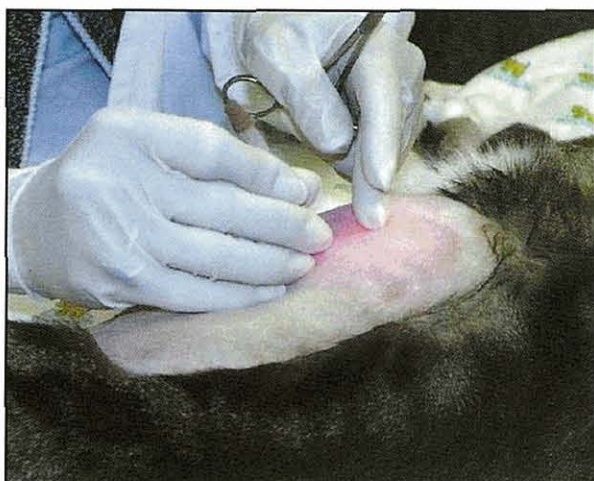**27.11** Example of a commercially available gastrostomy tube kit.

## Procedure

Placement of PEG tubes for delivery of enteral nutrition in dogs and cats has been used since the 1980s, and is even more widely used now that endoscopes are increasingly found in private veterinary practices. In general, minimal training and experience is required to properly use endoscopy for placement of gastrostomy tubes; and for most practitioners with some endoscopic experience, placement of a PEG tube is relatively easy to learn.

The first step is to determine whether a PEG tube is the proper choice for the particular patient, and then select the type of tube to place (Pezzer, standard tube or low-profile tube). The type of feeding tube selected depends on the length of time the tube is expected to stay in place, the size of the animal, and the equipment that the veterinary surgeon is most comfortable using. However, some large dogs, particularly those with a conformation in which the stomach is almost completely encased by the ribs, are poor PEG tube candidates because of the difficulties in securing the tube to the body wall in a way that avoids leakage around the tube. In such dogs the stomach should be pexied to the body wall at the time of the gastrostomy tube placement to reduce the risk of leakage, and so surgical tube placement is necessary.

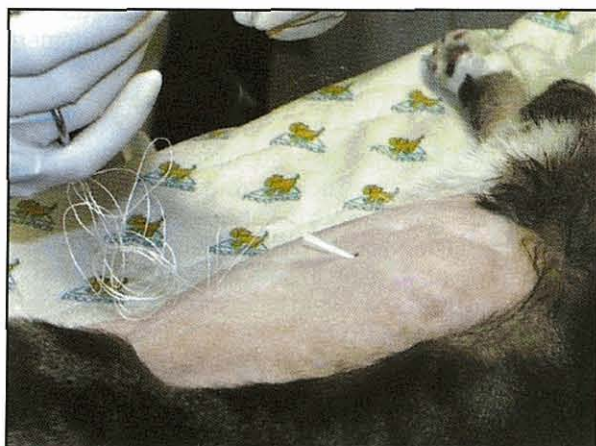Once the animal is under general anaesthesia and placed in right lateral recumbency (this is the opposite side down compared to most endoscopic procedures), an area extending from the last rib to the mid abdomen is clipped and surgically prepared to allow sterile placement of the tube at this site. The endoscope is inserted into the stomach and the stomach is insufflated maximally to make sure that the expanded gastric wall displaces bowel, spleen or liver from the insertion site. In larger dogs, it may be necessary to have an assistant apply external pressure to the cervical area to prevent the escape of air through the oesophagus. The site on the stomach wall best suited for insertion of the tube is selected by applying pressure with a finger into the dilated stomach just behind the last rib (Figure 27.12). The endoscopist helps direct the assistant to the best location in the stomach wall by visualizing the indented mucosa. In general, the goal is to avoid placing the tube in the pyloric antrum, the incisura angularis, the lesser curvature or lower regions of the greater curvature, as these regions are more motile and more likely to leak gastric contents around the tube site.



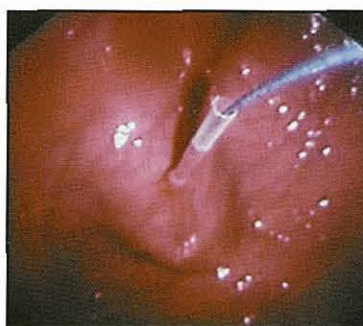
**27.12** Patient in right lateral recumbency and prepared for placement of PEG tube.

Once the stomach site is selected and visually agreed upon, the final surgical preparation of the skin is completed and the assistant can begin placement. The first step is to insert a large 12–14 gauge over-the-needle catheter percutaneously into the inflated stomach (Figure 27.13). Once inside the stomach, the needle is removed, leaving the catheter in the stomach (which should be easily visualized by the endoscopist) and a piece of long suture is introduced through the catheter into the stomach. This suture should be long enough to extend from the stomach to the mouth with plenty of length to spare. The suture is grasped by the endoscopist using a biopsy or foreign body retrieval device (Figure 27.14), and when the suture is secured the endoscope and suture are slowly retracted through the mouth. Alternatively, with some manufactured PEG tube kits (Mila and Wilson-Cook), a flexible wire loop is placed and grasped as the PEG tube has a corresponding swaged-on loop for a simple interlocking attachment.

At this point, different procedures are required to prepare the feeding tube for placement, depending on whether a Pezzer catheter or a commercial feeding tube kit is being used. However, readers are referred to



**27.13** Using an over-the-needle catheter to enter the inflated stomach. Once the catheter is in the stomach and well visualized by the endoscopist, the needle is removed and the string to be used to pull the tube through is introduced.



**27.14**

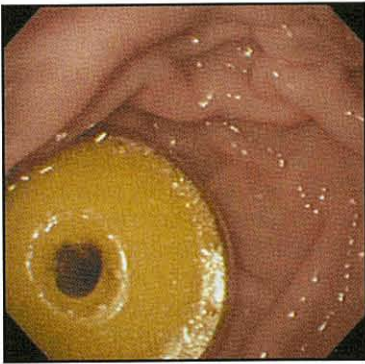
Visualization of the string passing through the catheter in the stomach wall, which is then grasped by grasping forceps passed through the endoscope. (Courtesy of James Simpson)

a recent review by Tams (1999) for the specific details required to place a commercial feeding tube using a kit.

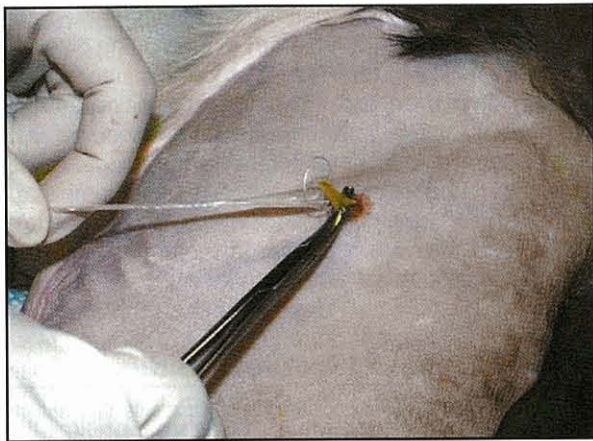
When using the Pezzer catheter, the first step is to cut the open end of the tube so that it is tapered to fit into a plastic pipette tip or catheter introducer. Then the suture is secured to the tube by using a needle to place several layers (Figure 27.15). Securing the suture tightly into the tube is essential for the tube to be successfully retracted through the oesophagus, into the stomach and finally back through the stomach wall and skin (which may need to be incised very slightly to facilitate passage of the tube). To be sure the tube is seated securely once it is through the stomach wall, the endoscope is used to follow the tube back down the oesophagus, into the stomach and assess how snug the fit is (Figure 27.16). Firm traction is used to pull the tube through the stomach wall and achieve a tight fit (Figure 27.17). The final step is placing either a flange (Figure 27.18) or Chinese finger-trap stay sutures (see Figure 27.9) to keep the stomach wall and the body wall close together to prevent leakage. Once the tube is in place, a t-shirt, tube gauze or loose body wrap is placed to protect the remaining tube and prevent it from being inadvertently or purposefully removed. The gastrostomy tube should remain in place for at least 10–14 days before it is removed, so that the gastric stoma will form a seal that prevents leakage but also forms an attachment between the stomach and the body wall. If a gastrostomy tube is accidentally removed before intended, a tube can be replaced through the same stoma site if the procedure is performed rapidly (e.g. within 24 hours of the tube removal). There are commercial kits available that allow replacement of the tube through the stoma; and in some cases, placing a human low profile tube may be beneficial.



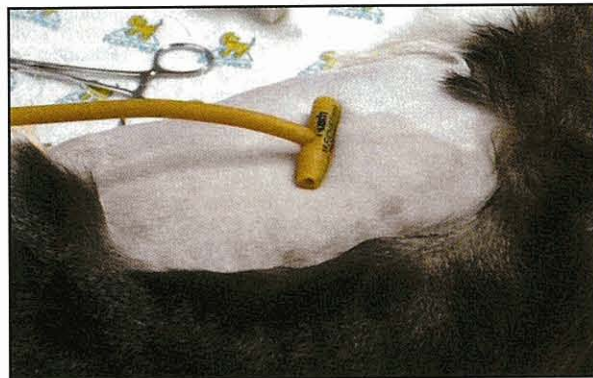
**27.15** Illustration showing the suture securely attached to the feeding tube, with the feeding tube attached to a pipette tip or other small plastic introducer, which allows the tube to be pulled through the hole in the stomach and body wall.



**27.16** Following the tube as it is pulled back down the oesophagus into the stomach and ready to be pulled through the wall. (Courtesy of Edward Hall)

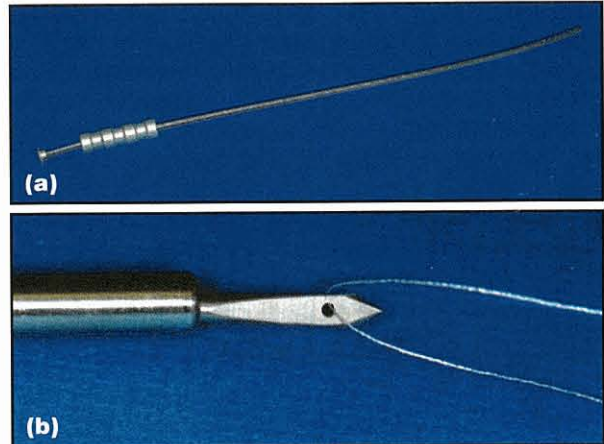


**27.17** The tube is pulled carefully, but with steady pressure, through the incision in the wall. If too much resistance is encountered, the incision should be widened slightly but using caution not to make the hole too large.



**27.18** An external flange is often used to help maintain contact between the stomach and the body wall.

An alternative procedure for placement of gastrostomy tubes in dogs and cats was developed using a rigid device (an ELD device) that facilitates gastrostomy tube placement without the need for an endoscope or surgical procedure (Figure 27.19). This procedure is certainly useful in practice settings where an endoscope is unavailable. The procedure is performed using the ELD device to place the suture through the stomach wall, using the retractable device to make the incision out through the gastric and body walls to grasp the suture. But, there are some important drawbacks, the least of which is that the



**27.19** An ELD device showing (a) the entire device and (b) the extended knife for puncturing the body wall and the hole in the end used to hold the suture in place as it is returned into the stomach.

procedure is performed blind. Thus, there is no way to be sure of the location in the stomach where the tube is being placed. In addition, it is quite easy, if due care is not taken, to perforate the spleen, liver or intestinal loops during the stab procedure. Improperly placed tubes may result in leakage of gastric contents into the abdomen, abnormal gastric function, abnormal reflux of gastric contents into the oesophagus or vomiting due to gastric outflow abnormalities. The procedure has been well described elsewhere and the reader is referred to Mauterer *et al.* (1994) and Marks (1998) for more information.

### Jejunostomy tubes

There are some situations when enteral feeding is best accomplished if the food is delivered directly into the small intestine (e.g. some cases of pancreatitis, gastric outflow disruption or animals with other duodenal or upper intestinal outflow problems). Until recently, placement of jejunostomy tubes was a surgical procedure performed during an exploratory laparotomy. However, a jejunostomy tube can be placed via endoscopic procedures as described by Ponsky and Agzodi (1984) and Tams (1999).

### Procedure

The method used most often is placement of a jejunostomy tube through an existing PEG tube. This procedure is relatively straightforward, but not necessarily easy to accomplish. First, a gastrostomy tube is placed, then the special jejunostomy tube is inserted into the stomach via the gastrostomy tube, and the endoscope is used to grasp the end of the jejunostomy tube and direct it into the duodenum. Once the jejunostomy tube is in the duodenum, the endoscope is carefully removed (leaving the jejunostomy tube in place) and the jejunostomy tube is passed further down into the jejunum using fluoroscopic guidance to advance it to the desired position. The jejunostomy tube has a weight on the end that helps to prevent its orad movement, but it can be difficult to get the jejunostomy tube into the jejunum and then to keep it there.



An alternative method for jejunostomy tube placement is the nasojejunoscopy tube. To place a nasojejunoscopy tube the endoscope is first advanced into the duodenum. A guide wire is then placed into the duodenum through the biopsy channel and advanced to the desired level in the jejunum. Once the guide wire is in place, the endoscope is carefully removed, leaving the wire so that the nasojejunoscopy tube can be advanced down the wire to the desired location. To place the guide wire into the nose, a red rubber or other feeding tube is passed through the nose (as if it were being placed as a naso-oesophageal tube) to the level of the oropharynx. The tube is pulled into the mouth and then this tube is used to transfer the guide wire back up through the nose and out. This entire process is assisted by using fluoroscopy to assess placement, but plain radiography can also be used once the tube is *in situ* to assure it is properly placed. As with naso-oesophageal tubes, nasojejunoscopy tubes are not as well tolerated as jejunostomy tubes placed through the gastrostomy tube, and for that reason, are not the approach most recommended.

### **Complications of feeding tubes**

Major complications of feeding tube placement in dogs and cats are uncommon and can usually be avoided with proper technique and careful client counselling. The most common complications are:

- Tube clogging
- Infection at the tube site
- Dislodgement of the tube by the animal
- Vomiting following feeding.

Other complications include:

- Leakage around the tube site
- The animal biting and transecting the tube
- Abnormal gastric outflow or function
- Diarrhoea due to overfeeding the small intestine
- Necrosis of the gastric wall
- Stricture of the oesophagus at the tube site
- Laceration or injury to the spleen or other organs.

Tube clogging can usually be avoided by carefully flushing the tube with water following each feeding and by using appropriate food for the size of the tube. If the tube does become clogged, it can often be unclogged

by forcefully injecting water into the tube, by using a guide wire to dislodge the attached food or by instilling a small amount of effervescent soda into the tube. In most situations, infections at or around the tube site can be prevented by careful tube-site care. All tube sites should be cleaned daily and topical use of an antibiotic cream is often very useful in preventing infection, ulceration or other tube-site problems. Careful placement of bandaging or body covers will reduce the risk of the tube being dislodged or inadvertently removed. If the animal is irritated by the tube, a careful assessment of the tube should be undertaken as the stoma may be getting infected or there may be some other problem; most tubes cause the patient no discomfort. Finally, if the patient vomits after feeding, check that the amount (volume) of food being given is not excessive (e.g. feed smaller more frequent meals initially), and then prokinetic (e.g. metoclopramide, cisapride, ranitidine) or anti-emetic (metoclopramide, ondansetron, dolasetron, chlorpromazine) drugs should be added to the regime. In most cases, the complicating factors can be resolved and enteral feeding accomplished successfully if alterations in volume, frequency or the type of food are completed.

### **References and further reading**

- Bartges JW (2001) Identifying and feeding patients that require nutritional support. *Veterinary Medicine* 96, 60–74
- Bright RM (1993) Percutaneous endoscopic gastrostomy. *Veterinary Clinics of North America* 23, 531–545
- Crowe DT (1986) Clinical use of an indwelling nasogastric tube for enteral nutrition and fluid therapy in the dog and cat. *Journal of the American Animal Hospital Association* 22, 675–682
- Devitt CM and Seim HB (2000) Esophageal feeding tubes. In: *Kirk's Current Veterinary Therapy XIII*, ed. JD Bonagura, pp. 597–600. WB Saunders, Philadelphia
- Guilford WG (1996) Nutritional management of gastrointestinal diseases. In: *Stombeck's Small Animal Gastroenterology 3<sup>rd</sup> edn*, ed. WG Guilford *et al.*, pp. 889–911. WB Saunders, Philadelphia
- Kelly N and Wills J (1996) *BSAVA Manual of Companion Animal Nutrition and Feeding*. BSAVA Publications, Cheltenham
- Marks SL (1998) The principles and practical application of enteral nutrition. *Veterinary Clinics of North America* 28, 677–708
- Mauterer JV, Abood SK, Buffington CA and Smeak DD (1994) New technique and management guidelines for percutaneous nonendoscopic tube gastrostomy. *Journal of the American Veterinary Medical Association* 205, 574–579
- Ponsky JL and Agzodi A (1984) Percutaneous endoscopic jejunostomy. *American Journal of Gastroenterology* 79, 113–116
- Remillard RL, Armstrong PJ and Davenport DJ (2000) Assisted feeding in hospitalized patients: enteral and parenteral nutrition. In: *Small Animal Clinical Nutrition 4<sup>th</sup> edn*, ed. DJ Davenport *et al.*, pp. 351–399. Morris ML Publication, Topeka
- Tams TR (1999) Endoscopic placement of gastrostomy and jejunostomy tubes. In: *Small Animal Endoscopy, 2<sup>nd</sup> edn*, ed. TR Tams, pp. 341–356. Mosby, St. Louis

# Therapeutics

Edward J. Hall

## Introduction

This chapter deals with licensed and non-licensed drugs available to treat gastrointestinal (GI) and liver disease, their modes of action, interactions and potential side-effects in dogs and cats. Details on dosages are listed in Appendix 1. The reader is referred to earlier chapters for information on diagnosis and recommendations on the complete therapy of specific conditions, including the critical roles of fluid therapy and nutritional modification, which are not covered in this chapter.

In addition to specific treatment(s) for specific conditions, symptomatic therapies are also used (Figure 28.1). However, as most GI disturbances are acute and self-limiting the need for some of these remedies is debatable and their efficacy has infrequently been proven. Ideally, such symptomatic remedies are only used *after* conditions requiring specific treatment have been excluded. If a definitive diagnosis is not made, then they should only be used for a short period (maximum of 72 hours) so that definitive treatment is not dangerously delayed. For example, using anti-emetics to mask the signs of an intestinal obstruction only delays surgery and endangers the patient.

## Gastrointestinal disease

### Antibacterials

It is commonly assumed that antibacterial agents (see also *BSAVA Manual of Canine and Feline Infectious Diseases*) are harmful because they disturb the normal intestinal microbial ecosystem. In humans, antibiotics shift the normal colonic flora towards Gram-negative aerobes replacing endogenous anaerobes such as *Bacteroides* with *Pseudomonas*, *Klebsiella*, *Clostridium* and yeasts. Fewer pathogenic organisms (e.g. *Salmonella*) are needed to colonize after antimicrobial therapy, and penicillins can lead to a fatal pseudomembranous colitis due to *Clostridium difficile* overgrowth. Yet, pseudomembranous colitis is rarely reported in dogs, and diarrhoea alone disturbs the flora, reducing anaerobe numbers.

Whilst oral antibiotics may cause diarrhoea in dogs and cats, the effect is transient; diarrhoea ceases when antibiotics are withdrawn. Nevertheless, despite their relative safety, the environmental risks of inducing antibiotic resistance and carrier status are real and thus antibiotic usage should be restricted to times of clear need. They are indicated in the following situations:

Sign or disease process	Treatment
<b>Gastrointestinal disease</b>	
Bacterial infection	Antibacterials
Constipation	Laxatives; cathartics; enemas
Diarrhoea	Anti-diarrhoeals; protectants; adsorbents
Gastric ulceration	Cytoprotectants; antisecretory agents
Hypomotility disorders	Prokinetics
Immune-mediated	Immunosuppressive
Inflammation	Anti-inflammatories
Maldigestion	Digestive enzymes
Neoplasia	Cytotoxics
Parasitic infection	Antiparasitics
Vomiting	Anti-emetics
<b>Liver disease</b>	
Bacterial infection	Antibacterials
Cholestasis	Cholagogues; choleretics
Copper accumulation	Decoppering agents
Fibrosis	Antifibrotics
Immune-mediated	Immunosuppressive
Inflammation	Anti-inflammatories; protectants; anti-oxidants; hepatotropic agents

### 28.1

Categories of treatment for specific and non-specific GI problems.

- Specific infections: e.g. *Salmonella*, *Campylobacter* (see Chapter 16)
- Haemorrhagic diarrhoea: i.e. risk of sepsis through mucosal ulceration (see Chapter 20)
- Antibiotic-responsive diarrhoea (ARD) or small intestinal bacterial overgrowth (SIBO) (see Chapter 20)
- Severe immunosuppression: e.g. chemotherapy-associated diarrhoea, parvovirus infection (see Chapter 16)
- Inhalation pneumonia associated with oesophageal disease (see Chapter 6)
- Prophylaxis in intestinal surgery (see *BSAVA Manual of Canine and Feline Abdominal Surgery*).

### Aminoglycosides

Aminoglycosides are mainly active against Gram-negative bacteria, although some streptococci and enterococci are susceptible.

**Gentamicin:** Gentamicin is effective against Gram-negative anaerobes; it is useful in combination with penicillins (see below). It is potentially nephrotoxic, and factors that increase the risk are:

- Renal dysfunction
- Age (young animals are more susceptible)
- Dehydration
- Fever and sepsis
- Concurrent treatment with non-steroidal anti-inflammatory drugs (NSAIDs)

Gentamicin (and other aminoglycosides, e.g. amikacin, tobramycin) should therefore be used only after patients have been rehydrated.

**Neomycin:** Neomycin is nephro- and ototoxic, but is not absorbed so can be given safely orally to reduce GI bacteria and ammonia production in hepatic encephalopathy. It is also present in some anti-diarrhoeal mixtures, but should **never** be used in haemorrhagic diarrhoea as it may cross the damaged mucosal barrier and cause renal damage or deafness.

### Cephalosporins and cephamycins

Oral cephalosporins are active against Gram-positive aerobes and some anaerobes, such as *Bacteroides* spp. and most *Clostridium* spp. However, they have variable activity against Gram-negative aerobes, such as *Escherichia* spp., due to acquired resistance. They are rarely used to treat primary GI infections.

Parenteral cephalosporins (e.g. cefazolin, cefamandole, cefotaxime, ceftiofur) combined with aminoglycosides may be used to treat patients with sepsis that develops from enteric bacterial translocation. Cefuroxime, ceftazidime and ceftiofur have broader activity against anaerobes and may be indicated in patients with intestinal rupture or undergoing colonic surgery.

### Chloramphenicol

Although very effective against all obligate anaerobes and bacteriostatic for most Gram-positive and many Gram-negative aerobes, chloramphenicol usage is restricted for public health reasons. Resistance develops rapidly, limiting the utility of chloramphenicol in the treatment of human salmonellosis. Chloramphenicol is metabolized by the liver, making it unsuitable for hepatic infections, and can cause bone marrow suppression, especially in cats. Concurrent administration with cimetidine causes impaired metabolism and increased toxicity.

### Lincosamides

Clindamycin and lincomycin are effective against Gram-positive aerobes and many obligate anaerobes. Both can cause serious diarrhoea in humans, horses and rabbits, but are relatively non-toxic in dogs and cats. Clindamycin is recommended for treating periodontal infection.

### Macrolides

Macrolides are generally bacteriostatic against Gram-positive aerobes and obligate anaerobes and suitable substitutes in penicillin-sensitive patients. Some may be effective at low doses by inhibiting bacterial adhesion.

**Erythromycin:** It can be bactericidal at high doses and is the drug of choice for *Campylobacter* infection, but erythromycin is ineffective against Enterobacteriaceae (e.g. *Pseudomonas*, *Escherichia*, *Klebsiella*). Erythromycin is acid-labile and should be administered on an empty stomach or as an enteric-coated formulation. It frequently causes vomiting because it mimics the GI hormone motilin. At lower doses it is prokinetic (see below).

**Tylosin:** This drug is also active against *Campylobacter* although it is only bacteriostatic. Tylosin has been used to treat SIBO, ARD and canine idiopathic colitis. It has a bitter taste.

**Spiramycin:** It is found in combination with metronidazole in some countries. Its activity against anaerobes makes it a suitable choice for periodontal infections.

**Clarithromycin and azithromycin:** Clarithromycin is more acid-stable and more active than erythromycin and has been used as part of triple therapy to treat gastric *Helicobacter* infection (see Chapter 19). Azithromycin has a longer tissue half-life than erythromycin, but again is not active against the Enterobacteriaceae.

### Metronidazole

Metronidazole is bactericidal for many Gram-positive and most Gram-negative obligate anaerobes, but has no effect on aerobes. It is often used in combination with clavulanate-amoxicillin for broad spectrum antibacterial cover. It may modulate the immune system and be beneficial in inflammatory bowel disease (IBD). At high doses it is anti-protozoal, and has been used to treat *Giardia* infection.

Metronidazole can be used alone to treat clostridial infections, SIBO, ARD and hepatic encephalopathy. Secreted in saliva, it is active against anaerobic infections in periodontal disease and is sometimes used in combination with spiramycin. However, metronidazole has a bitter taste and is not well tolerated by some cats.

Central nervous system (CNS) toxicity is common at high doses or after rapid intravenous administration, and it may be teratogenic. Cimetidine inhibits its hepatic metabolism, increasing the risk of toxicity.

### Penicillins

Penicillins are generally bactericidal against Gram-positive aerobes and anaerobes. Apart from penicillin G, they are acid-stable and can be administered orally. However, food may impair ampicillin and delay amoxicillin absorption, and so they are best given on an empty stomach.

Used alone penicillins are rarely effective against Gram-negative aerobes, except for the anti-pseudomonal penicillins, i.e. ticarcillin, carbenicillin and piperacillin. They may act synergistically with aminoglycosides, although they cannot be mixed in the same syringe. These anti-pseudomonal penicillins can be potentiated by concurrent administration with clavulanic acid, giving enhanced activity against Gram-negative pathogens and all anaerobes.

### Quinolones

Quinolones are bactericidal agents (e.g. enrofloxacin, difloxacin, ibafloxacin, marbofloxacin, orbifloxacin) which are distributed in high concentrations in the liver and GI tract as they are concentrated in bile and undergo enterohepatic recycling. Development of resistance is relatively uncommon. Highly effective against *Pseudomonas*, *Klebsiella* and Gram-negative aerobes found in the GI tract, they have some efficacy against Gram-positive aerobes. They are probably the most effective agent against *Salmonella* and, therefore, the least likely to induce carrier status. Quinolones are also effective against *Campylobacter*, and although not licensed for this use, do not have the emetic side-effect of conventional erythromycin treatment. In combination with metronidazole, they provide good cover against most enteric organisms.

Quinolones should not be used in skeletally immature patients, and should only be used with caution in epileptics. In cats there is concern that enrofloxacin can cause a dose-dependent retinal blindness. Cimetidine can reduce the clearance of fluoroquinolones, and sucralfate, aluminium-containing antacids, calcium carbonate and oral iron supplements can significantly impair their absorption; thus fluoroquinolones should be given two hours before sucralfate.

### Sulphonamides

The sulphonamides (sulfadiazine, sulfamethoxazole, sulfadimethoxine) are cheap, effective, bacteriostatic antibacterials, whose activity is potentiated by concurrent administration with trimethoprim, baquiloprim or ormetoprim, making them bactericidal. Outside the UK, they (plus sulfadimidine and sulfamethazine) are available without potentiation. Phthalylsulfathiazole is poorly absorbed from the GI tract and is present in some combination anti-diarrhoeal products.

Potentiated sulphonamides are effective against most aerobes, some anaerobes and protozoa, and are the treatment of choice for coccidiosis. In addition, they are frequently used for canine colitis, despite it being just sulfasalazine that has specific activity in the colon (see below).

Sulphonamides have a bitter taste and cats will froth at the mouth if the coated tablet is broken. Immune-mediated side-effects (e.g. polyarthritis, thrombocytopenia) are noted, but the most consistent side-effect is keratoconjunctivitis sicca (KCS) especially during sulfasalazine treatment of colitis. Sulphonamides have been shown to interfere with the measurement of thyroxine and serum folate concentrations.

### Tetracyclines

Tetracyclines (doxycycline, oxytetracycline, tetracycline) are bacteriostatic agents against many aerobes and atypical organisms, such as rickettsias and haemoplasmas. They are administered orally on an empty stomach for systemic absorption, as food, dairy products and antacids (including sucralfate) impair absorption. This may not be significant when treating intestinal luminal organisms, and interestingly, sucralfate enhances delivery of tetracyclines to sites of GI ulcers. Oxytetracycline is concentrated in the liver and undergoes biliary excretion, and thus may be effective in cholangitis. In young animals tetracyclines cause discolouration of developing teeth, but a doxycycline gel for topical treatment of periodontal infection in dental pockets is licensed for adult dogs.

Tetracyclines can cause GI disturbances, particularly in cats, where they may also cause anorexia, fever and depression. An association between oral doxycycline administration and oesophageal stricture formation exists in cats, and it is recommended that tablets are followed by a sip of water or a morsel of food. In dogs, they are most commonly used to treat ARD rather than SIBO. Despite their clear efficacy, how they can control diarrhoea for years without the development of resistance and why even sub-therapeutic doses may be effective is unclear (see Chapter 20). Tetracyclines do not sterilize the gut but may exert a pressure on the ecosystem, excluding potential pathogens, perhaps by inhibiting adherence. Alternatively, tetracyclines may be directly anti-inflammatory as they are used in humans to treat various skin disorders and arthritis.

### Antifungals

The GI tract suffers few primary fungal GI infections, and antifungal therapy is rarely indicated. The reader is referred to standard medical textbooks for further information on treating intestinal histoplasmosis and pythiosis (which do not occur naturally in the UK).

Candidiasis may occur secondary to antibacterial therapy. Oral infection can be treated with oral nystatin suspension. Protothecosis is actually an algal infection, but may respond to amphotericin B.

### Antiparasitics

#### Anthelmintics

The GI tract is susceptible to infection with numerous species of helminths (nematodes and cestodes) and a variety of compounds are available to treat them (Figure 28.2). They are used both therapeutically and as part of a general health plan to reduce any potential zoonotic risk.

**Benzimidazoles:** The benzimidazoles are selectively toxic against helminths; by inhibiting parasite tubulin in mitosis they have a lethal effect on dividing cells. Metabolism in non-dividing cells is also affected through inhibition of fumarate reductase, and non-lethal expulsion of parasites may occur.

Active ingredient	Class	Host (C = cats; D = dogs)	Roundworms				Hookworms		Whipworm	Tapeworm			Protozoa	Comment
			<i>Toxocara canis</i>	Transplacental/transmammary	<i>Toxocara cati</i>	<i>Toxascaris leonina</i>	<i>Ancylostoma caninum</i>	<i>Uncinaria stenocephala</i>	<i>Trichuris vulpis</i>	<i>Dipylidium caninum</i>	<i>Taenia</i> spp.	<i>Echinococcus granulosus</i>		
Albendazole	Benzimidazole	C, D	✓		✓	✓	✓	✓			✓	✓	Teratogenic; bone marrow suppression	
Bunamidine	Cestocide	C, D	✓						✓	✓	✗		Oral irritant	
Dichlorophen	Cestocide	C, D							✓	✗	✗			
Dichlorvos	Organophosphate				✓	✓	✓	✓					Organophosphate toxicity	
Doramectin	Avermectin	D	✓	✓		✓							<i>Spirocerca</i>	
Epsiprantel	Cestocide	C, D							✓	✓	?			
Febantel	Benzimidazole	C, D	✓		✓	✓	✓	✓				✓	Not safe in pregnancy	
Fenbendazole	Benzimidazole	C, D	✓	✓	✓	✓	✓	✓	✓	✓			Safe in pregnancy	
Flubendazole	Benzimidazole	D	✓		✓	✓	✓	✓		✓		✓		
Ivermectin	Avermectin	C	✓	✓	✓		✓	✓					Not in sensitive dogs (collies)	
Levamisole	Imidazothiazole	C, D	✓		✓	✓								
Mebendazole	Benzimidazole	C, D	✓		✓	✓	✓	✓		✓	✓		Idiosyncratic hepatopathy	
Milbemycin oxime	Milbemycin	D	✓		✓	✓	✓						Co-formulated with lufenuron	
Moxidectin	Milbemycin	D				✓								
Nicosamide	Cestocide	C, D							✓	✓				
Nitroscanate	Isothiocyanate	D	✓		✓	✓	✓		✓	✓	?			
Oxantel	Tetrahydropyrimidine	D						✓						
Oxibendazole	Benzimidazole	D	✓			✓	✓						Co-formulated with praziquantel	
Piperazine	Hexahydropyrazine	C, D	✓		✓	✓	✓							
Praziquantel	Cestocide	C, D							✓	✓	✓		Co-formulated with febantel and/or praziquantel	
Pyrantel	Tetrahydropyrimidine	D	✓		✓	✓	✓							
Selamectin	Avermectin	C, D	✓	✓	✓	✓	✓							
Tiabendazole	Benzimidazole	C, D	✓	✓	✓	✓	✓						Activity against <i>strongyloides</i>	

**28.2** Spectrum of activity of anthelmintics in dogs and cats. ✓ = effective; ✗ = not effective.

All drugs in this class have poor intestinal absorption. Concurrent administration with a fatty meal may increase absorption, but any absorbed drug is metabolized in the liver and excreted in the faeces (most derivatives) or urine (albendazole). Thus systemic clearance is rapid and related to intestinal transit time. As higher doses do not necessarily relate to higher systemic concentrations, repeated doses (generally for 3–7 days) may be as effective as a single high dose. High doses of benzimidazoles may affect the rapidly dividing cells in the host's GI tract and bone marrow, as well as being potentially teratogenic.

- **Tiabendazole** (thiabendazole), the first benzimidazole marketed, is now rarely used as it can be hepatotoxic. However, it is active against larval and adult roundworms, and is useful in *Strongyloides* infections.
- **Oxibendazole** (not in UK) is effective against roundworms, hookworms and whipworms; it is often marketed in combination with praziquantel.
- **Mebendazole**, when administered orally daily for 3 days, is effective against all nematodes and *Taenia* spp. Although the lethal dose is very high, individual dogs may have an idiosyncratic hepatotoxicity.

- **Flubendazole** (not in UK) has a spectrum activity similar to mebendazole, but with greater activity against whipworms.
- **Albendazole** has a similar spectrum of activity to fenbendazole but is rarely used because of associated bone marrow toxicity and teratogenicity.
- **Fenbendazole** is effective against: routine roundworms, hookworms and whipworms; unusual parasites, such as *Ollulanus*, *Physaloptera*; respiratory parasites; and *Angiostrongylus*. It is also very effective and licensed for treatment of *Giardia* infection at a dose of 50 mg/kg/day p.o. given for 3 days in dogs and 5 days in cats. It is remarkably safe and can be administered to pregnant bitches to prevent transplacental *Toxocara* transmission.
- **Febantel** is a pro-benzimidazole, converted to the active ingredients fenbendazole and oxfendazole, with a similar spectrum of activity to fenbendazole except for *Ancylostoma brasiliense* and transplacentally transmitted *Toxocara canis* larvae. It is often available in combination products with pyrantel and praziquantel, when enhanced activity against *Ancylostoma* and *Trichuris* occurs.

**Nicotinic anthelmintic agents:** They selectively block the nicotinic acetylcholine receptors in parasites leading to paralysis and expulsion. At high doses, receptor desensitization may occur and the parasite recovers. Therefore, repeated lower doses are more effective.

- **Pyrantel embonate** is poorly absorbed, increasing its safety and efficacy compared with pyrantel tartrate (pamoate) but may be eliminated too quickly if there is diarrhoea. It is antagonized by piperazine.
- **Oxantel** (not in UK) is an analogue of pyrantel, with particular activity against whipworms.

**Levamisole:** It is effective against roundworms and hookworms, but not against whipworms. However, it is rarely used for intestinal parasites because of its narrow therapeutic index and frequent side-effects of vomiting, shaking and arrhythmias.

**Avermectins:** They are potent anthelmintics with activity against intestinal parasites, *Dirofilaria* and arthropod parasites. Toxicity tends to occur in selected individuals, especially Collies, because of a genetic defect in a P-glycoprotein expression (multiple drug resistance gene, *MDR1*), which normally pumps such molecules out of the neurons. Susceptible dogs show depression, tremors, ataxia, stupor, emesis, salivation and coma.

- **Ivermectin** is effective against *Toxocara* (but not *Toxascaris*), *Ancylostoma*, *Uncinaria*, *Strongyloides* and *Physaloptera*. It is not licensed for use in dogs because of the potential for toxicity, especially in Collies, and can rarely be justified for treating endoparasites.
- **Selamectin** is the most recently marketed avermectin and is effective against *Toxocara* as a spot-on topical treatment used once a month. Evidence of its efficacy against other endoparasites is still unknown.

- **Doramectin** is not licensed for small animals as neurotoxicity may occur in ivermectin-sensitive individuals. It has been shown to stop milk transmission of *Toxocara* and *Ancylostoma*. It has been used to treat *Spirocerca lupi* infections causing oesophageal granulomas.

**Milbemycins:** They are similar to avermectins but have less CNS toxicity. Originally noted to be effective against mites and *Dirofilaria*, they can also kill endoparasites.

- **Milbemycin oxime** can kill *Toxocara*, *Trichuris* and *Ancylostoma*, and in the UK is marketed in combination with lufenuron.
- **Moxidectin** (not in UK) can stop milk transmission of *Ancylostoma*. Adverse reactions in some Collies are reported.

**Miscellaneous:** A number of other agents have antihelmintic properties. Some, such as toluene and *N*-butyl chloride, are not licensed in the UK but may be available in over-the-counter preparations.

- **Piperazine** is readily available over-the-counter. It paralyzes helminths by acting as a gamma amino-butyric acid (GABA) agonist, and the paralysed worm must then be expelled. As it does not actually kill adult worms or larvae repeated doses are needed to control infections in young animals. Its action is antagonized by pyrantel. It is remarkably safe, but vomiting, diarrhoea, inappetence and neurological signs may occur.
- **Dichlorvos** is an organophosphate effective against helminths; however, signs of organophosphate poisoning can occur as a result of overdosing or when given in combination with other organophosphates.
- **Nitroscanate** is effective against ascarids, hookworms (except *Trichuris*) and tapeworms. Its general safety is good, but at least 10% of dogs will vomit. Efficacy and safety are improved if it is given with food. It should not be used in cats as it will cause vomiting, inappetence and CNS disturbances.

**Cestocides:** Intestinal tapeworms rarely cause disease in dogs and cats. Treatment is indicated for public health concerns (i.e. elimination of *Echinococcus*), to stop transmission to food animals and for aesthetic reasons. A number of agents are available but praziquantel (see Figure 28.2) is usually preferred.

- **Bunamidine hydrochloride** (no longer licensed in UK) disrupts the tapeworm integument and adenosine triphosphate (ATP) production, destroying proglottids. It may not kill the scolex, permitting restrobilation. Bunamidine hydrochloride is irritant to the buccal mucosa if the coating is broken, and it can cause vomiting and diarrhoea. It can be cardiotoxic, and rare idiosyncratic hepatotoxicity and death in dogs is recorded.

- **Dichlorophen** is little used, as its efficacy is restricted to *Taenia* spp. It may fail to kill the scolex of *Dipylidium* and *Echinococcus*. Although it is poorly absorbed, in dogs it may cause vomiting and diarrhoea, and in cats inappetence, hyperaesthesia, salivation and ataxia are reported.
- **Niclosamide** (not in UK) is effective against *Taenia* spp. and *Dipylidium caninum*. It may cause transient vomiting and diarrhoea.
- **Praziquantel** is a highly effective and safe cestocide, and is also effective against trematodes (except *Fasciola*). It can be given orally or parenterally. Epsiprantel is available in some countries and has a similar mode of action, although it is only available orally. Praziquantel is rapidly taken up by tapeworms, causing contractions due to calcium fluxes and vacuolation of the integument making the worm susceptible to immune attack. It is absorbed from the GI tract (this is enhanced by food) and widely distributed to all tissues. It is rapidly metabolized and inactive compounds are excreted in urine. It has a high margin of safety but can cause transient vomiting, drowsiness and staggering. Pain at the site of injection is noted. Its efficacy is impaired by concurrent administration of corticosteroids.

#### Anti-protozoals

For the treatment of *Toxoplasma* see *BSAVA Manual of Canine and Feline Infectious Diseases*. Pathogenic enteric parasites include *Giardia* and *Isospora* and other coccidians including *Cryptosporidium*, *Entamoeba* spp., *Pentatrichomonas* spp., *Tritrichomonas foetus* and *Balantidium coli* are potential pathogens.

**Amprolium:** This has been reported to be effective against *Coccidia* and relatively safe in both puppies and cats, but is licensed in the UK only for the treatment of pigeons. Other poultry coccidiostats should never be used in dogs and cats as toxicity has been recorded in both species.

**Doxycycline:** It is effective against *Entamoeba* spp., *Balantidium coli*, *Isospora* spp. and *Toxoplasma* spp. (see above).

**Fenbendazole:** It (and albendazole) is (are) effective against *Giardia* spp. (see above).

**Furazolidone:** This antibacterial is also effective against *Giardia* but has been withdrawn because of concerns of carcinogenicity.

**Metronidazole:** At high doses it is effective against *Giardia*. Reports of resistance may be real but sometimes reflect underdosing, as the effective dose is near the neurotoxic dose (see above).

**Nitazoxanide:** This new product, used for the treatment of cryptosporidiosis and giardiasis in humans and horses, is currently undergoing pilot studies in dogs and cats. It is not licensed and cannot yet be recommended.

**Paromomycin:** It is an amoebicide and has been reported to treat *Cryptosporidium* successfully. However, it can damage kidneys and is probably too unsafe for cats.

**Quinacrine:** It is active against *Coccidia* and *Giardia*, has a very bitter taste but is no longer available.

**Sulphonamides:** They are considered the treatment of choice for *Coccidia*. Although most efficacy trials were performed with sulfamethoxine or sulfaguanidine, they are no longer available. Their substitution by potentiated sulphonamides has largely been extrapolated (see above).

**Tylosin:** There are anecdotal reports of efficacy against *Cryptosporidium*.

#### Anti-emetics

Anti-emetics inhibit vomiting and are indicated for:

- Prevention of vomiting in predictable circumstances, e.g. travel sickness, chemotherapy
- Control of vomiting, especially when protracted and profuse, causing water and electrolyte disturbances and patient distress.

They are contraindicated in:

- GI obstruction
- Toxin ingestion
- Hypotension.

Anti-emetics control emesis by either peripheral or central actions.

#### Peripherally acting anti-emetics

Occasionally drugs used for their locally protective effect on the GI tract will also stop vomiting; protectants and acid-blockers are discussed below. Prokinetics, such as metoclopramide, can physically antagonize emesis by increasing lower oesophageal sphincter tone and gastric emptying (see below).

**Anticholinergics:** The anticholinergics that cross the blood-brain barrier and exert a central effect are discussed below.

- **Glycopyrronium bromide, propantheline bromide, methscopolamine, isopropamide and aminopentamide** do not cross the blood-brain barrier and are anti-emetic because they inhibit efferent vagal stimuli, relieve smooth muscle spasm and reduce GI secretions. They are frequently used in practice but often inappropriately as they cause gastric atony and intestinal ileus, which may potentiate vomiting and absorption of toxins. They can also cause dry mouth, constipation, tachycardia and urine retention. They are not recommended for cats.

**Centrally acting anti-emetics**

Depending on which neurotransmitter they block and at which site, they have either a broad or narrow spectrum of activity.

**Anticholinergics:** Anticholinergics are anti-emetics blocking muscarinic receptors in higher centres of the brain and the vomiting centre, and so must be able to cross the blood-brain barrier.

- **Butylscopolamine (hyoscine)** acts centrally but still has a peripheral antimuscarinic action with the expected side-effects (see above). In the UK there is a veterinary licensed combination of butylscopolamine and a NSAID, metamizole (dypyrone).

**Antihistamines:**

- **Chlorphenamine (chlorpheniramine), cyclizine, dimenhydrinate and diphenhydramine** are largely ineffective against most causes of vomiting but control motion sickness in dogs by blocking H<sub>1</sub> receptors in the vestibular apparatus. Such receptors are not involved in motion sickness in cats. Drowsiness and dry mouth are recognized side-effects.
- **Meclizine and promethazine** have a longer duration of action and are chosen for vestibular disease.

**Phenothiazines:**

- **Prochlorperazine, acepromazine maleate, chlorpromazine and promazine** are broad spectrum anti-emetics blocking vomiting in the chemoreceptor trigger zone and possibly the vomiting centre. They are hypotensive and so should only be used once dehydration is resolved. These drugs can all cause drowsiness, but this effect is less with prochlorperazine. However, a tranquillizing effect can be helpful if the vomiting patient is distressed.

Phenothiazines can have significant interactions with organophosphates and CNS depressants (barbiturates, narcotics); anti-diarrhoeals and antacids may impair absorption; and phenothiazines are incompatible in the syringe with penicillin, chloramphenicol and hydrocortisone. Prochlorperazine is only available in some countries in a combination product with isopropamide.

**Butyrophenones:**

- **Haloperidol and droperidol** are potent anti-dopaminergic anti-emetics but are rarely used in veterinary medicine.

**Sedatives:**

- **Barbiturates and benzodiazepines.** Phenobarbital and a variety of benzodiazepines have been used to control psychogenic and behavioural vomiting, and limbic epilepsy. Phenobarbital is also useful to control hypersialism, sialoadenitis and salivary infarction, although the mechanism of action is unclear.

**Corticosteroids:**

- **Dexamethasone and methylprednisolone** can also be anti-emetic, by unknown mechanisms, particularly during chemotherapy.

**Anti-dopaminergic agents:** Metoclopramide is recognized as a generally safe anti-emetic, although animal studies are limited and most information is extrapolated from humans. Whilst it is the first choice anti-emetic in dogs, the veterinary licensed product is no longer marketed in the UK, although human and generic formulations are still available. It is active against emetics that stimulate the chemoreceptor trigger zone by antagonizing central D<sub>2</sub> dopaminergic and 5HT<sub>3</sub> serotonergic receptors. Metoclopramide is potentiated by glucocorticoids or phenothiazines. It has a number of other helpful properties, being prokinetic in the upper GI tract and inhibiting gastro-oesophageal reflux (see below).

Metoclopramide is available as tablets and a light-sensitive, injectable formulation. It is especially useful as a continuous intravenous infusion, particularly in puppies recovering from parvovirus that suffer ileus and continue to vomit, but also in other patients susceptible to its CNS side-effects. Like all anti-emetics it is contraindicated if there is a GI obstruction.

In some patients, especially cats, it may cause bizarre behavioural changes ranging from sedation to hyperactivity and tremors, which may be potentiated by phenothiazines and fluoxetine. It may reduce the amount of propofol needed for induction. It is excreted by the kidneys, and toxicity is more likely in cases of renal insufficiency.

**Anti-5HT<sub>3</sub> agents:** By blocking 5HT<sub>3</sub> receptors, ondansetron is a very potent anti-emetic developed for humans receiving chemotherapy. It is more likely to prevent vomiting (i.e. given before chemotherapy) than stop ongoing vomiting, and is effective in postoperative nausea.

It appears to be effective in dogs but is very expensive and not licensed; thus it is generally reserved for cisplatin toxicity and refractory vomiting. Side-effects are mild but include sedation and head-shaking. Related drugs (e.g. dolasetron, granisetron, tropisetron) are rarely used in veterinary medicine.

**Prokinetics**

Prokinetics stimulate motility in part or all of the GI tract and are indicated when there is ileus not related to electrolyte imbalances. They are contraindicated in intestinal obstruction.

**Cholinergics**

The use of cholinergics is limited by their tendency to cause systemic effects. Pilocarpine, arecoline and carbachol are purgatives causing marked abdominal cramping and pain.

**Bethanechol:** This acts exclusively on M<sub>2</sub> muscarinic receptors and increases contractions throughout the GI tract, but mostly at the lower oesophageal sphincter



and in the rectum. It has been suggested as a treatment for megaesophagus (its efficacy is unproven), reflux oesophagitis, megacolon and dysautonomia. It is poorly prokinetic in the small intestine but can also cause abdominal cramps, diarrhoea, salivation and bradycardia.

**Pyridostigmine:** This is an anticholinesterase used to treat focal myasthenia gravis of the oesophagus. It has prokinetic effects, potentiating the action of acetylcholine at the neuromuscular junction.

#### Metoclopramide

In addition to its central anti-emetic effect (see above) metoclopramide acts peripherally as an anti-dopaminergic and cholinergic agent. Its activity is abolished by antimuscarinics, such as atropine. Although its activity is confined to the upper GI tract, it can be useful in preventing gastro-oesophageal reflux and promoting gastric emptying. It is not effective in treating gastric dilatation or megacolon.

#### Domperidone

Domperidone is a dopamine antagonist with similar prokinetic activity to metoclopramide in humans. However, it cannot cross the blood-brain barrier so does not have central anti-emetic activity or cause CNS side-effects. Its activity in dogs or cats has not been fully studied.

#### Cisapride

Cisapride was the most effective prokinetic available until it was withdrawn a couple of years ago because of QT-prolongation and fatal cardiac arrhythmias (*torsades de pointes*) in humans. The risk was enhanced when concurrently administered with drugs inhibiting cytochrome P450. Cisapride stimulates GI 5HT<sub>4</sub> receptors, resulting in:

- Contraction of oesophageal smooth muscle (most significant in cats)
- Increased lower oesophageal sphincter tone
- Decreased pyloric tone
- Propulsive peristaltic waves in stomach, duodenum, jejunum and colon.

Cisapride was indicated for gastro-oesophageal reflux and GI motility disorders, including feline idiopathic megacolon. As the canine oesophagus is largely striated muscle, it was not effective in idiopathic megaesophagus. Although now withdrawn, stocks may still be available. Newer, 5HT<sub>4</sub> agonist prokinetics, prucalopride and tegaserod are in the late stages of human trials.

#### H<sub>2</sub> antagonists

H<sub>2</sub> antagonists, such as ranitidine and nizatidine, are anti-ulcer drugs (see below) and also weak prokinetics, and so may be an appropriate choice in gastritis where their acid-blocking activity will complement their ability to stimulate gastric emptying. They cause *in vitro* muscle contraction in the lower GI tract and have been recommended for feline idiopathic megacolon when cisapride is not available.

#### Erythromycin

The emetic side-effect of antibacterial doses of erythromycin (i.e. 10 mg/kg orally), through hyperstimulation of motilin receptors in the GI tract, is well known. At lower doses (i.e. 1–2 mg/kg orally) erythromycin stimulates motility resembling normal migrating motor complexes, and this can be used as a helpful prokinetic effect. However, the peristalsis it causes most resembles the interdigestive motility pattern.

#### Mucosal (cyto)-protectants

Protectants aid barrier function when oesophageal or gastric ulceration exists, and may act as cytoprotective agents, chemical diffusion barriers or both. Cytoprotective agents enhance the viability of GI epithelial cells, particularly through the effects of beneficial prostaglandins.

#### Prostaglandins

Cytoprotective prostaglandin (PG) Es are crucial to the health of the gastric mucosal barrier because they:

- Increase gastric mucosal blood flow
- Increase gastric mucus secretion
- Stabilize histamine-containing enterochromaffin-like cells
- Decrease gastric acid secretion.

It is the inhibition of the constitutive cyclo-oxygenase enzyme (COX-1) by NSAIDs that leads to a deficiency of cytoprotective PGE and gastric ulceration. Synthetic PGEs, misoprostol and enprostil (E1 and E2, respectively) can protect against such damage whilst the NSAIDs still exert their anti-inflammatory effect against the inducible COX-2 enzyme.

Misoprostol has been shown in dogs to protect the gastric mucosa from aspirin-induced ulceration, but it is not very effective at healing pre-existing ulcers. It is indicated in dogs that must take NSAIDs for chronic inflammatory disease but that suffer gastro-erosive side-effects. Misoprostol does not have a UK veterinary licence. It is given orally and diarrhoea is a side-effect that is usually self-limiting, and actually lessened if NSAIDs are being concurrently administered. Being a prostaglandin, misoprostol will cause abortions and must not be used in pregnancy.

#### Antacids

Compounds, such as aluminium hydroxide, calcium carbonate, sodium bicarbonate and magnesium oxide and hydroxide, are relatively safe and effective orally administered protectants. As well as neutralizing gastric acid they decrease pepsin activity, bind bile acids, stimulate bicarbonate secretion, and possibly increase endogenous PG production.

Most available preparations usually contain combinations of aluminium and magnesium hydroxide to maximize the buffering capacity and counter-balance their intestinal side-effects. Calcium and sodium carbonate have the shortest duration of action; magnesium hydroxide is more prolonged; and aluminium hydroxide has the most persistent effect. Aluminium

hydroxide is also helpful in the vomiting uraemic patient as it reduces hyperphosphataemia. Antacids are sometimes combined with a local anaesthetic (oxethazine), another protectant (sodium alginate) or an anti-foaming agent (activated dimethicone) to enhance their utility in gastro-oesophageal disease.

Antacids are not popular in veterinary medicine because oral administration is problematic in a vomiting patient and a high volume must be administered 4–6 times daily. If not given frequently, their administration is followed by a rebound secretion of acid, and gastric pH becomes even lower.

All antacids can interfere with the absorption of drugs such as digoxin, tetracyclines and fluoroquinolones. They may also alkalinize urine, increasing the excretion of weak acids, e.g. NSAIDs and phenobarbital. Calcium and sodium carbonate may produce large volumes of gas (CO<sub>2</sub>). Calcium-containing antacids tend to promote constipation, and predispose to metabolic alkalosis, soft tissue calcification and urolithiasis. Magnesium salts tend to promote diarrhoea through increased bowel motility, whilst aluminium salts reduce GI motility. They are frequently combined so that these effects counteract each other. Long-term use of aluminium compounds may cause hypophosphataemia and perhaps neurotoxicity.

#### Bismuth salts

Compounds such as bismuth subcarbonate, bismuth subnitrate, tripotassium dicitratobismuthate and bismuth subsalicylate have a cytoprotective effect in the stomach (stimulate bicarbonate and PG production) and are antibacterial against *Helicobacter* spp. They make stool colour darker, which can potentially be mistaken for melaena. They are also used as anti-diarrhoeals (see below). Long-term use should be avoided as absorbed bismuth is neurotoxic.

#### Sucralfate

Sucralfate is an orally administered complex of sucrose octasulphate and aluminium hydroxide, available in the UK as tablets and suspension. In some countries the suspension is not available, but the large 1 g tablets can be crushed and suspended in water.

At a basic level, sucralfate aids healing of gastro-oesophageal erosions and ulceration by binding to the tissue, forming a barrier against gastric acid penetration. In an acidic gastric environment the sucrose is freed from the aluminium hydroxide and cross-polymerizes the proteinaceous exudates over ulcerated tissue. Whilst this mechanism is important, it known that sucralfate also:

- Inactivates pepsin
- Binds refluxed bile acids
- Is cytoprotective through stimulation of endogenous PG synthesis
- Increases mucosal blood flow
- Binds and concentrates epidermal growth factor, stimulating GI epithelial cell proliferation
- Binds antibiotics, such as tetracyclines, at the ulcer site.

Sucralfate has no UK veterinary licence but its safety is well accepted. Less than 5% is absorbed and excreted unchanged in urine, and constipation is the only reported side-effect. The controversy concerning sucralfate relates to its drug interactions. There is no doubt that the aluminium component blocks the absorption of fluoroquinolones, tetracyclines, theophylline, aminophylline, digoxin, azithromycin and perhaps cimetidine. It is therefore recommended that these drugs are administered 2 hours before sucralfate.

However, there is a hypothetical argument that not only does concurrent administration with H<sub>2</sub> antagonists prevent their absorption, but also that their acid blockade may prevent sucralfate precipitation. These arguments appear to have little basis in fact; interaction with ranitidine has been shown by Millersman *et al.* (1986) to be insignificant but studies in dogs and cats are lacking. Thus, it is still recommended that these drugs be given 30–60 minutes apart, although which should be given first is rarely made clear! Antibiotics **must** be given 2 hours before sucralfate, but it seems sensible to give sucralfate both before and after feeding (i.e. on an empty stomach) to coat ulcerated areas, whilst acid-blockers are given 30 minutes before food to prevent reflex acid secretion. By using an acid-blocker that needs to be given only once daily (e.g. famotidine, omeprazole) problems of concurrent administration occur less frequently, and reduced frequency of administration improves owner compliance.

#### Acid blockers (anti-ulcer drugs)

Acid blockade is an important part of healing oesophageal and gastric ulceration, and although effective drugs have been available for over 25 years, recently more potent drugs, needing just once daily administration, have become available. Reduced acid secretion may enhance the activity of exogenous pancreatic enzyme in exocrine pancreatic insufficiency (EPI) but this effect is rarely clinically apparent. Raising the gastric pH can reduce the absorption of metoclopramide, digoxin, itraconazole and ketoconazole, which should therefore be given 2 hours prior. Chronic use may predispose to bacterial overgrowth.

#### H<sub>2</sub> antagonists

There are no UK licensed veterinary H<sub>2</sub> receptor antagonists. Nevertheless, they are effective, reversible competitive antagonists, blocking histamine-induced gastric acid and pepsin secretion. The four available compounds (cimetidine, ranitidine, nizatidine and famotidine) differ in their potency and pharmacokinetics (see below) but no studies have demonstrated enhanced clinical benefit in gastric ulceration providing equipotent doses are used. Rebound acid hypersecretion, after drug withdrawal, is greatest with cimetidine.

**Cimetidine:** Although not licensed, cimetidine has been used for over 25 years in veterinary medicine. It is an effective H<sub>2</sub> antagonist, blocking histamine-induced gastric acid secretion. It may also have immunomodulatory effects by blocking H<sub>2</sub> receptors on T cells.

Cimetidine can be given parenterally or orally, with an oral bioavailability of 70%. However, its plasma half-life is only 1 hour (this may be increased in hepatic or renal disease) and its acid blockade lasts less than 6 hours. Thus it needs to be given four times daily. It undergoes hepatic metabolism and is excreted in urine both changed and unchanged. The dose should be reduced by 50% in renal insufficiency.

Through its effects on hepatic cytochrome P450 activity, cimetidine has significant drug interactions; it decreases the breakdown of chloramphenicol, metronidazole, lidocaine, procainamide, theophylline, warfarin, propranolol, diazepam and others, and can therefore cause unexpected toxicities. It also decreases sex hormone degradation, and gynaecomastia is a recognized complication in men. It reduces hepatic blood flow significantly and is not a good choice to treat gastric ulceration in chronic hepatic disease. Ranitidine, nizatidine and famotidine do not have the hepatic side-effects and can be given less frequently, although studies of their efficacy in clinical cases is lacking for dogs and cats.

**Ranitidine:** It has lower oral bioavailability (50%) than cimetidine but is reported to be 5–10 times more potent. It has a longer duration of action, only needing to be given two or three times daily. It does not have the hepatic side-effects of cimetidine and has the added bonus of mild prokinetic activity (see above). The intravenous preparation should be administered slowly as it may cause cardiac arrhythmias.

**Nizatidine:** At least ten times more potent than cimetidine, nizatidine may require only once daily dosing. Oral nizatidine is almost completely absorbed and then excreted in urine, and is a good choice in liver disease. It also has a mild prokinetic effect (see above).

**Famotidine:** It is 20–50 times more potent than cimetidine, and although famotidine is poorly absorbed orally (37% bioavailable), its duration of action necessitates only once daily administration. It is completely excreted in urine. The intravenous preparation provides rapid onset acid blockade in critical patients, although the dose should be halved if there is renal impairment.

#### Proton pump inhibitors

Proton pump inhibitors (PPIs) are substituted benzimidazoles that irreversibly bind the proton pump, the final step in acid secretion (i.e.  $H^+K^+$ -ATPase), and so are very potent inhibitors of gastric acid secretion. Their advantage over most  $H_2$  antagonists of greater potency and once daily administration, with only marginally greater cost, means they are being used more frequently, although none is licensed for dogs or cats. They are the drug of choice for severe reflux oesophagitis, severe gastritis and gastric ulcers, and rare conditions such as gastrinomas.

**Omeprazole:** This was the first PPI to be marketed and is 30 times more potent than cimetidine. Omeprazole is a weak base and is unstable in an acid

environment; thus it is formulated as encapsulated enteric-coated granules that dissolve in the more alkaline intestinal pH. The granules must not be crushed. As acid secretion is progressively blocked and gastric pH rises, oral bioavailability increases and so plasma concentrations increase over the first 5 days. Molecules selectively partition into the acidic environment of the gastric parietal cell and, after protonation, irreversibly bind the proton pump. The gradual accumulation in the parietal cell results in a lag phase of up to 5 days before maximal effect, but activity continues after the drug is discontinued.

Omeprazole is probably the only PPI needed in small animal practice, being available in convenient 10 and 20 mg capsules, and an intravenous preparation. It is inactive at physiological pH and inhibits ATPase only in gastric parietal cells. It does inhibit the P450 elimination of some drugs, such as warfarin and diazepam, but has fewer side-effects than cimetidine. However, because of its potency, omeprazole can cause reflex hypergastrinaemia and therefore hypertrophic gastritis, which has been linked to induction of carcinoid tumours in rodents. A similar consequence has not been seen in dogs and cats, but gastric acid secretory capacity is increased after treatment.

#### Second generation PPIs:

- **Lansoprazole, pantoprazole and rabeprazole** appear to have little additional benefit over omeprazole. Pantoprazole was the first PPI to be available for intravenous use, but the data sheet reports it causes pulmonary oedema in dogs at high (7 mg/kg) doses.
- **Esomeprazole.** Omeprazole is a racemic mixture of two isomers, only one of which is active. The active isomer, esomeprazole, is now available as a pure preparation.

#### Anti-diarrhoeals

##### Intestinal protectants and adsorbents

Anti-diarrhoeal products include kaolin, aluminium hydroxide, aluminium phosphate, calcium carbonate, pectin, activated charcoal, magnesium trisilicate and hydrated magnesium-aluminium trisilicate (activated attapulgite). Such products have been used for years but their efficacy is unproven as most cases of acute diarrhoea are naturally self-limiting, and even microfine barium sulphate suspensions, used for radiological examination, appear to have an anti-diarrhoeal effect.

The concept that anti-diarrhoeals merely act by coating the mucosa, protecting it from irritation, has been challenged as most possess both protectant and adsorbent properties. Their positive actions probably include:

- Binding water and making diarrhoea less fluid
- A direct antisecretory effect
- Binding toxins and pathogenic bacteria.

They are all likely to interfere with the absorption of other orally administered drugs.

**Kaolin and pectin:** Kaolin is an aluminium silicate, whilst pectins are natural polygalacturonic acids extracted from fruit; their combination suspended in 20 parts of water is a demulcent and adsorbent. Their efficacy for treating diarrhoea in small animals is unproven, but their use has stood the test of time. They are sometimes combined with antibacterials, anticholinergics or morphine but such polypharmacy may be inappropriate (see Neomycin and Antiemetics above).

- **Montmorillonite** is a trilaminar smectite clay with adsorbent properties superior to those of regular kaolin. It is marketed in combination with simple sugars and electrolytes.

**Activated charcoal:** Activated charcoal is an adsorbent that is primarily used for treating intoxications. Activated charcoal possesses more pores and increased binding capacity than plain charcoal. Its efficacy in treating diarrhoea and odiferous flatulence is unproven.

**Bismuth:** As well as their use in treating gastric disease (see above), insoluble bismuth salts (bismuth subcarbonate, bismuth subnitrate and bismuth subsalicylate) may be beneficial in acute diarrhoea. The subsalicylate-containing preparation can be useful in acute inflammation but such compounds should be used cautiously in cats as nearly all the salicylate is systemically available.

**Colestyramine (cholestyramine):** Colestyramine is a basic anion exchange resin which binds bile acids that may be stimulating intestinal secretion, and thus can symptomatically reduce diarrhoea. It should be administered with food or water. Nausea and constipation are possible side-effects.

#### Motility modifiers

Modification of intestinal motility can be a useful symptomatic treatment for acute diarrhoea. Motility is often inextricably linked with GI secretion, and many of these motility modifiers are also antisecretory. Thus as well as delaying transit time, relieving abdominal pain and tenesmus, and reducing the frequency of defecation, motility modifiers may also decrease the volume of diarrhoea. However, they are rarely essential as most acute diarrhoea is self-limiting, and slowing intestinal transit may actually be deleterious if toxin-producing bacteria are retained.

**Anticholinergics:** Antimuscarinics are not recommended in the management of diarrhoea in small animals, although they are frequently included in combination products. As most diarrhoea is associated with intestinal hypomotility they are likely to worsen ileus, especially if concurrent hypokalaemia is present. Since they inhibit only gastric and not intestinal secretion, and they preferentially decrease segmental intestinal contractions, any propulsive peristalsis is unimpeded and diarrhoea will occur. They may also have undesirable systemic effects (see Antiemetics above).

Agents used include atropine, homatropine, butylscopolamine (hyoscine), aminopentamide, dicycloverine hydrochloride (dicyclomine), glycopyrrolate, propantheline bromide, and clidinium. They may be justified in the short term for the relief of tenesmus and pain in acute colitis. Butylscopolamine is commonly combined with metamizole (dypyrone), an NSAID. A combination of clidinium and a benzodiazepine (chloridiazepoxide) has been recommended for treating irritable bowel syndrome (IBS), although this syndrome is poorly characterized in small animal medicine. It is believed to occur in stressed working dogs and over-anxious toy breed dogs. However, this combination product is not available in the UK.

**Opioids:** The ability of opiates to cause constipation is well known, and opioids are effective anti-diarrhoeals. They increase segmental intestinal contractions, delay transit and have an antisecretory effect. They are indicated for temporary, non-specific relief of acute diarrhoea and may be of benefit in faecal incontinence. Paregoric (tincture of opium) is used occasionally, and a kaolin and morphine combination is available.

- **Diphenoxylate and loperamide.** As well as their motility-modifying effect these opioids also increase fluid and water absorption and inhibit the activity of secretagogues such as *Escherichia coli* enterotoxin. Diphenoxylate is a pethidine (meperidine) derivative marketed in combination with atropine to discourage substance abuse, but at therapeutic doses the atropine has no clinical effect.

**Anti-spasmodics:** Painful intestinal spasm in acute GI disease can be relieved by antimuscarinic agents. Butylscopolamine is used symptomatically (see above). Repeated intestinal spasm ('irritable bowel syndrome') is better treated with dietary modification and perhaps anxiolytics.

- **Mebeverine** is an antispasmodic, which acts as a calcium channel blocker, and is derived from peppermint oil. It, and its natural oil source, are used in humans to treat IBS and flatus, but their efficacy in dogs is untested.

#### Immunosuppressive and anti-inflammatory agents

Beneficial effects of NSAIDs may be noted in GI inflammation and the efficacy of bismuth subsalicylate and sulfasalazine is recognized in acute inflammatory intestinal disease. However, the deleterious effects of NSAIDs on the GI tract and kidneys, particularly in dehydrated patients, predominate and, in general, NSAIDs should not be used in GI disease.

#### Corticosteroids

**Prednisolone:** Prednisolone (and methylprednisolone) is (are) the first choice immunosuppressive agent(s) in dogs and cats. Dexamethasone has similar immunosuppressive effects in equipotent doses, but has deleterious effects on brush border enzyme activity and is not recommended.

An initial dose of 2–4 mg/kg q24h orally or parenterally of prednisolone is used and then tapered (see Chapter 20). The aim of therapy is always to find the minimum effective dose, which hopefully is either zero or at least low dose (0.5 mg/kg) every other day administration. The Cushingoid side-effects of prednisolone are well known and so if the minimum effective dose still causes significant side-effects, adjunctive agents should be introduced for their steroid-sparing effect.

**Budesonide:** An enteric-coated version of this novel steroid is available. Budesonide is largely metabolized first-pass through the liver and thus the systemic side-effects are minimized. However, steroid hepatopathy has been noted in dogs and there is certainly some depression of the adrenal axis. There are anecdotal reports of budesonide's efficacy in canine and feline IBD, but some studies used the non-enteric-coated formulation from asthma inhalers, and in others the appropriate dosage was unknown. Further evaluation in small animals is required before budesonide can be recommended.

#### Azathioprine

In humans, this immunosuppressive agent is not effective unless the patient is already on steroids, takes 2–4 weeks to be fully effective, and its premature withdrawal may result in relapse. Its major use is not as a first-line agent, but as a steroid-sparing drug.

Bone marrow toxicity (neutropenia, anaemia) is uncommon in dogs, but it will occur within weeks in some individuals. These animals probably lack thiopurine methyl transferase (TPMT), the enzyme necessary to degrade 6-mercaptopurine, azathioprine's active metabolite. TPMT activity is low in cats, which explains why the recommended dose for cats is so much lower than for dogs (0.3 *versus* 2.0 mg/kg/day). As the smallest formulation available in the UK is 25 mg, and splitting of this coated cytotoxic is prohibited, azathioprine is not a good choice for cats. In some countries reformulation is available, but there are still health concerns about the urinary excretion of this cytotoxic in the home.

#### Other cytotoxics

In feline IBD other immunosuppressive agents, such as chlorambucil or cyclophosphamide, are better choices if prednisolone alone is not effective.

#### 5-Aminosalicylic acid (5-ASA) derivatives

Colitis is common in dogs in some countries, but is also often secondary to SI disease or part of generalized IBD. Nevertheless, the use of 5-ASA derivatives with anti-inflammatory activity is appropriate in isolated acute and chronic colitis.

**Sulfasalazine:** This is a pro-drug; a diazo bond, binding sulfapyridine to 5-ASA, is cleaved by colonic bacteria to release free 5-ASA, which acts locally in high concentrations in the colon as an anti-inflammatory. Hepatotoxicity can occur but the major side-effect is keratoconjunctivitis sicca (KCS), and thus regular Schirmer tear tests should be performed. KCS is believed to be a complication of the sulphur-moiety,

although it has been seen with olsalazine, which contains no sulphonamide (see below).

**Olsalazine:** This is two 5-ASA molecules joined by a diazo bond and again released by colonic bacteria. It was developed in an attempt to reduce the frequency of KCS, which was considered to be an attribute of the sulfapyridine in sulfasalazine. It has been used successfully in dogs, although occasional KCS has still been reported. The dose of olsalazine is half that of sulfasalazine as it contains twice the amount of active ingredient.

**Balsalazide:** A newer pro-drug (4-aminobenzoyl- $\beta$ -alanine-mesalamine), balsalazide is activated by the same mechanism as sulfasalazine, but its safety and efficacy have not been evaluated in small animals.

**Mesalazine:** Native 5-ASA is termed mesalazine (mesalamine), and slow-release enteric formulations are available for humans. Premature release in the SI is likely to cause absorption and nephrotoxicity, but at human intestinal pH the majority of the 5-ASA is released in the colon. The safety of oral formulations in dogs and cats is unclear. Mesalazine enemas and suppositories are safe but unpopular.

#### Ciclosporin

Ciclosporin (cyclosporine) A (Cs A), one of nine ciclosporins isolated from fungi, is a potent immunosuppressive drug for human transplantation and selective (auto)immune diseases. It can be nephrotoxic, and ideally trough serum concentrations should be monitored.

In veterinary gastroenterology, Cs A has been used as a sole agent to treat anal furunculosis. Its activity can be potentiated by concurrent administration with ketoconazole, which inhibits its hepatic metabolism. In preliminary studies the efficacy of ciclosporin in IBD was variable, and it cannot yet be recommended.

#### Mycophenolate mofetil

Mycophenolate mofetil is an immunomodulator used to prevent transplant rejection, being an anti-metabolite inhibiting purine synthesis in lymphocytes. It has been reported by Dewey *et al.* (2000) to have successfully treated myasthenia gravis, including focal myasthenia gravis of the oesophagus. However, its use is not widespread and spontaneous improvement may give a false impression of efficacy.

#### Tacrolimus

Tacrolimus is a macrolide antibiotic produced by *Streptomyces* that inhibits T cell activation and is used to stop transplant rejection. In dogs it is more toxic than ciclosporin, but has been used topically to treat anal furunculosis.

#### Novel treatments

Pentoxifylline (oxpentifylline), thromboxane synthesis inhibitors, leucotriene antagonists, thalidomide and cytokine modulators have all been shown to have some activity in human IBD. Their efficacy in dogs and cats has not yet been studied. Infliximab is a monoclonal antibody against tumour necrosis factor  $\alpha$  used to treat

humans with IBD. No equivalent canine or feline specific monoclonal antibody has been produced.

**Laxatives and cathartics**

Both laxatives and cathartics promote defecation by increasing frequency, fluidity and volume of the faeces, and are used to treat constipation and aid the elimination of toxins. Laxatives (aperients) promote elimination of stool by increasing the hydration and softness of the faecal mass. Consequent increase in faecal bulk may stimulate intestinal peristalsis. In contrast, cathartics (purgatives) tend to produce a more violent and more fluid bowel evacuation. They alter intestinal electrolyte transport, thereby increasing faecal water and stimulate local myenteric reflexes. Excessive or constant use of cathartics can be deleterious with continual diarrhoea, dehydration and electrolyte disturbances, with the potential to develop megacolon.

**Bulk laxatives**

Bulk laxatives are simple substances (e.g. bran, *ispaghula*, *sterculia* and methylcellulose) that are hydrophilic in nature and are not digested. They absorb water and swell. The resultant increase in bulk stimulates reflex peristalsis and defecation. Examples of bulk laxatives are listed in Figure 28.3. Some fibres are fermentable and the resultant volatile fatty acids exert

an osmotic laxative effect as well. However, if excess is given diarrhoea and bloating may occur.

**Emollient laxatives**

Emollient laxatives are lubricants that act unchanged as faecal softeners. They are mild but not reliably effective.

**Paraffin:** It is available as a paste or as liquid paraffin (mineral oil). The paste is used as a mild treatment for hairballs and constipation in cats. By smearing it on the cat's nose or feet it will be licked off and ingested. Liquid paraffin is tasteless and if given orally by syringe there is a significant danger of inhalation and lipid pneumonia. Its use is no longer recommended.

**Docusate sodium:** Previously called dioctyl sodium sulfosuccinate (DSS), docusate is an anionic surfactant and detergent that acts as a faecal softener. It is sometimes combined with dantron (codanthramer), an irritant cathartic.

**Osmotic laxatives and cathartics**

Osmotic laxatives and cathartics have the desired effect by drawing water into the stool, making it softer and encouraging expulsive movement. Sugar alcohols, such as mannitol and sorbitol, found naturally in food have this effect but are rarely used intentionally as laxatives.

Laxatives	Cathartics	Enemas
<p>Simple bulk laxatives:</p> <ul style="list-style-type: none"> <li>Bran (wheat husk)</li> <li>Carboxymethylcellulose sodium</li> <li>Ispaghula</li> <li>Methylcellulose</li> <li>Prunes</li> <li>Psyllium seeds (<i>Plantago</i>, plantain)</li> <li>Pumpkin seeds</li> <li>Sterculia</li> </ul> <p>Emollient laxatives:</p> <ul style="list-style-type: none"> <li>Docusate sodium (dioctyl sodium sulfosuccinate, DSS)</li> <li>Liquid paraffin (mineral oil)</li> <li>Paraffin paste</li> <li>Poloxamer (in combination with dantron; codanthramer)</li> </ul> <p>Osmotic laxatives:</p> <ul style="list-style-type: none"> <li>Lactulose</li> <li>Magnesium salts                             <ul style="list-style-type: none"> <li>- Mg citrate</li> <li>- Mg hydroxide</li> <li>- Mg oxide (milk of magnesia)</li> <li>- Mg sulphate (Epsom salts)</li> </ul> </li> <li>Mannitol</li> <li>Polyethylene glycol</li> <li>Sodium salts                             <ul style="list-style-type: none"> <li>- Na chloride</li> <li>- Na citrate</li> <li>- Na lauryl sulphate</li> <li>- Na picosulphate</li> <li>- Na phosphate, Na acid phosphate</li> <li>- Na potassium tartrate (Rochelle's salt)</li> <li>- Na sulphate (Glauber's salt)</li> </ul> </li> </ul>	<p>Irritant cathartics:</p> <ul style="list-style-type: none"> <li>Aloe</li> <li>Arachis oil</li> <li>Bisacodyl</li> <li>Cascara</li> <li>Castor oil</li> <li>Dantron (in combination with poloxamer; codanthramer)</li> <li>Glycerol</li> <li>Linseed oil</li> <li>Olive oil</li> <li>Senna</li> </ul>	<p>Enemas:</p> <ul style="list-style-type: none"> <li>Bisacodyl</li> <li>Glycerol</li> <li>Lactulose</li> <li>Olive oil</li> <li>Phosphate (<b>NOT in cats</b>)</li> <li>Polyethylene glycol</li> <li>Saline (isotonic and hypertonic)</li> <li>Soapy water</li> <li>Sodium lauryl sulphate</li> <li>Sorbitol</li> <li>Warm water</li> </ul>

**28.3** Laxatives, cathartics and enemas available for dogs and cats.

**Lactulose:** It is an indigestible synthetic disaccharide that is fermented in the large intestine to acetate and lactate, with consequent osmotic laxative effect. In hepatic encephalopathy lactulose helps by eliminating fermenting material and acidifying the colon to prevent ammonia absorption. It is a relatively gentle, physiological laxative but individual response is variable, and thus the dose must be titrated so that the individual produces 2–3 soft stools per day without diarrhoea.

**Saline purgatives:** Magnesium and sodium salts that are not (or incompletely) absorbed are osmotic laxatives and even large volumes of saline are an effective purgative. A number of salts are listed in Figure 28.3. Solutions containing magnesium ions may also stimulate peristalsis directly as a cathartic. Although they are small in volume to administer, saline purgatives frequently cause vomiting, abdominal discomfort and dehydration, and sometimes cause hypermagnesaemia. It is imperative that the patient has water to drink after their administration and they should never be given to a dehydrated patient.

**Colonic cleansers:** Oral lavage solutions are ideal preparation for colonoscopy and can also be used as laxatives. They are iso-osmotic solutions of polyethylene glycol and electrolytes that produce osmotic diarrhoea to wash out gut contents. A number of products are available, and the patient is given two to four doses of 25–30 ml/kg, each at least 2 hours apart, and ideally the last dose is given 12 hours before colonoscopy. As large volumes must be given a stomach tube is used for administration to dogs. In cats the solution can be administered via a naso-oesophageal tube as a slow infusion of 20 ml/kg/h for 4 hours. Particular care should be taken in patients with dysphagia or delayed gastric emptying to avoid aspiration, as fatal inhalation pneumonia has recently been reported.

#### **Irritant cathartics**

Contact or irritant cathartics (see Figure 28.3) stimulate the local myenteric plexus and intestinal secretion to provoke fluid accumulation and expulsion. Natural irritant compounds include aloe, senna and cascara. Glycerol and bisacodyl have the mildest action, whilst a combination of sodium picosulphate and magnesium oxide is powerful.

**Vegetable oils:** Vegetable oils are hydrolysed by pancreatic lipase to irritant fatty acids: castor oil to highly irritant ricinoleates; linseed oil to less irritant linoleates; and olive oil to mild oliveates.

**Dantron (danthron):** Dantron is a synthetic anthroquinone derivative that is a stimulant. It is often combined with a stool softener (e.g. poloxamer (codanthramer), docusate (codanthrusate)).

#### **Enemas**

**Warm water:** Repeated warm water enemas are cheap and do not cause histological artefacts if used in preparation for colonoscopy but the method is unpleasant and the quality of colonic cleansing is poor.

Lavage (see above) is more suitable, especially if there is anorectal pain, and can be followed by a single enema before colonoscopy.

In medium-sized dogs, at least one litre of warm water should be used for each enema; the volume is doubled for patients weighing more than 30 kg. The enema tube is well lubricated and gently inserted to the level of the last rib. Warm water is instilled either by gravity from an enema bucket or gently by a Higginson pump. During instillation the tube is moved back and forth to loosen the faeces. Liquid may escape from the anus during the procedure when the colon is full; more fluid should not be forced in, especially if the patient vomits. Enemas are repeated until the liquid runs clear and contains no particulate matter. In normal-sized cats about 20 ml/kg of warm water is given as an enema through a soft, flexible urinary catheter attached to a large syringe. Instillation should be gradual or vomiting will occur.

**Irritant laxative enemas:** Enemas (see Figure 28.3) containing substances such as soap, bisacodyl and phosphate, should never be used before colonoscopy as they may cause artefactual inflammatory changes in mucosal biopsy samples. They are used to stimulate colonic evacuation for other purposes such as radiography. Phosphate enemas can cause fatal hyperphosphataemia in cats.

#### **Nutritional supplements**

##### **Digestive enzymes**

Freeze-dried pancreatic extracts from pig pancreas are used as replacement enzyme therapy in EPI (see Chapter 23). A number of preparations are available, varying in strength and formulation. Enteric-coated preparations are intended to protect the enzyme from gastric acid, but studies suggest uncoated powders or fresh pancreas work best. Premixing food and enzyme is not beneficial. Acid blockade can reduce the enzyme requirement and improve fat absorption, but this is usually neither clinically apparent nor cost-effective.

##### **Medium chain triglycerides**

Dietary supplementation with medium chain triglycerides (MCTs) (C8–C10 fatty acids found naturally in coconut milk) has been recommended in chylothorax, lymphangiectasia and other causes of fat malabsorption. Supplementation can be accomplished with a pharmaceutical preparation (MCT Oil BP). Each millilitre provides approximately 8 kcals and the total dose should not exceed 20% of the animal's daily energy intake. Thus a dose of 1–2 ml/kg bodyweight can be used in dogs, although gradual introduction is necessary as it may not be well tolerated initially. A more palatable 50% emulsion is available but the volume given is doubled. Alternatively one commercial diet contains approximately 25% of fat as MCTs.

MCTs are not recommended in cats as they are unpalatable and may cause anorexia and hepatic lipidosis. However, in dogs it was incorrectly believed that MCTs were absorbed directly into the portal blood and thus were an alternative source of lipid. However,

experiments cannulating the thoracic duct show that at least some MCTs do enter the lymphatics and so the efficiency of MCTs is questionable.

### Prebiotics

Prebiotics are naturally occurring substances added to food that, usually through their fermentation to volatile fatty acids, enhance the growth of potentially beneficial bacteria whilst inhibiting potential pathogens. Examples are chicory, fructo-oligosaccharides (FOSs), inulin and mannanoligosaccharides (MOSs). There is now good evidence that they alter the colonic flora, but there is limited evidence for significant effects in the SI. Nevertheless, a clinical beneficial effect on the colon is probably real, and may also explain the benefit of moderately fermentable dietary fibre, such as ispaghula and beet pulp.

### Probiotics

Probiotics are so-called 'beneficial bacteria', such as *Lactobacillus* and *Enterococcus*, given orally in an attempt to modulate the intestinal flora. Early products had poor viability and low numbers, so that it was doubtful if any actually passed the gastric acid barrier. Modern products undoubtedly do and can be cultured from the faeces. However, they do not usually colonize permanently and can no longer be cultured from faeces a few days after stopping oral administration.

Probiotics have been shown to decrease intestinal permeability in infants with viral gastroenteritis and have other effects on epithelial tight junctions and mucosal immune responses. Some clinical benefits have been demonstrated in humans but not yet clearly in dogs and cats. Further, the products currently available are not canine or feline in origin, again reducing the likelihood of true colonization.

### Vitamins

**Cobalamin:** Vitamin B12 (cobalamin) deficiency is a recognized complication of EPI and chronic intestinal malabsorption, and may contribute to morbidity and failure to respond to treatment (see Chapters 20 and 23). Once established, cobalamin deficiency cannot be corrected by oral supplementation. Repeated parenteral doses are given at weekly intervals until serum concentrations are normalized. Cats are particularly prone to developing severe cobalamin deficiency.

**Folic acid:** Folate deficiency may occur in intestinal malabsorption and is readily supplemented orally.

**Fat-soluble vitamins (A, D, E and K):** Deficiency of vitamins E and K may be clinically significant in EPI and fat malabsorption. Vitamin E can be supplemented orally but parenteral vitamin K1 is indicated if there is evidence of a coagulopathy.

### Liver disease

Many of the drugs used to treat liver disease (e.g. antibiotics, anti-emetics, azathioprine, glucocorticoids) are the same as for GI disease (see above) and are not repeated below. Attention should always be paid to

whether the drug undergoes hepatic metabolism so that, if it does, either the dose is altered accordingly or an alternative is substituted. For nutritional management of liver disease and hepatic encephalopathy see Chapters 15 and 24.

### Ursodeoxycholic acid (UDCA)

Ursodeoxycholic acid (UDCA) is a naturally occurring bile acid, originally found in the bile of the Chinese black bear. It is a relatively hydrophilic bile acid and is readily absorbed from the intestine and undergoes enterohepatic recycling. Very little enters the systemic circulation unless there is portosystemic shunting, but at each cycle some is degraded or lost in the faeces.

UDCA is recommended for the treatment of cholesterol-containing gall stones and non-obstructive biliary disease (see Chapter 25), although evidence of its efficacy is lacking in small animals. It may act by a number of mechanisms:

- Decreasing intestinal absorption and hepatic synthesis of cholesterol
- Displacing harmful hydrophobic bile acids from the bile acid pool, protecting the liver from damage
- Stimulating bile flow (choleresis) by increasing biliary bicarbonate secretion
- Immunomodulatory effects, decreasing immunoglobulin production, decreasing cytokine production and decreasing expression of major histocompatibility complex (MHC) class I molecules.

UDCA is non-toxic in dogs and cats. Aluminium-containing antacids and colestyramine reduce its absorption.

### Antifibrotics

Antifibrotics are used in chronic hepatopathies if histopathology indicates extensive hepatic fibrosis. Prednisolone is used as an anti-inflammatory/immunosuppressive, but also has antifibrotic activity. Penicillamine (see below) may also be antifibrotic.

### Colchicine

Controlled clinical trials are lacking, but anecdotal evidence suggests that colchicine may improve liver function and reverse, or at least slow, hepatic fibrosis. Colchicine inhibits the microtubules in collagen-secreting hepatic lipocytes and increases collagenase activity. It may also suppress fibrogenesis by inhibiting leucocyte migration and consequent inflammation.

No information is available on the pharmacokinetics of colchicine in dogs. Nausea, vomiting and diarrhoea may occur, and overdoses cause severe haemorrhagic diarrhoea. Its use in cats is not recommended. Use with myelosuppressive drugs and NSAIDs may enhance bone marrow suppression. Colchicine formulated with probenecid should be avoided as it is more likely to cause vomiting.

### Decoppering agents

Copper accumulation in chronic liver disease may be an effect of cholestasis or a primary defect of excretion, as in Bedlington Terriers (see Chapter 24). In either



case, the copper is hepatotoxic and decoppering agents are used to block intestinal copper uptake and increase urinary copper excretion by chelation.

#### Zinc salts

Zinc blocks intestinal copper absorption by induction of metallothionein, which traps the copper in the enterocyte and ultimately hepatic copper concentrations fall. Zinc acetate, sulphate or gluconate can be used, but the acetate derivative is least irritating to the stomach and least likely to cause vomiting.

#### D-Penicillamine

D-penicillamine has no antibacterial activity but chelates heavy metals. It is used in copper hepatotoxicosis (see Chapter 24) to bind copper as a water-soluble complex that can be excreted in urine. However, it may take months to years for hepatic copper concentrations to fall significantly although subjective clinical improvement after a few weeks is usually noted, suggesting other beneficial effects. Penicillamine induces metallothionein, which sequesters copper, and may also have an antifibrotic effect. It is best absorbed on an empty stomach, but it frequently causes vomiting. This can be reduced if the drug is introduced gradually or if it is given with food, although less drug is absorbed in the latter case.

#### Tetramine

The compound 2,2,2-tetramine (trientine) is a copper chelator with fewer side-effects than penicillamine, but both take many months to reduce hepatic copper. 2,3,2-tetramine is five to ten times more potent than trientine and lowers the hepatic copper content more rapidly, but is not available commercially.

### Nutritional supplements

#### Anti-oxidants

Anti-oxidant compounds are purported to reduce the hepatic damage caused by free radicals that are believed to perpetuate liver damage in chronic hepatitis.

**Vitamin E:** It has been recommended for chronic hepatitis for its anti-oxidant effect.

**S-Adenosylmethionine (SAME):** This compound acts as a supply of glutathione, which is important in hepatic detoxification. There are preliminary reports of a beneficial effect in chronic liver disease.

**Sylmarin (syn. silymarin; active ingredient silibin):** This is an extract of milk thistle that is reported to have anti-oxidant activity in liver disease.

#### Hepatotropic agents

A number of agents have a selective activity on the liver, stimulating bile flow, hastening the removal of hepatic fat and acting as anti-oxidants. Yet currently there is little information to confirm or deny the utility of compounds such as choline, methionine, lecithin or selenium.

### References and further reading

- Boothe DM (2001) *Small Animal Clinical Pharmacology and Therapeutics*. WB Saunders, Philadelphia
- Campieri M and Gianchetti P (1999) Probiotics in inflammatory bowel disease: new insight to pathogenesis or possible therapeutic alternative. *Gastroenterology* **116**, 1246–1249
- Dewey C, Boothe DM, Rinn KL, Coates JR and Burkholder WJ (2000) Treatment of a myasthenic dog with mycophenolate mofetil. *Journal of Veterinary Emergency and Critical Care* **10**, 177–187
- Hall JA and Washabau RJ (2000) Gastric prokinetic agents. In: *Current Veterinary Therapy XIII*, ed. J Bonagura, pp. 614–617. WB Saunders, Philadelphia
- Lavy E, Aroch I, Bark H, Markovics A, Aizenberg I, Mazaki-Tovi M, Hagag A and Harrus S (2002) Evaluation of doramectin for the treatment of experimental canine spirocerosis. *Veterinary Pathology* **109**, 65–73
- Leveille-Webster C (2000) Ursodeoxycholic acid therapy. In: *Current Veterinary Therapy XIII*, ed. J Bonagura, pp. 691–693. WB Saunders, Philadelphia
- Maddison J, Page S and Church D (2002) *Small Animal Clinical Pharmacology*. WB Saunders, Philadelphia
- McGrotty YL and Knottenbelt CM (2002) Oesophageal stricture in a cat due to oral administration of tetracyclines. *Journal of Small Animal Practice* **43**, 221–223
- Millersman G, Russell WL and Derendorf H (1986) Lack of clinically significant in vitro and in vivo interactions between ranitidine and sucralfate. *Journal of the Pharmaceutical Society* **75**, 995–998
- Papich MG (2002) *Saunders Handbook of Veterinary Drugs*. WB Saunders, Philadelphia
- Papich MG, Davis CE and Davis LE (1987) Absorption of salicylate from an antidiarrheal preparation in dogs and cats. *Journal of the American Animal Hospital Association* **23**, 221–228
- Ramsey I and Tennant B (2001) *BSAVA Manual of Canine and Feline Infectious Diseases*. BSAVA Publications, Gloucester
- Roulet A, Puel O, Gesta S, Lepage JF, Drag M, Soll M, Alvinerie M and Pineau T (2003) MDR1-deficient genotype in Collie dogs hypersensitive to the P-glycoprotein substrate ivermectin. *European Journal of Pharmacology* **460**, 85–91
- Salavaggione OE, Kidd L, Prondzinski JL, Szumlanski CL, Pankratz VS, Wang LW, Trepanier L and Weinshilboum RM (2002) Canine red blood cell thiopurine S-methyltransferase: companion animal pharmacogenetics. *Pharmacogenetics* **12**, 713–724
- Sigalek DL, Winkelaar GB and Smith LJ (1997) Determination of the route of medium-chain and long-chain fatty acid absorption by direct measurement in the rat. *Journal of Parenteral and Enteral Nutrition* **21**, 275–278
- Simpson KW, Fyfe J, Cornetta A, Sachs A, Strauss-Ayali D, Lamb SV and Reimers TJ (2001) Subnormal concentrations of serum cobalamin (vitamin B<sub>12</sub>) in cats with gastrointestinal disease. *Journal of Veterinary Internal Medicine* **15**, 26–32
- Stewart A (1997) The use of a novel formulation of budesonide as an improved treatment over prednisone for inflammatory bowel disease. *Proceedings of the 15th ACVIM Forum*, p. 662
- Tennant B (2002) *BSAVA Small Animal Formulary*, 4<sup>th</sup> edn, BSAVA Publications, Gloucester
- Ward DM, Leib MS, Johnston SA and Marini M (2003) The effect of dosing interval on the efficacy of misoprostol in the prevention of aspirin-induced gastric injury. *Journal of Veterinary Internal Medicine* **17**, 282–290
- Washabau RJ and Elie MS (1995) Antiemetic therapy. In: *Current Veterinary Therapy XII*, ed. J Bonagura, pp. 679–684. WB Saunders, Philadelphia
- Williams J and Niles J (in preparation) *BSAVA Manual of Canine and Feline Abdominal Surgery*, BSAVA Publications, Gloucester

# Appendix 1

## Drug formulary

This appendix lists the drugs used most commonly for the treatment of gastrointestinal (GI) problems, according to their indication. However, the reader should note that some drugs have more than one indication. Furthermore, the dosage regimes stated are those that refer to specific GI indications mentioned in this manual, and may not be applicable if the drug is used to treat other organ systems. The more important contraindications are noted, but the reader is referred to Chapter 28 and to the *BSAVA Small Animal Formulary* for

further details, licensing information and trade names. Further information on drugs used in the supportive care of emergency and critical patients mentioned in Chapter 26 can be found in the *BSAVA Manual of Canine and Feline Emergency and Critical Care*.

*The publishers and contributors cannot take responsibility for information provided on dosages and methods of application of drugs as listed in this Appendix. Details of this kind must be verified by individual users from the appropriate literature.*

Drug	Dosage	Indications and comments
<b>Antibacterial agents</b>		
Amoxicillin	10–20 mg/kg p.o. or s.c. q12h for 7–10 days	<i>Salmonella</i> , <i>Clostridium</i> infection
	10–20 mg/kg p.o. or s.c. q12h over 3–4 weeks	Neutrophilic cholangitis: elimination of bacteria (usually <i>Escherichia coli</i> ) from cats
	20 mg/kg p.o. q12h for 14 days	<i>Helicobacter</i> gastritis: with metronidazole and an H <sub>2</sub> antagonist or proton pump inhibitor
Ampicillin	10 mg/kg p.o. q8h	Hepatic encephalopathy
	10–40 mg/kg p.o. or s.c. q8h	<i>Clostridium perfringens</i> infection
Cefadroxil	10–30 mg/kg p.o. q12h	<i>Yersinia</i> infection
Enrofloxacin	2.5–5 mg/kg p.o. or s.c. q12–24h (dogs); 4 mg/kg p.o. or s.c. q24h (cats)	<i>Salmonella</i> , <i>Escherichia coli</i> infections
	5 mg/kg p.o. q12h (dogs)	<i>Campylobacter</i> infection, chronic histiocytic ulcerative colitis in dogs
		<b>Dose-dependent retinal damage reported in cats</b>
Erythromycin	10–20 mg/kg p.o. q8–12h	<i>Campylobacter</i> infection
Metronidazole (see also Antiparasitic agents)	7.5 mg/kg p.o. (or slow i.v. for dogs) q12h	Biliary infections
	10 mg/kg p.o. q12h for 14 days	<i>Helicobacter</i> gastritis: with amoxicillin or clarithromycin and an H <sub>2</sub> antagonist or proton pump inhibitor
	10–15 mg/kg p.o. q8–12h (dogs)	<i>Clostridium</i> infection, idiopathic antibiotic-responsive diarrhoea, inflammatory bowel disease
		<b>Avoid in severe hepatic insufficiency as hepatic metabolism impaired</b>
Neomycin	5–10 mg/kg p.o. q12h or as a retention enema q6–8h (dogs)	Hepatic encephalopathy. <i>Systemic absorption unlikely but may occur if GI ulceration present, and may lead to oto- and nephrotoxicity</i>
Oxytetracycline	10–20 mg/kg p.o. q8–12h	Small intestinal bacterial overgrowth, antibiotic-responsive diarrhoea

**Appendix 1** Drug formulary

Drug	Dosage	Indications and comments
<b>Antibacterial agents (continued)</b>		
Tetracycline	15–20 mg/kg p.o. q6–8h (dogs)	<i>Yersinia</i> , <i>Campylobacter</i> infection
Trimethoprim/sulphonamide (see also Antiparasitic agents)	15 mg/kg p.o. q12h	<i>Yersinia</i> , <i>Salmonella</i> infection
Tylosin	7–15 mg/kg p.o. q8–12h (dogs)	<i>Clostridium</i> infection, chronic enteropathies including inflammatory bowel disease and idiopathic antibiotic-responsive diarrhoea
<b>Antidiarrhoeal agents</b>		
Bismuth salts	1 ml/5 kg p.o. q8h	Acute vomiting or diarrhoea: cytoprotectant also with action against gastric spiral bacteria, used to coat the GI mucosa
Butylscopolamine (hyoscine)	4–10 mg/day i.v. or i.m (dogs)	Acute diarrhoea and irritable bowel syndrome: anticholinergic antispasmodic usually formulated in a combination product with metamizole
Colestyramine	1–2 g/dog q12h	Binds luminal bile acids that may stimulate intestinal secretion
Diphenoxylate	0.05–0.2 mg/kg p.o. q8–12h	Acute diarrhoea, especially in colonic disease: motility modifier used for symptomatic management
Kaolin and pectin	1–2 ml/kg p.o. q8h	Acute vomiting or diarrhoea: used to coat the GI mucosa and to bind bacteria and their toxins
Loperamide	0.1–0.2 mg/kg p.o. q8–12h	Acute diarrhoea, especially in colonic disease: motility modifier used for symptomatic management
<b>Anti-emetic agents</b>		
Bismuth salts	1 ml/5 kg p.o. q8h	Acute vomiting and diarrhoea: cytoprotectant used to coat the GI mucosa
Butylscopolamine (hyoscine)	4–10 mg/day i.v. or i.m (dogs)	Anticholinergic antispasmodic, usually formulated in a combination product with metamizole
Chlorphenamine (chlorpheniramine)	Maximum recommended dose 0.5 mg/kg p.o. q12h	Motion sickness
Chlorpromazine	0.2–0.4 mg/kg s.c. q8h	Phenothiazine anti-emetic
Dimenhydrinate	8 mg/kg p.o. or i.m. q8h	Motion sickness
Diphenhydramine	2–4 mg/kg p.o. or i.m. q8h	Motion sickness
Metoclopramide (see also Prokinetic agents)	0.2–0.5 mg/kg p.o. or s.c. q8h 1 mg/kg i.v. q24h CRI	Central anti-emetic. Both prokinetic and anti-emetic effects of value in parvovirus infection
Ondansetron	0.5–0.15 mg/kg i.v. q6h 0.5–1.0 mg/kg p.o. q12–24h	Powerful central anti-emetic
Prochlorperazine	0.1–0.5 mg/kg i.v., i.m. or s.c. q6–8h 0.5–1.0 mg/kg p.o. q8–12h	Phenothiazine anti-emetic
Promethazine	0.2–0.4 mg/kg i.v., i.m. or p.o. q6–8h (maximum dose 1 mg/kg)	Motion sickness
<b>Antifungal agents</b>		
Amphotericin B	0.25 mg/kg i.v. as test dose, then 0.25–0.5 mg/kg i.v. up to 3 times weekly, up to a total cumulative dose of 5–10 mg/kg (dogs) or 4–8 mg/kg (cats)	Histoplasmosis; fungal or algal colitis, with itraconazole
Itraconazole	5 mg/kg p.o. q12h for 4 days, q24h thereafter	Histoplasmosis
	10 mg/kg p.o. q24h	Fungal or algal colitis: alone or with amphotericin B
	10 mg/kg p.o. q12–24h	Gastric pythiosis following surgery: used with terbinafine for 2–3 months
Terbinafine	5–10 mg/kg p.o. q24h	Gastric pythiosis following surgery: with itraconazole for 2–3 months

Drug	Dosage	Indications and comments
<b>Anti-inflammatory agents</b>		
Ketoprofen	1–2 mg/kg s.c. once (cats)	Inflammation of gingiva and oral mucosa
Mesalazine	5–10 mg/kg p.o. q8–12h	Colitis
Olsalazine	5–10 mg/kg p.o. q8–12h	Colitis
Sulfasalazine	20–40 mg/kg p.o. q24h (dogs); 125 mg /cat q24h	Colitis. <b>Can cause keratoconjunctivitis sicca</b>
<b>Antiparasitic agents</b>		
Albendazole	25 mg/kg p.o. q12h for 5 days (cats), 5–10 days (dogs)	Giardiasis. <b>Not recommended due to potential bone marrow suppression</b>
Azithromycin	7–10 mg/kg p.o. q12h for 7 days	Cryptosporidiosis
Bunamidine	25–50 mg/kg p.o. once	Cestode infection
Dichlorophen	200 mg/kg p.o. once	<i>Taenia</i> infection
Dichlorvos	10 mg/kg p.o. once	Roundworm infection
Doramectin	1 mg/kg s.c.	<i>Spirocerca lupi</i> infection. <b>Do not use in collies</b>
Epsiprantel	2.75 mg/kg p.o. (cats); 5 mg/kg p.o. (dogs)	Similar to praziquantel
Febantel	10–15 mg mg/kg p.o.	Converted to fenbendazole and oxfendazole; similar spectrum of activity to fenbendazole
Fenbendazole	50 mg/kg p.o. q24h	Broad spectrum anthelmintic; <i>Giardia</i> infection (3–5 days); empirical treatment of eosinophilic enteritis (3 days)
	100 mg/kg for 3 days (puppies)	Administered to newborn puppies to kill larvae
	10 mg/kg p.o. q24h for 2 days	<i>Ollulanus tricuspis</i> gastritis
	30 mg/kg p.o. q24h for 6 consecutive days	<i>Eurytrema procyonis</i> infection
Flubendazole	22 mg/kg p.o.	Nematode infection, especially whipworm
Ivermectin	0.2–0.4 mg/kg s.c. or p.o. q7–14d on 2–4 occasions (cats)	<i>Toxocara</i> , <i>Ancylostoma</i> , <i>Uncinaria</i> infection. <b>Not licensed for or recommended in dogs. MUST NOT BE USED IN COLLIES</b>
Levamisole	7.5–10 mg/kg p.o. once	Roundworm, hookworm infection
Mebendazole	22 mg/kg p.o.	Nematode, <i>Taenia</i> infection
Metronidazole (see also Antibacterial agents)	25 mg/kg p.o. q12h for 5–10 days (dogs); 25 mg/kg p.o. q12h for 5 days (cats)	Giardiasis
Milbemycin oxime	0.5 mg/kg p.o. q30d	<i>Toxocara</i> , whipworm, hookworm infection
Moxidectin	0.003 mg/kg p.o.	Hookworm infection. <b>Do not use in collies</b>
Niclosamide	100–150 mg/kg p.o.	Cestode infection
Nitroscanate	50 mg/kg p.o. (dogs)	Active against most common cestodes and nematodes except whipworm
Oxibendazole	22 mg/kg p.o.	Often combined with praziquantel
Piperazine	100 mg/kg p.o.	Roundworm infection
Praziquantel	3.5–7.5 mg/kg i.m. or s.c.; 5 mg/kg p.o.	Tapeworm infection
	40 mg/kg q24h for 3 consecutive days	<i>Amphimerus pseudofelineus</i> infection
Pyrantel pamoate	5 mg/kg p.o.	Roundworm, hookworm, whipworm infection
	5 mg/kg p.o. (dogs single dose; cats two doses 14 days apart)	<i>Physaloptera</i> gastritis
Selamectin	6 mg/kg topical 'spot-on' monthly	Roundworm infection
Tiabendazole	50–75 mg/kg p.o. q24h for 3 days; 125 mg/cat p.o. q2h for 3 days	Roundworm infection, including <i>Strongyloides</i> : larvae and adults
Sulfadimethoxine	50 mg/kg p.o. q24h for 10 days	<i>Isospora</i> infection
Trimethoprim/sulphonamide	15–30 mg/kg p.o. q24h for 5 days	<i>Isospora</i> infection

**Appendix 1** Drug formulary

Drug	Dosage	Indications and comments
<b>Anti-ulcer agents</b>		
Aluminium hydroxide	10–30 mg/kg p.o. q8h (tablets) 5–10 ml p.o. q8h (gel)	Used to neutralize gastric acid. <i>Can block uptake of other drugs</i>
Bismuth compounds	1 ml/kg Pepto-Bismol p.o. q4–6h	Gastric cytoprotectant with action against gastric spiral bacteria
Cimetidine	5–10 mg/kg p.o. or i.v. q6–8h	Gastro-oesophageal reflux and gastric ulceration
Esomeprazole	0.5–1.0 mg/kg p.o. q24h	Gastro-oesophageal reflux and gastric ulceration
Famotidine	0.1–0.5 mg/kg p.o. or i.v. q12h	Gastro-oesophageal reflux and gastric ulceration
Misoprostol	3–5 µg/kg p.o. q8h for dogs	Protects against NSAID-induced erosions in dogs
Nizatidine (see also Prokinetic agents)	1–3 mg/kg s.c., i.m. or i.v. q8h	Gastro-oesophageal reflux and gastric ulceration
Octreotide	2–20 µg/kg s.c. q8h	Large ulcers: rapidly decreases gastric acid secretion; may help control gastric bleeding
Omeprazole	0.7 (0.2–1.0) mg/kg slow i.v. or p.o. q24h for dogs	Gastro-oesophageal reflux and gastric ulceration: treatment of choice for acid hypersecretion
Pantoprazole	0.2–1.0 mg/kg p.o. q24h for dogs	Gastro-oesophageal reflux and gastric ulceration
Rabeprazole	0.2–1.0 mg/kg p.o. q24h for dogs	Gastro-oesophageal reflux and gastric ulceration
Ranitidine (see also Prokinetic agents)	1–2 mg/kg p.o. or i.v. q8–12h; 0.5–2 mg/kg p.o. q12h (cats)	Gastro-oesophageal reflux, and gastric ulceration, including in liver disease
Sucralfate	1 g per 30 kg bodyweight p.o. q8h (dogs); 250 mg/cat p.o. q8h	Oesophagitis and gastric ulceration; can be used to coat GI mucosa and bind bacteria and toxins in acute vomiting or diarrhoea. <i>Oral suspension much more effective than intact tablet</i>
<b>Immunosuppressive agents</b>		
Azathioprine	1–2 mg/kg p.o. q24 for 5 days then q48h, and ultimately on alternating days with prednisolone (dogs); 0.3–0.5 mg/kg p.o. q48h (cats)	Moderate to severe lymphoplasmacytic gastritis and inflammatory bowel disease: given if glucocorticoids are not effective. <b>Not suitable for cats unless reformulated</b>
Budesonide	Suggested dose of 1–3 mg p.o. q8h <i>not verified</i>	Inflammatory bowel disease; fewer systemic steroid effects than prednisolone
Chlorambucil	0.1–0.2 mg/kg (2 mg/m <sup>2</sup> ) p.o. q24–48h (dogs); 0.25 mg/kg (2–6 mg/m <sup>2</sup> ) p.o. q24–48h (cats)	Chronic diarrhoea in cats: alternative to azathioprine; additional immunosuppressive therapy for lymphoplasmacytic enteritis and colitis
Ciclosporin A	1–5 mg/kg/day p.o. q12h	Chronic gingivostomatitis in cats; possible immunosuppressive for dogs with lymphoplasmacytic enteritis, colitis and perianal fistula
Methylprednisolone	Injectable 2 mg/kg (minimum dose 20 mg) every 2 weeks for a total of 2–3 treatments	Feline eosinophilic granuloma complex oral lesions
	15–20 mg/cat s.c.	Chronic gingivostomatitis in cats
Prednisolone	0.5–1.0 mg/kg s.c. or i.m. q12h	Oesophageal strictures
	0.5–1.0 mg/kg p.o., s.c. or i.m. q12h for 7 days, followed by a tapering dose over 2–3 weeks	Canine eosinophilic granuloma, stomatitis
	1 mg/kg p.o. q12h for 7–14 days	Exocrine pancreatic insufficiency: if concurrent lymphocytoplasmytic enteritis
	1–2 mg/kg p.o. q24h	Lymphangiectasia: initial dose
	1–2 mg/kg p.o., s.c. or i.m. q24h tapered to 0.5 mg/kg q24–48h	Liver disease
	2 mg/kg p.o. q24h for 2 weeks, reducing over 4–6 weeks	Anal furunculosis or perianal fistula: immunosuppressive dose
	2 mg/kg/day p.o., s.c. or i.m. divided over two doses	Vomiting and chronic diarrhoea caused by idiopathic inflammatory bowel disease
	2–4 mg/kg p.o. q24h in divided doses, tapered to q48h at lowest dose that maintains remission over 8–12 weeks	Destructive canine cholangitis: with ursodeoxycholic acid
		<b>Avoid in suppurative inflammation, portal hypertension, ascites, potential GI ulceration. Provide gastric protectants</b>

Drug	Dosage	Indications and comments
<b>Immunosuppressive agents (continued)</b>		
Tacrolimus	Topical	Perianal fistula
Triamcinolone acetonide	1 mg intralesional injection	Oesophageal stricture dilatation: may reduce risk of recurrence
	3 mg s.c. weekly	Feline eosinophilic granuloma complex oral lesions
<b>Laxatives</b>		
Aloe, arachis oil, bisacodyl, cascara, castor oil, glycerol, linseed oil, olive oil, senna	To effect	Irritant cathartics
Bran, prune, methylcellulose, carboxymethylcellulose, sterculia	To effect	Bulk laxatives
Dantron	2.5–5.0 ml p.o. q12h	Irritant cathartic often used with docusate (codanthramer)
Docusate sodium	50–200 mg p.o. q8–24h	Stool softener
GI lavage solutions	20–30 ml/kg p.o. for 3 doses q2h	Isotonic polyethylene glycol-salt solutions for colonoscopy preparation
Lactulose	0.25–0.5 mg/kg p.o. q6–8h	Stool softener
	1–15 ml p.o. q8h (dogs); 0.25–1 ml p.o. q8h (cats)	Hepatic encephalopathy: <i>overdose results in diarrhoea, therefore titrate to effect</i>
Magnesium salts: citrate, hydroxide, oxide, sulphate	Various	Osmotic laxatives
Paraffin	1 inch of paraffin paste per cat p.o. q12–24h	Emollient laxative. <b>The use of liquid paraffin (mineral oil) is no longer recommended due to the risk of inhalation lipid pneumonia</b>
Sodium salts: chloride, citrate, lauryl sulphate, picosulphate, phosphate sulphate, potassium tartrate	Various	Osmotic laxatives
<b>Prokinetic agents</b>		
Bethanechol	5–15 mg p.o. q8h (dogs); 1.25–5 mg p.o. q8h (cats)	May be of value in management of megaesophagus
Cisapride	0.1–0.5 mg/kg p.o. q8–12h	Promotes gastric emptying of solids; more potent than metoclopramide but has more drug interactions, no central anti-emetic effects and limited availability
Erythromycin	0.5–1.0 mg/kg p.o. q8h for dogs, given between meals	Promotes gastric emptying of solids by mimicking phase III of the MMC; may be useful in preventing gastro-oesophageal reflux
Metoclopramide (see also Anti-emetic agents)	0.2–0.5 mg/kg p.o. or s.c. q8h 1 mg/kg i.v. q24h CRI	Facilitates gastric emptying of liquids; less effective than cisapride in promoting gastroduodenal and intestinal motility; may be useful in preventing gastro-oesophageal reflux. Both prokinetic and anti-emetic effects of value in parvovirus infection
Nizatidine (see also Anti-ulcer agents)	0.5–1.0 mg/kg p.o. q8h	Facilitates gastric emptying of liquids, and colonic motility in cats with megacolon.
Pyridostigmine	1.0–3.0 mg/kg p.o. q8–12h	Myasthenia gravis
Ranitidine (see also Anti-ulcer agents)	0.5–1.0 mg/kg p.o. q8h	Facilitates gastric emptying of liquids, and colonic motility in cats with megacolon
<b>Vitamins and dietary supplements</b>		
S-Adenosylmethionine (SAME)	20 mg/kg p.o. q24h or higher (dogs); 20 mg/kg or 200–400 mg total q24h (cats)	Chronic hepatitis. <b>Must be given unbroken on an empty stomach</b>
Medium chain triglyceride (MCT) oil	0.5–2 ml/kg per meal	Exocrine pancreatic insufficiency, inflammatory bowel disease, lymphangiectasia: supplements lipid intake
Pancreatic extract	2 teaspoons of powder per 20 kg bodyweight	Enzyme replacement in exocrine pancreatic insufficiency: promotes weight gain
Psyllium	1–2 tbsp per 25 kg bodyweight p.o. q8–24h	Fibre-responsive diseases associated with the colon

## Appendix 1 Drug formulary

Drug	Dosage	Indications and comments
<b>Vitamins and dietary supplements (continued)</b>		
Vitamin B12 (cobalamin)	250–1000 µg (dogs), 100–250 µg (cats) i.m. or s.c. q7d for several weeks	Low serum cobalamin caused by exocrine pancreatic insufficiency or inflammatory bowel disease
Sylmarin (silymarin, silibin)	50–200 mg/dog p.o. q24h	Anti-oxidant derived from milk thistle. Effective dose not fully established but high safety margin reported
Vitamin E (tocopherol)	5–25 IU/kg BW p.o. q24h given with food for 1 month	Low serum tocopherol caused by exocrine pancreatic insufficiency
	400–600 IU/day p.o. for medium-sized dogs	Canine chronic hepatitis
Vitamin K1	0.5–2.0 mg/kg s.c. q12h for 3 treatments and then q7days	Vitamin K deficiency in liver disease: should be given 12 hours before biopsy and repeated every 7–21 days as necessary. <b>Do not overdose, as this results in haemolysis</b>
Zinc (acetate or sulphate)	1–20 mg/kg elemental zinc q24h (dogs); 7 mg/cat elemental zinc q24h (cats)	Copper-associated liver disease: monitor blood every 1–2 weeks and keep zinc at 31–46 µmol/l (200–300 µg/dl) to avoid toxicity. Give 1 hour before food to minimize vomiting
<b>Miscellaneous agents</b>		
Barium sulphate contrast media	5–20 ml/kg p.o. per procedure	GI contrast studies; has some antidiarrhoeal effect
Calcium gluconate	0.5–1 mg/kg of 10% solution i.v. over 30 minutes	Hypocalcaemia as a result of pancreatitis
Chlorhexidine	1% solution used to effect	Mouthwash; anal sac flush following expression
Co-enzyme Q10	30–100 mg daily for 4 months	Oral inflammation following full-mouth extraction
Colchicine	0.03 mg/kg p.o. q24h	Liver disease. <b>Monitor for bone marrow suppression. GI side-effects; not recommended for cats</b>
Dopamine	5.0 µg/kg/min i.v. low dose infusion	Pancreatitis
Lactoferrin	40 mg/kg daily, topical (cats)	Chronic gingivostomatitis
Mebeverine	2 mg/kg p.o. q8h	Irritable bowel syndrome: antispasmodic
Penicillamine	10–15 mg/kg p.o. q12h	Copper-associated liver disease. <b>Vomiting common; immune-mediated disease possible; not recommended for cats</b>
Spirolactone	2–4 mg/kg/day p.o. in divided doses	Ascites in liver disease; gradual onset of action
Trientine	10–15 mg/kg p.o. q12h	Copper-associated liver disease in dogs
Ursodeoxycholic acid	4–15 mg/kg p.o. total daily dose, preferably divided q12h	Liver disease: induces bile flow. Used with prednisolone in destructive canine cholangitis and post-surgical extra-hepatic bile duct obstruction. <b>Avoid in patients with biliary obstruction; not indicated for patients with congenital portosystemic shunts</b>

# Appendix 2

## Abbreviations used throughout the text

Abbreviation	Full name	Abbreviation	Full name
$\alpha_1$ -PI	$\alpha_1$ -Proteinase inhibitor	DIC	Disseminated intravascular coagulation
5-ASA	5-Aminosalicylic acid	DO <sub>2</sub>	Oxygen delivery
5-HT <sub>4</sub>	5-Hydroxytryptamine <sub>4</sub>	DSS	Dioctyl sodium sulfosuccinate
ABT	Aminopyrine breath test	EC	Eosinophilic colitis
ACTH	Adrenocorticotrophic hormone	ECL	Enterochromaffin-like (cells)
AHDS	Acute haemorrhagic diarrhoeal syndrome	EE	Eosinophilic enteritis
ALP	Alkaline phosphatase	EGC	Eosinophilic granuloma complex
ALT	Alanine aminotransferase	EGF	Epidermal growth factor
APC	Antigen-presenting cell	EHEC	Enterohaemorrhagic <i>Escherichia coli</i>
aPTT	Activated partial thromboplastin time	EIA	Enzyme immunoassay
ARD	Antibiotic-responsive diarrhoea	ELISA	Enzyme-linked immunosorbent assay
AST	Aspartate aminotransferase	EPEC	Enteropathogenic <i>Escherichia coli</i>
AT	Anti-thrombin	EPI	Exocrine pancreatic insufficiency
ATPase	Adenosine triphosphatase	ETEC	Enterotoxigenic <i>Escherichia coli</i>
AV	Arteriovenous	FECV	Feline enteric coronavirus
BCR	B cell receptor	FcLV	Feline leukaemia virus
BIPS	Barium impregnated polyethylene spheres	FIP	Feline infectious peritonitis
BT-PABA	Benzoyl-tyrosyl para-amino-benzoic acid	FITC	Fluorescein isothiocyanate
cAMP	Cyclic adenosine monophosphate	FIV	Feline immunodeficiency virus
CBC	Complete blood count	FNA	Fine needle aspiration
CCK	Cholecystokinin	FOS	Fructo-oligosaccharide
CCV	Canine coronavirus	GABA	Gamma amino-butyric acid
CEJ	Cementoenamel junction	GALT	Gut-associated lymphoid tissue
CFU	Colony-forming units	GCF	Gingival crevicular fluid
cGMP	Cyclic guanosine monophosphate	G-CSF	Granulocyte colony stimulating factor
CHO	Carbohydrate	GD	Gastric dilatation
CHUC	Chronic histiocytic ulcerative colitis	GDV	Gastric dilatation and volvulus
CLO	<i>Campylobacter</i> -like organism	GFST	Gastroscopic food sensitivity testing
CMI	Cell-mediated immunity	GGT	Gamma glutamyl transferase
CNS	Central nervous system	GI	Gastrointestinal
COX	Cyclooxygenase	GMB	Gastric mucosal barrier
CPE	<i>Clostridium perfringens</i> enterotoxin	GRP	Gastrin-releasing peptide
CPV	Canine parvovirus	GSA	<i>Giardia</i> -specific antigen
CRI	Constant rate infusion	GSE	Gluten-sensitive enteropathy
CRTZ	Chemoreceptor trigger zone	GUE	Gastroduodenal ulceration/erosion
Cs	Ciclosporin	H&E	Haematoxylin and eosin (stain)
CSF	Cerebrospinal fluid	HCT	Haematocrit
CT	Computed tomography	HE	Hepatic encephalopathy
CUPS	Chronic ulcerative periodontitis syndrome	HGE	Haemorrhagic gastroenteritis
CVP	Central venous pressure	HR	Heart rate
DFA	Direct fluorescent antibody assay	HVG	Haematoxylin-Van Gieson



## Appendix 2 Abbreviations used throughout the text

Abbreviation	Full name	Abbreviation	Full name
IBD	Inflammatory bowel disease	PGE <sub>2</sub>	Prostaglandin E <sub>2</sub>
IBS	Irritable bowel syndrome	pIgR	Polymeric immunoglobulin receptor
ICP	Intracranial pressure	PLE	Protein-losing enteropathy
ICU	Intensive care unit	PLI	Pancreatic lipase immunoreactivity
IEL	Intraepithelial lymphocyte	PLN	Protein-losing nephropathy
Ig	Immunoglobulin	PPi	Proton pump inhibitor
IL	Interleukin	PSS	Portosystemic shunt
IR	Ischaemia reperfusion	PSTI	Pancreatic secretory trypsin inhibitor
KCl	Potassium chloride	PU/PD	Polyuria/polydipsia
KCS	Keratoconjunctivitis sicca	PVR	Peripheral vascular resistance
LPC	Lymphocytic-plasmacytic colitis	RAAS	Renin-angiotensin-aldosterone system
LPE	Lymphocytic-plasmacytic enteritis	RBC	Red blood cell
LPS	Lipopolysaccharide	RER	Resting energy requirement
LSA	Lymphosarcoma	RFLP	Restriction fragment length polymorphism
LSEC	Liver sinusoidal endothelial cell	RL	Resorptive lesion
LT	Heat-labile (enterotoxin)	ROS	Reactive oxygen species
MALT	Mucosal-associated lymphoid tissue	RR	Respiratory rate
MCHC	Mean corpuscular haemoglobin concentration	RT-PCR	Reverse transcriptase polymerase chain reaction
MCT	Medium chain triglycerides	SAAG	Serum-ascites-albumin gradient
MCV	Mean corpuscular volume	SAMe	S-adenosylmethionine
MHC	Major histocompatibility complex	SBA	Sheep blood agar
MMC	Migrating myoelectric complex	SCC	Squamous cell carcinoma
MMP	Matrix metalloproteinase	SCFA	Short chain fatty acid
MOF	Multiple organ failure	SI	Small intestine
MOS	Mannan oligosaccharide	SIBO	Small intestinal bacterial overgrowth
MRI	Magnetic resonance imaging	ST	Heat-stable (enterotoxin)
MVD	Microvascular dysplasia	SUBA	Serum unconjugated bile acids
MVM	Microvillus membrane	TAP	Trypsinogen activation peptide
NAC	N-acetylcysteine	TCR	T cell receptor
NK	Natural killer (cell)	TEM	Transmission electron microscopy
NO	Nitric oxide	TGF	Transforming growth factor
NPO	Nothing <i>per os</i>	Th	T helper (lymphocyte)
NSAID	Non-steroidal anti-inflammatory drug	TLI	Trypsin-like immunoreactivity
O <sub>2</sub> ER	Oxygen extraction rate	TNF	Tumour necrosis factor
PAA	Pancreatic acinar atrophy	TP	Total protein
PAF	Platelet activating factor	TPMT	Thiopurine methyl transferase
PAS	Periodic acid-Schiff (stain)	TS	Total solids
PCR	Polymerase chain reaction	UDCA	Ursodeoxycholic acid
PCV	Packed cell volume	VO <sub>2</sub>	Oxygen uptake
PDL	Periodontal ligament	VOHC	Veterinary Oral Health Council
PEG	Percutaneous endoscopic gastrostomy (tube)	WSAVA	World Small Animal Veterinary Association
PG	Prostaglandin	ZN	Ziehl-Neelsen (stain)

# Appendix 3

## Conversion tables

### Biochemistry

	SI unit	Conversion	Non-SI unit
Alanine transferase	IU / l	x 1	IU / l
Albumin	g / l	x 0.1	g / dl
Alkaline phosphatase	IU / l	x 1	IU / l
Aspartate transaminase	IU / l	x 1	IU / l
Bilirubin	μmol / l	x 0.0584	mg / dl
Calcium	mmol / l	x 4	mg / dl
Carbon dioxide (total)	mmol / l	x 1	mEq / l
Cholesterol	mmol / l	x 38.61	mg / dl
Chloride	mmol / l	x 1	mEq / l
Cortisol	nmol / l	x 0.362	ng / ml
Creatine kinase	IU / l	x 1	IU / l
Creatinine	μmol / l	x 0.0113	mg / dl
Glucose	mmol / l	x 18.02	mg / dl
Insulin	pmol / l	x 0.1394	μIU / ml
Iron	μmol / l	x 5.587	μg / dl
Magnesium	mmol / l	x 2	mEq / l
Phosphorus	mmol / l	x 3.1	mg / dl
Potassium	mmol / l	x 1	mEq / l
Sodium	mmol / l	x 1	mEq / l
Total protein	g / l	x 0.1	g / dl
Thyroxine (T4) (free)	pmol / l	x 0.0775	ng / dl
Thyroxine (T4) (total)	nmol / l	x 0.0775	μg / dl
Tri-iodothyronine (T3)	nmol / l	x 65.1	ng / dl
Triglycerides	mmol / l	x 88.5	mg / dl
Urea	mmol / l	x 2.8	mg of urea nitrogen / dl

### Temperature

	SI unit	Conversion	Conventional unit
	° C	(x 9/5) + 32	° F

### Haematology

	SI unit	Conversion	Non-SI unit
Red blood cell count	10 <sup>12</sup> / l	x 1	10 <sup>6</sup> / μl
Haemoglobin	g / l	x 0.1	g / dl
MCH	pg / cell	x 1	pg / cell
MCHC	g / l	x 0.1	g / dl
MCV	fl	x 1	μm <sup>3</sup>
Platelet count	10 <sup>9</sup> / l	x 1	10 <sup>3</sup> / μl
White blood cell count	10 <sup>9</sup> / l	x 1	10 <sup>3</sup> / μl

### Hypodermic needles

	Metric	Non-metric
External diameter	0.8 mm	21 G
	0.6 mm	23 G
	0.5 mm	25 G
	0.4 mm	27 G
Needle length	12 mm	1/2 inch
	16 mm	5/8 inch
	25 mm	1 inch
	30 mm	1 1/4 inch
	40 mm	1 1/2 inch

### Suture material sizes

Metric	USP
0.1	11/0
0.2	10/0
0.3	9/0
0.4	8/0
0.5	7/0
0.7	6/0
1	5/0
1.5	4/0
2	3/0
3	2/0
3.5	0
4	1
5	2
6	3

---

# Index

---

Page numbers in *italics* indicate illustrations

- Abdominal pain, 4, 5  
Abdominal palpation, 8  
Abdominal radiography, 22–5, 84  
Abdominal ultrasonography, 84  
  ascites, 101  
  haematemesis, 92  
  jaundice, 108  
Abdominocentesis, 100  
Abscess  
  anal sac, 218  
  pancreatic, 225, 232  
*Absidia* spp., 191  
Absorbents, 186  
Abyssinian cat, alimentary tract disorders, 3  
Acepromazine maleate, 48, 303  
Acid–base balance, 161–2  
Acid blockers (anti-ulcer drugs), 305–6  
  H<sub>2</sub> antagonists, 305–6  
  proton pump inhibitors, 306  
Acquired idiopathic megaesophagus, 140  
Acquired secondary megaesophagus, 140, 141  
ACTH stimulation test, 11  
Activated charcoal, 307  
Acute gastritis, 6, 159–60  
Adenocarcinoma  
  anal gland, 218–19  
  gastric, 172, 173  
  intestine, 200  
Adenoma, biliary tract 278  
S-Adenosylmethionine, 312, 317  
Adsorbents, 159, 298–307  
Adynamic ileus, 202  
Airedale Terrier, pancreatic tumour, 3  
Alanine aminotransferase  
  and diarrhoea, 80  
  liver disease, 246, 247  
Albendazole, 114, 300, 301, 315  
Algal colitis, 208  
Algal diarrhoea, 192  
Alkaline phosphatase  
  and diarrhoea, 80  
  liver disease, 246, 247  
Aluminium hydroxide 316  
Amikacin, 298  
Aminoglycosides, 298  
Aminopentamide, 302  
<sup>13</sup>C-Aminopyrine demethylation blood/breath test, 19  
5-Aminosalicylic acid derivatives, 308  
Ammonia, 247  
Amoxicillin, 168, 208, 276, 313  
*Amphimerus pseudofelineus*, 238  
Amphotericin B, 120, 208, 314  
Ampicillin, 116, 313  
Amprolium, 302  
Amylase, 11, 20, 81  
Anaemia, 80, 84  
  gastrointestinal haemorrhage, 93  
Anal disorders, 217  
  diagnosis 215–16  
Anal furunculosis, 219  
Anal glands, 215  
Anal prolapse, 219  
Anal sacculitis, 218  
Anal sacs, 215  
  abscess, 205, 218  
  adenocarcinoma, 218–19  
  impaction, 205, 218  
  neoplasia, 205  
Anal strictures, 219  
Anal tonsil, 52  
Anal trauma, 220  
Analgesia, 279–80  
  colonoscopy, 48  
  gastric ulceration, 163  
  pancreatitis, 231, 284–5  
  postoperative, 127, 283  
*Ancylostoma* spp., 192  
*Ancylostoma caninum*, 112, 115  
Angiography, 101  
Anogenital clefts, 217  
Anorectum, 205  
Anorexia, 4  
Antacids, 304–5  
Anthelmintics, 299–302  
Anti-5HT<sub>3</sub> agents, 303  
Antibacterials, 297–9, 313–14  
  aminoglycosides, 298  
  cephalosporins and cephamycins, 298  
  chloramphenicol, 298  
  gastric ulceration, 162  
  lincosamides, 298  
  macrolides, 298  
  metronidazole, 298  
  pancreatic insufficiency, 237  
  pancreatitis, 231  
  penicillins, 298–9  
  quinolones, 299  
  small intestinal disease, 186  
  sulphonamides, 299  
  tetracyclines, 299  
  *see also individual drugs*  
Anticholinergics, 302, 303, 307  
Anti-diarrhoeals, 306–7, 314  
  intestinal protectants and adsorbents, 306–7  
  motility modifiers, 307

- Anti-dopaminergic agents, 303  
 Anti-emetics, 162, 302–3, 314  
 Antifibrotics, 311  
 Antifungals, 299, 314  
 Antigen-presenting cells, 50  
 Antihistamines, 303  
 Anti-inflammatory drugs, 307–9, 315  
   small intestinal disease, 187  
 Anti-oxidants, 267, 312  
 Antiparasitics, 299–302, 315  
   anthelmintics, 299–302  
   anti-protozoals, 302  
 Anti-spasmodics, 307  
 Anuria, 79  
 Anus, anatomy and physiology, 214–15  
*Aonchotheca* spp., 168  
*Aonchotheca putorii*, 14  
 Apothecia, 84  
 Appetite, 4  
 Ascites, 4, 5, 79, 97–102  
   characteristics, 97  
   clinical features, 98–9  
   diagnosis, 99–100  
     abdominocentesis, 100  
     investigations, 101, 102  
     laboratory examination, 100  
   differential diagnosis, 99  
   hypoalbuminaemia, 98  
   inflammation, 98  
   leakage, 98  
   pathophysiology, 98  
   portal hypertension, 98  
   treatment, 102  
 Aspartate aminotransferase, 246, 247  
 Aspirin, 160  
 Atresia ani, 217  
 Atrophic gastritis, 169  
 Avermectins, 301  
 Azathioprine, 169, 187, 197, 252, 308, 316  
 Azithromycin, 115, 298, 315  
 Azostix test, 75  
 Azotaemia, 6  
   pancreatitis, 229  
  
*Babesia canis*, 105  
*Babesia gibsoni*, 105  
*Bacillus piliformis*, 191  
 Bacterial colitis, 207–8  
 Bacterial diarrhoea, 190–1  
 Bacterial gastritis, 167–8  
 Bacteriology, 14, 15–16  
*Bacteroides* spp., 179  
*Balantidium* spp., 206  
 Ballottement, 99  
 Balsalazide, 308  
 Barbiturates, 303  
*Bartonella henselae*, 126  
 Basenji  
   enteropathy, 165  
   lymphocytic plasmacytic enteritis, 3  
*Basidiobolus* spp., 191  
 Beagle, chronic hepatitis, 3  
 Bedlington Terrier, copper hepatotoxicosis, 3, 255–8  
 Behaviour changes, 4  
 Belgian Shepherd Dog, gastric carcinoma, 3  
 Bengal cat; alimentary tract disorders, 3  
 Benzimidazoles, 299–302  
 Benzodiazepines, 303  
 Bethanechol, 142, 303–4, 317  
  
 Bile  
   characteristics, 97  
   flow, 269–70  
   investigations, 102  
 Bile acids, 19  
   ascites, 101  
 Bile duct  
   obstruction, 273–4  
   rupture, 274  
   tumours, 265  
 Bile salts  
   binding, 89  
   deconjugation, 89  
   insufficiency, 89  
   liver disease, 247  
   loss of, 89  
   precipitation, 89  
 Biliary calculi, 228  
 Biliary diseases, 272–8  
   bile duct rupture, 274  
   canine cholangitis, 275  
   cholecystitis, 274  
   cholelithiasis, 274–5  
   double gall bladder, 278  
   extra-hepatic bile duct obstruction, 273–4  
   feline cholangitis, 275–7  
   liver flukes, 276–7  
   lymphocytic cholangitis, 276  
   neoplasia, 277–8  
   neutrophilic cholangitis, 275–6  
 Biliary dysfunction  
   clinical signs, 271  
   diagnosis, 271–2  
   pathophysiology  
     cholestasis, 270  
     jaundice *see* Jaundice  
 Biliary reflux, 228  
 Biliary stasis, 249  
 Biliary system, 269–78  
   anatomy and physiology, 269–70  
 Bilirubin  
   formation and disposal, 103  
   liver disease, 247  
   *see also* Jaundice  
 Biopsy, 12, 57–61  
   duodenal, 47  
   endoscopic, 40–1, 58  
   gastrointestinal, 57–8  
   guillotine ligature technique, 59  
   hepatic, 58–60  
   histopathological examination, 64, 65  
   intestinal, 184–5  
   laparoscopic, 60  
   liver disease, 248–9  
   pancreatic, 60–1  
   percutaneous ultrasound-guided, 58  
   post-mortem samples, 63  
   processing, 63–4  
   sample collection, 62, 63  
   skin-punch, 59–60  
   specialized examination  
     electron microscopy, 66  
     immunohistochemistry, 66, 67  
     special stains, 65–6  
   stomach, 44–5  
   surgical, 58, 59  
   *see also* Fine needle aspiration cytology  
 Bismuth, 305, 307, 314, 316  
 Bladder neoplasia, 205

## Index

- Blood  
  characteristics, 97  
  investigations, 102  
Blood count, 108  
Blood transfusion, 282  
Borborygmi, 4, 82  
Boston Terrier, vascular ring anomaly, 3  
Bouvier des Flandres, oropharyngeal dysphagia, 134, 136  
Boxer  
  histiocytic colitis, 3  
  oral neoplasia, 136  
Breath hydrogen analysis, 11, 16, 183  
Breed dispositions, 3  
  hepatic encephalopathy, 110  
  oropharyngeal disease, 136  
Budesonide, 308, 316  
Bulk laxatives, 309, 317  
Bulldog  
  anomalous coronary artery, 136  
  hiatal hernia, 136  
  vascular ring anomaly, 3  
Bunamidine, 300, 301, 315  
Bupivacaine, 285  
Buprenorphine, 48, 127, 163  
Butylscopolamine (hyoscine), 303, 314  
Butyrophenones, 303  
  
Cairn Terrier  
  microvascular dysplasia, 3  
  oesophageal fistula, 136  
  portosystemic shunt, 3  
Calcium gluconate, 284, 318  
Calcium malabsorption, 88  
Calculus (tartar), 123  
*Campylobacter* spp., 16, 31–2, 79, 113, 116–17, 155, 182  
*Campylobacter jejuni*, 79, 190, 206, 208  
*Campylobacter upsaliensis*, 190  
Campylobacteriosis, 208  
Canine cholangitis, 275  
Canine chronic hepatitis, 258–62  
  aetiology, 258–9  
  diagnosis, 259  
  pathophysiology, 259  
  treatment, 260–2  
Canine coronavirus, 189–90  
Canine coronavirus enteritis, 120  
Canine eosinophilic granulomas, 128  
Canine hepatic encephalopathy, 109  
Canine liver disease, 242, 243  
Canine liver enzymes, 246  
Canine liver structure, 243–4  
Canine parvovirus, 118–19, 188–9  
*Capillaria aerophila*, 112  
Carbohydrates  
  digestion and absorption, 177–8  
  malabsorption, 88  
Carcinoma, biliary tract, 277–8  
Carprofen, 252  
Cathartics *see* Laxatives and cathartics  
Cats *see* Feline  
Cefadroxil, 313  
Central nervous system trauma/tumours, 4, 6  
Cephalosporins and cephamycins, 298  
Cestocides, 300  
Cestodes, 192  
Challenge trials, 194  
Chest X-ray, ascites, 101  
  
Chief cells, 151  
Chlorambucil, 187, 197, 316  
Chloramphenicol, 298  
  liver disease, 252  
Chlorphenamine (chlorpheniramine), 303, 314  
Chlorpromazine, 285, 303, 314  
Cholangitis, 251  
  canine, 275  
  feline, 275–7  
  lymphocytic, 276  
  neutrophilic, 275–6  
Cholelithiasis, 274–5  
Cholestasis, 104  
  biochemical investigation, 271  
Cholinergics, 303  
Chow Chow  
  exocrine pancreatic insufficiency, 3  
  hiatal hernia, 136  
Chronic gastritis, 6, 165–70  
Chronic histiocytic ulcerative colitis, 209  
Chronic ulcerative periodontitis syndrome, 124  
Chyle, 97  
Chymotrypsin, 227  
Ciclosporin A, 128, 308, 316  
Cimetidine, 138, 252, 305–6, 316  
Circumanal glands, 215  
  adenoma, 220  
Cirrhosis, 29  
Cisapride, 142, 172, 304, 317  
Clarithromycin, 168, 298  
Clinical biochemistry, 9–10  
  ascites, 101  
  diagnostic tests, 14–15, 17–18, 19, 20–1  
  gastric disorders, 155  
  gastric ulceration, 160  
  jaundice, 108  
  small intestinal disease, 181  
*Clostridium* spp., 179, 182, 206  
*Clostridium difficile*, 15, 116, 191  
*Clostridium perfringens*, 15, 79, 80, 95, 113, 115–16, 182, 191, 208  
Coagulation factors, 247  
Coagulation tests  
  gastric disease, 155  
  jaundice, 108  
Cobalamin, 11, 17–18, 311  
  absorption, 178, 184  
  diarrhoea, 85  
  malabsorption, 88  
  *see also* Vitamin B12  
Coccidia, 192–3  
Cocker Spaniel  
  chronic hepatitis, 3  
  oral neoplasia, 136  
  pharyngeal dysphagia, 3  
Coeliotomy, 85  
Co-enzyme Q10, 128, 318  
Colchicine, 267, 311, 318  
Colestyramine (cholestyramine), 89, 307, 314  
Colitis, 6  
  acute, 207  
  bacterial, 207–8  
  chronic *see* Inflammatory bowel disease  
  clostridial, 208  
  eosinophilic, 209  
  fungal/algal, 208  
  lymphocytic–plasmacytic, 209  
  parasitic, 207  
Colitis–proctitis, 205

- Colon  
 anatomy and physiology, 203–4  
 biopsy, 58  
 diseases of, 203–12  
   acute colitis, 207  
   bacterial colitis, 207–8  
   constipation, 7, 205, 211  
   diagnostic tests, 206–7  
   fungal and algal colitis, 208  
   history and clinical signs, 205–6  
   inflammatory bowel disease, 208–11  
   intussusception, 6, 211  
   irritable bowel syndrome, 205, 211  
   neoplasia, 211–12  
   parasitic colitis, 207  
   physical examination, 206  
 immunology, 52  
 mucosa, 204  
 ultrasonography, 27  
 Colonic cleansers, 310  
 Colonic motility disorders, 211–12  
 Colonoscopy, 47–9, 85, 207  
   dyschezia and tenesmus, 95  
   findings, 48–9  
   indications, 47  
   preparation, 47–8  
   procedure, 48  
 Complement, 227  
 Computed tomography, liver, 31–2  
 Congenital megaesophagus, 140  
   breed disposition, 136  
 Congenital oral disorders, 131–2  
 Congenital vascular disorders, 263–4  
*Conidiobolus* spp., 191  
 Constipation, 7, 205, 211  
   aetiology, 212  
 Contrast radiography  
   doses and media, 25  
   gastrointestinal tract, 23–5, 84  
 Copper storage disease in Bedlington Terriers, 255–8  
 Coprophagia, 4  
 Coronavirus, 101  
   canine, 120, 189–90  
   feline, 120, 190  
 Corticosteroids, 303, 307–8  
   liver disease, 252  
   pancreatitis, 231  
 C-reactive protein, 18  
 Craniomandibular osteopathy, 136  
 Cricopharyngeal achalasia, 134–5  
 Critical care, 279–87  
   analgesia, 279–80  
   diarrhoea, 286–7  
   electrolyte status, 280–1  
   gastric dilatation and volvulus, 281–2  
   infection surveillance, 281  
   liver disease, 285–6  
   multiple organ failure, 279  
   pancreatitis, 284–5  
   perfusion, 280  
   peritonitis, 283  
   small intestinal obstruction, 282–3  
   vital signs, 280  
 Cryoprecipitate transfusion, 282  
*Cryptosporidium* spp., 16, 114–15, 192  
*Cryptosporidium parvum*, 16  
 Cyclizine, 303  
 Cyclooxygenase, 160  
 Cystic disease of liver, 277  
 Cystic mucinous hyperplasia, 277  
 Cystitis, 205  
*Cytauxzoon felis*, 105  
 Dantron (danthron), 310, 317  
 Decoppering agents, 311  
 Depression, 4  
 Dermatomyositis, 141  
 Dexamethasone, 164, 303  
 Diabetes mellitus, 4, 6  
 Diagnosis, 2  
   diagnostic plan, 9–12  
   tests, 10–12  
 Diarrhoea, 4, 78–81  
   acute, 185, 188  
   antibiotic-responsive, 194–6  
   chronic, 82–6  
     baseline laboratory tests, 84  
     diagnosis, 83–4  
     diagnostic imaging, 84  
     dietary modification, 186  
     endoscopy, 85  
     exploratory coeliotomy, 85  
     GI function tests, 84–5  
     history, 82–3  
     physical examination, 83  
   clinical signs, 79  
   critical care, 286–7  
   diagnosis, 79, 80  
   differential diagnosis, 79  
   history, 78–9  
   infectious, 188–93  
     bacterial, 190–1  
     endoparasitic, 192  
     fungal/algal/oomycete, 191–2  
     protozoal, 192–3  
     viral, 188–90  
   life-threatening, 80–1  
   pathophysiology, 78, 82  
   prognosis, 81  
   self-limiting, 80  
   treatment, 81  
 Diazepam, 252, 254  
 Dichlorophen, 300, 302, 315  
 Dichlorvos, 300, 301, 315  
*Dieffenbachia* spp., 132  
 Dietary management  
   acute gastritis, 160  
   gastric motility disorders, 171  
   inflammatory bowel disease, 209–11  
   liver disease, 260–2, 266  
   pancreatic insufficiency, 236  
   pancreatitis, 232  
   small intestinal disease, 185–6  
 Diet-related disease  
   acute gastritis, 159  
   enteropathies, 193–4  
   pancreatitis, 227  
 Diffuse eosinophilic gastritis, 169  
 Digestion and absorption, 176–8  
 Digestive enzymes, 310  
 Digital rectal examination, 215–16  
 Dimenhydrinate, 303, 314  
 Diphenhydramine, 303, 314  
 Diphenoxylate, 186, 307, 314  
*Dipylidium caninum*, 112  
*Dirofilaria immitis*, 105  
 Distemper, 141  
 Diverticula, 205  
   oesophageal 143–43

## Index

- Dobermann  
  chronic hepatitis, 3  
  hepatic encephalopathy, 110
- Docusate sodium, 309, 317
- Domperidone, 304
- Dopamine, 231, 284, 318
- Doppler ultrasonography of liver, 30–1
- Doramectin, 300, 301, 315
- Double gall bladder, 278
- Doxycycline, 302
- Drentse Patrijshond  
  polyneuropathy, 165  
  stomatocytosis, 155
- Droperidol, 303
- Drug interactions and GI disease, 4, 6
- Drug toxicity  
  and hepatitis, 251–4  
  and pancreatitis, 227–8
- Duodenal aspiration and culture, 11, 15
- Duodenal reflux, 228
- Duodenum  
  biopsy, 47  
  ultrasonography, 26–7
- Dysautonomia, 141, 142–3
- Dyschezia, 4, 82, 94–6
- Dysphagia, 4, 5–6, 69–70, 133–5
- Ehrlich reaction, 271
- Ehrlichia canis*, 105
- Elastase, 227
- Electrocardiogram, ascites, 101
- Electromyography, 134
- Electron microscopy, 66
- Emollient laxatives, 309–10
- Endodontic disease, 123
- Endoparasitic infections, 192
- Endoscopes, 35–9
- Endoscopy, 12, 34–49  
  biopsy, 39–40  
  colonoscopy, 47–9  
  enteroscopy, 45–7  
  gastric disease, 157, 160  
  gastroscopy, 42–5  
  haematemesis, 92–3  
  ileoscopy, 47  
  oesophagoscopy, 40–2  
  patient preparation, 40  
  problems during, 39  
  small intestine, 184  
  upper GI tract, 85
- Enemas, 309, 310
- Enrofloxacin, 117, 208, 313
- Entamoeba* spp., 206
- Entamoeba histolytica*, 95
- Enterobacteriaceae*, 179
- Enterocytes, 176
- Enteropathogenic bacteria, 115–18
- Enteroscopy, 42, 45–7
- Enzyme inhibitors, 232
- Enzyme replacement, 235–6
- Enzymes  
  digestive, 310  
  liver, 246  
  pancreatic, 222, 223
- Eosinophilia, 80, 84, 165  
  small intestinal disease, 181
- Eosinophilic colitis, 209
- Eosinophilic enteritis, 197–8
- Eosinophilic gastritis, 169
- Eosinophilic granuloma, 128
- Epidermal growth factor, 153
- Epiprenum aureum*, 132
- Epsiprantel, 300, 315
- Epulides, 130–1
- Erythromycin, 117, 172, 208, 298, 304, 313, 317
- Escherichia coli*, 31–2, 117–18, 153, 179  
  clinical signs of infection, 118  
  diagnosis, 118  
  diarrhoea, 191  
  enterohaemorrhagic, 118  
  enteropathogenic, 118  
  enterotoxigenic, 117–18  
  treatment, 118
- Esomeprazole, 306, 316
- Eurytrema procyonis*, 238
- Exclusion diet, 193–4
- Exocrine pancreas *see* Pancreas, Pancreatic
- Extra-hepatic bile duct obstruction, 273–4
- Extra-hepatic cholestasis, 104
- Exudates, 101
- Faecal  $\alpha_1$ -proteinase inhibitor, 18, 101
- Faeces,  
  examination and tests, 10, 206  
  culture, 16  
  dyschezia and tenesmus, 95  
  flotation, 14, 16, 84, 113  
  immunoassays, 114  
  small intestinal disease, 181–2  
  smear, 16, 84, 112, 113  
  frequency, 82  
  mucus, 82  
  occult blood, 18  
  volume, 82
- Famotidine, 138, 168, 306, 316
- Fat malabsorption, 88
- Fatty liver, 29
- Febantel, 300, 301, 315
- Feeding tubes, 288–96  
  complications, 296  
  feeding plan, 289–90  
  feeding route, 288–9  
  placement  
    gastrostomy tubes, 293–5  
    jejunostomy tubes, 295–6  
    naso-oesophageal tubes, 290–1  
    pharyngostomy and oesophagostomy tubes, 291–2
- Feline cholangitis, 275–7
- Feline chronic gingivostomatitis, 5–7, 126–8
- Feline enteric coronavirus, 120, 190
- Feline eosinophilic granuloma complex, 128
- Feline hepatic encephalopathy, 109
- Feline hepatic lipidosis, 3
- Feline immunodeficiency virus, 4, 190
- Feline infectious peritonitis, 4  
  breed disposition, 3
- Feline leukaemia virus, 4, 190
- Feline liver disease, 242, 243
- Feline liver enzymes, 246
- Feline liver structure, 243–4
- Feline parvoviral enteritis, 119–20, 189
- Fenbendazole, 114, 115, 168, 193, 198, 238, 300, 301, 302, 315
- Fentanyl, 283, 284
- Fibre, physiological effects, 204
- Fibreoptic endoscopes, 35
- Fibrosarcoma, 131

- Fine needle aspiration cytology, 249  
 biliary disease, 272
- Flatus, 4, 82
- Flexispira rappini*, 166
- Flubendazole, 300, 301, 315
- Fluid and electrolyte balance, 178  
 critical care, 280-1
- Fluid therapy, 160, 162, 164-5, 185, 283, 284, 285, 286-7
- Flunixin meglumine, 160
- Fluoroscopy, 11
- Folate, 11, 17, 311  
 absorption, 178, 184  
 diarrhoea, 85  
 malabsorption, 88
- Fox Terrier  
 anal tumours, 3  
 congenital megaesophagus, 136
- French Bulldog, hiatal hernia, 136
- Fungal colitis, 208
- Fungal gastritis, 168
- Furazolidone, 302
- Furosemide, 218
- Gall bladder  
 disease, 29-30  
 double, 278  
 ultrasound-guided biopsy, 30
- Gallstones, 274-5
- Gamma-glutamyl transferase, 246
- Gastric acid, 152
- Gastric decompression, 164
- Gastric dilatation and volvulus, 140  
 clinical signs, 163  
 critical care, 281-2  
 diagnosis, 164  
 pathogenesis, 163  
 prognosis, 165  
 treatment, 164-5
- Gastric disorders  
 acute gastritis, 159-60  
 biochemistry, 155  
 chronic gastritis, 165-7  
 clinical signs, 69, 154-7  
 coagulation testing, 155  
 delayed gastric emptying and motility, 170-2  
 diagnostic approach, 153-8  
 endoscopy, 157  
 erosion and ulceration, 160-3  
 haematology, 155  
 history, 154  
 laboratory tests for, 14-15  
 physical examination, 154  
 radiography, 156  
 ultrasonography, 156  
 urinalysis, 155  
*see also individual diseases*
- Gastric emptying, 157-8  
 delayed, 170-2
- Gastric emptying breath test, 171
- Gastric flora, 153
- Gastric foreign body, 6
- Gastric function evaluation, 157-8
- Gastric lipase, 152
- Gastric motility, 153  
 disorders, 170-2
- Gastric neoplasia, 6  
 adenocarcinoma, 172, 173  
 benign tumours, 172  
 clinical findings, 173  
 diagnosis, 173-4  
 endoscopy, 45  
 leiomyosarcoma, 172, 173  
 lymphosarcoma, 172, 173  
 treatment, 174
- Gastric secretory testing, 158-9
- Gastric ulceration, 6, 160-3
- Gastrin test, 14-15
- Gastritis  
 acute *see* Acute gastritis  
 chronic *see* Chronic gastritis
- Gastro-oesophageal intussusception, 150  
 breed disposition, 136  
 radiographic findings, 137
- Gastro-oesophageal reflux, 139  
 radiographic findings, 137
- Gastrography, 24-5
- Gastrointestinal biopsy, 57-8
- Gastrointestinal diseases,  
 clinical signs, 4  
 investigative approach, 1-12
- Gastrointestinal haemorrhage, 91-3  
 anaemia and hypovolaemia, 93  
 haematemesis, 91-3  
 haematochezia, 93  
 melaena, 93
- Gastrointestinal tract  
 contrast radiography, 23-5  
 survey abdominal radiography, 22-3  
 ultrasonography, 26-7
- Gastrosocopy, 42-5
- Gastrostomy tube, 289, 293-5
- Gentamicin, 298
- German Shepherd Dog  
 antibiotic-responsive diarrhoea, 3  
 congenital megaesophagus, 136  
 exocrine pancreatic insufficiency, 3  
 gastro-oesophageal intussusception, 136  
 inflammatory bowel disease, 3  
 myasthenia gravis-associated megaesophagus, 136  
 pancreatic acinar atrophy, 234  
 persistent right aortic arch, 136
- Giardia* spp., 16, 95, 112, 114, 155, 182, 193, 206  
 vaccination, 114
- Gingival recession, 123
- Gingivitis, 123
- Glossitis, 132
- Glucocorticoids, 237
- Glucose, 246
- Glucostix test, 75
- Glycogen storage disease, 140
- Glycopyrronium bromide, 302
- Gnathostoma* spp., 14, 168
- Golden Retriever  
 hepatic encephalopathy, 110  
 inflammatory bowel disease, 3  
 myasthenia gravis-associated megaesophagus, 136  
 oral neoplasia, 136  
 oropharyngeal dysphagia, 136
- Great Dane  
 congenital megaesophagus, 136  
 gastric volvulus, 3  
 megaesophagus, 3
- Ground glass appearance, 228
- Gut-associated lymphoid tissue (GALT), 51, 53, 279



## Index

- H<sub>2</sub> antagonists, 304, 305–6  
Haemangiosarcoma, 265  
Haematemesis, 4, 91–3  
Haematochezia, 4, 93, 205  
Haematology, 9  
  ascites, 101  
  gastric disorders, 155  
  gastric ulceration, 160  
  small intestinal disease, 180–1  
Haematuria, 94  
Haemolysis, 103–4  
Haemorrhagic gastroenteritis, 3, 187–8  
Halitosis, 4  
Haloperidol, 303  
Harmonic ultrasonography, 31  
*Helicobacter bizzozeronii*, 167  
*Helicobacter felis*, 167  
*Helicobacter heilmannii*, 167, 168  
*Helicobacter pylori*, 14, 153, 167–8  
*Helicobacter salomonis*, 167  
Hepatic encephalopathy, 109–11  
Hepatic fibrosis 250–1, 262–3  
Hepatic lipidosis, 254–5  
  clinical signs, 254  
  diagnosis, 254  
  differential diagnosis, 29  
  pathogenesis, 254  
  treatment, 255  
Hepatic neoplasia, 264–6  
Hepatic nodular hyperplasia, 266  
Hepatitis, 6  
  canine chronic, 258–62  
  drug-induced, 251–4  
Hepatobiliary disease, 19  
Hepatocellular tumours, 265  
Hepatotropic agents, 312  
Hiatal hernia, 140, 149–50  
  breed disposition, 136  
  radiographic findings, 137  
*Histoplasma* spp., 95, 113, 164, 206  
*Histoplasma capsulatum*, 120  
History, 2–7  
Hookworm, 115, 192  
Hyperbilirubinaemia *see* Jaundice  
Hypercalcaemia, 227–8  
Hypercholesterolaemia, 229  
Hyperglobulinaemia, 165  
Hyperglycaemia, 229  
Hyperkalaemia, 84  
Hyperlipoproteinaemia, 227  
Hyperparathyroidism, 4  
Hypersalivation, 69  
Hyperthyroidism, 6, 104  
Hypertriglyceridaemia, 229  
Hypertrophic gastritis, 6, 169–70  
Hypertrophic gastropathy, 159  
Hypoadrenocorticism, 4, 6, 140  
Hypoalbuminaemia, 98, 155  
Hypocalcaemia, 281  
  diarrhoea, 81  
  pancreatitis, 229  
Hypoglycaemia, 80  
Hypokalaemia, 84, 281  
Hyponatraemia, 84  
Hypoparathyroidism, 4  
Hypothyroidism, 141  
Hypovolaemia, 93  
Ibuprofen, 160  
Icterus *see* Jaundice  
Idiopathic inflammatory bowel disease, 196–8  
  eosinophilic enteritis, 197–8  
  lymphocytic–plasmacytic enteritis, 196–7  
Idiopathic megaesophagus, 140–2  
Ileoscopy, 47  
Ileum, 27  
Imaging  
  colonic disease, 207  
  gastrointestinal, 22–7  
  liver, 27–32  
  pancreas, 32–3  
  pancreatitis, 228–9  
  *see also individual techniques*  
Immunohistochemistry, 66, 67  
Immunology, 50–6  
Immunosuppressants, 307–9, 316–17  
  small intestinal disease, 187  
Infection  
  and diarrhoea, 188–93  
  endoparasitic, 192  
  monitoring in critical care, 281  
  *see also individual agents*  
Inflammatory bowel disease, 208–11  
  breed disposition, 3  
  dietary treatment, 209–11  
Intestinal adenocarcinoma, 200  
Intestinal biopsy, 184–5  
Intestinal disease, laboratory tests for, 15–19  
Intestinal function tests, 11,  
  absorption and permeability, 183–4  
  breath hydrogen analysis, 183  
  gastrointestinal protein loss, 184  
  serum folate and cobalamin, 184  
Intestinal fungal infections, 120  
Intestinal lymphoma, 199–200  
Intestinal mucosal function, 18–19, 85  
Intestinal obstruction, 6, 201–2  
  critical care, 282–3  
Intestinal parasites, 114–15  
Intestinal permeability, 85  
Intestinal pseudo-obstruction, 202  
Intra-hepatic cholestasis, 104  
Intrinsic factor, 152  
Intussusception, 6, 211  
Irish Setter  
  congenital megaesophagus, 136  
  gastric volvulus, 3  
  gluten sensitivity, 3  
  megaesophagus, 3  
Irish Wolfhound  
  hepatic encephalopathy, 110  
  megaesophagus, 3  
  portosystemic shunt, 3  
Iron malabsorption, 88  
Irritable bowel syndrome, 205, 211  
Irritant cathartics, 310, 317  
Isopropamide, 302  
*Isospora canis*, 112, 192  
*Isospora felis*, 112, 192  
*Isospora rivolta*, 192  
Itraconazole, 120, 168, 208, 314  
Ivermectin, 300, 301, 315  
Jack Russell Terrier  
  myasthenia gravis-associated megaesophagus,  
  136  
  salivary gland necrosis, 3

- Jaundice, 4, 79, 103–9, 270–1  
 biliary tract rupture, 105  
 diagnosis, 106–8  
 and diarrhoea, 81  
 differential diagnosis, 105  
 extra-hepatic cholestasis, 104–5  
 intra-hepatic cholestasis, 104  
 pathophysiology, 103  
 pre-hepatic  
 haemolysis, 103–4  
 hyperthyroidism, 104  
 treatment, 109
- Jejunostomy tube, 289, 295–6
- Jejunum, 27
- Kallikrein, 227
- Kaolin and pectin, 307, 314
- Ketamine, 283, 285
- Ketoprofen, 128, 315
- Kinins, 227
- Kupffer cells, 55
- Laboratory tests, 13–21  
 choice of, 13  
 evaluation of results, 13–14  
 exocrine pancreatic diseases, 19–21  
 gastric disorders, 14–15  
 hepatobiliary diseases, 19  
 intestinal diseases, 15–19  
*see also individual tests*
- Labrador Retriever  
 congenital megaesophagus, 136  
 hepatic encephalopathy, 110  
 oropharyngeal dysphagia, 136
- Lactobacillus* spp., 153
- Lactoferrin, 128, 318
- Lactulose, 310, 317
- Lansoprazole, 306
- Laparotomy  
 ascites, 101  
 haematemesis, 93
- Large intestine *see* Colon
- Laxatives and cathartics, 309–10, 317
- Lead toxicity, 140, 155
- Leather bottle stomach, 173
- Leiomyosarcoma  
 gastric, 172, 173  
 hepatic, 265
- Leucocytosis, 229
- Levamisole, 300, 301, 315
- Lhasa Apso, pyloric stenosis, 3
- Lidocaine, 164, 283, 285
- Lincosamides, 298  
 liver disease, 252
- Lipase, 227  
 and diarrhoea, 81
- Lipid digestion and absorption, 177
- Lipid storage disease, 140
- Liver  
 anatomy, 240–1  
 arteriogram, 101  
 biopsy, 58–60  
 enzymes, 246  
 function, 241–2  
 tests, 11  
 imaging, 27–32  
 immunology, 55  
 ultrasound-guided biopsy, 30
- Liver disease, 240–68  
 acute  
 cholangitis, 251  
 clinical signs, 245, 251  
 clinicopathological tests, 251  
 hepatic lipidosis, 29, 254–5  
 hepatitis of drug toxicity, 251–4  
 treatment, 251, 252  
 chronic  
 canine chronic hepatitis, 258–62  
 clinical signs, 245  
 congenital vascular disorders, 263–4  
 copper storage disease, 255–8  
 hepatic neoplasia, 264–6  
 lobular dissecting hepatitis, 262  
 non-cirrhotic portal hypertension, 262–3  
 non-inflammatory hepatic fibrosis, 262–3  
 portal vein hypoplasia, 262–3  
 treatment, 266–8  
 critical care, 285–6  
 differences between dogs and cats, 242–4  
 differential diagnosis, 29  
 investigation, 244–9  
 biopsy, 248–9  
 clinicopathological changes, 245–7  
 diagnostic imaging, 247–8  
 history and clinical signs, 244–5  
 radiography, 248  
 ultrasonography, 28, 29, 248  
 pathology, 249–50  
 therapeutics, 266–8, 311–12  
*see also* Hepatic
- Liver flukes, 277
- Lobular dissecting hepatitis, 262
- Loperamide, 186, 307, 314
- Lymphadenopathy, 79
- Lymphangiectasia, 198–9
- Lymphatic obstruction, 90
- Lymphocytic cholangitis, 276
- Lymphocytic–plasmacytic colitis, 209
- Lymphocytic–plasmacytic enteritis, 196–7
- Lymphocytic–plasmacytic gastritis, 6, 168–9
- Lymphopenia, 80, 84
- Lymphosarcoma, 29  
 gastric, 172, 173
- $\alpha_2$ -Macroglobulins, 20, 224
- Macrolides, 298  
 liver disease, 252
- Magnesium sulphate, 281, 317
- Magnetic resonance imaging, liver, 31
- Malabsorption, 87–90
- Malignant melanoma, 131
- Maltese dog  
 haemorrhagic gastroenteritis, 3  
 hepatic encephalopathy, 110  
 lymphangiectasia, 3
- Manx cat, constipation and faecal incontinence, 3
- Masticatory myositis, 4
- Matrix metalloproteinases, 123
- MCT oil, 317
- Mebendazole, 300, 315
- Mebeverine, 307, 318
- Meclizine, 303
- Megaesophagus  
 acquired idiopathic, 140  
 acquired secondary, 140, 141  
 breed disposition, 3, 136  
 congenital, 140

## Index

- idiopathic, 140–2
- radiographic findings, 137
- Melaena, 4, 82, 93
- Mesalazine, 308, 315
- Metabolic acidosis, 155
- Metastatic disease, 4
- Methscopolamine, 302
- Methylprednisolone, 127–8, 303, 316
- Metoclopramide, 119, 142, 172, 285, 303, 304, 314, 317
- Metronidazole, 114, 116, 168, 193, 196, 298, 302, 313, 315
- Microglossia, 132
- Microvascular dysplasia, 264
- Milbemycins, 300, 301, 315
- Miniature Schnauzer
  - congenital megaesophagus, 136
  - haemorrhagic gastroenteritis, 3
  - hepatic encephalopathy, 110
  - pancreatitis, 3, 227
- Misoprostol, 163, 316
- Montmorillonite, 307
- Mortierella* spp., 191
- Motility disorders, 179
- Motility modifiers, 186, 307
- Motion sickness, 4, 6
- Moxidectin, 300, 301, 315
- Mucocele, 277
- Mucosal (cyto)-protectants, 304–5
- Mucosal malabsorption, 90
- Mucous neck cells, 151
- Multiple organ failure, 279
- Myasthenia gravis, 4
  - megaesophagus, 140
  - breed disposition, 136
- Mycobacterium* spp., 191
- Mycophenolate mofetil, 308
- Mycoplasma canis*, 105
- Mycoplasma haemofelis*, 105
  
- Nasal discharge, 79
- Naso-oesophageal tube, 289, 290–1
- Nausea, 4
  - see also Vomiting
- Nematodes, 115, 192
- Neomycin, 298, 313
- Neoplasia
  - anal, 3
  - anal sac, 205
  - biliary system, 277–8
  - bladder, 205
  - central nervous system, 4, 6
  - colon, 211–12
  - gastric, 3, 6, 45
  - liver, 264–6
  - oesophageal, 137, 145–6
  - oral, 130–1, 136
  - pancreatic, 3, 237–8
  - prostate, 205
  - small intestine, 199–201
  - urethra, 205
  - vagina, 205
- Neuroendocrine tumours, 265
- Neuropathy, 140
- Neutropenia, 80
- Neutrophilia, 80, 84
- Neutrophilic cholangitis, 275–6
- Newfoundland, congenital megaesophagus, 136
- Niclosamide, 300, 302, 315
- Nitazoxamide, 115, 302
- Nitroscanate, 300, 301, 315
- Nizatidine, 172, 306, 316, 317
- Nodular pancreatic hyperplasia, 239
- Non-cirrhotic portal hypertension, 262–3
- Non-inflammatory hepatic fibrosis, 262–3
- Non-steroidal anti-inflammatory drugs, 159–60
- Norwegian Lundehund, protein-losing enteropathy and lymphangiectasia, 3
- Nuclear scintigraphy, 170
- Nutritional supplements, 310–11, 312
  - anti-oxidants, 312
  - digestive enzymes, 310
  - medium chain triglycerides, 310
  - prebiotics, 311
  - probiotics, 311
  - vitamins, 311, 312
  
- Octreotide, 163, 316
- Oesophageal disease, 69
- Oesophageal diverticulum, 137, 143–4
- Oesophageal fistula, 136, 137, 139–40
- Oesophageal foreign body, 137, 146
- Oesophageal neoplasia, 137, 145–6
- Oesophageal stricture, 137, 144–5
- Oesophagitis, 137, 138–9, 141
- Oesophagography, 23–4
- Oesophagoscopy, 40–2
- Oesophagostomy tube, 289, 291–2
- Oesophagus,
  - anatomy and physiology, 135
  - diagnostic approach, 136–8
  - hypomotility disorders, 140–4
  - inflammatory diseases, 138–40
  - obstruction, 144–9
  - pathophysiology, 136
  - ultrasonography, 27
- Old English Sheepdog, hepatic encephalopathy, 110
- Oliguria, 79
- Ollulanus* spp., 165, 167
- Ollulanus tricuspis*, 14, 168
- Olsalazine, 308, 315
- Omeprazole, 138, 162, 306, 316
- Ondansetron, 303, 314
- Opioids, 307
- Oral cavity disorders, 122–32
  - canine eosinophilic granulomas, 128
  - chronic gingivostomatitis in cats, 126–8
  - congenital defects, 131–2
  - enlarged salivary glands, 132
  - feline eosinophilic granuloma complex oral lesions, 128
  - lingual lesions, 132
  - periodontal disease, 122–5
  - resorptive lesions, 129–30
  - trauma, 130
  - tumours, 130–1
  - ulcerative eosinophilic stomatitis, 128
- Oral cavity immunology, 50
- Oral eosinophilic granuloma, 136
- Oral neoplasia, 136
- Organophosphate toxicity, 141
- Oronasal fistula, 124
- Oropharyngeal disease, 69
- Oropharyngeal dysphagia, 133–4
  - breed disposition, 136
- Oropharynx, 27
- Osmotic diarrhoea, 179

- Oxantel, 300, 301  
 Oxibendazole, 300, 315  
 Oxyglobin transfusion, 282  
 Oxytetracycline, 313
- Packed red cell transfusion, 282
- Pancreas,  
 anatomy, 222–3  
 biopsy, 60–1  
 defences against autodigestion, 223–4  
 digestive enzymes *see* Pancreatic enzymes  
 diseases of  
 exocrine pancreatic insufficiency, 233–7  
 laboratory tests, 19–21  
 neoplasia, 237–8  
 nodular hyperplasia, 239  
 pancreatic bladder, 239  
 pancreatitis, 225–32  
 parasites, 238  
 function, 84–5  
 imaging, 32–3  
 regulation of secretion, 224–5  
 secretory proteins, 222
- Pancreatic abscess, 225, 232  
 Pancreatic bladder, 239  
 Pancreatic duct, 222  
 Pancreatic enzymes, 222, 223  
 ascites, 101  
 inactivation of, 88–9  
 in pancreatitis, 227
- Pancreatic extract, 235, 317  
 Pancreatic insufficiency, 88–9, 233–7  
 aetiology, 233  
 diagnosis, 234–5  
 clinical signs, 234–5  
 history, 234  
 laboratory tests, 235  
 pathophysiology, 233–4  
 nutritional status, 234  
 pancreatic regulatory peptides and glucose intolerance, 234  
 small intestinal microflora, 233  
 small intestinal mucosa, 233  
 prognosis, 237  
 treatment, 235–7  
 antibiotic therapy, 237  
 dietary modification, 236  
 enzyme replacement, 235–6  
 glucocorticoid therapy, 237  
 vitamin supplementation, 236
- Pancreatic ischaemia, 228  
 Pancreatic lipase immunoreactivity, 21, 230  
 Pancreatic pseudocysts, 232  
 Pancreatic secretory trypsin inhibitor, 224  
 Pancreatic trauma, 228  
 Pancreatitis, 6, 225–32  
 acute treatment, 231–2  
 aetiology, 227–8  
 classification, 225  
 complications, 232  
 critical care, 284–5  
 diagnosis,  
 history and clinical signs, 228  
 imaging, 228–9  
 laboratory tests, 229–31  
 long-term therapy, 232  
 pathophysiology, 226–7  
 prognosis, 232
- Panhypoproteinaemia, 84, 165
- Pantoprazole, 306, 316  
 Paraffin, 309, 317  
*Paragonimus*, 112  
 Parasitic gastritis, 168  
 Parasitology, 14, 16–17  
 Parietal cells, 151  
 Paromomycin, 302  
 Partial thromboplastin time, 81  
 Pellicle, 123  
 D-Penicillamine, 312, 318  
 Penicillins, 298–9  
*Pentatrachomonas hominis*, 207  
 Pepsin, 152  
 Pepsinogen, 152  
 Pepsinogen test, 15  
 Percutaneous ultrasound-guided biopsy, 58  
 Perfusion indices, 280  
 Perianal fistula, 205, 219  
 Perianal hernia, 205, 220–1  
 Perineal disease, 215–16  
 Perineal swelling, 221  
 Perineal trauma, 220  
 Perineum, anatomy and physiology, 213–14  
 Periodontal disease, 122–5  
 Periodontal pockets, 124  
 Periodontitis, 123  
 Peritonitis, 6  
 critical care, 283  
 Permeability diarrhoea, 179  
 Persian cat, alimentary tract disease, 3  
 Peyer's patches, 51  
 Pezzer catheter, 293–5  
 Pharyngostomy tube, 291–2  
 Pharynx,  
 anatomy and physiology, 133  
 diagnostic imaging, 133  
 disorders,  
 cricopharyngeal achalasia, 134–5  
 oropharyngeal dysphagia, 133–4  
 history, 133  
 laboratory tests, 133  
 physical examination, 133
- Phenobarbital, 252, 253  
 Phenothiazines, 303  
*Philodendron* spp., 132  
 Phospholipase A2, 227  
*Physaloptera* spp., 14, 165, 168  
*Physaloptera rara*, 168  
 Pica, 4  
 Piperazine, 115, 300, 301, 315  
 Plaque, 123  
 Pneumocolonography, 25  
 Poisoning, 4, 6  
 Pollakiuria, 94  
 Polydipsia, 4  
 Polymyositis/polymyopathy, 140  
 Polyphagia, 4  
 Polyuria, 4  
 Poodle, hepatic encephalopathy, 3  
 Portal hypertension, 98, 249–51  
 Portal vein hypoplasia, 262–3  
 Portosystemic shunts, 250  
 congenital, 263–4  
 Portovenography, 101  
 Postmucosal malabsorption, 90  
 Praziquantel, 239, 300, 302, 315  
 Prebiotics, 186–7, 311  
 Prednisolone, 128, 165, 169, 197, 199, 219, 237, 275,  
 307–8, 316

## Index

- Primary exocrine pancreatic failure, 88  
Primidone, hepatotoxicity, 252  
Probiotics, 186–7, 311  
Problem list, 9  
Problem-solving approach, 1–12  
Prochlorperazine, 303, 314  
Proctoscopy, 216  
Prokinetics, 171–2, 303–4, 317  
Promazine, 303  
Promethazine, 303, 314  
Propantheline bromide, 302  
Prostaglandins, 304  
Prostate  
    benign hypertrophy, 205  
    neoplasia, 205  
Prostatitis, 205  
Protectants, 159, 162, 186  
Protein digestion and absorption, 176–7  
Protein malabsorption, 88  
     $\alpha_1$ -Proteinase inhibitor, 224  
     $\alpha_1$ -Proteinase inhibitor–trypsin complexes, 20  
Protein-losing enteropathy, 85, 181  
    breed disposition, 3  
Proteinuria, 81  
*Proteus* spp., 153  
*Protheca* spp., 208  
Prothrombin time, 81  
Proton pump inhibitors, 306  
*Prototheca* spp., 113  
Protozoal cysts, 112  
Protozoal infections, 114–15, 192–3  
*Providencia alcalifaciens*, 191  
Pseudocoprostasis, 218  
Psyllium, 317  
Ptyalism, 4, 5  
Pulp, 123  
Pyloric stenosis, 6  
Pyometra, 4, 6  
Pyrantel, 115, 168, 300, 301, 315  
Pyrexia, 79  
Pyridostigmine, 304, 317  
Pythiosis, 168, 208  
*Pythium* spp., 166  
*Pythium insidiosum*, 165, 167, 168  
  
Quinacrine, 302  
Quinolones, 299  
  
Rabeprazole, 306, 316  
Radiography, 11  
    abdominal  
        contrast, 23–5  
        survey, 22–3  
    anal/perineal disease, 216  
    gastric disorders, 156  
    gastric motility disorders, 171  
    gastric ulceration, 160  
    liver and liver disease, 27–32, 28, 248  
    oesophageal disorders, 136  
    pancreas, 32  
    resorptive lesions, 129–30  
    small intestinal disease, 182  
Ranitidine, 138, 172, 306, 316, 317  
Rectal stricture, 205  
Regurgitation, 6, 71–2  
Renal failure, 4  
Resorptive oral lesions, 129–30  
    aetiology, 129  
    clinical features, 129  
    diagnosis, 129–30  
    treatment, 130  
Resting energy requirement, 289–90  
*Rhizopus* spp., 191  
Rottweiler, alimentary tract diseases, 3  
Rough Collie  
    exocrine pancreatic insufficiency, 3  
    gastric tumour, 3  
    pancreatic acinar atrophy, 234  
  
Saline purgatives, 310  
Salivary gland enlargement, 132  
Salivation, 4, 5  
*Salmonella* spp., 16, 79, 95, 117, 155, 182, 206  
    diarrhoea, 190–1  
Salmonellosis, 207–8  
Scintigraphy  
    biliary disease, 272  
    liver, 31–2  
Scottish Terrier, chronic hepatitis, 3  
Secretory diarrhoea, 179  
Selamectin, 300, 301, 315  
Serum amylase, 11, 20, 81  
Serum globulins, 101  
Serum lipase, 11, 20  
Serum trypsin-like immunoreactivity test, 11  
Serum unconjugated bile acids, 16  
Shar Pei  
    congenital megaesophagus, 136  
    food intolerance, 3  
    hiatal hernia, 136  
    inflammatory bowel disease, 3  
Shih Tzu, alimentary tract diseases, 3  
Short bowel syndrome, 202  
Sialadenitis, 132  
Sialadenosis, 132  
Sialocele, 132  
Siamese cat, alimentary tract disorders, 3  
Siberian Husky, oral eosinophilic granuloma, 136  
Small intestinal bacterial overgrowth (SIBO), 15–16,  
    85, 89, 159, 179, 194–6  
Small intestine  
    disease, 176–202  
        acute, 180  
        adynamic ileus and intestinal pseudo-  
            obstruction, 202  
        biochemistry, 181  
        biopsy, 184–5  
        chronic, 180  
        clinical signs, 180  
        diagnosis, 179–85  
        diagnostic imaging, 182–3  
        diarrhoea *see* Diarrhoea  
        diet-related enteropathies, 193–4  
        faecal analysis, 181–2  
        haematology, 180–1  
        haemorrhagic gastroenteritis, 187–8  
        idiopathic inflammatory bowel disease, 196–8  
        intestinal function tests, 183–4  
        intestinal obstruction, 201–2  
        lymphangiectasia, 198–9  
        neoplasia, 199–201  
        pathophysiology, 179  
        physical examination, 180  
        problem list and diagnostic plan, 180  
        serology, 181  
        short bowel syndrome, 202  
        treatment, 185–7  
        urinalysis, 181

- immunology, 51  
 structure and function, 176-9  
 digestion and absorption of food, 176-8  
 fluids and electrolytes, 178  
 microflora, 179  
 motility, 179  
 vitamins and minerals, 178
- Smooth Fox Terrier, myasthenia gravis-associated  
 megaesophagus, 136
- Soft Coated Wheaten Terrier, protein-losing  
 enteropathy, 3
- Somatostatin, 153, 231
- Space of Disse, 55
- Spathiphyllum*, 132
- Sphinx cat, inflammatory bowel disease, 3
- Spiramycin, 298
- Spirocerca* spp., 168
- Spirocerca lupi*, 14
- Spironolactone, 318
- Springer Spaniel, myasthenia gravis-associated  
 megaesophagus, 136
- Squamous cell carcinoma, oral 131
- Staphylococcus* spp., 179
- Steatorrhoea, 82
- Steroid hepatopathy diagnosis, 29
- Steroids  
 liver disease, 267  
 see also Corticosteroids, Glucocorticoids
- Stomach, 151-75  
 biopsy, 44-5  
 digestion and assimilation of nutrients, 151-2  
 diseases of see Gastric disorders  
 gastric flora, 153  
 gastric motility, 153  
 immunology, 50, 51  
 regulation of acid secretion, 152-3  
 structure and function, 151-3  
 ultrasonography, 27  
 see also Gastric
- Stomatitis, 132
- Stomatocytosis, 155
- Streptococcus* spp., 153, 179
- Strongyloides stercoralis*, 112
- Sucralfate, 138, 163, 305, 316
- Sucrose permeability test, 15
- Sulfadimethoxine, 192, 315
- Sulfasalazine, 308, 315
- Sulphonamides, 299, 302  
 liver disease, 252, 253
- Survey radiography, 10  
 abdomen, 22-3, 84  
 liver, 28
- Sylmarin, 312, 318
- Systemic diseases, 4
- Systemic lupus erythematosus, 140
- Tacrolimus, 308, 317
- Taenia* spp., 112
- Tapeworms, 192
- Tenesmus, 4, 82, 94-6, 205
- Terbinafine, 168, 314
- Tetracycline, 208, 252, 299, 314
- Tetramine, 312
- Therapeutics, 297-312  
 acid blockers (anti-ulcer drugs), 305-6  
 antibacterials, 297-9  
 anti-diarrhoeals, 306-7  
 anti-emetics, 302-3  
 antifungals, 299  
 antiparasitics, 299-302  
 immunosuppressive and antiinflammatory agents,  
 307-9  
 laxatives and cathartics, 309-10  
 liver disease, 311-12  
 mucosal (cyto)-protectants, 304-5  
 nutritional supplements, 310-11  
 prokinetics, 303-4
- Thirst, 4
- Thymoma, 141
- Tiabendazole, 300, 315
- Tobramycin, 298
- Tocopherol see Vitamin E
- Tongue lesions, 132
- Tooth brushing, 125
- Torovirus, 190
- Total protein, 80
- Toxascaris leonina*, 112, 115, 192
- Toxocara canis*, 112, 115, 192
- Toxocara cati*, 112, 115, 192
- Toxoplasma gondii*, 112
- Transudate, 101
- Trauma  
 anal, 220  
 central nervous system, 4, 6  
 oral, 130  
 pancreatic, 228
- Triaditis, 63
- Triamcinolone, 128, 145, 317
- Trichomonas* spp., 206
- Trichuris vulpis*, 95, 112, 115, 192, 206, 207
- Trientine, 318
- Tritrichomonas foetus*, 16, 17, 113, 115
- Trimethoprim/sulphonamide, 192, 208, 314, 315
- Trypsin, 225, 226, 227
- Trypsin-like immunoreactivity, 20-1, 230
- Trypsinogen, 225
- Trypsinogen activation peptide, 19-20
- Tumours see Neoplasia
- Tylosin, 116, 191, 196, 208, 298, 302, 314
- Ulcerative colitis, 49
- Ulcerative eosinophilic stomatitis, 128
- Ulcers, 160-3
- Ultrasonography, 12  
 abdominal, 84  
 anal/perineal disease, 216  
 biliary disease, 271-2  
 cardiac, in ascites, 101  
 colon, 27  
 Doppler, 30-1  
 duodenum, 26-7  
 gall bladder disease, 29-30  
 gastric disorders, 156  
 gastric ulceration, 160  
 gastrointestinal tract, 26-7  
 harmonic, 31  
 hepatopathy, 28-9  
 ileum, 27  
 jejunum, 27  
 liver and liver disease, 29-31, 248  
 oropharyngeal and oesophageal, 26, 27  
 pancreas, 32-3, 229  
 small intestinal disease, 182-3  
 stomach, 26
- Uncinaria* spp., 115
- Uncinaria stenocephala*, 112, 192
- Uraemia, 6
- Urea, 246

## Index

- Urethral neoplasia, 205  
Urgency, 82  
Urinalysis, 10  
  ascites, 101  
  gastric disorders, 155  
  gastric ulceration, 160  
  jaundice, 108  
  small intestinal disease, 181  
Urinary calculi, 205  
Urine  
  characteristics, 97  
  investigations, 102  
Urine protein immunoreactivity analysis, 101  
Ursodeoxycholic acid, 267, 275, 311, 318
- Vaginal neoplasia, 205  
Vascular ring anomaly, 146-7  
  breed disposition, 3  
  radiographic findings, 137  
Vegetable oils, 310  
Vestibular disease, 4, 6  
Video endoscopes, 35  
Viral diarrhoea, 188-90  
Viral infections,  
  canine coronavirus enteritis, 120  
  canine parvovirus, 118-19  
  feline enteric coronavirus, 120  
  feline parvoviral enteritis, 119-20  
Vital signs, 280  
Vitamin A, 311  
  malabsorption, 88  
Vitamin B12, 152, 236, 318  
  (see also Cobalamin)  
Vitamin D, 311  
  malabsorption, 88  
Vitamin E, 236, 311, 312, 318  
  malabsorption, 88  
Vitamin K, 311  
  malabsorption, 88
- Vitamin K1, 286, 318  
Vitamins, 311  
  pancreatic insufficiency, 236  
Volvulus, 140  
Vomiting, 4, 6, 73-7, 82, 154  
  clinical features, 73, 74  
  diagnosis, 74, 75-7  
  differential diagnosis, 74  
  gastric disorders, 69  
  history, 73  
  initiation of, 73  
  oesophageal disease, 69  
  oropharyngeal disease, 69  
  physical examination, 73-4  
  treatment, 77  
Vomitus, microscopic examination, 14
- Weight loss, 4, 82  
Weimaraner, oral neoplasia, 136  
West Highland White Terrier  
  chronic hepatopathy, 3  
  craniomandibular osteopathy, 136  
Whole blood transfusion, 282  
Wirsung's duct, 222
- Yersinia* spp., 16  
*Yersinia enterocolitica*, 191, 208  
*Yersinia pseudotuberculosis*, 191  
Yorkshire Terrier  
  hepatic encephalopathy, 110  
  lymphangiectasia, 3  
  portosystemic shunt, 3  
  protein-losing enteropathy, 3
- Zinc  
  drugs, 267, 312, 318  
  malabsorption, 88  
  toxicosis, 228  
Zollinger-Ellison syndrome, 77, 87, 159  
Zygomycosis, 208  
Zymogen, 225
-

# BSAVA Manual of Canine and Feline Gastroenterology

## Second edition

Edited by Edward J. Hall, James W. Simpson and David A. Williams

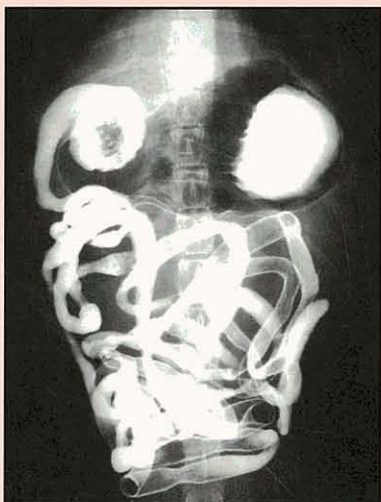Building on the success of the previous edition, the *BSAVA Manual of Canine and Feline Gastroenterology, 2<sup>nd</sup> edition* incorporates not only the new information available since the original publication but also additional chapters on diagnostic techniques and presenting complaints.



Part 1 considers diagnostic techniques, with chapters on the approach to a gastrointestinal case, laboratory evaluation, imaging, endoscopy, immunology and

biopsy. The completely new chapter on imaging of the gastrointestinal tract, liver and pancreas covers in detail the modalities most frequently employed in small animal practice, namely radiography and ultrasonography, whilst also briefly discussing more advanced techniques of Doppler and harmonic ultrasonography, scintigraphy, CT and MRI.

The short chapters in Part 2 provide a practical approach to investigating presenting complaints: dysphagia and regurgitation; vomiting; acute and chronic diarrhoea; malabsorption; GI haemorrhage; dyschezia and tenesmus; jaundice; hepatic encephalopathy and infectious diseases. All follow the same basic format: outlining the clinical features, ranking the differential diagnoses in order of importance, and providing step-by-step algorithms for diagnosis.



The more traditional organ-based systems approach in Part 3 has been expanded from the previous edition to include chapters on disorders of the oral cavity, perineum and anus, and biliary system. Each chapter is presented in a similar style, starting with a brief description of relevant anatomy and physiology, then detailing diagnostic tests, and concluding with a discussion of the disorders that can be encountered, including their treatment.

The completely new final part contains chapters devoted to critical care, assisted feeding techniques, and an overview of therapeutics.

The chapters, written by a host of international authors, all experts in their field, are accompanied throughout by full colour illustrations.

### CONTENTS

Approach to the investigation of gastrointestinal diseases; Laboratory evaluation of gastrointestinal disease; Imaging of the gastrointestinal tract, liver and pancreas; Gastrointestinal endoscopy; Gastrointestinal immunology; Biopsy: sample collection; Biopsy: handling, processing and interpretation; Dysphagia and regurgitation; Acute and chronic vomiting; Acute diarrhoea; Chronic diarrhoea; Malabsorption; Gastrointestinal haemorrhage; Dyschezia and tenesmus; Ascites; Jaundice; Hepatic encephalopathy; Infectious and parasitic diseases; Disorders of the oral cavity; Disorders of the pharynx and oesophagus; Diseases of the stomach; Diseases of the small intestine; Diseases of the colon and rectum; Disorders of the perineum and anus; Diseases of the exocrine pancreas; Diseases of the liver; Diseases of the biliary system; Critical care of patients with gastrointestinal disease; Feeding tubes; Therapeutics; Appendices; Index.



BIBLIOTECA GERAL

1084936



ISBN 0-905214-73-0



9 780905 214733